ISSN 2689-7164 (online)

Artificial Intelligence in *Gastrointestinal Endoscopy*

Artif Intell Gastrointest Endosc 2020 July 28; 1(1): 1-27

Published by Baishideng Publishing Group Inc

AIGE

Artificial Intelligence in Gastrointestinal Endoscopy

Contents

Bimonthly Volume 1 Number 1 July 28, 2020

EDITORIAL

MINIREVIEWS

Contents

ABOUT COVER

Editorial board member of *Artificial Intelligence in Gastrointestinal Endoscopy*, Professor Yirupaiahgari KS Viswanath is an upper gastrointestinal (GI) Consultant Surgeon and Visiting Chair at Teesside University, who works at James Cook University Hospital over 20 years. He is the Programme Director for MCh postgraduate surgical specialties works in collaboration with Teesside University. His research interests mainly focused in upper GI cancer, acid reflux and Barrett's. He has supervised PhD, MSc MCh and MPhil students. He oversees dissertations every year and presents and publishes articles in GI surgery. Last 2 years, he have put efforts in developing a team of clinical and data scientists in artificial Intelligence in upper GI endoscopy. He remains active in clinical, radiological and lab-based research. His other noteworthy interests are on cancer immunology and molecular biology. He has received national and international accolades over years.

AIMS AND SCOPE

The primary aim of *Artificial Intelligence in Gastrointestinal Endoscopy* (*AIGE*, *Artif Intell Gastrointest Endosc*) is to provide scholars and readers from various fields of artificial intelligence in gastrointestinal endoscopy with a platform to publish high-quality basic and clinical research articles and communicate their research findings online.

AIGE mainly publishes articles reporting research results obtained in the field of artificial intelligence in gastrointestinal endoscopy and covering a wide range of topics, including artificial intelligence in capsule endoscopy, colonoscopy, double-balloon enteroscopy, duodenoscopy, endoscopic retrograde cholangiopancreatography, endosonography, esophagoscopy, gastrointestinal endoscopy, gastroscopy, laparoscopy, natural orifice endoscopic surgery, proctoscopy, and sigmoidoscopy.

INDEXING/ABSTRACTING

There is currently no indexing.

RESPONSIBLE EDITORS FOR THIS ISSUE

Electronic Editor: *Jia-Hui Li*; **Production Department Director:** *Xiang Li*; **Editorial Office Director:** *Jin-Lei Wang*.

NAME OF JOURNAL
Artificial Intelligence in Gastrointestinal Endoscopy

ISSN
ISSN 2689-7164 (online)

LAUNCH DATE
June 28, 2020

FREQUENCY
Bimonthly

EDITORS-IN-CHIEF
Fatih Altintoprak

EDITORIAL BOARD MEMBERS
https://www.wjgnet.com/2689-7164/editorialboard.htm

PUBLICATION DATE
July 28, 2020

COPYRIGHT
© 2020 Baishideng Publishing Group Inc

INSTRUCTIONS TO AUTHORS
https://www.wjgnet.com/bpg/gerinfo/204

GUIDELINES FOR ETHICS DOCUMENTS
https://www.wjgnet.com/bpg/GerInfo/287

GUIDELINES FOR NON-NATIVE SPEAKERS OF ENGLISH
https://www.wjgnet.com/bpg/gerinfo/240

PUBLICATION ETHICS
https://www.wjgnet.com/bpg/GerInfo/288

PUBLICATION MISCONDUCT
https://www.wjgnet.com/bpg/gerinfo/208

ARTICLE PROCESSING CHARGE
https://www.wjgnet.com/bpg/gerinfo/242

STEPS FOR SUBMITTING MANUSCRIPTS
https://www.wjgnet.com/bpg/GerInfo/239

ONLINE SUBMISSION
https://www.f6publishing.com

Artificial Intelligence in Gastrointestinal Endoscopy

Submit a Manuscript: https://www.f6publishing.com

Artif Intell Gastrointest Endosc 2020 July 28; 1(1): 1-5

DOI: 10.37126/aige.v1.i1.1

ISSN 2689-7164 (online)

EDITORIAL

Application of convolutional neural networks for computer-aided detection and diagnosis in gastrointestinal pathology: A simplified exposition for an endoscopist

Yirupaiahgari KS Viswanath, Sagar Vaze, Richie Bird

ORCID number: Yirupaiahgari KS Viswanath 0000-0003-3880-1172; Sagar Vaze 0000-0003-2920-9345; Richie Bird 0000-0002-4560-708X.

Author contributions: Vaze S wrote the convolutional neural network (CNN) section, expert comments, diagrams, proofreading; Bird R expert comments, appraised the process; Viswanath YKS contributed the conceptualization, writing and proofreading of the paper.

Conflict-of-interest statement: Nothing to disclose.

Manuscript source: Invited

Yirupaiahgari KS Viswanath, Department of Upper GI Laparoscopic and Endoscopic Unit, James Cook University Hospital, Cleveland TS43BW, United Kingdom

Sagar Vaze, University of Oxford, Oxford OX1 2JD, United Kingdom

Richie Bird, Data Science, King's College, London E14 0ST, United Kingdom

Corresponding author: Yirupaiahgari KS Viswanath, CCST, FRCS, FRCS (Gen Surg), MBBS, Professor, Upper GI Laparoscopic and Endoscopic Unit, James Cook University Hospital, Marton Road, Middlesbrough, Cleveland TS43BW, United Kingdom. keyhole1234@gmail.com

Abstract

The application of artificial intelligence (AI), especially machine learning or deep learning (DL), is advancing at a rapid pace. The need for increased accuracy at endoscopic visualisation of the gastrointestinal (GI) tract is also growing. Convolutional neural networks (CNNs) are one such model of DL, which have been used for endoscopic image analysis, whereby computer-aided detection and diagnosis of GI pathology can be carried out with increased scrupulousness. In this article, we briefly focus on the framework of the utilisation of CNNs in GI endoscopy along with a short review of a few published AI-based articles in the last 4 years.

Key words: Convolutional neural network; Gastrointestinal endoscopy; Artificial intelligence; Deep learning; Machine learning

Core tip: The convolutional neural network (CNN), a deep learning model, has gained immense success in endoscopy image analysis, with its application to diagnose and detect gastrointestinal (GI) pathology at endoscopy. This article shares a basic framework of the utilisation of CNNs in GI endoscopy, along with a concise review of a few published AI-based endoscopy articles in the last 4 years.

manuscript

Received: June 1, 2020
Peer-review started: June 1, 2020
First decision: June 18, 2020
Revised: July 14, 2020
Accepted: July 17, 2020
Article in press: July 17, 2020
Published online: July 28, 2020

P-Reviewer: Hammoud CM, Inamdar S, Pang S, Kim GH
S-Editor: Wang JL
L-Editor: A
E-Editor: Li JH

Citation: Viswanath YK, Vaze S, Bird R. Application of convolutional neural networks for computer-aided detection and diagnosis in gastrointestinal pathology: A simplified exposition for an endoscopist. *Artif Intell Gastrointest Endosc* 2020; 1(1): 1-5
URL: https://www.wjgnet.com/2689-7164/full/v1/i1/1.htm
DOI: https://dx.doi.org/10.37126/aige.v1.i1.1

INTRODUCTION

The role of artificial intelligence (AI), specifically machine learning (ML) or deep learning (DL), in medicine is evolving and studies have surfaced beholding its advantages in performing gastrointestinal (GI) endoscopy[1,2]. The pace of AI utilisation in medicine will further increase, especially in the coming years as a "new normal" is established post-coronavirus disease 2019 (COVID-19). Already, there is evidence of the advantages of AI utilisation in the diagnosis of various pathologies such as colonic polyps, esophagitis and GI cancer. It is also a fact that the translation of gained experience and skills over many years to a novice trainee is not easy and bound with initial problems, and raises errors whether in diagnosis or decision making. We believe that ML could play a resolute role in passing on this knowledge and facilitate better patient management.

Though computer programmes mimicking human cognitive functions have existed since the 1950s, it is only in the 1980s onwards that ML, followed by DL, applications have been studied in medical fields[3]. The future is looking likely to be increasingly automated and therefore driving AI research safely and fairly, with increased accuracy and interpretability, would reduce the dependency on skilled professionals, while concurrently aiding patient management at an early stage. There is increasing evidence that these results in a reduction in time-to-treatment and facilitate early patient management. However, AI in gastroenterology comes with some assurance as well as drawbacks.

Recent advances in AI as applied to medicine have largely come through ML, in which mathematical computer algorithms learn to interpret complex patterns in data. Specifically, DL, a subclass of ML originally inspired by the brain, uses layers of artificial neurons to form a "neural network" which maps inputs to an output. Typically, these networks are "trained" on large amounts of manually labelled data, in which example input-output pairs are provided to the model to enable it to "learn". Of most interest to us in this article are the DL models which have achieved great success in image analysis tasks, namely convolutional neural networks (CNNs)[1-3]. We briefly focus on a high-level outline of the utilisation of CNNs in a simplified form to enable an endoscopist to cognize, along with a concise review of a few published GI endoscopy articles on AI in the last 4 years.

CONVOLUTIONAL NEURAL NETWORKS

CNN's are a type of DL model, commonly used to analyse endoscopy images.

Figure 1 illustrates the CNN training method where ultrasound scan images have been used, highlighting the salient steps of the DL framework. At a high level, the CNN is a parametric model which maps an input - in this case, an image - to an output. The output can take a variety of forms: from a classification (a label of the image containing or not containing a tumour); to a detection (a bounding box around the tumour); to a segmentation (specification of exactly which pixels in the image contain the tumour)[4]. The model is "trained" by giving the model multiple (usually, thousands) of examples of input-output pairs.

This training (Figure 2) involves, given an input image, computing the error between the model's prediction and the manual label, with the parameters of the model then adjusted to reduce this error. This process is repeated numerous times until the performance of the model is acceptable, with its final accuracy computed on a held-out "test set" of manually labelled images which it has not seen during training. Figure 1 illustrates the CNN framework, with the process rephrased in words in Figure 3. Figure 2 expands upon the training process specifically, in which the CNN parameters are iteratively updated so that its predictions are in closer alignment with the manual expert annotations. We highlight that the process involves partitioning the dataset into "training" and "testing" data, with the final model evaluation done on the

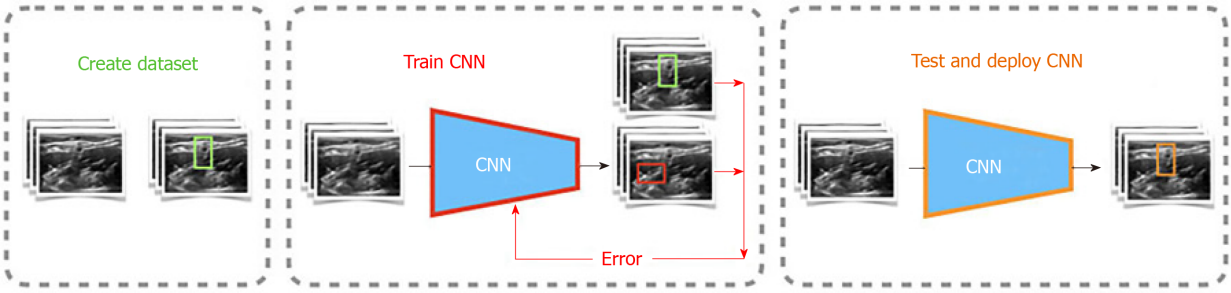

Figure 1 Illustrated convolutional neural network framework. CNN: Convolutional neural network.

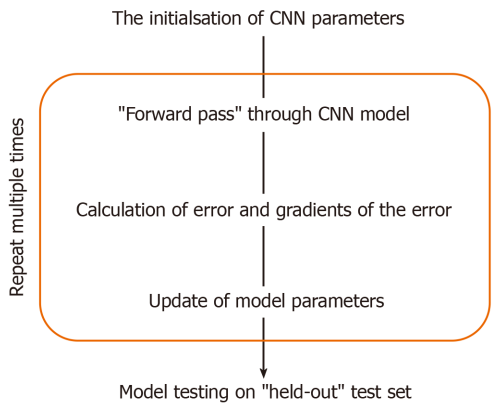

Figure 2 Convolutional neural network training; further defined. CNN: Convolutional neural network.

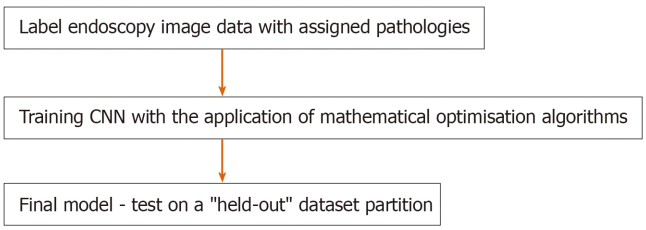

Figure 3 The convolutional neural network framework simplified. CNN: Convolutional neural network.

"held-out" test set - on images which the CNN has not seen during training. In this way, the model's performance on this test set can be used to approximate how well the model generalises to images, not in the dataset.

The training has been well described in the recent article[2], where authors have highlighted splitting the computer learning model into training followed by validation set and then the test set. The initial game was to train the model to predict labelled image pathology followed by validation. This will allow the model to detect unseen pathology and lastly evaluate the outcomes of the trained model with optimal hyperparameters.

It can be seen, here, that by ensuring that the manual labels are generated by expert physicians, the model could encode this knowledge and be used to transfer it to trainees. The validation of this idea is an interesting avenue of research, in which two sets of labels could be collected for the "test-set", from both experts and non-experts, to see if the CNN predictions can better align with the experts' annotation than those of the less experienced physicians.

Data augmentation is one technique that can be used to supplement and amplify a small or limited dataset[2,4]. This can be beneficial in increasing data variability, thus exposing CNN to more examples to learn from and improve final model accuracy. Traditional augmentation methods on image data include image scaling and rotation,

as well as manipulation of an images' brightness, contrast or saturation. Synthesised images generated from a class of DL algorithms known as generative adversarial networks have also augmented data used to train CNNs, Frid-Adar *et al*[5].

We also highlight the potential risks of the naive implementation of this technology. The model will encode and operate well on patterns seen in the training data but will fail (often catastrophically and uninterpretably) when exposed to unseen patterns. As such, researchers and clinicians must carefully ascertain whether biases are encoded into the curated datasets. These biases may be clinical (*e.g.*, omitted pathologies in the data) but also socio-technical (*e.g.* underrepresentation of sub-groups according to age, ethnicity, gender *etc.*). We direct the reader to further work on this topic[6].

CNN'S IN GI ENDOSCOPY

The CNN training process has been well described in a recent article[2] where the authors have highlighted splitting the dataset into training, validation and test sets. The initial game was to train the model to predict labelled image pathology followed by validation.

The use of CNN's in the early detection of oesophageal carcinoma has been published by Medel *et al*[7]. Here, the authors concluded improvement in sensitivity to 0.94 and specificity to 0.88. They defined C0 as a non-cancerous area and C1 as a cancerous area, highlighting the two regions and ultimately classified images as cancerous or non-cancerous using a patch-based approach. They concluded that future studies should include a greater number of images in the training set. Though adenoma detection rates at colonoscopy is variable with human interpretation, polyps' localisation and detection rate using a CNN has been shown to improve accuracy to 96.4%. This, in turn, can affect a reduction in colorectal interval cancers and associated cancer mortality[8].

The CNN can be used as an image feature extractor along with a support vector machine (SVM) as an aid for polyp classification. Shape, size and surface characteristics guide the attending gastrointestinal physician to identify and differentiate benign and malignant polyps. The accuracy of detection and diagnosis is variable depending on the experience of the endoscopist and the equipment. It has been shown that AI-based systems increase the accuracy of diagnosis and detection rate of polyps.

A Japanese team published an article on polyp classification in 2017, where they used a CNN to extract features from the endoscopic image and an SVM to classify colonic polyps. The SVM algorithms are used primarily for classification and regression analysis. In this study, the authors noted increased accuracy by using multiple CNN-SVM classifiers[9]. A further improvement in the detection and classification can be achieved through improved extraction methods such as wavelet colour texture feature extraction. This is nicely illustrated in an article by Billlah *et al*[10]. In another study, authors showed an accuracy of 78.4% to differentiate adenomatous vs non-adenomatous colonic polyps[11]. The system used linked colour imaging and showed a sensitivity of 83% and specificity of 70.1%[9]. Likewise, AI has been used to classify inflammatory bowel disease with 90% accuracy[12]. In another study authors collected and tagged 6 colorectal segments from 100 patients - they inferred the computer-aided detection system has potential for automatic identification of persistent histological inflammation in patients with ulcerative colitis[13].

CONCLUSION

AI use in medicine is likely to rise fast along with its endoscopy applications, followed by a noticeable surge in investment by big industry players. Gastrointestinal physicians will witness many breakthroughs in the coming years; however, a lack of proper legislation and clinical governance structure needs to be addressed soon. This requires evidence-based consensus and acceptable international standards without compromising a patient's safety in the coming years. Likewise, several technical issues within AI must be addressed, such as algorithm interpretability, fairness in results, and diverse representation in the dataset. However, reduction of errors due to endoscopist fatigue, inter-observer variability and learner endoscopist misconception are few rewards of AI; all these can no-doubt be leveraged to improve patient management. One cannot answer, whether, in the coming years, AI will replace

humans in performing the endoscopies themselves! Indisputably, AI is here to stay and will play a vital role in the post-COVID-19 "new normal" era.

REFERENCES

1 **Ruffle JK**, Farmer AD, Aziz Q. Artificial Intelligence-Assisted Gastroenterology- Promises and Pitfalls. *Am J Gastroenterol* 2019; **114**: 422-428 [PMID: 30315284 DOI: 10.1038/s41395-018-0268-4]

2 **van der Sommen F**, de Groof J, Struyvenberg M, van der Putten J, Boers T, Fockens K, Schoon EJ, Curvers W, de With P, Mori Y, Byrne M, Bergman JJGHM. Machine learning in GI endoscopy: practical guidance in how to interpret a novel field. *Gut* 2020 [PMID: 32393540 DOI: 10.1136/gutjnl-2019-320466]

3 **Min JK**, Kwak MS, Cha JM. Overview of Deep Learning in Gastrointestinal Endoscopy. *Gut Liver* 2019; **13**: 388-393 [PMID: 30630221 DOI: 10.5009/gnl18384]

4 **Ragab DA**, Sharkas M, Marshall S, Ren J. Breast cancer detection using deep convolutional neural networks and support vector machines. *PeerJ* 2019; **7**: e6201 [PMID: 30713814 DOI: 10.7717/peerj.6201]

5 **Frid-Adar M**, Diamant I, Klang E, Amitai M, Goldberger J, Greenspan H. GAN-based synthetic medical image augmentation for increased CNN performance in liver lesion classification. *Neurocomputing* 2018; **321**: 321-331 [DOI: 10.1016/j.neucom.2018.09.013]

6 **Parikh RB**, Teeple S, Navathe AS. Addressing Bias in Artificial Intelligence in Health Care. *JAMA* 2019; **322**: 2377-2378 [PMID: 31755905 DOI: 10.1001/jama.2019.18058]

7 **Mendel R**, Ebigbo A, Probst A, Messmann H, Palm C. Barrett's Esophagus Analysis Using Convolutional Neural Networks. In: Bildverarbeitung für die Medizin. Springer, 2017: 80-85 [DOI: 10.1007/978-3-662-54345-0_23]

8 **Urban G**, Tripathi P, Alkayali T, Mittal M, Jalali F, Karnes W, Baldi P. Deep Learning Localizes and Identifies Polyps in Real Time With 96% Accuracy in Screening Colonoscopy. *Gastroenterology* 2018; **155**: 1069-1078.e8 [PMID: 29928897 DOI: 10.1053/j.gastro.2018.06.037]

9 **Murata M**, Usami H, Iwahori Y, Wang AL, Ogasawara N, Kasugai K. Polyp classification using multiple CNN-SVN classifiers from endoscopy images. In: Patterns 2017: the Ninth International Conferences on Pervasive Patterns and Applications. International Academy, Research, and Industry Association, 2017. Available from: https://www.thinkmind.org/download.php?articleid=patterns_2017_8_30_78008/

10 **Billah M**, Waheed S. Gastrointestinal polyp detection in endoscopic images using an improved feature extraction method. *Biomed Eng Lett* 2018; **8**: 69-75 [PMID: 30603191 DOI: 10.1007/s13534-017-0048-x]

11 **Min M**, Su S, He W, Bi Y, Ma Z, Liu Y. Computer-aided diagnosis of colorectal polyps using linked color imaging colonoscopy to predict histology. *Sci Rep* 2019; **9**: 2881 [PMID: 30814661 DOI: 10.1038/s41598-019-39416-7]

12 **Mossotto E**, Ashton JJ, Coelho T, Beattie RM, MacArthur BD, Ennis S. Classification of Paediatric Inflammatory Bowel Disease using Machine Learning. *Sci Rep* 2017; **7**: 2427 [PMID: 28546534 DOI: 10.1038/s41598-017-02606-2]

13 **Maeda Y**, Kudo SE, Mori Y, Misawa M, Ogata N, Sasanuma S, Wakamura K, Oda M, Mori K, Ohtsuka K. Fully automated diagnostic system with artificial intelligence using endocytoscopy to identify the presence of histologic inflammation associated with ulcerative colitis (with video). *Gastrointest Endosc* 2019; **89**: 408-415 [PMID: 30268542 DOI: 10.1016/j.gie.2018.09.024]

AIGE Artificial Intelligence in Gastrointestinal Endoscopy

Submit a Manuscript: https://www.f6publishing.com

Artif Intell Gastrointest Endosc 2020 July 28; 1(1): 6-18

DOI: 10.37126/aige.v1.i1.6

ISSN 2689-7164 (online)

MINIREVIEWS

Emerging artificial intelligence applications in gastroenterology: A review of the literature

Gaetano Cristian Morreale, Emanuele Sinagra, Alessandro Vitello, Endrit Shahini, Erjon Shahini, Marcello Maida

ORCID number: Gaetano Cristian Morreale 0000-0001-8954-7819; Emanuele Sinagra 0000-0002-8528-0384; Alessandro Vitello 0000-0001-9099-9468; Endrit Shahini 0000-0002-4909-0436; Erjon Shahini 0000-0003-1242-1593; Marcello Maida 0000-0002-4992-9289.

Author contributions: Morreale GC and Maida M are guarantors of the integrity of the entire study and contributed to the manuscript drafting and manuscript revision for important intellectual content; all authors contributed to the manuscript editing and had full control over the preparation of the manuscript.

Conflict-of-interest statement: The authors have no proprietary, financial, professional or other personal interest of any nature or kind in any product, service and/or company that could be construed as influencing the position presented in, or the review of this manuscript.

Gaetano Cristian Morreale, Alessandro Vitello, Marcello Maida, Gastroenterology and Endoscopy Unit, S. Elia- M. Raimondi Hospital, Caltanissetta 93100, Italy

Emanuele Sinagra, Gastroenterology and Endoscopy Unit, Fondazione Istituto G. Giglio, Cefalù 90015, Italy

Endrit Shahini, Gastroenterology and Endoscopy Unit, Istituto di Candiolo, FPO-IRCCS, Candiolo (Torino) 93100, Italy

Erjon Shahini, Polytechnic University of Bari, Bari 70126, Italy

Corresponding author: Marcello Maida, MD, Doctor, Senior Researcher, Gastroenterology and Endoscopy Unit, S. Elia–M. Raimondi Hospital, Via Giacomo Cusmano, 1, Caltanissetta 93100, Italy. marcello.maida@hotmail.it

Abstract

Artificial intelligence (AI) allows machines to provide disruptive value in several industries and applications. Applications of AI techniques, specifically machine learning and more recently deep learning, are arising in gastroenterology. Computer-aided diagnosis for upper gastrointestinal endoscopy has growing attention for automated and accurate identification of dysplasia in Barrett's esophagus, as well as for the detection of early gastric cancers (GCs), therefore preventing esophageal and gastric malignancies. Besides, convoluted neural network technology can accurately assess *Helicobacter pylori (H. pylori)* infection during standard endoscopy without the need for biopsies, thus, reducing gastric cancer risk. AI can potentially be applied during colonoscopy to automatically discover colorectal polyps and differentiate between neoplastic and non-neoplastic ones, with the possible ability to improve adenoma detection rate, which changes broadly among endoscopists performing screening colonoscopies. In addition, AI permits to establish the feasibility of curative endoscopic resection of large colonic lesions based on the pit pattern characteristics. The aim of this review is to analyze current evidence from the literature, supporting recent technologies of AI both in upper and lower gastrointestinal diseases, including Barrett's esophagus, GC, *H. pylori* infection, colonic polyps and colon cancer.

Key words: Artificial intelligence; Machine learning; Deep learning; Computer-aided

Manuscript source: Invited manuscript

Received: June 23, 2020
Peer-review started: June 23, 2020
First decision: July 3, 2020
Revised: July 7, 2020
Accepted: July 17, 2020
Article in press: July 17, 2020
Published online: July 28, 2020

P-Reviewer: Viswanath YKS
S-Editor: Wang JL
L-Editor: A
E-Editor: Li X

diagnosis; Gastroenterology; Endoscopy

Core tip: Artificial intelligence (AI) allows machines to provide disruptive value in a multitude of industries and knowledge domains. Applications of artificial intelligence techniques, specifically machine learning and more recently deep learning, are arising in gastrointestinal endoscopy. Computer-aided diagnosis has been performed during upper gastrointestinal endoscopy for the automated identification of dysplastic lesions in Barrett's esophagus for preventing esophageal cancer, as well as in lower gastrointestinal endoscopy for detecting colorectal polyps to prevent colorectal cancer. The aim of this review is to investigate current data from the literature, supporting recent technologies of AI both in upper and lower gastrointestinal diseases, including Barrett's esophagus, gastric cancer, *Helicobacter pylori* infection, colonic polyps and colon cancer.

Citation: Morreale GC, Sinagra E, Vitello A, Shahini E, Shahini E, Maida M. Emerging artificial intelligence applications in gastroenterology: A review of the literature. *Artif Intell Gastrointest Endosc* 2020; 1(1): 6-18
URL: https://www.wjgnet.com/2689-7164/full/v1/i1/6.htm
DOI: https://dx.doi.org/10.37126/aige.v1.i1.6

INTRODUCTION

Artificial intelligence (AI) is based on intelligent agents performing functions associated with human mind, such as learning and problem solving[1,2].

In endoscopy, AI has begun to assist the improvement of colonic polyp detection and adenoma detection rate (ADR), to discriminate between benign and precancerous lesions based on the interpretation of their superficial patterns.

Machine learning (ML) and deep learning (DL) can be considered subfields of AI. ML is a form of AI that can support decision process allowing the improvement, without any Programmation, of the algorithms applied, including data testing and the implementation of descriptive and predictive models (Figure 1).

ML is distinguished into supervised and unsupervised methods. An instance of supervised ML, artificial neural networks (ANN), mirror the scheme function of the brain. Each neuron is a computing unit and all neurons are connected to produce a network. ML and convoluted neural network (CNN) algorithms have been created to train software to discriminate normal from abnormal regions in the lumen of the gut. For polyp detection, ML uses a fixed number of characteristics, such as polyp size, shape, and mucosal patterns.

A variety of deep learning neural network architectures are included in DL-based methods that automatically extract relevant imaging features without the human perceptual biases[3].

AI, BARRETT'S ESOPHAGUS AND ESOPHAGEAL CANCER

Barrett's esophagus (BE) is characterized by an unusual (metaplastic) transformation of the mucosal cells, lining the lower part of the esophagus, from normal stratified squamous epithelium to columnar one and associated with interspersed goblet cells[4]. This condition represents a risk factor for esophageal adenocarcinoma (EAC) whose most serious prognosis is related to the late diagnosis[4]. Moreover, 93% of patients can achieve a complete disease remission after a regular surveillance during 10 years and treatment[5-7]. Promising techniques for the management of BE with the potential of reducing the cancer risk by an accurate diagnosis of dysplasia, are being developed.

However, despite some limitations in interventional therapies, such as endoscopic resection (ER) and ablation techniques (radiofrequency ablation or cryoablation) they can help preventing the evolution into malignancy[8-11].

The recognition of neoplastic changes in BE patients is crucial and innovations in endoscopic imaging have worked for early detection of minimal epithelial neoplastic lesions based on distinct mucosal features.

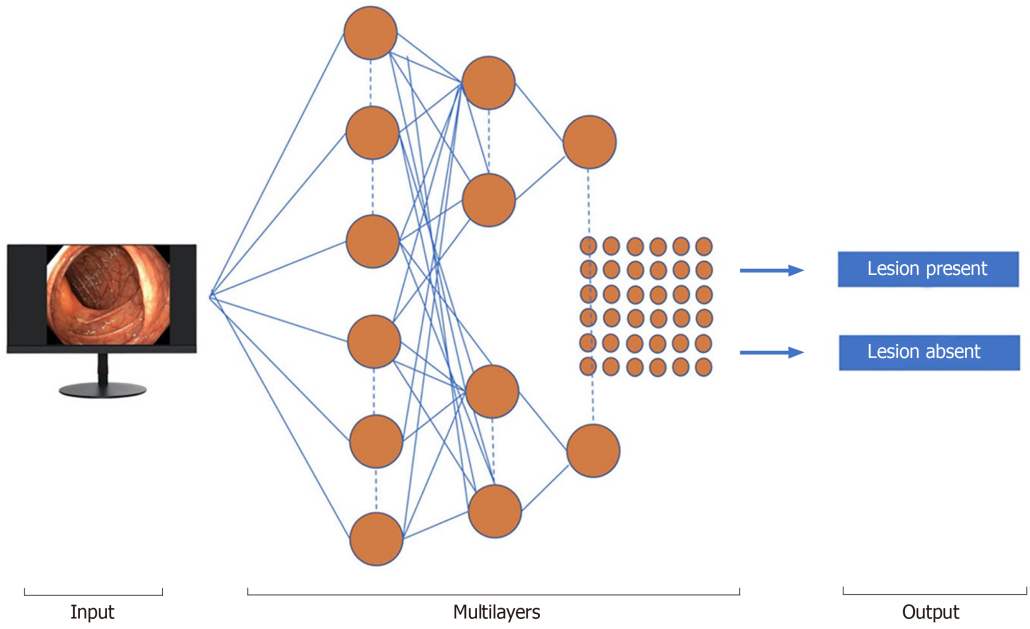

Figure 1 Schematic model of the deep learning algorithm in endoscopy.

In a first study, Mendel *et al*[12], introduced a useful method for generating an automatic classification based on endoscopic white light images through the learning of specific features helped by a pretrained deep residual network, instead of handcrafted texture features. The study used a data set of 100 high-resolution endoscopic images from 39 patients supplied by the Endoscopic Vision Challenge Medical Image Computing and Computer-Assisted Intervention (MICCAI). While 22 BE patients had cancerous lesions, 17 had non-cancerous BE.

The endoscopic images were independently evaluated by five experts and then compared with probability maps provided by AI, showing a strong correspondence. Since the significant of manual segmentations vary significantly, their intersection was considered as a cancerous region (C1-region) within each C1-image.

Ebigbo *et al*[13], employed two data sets to train and validate a computer-aided diagnosis (CAD) system relying on a deep CNN with a residual net (ResNet) architecture. Images consisted of 148 high-definition white light endoscopy (WLE) and narrowband imaging (NBI) images regarding 33 EAC and 41 areas of non-neoplastic BE in the Augsburg data set, while the MICCAI data set comprised 100 high-definition WLE images, 17 early EAC and 22 areas of non-neoplastic BE. CAD-DL system diagnosed EAC with a sensitivity of 97% and a specificity of 88% for WLE images, whereas a sensitivity and specificity of 94% and 80% for NBI images, respectively. CAD-DL reached a sensitivity and specificity of 92% and 100%, respectively, for the MICCAI images.

In these beginning studies, the authors developed a CAD model and displayed promising performance scores in the classification/segmentation areas during BE assessment.

However, these results were achieved using high-quality endoscopic imaging that cannot always be obtained during daily clinical practice. This system was previously developed to further increase the speed of image analysis for classification and the resolution of the dense prediction, displaying the color-coded spatial distribution of cancer probabilities.

Still based on deep CNNs and a ResNet architecture with DeepLab V.3+, a state-of-the-art encoder-decoder network was readjusted. To transfer the endoscopic Livestream to our AI system, a capture card (Avermedia, Taiwan) for image aquisition was incorporated into the endoscopic monitor[14] and the AI system was trained by using 129 endoscopic images. All AI-image outcomes were confirmed by pathological examination of resection specimens (EAC), as well as forceps biopsies (*i.e.*, normal BE). The AI system showed high performance scores in the categorization task with a sensitivity and specificity of 83.7% and 100%, respectively.

CNN was also used by Horie *et al*[15], that retrospectively collected 8428 training images from esophageal cancer of 384 patients through CNNs. CNN took 27 seconds to analyze 1118 test images and correctly detected esophageal cancer cases with a

sensitivity of 98%. CNN detected every 7 small cancer lesions lower than 10 mm in size. This system facilitated early and rapid malignancy detection leading to a better prognosis of these patients.

AI can assist endoscopists to make targeted biopsies with high-accuracy, saving work/time-intensive random sampling, with a low sensitivity (64%) for the detection of dysplasia. An international, randomized, crossover trial[16], compared high-definition white-light endoscopy (HD-WLE) and NBI for detecting IM and malignancy in 123 patients with BE (mean circumferential and maximal sizes, 1.8 and 3.6 cm, respectively).

Both HD-WLE and NBI detected 104/113 (92%) patients with IM, but NBI required fewer biopsies per-patient and exhibited a significantly higher dysplasia detection rate (30% *vs* 21%). During endoscopic examination with NBI, all areas of HGD and cancer presented an irregular mucosal or vascular pattern. Regular NBI surface patterns did not harbor HGD or cancer, suggesting that biopsies could be potentially avoided in the latter cases. Besides, in a multicenter, randomized crossover study[17], using endoscopic trimodal imaging (ETMI) for detection of early neoplasia in BE, ETMI showed no improvement in overall dysplasia detection than standard video endoscopy. The diagnosis of dysplasia was still made in a significant number of patients by random biopsies, and patients with a confirmed diagnosis of LGIN had a significant risk of HGIN/carcinoma.

Van der Sommen *et al*[18] used a computer algorithm to detect early neoplastic lesions in BE and employed specific texture, color filters, and ML-based on 100 images from 44 patients with BE. This system identified early neoplastic lesions on a patient-level with a sensitivity and specificity of 86% and 87%, respectively. The author assumed that the automated computer algorithm implemented for this study was able to identify early neoplastic lesions with reasonable accuracy.

De Groof *et al*[19] developed a CAD system using endoscopic images of Barrett's neoplasm based on the endoscopic images of 40 Barrett's neoplastic lesions and 20 non-dysplastic BE, reaching a sensitivity and specificity for the detection of such lesions of 95% and 85%, respectively.

AI technology was applied for volumetric laser endomicroscopy (VLE) in 2017. VLE with laser marking is a broad field of advanced imaging technology that was commercially available in the United States in 2013 to facilitate dysplasia detection.

VLE can enhance the detection of neoplastic lesions in BE by performing a circumferential scan of the esophageal wall layers. Sixteen patients with BE were included in the study and a total of 222 laser markers (LMs) were placed, 97% of them were visible on WLE. All LMs were evident on VLE directly after marking, and 86% were confirmed during the post hoc analysis. LM targeting held an accuracy of 85% of cautery marks. This original study applied to humans showed that VLE-guided LM can be a possible and secure procedure[20].

In another study[21] the same authors used a database of VLE images from BE endoscopic resection specimens with/without neoplasia, precisely correlated them with histology to develop a VLE prediction score. The receiving operating characteristic curve of this prediction score showed an area under the curve (AUC) of 0.81. A value ≥ 8 correlated with an 83% sensitivity and 71% specificity.

Optical coherence tomography (OCT) is a technique that produces high-resolution esophageal images through endoscopy. OCT can recognize specialized IM from epithelial squamous cells, but image criteria for distinguishing intramucosal carcinoma (IMC) and HGD from LGD, indeterminate-grade dysplasia (IGD), and specialized IM without dysplasia have not been approved yet.

Evans *et al*[22], examined 177 OCT images from patients with a histological diagnosis of BE. The histopathology analysis was IMC/HGD in 49 cases, LGD in 15, IGD in 8, specialized IM in 100, whereas gastric mucosa in 5 patients. A meaningful correlation was found between the MC/HGD histopathologic result and scores for each image feature, surface maturation, and gland architecture. When a dysplasia index determination of ≥ 2 was used, an 83% sensitivity and 75% specificity were determined for diagnosing IMC/HGD.

In a tertiary-care center, 27 BE patients underwent 50 EMRs imaged by VLE and pCLE, and were classified into neoplastic/non-neoplastic on the basis of histology result. The sensitivity and specificity of pCLE for detecting BE dysplasia, was 76% and 79%, respectively. The OCT-SI showed a sensitivity of 70% and a specificity of 60%. Moreover, the novel VLE-DA showed a sensitivity of 86%, specificity of 88% and a diagnostic accuracy of 87%[23].

Esophageal squamous cell carcinoma (SCC) is the sixth malignant cause of mortality worldwide and a greater percentage affect developing countries due to a delayed diagnosis[24]. Lugol's chromoendoscopy currently represents the gold standard

technique for identifying SCC during gastroscopy, despite a low specificity (about 70%) but a higher sensitivity (over 90%).

Among non-invasive tests, NBI is another approach that has a low diagnostic specificity as displayed in a randomized controlled trial (RCT), related to the physician's experience[25].

High-resolution microendoscopy (HRME) has shown the potential to enhance esophageal SCC detection during screening. An automated, real-time analysis algorithm has been developed and assessed using training tests, and validation images derived from a previous *in-vivo* study including 177 subjects involved for screening/surveillance programs. In a post hoc analysis, the algorithm recognized malignant tumors with a 95% sensitivity and 91% specificity, in the validation dataset, while 84% and 95% in the original study. Therefore, this technology could be applied in settings with less expertise operators in interpreting HRME images[26].

Kodashima *et al*[27] realized a computer system architecture to simplify the differentiation among neoplastic features and healthy tissues as a result of analyzing images in endocytoscopy of esophageal tissue from histopathological analysis, by analyzing the nuclear area of the collected images from 10 patients, to achieve an accurate and automatic diagnosis[27].

Shin *et al*[28] developed a quantitative image analysis algorithm that was able to recognize squamous dysplasia from non-neoplastic mucosa. They completed an image interpretation of 177 subjects undergoing upper endoscopy for SCC screening or surveillance, by using HRME. Quantitative data from the high-resolution images were used to create an algorithm to identify high-grade squamous dysplastic lesions or invasive SCC on histopathology.

The highest performance was gained using the mean nuclear area as the input for classification, resulting in a sensitivity and specificity of 93% and 92% in the training set, 87% and 97% in the test set, 84% and 95% in an independent validation set, respectively. ER is a technique employed for treating tumors with submucosal invasion depth 1 (SM1), whereas surgical removal with/without chemo-radiotherapy is usually used for SCC cases with a tumor infiltration deeper than SM2.

Accordingly, the preoperative endoscopic estimation of the ESCC invasion depth is critical. Recently, a rapid improvement in the application of AI with DL in medicine has been realized. A study by Tokai *et al*[29], evaluated the efficacy of AI in measuring ESCC invasion depth in a set of 1751 ESCC training images. AI recognized 95.5% (279/291) of the ESCC in the 10 test images when analyzing the 279 images it correctly predicted the invasion depth of the ESCC with an 84.1% sensitivity and an 80.9% accuracy in 6 seconds, much more precise for the estimation of ESCC invasion depth from endoscopists.

AI AND GASTRIC CANCER

Gastric cancer (GC) ranks third main cause of malignancy mortality worldwide, and esophagogastroduodenoscopy (EGD) is considered the best diagnostic tool for neoplasms at their early stages. The treatment of gastric tumors depends on the depth of the submucosal invasion; indeed, for differentiated intramucosal tumors (M) or those that invade the superficial submucosal layer (≤ 500 lm: SM1) ER is provided, while those with a deep submucosal invasion (> 500 lm: SM2) should be surgically treated for the potential risk of local invasiveness and metastases. Magnifying endoscopy combined with NBI or FICE (flexible color enhancement of spectral imaging) is clinically useful in discriminating gastric malignant from non-malignant areas[30-34]. However, this optical diagnosis strictly depends on the expertise and the experience of the operator, which prevents its general use in clinical practice.

Two RCTs examined the performance of endoscopy with/without the support of AI algorithms. The first research estimated the performance of a real-time DL system, WISENSE, to control the presence of blind spots during EGD. Overall, 324 patients randomly performed endoscopy with or without the use of WISENSE that monitored blind spots with a 90% average accuracy, and a separate accuracy for each site ranging 70.2%-100% in the 107 live endoscopic videos.

The average sensitivity and specificity were 87.6% and 95%, ranging between 63.4%-100% and 75%-100%, respectively. For timing endoscopic procedure, WISENSE accurately predicted the start and end times in 93.5% (100/107) and 97.2% (104/107) videos, respectively[35].

Miyaki *et al*[36], developed software allowing a quantitative evaluation of mucosal GCs on magnifying gastrointestinal endoscopy images obtained with FICE. They

adopted a set of features framework having densely sampled scale-invariant feature transform descriptors to magnifying FICE images of 46 intramucosal GCs then compared with histologic findings. The CAD system allowed an 86%detection accuracy, a sensitivity and specificity of 85% and 87% for a cancer diagnosis, respectively.

In the study by Kanesaka *et al*[37], a total of 127 patients with EGC contributed to 127 cancerous M-NBI images, while 20 not-EGC patients provided to 60 not-cancerous M-NBI images. The authors created software that allowed both the identification of GC and outlined the edge between malignant and non-malignant regions. This CAD algorithm was designed to investigate grey-level co-occurrence matrix characteristics of partitioned pixel slices of magnifying NBI images, and a support vector machine was used for the ML method. The models showed a 97% sensitivity and 95% specificity in distinguishing cancer, while the performance for area concordance displayed a sensitivity and specificity, of 81% and 66% respectively.

In 2018, Hirasawa *et al*[38], elaborated an AI-based diagnostic system to detect GC, using a CNN simulating the human brain.

A total of 714 among 2,296 test image sets (31.1%) confirmed GC presence, and 84.1% had moderate/severe gastric atrophy. The CNN employed 47 seconds to analyze the 2,296 test images, diagnosing overall 232 GCs, 161 as non-malignant lesions, 71 of 77 as GC lesions with a sensitivity of 92.2%. The majority of gastric lesions (98.6%) with a diameter ≥ 6 mm were precisely identified by CNN, additionally to all invasive carcinomas (T1b or deeper). The undiagnosed lesions had a superficial depression and were more frequently intramucosal cancers with a differentiated-histotype, whose discrimination from gastric inflammation was challenging also for experienced endoscopists. Another usual reason for misdiagnosis was the anatomical sites of the cardia, incisura angularis, and pylorus.

Zhu *et al*[39] examined the potential of AI to address the prediction of invasion depth of early GC. In particular, they developed and validated an AI model CNN-CAD that used a deep learning algorithm for determining EGC invasion depth ("M/SM1" *vs* "SM2 or deeper").

A total of 790 endoscopic images of GCs were employed for ML, while an additional 203 images, completely autonomous from the learning material, were handled as a test set. The AI model exhibited a sensitivity and specificity of 76% and 96%, respectively in distinguishing SM2 or deeper cancer invasion, with a higher diagnostic performance as compared to the one reached by endoscopists. This high specificity could lessen the overestimation of tumoral invasion, which would contribute indirectly to reduce avoidable surgeries for M/SM1 malignancies. Moreover, in this study, the CNN-CAD system also achieved significantly greater accuracy and specificity than both expert and junior trained endoscopists.

AI might assist physicians to predict prognoses of patients with GC. Some crucial clinical trials evaluating adjuvant strategies of advanced GC were produced over the past decade, but the most suitable therapy for GC is so far uncertain. Besides, two contemporary molecular landscape studies proved the presence of various molecular GC subtypes[40,41].

A DL-based model (survival recurrent network, SRN) was developed to predict survival events for a total of 1190 GC patients, based on clinical/pathology data as well as therapy regimens, predicting the outcome at each-time point during a 5-year surveillance time.

The SRN showed that the mesenchymal subtype of GC should stimulate a tailored postoperative therapeutical strategy as a consequence of its great risk of recurrence rate. Conversely, the SRN observed that GCs with microsatellite instability and the papillary type displayed significantly more favorable prognosis after chemotherapy including capecitabine and cisplatin. SRN reached a survival of 92%, 5 years after curative gastrectomy resection[42].

ANN model was used to evaluate 452 GC patients, determining survival times with approximately 90% accuracy, and focusing on producing an adequate ANN structure with the capacity to handle censored data[43]. In detail, 5 sets of single time-point feed-forward ANN models were generated to predict the outcomes of GC patients at regular time intervals (every year) until the fifth year after gastrectomy. Hence, the ANN prediction models exhibited accuracy, sensitivity, and specificity ranging as follows 88.7%-90.2%, 70.2%-92.5%, and 66.7%-96.2%, respectively.

AI IN THE IDENTIFICATION OF *HELICOBACTER PYLORI* INFECTION

Helicobacter pylori (*H. pylori*) infects the epithelial gastric cells and is associated with functional dyspepsia, peptic ulcers, mucosal atrophy, intestinal metaplasia, and GC[44]. *H. pylori*-associated chronic gastritis may also raise the risk of GC[45,46]. CNN technology can accurately assess *H. pylori* infection during conventional endoscopy without needing biopsies. In a pilot study by Zheng *et al*[47], the authors produced a Computer-Aided Decision Support System that uses CNN to estimate *H. pylori* infection based on endoscopic images. From 1959 patients, 77% were assigned to the derivation cohort (1507 patients; 11729 gastric images) and 56% of them had *H. pylori* infection (847), while 23% were selected for the validation cohort (452) and 69% of patients were *H. pylori* infected (310; 3755 total images).

Huang *et al*[48] applied neural networks (refined feature selection with a neural network, RFSNN) to predict *H. pylori*-related gastric histological hallmarks based on standard endoscopic images. The authors trained the model using endoscopic images of 30 patients and used image parameters taken from a different cohort of 74 patients to generate a model to predict *H. pylori* infection, showing an 85% sensitivity and a 91% specificity for identifying *H. pylori* infection. Moreover, RFSNN revealed an accuracy higher than 80% in predicting the presence of gastric atrophy, IM, and *H. pylori*-related gastritis severity.

Shichijo *et al*[49] produced a 22-layer deep CNN to predict *H. pylori* infection during real-time endoscopy. A dataset including 32208 images of 735 *H. pylori*-positive and 1015 *H. pylori*-negative patients was handled. The sensitivity/specificity/accuracy, were 81.9/83.4/83.1%, respectively, for the first CNN, and 88.9/87.4/87.7%, respectively, for the secondary CNN, employing in both cases a similar time (198 seconds and 194 seconds, respectively).

Another study group developed a CNN, preparing 179 endoscopic images obtained from 139 patients (65 were *H. pylori*-positive and 74 *H. pylori*-negative). One hundred and fifty-nine of all images were adopted as training for a standard neural network, and the remaining 30 (15 of *H. pylori*-negative and 15 of *H. pylori*-positive patients) as test images. CAD model showed an 87% sensitivity and specificity to detect *H. pylori* infection with an AUC of 0.96[50].

Nakashima *et al*[51] used blue laser images (BLI)-bright and linked color imaging (LCI) on 162 patients as learning material and those from 60 patients as a test data set. From each patient, three white-light images (WLI), three BLI, and three linked color images (LCI; Fujifilm Corp.) were obtained, respectively. For WLI, the AUC was 0.66.

AI FOR COLONIC POLYPS AND COLON CANCER

Colorectal cancer (CRC) is the third most frequent malignancy in males and second in females, and the fourth most frequent cause of cancer fatality[52]. The National Polyp Study registered that 70%-90% of CRCs can be prevented by routine endoscopic surveillance and removal of polyps[53], but 7%-9% of CRCs can occur despite these measures[54].

Around 85% of "interval cancers" are due to missed polyps or inadequately removed polyps[55]. Adenomas are the most common precancerous lesions throughout the colon. The ADR measures the endoscopist ability to identify adenomas. The ADR ranges between 7%–53% among endoscopists making depending on their training, endoscopic removal technique, withdrawal time, quality of bowel preparation, and other procedure-dependent determinants[56,57].

Several endoscopic innovations have been promoted to increase the ADR[58,59].

A review including 5 studies on the effect of high-resolution colonoscopes on the ADR showed conflicting results; a study concluded that the ADR is raised exclusively for endoscopists with an ADR lower than 20%[60].

CAD analysis has the potential to aid adenoma detection further.

Urban *et al*[61], used a different and representative set of 8641 hand-labeled images from screening colonoscopies handled among over 2000 patients. They tested the models on 20 colonoscopy videos with a whole duration of 5 hours. Expert colonoscopists were asked to identify all polyps in 9 de-identified colonoscopy videos, which were selected from archived video studies, with/without the benefit of the CNN overlay. Their findings were correlated with those of the CNN using CNN assisted expert review as the reference. The CNN identified polyps with an AUC of 0.99 and an accuracy of 96.4%. Indeed, in the analysis of colonoscopy videos involving the removal of 28 polyps, 4 expert reviewers identified 8 further (missed) polyps

without CNN assistance and recognized an additional 17 polyps with CNN support. All polyps removed and recognized by the expert review were discovered by CNN, which showed a 7% false-positivity rate. This strategy could improve the ADR and lower interval cancers but it requires further studies to be adequately implemented.

AI can be used during endoscopic assessment to automatically recognize colorectal polyps and distinguish between malignant and non-malignant lesions. CAD is based on the latency time between the image acquisition to its processing for the ultimate visualization on the screen. This model was able to detect polyps with a 96.5% sensitivity[62,63].

A recent RCT estimated the impact of an automatic polyp detection system based on DL during real-time endoscopy. This study enrolling 1058 patients demonstrated that the AI system enhanced ADR of almost 10%[64].

A prospective study of 55 patients used a prototype of a novel automated polyp detection software (APDS) for automated image-based polyp detection and with overall real-time polyp detection of 75%[65]. Smaller polyp size and flat polyp morphology were associated with insufficient polyp detection by the APDS.

Aside from CADe machinery, CADx has been used for differentiating between adenomas and hyperplastic polyps.

Byrne *et al*[66] suggested the use of computerized image analysis to diminish the variability in endoscopic detection and histological prediction. This AI model was trained using endoscopic videos and was able to discriminate among diminutive adenomas and hyperplastic polyps with high accuracy. Additionally, it predicted histology with a 94% accuracy, 98% sensitivity, 83% specificity, a negative and positive predictive value of 97% and 90%, respectively.

Moreover, an AI-assisted image classifier, based on non-optical magnified endoscopic NBI, has been employed to predict the histology of isolated colonic lesions[67], following the evaluation of 3509 colonic lesions. The most prevalent histological types were tubular adenoma (47.6%), carcinoma with deep invasion (15.9%), carcinomas with superficial invasion (7.9%), hyperplastic polyps (14.3%), sessile serrated polyps (7.9%) and tubulovillous adenomas (6.6%). The sensitivity of hyperplastic and serrated polyps was 96.6%, although it was lower for tubular adenoma and cancer. When investigating only diminutive colonic polyps, the correlation of surveillance colonoscopy interval using AI image classifier and histology was 0.97. Moreover, this classifier also showed high accuracy (88.2%) in the prediction of carcinoma with deep invasion, which is not endoscopically curable, and the HNPV and accuracy for carcinoma with deep invasion also suggested that it can assist to select treatable lesions.

The same author assessed the use of AI-assisted image classifiers in determining the feasibility of ER of large colonic lesions based on non-magnified images. The independent testing set included 76 large colonic lesions that fulfilled the indications for endoscopic submucosal dissection. Overall, the trained AI image classifier showed a 88.2% sensitivity (95%CI: 84.7-91.1%) in differentiating endoscopically curable *vs* incurable lesions with a 77.9% specificity (95%CI: 70.3-84.4%) and 85.5% accuracy (95%CI: 82.4-88.3%). This study determined a high accuracy of the trained AI image classifier in predicting the feasibility of curative ER of large colonic lesions. While the progress of AI using CNN is great for the recognition of specific mucosal patterns and image classification, in the next future the prediction performance might outperform an expert endoscopist[68].

Hotta *et al*[69] aimed to validate the effectiveness of endocytoscopy (EC)-CAD in diagnosing malignant or non-malignant colorectal lesions, by comparing diagnostic ability between expert and non-expert endoscopists, by using web-based tests. A validation test was produced using endocytoscopic images of 100 small colorectal lesions (< 10 mm). Diagnostic accuracies and sensitivities of EB-01 and non-expert for stained endocytoscopic images were 98.0% *vs* 69.0%, showing a diagnostic accuracy and sensitivity significantly higher to non-expert endoscopists when diagnosing small colorectal lesions.

A single-group open-label prospective study assessed the performance of real-time EC-CAD on 791 consecutive patients undergoing colonoscopy and 23 endoscopists to differentiate neoplastic polyps (adenomas) requiring resection from non-neoplastic polyps not requiring treatment, potentially reducing cost[70]. The results revealed a 96.4% negative predictive value of CAD with stained mode in the best-case whereas 93.7% in the worst-case scenario. Wile by using NBI, 96.5%, and 95.2% in the best and worst-case scenario.

Another study developed an automatic quality control system (AQCS) and assessed a hypothetical improvement of polyp and adenoma detection in clinical practice based on deep CNN. The primary outcome of the study was to assess the ADR in the 308

AQCS and 315 control group patients. AQCS significantly increased the ADR than the control group. A significant improvement was similarly seen in the polyp detection rate and the mean number of polyps identified per-procedure[71].

Finally, in a study including 117 patients with stage IIA CRC after radical surgery, an ANN-based scoring system, based on the tumor molecular features, recognized those with a high, moderate, and low probability of survival at 10-year surveillance interval[72]. The 10-year overall survival rates were 16.7%, 62.9%, and 100% ($P < 0.001$), whereas the 10-year disease-free survival rates were 16.7%, 61.8%, and 98.8%, respectively. This study revealed that the scoring system for stage IIA CRC high-risk individuals for a more aggressive therapeutic approach.

DL distinguishes patients with a complete response to neoadjuvant chemoradiotherapy for locally advanced rectal cancer with an 80% accuracy. This technology support might allow to choose patients particularly benefitting the conservative treatment than complete surgical resection[73]. This is the first study using DL to predict total pathological response after neoadjuvant chemoradiotherapy in locally advanced rectal cancer.

DISCUSSION

AI could represent an essential diagnostic method for endoscopists and gastroenterologists for the patient's treatments tailoring and prediction of their clinical outcomes.

AI seems particularly valuable in gastrointestinal endoscopy, to improve the detection of premalignant lesions and malignant, or inflammatory lesions, gastrointestinal bleeding, and pancreaticobiliary diseases[74].

However, current limitations of AI include the lack of high-quality datasets for ML development. Moreover, a substantial evidence used to elaborate ML algorithms comes only from preclinical studies[74]. Potential selection biases cannot be excluded in such cases. In this setting, a rigorous validation of AI performance before its employment in daily clinical practice is necessary.

A real measure of AI accuracy, should include as a side effect in the performances overfitting and spectrum bias[75].

Overfitting occurs when a learning model tailors itself too much on the training dataset and predictions are not well generalized to new datasets[75,76]. This effect is in open contradiction with the problem-solving principle of Occam's razor, which states that simpler theories have a higher quality of prediction[77]. In worst cases of AI algorithm application, underfitting can occur, obtaining models that cannot evidence accurately the underlying structure of the dataset, thus obtaining also bad predictivity model features[78].

On the other hand, spectrum bias happens when the dataset used for model development is not representative of the target population[75,79]. To avoid an overestimation of the accuracy and generalization, an external validation dataset collected in a way that minimizes the spectrum bias, should be guaranteed. Besides, well-designed multicenter observational studies, are required for a stronger validation.

Certainly, it is also noteworthy to acknowledge ethical issues since AI is not aware of the patient's choices or legal liabilities. The privacy issues could be addressed using federated datasets that don't involve centralized servers.

Future randomized studies could directly increase the overall value (quality *vs* cost) of the CNN by examining its effects on surveillance colonoscopy, endoscopic time, polyps and ADR, and pathology charges.

Since AI science is in progress, the current limitations must be considered as a future challenge, so actually they are inherited also in the medicine applications, including difficult predictability of situations characterized by some uncertainty.

In general, AI is revolutionizing the technology and impacting also other ethical aspects like human work replacement by machines, but this has always been an open question since the industrial revolution.

What can be done is to promote the mutual collaboration through gastrointestinal endoscopy applications, to reciprocally benefit from the achievements in both science fields.

REFERENCES

1 **Russell S**, Norvig P. Artificial Intelligence: A Modern Approach, Global Edition. 3rd editon. London: Pearson, 2016

2 **Colom R**, Karama S, Jung RE, Haier RJ. Human intelligence and brain networks. *Dialogues Clin Neurosci* 2010; **12**: 489-501 [PMID: 21319494]

3 **Goodfellow I**, Bengio Y, Courville A. Deep Learning. Cambridge: The MIT Press, 2016

4 **Pohl H**, Welch HG. The role of overdiagnosis and reclassification in the marked increase of esophageal adenocarcinoma incidence. *J Natl Cancer Inst* 2005; **97**: 142-146 [PMID: 15657344 DOI: 10.1093/jnci/dji024]

5 **Dent J**. Barrett's esophagus: A historical perspective, an update on core practicalities and predictions on future evolutions of management. *J Gastroenterol Hepatol* 2011; **26** Suppl 1: 11-30 [PMID: 21199510 DOI: 10.1111/j.1440-1746.2010.06535.x]

6 **Sharma P**, Bergman JJ, Goda K, Kato M, Messmann H, Alsop BR, Gupta N, Vennalaganti P, Hall M, Konda V, Koons A, Penner O, Goldblum JR, Waxman I. Development and Validation of a Classification System to Identify High-Grade Dysplasia and Esophageal Adenocarcinoma in Barrett's Esophagus Using Narrow-Band Imaging. *Gastroenterology* 2016; **150**: 591-598 [PMID: 26627609 DOI: 10.1053/j.gastro.2015.11.037]

7 **Phoa KN**, Pouw RE, Bisschops R, Pech O, Ragunath K, Weusten BL, Schumacher B, Rembacken B, Meining A, Messmann H, Schoon EJ, Gossner L, Mannath J, Seldenrijk CA, Visser M, Lerut T, Seewald S, ten Kate FJ, Ell C, Neuhaus H, Bergman JJ. Multimodality endoscopic eradication for neoplastic Barrett oesophagus: results of an European multicentre study (EURO-II). *Gut* 2016; **65**: 555-562 [PMID: 25731874 DOI: 10.1136/gutjnl-2015-309298]

8 **Shaheen NJ**, Sharma P, Overholt BF, Wolfsen HC, Sampliner RE, Wang KK, Galanko JA, Bronner MP, Goldblum JR, Bennett AE, Jobe BA, Eisen GM, Fennerty MB, Hunter JG, Fleischer DE, Sharma VK, Hawes RH, Hoffman BJ, Rothstein RI, Gordon SR, Mashimo H, Chang KJ, Muthusamy VR, Edmundowicz SA, Spechler SJ, Siddiqui AA, Souza RF, Infantolino A, Falk GW, Kimmey MB, Madanick RD, Chak A, Lightdale CJ. Radiofrequency ablation in Barrett's esophagus with dysplasia. *N Engl J Med* 2009; **360**: 2277-2288 [PMID: 19474425 DOI: 10.1056/NEJMoa0808145]

9 **Johnston MH**, Eastone JA, Horwhat JD, Cartledge J, Mathews JS, Foggy JR. Cryoablation of Barrett's esophagus: a pilot study. *Gastrointest Endosc* 2005; **62**: 842-848 [PMID: 16301023 DOI: 10.1016/j.gie.2005.05.008]

10 **Overholt BF**, Panjehpour M, Halberg DL. Photodynamic therapy for Barrett's esophagus with dysplasia and/or early stage carcinoma: long-term results. *Gastrointest Endosc* 2003; **58**: 183-188 [PMID: 12872083 DOI: 10.1067/mge.2003.327]

11 **Sharma P**, Brill J, Canto M, DeMarco D, Fennerty B, Gupta N, Laine L, Lieberman D, Lightdale C, Montgomery E, Odze R, Tokar J, Kochman M. White Paper AGA: Advanced Imaging in Barrett's Esophagus. *Clin Gastroenterol Hepatol* 2015; **13**: 2209-2218 [PMID: 26462567 DOI: 10.1016/j.cgh.2015.09.017]

12 **Mendel R**, Ebigbo A, Probst A, Messmann H, Palm C. Barrett's Esophagus Analysis Using Convolutional Neural Networks. In: Bildverarbeitung für die Medizin. Springer, 2017: 80-85 [DOI: 10.1007/978-3-662-54345-0_23]

13 **Ebigbo A**, Mendel R, Probst A, Manzeneder J, Souza LA Jr, Papa JP, Palm C, Messmann H. Computer-aided diagnosis using deep learning in the evaluation of early oesophageal adenocarcinoma. *Gut* 2019; **68**: 1143-1145 [PMID: 30510110 DOI: 10.1136/gutjnl-2018-317573]

14 **Ebigbo A**, Mendel R, Probst A, Manzeneder J, Prinz F, de Souza LA Jr, Papa J, Palm C, Messmann H. Real-time use of artificial intelligence in the evaluation of cancer in Barrett's oesophagus. *Gut* 2020; **69**: 615-616 [PMID: 31541004 DOI: 10.1136/gutjnl-2019-319460]

15 **Horie Y**, Yoshio T, Aoyama K, Yoshimizu S, Horiuchi Y, Ishiyama A, Hirasawa T, Tsuchida T, Ozawa T, Ishihara S, Kumagai Y, Fujishiro M, Maetani I, Fujisaki J, Tada T. Diagnostic outcomes of esophageal cancer by artificial intelligence using convolutional neural networks. *Gastrointest Endosc* 2019; **89**: 25-32 [PMID: 30120958 DOI: 10.1016/j.gie.2018.07.037]

16 **Sharma P**, Hawes RH, Bansal A, Gupta N, Curvers W, Rastogi A, Singh M, Hall M, Mathur SC, Wani SB, Hoffman B, Gaddam S, Fockens P, Bergman JJ. Standard endoscopy with random biopsies versus narrow band imaging targeted biopsies in Barrett's oesophagus: a prospective, international, randomised controlled trial. *Gut* 2013; **62**: 15-21 [PMID: 22315471 DOI: 10.1136/gutjnl-2011-300962]

17 **Curvers WL**, van Vilsteren FG, Baak LC, Böhmer C, Mallant-Hent RC, Naber AH, van Oijen A, Ponsioen CY, Scholten P, Schenk E, Schoon E, Seldenrijk CA, Meijer GA, ten Kate FJ, Bergman JJ. Endoscopic trimodal imaging versus standard video endoscopy for detection of early Barrett's neoplasia: a multicenter, randomized, crossover study in general practice. *Gastrointest Endosc* 2011; **73**: 195-203 [PMID: 21168835 DOI: 10.1016/j.gie.2010.10.014]

18 **van der Sommen F**, Zinger S, Curvers WL, Bisschops R, Pech O, Weusten BL, Bergman JJ, de With PH, Schoon EJ. Computer-aided detection of early neoplastic lesions in Barrett's esophagus. *Endoscopy* 2016; **48**: 617-624 [PMID: 27100718 DOI: 10.1055/s-0042-105284]

19 **de Groof J**, van der Sommen F, van der Putten J, Struyvenberg MR, Zinger S, Curvers WL, Pech O, Meining A, Neuhaus H, Bisschops R, Schoon EJ, de With PH, Bergman JJ. The Argos project: The development of a computer-aided detection system to improve detection of Barrett's neoplasia on white light endoscopy. *United European Gastroenterol J* 2019; **7**: 538-547 [PMID: 31065371 DOI: 10.1177/2050640619837443]

20 **Swager AF**, de Groof AJ, Meijer SL, Weusten BL, Curvers WL, Bergman JJ. Feasibility of laser marking in Barrett's esophagus with volumetric laser endomicroscopy: first-in-man pilot study. *Gastrointest Endosc* 2017; **86**: 464-472 [PMID: 28161451 DOI: 10.1016/j.gie.2017.01.030]

21 **Swager AF**, Tearney GJ, Leggett CL, van Oijen MGH, Meijer SL, Weusten BL, Curvers WL, Bergman JJGHM. Identification of volumetric laser endomicroscopy features predictive for early neoplasia in Barrett's

esophagus using high-quality histological correlation. *Gastrointest Endosc* 2017; **85**: 918-926.e7 [PMID: 27658906 DOI: 10.1016/j.gie.2016.09.012]

22 **Evans JA**, Poneros JM, Bouma BE, Bressner J, Halpern EF, Shishkov M, Lauwers GY, Mino-Kenudson M, Nishioka NS, Tearney GJ. Optical coherence tomography to identify intramucosal carcinoma and high-grade dysplasia in Barrett's esophagus. *Clin Gastroenterol Hepatol* 2006; **4**: 38-43 [PMID: 16431303 DOI: 10.1053/S1542-3565(05)00746-9]

23 **Leggett CL**, Gorospe EC, Chan DK, Muppa P, Owens V, Smyrk TC, Anderson M, Lutzke LS, Tearney G, Wang KK. Comparative diagnostic performance of volumetric laser endomicroscopy and confocal laser endomicroscopy in the detection of dysplasia associated with Barrett's esophagus. *Gastrointest Endosc* 2016; **83**: 880-888.e2 [PMID: 26344884 DOI: 10.1016/j.gie.2015.08.050]

24 **Jemal A**, Bray F, Center MM, Ferlay J, Ward E, Forman D. Global cancer statistics. *CA Cancer J Clin* 2011; **61**: 69-90 [PMID: 21296855 DOI: 10.3322/caac.20107]

25 **Okumura S**, Yasuda T, Ichikawa H, Hiwa S, Yagi N, Hiroyasu T. Unsupervised Machine Learning Based Automatic Demarcation Line Drawing System on Nbi Images of Early GC. *Gastroenterology* 2019; **156**: S-937 [DOI: 10.1016/S0016-5085(19)39303-5]

26 **Quang T**, Schwarz RA, Dawsey SM, Tan MC, Patel K, Yu X, Wang G, Zhang F, Xu H, Anandasabapathy S, Richards-Kortum R. A tablet-interfaced high-resolution microendoscope with automated image interpretation for real-time evaluation of esophageal squamous cell neoplasia. *Gastrointest Endosc* 2016; **84**: 834-841 [PMID: 27036635 DOI: 10.1016/j.gie.2016.03.1472]

27 **Kodashima S**, Fujishiro M, Takubo K, Kammori M, Nomura S, Kakushima N, Muraki Y, Goto O, Ono S, Kaminishi M, Omata M. Ex vivo pilot study using computed analysis of endo-cytoscopic images to differentiate normal and malignant squamous cell epithelia in the oesophagus. *Dig Liver Dis* 2007; **39**: 762-766 [PMID: 17611178 DOI: 10.1016/j.dld.2007.03.004]

28 **Shin D**, Protano MA, Polydorides AD, Dawsey SM, Pierce MC, Kim MK, Schwarz RA, Quang T, Parikh N, Bhutani MS, Zhang F, Wang G, Xue L, Wang X, Xu H, Anandasabapathy S, Richards-Kortum RR. Quantitative analysis of high-resolution microendoscopic images for diagnosis of esophageal squamous cell carcinoma. *Clin Gastroenterol Hepatol* 2015; **13**: 272-279.e2 [PMID: 25066838 DOI: 10.1016/j.cgh.2014.07.030]

29 **Tokai Y**, Yoshio T, Aoyama K, Horie Y, Yoshimizu S, Horiuchi Y, Ishiyama A, Tsuchida T, Hirasawa T, Sakakibara Y, Yamada T, Yamaguchi S, Fujisaki J, Tada T. Application of artificial intelligence using convolutional neural networks in determining the invasion depth of esophageal squamous cell carcinoma. *Esophagus* 2020; **17**: 250-256 [PMID: 31980977 DOI: 10.1007/s10388-020-00716-x]

30 **Nakanishi H**, Doyama H, Ishikawa H, Uedo N, Gotoda T, Kato M, Nagao S, Nagami Y, Aoyagi H, Imagawa A, Kodaira J, Mitsui S, Kobayashi N, Muto M, Takatori H, Abe T, Tsujii M, Watari J, Ishiyama S, Oda I, Ono H, Kaneko K, Yokoi C, Ueo T, Uchita K, Matsumoto K, Kanesaka T, Morita Y, Katsuki S, Nishikawa J, Inamura K, Kinjo T, Yamamoto K, Yoshimura D, Araki H, Kashida H, Hosokawa A, Mori H, Yamashita H, Motohashi O, Kobayashi K, Hirayama M, Kobayashi H, Endo M, Yamano H, Murakami K, Koike T, Hirasawa K, Miyaoka Y, Hamamoto H, Hikichi T, Hanabata N, Shimoda R, Hori S, Sato T, Kodashima S, Okada H, Mannami T, Yamamoto S, Niwa Y, Yashima K, Tanabe S, Satoh H, Sasaki F, Yamazato T, Ikeda Y, Nishisaki H, Nakagawa M, Matsuda A, Tamura F, Nishiyama H, Arita K, Kawasaki K, Hoppo K, Oka M, Ishihara S, Mukasa M, Minamino H, Yao K. Evaluation of an e-learning system for diagnosis of gastric lesions using magnifying narrow-band imaging: a multicenter randomized controlled study. *Endoscopy* 2017; **49**: 957-967 [PMID: 28637065 DOI: 10.1055/s-0043-111888]

31 **Osawa H**, Yamamoto H. Present and future status of flexible spectral imaging color enhancement and blue laser imaging technology. *Dig Endosc* 2014; **26** Suppl 1: 105-115 [PMID: 24373002 DOI: 10.1111/den.12205]

32 **Osawa H**, Yamamoto H, Miura Y, Yoshizawa M, Sunada K, Satoh K, Sugano K. Diagnosis of extent of early gastric cancer using flexible spectral imaging color enhancement. *World J Gastrointest Endosc* 2012; **4**: 356-361 [PMID: 22912909 DOI: 10.4253/wjge.v4.i8.356]

33 **Kimura-Tsuchiya R**, Dohi O, Fujita Y, Yagi N, Majima A, Horii Y, Kitaichi T, Onozawa Y, Suzuki K, Tomie A, Okayama T, Yoshida N, Kamada K, Katada K, Uchiyama K, Ishikawa T, Takagi T, Handa O, Konishi H, Kishimoto M, Naito Y, Yanagisawa A, Itoh Y. Magnifying Endoscopy with Blue Laser Imaging Improves the Microstructure Visualization in Early Gastric Cancer: Comparison of Magnifying Endoscopy with Narrow-Band Imaging. *Gastroenterol Res Pract* 2017; **2017**: 8303046 [PMID: 28947900 DOI: 10.1155/2017/8303046]

34 **Yoshifuku Y**, Sanomura Y, Oka S, Kuroki K, Kurihara M, Mizumoto T, Urabe Y, Hiyama T, Tanaka S, Chayama K. Clinical Usefulness of the VS Classification System Using Magnifying Endoscopy with Blue Laser Imaging for Early Gastric Cancer. *Gastroenterol Res Pract* 2017; **2017**: 3649705 [PMID: 28596787 DOI: 10.1155/2017/3649705]

35 **Wu L**, Zhang J, Zhou W, An P, Shen L, Liu J, Jiang X, Huang X, Mu G, Wan X, Lv X, Gao J, Cui N, Hu S, Chen Y, Hu X, Li J, Chen D, Gong D, He X, Ding Q, Zhu X, Li S, Wei X, Li X, Wang X, Zhou J, Zhang M, Yu HG. Randomised controlled trial of WISENSE, a real-time quality improving system for monitoring blind spots during esophagogastroduodenoscopy. *Gut* 2019; **68**: 2161-2169 [PMID: 30858305 DOI: 10.1136/gutjnl-2018-317366]

36 **Miyaki R**, Yoshida S, Tanaka S, Kominami Y, Sanomura Y, Matsuo T, Oka S, Raytchev B, Tamaki T, Koide T, Kaneda K, Yoshihara M, Chayama K. Quantitative identification of mucosal gastric cancer under magnifying endoscopy with flexible spectral imaging color enhancement. *J Gastroenterol Hepatol* 2013; **28**: 841-847 [PMID: 23424994 DOI: 10.1111/jgh.12149]

37 **Kanesaka T**, Lee TC, Uedo N, Lin KP, Chen HZ, Lee JY, Wang HP, Chang HT. Computer-aided diagnosis for identifying and delineating early gastric cancers in magnifying narrow-band imaging. *Gastrointest Endosc* 2018; **87**: 1339-1344 [PMID: 29225083 DOI: 10.1016/j.gie.2017.11.029]

38 **Hirasawa T**, Aoyama K, Tanimoto T, Ishihara S, Shichijo S, Ozawa T, Ohnishi T, Fujishiro M, Matsuo K, Fujisaki J, Tada T. Application of artificial intelligence using a convolutional neural network for detecting gastric cancer in endoscopic images. *Gastric Cancer* 2018; **21**: 653-660 [PMID: 29335825 DOI: 10.1007/s10120-018-0793-2]

39 **Zhu Y**, Wang QC, Xu MD, Zhang Z, Cheng J, Zhong YS, Zhang YQ, Chen WF, Yao LQ, Zhou PH, Li QL. Application of convolutional neural network in the diagnosis of the invasion depth of gastric cancer based on conventional endoscopy. *Gastrointest Endosc* 2019; **89**: 806-815.e1 [PMID: 30452913 DOI: 10.1016/j.gie.2018.11.011]

40 **Cancer Genome Atlas Research Network**. Comprehensive molecular characterization of gastric adenocarcinoma. *Nature* 2014; **513**: 202-209 [PMID: 25079317 DOI: 10.1038/nature13480]

41 **Cristescu R**, Lee J, Nebozhyn M, Kim KM, Ting JC, Wong SS, Liu J, Yue YG, Wang J, Yu K, Ye XS, Do IG, Liu S, Gong L, Fu J, Jin JG, Choi MG, Sohn TS, Lee JH, Bae JM, Kim ST, Park SH, Sohn I, Jung SH, Tan P, Chen R, Hardwick J, Kang WK, Ayers M, Hongyue D, Reinhard C, Loboda A, Kim S, Aggarwal A. Molecular analysis of gastric cancer identifies subtypes associated with distinct clinical outcomes. *Nat Med* 2015; **21**: 449-456 [PMID: 25894828 DOI: 10.1038/nm.3850]

42 **Lee J**, An JY, Choi MG, Park SH, Kim ST, Lee JH, Sohn TS, Bae JM, Kim S, Lee H, Min BH, Kim JJ, Jeong WK, Choi DI, Kim KM, Kang WK, Kim M, Seo SW. Deep Learning-Based Survival Analysis Identified Associations Between Molecular Subtype and Optimal Adjuvant Treatment of Patients With Gastric Cancer. *JCO Clin Cancer Inform* 2018; **2**: 1-14 [PMID: 30652558 DOI: 10.1200/CCI.17.00065]

43 **Nilsaz-Dezfouli H**, Abu-Bakar MR, Arasan J, Adam MB, Pourhoseingholi MA. Improving Gastric Cancer Outcome Prediction Using Single Time-Point Artificial Neural Network Models. *Cancer Inform* 2017; **16**: 1176935116686062 [PMID: 28469384 DOI: 10.1177/1176935116686062]

44 **Parsonnet J**, Friedman GD, Vandersteen DP, Chang Y, Vogelman JH, Orentreich N, Sibley RK. Helicobacter pylori infection and the risk of gastric carcinoma. *N Engl J Med* 1991; **325**: 1127-1131 [PMID: 1891020 DOI: 10.1056/NEJM199110173251603]

45 **Uemura N**, Okamoto S, Yamamoto S, Matsumura N, Yamaguchi S, Yamakido M, Taniyama K, Sasaki N, Schlemper RJ. Helicobacter pylori infection and the development of gastric cancer. *N Engl J Med* 2001; **345**: 784-789 [PMID: 11556297 DOI: 10.1056/NEJMoa001999]

46 **Kato T**, Yagi N, Kamada T, Shimbo T, Watanabe H, Ida K; Study Group for Establishing Endoscopic Diagnosis of Chronic Gastritis. Diagnosis of Helicobacter pylori infection in gastric mucosa by endoscopic features: a multicenter prospective study. *Dig Endosc* 2013; **25**: 508-518 [PMID: 23369058 DOI: 10.1111/den.12031]

47 **Zheng W**, Zhang X, Kim JJ, Zhu X, Ye G, Ye B, Wang J, Luo S, Li J, Yu T, Liu J, Hu W, Si J. High Accuracy of Convolutional Neural Network for Evaluation of Helicobacter pylori Infection Based on Endoscopic Images: Preliminary Experience. *Clin Transl Gastroenterol* 2019; **10**: e00109 [PMID: 31833862 DOI: 10.14309/ctg.0000000000000109]

48 **Huang CR**, Sheu BS, Chung PC, Yang HB. Computerized diagnosis of Helicobacter pylori infection and associated gastric inflammation from endoscopic images by refined feature selection using a neural network. *Endoscopy* 2004; **36**: 601-608 [PMID: 15243882 DOI: 10.1055/s-2004-814519]

49 **Shichijo S**, Nomura S, Aoyama K, Nishikawa Y, Miura M, Shinagawa T, Takiyama H, Tanimoto T, Ishihara S, Matsuo K, Tada T. Application of Convolutional Neural Networks in the Diagnosis of Helicobacter pylori Infection Based on Endoscopic Images. *EBioMedicine* 2017; **25**: 106-111 [PMID: 29056541 DOI: 10.1016/j.ebiom.2017.10.014]

50 **Itoh T**, Kawahira H, Nakashima H, Yata N. Deep learning analyzes Helicobacter pylori infection by upper gastrointestinal endoscopy images. *Endosc Int Open* 2018; **6**: E139-E144 [PMID: 29399610 DOI: 10.1055/s-0043-120830]

51 **Nakashima H**, Kawahira H, Kawachi H, Sakaki N. Artificial intelligence diagnosis of *Helicobacter pylori* infection using blue laser imaging-bright and linked color imaging: a single-center prospective study. *Ann Gastroenterol* 2018; **31**: 462-468 [PMID: 29991891 DOI: 10.20524/aog.2018.0269]

52 **Maida M**, Macaluso FS, Ianiro G, Mangiola F, Sinagra E, Hold G, Maida C, Cammarota G, Gasbarrini A, Scarpulla G. Screening of colorectal cancer: present and future. *Expert Rev Anticancer Ther* 2017; **17**: 1131-1146 [PMID: 29022408 DOI: 10.1080/14737140.2017.1392243]

53 **Winawer SJ**, Zauber AG, Ho MN, O'Brien MJ, Gottlieb LS, Sternberg SS, Waye JD, Schapiro M, Bond JH, Panish JF. Prevention of colorectal cancer by colonoscopic polypectomy. The National Polyp Study Workgroup. *N Engl J Med* 1993; **329**: 1977-1981 [PMID: 8247072 DOI: 10.1056/NEJM199312303292701]

54 **Patel SG**, Ahnen DJ. Prevention of interval colorectal cancers: what every clinician needs to know. *Clin Gastroenterol Hepatol* 2014; **12**: 7-15 [PMID: 23639602 DOI: 10.1016/j.cgh.2013.04.027]

55 **Pohl H**, Robertson DJ. Colorectal cancers detected after colonoscopy frequently result from missed lesions. *Clin Gastroenterol Hepatol* 2010; **8**: 858-864 [PMID: 20655393 DOI: 10.1016/j.cgh.2010.06.028]

56 **Corley DA**, Levin TR, Doubeni CA. Adenoma detection rate and risk of colorectal cancer and death. *N Engl J Med* 2014; **370**: 2541 [PMID: 24963577 DOI: 10.1056/NEJMc1405329]

57 **Anderson JC**, Butterly LF. Colonoscopy: quality indicators. *Clin Transl Gastroenterol* 2015; **6**: e77 [PMID: 25716302 DOI: 10.1038/ctg.2015.5]

58 **Maida M**, Camilleri S, Manganaro M, Garufi S, Scarpulla G. New endoscopy advances to refine adenoma detection rate for colorectal cancer screening: None is the winner. *World J Gastrointest Oncol* 2017; **9**: 402-406 [PMID: 29085566 DOI: 10.4251/wjgo.v9.i10.402]

59 **Bond A**, Sarkar S. New technologies and techniques to improve adenoma detection in colonoscopy. *World J Gastrointest Endosc* 2015; **7**: 969-980 [PMID: 26265990 DOI: 10.4253/wjge.v7.i10.969]

60 **Waldmann E**, Britto-Arias M, Gessl I, Heinze G, Salzl P, Sallinger D, Trauner M, Weiss W, Ferlitsch A, Ferlitsch M. Endoscopists with low adenoma detection rates benefit from high-definition endoscopy. *Surg Endosc* 2015; **29**: 466-473 [PMID: 25005016 DOI: 10.1007/s00464-014-3688-2]

61 **Urban G**, Tripathi P, Alkayali T, Mittal M, Jalali F, Karnes W, Baldi P. Deep Learning Localizes and Identifies Polyps in Real Time With 96% Accuracy in Screening Colonoscopy. *Gastroenterology* 2018; **155**: 1069-1078.e8 [PMID: 29928897 DOI: 10.1053/j.gastro.2018.06.037]

62 **Misawa M**, Kudo SE, Mori Y, Cho T, Kataoka S, Yamauchi A, Ogawa Y, Maeda Y, Takeda K, Ichimasa K, Nakamura H, Yagawa Y, Toyoshima N, Ogata N, Kudo T, Hisayuki T, Hayashi T, Wakamura K, Baba T, Ishida F, Itoh H, Roth H, Oda M, Mori K. Artificial Intelligence-Assisted Polyp Detection for Colonoscopy: Initial Experience. *Gastroenterology* 2018; **154**: 2027-2029.e3 [PMID: 29653147 DOI: 10.1053/j.gastro.2018.04.003]

63 **Guizard N**, Ghalehjegh SH, Henkel M, Ding L, Shahidi N, Jonathan GRP, Lahr RE, Chandelier F, Rex D, Byrne MF. Artificial Intelligence for Real-Time Multiple Polyp Detection with Identification, Tracking, and Optical Biopsy During Colonoscopy. *Gastroenterology* 2019; **156**: S-48 [DOI: 10.1016/S0016-5085(19)36900-8]

64 **Wang P**, Berzin TM, Glissen Brown JR, Bharadwaj S, Becq A, Xiao X, Liu P, Li L, Song Y, Zhang D, Li Y, Xu G, Tu M, Liu X. Real-time automatic detection system increases colonoscopic polyp and adenoma detection rates: a prospective randomised controlled study. *Gut* 2019; **68**: 1813-1819 [PMID: 30814121 DOI: 10.1136/gutjnl-2018-317500]

65 **Klare P**, Sander C, Prinzen M, Haller B, Nowack S, Abdelhafez M, Poszler A, Brown H, Wilhelm D, Schmid RM, von Delius S, Wittenberg T. Automated polyp detection in the colorectum: a prospective study (with videos). *Gastrointest Endosc* 2019; **89**: 576-582.e1 [PMID: 30342029 DOI: 10.1016/j.gie.2018.09.042]

66 **Byrne MF**, Chapados N, Soudan F, Oertel C, Linares Pérez M, Kelly R, Iqbal N, Chandelier F, Rex DK. Real-time differentiation of adenomatous and hyperplastic diminutive colorectal polyps during analysis of unaltered videos of standard colonoscopy using a deep learning model. *Gut* 2019; **68**: 94-100 [PMID: 29066576 DOI: 10.1136/gutjnl-2017-314547]

67 **Lui TKL**, Yee K, Wong K, Leung WK. Artificial Intelligence Image Classifier Based on Nonoptical Magnified Images Accurately Predicts Histology and Endoscopic Resectability of Different Colonic Lesions. *Gastroenterology* 2019; **156**: S-48 [DOI: 10.1016/S0016-5085(19)36899-4]

68 **Lui TKL**, Wong KKY, Mak LLY, Ko MKL, Tsao SKK, Leung WK. Endoscopic prediction of deeply submucosal invasive carcinoma with use of artificial intelligence. *Endosc Int Open* 2019; **7**: E514-E520 [PMID: 31041367 DOI: 10.1055/a-0849-9548]

69 **Hotta K**, Kudo S, Mori Y, Ikematsu H, Saito Y, Ohtsuka K, Misawa M, Itoh H, Oda M, Mori K. Computer-Aided Diagnosis For Small Colorectal Lesions: A Multi-Center Validation "Endobrain Study" Designed To Obtain Regulatory Approval. *Gastrointest Endosc* 2019; **89**: AB76 [DOI: 10.1016/j.gie.2019.04.051]

70 **Mori Y**, Kudo SE, Misawa M, Saito Y, Ikematsu H, Hotta K, Ohtsuka K, Urushibara F, Kataoka S, Ogawa Y, Maeda Y, Takeda K, Nakamura H, Ichimasa K, Kudo T, Hayashi T, Wakamura K, Ishida F, Inoue H, Itoh H, Oda M, Mori K. Real-Time Use of Artificial Intelligence in Identification of Diminutive Polyps During Colonoscopy: A Prospective Study. *Ann Intern Med* 2018; **169**: 357-366 [PMID: 30105375 DOI: 10.7326/M18-0249]

71 **Su JR**, Li Z, Shao XJ, Ji CR, Ji R, Zhou RC, Li GC, Liu GQ, He YS, Zuo XL, Li YQ. Impact of a real-time automatic quality control system on colorectal polyp and adenoma detection: a prospective randomized controlled study (with videos). *Gastrointest Endosc* 2020; **91**: 415-424.e4 [PMID: 31454493 DOI: 10.1016/j.gie.2019.08.026]

72 **Peng JH**, Fang YJ, Li CX, Ou QJ, Jiang W, Lu SX, Lu ZH, Li PX, Yun JP, Zhang RX, Pan ZZ, Wan de S. A scoring system based on artificial neural network for predicting 10-year survival in stage II A colon cancer patients after radical surgery. *Oncotarget* 2016; **7**: 22939-22947 [PMID: 27008710 DOI: 10.18632/oncotarget.8217]

73 **Bibault JE**, Giraud P, Housset M, Durdux C, Taieb J, Berger A, Coriat R, Chaussade S, Dousset B, Nordlinger B, Burgun A. Deep Learning and Radiomics predict complete response after neo-adjuvant chemoradiation for locally advanced rectal cancer. *Sci Rep* 2018; **8**: 12611 [PMID: 30135549 DOI: 10.1038/s41598-018-30657-6]

74 **Le Berre C**, Sandborn WJ, Aridhi S, Devignes MD, Fournier L, Smaïl-Tabbone M, Danese S, Peyrin-Biroulet L. Application of Artificial Intelligence to Gastroenterology and Hepatology. *Gastroenterology* 2020; **158**: 76-94.e2 [PMID: 31593701 DOI: 10.1053/j.gastro.2019.08.058]

75 **Yang YJ**, Bang CS. Application of artificial intelligence in gastroenterology. *World J Gastroenterol* 2019; **25**: 1666-1683 [PMID: 31011253 DOI: 10.3748/wjg.v25.i14.1666]

76 **England JR**, Cheng PM. Artificial Intelligence for Medical Image Analysis: A Guide for Authors and Reviewers. *AJR Am J Roentgenol* 2019; **212**: 513-519 [PMID: 30557049 DOI: 10.2214/AJR.18.20490]

77 **Schaffer J**. What Not to Multiply Without Necessity. *Australas J Philos* 2015; **93**: 644–664 [DOI: 10.1080/00048402.2014.992447]

78 **Everitt BS**, Skrondal A. Cambridge Dictionary of Statistics. Cambridge: Cambridge University Press, 2010

79 **Park SH**, Han K. Methodologic Guide for Evaluating Clinical Performance and Effect of Artificial Intelligence Technology for Medical Diagnosis and Prediction. *Radiology* 2018; **286**: 800-809 [PMID: 29309734 DOI: 10.1148/radiol.2017171920]

AIGE Artificial Intelligence in Gastrointestinal Endoscopy

Submit a Manuscript: https://www.f6publishing.com

Artif Intell Gastrointest Endosc 2020 July 28; 1(1): 19-27

DOI: 10.37126/aige.v1.i1.19

ISSN 2689-7164 (online)

MINIREVIEWS

Techniques to integrate artificial intelligence systems with medical information in gastroenterology

Hong-Yu Jin, Man Zhang, Bing Hu

ORCID number: Hong-Yu Jin 0000-0001-6585-825X; Man Zhang 0000-0002-7391-946X; Bing Hu 0000-0002-9898-8656.

Author contributions: Jin HY and Hu B contributed to the conceptualization of the study; Jin HY, and Zhang M contributed to data curation, investigation, methodology, and software; Jin HY drafted the manuscript; Zhang M contributed to the formal analysis; Hu B contributed to the funding acquisition; project administration, resources and supervision; Jin HY, Zhang M, and Hu B reviewed and edited the manuscript.

Conflict-of-interest statement: None declared.

Hong-Yu Jin, Department of Liver Surgery, Liver Transplantation Center, West China Hospital, Sichuan University, Chengdu 610041, Sichuan Province, China

Man Zhang, Department of Gynecology and Obstetrics, West China Second University Hospital, Sichuan University, Chengdu 610041, Sichuan Province, China

Bing Hu, Department of Gastroenterology, Endoscopy Center, West China Hospital, Sichuan University, Chengdu 610041, Sichuan Province, China

Corresponding author: Bing Hu, MBBS, MD, Professor, Department of Gastroenterology, Endoscopy Center, West China Hospital, Sichuan University, No. 37, Guoxue Lane, Wuhou District, Chengdu 610041, Sichuan Province, China. hubingnj@163.com

Abstract

Gastrointestinal (GI) endoscopy is the central element in contemporary gastroenterology as it provides direct evidence to guide targeted therapy. To increase the accuracy of GI endoscopy and to reduce human-related errors, artificial intelligence (AI) has been applied in GI endoscopy, which has been proved to be effective in diagnosing and treating numerous diseases. Therefore, we review current research on the efficacy of AI-assisted GI endoscopy in order to assess its functions, advantages and how the design can be improved.

Key words: Gastrointestinal endoscopy; Artificial intelligence; Diagnosis; Advantages

Core tip: Artificial intelligence (AI) has been the center of medical information in the 21st century and we have witnessed the tremendous change it has triggered in the diagnosis and treatment of many diseases. Gastrointestinal endoscopy is the core element of clinical procedures in modern gastroenterology as it provides direct evidence and guides precise diagnosis and treatment. Therefore, in this article, we review the latest findings on AI-assisted gastrointestinal endoscopy concerning its applications in the diagnosis and treatment of gastrointestinal diseases.

Citation: Jin HY, Zhang M, Hu B. Techniques to integrate artificial intelligence systems with medical information in gastroenterology. *Artif Intell Gastrointest Endosc* 2020; 1(1): 19-27

Manuscript source: Invited manuscript

Received: June 27, 2020
Peer-review started: June 27, 2020
First decision: July 3, 2020
Revised: July 7, 2020
Accepted: July 15, 2020
Article in press: July 15, 2020
Published online: July 28, 2020

P-Reviewer: Cabezuelo AS, Morozov S
S-Editor: Wang JL
L-Editor: Webster JR
E-Editor: Li JH

URL: https://www.wjgnet.com/2689-7164/full/v1/i1/19.htm
DOI: https://dx.doi.org/10.37126/aige.v1.i1.19

INTRODUCTION

The 21st century has witnessed a tremendous revolution in life sciences. Targets within cells are increasingly being found so that targeted therapiesc, which will provide the maximum benefits while causing minimum or even no damage, are available to treat difficult miscellaneous diseases; hereditary information is continuously being deciphered in order that much more in-depth information on the mechanism of disease occurrence and progression can be established and interpreted. In addition, the first 20 years of the 21st century has also experienced the combination of computer science and clinical medicine, or what we call the application of artificial intelligence (AI) in the diagnosis and treatment of diseases. With the help of machine learning and deep learning algorithms, the sensitivity and specificity of diagnosis involving morphological judgement has rapidly increased, such as the diagnosis of diabetic retinopathy and breast cancer screening using mammography[1-3]. Moreover, incorporated with convoluted neural network (CNN) technology, automated classification of the condition of skin lesions is even possible by experts from a distance[4]. Thus, with the development of network technology to change from 4G network to 5G or an even more advanced network, the addition of AI in medicine will play a more important role in helping clinicians to more accurately combat diseases[5].

The diagnosis and treatment in gastrointestinal (GI) diseases has become more accurate and evidence-based since the popularization of GI endoscopy, which helps detect early-stage lesions and malignancies and thus guide the subsequent intervention[6]. In addition, GI endoscopy also contributes to the removal of early-stage lesions, which results in minuscule operative wounds and prevents further malignant change[7]. However, despite the fact that an increasing number of physicians are trained to operate a GI endoscope, a number of mis-diagnoses are reported annually due to physicians' incompetence, carelessness and visual fatigue[8]. AI-assisted GI endoscopy has been proved to have considerable potential in reducing the number of errors in order to optimize clinical performance by establishing a more suitable treatment strategy and improving long-term prognosis. As many clinical studies have been carried out in recent years, some of the basic disciplines and information concerning the area are known; however, global research is still in a very early phase[9]. Gastroenterology is regarded as a field where AI could have a significant impact and shape the future diagnosis and treatment pattern as both rely greatly on image- or video-based investigations[10]. Some of the research carried out so far has demonstrated that AI-guided endoscopy provides more solid evidence of suspicious neoplasia during examinations and assists optical biopsy to determine the features of lesions and subsequently integrate genomic and epigenomic information to provide optimal therapeutic plans[11]. Therefore, this review aims to summarize high-quality studies completed so far in order to assess the efficiency of the latest AI technology incorporated into GI endoscopy and determine how this technology can be improved.

THE ROLE OF AI IN GI ENDOSCOPY

To date, AI has proved efficient in aiding endoscopic examination and the treatment of GI lesions with high sensitivity, specificity and a successful treatment rate. These lesions include polyps, acute bleeding, precursor lesions and early-stage malignant tumors, especially tumors invading the mucosal and submucosal layers[12]. Without AI, observer variation and errors due to limited experience and expertise occur every now and then. AI-assisted GI endoscopy, is believed to largely reduce these errors and prevent visual fatigue. Among its applications, AI-guided identification and characterization of polyps is the earliest established and the best understood[13]. A team of physicians reported that their AI-guided model could not only accurately recognize the presence of polyps, but could also distinguish hyperplastic and adenomatous polyps based on the assessment of video images under GI endoscopy with a high sensitivity of 98% and a relatively satisfactory specificity of 83%. Their study indicated that AI-guided GI endoscopy was unlikely to miss possible malignant lesions[14]. Misawa *et al*[15] reported that AI-guided endoscopic optical biopsy based on the

EndoBRAIN system could identify and characterize the pathological features of polyps with the aid of indigo carmine dye. If this technology was further improved, it could increase the detection rate of small polyps as well as judge their pathological features, which could lead to correct decision-making regarding resection of the polyps[15]. Similarly, another team used a different algorithm based on CNN to train an AI system using archived images from endoscopic videos. Their test results indicated that the accuracy was as high as 96.4% with an area under the curve (AUC) of the receiver operating characteristics (ROC) of 0.991. They even found that AI-guided GI endoscopy was capable of identifying small adenomas of 1-3 and 4-6 mm in size, and that the number of polyps identified by AI-guided GI endoscopy was much higher than that identified by human-operated GI endoscopy[16]. In 2019, a research group also demonstrated that AI-guided GI endoscopy showed higher efficiency in detecting small adenomas. This research group conducted an open and non-blinded trial with over 1000 patients, who were later randomly divided into 2 groups who underwent GI endoscopy with or without the aid of AI. It was found that AI-guided GI endoscopy increased the identification rate from 20.3% to 29.1% and increased the number of identified adenomas from 0.31 to 0.53 per patient. However, in this study, GI endoscopy with and without AI showed no difference when examining patients with diminutive polyps, as human eyes were also unlikely to miss such apparent lesions[17]. Interestingly, AI-guided GI endoscopy was found to be even more efficient when used by less competent endoscopists and it was reported to be able to increase the skills of these physicians, which might be of significant help in continuous education and promote the popularization of GI endoscopy[18]. Besides the detection of polyps, AI experts along with physicians are now able to detect pre-malignant or early-stage malignant lesions in the GI tract using the latest AI technology, which was a huge challenge as senior endoscopists would sometimes mistakenly ignore such tiny mucosal or submucosal changes[19]. According to a recent study, when used to detect gastric precursor and early-stage malignancy, AI-guided GI endoscopy had the capability of less diagnostic time but resulted in greater sensitivity (65.6% *vs* 31.9%) and a higher positive predictive value (PPV) (41.9% *vs* 36.7%) compared with the naked eye[20]. With the increased prevalence of gastroesophageal junctional diseases, such as gastroesophageal reflux disease and others, gastroesophageal junctional adenocarcinoma has been the focus of attention in many gastroenterologists. AI-guided GI endoscopy was demonstrated to be effective in aiding physicians to detect underlying problems in the gastroesophageal junction and judge their pathological features. Moreover, some technologies have even made it possible for an AI-guided endoscopic resection for early-stage lesions in the gastroesophageal area[21]. In addition to the identification of neoplasms and their pathological features, some recent AI-assisted programs have made it possible to evaluate the depth of cancer invasion, which is of great help to clinicians as the invasion depth is difficult to evaluate with the naked eye. A team in Japan demonstrated that by using white light imaging (WLI) and narrow-band imaging (NBI), an AI system could be trained to differentiate superficial and deep invasion of esophageal squamous cell carcinoma (ESCC) within several seconds and with an accuracy of more than 80%[22]. Besides the determination of invasion depth, another team found that AI could actually define the benign and malignant borderline and subsequently help guide endoscopic dissection[23]. Moreover, the ability to judge whether the dissection completely removed the suspected malignancy has contributed greatly to planning subsequent therapy. Therefore, if these technologies could be further validated and developed, AI-guided GI endoscopy could have greater application potential.

URGENT NEED FOR AI-GUIDED ESOPHAGOGASTRODUODENOSCOPY

With the popularization of esophagogastroduodenoscopy (EGD), it is now possible to detect stomach lesions at an early stage. However, as early-stage lesions are much more insidious in terms of size, morphology and biological activity, the efficiency varied with the competence of endoscopists as long-term specialized training is mandatory to gain the expertise and experience needed to detect insidious precursor lesions[24]. This was confirmed by a series of statistics reporting that the rate of mis-diagnosis of upper GI lesions was around 15% over the last 3 years mainly due to human factors[25,26]. To resolve this problem, AI-guided GI endoscopy was invented to reduce the possibility of human-related errors. However, since GI endoscopy carried more uncertainty and anatomical variations, the application of AI in GI endoscopy has been difficult[27].

AI-GUIDED EGD IN DEFINING GI MALIGNANCIES

One of the milestones of EGD is that it has made it possible to detect and resect precursor cancerous tissue and so prevent traditional surgical resection which would produce massive tissue damage. Thus, there was always an urgent need to increase the sensitivity, specificity and accuracy for the detection of precursor cancerous lesions under EGD. The first attempt to combine AI and EGD was by a Japanese scholar who trained his system with WLIs, NBIs and chromoendoscopy based on indigo carmine. Validation with 2296 images provided a sensitivity of 92.2% and a PPV of 30.6%[28,29]. Therefore, this indicated that despite a satisfactory detectable rate, it might also produce a large number of false positive results, thus aggravate the social medical burden. Another Japanese team evaluated a CNN-based model trained using an endoscopic video and reported a sensitivity of 94.1%[20,30]. A Japanese team attempted to diagnose *Helicobacter pylori* (*H. pylori*)-related gastritis based on WLIs, NBIs and chromoendoscopy images and videos, and demonstrated a sensitivity and specificity of 81.9% and 83.4%, respectively[31]. A study validated the performance of their AI-guided model using 100 defined gastric cancer examination videos and 100 non-gastric cancer examination videos and found a sensitivity of 94.0%, a specificity of 91.0% and an accuracy of 92.5%[32]. A multicenter study validated the capability of their AI-guided diagnosis system using 7 validation sets collected from over 10 different hospitals to detect upper and lower GI tract tumors. The reported accuracy was between 91.5% and 97.7% with regard to different validation subsets[33]. They also compared the performance of their AI-guided GI endoscopy to the results of senior experienced physicians and junior physicians working in minor hospitals, which indicated that the AI-guided system could achieve comparative sensitivity to that of the experts (94.2% *vs* 94.5%) and could exceed that of junior physicians (94.2% *vs* 72.2%). Considering that most patients would consult outside of advanced or national hospitals, the help provided by AI-guided systems is necessary in minor hospitals to ensure diagnostic accuracy. Kanesaka *et al*[34] trained an AI system with the help of NBIs and successfully achieved an accuracy of 96%. Besides the aforementioned studies, other studies have also reported high accuracy and sensitivity for the detection of early-stage lesions using AI systems trained using magnified NBIs, which seem to be the future direction[35]. According to some other reports, AI-guided GI endoscopy was not only able to detect early-stage lesions, but was also capable of characterizing their features, such as invasion depth or biological activities. For example, an AI-guided system was used to estimate the invasion depth and the accuracy was 89.16%, which was much higher than that by humans[36,37]. Our team also attempted to build an AI-assisted automated system for the diagnosis of precancerous lesions and ESCC by training the system using 6473 NBIs images and 47 video datasets. Our findings demonstrated that the AI system involving deep learning could achieve a sensitivity of 98.04% and a specificity of 95.03% when distinguishing between ESCC and non-cancerous lesions[38].

AI-GUIDED EDG IN DEFINING OTHER GI DISORDERS

Besides defining early GI tumors, AI is also able to determine other benign gastric disorders, such as chronic non-atrophic gastritis, gastric and duodenal ulcers, *etc*. Among these, the most well-known is the ability to recognize *H. pylori* gastritis, which has been widely discussed. In 2020, Lui *et al*[39] carried out a meta-analysis involving 23 studies including 969318 images. They pointed out that the AUC for AI detection of Barrett's esophagus, neoplastic lesions in the stomach, squamous esophagus and *H. pylori* infection state were 0.96 (95%CI: 0.93-0.99), 0.96 (95%CI: 0.93-0.99), 0.88 (95%CI: 0.82-0.96) and 0.92 (95%CI: 0.88-0.97), respectively[39,40]. They also pointed out that by using NBIs, the AI system was superior to white light with regard to the detection of neoplastic lesions of the esophagus (0.92 *vs* 0.83, $P < 0.001$). Moreover, they reported a superior performance of the AI system over the human eye in detecting neoplastic lesions in the stomach (AUC 0.98 *vs* 0.87, $P < 0.001$), Barrett's esophagus (AUC 0.96 *vs* 0.82, $P < 0.001$) and *H. pylori* state (AUC 0.90 *vs* 0.82, $P < 0.001$)[41,42]. Earlier this year, Xia *et al*[43] developed a new automatic lesion detection system using CNN and faster region-based CNN (Faster-RCNN) and a total of 1023955 MCE images were used to train the AI system and help validate it, including erosion, polyps, ulcers, submucosal tumors, xanthomas, normal mucosa, and invalid images. They found that their AI system could detect gastric lesions with a sensitivity of 96.2% (95%CI: 95.7%-96.5%), a specificity of 76.3% (95%CI: 75.97%-76.3%), a PPV of 16.0% (95%CI: 15.7%-16.3%), a

negative predictive value (NPV) of 99.7% (95%CI: 99.74%-99.79%). They also demonstrated the accuracy for each type of lesion, the accuracy for erosion was 77.1% (95%CI: 76.9%-77.3%), the accuracy for polyps was 96.5%, the accuracy for ulcers was 89.3%, the accuracy for submucosal tumors was 87.2%, the accuracy for xanthomas was 90.6%, the accuracy for normal tissues was 67.8% and the accuracy for invalid images was 96.1%[43,44]. Their study also showed that the AI system was likely to indicate problems during an endoscopy examination rather than determine that it was normal. Another team also performed a validation test using an AI model based on WLIs and reported a sensitivity of 86.7%[45,46]. In addition, they pointed out that AI-guided GI endoscopy met difficult problems when trying to define benign lesions compared with malignant lesions as the stomach is often inflamed and even eroded which could add to the difficulty in making a definite diagnosis. Another study also reported the diagnostic value of AI-guided GI endoscopy based on CNN technology with an accuracy of 92.9%detected[47]. Some scientists have started to optimize the AI system by introducing blue light imaging and linked color imaging techniques, and have compared their efficiencies with single WLI. The results showed that the AUCs of ROC analysis of blue light imaging, linked light imaging and WLI were 0.96, 0.95 and 0.66, respectively, which indicated that the newly introduced technologies could enhance the examination findings[45]. In addition to defining *H. pylori*-related gastritis, deep learning technology has also helped physicians to detect and evaluate gastric and duodenal ulcers and predict their prognosis[40,48]. With regard to polyps, contemporary AI technology is able to precisely detect polyps, make an accurate classification based on histology, predict the possibility of disease progression and guide subsequent treatment. In the past, older models of computer-aided diagnosis could not analyze polyps in real-time, which resulted in the diagnosis of polyps being challenging. A scientific team designed an AI model with the capability of analyzing nearly 100 images a second which greatly increased the speed of machine reading as the previous model was only able to process fewer than 10 images a second[49]. In addition, the technology they applied allowed their model to achieve an accuracy of up to 96.4% when detecting polyps among 8641 images of 2000 patients. Later, similar models were designed and used to compare the detection efficiency between experts only and experts with the help of AI systems. The results demonstrated that the AI system was able to detect all polyps, which were also identified by the experts with a 7% false positive rate. Moreover, the AI system extracted 9 other insidious polyps which were not detected by the naked eye[50]. In addition, scientists developed a more advanced model based on deep learning which could determine the histological features of polyps. This team found that with the help of NBIs, the AI diagnostic model could achieve an accuracy of 95% while restricting the NPV value within the limit set by the Preservation and Incorporation of Valuable Endoscopic Innovations for Adenoma Assessment of Diminutive Adenomas[51]. One of the major purposes of AI-guided GI endoscopy was to reduce human-related factors as much as possible, and to maintain a stable sensitivity, specificity and accuracy regardless of the expertise of the operator. One AI model presented by Mori *et al*[18] demonstrated that the application of AI systems for real-time histological classification based on NBI or staining and magnification with an integrated endoscopy lens provided NPV rates of > 92 for distal diminutive lesions, which was not related to the operators' expertise. In addition, full evaluation of the polyps could be done within a minute. The detailed information of some studies concerning the diagnosis of polyps and neoplasms in the GI tract published after 2018 is shown in Table 1.

DISCUSSION

From the studies we have researched and analyzed in depth so far, we have found that by incorporating several AI technologies, GI endoscopy has achieved higher accuracy, faster diagnostic speed, and fewer human-related errors, *etc*. Firstly, AI technology has made it possible to eliminate the errors caused by doctors' incompetence and lack of experience and has guided junior doctors and doctors working in less prestigious hospitals to gain the necessary expertise. Secondly, this technology improves the relevance rate and recall factor of less obvious and less typical lesions due to their size or atypical shape and helps to achieve "early discovery and early treatment". Thirdly, the present AI technology is able to assist judgement in a number of lesion types including polyps, precursor changes in tumors, all types of mucosal and submucosal abnormalities, and inflammation, *etc*., which almost covers the disease spectrum of the GI tract. Thus, it can be concluded that as a diagnostic tool, AI greatly contributes to

Table 1 Detailed information on the studies concerning the diagnosis of polyps and neoplasms in the gastrointestinal tract published after 2018

Ref.	Training	Validation	AUC	Sensitivity	Accuracy
Chen *et al*[51], 2018	1476 images of neoplasms; 681 images of *H. pylori*	188 images of neoplasms; 96 images of *H. pylori*	NA	96.3%	90.1%
Urban *et al*[16], 2018	8641 images; 9 videos	1330 images; 9 videos	0.974	NA	96.4%
Misawa *et al*[15], 2018	73 videos	Cross validation	NA	90%	76.5%
Yamada *et al*[56], 2019	4087 images of polyps; videos	705 images with polyps; 4135 images without polyps	0.975	97.3%	NA
Klare *et al*[57], 2019	NA	55 colonoscopy examination videos	NA	75.3%	NA
Wang *et al*[17], 2019	3634 images with polyps; 1911 images without polyps	5541 images with polyps and 21572 images without polyps	0.984	94.4%	NA
Song *et al*[58], 2020	12480 images	545 images	0.93	82.1%	81.3%
Zachariah *et al*[59], 2020	8246 images	634 images	NA	96%	94%

H. pylori: Helicobacter pylori; AUC: Area under curve; NA: Not applicable.

the work of clinical physicians.

However, studies concerning the guidance of AI during treatment under GI endoscopy have rarely been published and trials on training AI systems to gain the ability to direct the resection of malformations have seldom been discussed. One of the major advantages of GI endoscopy is that it allows the resection of abnormalities to be performed in a minimally invasive way, which results in less damage than traditional surgery or laparoscopic surgery, AI guided-treatment under GI endoscopy should be further developed and discussed. Moreover, an AI-guided robot physician may even be possible when AI is trained to guide such a process.

CONCLUSION

The last decade has witnessed a number of studies concerning the application of AI in modern medical procedures. However, due to specific reasons, there is an obvious lack of high-quality prospective clinical trials. In fact, despite the large number of clinical studies published so far, only 6 were prospective randomized controlled trials (RCTs) that were focused on the efficiency and effects of AI-guided models[17]. Far fewer RCTs have emphasized the comparison between machines and the human eye. Gastroenterology has always led RCTs concerning AI, and of the abovementioned 6 RCTs concerning AI in medical fields, 5 of them are related to gastroenterology. Therefore, more RCTs should be planned and carried out to gain more reliable data[52]. To perform effective RCTs, a series of protocols and rules should be strictly followed. For instance, the optimal study design approaches for clinical trials of AI have been put forward and these recommendations have significant implications for GI endoscopy. Clinically-related outcome measures should be prespecified according to the way the AI model is being investigated. Moreover, AI-assisted polyp detection studies should apply validated outcome parameters such as adenoma detection rate, adenomas per colonoscopy, or adenoma miss rate, *etc*[53-55].

The next couple of years will witness a tremendous change in the medical field with the ever-accelerating development of AI technologies, in which the field of gastroenterology will be the center of such unprecedented change. With the advancement of AI technology, more high-quality RCTs should be designed and carried out to assess the technologies being developed and to correct any errors. In addition, standardized methods that contribute to the storage, organization and labeling of clinical images should also be the focus of attention.

REFERENCES

1 **Kaul V**, Enslin S, Gross SA. The history of artificial intelligence in medicine. *Gastrointest Endosc* 2020 [PMID: 32565184 DOI: 10.1016/j.gie.2020.06.040]

2 **McCoy LG**, Nagaraj S, Morgado F, Harish V, Das S, Celi LA. What do medical students actually need to know about artificial intelligence? *NPJ Digit Med* 2020; **3**: 86 [PMID: 32577533 DOI: 10.1038/s41746-020-0294-7]

3 **Lal A**, Pinevich Y, Gajic O, Herasevich V, Pickering B. Artificial intelligence and computer simulation models in critical illness. *World J Crit Care Med* 2020; **9**: 13-19 [PMID: 32577412 DOI: 10.5492/wjccm.v9.i2.13]

4 **Namikawa K**, Hirasawa T, Nakano K, Ikenoyama Y, Ishioka M, Shiroma S, Tokai Y, Yoshimizu S, Horiuchi Y, Ishiyama A, Yoshio T, Tsuchida T, Fujisaki J, Tada T. Artificial intelligence-based diagnostic system classifying gastric cancer and ulcer: Comparison between the original and newly developed systems. *Endoscopy* 2020 [PMID: 32503056 DOI: 10.1055/a-1194-8771]

5 **Namikawa K**, Hirasawa T, Yoshio T, Fujisaki J, Ozawa T, Ishihara S, Aoki T, Yamada A, Koike K, Suzuki H, Tada T. Utilizing artificial intelligence in endoscopy: a clinician's guide. *Expert Rev Gastroenterol Hepatol* 2020; 1-18 [PMID: 32500760 DOI: 10.1080/17474124.2020.1779058]

6 **Sung JJY**, Poon NCH. Artificial intelligence in gastroenterology: where are we heading? *Front Med* 2020 [PMID: 32458189 DOI: 10.1007/s11684-020-0742-4]

7 **Kahn A**, Leggett CL. Artificial intelligence in the age of cognitive endoscopy. *Gastrointest Endosc* 2020; **91**: 1251-1252 [PMID: 32439096 DOI: 10.1016/j.gie.2020.03.009]

8 **Shung DL**, Byrne MF. How Artificial Intelligence Will Impact Colonoscopy and Colorectal Screening. *Gastrointest Endosc Clin N Am* 2020; **30**: 585-595 [PMID: 32439090 DOI: 10.1016/j.giec.2020.02.010]

9 **Parasa S**, Wallace M, Bagci U, Antonino M, Berzin T, Byrne M, Celik H, Farahani K, Golding M, Gross S, Jamali V, Mendonca P, Mori Y, Ninh A, Repici A, Rex D, Skrinak K, Thakkar SJ, van Hooft JE, Vargo J, Yu H, Xu Z, Sharma P. Proceedings from the First Global Artificial Intelligence in Gastroenterology and Endoscopy Summit. *Gastrointest Endosc* 2020; Online ahead of print [PMID: 32343978 DOI: 10.1016/j.gie.2020.04.044]

10 **Abadir AP**, Ali MF, Karnes W, Samarasena JB. Artificial Intelligence in Gastrointestinal Endoscopy. *Clin Endosc* 2020; **53**: 132-141 [PMID: 32252506 DOI: 10.5946/ce.2020.038]

11 **Choi J**, Shin K, Jung J, Bae HJ, Kim DH, Byeon JS, Kim N. Convolutional Neural Network Technology in Endoscopic Imaging: Artificial Intelligence for Endoscopy. *Clin Endosc* 2020; **53**: 117-126 [PMID: 32252504 DOI: 10.5946/ce.2020.054]

12 **Byrne MF**. Hype or Reality? Will Artificial Intelligence Actually Make Us Better at Performing Optical Biopsy of Colon Polyps? *Gastroenterology* 2020; **158**: 2049-2051 [PMID: 32222397 DOI: 10.1053/j.gastro.2020.03.038]

13 **Li J**, Qian JM. Artificial intelligence in inflammatory bowel disease: current status and opportunities. *Chin Med J (Engl)* 2020; **133**: 757-759 [PMID: 32132365 DOI: 10.1097/CM9.0000000000000714]

14 **Byrne MF**, Chapados N, Soudan F, Oertel C, Linares Pérez M, Kelly R, Iqbal N, Chandelier F, Rex DK. Real-time differentiation of adenomatous and hyperplastic diminutive colorectal polyps during analysis of unaltered videos of standard colonoscopy using a deep learning model. *Gut* 2019; **68**: 94-100 [PMID: 29066576 DOI: 10.1136/gutjnl-2017-314547]

15 **Misawa M**, Kudo SE, Mori Y, Cho T, Kataoka S, Yamauchi A, Ogawa Y, Maeda Y, Takeda K, Ichimasa K, Nakamura H, Yagawa Y, Toyoshima N, Ogata N, Kudo T, Hisayuki T, Hayashi T, Wakamura K, Baba T, Ishida F, Itoh H, Roth H, Oda M, Mori K. Artificial Intelligence-Assisted Polyp Detection for Colonoscopy: Initial Experience. *Gastroenterology* 2018; **154**: 2027-2029.e3 [PMID: 29653147 DOI: 10.1053/j.gastro.2018.04.003]

16 **Urban G**, Tripathi P, Alkayali T, Mittal M, Jalali F, Karnes W, Baldi P. Deep Learning Localizes and Identifies Polyps in Real Time With 96% Accuracy in Screening Colonoscopy. *Gastroenterology* 2018; **155**: 1069-1078.e8 [PMID: 29928897 DOI: 10.1053/j.gastro.2018.06.037]

17 **Wang P**, Berzin TM, Glissen Brown JR, Bharadwaj S, Becq A, Xiao X, Liu P, Li L, Song Y, Zhang D, Li Y, Xu G, Tu M, Liu X. Real-time automatic detection system increases colonoscopic polyp and adenoma detection rates: a prospective randomised controlled study. *Gut* 2019; **68**: 1813-1819 [PMID: 30814121 DOI: 10.1136/gutjnl-2018-317500]

18 **Mori Y**, Kudo SE, Misawa M, Saito Y, Ikematsu H, Hotta K, Ohtsuka K, Urushibara F, Kataoka S, Ogawa Y, Maeda Y, Takeda K, Nakamura H, Ichimasa K, Kudo T, Hayashi T, Wakamura K, Ishida F, Inoue H, Itoh H, Oda M, Mori K. Real-Time Use of Artificial Intelligence in Identification of Diminutive Polyps During Colonoscopy: A Prospective Study. *Ann Intern Med* 2018; **169**: 357-366 [PMID: 30105375 DOI: 10.7326/M18-0249]

19 **Ikenoyama Y**, Hirasawa T, Ishioka M, Namikawa K, Nakano K, Yoshimizu S, Horiuchi Y, Ishiyama A, Yoshio T, Tsuchida T, Fujisaki J, Tada T. Comparing artificial intelligence using deep learning throught convolutional neural networks and endoscopist's diagnostic ability for detecting early gastric cancer. *Gastrointest Endosc* 2019; **89**: AB75 [DOI: 10.1016/j.gie.2019.04.049]

20 **Ishioka M**, Hirasawa T, Tada T. Detecting gastric cancer from video images using convolutional neural networks. *Dig Endosc* 2019; **31**: e34-e35 [PMID: 30449050 DOI: 10.1111/den.13306]

21 **Iwagami H**, Ishihara R, Fukuda H, Shimamoto Y, Kono M, Nakagawa K, Ohmori M, Matsuno K, Inoue S, Iwatsubo T, Nakahira H, Matsuura N, Shichijo S, Maekawa A, Kanesaka T, Takeuchi Y, Higashino K, Uetake H, Aoyama K, Tada T. Artificial intelligence for the diagnosis of Siewert type I and II esophagogastric junction adenocarcinomas. *Gastrointest Endosc* 2019; **89**: AB630 [DOI: 10.1016/j.gie.2019.03.1098]

22 **Tokai Y**, Yoshio T, Aoyama K, Horie Y, Yoshimizu S, Horiuchi Y, Ishiyama A, Tsuchida T, Hirasawa T, Sakakibara Y, Yamada T, Yamaguchi S, Fujisaki J, Tada T. Application of artificial intelligence using convolutional neural networks in determining the invasion depth of esophageal squamous cell carcinoma. *Esophagus* 2020; **17**: 250-256 [PMID: 31980977 DOI: 10.1007/s10388-020-00716-x]

23 **Ichimasa K**, Kudo S, Mori Y, Misawa M, Kouyama Y, Matsudaira S, Takeda K, Nakamura H, Ishigaki T,

Toyoshima N, Ogata N, Kudo T, Hisayuki T, Hayashi T, Wakamura W, Sawada N, Baba T, Ishida F. Artificial intelligence with help in determining the need for additional surgery after endoscopic resection of T1 colorectal cancer-analysis based on a big data for machine learning. *Gastrointest Endosc* 2019; **89**: AB85-AB86 [DOI: 10.1016/j.gie.2019.04.068]

24 **Loughenbury PR**, Berry L, Brooke BT, Rao AS, Dunsmuir RA, Millner PA. Benefits of the use of blood conservation in scoliosis surgery. *World J Orthop* 2016; **7**: 808-813 [PMID: 28032033 DOI: 10.5312/wjo.v7.i12.808]

25 **Menon S**, Trudgill N. How commonly is upper gastrointestinal cancer missed at endoscopy? A meta-analysis. *Endosc Int Open* 2014; **2**: E46-E50 [PMID: 26135259 DOI: 10.1055/s-0034-1365524]

26 **Yalamarthi S**, Witherspoon P, McCole D, Auld CD. Missed diagnoses in patients with upper gastrointestinal cancers. *Endoscopy* 2004; **36**: 874-879 [PMID: 15452783 DOI: 10.1055/s-2004-825853]

27 **Hosokawa O**, Hattori M, Douden K, Hayashi H, Ohta K, Kaizaki Y. Difference in accuracy between gastroscopy and colonoscopy for detection of cancer. *Hepatogastroenterology* 2007; **54**: 442-444 [PMID: 17523293]

28 **Hirasawa T**, Aoyama K, Tanimoto T, Ishihara S, Shichijo S, Ozawa T, Ohnishi T, Fujishiro M, Matsuo K, Fujisaki J, Tada T. Application of artificial intelligence using a convolutional neural network for detecting gastric cancer in endoscopic images. *Gastric Cancer* 2018; **21**: 653-660 [PMID: 29335825 DOI: 10.1007/s10120-018-0793-2]

29 **Thakkar SJ**, Kochhar GS. Artificial intelligence for real-time detection of early esophageal cancer: another set of eyes to better visualize. *Gastrointest Endosc* 2020; **91**: 52-54 [PMID: 31865996 DOI: 10.1016/j.gie.2019.09.036]

30 **Ragunath K**. Artificial intelligence in gastrointestinal endoscopy: how intelligent can it get? *Lancet Oncol* 2019; **20**: 1616-1617 [PMID: 31797775 DOI: 10.1016/S1470-2045(19)30677-1]

31 **Itoh T**, Kawahira H, Nakashima H, Yata N. Deep learning analyzes Helicobacter pylori infection by upper gastrointestinal endoscopy images. *Endosc Int Open* 2018; **6**: E139-E144 [PMID: 29399610 DOI: 10.1055/s-0043-120830]

32 **Wu L**, Zhou W, Wan X, Zhang J, Shen L, Hu S, Ding Q, Mu G, Yin A, Huang X, Liu J, Jiang X, Wang Z, Deng Y, Liu M, Lin R, Ling T, Li P, Wu Q, Jin P, Chen J, Yu H. A deep neural network improves endoscopic detection of early gastric cancer without blind spots. *Endoscopy* 2019; **51**: 522-531 [PMID: 30861533 DOI: 10.1055/a-0855-3532]

33 **Luo H**, Xu G, Li C, He L, Luo L, Wang Z, Jing B, Deng Y, Jin Y, Li Y, Li B, Tan W, He C, Seeruttun SR, Wu Q, Huang J, Huang DW, Chen B, Lin SB, Chen QM, Yuan CM, Chen HX, Pu HY, Zhou F, He Y, Xu RH. Real-time artificial intelligence for detection of upper gastrointestinal cancer by endoscopy: a multicentre, case-control, diagnostic study. *Lancet Oncol* 2019; **20**: 1645-1654 [PMID: 31591062 DOI: 10.1016/S1470-2045(19)30637-0]

34 **Kanesaka T**, Lee TC, Uedo N, Lin KP, Chen HZ, Lee JY, Wang HP, Chang HT. Computer-aided diagnosis for identifying and delineating early gastric cancers in magnifying narrow-band imaging. *Gastrointest Endosc* 2018; **87**: 1339-1344 [PMID: 29225083 DOI: 10.1016/j.gie.2017.11.029]

35 **Horiuchi Y**, Aoyama K, Tokai Y, Hirasawa T, Yoshimizu S, Ishiyama A, Yoshio T, Tsuchida T, Fujisaki J, Tada T. Convolutional Neural Network for Differentiating Gastric Cancer from Gastritis Using Magnified Endoscopy with Narrow Band Imaging. *Dig Dis Sci* 2020; **65**: 1355-1363 [PMID: 31584138 DOI: 10.1007/s10620-019-05862-6]

36 **Zhu Y**, Wang QC, Xu MD, Zhang Z, Cheng J, Zhong YS, Zhang YQ, Chen WF, Yao LQ, Zhou PH, Li QL. Application of convolutional neural network in the diagnosis of the invasion depth of gastric cancer based on conventional endoscopy. *Gastrointest Endosc* 2019; **89**: 806-815.e1 [PMID: 30452913 DOI: 10.1016/j.gie.2018.11.011]

37 **Patel V**, Khan MN, Shrivastava A, Sadiq K, Ali SA, Moore SR, Brown DE, Syed S. Artificial Intelligence Applied to Gastrointestinal Diagnostics: A Review. *J Pediatr Gastroenterol Nutr* 2020; **70**: 4-11 [PMID: 31567886 DOI: 10.1097/MPG.0000000000002507]

38 **Guo L**, Xiao X, Wu C, Zeng X, Zhang Y, Du J, Bai S, Xie J, Zhang Z, Li Y, Wang X, Cheung O, Sharma M, Liu J, Hu B. Real-time automated diagnosis of precancerous lesions and early esophageal squamous cell carcinoma using a deep learning model (with videos). *Gastrointest Endosc* 2020; **91**: 41-51 [PMID: 31445040 DOI: 10.1016/j.gie.2019.08.018]

39 **Lui TK**, Tsui VW, Leung WK. Accuracy of artificial intelligence-assisted detection of upper GI lesions: a systematic review and meta-analysis. *Gastrointest Endosc* 2020 [PMID: 32562608 DOI: 10.1016/j.gie.2020.06.034]

40 **Sharma P**, Pante A, Gross SA. Artificial intelligence in endoscopy. *Gastrointest Endosc* 2020; **91**: 925-931 [PMID: 31874161 DOI: 10.1016/j.gie.2019.12.018]

41 **Zhang Y**, Li F, Yuan F, Zhang K, Huo L, Dong Z, Lang Y, Zhang Y, Wang M, Gao Z, Qin Z, Shen L. Diagnosing chronic atrophic gastritis by gastroscopy using artificial intelligence. *Dig Liver Dis* 2020; **52**: 566-572 [PMID: 32061504 DOI: 10.1016/j.dld.2019.12.146]

42 **Hashimoto R**, Requa J, Dao T, Ninh A, Tran E, Mai D, Lugo M, El-Hage Chehade N, Chang KJ, Karnes WE, Samarasena JB. Artificial intelligence using convolutional neural networks for real-time detection of early esophageal neoplasia in Barrett's esophagus (with video). *Gastrointest Endosc* 2020; **91**: 1264-1271.e1 [PMID: 31930967 DOI: 10.1016/j.gie.2020.05.027]

43 **Xia J**, Xia T, Pan J, Gao F, Wang S, Qian YY, Wang H, Zhao J, Jiang X, Zou WB, Wang YC, Zhou W, Li ZS, Liao Z. Use of artificial intelligence for detection of gastric lesions by magnetically controlled capsule endoscopy. *Gastrointest Endosc* 2020 [PMID: 32470426 DOI: 10.1016/j.gie.2019.12.049]

44 **McNeil MB**, Gross SA. Siri here, cecum reached, but please wash that fold: Will artificial intelligence improve gastroenterology? *Gastrointest Endosc* 2020; **91**: 425-427 [PMID: 32036947 DOI: 10.1016/j.gie.2019.10.027]

45 **Nakashima H**, Kawahira H, Kawachi H, Sakaki N. Artificial intelligence diagnosis of *Helicobacter pylori* infection using blue laser imaging-bright and linked color imaging: a single-center prospective study. *Ann Gastroenterol* 2018; **31**: 462-468 [PMID: 29991891 DOI: 10.20524/aog.2018.0269]

46 **Picardo S**, Ragunath K. Artificial intelligence in endoscopy: the guardian angel is around the corner.

Gastrointest Endosc 2020; **91**: 340-341 [PMID: 32036941 DOI: 10.1016/j.gie.2019.10.026]
47 **Guimarães P**, Keller A, Fehlmann T, Lammert F, Casper M. Deep-learning based detection of gastric precancerous conditions. *Gut* 2020; **69**: 4-6 [PMID: 31375599 DOI: 10.1136/gutjnl-2019-319347]
48 **Wong GL**, Ma AJ, Deng H, Ching JY, Wong VW, Tse YK, Yip TC, Lau LH, Liu HH, Leung CM, Tsang SW, Chan CW, Lau JY, Yuen PC, Chan FK. Machine learning model to predict recurrent ulcer bleeding in patients with history of idiopathic gastroduodenal ulcer bleeding. *Aliment Pharmacol Ther* 2019; **49**: 912-918 [PMID: 30761584 DOI: 10.1111/apt.15145]
49 **Schmidt A**, Beyna T, Schumacher B, Meining A, Richter-Schrag HJ, Messmann H, Neuhaus H, Albers D, Birk M, Thimme R, Probst A, Faehndrich M, Frieling T, Goetz M, Riecken B, Caca K. Colonoscopic full-thickness resection using an over-the-scope device: a prospective multicentre study in various indications. *Gut* 2018; **67**: 1280-1289 [PMID: 28798042 DOI: 10.1136/gutjnl-2016-313677]
50 **Ding L**, Liu GW, Zhao BC, Zhou YP, Li S, Zhang ZD, Guo YT, Li AQ, Lu Y, Yao HW, Yuan WT, Wang GY, Zhang DL, Wang L. Artificial intelligence system of faster region-based convolutional neural network surpassing senior radiologists in evaluation of metastatic lymph nodes of rectal cancer. *Chin Med J (Engl)* 2019; **132**: 379-387 [PMID: 30707177 DOI: 10.1097/CM9.0000000000000095]
51 **Chen PJ**, Lin MC, Lai MJ, Lin JC, Lu HH, Tseng VS. Accurate Classification of Diminutive Colorectal Polyps Using Computer-Aided Analysis. *Gastroenterology* 2018; **154**: 568-575 [PMID: 29042219 DOI: 10.1053/j.gastro.2017.10.010]
52 **Wu L**, Zhang J, Zhou W, An P, Shen L, Liu J, Jiang X, Huang X, Mu G, Wan X, Lv X, Gao J, Cui N, Hu S, Chen Y, Hu X, Li J, Chen D, Gong D, He X, Ding Q, Zhu X, Li S, Wei X, Li X, Wang X, Zhou J, Zhang M, Yu HG. Randomised controlled trial of WISENSE, a real-time quality improving system for monitoring blind spots during esophagogastroduodenoscopy. *Gut* 2019; **68**: 2161-2169 [PMID: 30858305 DOI: 10.1136/gutjnl-2018-317366]
53 **Bernal J**, Histace A, Masana M, Angermann Q, Sánchez-Montes C, Rodríguez de Miguel C, Hammami M, García-Rodríguez A, Córdova H, Romain O, Fernández-Esparrach G, Dray X, Sánchez FJ. GTCreator: a flexible annotation tool for image-based datasets. *Int J Comput Assist Radiol Surg* 2019; **14**: 191-201 [PMID: 30255462 DOI: 10.1007/s11548-018-1864-x]
54 **Chen D**, Wu L, Li Y, Zhang J, Liu J, Huang L, Jiang X, Huang X, Mu G, Hu S, Hu X, Gong D, He X, Yu H. Comparing blind spots of unsedated ultrafine, sedated, and unsedated conventional gastroscopy with and without artificial intelligence: a prospective, single-blind, 3-parallel-group, randomized, single-center trial. *Gastrointest Endosc* 2020; **91**: 332-339.e3 [PMID: 31541626 DOI: 10.1016/j.gie.2019.09.016]
55 **Topol EJ**. High-performance medicine: the convergence of human and artificial intelligence. *Nat Med* 2019; **25**: 44-56 [PMID: 30617339 DOI: 10.1038/s41591-018-0300-7]
56 **Yamada M**, Saito Y, Imaoka H, Saiko M, Yamada S, Kondo H, Takamaru H, Sakamoto T, Sese J, Kuchiba A, Shibata T, Hamamoto R. Development of a real-time endoscopic image diagnosis support system using deep learning technology in colonoscopy. *Sci Rep* 2019; **9**: 14465 [PMID: 31594962 DOI: 10.1038/s41598-019-50567-5]
57 **Klare P**, Sander C, Prinzen M, Haller B, Nowack S, Abdelhafez M, Poszler A, Brown H, Wilhelm D, Schmid RM, von Delius S, Wittenberg T. Automated polyp detection in the colorectum: a prospective study (with videos). *Gastrointest Endosc* 2019; **89**: 576-582.e1 [PMID: 30342029 DOI: 10.1016/j.gie.2018.09.042]
58 **Song EM**, Park B, Ha CA, Hwang SW, Park SH, Yang DH, Ye BD, Myung SJ, Yang SK, Kim N, Byeon JS. Endoscopic diagnosis and treatment planning for colorectal polyps using a deep-learning model. *Sci Rep* 2020; **10**: 30 [PMID: 31913337 DOI: 10.1038/s41598-019-56697-0]
59 **Zachariah R**, Samarasena J, Luba D, Duh E, Dao T, Requa J, Ninh A, Karnes W. Prediction of Polyp Pathology Using Convolutional Neural Networks Achieves "Resect and Discard" Thresholds. *Am J Gastroenterol* 2020; **115**: 138-144 [PMID: 31651444 DOI: 10.14309/ajg.0000000000000429]

Published by **Baishideng Publishing Group Inc**
7041 Koll Center Parkway, Suite 160, Pleasanton, CA 94566, USA
Telephone: +1-925-3991568
E-mail: bpgoffice@wjgnet.com
Help Desk: https://www.f6publishing.com/helpdesk
https://www.wjgnet.com