

Artificial Intelligence in *Medical Imaging*

Artif Intell Med Imaging 2021 February 28; 2(1): 1-12





Artificial Intelligence in Medical Imaging

Contents

Bimonthly Volume 2 Number 1 February 28, 2021

EDITORIAL

- 1 New Year's greeting and overview of *Artificial Intelligence in Medical Imaging* in 2021
Wu YXJ, Shen J

MINIREVIEWS

- 5 Artificial intelligence in ophthalmology: A new era is beginning
Panda BB, Thakur S, Mohapatra S, Parida S

Contents

Artificial Intelligence in Medical Imaging

Bimonthly Volume 2 Number 1 February 28, 2021

ABOUT COVER

Georges Nassar, PhD, Academic Research, Professor, Ultrasonic Division, Institute of Electronic, Microelectronic and Nanotechnology, Lille 59300, Hauts-de-France, France. gnessar@univ-valenciennes.fr

AIMS AND SCOPE

The primary aim of *Artificial Intelligence in Medical Imaging* (AIMI, *Artif Intell Med Imaging*) is to provide scholars and readers from various fields of artificial intelligence in medical imaging with a platform to publish high-quality basic and clinical research articles and communicate their research findings online.

AIMI mainly publishes articles reporting research results obtained in the field of artificial intelligence in medical imaging and covering a wide range of topics, including artificial intelligence in radiology, pathology image analysis, endoscopy, molecular imaging, and ultrasonography.

INDEXING/ABSTRACTING

There is currently no indexing.

RESPONSIBLE EDITORS FOR THIS ISSUE

Production Editor: *Yun-Xia Xing*, **Production Department Director:** *Yun-Xiaoqian Wu*, **Editorial Office Director:** *Yun-Xiaoqiao Wu*.

NAME OF JOURNAL

Artificial Intelligence in Medical Imaging

ISSN

ISSN 2644-3260 (online)

LAUNCH DATE

June 28, 2020

FREQUENCY

Bimonthly

EDITORS-IN-CHIEF

Xue-Li Chen, Caroline Chung, Jun Shen

EDITORIAL BOARD MEMBERS

<https://www.wjnet.com/2644-3260/editorialboard.htm>

PUBLICATION DATE

February 28, 2021

COPYRIGHT

© 2021 Baishideng Publishing Group Inc

INSTRUCTIONS TO AUTHORS

<https://www.wjnet.com/bpg/gerinfo/204>

GUIDELINES FOR ETHICS DOCUMENTS

<https://www.wjnet.com/bpg/GerInfo/287>

GUIDELINES FOR NON-NATIVE SPEAKERS OF ENGLISH

<https://www.wjnet.com/bpg/gerinfo/240>

PUBLICATION ETHICS

<https://www.wjnet.com/bpg/GerInfo/288>

PUBLICATION MISCONDUCT

<https://www.wjnet.com/bpg/gerinfo/208>

ARTICLE PROCESSING CHARGE

<https://www.wjnet.com/bpg/gerinfo/242>

STEPS FOR SUBMITTING MANUSCRIPTS

<https://www.wjnet.com/bpg/GerInfo/239>

ONLINE SUBMISSION

<https://www.f6publishing.com>

© 2021 Baishideng Publishing Group Inc. All rights reserved. 7041 Koll Center Parkway, Suite 160, Pleasanton, CA 94566, USA

E-mail: bpgoffice@wjnet.com <https://www.wjnet.com>



New Year's greeting and overview of Artificial Intelligence in Medical Imaging in 2021

Yun-Xiaojian Wu, Jun Shen

ORCID number: Yun-Xiaojian Wu
0000-0003-1146-7872; Jun Shen
0000-0001-7746-5285.

Author contributions: Wu YXJ
drafted this editorial; Shen J
revised the manuscript.

Conflict-of-interest statement: The
authors declare having no conflicts
of interest.

Open-Access: This article is an
open-access article that was
selected by an in-house editor and
fully peer-reviewed by external
reviewers. It is distributed in
accordance with the Creative
Commons Attribution
NonCommercial (CC BY-NC 4.0)
license, which permits others to
distribute, remix, adapt, build
upon this work non-commercially,
and license their derivative works
on different terms, provided the
original work is properly cited and
the use is non-commercial. See: <http://creativecommons.org/licenses/by-nc/4.0/>

Manuscript source: Invited
manuscript

Specialty type: Radiology, nuclear
medicine and medical imaging

Country/Territory of origin: United
States

**Peer-review report's scientific
quality classification**

Yun-Xiaojian Wu, Production Department, Baishideng Publishing Group Inc, Pleasanton, CA 94566, United States

Jun Shen, Department of Radiology, Sun Yat-Sen Memorial Hospital, Sun Yat-Sen University, Guangzhou 510120, Guangdong Province, China

Corresponding author: Yun-Xiaojian Wu, BSc, Vice Director, Production Department, Baishideng Publishing Group Inc, 7041 Koll Center Parkway, Suite 160, Pleasanton, CA 94566, United States. y.xj.wu@wjgnet.com

Abstract

As editors of *Artificial Intelligence in Medical Imaging (AIMI)*, it is our great pleasure to take this opportunity to wish all of our authors, subscribers, readers, Editorial Board members, independent expert referees, and staff of the Editorial Office a Very Happy New Year. On behalf of the Editorial Team, we would like to express our gratitude to all of the authors who have contributed their valuable manuscripts, our independent referees, and our subscribers and readers for their continuous support, dedication, and encouragement. Together with an excellent of team effort by our Editorial Board members and staff of the Editorial Office, *AIMI* advanced in 2020 and we look forward to greater achievements in 2021.

Key Words: New Year's greeting; *Artificial Intelligence in Medical Imaging*; Baishideng; Journal development

©The Author(s) 2021. Published by Baishideng Publishing Group Inc. All rights reserved.

Core Tip: On behalf of the *Artificial Intelligence in Medical Imaging (AIMI)* Editorial Team, we would like to express our gratitude to all authors who have contributed their valuable manuscripts, to our independent referees, and to our subscribers and readers for their continuous support, dedication, and encouragement. Together with an excellent team effort by our Editorial Board members and staff of the Editorial Office, *AIMI* advanced in 2020 and we look forward to greater achievements in 2021.

Citation: Wu YXJ, Shen J. New Year's greeting and overview of *Artificial Intelligence in Medical Imaging* in 2021. *Artif Intell Med Imaging* 2021; 2(1): 1-4

Grade A (Excellent): A
Grade B (Very good): 0
Grade C (Good): 0
Grade D (Fair): 0
Grade E (Poor): 0

Received: January 17, 2021

Peer-review started: January 17, 2021

First decision: January 28, 2021

Revised: February 19, 2021

Accepted: February 22, 2021

Article in press: February 22, 2021

Published online: February 28, 2021

P-Reviewer: Liu G

S-Editor: Wang JL

L-Editor: Filipodia

P-Editor: Xing YX



URL: <https://www.wjgnet.com/2644-3260/full/v2/i1/1.htm>

DOI: <https://dx.doi.org/10.35711/aimi.v2.i1.1>

INTRODUCTION

As editors of *Artificial Intelligence in Medical Imaging (AIMI)*, it is our great pleasure to take this opportunity to wish all of our authors, subscribers, readers, Editorial Board members, independent expert referees, and staff of the Editorial Office a Very Happy New Year. On behalf of the Editorial Team, we would also like to express our gratitude to all authors who have contributed their valuable manuscripts, to independent referees, and to our subscribers and readers for their continuous support, dedication, and encouragement.

AIMI mainly focuses on reporting research results obtained in the field of artificial intelligence (AI) in medical imaging, but covers a wide range of topics within that field. With the joint efforts of Editorial Board members and Editorial Office staff, it is our hope that *AIMI* will achieve further advancement in 2021, establishing a strong foundation upon which we may build to become the top journal in the field of AI.

ACADEMIC INFLUENCE OF *AIMI*

AIMI is a high-quality, bimonthly, online, open-access, and single-blind peer-reviewed journal, featuring research advances in AI involving the emerging fields of medical imaging in each issue. The scope of *AIMI* covers a wide range of topics, including but not limited to coronavirus disease 2019, radiomics, computed tomography, magnetic resonance imaging, machine learning, deep learning, nuclear medicine, positron emission tomography, pathology image analysis, endoscopy, molecular imaging, and ultrasonography.

With the rapid development of AI technology, the combination of deep learning and image-omics will enjoy broader application and more substantive development prospects, ultimately creating new fields of computer-aided diagnosis and personalized medical imaging. As a future research hotspot, they will continue to support even further investigative and clinical focus, advancing the overall use of AI and its benefit to human health. We will invite global experts to contribute original articles that focus on key scientific issues in medical imaging technology, methodology, and applied research, and propose research ideas, key research directions, and future research trends, to lead the development of the field.

As one of the key developing journals of the Baishideng Publishing Group Inc (BPG), *AIMI* was launched in 2020, publishing Volume 1, Issue 1 on June 28^[1]. To date, it has published 3 issues with 11 articles (Figure 1). The authors of these manuscripts come from countries across the globe (Figure 2). In 2020, the Editorial Board of *AIMI* consisted of 77 members from 23 countries and regions including 33 from China (42.9%), 9 from the United States (11.7%), 7 from India (9.1%), and 28 from other countries and regions (36.3%) (Figure 3)^[2].

To help *AIMI* develop more efficiently, BPG instituted and implemented the following in 2020. (1) In order to provide authors with better services, and supervise and promote BPG's efforts to publish each article more openly and transparently, BPG published the Author Reviews (<https://www.f6publishing.com/AuthorReviews>) for each publication, so that all can see the authors' evaluation and feedback on the publication process. (2) Throughout 2020, BPG continued systematic efforts to encourage more authors to generate articles that are outstanding for their originality and innovativeness and to strengthen our open-access strategy of publication; these efforts were motivated by our dedication to maximizing readers' access to the latest research results, to promote development of the medical sciences worldwide. In doing so, BPG invited Editorial Board members to conduct Article Quality Tracking-Peer-Review and published the comments (<https://www.f6publishing.com/ArticleQualityTrackings>) after the publication of the article. (3) To continue to advance BPG's publishing efficiency and quality, we successfully developed an automated manuscript editor system for manuscript revision and submission, as well as an artificially intelligent program to generate a PDF version of the manuscript. (4) To enable more peers to read, share, and cite authors' published research results and to help enhance their global academic influence and reputations, thereby also promoting

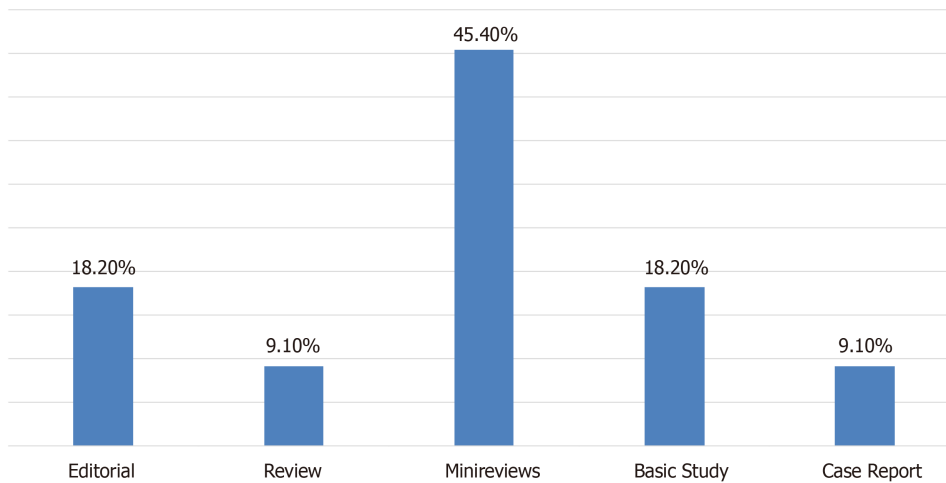


Figure 1 Column type distribution of manuscripts published in *Artificial Intelligence in Medical Imaging* in 2020.

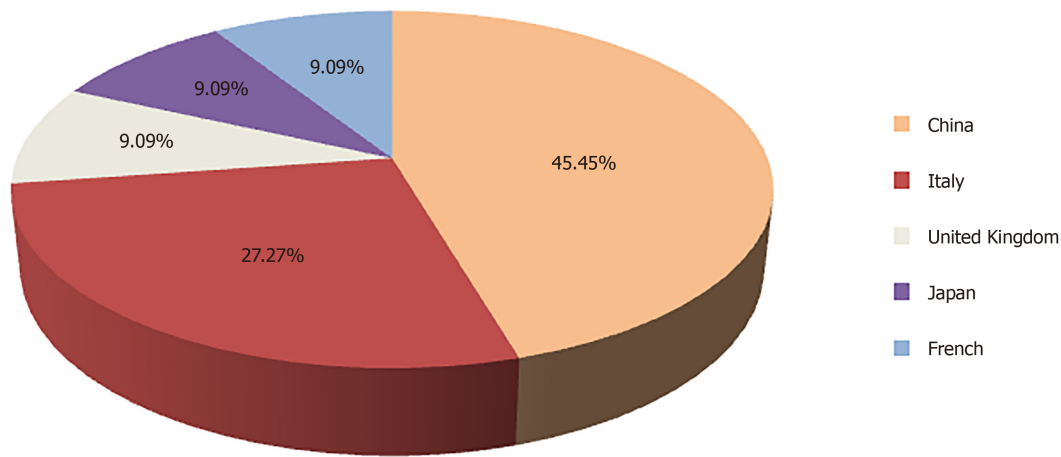


Figure 2 Distribution of authors' countries for the manuscripts published in *Artificial Intelligence in Medical Imaging* in 2020.

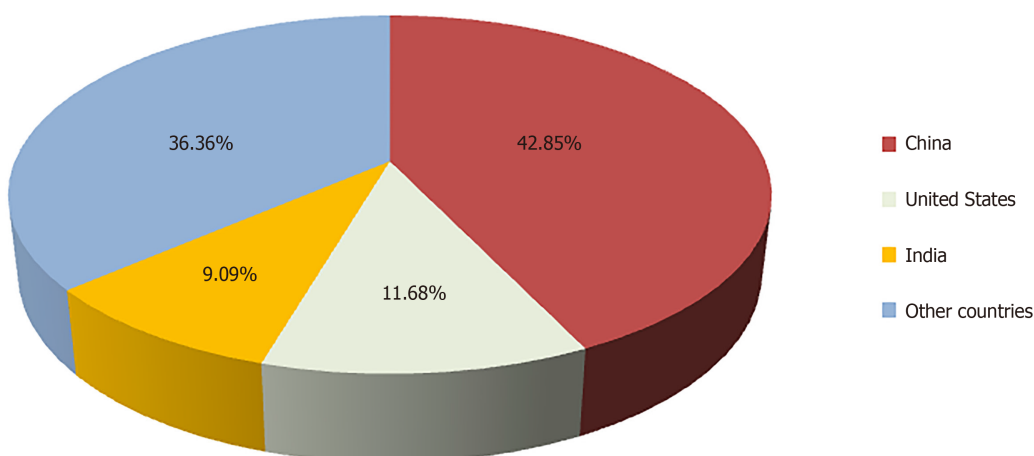


Figure 3 Distribution of Editorial Board members' countries for *Artificial Intelligence in Medical Imaging*.

the overall development of the field, BPG initiated the routine of sending its published articles to 1000-10000 highly influential experts in a topically accurate manner. After completing this outreach activity, BPG formally notifies the paper's authors of the number of experts to whom their manuscript was sent *via* email.

We are pleased to announce that we have now submitted evaluation applications to

the Web of Science, with the expectation that the *AIMI* could be included in Science Citation Index Expanded in 2021.

CONCLUSION

With the collective support of BPG's contributors and staff, we expect to continue the trajectory towards more productive efforts that will raise the academic rank of *AIMI* in 2021. To achieve these goals, we appreciate the need for continuous support and submissions from authors and the dedicated efforts and expertise by our invited reviewers, many of them who also serve on our Editorial Board. As the chief editors of *AIMI*, we strive to work with the journal's Editorial Office staff to make the manuscript submission process as simple as possible and to ensure efficient communication with the authors to provide professional support and answer their questions. We are also open to any suggestions that could improve *AIMI*'s operations and publication. Please feel free to contact us at (editorialoffice@wjgnet.com) with any question on your submission or suggestions.

Once again, on behalf of *AIMI*, we wish you and your families the best for the New Year.

REFERENCES

- 1 **Baishideng Publishing Group Inc.** All published articles of Artificial Intelligence in Medical Imaging from its launch in 2020 to present. Available from <https://www.wjgnet.com/2644-3260/archive.htm>
- 2 **Baishideng Publishing Group Inc.** The Editorial Board of Artificial Intelligence in Medical Imaging. Available from <https://www.wjgnet.com/2644-3260/editorialboard.htm>

Artificial intelligence in ophthalmology: A new era is beginning

Bijnya Birajita Panda, Subhodeep Thakur, Sumita Mohapatra, Subhabrata Parida

ORCID number: Bijnya Birajita Panda 0000-0002-0887-1690; Subhodeep Thakur 0000-0003-1782-3567; Sumita Mohapatra 0000-0001-7165-9572; Subhabrata Parida 0000-0002-3871-3490.

Author contributions: Panda BB and Thakur S designed the review, collected the data, analyzed the data and prepared the initial draft. Mohapatra S and Parida S revised the manuscript for important intellectual content and prepared the final draft; All authors read the manuscript and approved for the publication.

Conflict-of-interest statement: The authors declare no conflicts of interest.

Open-Access: This article is an open-access article that was selected by an in-house editor and fully peer-reviewed by external reviewers. It is distributed in accordance with the Creative Commons Attribution NonCommercial (CC BY-NC 4.0) license, which permits others to distribute, remix, adapt, build upon this work non-commercially, and license their derivative works on different terms, provided the original work is properly cited and the use is non-commercial. See: <http://creativecommons.org/licenses/by-nc/4.0/>

Manuscript source: Unsolicited manuscript

Bijnya Birajita Panda, Subhodeep Thakur, Sumita Mohapatra, Subhabrata Parida, Department of Ophthalmology, S.C.B Medical College and Hospital, Cuttack 753007, Odisha, India

Corresponding author: Bijnya Birajita Panda, MBBS, MS, Assistant Professor, Ophthalmology, S.C.B Medical College and Hospital, Manglabag, Cuttack 753007, Odisha, India. bigyan_panda@yahoo.co.in

Abstract

The use of artificial intelligence (AI) in ophthalmology is not very new and its use is expanding into various subspecialties of the eye like retina and glaucoma, thereby helping ophthalmologists to diagnose and treat diseases better than before. Incorporating "deep learning" (a subfield of AI) into image-based systems such as optical coherence tomography has dramatically improved the machine's ability to screen and identify stages of diabetic retinopathy accurately. Similar applications have been tried in the field of retinopathy of prematurity and age-related macular degeneration, a silent retinal condition that needs to be diagnosed early to prevent progression. The advent of AI into glaucoma diagnostics in analyzing visual fields and assessing disease progression also holds a promising role. The ability of the software to detect even a subtle defect that the human eye can miss has led to a revolution in the management of certain ocular conditions. However, there are few significant challenges in the AI systems, such as the incorporation of quality images, training sets and the black box dilemma. Nevertheless, despite the existing differences, there is always a chance of improving the machines/software to potentiate their efficacy and standards. This review article shall discuss the current applications of AI in ophthalmology, significant challenges and the prospects as to how both science and medicine can work together.

Key Words: Artificial intelligence; Retina; Diabetic retinopathy; Glaucoma; Retinopathy of prematurity; Image-based learning

©The Author(s) 2021. Published by Baishideng Publishing Group Inc. All rights reserved.

Core Tip: Artificial intelligence has improved the diagnostic ability in the ophthalmology field, thereby improving patient care. The in-depth image recognition in diabetic retinopathy, retinopathy of prematurity and age-related macular degeneration has helped in early diagnosis and prevention. The detection of visual field

Specialty type: Ophthalmology**Country/Territory of origin:** India**Peer-review report's scientific quality classification**

Grade A (Excellent): 0

Grade B (Very good): 0

Grade C (Good): C

Grade D (Fair): D

Grade E (Poor): 0

Received: November 28, 2020**Peer-review started:** November 28, 2020**First decision:** December 18, 2020**Revised:** December 31, 2020**Accepted:** February 12, 2021**Article in press:** February 12, 2021**Published online:** February 28, 2021**P-Reviewer:** Boon CS, Zhang LZ**S-Editor:** Wang JL**L-Editor:** Filipodia**P-Editor:** Xing YX

defect even at its minute stage in glaucoma and other ocular conditions has accurately staged the disease with the prediction of its severity. Still, many challenges need to be addressed, such as image incorporation, training sets and the black box dilemma. Nevertheless, despite the existing differences, there is always a chance of improving machines to potentiate their efficacy and standards.

Citation: Panda BB, Thakur S, Mohapatra S, Parida S. Artificial intelligence in ophthalmology: A new era is beginning. *Artif Intell Med Imaging* 2021; 2(1): 5-12

URL: <https://www.wjgnet.com/2644-3260/full/v2/i1/5.htm>

DOI: <https://dx.doi.org/10.35711/aimi.v2.i1.5>

INTRODUCTION

Artificial intelligence (AI) software can perform cognitive functions like problem-solving and learning by processing and analyzing a large amount of data; in other words, the machine can gain experience as humans do. It came into existence in 1956 and in no time spread its roots into many medical fields, including ophthalmology in the late 1990s when colour fundus photography had started gaining importance in diabetic retinopathy (DR) screening^[1]. Later on, its use was not limited to but tried extensively in many subspecialties of the eye such as cataract, myopia and glaucoma screening, corneal ectasia, keratoconus, retinopathy of prematurity (ROP) and ocular reconstruction. It can also be used in calculating intraocular lens power and while planning squint surgery and intravitreal injections. AI can even detect cognitive loss, Alzheimer's disease and cerebrovascular stroke risk from fundus photographs and optical coherence tomography (OCT). AI in ophthalmology started with machine learning (ML), which meant automatic behaviour modification after exposure to several inputs. Deep learning (DL) is a subset of ML that uses convolutional neural networks (CNN) to add decision-making capability. When incorporated into OCT, these features can help in the diagnosis of many anterior and posterior segment diseases.

AI AND DR

The disease burden of diabetes mellitus increases day by day, and millions of people are affected. According to published data, the present disease burden is 463 million^[2] and likely to rise to 642 million by 2040. DR is a microvascular complication affecting the retina's blood vessels, leading to progressive damage and irreversible blindness. These patients need to be diagnosed early, and prompt treatment should be started regardless of the type of diabetes. Routine dilated fundus screening in these patients with ophthalmoscopy and colour fundus photographs is the need of the hour and, therefore, eases the burden on the retina specialists. AI has shown promising results in the automated grading of DR based on ML and DL models, the CNN and the massive-training artificial neural network. The lesions in DR are recognized by ML as different colours like red (microaneurysms, haemorrhage, venous abnormalities, intraretinal microvascular abnormalities, new vessels, *etc.*), yellow (hard exudates, drusen) and white (cotton wool spots, fibrous proliferation, retinal oedema)^[3]. Staging in DR is usually done by the Davis staging practiced worldwide^[4]. In 2017, Takahashi *et al*^[5] developed a modified Davis staging adopting the DL criterion. The DL approach increases the possibility of identifying neovascularization or other features of proliferative DR (PDR) outside a 45° angle to the posterior pole by detecting non-verbalizable unclear signals. A major breakthrough in this arena was the United States Food and Drug Administration approval of IDx-DR in 2018^[6]. A CNN DL algorithm-based AI system to be used along with a Topcon fundus camera has now been proven to be an essential tool in non-ophthalmic healthcare places where it can diagnose DR in just a matter of 20 sec. Lately, the automated DR image accessing system has been applied in conditions affecting the macula such as PDR and clinically significant macular oedema. Another new entity has evolved termed as mtmDR (more than minimal DR), which is defined as the presence of Early Treatment Diabetic Retinopathy Study level 35 or higher, *i.e.* showing microaneurysms, hard exudates,

cotton wool spots and mild retinal haemorrhages and presence of macular oedema in at least one eye^[7].

Abràmoff *et al*^[8] reported that DL enhanced algorithm for automated detection of DR has better sensitivity than the Iowa Detection Program—without DL components. The sensitivity and specificity of DL-based automated DR detection algorithm was 96.8% [95% confidence interval (CI): 93.3%-98.8%] and 87.0% (95% CI: 84.2%-89.4%) with 6/874 false negatives, resulting in a negative predictive value of 99.0% (95% CI: 97.8%-99.6%). The authors did not miss a single case of severe non-proliferative DR, PDR or macular oedema with DL technology^[8]. Gargeya *et al*^[9] developed a data-driven DL algorithm where the colour fundus images were classified as healthy (no-retinopathy) or DR. Their model achieved a 0.97 area under the curve with a 94% and 98% sensitivity and specificity, respectively^[9].

Several studies came out with different proposals of classifying DR stages, some of which are worth mentioning^[10]. A three-layer feed-forward neural network based on identifying microaneurysms and haemorrhages was proposed by Wong *et al*^[11] to stage DR. A novel technique known as morphological component analysis was formulated by Imani *et al*^[12] to detect oedema and haemorrhages. Yazid *et al*^[13] used inverse surface thresholding and Lattice Neural Network with Dendritic Processing or enhancement techniques to identify hard exudates and optic disc pathologies. Akyol *et al*^[14] tried using key point detection, texture analysis and visual dictionary techniques to detect automatically the optic disc changes from fundus images. The sensitivity and specificity of these studies ranged from 75% to 94.7%. Few studies have used the Eye Art software smartphone-based fundus photography with a sensitivity of around 95% and specificity of 91.5%. The EyeNuk software using the desktop fundus cameras to evaluate retinal images showed that EyeArt's sensitivity for DR screening was 91.7% and specificity was 91.5%^[15-17]. Ting *et al*^[18] validated the DL algorithm with retinal images taken with conventional fundus cameras that had high sensitivity and specificity for identifying DR and age-related macular degeneration (AMD). The intelligent retinal imaging system is another milestone achieved in the field of AI. It is a tele-retinal DR screening program that compares non-mydratic retinal images taken by a fundus camera with a standard set of images from Early Treatment Diabetic Retinopathy Study to recommend referral in selected cases of severe non-proliferative DR or more advanced vision-threatening disease^[19].

Wong *et al*^[20] pointed out certain limitations of DL technology in AI for the screening of DR. There is no simple, standardized algorithm to follow. The technology can talk about the referral cases but fail to detect severe sight-threatening DR that need urgent attention. The software may fail to detect associated glaucoma and AMD while screening for DR. The most severe problem is the development of the faith of the physicians on the machine. The heterogeneous population, different races and variability in pupil dilatation, cataract severity and media opacities may befool the machine and can be one of the reasons for refusal of the technology by the physicians^[20].

AI AND ROP

ROP is one of the leading causes of childhood blindness throughout the world. This vasoproliferative condition affects preterm infants with low gestational age and those with low birth weight. This condition should be diagnosed promptly so that timely intervention can be done. This can be abetted with the help of AI, which provides an automated, quantifiable and highly objective diagnosis in plus disease in ROP^[21]. One more area of application of AI in ROP is the utilization of the DL algorithms into medical training to standardize ROP training and education through tele-education. However, there are few clinical and technical challenges in the implementation of AI in the actual scenario.

According to International Classification of Retinopathy of Prematurity, ROP is classified based on the location, extent and severity of disease^[22]. However, there is much inter-observer variability in the subjective and qualitative assessment of disease severity (zone, stage and plus-disease) due to wide disparities among the diagnosing abilities of ophthalmologists attending these preterm babies. Therefore, there is a need to add objective methods of diagnosis and record-keeping for future comparisons to improve accuracy. Today, digital fundus photography using telemedicine has already paved the way for screening at-risk preterm babies at any geographical location that can be evaluated by a trained retina specialist sitting at another location.

Earlier systems of computer-based ROP diagnosis as described by Wittenberg *et al*^[23]

(2012) include the ROP-Tool, retinal image multiScale analysis, vessel map and computer-assisted image analysis of the retina, which were feature extraction-based systems. These systems could quantify vessel type, dilation and tortuosity into some value that had a variable diagnostic agreement with the clinical diagnosis of ROP.

Newer ML-based systems used a support vector machine that is trained to combine the features (vessel tortuosity) and the field of view (six-disc diameter radius) and then provide the diagnosis, quite similar to what an expert can do. This improved machine efficacy and accuracy to almost 85%-95%^[24,25]. However, there were few limitations as they required manual drawings for input. In 2018, Brown *et al*^[24] described a fully automated convoluted neural networks-based system known as the i-ROP DL system for the diagnosis of plus-ROP that can diagnose plus disease with a sensitivity and specificity of 93% and 94%, respectively. Taylor *et al*^[25] used the i-ROP DL algorithm to create a scoring system related to vascular tortuosity and termed it as continuous ROP vascular severity score (1-9), which could classify ROP as no ROP, mild ROP, type 2 ROP and pre-plus disease or type 1 ROP. This scoring system could help augment treatment regimens by better predicting the preterm infants at risk for treatment failure and disease recurrence. However, few regulatory and medicolegal issues in utilizing the DL systems for ROP diagnosis need to be resolved for proper implication.

AI AND AMD

AMD is considered the leading cause of central vision loss in the elderly age group. The challenges in diagnosing and managing this silent progressive retinal condition have led to the rising prevalence of the disease. AI has evolved to help in the automated detection of drusens in the very early stages and stratify the disease's progression. AMD is clinically characterized by the presence of drusens and retinal pigment epithelium changes progressing into geographic atrophy and neovascularization.

Many of the studies related to incorporating AI in the screening of AMD have used colour fundus images as input materials and then extract features of early, intermediate and late AMD to differentiate from the healthy ones with relatively high accuracy and sensitivity ranging from 87%-100%^[26,27]. They found this technique much cheaper than using OCT to stage the disease. Fang *et al*^[28] proposed a spectral-domain OCT combined with DL system that could determine the macular fluid quantity of neovascular AMD and the segmentation of the retinal layers of dry AMD and validated the accuracy as 100%. Bogunovic *et al*^[29] developed an algorithm to evaluate the response to treatment using OCT images. More recently, Bhuiyan *et al*^[30] did pioneer research in creating and validating AI-based models for AMD screening (accuracy 99.2%) and predicting late dry and wet AMD progression within 1 and 2 years (accuracy 66%-83%). They used the DL screening methods on the Age-related Eye Disease Study (AREDS) dataset to classify their colour fundus photos into no, early, intermediate or advanced AMD and further classified them along the AREDS 12 Level severity scale^[30]. They combined the AMD scores with sociodemographic, clinical data and other automatically extracted imaging data by a logistic model tree ML technique to predict risk for progression to late AMD.

AI AND GLAUCOMA

Glaucoma is a progressive optic neuropathy caused by high intra-ocular pressure leading to retinal nerve fibre loss and irreversible blindness. Early treatment can retard the progression of the disease. AI can help in identifying the borderline cases and predict the course of the disease. Many studies have tried to apply ML to identify the disease. A comprehensive AI for glaucoma should be able to evaluate all the necessary parameters such as optic disc changes, intraocular pressure (IOP), gonioscopy, retinal nerve fiber layer thickness, visual fields *etc.* However, such a comprehensive package is yet to come to the real-time world. The application of AI in measuring IOP is now limited to the Sensimed Triggerfish, a contact lens-based continuous IOP monitoring device that measures the corneal strain changes induced by IOP fluctuations. Martin *et al*^[31] used data from 24 prospective studies of Triggerfish using Random Forest Modelling (a ML method) to identify the parameters associated with glaucoma patients.

Omodaka *et al*^[32] developed a ML algorithm based on the segmentation technique where the parameters such as optic disc cupping, neuroretinal rim thickness and

ganglion cell thickness could be quantified with the help of swept-source OCT to the accuracy as high as 87%. Other studies by Christopher *et al*^[33], Barella *et al*^[34], Bizios *et al*^[35] and Larrosa *et al*^[36] evaluated unsupervised ML, ML classifiers, artificial neural networks, support vector machines and segmentation methods for glaucoma OCT.

Many studies have evaluated a DL algorithm to detect glaucomatous optic disc changes from colour fundus photographs with high sensitivity and specificity^[37,38]. The available AI devices for detecting glaucomatous optic neuropathy from fundus photos are the Pegasus (Orbis Cybersight Consult Platform), NetraAI (Leben Care Technologies Pte Ltd) and the Retinal Image Analysis - Glaucoma (RIA-G). RIA-G is the AI device based on DL made by the Indian startup Kalpah Innovations (Vishakapatnam, India). It is a cloud-based software that uses advanced image processing algorithms to measure the cup disc size and ratio, NeuroRetinal Rim Thickness and Disc Damage Likelihood Score^[39].

AI can also augment the interpretation of visual fields in studies showed by Asaoka *et al*^[40] and Andersson *et al*^[41] using a Feed-Forward Neural Network to identify pre-perimetric visual fields (VF). Goldbaum *et al*^[42] used unsupervised ML and variational Bayesian independent component analysis mixture model (vB-ICA-mm) to analyze VF defects. Bowd *et al*^[43] used the variational Bayesian independent component analysis-mixture model, which is an unsupervised machine-learning classifier and can be used in the analysis of frequency doubling technology perimetry data^[43].

AI AND CATARACT

Studies have described techniques to grade nuclear cataracts by the help of AI using algorithms based on ML or DL systems that work as efficiently as a clinician's grading. Gao *et al*^[44] proposed a system that could process slit-lamp images to grade cataracts. Liu *et al*^[45] focused on identifying and categorizing pediatric cataracts with excellent accuracy and sensitivity. Wu *et al*^[46] developed a universal AI platform and multilevel collaborative pattern that could perform effectively in diagnostic and referral service for pediatric and age-related cataracts. Dong *et al*^[47] have proposed the automated detection and grading of cataracts from colour fundus photographs using a combination of a DL system to extract images (Caffe software) followed by a ML algorithm (called as Softmax function) for severity grading. AI has also been tried in residents' cataract surgery training due to recognizing different phases of cataract surgery^[48,49]. Some researchers have derived new AI-based calculation formulae for pre-cataract surgery intraocular lens power, *e.g.*, the Hill-Radial basis function method and the Kane formula, which are reported to be able to estimate individual eye's intraocular lens power with promising results with further improvements needed for short axial length eyes^[50-52].

CONCLUSION

AI-assisted screening and diagnosis of high incidence diseases will help in better medical care and reduce the limitations to access ophthalmic care at remote areas devoid of ophthalmologists. In doing so, it will also reduce the overburdened healthcare system. However, this project at its infancy is nonetheless riddled with certain limitations. The assessment is highly dependent on image quality. Hence, patient factors such as head and eyeball movement and poor fixation may lead to a substandard image and a wrong assessment. However, this is the basis of ML, and in future, we expect a much more robust system. A certain degree of human supervision is required to find the subtle variations and atypical findings missed by AI. Computational cost and running expenses could be over the roof. AI mainly targets diseases with high incidence and morbidity, but not much effective for rare diseases with fewer incidences.

Future outlook

Not only for screening and diagnosis, AI has also been found to be instrumental in maintaining Electronic Health Record (EHR) data. Given the plethora of diagnostic tests that patients undergo, these collected EHR data could be fed into the AI system and trained through exposure to normal and pathological clinical data. Therefore, it could be used for risk assessment as well as to predict postoperative complications and outcome.

REFERENCES

- 1 **Ruamviboonsuk P**, Cheung CY, Zhang X, Raman R, Park SJ, Ting DSW. Artificial Intelligence in Ophthalmology: Evolutions in Asia. *Asia Pac J Ophthalmol (Phila)* 2020; **9**: 78-84 [PMID: [32349114](#) DOI: [10.1097/01.APO.0000656980.41190.bf](#)]
- 2 **Sinclair A**, Saeedi P, Kaundal A, Karuranga S, Malanda B, Williams R. Diabetes and global ageing among 65-99-year-old adults: Findings from the International Diabetes Federation Diabetes Atlas, 9th edition. *Diabetes Res Clin Pract* 2020; **162**: 108078 [PMID: [32068097](#) DOI: [10.1016/j.diabres.2020.108078](#)]
- 3 **Padhy SK**, Takkar B, Chawla R, Kumar A. Artificial intelligence in diabetic retinopathy: A natural step to the future. *Indian J Ophthalmol* 2019; **67**: 1004-1009 [PMID: [31238395](#) DOI: [10.4103/ijo.IJO_1989_18](#)]
- 4 **Meyer M**, Wiedorn KH, Hofschneider PH, Koshy R, Caselmann WH. A chromosome 17:7 translocation is associated with a hepatitis B virus DNA integration in human hepatocellular carcinoma DNA. *Hepatology* 1992; **15**: 665-671 [PMID: [1312986](#)]
- 5 **Takahashi H**, Tampo H, Arai Y, Inoue Y, Kawashima H. Applying artificial intelligence to disease staging: Deep learning for improved staging of diabetic retinopathy. *PLoS One* 2017; **12**: e0179790 [PMID: [28640840](#) DOI: [10.1371/journal.pone.0179790](#)]
- 6 **US Food and Drug Administration**. FDA permits marketing of artificial intelligence-based device to detect certain diabetes-related eye problems, 2018. [Cited December 21, 2020]. Available from: <https://www.fda.gov/NewsEvents/Newsroom/PressAnnouncements/ucm604357.htm>
- 7 **Optometry Times**. Pros and Cons of Using an AI-Based Diagnosis for Diabetic Retinopathy. [Cited December 21, 2020]. Available from: <http://www.optometrytimes.com/article/pros-and-cons-using-ai-based-diagnosis-diabetic-retinopathy>
- 8 **Abràmoff MD**, Lou Y, Erginay A, Clarida W, Amelon R, Folk JC, Niemeijer M. Improved Automated Detection of Diabetic Retinopathy on a Publicly Available Dataset Through Integration of Deep Learning. *Invest Ophthalmol Vis Sci* 2016; **57**: 5200-5206 [PMID: [27701631](#) DOI: [10.1167/iovs.16-19964](#)]
- 9 **Gargeya R**, Leng T. Automated Identification of Diabetic Retinopathy Using Deep Learning. *Ophthalmology* 2017; **124**: 962-969 [PMID: [28359545](#) DOI: [10.1016/j.ophtha.2017.02.008](#)]
- 10 **Abràmoff MD**, Lavin PT, Birch M, Shah N, Folk JC. Pivotal trial of an autonomous AI-based diagnostic system for detection of diabetic retinopathy in primary care offices. *NPJ Digit Med* 2018; **1**: 39 [PMID: [31304320](#) DOI: [10.1038/s41746-018-0040-6](#)]
- 11 **Wong LY**, Acharya R, Venkatesh YV, Chee C, Min LC. Identification of different stages of diabetic retinopathy using retinal optical images. *Inf Sci* 2008; **178**: 106-121
- 12 **Imani E**, Pourreza HR, Banaee T. Fully automated diabetic retinopathy screening using morphological component analysis. *Comput Med Imaging Graph* 2015; **43**: 78-88 [PMID: [25863517](#) DOI: [10.1016/j.compmedimag.2015.03.004](#)]
- 13 **Yazid H**, Arof H, Isa HM. Automated identification of exudates and optic disc based on inverse surface thresholding. *J Med Syst* 2012; **36**: 1997-2004 [PMID: [21318328](#) DOI: [10.1007/s10916-011-9659-4](#)]
- 14 **Akyol K**, Şen B, Bayır Ş. Automatic Detection of Optic Disc in Retinal Image by Using Keypoint Detection, Texture Analysis, and Visual Dictionary Techniques. *Comput Math Methods Med* 2016; **2016**: 6814791 [PMID: [27110272](#) DOI: [10.1155/2016/6814791](#)]
- 15 **Niemeijer M**, Abràmoff MD, van Ginneken B. Fast detection of the optic disc and fovea in color fundus photographs. *Med Image Anal* 2009; **13**: 859-870 [PMID: [19782633](#) DOI: [10.1016/j.media.2009.08.003](#)]
- 16 **Rajalakshmi R**, Subashini R, Anjana RM, Mohan V. Automated diabetic retinopathy detection in smartphone-based fundus photography using artificial intelligence. *Eye (Lond)* 2018; **32**: 1138-1144 [PMID: [29520050](#) DOI: [10.1038/s41433-018-0064-9](#)]
- 17 **Bhaskaranand M**, Ramachandra C, Bhat S, Cuadros J, Nittala MG, Sadda S, Solanki K. Automated Diabetic Retinopathy Screening and Monitoring Using Retinal Fundus Image Analysis. *J Diabetes Sci Technol* 2016; **10**: 254-261 [PMID: [26888972](#) DOI: [10.1177/1932296816628546](#)]
- 18 **Ting DSW**, Cheung CY, Lim G, Tan GSW, Quang ND, Gan A, Hamzah H, Garcia-Franco R, San Yeo IY, Lee SY, Wong EYM, Sabanayagam C, Baskaran M, Ibrahim F, Tan NC, Finkelstein EA, Lamoureux EL, Wong IY, Bressler NM, Sivaprasad S, Varma R, Jonas JB, He MG, Cheng CY, Cheung GCM, Aung T, Hsu W, Lee ML, Wong TY. Development and Validation of a Deep Learning System for Diabetic Retinopathy and Related Eye Diseases Using Retinal Images From Multiethnic Populations With Diabetes. *JAMA* 2017; **318**: 2211-2223 [PMID: [29234807](#) DOI: [10.1001/jama.2017.18152](#)]
- 19 **Huemer J**, Wagner SK, Sim DA. The Evolution of Diabetic Retinopathy Screening Programmes: A Chronology of Retinal Photography from 35 mm Slides to Artificial Intelligence. *Clin Ophthalmol* 2020; **14**: 2021-2035 [PMID: [32764868](#) DOI: [10.2147/OPTH.S261629](#)]
- 20 **Wong TY**, Bressler NM. Artificial Intelligence With Deep Learning Technology Looks Into Diabetic Retinopathy Screening. *JAMA* 2016; **316**: 2366-2367 [PMID: [27898977](#) DOI: [10.1001/jama.2016.17563](#)]
- 21 **Ataer-Cansizoglu E**, Bolon-Canedo V, Campbell JP, Bozkurt A, Erdogmus D, Kalpathy-Cramer J, Patel S, Jonas K, Chan RV, Ostmo S, Chiang MF; i-ROP Research Consortium. Computer-Based Image Analysis for Plus Disease Diagnosis in Retinopathy of Prematurity: Performance of the "i-

- ROP" System and Image Features Associated With Expert Diagnosis. *Transl Vis Sci Technol* 2015; **4**: 5 [PMID: 26644965 DOI: 10.1167/tvst.4.6.5]
- 22 **International Committee for the Classification of Retinopathy of Prematurity.** The International Classification of Retinopathy of Prematurity revisited. *Arch Ophthalmol* 2005; **123**: 991-999 [PMID: 16009843 DOI: 10.1001/archophth.123.7.991]
 - 23 **Wittenberg LA, Jonsson NJ, Chan RV, Chiang MF.** Computer-based image analysis for plus disease diagnosis in retinopathy of prematurity. *J Pediatr Ophthalmol Strabismus* 2012; **49**: 11-9; quiz 10, 20 [PMID: 21366159 DOI: 10.3928/01913913-20110222-01]
 - 24 **Brown JM, Campbell JP, Beers A, Chang K, Ostmo S, Chan RVP, Dy J, Erdogmus D, Ioannidis S, Kalpathy-Cramer J, Chiang MF; Imaging and Informatics in Retinopathy of Prematurity (i-ROP) Research Consortium.** Automated Diagnosis of Plus Disease in Retinopathy of Prematurity Using Deep Convolutional Neural Networks. *JAMA Ophthalmol* 2018; **136**: 803-810 [PMID: 29801159 DOI: 10.1001/jamaophthalmol.2018.1934]
 - 25 **Taylor S, Brown JM, Gupta K, Campbell JP, Ostmo S, Chan RVP, Dy J, Erdogmus D, Ioannidis S, Kim SJ, Kalpathy-Cramer J, Chiang MF; Imaging and Informatics in Retinopathy of Prematurity Consortium.** Monitoring Disease Progression With a Quantitative Severity Scale for Retinopathy of Prematurity Using Deep Learning. *JAMA Ophthalmol* 2019 [PMID: 31268518 DOI: 10.1001/jamaophthalmol.2019.2433]
 - 26 **Mookiah MR, Acharya UR, Fujita H, Koh JE, Tan JH, Noronha K, Bhandary SV, Chua CK, Lim CM, Laude A, Tong L.** Local configuration pattern features for age-related macular degeneration characterization and classification. *Comput Biol Med* 2015; **63**: 208-218 [PMID: 26093788 DOI: 10.1016/j.compbiomed.2015.05.019]
 - 27 **Burlina P, Pacheco KD, Joshi N, Freund DE, Bressler NM.** Comparing humans and deep learning performance for grading AMD: A study in using universal deep features and transfer learning for automated AMD analysis. *Comput Biol Med* 2017; **82**: 80-86 [PMID: 28167406 DOI: 10.1016/j.compbiomed.2017.01.018]
 - 28 **Fang L, Cunefare D, Wang C, Guymer RH, Li S, Farsiu S.** Automatic segmentation of nine retinal layer boundaries in OCT images of non-exudative AMD patients using deep learning and graph search. *Biomed Opt Express* 2017; **8**: 2732-2744 [PMID: 28663902 DOI: 10.1364/BOE.8.002732]
 - 29 **Bogunovic H, Waldstein SM, Schlegl T, Langs G, Sadeghipour A, Liu X, Gerendas BS, Osborne A, Schmidt-Erfurth U.** Prediction of Anti-VEGF Treatment Requirements in Neovascular AMD Using a Machine Learning Approach. *Invest Ophthalmol Vis Sci* 2017; **58**: 3240-3248 [PMID: 28660277 DOI: 10.1167/iovs.16-21053]
 - 30 **Bhuiyan A, Wong TY, Ting DSW, Govindaiah A, Souied EH, Smith RT.** Artificial Intelligence to Stratify Severity of Age-Related Macular Degeneration (AMD) and Predict Risk of Progression to Late AMD. *Transl Vis Sci Technol* 2020; **9**: 25 [PMID: 32818086 DOI: 10.1167/tvst.9.2.25]
 - 31 **Martin KR, Mansouri K, Weinreb RN, Wasilewicz R, Gisler C, Hennebert J, Genoud D; Research Consortium.** Use of Machine Learning on Contact Lens Sensor-Derived Parameters for the Diagnosis of Primary Open-angle Glaucoma. *Am J Ophthalmol* 2018; **194**: 46-53 [PMID: 30053471 DOI: 10.1016/j.ajo.2018.07.005]
 - 32 **Omodaka K, An G, Tsuda S, Shiga Y, Takada N, Kikawa T, Takahashi H, Yokota H, Akiba M, Nakazawa T.** Classification of optic disc shape in glaucoma using machine learning based on quantified ocular parameters. *PLoS One* 2017; **12**: e0190012 [PMID: 29261773 DOI: 10.1371/journal.pone.0190012]
 - 33 **Christopher M, Belghith A, Weinreb RN, Bowd C, Goldbaum MH, Saunders LJ, Medeiros FA, Zangwill LM.** Retinal Nerve Fiber Layer Features Identified by Unsupervised Machine Learning on Optical Coherence Tomography Scans Predict Glaucoma Progression. *Invest Ophthalmol Vis Sci* 2018; **59**: 2748-2756 [PMID: 29860461 DOI: 10.1167/iovs.17-23387]
 - 34 **Barella KA, Costa VP, Gonçalves Vidotti V, Silva FR, Dias M, Gomi ES.** Glaucoma Diagnostic Accuracy of Machine Learning Classifiers Using Retinal Nerve Fiber Layer and Optic Nerve Data from SD-OCT. *J Ophthalmol* 2013; **2013**: 789129 [PMID: 24369495 DOI: 10.1155/2013/789129]
 - 35 **Bizios D, Heijl A, Hougaard JL, Bengtsson B.** Machine learning classifiers for glaucoma diagnosis based on classification of retinal nerve fibre layer thickness parameters measured by Stratus OCT. *Acta Ophthalmol* 2010; **88**: 44-52 [PMID: 20064122 DOI: 10.1111/j.1755-3768.2009.01784.x]
 - 36 **Larrosa JM, Polo V, Ferreras A, García-Martín E, Calvo P, Pablo LE.** Neural Network Analysis of Different Segmentation Strategies of Nerve Fiber Layer Assessment for Glaucoma Diagnosis. *J Glaucoma* 2015; **24**: 672-678 [PMID: 25055209 DOI: 10.1097/IJG.0000000000000071]
 - 37 **Li Z, He Y, Keel S, Meng W, Chang RT, He M.** Efficacy of a Deep Learning System for Detecting Glaucomatous Optic Neuropathy Based on Color Fundus Photographs. *Ophthalmology* 2018; **125**: 1199-1206 [PMID: 29506863 DOI: 10.1016/j.ophtha.2018.01.023]
 - 38 **Al-Aswad LA, Kapoor R, Chu CK, Walters S, Gong D, Garg A, Gopal K, Patel V, Sameer T, Rogers TW, Nicolas J, De Moraes GC, Moazami G.** Evaluation of a Deep Learning System For Identifying Glaucomatous Optic Neuropathy Based on Color Fundus Photographs. *J Glaucoma* 2019; **28**: 1029-1034 [PMID: 31233461 DOI: 10.1097/IJG.0000000000001319]
 - 39 **Akkara JD, Kuriakose A.** Role of artificial intelligence and machine learning in ophthalmology. *Kerala J Ophthalmol* 2019; **31**: 150-160
 - 40 **Asaoka R, Murata H, Iwase A, Araie M.** Detecting Preperimetric Glaucoma with Standard Automated Perimetry Using a Deep Learning Classifier. *Ophthalmology* 2016; **123**: 1974-1980 [PMID: 27395766 DOI: 10.1016/j.ophtha.2016.05.029]

- 41 **Andersson S**, Heijl A, Bizios D, Bengtsson B. Comparison of clinicians and an artificial neural network regarding accuracy and certainty in performance of visual field assessment for the diagnosis of glaucoma. *Acta Ophthalmol* 2013; **91**: 413-417 [PMID: [22583841](#) DOI: [10.1111/j.1755-3768.2012.02435.x](#)]
- 42 **Goldbaum MH**, Sample PA, Zhang Z, Chan K, Hao J, Lee TW, Boden C, Bowd C, Bourne R, Zangwill L, Sejnowski T, Spinak D, Weinreb RN. Using unsupervised learning with independent component analysis to identify patterns of glaucomatous visual field defects. *Invest Ophthalmol Vis Sci* 2005; **46**: 3676-3683 [PMID: [16186349](#) DOI: [10.1167/iovs.04-1167](#)]
- 43 **Bowd C**, Weinreb RN, Balasubramanian M, Lee I, Jang G, Yousefi S, Zangwill LM, Medeiros FA, Girkin CA, Liebmann JM, Goldbaum MH. Glaucomatous patterns in Frequency Doubling Technology (FDT) perimetry data identified by unsupervised machine learning classifiers. *PLoS One* 2014; **9**: e85941 [PMID: [24497932](#) DOI: [10.1371/journal.pone.0085941](#)]
- 44 **Gao X**, Lin S, Wong TY. Automatic Feature Learning to Grade Nuclear Cataracts Based on Deep Learning. *IEEE Trans Biomed Eng* 2015; **62**: 2693-2701 [PMID: [26080373](#) DOI: [10.1109/TBME.2015.2444389](#)]
- 45 **Liu X**, Jiang J, Zhang K, Long E, Cui J, Zhu M, An Y, Zhang J, Liu Z, Lin Z, Li X, Chen J, Cao Q, Li J, Wu X, Wang D, Lin H. Localization and diagnosis framework for pediatric cataracts based on slit-lamp images using deep features of a convolutional neural network. *PLoS One* 2017; **12**: e0168606 [PMID: [28306716](#) DOI: [10.1371/journal.pone.0168606](#)]
- 46 **Wu X**, Huang Y, Liu Z, Lai W, Long E, Zhang K, Jiang J, Lin D, Chen K, Yu T, Wu D, Li C, Chen Y, Zou M, Chen C, Zhu Y, Guo C, Zhang X, Wang R, Yang Y, Xiang Y, Chen L, Liu C, Xiong J, Ge Z, Wang D, Xu G, Du S, Xiao C, Wu J, Zhu K, Nie D, Xu F, Lv J, Chen W, Liu Y, Lin H. Universal artificial intelligence platform for collaborative management of cataracts. *Br J Ophthalmol* 2019; **103**: 1553-1560 [PMID: [31481392](#) DOI: [10.1136/bjophthalmol-2019-314729](#)]
- 47 **Dong Y**, Zhang Q, Qiao Z, Yang J. Classification of cataract fundus image based on deep learning. In: 2017 IEEE International Conference on Imaging Systems and Techniques; 2017 Oct 18-20; Beijing, China. IEEE; 2017: 1-5
- 48 **Yu F**, Silva Croso G, Kim TS, Song Z, Parker F, Hager GD, Reiter A, Vedula SS, Ali H, Sikder S. Assessment of Automated Identification of Phases in Videos of Cataract Surgery Using Machine Learning and Deep Learning Techniques. *JAMA Netw Open* 2019; **2**: e191860 [PMID: [30951163](#) DOI: [10.1001/jamanetworkopen.2019.1860](#)]
- 49 **Zisimopoulos O**, Flouty E, Luengo I, Giataganas P, Nehme J, Chow A, Stoyanov D. Deep Phase: surgical phase recognition in CATARACTS videos. In: Frangi A, Schnabel J, Davatzikos C, Alberola-López C, Fichtinger G, editors. Medical Image Computing and Computer Assisted Intervention – MICCAI 2018. Cham: Springer; 2018: 265-272 [DOI: [10.1007/978-3-030-00937-3_31](#)]
- 50 **Melles RB**, Kane JX, Olsen T, Chang WJ. Update on Intraocular Lens Calculation Formulas. *Ophthalmology* 2019; **126**: 1334-1335 [PMID: [30980854](#) DOI: [10.1016/j.ophtha.2019.04.011](#)]
- 51 **Connell BJ**, Kane JX. Comparison of the Kane formula with existing formulas for intraocular lens power selection. *BMJ Open Ophthalmol* 2019; **4**: e000251 [PMID: [31179396](#) DOI: [10.1136/bmjophth-2018-000251](#)]
- 52 **Hoffer KJ**. Intraocular lens power calculation after previous laser refractive surgery. *J Cataract Refract Surg* 2009; **35**: 759-765 [PMID: [19304101](#) DOI: [10.1016/j.jcrs.2009.01.005](#)]



Published by **Baishideng Publishing Group Inc**
7041 Koll Center Parkway, Suite 160, Pleasanton, CA 94566, USA

Telephone: +1-925-3991568

E-mail: bpgoffice@wjgnet.com

Help Desk: <https://www.f6publishing.com/helpdesk>

<https://www.wjgnet.com>

