ISSN 2308-3840 (online)

World Journal of *Meta-Analysis*

World J Meta-Anal 2019 April 30; 7(4): 120-183

Published by Baishideng Publishing Group Inc

WJMA

World Journal of Meta-Analysis

Contents

Irregular Volume 7 Number 4 April 30, 2019

ABOUT COVER

Editorial Board Member of *World Journal of Meta-Analysis*, Matthew L Bechtold, MD, Assistant Professor, Director of Endoscopy and Ambulatory Services, Division of Gastroenterology and Hepatology, Department of Internal Medicine, University Hospital and Clinics, Columbia, MO 65212, United States

AIMS AND SCOPE

World Journal of Meta-Analysis (*World J Meta-Anal*, *WJMA*, online ISSN 2308-3840, DOI: 10.13105) is a peer-reviewed open access academic journal that aims to guide clinical practice and improve diagnostic and therapeutic skills of clinicians, with a specific focus on meta-analysis, systematic review, mixed-treatment comparison, meta-regression, overview of reviews.

The *WJMA* covers a variety of clinical medical fields including allergy, anesthesiology, cardiac medicine, clinical genetics, clinical neurology, critical care, dentistry, dermatology, emergency medicine, endocrinology, family medicine, gastroenterology and hepatology, geriatrics and gerontology, hematology, immunology, infectious diseases, internal medicine, obstetrics and gynecology, oncology, ophthalmology, orthopedics, otolaryngology, pathology, *etc*, while maintaining its unique dedication to systematic reviews and meta-analyses.

INDEXING/ABSTRACTING

The *WJMA* is now abstracted and indexed in Emerging Sources Citation Index (Web of Science), China National Knowledge Infrastructure (CNKI), China Science and Technology Journal Database (CSTJ), and Superstar Journals Database

RESPONSIBLE EDITORS FOR THIS ISSUE

Responsible Electronic Editor: *Yun-Xiaojian Wu* **Proofing Editorial Office Director:** *Jin-Lei Wang*

NAME OF JOURNAL
World Journal of Meta-Analysis

ISSN
ISSN 2308-3840 (online)

LAUNCH DATE
May 26, 2013

FREQUENCY
Irregular

EDITORS-IN-CHIEF
Giuseppe Biondi-Zoccai

EDITORIAL BOARD MEMBERS
https://www.wjgnet.com/2308-3840/editorialboard.htm

EDITORIAL OFFICE
Jin-Lei Wang, Director

PUBLICATION DATE
April 30, 2019

INSTRUCTIONS TO AUTHORS
https://www.wjgnet.com/bpg/gerinfo/204

GUIDELINES FOR ETHICS DOCUMENTS
https://www.wjgnet.com/bpg/GerInfo/287

GUIDELINES FOR NON-NATIVE SPEAKERS OF ENGLISH
https://www.wjgnet.com/bpg/gerinfo/240

PUBLICATION MISCONDUCT
https://www.wjgnet.com/bpg/gerinfo/208

ARTICLE PROCESSING CHARGE
https://www.wjgnet.com/bpg/gerinfo/242

STEPS FOR SUBMITTING MANUSCRIPTS
https://www.wjgnet.com/bpg/GerInfo/239

ONLINE SUBMISSION
https://www.f6publishing.com

World Journal of Meta-Analysis

Submit a Manuscript: https://www.f6publishing.com

World J Meta-Anal 2019 April 30; 7(4): 120-128

DOI: 10.13105/wjma.v7.i4.120

ISSN 2308-3840 (online)

REVIEW

Endoscopic management of biliary strictures post-liver transplantation

Ahmed Akhter, Patrick Pfau, Mark Benson, Anurag Soni, Deepak Gopal

ORCID number: Ahmed Akhter (0000-0003-2747-2879); Pat Pfau (0000-0002-1050-4777); Mark Benson (0000-0002-7358-5068); Anurag Soni (0000-0002-9896-251X); Deepak Gopal (0000-0002-2679-9856).

Author contributions: All authors contributed to this paper with conception and design of the study, literature review and analysis, drafting and critical revision and editing, and final approval of the final version.

Conflict-of-interest statement: No potential conflicts of interest. No financial support.

Manuscript source: Invited manuscript

Received: February 22, 2019
Peer-review started: February 22, 2019
First decision: April 13, 2019
Revised: April 22, 2019
Accepted: April 23, 2019
Article in press: April 23, 2019

Ahmed Akhter, Patrick Pfau, Mark Benson, Anurag Soni, Deepak Gopal, Division of Gastroenterology and Hepatology, Department of Medicine, University of Wisconsin Hospitals and Clinics, Madison, WI 53705, United States

Corresponding author: Deepak Gopal, MD, FRCP (C), FASGE, FACP, FACG, AGAF, Professor, Division of Gastroenterology and Hepatology, Department of Medicine, University of Wisconsin Hospitals and Clinics, 1685 Highland Avenue, Madison, WI 53705, United States. dvg@medicine.wisc.edu
Telephone: +1-608-2637322
Fax: +1-608-2655677

Abstract

Biliary complications play a significant role in morbidity of liver transplant recipients. Biliary strictures occur between 10%-25% of patients with a higher incidence in living donor recipients compared to deceased donors. Strictures can be classified as either anastomotic or non-anastomotic and may be related to ischemic events. Endoscopic management of biliary strictures in the post-transplant setting has become the preferred initial approach due to adequate rates of resolution of anastomotic and non-anastomotic strictures (NAS). However, several factors may increase complexity of the endoscopic approach including surgical anatomy, location, number, and severity of bile duct strictures. Many endoscopic tools are available, however, the approach to management of anastomotic and NAS has not been standardized. Multi-disciplinary techniques may be necessary to achieve optimal outcomes in select patients. We will review the risk factors associated with the development of bile duct strictures in the post-transplant setting along with the efficacy and complications of current endoscopic approaches available for the management of bile duct strictures.

Key words: Liver transplantation; Endoscopic management; Anastomosis; Biliary strictures; Biliary balloon dilation; Biliary stents

Core tip: Biliary strictures occur between 10%-25% of patients with a higher incidence in living donor recipients compared to deceased donors. Strictures can be classified as either anastomotic or non-anastomotic and may be related to ischemic events. Many endoscopic tools are available, however, the approach to management of anastomotic and non-anastomotic strictures has not been standardized. We will review the risk factors associated with the development of bile duct strictures in the post-transplant setting

Published online: April 30, 2019

P-Reviewer: de Moura DTH, Hu B, Tsou YK
S-Editor: Ji FF
L-Editor: A
E-Editor: Wu YXJ

along with the efficacy and complications of current endoscopic approaches available for the management of bile duct strictures.

Citation: Akhter A, Pfau P, Benson M, Soni A, Gopal D. Endoscopic management of biliary strictures post-liver transplantation. *World J Meta-Anal* 2019; 7(4): 120-128
URL: https://www.wjgnet.com/2308-3840/full/v7/i4/120.htm
DOI: https://dx.doi.org/10.13105/wjma.v7.i4.120

INTRODUCTION

Biliary complications after liver transplantation (LT) is a known and significant cause of morbidity in LT recipients. The incidence of post-LT biliary complications is increasing due to increased volume of transplants and longer survival of LT recipients[1]. It is estimated between 5%-35% of LT recipients have biliary complications[2,3]. The incidence of complications can be attributed to various techniques of LT including the use of living and deceased cardiac donors, number of donor bile ducts used, and type of surgical anastomosis[4]. Most often the donor liver and residual native bile duct are established in continuity with the creation of a choledochocholedochostomy[5,6]. However, the presence of primary sclerosing cholangitis (PSC) results in the creation of a hepaticojejunostomy. A roux limb is created and adds to the complexity of endoscopic management of biliary complications and may require the aid of a balloon assisted enteroscope for technical success[7].

There are a variety of biliary complications that can arise which include the development of anastomotic and non-anastomotic strictures (NAS), bile duct leaks, papillary stenosis, and presence of bile duct stones/casts. Diagnosis is usually made with a combination of non-invasive tests including liver chemistries, abdominal ultrasound, and cross-sectional imaging (computed tomography and/or magnetic resonance cholangiopancreatography). It is important to consider non-obstructive causes of cholestasis including cellular rejection, drug induced cholestasis, or recurrence of primary disease as this may prevent a delay in therapeutic intervention. Advancements in endoscopic techniques and tools have allowed endoscopic management to be the preferred method to manage most biliary complications[8,9]. Our review will focus on endoscopic management of biliary strictures that can arise after LT.

BILE DUCT STRICTURES

There are several risk factors that predispose to the development of bile duct strictures including hepatic artery thrombosis, donor after cardiac death, ABO incompatibility, preservation injury (cold and warm ischemia time), cytomegalovirus infection, duct mismatch between donor and recipient, presence of PSC, bile duct leaks, placement of T-tubes, and living donor transplantation (LDT)[10-15]. Bile duct strictures can be noted early (< 30 d), delayed (30-90 d), or late (> 90 d) after LT[11,16] (Figure 1). Early complications include hepatic artery thrombosis which can result in ductal stenosis and strictures as well as hepatic ischemia[5]. Post-operative edema can also result in early ductal stenosis. Delayed and late complications can involve biliary obstruction at the anastomotic site or intrahepatic ducts due to ischemia[17]. Bile leaks and recurrence of PSC are risk factors for the development of delayed/late bile duct strictures. T-tubes were previously used more frequently after LT to help maintain the reconstruction of the bile duct anastomosis. However, recent studies have found they may increase the risk of biliary complications including biliary strictures and may be more beneficial for select patients such as those who have a donor-recipient duct mismatch or a bile duct diameter < 7 mm[18,19].

LDT was first performed successfully in 1994 and has been steadily increasing due to limited supply of deceased donors[20]. LDT has advantages over deceased donor transplantation (DDT) including reduction of cold ischemia time and improved graft viability[21,22]. Nonetheless, there is a higher risk of biliary complications and specifically biliary strictures in LDT *vs* DDT (13%-32% *vs* 5%-15%)[23-25]. Incidence of biliary strictures in living donors' range between 0.5%-4%[26,27]. LDT is presumed to carry a higher risk of biliary strictures due to the anastomosis of low-caliber and small

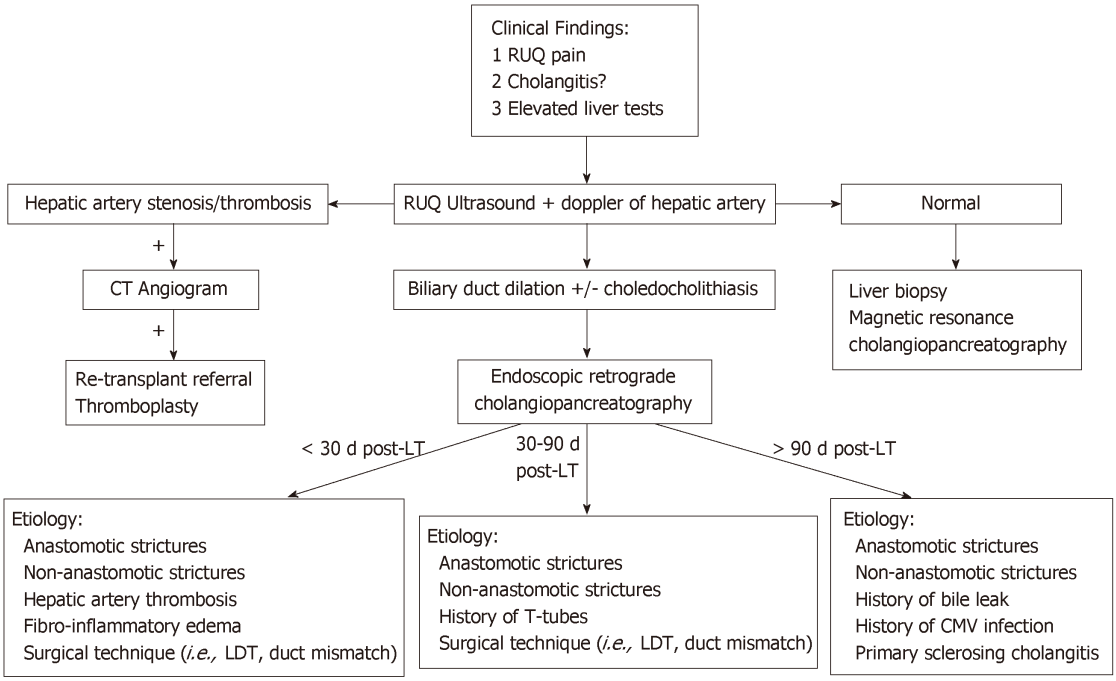

Figure 1 Evaluation of suspected bile duct strictures post-liver transplantation. LDT: Living donor transplantation; LT: Liver transplantation; RUQ: Right upper quadrant.

ducts as well as increased number of donor ducts needed to establish biliary continuity[23]. Bile duct strictures can be categorized as anastomotic or non-anastomotic with differences in endoscopic management and outcomes.

ANASTOMOTIC BILE DUCT STRICTURES

Anastomotic bile duct strictures (AS) occur in 5%-10% of patients within the first 12 mo of transplantation[28,29]. However, they should always be considered in the setting of a cholestatic pattern of liver injury in LT recipients. As opposed to NAS, AS are segmental, shorter, and localized to the site of anastomosis[23,30]. Bile leaks may be an independent risk factor for the development of an AS. An AS may form within 60 d after LT due to post-operative edema and fibro-inflammatory response along with transient ischemia[1,31,32]. Strictures that form within the first 60 d respond well to 1-2 sessions of endoscopic dilation and plastic stent placement[1].

However, biliary strictures that form after 3 mo have a protracted course and require prolonged endoscopic sessions for adequate response. Endoscopic approaches for anastomotic strictures include balloon dilation, passage dilation with a Soehendra biliary dilation catheter, plastic biliary stents, and self-expandable metal stents (SEMS). A guidewire is used to cross the stricture and balloon dilators from 4-10 mm are used to dilate the anastomosis along with placement of 7 Fr to 11.5 Fr plastic stents bridging the anastomosis. The balloon size used to dilate is predicated upon the diameter of the donor bile duct. Soehendra dilators are useful in patients whom the anastomosis is severely stenosed and can be dilated from 4-10 Fr. In addition, balloon dilation is generally avoided in early strictures (< 3 mo) to avoid perforation or leaks of a recently constructed anastomosis. Most patients with an AS and those who present after 3 mo of LT, require several endoscopic sessions (3-5) for long-term success[28,33]. The patency of most plastic biliary stents is 3 mo and thus, endoscopic sessions are performed at 8-12-wk intervals to prevent biliary obstruction[16]. The pre-existing stent is removed using a snare or forceps and a cholangiogram is performed to evaluate the patency of the anastomosis. There is no standardized bile duct diameter that corresponds to a clinically significant bile duct stenosis. However, cholangiogram features of a thin focal narrowing with proximal bile duct dilation along with evaluating the resistance encountered with anterograde and/or retrograde biliary balloon sweeps with an 8.5 mm or 11.5 mm biliary balloon across the anastomosis can help determine the patency of the anastomosis. In general, the goal is to dilate the anastomosis with larger sized dilators and in combination with increasing size or number of plastic biliary stents until patency is achieved and a waist

is no longer seen (Figure 2). Combination of balloon dilation and biliary stenting have shown to be more effective than balloon dilation alone[34,35]. Balloon dilation alone has a high recurrence rate of stricture formation when compared to balloon dilation and biliary stenting (62% *vs* 31%)[35]. LDT has lower success rates of stricture resolution compared to DDT despite similar techniques of balloon dilation plus plastic biliary stents (37%-71% *vs* 75%-91%)[36-39]. This may in part be explained due to the use of peripheral ducts and presence of smaller multiple anastomotic strictures[1]. Resolution of anastomotic strictures are improved with multiple and maximum number of plastic biliary stents. Several studies evaluating anastomotic stricture resolution in LT recipients found resolution rates to range between 87%-100% with recurrence in 0%-18% of patients[32,40-43]. Number of endoscopic sessions to achieve stricture resolution ranged between 3-4 with a complication rate of 1.5%-5%. Complications were primarily related to pancreatitis and cholangitis.

An alternative strategy is to place a SEMS to prevent or reduce the need for frequent ERCPs that is necessary in the setting of plastic biliary stenting. Covered metallic stents have been used as uncovered SEMS may not be able to be removed and may preclude surgical bile duct intervention. In addition, a metallic stent may lead to hyperplasia leading to the formation of sludge/stone formation proximal to the stent[1]. The role of covered SEMS has yet to be precisely defined but can be useful because of their larger diameter (10 mm), longer patency, and ability to be removed. However, they are limited because of rates of stent migration (4%-38%). Several studies examining the utility of covered SEMS after LT found resolution rates of anastomotic strictures between 61%-83%[44-48]. Recurrence rates were higher in those who received SEMS ranging between 7%-32%[44-49]. A randomized trial evaluating covered SEMS and plastic biliary stents found in sub-group analysis of post-transplant patients resolution rates of 89% *vs* 86% with 158 to 194 d till resolution respectively. Stricture recurrence was higher in the covered SEMS group and stent migration occurred more frequently in post-transplant AS compared to all other cases[50]. To mitigate the risks of stent migration an alternative is to use partially covered SEMS or stents with special anchoring flanges and anti-migration waists[51]. A systematic review of case series including 446 patients by Kao *et al*[52] did not find SEMS to have a clear advantage over multiple plastic biliary stents in LT recipients but found stricture resolution was improved in those patients whom the stent duration was longer than 3 mo. A recent meta-analysis of four randomized controlled trials comparing plastic stents to fully covered SEMS found no difference between stricture resolution, stricture recurrence, and adverse events. However, those who received a metal stent did have fewer ERCPs performed as compared to those who had plastic stents[53]. Currently, there is no standardized approach for endoscopic management of AS. The use of multiple plastic biliary stents with balloon dilation and fully covered SEMS can provide similar resolution rates of AS after LT with overall low risk of adverse events.

NAS

NAS of the bile ducts have an incidence of 5%-10% after LT[33,54,55]. The definition of a NAS is the presence of stenosis > 5 mm away from the anastomosis and may be located within the intrahepatics, hilum, or anywhere else along the bile duct (including the recipient duct). In contrast to AS, NAS may be multiple and longer in length. Recurrent PSC in the allograft or vascular insufficiency may result in the development of NAS. Vascular ischemia secondary to hepatic artery thrombosis results in biliary destruction and warm and cold ischemia, donation after cardiac death, ABO incompatibility, and chronic rejection are also risk factors for the development of NAS[1,30]. NAS tend to occur 3-6 mo after LT though as many as 50% of patients may develop NAS after the first-year post-transplant[54,56,57].

The principles regarding the management of NAS are similar to anastomotic strictures, however, the optimal protocol has not been established. Balloon dilation with placement of plastic biliary stents have shown to be helpful though with less success and longer time to resolution as compared to anastomotic strictures[33,58]. Balloon dilation is often not as aggressive as in AS with 4-6 mm biliary balloons commonly used. Overall, resolution rates of NAS range between 50%-75% and are associated with worse graft survival[30,59]. However, a study of 48 patients comparing balloon dilation alone *vs* balloon dilation and plastic biliary stents found a significant difference and improvement in stricture resolution in those who only underwent balloon dilation (91% *vs* 31%)[60]. This may in part be explained by most of these strictures being located extra-hepatic.

Bile duct strictures involving the hilum and intrahepatics may be more challenging

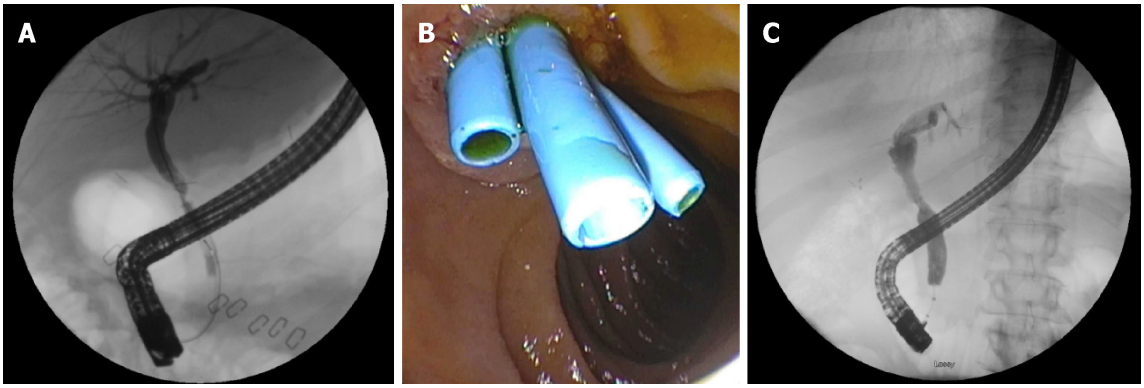

Figure 2 Anastomotic bile duct stricture managed with biliary stenting and balloon dilation. A: A patient less than 60 d post-liver transplantation who presented with elevated liver tests and found to have an anastomotic bile duct stricture; B: The patient was managed with serial balloon dilation and multiple biliary stents; C: Approximately 9 mo post-liver transplantation the anastomotic stricture had resolved and required no further intervention.

due to difficulty with traversing the stricture secondary to the small caliber of these ducts as well as tortuosity that may be encountered. Longer, fenestrated stents (Johlin), are flexible and can be used for intrahepatic strictures and allow for adequate drainage *via* multiple side holes and interstent space[61]. Covered metal stents have not been readily used as they may impede flow from surrounding bile ducts and potentially increase risk of cholangitis.

NAS may progress despite improvement in liver enzymes in up to two-third of patients[40,54]. Progression of NAS is more common in patients who develop NAS within the first year after transplantation or who have recurrent cholangitis[57]. Like AS endoscopic resolution rates for NAS in LDT is lower than in DDT 25%-33% *vs* 50%-60% respectively[39,62]. Currently there is no standard protocol for management of NAS. NAS are of varying complexity with intrahepatic and hilar strictures providing an especially unique challenge to the endoscopist which may require alternative approaches for access and therapeutic interventions to the bile duct.

ALTERNATIVE APPROACHES

Endoscopic methods may not be feasible due to surgical anatomy (bilio-enteric anastomosis), tortuosity and angulation of the bile duct, or severity and location of the stricture which prevents a guidewire or dilation devices to traverse the stricture. Roux-en-Y hepaticojejunosotomy or roux-en-Y gastric bypass require deep ERCP methods such as balloon-assisted enteroscopy, endoscopic ultrasonography-directed transgastric ERCP, or percutaneous transhepatic cholangiography (PTC). A multi-center trial showed balloon assisted enteroscopy to be successful in two thirds of cases and in 88% of patients in whom the papilla is reached. Single or double balloon assisted enteroscopy may be an alternative before pursuing PTC or surgical alternatives[63].

A rendezvous technique may also be used which combines PTC and an endoscopic transpapillary approach to access the bile duct and traverse the stricture that otherwise may have failed with conventional endoscopy (Figure 3). PTC in cases of benign bilio-enteric anastomotic strictures are reported to have an overall success rate of 80%[64]. It is also especially helpful in those with intractable or multiple intrahepatic strictures as internal-external stents can be placed and relieve the obstruction. In addition, the potential of swing-tip cannulas in accessing tight intrahepatic strictures have been reported and may also help achieve faster cannulation of the bile duct[65,66].

Single-operator peroral cholangioscopy can also be used in the treatment of bile duct strictures by providing direct visualization of the lumen of the bile ducts. Direct visualization of the inside of the bile duct may help predict outcomes of endoscopic therapy based upon the pattern and severity of edema and inflammation seen[67]. In addition, direct visualization can also be used in conjunction with the rendezvous technique to puncture the bile duct and safely traverse a completely obstructed duct[68,69].

Magnetic compression anastomosis (MCA) is a rescue technique used in the setting of complete biliary obstruction. A magnet is advanced to the site of the stricture *via* ERCP and another magnet is advanced percutaneously *via* PTC. Fluoroscopy is used to properly align the magnets and a hole in the center of the magnets allow a guidewire to be advanced. Recanalization can be achieved *via* PTC and serial biliary

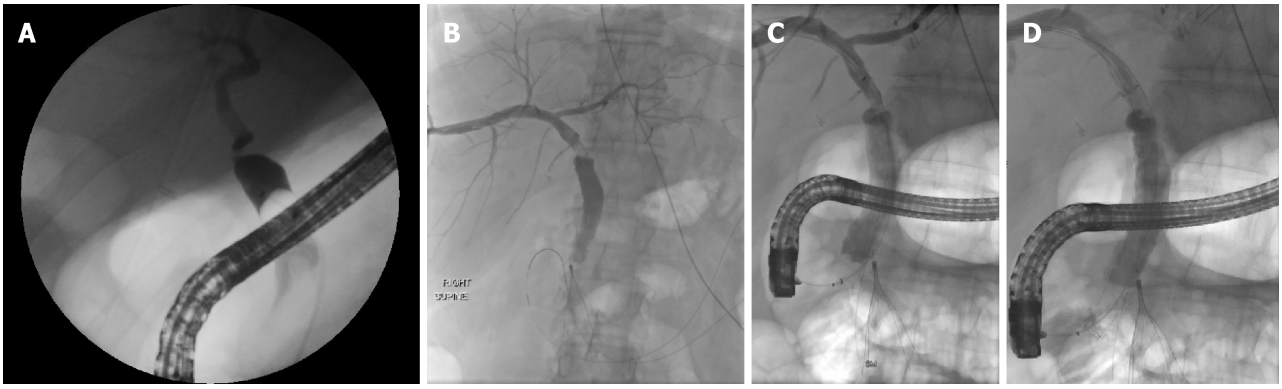

Figure 3 Anastomotic bile duct stricture treated with rendezvous technique. A: A 56-year-old patient who presented two years after transplantation with jaundice and found to have a severe anastomotic stricture which was not able to be traversed with a guidewire; B: Percutaneous transhepatic cholangiogram showing a stricture at the anastomosis with the guidewire inserted through the transhepatic tract; C: The rendezvous technique was used to advance the endoscopic catheter over the transhepatic guidewire and proximal to the anastomotic stricture; D: A fully covered metal biliary stent was placed traversing the anastomosis.

stenting can be performed. Magnet approximation and recanalization have been reported to be successful in 84% and 77% of patients respectively. MCA has been shown to be effective for short strictures (< 1 cm) with a low stricture recurrence rate[70,71].

CONCLUSION

Biliary strictures play a significant role in morbidity of LT recipients. There exists a variety of techniques to approach anastomotic and NAS. However, despite the use of balloon and passage dilators along with plastic and metal stents, there is no standardized method to approach intrahepatic, hilar, or extra-hepatic bile duct strictures. In addition, patients with altered surgical anatomy and increasing use of LDT add to the complexity of providing successful outcomes. Nonetheless, endoscopic management of anastomotic and NAS are predominantly successful with relatively low complication rates. Further larger and comparative trials along with the advent of more endoscopic tools may allow for increasing rates of success and improved times till resolution of biliary strictures.

ACKNOWLEDGEMENTS

John McDermott, Department of Radiology, University of Wisconsin Hospitals and Clinics, Madison, WI 53719, United States.

REFERENCES

1 **Girotra M**, Soota K, Klair JS, Dang SM, Aduli F. Endoscopic management of post-liver transplant biliary complications. *World J Gastrointest Endosc* 2015; **7**: 446-459 [PMID: 25992185 DOI: 10.4253/wjge.v7.i5.446]

2 **Ayoub WS**, Esquivel CO, Martin P. Biliary complications following liver transplantation. *Dig Dis Sci* 2010; **55**: 1540-1546 [PMID: 20411422 DOI: 10.1007/s10620-010-1217-2]

3 **Balderramo D**, Navasa M, Cardenas A. Current management of biliary complications after liver transplantation: emphasis on endoscopic therapy. *Gastroenterol Hepatol* 2011; **34**: 107-115 [PMID: 20692731 DOI: 10.1016/j.gastrohep.2010.05.008]

4 **Lee HW**, Shah NH, Lee SK. An Update on Endoscopic Management of Post-Liver Transplant Biliary Complications. *Clin Endosc* 2017; **50**: 451-463 [PMID: 28415168 DOI: 10.5946/ce.2016.139]

5 **Ostroff JW**. Post-transplant biliary problems. *Gastrointest Endosc Clin N Am* 2001; **11**: 163-183 [PMID: 11175980 DOI: 10.1016/S1052-5157(18)30092-8]

6 **Stratta RJ**, Wood RP, Langnas AN, Hollins RR, Bruder KJ, Donovan JP, Burnett DA, Lieberman RP, Lund GB, Pillen TJ. Diagnosis and treatment of biliary tract complications after orthotopic liver transplantation. *Surgery* 1989; **106**: 675-683; discussion 683-684 [PMID: 2799642 DOI: 10.1097/00006534-198984040-00022]

7 **Scatton O**, Meunier B, Cherqui D, Boillot O, Sauvanet A, Boudjema K, Launois B, Fagniez PL, Belghiti J, Wolff P, Houssin D, Soubrane O. Randomized trial of choledochocholedochostomy with or without a T tube in orthotopic liver transplantation. *Ann Surg* 2001; **233**: 432-437 [PMID: 11224633 DOI: 10.1097/00000658-200103000-00019]

8 **Scanga AE**, Kowdley KV. Management of biliary complications following orthotopic liver transplantation. *Curr Gastroenterol Rep* 2007; **9**: 31-38 [PMID: 17335675 DOI:

10.1007/s11894-008-0018-7]
9 **Shah SA**, Grant DR, McGilvray ID, Greig PD, Selzner M, Lilly LB, Girgrah N, Levy GA, Cattral MS. Biliary strictures in 130 consecutive right lobe living donor liver transplant recipients: results of a Western center. *Am J Transplant* 2007; **7**: 161-167 [PMID: 17227565 DOI: 10.1111/j.1600-6143.2006.01601.x]
10 **Greif F**, Bronsther OL, Van Thiel DH, Casavilla A, Iwatsuki S, Tzakis A, Todo S, Fung JJ, Starzl TE. The incidence, timing, and management of biliary tract complications after orthotopic liver transplantation. *Ann Surg* 1994; **219**: 40-45 [PMID: 8297175 DOI: 10.1097/00000658-199401000-00007]
11 **Thuluvath PJ**, Pfau PR, Kimmey MB, Ginsberg GG. Biliary complications after liver transplantation: the role of endoscopy. *Endoscopy* 2005; **37**: 857-863 [PMID: 16116539 DOI: 10.1055/s-2005-870192]
12 **Pascher A**, Neuhaus P. Biliary complications after deceased-donor orthotopic liver transplantation. *J Hepatobiliary Pancreat Surg* 2006; **13**: 487-496 [PMID: 17139421 DOI: 10.1007/s00534-005-1083-z]
13 **Dacha S**, Barad A, Martin J, Levitsky J. Association of hepatic artery stenosis and biliary strictures in liver transplant recipients. *Liver Transpl* 2011; **17**: 849-854 [PMID: 21455929 DOI: 10.1002/lt.22298]
14 **Brunner SM**, Junger H, Ruemmele P, Schnitzbauer AA, Doenecke A, Kirchner GI, Farkas SA, Loss M, Scherer MN, Schlitt HJ, Fichtner-Feigl S. Bile duct damage after cold storage of deceased donor livers predicts biliary complications after liver transplantation. *J Hepatol* 2013; **58**: 1133-1139 [PMID: 23321317 DOI: 10.1016/j.jhep.2012.12.022]
15 **Sundaram V**, Jones DT, Shah NH, de Vera ME, Fontes P, Marsh JW, Humar A, Ahmad J. Posttransplant biliary complications in the pre- and post-model for end-stage liver disease era. *Liver Transpl* 2011; **17**: 428-435 [PMID: 21445926 DOI: 10.1002/lt.22251]
16 **Gopal DV**, Pfau PR, Lucey MR. Endoscopic Management of Biliary Complications After Orthotopic Liver Transplantation. *Curr Treat Options Gastroenterol* 2003; **6**: 509-515 [PMID: 14585240 DOI: 10.1007/s11938-003-0053-2]
17 **Mosca S**, Militerno G, Guardascione MA, Amitrano L, Picciotto FP, Cuomo O. Late biliary tract complications after orthotopic liver transplantation: diagnostic and therapeutic role of endoscopic retrograde cholangiopancreatography. *J Gastroenterol Hepatol* 2000; **15**: 654-660 [PMID: 10921420 DOI: 10.1046/j.1440-1746.2000.02198.x]
18 **Sotiropoulos GC**, Sgourakis G, Radtke A, Molmenti EP, Goumas K, Mylona S, Fouzas I, Karaliotas C, Lang H. Orthotopic liver transplantation: T-tube or not T-tube? Systematic review and meta-analysis of results. *Transplantation* 2009; **87**: 1672-1680 [PMID: 19502959 DOI: 10.1097/TP.0b013e3181a5cf3f]
19 **López-Andújar R**, Orón EM, Carregnato AF, Suárez FV, Herraiz AM, Rodríguez FS, Carbó JJ, Ibars EP, Sos JE, Suárez AR, Castillo MP, Pallardó JM, De Juan Burgueño M. T-tube or no T-tube in cadaveric orthotopic liver transplantation: the eternal dilemma: results of a prospective and randomized clinical trial. *Ann Surg* 2013; **258**: 21-29 [PMID: 23426348 DOI: 10.1097/SLA.0b013e318286e0a0]
20 **Yamaoka Y**, Washida M, Honda K, Tanaka K, Mori K, Shimahara Y, Okamoto S, Ueda M, Hayashi M, Tanaka A. Liver transplantation using a right lobe graft from a living related donor. *Transplantation* 1994; **57**: 1127-1130 [PMID: 8165712 DOI: 10.1097/00007890-199404000-00024]
21 **Simoes P**, Kesar V, Ahmad J. Spectrum of biliary complications following live donor liver transplantation. *World J Hepatol* 2015; **7**: 1856-1865 [PMID: 26207167 DOI: 10.4254/wjh.v7.i14.1856]
22 **Maluf DG**, Stravitz RT, Cotterell AH, Posner MP, Nakatsuka M, Sterling RK, Luketic VA, Shiffman ML, Ham JM, Marcos A, Behnke MK, Fisher RA. Adult living donor versus deceased donor liver transplantation: a 6-year single center experience. *Am J Transplant* 2005; **5**: 149-156 [PMID: 15636624 DOI: 10.1111/j.1600-6143.2004.00654.x]
23 **Akamatsu N**, Sugawara Y, Hashimoto D. Biliary reconstruction, its complications and management of biliary complications after adult liver transplantation: a systematic review of the incidence, risk factors and outcome. *Transpl Int* 2011; **24**: 379-392 [PMID: 21143651 DOI: 10.1111/j.1432-2277.2010.01202.x]
24 **Freise CE**, Gillespie BW, Koffron AJ, Lok AS, Pruett TL, Emond JC, Fair JH, Fisher RA, Olthoff KM, Trotter JF, Ghobrial RM, Everhart JE; A2ALL Study Group. Recipient morbidity after living and deceased donor liver transplantation: findings from the A2ALL Retrospective Cohort Study. *Am J Transplant* 2008; **8**: 2569-2579 [PMID: 18976306 DOI: 10.1111/j.1600-6143.2008.02440.x]
25 **Wadhawan M**, Kumar A, Gupta S, Goyal N, Shandil R, Taneja S, Sibal A. Post-transplant biliary complications: an analysis from a predominantly living donor liver transplant center. *J Gastroenterol Hepatol* 2013; **28**: 1056-1060 [PMID: 23432435 DOI: 10.1111/jgh.12169]
26 **Woo HY**, Lee IS, Chang JH, Youn SB, Bae SH, Choi JY, Chun HJ, You YK, Kim DG, Yoon SK. Outcome of donor biliary complications following living donor liver transplantation. *Korean J Intern Med* 2018; **33**: 705-715 [PMID: 29529841 DOI: 10.3904/kjim.2017.264]
27 **Gruttadauria S**, Marsh JW, Vizzini GB, di Francesco F, Luca A, Volpes R, Marcos A, Gridelli B. Analysis of surgical and perioperative complications in seventy-five right hepatectomies for living donor liver transplantation. *World J Gastroenterol* 2008; **14**: 3159-3164 [PMID: 18506919 DOI: 10.3748/wjg.14.3159]
28 **Verdonk RC**, Buis CI, Porte RJ, van der Jagt EJ, Limburg AJ, van den Berg AP, Slooff MJ, Peeters PM, de Jong KP, Kleibeuker JH, Haagsma EB. Anastomotic biliary strictures after liver transplantation: causes and consequences. *Liver Transpl* 2006; **12**: 726-735 [PMID: 16628689 DOI: 10.1002/lt.20714]
29 **Albert JG**, Filmann N, Elsner J, Moench C, Trojan J, Bojunga J, Sarrazin C, Friedrich-Rust M, Herrmann E, Bechstein WO, Zeuzem S, Hofmann WP. Long-term follow-up of endoscopic therapy in stenosis of the bilio-biliary anastomosis associated with orthotopic liver transplantation. *Liver Transpl* 2013 [PMID: 23526624 DOI: 10.1002/lt.22643]
30 **Sharma S**, Gurakar A, Jabbour N. Biliary strictures following liver transplantation: past, present and preventive strategies. *Liver Transpl* 2008; **14**: 759-769 [PMID: 18508368 DOI: 10.1002/lt.21509]
31 **Verdonk RC**, Buis CI, Porte RJ, Haagsma EB. Biliary complications after liver transplantation: a review. *Scand J Gastroenterol Suppl* 2006; 89-101 [PMID: 16782628 DOI: 10.1080/00365520600664375]
32 **Pasha SF**, Harrison ME, Das A, Nguyen CC, Vargas HE, Balan V, Byrne TJ, Douglas DD, Mulligan DC. Endoscopic treatment of anastomotic biliary strictures after deceased donor liver transplantation: outcomes after maximal stent therapy. *Gastrointest Endosc* 2007; **66**: 44-51 [PMID: 17591473 DOI: 10.1016/j.gie.2007.02.017]
33 **Graziadei IW**, Schwaighofer H, Koch R, Nachbaur K, Koenigsrainer A, Margreiter R, Vogel W. Long-term outcome of endoscopic treatment of biliary strictures after liver transplantation. *Liver Transpl* 2006; **12**: 718-725 [PMID: 16482553 DOI: 10.1002/lt.20644]
34 **Lee DW**, Jo HH, Abdullah J, Kahaleh M. Endoscopic Management of Anastomotic Strictures after Liver Transplantation. *Clin Endosc* 2016; **49**: 457-461 [PMID: 27744664 DOI: 10.5946/ce.2016.130]
35 **Zoepf T**, Maldonado-Lopez EJ, Hilgard P, Malago M, Broelsch CE, Treichel U, Gerken G. Balloon

dilatation vs. balloon dilatation plus bile duct endoprostheses for treatment of anastomotic biliary strictures after liver transplantation. *Liver Transpl* 2006; **12**: 88-94 [PMID: 16382450 DOI: 10.1002/lt.20548]

36 **Morelli J**, Mulcahy HE, Willner IR, Cunningham JT, Draganov P. Long-term outcomes for patients with post-liver transplant anastomotic biliary strictures treated by endoscopic stent placement. *Gastrointest Endosc* 2003; **58**: 374-379 [PMID: 14528211 DOI: 10.1067/S0016-5107(03)00011-7]

37 **Elmi F**, Silverman WB. Outcome of ERCP in the management of duct-to-duct anastomotic strictures in orthotopic liver transplant. *Dig Dis Sci* 2007; **52**: 2346-2350 [PMID: 17429736 DOI: 10.1007/s10620-006-9142-0]

38 **Kim TH**, Lee SK, Han JH, Park DH, Lee SS, Seo DW, Kim MH, Song GW, Ha TY, Kim KH, Hwang S, Lee SG. The role of endoscopic retrograde cholangiography for biliary stricture after adult living donor liver transplantation: technical aspect and outcome. *Scand J Gastroenterol* 2011; **46**: 188-196 [PMID: 20955089 DOI: 10.3109/00365521.2010.522722]

39 **Tsujino T**, Isayama H, Sugawara Y, Sasaki T, Kogure H, Nakai Y, Yamamoto N, Sasahira N, Yamashiki N, Tada M, Yoshida H, Kokudo N, Kawabe T, Makuuchi M, Omata M. Endoscopic management of biliary complications after adult living donor liver transplantation. *Am J Gastroenterol* 2006; **101**: 2230-2236 [PMID: 16952286 DOI: 10.1111/j.1572-0241.2006.00797.x]

40 **Rerknimitr R**, Sherman S, Fogel EL, Kalayci C, Lumeng L, Chalasani N, Kwo P, Lehman GA. Biliary tract complications after orthotopic liver transplantation with choledochocholedochostomy anastomosis: endoscopic findings and results of therapy. *Gastrointest Endosc* 2002; **55**: 224-231 [PMID: 11818927 DOI: 10.1067/mge.2002.120813]

41 **Alazmi WM**, Fogel EL, Watkins JL, McHenry L, Tector JA, Fridell J, Mosler P, Sherman S, Lehman GA. Recurrence rate of anastomotic biliary strictures in patients who have had previous successful endoscopic therapy for anastomotic narrowing after orthotopic liver transplantation. *Endoscopy* 2006; **38**: 571-574 [PMID: 16802268 DOI: 10.1055/s-2006-925027]

42 **Morelli G**, Fazel A, Judah J, Pan JJ, Forsmark C, Draganov P. Rapid-sequence endoscopic management of posttransplant anastomotic biliary strictures. *Gastrointest Endosc* 2008; **67**: 879-885 [PMID: 18178206 DOI: 10.1016/j.gie.2007.08.046]

43 **Tabibian JH**, Asham EH, Han S, Saab S, Tong MJ, Goldstein L, Busuttil RW, Durazo FA. Endoscopic treatment of postorthotopic liver transplantation anastomotic biliary strictures with maximal stent therapy (with video). *Gastrointest Endosc* 2010; **71**: 505-512 [PMID: 20189508 DOI: 10.1016/j.gie.2009.10.023]

44 **Traina M**, Tarantino I, Barresi L, Volpes R, Gruttadauria S, Petridis I, Gridelli B. Efficacy and safety of fully covered self-expandable metallic stents in biliary complications after liver transplantation: a preliminary study. *Liver Transpl* 2009; **15**: 1493-1498 [PMID: 19877248 DOI: 10.1002/lt.21886]

45 **Poley JW**, Cahen DL, Metselaar HJ, van Buuren HR, Kazemier G, van Eijck CH, Haringsma J, Kuipers EJ, Bruno MJ. A prospective group sequential study evaluating a new type of fully covered self-expandable metal stent for the treatment of benign biliary strictures (with video). *Gastrointest Endosc* 2012; **75**: 783-789 [PMID: 22325806 DOI: 10.1016/j.gie.2011.10.022]

46 **Tarantino I**, Traina M, Mocciaro F, Barresi L, Curcio G, Di Pisa M, Granata A, Volpes R, Gridelli B. Fully covered metallic stents in biliary stenosis after orthotopic liver transplantation. *Endoscopy* 2012; **44**: 246-250 [PMID: 22354824 DOI: 10.1055/s-0031-1291465]

47 **Sauer P**, Chahoud F, Gotthardt D, Stremmel W, Weiss KH, Büchler M, Schemmer P, Weitz J, Schaible A. Temporary placement of fully covered self-expandable metal stents in biliary complications after liver transplantation. *Endoscopy* 2012; **44**: 536-538 [PMID: 22370701 DOI: 10.1055/s-0031-1291714]

48 **Kahaleh M**, Brijbassie A, Sethi A, Degaetani M, Poneros JM, Loren DE, Kowalski TE, Sejpal DV, Patel S, Rosenkranz L, McNamara KN, Raijman I, Talreja JP, Gaidhane M, Sauer BG, Stevens PD. Multicenter trial evaluating the use of covered self-expanding metal stents in benign biliary strictures: time to revisit our therapeutic options? *J Clin Gastroenterol* 2013; **47**: 695-699 [PMID: 23442836 DOI: 10.1097/MCG.0b013e31827fd311]

49 **Martins FP**, De Paulo GA, Contini MLC, Ferrari AP. Metal versus plastic stents for anastomotic biliary strictures after liver transplantation: a randomized controlled trial. *Gastrointest Endosc* 2018; **87**: 131.e1-131.e13 [PMID: 28455159 DOI: 10.1016/j.gie.2017.04.013]

50 **Coté GA**, Slivka A, Tarnasky P, Mullady DK, Elmunzer BJ, Elta G, Fogel E, Lehman G, McHenry L, Romagnuolo J, Menon S, Siddiqui UD, Watkins J, Lynch S, Denski C, Xu H, Sherman S. Effect of Covered Metallic Stents Compared With Plastic Stents on Benign Biliary Stricture Resolution: A Randomized Clinical Trial. *JAMA* 2016; **315**: 1250-1257 [PMID: 27002446 DOI: 10.1001/jama.2016.2619]

51 **Park DH**, Lee SS, Lee TH, Ryu CH, Kim HJ, Seo DW, Park SH, Lee SK, Kim MH, Kim SJ. Anchoring flap versus flared end, fully covered self-expandable metal stents to prevent migration in patients with benign biliary strictures: a multicenter, prospective, comparative pilot study (with videos). *Gastrointest Endosc* 2011; **73**: 64-70 [PMID: 21184871 DOI: 10.1016/j.gie.2010.09.039]

52 **Kao D**, Zepeda-Gomez S, Tandon P, Bain VG. Managing the post-liver transplantation anastomotic biliary stricture: multiple plastic versus metal stents: a systematic review. *Gastrointest Endosc* 2013; **77**: 679-691 [PMID: 23473000 DOI: 10.1016/j.gie.2013.01.015]

53 **Visconti TAC**, Bernardo WM, Moura DTH, Moura ETH, Gonçalves CVT, Farias GF, Guedes HG, Ribeiro IB, Franzini TP, Luz GO, Dos Santos MEDL, de Moura EGH. Metallic vs plastic stents to treat biliary stricture after liver transplantation: a systematic review and meta-analysis based on randomized trials. *Endosc Int Open* 2018; **6**: E914-E923 [PMID: 30258982 DOI: 10.1055/a-0626-7048]

54 **Guichelaar MM**, Benson JT, Malinchoc M, Krom RA, Wiesner RH, Charlton MR. Risk factors for and clinical course of non-anastomotic biliary strictures after liver transplantation. *Am J Transplant* 2003; **3**: 885-890 [PMID: 12814481 DOI: 10.1034/j.1600-6143.2003.00165.x]

55 **Koneru B**, Sterling MJ, Bahramipour PF. Bile duct strictures after liver transplantation: a changing landscape of the Achilles' heel. *Liver Transpl* 2006; **12**: 702-704 [PMID: 16628684 DOI: 10.1002/lt.20753]

56 **Roos FJM**, Poley JW, Polak WG, Metselaar HJ. Biliary complications after liver transplantation; recent developments in etiology, diagnosis and endoscopic treatment. *Best Pract Res Clin Gastroenterol* 2017; **31**: 227-235 [PMID: 28624111 DOI: 10.1016/j.bpg.2017.04.002]

57 **Verdonk RC**, Buis CI, van der Jagt EJ, Gouw AS, Limburg AJ, Slooff MJ, Kleibeuker JH, Porte RJ, Haagsma EB. Nonanastomotic biliary strictures after liver transplantation, part 2: Management, outcome, and risk factors for disease progression. *Liver Transpl* 2007; **13**: 725-732 [PMID: 17457935 DOI: 10.1002/lt.21165]

58 **Rizk RS**, McVicar JP, Emond MJ, Rohrmann CA, Kowdley KV, Perkins J, Carithers RL, Kimmey MB.

Endoscopic management of biliary strictures in liver transplant recipients: effect on patient and graft survival. *Gastrointest Endosc* 1998; **47**: 128-135 [PMID: 9512276 DOI: 10.1016/S0016-5107(98)70344-X]

59 **Thuluvath PJ**, Atassi T, Lee J. An endoscopic approach to biliary complications following orthotopic liver transplantation. *Liver Int* 2003; **23**: 156-162 [PMID: 12955878 DOI: 10.1034/j.1600-0676.2003.00823.x]

60 **Zoepf T**, Maldonado de Dechêne EJ, Dechêne A, Malágo M, Beckebaum S, Paul A, Gerken G, Hilgard P. Optimized endoscopic treatment of ischemic-type biliary lesions after liver transplantation. *Gastrointest Endosc* 2012; **76**: 556-563 [PMID: 22898414 DOI: 10.1016/j.gie.2012.04.474]

61 **Arain MA**, Attam R, Freeman ML. Advances in endoscopic management of biliary tract complications after liver transplantation. *Liver Transpl* 2013; **19**: 482-498 [PMID: 23417867 DOI: 10.1002/lt.23624]

62 **Yazumi S**, Yoshimoto T, Hisatsune H, Hasegawa K, Kida M, Tada S, Uenoyama Y, Yamauchi J, Shio S, Kasahara M, Ogawa K, Egawa H, Tanaka K, Chiba T. Endoscopic treatment of biliary complications after right-lobe living-donor liver transplantation with duct-to-duct biliary anastomosis. *J Hepatobiliary Pancreat Surg* 2006; **13**: 502-510 [PMID: 17139423 DOI: 10.1007/s00534-005-1084-y]

63 **Shah RJ**, Smolkin M, Yen R, Ross A, Kozarek RA, Howell DA, Bakis G, Jonnalagadda SS, Al-Lehibi AA, Hardy A, Morgan DR, Sethi A, Stevens PD, Akerman PA, Thakkar SJ, Brauer BC. A multicenter, U.S. experience of single-balloon, double-balloon, and rotational overtube-assisted enteroscopy ERCP in patients with surgically altered pancreaticobiliary anatomy (with video). *Gastrointest Endosc* 2013; **77**: 593-600 [PMID: 23290720 DOI: 10.1016/j.gie.2012.10.015]

64 **Kim JH**, Lee SK, Kim MH, Song MH, Park DH, Kim SY, Lee SS, Seo DW, Bae JS, Kim HJ, Han J, Sung KB, Min YI. Percutaneous transhepatic cholangioscopic treatment of patients with benign bilio-enteric anastomotic strictures. *Gastrointest Endosc* 2003; **58**: 733-738 [PMID: 14595311 DOI: 10.1016/S0016-5107(03)02144-8]

65 **Uchida D**, Kato H, Saragai Y, Takada S, Muro S, Tomoda T, Matsumoto K, Horiguchi S, Okada H. Usefulness of a Cannula with a Flexible Tip (Swing Tip) for Managing Severe Biliary Stricture. *Can J Gastroenterol Hepatol* 2018; **2018**: 7125714 [PMID: 30643761 DOI: 10.1155/2018/7125714]

66 **Laasch HU**, Tringali A, Wilbraham L, Marriott A, England RE, Mutignani M, Perri V, Costamagna G, Martin DF. Comparison of standard and steerable catheters for bile duct cannulation in ERCP. *Endoscopy* 2003; **35**: 669-674 [PMID: 12929062 DOI: 10.1055/s-2003-41515]

67 **Balderramo D**, Sendino O, Miquel R, de Miguel CR, Bordas JM, Martinez-Palli G, Leoz ML, Rimola A, Navasa M, Llach J, Cardenas A. Prospective evaluation of single-operator peroral cholangioscopy in liver transplant recipients requiring an evaluation of the biliary tract. *Liver Transpl* 2013; **19**: 199-206 [PMID: 23404861 DOI: 10.1002/lt.23585]

68 **Bukhari MA**, Haito-Chavez Y, Ngamruengphong S, Brewer Gutierrez O, Chen YI, Khashab MA. Rendezvous Biliary Recanalization of Complete Biliary Obstruction With Direct Peroral and Percutaneous Transhepatic Cholangioscopy. *Gastroenterology* 2018; **154**: 23-25 [PMID: 29102615 DOI: 10.1053/j.gastro.2017.09.050]

69 **Gürakar A**, Wright H, Camci C, Jaboour N. The application of SpyScope® technology in evaluation of pre and post liver transplant biliary problems. *Turk J Gastroenterol* 2010; **21**: 428-432 [PMID: 21331998 DOI: 10.4318/tjg.2010.0131]

70 **Jang SI**, Kim JH, Won JY, Lee KH, Kim HW, You JW, Itoi T, Lee D. Magnetic compression anastomosis is useful in biliary anastomotic strictures after living donor liver transplantation. *Gastrointest Endosc* 2011; **74**: 1040-1048 [PMID: 21855872 DOI: 10.1016/j.gie.2011.06.026]

71 **Parlak E**, Koksal AS, Kucukay F, Eminler AT, Toka B, Uslan MI. A novel technique for the endoscopic treatment of complete biliary anastomosis obstructions after liver transplantation: through-the-scope magnetic compression anastomosis. *Gastrointest Endosc* 2017; **85**: 841-847 [PMID: 27566054 DOI: 10.1016/j.gie.2016.07.068]

World Journal of Meta-Analysis

Submit a Manuscript: https://www.f6publishing.com

World J Meta-Anal 2019 April 30; 7(4): 129-141

DOI: 10.13105/wjma.v7.i4.129

ISSN 2308-3840 (online)

REVIEW

Anti-inflammatory properties of antidiabetic agents

Eleni Xourgia, Eleni-Margarita Tzouganatou, Athanasia Papazafeiropoulou, Andreas Melidonis

ORCID number: Eleni Xourgia (0000-0001-5766-3209); Eleni Margarita Tzouganatou (0000-0002-3074-652X); Athanasia Papazafeiropoulou (0000-0002-7596-4942); Andreas Melidonis (0000-0003-0505-5708).

Author contributions: All authors equally contributed to this paper with conception and design of the study, literature review and analysis, drafting and critical revision and editing, and final approval of the final version.

Conflict-of-interest statement: No potential conflicts of interest. No financial support.

Manuscript source: Invited manuscript

Received: March 19, 2019
Peer-review started: March 19, 2019
First decision: April 13, 2019
Revised: April 20, 2019
Accepted: April 23, 2019
Article in press: April 23, 2019
Published online: April 30, 2019

P-Reviewer: Su CC

Eleni Xourgia, Eleni-Margarita Tzouganatou, Athanasia Papazafeiropoulou, Andreas Melidonis, 1st Department of Internal Medicine and Diabetes Center, Tzaneio General Hospital of Piraeus, Athens 18536, Greece

Corresponding author: Athanasia Papazafeiropoulou, MD, MSc, PhD, Attending Doctor, Research Scientist, 1st Department of Internal Medicine and Diabetes Center, Tzaneio General Hospital of Piraeus, 1 Zanni and Afentouli Street, Athens 18536, Greece.
pathan@ath.forthnet.gr
Telephone: +30-697-996483

Abstract

The reciprocal relationship between hyperglycemia and inflammation in the setting of diabetes mellitus has been the subject of extensive research. Insulin resistance, the hallmark of diabetic metabolic dysregulation, has been linked to the inflammatory cascade occurring mainly in adipose tissue. The main pathophysiologic processes facilitating the aforementioned interplay, is a phenotype switch of macrophages to the M1 class following gluco- and lipotoxicity and gut microbial remodeling. Given the correlation between inflammation and metabolic abnormalities, the elucidation of the exact mechanisms linking the two along with exploring the possible role of modulation of one in order to alter the other, could open up the possibility of novel therapeutic approaches for diabetes mellitus and its complications. Therefore, the aim of this review is to summarize the growing body of evidence concerning the molecular basis and results of pro-inflammatory processes in diabetic subjects along with the effect of current antidiabetic treatment options on tissue inflammation.

Key words: Inflammation; Adipose tissue; Anti-inflammatory; Type 2 diabetes mellitus; Antidiabetic drugs

Core tip: In this review, we aim to create a concise overview of the interplay between hyperglycemia and inflammation, while describing the immunomodulatory potential of each antidiabetic drug and its effects exerted in the inflammatory cascade in subjects with type 2 diabetes.

Citation: Xourgia E, Tzouganatou EM, Papazafeiropoulou A, Melidonis A. Anti-inflammatory properties of antidiabetic agents. *World J Meta-Anal* 2019; 7(4): 129-141
URL: https://www.wjgnet.com/2308-3840/full/v7/i4/129.htm

S-Editor: Dou Y
L-Editor: A
E-Editor: Wu YXJ

DOI: https://dx.doi.org/10.13105/wjma.v7.i4.129

INTRODUCTION

Type 2 diabetes mellitus (T2DM) is currently considered a worldwide epidemic. It is regarded as one of the most important chronic conditions because of the high disease prevalence and its debilitating chronic complications, responsible for elevated indexes of morbidity and mortality. According to World Health Organization, the number of people affected by diabetes in 2014 has approximately quadrupled since 1980, worldwide. In detail, the age-standardized prevalence of diabetes in adults has nearly doubled since 1980, reaching 8.5%[1].

While the development of diabetes and its complications is a multifactorial process, the interplay between innate and acquired immunity in the pathogenesis of metabolic diseases has been attracting increasing research interest, mainly in the context of seeking novel treatment approaches and, ultimately, a causative therapy. Inflammation has been speculated to play an important role, central to the pathophysiologic dysregulation of the pancreatic islet in type 1 diabetics. Furthermore, growing evidence suggests that inflammation also affects the pathogenetic process of T2DM, modulating processes like obesity-related insulin resistance, impaired insulin secretion, and diabetes-related vascular dysfunction[2]. Furthermore, it is now understood that inflammation plays a major role in the pathogenesis of cardiovascular disease with ongoing research in the field of prevention of coronary artery disease by use of anti-inflammatory drugs[3-6]. Therefore, the purpose of this review is to discuss the potential anti-inflammatory effects of currently available antidiabetic medications in relation to the disruption of metabolic homeostasis.

TYPE 2 DIABETES AND INFLAMMATION

Adipocytes are the main site of interplay between inflammation and insulin resistance in T2DM. The immunomodulatory role of adipose tissue has now been well-described, as adipocytes not only produce various adipocytokines that can interfere with insulin production and sensitivity but interact in close communication with the immune cells surrounding them[7]. Adipose tissue macrophages affect tissue remodeling and metabolic balance through presenting with an M2 phenotype in lean fat[8]. The activity and expression patterns of M2 macrophages depend heavily on cytokine signaling cascades, namely those including interleukin (IL)-4 and IL-13. Macrophages shifted to the M2 phenotype produce arginase and IL-10[9]. In obesity, macrophages proliferate and shift to the M1 phenotype, activated by pro-inflammatory cytokines. M1 macrophages express CD11c and produce tumor necrosis factor-α (TNF-α), IL-6, and reactive oxygen species (ROS)[9]. The accumulation of M1 macrophages is incremental in the development of insulin resistance[7]. Adipose tissue inflammation can also be induced by localized decreased oxygen perfusion in tissues rapidly expanding with disproportional to the proliferation vascular adaptation[10].

In diabetes, hyperglycemia and elevated levels of free fatty acids (FFAs) may act as proinflammatory stimulants through the induction of glucose utilization and modulating the process of oxidative phosphorylation[11,12]. Such metabolic dysregulation has been shown to induce a proinflammatory shift in adipose, islet and vascular tissue-related anti-inflammatory cells[7-9]. Glucotoxicity and lipotoxicity fuel processes induce oxidative and endoplasmic reticulum stress, further initiating inflammation by activation of thioredoxin-interacting protein and the NLR family, pyrin domain containing 3 (NLRP3) inflammasome, which increase the release of active IL-1β[11-14]. IL-1β plays an important initiator role in the inflammatory cascade, recruiting macrophages and other cells of the immune response ("auto-stimulation")[14]. The same interplay between metabolic dysregulation and inflammation occur between other tissue and cell types in the pancreas and circulatory system[13,14]. In T2DM, amyloid depositions in pancreatic islets induce inflammation through NLRP3 inflammasome formation and the production of IL-1β[15]. Increasing stress and inflammation, instigated in a positive-feedback manner, trigger cellular pro-apoptotic cascades and β-cell impairment, insulin resistance, and arterial atheromatosis.

Additionally, obesity is associated with alterations in the gut microbiome leading to

functional changes of inherent gut homeostasis, with bacterial wall lipopolysaccharides (endotoxins) further promoting tissue inflammation[16]. Endotoxins, FFAs and cholesterol have a pro-inflammatory capacity through the activation of Toll-like receptor (TLR) pathways and, subsequently, nuclear factor-κB (NF-κB)-mediated cytokine and chemokine signaling including TNF-α, IL-1β, IL-8, and monocytes chemoattractant protein-1 (MCP-1) promoting immune cell attraction in several tissue types[17]. It has recently been reported that in obesity, gut microbiota aberrant growth patterns might affect the innate and acquired immune system responses, thereby promoting insulin resistance[18].

The interplay of metabolism and inflammation could justify the theory that metabolic dysfunction amelioration through lifestyle modification and pharmaceutical intervention could attenuate inflammation. Current antidiabetic treatments induce normoglycemia by acting on several different pathways. Many of these treatments also exert anti-inflammatory effects that might be mediated *via* their hypoglycemic and hypolipidemic capacities or by directly modulating the immune system. Below, we gather and discuss the current data on the anti-inflammatory properties of antidiabetic medications.

ANTIDIABETIC TREATMENT AND INFLAMMATION

Metformin

Metformin is considered a first-line treatment for T2DM in almost all guidelines and expert recommendations issued worldwide. The molecular mechanisms behind the pharmacologic activity of metformin appear to be rather complex and remain controversial. However, it is universally accepted that metformin phosphorylates and activates AMP-activated protein kinase (AMPK)[19]. In the liver, the AMPK cascade activates fatty acid oxidation with inhibition of cholesterol and triglyceride synthesis[19]. Peripheral effects include the activation of fatty acid oxidation and glucose uptake in skeletal muscle as well as a systemic increase in insulin sensitivity[19].

It has been reported that metformin increased nitric oxide (NO) synthesis via activation of AMPK[20] and decreased ROS production through inhibition of nicotinamide adenine dinucleotide phosphate (NADPH) oxidase and the respiratory mitochondrial chain[21]. Another study showed that metformin inhibited NFκB activation in the vessel wall and decreased serum C-reactive protein (CRP) level in high-fat-fed atherogenic rabbits[22]. Furthermore, Isoda *et al*[23] have reported that metformin inhibited NFκB activation through blockade of the phosphoinositide 3-kinase (PI3K)-Akt pathway in human vascular wall cells. Also, in lipopolysaccharide-activated macrophages, metformin inhibited production of the IL-1β precursor molecule and other pro-inflammatory cytokines, while it boosted induction of the anti-inflammatory cytokine, IL-10[24]. Another possible mechanism of the anti-inflammatory action of metformin is inhibition of advanced glycation end products (AGEs) formation. Metformin inhibits the formation of AGEs which promote inflammation and ROS (glycoxidation)[25].

Apart from the studies where the molecular effects of metformin were examined in vitro, there are also clinical studies. In the Diabetes Prevention Program (DPP) study, metformin slightly reduced the levels of CRP compared with placebo[26]. Similar results were provided by the Bypass Angioplasty Revascularization Investigation 2 Diabetes (BARI 2D) trial, in which metformin and/or a thiazolidinedione (TZD) led to lower plasma insulin, lower plasminogen activator inhibitor type 1 (PAI-1) antigen, lower CRP and lower fibrinogen levels compared with a sulphonylurea (SU) or meglitinide in a population of diabetic patients with coronary artery disease[27]. Krysiak *et al*[28] have reported that metformin reduced monocyte release of TNF-α, IL-1β, IL-6, MCP-1 and IL-8, as well as plasma CRP level in patients with impaired fasting glucose. On the other hand, in the LANCET Trial: A Trial of Long-acting Insulin Injection to Reduce C-reactive Protein in Patients with Type 2 Diabetes, metformin did not alter inflammatory biomarkers in patients with a short T2DM duration, in spite of glucose regulation[29]. In addition, it has been reported that metformin treatment did not change CRP or 8-iso-prostaglandin F2α(8-iso-PGF2α) level in subjects with normal glucose tolerance[30].

Overall, the various results are conflicting and even though metformin seems to have several anti-inflammatory pharmacologic properties *in vitro*, those are not always observed *in vivo*. Therefore, it remains uncertain whether the anti-inflammatory effect of metformin is due to its direct tissue-action or, induced indirectly, through the improvement of insulin sensitivity and hyperglycemia.

Sulphonylureas

Apart from the potent hypoglycemic effect of SUs, many studies have shown that they may have additional anti-inflammatory potential. Glyburide has been shown to inhibit the NLRP3 inflammasome and subsequent IL-1β activation in macrophages[31] while gliclazide, as compared with glibenclamide, decreased the serum levels of soluble intercellular adhesion molecule-1 (sICAM-1), sE-selectin and high sensitive CRP (hsCRP), in a population of diabetic patients[32]. Mu-Huo *et al*[33] showed that in an animal model of sepsis, glibenclamide pretreatment exerted protective properties on the lung parenchyma by inhibiting both the inflammatory responses and oxidative stress. In addition, glibenclamide reduces pro-inflammatory cytokine production by neutrophils in patients with diabetes in response to bacterial infection[34]. Mavridis *et al*[35] reported that T2DM patients treated with SU had significantly lower cytokine levels than the insulin-treated.

By contrast, in various head-to-head clinical trials, no significant changes in CRP and other inflammatory markers were observed with SU therapy, whereas significant reductions were found with TZD, pioglitazone and the glucagon-like peptide 1 (GLP-1) receptor agonist (GLP-1 RA) exenatide[36-38]. Also, in a recent 52-wk head-to-head study between metformin, gliclazide, and pioglitazone on pro-inflammatory biomarkers, coagulation, and endothelial function, no improvements were seen in the circulating levels of inflammatory markers selected (IL-1, IL-6, and TNF-α) with SU therapy when compared to the other treatment types, while glycemic control was comparamble among all treatment groups[39].

It is notable that while SU appears to have some effect in the expression of various inflammatory cytokines, its anti-inflammatory effect is less potent when compared to metformin or pioglitazone.

Alpha-glucosidase inhibitors

Alpha-glucosidase (α-glucosidase) inhibitors are a unique class of antidiabetic medications which, by competitive and reversible inhibition of intestinal alpha-glucosidases, delay carbohydrate digestion and thereby extend the total time of glucose absorption[40]. Given the research data suggesting that postprandial glucose load results in a biomarker profile consistent with systemic low-grade inflammation and endothelial dysfunction, with increased levels of hsCRP, IL-6, TNF-α, sICAM-1, soluble vascular cell adhesion molecule 1 (sVCAM-1), E-selectin, and metalloproteinases (MMPs) 2 and 9 in patients with T2DM compared to healthy patients[41], α-glucosidase inhibitors are expected to have anti-inflammatory potential, justified by their mechanism of action.

Osonoi *et al*[42] suggested that miglitol depresses the production and release of inflammatory cytokines/cytokine-like factors in peripheral leukocytes by flattening glucose level fluctuation curves in Japanese patients with T2DM, incrementally more than other α-glucosidase inhibitors. Emoto *et al*[43] studied patients with T2DM and coronary artery disease on a 3-mo regimen of miglitol and demonstrated an improvement in both the insulin resistance index and CRP. Derosa *et al*[44] evaluated effects of acarbose in patients with T2DM and found it to be effective in reducing the post-oral-fat-load peaks of various parameters including inflammatory markers such as hsCRP, after 7 mo of therapy.

In a randomized double-blind, placebo-controlled crossover study, acarbose-induced normoglycemia did not affect adiponectin, insulin sensitivity, or pro-inflammatory circulating biomarkers (MCP-1, IL-6, and IL-1β)[45]. Similarly, a comparison of pioglitazone *vs* voglibose by Fujitaka *et al*[46] showed an improvement in serum adiponectin, hsCRP levels and insulin resistance assessment through the homeostatic model only in the pioglitazone group.

While, α-glucosidase inhibitors may have some indirect anti-inflammatory properties mainly *via* lowering the post prandial glucose levels, they do not seem to have further immunomodulatory potential.

Thiazolidinedione

Rosiglitazone and pioglitazone, also known as TZDs, are selective agonists of nuclear transcription factor peroxisome proliferator-activated receptor-γ (PPAR-γ).

There is plenty of scientific evidence that TZDs act not only as hypoglycemic medications but as anti-inflammatory agents as well. Specifically, PPAR-γ is mainly expressed in adipocytes and appears to attenuate pro-inflammatory biomarkers in visceral adipose tissue (VAT) deposits, steatotic liver, atherosclerotic plaques and plasma. Furthermore, in vitro results demonstrate that the anti-inflammatory activity of TZDs is partially resulting from their modulatory properties in glucocorticoid nuclear translocation activation, in a PPAR-γ-independent manner[47].

TZDs have been shown to decrease inflammatory markers in visceral adipose tissue, liver, atherosclerotic plaques, and circulating plasma[48]. Pioglitazone treatment

decreased invasion of adipose tissue by proinflammatory macrophages and increased hepatic and peripheral insulin sensitivity in obese subjects[49]. Patients with insulin resistance had a decreased total adipose macrophage population, with a decrease in M1 macrophages and an increase in M2 macrophages with pioglitazone treatment[50]. Also, treatment with TZDs attenuated inflammation in nonalcoholic steatohepatitis and in atherosclerotic lesions[51,52].

The notion that PPAR-γ activation by TZDs can modulate monocyte and macrophage activity and have an impact on the inflammatory process is supported by *in vitro* research data. Further evidence of this is provided by studies *in vivo*, both in animal models and in humans. Haffner *et al*[53] in their study of approximately 300 T2DM patients on a 26-wk rosiglitazone treatment regimen, reported a reduction of at least 20% in plasma CRP levels and MMP-9 and approximately 12% in total white blood cell count. A reduction in MMP-9 was also observed by Marx *et al*[54] along with a concomitant decrease in plasma sCD40 levels (another emerging marker of inflammation and cardiovascular risk) in T2DM patients with established cardiovascular disease, following rosiglitazone treatment.

In addition, a recent meta-analysis of 27 randomized controlled trials, found that circulating levels of hsCRP, monocyte chemoattractant protein-1, von Willebrand factor, fibrinogen, and E-selectin were significantly decreased after TZD therapy. However, IL-6, MMP-9, sCD40 ligand, PAI-1 and ICAM-1 were not significantly affected[55]. In the PERISCOPE trial, treatment of diabetic patients with known coronary artery disease with pioglitazone resulted in a significantly lower rate of progression of coronary atherosclerosis and a decrease in hsCRP levels, compared with glimepiride[56].

Nonetheless, one could argue that all the aforementioned anti-inflammatory actions of TZDs can be attributed to their effect on glucose lowering. Satoh *et al*[57], following pioglitazone treatment in T2DM, observed a decrease in CRP levels of the same magnitude both in patients who responded to therapy (defined as an improvement in glucose control) and in non-responders. Also, Nitta *et al*[58] showed that, compared with glimepiride, pioglitazone reduced coronary arterial inflammation in patients with T2DM or impaired glucose tolerance, even though both agents decreased glucose-control related parameters such as HbA1c and fasting plasma glucose.

TZDs appear to be potent modulators of the inflammatory cascade, independently of their glucose lowering effect. Currently, various studies examine their potential use as immunomodulators outside the setting of diabetes, in normoglycemic subjects with rheumatic and other auto-immune diseases[59,60].

SGLT-2 inhibitors

Sodium–glucose cotransporter (SGLT) 2 inhibitors improve glycemia by inhibiting reabsorption of glucose in the proximal tubule of the kidney, inducing glucosuria and lowering plasma glucose levels, without inducing hypoglycemia.

In T2DM mice, the SGLT-2 inhibitor ipragliflozin was shown to improve hyperglycemia, insulin secretion, hyperlipidemia, and liver levels of oxidative stress biomarkers and reduce markers of inflammation including IL-6, TNF-α, MCP-1, and CRP levels[61]. In another study, short-term luseogliflozin treatment normalized the expression of inflammation-related genes such as F4/80, TNFα, IL-1β, IL-6, ICAM-1, platelet endothelial cell adhesion molecule-1 (PECAM-1), MMP2 and MMP9 in apolipoprotein-E deficient knockout (ApoE KO) mice, while markedly attenuating the progression of atherosclerosis[62]. Another study in mice treated with empagliflozin provided similar results[63]. Furthermore, empagliflozin reduced M1-polarized macrophage accumulation while inducing the anti-inflammatory M2 phenotype of macrophages within adipose tissue and liver, lowering plasma TNFα levels and attenuating obesity-related chronic inflammation in diet-induced obese mice[64]. Also, empagliflozin, alone or in combination with linagliptin, attenuated (nonalcoholic steatohepatitis) NASH development in diabetic mice, through reducing hepatic expression of inflammatory genes (TNF-α, IL-6, and MCP-1)[65]. Dapagliflozin also reduced mRNA levels of various cytokines and attenuated the development of diabetic cardiomyopathy in diabetic mice[66].

Moreover, there is evidence that the important renoprotective effect of SGLT-2 inhibitors is partly due to their anti-inflammatory properties. Vallon *et al*[67] showed that administration of empagliflozin in diabetic mice not only attenuated glomerular hyperfiltration, albuminuria, but also inhibited diabetes-induced renal expression of inflammation markers, such as NF-κB and IL-6. Hatanaka *et al*[68] reported that the administration of dapagliflozin to Akita mice induced an incremental renal macrophage tissue accumulation and attenuated interstitial fibrosis when compared with insulin, despite glycemic control being equally efficient in the two groups, indicating that dapagliflozin exerts renoprotective effects beyond glucose reduction. In addition, studies using cultured proximal tubular cells support the notion that a

decrease in the expression and circulation of pro-inflammatory molecules, such as transforming growth factor-β, MCP-1, osteopontin, and ICAM-1, oxidative stress, NADPH oxidase 4 (Nox4) expression and ROS production underlie the major actions of dapagliflozin[69].

In a small study with 32 male diabetic patients empagliflozin and canagliflozin lowered interferon-λ, TNF-α, IL-6[70]. Sato *et al*[71] studied the effect of dapagliflozin on epicardial adipose tissue and observed that treatment with dapagliflozin resulted in a slight reduction of serum PAI and a greater reduction of serum TNF-a in T2DM patients with coronary artery disease. Okamoto *et al*[72] studied the effects of dapagliflozin on several biomarkers using a population of 27 obese T2DM patients and showed that dapagliflozin treatment led to a significant increase in serum adiponectin and a mild decrease in CRP. A small decrease in CRP with dapagliflozin treatment was also observed in another study[73]. In a post-hoc exploratory analysis of the CANTATA-SU study, changes from baseline in serum leptin, adiponectin, IL-26, TNF-a, CRP, PAI-1, VCAM-1 and MCP-1 were measured in T2DM patients taking metformin, but also receiving either canagliflozin or glimepiride. Canagliflozin shifted the balance of appetite-related hormones, significantly decreasing median serum leptin and increasing median serum adiponectin when compared to glimepiride. Median serum IL-6 was accordingly decreased as well accompanied by a trend towards a slight reduction in hsCRP which, however, contrasted with a modest increase in median serum TNF-a in the canagliflozin group over glimepiride. Despite changes in serum leptin being associated with changes in body weight, there were no notable correlations between changes in adiponectin, IL-6, TNF-a and CRP levels and alterations in body weight and HbA1c[74].

The majority of studies that have been discussed above used animal models. Evidence from clinical trials in human subjects is limited and as a result it is not safe to reach a conclusion regarding the anti-inflammatory effect of this particular category.

DPP-4 inhibitors

Dipeptidyl peptidase (DPP)-4 inhibitors reduce DPP-4 activity in peripheral plasma, preventing the inactivation of the incretin hormone GLP)-1[75]. The ubiquitous tissue localization of DPP-4 (monocytes, natural killer cells, macrophages, epithelial and endothelial cells, lung, spleen, pancreas, kidney, liver and intestinal cells) could play a role in explaining the immunomodulatory role of this enzyme. DPP-4 hormone production in macrophages, especially in visceral adipose tissue depots, binds to adenosine deaminase, facilitating, *via* nonenzymatic function, T-cell proliferation and activation. Also, CD26, which can partially act as an *in vivo* DPP-4 mimic, serves as a signaling molecule in T-cell activation and immunoregulation [76].

The DPP-4 inhibitor alogliptin can attenuate TLR-4 mediated extracellular signal regulated kinase (ERK) activation and ERK-dependent expression of MMPs in histiocytes, and inhibit TLR4-mediated IL-6 and IL-1-beta production[77]. In human macrophages cultured *in vitro*, the DPP-4 inhibitor sitagliptin significantly increased GLP-1 induced the levels of cyclic adenosine monophosphate (cAMP) in the cytosol, resulting in hindering of NF-κB p65 nuclear translocation and suppression of pro-inflammatory mediator production in response to lipopolysaccharide (LPS)[78]. Treatment with linagliptin notably suppressed the activation of the fibrotic process in an experimental model of autoimmune myocarditis mice and was associated with reduced inflammatory cytokine (IL-2, TNF-α, IL-1β, and IL-6) gene expression[79]. Another study indicated that sitagliptin treatment of obese insulin-resistant mice was associated with an improved metabolic phenotype and concurrent reduction of inflammation in pancreatic islets and adipose tissue[80]. In diabetic rats, sitagliptin decreased circulating levels of CRP, MCP-1, TNF-α, IL-6, PAI-1, and suppressed vascular smooth muscle cells proliferation[81].

Surface expression of CD26 on CD4+ and CD8+ T-cells was found to be higher in T2DM patients when compared to healthy controls[82]. In a recent study concerning the production of inflammatory mediators, treatment with sitagliptin for 12 wk reduced mRNA expression of CD26, TNF-α, TLR2, TLR4, proinflammatory kinases c-Jun N-terminal kinase-1 and inhibitory κB kinase, and inhibitor of chemokine receptor CCR-2 in mononuclear cells, as well as of plasma CRP, IL-6, and FFAs[83]. Similarly, another study showed that sitagliptin reduced the expression of inflammatory cytokines and improved the unfavorable M1/M2 phenotypes of peripheral blood monocytes in Japanese diabetic patients[84]. Treatment with sitagliptin or vildagliptin lowered plasma IL-6, IL-18, TNF-alpha and nitrotyrosine levels compared with baseline in T2DM patients[85]. Furthermore, in a study of subjects with coronary artery disease and uncontrolled T2DM, sitagliptin significantly improved endothelial function and inflammatory state beyond its hypoglycemic action[86]. In hemodialysis patients with T2DM, linagliptin decreased levels of prostaglandin E2, IL-6, hsCRP, glycated

albumin, and blood glucose which was associated with an increase in active GLP-1[87]. However, on a model of sitagliptin or metformin as add-on therapy to a pioglitazone regimen in patients with poorly controlled T2DM demonstrated that only metformin led to a decrease of body weight and to a faster and superior improvement of insulin resistance and inflammatory parameters, such as adiponectin and TNF-a[88].

In summary, research suggests that all currently available DPP-4 inhibitors have multiple immunomodulatory effects, in a way that is independent of their glucose lowering effect.

GLP-1 receptor agonists

GLP-1 receptor agonists have been shown to activate GLP-1 receptor to increase the intracellular concentration of cAMP in acinar cells of the pancreas, resulting in an increased insulin secretion and decreased glucagon secretion.

In patients with T2DM, treatment with GLP-1 analogs appears to modulate the pro-inflammatory activity of the innate immune system, leading to reduced pro-inflammatory activation of macrophages and consequently the expression and secretion of proinflammatory cytokines, such as TNF-α, IL-1β, and IL-6 and increased adiponectin. This effect is not dependent on the glycemic or body weight effects of GLP-1[89]. With regard to the effects of GLP-1 analogs on CRP, a small placebo-controlled study demonstrated a significant reduction in CRP levels with exenatide[90]. Also, in a 12-mo comparative study, exenatide demonstrated a significant decrease in hsCRP compared with SU[37].

Treatment of cultured human islets with exendin-4, a GLP-1 RA, suppressed the expression of inflammatory genes such as NFκB1(p105), NFκB2(p100), RelA (also termed p65), TNF receptor superfamily member 1A, and receptor-interacting serine/threonine kinase 2[91]. In addition, administration of a recombinant adenovirus producing GLP-1 to ob/ob mice reduced the macrophage population and production of TNF-α, MCP-1, and IL-6 in adipose tissue via inhibition of NF-κB activation and phosphorylation of ERK1/2 and c-Jun N-terminal kinases[92]. Also, Arakawa *et al*[93] observed that GLP-1 receptor agonists reduced monocyte/macrophage accumulation in the arterial wall by inhibiting the inflammatory response in macrophages, in C57BL/6 or apolipoprotein E-deficient mice apoE(-/-). In another study, exenatide significantly increased the level of IL-10 and decreased both TNF-α and IL-1β in LPS-treated monocytes/macrophages, via activation of protein kinase A[94].

Exendin-4 also prevented macrophage infiltration, and decreased protein levels of ICAM-1 and type IV collagen, as well as decreasing oxidative stress and NF-κB activation in kidney tissue, in a rat model of type 1 diabetes[95]. Furthermore, Kim *et al*[96], showed that exendin-4 had an anti-inflammatory, neuroprotective effect in mice after a stroke, through inhibition of COX-2 through modulating JNK signaling-mediated stimulation of islet brain 1. Moreover, exendin-4 treatment reduced hepatic expression of the inflammatory markers TNF-α, IL-1β, and IL-6 and macrophage markers, cluster of differentiation 68 (CD68), and F4/80 in the liver of mice fed a western-type diet[97,98].

In addition, exenatide plus metformin resulted in a significant reduction in CRP and TNF-α compared with baseline[99]. In another study, treatment of diabetic patients with exenatide for 1 year significantly reduced increased total adiponectin by 12% and reduced hsCRP by 61% and these changes were statistically independent of the change in total body fat mass and body weight[100]. Moreover, Daousi *et al*[101] showed that GLP-1 continuous infusion in patients with T2DM was associated with a significant reduction in circulating IL-6 at 120 and 180 min post-administration. In a retrospective analysis of 110 obese patients with T2DM treated with liraglutide, the mean concentration of CRP declined after treatment with liraglutide for a mean duration of 7.5 mo[102].

Overall, the results of a number of studies all agree that GLP-1 RAs present many anti-inflammatory properties via multiple molecular pathways. It is also important to underscore that these immunomodulatory effects seem to be independent of their metabolic effects in weight and glucose lowering.

Insulin

Insulin induces an attenuation of inflammatory processes through several mechanisms, including increased endothelial nitric oxide release and decreased expression of proinflammatory cytokines and immune mediators, such as NF-κB, ICAM-1, and MCP-1, as well as several TLRs[103].

In a randomized parallel-group study in patients with T2DM, serum concentrations of hsCRP and IL-6 were markedly reduced in insulin-treated patients compared with metformin, despite the achievement of similar glycemic control[104]. This may suggest that insulin reduces inflammation, irrespectively of its effects on glycemia. In another study, treatment of insulin in patients with poorly controlled T2DM reduced serum

hsCRP levels, without affecting plasma fibrinogen or serum MCP-1 levels[105]. In contrast, in the LANCET trial, treatment with insulin compared with a placebo or metformin did not reduce inflammatory biomarker levels despite improving glucose control[29]. Also, Jansen *et al*[106] observed that patients characterized by a pronounced insulin-associated weight gain had an influx of macrophages into the adipose tissue and higher protein levels of MCP-1, TNF-α and IL-1β after 6 mo of insulin therapy compared with those who had not gained weight.

Overall, the results of the various studies concerning insulin are rather conflicting. It is unclear both whether insulin has notable anti-inflammatory properties and whether or not they correlate with its hypoglycemic effect. The lack of large, randomized, double-blind, controlled trials on the subject, or head-to-head studies with other antidiabetic agents, is a major limitation in drawing safe conclusions.

CONCLUSION

The inflammatory process and its causal relationship with the pathophysiology of diabetes mellitus and its complications remains a rather complex matter due to the numerous intertwining pathways involved in various tissue types, along with the interpersonal multifactorial variation of the inflammatory response. While the antidiabetic agents and their indications in the treatment algorithm are mainly evaluated based on their glucose lowering attributes, their immu-nomodulatory potential, most importantly on M1 macrophages could carry great therapeutic benefit, especially in highly insulin resistant patients. Another point of great interest when discussing the aforementioned attributes of these agents is whether the attenuation of the inflammatory cascade activation is secondary to normoglycemia achievement or independent to glycemic regulation, a differentiation that significantly alters the appropriate setting in which they could be successfully introduced to a particular anti-inflammatory-oriented treatment regimen. Moreover, most of the research data on the subject derives from studies on animal subjects, with large, randomized, double-blind studies lacking at the moment, a fact that does not allow for safe conclusions to be drawn as far as clinical correlation of molecular changes is concerned. In conclusion, there is need for further research quantifying the immunomodulatory capacity of antidiabetic agents, elucidating the mechanisms by which those effects are induced and exploring whether those theoretical alterations in circulatory and tissue cytokine and cell-phenotype patterns can be translated into clinical benefit for diabetes and its complications.

REFERENCES

1 **Wild S**, Roglic G, Green A, Sicree R, King H. Global prevalence of diabetes: estimates for the year 2000 and projections for 2030. *Diabetes Care* 2004; **27**: 1047-1053 [PMID: 15111519 DOI: 10.2337/diacare.27.5.1047]

2 **Pollack RM**, Donath MY, LeRoith D, Leibowitz G. Anti-inflammatory Agents in the Treatment of Diabetes and Its Vascular Complications. *Diabetes Care* 2016; **39** Suppl 2: S244-S252 [PMID: 27440839 DOI: 10.2337/dcS15-3015]

3 **Hansson GK**. Inflammation, atherosclerosis, and coronary artery disease. *N Engl J Med* 2005; **352**: 1685-1695 [PMID: 15843671 DOI: 10.1056/NEJMra043430]

4 **Ridker PM**, Hennekens CH, Buring JE, Rifai N. C-reactive protein and other markers of inflammation in the prediction of cardiovascular disease in women. *N Engl J Med* 2000; **342**: 836-843 [PMID: 10733371 DOI: 10.1056/NEJM200003233421202]

5 **Bohula EA**, Giugliano RP, Cannon CP, Zhou J, Murphy SA, White JA, Tershakovec AM, Blazing MA, Braunwald E. Achievement of dual low-density lipoprotein cholesterol and high-sensitivity C-reactive protein targets more frequent with the addition of ezetimibe to simvastatin and associated with better outcomes in IMPROVE-IT. *Circulation* 2015; **132**: 1224-1233 [PMID: 26330412 DOI: 10.1161/CIRCULATIONAHA.115.018381]

6 **Ridker PM**, Libby P, MacFadyen JG, Thuren T, Ballantyne C, Fonseca F, Koenig W, Shimokawa H, Everett BM, Glynn RJ. Modulation of the interleukin-6 signalling pathway and incidence rates of atherosclerotic events and all-cause mortality: analyses from the Canakinumab Anti-Inflammatory Thrombosis Outcomes Study (CANTOS). *Eur Heart J* 2018; **39**: 3499-3507 [PMID: 30165610 DOI: 10.1093/eurheartj/ehy310]

7 **Kohlgruber A**, Lynch L. Adipose tissue inflammation in the pathogenesis of type 2 diabetes. *Curr Diab Rep* 2015; **15**: 92 [PMID: 26374569 DOI: 10.1007/s11892-015-0670-x]

8 **Sun K**, Kusminski CM, Scherer PE. Adipose tissue remodeling and obesity. *J Clin Invest* 2011; **121**: 2094-2101 [PMID: 21633177 DOI: 10.1172/JCI45887]

9 **Lumeng CN**, Bodzin JL, Saltiel AR. Obesity induces a phenotypic switch in adipose tissue macrophage polarization. *J Clin Invest* 2007; **117**: 175-184 [PMID: 17200717 DOI: 10.1172/JCI29881]

10 **Ye J**. Emerging role of adipose tissue hypoxia in obesity and insulin resistance. *Int J Obes (Lond)* 2009; **33**: 54-66 [PMID: 19050672 DOI: 10.1038/ijo.2008.229]

11 **Maedler K**, Sergeev P, Ris F, Oberholzer J, Joller-Jemelka HI, Spinas GA, Kaiser N, Halban PA, Donath MY. Glucose-induced beta cell production of IL-1beta contributes to glucotoxicity in human pancreatic

islets. *J Clin Invest* 2002; **110**: 851-860 [PMID: 12235117 DOI: 10.1172/JCI15318]
12 **Zhou R**, Tardivel A, Thorens B, Choi I, Tschopp J. Thioredoxin-interacting protein links oxidative stress to inflammasome activation. *Nat Immunol* 2010; **11**: 136-140 [PMID: 20023662 DOI: 10.1038/ni.1831]
13 **Vandanmagsar B**, Youm YH, Ravussin A, Galgani JE, Stadler K, Mynatt RL, Ravussin E, Stephens JM, Dixit VD. The NLRP3 inflammasome instigates obesity-induced inflammation and insulin resistance. *Nat Med* 2011; **17**: 179-188 [PMID: 21217695 DOI: 10.1038/nm.2279]
14 **Dinarello CA**. Immunological and inflammatory functions of the interleukin-1 family. *Annu Rev Immunol* 2009; **27**: 519-550 [PMID: 19302047 DOI: 10.1146/annurev.immunol.021908.132612]
15 **Masters SL**, Dunne A, Subramanian SL, Hull RL, Tannahill GM, Sharp FA, Becker C, Franchi L, Yoshihara E, Chen Z, Mullooly N, Mielke LA, Harris J, Coll RC, Mills KH, Mok KH, Newsholme P, Nuñez G, Yodoi J, Kahn SE, Lavelle EC, O'Neill LA. Activation of the NLRP3 inflammasome by islet amyloid polypeptide provides a mechanism for enhanced IL-1β in type 2 diabetes. *Nat Immunol* 2010; **11**: 897-904 [PMID: 20835230 DOI: 10.1038/ni.1935]
16 **Ley RE**, Bäckhed F, Turnbaugh P, Lozupone CA, Knight RD, Gordon JI. Obesity alters gut microbial ecology. *Proc Natl Acad Sci U S A* 2005; **102**: 11070-11075 [PMID: 16033867 DOI: 10.1073/pnas.0504978102]
17 **Nguyen MT**, Favelyukis S, Nguyen AK, Reichart D, Scott PA, Jenn A, Liu-Bryan R, Glass CK, Neels JG, Olefsky JM. A subpopulation of macrophages infiltrates hypertrophic adipose tissue and is activated by free fatty acids via Toll-like receptors 2 and 4 and JNK-dependent pathways. *J Biol Chem* 2007; **282**: 35279-35292 [PMID: 17916553 DOI: 10.1074/jbc.M706762200]
18 **Sell H**, Habich C, Eckel J. Adaptive immunity in obesity and insulin resistance. *Nat Rev Endocrinol* 2012; **8**: 709-716 [PMID: 22847239 DOI: 10.1038/nrendo.2012.114]
19 **Gong L**, Goswami S, Giacomini KM, Altman RB, Klein TE. Metformin pathways: pharmacokinetics and pharmacodynamics. *Pharmacogenet Genomics* 2012; **22**: 820-827 [PMID: 22722338 DOI: 10.1097/FPC.0b013e3283559b22]
20 **Davis BJ**, Xie Z, Viollet B, Zou MH. Activation of the AMP-activated kinase by antidiabetes drug metformin stimulates nitric oxide synthesis in vivo by promoting the association of heat shock protein 90 and endothelial nitric oxide synthase. *Diabetes* 2006; **55**: 496-505 [PMID: 16443786 DOI: 10.2337/diabetes.55.02.06.db05-1064]
21 **Ouslimani N**, Peynet J, Bonnefont-Rousselot D, Thérond P, Legrand A, Beaudeux JL. Metformin decreases intracellular production of reactive oxygen species in aortic endothelial cells. *Metabolism* 2005; **54**: 829-834 [PMID: 15931622 DOI: 10.1016/j.metabol.2005.01.029]
22 **Li SN**, Wang X, Zeng QT, Feng YB, Cheng X, Mao XB, Wang TH, Deng HP. Metformin inhibits nuclear factor kappaB activation and decreases serum high-sensitivity C-reactive protein level in experimental atherogenesis of rabbits. *Heart Vessels* 2009; **24**: 446-453 [PMID: 20108078 DOI: 10.1007/s00380-008-1137-7]
23 **Isoda K**, Young JL, Zirlik A, MacFarlane LA, Tsuboi N, Gerdes N, Schönbeck U, Libby P. Metformin inhibits proinflammatory responses and nuclear factor-kappaB in human vascular wall cells. *Arterioscler Thromb Vasc Biol* 2006; **26**: 611-617 [PMID: 16385087 DOI: 10.1161/01.ATV.0000201938.78044.75]
24 **Kelly B**, Tannahill GM, Murphy MP, O'Neill LA. Metformin Inhibits the Production of Reactive Oxygen Species from NADH:Ubiquinone Oxidoreductase to Limit Induction of Interleukin-1β (IL-1β) and Boosts Interleukin-10 (IL-10) in Lipopolysaccharide (LPS)-activated Macrophages. *J Biol Chem* 2015; **290**: 20348-20359 [PMID: 26152715 DOI: 10.1074/jbc.M115.662114]
25 **Ruggiero-Lopez D**, Lecomte M, Moinet G, Patereau G, Lagarde M, Wiernsperger N. Reaction of metformin with dicarbonyl compounds. Possible implication in the inhibition of advanced glycation end product formation. *Biochem Pharmacol* 1999; **58**: 1765-1773 [PMID: 10571251 DOI: 10.1016/S0006-2952(99)00263-4]
26 **Haffner S**, Temprosa M, Crandall J, Fowler S, Goldberg R, Horton E, Marcovina S, Mather K, Orchard T, Ratner R, Barrett-Connor E; Diabetes Prevention Program Research Group. Intensive lifestyle intervention or metformin on inflammation and coagulation in participants with impaired glucose tolerance. *Diabetes* 2005; **54**: 1566-1572 [PMID: 15855347 DOI: 10.2337/diabetes.54.5.1566]
27 **Sobel BE**, Hardison RM, Genuth S, Brooks MM, McBane RD, Schneider DJ, Pratley RE, Huber K, Wolk R, Krishnaswami A, Frye RL; BARI 2D Investigators. Profibrinolytic, antithrombotic, and antiinflammatory effects of an insulin-sensitizing strategy in patients in the Bypass Angioplasty Revascularization Investigation 2 Diabetes (BARI 2D) trial. *Circulation* 2011; **124**: 695-703 [PMID: 21768545 DOI: 10.1161/CIRCULATIONAHA.110.014860]
28 **Krysiak R**, Okopien B. The effect of metformin on monocyte secretory function in simvastatin-treated patients with impaired fasting glucose. *Metabolism* 2013; **62**: 39-43 [PMID: 22841520 DOI: 10.1016/j.metabol.2012.06.009]
29 **Pradhan AD**, Everett BM, Cook NR, Rifai N, Ridker PM. Effects of initiating insulin and metformin on glycemic control and inflammatory biomarkers among patients with type 2 diabetes: the LANCET randomized trial. *JAMA* 2009; **302**: 1186-1194 [PMID: 19755697 DOI: 10.1001/jama.2009.1347]
30 **Lima LM**, Wiernsperger N, Kraemer-Aguiar LG, Bouskela E. Short-term treatment with metformin improves the cardiovascular risk profile in first-degree relatives of subjects with type 2 diabetes mellitus who have a metabolic syndrome and normal glucose tolerance without changes in C-reactive protein or fibrinogen. *Clinics (Sao Paulo)* 2009; **64**: 415-420 [PMID: 19488607 DOI: 10.1590/S1807-59322009000500008]
31 **Lamkanfi M**, Mueller JL, Vitari AC, Misaghi S, Fedorova A, Deshayes K, Lee WP, Hoffman HM, Dixit VM. Glyburide inhibits the Cryopyrin/Nalp3 inflammasome. *J Cell Biol* 2009; **187**: 61-70 [PMID: 19805629 DOI: 10.1083/jcb.200903124]
32 **Räkel A**, Renier G, Roussin A, Buithieu J, Mamputu JC, Serri O. Beneficial effects of gliclazide modified release compared with glibenclamide on endothelial activation and low-grade inflammation in patients with type 2 diabetes. *Diabetes Obes Metab* 2007; **9**: 127-129 [PMID: 17199728 DOI: 10.1111/j.1463-1326.2006.00571.x]
33 **Mu-Huo J**, Jiao-Jiao Y, Lin-Sha J, Si-Hai Zhu, Jian-Jun Yang. Glibenclamide pretreatment attenuates acute lung injury by inhibiting the inflammatory responses and oxidative stress in a polymicrobial sepsis animal model. *J Anesth Perioper Med* 2014; **1**: 36-43 [DOI: 10.24015/JAPM.2014.0006]
34 **Kewcharoenwong C**, Rinchai D, Utispan K, Suwannasaen D, Bancroft GJ, Ato M, Lertmemongkolchai G. Glibenclamide reduces pro-inflammatory cytokine production by neutrophils of diabetes patients in response to bacterial infection. *Sci Rep* 2013; **3**: 3363 [PMID: 24285369 DOI: 10.1038/srep03363]
35 **Mavridis G**, Souliou E, Diza E, Symeonidis G, Pastore F, Vassiliou AM, Karamitsos D. Inflammatory

cytokines in insulin-treated patients with type 2 diabetes. *Nutr Metab Cardiovasc Dis* 2008; **18**: 471-476 [PMID: 17976964 DOI: 10.1016/j.numecd.2007.02.013]

36 **Derosa G**, Cicero AF, Fogari E, D'Angelo A, Bianchi L, Maffioli P. Pioglitazone compared to glibenclamide on lipid profile and inflammation markers in type 2 diabetic patients during an oral fat load. *Horm Metab Res* 2011; **43**: 505-512 [PMID: 21590648 DOI: 10.1055/s-0031-1275704]

37 **Derosa G**, Maffioli P, Salvadeo SA, Ferrari I, Ragonesi PD, Querci F, Franzetti IG, Gadaleta G, Ciccarelli L, Piccinni MN, D'Angelo A, Cicero AF. Exenatide versus glibenclamide in patients with diabetes. *Diabetes Technol Ther* 2010; **12**: 233-240 [PMID: 20151774 DOI: 10.1089/dia.2009.0141]

38 **Schöndorf T**, Musholt PB, Hohberg C, Forst T, Lehmann U, Fuchs W, Löbig M, Müller J, Pfützner A. The fixed combination of pioglitazone and metformin improves biomarkers of platelet function and chronic inflammation in type 2 diabetes patients: results from the PIOfix study. *J Diabetes Sci Technol* 2011; **5**: 426-432 [PMID: 21527115 DOI: 10.1177/193229681100500233]

39 **Erem C**, Ozbas HM, Nuhoglu I, Deger O, Civan N, Ersoz HO. Comparison of effects of gliclazide, metformin and pioglitazone monotherapies on glycemic control and cardiovascular risk factors in patients with newly diagnosed uncontrolled type 2 diabetes mellitus. *Exp Clin Endocrinol Diabetes* 2014; **122**: 295-302 [PMID: 24710641 DOI: 10.1055/s-0034-1370989]

40 **Bischoff H**. The mechanism of alpha-glucosidase inhibition in the management of diabetes. *Clin Invest Med* 1995; **18**: 303-311 [PMID: 8549017]

41 **Derosa G**, D'Angelo A, Salvadeo SA, Ferrari I, Fogari E, Gravina A, Mereu R, Palumbo I, Maffioli P, Randazzo S, Cicero AF. Modification of vascular and inflammation biomarkers after OGTT in overweight healthy and diabetic subjects. *Microvasc Res* 2010; **79**: 144-149 [PMID: 20079360 DOI: 10.1016/j.mvr.2010.01.002]

42 **Osonoi T**, Saito M, Mochizuki K, Fukaya N, Muramatsu T, Inoue S, Fuchigami M, Goda T. The α-glucosidase inhibitor miglitol decreases glucose fluctuations and inflammatory cytokine gene expression in peripheral leukocytes of Japanese patients with type 2 diabetes mellitus. *Metabolism* 2010; **59**: 1816-1822 [PMID: 20667563 DOI: 10.1016/j.metabol.2010.06.006]

43 **Emoto T**, Sawada T, Hashimoto M, Kageyama H, Terashita D, Mizoguchi T, Mizuguchi T, Motodi Y, Iwasaki M, Taira K, Okamoto H, Matsuo Y, Kim SK, Takarada A, Yokoyama M. Effect of 3-month repeated administration of miglitol on vascular endothelial function in patients with diabetes mellitus and coronary artery disease. *Am J Cardiol* 2012; **109**: 42-46 [PMID: 21944671 DOI: 10.1016/j.amjcard.2011.08.005]

44 **Derosa G**, Maffioli P, Ferrari I, Fogari E, D'Angelo A, Palumbo I, Randazzo S, Bianchi L, Cicero AF. Acarbose actions on insulin resistance and inflammatory parameters during an oral fat load. *Eur J Pharmacol* 2011; **651**: 240-250 [PMID: 21118681 DOI: 10.1016/j.ejphar.2010.11.015]

45 **Shimazu T**, Inami N, Satoh D, Kajiura T, Yamada K, Iwasaka T, Nomura S. Effect of acarbose on platelet-derived microparticles, soluble selectins, and adiponectin in diabetic patients. *J Thromb Thrombolysis* 2009; **28**: 429-435 [PMID: 19137265 DOI: 10.1007/s11239-008-0301-3]

46 **Fujitaka K**, Otani H, Jo F, Jo H, Nomura E, Iwasaki M, Nishikawa M, Iwasaka T. Comparison of metabolic profile and adiponectin level with pioglitazone versus voglibose in patients with type-2 diabetes mellitus associated with metabolic syndrome. *Endocr J* 2011; **58**: 425-432 [PMID: 21498915 DOI: 10.1507/endocrj.K10E-327]

47 **Ialenti A**, Grassia G, Di Meglio P, Maffia P, Di Rosa M, Ianaro A. Mechanism of the anti-inflammatory effect of thiazolidinediones: relationship with the glucocorticoid pathway. *Mol Pharmacol* 2005; **67**: 1620-1628 [PMID: 15684043 DOI: 10.1124/mol.104.004895]

48 **Ceriello A**. Thiazolidinediones as anti-inflammatory and anti-atherogenic agents. *Diabetes Metab Res Rev* 2008; **24**: 14-26 [PMID: 17990280 DOI: 10.1002/dmrr.790]

49 **Esterson YB**, Zhang K, Koppaka S, Kehlenbrink S, Kishore P, Raghavan P, Maginley SR, Carey M, Hawkins M. Insulin sensitizing and anti-inflammatory effects of thiazolidinediones are heightened in obese patients. *J Investig Med* 2013; **61**: 1152-1160 [PMID: 24141239 DOI: 10.2310/JIM.0000000000000017]

50 **Szanto A**, Nagy L. The many faces of PPARgamma: anti-inflammatory by any means? *Immunobiology* 2008; **213**: 789-803 [PMID: 18926294 DOI: 10.1016/j.imbio.2008.07.015]

51 **Boettcher E**, Csako G, Pucino F, Wesley R, Loomba R. Meta-analysis: pioglitazone improves liver histology and fibrosis in patients with non-alcoholic steatohepatitis. *Aliment Pharmacol Ther* 2012; **35**: 66-75 [PMID: 22050199 DOI: 10.1111/j.1365-2036.2011.04912.x]

52 **Reiss AB**, Vagell ME. PPARgamma activity in the vessel wall: anti-atherogenic properties. *Curr Med Chem* 2006; **13**: 3227-3238 [PMID: 17168709 DOI: 10.2174/092986706778742909]

53 **Haffner SM**, Greenberg AS, Weston WM, Chen H, Williams K, Freed MI. Effect of rosiglitazone treatment on nontraditional markers of cardiovascular disease in patients with type 2 diabetes mellitus. *Circulation* 2002; **106**: 679-684 [PMID: 12163427 DOI: 10.1161/01.CIR.0000025403.20953.23]

54 **Marx N**, Imhof A, Froehlich J, Siam L, Ittner J, Wierse G, Schmidt A, Maerz W, Hombach V, Koenig W. Effect of rosiglitazone treatment on soluble CD40L in patients with type 2 diabetes and coronary artery disease. *Circulation* 2003; **107**: 1954-1957 [PMID: 12695287 DOI: 10.1161/01.CIR.0000069272.06194.91]

55 **Chen R**, Yan J, Liu P, Wang Z. Effects of thiazolidinedione therapy on inflammatory markers of type 2 diabetes: a meta-analysis of randomized controlled trials. *PLoS One* 2015; **10**: e0123703 [PMID: 25897968 DOI: 10.1371/journal.pone.0123703]

56 **Nissen SE**, Nicholls SJ, Wolski K, Nesto R, Kupfer S, Perez A, Jure H, De Larochellière R, Staniloae CS, Mavromatis K, Saw J, Hu B, Lincoff AM, Tuzcu EM; PERISCOPE Investigators. Comparison of pioglitazone vs glimepiride on progression of coronary atherosclerosis in patients with type 2 diabetes: the PERISCOPE randomized controlled trial. *JAMA* 2008; **299**: 1561-1573 [PMID: 18378631 DOI: 10.1001/jama.299.13.1561]

57 **Satoh N**, Ogawa Y, Usui T, Tagami T, Kono S, Uesugi H, Sugiyama H, Sugawara A, Yamada K, Shimatsu A, Kuzuya H, Nakao K. Antiatherogenic effect of pioglitazone in type 2 diabetic patients irrespective of the responsiveness to its antidiabetic effect. *Diabetes Care* 2003; **26**: 2493-2499 [PMID: 12941708 DOI: 10.2337/diacare.26.9.2493]

58 **Nitta Y**, Tahara N, Tahara A, Honda A, Kodama N, Mizoguchi M, Kaida H, Ishibashi M, Hayabuchi N, Ikeda H, Yamagishi S, Imaizumi T. Pioglitazone decreases coronary artery inflammation in impaired glucose tolerance and diabetes mellitus: evaluation by FDG-PET/CT imaging. *JACC Cardiovasc Imaging* 2013; **6**: 1172-1182 [PMID: 24229770 DOI: 10.1016/j.jcmg.2013.09.004]

59 **Celinski K**, Dworzanski T, Fornal R, Korolczuk A, Madro A, Brzozowski T, Slomka M. Comparison of anti-inflammatory properties of peroxisome proliferator-activated receptor gamma agonists rosiglitazone

and troglitazone in prophylactic treatment of experimental colitis. *J Physiol Pharmacol* 2013; **64**: 587-595 [PMID: 24304573]

60 **Shahin D**, Toraby EE, Abdel-Malek H, Boshra V, Elsamanoudy AZ, Shaheen D. Effect of peroxisome proliferator-activated receptor gamma agonist (pioglitazone) and methotrexate on disease activity in rheumatoid arthritis (experimental and clinical study). *Clin Med Insights Arthritis Musculoskelet Disord* 2011; **4**: 1-10 [PMID: 21339857 DOI: 10.4137/CMAMD.S5951]

61 **Tahara A**, Kurosaki E, Yokono M, Yamajuku D, Kihara R, Hayashizaki Y, Takasu T, Imamura M, Li Q, Tomiyama H, Kobayashi Y, Noda A, Sasamata M, Shibasaki M. Effects of SGLT2 selective inhibitor ipragliflozin on hyperglycemia, hyperlipidemia, hepatic steatosis, oxidative stress, inflammation, and obesity in type 2 diabetic mice. *Eur J Pharmacol* 2013; **715**: 246-255 [PMID: 23707905 DOI: 10.1016/j.ejphar.2013.05.014]

62 **Nakatsu Y**, Kokubo H, Bumdelger B, Yoshizumi M, Yamamotoya T, Matsunaga Y, Ueda K, Inoue Y, Inoue MK, Fujishiro M, Kushiyama A, Ono H, Sakoda H, Asano T. The SGLT2 Inhibitor Luseogliflozin Rapidly Normalizes Aortic mRNA Levels of Inflammation-Related but Not Lipid-Metabolism-Related Genes and Suppresses Atherosclerosis in Diabetic ApoE KO Mice. *Int J Mol Sci* 2017; 18 [PMID: 28777298 DOI: 10.3390/ijms18081704]

63 **Han JH**, Oh TJ, Lee G, Maeng HJ, Lee DH, Kim KM, Choi SH, Jang HC, Lee HS, Park KS, Kim YB, Lim S. The beneficial effects of empagliflozin, an SGLT2 inhibitor, on atherosclerosis in ApoE ^{-/-} mice fed a western diet. *Diabetologia* 2017; **60**: 364-376 [PMID: 27866224 DOI: 10.1007/s00125-016-4158-2]

64 **Xu L**, Nagata N, Nagashimada M, Zhuge F, Ni Y, Chen G, Mayoux E, Kaneko S, Ota T. SGLT2 Inhibition by Empagliflozin Promotes Fat Utilization and Browning and Attenuates Inflammation and Insulin Resistance by Polarizing M2 Macrophages in Diet-induced Obese Mice. *EBioMedicine* 2017; **20**: 137-149 [PMID: 28579299 DOI: 10.1016/j.ebiom.2017.05.028]

65 **Jojima T**, Tomotsune T, Iijima T, Akimoto K, Suzuki K, Aso Y. Empagliflozin (an SGLT2 inhibitor), alone or in combination with linagliptin (a DPP-4 inhibitor), prevents steatohepatitis in a novel mouse model of non-alcoholic steatohepatitis and diabetes. *Diabetol Metab Syndr* 2016; **8**: 45 [PMID: 27462372 DOI: 10.1186/s13098-016-0169-x]

66 **Ye Y**, Bajaj M, Yang HC, Perez-Polo JR, Birnbaum Y. SGLT-2 Inhibition with Dapagliflozin Reduces the Activation of the Nlrp3/ASC Inflammasome and Attenuates the Development of Diabetic Cardiomyopathy in Mice with Type 2 Diabetes. Further Augmentation of the Effects with Saxagliptin, a DPP4 Inhibitor. *Cardiovasc Drugs Ther* 2017; **31**: 119-132 [PMID: 28447181 DOI: 10.1007/s10557-017-6725-2]

67 **Vallon V**, Gerasimova M, Rose MA, Masuda T, Satriano J, Mayoux E, Koepsell H, Thomson SC, Rieg T. SGLT2 inhibitor empagliflozin reduces renal growth and albuminuria in proportion to hyperglycemia and prevents glomerular hyperfiltration in diabetic Akita mice. *Am J Physiol Renal Physiol* 2014; **306**: F194-F204 [PMID: 24226524 DOI: 10.1152/ajprenal.00520.2013]

68 **Hatanaka T**, Ogawa D, Tachibana H, Eguchi J, Inoue T, Yamada H, Takei K, Makino H, Wada J. Inhibition of SGLT2 alleviates diabetic nephropathy by suppressing high glucose-induced oxidative stress in type 1 diabetic mice. *Pharmacol Res Perspect* 2016; **4**: e00239 [PMID: 28116093 DOI: 10.1002/prp2.239]

69 **Terami N**, Ogawa D, Tachibana H, Hatanaka T, Wada J, Nakatsuka A, Eguchi J, Horiguchi CS, Nishii N, Yamada H, Takei K, Makino H. Long-term treatment with the sodium glucose cotransporter 2 inhibitor, dapagliflozin, ameliorates glucose homeostasis and diabetic nephropathy in db/db mice. *PLoS One* 2014; **9**: e100777 [PMID: 24960177 DOI: 10.1371/journal.pone.0100777]

70 **Tan SA**, Tan L. Empagliflozin and canagliflozin attenuate inflammatory cytokines interferon-λ, tumor necrosis factor-α, intrleukin-6: possible mechanism of decreasing cardiovascular risk in diabetes mellitus. *J Am Coll Cardiol* 2018; **71**: A1830 [DOI: 10.1016/S0735-1097(18)32371-4]

71 **Sato T**, Aizawa Y, Yuasa S, Kishi S, Fuse K, Fujita S, Ikeda Y, Kitazawa H, Takahashi M, Sato M, Okabe M. The effect of dapagliflozin treatment on epicardial adipose tissue volume. *Cardiovasc Diabetol* 2018; **17**: 6 [PMID: 29301516 DOI: 10.1186/s12933-017-0658-8]

72 **Okamoto A**, Yokokawa H, Sanada H, Naito T. Changes in Levels of Biomarkers Associated with Adipocyte Function and Insulin and Glucagon Kinetics During Treatment with Dapagliflozin Among Obese Type 2 Diabetes Mellitus Patients. *Drugs R D* 2016; **16**: 255-261 [PMID: 27333994 DOI: 10.1007/s40268-016-0137-9]

73 **Ferrannini E**, Ramos SJ, Salsali A, Tang W, List JF. Dapagliflozin monotherapy in type 2 diabetic patients with inadequate glycemic control by diet and exercise: a randomized, double-blind, placebo-controlled, phase 3 trial. *Diabetes Care* 2010; **33**: 2217-2224 [PMID: 20566676 DOI: 10.2337/dc10-0612]

74 **Garvey WT**, Van Gaal L, Leiter LA, Vijapurkar U, List J, Cuddihy R, Ren J, Davies MJ. Effects of canagliflozin versus glimepiride on adipokines and inflammatory biomarkers in type 2 diabetes. *Metabolism* 2018; **85**: 32-37 [PMID: 29452178 DOI: 10.1016/j.metabol.2018.02.002]

75 **Thornberry NA**, Gallwitz B. Mechanism of action of inhibitors of dipeptidyl-peptidase-4 (DPP-4). *Best Pract Res Clin Endocrinol Metab* 2009; **23**: 479-486 [PMID: 19748065 DOI: 10.1016/j.beem.2009.03.004]

76 **Yang L**, Yuan J, Zhou Z. Emerging roles of dipeptidyl peptidase 4 inhibitors: anti-inflammatory and immunomodulatory effect and its application in diabetes mellitus. *Can J Diabetes* 2014; **38**: 473-479 [PMID: 25034244 DOI: 10.1016/j.jcjd.2014.01.008]

77 **Ta NN**, Schuyler CA, Li Y, Lopes-Virella MF, Huang Y. DPP-4 (CD26) inhibitor alogliptin inhibits atherosclerosis in diabetic apolipoprotein E-deficient mice. *J Cardiovasc Pharmacol* 2011; **58**: 157-166 [PMID: 21558879 DOI: 10.1097/FJC.0b013e31821e5626]

78 **Matsubara J**, Sugiyama S, Sugamura K, Nakamura T, Fujiwara Y, Akiyama E, Kurokawa H, Nozaki T, Ohba K, Konishi M, Maeda H, Izumiya Y, Kaikita K, Sumida H, Jinnouchi H, Matsui K, Kim-Mitsuyama S, Takeya M, Ogawa H. A dipeptidyl peptidase-4 inhibitor, des-fluoro-sitagliptin, improves endothelial function and reduces atherosclerotic lesion formation in apolipoprotein E-deficient mice. *J Am Coll Cardiol* 2012; **59**: 265-276 [PMID: 22240132 DOI: 10.1016/j.jacc.2011.07.053]

79 **Hirakawa H**, Zempo H, Ogawa M, Watanabe R, Suzuki J, Akazawa H, Komuro I, Isobe M. A DPP-4 inhibitor suppresses fibrosis and inflammation on experimental autoimmune myocarditis in mice. *PLoS One* 2015; **10**: e0119360 [PMID: 25768281 DOI: 10.1371/journal.pone.0119360]

80 **Dobrian AD**, Ma Q, Lindsay JW, Leone KA, Ma K, Coben J, Galkina EV, Nadler JL. Dipeptidyl peptidase IV inhibitor sitagliptin reduces local inflammation in adipose tissue and in pancreatic islets of obese mice. *Am J Physiol Endocrinol Metab* 2011; **300**: E410-E421 [PMID: 21081706 DOI: 10.1152/ajpendo.00463.2010]

81 **Lim S**, Choi SH, Shin H, Cho BJ, Park HS, Ahn BY, Kang SM, Yoon JW, Jang HC, Kim YB, Park KS. Effect of a dipeptidyl peptidase-IV inhibitor, des-fluoro-sitagliptin, on neointimal formation after balloon injury in rats. *PLoS One* 2012; **7**: e35007 [PMID: 22493727 DOI: 10.1371/journal.pone.0035007]

82 **Lee SA**, Kim YR, Yang EJ, Kwon EJ, Kim SH, Kang SH, Park DB, Oh BC, Kim J, Heo ST, Koh G, Lee DH. CD26/DPP4 levels in peripheral blood and T cells in patients with type 2 diabetes mellitus. *J Clin Endocrinol Metab* 2013; **98**: 2553-2561 [PMID: 23539735 DOI: 10.1210/jc.2012-4288]

83 **Makdissi A**, Ghanim H, Vora M, Green K, Abuaysheh S, Chaudhuri A, Dhindsa S, Dandona P. Sitagliptin exerts an antinflammatory action. *J Clin Endocrinol Metab* 2012; **97**: 3333-3341 [PMID: 22745245 DOI: 10.1210/jc.2012-1544]

84 **Satoh-Asahara N**, Sasaki Y, Wada H, Tochiya M, Iguchi A, Nakagawachi R, Odori S, Kono S, Hasegawa K, Shimatsu A. A dipeptidyl peptidase-4 inhibitor, sitagliptin, exerts anti-inflammatory effects in type 2 diabetic patients. *Metabolism* 2013; **62**: 347-351 [PMID: 23062489 DOI: 10.1016/j.metabol.2012.09.004]

85 **Rizzo MR**, Barbieri M, Marfella R, Paolisso G. Reduction of oxidative stress and inflammation by blunting daily acute glucose fluctuations in patients with type 2 diabetes: role of dipeptidyl peptidase-IV inhibition. *Diabetes Care* 2012; **35**: 2076-2082 [PMID: 22688551 DOI: 10.2337/dc12-0199]

86 **Matsubara J**, Sugiyama S, Akiyama E, Iwashita S, Kurokawa H, Ohba K, Maeda H, Fujisue K, Yamamoto E, Kaikita K, Hokimoto S, Jinnouchi H, Ogawa H. Dipeptidyl peptidase-4 inhibitor, sitagliptin, improves endothelial dysfunction in association with its anti-inflammatory effects in patients with coronary artery disease and uncontrolled diabetes. *Circ J* 2013; **77**: 1337–1344 [DOI: 10.1253/circj.CJ-12-1168]

87 **Nakamura Y**, Tsuji M, Hasegawa H, Kimura K, Fujita K, Inoue M, Shimizu T, Gotoh H, Goto Y, Inagaki M, Oguchi K. Anti-inflammatory effects of linagliptin in hemodialysis patients with diabetes. *Hemodial Int* 2014; **18**: 433-442 [PMID: 24405885 DOI: 10.1111/hdi.12127]

88 **Derosa G**, Maffioli P, Salvadeo SA, Ferrari I, Ragonesi PD, Querci F, Franzetti IG, Gadaleta G, Ciccarelli L, Piccinni MN, D'Angelo A, Cicero AF. Effects of sitagliptin or metformin added to pioglitazone monotherapy in poorly controlled type 2 diabetes mellitus patients. *Metabolism* 2010; **59**: 887-895 [PMID: 20015525 DOI: 10.1016/j.metabol.2009.10.007]

89 **Hogan AE**, Gaoatswe G, Lynch L, Corrigan MA, Woods C, O'Connell J, O'Shea D. Glucagon-like peptide 1 analogue therapy directly modulates innate immune-mediated inflammation in individuals with type 2 diabetes mellitus. *Diabetologia* 2014; **57**: 781-784 [PMID: 24362727 DOI: 10.1007/s00125-013-3145-0]

90 **Wu JD**, Xu XH, Zhu J, Ding B, Du TX, Gao G, Mao XM, Ye L, Lee KO, Ma JH. Effect of exenatide on inflammatory and oxidative stress markers in patients with type 2 diabetes mellitus. *Diabetes Technol Ther* 2011; **13**: 143-148 [PMID: 21284481 DOI: 10.1089/dia.2010.0048]

91 **Lee YS**, Jun HS. Anti-Inflammatory Effects of GLP-1-Based Therapies beyond Glucose Control. *Mediators Inflamm* 2016; **2016**: 3094642 [PMID: 27110066 DOI: 10.1155/2016/3094642]

92 **Lee YS**, Park MS, Choung JS, Kim SS, Oh HH, Choi CS, Ha SY, Kang Y, Kim Y, Jun HS. Glucagon-like peptide-1 inhibits adipose tissue macrophage infiltration and inflammation in an obese mouse model of diabetes. *Diabetologia* 2012; **55**: 2456-2468 [PMID: 22722451 DOI: 10.1007/s00125-012-2592-3]

93 **Arakawa M**, Mita T, Azuma K, Ebato C, Goto H, Nomiyama T, Fujitani Y, Hirose T, Kawamori R, Watada H. Inhibition of monocyte adhesion to endothelial cells and attenuation of atherosclerotic lesion by a glucagon-like peptide-1 receptor agonist, exendin-4. *Diabetes* 2010; **59**: 1030-1037 [PMID: 20068138 DOI: 10.2337/db09-1694]

94 **Bułdak Ł**, Machnik G, Bułdak RJ, Łabuzek K, Bołdys A, Belowski D, Basiak M, Okopień B. Exenatide (a GLP-1 agonist) expresses anti-inflammatory properties in cultured human monocytes/macrophages in a protein kinase A and B/Akt manner. *Pharmacol Rep* 2016; **68**: 329-337 [PMID: 26922535 DOI: 10.1016/j.pharep.2015.10.008]

95 **Kodera R**, Shikata K, Kataoka HU, Takatsuka T, Miyamoto S, Sasaki M, Kajitani N, Nishishita S, Sarai K, Hirota D, Sato C, Ogawa D, Makino H. Glucagon-like peptide-1 receptor agonist ameliorates renal injury through its anti-inflammatory action without lowering blood glucose level in a rat model of type 1 diabetes. *Diabetologia* 2011; **54**: 965-978 [PMID: 21253697 DOI: 10.1007/s00125-010-2028-x]

96 **Kim S**, Jeong J, Jung HS, Kim B, Kim YE, Lim DS, Kim SD, Song YS. Anti-inflammatory Effect of Glucagon Like Peptide-1 Receptor Agonist, Exendin-4, through Modulation of IB1/JIP1 Expression and JNK Signaling in Stroke. *Exp Neurobiol* 2017; **26**: 227-239 [PMID: 28912645 DOI: 10.5607/en.2017.26.4.227]

97 **Wang XC**, Gusdon AM, Liu H, Qu S. Effects of glucagon-like peptide-1 receptor agonists on non-alcoholic fatty liver disease and inflammation. *World J Gastroenterol* 2014; **20**: 14821-14830 [PMID: 25356042 DOI: 10.3748/wjg.v20.i40.14821]

98 **Wang Y**, Parlevliet ET, Geerling JJ, van der Tuin SJ, Zhang H, Bieghs V, Jawad AH, Shiri-Sverdlov R, Bot I, de Jager SC, Havekes LM, Romijn JA, Willems van Dijk K, Rensen PC. Exendin-4 decreases liver inflammation and atherosclerosis development simultaneously by reducing macrophage infiltration. *Br J Pharmacol* 2014; **171**: 723-734 [PMID: 24490861 DOI: 10.1111/bph.12490]

99 **Derosa G**, Franzetti IG, Querci F, Carbone A, Ciccarelli L, Piccinni MN, Fogari E, Maffioli P. Exenatide plus metformin compared with metformin alone on β-cell function in patients with Type 2 diabetes. *Diabet Med* 2012; **29**: 1515-1523 [PMID: 22540883 DOI: 10.1111/j.1464-5491.2012.03699.x]

100 **Bunck MC**, Diamant M, Eliasson B, Cornér A, Shaginian RM, Heine RJ, Taskinen MR, Yki-Järvinen H, Smith U. Exenatide affects circulating cardiovascular risk biomarkers independently of changes in body composition. *Diabetes Care* 2010; **33**: 1734-1737 [PMID: 20424219 DOI: 10.2337/dc09-2361]

101 **Daousi C**, Pinkney JH, Cleator J, Wilding JP, Ranganath LR. Acute peripheral administration of synthetic human GLP-1 (7-36 amide) decreases circulating IL-6 in obese patients with type 2 diabetes mellitus: a potential role for GLP-1 in modulation of the diabetic pro-inflammatory state? *Regul Pept* 2013; **183**: 54-61 [PMID: 23499806 DOI: 10.1016/j.regpep.2013.03.004]

102 **Varanasi A**, Patel P, Makdissi A, Dhindsa S, Chaudhuri A, Dandona P. Clinical use of liraglutide in type 2 diabetes and its effects on cardiovascular risk factors. *Endocr Pract* 2012; **18**: 140-145 [PMID: 21856595 DOI: 10.4158/EP11169.OR]

103 **Dandona P**, Chaudhuri A, Ghanim H, Mohanty P. Insulin as an anti-inflammatory and antiatherogenic modulator. *J Am Coll Cardiol* 2009; **53**: S14-S20 [PMID: 19179212 DOI: 10.1016/j.jacc.2008.10.038]

104 **Mao XM**, Liu H, Tao XJ, Yin GP, Li Q, Wang SK. Independent anti-inflammatory effect of insulin in newly diagnosed type 2 diabetes. *Diabetes Metab Res Rev* 2009; **25**: 435-441 [PMID: 19405039 DOI: 10.1002/dmrr.968]

105 **Takebayashi K**, Aso Y, Inukai T. Initiation of insulin therapy reduces serum concentrations of high-sensitivity C-reactive protein in patients with type 2 diabetes. *Metabolism* 2004; **53**: 693-699 [PMID:

15164314 DOI: 10.1016/j.metabol.2004.01.003]
106 **Jansen HJ**, Stienstra R, van Diepen JA, Hijmans A, van der Laak JA, Vervoort GM, Tack CJ. Start of insulin therapy in patients with type 2 diabetes mellitus promotes the influx of macrophages into subcutaneous adipose tissue. *Diabetologia* 2013; **56**: 2573-2581 [PMID: 24065152 DOI: 10.1007/s00125-013-3018-6]

World Journal of Meta-Analysis

Submit a Manuscript: https://www.f6publishing.com

World J Meta-Anal 2019 April 30; 7(4): 142-155

DOI: 10.13105/wjma.v7.i4.142

ISSN 2308-3840 (online)

REVIEW

Subcellular expression of maspin – from normal tissue to tumor cells

Laura Banias, Ioan Jung, Simona Gurzu

ORCID number: Laura Banias (0000-0002-2240-2540); Ioan Jung (0000-0001-6537-2807); Simona Gurzu (0000-0003-3968-5118).

Author contributions: Banias L designed the research and drafted the article; Jung I analyzed the literature data and revised the collected data; Gurzu S designed the research and approved the final draft; Banias L and Jung I are co-first authors, having an equal contribution to the paper.

Supported by Romanian National Authority for Scientific Research, CNCS – UEFISCDI, No. 20 PCCF/2018, code: PN-III-P4-ID-PCCF-2016-0006.

Conflict-of-interest statement: The authors have no conflict of interest to report.

Manuscript source: Invited manuscript

Received: March 18, 2019
Peer-review started: March 19, 2019

Laura Banias, Ioan Jung, Simona Gurzu, Department of Pathology, University of Medicine, Pharmacy, Sciences and Technology of Tirgu-Mures, Tirgu Mures 540139, Romania

Laura Banias, Simona Gurzu, Department of Pathology, Clinical County Emergency Hospital, Tirgu Mures 540139, Romania

Corresponding author: Simona Gurzu, MD, PhD, Professor, Head, Department of Pathology, University of Medicine, Pharmacy, Sciences and Technology, 38 Gheorghe Marinescu Street, Targu Mures 530149, Romania. simona.gurzu@umfst.ro
Telephone: +40-745-673550
Fax: +40-265-210407

Abstract

Maspin or SerpinB5, a member of the serine protease inhibitor family, was shown to function as a tumor suppressor, especially in carcinomas. It seems to inhibit invasion, tumor cells motility and angiogenesis, and promotes apoptosis. Maspin can also induce epigenetic changes such as cytosine methylation, de-acetylation, chromatin condensation, and histone modulation. In this review, a comprehensive synthesis of the literature was done to present maspin function from normal tissues to pathologic conditions. Data was sourced from MEDLINE and PubMed. Study eligibility criteria included: Published in English, between 1994 and 2019, specific to humans, and with full-text availability. Most of the 118 studies included in the present review focused on maspin immunostaining and mRNA levels. It was shown that maspin function is organ-related and depends on its subcellular localization. In malignant tumors, it might be downregulated or negative (*e.g.*, carcinoma of prostate, stomach, and breast) or upregulated (*e.g.*, colorectal and pancreatic tumors). Its subcellular localization (nuclear *vs* cytoplasm), which can be proved using immunohistochemical methods, was shown to influence both tumor behavior and response to chemotherapy. Although the number of maspin-related papers increased, the exact role of this protein remains unknown, and its interpretation should be done with extremely high caution.

Key words: Maspin; SerpinB5; Prognosis; Cancer; Tumor suppressor

Core tip: The present paper concentrated on showing different patterns of immunohistochemical expression and mRNA levels of maspin, as presented in published

First decision: April 18, 2019
Revised: April 22, 2019
Accepted: April 23, 2019
Article in press: April 23, 2019
Published online: April 30, 2019

P-Reviewer: El Ghoch M
S-Editor: Ji FF
L-Editor: Filipodia
E-Editor: Wu YXJ

studies from 1994 until the beginning of 2019 that were included in the PubMed database. It was shown that maspin, a member of the serine protease inhibitor family, functions as a tumor suppressor or tumor promoter. Its function is organ-related and depends on its subcellular localization. In colorectal cancer specimens, maspin was a helpful marker of budding assessment. In most of the malignant tumors, it was demonstrated to be an independent prognostic and predictive factor.

Citation: Banias L, Jung I, Gurzu S. Subcellular expression of maspin – from normal tissue to tumor cells. *World J Meta-Anal* 2019; 7(4): 142-155
URL: https://www.wjgnet.com/2308-3840/full/v7/i4/142.htm
DOI: https://dx.doi.org/10.13105/wjma.v7.i4.142

INTRODUCTION

Maspin, also known as SerpinB5, is a member of the serine protease inhibitor family, which was identified by Zou *et al*[1] in 1994[2-4]. In most of the studies, it acted as a tumor suppressor through inhibitory effects on invasion, motility, and angiogenesis and through stimulation of a mitochondrial apoptosis pathway[1-4]. This negative impact on tumor cells is supposed to be p53-linked[5].

Maspin can also induce epigenetic changes like cytosine methylation, deacetylation, chromatin condensation, or histone modulation[3]. Recent *in vitro* studies focused on maspin secretion[6,7]. These studies tried to prove that maspin is a soluble free or an exosome cargo protein, which might be chemically synthesized and used as a future medical drug[6,7]. *In vitro*, maspin influenced the peritumoral microenvironment by enhancing macrophage secretion of inflammatory cytokines[6,7].

In the human body, maspin is expressed in many tissues or organs and is down or upregulated in malignant tumors. As maspin shows different subcellular localizations (cytoplasmic and nuclear), in both normal and tumor tissues, it is difficult to appreciate its exact role in tumorigenesis, tumor invasion, or progression[8]. The aim of this review was to perform a complex synthesis regarding maspin expression in different organs, from normal tissue to non-tumor disorders and malignant transformation. The organ-related subcellular expression was also emphasized.

METHODOLOGY

The present paper represents a narrative review of the literature on the serine protease inhibitor maspin, focusing mainly on its immunohistochemical (IHC) expression in different tissues and pathologic processes.

The online search consisted of browsing the PubMed/MEDLINE database using the MeSH terms and keywords "maspin" and "serpinB5" to identify articles published between 1994 and the beginning of 2019. Eligible for inclusion were only publications written in English, studies for human species, and with full-text availability (Figure 1).

Besides the detailed presentation of data, summary tables regarding maspin immunoexpression in different organs in various conditions were constructed based on the data published in the included articles (Tables 1-3).

TISSUE- AND ORGAN-RELATED MASPIN EXPRESSION, IN NORMAL AND PATHOLOGIC CONDITIONS

Placenta

Dokras *et al*[9] first evaluated IHC expression and mRNA levels of placenta maspin, in 2002. Placentas obtained after first and second trimester pregnancy and after caesarian deliveries at term were included in their observations. The maximum values of maspin mRNA level were detected in the third trimester of pregnancy. On the other hand, negative expression was observed in the immortalized first trimester cytotrophoblasts and choriocarcinoma cell lines with high invasive ability. Similar to the mRNA levels, IHC expression showed patchy staining of the cytotrophoblastic layer in the first trimester, uniform cyto- and syncytiotrophoblastic layers in the

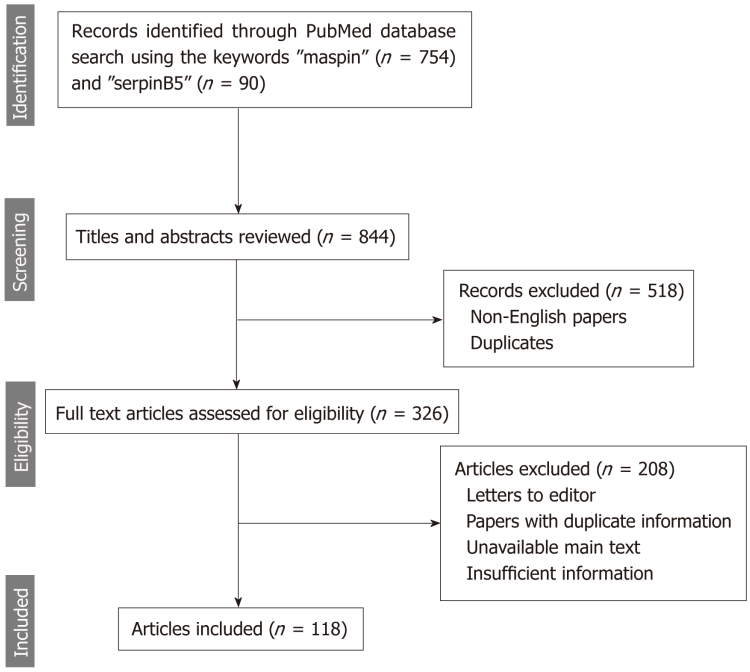

Figure 1 The methodology (PRISMA flow diagram) used for this review.

second trimester, and more intense expression in the third trimester[9] (Table 1).

In preeclamptic (PE) placentas, both mRNA and protein levels were upregulated (Table 1) and correlated with modifications observed with Hematoxylin and Eosin stain[10]. It was intimal enlargement of the vessel wall, thickening of the syncytiotrophoblast membranes, and increased number of syncytial knots. It was concluded that hypomethylation of the maspin promoter might be the causal factor of the increased expression of maspin in PE placentas[10].

Qi *et al*[11] evaluated the plasmatic level of unmethylated maspin DNA in a population consisting of women with normal pregnancies, PE, and gestational trophoblastic disease. Unmethylated maspin DNA was not detected in healthy nonpregnant women and in those with the trophoblastic gestational disease. The level was higher in women with severe PE than in those with normal third trimester pregnancies and presented a gradual increase with the gestational age[11].

Methylated and unmethylated maspin DNA blood concentrations may be useful for identification of noninvasive fetal trisomy 18 beginning in the first trimester[12]. Methylation of the maspin gene induces downregulation of maspin protein expression and subsequently inhibits migration and invasion of the first trimester extravillous trophoblast cell line through interaction with the proangiogenic factors such as mismatch repair proteins (*e.g.*, MMP2) or vascular endothelial growth factors (VEGF-A and VEGF-C)[13]. This interaction might lead to the occurrence of PE[13].

Regarding maspin subcellular localization, nuclear expression was limited to the chorionic plate with significant downregulation in the extravillous trophoblasts[14]. Cytoplasmic positivity can be seen in endothelial cells and trophoblasts[9,14] (Table 1).

Mammary gland

Maspin expression was evaluated in both normal tissues, especially during pregnancy and carcinomas of the mammary gland[15-20]. In late pregnancy, a peak of expression is seen during lactation and the level decreases and remains constant after the lactation period[20]. Almost all cells presented cytoplasmic staining with infrequent nuclear positivity (Table 1), which can be an indicator of epithelial growth factor induced maspin phosphorylation[20].

In breast carcinomas, there are several maspin-related studies, but in most of them no data about the subcellular localization of staining were included. In these tumors, maspin IHC positivity (independently by the localization) was directly correlated with larger tumor size, younger age, high histologic grade, negative expression of estrogen receptor and/or progesterone receptor, positivity for p53, and a lymphocyte-rich stroma[15-18]. In other studies, it was hypothesized that maspin is not involved in breast cancer histogenesis, at least in those carcinomas with extremely aggressive behavior[21].

Table 1 Maspin expression in placenta, mammary gland, and urogenital organs

Organ/ tissue	Subcellular expression in normal tissue	Subcellular expression in pathologic conditions
Placenta	Cytoplasm: Syncytio- and cytotrophoblasts, and endothelial cells; Nucleus: Chorionic plate	Preeclampsia: Upregulation
Mammary gland	Cytoplasm: Myoepithelial cells (intense in pregnancy and lactation); Nucleus: Myoepithelial cells	Invasive breast cancer: Maspin positivity is more frequent in ductal than lobular carcinomas; Cytoplasm only: Negative prognostic indicator, ER and PgR negativity; Nucleus: Better prognosis, ER and PgR positivity; Negativity: Loss or cytoplasm to nuclear translocation in metastatic tissue
Ovary	Negative	Benign tumors: Negative or infrequent nuclear; Ovarian carcinomas: Cytoplasm only: Cisplatin sensitivity; Mixed expression (cytoplasm and nucleus): Indicator of low malignant potential
Uterine cervix	Squamous epithelium: Cytoplasmic and nuclear staining	CIN3: Cytoplasm: Down regulation; Nucleus: Upregulation; Squamous cell carcinoma: Cytoplasm: Tumor suppressor role; Adenocarcinoma: Cytoplasm: Aggressive behavior
Uterine body	Negative or positive (mostly nuclear) staining in normal endometrial glands; Low intensity in atrophic endometrium	Endometrial hyperplasia: Nucleus: Indicator of atypia; Endometrioid endometrial adenocarcinoma: Cytoplasm: Aggressive behavior; Nucleus: Better prognosis
Prostate	Basal cells: Positive; Secretory cells: Negative	HGPIN: Basal cells: Positive (same intensity as normal); Secretory cells: Positive; Adenocarcinoma: Low-grade carcinoma: Reduced expression compared with HGPIN; High-grade carcinoma: Low or no expression
Urinary bladder	Positive in epithelial cells	Urothelial carcinoma: Nucleus: Better prognosis

CIN: Cervical intraepithelial neoplasia; ER: Estrogen receptor; HGPIN: High-grade prostate intraepithelial neoplasia; PgR: Progesterone receptor.

Examination of the subcellular localization (Table 1) revealed that maspin cytoplasmic positivity is observed in 36% of invasive ductal carcinomas and 7% of lobular carcinomas, the latter being mostly maspin-negative[18,21]. The nuclear expression is related with estrogen receptor and progesterone receptor positivity, while the cytoplasmic location is an indicator of negativity for hormone receptors, high S-phase fraction, and aneuploidy[19]. Maspin cytoplasmic positivity was suggested to be a poor prognostic indicator of invasive breast cancer, independently of the histologic subtype[19].

Machowska *et al*[22] presented nuclear location as a better prognostic factor in cases with invasive ductal carcinoma. Nuclear positivity was an indicator of Ki-67 negativity or low expression[22]. In a study by Strien *et al*[23], which compares luminal subtype A and B breast cancers, it was shown that maspin expression was lost in metastases, in the majority of maspin-positive primary tumors, or presented translocation from cytoplasmic to nuclear positivity. No differences between subtype A and B were noted.

Wakahara *et al*[24], examining four categories of maspin expression [cytoplasmic only, nuclear only, mixed (cytoplasm + nuclei), and negative] and their correlations with histone deacetylase 1, showed that maspin cytoplasmic only represents an independent negative prognostic factor, thus being an indicator of higher histological grade, negative progesterone receptor expression, shorter disease-free survival, and higher histone deacetylase 1 compared with the mixed expression group. They suggested that inhibition of histone deacetylase 1 could represent an inhibitory mechanism for maspin[24].

Recently, Umekita *et al*[25] demonstrated that maspin mRNA expression in sentinel lymph nodes represents an independent factor of nonsentinel lymph node metastasis. Maspin was shown to act upon peritumoral stroma and to increase collagen production as a cause for doxorubicin resistance[26].

Urogenital system

Ovary: Expression of maspin was not present in the normal ovary[27-30]. In ovarian carcinomas, maspin expression in over 50% of the tumor cells was associated with higher tumor grade, positive peritoneal effusion cytology, lower survival rate, and positivity for the proangiogenic factors VEGF-A, -C, and -D[27,28]. Most of the

Table 2 Maspin expression in organs of the respiratory and gastroenteropancreatic system

Organ/ tissue	Subcellular expression in normal tissue	Subcellular expression in pathologic conditions
Lung	Bronchial basal cells: Nuclear staining; Alveolocytes: Negative	Non-small cell carcinomas: Cytoplasm only: Negative prognostic factor; Nucleus only: Low aggressivity
Esophagus	Squamous epithelium: Negative or weak cytoplasm	SCC: Nucleus: Low pTNM stage; Cytoplasm: Risk for lymph node metastases
Stomach	Foveolar and glandular cells: Cytoplasm or negative	Dysplasia: Nucleus: High-grade dysplasia; Carcinomas: Cytoplasm: Better prognosis; Nuclear: Local aggressive behavior; Negative: Risk for distant metastases or neuroendocrine component
Colon and rectum	Normal mucosa: Cytoplasm or negative	Dysplasia: Nucleus: High-grade dysplasia; Adenocarcinoma: Cytoplasm only: Low-grade tumor, low risk for metastases, high chance for MSI-H status; Nuclear only: High pTNM stage, high-grade budding; Negative: Risk for distant metastases or neuroendocrine component
Liver and intrahepatic biliary ducts	Negative in most of the normal hepatocytes and in normal biliary ducts	Carcinoma: Positive (cytoplasmic, nuclear or mixed cyto-nuclear expression), with unknown significance
Pancreas	Negative in exo- and endocrine pancreas	PanIN grade 1 and grade 2: Negative; PanIN grade 3 and PDAC: Positive (cytoplasmic and nuclear staining); Endocrine tumors: Negative; Ductal adenocarcinoma: Nuclear
Gallbladder	Negative or positive (cyto-nuclear staining)	Dysplasia: Negative or weak staining; BilIN, carcinoma: Cyto-nuclear expression gradually increases from normal epithelium to BilIN and carcinoma

BilIN: Biliary intraepithelial neoplasia; MSI-H: High microsatellite instability; PanIN: Pancreatic intraepithelial neoplasia; SCC: Squamous cell carcinoma; PDAC: Pancreatic ductal adenocarcinoma

malignant tumors presented with cytoplasmic only expression, but those with low malignant potential showed mixed positivity (cytoplasm and nucleus)[29]. The localization of maspin expression might have therapeutic importance because the cytoplasmic positivity associates with cisplatin sensitivity[30] (Table 1).

Uterine cervix: Maspin is expressed both in the cytoplasm and nucleus of the normal squamous cervical epithelium[31,32]. The cytoplasmic expression is downregulated in premalignant disorders such as cervical intraepithelial neoplasia grade 3 and even more downregulated from microinvasive to invasive squamous cell carcinoma (SCC)[31,32].

In SCC, cytoplasmic maspin can be colocalized with cytoplasmic testisin, a serine protease normally found in testicular germ cells, which inhibits the tumor suppressor activity of maspin[33]. Maspin positivity is correlated with advanced stage, increased lymphatic microvessel density, and the presence of lymph node metastases[31,32]. Nuclear expression increases in cervical intraepithelial neoplasia grade 3 but significantly decreases in SCC cells[31,32]. Maspin expression is decreased or lost in intravascular emboli from SCCs[31,32]. In adenocarcinomas of the uterine cervix, cytoplasmic expression of maspin was found to be an indicator of aggressive behavior[34] (Table 1).

Uterine body: The normal endometrium is maspin negative or localizes to the nucleus[35-37]. Maspin is positive in most of the cases diagnosed as atypical hyperplasia or endometrioid endometrial adenocarcinoma (nuclear and/or cytoplasmic staining). Maspin expression is also correlated with lymph node metastases and FIGO stage in endometrioid endometrial adenocarcinoma[35-37]. Nuclear subcellular localization was correlated with squamous cell differentiation of endometrioid endometrial adenocarcinoma and with better prognosis, while concurrent cytoplasmic positivity represents an indicator of a more aggressive tumor[36,38] (Table 1).

Prostate gland: In normal prostate, maspin marks basal but not secretory cells[39-43]. Its expression is upregulated in high-grade prostatic intraepithelial neoplasia and downregulated during progression to invasive carcinoma[41] (Table 1). In prostate carcinomas, maspin exerts a tumor suppressing role[39,40]. Negative or decreased IHC

Table 3 Maspin expression in brain, organs of the head and neck area, skin and soft tissues

Organ/ tissue	Subcellular expression in normal tissue	Subcellular expression in pathologic conditions
Brain	Positive in nucleus and cytoplasm	Decreased expression in parallel with the advancing glioma stage
Head and neck	Cytoplasm: Oral cavity epithelium and temporal bone; Nucleus: Salivary glands: Myoepithelial cells, basal cells of the ducts and some luminal cells; Negative: Salivary glands: Secretory cells	Oral SCC: Cytoplasm (better prognosis); Temporal bone SCC: Negative, cytoplasm-only or cyto-nuclear; Salivary glands: Pleomorphic adenoma (cyto-nuclear or cytoplasmic only), Warthin's tumor (cyto-nuclear or cytoplasmic only, weaker than in pleomorphic adenoma), adenoid cystic carcinoma, mucoepidermoid carcinoma (cytoplasmic only, negative in an anaplastic variant of adenoid cystic carcinoma); Laryngeal SCC: Cytoplasm and nucleus
Thyroid	Negative	Negative follicular adenoma, follicular carcinomas, poorly and undifferentiated carcinomas; Cytoplasm: Papillary thyroid carcinoma
Skin	Cytoplasmic: Normal epidermis; Nuclear: Myoepithelial cells of the sweat glands and mature sebaceous glands	SCC: Cytoplasm expression in low stages and nuclear staining in dedifferentiated tumors; Basal cell carcinoma: Cytoplasm and nucleus; Melanoma: Nuclear expression is an indicator of aggressiveness
Soft tissue	Negative	Inflammation: Negative; Lipoma, atypical lipomatous tumor: Cytoplasm; Sarcomas: Cytoplasm or nucleus, as indicators of aggressive behavior

SCC: Squamous cell carcinoma.

expression was correlated with p53 positivity and a higher tumor grade and stage[39,40] (Table 1).

Positive immunostaining was noted in tumors that showed a histological response to therapy administered before prostatectomy[39,40]. Maspin also proved its ability to enhance the sensitivity of hormone-resistant prostate cancer cells to curcumin treatment by modulating levels of proapoptotic proteins Bad and Bax[42]. The experimental studies proved that maspin can influence prostate carcinoma host immune response through stimulation of neutrophil maturation at both the systemic and intratumoral levels along with antibody-dependent cytotoxicity and decreased lymphatic vessels formation[43].

Urinary bladder: In normal bladder, maspin expression can be seen in epithelial cells[44-47]. Maspin downregulation in bladder carcinoma cells has been shown to be significantly associated with a lower progression-free survival rate[44-46] (Table 1). Elevated levels inhibited proangiogenic factors such as insulin-like growth factor binding protein-2 or VEGF-C and upregulated the apoptosis rate of cancer cells[44-46]. Maspin increased the sensitivity of bladder cancer cells to cisplatin therapy by enhancing its inhibitory effect on tumor cell proliferation[44-46].

Induction of maspin was suggested to be the mechanism through which Prostate-derived E-twenty six factor (decreased in tumor cells compared with the normal bladder) inhibit tumor development and invasion along with repressing epithelial-mesenchymal transition by upregulating E-cadherin expression and downregulating vimentin, SNAIL, SLUG, and N-cadherin[47].

Studies of IHC expression observed contradictory results. In some studies, maspin was mostly positive in low-grade tumors and associated with better survival. Others showed an important increase in maspin expression in high-grade bladder tumors[8].

Lung

In normal bronchial cells, maspin expression can be seen in the nuclei of basal cells[48-52]. In non-small cell carcinomas, both SCC and adenocarcinomas, subcellular localization of maspin proved to be correlated with some clinicopathological parameters (Table 2).

Cytoplasmic expression was an independent negative prognostic indicator and was correlated with the micropapillary component, higher pTNM stage, shorter disease-free survival, and low disease-specific survival[48-51]. On the other hand, nuclear only staining (without synchronous cytoplasm positivity) was correlated with earlier

pathological stage, absence of aggressive invasion, and negative p53[48-51]. Maspin mRNA expression appeared to be upregulated in adenocarcinoma cells compared to the adjacent normal lung with higher levels of mRNA in advanced stages[52].

Gastrointestinal tract

Esophagus: Maspin can show infrequent cytoplasmic positivity in squamous cell epithelium[53-55] (Table 2). In SCC cells, downregulation of maspin was noted compared with the adjacent normal epithelium. Strong nuclear staining is associated with favorable prognosis, increased patient survival, and a lower pTN stage while high cytoplasmic staining correlates with the presence of lymph node metastases[53,54]. Based on an *in vitro* study, which used esophageal SCC cell lines, it was hypothesized that the inhibitory effect of maspin is based on switching the metabolic phenotype to low glycolysis through disrupting the hypoxia inducible factor 1α[55].

Stomach: Maspin expression can be absent or in the cytoplasm of normal epithelium and increases in gastric epithelial cells with intestinal metaplasia likely as a result of demethylation of the maspin gene promoter[56-62]. Nuclear maspin marks cells with high-grade intraepithelial neoplasia and is one of the factors that plays a role in the progression of intramucosal clusters of signet ring cells to signet ring cell carcinoma, especially multifocal carcinomas[57,58] (Table 2).

In gastric adenocarcinoma cells, maspin expression can be lost, which is an indication of a high risk for distant metastases[21,59]. Complete loss of maspin was also observed more frequently in elderly patients, poorly cohesive carcinomas, and poorly differentiated adenocarcinomas located in the distal part of the stomach[58-61]. Maspin is negative in neuroendocrine components of adenocarcinomas and is not involved in tumorigenesis of gastric neuroendocrine tumors[62].

Cytoplasm only staining is rarely seen in clinical practice in poorly cohesive carcinomas[58]. In adenocarcinomas, cytoplasm expression is as an indicator of lower pTNM stage and high angiogenic phenotype and correlates with positivity for p53, Bax, Ki-67 and E-cadherin[58].

Nuclear positivity (with or without associated cytoplasm expression) is predominant in undifferentiated intestinal type carcinoma and poorly cohesive carcinoma[58]. Nuclear positivity is associated with locally aggressive behavior and high risk for lymph node metastases and is more frequent in young patients[21,58,59,62]. It is associated with Bax, p53, and Ki-67 negativity and lower angiogenesis[58]. In daily practice, we use nuclear maspin for a better approach of the depth of invasion (pT stage) of poorly cohesive carcinomas (personal unpublished observations).

Colon and rectum: Similar to the gastric epithelium, in colorectal segments maspin expression can be absent or present in the cytoplasm of normal epithelium and increases in epithelial cells with high-grade dysplasia[62-73]. Maspin serum levels are increased in patients with high-grade dysplasia and carcinomas and might be used as an indicator for colonoscopy[69,70].

In colorectal segments, maspin does not mark neuroendocrine tumors[62], but its subcellular expression has a great value in the assessment of adenocarcinomas[72,73]. Although there are studies that proved that maspin expression is correlated with carcinoembryonic antigen serum levels, infiltrative borders, and high histological grade and stage in colorectal adenocarcinomas[65], few articles regard maspin subcellular expression. We use this marker for daily diagnosis and data showed in this review are based on personal observations (over 200 cases were revised) and literature data (Table 2).

Maspin cytoplasmic only positivity is correlated with the absence or a low number of lymph node metastases, low-grade buddings, and absence of p53 positivity[72,73]. It is important to consider a case with cytoplasmic only staining is necessary to have no nuclear positivity (in both tumor center and invasion front).

Maspin nuclear staining is an indicator of aggressive tumor behavior, high tumor grade, high budding grade, high pTNM stage, high risk of local recurrence, or lymph node metastases and absence of peritumoral lymphoid reaction and p53 and VEGF-A positivity[63,64,72,73]. As the maspin nuclear expression is characteristic for tumor buds[73], we use this marker to diagnose patients because maspin is more efficient than cytokeratins (personal observations). For stage II and III colon cancer patients, nuclear maspin staining is an independent predictor of sensitivity for adjuvant chemotherapy with 5-fluorouracil and levamisole[67,68,74].

Although it was postulated that elevated nuclear maspin is associated with microsatellite instability[63], we observed that it is associated with low microsatellite instability. The high microsatellite instability (MSI-H) cases usually show cytoplasmic or mixed (cyto-nuclear) maspin positivity[72]. In a few cases, nuclear predominance can be seen in MSI-H cases, but this pattern is observed in p53 negative carcinomas

only[74]. It was even suggested that MSI-H carcinomas with nuclear maspin might respond to 5-fluorouracil-based therapy[74]. For patients who received preoperative neoadjuvant chemoradiotherapy, maspin should be downregulated as a result of chemotherapeutic influence[66].

Combining the microsatellite status with BRAF mutation and IHC expression of p53 and maspin, a classification of colorectal cancer was proposed with the best prognosis attributed to MSI-H/BRAF mutated/p53 negative cases with a high number of tumor infiltrating lymphocytes and cytoplasmic maspin expression[71]. Cases with the worst prognosis were described as those being MSS/BRAF mutated/p53 positive with low tumor infiltrating lymphocytes and nuclear maspin staining predominance[71]. Similar to gastric carcinomas, loss of maspin expression is an indicator of a neuroendocrine component or high risk for distant metastases[72].

Hepatic and pancreatic system

Liver and intrahepatic bile ducts: Maspin infrequently marks hepatocytes and biliary epithelium[75-78]. It is downregulated in hepatocellular carcinoma cells (Table 2), but the exact mechanism is still unknown. Maspin downregulation can be the result of activation of inhibitor κB kinase α by HBx protein and can induce chemoresistance[75]. Decreased maspin expression along with increased VEGF-A expression may be induced by overexpression of chloride intracellular channel 1[76]. Yang *et al*[77] identified a correlation between patients with a C allele polymorphism of maspin rs2289520 and high Child-Pugh grade (B/C)[77].

In intrahepatic cholangiocarcinomas, a delayed progression was shown to be the benefit of maspin and Bax coexpression[78].

Pancreas: Normal pancreatic ducts, Langerhans islets, endocrine tumors, and low-grade lesions of the pancreas do not express maspin[79-82]. Maspin is localized in the cytoplasm and nucleus of the premalignant lesions such as pancreatic intraepithelial neoplasia (PanIN) grade 3 and also in pancreatic ductal adenocarcinoma (with/without cystic changes; with/without mucinous component) (Table 2) along with strong expression of carcinoembryonic antigen and p53[79-82].

In chronic pancreatitis, which causes diagnostic problems, the presence of an unmethylated maspin promoter can be used to differentiate this lesion from pancreatic ductal adenocarcinoma (PDAC)[83]. In a recent meta-analysis, maspin and trefoil factor 1 were found to display significantly higher blood plasma levels in PDAC compared to normal tissue[84]. Overexpression of maspin was confirmed by RT-PCR in PDAC and normal adjacent pancreatic tissue[85].

Gallbladder: Although maspin is mostly negative in normal epithelium, it might be helpful for differentiating a malignant tumor from atypical reactive changes of the bile ducts (Table 2) in combination with p53[86-91]. Maspin shows gradually increasing cyto-nuclear expression from regenerative atypia to biliary intraepithelial neoplasia with significant upregulation in carcinomas[86]. The stepwise rise in maspin level from normal epithelium to gallbladder carcinoma is also reflected in its mRNA level[87].

For bile duct biopsy specimens, the use of an immunomarkers complex was also proposed consisting of maspin, insulin-like growth factor-II mRNA binding protein-3, S100P, and von Hippel-Lindau gene product. Positive reactions for maspin, S100P, insulin-like growth factor-II mRNA binding protein-3 along with negativity for von Hippel-Lindau gene product was suggested as a specific staining pattern for bile duct adenocarcinoma[88,89]. Double IHC expressions for maspin (nuclear and cytoplasmic) and claudin-18 (membrane) may improve the diagnostic sensitivity to differentiate a bile duct carcinoma from a ductal adenocarcinoma[90]. This combination was also proposed for distinguishing biliary intraepithelial neoplasia from non-neoplastic changes[91].

Brain

Normal brain tissue strongly expresses maspin in the cytoplasm and nucleus and is downregulated in parallel with increasing glioma grade (Table 3) possibly by maspin promoter methylation[92,93].

Head and neck

Maspin expression is observed in the cytoplasm or nuclei of salivary glands (myoepithelial cells) and also in oral cavity epithelium[94-105] (Table 3). Maspin mRNA was identified in the corneal layers and stroma where it may exert adhesion regulatory functions between the cells and matrix molecules and where it may play a role in wound healing through regulation of the activated fibroblasts migration[105]. In inflammation, maspin was hypothesized to be an indicator of invasive fungal rhinosinusitis. It was downregulated in comparison with the noninvasive type and

with chronic rhinosinusitis for both cyto-plasm and nucleus[104]. Nuclear reaction and a higher intensity of maspin staining were associated with benign lesions of the salivary glands[102,103].

No significant differences in maspin expression were discovered between recurrent and nonrecurrent ameloblastoma and/or ameloblastic carcinoma[94]. After studying the maspin gene in a large number of participants, it was found that heterozygous T-C of rs17071138 polymorphism and G-G homozygotes or heterozygotes of rs2289520 increase the susceptibility to oral cancer development[95,96]. IHC-based studies on SCC of the oral cavity and tongue emphasized an association between high maspin expression and better overall survival, while the absence of maspin was correlated with high pT stage and presence of lymph node metastases[97-99].

In the temporal bone SCC cases, cytoplasmic subcellular localization of maspin expression was significantly higher in the recurrence-free group, thus representing a potential prognostic marker[100]. For laryngeal SCC, a separate evaluation of cytoplasmic and nuclear immunostaining has led to an association of the nuclear positivity with a longer disease-free interval after surgery[101].

Thyroid: Maspin is one of the six gene panel proposed for distinguishing normal thyroid from papillary thyroid carcinoma, along with TIMP3, RARB2, RASSF1, TPO, and TSHR[106]. In a study by Boltze *et al*[107], positive maspin immunoreaction (cytoplasm and nucleus) was observed in papillary thyroid carcinomas, while the normal thyroid tissue, follicular adenomas, follicular carcinomas, and poorly and undifferentiated carcinomas were negative (Table 3). The study also presented maspin promoter methylation as a factor of the silencing mechanism of the dedifferentiation degree[107].

Skin and soft tissues

Skin: Normal epidermis and sweat or sebaceous glands are maspin positive[108-111]. In SCCs, translocation of maspin immunoexpression from the cytoplasm to the nucleus in the front of invasion was seen as an indicator of tumor dedifferentiation[108,111] (Table 3). All well-differentiated tumors and all cases diagnosed in pT1 stage presented cytoplasmic maspin expression only[108].

The PCR-related studies showed maspin downregulation in tumor tissues compared with the normal adjacent cutis showing the potential role of maspin in tumor development inhibition[109]. Basal cell carcinoma cells variably express maspin at the cytoplasm and nucleus in the center of the nodules especially in nodular basal cell carcinoma[110]. Although infrequently observed, nuclear maspin can be seen in Merkel carcinoma cells, especially in sun-exposed areas[111]. A sun-activated maspin-induced DNA damage was hypothesized[111].

In melanoma cases, a significant association of nuclear maspin staining with aggressive tumor behavior and shorter disease-free survival was shown, while cytoplasmic predominance was present in superficial spreading melanoma[111,112]. High maspin intensity in the invasive margins of primary melanomas was correlated with an unfavorable prognosis[113].

Soft tissues and joints: Although it can act as a proangiogenic marker, maspin expression is negative in soft tissue structures and does not mediate osteoarthritis[114]. For malignant soft tissue tumors, cytoplasmic expression of maspin was correlated with higher histological grade and risk for distant metastasis[115]. In liposarcomas, maspin and VEGF-A seem to be angiogenic promoters[116]. Negative staining was observed for most soft tissue tumors such as granular cell (Abrikossoff) tumor[117], but also for other mesenchymal tumors such as gastrointestinal stromal tumors[118].

CONCLUSION

Although several studies tried to elucidate parts of the molecular journey in which maspin influences the transformation of epithelial cells and tumor behavior, the maspin-related processes are yet to be elucidated. Experimental studies are needed before chemical synthesis of a maspin-based agent can begin. Despite several unknown areas of the effects of maspin, several aspects have been confirmed by us and others. These aspects include: maspin is a good marker of budding quantification in colorectal carcinomas; it can be used for identification of intragastric mucosa signet ring cells (in biopsic specimens) or a proper evaluation of poorly cohesive gastric carcinoma invasion; and it is a useful marker for differential diagnosis of PanIN from a ductal adenocarcinoma of pancreas. The other aspects should be elucidated by further studies.

REFERENCES

1 **Zou Z**, Anisowicz A, Hendrix MJ, Thor A, Neveu M, Sheng S, Rafidi K, Seftor E, Sager R. Maspin, a serpin with tumor-suppressing activity in human mammary epithelial cells. *Science* 1994; **263**: 526-529 [PMID: 8290962 DOI: 10.1126/science.8290962]

2 **Sheng S**, Carey J, Seftor EA, Dias L, Hendrix MJ, Sager R. Maspin acts at the cell membrane to inhibit invasion and motility of mammary and prostatic cancer cells. *Proc Natl Acad Sci USA* 1996; **93**: 11669-11674 [PMID: 8876194 DOI: 10.1073/pnas.93.21.11669]

3 **Bodenstine TM**, Seftor RE, Khalkhali-Ellis Z, Seftor EA, Pemberton PA, Hendrix MJ. Maspin: molecular mechanisms and therapeutic implications. *Cancer Metastasis Rev* 2012; **31**: 529-551 [PMID: 22752408 DOI: 10.1007/s10555-012-9361-0]

4 **Latha K**, Zhang W, Cella N, Shi HY, Zhang M. Maspin mediates increased tumor cell apoptosis upon induction of the mitochondrial permeability transition. *Mol Cell Biol* 2005; **25**: 1737-1748 [PMID: 15713631 DOI: 10.1128/MCB.25.5.1737-1748.2005]

5 **Zou Z**, Gao C, Nagaich AK, Connell T, Saito S, Moul JW, Seth P, Appella E, Srivastava S. p53 regulates the expression of the tumor suppressor gene maspin. *J Biol Chem* 2000; **275**: 6051-6054 [PMID: 10692390 DOI: 10.1074/jbc.275.9.6051]

6 **Wang Y**, Sun L, Song Z, Wang D, Bao Y, Li Y. Maspin inhibits macrophage phagocytosis and enhances inflammatory cytokine production via activation of NF-κB signaling. *Mol Immunol* 2017; **82**: 94-103 [PMID: 28064070 DOI: 10.1016/j.molimm.2016.12.021]

7 **Dean I**, Dzinic SH, Bernardo MM, Zou Y, Kimler V, Li X, Kaplun A, Granneman J, Mao G, Sheng S. The secretion and biological function of tumor suppressor maspin as an exosome cargo protein. *Oncotarget* 2017; **8**: 8043-8056 [PMID: 28009978 DOI: 10.18632/oncotarget.13302]

8 **Berardi R**, Morgese F, Onofri A, Mazzanti P, Pistelli M, Ballatore Z, Savini A, De Lisa M, Caramanti M, Rinaldi S, Pagliaretta S, Santoni M, Pierantoni C, Cascinu S. Role of maspin in cancer. *Clin Transl Med* 2013; **2**: 8 [PMID: 23497644 DOI: 10.1186/2001-1326-2-8]

9 **Dokras A**, Gardner LM, Kirschmann DA, Seftor EA, Hendrix MJ. The tumour suppressor gene maspin is differentially regulated in cytotrophoblasts during human placental development. *Placenta* 2002; **23**: 274-280 [PMID: 11969337 DOI: 10.1053/plac.2001.0784]

10 **Liu Q**, Qiao FY, Shi XW, Liu HY, Gong X, Wu YY. Promoter hypomethylation and increased maspin expression in preeclamptic placentas in a Chinese population. *Placenta* 2014; **35**: 876-882 [PMID: 25151033 DOI: 10.1016/j.placenta.2014.08.088]

11 **Qi YH**, Teng F, Zhou Q, Liu YX, Wu JF, Yu SS, Zhang X, Ma MY, Zhou N, Chen LJ. Unmethylated-maspin DNA in maternal plasma is associated with severe preeclampsia. *Acta Obstet Gynecol Scand* 2015; **94**: 983-988 [PMID: 26095742 DOI: 10.1111/aogs.12691]

12 **Lee DE**, Kim SY, Lim JH, Park SY, Ryu HM. Non-invasive prenatal testing of trisomy 18 by an epigenetic marker in first trimester maternal plasma. *PLoS One* 2013; **8**: e78136 [PMID: 24223769 DOI: 10.1371/journal.pone.0078136]

13 **Shi X**, Liu Q, Liu H, Deng D, Qiao F, Wu Y. Effects of shRNA Targeting Maspin on the Invasion of Extravillous Trophoblast Cell. *Am J Perinatol* 2017; **34**: 966-973 [PMID: 28376551 DOI: 10.1055/s-0037-1601458]

14 **Taglauer ES**, Gundogan F, Johnson KL, Scherjon SA, Bianchi DW. Chorionic plate expression patterns of the maspin tumor suppressor protein in preeclamptic and egg donor placentas. *Placenta* 2013; **34**: 385-387 [PMID: 23410722 DOI: 10.1016/j.placenta.2013.01.008]

15 **Umekita Y**, Ohi Y, Sagara Y, Yoshida H. Expression of maspin predicts poor prognosis in breast-cancer patients. *Int J Cancer* 2002; **100**: 452-455 [PMID: 12115529 DOI: 10.1002/ijc.10500]

16 **Umekita Y**, Ohi Y, Souda M, Rai Y, Sagara Y, Sagara Y, Tamada S, Tanimoto A. Maspin expression is frequent and correlates with basal markers in triple-negative breast cancer. *Diagn Pathol* 2011; **6**: 36 [PMID: 21496280 DOI: 10.1186/1746-1596-6-36]

17 **Lee MJ**, Suh CH, Li ZH. Clinicopathological significance of maspin expression in breast cancer. *J Korean Med Sci* 2006; **21**: 309-314 [PMID: 16614520 DOI: 10.3346/jkms.2006.21.2.309]

18 **Kim DH**, Yoon DS, Dooley WC, Nam ES, Ryu JW, Jung KC, Park HR, Sohn JH, Shin HS, Park YE. Association of maspin expression with the high histological grade and lymphocyte-rich stroma in early-stage breast cancer. *Histopathology* 2003; **42**: 37-42 [PMID: 12493023 DOI: 10.1046/j.1365-2559.2003.01567.x]

19 **Mohsin SK**, Zhang M, Clark GM, Craig Allred D. Maspin expression in invasive breast cancer: association with other prognostic factors. *J Pathol* 2003; **199**: 432-435 [PMID: 12635133 DOI: 10.1002/path.1319]

20 **Tamazato Longhi M**, Magalhães M, Reina J, Morais Freitas V, Cella N. EGFR Signaling Regulates Maspin/SerpinB5 Phosphorylation and Nuclear Localization in Mammary Epithelial Cells. *PLoS One* 2016; **11**: e0159856 [PMID: 27447178 DOI: 10.1371/journal.pone.0159856]

21 **Gurzu S**, Banias L, Bara T, Feher I, Bara T, Jung I. The Epithelial-Mesenchymal Transition Pathway in Two Cases with Gastric Metastasis Originating from Breast Carcinoma, One with a Metachronous Primary Gastric Cancer. *Recent Pat Anticancer Drug Discov* 2018; **13**: 118-124 [PMID: 29090670 DOI: 10.2174/2212798409666171101121108]

22 **Machowska M**, Wachowicz K, Sopel M, Rzepecki R. Nuclear location of tumor suppressor protein maspin inhibits proliferation of breast cancer cells without affecting proliferation of normal epithelial cells. *BMC Cancer* 2014; **14**: 142 [PMID: 24581141 DOI: 10.1186/1471-2407-14-142]

23 **Strien L**, Joensuu K, Heikkilä P, Leidenius MH. Different Expression Patterns of CXCR4, CCR7, Maspin and FOXP3 in Luminal Breast Cancers and Their Sentinel Node Metastases. *Anticancer Res* 2017; **37**: 175-182 [PMID: 28011488 DOI: 10.21873/anticanres.11303]

24 **Wakahara M**, Sakabe T, Kubouchi Y, Hosoya K, Hirooka Y, Yurugi Y, Nosaka K, Shiomi T, Nakamura H, Umekita Y. Subcellular Localization of Maspin Correlates with Histone Deacetylase 1 Expression in Human Breast Cancer. *Anticancer Res* 2017; **37**: 5071-5077 [PMID: 28870936 DOI: 10.21873/anticanres.11924]

25 **Umekita Y**, Ohi Y, Iwaya O, Souda M, Sagara Y, Tamada S, Yotsumoto D, Tanimoto A. Maspin mRNA expression in sentinel lymph nodes predicts non-SLN metastasis in breast cancer patients with SLN metastasis. *Histopathology* 2018; **73**: 916-922 [PMID: 30035819 DOI: 10.1111/his.13718]

26 **Triulzi T**, Ratti M, Tortoreto M, Ghirelli C, Aiello P, Regondi V, Di Modica M, Cominetti D, Carcangiu ML, Moliterni A, Balsari A, Casalini P, Tagliabue E. Maspin influences response to doxorubicin by changing the tumor microenvironment organization. *Int J Cancer* 2014; **134**: 2789-2797 [PMID: 24242003

DOI: 10.1002/ijc.28608]
27 **Sood AK**, Fletcher MS, Gruman LM, Coffin JE, Jabbari S, Khalkhali-Ellis Z, Arbour N, Seftor EA, Hendrix MJ. The paradoxical expression of maspin in ovarian carcinoma. *Clin Cancer Res* 2002; **8**: 2924-2932 [PMID: 12231537 DOI: 10.1159/000063870]
28 **Bolat F**, Gumurdulu D, Erkanli S, Kayaselcuk F, Zeren H, Ali Vardar M, Kuscu E. Maspin overexpression correlates with increased expression of vascular endothelial growth factors A, C, and D in human ovarian carcinoma. *Pathol Res Pract* 2008; **204**: 379-387 [PMID: 18343598 DOI: 10.1016/j.prp.2008.01.011]
29 **Abd El-Wahed MM**. Expression and subcellular localization of maspin in human ovarian epithelial neoplasms: correlation with clinicopathologic features. *J Egypt Natl Canc Inst* 2005; **17**: 173-183 [PMID: 16799655]
30 **Surowiak P**, Materna V, Drag-Zalesinska M, Wojnar A, Kaplenko I, Spaczyński M, Dietel M, Zabel M, Lage H. Maspin expression is characteristic for cisplatin-sensitive ovarian cancer cells and for ovarian cancer cases of longer survival rates. *Int J Gynecol Pathol* 2006; **25**: 131-139 [PMID: 16633061 DOI: 10.1097/01.pgp.0000183050.30212.2f]
31 **Xu C**, Quddus MR, Sung CJ, Steinhoff MM, Zhang C, Lawrence WD. Maspin expression in CIN 3, microinvasive squamous cell carcinoma, and invasive squamous cell carcinoma of the uterine cervix. *Mod Pathol* 2005; **18**: 1102-1106 [PMID: 15731774 DOI: 10.1038/modpathol.3800393]
32 **Liu Z**, Shi Y, Meng W, Liu Y, Yang K, Wu S, Peng Z. Expression and localization of maspin in cervical cancer and its role in tumor progression and lymphangiogenesis. *Arch Gynecol Obstet* 2014; **289**: 373-382 [PMID: 23959090 DOI: 10.1007/s00404-013-2988-4]
33 **Yeom SY**, Jang HL, Lee SJ, Kim E, Son HJ, Kim BG, Park C. Interaction of testisin with maspin and its impact on invasion and cell death resistance of cervical cancer cells. *FEBS Lett* 2010; **584**: 1469-1475 [PMID: 20211623 DOI: 10.1016/j.febslet.2010.02.072]
34 **Nosaka K**, Horie Y, Shiomi T, Itamochi H, Oishi T, Shimada M, Sato S, Sakabe T, Harada T, Umekita Y. Cytoplasmic Maspin Expression Correlates with Poor Prognosis of Patients with Adenocarcinoma of the Uterine Cervix. *Yonago Acta Med* 2015; **58**: 151-156 [PMID: 26740733]
35 **Blandamura S**, Alessandrini L, Saccardi C, Giacomelli L, Fabris A, Borghero A, Litta P. Maspin expression, subcellular localization and clinicopathological correlation in endometrial hyperplasia and endometrial adenocarcinoma. *Histol Histopathol* 2014; **29**: 777-783 [PMID: 24346847 DOI: 10.14670/HH-29.777]
36 **Li HW**, Leung SW, Chan CS, Yu MM, Wong YF. Expression of maspin in endometrioid adenocarcinoma of endometrium. *Oncol Rep* 2007; **17**: 393-398 [PMID: 17203179 DOI: 10.3892/or.17.2.393]
37 **Tsuji T**, Umekita Y, Ohi Y, Kamio M, Douchi T, Yoshida H. Maspin expression is up-regulated during the progression of endometrioid endometrial carcinoma. *Histopathology* 2007; **51**: 871-874 [PMID: 18042077 DOI: 10.1111/j.1365-2559.2007.02872.x]
38 **Murai S**, Maesawa C, Masuda T, Sugiyama T. Aberrant maspin expression in human endometrial cancer. *Cancer Sci* 2006; **97**: 883-888 [PMID: 16822296 DOI: 10.1111/j.1349-7006.2006.00266.x]
39 **Machtens S**, Serth J, Bokemeyer C, Bathke W, Minssen A, Kollmannsberger C, Hartmann J, Knüchel R, Kondo M, Jonas U, Kuczyk M. Expression of the p53 and Maspin protein in primary prostate cancer: correlation with clinical features. *Int J Cancer* 2001; **95**: 337-342 [PMID: 11494236 DOI: 10.1002/1097-0215(20010920)95:5<337::aid-ijc1059>3.0.co;2-1]
40 **Zou Z**, Zhang W, Young D, Gleave MG, Rennie P, Connell T, Connelly R, Moul J, Srivastava S, Sesterhenn I. Maspin expression profile in human prostate cancer (CaP) and in vitro induction of Maspin expression by androgen ablation. *Clin Cancer Res* 2002; **8**: 1172-1177 [PMID: 12006534 DOI: 10.1159/000057670]
41 **Pierson CR**, McGowen R, Grignon D, Sakr W, Dey J, Sheng S. Maspin is up-regulated in premalignant prostate epithelia. *Prostate* 2002; **53**: 255-262 [PMID: 12430137 DOI: 10.1002/pros.10107]
42 **Cheng WL**, Huang CY, Tai CJ, Chang YJ, Hung CS. Maspin Enhances the Anticancer Activity of Curcumin in Hormone-refractory Prostate Cancer Cells. *Anticancer Res* 2018; **38**: 863-870 [PMID: 29374713 DOI: 10.21873/anticanres.12295]
43 **Dzinic SH**, Chen K, Thakur A, Kaplun A, Bonfil RD, Li X, Liu J, Bernardo MM, Saliganan A, Back JB, Yano H, Schalk DL, Tomaszewski EN, Beydoun AS, Dyson G, Mujagic A, Krass D, Dean I, Mi QS, Heath E, Sakr W, Lum LG, Sheng S. Maspin expression in prostate tumor elicits host anti-tumor immunity. *Oncotarget* 2014; **5**: 11225-11236 [PMID: 25373490 DOI: 10.18632/oncotarget.2615]
44 **Chen J**, Wang L, Tang Y, Gong G, Liu L, Chen M, Chen Z, Cui Y, Li C, Cheng X, Qi L, Zu X. Maspin enhances cisplatin chemosensitivity in bladder cancer T24 and 5637 cells and correlates with prognosis of muscle-invasive bladder cancer patients receiving cisplatin based neoadjuvant chemotherapy. *J Exp Clin Cancer Res* 2016; **35**: 2 [PMID: 26733306 DOI: 10.1186/s13046-015-0282-y]
45 **Zhu H**, Yun F, Shi X, Wang D. Inhibition of IGFBP-2 improves the sensitivity of bladder cancer cells to cisplatin via upregulating the expression of maspin. *Int J Mol Med* 2015; **36**: 595-601 [PMID: 26080829 DOI: 10.3892/ijmm.2015.2250]
46 **Zhu H**, Yun F, Shi X, Wang D. VEGF-C inhibition reverses resistance of bladder cancer cells to cisplatin via upregulating maspin. *Mol Med Rep* 2015; **12**: 3163-3169 [PMID: 25936422 DOI: 10.3892/mmr.2015.3684]
47 **Tsui KH**, Lin YH, Chung LC, Chuang ST, Feng TH, Chiang KC, Chang PL, Yeh CJ, Juang HH. Prostate-derived ets factor represses tumorigenesis and modulates epithelial-to-mesenchymal transition in bladder carcinoma cells. *Cancer Lett* 2016; **375**: 142-151 [PMID: 26965996 DOI: 10.1016/j.canlet.2016.02.056]
48 **Lonardo F**, Li X, Siddiq F, Singh R, Al-Abbadi M, Pass HI, Sheng S. Maspin nuclear localization is linked to favorable morphological features in pulmonary adenocarcinoma. *Lung Cancer* 2006; **51**: 31-39 [PMID: 16159682 DOI: 10.1016/j.lungcan.2005.07.011]
49 **Matsuoka Y**, Takagi Y, Nosaka K, Sakabe T, Haruki T, Araki K, Taniguchi Y, Shiomi T, Nakamura H, Umekita Y. Cytoplasmic expression of maspin predicts unfavourable prognosis in patients with squamous cell carcinoma of the lung. *Histopathology* 2016; **69**: 114-120 [PMID: 27297724 DOI: 10.1111/his.12921]
50 **Takagi Y**, Matsuoka Y, Shiomi T, Nosaka K, Takeda C, Haruki T, Araki K, Taniguchi Y, Nakamura H, Umekita Y. Cytoplasmic maspin expression is a predictor of poor prognosis in patients with lung adenocarcinoma measuring < 3 cm. *Histopathology* 2015; **66**: 732-739 [PMID: 25322663 DOI: 10.1111/his.12586]
51 **Ohno T**, Kubouchi Y, Wakahara M, Nosaka K, Sakabe T, Haruki T, Miwa K, Taniguchi Y, Nakamura H, Umekita Y. Clinical Significance of Subcellular Localization of Maspin in Patients with Pathological Stage IA Lung Adenocarcinoma. *Anticancer Res* 2018; **38**: 3001-3007 [PMID: 29715131 DOI: 10.21873/anticanres.12553]

52 **Lu M**, Li J, Huang Z, Du Y, Jin S, Wang J. Aberrant Maspin mRNA Expression is Associated with Clinical Outcome in Patients with Pulmonary Adenocarcinoma. *Med Sci Monit* 2016; **22**: 134-139 [PMID: 26757744 DOI: 10.12659/MSM.894995]

53 **Meng H**, Guan X, Guo H, Xiong G, Yang K, Wang K, Bai Y. Association between SNPs in Serpin gene family and risk of esophageal squamous cell carcinoma. *Tumour Biol* 2015; **36**: 6231-6238 [PMID: 25775950 DOI: 10.1007/s13277-015-3308-3]

54 **Wang Y**, Sheng S, Zhang J, Dzinic S, Li S, Fang F, Wu N, Zheng Q, Yang Y. Elevated maspin expression is associated with better overall survival in esophageal squamous cell carcinoma (ESCC). *PLoS One* 2013; **8**: e63581 [PMID: 23717449 DOI: 10.1371/journal.pone.0063581]

55 **Cai Z**, Zhou Y, Lei T, Chiu JF, He QY. Mammary serine protease inhibitor inhibits epithelial growth factor-induced epithelial-mesenchymal transition of esophageal carcinoma cells. *Cancer* 2009; **115**: 36-48 [PMID: 19090015 DOI: 10.1002/cncr.23991]

56 **Akiyama Y**, Maesawa C, Ogasawara S, Terashima M, Masuda T. Cell-type-specific repression of the maspin gene is disrupted frequently by demethylation at the promoter region in gastric intestinal metaplasia and cancer cells. *Am J Pathol* 2003; **163**: 1911-1919 [PMID: 14578190 DOI: 10.1016/S0002-9440(10)63549-3]

57 **Gurzu S**, Jung I, Orlowska J, Sugimura H, Kadar Z, Turdean S, Bara T. Hereditary diffuse gastric cancer--An overview. *Pathol Res Pract* 2015; **211**: 629-632 [PMID: 26150395 DOI: 10.1016/j.prp.2015.06.003]

58 **Gurzu S**, Kadar Z, Sugimura H, Bara T, Bara T, Halmaciu I, Jung I. Gastric cancer in young vs old Romanian patients: immunoprofile with emphasis on maspin and mena protein reactivity. *APMIS* 2015; **123**: 223-233 [PMID: 25556597 DOI: 10.1111/apm.12347]

59 **Gurzu S**, Kadar Z, Sugimura H, Orlowska J, Bara T, Bara T, Szederjesi J, Jung I. Maspin-related Orchestration of Aggressiveness of Gastric Cancer. *Appl Immunohistochem Mol Morphol* 2016; **24**: 326-336 [PMID: 26067133 DOI: 10.1097/PAI.0000000000000189]

60 **Zheng HC**, Gong BC. The roles of maspin expression in gastric cancer: a meta- and bioinformatics analysis. *Oncotarget* 2017; **8**: 66476-66490 [PMID: 29029529 DOI: 10.18632/oncotarget.20192]

61 **Wang MC**, Yang YM, Li XH, Dong F, Li Y. Maspin expression and its clinicopathological significance in tumorigenesis and progression of gastric cancer. *World J Gastroenterol* 2004; **10**: 634-637 [PMID: 14991928 DOI: 10.3748/wjg.v10.i5.634]

62 **Gurzu S**, Kadar Z, Bara T, Bara T, Tamasi A, Azamfirei L, Jung I. Mixed adenoneuroendocrine carcinoma of gastrointestinal tract: report of two cases. *World J Gastroenterol* 2015; **21**: 1329-1333 [PMID: 25632209 DOI: 10.3748/wjg.v21.i4.1329]

63 **Bettstetter M**, Woenckhaus M, Wild PJ, Rümmele P, Blaszyk H, Hartmann A, Hofstädter F, Dietmaier W. Elevated nuclear maspin expression is associated with microsatellite instability and high tumour grade in colorectal cancer. *J Pathol* 2005; **205**: 606-614 [PMID: 15714592 DOI: 10.1002/path.1732]

64 **Kim JH**, Cho NY, Bae JM, Kim KJ, Rhee YY, Lee HS, Kang GH. Nuclear maspin expression correlates with the CpG island methylator phenotype and tumor aggressiveness in colorectal cancer. *Int J Clin Exp Pathol* 2015; **8**: 1920-1928 [PMID: 25973084]

65 **Baek JY**, Yeo HY, Chang HJ, Kim KH, Kim SY, Park JW, Park SC, Choi HS, Kim DY, Oh JH. Serpin B5 is a CEA-interacting biomarker for colorectal cancer. *Int J Cancer* 2014; **134**: 1595-1604 [PMID: 24114705 DOI: 10.1002/ijc.28494]

66 **Chang IW**, Liu KW, Ragunanan M, He HL, Shiue YL, Yu SC. SERPINB5 Expression: Association with CCRT Response and Prognostic Value in Rectal Cancer. *Int J Med Sci* 2018; **15**: 376-384 [PMID: 29511373 DOI: 10.7150/ijms.22823]

67 **Hestetun KE**, Brydøy M, Myklebust MP, Dahl O. Nuclear maspin expression as a predictive marker for fluorouracil treatment response in colon cancer. *Acta Oncol* 2015; **54**: 470-479 [PMID: 25227897 DOI: 10.3109/0284186X.2014.952386]

68 **Dietmaier W**, Bettstetter M, Wild PJ, Woenckhaus M, Rümmele P, Hartmann A, Dechant S, Blaszyk H, Pauer A, Klinkhammer-Schalke M, Hofstädter F. Nuclear Maspin expression is associated with response to adjuvant 5-fluorouracil based chemotherapy in patients with stage III colon cancer. *Int J Cancer* 2006; **118**: 2247-2254 [PMID: 16331619 DOI: 10.1002/ijc.21620]

69 **Findeisen P**, Röckel M, Nees M, Röder C, Kienle P, Von Knebel Doeberitz M, Kalthoff H, Neumaier M. Systematic identification and validation of candidate genes for detection of circulating tumor cells in peripheral blood specimens of colorectal cancer patients. *Int J Oncol* 2008; **33**: 1001-1010 [PMID: 18949363]

70 **Uzozie AC**, Selevsek N, Wahlander A, Nanni P, Grossmann J, Weber A, Buffoli F, Marra G. Targeted Proteomics for Multiplexed Verification of Markers of Colorectal Tumorigenesis. *Mol Cell Proteomics* 2017; **16**: 407-427 [PMID: 28062797 DOI: 10.1074/mcp.M116.062273]

71 **Gurzu S**, Szentirmay Z, Jung I. Molecular classification of colorectal cancer: a dream that can become a reality. *Rom J Morphol Embryol* 2013; **54**: 241-245 [PMID: 23771065 DOI: 10.1159/000350687]

72 **Gurzu S**, Szentirmay Z, Popa D, Jung I. Practical value of the new system for Maspin assessment, in colorectal cancer. *Neoplasma* 2013; **60**: 373-383 [PMID: 23581409 DOI: 10.4149/neo_2013_049]

73 **Banias L**, Gurzu S, Kovacs Z, Bara T, Bara T, Jung I. Nuclear maspin expression: A biomarker for budding assessment in colorectal cancer specimens. *Pathol Res Pract* 2017; **213**: 1227-1230 [PMID: 28780084 DOI: 10.1016/j.prp.2017.07.025]

74 **Gurzu S**, Szentirmay Z, Toth E, Jung I. Possible predictive value of maspin expression in colorectal cancer. *Recent Pat Anticancer Drug Discov* 2013; **8**: 183-190 [PMID: 22963136 DOI: 10.2174/1574892811308020006]

75 **Chen WS**, Liu LC, Yen CJ, Chen YJ, Chen JY, Ho CY, Liu SH, Chen CC, Huang WC. Nuclear IKKα mediates microRNA-7/-103/107/21 inductions to downregulate maspin expression in response to HBx overexpression. *Oncotarget* 2016; **7**: 56309-56323 [PMID: 27409165 DOI: 10.18632/oncotarget.10462]

76 **Wei X**, Li J, Xie H, Wang H, Wang J, Zhang X, Zhuang R, Lu D, Ling Q, Zhou L, Xu X, Zheng S. Chloride intracellular channel 1 participates in migration and invasion of hepatocellular carcinoma by targeting maspin. *J Gastroenterol Hepatol* 2015; **30**: 208-216 [PMID: 24989236 DOI: 10.1111/jgh.12668]

77 **Yang SF**, Yeh CB, Chou YE, Lee HL, Liu YF. Serpin peptidase inhibitor (SERPINB5) haplotypes are associated with susceptibility to hepatocellular carcinoma. *Sci Rep* 2016; **6**: 26605 [PMID: 27221742 DOI: 10.1038/srep26605]

78 **Romani AA**, Soliani P, Desenzani S, Borghetti AF, Crafa P. The associated expression of Maspin and Bax proteins as a potential prognostic factor in intrahepatic cholangiocarcinoma. *BMC Cancer* 2006; **6**: 255 [PMID: 17067385 DOI: 10.1186/1471-2407-6-255]

79 **Furuhata A**, Minamiguchi S, Shirahase H, Kodama Y, Adachi S, Sakurai T, Haga H.

Immunohistochemical Antibody Panel for the Differential Diagnosis of Pancreatic Ductal Carcinoma From Gastrointestinal Contamination and Benign Pancreatic Duct Epithelium in Endoscopic Ultrasound-Guided Fine-Needle Aspiration. *Pancreas* 2017; **46**: 531-538 [PMID: 28099249 DOI: 10.1097/MPA.0000000000000774]

80 **Nitta T**, Mitsuhashi T, Hatanaka Y, Hirano S, Matsuno Y. Pancreatic ductal adenocarcinomas with multiple large cystic structures: a clinicopathologic and immunohistochemical study of seven cases. *Pancreatology* 2013; **13**: 401-408 [PMID: 23890139 DOI: 10.1016/j.pan.2013.05.004]

81 **Ohike N**, Maass N, Mundhenke C, Biallek M, Zhang M, Jonat W, Lüttges J, Morohoshi T, Klöppel G, Nagasaki K. Clinicopathological significance and molecular regulation of maspin expression in ductal adenocarcinoma of the pancreas. *Cancer Lett* 2003; **199**: 193-200 [PMID: 12969792 DOI: 10.1016/S0304-3835(03)00390-2]

82 **Gurzu S**, Bara T, Molnar C, Bara T, Butiurca V, Beres H, Savoji S, Jung I. The epithelial-mesenchymal transition induces aggressivity of mucinous cystic neoplasm of the pancreas with neuroendocrine component: An immunohistochemistry study. *Pathol Res Pract* 2019; **215**: 82-89 [PMID: 30391209 DOI: 10.1016/j.prp.2018.10.019]

83 **Mardin WA**, Ntalos D, Mees ST, Spieker T, Senninger N, Haier J, Dhayat SA. SERPINB5 Promoter Hypomethylation Differentiates Pancreatic Ductal Adenocarcinoma From Pancreatitis. *Pancreas* 2016; **45**: 743-747 [PMID: 26646275 DOI: 10.1097/MPA.0000000000000526]

84 **Klett H**, Fuellgraf H, Levit-Zerdoun E, Hussung S, Kowar S, Küsters S, Bronsert P, Werner M, Wittel U, Fritsch R, Busch H, Boerries M. Identification and Validation of a Diagnostic and Prognostic Multi-Gene Biomarker Panel for Pancreatic Ductal Adenocarcinoma. *Front Genet* 2018; **9**: 108 [PMID: 29675033 DOI: 10.3389/fgene.2018.00108]

85 **Mao Y**, Shen J, Lu Y, Lin K, Wang H, Li Y, Chang P, Walker MG, Li D. RNA sequencing analyses reveal novel differentially expressed genes and pathways in pancreatic cancer. *Oncotarget* 2017; **8**: 42537-42547 [PMID: 28418924 DOI: 10.18632/oncotarget.16451]

86 **Kanzawa M**, Sanuki T, Onodera M, Fujikura K, Itoh T, Zen Y. Double immunostaining for maspin and p53 on cell blocks increases the diagnostic value of biliary brushing cytology. *Pathol Int* 2017; **67**: 91-98 [PMID: 28074620 DOI: 10.1111/pin.12505]

87 **Baghel K**, Kazmi HR, Raj S, Chandra A, Srivastava RN. Elevated expression of maspin mRNA as a predictor of survival in stage II and III gallbladder cancer cases. *Asian Pac J Cancer Prev* 2014; **15**: 343-347 [PMID: 24528054 DOI: 10.7314/APJCP.2014.15.1.343]

88 **Shi J**, Liu H, Wang HL, Prichard JW, Lin F. Diagnostic utility of von Hippel-Lindau gene product, maspin, IMP3, and S100P in adenocarcinoma of the gallbladder. *Hum Pathol* 2013; **44**: 503-511 [PMID: 23079206 DOI: 10.1016/j.humpath.2012.06.010]

89 **Chen L**, Huang K, Himmelfarb EA, Zhai J, Lai JP, Lin F, Wang HL. Diagnostic value of maspin in distinguishing adenocarcinoma from benign biliary epithelium on endoscopic bile duct biopsy. *Hum Pathol* 2015; **46**: 1647-1654 [PMID: 26362203 DOI: 10.1016/j.humpath.2015.07.005]

90 **Tokumitsu T**, Sato Y, Yamashita A, Moriguchi-Goto S, Kondo K, Nanashima A, Asada Y. Immunocytochemistry for Claudin-18 and Maspin in biliary brushing cytology increases the accuracy of diagnosing pancreatobiliary malignancies. *Cytopathology* 2017; **28**: 116-121 [PMID: 27527114 DOI: 10.1111/cyt.12368]

91 **Keira Y**, Takasawa A, Murata M, Nojima M, Takasawa K, Ogino J, Higashiura Y, Sasaki A, Kimura Y, Mizuguchi T, Tanaka S, Hirata K, Sawada N, Hasegawa T. An immunohistochemical marker panel including claudin-18, maspin, and p53 improves diagnostic accuracy of bile duct neoplasms in surgical and presurgical biopsy specimens. *Virchows Arch* 2015; **466**: 265-277 [PMID: 25503275 DOI: 10.1007/s00428-014-1705-4]

92 **Ma S**, Pang C, Song L, Guo F, Sun H. Activating transcription factor 3 is overexpressed in human glioma and its knockdown in glioblastoma cells causes growth inhibition both in vitro and in vivo. *Int J Mol Med* 2015; **35**: 1561-1573 [PMID: 25872784 DOI: 10.3892/ijmm.2015.2173]

93 **Xu L**, Liu H, Yu J, Wang Z, Zhu Q, Li Z, Zhong Q, Zhang S, Qu M, Lan Q. Methylation-induced silencing of maspin contributes to the proliferation of human glioma cells. *Oncol Rep* 2016; **36**: 57-64 [PMID: 27177016 DOI: 10.3892/or.2016.4783]

94 **Safadi RA**, Quda BF, Hammad HM. Immunohistochemical expression of K6, K8, K16, K17, K19, maspin, syndecan-1 (CD138), α-SMA, and Ki-67 in ameloblastoma and ameloblastic carcinoma: diagnostic and prognostic correlations. *Oral Surg Oral Med Oral Pathol Oral Radiol* 2016; **121**: 402-411 [PMID: 26972539 DOI: 10.1016/j.oooo.2015.11.015]

95 **Yang PY**, Miao NF, Lin CW, Chou YE, Yang SF, Huang HC, Chang HJ, Tsai HT. Impact of Maspin Polymorphism rs2289520 G/C and Its Interaction with Gene to Gene, Alcohol Consumption Increase Susceptibility to Oral Cancer Occurrence. *PLoS One* 2016; **11**: e0160841 [PMID: 27525723 DOI: 10.1371/journal.pone.0160841]

96 **Tsai HT**, Hsieh MJ, Lin CW, Su SC, Miao NF, Yang SF, Huang HC, Lai FC, Liu YF. Combinations of SERPINB5 gene polymorphisms and environmental factors are associated with oral cancer risks. *PLoS One* 2017; **12**: e0163369 [PMID: 28339463 DOI: 10.1371/journal.pone.0163369]

97 **Xia W**, Lau YK, Hu MC, Li L, Johnston DA, Sheng Sj, El-Naggar A, Hung MC. High tumoral maspin expression is associated with improved survival of patients with oral squamous cell carcinoma. *Oncogene* 2000; **19**: 2398-2403 [PMID: 10828881 DOI: 10.1007/s11769-002-0015-y]

98 **Yasumatsu R**, Nakashima T, Hirakawa N, Kumamoto Y, Kuratomi Y, Tomita K, Komiyama S. Maspin expression in stage I and II oral tongue squamous cell carcinoma. *Head Neck* 2001; **23**: 962-966 [PMID: 11754500]

99 **Choi KY**, Choi HJ, Chung EJ, Lee DJ, Kim JH, Rho YS. Loss of heterozygosity in mammary serine protease inhibitor (maspin) and p53 at chromosome 17 and 18 in oral cavity squamous cell carcinoma. *Head Neck* 2015; **37**: 1239-1245 [PMID: 24801268 DOI: 10.1002/hed.23741]

100 **Marioni G**, Zanoletti E, Stritoni P, Lionello M, Giacomelli L, Gianatti A, Cattaneo L, Blandamura S, Mazzoni A, Martini A. Expression of the tumour-suppressor maspin in temporal bone carcinoma. *Histopathology* 2013; **63**: 242-249 [PMID: 23730906 DOI: 10.1111/his.12151]

101 **Marioni G**, Blandamura S, Giacomelli L, Calgaro N, Segato P, Leo G, Fischetto D, Staffieri A, de Filippis C. Nuclear expression of maspin is associated with a lower recurrence rate and a longer disease-free interval after surgery for squamous cell carcinoma of the larynx. *Histopathology* 2005; **46**: 576-582 [PMID: 15842640 DOI: 10.1111/j.1365-2559.2005.02141.x]

102 **Reshma V**, Rao K, Priya NS, Umadevi HS, Smitha T, Sheethal HS. Expression of maspin in benign and malignant salivary gland tumors: an immunohistochemical study. *Indian J Dent Res* 2014; **25**: 346-351

[PMID: 25098993 DOI: 10.4103/0970-9290.138334]
103 **Tarakji B**, Ashok N, Sheirawan MK, Altamimi MA, Alenzi F, Azzeghaiby SN, Baroudi K, Nassani MZ. Maspin as a tumour suppressor in salivary gland tumour. *J Clin Diagn Res* 2014; **8**: ZE05-ZE07 [PMID: 25654053 DOI: 10.7860/JCDR/2014/9124.5241]
104 **Huang YD**, Yu HW, Xia SW, Kang ZH, He YS, Han DY. Expression of maspin in invasive fungal rhinosinusitis. *J Laryngol Otol* 2017; **131**: 150-154 [PMID: 28031066 DOI: 10.1017/S0022215116009890]
105 **Ngamkitidechakul C**, Burke JM, O'Brien WJ, Twining SS. Maspin: synthesis by human cornea and regulation of in vitro stromal cell adhesion to extracellular matrix. *Invest Ophthalmol Vis Sci* 2001; **42**: 3135-3141 [PMID: 11726614 DOI: 10.1139/m97-107]
106 **Stephen JK**, Chen KM, Merritt J, Chitale D, Divine G, Worsham MJ. Methylation markers differentiate thyroid cancer from benign nodules. *J Endocrinol Invest* 2018; **41**: 163-170 [PMID: 28612287 DOI: 10.1007/s40618-017-0702-2]
107 **Boltze C**, Schneider-Stock R, Quednow C, Hinze R, Mawrin C, Hribaschek A, Roessner A, Hoang-Vu C. Silencing of the maspin gene by promoter hypermethylation in thyroid cancer. *Int J Mol Med* 2003; **12**: 479-484 [PMID: 12964023 DOI: 10.3892/ijmm.12.4.479]
108 **Ciortea CD**, Jung I, Gurzu S, Kövecsi A, Turdean SG, Bara T. Correlation of angiogenesis with other immunohistochemical markers in cutaneous basal and squamous cell carcinomas. *Rom J Morphol Embryol* 2015; **56**: 665-670 [PMID: 26429157]
109 **Zhu H**, Mao Q, Liu W, Yang Z, Jian X, Qu L, He C. Maspin suppresses growth, proliferation and invasion in cutaneous squamous cell carcinoma cells. *Oncol Rep* 2017; **37**: 2875-2882 [PMID: 28405681 DOI: 10.3892/or.2017.5574]
110 **Reis-Filho JS**, Torio B, Albergaria A, Schmitt FC. Maspin expression in normal skin and usual cutaneous carcinomas. *Virchows Arch* 2002; **441**: 551-558 [PMID: 12461611 DOI: 10.1007/s00428-002-0710-1]
111 **Turdean SG**, Gurzu S, Jung I, Neagoe RM, Sala D. Unexpected maspin immunoreactivity in Merkel cell carcinoma. *Diagn Pathol* 2015; **10**: 206 [PMID: 26607425 DOI: 10.1186/s13000-015-0437-3]
112 **Martinoli C**, Gandini S, Luise C, Mazzarol G, Confalonieri S, Giuseppe Pelicci P, Testori A, Ferrucci PF. Maspin expression and melanoma progression: a matter of sub-cellular localization. *Mod Pathol* 2014; **27**: 412-419 [PMID: 24030740 DOI: 10.1038/modpathol.2013.157]
113 **Pföhler C**, Knöpflen T, Körner R, Vogt T, Rösch A, Müller CS. Maspin expression in the invasive margin of primary melanomas may reflect an aggressive tumor phenotype. *J Dtsch Dermatol Ges* 2013; **11**: 993-999 [PMID: 23848940 DOI: 10.1111/ddg.12121]
114 **Gurzu S**, Turdean SG, Pop ST, Zazgyva A, Roman CO, Opris M, Jung I. Different synovial vasculogenic profiles of primary, rapidly destructive and osteonecrosis-induced hip osteoarthritis. An immunohistochemistry study. *Int Orthop* 2017; **41**: 1107-1112 [PMID: 27704157 DOI: 10.1007/s00264-016-3302-4]
115 **Takeda C**, Takagi Y, Shiomi T, Nosaka K, Yamashita H, Osaki M, Endo K, Minamizaki T, Teshima R, Nagashima H, Umekita Y. Cytoplasmic maspin expression predicts poor prognosis of patients with soft tissue sarcomas. *Diagn Pathol* 2014; **9**: 205 [PMID: 25358722 DOI: 10.1186/s13000-014-0205-9]
116 **Jung I**, Gurzu S, Turdean S, Ciortea D, Sahlean DI, Golea M, Bara T. Relationship of endothelial area with VEGF-A, COX-2, maspin, c-KIT, and DOG-1 immunoreactivity in liposarcomas versus non-lipomatous soft tissue tumors. *Int J Clin Exp Pathol* 2015; **8**: 1776-1782 [PMID: 25973067]
117 **Gurzu S**, Ciortea D, Tamasi A, Golea M, Bodi A, Sahlean DI, Kovecsi A, Jung I. The immunohistochemical profile of granular cell (Abrikossoff) tumor suggests an endomesenchymal origin. *Arch Dermatol Res* 2015; **307**: 151-157 [PMID: 25262119 DOI: 10.1007/s00403-014-1505-3]
118 **Bara T**, Jung I, Gurzu S, Kádár Z, Kövecsi A, Bara T. Giant gastrointestinal stromal tumor of the stomach: a challenging diagnostic and therapeutically approach. *Rom J Morphol Embryol* 2015; **56**: 1503-1506 [PMID: 26743300]

World Journal of Meta-Analysis

Submit a Manuscript: https://www.f6publishing.com

World J Meta-Anal 2019 April 30; 7(4): 156-161

DOI: 10.13105/wjma.v7.i4.156

ISSN 2308-3840 (online)

MINIREVIEWS

Drug interactions of dipeptidyl peptidase 4 inhibitors involving CYP enzymes and P-gp efflux pump

Naina Mohamed Pakkir Maideen

ORCID number: Naina Mohamed Pakkir Maideen (0000-0002-6950-9783).

Author contributions: Maideen NMP solely contributed to this article.

Conflict-of-interest statement: There is no conflict of interest for this review.

Manuscript source: Unsolicited manuscript

Received: March 18, 2019
Peer-review started: March 18, 2019
First decision: April 13, 2019
Revised: April 21, 2019
Accepted: April 23, 2019
Article in press: April 23, 2019
Published online: April 30, 2019

P-Reviewer: Raghow R
S-Editor: Ji FF
L-Editor: Filipodia
E-Editor: Wu YXJ

Naina Mohamed Pakkir Maideen, Department of Pharmacy, Dubai Health Authority, Dubai 4545, United Arab Emirates

Corresponding author: Naina Mohamed Pakkir Maideen, PhD, Doctor, Pharmacist, Pharmacologist, Department of Pharmacy, Dubai Health Authority, Al Maktoum Bridge Street, Dubai 4545, United Arab Emirates. nmmaideen@dha.gov.ae
Telephone: +971-42-164952
Fax: +971-42-244302

Abstract

Dipeptidyl peptidase 4 (DPP4) inhibitors are oral antidiabetic drugs approved to manage type 2 diabetes mellitus. Saxagliptin is a substrate of CYP3A4/5 enzymes while other DPP4 inhibitors such as sitagliptin, linagliptin, gemigliptin and teneligliptin are weak substrates of CYP3A4. DPP4 inhibitors have also been identified as substrates of P-gp. Hence, the drugs inhibiting or inducing CYP3A4/5 enzymes and/or P-gp can alter the pharmacokinetics of DPP4 inhibitors. This review is aimed to identify the drugs interacting with DPP4 inhibitors. The plasma concentrations of saxagliptin have been reported to be increased significantly by the concomitant administration of ketoconazole or diltiazem while no significant interactions between various DPP4 inhibitors and drugs like warfarin, digoxin or cyclosporine have been identified.

Key words: Drug interactions; Sitagliptin; Saxagliptin; Linagliptin; Gemigliptin; Teneligliptin; Vildagliptin; Anagliptin; CYP3A4; P-gp efflux pump

Core tip: The probability of adverse drug interactions is higher among diabetic patients due to the concomitant administration of antidiabetic drugs with multiple medications to treat comorbidities such as hypertension, dyslipidemia, other cardiovascular problems, infections, depression, and others. Dipeptidyl peptidase 4 (DPP4) inhibitors are oral antidiabetic drugs approved to manage type 2 diabetes mellitus. Some of the DPP4 inhibitors have been identified as substrates of CYP3A4/5 enzymes and P-gp efflux pump. The drugs inhibiting or inducing CYP3A4/5 enzymes and/or P-gp can alter the pharmacokinetics of DPP4 inhibitors. The prescribers and the pharmacists are required to be aware of the drugs altering the pharmacokinetics of DPP4 inhibitors significantly to prevent adverse drug interactions.

Citation: Maideen NMP. Drug interactions of dipeptidyl peptidase 4 inhibitors involving CYP enzymes and P-gp efflux pump. *World J Meta-Anal* 2019; 7(4): 156-161
URL: https://www.wjgnet.com/2308-3840/full/v7/i4/156.htm
DOI: https://dx.doi.org/10.13105/wjma.v7.i4.156

INTRODUCTION

Dipeptidyl peptidase 4 (DPP4) inhibitors are oral antidiabetic drugs approved to manage type 2 diabetes mellitus. The members of this class include sitagliptin, vildagliptin, saxagliptin, linagliptin, gemigliptin, anagliptin, teneligliptin and alogliptin. DPP4 enzyme is involved in the biodegradation of incretins such as glucagon-like peptide 1 and glucose-dependent insulinotropic polypeptide. DPP4 inhibitors help to increase the postprandial insulin secretion and inhibit glucagon secretion through the inhibition of inactivation of glucagon-like peptide 1 and glucose-dependent insulinotropic polypeptide[1].

Diabetes is a group of metabolic disorders occurring due to the defects in insulin secretion and insulin action. It has been estimated that more than 500 million people around the globe were living with diabetes in 2018 and the numbers are increasing daily[2].

Inappropriate use of multiple medications or polypharmacy is more common among diabetic patients as they may receive many medications to manage comorbid conditions such as hypertension, dyslipidemia, other cardiovascular problems, infections, depression, and others along with their antidiabetic medications. The risk of drug interactions increases with the number of comedications. Drug interaction is defined as the interference of effects of a drug by the concomitantly administered other drug(s), herbs, minerals, vitamins, food, fruit juices, tobacco smoke or alcohol, and the drug interaction resulting in increased unintended effects or decreased intended effects is termed adverse drug interaction[3,4].

The cytochrome P450 (CYP) enzymes are involved in the phase 1 metabolism of drugs and they consist of 57 different CYP forms. Almost 90% of drugs are metabolized by seven CYP enzymes including CYP3A4 and others[5]. Saxagliptin is a substrate of CYP enzymes, and it is primarily metabolized by CYP3A4/5 to form the active metabolite, 5-hydroxy saxagliptin through hydroxylation[6]. Moreover, other DPP4 inhibitors such as sitagliptin[7], linagliptin[8], gemigliptin[9] and teneligliptin[10] are weak substrates of the CYP3A4 enzyme. They are metabolized incompletely by CYP3A4, and major parts of the drugs are excreted as unchanged drug through urine except linagliptin, which is excreted through feces. Vildagliptin[11] and anagliptin[12] are metabolized by cyano group hydrolysis and about 50% of the administered dose is excreted as unchanged drug. The drugs inhibiting or inducing the CYP3A4 enzyme may interact with DPP4 inhibitors as some of them are substrates of the CYP3A4 enzyme.

P-glycoprotein (P-gp) is an efflux transporter and it is also known as multidrug resistance protein 1 as it is overexpressed in tumor cells causing resistance to different anticancer drugs. P-gp is involved in the absorption and excretion of drugs as it is also found in various tissues like small intestine, liver and kidney. P-gp pumps the orally administered drugs back in to lumen and limit their bioavailability[13]. DPP4 inhibitors have been identified as substrates of P-gp[14] and the drugs inducing or inhibiting P-gp transporters may also affect the pharmacokinetics of DPP4 inhibitors.

LITERATURE REVIEW

As the DPP4 inhibitors are the substrates of both CYP3A4 enzymes and the P-gp transporter, the present review is focused on the possible drug-drug interactions of them. The literature review was done in databases such as MEDLINE/PubMed/PMC, ScienceDirect, Google scholar, Cochrane Library and reference lists using the keywords such as drug interactions, sitagliptin, saxagliptin, linagliptin, gemigliptin, teneligliptin, vildagliptin, anagliptin, CYP3A4 and P-gp efflux pump.

LITERATURE REVIEW RESULTS

Most of the drug-drug interactions of DPP4 inhibitors involve mainly saxagliptin as it

is metabolized extensively by the CYP3A4 enzyme. The plasma concentrations of saxagliptin increased by the concomitant administration of CYP3A4 and P-gp inhibitors such as ketoconazole and diltiazem and future studies are required to confirm the possibility of drug-drug interactions with other CYP3A4 inhibitors. In addition, other DPP4 inhibitors such as sitagliptin, linagliptin, gemigliptin and teneligliptin interact with CYP3A4 inhibitors insignificantly as they are weak substrates of CYP3A4 enzyme. The prescribers and the pharmacists are required to be aware of the drug-drug interactions of saxagliptin to prevent adverse complications.

Ketoconazole

Ketoconazole is an antifungal agent and it is a known potent inhibitor of CYP3A4 enzyme and P-gp transporter[15]. It has been observed that the plasma exposure of saxagliptin was increased by the concurrent administration of ketoconazole due to the inhibition of CYP3A4 enzyme-mediated metabolism of saxagliptin and a weak inhibition of P-gp mediated transport. Hence, it has been suggested to use the lowest therapeutic dose (2.5 mg) of saxagliptin when concomitant use of ketoconazole and saxagliptin is necessary[16]. Significant elevation of plasma concentrations of gemigliptin was observed in healthy male Korean volunteers who took ketoconazole along with gemigliptin[17] while there was no significant interaction reported with the concomitant use of ketoconazole and teneligliptin[18].

Diltiazem

Diltiazem is a calcium channel blocker and it is indicated in the management of hypertension, angina and certain cardiac arrhythmias. Diltiazem is a moderate inhibitor of CYP3A4 enzyme and P-gp transporter[19] and its coadministration with saxagliptin resulted in a significant increase in plasma exposure of saxagliptin[16].

Other CYP3A4 inhibitors

The plasma concentrations of saxagliptin might be elevated by its coadministration with strong CYP3A4 inhibitors including macrolide antibiotics like clarithromycin and antiretroviral drugs (protease inhibitors) such as ritonavir, atazanavir, and others[20]. Future studies are required to confirm the interaction of macrolide antibiotics, antiretroviral drugs and other potent CYP3A4 inhibitors with saxagliptin and other DPP4 inhibitors.

3-Hydroxy-3-Methyl-Glutaryl-CoA reductase inhibitors (statins)

3-Hydroxy-3-Methyl-Glutaryl-CoA reductase inhibitors or statins are used to lower the risk of acute cardiovascular events by controlling dyslipidemia[21]. Statins include lovastatin, simvastatin, atorvastatin, cerivastatin, fluvastatin, pravastatin, rosuvastatin and pitavastatin[22]. The statins such as lovastatin, simvastatin, atorvastatin and cerivastatin are reported to be substrates of CYP3A4 enzyme and P-gp transporter[23].

The exposure of saxagliptin was slightly increased by the concomitant use of simvastatin[16], and no clinically significant changes in pharmacokinetics of simvastatin and sitagliptin[24] or vildagliptin[25] was observed when they were used concomitantly.

Although the initiation of sitagliptin in a patient with chronic renal insufficiency and receiving simvastatin resulted in developing the symptoms of rhabdomyolysis such as leg pain, weakness and tenderness[26] the efficacy and safety of the fixed dose combination of sitagliptin and simvastatin was found to be acceptable[7]. However, the pharmacokinetics of either gemigliptin or rosuvastatin was not altered during their concurrent use[27].

Furthermore, it has been reported that a patient taking sitagliptin and lovastatin[28] and the patients taking sitagliptin and atorvastatin[29,30] developed rhabdomyolysis. The patients taking sitagliptin along with statins like atorvastatin and lovastatin are required to be monitored for the symptoms of muscle toxicity.

Warfarin

Warfarin is an oral anticoagulant agent, and R-warfarin is a substrate of CYP1A2 and CYP3A4 enzymes[31]. The pharmacokinetics of warfarin and sitagliptin[32], linagliptin[33], or vildagliptin[34] did not significantly get altered during their concomitant use, and it has been reported that no dosage adjustments of either drugs are required.

Digoxin

Digoxin is a cardio tonic agent, and it is approved to treat patients with heart failure and arrhythmias including atrial fibrillation[35]. Digoxin is a substrate of P-gp and its co-administration with linagliptin[36] or vildagliptin[37] did not lead to significant alterations in pharmacokinetic parameters of digoxin. Moreover, no dosage

adjustment of either drugs are required when digoxin and linagliptin or vildagliptin are used concomitantly.

Cyclosporine

Cyclosporine is an immunosuppressant, and it is an inhibitor of CYP3A4 enzymes[38] and P-gp transporter[39]. The Pgp-mediated transport of sitagliptin was reported to be inhibited significantly by the coadministration of cyclosporine[40]. The magnitude of this interaction is considered low as sitagliptin has a high safety margin[41].

Rifampicin

Rifampicin is an antitubercular antibiotic, and it is a potent inducer of CYP3A4 enzymes and P-gp transporter[42]. Clinically insignificant reduction of systemic exposure of saxagliptin was observed when it was coadministered with rifampicin and no dosage adjustment of saxagliptin is required[43]. However, the concomitant use of gemigliptin and rifampicin in Korean volunteers resulted in significant reduction of systemic exposure of gemigliptin. The dose of gemigliptin may need to be adjusted when concurrent use is necessary[17].

CONCLUSION

Saxagliptin is a substrate of CYP3A4/5 enzymes and other DPP4 inhibitors such as sitagliptin, linagliptin, gemigliptin and teneligliptin are metabolized incompletely by CYP3A4 enzymes as they are weak substrates of CYP3A4. The plasma concentrations of saxagliptin have been reported to be increased significantly by the concomitant administration of ketoconazole or diltiazem while no significant interactions between various DPP4 inhibitors and drugs like warfarin, digoxin or cyclosporine have been identified.

REFERENCES

1 **Deacon CF**. Physiology and Pharmacology of DPP-4 in Glucose Homeostasis and the Treatment of Type 2 Diabetes. *Front Endocrinol (Lausanne)* 2019; **10**: 80 [PMID: 30828317 DOI: 10.3389/fendo.2019.00080]

2 **Kaiser AB**, Zhang N, Van Der Pluijm WO. Global Prevalence of Type 2 Diabetes over the Next Ten Years (2018-2028). *Diabetes* 2018; 67 (Supplement 1) [DOI: 10.2337/db18-202-LB]

3 **Mohamed N**, Maideen P. Thiazolidinediones and their Drug Interactions involving CYP enzymes. *A J Physiol Biochem Pharmacol* 2018; **8**: 47-54 [DOI: 10.5455/ajpbp.20181022083057]

4 **Maideen NM**. Tobacco smoking and its drug interactions with comedications involving CYP and UGT enzymes and nicotine. *World J Pharmacol* 2019; 14-25 [DOI: 10.5497/wjp.v8.i2.14]

5 **Raunio H**, Kuusisto M, Juvonen RO, Pentikäinen OT. Modeling of interactions between xenobiotics and cytochrome P450 (CYP) enzymes. *Front Pharmacol* 2015; **6**: 123 [PMID: 26124721 DOI: 10.3389/fphar.2015.00123]

6 **Stoltze D**, Böttger E. [Computerized tomography and densitometry using computerized tomography in abdominal injuries]. *Zentralbl Chir* 1981; **106**: 400-407 [PMID: 7282159 DOI: 10.1007/s40262-016-0421-4]

7 **Ramadan WH**, Kabbara WK. Sitagliptin/Simvastatin: a first combination tablet to treat type 2 diabetes and hypercholesterolemia--a review of its characteristics. *Vasc Health Risk Manag* 2015; **11**: 125-132 [PMID: 25709467 DOI: 10.2147/VHRM.S79198]

8 **Ceriello A**, Inagaki N. Pharmacokinetic and pharmacodynamic evaluation of linagliptin for the treatment of type 2 diabetes mellitus, with consideration of Asian patient populations. *J Diabetes Investig* 2017; **8**: 19-28 [PMID: 27180612 DOI: 10.1111/jdi.12528]

9 **Kim N**, Patrick L, Mair S, Stevens L, Ford G, Birks V, Lee SH. Absorption, metabolism and excretion of [14C]gemigliptin, a novel dipeptidyl peptidase 4 inhibitor, in humans. *Xenobiotica* 2014; **44**: 522-530 [PMID: 24304170 DOI: 10.3109/00498254.2013.865856]

10 **Kishimoto M**. Teneligliptin: a DPP-4 inhibitor for the treatment of type 2 diabetes. *Diabetes Metab Syndr Obes* 2013; **6**: 187-195 [PMID: 23671395 DOI: 10.2147/DMSO.S35682]

11 **He YL**. Clinical pharmacokinetics and pharmacodynamics of vildagliptin. *Clin Pharmacokinet* 2012; **51**: 147-162 [PMID: 22339447 DOI: 10.2165/11598080-000000000-00000]

12 **Furuta S**, Smart C, Hackett A, Benning R, Warrington S. Pharmacokinetics and metabolism of [14C]anagliptin, a novel dipeptidyl peptidase-4 inhibitor, in humans. *Xenobiotica* 2013; **43**: 432-442 [PMID: 23075005 DOI: 10.3109/00498254.2012.731618]

13 **Finch A**, Pillans P. P-glycoprotein and its role in drug-drug interactions. *Aust Prescr* 2014; **37**: 137-139 [DOI: 10.18773/austprescr.2014.050]

14 **Filippatos TD**, Athyros VG, Elisaf MS. The pharmacokinetic considerations and adverse effects of DPP-4 inhibitors [corrected]. *Expert Opin Drug Metab Toxicol* 2014; **10**: 787-812 [PMID: 24746233 DOI: 10.1517/17425255.2014.907274]

15 **Ramos L**, Brignol N, Bakhtiar R, Ray T, Mc Mahon LM, Tse FL. High-throughput approaches to the quantitative analysis of ketoconazole, a potent inhibitor of cytochrome P450 3A4, in human plasma. *Rapid Commun Mass Spectrom* 2000; **14**: 2282-2293 [PMID: 11114039 DOI: 10.1002/1097-0231(20001215)14:23<2282::AID-RCM164>3.0.CO;2-V]

16 **Patel CG**, Li L, Girgis S, Kornhauser DM, Frevert EU, Boulton DW. Two-way pharmacokinetic interaction studies between saxagliptin and cytochrome P450 substrates or inhibitors: simvastatin,

diltiazem extended-release, and ketoconazole. *Clin Pharmacol* 2011; **3**: 13-25 [PMID: 22287853 DOI: 10.2147/CPAA.S15227]
17 **Noh YH**, Lim HS, Jin SJ, Kim MJ, Kim YH, Sung HR, Choi HY, Bae KS. Effects of ketoconazole and rifampicin on the pharmacokinetics of gemigliptin, a dipeptidyl peptidase-IV inhibitor: a crossover drug-drug interaction study in healthy male Korean volunteers. *Clin Ther* 2012; **34**: 1182-1194 [PMID: 22534255 DOI: 10.1016/j.clinthera.2012.04.001]
18 **Nakamaru Y**, Hayashi Y, Sekine M, Kinoshita S, Thompson J, Kawaguchi A, Davies M, Jürgen Heuer H, Yamazaki H, Akimoto K. Effect of ketoconazole on the pharmacokinetics of the dipeptidyl peptidase-4 inhibitor teneligliptin: an open-label study in healthy white subjects in Germany. *Clin Ther* 2014; **36**: 760-769 [PMID: 24726088 DOI: 10.1016/j.clinthera.2014.03.002]
19 **Teng R**, Butler K. Effect of the CYP3A inhibitors, diltiazem and ketoconazole, on ticagrelor pharmacokinetics in healthy volunteers. *J Drug Assess* 2013; **2**: 30-39 [PMID: 27536435 DOI: 10.3109/21556660.2013.785413]
20 **May M**, Schindler C. Clinically and pharmacologically relevant interactions of antidiabetic drugs. *Ther Adv Endocrinol Metab* 2016; **7**: 69-83 [PMID: 27092232 DOI: 10.1177/2042018816638050]
21 **Oliveira EF**, Santos-Martins D, Ribeiro AM, Brás NF, Cerqueira NS, Sousa SF, Ramos MJ, Fernandes PA. HMG-CoA Reductase inhibitors: an updated review of patents of novel compounds and formulations (2011-2015). *Expert Opin Ther Pat* 2016; **26**: 1257-1272 [PMID: 27537201 DOI: 10.1080/13543776.2016.1216977]
22 **Neuvonen PJ**. Drug interactions with HMG-CoA reductase inhibitors (statins): the importance of CYP enzymes, transporters and pharmacogenetics. *Curr Opin Investig Drugs* 2010; **11**: 323-332 [PMID: 20178046 DOI: 10.1016/j.cct.2010.01.003]
23 **Law M**, Rudnicka AR. Statin safety: a systematic review. *Am J Cardiol* 2006; **97**: 52C-60C [PMID: 16581329 DOI: 10.1016/j.amjcard.2005.12.010]
24 **Bergman AJ**, Cote J, Maes A, Zhao JJ, Roadcap BA, Sun L, Valesky RJ, Yang A, Keymeulen B, Mathijs Z, De Smet M, Laethem T, Davies MJ, Wagner JA, Herman GA. Effect of sitagliptin on the pharmacokinetics of simvastatin. *J Clin Pharmacol* 2009; **49**: 483-488 [PMID: 19204138 DOI: 10.1177/0091270008330983]
25 **Ayalasomayajula SP**, Dole K, He YL, Ligueros-Saylan M, Wang Y, Campestrini J, Humbert H, Sunkara G. Evaluation of the potential for steady-state pharmacokinetic interaction between vildagliptin and simvastatin in healthy subjects. *Curr Med Res Opin* 2007; **23**: 2913-2920 [PMID: 17931461 DOI: 10.1185/030079907X233296]
26 **Kao DP**, Kohrt HE, Kugler J. Renal failure and rhabdomyolysis associated with sitagliptin and simvastatin use. *Diabet Med* 2008; **25**: 1229-1230 [PMID: 19046202 DOI: 10.1111/j.1464-5491.2008.02536.x]
27 **Choi HY**, Lim HS, Kim YH, Jeon HS, Kim MJ, Lee SH, Jung JH, Lee YK, Kim HJ, Bae KS. Evaluation of the pharmacokinetics of the DPP-4 inhibitor gemigliptin when coadministered with rosuvastatin or irbesartan to healthy subjects. *Curr Med Res Opin* 2015; **31**: 229-241 [PMID: 25350224 DOI: 10.1185/03007995.2014.980886]
28 **DiGregorio RV**, Pasikhova Y. Rhabdomyolysis caused by a potential sitagliptin-lovastatin interaction. *Pharmacotherapy* 2009; **29**: 352-356 [PMID: 19249953 DOI: 10.1592/phco.29.3.352]
29 **Khan MW**, Kurian S, Bishnoi R. Acute-onset rhabdomyolysis secondary to sitagliptin and atorvastatin interaction. *Int J Gen Med* 2016; **9**: 103-106 [PMID: 27199569 DOI: 10.2147/IJGM.S98543]
30 **Bhome R**, Penn H. Rhabdomyolysis precipitated by a sitagliptin-atorvastatin drug interaction. *Diabet Med* 2012; **29**: 693-694 [PMID: 22023482 DOI: 10.1111/j.1464-5491.2011.03502.x]
31 **King CA**, Babcock KM, Godios RJ, King BS. Significant drug-drug interaction between warfarin and nafcillin. *Ther Adv Drug Saf* 2018; **9**: 667-671 [PMID: 30479741 DOI: 10.1177/2042098618796186]
32 **Wright DH**, Herman GA, Maes A, Liu Q, Johnson-Levonas AO, Wagner JA. Multiple doses of sitagliptin, a selective DPP-4 inhibitor, do not meaningfully alter pharmacokinetics and pharmacodynamics of warfarin. *J Clin Pharmacol* 2009; **49**: 1157-1167 [PMID: 19783710 DOI: 10.1177/0091270009341653]
33 **Graefe-Mody EU**, Brand T, Ring A, Withopf B, Stangier J, Iovino M, Woerle HJ. Effect of linagliptin on the pharmacokinetics and pharmacodynamics of warfarin in healthy volunteers. *Int J Clin Pharmacol Ther* 2011; **49**: 300-310 [PMID: 21543033 DOI: 10.5414/CP201507]
34 **He YL**, Sabo R, Riviere GJ, Sunkara G, Leon S, Ligueros-Saylan M, Rosenberg M, Dole WP, Howard D. Effect of the novel oral dipeptidyl peptidase IV inhibitor vildagliptin on the pharmacokinetics and pharmacodynamics of warfarin in healthy subjects. *Curr Med Res Opin* 2007; **23**: 1131-1138 [PMID: 17519080 DOI: 10.1185/030079907X188008]
35 **Cheng JW**, Rybak I. Use of digoxin for heart failure and atrial fibrillation in elderly patients. *Am J Geriatr Pharmacother* 2010; **8**: 419-427 [PMID: 21335295 DOI: 10.1016/j.amjopharm.2010.10.001]
36 **Friedrich C**, Ring A, Brand T, Sennewald R, Graefe-Mody EU, Woerle HJ. Evaluation of the pharmacokinetic interaction after multiple oral doses of linagliptin and digoxin in healthy volunteers. *Eur J Drug Metab Pharmacokinet* 2011; **36**: 17-24 [PMID: 21340661 DOI: 10.1007/s13318-011-0028-y]
37 **He YL**, Sabo R, Sunkara G, Bizot MN, Riviere GJ, Leon S, Ligueros-Saylan M, Dole WP, Howard D. Evaluation of pharmacokinetic interactions between vildagliptin and digoxin in healthy volunteers. *J Clin Pharmacol* 2007; **47**: 998-1004 [PMID: 17660482 DOI: 10.1177/0091270007301802]
38 **Pakkir Maideen NM**, Manavalan G, Balasubramanian K. Drug interactions of meglitinide antidiabetics involving CYP enzymes and OATP1B1 transporter. *Ther Adv Endocrinol Metab* 2018; **9**: 259-268 [PMID: 30181852 DOI: 10.1177/2042018818767220]
39 **Dorababu M**, Nishimura A, Prabha T, Naruhashi K, Sugioka N, Takada K, Shibata N. Effect of cyclosporine on drug transport and pharmacokinetics of nifedipine. *Biomed Pharmacother* 2009; **63**: 697-702 [PMID: 19819100 DOI: 10.1016/j.biopha.2009.04.031]
40 **Krishna R**, Bergman A, Larson P, Cote J, Lasseter K, Dilzer S, Wang A, Zeng W, Chen L, Wagner J, Herman G. Effect of a single cyclosporine dose on the single-dose pharmacokinetics of sitagliptin (MK-0431), a dipeptidyl peptidase-4 inhibitor, in healthy male subjects. *J Clin Pharmacol* 2007; **47**: 165-174 [PMID: 17244767 DOI: 10.1177/0091270006296523]
41 **Chu XY**, Bleasby K, Yabut J, Cai X, Chan GH, Hafey MJ, Xu S, Bergman AJ, Braun MP, Dean DC, Evers R. Transport of the dipeptidyl peptidase-4 inhibitor sitagliptin by human organic anion transporter 3, organic anion transporting polypeptide 4C1, and multidrug resistance P-glycoprotein. *J Pharmacol Exp Ther* 2007; **321**: 673-683 [PMID: 17314201 DOI: 10.1124/jpet.106.116517]
42 **Kim KA**, Park PW, Liu KH, Kim KB, Lee HJ, Shin JG, Park JY. Effect of rifampin, an inducer of CYP3A and P-glycoprotein, on the pharmacokinetics of risperidone. *J Clin Pharmacol* 2008; **48**: 66-72 [PMID: 18094221 DOI: 10.1177/0091270007309888]

43 **Upreti VV**, Boulton DW, Li L, Ching A, Su H, Lacreta FP, Patel CG. Effect of rifampicin on the pharmacokinetics and pharmacodynamics of saxagliptin, a dipeptidyl peptidase-4 inhibitor, in healthy subjects. *Br J Clin Pharmacol* 2011; **72**: 92-102 [PMID: 21651615 DOI: 10.1111/j.1365-2125.2011.03937.x]

World Journal of Meta-Analysis

Submit a Manuscript: https://www.f6publishing.com

World J Meta-Anal 2019 April 30; 7(4): 162-169

DOI: 10.13105/wjma.v7.i4.162

ISSN 2308-3840 (online)

SYSTEMATIC REVIEW

Safety and efficacy of percutaneous transhepatic balloon dilation in removing common bile duct stones: A systematic review

Yu-Liang Li, Dong Li, Bin Liu, Wu-Jie Wang, Wei Wang, Yong-Zheng Wang

ORCID number: Yu-Liang Li (0000-0001-8117-4317); Dong Li (0000-0002-3944-3680); Bin Liu (0000-0003-1686-1553); Wu-Jie Wang (0000-0001-9431-7153); Wei Wang (0000-0002-2124-5328); Yong-Zheng Wang (0000-0001-5889-2118).

Author contributions: Li YL initiated the study and secured the funding; Li D and Liu B designed the review and carried out the analysis; Li D drafted the initial manuscript and Li YL and Wang W revised the manuscript; Wang WJ and Wang YZ participated in developing the manuscript; all authors reviewed and approved the final manuscript as submitted.

Supported by the Natural Science Foundation of Shandong Province, Nos. 2014ZRE27479, ZR2018PH032, and ZR2018PH033; and the National Natural Science Foundation of China, No. 6167276.

Conflict-of-interest statement: There are no conflicts of interest.

Yu-Liang Li, Dong Li, Bin Liu, Wu-Jie Wang, Wei Wang, Yong-Zheng Wang, Department of Interventional Medicine, The Second Hospital of Shandong University, Jinan 250033, Shandong Province, China

Corresponding author: Yu-Liang Li, MD, PhD, Chief Doctor, Doctor, Professor, Department of Interventional Medicine, The Second Hospital of Shandong University, No. 247, Beiyuan Street, Jinan 250033, Shangdong Province, China. lyl.pro@sdu.edu.cn
Telephone: +86-531-8524777

Abstract

BACKGROUND

Endoscopic sphincterotomy (EST) is widely regarded as the first choice in the management of common bile duct (CBD) stones. However, for some patients, this treatment is not possible. The percutaneous transhepatic balloon dilation (PTBD) technique has been suggested as an alternative but has yet to gain wide acceptance.

AIM

To review cases of PTBD for removing CBD stones and explore the safety and efficacy of this treatment.

METHODS

We conducted a systematic review using the Preferred Reporting Items for Systematic Reviews and Meta-Analyses guidelines. We searched EMBASE, PubMed, and Web of Science for cases of PTBD that underwent CBD stone removal from 1981 to January 2019. We analyzed all relevant articles available in full text. We extracted data on patient's age, gender, overall technique success rate, reasons for technique failure, and the presence and type of major and minor complications. We analyzed the data and reported the results in a table and text. Altogether, we retrieved 12 case series and 6 case reports, for a total of 1347 patients. Thirty cases were excluded due to a lack of patient data.

RESULTS

The overall technique success rate for removing a CBD stone was 98.5% (1327/1347) and 98.1% (109/111) for removing concurrent CBD and gallbladder stones. Based on available data (n = 1312), mean age of all patients (687 males and 625 females) was 68.9 years. The total number of procedures in the remaining 1317 patients (after exclusion) was 3237 (average 2.4 procedures per patient). The total number of failures for eliminating a CBD stone was 20, and the reasons for failure included: Stone impaction (n = 10), intrahepatic bile duct stricture (n = 5),

Manuscript source: Invited manuscript

Received: March 12, 2019
Peer-review started: March 13, 2019
First decision: March 27, 2019
Revised: April 3, 2019
Accepted: April 18, 2019
Article in press: April 18, 2019
Published online: April 30, 2019

P-Reviewer: Bramhall S, Espinel J, Kanno Y, Mercado MA, Pan SM
S-Editor: Ji FF
L-Editor: Wang TQ
E-Editor: Wu YXJ

large stone (n = 2), severe CBD dilation (n = 1), multiple stones (n = 1), and duodenal perforation (n = 1). Various major complications related to the procedure were reported, but the incidence rate was low (1.4%). No pancreatitis or procedure related mortality was reported. Minor complications including transient hyperamylasemia, nausea, vomiting, abdominal pain, fever, and mild hemobilia were reported. For 218 patients (88 patients with unsuccessful endoscopic removal due to anatomical change and large or impacted stone and 130 cases who refused endoscopic procedure due to poor general condition or other additional disease), the CBD stones were successfully pushed into the duodenum by performing the PTBD procedure.

CONCLUSION

PTBD is a safe and effective approach in the nonoperative management of CBD stones. PTBD provides an alternative treatment when endoscopic procedures fail or are unsuitable for the patient.

Key words: Common bile duct stone; Percutaneous transhepatic approach; Balloon dilation; Interventional procedures; Papilla; Endoscopic sphincterotomy

Core tip: Endoscopic treatment for common bile duct (CBD) stones has been widely accepted. However, for specific patients, such as those with gastrointestinal anatomical changes, duodenal diverticulum, esophageal varices, or other conditions, endoscopic treatment is unsuitable and difficult to perform. Under these circumstances, it has been shown that percutaneous transhepatic balloon dilation (PTBD) can remove CBD stones *via* a percutaneous transhepatic route after papilla dilation. However, no review on this technique has been published. Therefore, we performed a systematic review to confirm the safety and efficacy of PTBD in removing CBD stones in terms of the key outcomes, success rate, reasons for failure, and procedure-related complications.

Citation: Li YL, Li D, Liu B, Wang WJ, Wang W, Wang YZ. Safety and efficacy of percutaneous transhepatic balloon dilation in removing common bile duct stones: A systematic review. *World J Meta-Anal* 2019; 7(4): 162-169
URL: https://www.wjgnet.com/2308-3840/full/v7/i4/162.htm
DOI: https://dx.doi.org/10.13105/wjma.v7.i4.162

INTRODUCTION

Since 1974 when Kawai first described endoscopic sphincterotomy (EST), this treatment has been widely accepted and regarded as the first choice in the management of common bile duct (CBD) stones[1]. Indeed, endoscopic therapies have initiated a great revolution in the treatment of choledocholithiasis[2-4]. However, for specific patients, such as those with gastrointestinal anatomical changes, duodenal diverticulum, esophageal varices, or poor general condition, endoscopic treatment can be difficult to perform, and it has been deemed unsuitable in these particular cases[5-7].

In cases that preclude EST, percutaneous transhepatic stone removal through the papilla into the duodenum without balloon dilation was first reported as an alternative in 1979 by Dotter *et al*[8] and Perez *et al*[9]. Further, in 1981 Centola *et al*[10] first introduced transpapillary elimination of a stone by dilating the papilla with a 6-mm balloon, and since then, this technique has been implemented as a standard percutaneous stone removal procedure. This technique has increased efficacy, with a high success rate and low incidence of complications. Despite these reports, the percutaneous transhepatic balloon dilation (PTBD) technique has still not gained wide acceptance. This is mainly due to a lack of awareness and evaluation of the safety, efficacy, and risk of complications associated with this procedure.

Individual studies alone may not provide strong and sufficient evidence to help PTBD gain greater acceptance, and to the best of our knowledge, no review on the use of PTBD in removing CBD stones has previously been published. In the current review, we aim to objectively evaluate the potential role of PTBD in the management of CBD stones, as an alternative to EST. We performed a systematic review of the

currently available literature for success rate, reasons for failure, and procedure-related complications associated with the implementation of the PTBD procedure. This review was conducted in an effort to clarify the safety and efficacy of the procedure.

MATERIALS AND METHODS

This systematic review was performed according to the Preferred Reporting Items for Systematic Reviews and Meta-Analyses (PRISMA) guidelines[11]. We searched Embase, PubMed, and Web of Science for relevant studies involving the use of PTBD for removal of CBD stones. Our search covered studies conducted during the period from 1981 to January 2019. We used the following Medical Subject Headings (MeSH): "gallstone" and "dilation" and "percutaneous" and "transhepatic" and "balloon". The complete terms used for the PubMed search were: (dilation [Title/Abstract]) OR dilations [Title/Abstract] OR dilatations [Title/Abstract] OR dilatation [Title/Abstract]) AND (transhepatic [Title/Abstract] OR interventional radiography [Title/Abstract]) AND (percutaneous [Title/Abstract] OR radiography, interventional [Title/Abstract]) AND (balloon [Title/Abstract]) AND (gallstones [Mesh] OR gallstone [Title/Abstract] OR gall Stones [Title/Abstract] OR biliary calculi [Title/Abstract] OR calculi, biliary [Title/Abstract] OR gall Stone [Title/Abstract] OR common bile duct calculi [Title/Abstract] OR gallstones, common bile duct [Title/Abstract] OR common bile duct gallstones [Title/Abstract] OR gall Stones, common bile duct [Title/Abstract] OR biliary calculi, common bile duct [Title/Abstract] OR common bile duct gall stones [Title/Abstract]).

We regarded studies as available for inclusion if they applied a percutaneous transhepatic route, applied a balloon dilation technique, and involved treatment of CBD stones or concurrent CBD stones in addition to gallbladder stones. Case reports and case series were both included. We excluded non-English published studies and studies for which the full text article was unavailable. The studies were reviewed by two individual researchers (DL and BL) and data analysis and extraction were done by the same two researchers (DL and BL). After screening the full text, we extracted the following data from each study for inclusion in our review: Age, gender, number of procedures, overall technique success rate, reasons for failure, and various major and minor complications. Using descriptive statistical analysis, the variables were described as number, proportion, and mean (Table 1).

RESULTS

The search results and flow diagram are shown in Figure 1. We retrieved 12 case series and 6 case reports, for a total of 1347 cases treated by percutaneous transhepatic papilla balloon dilation[10,12-28].

According to our findings, 7 studies were published before the year 2000 and 11 studies were published after the year 2000. Centola *et al*[10] from England was the first to report a case in which a balloon was used to dilate the papilla and remove a stone in the duodenum in 1981. Among those case series which applied PPBD, the largest included 916 cases and was reported by Shin *et al*[14] in South Korea in 2017. In our review, 1050 cases were published from Asia, with 297 cases published from Europe and North America.

As for the patient characteristics, not all the studies reported age and sex (n = 35)[16,20,27]. Based on the available data (n = 1312), the average age of patients was 66.89 years and there were 687 males and 625 females. All patients were treated by PTBD for CBD stone removal, and 111 patients who had CBD stones and gallbladder stones concurrently were treated by the combination of PTBD and an additional procedure. Indications cited in these studies for the use of the PTBD procedure to remove stones were: unsuitable for endoscopic procedure due to the poor condition or other additional disease (n = 130), which included coronary artery disease, emphysema, pulmonary insufficiency, cardiac insufficiency, multiple sclerosis, and other diseases, unsuccessful endoscopic removal due to the anatomical change and large or impacted stone (n = 88), and unsuccessful basket extraction (n = 2). Determination of the number of patients treated by an unsuccessful endoscopic procedure or who were unsuitable for an endoscopic proce-dure was low (16.1%), as the largest case series (n = 916) did not mention the other forms of treatment or the patients' additional diseases.

The overall PTBD technique success rate for removing a CBD stone was 98.5% (1327/1347), and 98.1% (109/111) for removing concurrent CBD and gallbladder

Table 1 Characteristics of the patients and procedure

Characteristic	Value
No. of patients	1347
Gender	1312
Female	625 (47.64)
Male	687 (52.36)
Average age	66.89
Overall technique success rate	98.51
Average number of procedure	2.46
Reasons of failure	
Severe CBD dilation	1 (0.07)
Multiple stones	1 (0.07)
Large stone	2 (0.15)
Stone impaction	10 (0.74)
Intrahepatic bile duct stricture	5 (0.37)
Duodenal perforation	1 (0.07)
Major complications	
Cholangitis	11 (0.82)
Bile duct hemorrhage	1 (0.07)
Subcapsular biloma	1 (0.07)
Subcapsular hematoma	1 (0.07)
Subcapsular abscess	1 (0.07)
Bile peritonitis	1 (0.07)
Duodenal perforation	1 (0.07)
CBD perforation	1 (0.07)
Gastroduodenal artery pseudoaneurysm	1 (0.07)
Right hepatic artery transection	1 (0.07)

CBD: Common bile duct.

stones. The largest diameter of CBD stone was 25 mm reported by Chang *et al*[13] in 2018, and the CBD stone was successfully removed through dilated papilla by using a 24 mm balloon. Before stone removal, percutaneous transhepatic biliary drainage was conducted on 1024 patients, which is performed to relieve clinical symptoms and build the approach for the stone removal procedure that follows. Based on the available data, the total number of procedures in 1317 patients was 3237, with an average of 2.4 procedures per patient (30 cases did not have this information). The total number of failures in eliminating a CBD stone was 20, and there were multiple reasons for failure, including severe CBD dilation (n = 1), large stone (n = 2), multiple stones (n = 1), stone impaction (n = 10), bile duct stricture (n = 5), and duodenal perforation (n = 1).

Major complications related to the procedure were reported, but the incidence rate for these complications was low (1.4%). Among the included studies, the incidence rate of major complications varied from 0%-6.8%. Major complications included cholangitis (n = 11), bile duct hemorrhage (n = 1), subcapsular biloma (n = 1), subcapsular hematoma (n = 1), subcapsular abscess (n = 1), bile peritonitis (n = 1), duodenal perforation (n = 1), CBD perforation (n = 1), gastroduodenal artery pseudoaneurysm (n = 1), and right hepatic artery transection (n = 1). No pancreatitis or procedure related mortality was reported. Minor complications, such as hyperamylasemia, nausea, vomiting, abdominal pain, fever, and mild hemobilia, were reported. The complete data for these complications were not provided in many case series as most of the minor complications had transient adverse effects and did not require any treatment.

DISCUSSION

The results of this review show that the use of the PTBD technique in removing CBD stones can yield a high success rate and a low incidence of complications.

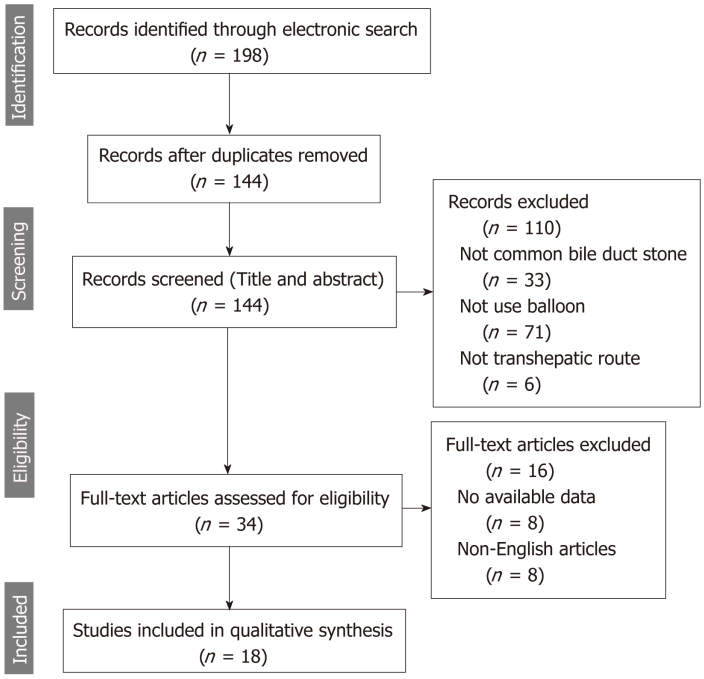

Figure 1 Flow diagram of study selection.

Furthermore, our findings suggest that PTBD offers a safe and effective choice for removing CBD stones in those patients with a prior failed endoscopic treatment or who are unsuitable for an endoscopic procedure. These data demonstrate and support the PTBD technique as an effective and safe therapeutic management tool, which can be implemented as an alternative, and supplement, to endoscopic therapies.

The overall technique success rate for removing a CBD stone by performing PTBD was 98.5%. The success rate of endoscopic treatment of CBD stones is compromised by several limitations, including gastrointestinal anatomical changes (*e.g.*, Billroth II surgery and duodenal diverticulum) and a limited application in those with a poor general condition. Under these circumstances, endoscopic treatment is unsuitable and difficult to perform. In the current study, the results show that among 218 patients, 88 had unsuccessful endoscopic removal and 130 were unfit for an endoscopic procedure, and the CBD stone was successfully pushed into the duodenum by performing the PTBD procedure. Compared to endoscopic procedures, PTBD uses percutaneous transhepatic and transpapillary routes which could avoid the effects of anatomical changes and is easier to complete the procedure through the papilla. The overall technique success rate for removing concurrent CBD and gallbladder stones was 98.1% (109/111) when performing a combination of the PTBD procedure and another treatment such as laparoscopic choledochotomy (LC) and percutaneous transcystic procedure. Interestingly, in the studies included in our review, there is data suggesting that PTBD + LC is more effective and safe in patients with both CBD and gallbladder stones when compared to the endoscopic papillary balloon dilatation + LC technique. Based on these findings, we postulate that PTBD is an alternative technique that can potentially mitigate the limitations of endoscopic treatment.

Although the success rate of PTBD was quite high, there were a few failed cases. Our results show that the reasons some cases failed were related to the presence of a large stone and duodenal perforation. The large stone is difficult to push through the papilla, which needs use of stone basket or other lithotripsy. And a larger balloon may be used to dilate the papilla, which could cause more abdominal pain and overexpansion of the papilla. For patients with a history of gastrointestinal surgery, it should be performed gently when the guide wire pass through the papilla and the stones were pushed into the duodenum with a balloon. In our systematic review, we conclude several procedure details or key points, which could help surgeons improve their performance with this technique. We suggest the following: (1) In the supine position, puncturing the bile duct in the right anterior lobe under the guidance of B-type ultrasound to make the angle between the bile duct and the CBD as large as possible; (2) After passing through the Oddi sphincter, the stiff guide wire is introduced for greater support; (3) When dilating the Oddi sphincter, the balloon catheter should be accurately positioned and fully dilated. The preferred diameter of

the balloon is 8 mm. If the expansion is unsatisfactory, it can be increased by 2 mm successively, with a maximum of 20 mm; (4) Intermittent expansion should be used to avoid tearing of sphincter fibers. We found that the duodenal papilla can be expanded at multiple angles for a duration of 15 s; (5) When the diameter of the stone is > 10 mm, transpapillary stone removal can be achieved by performing lithotripsy first, and then pushing the stone into the duodenum with a balloon; (6) Multiple stones should be rolled out one by one to avoid pancreatitis caused by stone debris reflux to the pancreatic duct. Alternatively, the clinician can leave an external drainage tube for the second stage of stone removal; and (7) Routine placement of internal and external biliary drainage tubes can effectively reduce the incidence of pancreatitis by reducing the intrabiliary pressure. We believe that these suggestions will result in increased efficacy and a further reduction in complications due to the PTBD procedure.

For the 1347 cases we retrieved in this study, major complications related to the PTBD procedure were reported, but the incidence rate was low (1.4%). The most common major complication was cholangitis, at a rate of less than 1% of all cases included in our review. The incidence of other major complications was even lower. Further, we found no reported procedure related mortality. Importantly, the minor complications noted in the results from the included studies were easily controlled by conservative treatment. Several case series (n = 4, 26 patients) reported transient hyperamylasemia after the procedure; however, the level of amylase was decreased to normal after a few days of recovery. These data suggest that PTBD is a safe procedure with a low incidence of complications.

To the best of our knowledge, no review on the effectiveness of the PTBD procedure in removing CBD stones has previously been published. Therefore, we performed this systematic review to confirm the safety and efficacy of PTBD procedure in removing CBD stones by analyzing key outcomes such as success rate, reasons for failure, and procedure-related complications. However, our study had several limitations. First, there are no randomized clinical trials currently published that compare endoscopic treatment and the PTBD procedure. These trials would provide stronger evidence in proving the safety and efficacy of the PTBD procedure as an alternative to endoscopic treatment. However, even given this lack of data, we believe our review fills in some of the blanks that currently exist pertaining to the safety and efficacy of PTBD. Second, long-term effectiveness of this procedure is unknown. There are no long-term follow-up studies published currently, and as such there is no data on any long-term complications, such as stone recurrence and reflux cholangitis. Moreover, there remain no high quality, rigorous manuscripts published on the PTBD procedure. This has resulted in a lack of patient characteristics and incomplete procedure details, which may cause bias. Although further research is required to investigate better application of this treatment, our limited evidence clearly demonstrates that PTBD is a safe and effective approach in the nonoperative management of the CBD stones. This technique provides an alternative treatment when endoscopic procedures fail or are unsuitable for specific patients.

ARTICLE HIGHLIGHTS

Research background

Endoscopic sphincterotomy (EST) is widely regarded as the first choice in the management of common bile duct (CBD) stones. However, for some patients, this treatment is not possible.

Research motivation

The percutaneous transhepatic balloon dilation (PTBD) technique has been suggested as an alternative but has yet to gain wide acceptance.

Research objectives

This review was conducted in an effort to clarify the safety and efficacy of the procedure *via* reviewing cases of PTBD for removing CBD stones. We conducted a systematic review using the Preferred Reporting Items for Systematic Reviews and Meta-Analyses guidelines.

Research methods

We searched EMBASE, PubMed, and Web of Science for cases of PTBD that underwent CBD stone removal from 1981 to January 2019. We analyzed all relevant articles available in full text. We extracted data on patient's age, gender, overall technique success rate, reasons for technique failure, and the presence and type of major and minor complications.

Research results

The overall technique success rate for removing a CBD stone was 98.5% (1327/1347) and 98.1% (109/111) for removing concurrent CBD and gallbladder stones. The total number of failures for eliminating a CBD stone was 20, and the reasons for failure included: Stone impaction (n = 10),

intrahepatic bile duct stricture (n = 5), large stone (n = 2), severe CBD dilation (n = 1), multiple stones (n = 1), and duodenal perforation (n = 1).

Research conclusions

Various major complications related to the procedure were reported, but the incidence rate was low (1.4%). No pancreatitis or procedure related mortality was reported. Minor complications including transient hyperamylasemia, nausea, vomiting, abdominal pain, fever, and mild hemobilia were reported. For 218 patients (88 patients with unsuccessful endoscopic removal due to anatomical change and large or impacted stone and 130 cases who refused endoscopic procedure due to poor general condition or other additional disease), the CBD stones were successfully pushed into the duodenum by performing the PTBD procedure.

Research perspectives

PTBD is a safe and effective approach in the nonoperative management of CBD stones. PTBD provides an alternative treatment when endoscopic procedures fail or are unsuitable for the patient.

ACKNOWLEDGEMENTS

We thank Yuan Zhang for her dedicated assistance in statistical analysis of the data.

REFERENCES

1 **Kawai K**, Akasaka Y, Murakami K, Tada M, Koli Y. Endoscopic sphincterotomy of the ampulla of Vater. *Gastrointest Endosc* 1974; **20**: 148-151 [PMID: 4825160 DOI: 10.1016/S0016-5107(74)73914-1]

2 **Williams E**, Beckingham I, El Sayed G, Gurusamy K, Sturgess R, Webster G, Young T. Updated guideline on the management of common bile duct stones (CBDS). *Gut* 2017; **66**: 765-782 [PMID: 28122906 DOI: 10.1136/gutjnl-2016-312317]

3 **Trikudanathan G**, Arain MA, Attam R, Freeman ML. Advances in the endoscopic management of common bile duct stones. *Nat Rev Gastroenterol Hepatol* 2014; **11**: 535-544 [PMID: 24860928 DOI: 10.1038/nrgastro.2014.76]

4 **Teoh AY**, Cheung FK, Hu B, Pan YM, Lai LH, Chiu PW, Wong SK, Chan FK, Lau JY. Randomized trial of endoscopic sphincterotomy with balloon dilation versus endoscopic sphincterotomy alone for removal of bile duct stones. *Gastroenterology* 2013; **144**: 341-345.e1 [PMID: 23085096 DOI: 10.1053/j.gastro.2012.10.027]

5 **Köksal AŞ**, Eminler AT, Parlak E. Biliary endoscopic sphincterotomy: Techniques and complications. *World J Clin Cases* 2018; **6**: 1073-1086 [PMID: 30613665 DOI: 10.12998/wjcc.v6.i16.1073]

6 **Duan F**, Cui L, Bai Y, Li X, Yan J, Liu X. Comparison of efficacy and complications of endoscopic and percutaneous biliary drainage in malignant obstructive jaundice: a systematic review and meta-analysis. *Cancer Imaging* 2017; **17**: 27 [PMID: 29037223 DOI: 10.1186/s40644-017-0129-1]

7 **Freeman ML**, Nelson DB, Sherman S, Haber GB, Herman ME, Dorsher PJ, Moore JP, Fennerty MB, Ryan ME, Shaw MJ, Lande JD, Pheley AM. Complications of endoscopic biliary sphincterotomy. *N Engl J Med* 1996; **335**: 909-918 [PMID: 8782497 DOI: 10.1056/NEJM199609263351301]

8 **Dotter CT**, Bilbao MK, Katon RM. Percutaneous transhepatic gallstone removal by needle tract. *Radiology* 1979; **133**: 242-243 [PMID: 472301 DOI: 10.1148/133.1.242]

9 **Perez MR**, Oleaga JA, Freiman DB, McLean GL, Ring EJ. Removal of a distal common bile duct stone through percutaneous transhepatic catheterization. *Arch Surg* 1979; **114**: 107-109 [PMID: 758870 DOI: 10.1001/archsurg.1979.01370250109024]

10 **Centola CA**, Jander HP, Stauffer A, Russinovich NA. Balloon dilatation of the papilla of Vater to allow biliary stone passage. *AJR Am J Roentgenol* 1981; **136**: 613-614 [PMID: 6781307 DOI: 10.2214/ajr.136.3.613]

11 **Preferred Reporting Items for Systematic Reviews and Meta-Analyses**. PRISMA statement. Accessed on Sep 10, 2013. Available from: http://www.prisma-statement.org/

12 **Liu B**, Wu DS, Cao PK, Wang YZ, Wang WJ, Wang W, Chang HY, Li D, Li X, Hertzanu Y, Li YL. Percutaneous transhepatic extraction and balloon dilation for simultaneous gallbladder stones and common bile duct stones: A novel technique. *World J Gastroenterol* 2018; **24**: 3799-3805 [PMID: 30197485 DOI: 10.3748/wjg.v24.i33.3799]

13 **Chang HY**, Wang CJ, Liu B, Wang YZ, Wang WJ, Wang W, Li D, Li YL. Ursodeoxycholic acid combined with percutaneous transhepatic balloon dilation for management of gallstones after elimination of common bile duct stones. *World J Gastroenterol* 2018; **24**: 4489-4498 [PMID: 30356997 DOI: 10.3748/wjg.v24.i39.4489]

14 **Shin JS**, Shim HJ, Kwak BK, Yoon HK. Biliary stone removal through the percutaneous transhepatic biliary drainage route, focusing on the balloon sphincteroplasty flushing technique: a single center study with 916 patients. *Jpn J Radiol* 2017; **35**: 440-447 [PMID: 28589507 DOI: 10.1007/s11604-017-0651-x]

15 **Li D**, Li YL, Wang WJ, Liu B, Chang HY, Wang W, Wang YZ, Li Z. Percutaneous transhepatic papilla balloon dilatation combined with a percutaneous transcystic approach for removing concurrent gallbladder stone and common bile duct stone in a patient with billroth II gastrectomy and acute cholecystitis: A case report. *Medicine (Baltimore)* 2017; **96**: e7964 [PMID: 28858128 DOI: 10.1097/MD.0000000000007964]

16 **Li S**, Li Y, Geng J, Liu B, Gao R, Zhou Z, Hu S. Concurrent Percutaneous Transhepatic Papillary Balloon Dilatation Combined with Laparoscopic Cholecystectomy for the Treatment of Gallstones with Common Bile Duct Stones. *J Laparoendosc Adv Surg Tech A* 2015; **25**: 886-891 [PMID: 26575245 DOI: 10.1089/lap.2015.0220]

17 **Ozcan N**, Kahriman G, Mavili E. Percutaneous transhepatic removal of bile duct stones: results of 261 patients. *Cardiovasc Intervent Radiol* 2012; **35**: 621-627 [PMID: 21647808 DOI: 10.1007/s00270-011-0190-2]

18 **Oguzkurt L**, Ozkan U, Gumus B. Percutaneous transhepatic cutting balloon papillotomy for removal of common bile duct stones. *Cardiovasc Intervent Radiol* 2009; **32**: 1117-1119 [PMID: 19093146 DOI: 10.1007/s00270-008-9487-1]

19 **Park YS**, Kim JH, Choi YW, Lee TH, Hwang CM, Cho YJ, Kim KW. Percutaneous treatment of extrahepatic bile duct stones assisted by balloon sphincteroplasty and occlusion balloon. *Korean J Radiol* 2005; **6**: 235-240 [PMID: 16374081 DOI: 10.3348/kjr.2005.6.4.235]

20 **Nagashima I**, Takada T, Shiratori M, Inaba T, Okinaga K. Percutaneous transhepatic papillary balloon dilation as a therapeutic option for choledocholithiasis. *J Hepatobiliary Pancreat Surg* 2004; **11**: 252-254 [PMID: 15368109 DOI: 10.1007/s00534-003-0851-x]

21 **Chikamori F**, Kuniyoshi N, Shibuya S, Takase Y. Simultaneous laparoscopic cholecystectomy and percutaneous papillary balloon dilatation for cholecystocholedocholithiasis. *Dig Surg* 2003; **20**: 12-17 [PMID: 12637799 DOI: 10.1159/000068859]

22 **Shirai N**, Hanai H, Kajimura M, Kataoka H, Yoshida K, Nakagawara M, Nemoto M, Nagasawa M, Kaneko E. Successful treatment of percutaneous transhepatic papillary dilation in patients with obstructive jaundice due to common bile duct stones after Billroth II gastrectomy: report of two emergent cases. *J Clin Gastroenterol* 2000; **30**: 91-93 [PMID: 10636221 DOI: 10.1097/00004836-200001000-00020]

23 **Chikamori F**, Nishio S, LeMaster JC. Percutaneous papillary balloon dilatation as a therapeutic option for cholecystocholedocholithiasis in the era of laparoscopic cholecystectomy. *Surg Today* 1999; **29**: 856-861 [PMID: 10489125 DOI: 10.1007/bf02482775]

24 **Graziani L**, Fabrizzi G, Manfrini E, Galeazzi R, Freddara U. Percutaneous transhepatic Oddi-sphincter dilatation for bile duct stone removal. *AJR Am J Roentgenol* 1989; **152**: 73-75 [PMID: 2783292 DOI: 10.2214/ajr.152.1.73]

25 **Berkman WA**, Bishop AF, Palagallo GL, Cashman MD. Transhepatic balloon dilation of the distal common bile duct and ampulla of Vater for removal of calculi. *Radiology* 1988; **167**: 453-455 [PMID: 3357955 DOI: 10.1148/radiology.167.2.3357955]

26 **Saeed M**, Newman GE, Dunnick NR. Use of angioplasty balloons in the percutaneous management of biliary calculi: tandem-balloon method. *AJR Am J Roentgenol* 1987; **148**: 745-746 [PMID: 2950741 DOI: 10.2214/ajr.148.4.745]

27 **Meranze SG**, Stein EJ, Burke DR, Hartz WH, McLean GK. Removal of retained common bile duct stones with angiographic occlusion balloons. *AJR Am J Roentgenol* 1986; **146**: 383-385 [PMID: 2934962 DOI: 10.2214/ajr.146.2.383]

28 **Fataar S**, Bassiony H, Abou-Neema T. The percutaneous "stretch and push" technique for removing retained biliary calculi. *Br J Radiol* 1982; **55**: 456-459 [PMID: 7104573 DOI: 10.1259/0007-1285-55-654-456]

World Journal of Meta-Analysis

Submit a Manuscript: https://www.f6publishing.com

World J Meta-Anal 2019 April 30; 7(4): 170-183

DOI: 10.13105/wjma.v7.i4.170

ISSN 2308-3840 (online)

META-ANALYSIS

Effectiveness of taxanes over anthracyclines in neoadjuvant setting: A systematic-review and meta-analysis

Mona Pathak, Sada Nand Dwivedi, SVS Deo, Bhaskar Thakur, Vishnubhatla Sreenivas, Goura Kishor Rath

ORCID number: Mona Pathak (0000-0002-2103-9890); Sada Nand Dwivedi (0000-0002-6594-8826); SVS Deo (0000-0003-1955-8234); Bhaskar Thakur (0000-0001-6869-8968); Sreenivas Vishnubhatla (0000-0003-1456-4029); Goura Kishor Rath (0000-0003-1620-3008).

Author contributions: Pathak M, Dwivedi SN, Deo SVS and Sreenivas V conceived and designed the study. Study searching was done by Pathak M. Further, Studies screening and selection was done by Pathak M and Thakur B independently and disagreement was resolved by Deo SVS. Pathak M and Thakur B performed data extraction independently. Pathak M did analysis in supervision of Dwivedi SN. All authors were involved in interpretation of the results. The final draft of this manuscript was done by Pathak M and read and approved by all the authors.

Conflict-of-interest statement: The authors deny any conflict of interest.

PRISMA 2009 Checklist statement: The manuscript is designed as per PRISMA 2009 guideline and checklist is provided as supplementary file.

Mona Pathak, Sada Nand Dwivedi, Vishnubhatla Sreenivas, Department of Biostatistics, All India Institute of Medical Sciences, New Delhi 110029, India

Mona Pathak, Bhaskar Thakur, Division of Biostatistics, Kalinga Institute of Medical Sciences, Bhubaneswar 751024, India

SVS Deo, Department of Surgical Oncology, BRAIRCH, All India Institute of Medical Sciences, New Delhi 110029, India

Goura Kishor Rath, Department of Radiotherapy, BRAIRCH, All India Institute of Medical Sciences, New Delhi 110029, India

Corresponding author: Sada Nand Dwivedi, PhD, Professor, Department of Biostatistics, All India Institute of Medical Sciences, Room No.5, New Delhi 110029, India.
dwivedi@aiims.ac.in
Telephone: +91-11-26593387

Abstract

BACKGROUND

Anthracyclines and taxanes are more active group of chemotherapy regimen. Randomized controlled trials (RCTs) reported variable evidences regarding efficacy of taxanes over anthracyclines for tumor response and survival outcomes. The present study compares the relative efficacy of taxanes over anthracyclines using pathological complete response (pCR), clinical responses, breast-conserving surgeries and survival outcomes in female breast cancer patients by systematic review and meta-analysis of available RCTs.

AIM

To assess the effectiveness of taxanes over anthracyclines in neoadjuvant setting in terms of tumor response and survival outcomes.

METHODS

All RCTs assessing efficacy of taxanes over anthracyclines in neoadjuvant setting for management of breast cancer searched through PubMed and Cochrane register of controlled trials on 28 April 2017 and published in English language were considered. Following PRISMA guideline, retrieved records were screened and data were extracted by two independent reviewers. Meta-analysis was performed using fixed effect or random effect method depending on heterogeneity assessed using I^2 statistic. Subgroup meta-analyses on the basis of taxane alone or taxane along with anthracycline in comparison to anthracycline alone were also performed for each considered outcomes.

Manuscript source: Invited manuscript

Received: March 2, 2019
Peer-review started: March 4, 2019
First decision: April 11, 2019
Revised: April 20, 2019
Accepted: April 23, 2019
Article in press: April 23, 2019
Published online: April 30, 2019

P-Reviewer: Cheng TH
S-Editor: Dou Y
L-Editor: A
E-Editor: Wu YXJ

RESULTS
A total of 16 RCTs involving 6752 breast cancer patients were found eligible. Taxanes based chemotherapy significantly improved pCR (n = 7, RR = 1.48, 95%CI: 1.04-2.12), disease free survival [n = 6, RR = 0.89 (0.80-0.99)] and loco-regional recurrence free survival [n = 4, RR = 0.74 (0.59-0.94)]. Interestingly in subgroup analysis, addition of taxane to anthracyclines showed better effectiveness regarding these survivals over anthracyclines than taxane alone over anthracycline.

CONCLUSION
Addition of taxanes to anthracyclines based chemotherapy significantly improves pCR, disease free survival and loco-regional recurrence free survival but with no significant impact on breast conservation rates.

Key words: Docetaxel; Paclitaxel; Epirubicin; Doxorubicin; Pathological complete response; Breast conserving surgery

Core tip: There is contradictory reporting through randomized controlled trials regarding relative efficacy of taxanes over anthracyclines which are used in neo-adjuvant setting for treatment of breast cancer patients. As a first systematic review and Meta analysis on the topic, present study is to assess the relative efficacy of taxanes (docetaxel and paclitaxel) alone or their addition to anthracyclines over anthracyclines alone in terms of pathological complete response, clinical response, breast conserving surgery, survival outcomes and toxicity.

Citation: Pathak M, Dwivedi SN, Deo SVS, Thakur B, Sreenivas V, Rath GK. Effectiveness of taxanes over anthracyclines in neoadjuvant setting: A systematic-review and meta-analysis. *World J Meta-Anal* 2019; 7(4): 170-183
URL: https://www.wjgnet.com/2308-3840/full/v7/i4/170.htm
DOI: https://dx.doi.org/10.13105/wjma.v7.i4.170

INTRODUCTION

Neoadjuvant chemotherapy, given prior to loco-regional treatment (surgery/radiotherapy) is standard of care for locally advanced breast cancer but now became popular for early breast cancer as well[1]. The response to chemotherapy depends on the used regimen. Anthracyclines and taxanes are more active group of chemotherapy regimen used for breast cancer[2]. These regimens are usually administered with other chemotherapy drugs like cyclophosphamide, flurourocil. Anthracyclines based drugs include doxorubicin, epirubicin and mitoxantrone. On the other hand, widely used taxanes, originally identified from plant of genus Taxus, are docetaxel and paclitaxel[3]. Neoadjuvant chemotherapy increases the chance of breast conserving surgery (BCS) but there is no consensus regarding role of chemotherapy drugs in further increasing BCS rate[4,5]. Further, pathological complete response (pCR) to neoadjuvant chemotherapy predict long term survival outcomes as the breast cancer patients achieving pCR have better survival than the patients who do not[6]. The reported results from randomized controlled trials (RCTs) were contradictory as some favored taxanes based chemotherapy over anthracyclines based chemotherapy[7,8] regarding pCR, while some showed the other way[9,10]. The efficacy of taxanes over anthracyclines has been examined and found to be associated with increased overall survival in adjuvant setting[11]. Two reviews have discussed about the relative effectiveness of taxanes but could not synthesize the results for response because of very few RCTs at that point of time[12,13]. Further, these reviews could not comment on the effect of taxanes on long term outcomes. To the best of our knowledge, the relative efficacy of taxanes over anthracyclines has not been synthesized in neoadjuvant setting. Accordingly, present study aims to assess the effectiveness of taxanes based Neoadjuvant chemotherapy in comparison to anthracyclines based neoadjuvant chemotherapy on the basis of pCR, clinical responses, breast conserving surgeries and survival outcomes in female breast cancer patients by systematic review and meta-

analysis of RCTs.

MATERIALS AND METHODS

The present systematic review is designed as per the guidelines of Preferred Reporting Items for Systematic Reviews and Meta-Analysis (PRISMA)[14-16]. This study has been registered with International prospective register of systematic reviews and the registration Number is CRD42016027236.

Eligibility criteria

All RCTs assessing efficacy of taxanes based Neoadjuvant Chemotherapy (NACT) in comparison to anthracyclines based NACT in the management of breast cancer, published in English language were considered. There was no restriction regarding the regimens used in the chemotherapy. The Population, Intervention, Comparator, Outcome and Time considered in the present systematic review is given below: (1) Population**:** Non-metastatic Female Breast Cancer Patients; (2) Intervention: Taxanes (Docetaxel or Paclitaxel); (3) Comparator: Anthracyclines; (4) Outcomes: PCR, overall response (OR) and BCS; (5) Design:RCTs; and (6) Time: Assessed on and up to 28 April 2017.

Outcome definitions

pCR: pCR was reported under three definitions as follows: (1) pCR1: pCR was defined as complete response of primary as well as axilla; (2) pCR2: pCR was defined as complete response of primary regardless of axilla; and (3) pCR3: pCR was defined as complete response of primary allowing for ductal carcinoma *in situ* (DCIS).

Considering variability in the definitions, results were synthesized separately under these three definitions.

OR: OR was defined as complete disappearance of clinically palpable tumor or more than 50% reduction in tumor volume.

BCS: BCS rate was defined as rate of breast conserving surgery, *i.e.*, removal of lump only or removal of partial breast including tumor as well as some normal tissues.

Long term outcomes, *i.e.*, overall survival, disease free survival, loco-regional recurrence free survival and metastasis free survival were also considered as secondary outcomes.

Information sources and study selection

Details of search strategies development as well as electronic search strategies for PubMed and Cochrane register of controlled trials along with methodologies for study selection are available in the published protocol[17]. Data collection process, data extraction tool and method for risk of bias assessment are also available under published protocol. There was no deviation from the published protocol[17].

Summary measures

Effect sizes under consideration were "risk ratio" for all response outcomes and BCS. However, long term outcomes including, overall survival, disease free survival, loco-regional recurrence and distant metastasis, it was "hazards ratio".

Data synthesis and analysis

Statistical heterogeneity was examined by I^2 statistics[18]. Publication bias assessment was performed using Eggers test and visualized using funnel plot[19]. In case of very low extent of heterogeneity (*i.e.*, I^2 = 0-25%), fixed effect method of synthesizing the effect size was used. However, for moderate to large extent of heterogeneity random effect method of meta-analysis was used. All analyses were performed using Stata 14 (StataCorp, Texas, United States) and RevMan 5.3.3, Copenhagen: The Nordic Cochrane Centre, The Cochrane Collaboration, 2014.

Additional analysis

To derive additional inferences, Subgroup analyses were performed for the RCTs comparing taxanes versus anthracycline; and, addition of taxanes to anthracyclines versus anthracyclines under neoadjuvant setting.

RESULTS

Study selection

A total of 16 RCTs comparing effectiveness of taxanes versus anthracyclines involving 6752 breast cancer patients and measuring atleast one of the considered outcomes were found eligible out of 1286 searched records. These details are presented using PRISMA flow chart (Figure 1).

Study characteristics

RCTs assessing the effectiveness of taxanes were sub-divided in two groups, *i.e.*, RCTs comparing taxanes alone to anthracyclines alone[20-23] (n = 5); and RCTs comparing taxanes and anthracyclines together to anthracyclines alone[4-6,9,24-30] (n = 11). Out of these 16 RCTs, 10 RCTs assessed the effectiveness of docetaxel (3 RCT assessed the effectiveness of docetaxel *vs* doxorubicin along with other chemotherapy drugs however 7 RCTs assessed effectiveness of addition of docetaxel to anthracyclines based chemotherapy). However, six RCTs assessed effectiveness of paclitaxel, more precisely two RCT assessed paclitaxel and four RCT assessed addition of paclitaxel to anthracyclines based chemotherapy. The details of Population, intervention and outcome are presented in Table 1.

Risk of bias within studies

Risk of bias was assessed for each individual study using Cochrane bias assessment tool Figure 2. However, overall summary of risk of bias for all considered studies is presented in Figure 3. In summary, there were around 30% of the studies, which did not perform blinding of patients and/or outcome assessment. In addition, a large proportion of the trials did not report sufficient details to judge blinding. However, it is worthwhile to mention here that objective measurement of pCR and BCS was not affected by non-blinding of outcome assessment. But clinical responses might get affected by non-blinding of outcome assessment because of obvious subjectivity.

Publication bias

There was no publication bias for any of the outcomes except OR while assessing the effectiveness of taxane based chemotherapy tested using Egger's test (Table 2) and visualized using Funnel Plots.

Meta-analysis

Pathological complete response: As mentioned earlier, effect sizes were synthesized separately under three definitions of pCR. Considering pCR to breast as well axilla reported under eight RCTs randomizing 1442 patients, 127 (16.8%) in anthracycline arm and 127 (18.5%) in taxane arm achieved pCR. But this increase in pCR with taxane (especially with addition of taxane to anthracycline) was not statistically significant (n = 8, I^2 = 34.4%, RR = 1.14, 95%CI: 0.84-1.55). Further, subgroup analyses also revealed the similar results for anthracycline versus taxane (n = 2, I^2 = 38.3%, RR=0.74, 95%CI: 0.23-2.39) as well as anthracycline versus taxane along with anthracycline (n = 6, I^2 = 41.9%, RR = 1.23, 95%CI: 0.86-1.76). Although some of the RCTs on which evidence is based were non-blinded but objective measurement of pCR would not change drawn evidences which were graded as high (Table 2).

PCR of breast regardless of axilla was reported by seven RCTs randomizing 4007 patients due to inclusion of two large RCTs[26,31] which contribute around 50% in the pooled effect estimates. Out of these seven RCTs, six RCTs assessed the effectiveness of addition of taxanes. pCR by this definition was observed to be 16.8% with anthracycline group and 23.0% in taxane group which was found to be statistically significant because of significant results under two big RCTs involving 390 patients (I^2 = 72.6%, RR = 1.48, 95%CI: 1.04-2.12). Similarly, pCR of breast with DCIS was found to be significantly higher in taxanes group (I^2 = 69.6%, RR = 1.54, 95%CI: 1.11-2.15). Apart from inclusion of some non-blinded trials for the objectively measured outcomes, evidences were downgraded one label to moderate due to high heterogeneity. The third definition of pCR, *i.e.*, allowing for DCIS revealed beneficial effect of addition of taxanes to anthracycline based chemotherapy.

Clinical response: OR measured clinically was higher with taxane based chemotherapy (79.0%) in comparison to anthracycline based chemotherapy (73.5%) (I^2 =69.1%, RR = 1.13, 95%CI: 1.04-1.24). Similarly, addition of taxane based chemotherapy also improved clinical complete response in comparison to anthracyclines alone (I^2 = 49.5%, RR = 1.18, 95%CI: 0.97-1.44). Subjective measurement of these outcomes was based on few non-blinded trials which downgraded the evidence one level. Further, due to high heterogeneity and presence of publication bias, evidence for OR further downgraded to Low but that for complete clinical response remains at moderate level.

Breast conserving surgery: Taxane based chemotherapy could not further improve BCS, weather it was given with or without anthracycline in comparison to

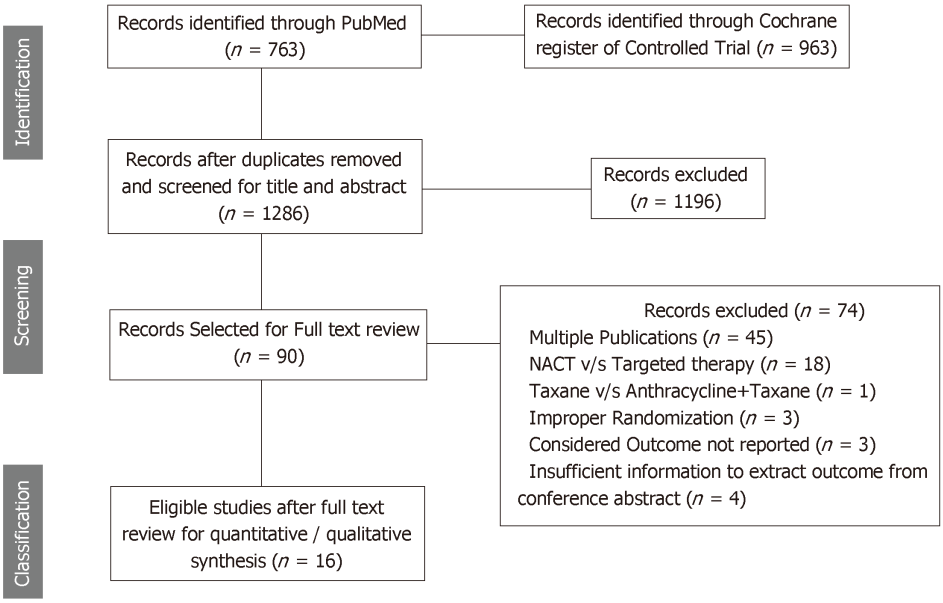

Figure 1 Preferred Reporting Items for Systematic Reviews and Meta-Analysis flow chart for inclusion of studies.

anthracyclines (I^2 = 1%, RR = 1.04, 95%CI: 0.98-1.10) with high grade of evidence.

Survival and recurrences: Long term outcomes like overall survival outcomes, disease free survival and recurrences were reported by very few RCTs. A total of seven RCTs (Three compared taxane v/s anthracycline and four RCTs compared anthracycline + taxane v/s anthracycline) reported overall survival (Table 2). Overall survival was relatively better with taxane based NACT in comparison to anthracyclines but due to few RCTs, it could not reach at significance level [*n* = 7, RR = 0.86 (0.70-1.05)]. However, taxanes based NACT especially addition of taxanes to anthracycline based NACT significantly improved disease-free survival [*n* = 6, RR = 0.89 (0.80-0.99)]. Recurrences, *i.e.*, loco-regional recurrence and distant metastasis were reported by only four RCTs comparing addition of taxanes to anthracycline based NACT in comparison to anthracycline alone. Taxanes played a significant role in combating loco-regional recurrence [RR=0.74 (0.59-0.94)] but not distant metastasis [RR=0.94 (0.82-1.07)].

Toxicities: Meta-analysis of toxicities involve both group of RCTs comparing taxane alone *vs* anthracycline alone as well as taxane and anthracycline combination *vs* anthracycline alone. In comparison to anthracycline based chemotherapy, taxane based chemotherapy was found to lower down the risk for nausea (n=7, RR = 0.33, 95%CI: 0.24-0.44) and vomiting (*n* = 4, RR = 0.23, 95%CI: 0.16-0.33) (Table 3). In contrary, it was found to raise the chance of febrile Neutropenia [*n* = 4, RR = 2.67 (2.33-3.07)] and infection [*n* = 4, RR = 2.53 (2.00-3.19)] significantly. However, due to lack of sufficient sample size/event rate, stable results could not be obtained for allergic reaction, hand foot syndrome, sensory neuropathy, gastrointestinal problems and dermatological problems as the confidence interval of the related risk ratio was observed to be very wide while comparing taxanes and anthracyclines.

DISCUSSION

A total of 16 RCTs assessing efficacy of taxanes based NACT (taxanes alone or addition of taxanes) in comparison to anthracyclines based NACT in the treatment of breast cancer, reporting at least one of the considered outcomes were included for this systematic review and meta analyses. Out of these trials, most of the big RCTs compared addition of taxanes to anthracyclines over anthracyclines (having 86% of the total randomized patients among all 16 RCTs). Meta-analysis sample size varied for outcome-wise synthesis. It was highest with 11 RCTs reporting clinical responses, i.e., OR and clinical complete response. Further, pCR was reported by six to eight RCTs with varying definitions and BCS rates were reported by 9 RCTs. Survival outcomes (overall survival and disease free survival) were reported by only seven RCTs and recurrences (loco-regional recurrences and distant metastasis) were

Table 1 Population, intervention, comparison and outcome characteristics of included studies

Study	Accrual	Population	Regimen Comparison	Outcomes
ABDREEN[9], 2002	104	Locally advanced breast cancer patients in which only responders of previous four cycles of CVAP	Anthracycline Arm: CVAP chemotherapy, comprised of cyclophosphamide (C) 1000 mg/m^2, doxorubicin (A) 50 mg/m^2, vincristine (V) 1.5 mg/m^2 (I.V.), and prednisone 40 mg/d p.o. for 5 d; Taxane Arm: 4 cycles of Docetaxel (D) 100 mg/m^2 was given as an I.V. infusion over 1 h and repeated at 21-d intervals. In addition, these patients received prednisone 100 mg for 5 d, beginning 24 h prior to docetaxel administration.	pCR1, pCR2, OR, cCR, OS
ACCOG[24], 2010	363	Patients with primary tumour>3 cm, inflammatory or locally advanced non-metastatic breast cancer patients	Anthracycline Arm: Six cycles of doxorubicin (60 mg/m^2) and cyclophosphamide (600 mg/m^2) both administered every 3 wk (6xAC); Taxane Arm: Six cycles of doxorubicin (50 mg/m^2) and docetaxel (75 mg/m^2) administered as a 1-h I.V., with both drugs being given every 3 wk (6xAD).	pCR1, pCR2, pCR3, OR, cCR, BCS; Toxicity, OS, DFS, LRR, DM
Amsterdam trial[25], 2005	57	Invasive breast cancer greater than 3 cm and/or at least one tumor-positive auxiliary lymph node	Anthracycline Arm: Six cycles of doxorubicin 60 mg/m^2 and cyclophosphamide 600 mg/m^2 administered every 3 ws (6xAC); Taxane Arm: Six cycles of doxorubicin 50 mg/m^2 and docetaxel 75 mg/m^2 (6xAD) 3 wk.	pCR2,
EORCT BIG-01[26], 2011	1856	Invasive breast cancer <71 years with large operable/inflammatory breast cancer patients suitable for neoadjuvant chemotherapy	Anthracycline Arm: Six cycles of iv FEC (fluorouracil 500 mg/m^2, epirubicin 100 mg/m^2, and cyclophosphamide 500 mg/m^2) or tailored FEC (F600, E75, C900) starting on day 1 and then every 21 d with GCF (6xFEC); Taxane Arm: Three cycles of docetaxel 100 mg/m^2 iv, followed by 3 cycles of epirubicin 90 mg/m^2 and docetaxel 75 mg/m^2 on day 1 every 21 d, without GCF.	pCR2, cCR, BCS; Toxicity
NSABP FB-9[8], 2015	50	HER2 negative breast cancer patients with palpable mass of ≥ 2cm in breast or axilla or inflammatory breast cancer patients	Anthracycline Arm: 4 cycles of Eribuline 1.4 mg/m^2 on days 1 and 8 of a 21-d cycle followed by A60 C600, every 21 d for 4 cycles; Taxane Arm: Weekly Paclitaxel 80 mg/m^2 for 12 doses followed by standard A60C600 every 21 d for 4 cycles.	pCR1, OR, cCR, BCS, Toxicity
Madrid trial[20], 2011	211	Female breast cancer patients aged 18-78 years of clinical stage IIB, IIIA or IIIB and with palpable breast cancer not amenable to BCS	Anthracycline Arm: Four cycles of doxorubicin (75 mg/m^2 body surface area); Taxane Arm: Four cycles docetaxel 100 mg/m^2 with G-CSF support every 3 wk.	pCR1

Saura *et al*[4], 2013	295	Breast cancer patients of stage T2-3N0-3M0	Pretreatment: patients received four cycles of doxorubicin (60mg/m^2 iv) and cyclophosphamide (600 mg/m^2 iv) every 3 wk; Anthracycline Arm: Ixabepilone (40 mg/m^2, 3-h infusion) every 3 wk for 4 cycles; Taxane Arm: paclitaxel (80 mg/m^2, 1-h infusion) weekly for 12 wk.	pCR1, pCR3, OR, cCR, BCS, Toxicity
NCC Korea[21], 2008	209	Previously untreated stage II/III breast cancer patients with auxiliary lymph node involvement of age ≥ 18 years, ECOG performance status ≤ 1	Anthracycline Arm: doxorubicin 60 mg/m^2 IV on day 1 plus cyclophosphamide 600 mg/m^2 IV on day 1 every 3 wk for four cycles; Taxane Arm: docetaxel 75 mg/m^2 1-h infusion on day 1 plus capecitabine 1000 mg/m^2 orally twice daily on days 1-14 every 3 wk for four cycles.	pCR3, OR, cCR, Toxicity, OS, DFS
Norwagian trial[22], 2012	223	Primary stage III breast cancer patients	Anthracycline Arm: 4x Epirubicin 90 mg/m^2 administered at 3 wk interval; Taxane Arm: four cycles of paclitaxel 200 mg/m^2 administered at 3 wk intervals.	OR, cCR, BCS, OS
Learn *et al*[27], 2005	144	Invasive breast carcinoma with clinical staging T1c-T3, N0M0 or T1-3, N1M0	Anthracycline Arm: 4 cycles of doxorubicin and cyclophosphamide (A60 C600) every 21 as well as tamoxifen 20 mg per day for 5 yr as NACT; Taxane Arm: 4 cycles of A60 C600 every 21 d further 4 cycles of docetaxel at 100 mg/m2 every 21 d as NACT; Arm 3 (Docetaxel as ACT): 4x AC as ACT (not part of the current study).	pCR1; OR
Diéras *et al*[5], 2004	240	Breast cancer patients of stage T2-3N0-1M0, who were not assessable for breast conserving surgery	Anthracycline Arm: 4 cycles of A60 C600 i.v. every 21 d; Taxane Arm: doxorubicin 60 mg/m^2 as (IV) bolus during 5 to 15 min immediately followed by paclitaxel 200 mg/m^2 as a 3-h infusion every 21 d for 4 cycles.	pCR3, OR, cCR, cPR, BCS; Toxicity, OS, DFS, LRR, DM
Tabchy *et al*[28], 2010	273	Breast cancer patients with clinical stage I to III	Anthracycline Arm: six courses of 5-fluorouracil (500 mg/m2), doxorubicin50/epirubicine100, and cyclophosphamide (500 mg/m^2) all on day 1 repeated in 21-d cycles; Taxane Arm: 12 courses of weekly paclitaxel (80 mg/m^2/wk) followed four cycles of anthracycline chemotherapy all on day 1 repeated in 21-d cycles.	pCR1; BCS
NSABP-27[6], 2006	2411	Primary operable breast cancer patients with palpable tumor of stage T1c-3, N0-1 M0.	Arm1- 4 cycles of Doxorubicin 60 mg/m^2 Cyclophosphamide 600 mg/m^2 every 3 wk; Arm 2- Doxorubicin 60 mg/m^2 Cyclophosphamide 600 mg/m^2 every 3 wk × 4 followed by Docetaxel 100 mg/m^2 every 3 wk × 4 followed by surgery; Arm3 (ACT arm)- Doxorubicin 60 mg/m^2 Cyclophosphamide 600 mg/m^2 every 3 wk × 4 followed by surgey--> Docetaxel 100 mg/m^2 every 3 wk × 4	pCR2, pCR3, OR, cCR, BCS; Toxicity, OPS, DFS, LRR, DM

Buzdar *et al*[23], 1999	174	Invasive, but non-inflammatory, breast cancer with stage II to IIIA disease	Anthracycline Arm: 4 × FAC (fluorouracil 500, cyclophosphamide 500 mg/m^2, doxorubicin 50 mg/m^2) every 3 wk interval; Taxane Arm: Paclitaxel 250 mg/m^2 as a 24-h continuous infusion at 3-wk intervals for four cycles.	pCR3, OR, cCR, BCS; Toxicity, DFS
Cortés-Flores *et al*[30], 2008	41	Stage IIB and IIIA, locally advanced breast cancer patients	Anthracycline Arm: 5-fluorouracil epirubicine cyclophosphamide; Taxane Arm: docetaxel and epirubicine.	pCR2
Sivasanker *et al*[29],2017	101	Locally advanced breast cancer patients' candidates for NACT	Anthracycline Arm: Cyclophosphamide 500 mg/m^2, Doxorubicin 50 mg/m^2 and 5-FU 500/m^2 as IV infusion repeated every 21 d; Taxane Group: Paclitaxel 175 mg/m^2 as a 3 h IV infusion, Doxorubicin 50 mg/m^2 as IV infusion.	pCR1, pCR2, OR, cCR, BCS

pCR1: Pathological complete response to breast as well as axilla; pCR2: Pathological complete response to breast regardless of axilla; pCR3: Pathological complete response to breast allowing for ductal carcinoma *in situ*; NACT: Neoadjuvant Chemotherapy; OR: Overall response; cCR: Clinical complete response; BCS: Breast conserving surgery; OS: Overall survival; DFS: Disease free survival; LRR: Loco-regional recurrence; DM: Distant metastasis.

reported by only four RCTs assessing the effectiveness of addition of taxanes over anthracyclines alone. Pattern of reported toxicities were also varied among RCTs. Most of the trials (n = 7) reported Neutropenia. All of the included RCTs used proper method for randomization but enough information to assess concealment was not reported by many RCTs. Further, six out of 16 RCTs were open label RCTs and may have an obvious impact on subjectively measured outcomes like OR and clinically complete response. Most of the RCTs have reported results based on intention to treat analysis. Overall, quality of included RCTs can be treated as adequate for objectively measured outcomes. Further, quantity of RCTs was sufficient to assess the relative effectiveness of addition of taxanes to anthracyclines over anthracyclines alone but not for subgroup assessing efficacy of taxanes alone versus anthracyclines alone.

The effectiveness of neoadjuvant chemotherapy depends on the used regimens. Response to neoadjuvant chemotherapy predict the prognosis and recurrence in breast cancer patients regardless of the type of surgery performed[32]. Patients having pCR have prolonged disease-free survival and overall survival. NSABP B-18 and B-27 trials revealed significantly better disease-free survival and overall survival among patients achieving pCR in comparison to the patients who could not[6]. It revealed that pCR is valid surrogate point for long term outcomes. This may be the reason; most of the trials comparing two neoadjuvant chemotherapy regimens reported tumor response instead of survival outcomes. Anthracyclines and taxanes are most active groups of chemotherapy regimens. Taxanes are standard of care for metastatic breast cancer patients because they are significantly more effective than anthracyclines based regimens[33]. Systematic review to assess the role of taxanes was performed a long back in 2004 and 2005 by Nowak *et al*[12] and Trudeau *et al*[13]. But most of the RCTs assessing effectiveness of taxanes over anthracyclines were reported after publication of these two reviews. Further, these two reviews included abstracts of ongoing trials which were not complete at that point of time. Since trials were not mature to report survival outcomes, these two studies could not comment on efficacy of taxanes for long term outcomes like survival and recurrences[13]. Further, Due to availability of very few trials, these two reviews could not perform meta-analysis for response outcomes and limit their finding with qualitative synthesis of these trials. As a matter of fact, present study could be able to quantitatively synthesize the results of tumor responses as well as for long term outcomes like overall survival, disease free survival, loco-regional recurrence and distant metastasis.

Addition of taxanes to anthracyclines based chemotherapy was found to be associated with higher pCR, better disease-free survival and decreased loco-regional recurrence. It was also found beneficial for clinical responses like OR and clinical complete response. But evidences on clinical responses have limited use due to downgrading of their quality because of involvement of some non-blinded trials. Also, clinical response to NACT also guides for further systemic therapy[34,35]. NACT increases the chance of BCS[36] but taxanes could not further improve the conservation

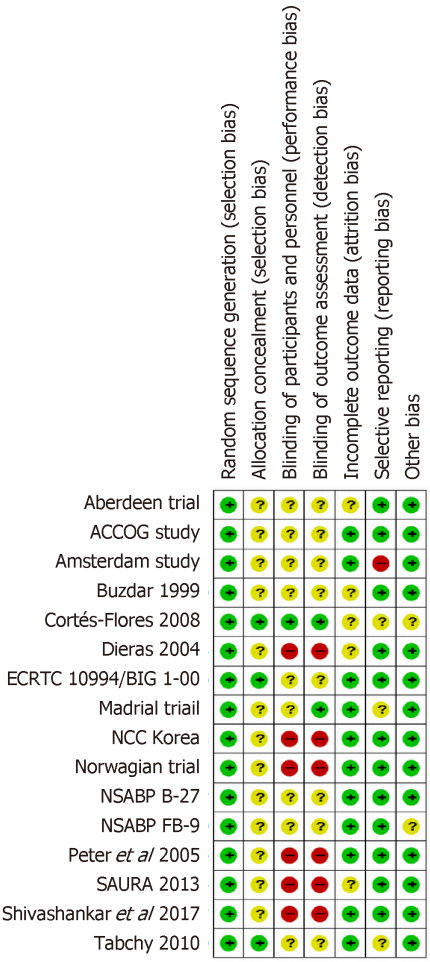

Figure 2 Risk of bias assessed for each individual study using Cochrane bias assessment tool.

surgery rate over anthracyclines alone. Evidences for the subgroup assessing effectiveness of addition of taxanes to anthracyclines over anthracyclines were rated as of high grade and stable due to availability of large RCTs with adequate number. On the other hand, synthesized results for the subgroup comparing taxanes alone to anthracyclines alone involved few RCTs that too of small sample size. Further, the conclusive results for toxicities cannot be summarized because these were reported by very few RCTs and reporting of toxicities also involved variation in their definitions. In summary, addition of taxanes improves pCR, disease free survival and loco-regional recurrence free survival but has no major impact on BCT rates.

Table 2 Subgroup as well as overall meta-analysis for all considered outcomes

Outcome	Sub-Group	Number of studies	Events taxane	Events anthracycline	Egger's test *P*-value	I^2 Statistic	Risk Ratio(95%CI)	Grade
pCR (BA)	Taxane v/s Anthracycline	2	21/125	24/128	-	38.3	0.74 (0.23-2.39)	High
	Taxane + Anthracyline v/s Anthracycline	6	106/562	103/627	0.110	41.9	1.23 (0.86-1.76)	High[1]
	Overall	8	127/687	127/755	0.573	34.4	1.14 (0.84-1.55)	High[1]
pCR (B)	Taxane v/s Anthracycline	1	16/47	8/50	-	-	2.13 (1.01-4.50)	Moderate[2]
	Taxane + Anthracyline v/s Anthracycline	6	443/1951	329/1959	0.475	72.6	1.48 (1.04-2.12)	Moderate[1, 3]
	Overall	7	459/1998	337/2009	0.331	69.6	1.54 (1.11-2.15)	Moderate[1, 3]
pCR (DCIS)	Taxane v/s Anthracycline	2	29/189	24/186	-	85.4	1.06 (0.25-4.47)	Moderate[1, 3]
	Taxane + Anthracyline v/s Anthracycline	4	761/1679	183/683	0.339	71.4	1.23 (0.86-1.75)	Moderate[1, 3]
	Overall	6	790/1868	207/869	0.277	71.7	1.20 (0.84 -1.70)	Moderate[1, 3]
Overall response	Taxane v/s Anthracycline	4	249/356	221/349	0.956	66.2	1.12 (0.94-1.33)	Low[3, 4]
	Taxane + Anthracyline v/s Anthracycline	7	1098/1348	1024/1345	0.045	71.4	1.14 (1.02-1.27)	Low[3, 4]
	Overall	11	1347/1704	1245/1694	0.031	69.1	1.13 (1.04-1.24)	Low[3, 4]
Complete clinical response	Taxane v/s Anthracycline	4	62/356	45/349	0.908	00.0	1.40 (1.01-1.93)	Moderate[4]
	Taxane + Anthracyline v/s Anthracycline	7	548/2231	511/2176	0.273	60.1	1.13 (0.88-1.43)	Low[3, 4]
	Overall	11	610/2587	556/2525	0.106	49.5	1.18 (0.97-1.44)	Moderate[4]
Breast conserving surgery	Taxane v/s Anthracycline	1	40/86	30/85	-	-	1.32 (0.91-1.90)	Moderate[2]
	Taxane + Anthracyline v/s Anthracycline	8	1040/2206	1007/2199	0.633	00.0	1.03 (0.97-1.09)	High[1]
	Overall	9	1080/2292	1037/2284	0.406	01.1	1.04 (0.98-1.10)	High[1]
Overall survival	Taxane v/s Anthracycline	3	18/255	31/251	0.002	74.9	0.41 (0.13-1.31)	Low[1, 35]
	Taxane + Anthracyline v/s Anthracycline	4	424/2026	456/1960	0.899	0.0	0.91 (0.79-1.05)	High[1]
	Overall	7	442/2281	487/2211	0.059	37.4	0.86 (0.70-1.05)	High[1]
Disease free survival	Taxane v/s Anthracycline	3	71/285	84/289	0.144	0.00	0.92 (0.63-1.36)	High[1]
	Taxane + Anthracyline v/s Anthracycline	4	722/2026	772/1958	0.685	0.00	0.89 (0.80-0.99)	High[1]
	Overall	7	793/2311	856/2247	0.791	0.00	0.89 (0.80-0.99)	High[1]
Loco-regional recurrence	Overall	4	120/2026	161/1960	0.808	0.00	0.74 (0.59-0.94)	High
Distant metastasis	Overall	4	426/2026	441/1960	0.264	0.00	0.94 (0.82-1.07)	High

[1]Involves non-blinded RCT(s) but objective measurement will not change the drawn evidences.

[2]Evidence is based on few sample (Imprecise).
[3]Imprecision because of higher heterogeneity (I^2).
[4]Involves non-blinded RCTs which may change the drawn evidence.
[5]Publication Bias.pCR: Pathological complete response; DCIS: Ductal carcinoma *in situ*.

Table 3 Pooled effect estimates for various toxicity in taxanes in comparison to anthracyclines

Toxicity	Number of studies	RR (95%CI)
Hematological toxicity		
Neutropenia	7	1.00 (0.78-1.29)
Febrile neutropenia	4	2.67 (2.33-3.07)
Leucopenia	4	0.72 (0.36-1.45)
Anemia	3	0.75 (0.12-4.53)
Thrombocytopenia	4	0.07 (0.03-0.19)
Thrombosis	2	1.07 (0.59-1.96)
Cardiac and nervous system toxicity		
Neuropathy	2	1.01 (0.35-2.93)
Sensory neuropathy	3	18.26 (5.87-56.80)
Cardiac left ventricular function	1	0.33 (0.01-8.14)
Cardiovascular toxicity	1	2.74 (0.88-8.57)
Dermatological toxicities		
Hand foot syndrome	2	27.43 (3.75-200.84)
Rash	1	8.96 (0.48-166.20)
Dermatological toxicity	2	3.71 (1.18-11.67)
Alopecia	1	0.78 (0.73-0.83)
Diarrhea	5	1.90 (0.97-3.73)
Gastro	1	4.23 (1.43-12.53)
constipation	1	3.49 (0.73-16.73)
Oral toxicities		
Stomatitis	6	1.89 (1.23-2.91)
Musculoskeletal pain	1	1.01 (0.06-15.95)
General toxicity		
Nausea	7	0.33 (0.24-0.44)
Fatigue	5	1.29 (0.96-1.73)
Infection	4	2.53 (2.00-3.19)
Other	6	1.12 (0.61-2.06)
Vomiting	4	0.23 (0.16-0.33)
Allergic reaction	3	21.25 (2.74-164.67)
Myalgia	3	1.99 (0.36-11.01)
Serious adverse event	1	0.65 (0.29-1.45)
edema	1	6.97 (0.36-134.74)
Fever	1	15.85 (0.96-260.89)
Hypotension	1	6.97 (0.36-134.74)
Pulmonary	1	3.54 (0.92-13.65)
Arthelgia	3	0.02 (0.01-0.04)
Bone pain	1	0.07 (0.00-1.17)

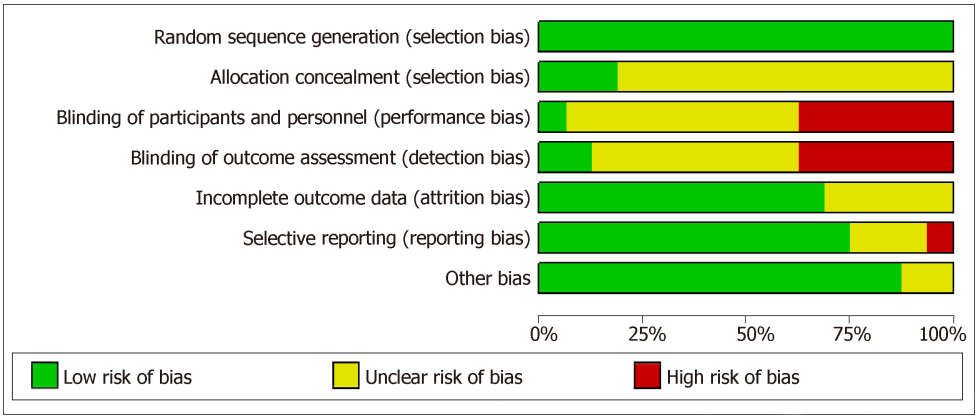

Figure 3 Summary risk of bias using Cochrane bias assessment tool.

ARTICLE HIGHLIGHTS

Research background

There are mainly two active group of chemotherapy regimen namely Anthracyclines and taxanes. Randomized controlled trials (RCTs) have reported variable evidences regarding efficacy of taxanes over anthracyclines especially for tumor response and survival outcomes. Hence, as required, the present study synthesizes the relative efficacy of taxanes over anthracyclines using pathological complete response, clinical responses, breast-conserving surgeries and survival outcomes in female breast cancer patients by systematic review and meta-analysis of available RCTs.

Research motivation

There is contradictory reporting regarding relative efficacy of taxanes over anthracycline. To resolve this, for the first time, present meta-analysis is to assess the relative efficacy of taxanes (Docetaxel and Paclitaxel) alone or their addition to anthracyclines over anthracyclines alone in terms of pCR, clinical response, breast conserving surgery, survival outcomes and toxicity in neo-adjuvant setting. As and when there is further addition in regimes, such appraisals from time to time are unavoidable.

Research objectives

Keeping in view of contradictory reporting, this study aimed to assess the relative effectiveness of taxanes over anthracyclines in neo-adjuvant setting in terms of tumor response and survival outcomes through systematic review and Meta analysis. This was expected to provide important clues regarding appropriate clinical practice.

Research methods

The RCTs have reported contradictory findings on relative effectiveness of taxanes over anthracyclines in neo-adjuvant setting regarding treatment of breast cancer patients. In spite of this, no earlier attempt is made to synthesize relative effectiveness of taxanes over anthracyclines. For the first time, using a focused systematic review and Meta analysis of existing RCTs, this study attempted to synthesize relative effectiveness of taxanes over anthracyclines in terms of pCR, clinical response, BCS, survival outcomes and toxicity in neo-adjuvant setting. For this, all related RCTs were searched through PubMed and Cochrane register of controlled trials on 28 April 2017 and published in English language. Using PRISMA guidelines, retrieved records were screened and data were extracted by two independent reviewers. Depending on heterogeneity assessed through I^2 statistic, Meta-analysis was performed using either fixed effect or random effect method. Subgroup meta-analyses were also performed for each considered outcomes on the basis of taxanes alone or taxanes along with anthracyclines in comparison to anthracyclines alone.

Research results

Through a search through PubMed and Cochrane register of controlled trials on 28 April 2017, for this study, a total of 16 RCTs were found eligible in view of reporting at least one of the considered outcomes. The analytical results revealed that taxanes based chemotherapy significantly improved pCR, disease free survival and loco-regional recurrence free survival. Further, subgroup analysis showed that addition of taxanes to anthracyclines has better effectiveness regarding these survivals over anthracyclines alone than taxanes alone over anthracyclines alone.

Research conclusions

This study hypothesized that effectiveness of neo-adjuvant chemotherapy may rely on used regimens. Keeping in view of varying reporting under related RCTs, as an appraisal, to assess

relative effectiveness of taxanes in comparison to anthracyclines was planned. For this, it was carried out as a first systematic review and Meta analysis of the related RCTS. As obvious, as a first-time observation, the synthesized results suggest that taxanes based chemotherapy may significantly improve pCR, disease free survival and loco-regional recurrence free survival. Further, as additional clues, subgroup analysis showed that addition of Taxanes to anthracyclines emerged to be more effective regarding these survivals over anthracyclines alone than taxanes alone over anthracyclines alone.

Research perspectives

In presence of contradictory findings under RCTs, a systematic review and Meta analysis of available RCTs may provide important clues towards clinical practice. Completeness of data is crucial for such studies. To achieve this, as true in case of other study designs, an appropriate protocol needs to be written for carrying out such studies. Although such studies are being carried out on other study designs as well, to ensure high level of evidence, such studies on RCTs need to be preferred.

REFERENCES

1 **Costa R**, Hansen NM, Gradishar WJ. Locally Advanced Breast Cancer, In: The Breast: Comprehensive Management of Benign and Malignant Diseases. Elsevier Inc. 2017; **e6**: 819-830 [DOI: 10.1016/B978-0-323-35955-9.00063-5]

2 **Anampa J**, Makower D, Sparano JA. Progress in adjuvant chemotherapy for breast cancer: an overview. *BMC Med* 2015; **13**: 195 [PMID: 26278220 DOI: 10.1186/s12916-015-0439-8]

3 **Estévez LG**, Gradishar WJ. Evidence-based use of neoadjuvant taxane in operable and inoperable breast cancer. *Clin Cancer Res* 2004; **10**: 3249-3261 [PMID: 15161677 DOI: 10.1158/1078-0432.CCR-03-0133]

4 **Saura C**, Tseng LM, Chan S, Chacko RT, Campone M, Manikhas A, Nag SM, Leichman CG, Dasappa L, Fasching PA, Hurtado de Mendoza F, Symmans WF, Liu D, Mukhopadhyay P, Horak C, Xing G, Pusztai L. Neoadjuvant doxorubicin/cyclophosphamide followed by ixabepilone or paclitaxel in early stage breast cancer and evaluation of βIII-tubulin expression as a predictive marker. *Oncologist* 2013; **18**: 787-794 [PMID: 23853246 DOI: 10.1634/theoncologist.2013-0075]

5 **Diéras V**, Fumoleau P, Romieu G, Tubiana-Hulin M, Namer M, Mauriac L, Guastalla JP, Pujade-Lauraine E, Kerbrat P, Maillart P, Pénault-Llorca F, Buyse M, Pouillart P. Randomized parallel study of doxorubicin plus paclitaxel and doxorubicin plus cyclophosphamide as neoadjuvant treatment of patients with breast cancer. *J Clin Oncol* 2004; **22**: 4958-4965 [PMID: 15611510 DOI: 10.1200/JCO.2004.02.122]

6 **Rastogi P**, Anderson SJ, Bear HD, Geyer CE, Kahlenberg MS, Robidoux A, Margolese RG, Hoehn JL, Vogel VG, Dakhil SR, Tamkus D, King KM, Pajon ER, Wright MJ, Robert J, Paik S, Mamounas EP, Wolmark N. Preoperative chemotherapy: updates of National Surgical Adjuvant Breast and Bowel Project Protocols B-18 and B-27. *J Clin Oncol* 2008; **26**: 778-785 [PMID: 18258986 DOI: 10.1200/JCO.2007.15.0235]

7 **Romero A**, García-Sáenz JA, Fuentes-Ferrer M, López Garcia-Asenjo JA, Furió V, Román JM, Moreno A, de la Hoya M, Díaz-Rubio E, Martín M, Caldés T. Correlation between response to neoadjuvant chemotherapy and survival in locally advanced breast cancer patients. *Ann Oncol* 2013; **24**: 655-661 [PMID: 23104719 DOI: 10.1093/annonc/mds493]

8 **Abraham J**, Robidoux A, Tan AR, Limentani S, Sturtz K, Shalaby I, Alcorn H, Buyse ME, Wolmark N, Jacobs SA. Phase II randomized clinical trial evaluating neoadjuvant chemotherapy regimens with weekly paclitaxel or eribulin followed by doxorubicin and cyclophosphamide in women with locally advanced HER2-negative breast cancer: NSABP Foundation Study FB-9. *Breast Cancer Res Treat* 2015; **152**: 399-405 [PMID: 26126970 DOI: 10.1007/s10549-015-3466-4]

9 **Heys SD**, Hutcheon AW, Sarkar TK, Ogston KN, Miller ID, Payne S, Smith I, Walker LG, Eremin O; Aberdeen Breast Group. Neoadjuvant docetaxel in breast cancer: 3-year survival results from the Aberdeen trial. *Clin Breast Cancer* 2002; **3** Suppl 2: S69-S74 [PMID: 12435290 DOI: 10.3816/CBC.2002.s.015]

10 **Evans TR**, Yellowlees A, Foster E, Earl H, Cameron DA, Hutcheon AW, Coleman RE, Perren T, Gallagher CJ, Quigley M, Crown J, Jones AL, Highley M, Leonard RC, Mansi JL. Phase III randomized trial of doxorubicin and docetaxel versus doxorubicin and cyclophosphamide as primary medical therapy in women with breast cancer: an anglo-celtic cooperative oncology group study. *J Clin Oncol* 2005; **23**: 2988-2995 [PMID: 15860854 DOI: 10.1200/JCO.2005.06.156]

11 **Fujii T**, Le Du F, Xiao L, Kogawa T, Barcenas CH, Alvarez RH, Valero V, Shen Y, Ueno NT. Effectiveness of an Adjuvant Chemotherapy Regimen for Early-Stage Breast Cancer: A Systematic Review and Network Meta-analysis. *JAMA Oncol* 2015; **1**: 1311-1318 [PMID: 26402167 DOI: 10.1001/jamaoncol.2015.3062]

12 **Nowak AK**, Wilcken NR, Stockler MR, Hamilton A, Ghersi D. Systematic review of taxane-containing versus non-taxane-containing regimens for adjuvant and neoadjuvant treatment of early breast cancer. *Lancet Oncol* 2004; **5**: 372-380 [PMID: 15172358 DOI: 10.1016/S1470-2045(04)01494-9]

13 **Trudeau M**, Sinclair SE, Clemons M; Breast Cancer Disease Site Group. Neoadjuvant taxanes in the treatment of non-metastatic breast cancer: a systematic review. *Cancer Treat Rev* 2005; **31**: 283-302 [PMID: 15916855 DOI: 10.1016/j.ctrv.2005.03.007]

14 **Moher D**, Liberati A, Tetzlaff J, Altman DG; PRISMA Group. Preferred reporting items for systematic reviews and meta-analyses: the PRISMA statement. *Ann Intern Med* 2009; **151**: 264-269, W64 [PMID: 19622511 DOI: 10.7326/0003-4819-151-4-200908180-00135]

15 **Beller EM**, Glasziou PP, Altman DG, Hopewell S, Bastian H, Chalmers I, Gøtzsche PC, Lasserson T, Tovey D; PRISMA for Abstracts Group. PRISMA for Abstracts: reporting systematic reviews in journal and conference abstracts. *PLoS Med* 2013; **10**: e1001419 [PMID: 23585737 DOI: 10.1371/journal.pmed.1001419]

16 **Liberati A**, Altman DG, Tetzlaff J, Mulrow C, Gøtzsche PC, Ioannidis JP, Clarke M, Devereaux PJ, Kleijnen J, Moher D. The PRISMA statement for reporting systematic reviews and meta-analyses of studies that evaluate health care interventions: explanation and elaboration. *PLoS Med* 2009; **6**: e1000100 [PMID: 19621070 DOI: 10.1371/journal.pmed.1000100]

17 **Pathak M**, Dwivedi SN, Deo SVS, Thakur B, Sreenivas V, Rath GK. Neoadjuvant chemotherapy

regimens in treatment of breast cancer: a systematic review and network meta-analysis protocol. *Syst Rev* 2018; **7**: 89 [PMID: 29945652 DOI: 10.1186/s13643-018-0754-1]

18 **Pathak M**, Dwivedi SN, Deo S, Vishnubhatla S, Thakur B. Which is the Preferred Measure of Heterogeneity in Meta-Analysis and Why? A Revisit. *Biostat Biom Open Acc J* 2017; **1**: 55555 [DOI: 10.19080/BBOAJ.2017.01.555555]

19 **Egger M**, Davey Smith G, Schneider M, Minder C. Bias in meta-analysis detected by a simple, graphical test. *BMJ* 1997; **315**: 629-634 [PMID: 9310563 DOI: 10.1136/bmj.315.7109.629]

20 **Martin M**, Romero A, Cheang MC, López García-Asenjo JA, García-Saenz JA, Oliva B, Román JM, He X, Casado A, de la Torre J, Furio V, Puente J, Caldés T, Vidart JA, Lopez-Tarruella S, Diaz-Rubio E, Perou CM. Genomic predictors of response to doxorubicin versus docetaxel in primary breast cancer. *Breast Cancer Res Treat* 2011; **128**: 127-136 [PMID: 21465170 DOI: 10.1007/s10549-011-1461-y]

21 **Lee KS**, Ro J, Nam BH, Lee ES, Kwon Y, Kwon HS, Chung KW, Kang HS, Kim EA, Kim SW, Shin KH, Kim SK. A randomized phase-III trial of docetaxel/capecitabine versus doxorubicin/cyclophosphamide as primary chemotherapy for patients with stage II/III breast cancer. *Breast Cancer Res Treat* 2008; **109**: 481-489 [PMID: 17653851 DOI: 10.1007/s10549-007-9672-y]

22 **Cao MD**, Giskeødegård GF, Bathen TF, Sitter B, Bofin A, Lønning PE, Lundgren S, Gribbestad IS. Prognostic value of metabolic response in breast cancer patients receiving neoadjuvant chemotherapy. *BMC Cancer* 2012; **12**: 39 [PMID: 22277092 DOI: 10.1186/1471-2407-12-39]

23 **Buzdar AU**, Singletary SE, Theriault RL, Booser DJ, Valero V, Ibrahim N, Smith TL, Asmar L, Frye D, Manuel N, Kau SW, McNeese M, Strom E, Hunt K, Ames F, Hortobagyi GN. Prospective evaluation of paclitaxel versus combination chemotherapy with fluorouracil, doxorubicin, and cyclophosphamide as neoadjuvant therapy in patients with operable breast cancer. *J Clin Oncol* 1999; **17**: 3412-3417 [PMID: 10550135 DOI: 10.1200/JCO.1999.17.11.3412]

24 **Mansi JL**, Yellowlees A, Lipscombe J, Earl HM, Cameron DA, Coleman RE, Perren T, Gallagher CJ, Quigley M, Crown J, Jones AL, Highley M, Leonard RC, Evans TR. Five-year outcome for women randomised in a phase III trial comparing doxorubicin and cyclophosphamide with doxorubicin and docetaxel as primary medical therapy in early breast cancer: an Anglo-Celtic Cooperative Oncology Group study. *Breast Cancer Res Treat* 2010; **122**: 787-794 [PMID: 20559708 DOI: 10.1007/s10549-010-0989-6]

25 **Hannemann J**, Oosterkamp HM, Bosch CA, Velds A, Wessels LF, Loo C, Rutgers EJ, Rodenhuis S, van de Vijver MJ. Changes in gene expression associated with response to neoadjuvant chemotherapy in breast cancer. *J Clin Oncol* 2005; **23**: 3331-3342 [PMID: 15908647 DOI: 10.1200/JCO.2005.09.077]

26 **Bonnefoi H**, Piccart M, Bogaerts J, Mauriac L, Fumoleau P, Brain E, Petit T, Rouanet P, Jassem J, Blot E, Zaman K, Cufer T, Lortholary A, Lidbrink E, André S, Litière S, Lago LD, Becette V, Cameron DA, Bergh J, Iggo R; EORTC 10994/BIG 1-00 Study Investigators. TP53 status for prediction of sensitivity to taxane versus non-taxane neoadjuvant chemotherapy in breast cancer (EORTC 10994/BIG 1-00): a randomised phase 3 trial. *Lancet Oncol* 2011; **12**: 527-539 [PMID: 21570352 DOI: 10.1016/S1470-2045(11)70094-8]

27 **Learn PA**, Yeh IT, McNutt M, Chisholm GB, Pollock BH, Rousseau DL, Sharkey FE, Cruz AB, Kahlenberg MS. HER-2/neu expression as a predictor of response to neoadjuvant docetaxel in patients with operable breast carcinoma. *Cancer* 2005; **103**: 2252-2260 [PMID: 15834928 DOI: 10.1002/cncr.21037]

28 **Tabchy A**, Valero V, Vidaurre T, Lluch A, Gomez H, Martin M, Qi Y, Barajas-Figueroa LJ, Souchon E, Coutant C, Doimi FD, Ibrahim NK, Gong Y, Hortobagyi GN, Hess KR, Symmans WF, Pusztai L. Evaluation of a 30-gene paclitaxel, fluorouracil, doxorubicin, and cyclophosphamide chemotherapy response predictor in a multicenter randomized trial in breast cancer. *Clin Cancer Res* 2010; **16**: 5351-5361 [PMID: 20829329 DOI: 10.1158/1078-0432.CCR-10-1265]

29 **Sivasanker M**, Sistla SC, Manwar SA, Vivekanandam S. Clinical and pathologic response following taxane based neoadjuvant chemotherapy in locally advanced breast cancer patients in a tertiary care centre in India. *Indian J Cancer* 2016; **53**: 220-225 [PMID: 28071613 DOI: 10.4103/0019-509X.197715]

30 **Cortés-Flores AO**, Morgan-Villela G, Castro-Cervantes JM, Vázquez-Camacho G, Fuentes-Orozco C, González-Ojeda A. [Neoadjuvant treatment for locally advanced breast cancer. Comparison of two schemes based on docetaxel-epirubicin vs. 5-fluorouracil-epirubicin-cyclophosphamide]. *Cir Cir* 2008; **76**: 23-28 [PMID: 18492416]

31 **Bear HD**, Anderson S, Smith RE, Geyer CE, Mamounas EP, Fisher B, Brown AM, Robidoux A, Margolese R, Kahlenberg MS, Paik S, Soran A, Wickerham DL, Wolmark N. Sequential preoperative or postoperative docetaxel added to preoperative doxorubicin plus cyclophosphamide for operable breast cancer:National Surgical Adjuvant Breast and Bowel Project Protocol B-27. *J Clin Oncol* 2006; **24**: 2019-2027 [PMID: 16606972 DOI: 10.1200/JCO.2005.04.1665]

32 **Hanrahan EO**, Hennessy BT, Valero V. Neoadjuvant systemic therapy for breast cancer: an overview and review of recent clinical trials. *Expert Opin Pharmacother* 2005; **6**: 1477-1491 [PMID: 16086636 DOI: 10.1517/14656566.6.9.1477]

33 **Ghersi D**, Wilcken N, Simes J, Donoghue E. Taxane containing regimens for metastatic breast cancer. *Cochrane Database Syst Rev* 2005; CD003366 [PMID: 15846659 DOI: 10.1002/14651858.CD003366.pub2]

34 **Schott AF**, Hayes DF. Defining the benefits of neoadjuvant chemotherapy for breast cancer. *J Clin Oncol* 2012; **30**: 1747-1749 [PMID: 22508810 DOI: 10.1200/JCO.2011.41.3161]

35 **von Minckwitz G**, Blohmer JU, Costa SD, Denkert C, Eidtmann H, Eiermann W, Gerber B, Hanusch C, Hilfrich J, Huober J, Jackisch C, Kaufmann M, Kümmel S, Paepke S, Schneeweiss A, Untch M, Zahm DM, Mehta K, Loibl S. Response-guided neoadjuvant chemotherapy for breast cancer. *J Clin Oncol* 2013; **31**: 3623-3630 [PMID: 24002511 DOI: 10.1200/JCO.2012.45.0940]

36 **Pathak M**, Deo SVS, Dwivedi SN, Vishnubhatla S, Thakur B, Julka PK, Rath GK. Role of Neoadjuvant Chemotherapy in breast cancer patients: Systematic Review and Meta-analysis. *Indian J Med Pediatr Oncol* 2019 [DOI: 10.4103/ijmpo.ijmpo_21_18]

Published By Baishideng Publishing Group Inc
7041 Koll Center Parkway, Suite 160, Pleasanton, CA 94566, USA
Telephone: +1-925-2238242
Fax: +1-925-2238243
E-mail: bpgoffice@wjgnet.com
Help Desk: https://www.f6publishing.com/helpdesk
https://www.wjgnet.com