


# World Journal of *Clinical Cases*

*World J Clin Cases* 2016 September 16; 4(9): 253-309



## Editorial Board

2012-2016

The *World Journal of Clinical Cases* Editorial Board consists of 503 members, representing a team of worldwide experts in clinical medical research. They are from 57 countries, including Albania (1), Australia (7), Bangladesh (3), Belgium (3), Brazil (9), Bulgaria (1), Canada (10), China (45), Colombia (2), Croatia (4), Cuba (1), Czech Republic (2), Egypt (5), France (4), Germany (12), Greece (15), Hungary (2), India (53), Indonesia (1), Iran (12), Iraq (1), Ireland (1), Israel (5), Italy (55), Japan (34), Jordan (1), Kazakhstan (1), Kuwait (1), Lebanon (3), Malaysia (1), Mexico (1), Morocco (2), Nepal (1), Netherlands (2), New Zealand (2), Nigeria (1), Oman (1), Pakistan (1), Peru (1), Poland (4), Portugal (3), Qatar (1), Romania (3), Saudi Arabia (3), Serbia (4), Singapore (3), Slovakia (2), Slovenia (1), South Korea (27), Spain (9), Sudan (1), Thailand (2), Trinidad and Tobago (1), Tunisia (1), Turkey (29), United Kingdom (22), United States (80).

### EDITORS-IN-CHIEF

Giuseppe Di Lorenzo, *Naples*  
Jan Jacques Michiels, *Rotterdam*  
Sandro Vento, *Astana*  
Shuhei Yoshida, *Chiba*

### GUEST EDITORIAL BOARD MEMBERS

Hung-Yang Chang, *Hsinchu*  
Ning-Chia Chang, *Kaohsiung*  
Yao-Lung Chang, *Tao Yuan*  
Chang-Han Chen, *Kaohsiung*  
Kuen-Bao Chen, *Taichung*  
Shao-Tsu Chen, *Hualien*  
Yen-Hsu Chen, *Kaohsiung*  
Yi-Ming Arthur Chen, *Taipei*  
Chi-Chun Chin, *Taoyuan*  
I-Ching Chou, *Taichung*  
Jun-Te Hsu, *Tao Yuan*  
Shu-Pin Huang, *Kaohsiung*  
Chi-Wen Juan, *Changhua*  
Chih-Yuan Lin, *Taipei*  
Chiung-Chyi Shen, *Taichung*  
Jim Jinn-Chyuan Sheu, *TaiChung*  
Bing-wen Soong, *Taipei*  
Hwei-Fang Tien, *Taipei*  
Rong Kung Tsai, *Hualien*  
Han-Ping Wu, *Taichung*  
Hsu-Heng Yen, *Changhua*

### MEMBERS OF THE EDITORIAL BOARD



**Albania**

Ridvan Alimehmeti, *Tirana*



**Australia**

Jian Yuan Cheng, *Clayton*  
Devang J Desai, *Toowoomba*  
Manuel B Graeber, *Sydney*  
Gulam Khandaker, *Sydney*  
Finlay A Macrae, *Victoria*  
Harunor Rashid, *Sydney*  
Harrison S Weisinger, *Geelong*



**Bangladesh**

Forhad H Chowdhury, *Dhaka*  
Md. Jafrul Hannan, *Chittagong*  
Aliya Naheed, *Dhaka*



**Belgium**

Guy C Cheron, *Brussels*  
Yves Jacquemyn, *Edegem*  
Jean-Yves Reginster, *Liege*



**Brazil**

Everson LDA Artifon, *Sao Paulo*  
Juliano J Cerci, *Sao Paulo*  
Daniel Cesar, *Rio de Janeiro*  
Jose Mario F de Oliveira, *Rio de Janeiro*  
Fabio Francesconi do Valle, *Manaus*  
Marcio A Lopes, *Piracicaba*  
Helio AG Teive, *Curitiba*

Eduardo N Trindade, *Porto Alegre*  
Flavia M Valente, *Sao Paulo*



**Bulgaria**

Plamen K Nedev, *Varna*



**Canada**

Mark O Baerlocher, *Barrie*  
Ali Izadpanah, *Montreal*  
Gang Li, *Vancouver*  
Abdul Q Rana, *Toronto*  
Habib U Rehman, *Regina*  
Consolato M Sergi, *Edmonton*  
Rashmi R Singh, *Vancouver*  
Jennifer L Spratlin, *Edmonton*  
Ted L Tewfik, *Montreal*  
Sam M Wiseman, *Vancouver*



**China**

Shiu-yin Cho, *Hong Kong*  
Lian Duan, *Beijing*  
David Harold Garfield, *Shanghai*  
Yong-Song Guan, *Chengdu*  
Guo-Rong Han, *Nanjing*  
Bin Jiang, *Beijing*  
Alice Pik Shan Kong, *Hong Kong*  
Fung Yee Janet Lee, *Hong Kong*  
Jian-Jun Li, *Beijing*  
Dezhi Mu, *Chengdu*

Simon SM Ng, *Hong Kong*  
 Huai-Yin Shi, *Beijing*  
 Su-Sheng Shi, *Beijing*  
 Xue-Ying Sun, *Harbin*  
 Xue-Rui Tan, *Shantou*  
 Feng Wang, *Shanghai*  
 Gang Wang, *Chengdu*  
 Niansong Wang, *Shanghai*  
 Ge Xiong, *Beijing*  
 Zheng-Feng Yin, *Shanghai*  
 Qing Zhang, *Jingzhou*  
 Ming-Hua Zheng, *Wenzhou*  
 Jun Zhong, *Shanghai*  
 Yan-Ming Zhou, *Xiamen*



#### **Colombia**

Carlos A Calderon-Ospina, *Bogota*  
 Ivan Dario Velez Bernal, *Medellin*



#### **Croatia**

Iva Brcic, *Zagreb*  
 Srdana Culic, *Split*  
 Tomislav Kulis, *Zagreb*  
 Zvonimir Lovric, *Zagreb*



#### **Cuba**

Alain Cruz Portelles, *Holguin*



#### **Czech Republic**

David Bludovsky, *Plzen*  
 Ivo A Marik, *Prague*



#### **Egypt**

RA Ali, *Mansoura*  
 Farid S El-Askary, *Cairo*  
 Sherifa A Hamed, *Assiut*  
 Ahmad Abd-Elgawad Nofal, *Zagazig*  
 Mohamed I Seleem, *Cairo*



#### **France**

Alain Braillon, *Amiens*  
 Isabelle Andrée Chemin, *Lyon*  
 Jean-Francois Emile, *Boulogne*  
 Christophe Martinaud, *Clamart*



#### **Germany**

Sebastian Decker, *Hannover*  
 Michael Froehner, *Dresden*  
 Arndt Hartmann, *Erlangen*  
 Dirk M Hermann, *Essen*  
 Karl-Anton Kreuzer, *Berlin*  
 Wolf C Mueller, *Leipzig*  
 Andres HM Neuhaus, *Berlin*

Ingo S Nolte, *Mannheim*  
 Martin P Schencking, *Witten*  
 Hans-Joachim Schmoll, *Halle*  
 Andreas G Schreyer, *Regensburg*  
 Mathias Z Strowski, *Berlin*



#### **Greece**

Andrew P Andonopoulos, *Patras*  
 Dimitrios Daoussis, *Patras*  
 Ioanna Dimopoulou, *Athens*  
 Moses S Elisaf, *Ioannina*  
 Costas Fourtounas, *Rio-Patras*  
 Olga-Elpis Kolokitha, *Thessaloniki*  
 Marilita M Moschos, *Athens*  
 Nikolaos Papanas, *Alexandroupolis*  
 Athanasios G Papatsois, *Athens*  
 Panagiotis Peitsidis, *Athens*  
 Zervoudis Stephane, *Athens*  
 Konstantinos Tepetes, *Larissa*  
 Apostolos Tsapas, *Thessaloniki*  
 Michail N Varras, *Athens*  
 Dimitrios Vavilis, *Thessaloniki*



#### **Hungary**

Andreas M Fette, *Budapest*  
 Tibor Hortobagyi, *Debrecen*



#### **India**

Subrat K Achaya, *New Delhi*  
 Amit A Agrawal, *Nasik*  
 Hena A Ansari, *Aligarh*  
 M S Ansari, *Meerut*  
 Ashu S Bhalla, *New Delhi*  
 Laxminarayan Bhandari, *Calicut*  
 Sachin A Borkar, *New Delhi*  
 Bhuvan Chanana, *New Delhi*  
 Kanishka Das, *Bangalore*  
 Reena Das, *Chandigarh*  
 Deep Dutta, *Calcutta*  
 Mimi Gangopadhyay, *Siliguri*  
 Rakesh Garg, *New Delhi*  
 Sandeep Grover, *Chandigarh*  
 Meena Gupta, *New Delhi*  
 Mahendra S Hada, *Kota*  
 Produl Hazarika, *Manipal*  
 Sachin B Ingle, *Latur*  
 S Jayaprakash, *Kerala*  
 Parwez S Khan, *Srinagar*  
 Amol Lunkad, *Pune*  
 Nikhil Marwah, *Jaipur*  
 Amit K Mishra, *Indore*  
 Soma Mukherjee, *Bombay*  
 Deb S Nag, *Jamshedpur*  
 Kushal Naha, *Manipal*  
 Janardhanan C Narayanaswamy, *Bangalore*  
 Soubhagya R Nayak, *Mangalore*  
 Narendra Pamidi, *Karnataka*  
 Samir K Praharaj, *Karnataka*  
 Peralam Y Prakash, *Manipal*  
 C S Pramesh, *Mumbai*

Kishore Puthezhath, *Kerala*  
 Harbans S Randhawa, *Delhi*  
 Muthukumaran Rangarajan, *Coimbatore*  
 Sayantan Ray, *Kolkata*  
 Bharat Rekhi, *Bombay*  
 Dhananjaya Sabat, *New Delhi*  
 B Saha, *Calcutta*  
 Sachin C Sarode, *Pune*  
 J Sharma, *Udaipur*  
 Hakim I Showkat, *Srinagar*  
 Rikki Singal, *Mullana*  
 Deepak K Singh, *Jaipur*  
 Yashpal Singh, *Ghaziabad*  
 Shyam Sundar, *Varanasi*  
 Naveen S Tahasildar, *Chandigarh*  
 Devinder M Thappa, *Pondicherry*  
 Pradeep Vaideeswar, *Bombay*  
 Murali P Vettath, *Kozhikode*  
 Mukul Vij, *Chennai*  
 Rajesh Vijayvergiya, *Chandigarh*  
 B Viswanatha, *Bangalore*



#### **Indonesia**

Coen Pramono, *Surabaya*



#### **Iran**

Masoud Amiri, *Shahrekord*  
 Seyyed A Ayatollahi Mousavi, *Kerman*  
 Mostafa Ghanei, *Tehran*  
 Mahdi Malekpour, *Tehran*  
 Setareh Mamishi, *Tehran*  
 Afshin Mohammadi, *Urmia*  
 Mohammad T Rajabi, *South Kargar*  
 Amin Saburi, *Tehran*  
 Maryam Sahebari, *Mashhad*  
 Iman Salahshourifar, *Tehran*  
 Payman Vahedi, *Mashad*  
 Amir R Vosoughi, *Shiraz*



#### **Iraq**

Bassim I Mohammad, *Al-Qadisiya*



#### **Ireland**

Robbie SR Woods, *Dublin*



#### **Israel**

Nimer Assy, *Safed*  
 Gil Bar-Sela, *Haifa*  
 Itzhak Braverman, *Hadera*  
 Gary M Ginsberg, *Jerusalem*  
 Eyal Itshayek, *Jerusalem*



#### **Italy**

Giovanni Addolorato, *Rome*

Piero L Almasio, *Palermo*  
 Francesco Angelico, *Rome*  
 Marialuisa Appetecchia, *Rome*  
 Valeria Barresi, *Messina*  
 Gabrio Bassotti, *San Sisto*  
 Paolo Boffano, *Aosta*  
 Maria L Brandi, *Florence*  
 Michelangelo Buonocore, *Pavia*  
 Giovanni Cammarota, *Rome*  
 Andrea Ciorba, *Ferrara*  
 Lucio Cocco, *Bologna*  
 Carlo Colosimo, *Rome*  
 Alfredo Conti, *Messina*  
 Giovanni Conzo, *Napoli*  
 Gennaro Cormio, *Bari*  
 Luigi De Gennaro, *Rome*  
 Elia De Maria, *Modena*  
 Isidoro Di Carlo, *Catania*  
 Alessandro Federico, *Naples*  
 Gabriella M Ferrandina, *Campobasso*  
 Davide Firinu, *Cagliari*  
 Caterina Foti, *Bari*  
 Gennaro Galizia, *Naples*  
 Silvio Garattini, *Milan*  
 Giampietro Gasparini, *Roma*  
 Giorgio Ghilardi, *Milan*  
 Domenico Girelli, *Verona*  
 Carlo Lajolo, *Rome*  
 Alessandro Landi, *Rome*  
 Salvatore Leonardi, *Catania*  
 Carmela Loguercio, *Naples*  
 Marianna Luongo, *Potenza*  
 Roberto Manfredini, *Ferrara*  
 Annunziato Mangiola, *Rome*  
 Marco Mazzocchi, *Rome*  
 Roberto L Meniconi, *Rome*  
 Marco Milone, *Naples*  
 Paolo Nozza, *Genoa*  
 Pier P Panciani, *Brescia*  
 Desire' Pantalone, *Firenze*  
 Raffaele Pezzilli, *Bologna*  
 Giorgina B Piccoli, *Torino*  
 Roberto Pola, *Rome*  
 Marco Romano, *Naples*  
 Gianantonio Saviola, *Mantua*  
 Stefania Scala, *Naples*  
 Leonardo A Sechi, *Udine*  
 Leonello Tacconi, *Trieste*  
 Matteo Tebaldi, *Ferrara*  
 Riccardina Tesse, *Bari*  
 Tiziano Testori, *Milano*  
 Maddalena Zippi, *Rome*  
 Gian V Zuccotti, *Milan*



#### **Japan**

Ukei Anazawa, *Chiba*  
 Junichi Asaumi, *Okayama*  
 Takashi Asazuma, *Saitama-ken*  
 Norihiro Furusyo, *Fukuoka*  
 Kunihiro Hiraiwa, *Shizuoka*  
 Masaru Ishida, *Tokyo*

Tatsuaki Ishiguro, *Tokyo*  
 Hajime Isomoto, *Nagasaki*  
 Keita Kai, *Saga*  
 Terumi Kamisawa, *Tokyo*  
 Tatsuo Kanda, *Niigata*  
 Yuichi Kasai, *Mie prefecture*  
 Shigeyuki Kawa, *Matsumoto*  
 Kazushi Kishi, *Wakayama*  
 Satoru Kyo, *Ishikawa*  
 Nozomi Majima, *Takatsuki*  
 Kenji Miki, *Tokyo*  
 K Mizumoto, *Fukuoka*  
 Ryuichi Morishita, *Suita*  
 Atsushi Nakajima, *Yokohama*  
 Yuzuru Niibe, *Kanagawa*  
 Rui Niimi, *Mie Prefecture*  
 Masaharu Nomura, *Tokyo*  
 Yosuke Sato, *Niigata*  
 Boban Stanojevic, *Nagasaki*  
 Mitsushige Sugimoto, *Shiga*  
 Haruhiko Sugimura, *Hamamatsu*  
 Keisuke Uehara, *Aichi*  
 Manabu Watanabe, *Tokyo*  
 Takayuki Yamamoto, *Mie*  
 Junkichi Yokoyama, *Tokyo*  
 Yoshihito Yokoyama, *Aomori*  
 Kiyoshi Yoshino, *Osaka*



#### **Jordan**

Khaled M Sarraf, *Amman*



#### **Kuwait**

Naorem G Singh, *Jahra*



#### **Lebanon**

Maroun M Abou-Jaoude, *Beirut*  
 Kassem A Barada, *Beirut*  
 Raja Sawaya, *Beirut*



#### **Malaysia**

Mohamad N Shafiee, *Kuala Lumpur*



#### **Mexico**

Ernesto Roldan-Valadez, *Mexico*



#### **Morocco**

Alae El Koraichi, *Rabat*  
 Faycal Lakhdar, *Rabat*



#### **Nepal**

Laxmi V Ghimire, *Kathmandu*



#### **Netherlands**

Paul E Sijens, *Groningen*



#### **New Zealand**

Rita R Krishnamurthi, *Auckland*  
 K Yun, *Dunedin*



#### **Nigeria**

Shamsideen A Ogun, *Ikorodu*



#### **Oman**

Itrat Mehdi, *Muscat*



#### **Pakistan**

Sabiha Anis, *Karachi*



#### **Peru**

Eduardo Gotuzzo, *Lima*



#### **Poland**

Lukasz S Matuszewski, *Lublin*  
 Tadeusz Robak, *Lodz*  
 Adam Wysokinski, *Lodz*  
 Witold A Zatonski, *Warsaw*



#### **Portugal**

Jorge Alves, *Braga*  
 Gustavo M Rocha, *Oporto*  
 Zacharoula Sidiropoulou, *Barreiro*



#### **Qatar**

Fahmi Y Khan, *Doha*



#### **Romania**

Simona Gurzu, *Targu Mures*  
 Doina Piciu, *Cluj*  
 Mugurel C Rusu, *Bucharest*



#### **Saudi Arabia**

Ahmed Alkhani, *Riyadh*  
 Iqbal A Bukhari, *Al Khobar*  
 Mohamed F Ibrahim, *Riyadh*



#### **Serbia**

Ivona M Djordjevic, *Nish*



Jelena I Lazic, *Belgrade*  
 Momcilo Pavlovic, *Subotica*  
 Mihailo I Stjepanovic, *Belgrade*



#### **Singapore**

Wei-Sheng Chong, *Singapore*  
 Khek-Yu Ho, *Singapore*  
 Yong Kuei Lim, *Singapore*



#### **Slovakia**

Michal Mego, *Bratislava*  
 Pavel Skok, *Maribor*  
 Ivan Varga, *Bratislava*



#### **South Korea**

Young-Seok Cho, *Seoul*  
 Tae Hyun Choi, *Seoul*  
 Yeun-Jun Chung, *Seoul*  
 Ki-Baik Hahm, *Seongnam*  
 Seung-Jae Hyun, *Gyeonggi Do*  
 Soo Bin Im, *Kyungki Do*  
 Soung Won Jeong, *Seoul*  
 Choun-Ki Joo, *Seoul*  
 Chang Moo Kang, *Seoul*  
 Byung-Wook Kim, *Incheon*  
 Gwi Eon Kim, *Seoul*  
 Gyeong-Moon Kim, *Seoul*  
 Hahn Young Kim, *Seoul*  
 Myoung Soo Kim, *Seoul*  
 Seung Taik Kim, *Cheongju*  
 Won Seog Kim, *Seoul*  
 Yoon Jun Kim, *Seoul*  
 Yun-Hee Kim, *Seoul*  
 Sun-Young Lee, *Seoul*  
 Sang-Chul Lim, *Kwangju*  
 Seung Sam Paik, *Seoul*  
 Jae Yong Park, *Taegu*  
 Jong-Ho Park, *Goyang*  
 Jun-Beom Park, *Seoul*  
 Chan Sup Shim, *Seoul*  
 Hae Ryong Song, *Seoul*  
 Hwa-Seung Yoo, *Daejeon*



#### **Spain**

Manuel Benito, *Madrid*  
 Vicente Carreno, *Madrid*  
 Rosa Corcoy, *Barcelona*  
 Exuperio Diez-Tejedor, *Madrid*  
 Carlos Alberto Dussan Luberth, *Torre Vieja*  
 Sergio Fernandez-Pello Montes, *Gijon*  
 Luis I Gonzalez-Granado, *Madrid*  
 Juan D Molina Martin, *Madrid*  
 Tomas Sobrino, *Compostela*



#### **Sudan**

Samir MH Shaheen, *Khartoum*



#### **Thailand**

Sarunyou Chusri, *Songkhla*  
 Weekitt Kittisupamongkol, *Bangkok*



#### **Trinidad and Tobago**

Dale A Maharaj, *Trinidad*



#### **Tunisia**

Makram Koubaa, *Sfax*



#### **Turkey**

Sami Akbulut, *Diyarbakir*  
 Tamer Akca, *Mersin*  
 Cengiz AKKAYA, *Bursa*  
 Ahmet Baydin, *Kurupelit*  
 Hasan Belli, *Istanbul*  
 Serbülent G Beyaz, *Sakarya*  
 Güldeniz K Cakmak, *Kozlu Zonguldak*  
 Turgay Celik, *Ankara*  
 Yasemin B Cihan, *Kayseri*  
 Omur Dereci, *Eskisehir*  
 Mehmet Doganay, *Kayseri*  
 Aylin T Ermercan, *Manisa*  
 Kadir Ertem, *Malatya*  
 Aydin Gulses, *Ankara*  
 Mustafa K Gumus, *Kayseri*  
 F. Neslihan Inal-Emiroglu, *Izmir*  
 Ramazan Kahveci, *Kirikkale*  
 Saadettin Kilickap, *Ankara*  
 Fatih Kucukdurmaz, *Istanbul*  
 Aslihan Kucuker, *Ankara*  
 Nuray B Muluk, *Cankaya*  
 Orhan V Ozkan, *Sakarya*  
 Zeynep Ozkurt, *Istanbul*  
 Mustafa Sahin, *Ankara*  
 Ibrahim Sakcak, *Ankara*  
 Feyzi B Sarica, *Adana*  
 Ilke Sipahi, *Istanbul*  
 Selim Sozen, *Kayseri*  
 Murat Ugurlucan, *Istanbul*



#### **United Kingdom**

Henry DE Atkinson, *London*  
 Ioannis G Baraboutis, *Peterborough*  
 I Beegun, *London*  
 Roy G Beran, *Liverpool*  
 Ricky H Bhogal, *Birmingham*  
 Kuntal Chakravarty, *Essex*  
 Deyaa Elsandabesee, *Great Yarmouth*  
 Radwan Faraj, *South Yorkshire*  
 Babatunde A Gbolade, *Leeds*  
 Sanju George, *Birmingham*  
 David JA Goldsmith, *London*  
 Nadey S Hakim, *London*  
 Koshy Jacob, *Manchester*  
 Andrew RL Medford, *Leicester*

Rahul T Rao, *London*  
 Francis P Rugman, *Preston*  
 Crispin Schneider, *Nottingham*  
 Yousef Shahin, *Hull*  
 Badri M Shrestha, *Sheffield*  
 Jagdeep S Virk, *Harrow*  
 James CL Wong, *Manchester*  
 Kimia Ziahosseini, *Liverpool*



#### **United States**

Doru T Alexandrescu, *New York*  
 Naim Alkhouri, *Cleveland*  
 Mohammad M Alsolaiman, *Lehi*  
 Bhupinder S Anand, *Houston*  
 Suresh J Antony, *El Paso*  
 Normadeane Armstrong, *New York*  
 Wilbert S Aronow, *Valhalla*  
 Hossam M Ashour, *Detroit*  
 Rajendra Badgaiyan, *Buffalo*  
 Joseph R Berger, *Lexington*  
 Dennis A Bloomfield, *New York*  
 Neil F Box, *Aurora*  
 Jeffrey A Breall, *Indianapolis*  
 Susana M Campos, *Boston*  
 Robert Carter III, *San Antonio*  
 Kaisorn L Chaichana, *Baltimore*  
 Antonio J Chamoun, *Thorndale*  
 Vince P Clark, *Albuquerque*  
 Suzanne M Crumley, *Houston*  
 Parakkal Deepak, *Evanston*  
 Yuchuan Ding, *Detroit*  
 C. Donald Combs, *Norfolk*  
 Konstantin H Dragnev, *Lebanon*  
 Cecilia L Dragomir, *New York*  
 Konstantinos P Economopoulos, *Boston*  
 James M Ford, *Stanford*  
 Yun Gong, *Houston*  
 Zeba H Hafeez, *Las Vegas*  
 Ardeshtir Hakam, *Tampa*  
 T. Patrick Hill, *New Brunswick*  
 Hitoshi Hirose, *Philadelphia*  
 Elias Jabbour, *Houston*  
 Robert T Jensen, *Bethesda*  
 Huanguang Jia, *Gainesville*  
 Zhong Jiang, *Worcester*  
 Theodoros Kelesidis, *Los Angeles*  
 Kusum K Kharbanda, *Omaha*  
 Praveen Kumar, *Chicago*  
 Julius GS Latorre, *Syracuse*  
 Guojun Li, *Houston*  
 Sophia Lionaki, *Chapel Hill*  
 Yaling Liu, *Rochester*  
 Marios-Nikolaos Lykissas, *New York*  
 Kenneth Maiese, *Newark*  
 Serge P Marinkovic, *Lafayette*  
 Charles C Matouk, *New Haven*  
 Kapil Mehta, *Houston*  
 Zaher Merhi, *Brooklyn*  
 Ayse L Mindikoglu, *Baltimore*  
 Roberto N Miranda, *Houston*  
 Majaz Moonis, *Worcester*  
 Assad Movahed, *Greenville*  
 Mohammad R Movahed, *Tucson*

Srinivasan Paramasivam, *New York*  
Edwin M Posadas, *Los Angeles*  
Xiaofa Qin, *Newark*  
Michel E Rivlin, *Jackson*  
Jae Y Ro, *Houston*  
Bruce S Rudy, *Hershey*  
Abdulaziz Sachedina, *Charlottesville*  
Ravi P Sahu, *Indianapolis*  
Michael W Schlund, *Baltimore*

Eric L Scott, *Indianapolis*  
Volney L Sheen, *Boston*  
Herrick J Siegel, *Birmingham*  
Subbaya Subramanian, *Minneapolis*  
Jessica D Sun, *South San Francisco*  
Ulas Sunar, *Buffalo*  
Scott Tenner, *Brooklyn*  
Diana O Treaba, *Providence*  
Richard G Trohman, *Chicago*

Ming C Tsai, *New York*  
Vassiliy Tsytsarev, *Baltimore*  
Howard J Worman, *New York*  
Jun Yao, *Chicago*  
Shahram Yazdani, *Los Angeles*  
Panitan Yossuck, *Morgantown*  
Stanley Zaslau, *Morgantown*  
Sheng Zhang, *New Haven*  
Xinmin Zhang, *Philadelphia*



### ORIGINAL ARTICLE

#### Observational Study

- 253 450 nm diode laser: A new help in oral surgery

*Fornaini C, Rocca JP, Merigo E*

### CASE REPORT

- 258 Fluorine-18 fluorodeoxyglucose positron emission tomography/computed tomography evaluation of subcutaneous panniculitis-like T cell lymphoma and treatment response

*Gorodetskiy VR, Mukhortova OV, Aslanidis IP, Klapper W, Probatova NA*

- 264 Small bowel entrapment and ureteropelvic junction disruption associated with L3 Chance fracture-dislocation

*Pesenti S, Blondel B, Faure A, Peltier E, Launay F, Jouve JL*

- 269 Incidentally detected hydatid cyst of the adrenal gland: A case report

*Akbulut S*

- 273 Tuberculosis terminal ileitis: A forgotten entity mimicking Crohn's disease

*Gurzu S, Molnar C, Contac AO, Fetyko A, Jung I*

- 281 Cystic jejunal duplication with Heinrich's type I ectopic pancreas, incidentally discovered in a patient with pancreatic tail neoplasm

*Gurzu S, Bara Jr T, Bara T, Fetyko A, Jung I*

- 285 Tooth loss caused by displaced elastic during simple preprosthetic orthodontic treatment

*Dianiskova S, Calzolari C, Migliorati M, Silvestrini-Biavati A, Isola G, Savoldi F, Dalessandri D, Paganelli C*

- 290 Surgical treatment of cementoblastoma associated with apicoectomy and endodontic therapy: Case report

*Costa BC, de Oliveira GJPL, Chaves MGAM, da Costa RR, Gabrielli MFR, Guerreiro-Tanomaru JM, Tanomaru-Filho M*

- 296 Unique case of oligoastrocytoma with recurrence and grade progression: Exhibiting differential expression of high mobility group-A1 and human telomerase reverse transcriptase

*Gandhi P, Khare R, Niraj K, Garg N, Sorte SK, Gulwani H*

- 302 Gliosarcoma: A rare variant of glioblastoma multiforme in paediatric patient: Case report and review of literature

*Meena US, Sharma S, Chopra S, Jain SK*

- 306**    Huge peripheral primitive neuroectodermal tumor of the small bowel mesentery at nonage: A case report and review of the literature

*Liu Z, Xu YH, Ge CL, Long J, Du RX, Guo KJ*



**ABOUT COVER**

Editorial Board Member of *World Journal of Clinical Cases*, Jong-Ho Park, MD, PhD, Associate Professor, Stroke Division, Department of Neurology, Myongji Hospital, Kwandong University College of Medicine, Goyang 412-270, South Korea

**AIM AND SCOPE**

*World Journal of Clinical Cases* (*World J Clin Cases*, *WJCC*, online ISSN 2307-8960, DOI: 10.12998) is a peer-reviewed open access academic journal that aims to guide clinical practice and improve diagnostic and therapeutic skills of clinicians.

The primary task of *WJCC* is to rapidly publish high-quality Autobiography, Case Report, Clinical Case Conference (Clinicopathological Conference), Clinical Management, Diagnostic Advances, Editorial, Field of Vision, Frontier, Medical Ethics, Original Articles, Clinical Practice, Meta-Analysis, Minireviews, Review, Therapeutics Advances, and Topic Highlight, in the fields of allergy, anesthesiology, cardiac medicine, clinical genetics, clinical neurology, critical care, dentistry, dermatology, emergency medicine, endocrinology, family medicine, gastroenterology and hepatology, geriatrics and gerontology, hematology, immunology, infectious diseases, internal medicine, obstetrics and gynecology, oncology, ophthalmology, orthopedics, otolaryngology, pathology, pediatrics, peripheral vascular disease, psychiatry, radiology, rehabilitation, respiratory medicine, rheumatology, surgery, toxicology, transplantation, and urology and nephrology.

**INDEXING/ABSTRACTING**

*World Journal of Clinical Cases* is now indexed in PubMed, PubMed Central.

**FLYLEAF**

I-V Editorial Board

**EDITORS FOR THIS ISSUE**

Responsible Assistant Editor: *Xiang Li*  
Responsible Electronic Editor: *Ya-Jing Lu*  
Proofing Editor-in-Chief: *Lian-Sheng Ma*

Responsible Science Editor: *Shui Qiu*  
Proofing Editorial Office Director: *Xiu-Xia Song*

**NAME OF JOURNAL**  
*World Journal of Clinical Cases*

**ISSN**  
ISSN 2307-8960 (online)

**LAUNCH DATE**  
April 16, 2013

**FREQUENCY**  
Monthly

**EDITORS-IN-CHIEF**  
**Giuseppe Di Lorenzo, MD, PhD, Professor**, Genitourinary Cancer Section and Rare-Cancer Center, University Federico II of Napoli, Via Sergio Pansini, 5 Ed. 1, 80131, Naples, Italy

**Jan Jacques Michiels, MD, PhD, Professor**, Primary Care, Medical Diagnostic Center Rijnmond Rotterdam, Bloodcoagulation, Internal and Vascular Medicine, Erasmus University Medical Center, Rotterdam, Goodheart Institute and Foundation, Erasmus Tower, Veemnos 13, 3069 AT, Erasmus City, Rotterdam, The Netherlands

**Sandro Vento, MD**, Department of Internal Medicine, University of Botswana, Private Bag 00713, Gaborone, Botswana

**Shuhei Yoshida, MD, PhD**, Division of Gastroenterology, Beth Israel Deaconess Medical Center, Dana 509, Harvard Medical School, 330 Brookline Ave, Boston, MA 02215, United States

**EDITORIAL BOARD MEMBERS**  
All editorial board members resources online at <http://www.wjnet.com/2307-8960/editorialboard.htm>

**EDITORIAL OFFICE**  
Xiu-Xia Song, Director  
Fang-Fang Ji, Vice Director  
*World Journal of Clinical Cases*  
Baishideng Publishing Group Inc  
8226 Regency Drive, Pleasanton, CA 94588, USA  
Telephone: +1-925-2238242  
Fax: +1-925-2238243  
E-mail: [editorialoffice@wjnet.com](mailto:editorialoffice@wjnet.com)  
Help Desk: <http://www.wjnet.com/esps/helpdesk.aspx>  
<http://www.wjnet.com>

**PUBLISHER**  
Baishideng Publishing Group Inc  
8226 Regency Drive, Pleasanton, CA 94588, USA  
Telephone: +1-925-2238242  
Fax: +1-925-2238243  
E-mail: [bpgoffice@wjnet.com](mailto:bpgoffice@wjnet.com)

Help Desk: <http://www.wjnet.com/esps/helpdesk.aspx>  
<http://www.wjnet.com>

**PUBLICATION DATE**  
September 16, 2016

**COPYRIGHT**  
© 2016 Baishideng Publishing Group Inc. Articles published by this Open Access journal are distributed under the terms of the Creative Commons Attribution Non-commercial License, which permits use, distribution, and reproduction in any medium, provided the original work is properly cited, the use is non commercial and is otherwise in compliance with the license.

**SPECIAL STATEMENT**  
All articles published in journals owned by the Baishideng Publishing Group (BPG) represent the views and opinions of their authors, and not the views, opinions or policies of the BPG, except where otherwise explicitly indicated.

**INSTRUCTIONS TO AUTHORS**  
<http://www.wjnet.com/bpg/gerinfo/204>

**ONLINE SUBMISSION**  
<http://www.wjnet.com/esps/>

Observational Study

## 450 nm diode laser: A new help in oral surgery

Carlo Fornaini, Jean-Paul Rocca, Elisabetta Merigo

Carlo Fornaini, Jean-Paul Rocca, Elisabetta Merigo, Micoralis Laboratory EA7354, Faculty of Dentistry, University of Nice, 06357 Nice, France

**Author contributions:** Fornaini C performed surgical procedure; all the authors contributed equally to this work: All participated in the acquisition of the data (VAS, NRS, pictures) and also in the redaction of the article.

**Institutional review board statement:** N/A.

**Informed consent statement:** The described patient gave her informed consent prior to study inclusion.

**Conflict-of-interest statement:** Authors disclosed no potential financial conflict of interest with this study.

**Open-Access:** This article is an open-access article which was selected by an in-house editor and fully peer-reviewed by external reviewers. It is distributed in accordance with the Creative Commons Attribution Non Commercial (CC BY-NC 4.0) license, which permits others to distribute, remix, adapt, build upon this work non-commercially, and license their derivative works on different terms, provided the original work is properly cited and the use is non-commercial. See: <http://creativecommons.org/licenses/by-nc/4.0/>

**Manuscript source:** Invited manuscript

**Correspondence to:** Carlo Fornaini, MD, Micoralis Laboratory EA7354, Faculty of Dentistry, University of Nice, Diablos Bleus Avenue, 06357 Nice, France. [carlo@fornainident.it](mailto:carlo@fornainident.it)  
 Telephone: +33-4-92001111  
 Fax: +33-4-92001263

Received: February 14, 2016  
 Peer-review started: February 16, 2016  
 First decision: March 25, 2016  
 Revised: July 1, 2016  
 Accepted: July 14, 2016  
 Article in press: July 16, 2016  
 Published online: September 16, 2016

### Abstract

#### AIM

To describe the performance of 450 nm diode laser in oral surgery procedures.

#### METHODS

The case described consisted of the removal of a lower lip fibroma through a blue diode laser ( $\lambda = 450$  nm).

#### RESULTS

The efficacy of this device, even at very low power (1W, CW), allows us to obtain very high intra and postoperative comfort for the patient, even with just topical anaesthesia and without needing suture. The healing process was completed in one week and, during the follow-up, the patient did not report any problems, pain or discomfort even without the consumption of any kind of drugs, such as painkillers and antibiotics. The histological examination performed by the pathologist showed a large area of fibrous connective tissue with some portions of epithelium-connective detachments and a regular incision with very scanty areas of carbonization.

#### CONCLUSION

The 450 nm diode laser proved of being very efficient in the oral soft tissue surgical procedures, with no side effects for the patients.

**Key words:** Blue laser; Advantages; Oral surgery; Patient satisfaction

© The Author(s) 2016. Published by Baishideng Publishing Group Inc. All rights reserved.

**Core tip:** In this work we described a single case consisting of the removal of a lower lip fibroma by means of a blue diode laser ( $\lambda = 450$  nm), showing its efficacy even at very low power (1W, CW) and allowing us to

obtain very high intra and postoperative comfort for the patient, even with just topical anaesthesia and without needing suture. The observed healing process after one week and the complete absence of pain during the follow-up without the consumption of any kind of drugs, such as painkillers and antibiotics, together with the perfect histological readability are very great advantages in favour of this surgical approach.

Fornaini C, Rocca JP, Merigo E. 450 nm diode laser: A new help in oral surgery. *World J Clin Cases* 2016; 4(9): 253-257 Available from: URL: <http://www.wjgnet.com/2307-8960/full/v4/i9/253.htm> DOI: <http://dx.doi.org/10.12998/wjcc.v4.i9.253>

## INTRODUCTION

In 1964 Goldman introduced laser technology in dentistry field<sup>[1]</sup> and, even if several authors in those years described several laser applications in dentistry<sup>[2-5]</sup>, only Frame was the first who showed the absence of biological damage in a laser-assisted surgical intervention with CO<sub>2</sub> laser<sup>[6]</sup>.

Many papers described the advantages for laser-assisted oral surgery as the reduction of the surgical time, the absence of bleeding and consequently the good vision of the surgical site, the possibility to avoid infiltrative anaesthesia and suture with a greater compliance for the patient and the better and faster healing process<sup>[7-12]</sup>.

Together with wavelengths specific for soft tissues, thanks to Hibst and Keller, since 1990, we can use also the Erbium laser (2940 nm) for decay removal in restorative dentistry<sup>[13,14]</sup>.

Today, in addition to lasers working in infrared spectrum, for oral surgery we can use wavelengths working in the visible spectrum as Argon laser (435 nm) useful in oral surgery but also in restorative dental field, and KTP laser (532 nm) well working in oral surgery thanks to its characteristics at low parameters and with a good bleeding control<sup>[14-16]</sup>.

Supercontinuum source is a device allowing to evaluate laser-tissue interactions, mainly transmission; an "ex vivo" recent study showed that the lowest transmission is in the blue and green portion of visible spectrum and in the infrared portion ranging from 1300 to 1400 nm<sup>[17]</sup>: These results could justify the utilisation of dental blue laser, considering also the demonstration, by Enwemeka *et al.*<sup>[18]</sup>, of the of blue light capacity to neutralise some bacterial species also being effective on periodontal biofilm, as shown in several *in vitro* studies<sup>[19-21]</sup> as well as in Photodynamic Therapy field on *Streptococcus Mutans* cultures, as described by Merigo *et al.*<sup>[22]</sup>.

Blue light has been evaluated also for its biomodulatory properties, with laser or LED devices, showing positive effects<sup>[23-26]</sup>.

Even if blue laser was previously proposed in den-

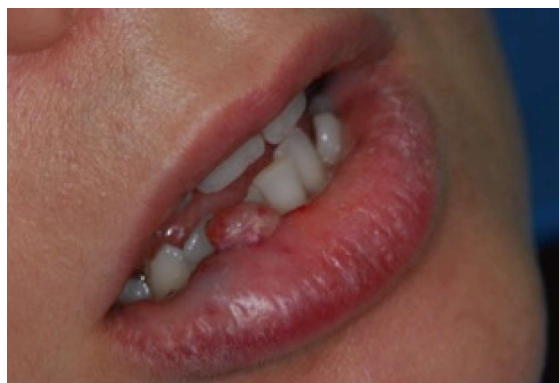

Figure 1 Clinical appearance of the lower lip lesion with aesthetical impairment.

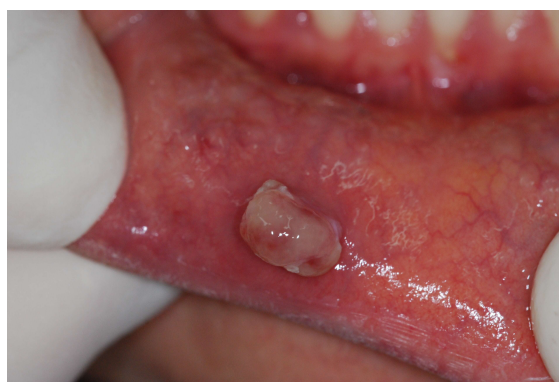

Figure 2 Lower lip fibroma probably caused by a lip biting habit.

tistry field for composite resin polymerization, while argon laser showed its efficacy, diode lasers apparently are not proposed as useful for this use<sup>[27-31]</sup>.

Lately, the combined treatment with blue laser and titanium oxide has been indicated for teeth whitening, but there are still no works describing the utilisation of this wavelength in oral surgery<sup>[32]</sup>.

The purpose of this paper was to demonstrate the advantages of this wavelength in oral soft tissue surgery.

## MATERIALS AND METHODS

The patient ML, a thirty-eight years old female, came to our clinic for the examination of a lesion in the margin of the lower lip. She reported that it had been present for a year and, in the last few months, she had noticed an enlargement of its size (Figures 1 and 2). She required the surgical removal for aesthetical reasons.

She had a medical history without significant diseases and the oral clinical examination did not reveal any suspicious aspect.

The clinical diagnosis was positive for fibroma, probably related to a lip biting habit. Based on the age of the patient, the anatomical area and the size of the lesion, it was decided to perform a laser-assisted surgery session for the lesion removing, so avoiding the complications related to the conventional surgery, such

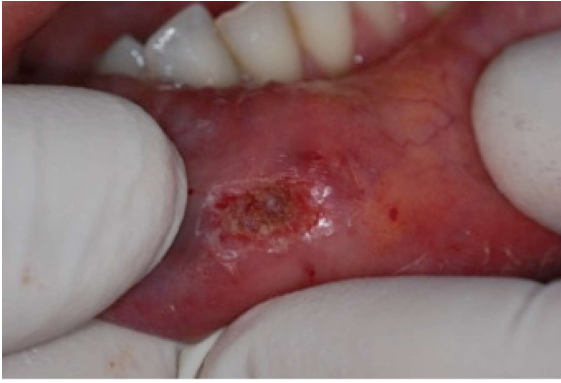

Figure 3 Image of the surgical site immediately after surgery.

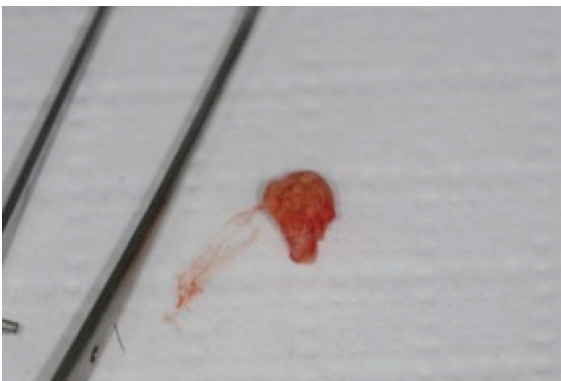

Figure 4 Sample for histological analysis.

as the formation of post-operative scars and bleeding<sup>[33]</sup>. Regarding the choice of the wavelength, in order to limit the thermal elevation and, at the same time, to obtain a good sample for histological observation<sup>[34]</sup> and to offer the patient the most comfort during the healing process, it was decided to use the blue diode laser (Ermes Blue Diode, Gardalaser, Italy,  $\lambda = 450$  nm) with this protocol: Power 1W in CW (Continuous Wave) with an optical fiber of 320  $\mu$ m of diameter in contact mode at a speed of around 5 mm/s (Power density 1244 W/cm<sup>2</sup>, Total fluence: 95790 J/cm<sup>2</sup>).

The patient was informed about all the aspects of the intervention, and she signed the consensus for the surgical removal of the fibroma. The use of anaesthetic injection and the sutures apposition were avoided; only a topical anaesthetic was applied (EMLA, Astratech, Sweden) and the duration of the intervention was 77 s.

The patient was instructed on the need to record the intensity of the pain she felt through a visual analogue scale (VAS) and a numerical rating scale (NRS) every day after surgery beginning with the first day after surgery until the re-evaluation we performed seven days after surgery.

Clinical observations at 1 and 3 mo after surgery did not show any sign of recurrence.

## RESULTS

During the whole duration of the intervention patient

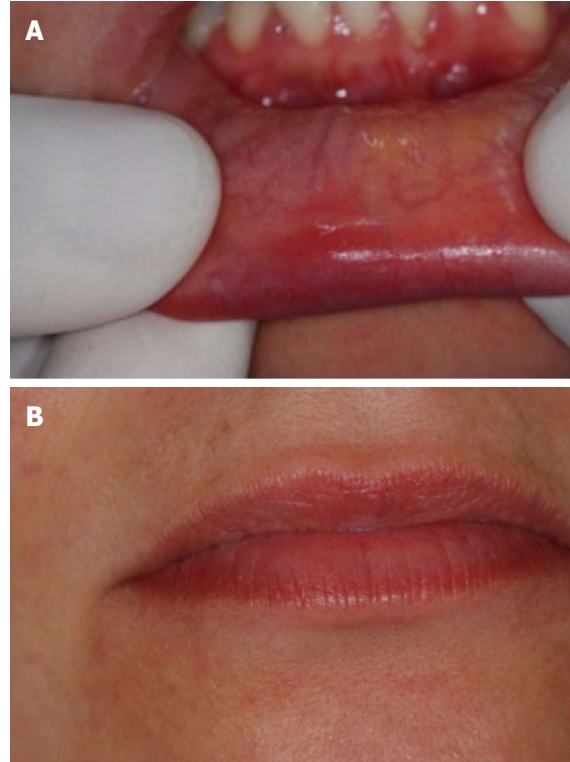


Figure 5 The healing process was completed in seven days. A: Surgical site seven days after surgery; B: Appearance of the lip seven days after surgery with a complete recovering of aesthetic aspect.

described the absence of pain or discomfort.

The site of the lesion, after the removal, did not show any bleeding and did not require any suture (Figure 3).

Both the site and the sample removed did not evidence any sign of carbonization (Figure 4) and the healing process was completed in seven days (Figure 5).

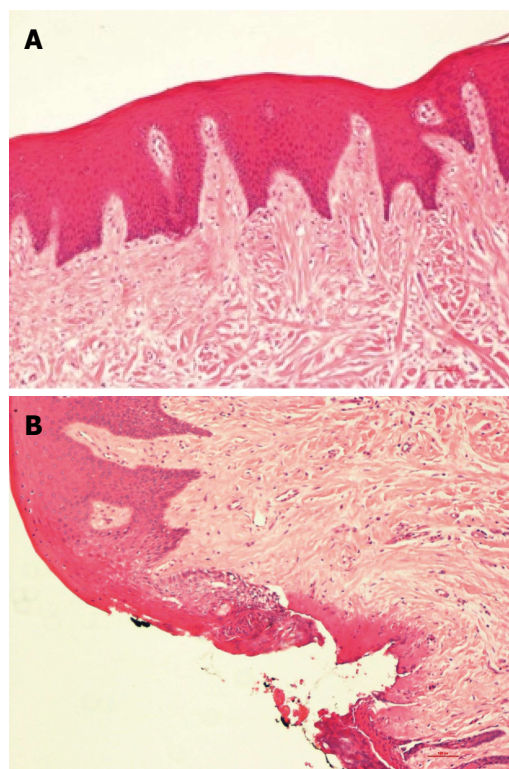
During the follow-up the patient did not take any drugs, such as painkillers and antibiotics, did not reveal any sign of oedema and/or infection and reported that she did not feel any form of pain (VAS and NRS were 0 in every record), discomfort or other problems.

The histological evaluation of the sample, performed by the pathologist, showed a large area of fibrous connective tissue with some portions of epithelium-connective detachments and a regular incision with very scanty areas of carbonization (Figure 6).

## DISCUSSION

This report confirms the advantages of the utilization of 450 nm laser in oral surgery, showing undeniable benefits for its use at very low power. During the operative session it allows for the reduction of the time of the intervention, the avoidance of the anaesthetic injection and the control of the tissue bleeding. From the patient's comfort point of view, it allows us to minimize the pain and avoid the use of suture. During the follow-up, the use of drugs is not requested, and pain, discomfort, oedema and infection are not present. The healing process is very fast and was completed in a





**Figure 6** A large area of fibrous connective tissue with some portions of epithelium-connective detachments and a regular incision with very scanty areas of carbonization. A: Fibrous connective tissue without signs of inflammation; B: Regular incision with discrete signs of coagulations.

week without side effects.

From the histological point of view, the sample removed shows significantly fewer zones of carbonization, so as avoiding the risk of the impossibility of not being able to make a correct diagnosis of the lesion. This technique may be considered a good approach in oral soft tissues surgery.

## COMMENTS

### Background

Many papers described the advantages for laser-assisted oral surgery as the reduction of the surgical time, the absence of bleeding and consequently the good vision of the surgical site, the possibility to avoid infiltrative anaesthesia and suture with a greater compliance for the patient and the better and faster healing process. Blue light has been evaluated for its biomodulatory properties, with laser or LED devices, and for its usefulness in dental bleaching procedures, showing positive effects.

### Research frontiers

Actually there are still no works describing the utilisation of this wavelength in oral surgery. The purpose of this paper was to demonstrate the advantages of this wavelength in oral soft tissue surgery.

### Innovations and breakthroughs

This report confirms the advantages of the utilization of 450 nm laser in oral surgery, showing undeniable benefits for its use at very low power. During the operative session it allows for the reduction of the time of the intervention, the avoidance of the anaesthetic injection and the control of the tissue bleeding. From the patient's comfort point of view, it allows us to minimize the pain and avoid the use of suture. During the follow-up, the use of drugs is not requested,

and pain, discomfort, oedema and infection are not present. The healing process is very fast and was completed in a week without side effects. From the histological point of view, the sample removed shows significantly fewer zones of carbonization, so as avoiding the risk of the impossibility of not being able to make a correct diagnosis of the lesion.

### Applications

This technique may be considered a good approach in oral soft tissues surgery.

### Terminology

CW or continuous wave is a working mode of laser devices. VAS or visual analogue scale and NRS or numerical rating scale are two methods to evaluate the discomfort or pain felt by the patient in the intra and postoperative period.

### Peer-review

Interesting case report of the use of blue diode laser for the removal of oral and intraoral soft tissue benign tumors. The case report is well written with a comprehensive description of the application of the blue diode laser.

## REFERENCES

- 1 **Goldman L**, Gray JA, Goldman J, Goldman B, Meyer R. Effect of laser beam impacts on teeth. *J Am Dent Assoc* 1965; **70**: 601-606 [PMID: 14245324 DOI: 10.14219/jada.archive.1965.0260]
- 2 **Kinersly T**, Jarabak JP, Phatak NM, Dement J. Laser effects on tissue and materials related to dentistry. *J Am Dent Assoc* 1965; **70**: 593-600 [PMID: 14245323 DOI: 10.14219/jada.archive.1965.0268]
- 3 **Morrant GA**. Lasers: an appraisal of their possible use in dentistry. *Dent Pract Dent Rec* 1965; **16**: 5-9 [PMID: 5212929]
- 4 **Stern RH**, Sognnaes RF. Laser effect on dental hard tissues. a preliminary report. *J South Calif Dent Assoc* 1965; **33**: 17-19 [PMID: 14241171]
- 5 **Taylor R**, Shklar G, Roeber F. The effects of laser radiation on teeth, dental pulp, and oral mucosa of experimental animals. *Oral Surg Oral Med Oral Pathol* 1965; **19**: 786-795 [PMID: 14293970 DOI: 10.1016/0030-4220(65)90351-8]
- 6 **Basu MK**, Frame JW, Rhys Evans PH. Wound healing following partial glossectomy using the CO2 laser, diathermy and scalpel: a histological study in rats. *J Laryngol Otol* 1988; **102**: 322-327 [PMID: 3385322 DOI: 10.1017/S0022215100104852]
- 7 **Vescovi P**, Del Vecchio A, Manfredi M, Fornaini C, Tenore G, Romeo U. The use of laser for treatment of oral mucosal diseases. *Dental Cadmos* 2009; **77**: 10
- 8 **Tuncer I**, Ozçakir-Tomruk C, Sencift K, Cöloğlu S. Comparison of conventional surgery and CO2 laser on intraoral soft tissue pathologies and evaluation of the collateral thermal damage. *Photomed Laser Surg* 2010; **28**: 75-79 [PMID: 19715451 DOI: 10.1089/pho.2008.2353]
- 9 **Fornaini C**, Rocca JP, Bertrand MF, Merigo E, Nammour S, Vescovi P. Nd: YAG and diode laser in the surgical management of soft tissues related to orthodontic treatment. *Photomed Laser Surg* 2007; **25**: 381-392 [PMID: 17975951 DOI: 10.1089/pho.2006.2068]
- 10 **Rocca JP**. Les lasers en odontologie. France: Walters Kluwer, 2008
- 11 **Fornaini C**. Case report: Use of Er: YAG and Nd: YAG lasers during orthodontic treatment. *Journal of the Laser and Health Academy* 2014; **1**: 47-54
- 12 **Fornaini C**, Rocca JP. Oral Laserology. Italy: Monduzzi Editore, Bologna, 2015
- 13 **Hibst R**, Keller U. Experimental studies of the application of the Er: YAG laser on dental hard substances: I. Measurement of the ablation rate. *Lasers Surg Med* 1989; **9**: 338-344 [PMID: 2761329 DOI: 10.1002/lsm.1900090405]
- 14 **Majaron B**, Plestenjak P, Lukac M. Thermo-mechanical laser ablation of soft tissue: modeling the micro-explosions. *Appl Phys B* 1999; **69**: 71-80 [DOI: 10.1007/s003400050772]

- 15 **Kelsey WP**, Blankenau RJ, Powell GL. Application of the argon laser to dentistry. *Lasers Surg Med* 1991; **11**: 495-498 [PMID: 1753844 DOI: 10.1002/lsm.1900110602]
- 16 **Fornaini C**, Rocca JP, Merigo E, Meleti M, Manfredi M, Nammour S, Vescovi P. Low energy KTP laser in oral soft tissue surgery: A 52 patients clinical study. *Med Oral Patol Oral Cir Bucal* 2012; **17**: e287-e291 [PMID: 22143694 DOI: 10.4317/medoral.17428]
- 17 **Fornaini C**, Sozzi M, Merigo E, Poli F, Selleri S, Pasotti P, Cucinotta A. Different wavelengths absorption in different tissue kinds: ex vivo study with a supercontinuum broadband source. *Las Surg Med* 2015; **47**: 380-381 [DOI: 10.1002/lsm.2235]
- 18 **Enwemeka CS**. Antimicrobial blue light: an emerging alternative to antibiotics. *Photomed Laser Surg* 2013; **31**: 509-511 [PMID: 24138170 DOI: 10.1089/pho.2013.9871]
- 19 **Bumah VV**, Masson-Meyers DS, Cashin SE, Enwemeka CS. Wavelength and bacterial density influence the bactericidal effect of blue light on methicillin-resistant *Staphylococcus aureus* (MRSA). *Photomed Laser Surg* 2013; **31**: 547-553 [PMID: 23621894 DOI: 10.1089/pho.2012.3461]
- 20 **de Sousa NT**, Santos MF, Gomes RC, Brandino HE, Martinez R, de Jesus Guirro RR. Blue Laser Inhibits Bacterial Growth of *Staphylococcus aureus*, *Escherichia coli*, and *Pseudomonas aeruginosa*. *Photomed Laser Surg* 2015; **33**: 278-282 [PMID: 25954830 DOI: 10.1089/pho.2014.3854]
- 21 **Fontana CR**, Song X, Polymeri A, Goodson JM, Wang X, Soukos NS. The effect of blue light on periodontal biofilm growth in vitro. *Lasers Med Sci* 2015; **30**: 2077-2086 [PMID: 25759232 DOI: 10.1007/s10103-015-1724-7]
- 22 **Merigo E**, Sozzi M, Ciociola T, Conti S, Fornaini C, Selleri S, Cucinotta A. Photodynamic therapy: a synergy between light and colors. Proceedings of the SPIE, Volume 9306, id. 93060A 8 pp. United States: Spie Bios, 2015 [DOI: 10.1117/12.2079131]
- 23 **Smith KC**. Laser (and LED) therapy is phototherapy. *Photomed Laser Surg* 2005; **23**: 78-80 [PMID: 15782040 DOI: 10.1089/pho.2005.23.78]
- 24 **Adamskaya N**, Dungal P, Mittermayr R, Hartinger J, Feichtinger G, Wassermann K, Redl H, van Griensven M. Light therapy by blue LED improves wound healing in an excision model in rats. *Injury* 2011; **42**: 917-921 [PMID: 22081819 DOI: 10.1016/j.injury.2010.03.023]
- 25 **Kushibiki T**, Tajiri T, Ninomiya Y, Awazu K. Chondrogenic mRNA expression in prechondrogenic cells after blue laser irradiation. *J Photochem Photobiol B* 2010; **98**: 211-215 [PMID: 20163967 DOI: 10.1016/j.jphotobiol.2010.01.008]
- 26 **Omi T**, Bjerring P, Sato S, Kawana S, Hankins RW, Honda M. 420 nm intense continuous light therapy for acne. *J Cosmet Laser Ther* 2004; **6**: 156-162 [PMID: 15545101 DOI: 10.1080/14764170410023785]
- 27 **Meniga A**, Tarle Z, Ristic M, Sutalo J, Pichler G. Pulsed blue laser curing of hybrid composite resins. *Biomaterials* 1997; **18**: 1349-1354 [PMID: 9363334 DOI: 10.1016/S0142-9612(97)00047-1]
- 28 **Fleming MG**, Mailliet WA. Photopolymerization of composite resin using the argon laser. *J Can Dent Assoc* 1999; **65**: 447-450 [PMID: 10518340]
- 29 **Mirsasaani SS**, Atai MM, Hasani-Sadabadi MM. Photopolymerization of a dental nanocomposite as restorative material using the argon laser. *Lasers Med Sci* 2011; **26**: 553-561 [PMID: 19618232 DOI: 10.1007/s10103-009-0699-7]
- 30 **Fornaini C**, Lagori G, Merigo E, Rocca JP, Chiusano M, Cucinotta A. 405 nm diode laser, halogen lamp and LED device comparison in dental composites cure: an "in vitro" experimental trial. *Laser Ther* 2015; **24**: 265-274 [PMID: 26877591 DOI: 10.5978/islm.15-OR-16]
- 31 **Ro JH**, Son SA, Park JK, Jeon GR, Ko CC, Kwon YH. Effect of two lasers on the polymerization of composite resins: single vs combination. *Lasers Med Sci* 2015; **30**: 1497-1503 [PMID: 25895056 DOI: 10.1007/s10103-015-1753-2]
- 32 **Tano E**, Otsuki M, Kato J, Sadr A, Ikeda M, Tagami J. Effects of 405 nm diode laser on titanium oxide bleaching activation. *Photomed Laser Surg* 2012; **30**: 648-654 [PMID: 23003121 DOI: 10.1089/pho.2012.3273]
- 33 **Yagüe-García J**, España-Tost AJ, Berini-Aytés L, Gay-Escoda C. Treatment of oral mucocoele-scalpel versus CO2 laser. *Med Oral Patol Oral Cir Bucal* 2009; **14**: e469-e474 [PMID: 19415059]
- 34 **Vescovi P**, Merigo E, Fornaini C, Rocca JP, Nammour S. Thermal increase in the oral mucosa and in the jawbone during Nd: YAG laser applications. Ex vivo study. *Med Oral Patol Oral Cir Bucal* 2012; **17**: e697-e704 [PMID: 22322506 DOI: 10.4317/medoral.17726]

**P- Reviewer:** Ebid AA, Rapidis AD    **S- Editor:** Qiu S    **L- Editor:** A  
**E- Editor:** Lu YJ



## Fluorine-18 fluorodeoxyglucose positron emission tomography/computed tomography evaluation of subcutaneous panniculitis-like T cell lymphoma and treatment response

Vadim R Gorodetskiy, Olga V Mukhortova, Irakli P Aslanidis, Wolfram Klapper, Natalya A Probatova

Vadim R Gorodetskiy, Department of Intensive Methods of Therapy, V.A. Nasonova Research Institute of Rheumatology, Russian Academy of Medical Sciences, 115522 Moscow, Russia

Olga V Mukhortova, Irakli P Aslanidis, Department of Nuclear Diagnostics, Bakoulev Scientific Center for Cardiovascular Surgery, 121552 Moscow, Russia

Wolfram Klapper, Department of Pathology, Hematopathology Section and Lymph Node Registry, Christian-Albrecht University Kiel and University Hospital Schleswig-Holstein, 24105 Kiel, Germany

Natalya A Probatova, Department of Pathology, N.N. Blokhin Russian Cancer Research Center, Russian Academy of Medical Sciences, 115478 Moscow, Russia

**Author contributions:** Gorodetskiy VR designed the report, analyzed the data and wrote the paper; Mukhortova OV and Aslanidis IP performed the FDG PET/CT; Klapper W and Probatova NA performed the histological and immunohistochemical studies.

**Institutional review board statement:** The study was reviewed and approved by the Institutional Review Board of the V.A. Nasonova Research Institute of Rheumatology, Russian Academy of Medical Sciences.

**Informed consent statement:** All study participants provided informed written consent prior to study enrollment.

**Conflict-of-interest statement:** The authors declare that they have no conflict of interests regarding the publication of this study.

**Open-Access:** This article is an open-access article which was selected by an in-house editor and fully peer-reviewed by external reviewers. It is distributed in accordance with the Creative Commons Attribution Non Commercial (CC BY-NC 4.0) license, which permits others to distribute, remix, adapt, build upon this work non-commercially, and license their derivative works on

different terms, provided the original work is properly cited and the use is non-commercial. See: <http://creativecommons.org/licenses/by-nc/4.0/>

**Manuscript source:** Invited manuscript

**Correspondence to:** Vadim R Gorodetskiy, MD, PhD, Department of Intensive Methods of Therapy, V.A. Nasonova Research Institute of Rheumatology, Russian Academy of Medical Sciences, Kashirskoye Shosse 34A, 115522 Moscow, Russia. [gorodetskiyblood@mail.ru](mailto:gorodetskiyblood@mail.ru)  
**Telephone:** +7-916-5178192  
**Fax:** +7-499-6144468

**Received:** March 28, 2016  
**Peer-review started:** March 28, 2016  
**First decision:** June 16, 2016  
**Revised:** June 22, 2016  
**Accepted:** July 11, 2016  
**Article in press:** July 13, 2016  
**Published online:** September 16, 2016

### Abstract

Subcutaneous panniculitis-like T cell lymphoma (SPTCL) is a very rare variant of non-Hodgkin's lymphoma. Currently, there is no standard imaging method for staging of SPTCL nor for assessment of treatment response. Here, we describe our use of fluorine-18 fluorodeoxyglucose (FDG) positron emission tomography/computed tomography (PET/CT) for staging and monitoring of treatment response in 3 cases of SPTCL. Primary staging by PET/CT showed that all 3 patients had multiple foci in the subcutaneous fat tissue, with SUVmax from 10.5 to 14.6. Involvement of intra-abdominal fat with high SUVmax was identified in 2 of the patients. Use of the triple drug regimen of gemcitabine, cisplatin and methylprednisolone (commonly known as "GEM-P") as first-line therapy

or second-line therapy facilitated complete metabolic response for all 3 cases. FDG PET/CT provides valuable information for staging and monitoring of treatment response and can reveal occult involvement of the intra-abdominal visceral fat. High FDG uptake on pre-treatment PET can identify patients with aggressive disease and help in selection of first-line therapy.

**Key words:** Staging; Subcutaneous panniculitis-like T cell lymphoma; Positron emission tomography; Treatment; Non-Hodgkin's lymphoma

© **The Author(s) 2016.** Published by Baishideng Publishing Group Inc. All rights reserved.

**Core tip:** We used fluorine-18 fluorodeoxyglucose (FDG) positron emission tomography/computed tomography (PET/CT) for staging and monitoring of treatment response in 3 cases of subcutaneous panniculitis-like T cell lymphoma (SPTCL), a very rare variant of non-Hodgkin's lymphoma. FDG PET/CT provided valuable information for SPTCL staging and monitoring of treatment response in the patients. It can reveal occult involvement of the intra-abdominal visceral fat and identify patients with aggressive SPTCL disease.

Gorodetskiy VR, Mukhortova OV, Aslanidis IP, Klapper W, Probatova NA. Fluorine-18 fluorodeoxyglucose positron emission tomography/computed tomography evaluation of subcutaneous panniculitis-like T cell lymphoma and treatment response. *World J Clin Cases* 2016; 4(9): 258-263 Available from: URL: <http://www.wjgnet.com/2307-8960/full/v4/i9/258.htm> DOI: <http://dx.doi.org/10.12998/wjcc.v4.i9.258>

## INTRODUCTION

Subcutaneous panniculitis-like T cell lymphoma (SPTCL) was first defined as a clinical entity in 1991, and described as a cytotoxic T cell lymphoma that preferentially infiltrates the subcutaneous tissue<sup>[1]</sup>. Patients present with multiple subcutaneous nodules, usually exclusively, with no other involved sites<sup>[2-5]</sup>. The original description of SPTCL was further refined in 2008 by the World Health Organization, which restricted the classification to exclude  $\gamma\delta$ T cell lymphoma<sup>[2]</sup>. To date, SPTCL remains a very rare variant of non-Hodgkin's lymphoma, and the hematologist faces several unresolved issues in the management of patients with SPTCL. The best imaging method for staging of SPTCL and assessment of response to treatment in patients is controversial.

We report here 3 cases of SPTCL that were examined by positron emission tomography (PET) with fluorine-18 fluorodeoxyglucose (FDG) combined with computed tomography (CT) in order to determine their disease stage and to monitor their treatment response.

## CASE REPORT

All 3 cases of SPTCL were diagnosed in the V.A. Nasonova Research Institute of Rheumatology (Moscow, Russia). On admission to the Institute, each patient underwent laboratory testing for complete blood count, urinalysis, blood chemistry and immunological analysis, the latter of which included measurement of antinuclear antibodies by indirect immunofluorescence test and of antibody titer for double-stranded DNA, Sm, anti-Ro and anti-La. In addition, histological and cytological examination of the bone marrow was performed. Formalin-fixed and paraffin-embedded skin biopsy specimens were also reviewed by 2 pathologists working independently (Wolfram Klapper and Natalya A Probatova), which was followed by immunohistochemical staining and molecular analyses. The immunohistochemical study of paraffin-embedded sections was performed using a wide panel of antibodies, including CD2, CD3, CD4, CD5, CD7, CD8, CD10, CD20, CD56, CD68, CD138, VS38c, Ki67 (proliferation marker, expressed as %), granzyme B, TIA1, perforin,  $\beta$ F1 and TdT. The T cell receptor (TCR) C gamma M1-antibody (gamma 3.20; Pierce Biotechnology, Rockford, IL, United States) was used for staining of TCR $\gamma$ .

Determination of T cell clonality by investigating rearrangements of the genes encoding the gamma, beta and delta chains of TCRs was carried out on paraffin-embedded tissue blocks using the polymerase chain reaction (PCR) followed by fragment analysis as described previously<sup>[6,7]</sup>.

All patients underwent whole-body FDG PET/CT, with calculation of the maximum standardized FDG accumulation in pathological foci (standard uptake value, SUV<sub>max</sub>). FDG PET/CT studies were performed before treatment, during the treatment, and 1 mo after completion of chemotherapy.

The complete resolution of FDG uptake at sites of initial disease and the absence of new uptake areas were considered to indicate complete metabolic response (CMR), and were treated as a complete remission of lymphoma regardless of presence of nodules in the subcutaneous tissue found upon physical examination or of residual tumor signs found on CT.

### **Histological, immunohistochemical and molecular features**

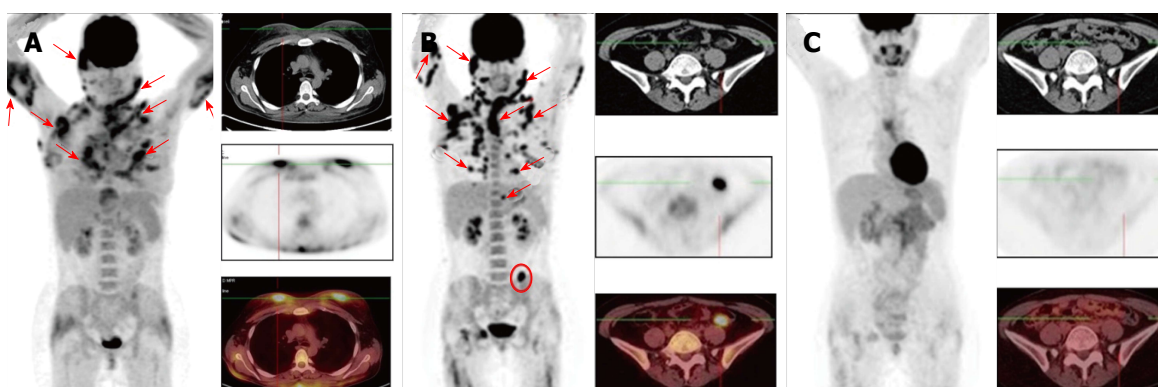
All 3 cases showed the characteristic panniculitis-like infiltration with obvious rimming of subcutaneous fat cells. The observed atypical CD8-positive lymphoma cells were small and medium-sized. Tumor infiltration did not affect the dermis and epidermis. The lymphoma cells were positive for TCR $\beta$ , CD3 and CD8, and expressed the cytotoxic markers TIA1, granzyme B and perforin. Proliferation rate of the neoplastic T cells was 50%-70% (as indicated by Ki-67) for all 3 cases. T cell clonality was confirmed in case 1, which showed incomplete (D $\beta$ -J $\beta$ ) clonal rearrangement of the TCR  $\beta$  chain, and case 3, which showed complete clonal rearrangement of the TCR



**Table 1 Clinical features of the 3 cases of subcutaneous panniculitis like T cell lymphoma**

Case	Age in years/sex	Localization	Autoimmune disorders	B-symptoms	LDH, IU/mL <sup>1</sup>	SUVmax	Chemotherapy	Outcome, FU in mo
1	27/F	Head, neck, upper extremities, chest, breasts, mesocolon	-	+	1.165	14.6	PD*6 × CHOP* 6 × GEM-P	CR, 29
2	22/M	Right cheek, upper and lower extremities, trunk	Positive direct Coombs test	+	1.741	10.5	7 × GEM-P	CR, 26
3	53/F	Head, trunk, upper and lower extremities, epiploon in the left mesogastric area	Autoimmune thyroiditis, 2-fold increase of anti-La/SS-B level	+	274	13.8	3 × FCM*6 × GEM-P	CR, 8

<sup>1</sup>Normal range, < 225 IU/mL. CHOP: Cyclophosphamide, doxorubicine, vincristine and prednisolone; CR: Complete response; FCM: Fludarabine, mitoxantrone and cyclophosphamide; FU: Follow-up; GEM-P: Gemcitabine, cisplatin and methylprednisolone; PD: Prednisone; F: Female; M: Male.



**Figure 1 Case 1.** A: Before treatment, showing multiple confluent pathological foci of hypermetabolic activity in subcutaneous fat (the largest are indicated by arrows on the whole-body image) and pathological foci in the breasts (in transverse sections); B: After 6 cycles of the CHOP regimen, showing no changes in the follow-up examinations, with conservation of previously defined lesions and development of new ones in the subcutaneous tissue (indicated by arrows on the whole-body image) and pathological focus of hypermetabolic activity which had developed in the mesentery of the descending colon (indicated by circles, on the whole-body image as well); C: After 6 cycles of the GEM-P chemotherapy regimen, showing marked improvement, as indicated by resorption of all previously defined foci. CHOP: Cyclophosphamide, doxorubicine, vincristine and prednisolone; GEM-P: Gemcitabine, cisplatin and methylprednisolone.

$\beta$  and  $\gamma$  chains.

### Clinical features and results of FDG PET/CT

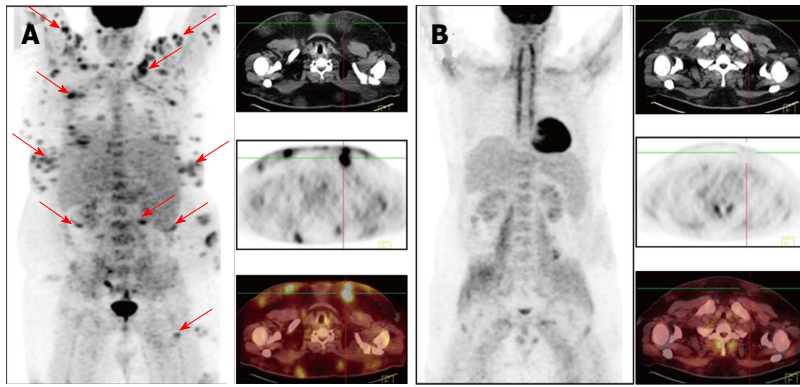
Table 1 shows the clinical features of the 3 patients (2 females and 1 male). Two patients had autoimmune disorders, with case 2 showing IgG antibodies to erythrocytes and case 3 showing autoimmune thyroiditis and 2-fold increase of antibody titer to the La/SS-B. None of the patients showed evidence of lupus erythematosus. All 3 patients suffered from multifocal disease with red to purple, non-ulcerated, sometimes painful nodules or plaques involving the face, trunk and extremities. All 3 patients also had B-symptoms and elevated lactate dehydrogenase (LDH) level.

Figures 1-3 show results of the PET/CT primary staging and monitoring of treatment response in the 3 patients, respectively. Primary staging by PET/CT showed multiple foci of increased uptake in the subcutaneous fat of all patients, with the SUVmax ranging from 10.5 to 14.6. Involvement of intra-abdominal fat with high SUVmax was identified in two patients; specifically, case 1 showed progression of lymphoma at interim PET, and case 3 showed presence at primary staging.

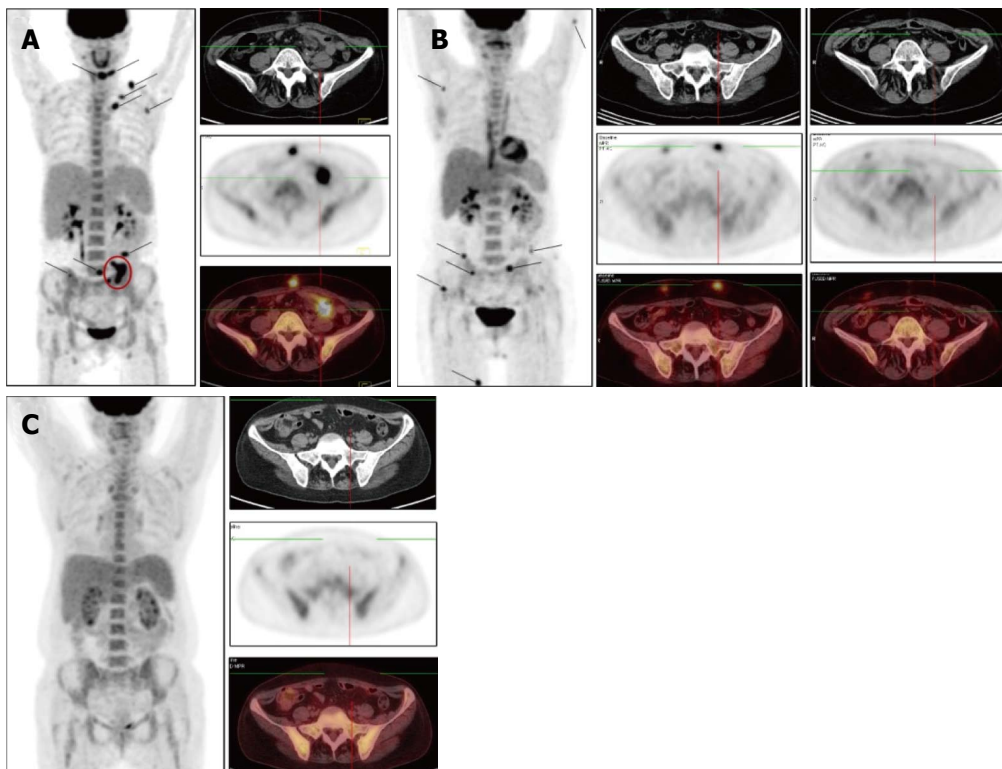
Initial steroid monotherapy was unsuccessful in case 1. All 3 patients received multi-agent chemotherapy. In cases 1 and 3, the lymphoma was refractory to the therapy; case 1 received the cyclophosphamide, doxorubicine, vincristine and prednisolone (CHOP) regimen and case 3 received the fludarabine, mitoxantrone and cyclophosphamide (FCM) regimen. The gemcitabine, cisplatin and methylprednisolone (GEM-P) regimen was used as first-line therapy for case 2 and as second-line therapy for cases 1 and 3, and led to CMR in all. All 3 of the patients remained in remission at the time of last follow-up (range, 8-29 mo).

### DISCUSSION

The extent of lymphoid tumors and their associated pathologic characteristics play an important role in the choice of therapeutic algorithm, and quantification of disease burden during the therapy is crucial for decision-making of whether to continue the ongoing treatment regimen or to change it. Despite the fact that FDG PET has been used increasingly for staging and response assessment for different types of lymphomas, the



**Figure 2 Case 2.** A: Before treatment, showing multiple separate and confluent pathological foci of fluorine-18 fluorodeoxyglucose uptake in local dense areas of subcutaneous fat (the largest are indicated by arrows on the whole-body image); B: After 7 cycles of the GEM-P chemotherapy regimen, showing preservation of metabolically inactive areas of consolidation of subcutaneous fat. GEM-P: Gemcitabine, cisplatin and methylprednisolone.



**Figure 3 Case 3.** A: Before treatment, showing multiple pathological foci of hypermetabolic activity in local dense areas of subcutaneous fat (the largest are indicated by arrows, on the whole-body image as well) and pathological foci of fluorine-18 fluorodeoxyglucose uptake in the epiploon in the left mesogastric area (indicated by circles, on the whole-body image as well); B: After 3 cycles of FCM, showing resorption of all previously defined foci (including those in the greater omentum) but development of new ones in the subcutaneous tissue; C: After 3 cycles of GEM-P, showing marked improvement that was indicated by resorption of all previously defined foci. FCM: Fludarabine, mitoxantrone and cyclophosphamide; GEM-P: Gemcitabine, cisplatin and methylprednisolone.

experience of its use in SPTCL is limited<sup>[8-14]</sup>. Analysis of published data on 7 patients with SPTCL revealed FDG-avid tumors in 71%<sup>[8]</sup>. Feeney *et al.*<sup>[11]</sup> studied 9 SPTCL patients, all of who were PET-positive, and the average SUVmax was 5.7 (range, 1.5-13.1).

All 3 of our patients showed FDG-avid lesions in the pre-treatment PET, which correlated with a high index of proliferative activity of lymphoid cells. In addition, generalized distribution of subcutaneous fat foci with high SUVmax were identified in the mesenteric fat in 2 of the patients. Involvement of intra-abdominal fat in SPTCL has been described in recent years<sup>[15,16]</sup>. Our results suggest that PET/CT may therefore be useful in detecting occult extracutaneous involvement in SCPTL. However, the prognostic value of intra-abdominal dissemination of

SCPTL is unknown.

To evaluate the effectiveness of chemotherapy, we focused on the FDG PET/CT data in addition to the clinical picture of the cases. In case 1, following 6 cycles of the CHOP regimen, a marked improvement was noted, which manifested as normalization of temperature and LDH level, and a significant reduction in the size and density of the subcutaneous nodules. However, the FDG PET/CT data revealed preservation of previously defined and developing new lesions, which led to a change in the chemotherapy regimen to that of GEM-P. After 6 cycles of the GEM-P chemotherapy regimen, CMR was obtained. In case 2, following 7 cycles of the GEM-P chemotherapy regimen, palpable subcutaneous nodules and elevated LDH was still present but the FDG PET/CT data revealed

CMR; as a result, the therapy was discontinued and the risks associated with overtreatment were avoided. In case 3, following 3 cycles of the FCM chemotherapy regimen, an ambivalent picture was observed, with the disappearance of previously palpable nodes and the emergence of new, fast-growing, subcutaneous nodules. For this last case, the FDG PET/CT data confirmed development of new lesions, with SUVmax of 12.9, and a lack of FDG accumulation in the previous nodules. Three cycles of the GEM-P chemotherapy regimen produced CMR, after which 3 consolidating cycles of GEM-P were added.

Recently, SPTCL was classified as a lymphoid tumor with indolent clinical course<sup>[17]</sup>. However, in each of our 3 patients, despite the lack of hemophagocytic syndrome, the SPTCL course progressed rapidly. B-symptoms and LDH increase were observed, and the index of proliferative activity of the tumor was about 50%-70%, which is comparable with the proliferative activity of diffuse large B cell lymphoma. Additionally, the PET/CT findings in our cases also suggested aggressive behavior of the tumors.

The GEM-P regimen is accepted as a first-line therapy for treatment of peripheral T cell lymphomas, as well as for lymphoma cases of recurrence or primary resistance<sup>[18-20]</sup>. Our review of the literature found only a single SPTCL case for which the GEM-P regimen was used as treatment. That patient had been refractory to the CHOP regimen but responded well to GEM-P<sup>[21]</sup>. Our results suggest that the GEM-P regimen is efficacious for the treatment of SPTCL, including in those patients who are refractory to the CHOP or FCM regimens.

It is possible that SPTCL is an inherently biologically heterogeneous tumor or acquires heterogeneity in the course of tumor progression. It would then be assumed that some SPTCL cases are indolent, have a low index of proliferative activity, with low FDG accumulation, and respond well to immunosuppressive therapy. Alternatively, a rapidly progressive disease course would then be observed in some cases, accompanied by constitutional symptoms and with a high index of proliferative activity and high level of FDG uptake. These more aggressive lymphomas would presumably require multi-agent chemotherapy.

Although there is need for further study, the findings from our 3 cases suggest that FDG PET/CT provides valuable information towards detecting occult lesions in SPTCL and may be useful in disease staging and monitoring of treatment response. Moreover, high FDG uptake on pre-treatment PET could identify patients with aggressive disease and help in choosing first-line therapy.

## COMMENTS

### Case characteristics

Three patients (two females aged 27 and 53, and one male aged 22) presented with multiple subcutaneous nodules and accompanying fever.

### Clinical diagnosis

Panniculitis was the provisional diagnosis.

### Differential diagnosis

The morphological differential diagnosis included atypical lymphocytic lobular panniculitis, lupus profundus, natural killer (NK) cell and NK-like T cell lymphomas involving subcutis.

### Laboratory diagnosis

All 3 patients in this study had elevated lactate dehydrogenase level.

### Imaging diagnosis

Positron emission tomography combined with computed tomography (PET/CT) showed multiple foci of increased uptake of fluorine-18 fluorodeoxyglucose in the subcutaneous fat of all 3 patients; the SUVmax values ranged from 10.5 to 14.6. Involvement of intra-abdominal fat was identified in 2 of the patients.

### Pathological diagnosis

Subcutaneous panniculitis-like T cell lymphoma (SPTCL).

### Treatment

Use of the gemcitabine, cisplatin and methylprednisolone regimen as first-line therapy or second-line therapy was followed by achievement of complete metabolic response for all 3 cases.

### Related reports

SPTCL is a very rare variant of non-Hodgkin's lymphoma, commonly confused with a non-neoplastic process due to its unusual location; in histological analysis, it can mimic panniculitis.

### Term explanation

SPTCL is a malignant neoplasm belonging to the non-Hodgkin's lymphomas.

### Experiences and lessons

Fluorine-18 fluorodeoxyglucose PET/CT provides valuable information for staging of SPTCL and monitoring of treatment response in patients.

### Peer-review

The article is well written, clear and concise. The topic and the results are interesting. Methods are sound.

## REFERENCES

- 1 **Gonzalez CL**, Medeiros LJ, Brazier RM, Jaffe ES. T-cell lymphoma involving subcutaneous tissue. A clinicopathologic entity commonly associated with hemophagocytic syndrome. *Am J Surg Pathol* 1991; **15**: 17-27 [PMID: 1985499 DOI: 10.1097/00000478-199101000-00002]
- 2 **Jaffe ES**, Gaulard P, Ralfkiaer E, Cerroni L, Meijer CJLM. Subcutaneous panniculitis-like T-cell lymphoma. In: Swerdlow SH, Campo E, Harris NL, editors. WHO Classification of Tumors of Haematopoietic and Lymphoid Tissues. Lyon: IARC, 2008: 294-295
- 3 **Go RS**, Wester SM. Immunophenotypic and molecular features, clinical outcomes, treatments, and prognostic factors associated with subcutaneous panniculitis-like T-cell lymphoma: a systematic analysis of 156 patients reported in the literature. *Cancer* 2004; **101**: 1404-1413 [PMID: 15368328 DOI: 10.1002/cncr.20502]
- 4 **Willemze R**, Jansen PM, Cerroni L, Berti E, Santucci M, Assaf C, Canninga-van Dijk MR, Carlotti A, Geerts ML, Hahtola S, Hummel M, Jeskanen L, Kempf W, Massone C, Ortiz-Romero PL, Paulli M, Petrella T, Ranki A, Peralto JL, Robson A, Senff NJ, Vermeer MH, Wechsler J, Whittaker S, Meijer CJ. Subcutaneous panniculitis-like T-cell lymphoma: definition, classification, and

- prognostic factors: an EORTC Cutaneous Lymphoma Group Study of 83 cases. *Blood* 2008; **111**: 838-845 [PMID: 17934071 DOI: 10.1182/blood-2007-04-087288]
- 5 **Oschlies I**, Simonitsch-Klupp I, Maldyk J, Konovalov D, Abramov D, Myakova N, Lisfeld J, Attarbaschi A, Kontny U, Woessmann W, Klapper W. Subcutaneous panniculitis-like T-cell lymphoma in children: a detailed clinicopathological description of 11 multifocal cases with a high frequency of haemophagocytic syndrome. *Br J Dermatol* 2015; **172**: 793-797 [PMID: 25456748 DOI: 10.1111/bjd.13440]
  - 6 **van Dongen JJ**, Langerak AW, Brüggemann M, Evans PA, Hummel M, Lavender FL, Delabesse E, Davi F, Schuurin E, García-Sanz R, van Krieken JH, Droese J, González D, Bastard C, White HE, Spaargaren M, González M, Parreira A, Smith JL, Morgan GJ, Kneba M, Macintyre EA. Design and standardization of PCR primers and protocols for detection of clonal immunoglobulin and T-cell receptor gene recombinations in suspect lymphoproliferations: report of the BIOMED-2 Concerted Action BMH4-CT98-3936. *Leukemia* 2003; **17**: 2257-2317 [PMID: 14671650 DOI: 10.1038/sj.leu.2403202]
  - 7 **Sandberg Y**, van Gastel-Mol EJ, Verhaaf B, Lam KH, van Dongen JJ, Langerak AW. BIOMED-2 multiplex immunoglobulin/T-cell receptor polymerase chain reaction protocols can reliably replace Southern blot analysis in routine clonality diagnostics. *J Mol Diagn* 2005; **7**: 495-503 [PMID: 16237219 DOI: 10.1016/S1525-1578(10)60580-6]
  - 8 **Barrington SF**, Mikhael NG, Kostakoglu L, Meignan M, Hutchings M, Müller SP, Schwartz LH, Zucca E, Fisher RI, Trotman J, Hoekstra OS, Hicks RJ, O'Doherty MJ, Hustinx R, Biggi A, Cheson BD. Role of imaging in the staging and response assessment of lymphoma: consensus of the International Conference on Malignant Lymphomas Imaging Working Group. *J Clin Oncol* 2014; **32**: 3048-3058 [PMID: 25113771 DOI: 10.1200/JCO.2013.53.5229]
  - 9 **Kako S**, Izutsu K, Ota Y, Minatani Y, Sugaya M, Momose T, Ohtomo K, Kanda Y, Chiba S, Motokura T, Kurokawa M. FDG-PET in T-cell and NK-cell neoplasms. *Ann Oncol* 2007; **18**: 1685-1690 [PMID: 17716987 DOI: 10.1093/annonc/mdm265]
  - 10 **Rodriguez VR**, Joshi A, Peng F, Rabah RM, Stockmann PT, Savaşan S. Positron emission tomography in subcutaneous panniculitis-like T-cell lymphoma. *Pediatr Blood Cancer* 2009; **52**: 406-408 [PMID: 18985722 DOI: 10.1002/pbc.21805]
  - 11 **Feeney J**, Horwitz S, Gönen M, Schöder H. Characterization of T-cell lymphomas by FDG PET/CT. *AJR Am J Roentgenol* 2010; **195**: 333-340 [PMID: 20651187 DOI: 10.2214/AJR.09.3665]
  - 12 **Babb A**, Zerizer I, Naresh KN, Macdonald D. Subcutaneous panniculitis-like T-cell lymphoma with extracutaneous dissemination demonstrated on FDG PET/CT. *Am J Hematol* 2011; **86**: 375-376 [PMID: 21442643 DOI: 10.1002/ajh.21874]
  - 13 **Uematsu T**, Kasami M. 3T-MRI, elastography, digital mammography, and FDG-PET CT findings of subcutaneous panniculitis-like T-cell lymphoma (SPTCL) of the breast. *Jpn J Radiol* 2012; **30**: 766-771 [PMID: 22872501 DOI: 10.1007/s11604-012-0112-5]
  - 14 **Kim JS**, Jeong YJ, Sohn MH, Jeong HJ, Lim ST, Kim DW, Kwak JY, Yim CY. Usefulness of F-18 FDG PET/CT in subcutaneous panniculitis-like T cell lymphoma: disease extent and treatment response evaluation. *Radiol Oncol* 2012; **46**: 279-283 [PMID: 23412422 DOI: 10.2478/v10019-012-0017-z]
  - 15 **Mitsuhashi K**, Momose M, Masuda A, Tsunemi Y, Motoji T. Positron emission tomography revealed diffuse involvement of the lower legs and occult extracutaneous lesions in subcutaneous panniculitis-like T-cell lymphoma. *Clin Nucl Med* 2013; **38**: 209-211 [PMID: 23354029 DOI: 10.1097/RLU.0b013e31827087ca]
  - 16 **Lester L**, Ewalt M, Warnke R, Kim J. Systemic panniculitis-like T-cell lymphoma with involvement of mesenteric fat and subcutis. *J Cutan Pathol* 2015; **42**: 46-49 [PMID: 25384366 DOI: 10.1111/cup.12436]
  - 17 **Quintanilla-Martinez L**, Jansen PM, Kinney MC, Swerdlow SH, Willemze R. Non-mycosis fungoides cutaneous T-cell lymphomas: report of the 2011 Society for Hematopathology/European Association for Haematopathology workshop. *Am J Clin Pathol* 2013; **139**: 491-514 [PMID: 23525618 DOI: 10.1309/AJCP83AOQTMLOJTM]
  - 18 **Ng M**, Waters J, Cunningham D, Chau I, Horwich A, Hill M, Norman AR, Wotherspoon A, Catovsky D. Gemcitabine, cisplatin and methylprednisolone (GEM-P) is an effective salvage regimen in patients with relapsed and refractory lymphoma. *Br J Cancer* 2005; **92**: 1352-1357 [PMID: 15812553 DOI: 10.1038/sj.bjc.6602514]
  - 19 **Arkenau HT**, Chong G, Cunningham D, Watkins D, Sirohi B, Chau I, Wotherspoon A, Norman A, Horwich A, Matutes E. Gemcitabine, cisplatin and methylprednisolone for the treatment of patients with peripheral T-cell lymphoma: the Royal Marsden Hospital experience. *Haematologica* 2007; **92**: 271-272 [PMID: 17296587 DOI: 10.3324/haematol.10737]
  - 20 **Yim KL**, Ashley S. Assessment of gemcitabine, cisplatin and methylprednisolone (GEM-P) combination treatment for non-Hodgkin T cell lymphoma. *Med Oncol* 2012; **29**: 3535-3539 [PMID: 22825684 DOI: 10.1007/s12032-012-0309-6]
  - 21 **Velez NF**, Ishizawa RC, Dellaripa PF, Saavedra AP, Laga AC, Murphy GF, Fisher DC, Kupper TS, Vleugels RA. Full facial edema: a novel presentation of subcutaneous panniculitis-like T-cell lymphoma. *J Clin Oncol* 2012; **30**: e233-e236 [PMID: 22826278 DOI: 10.1200/JCO.2011.40.7684]

P- Reviewer: Mehdi I, Mocellin S S- Editor: Ji FF L- Editor: A  
E- Editor: Lu YJ





## Small bowel entrapment and ureteropelvic junction disruption associated with L3 Chance fracture-dislocation

Sebastien Pesenti, Benjamin Blondel, Alice Faure, Emilie Peltier, Franck Launay, Jean-Luc Jouve

Sebastien Pesenti, Emilie Peltier, Franck Launay, Jean-Luc Jouve, Pediatric Orthopaedics, Hopital d'Enfants de la Timone, Aix Marseille University, 13005 Marseille, France

Benjamin Blondel, Spine Unit, Aix Marseille University, 13005 Marseille, France

Alice Faure, Pediatric Surgery, Hôpital Nord, Aix-Marseille University, 13015 Marseille, France

**Author contributions:** All authors contributed equally to this work.

**Institutional review board statement:** The family of the patient has given her approval for publication of the clinical case.

**Informed consent statement:** The legally authorized representative of the patient gave informed consent for inclusion in the study and approval for publication of the clinical case.

**Conflict-of-interest statement:** No fund from any sources was received for this work.

**Open-Access:** This article is an open-access article which was selected by an in-house editor and fully peer-reviewed by external reviewers. It is distributed in accordance with the Creative Commons Attribution Non Commercial (CC BY-NC 4.0) license, which permits others to distribute, remix, adapt, build upon this work non-commercially, and license their derivative works on different terms, provided the original work is properly cited and the use is non-commercial. See: <http://creativecommons.org/licenses/by-nc/4.0/>

**Manuscript source:** Invited manuscript

**Correspondence to:** Sebastien Pesenti, MD, Pediatric Orthopaedics, Hopital d'Enfants de la Timone, Aix Marseille University, 264 rue Saint Pierre, 13005 Marseille, France. [sebastien.pesenti@ap-hm.fr](mailto:sebastien.pesenti@ap-hm.fr)  
Telephone: +33-4-91386697  
Fax: +33-4-91384227

Received: April 27, 2016

Peer-review started: April 28, 2016

First decision: June 16, 2016

Revised: July 8, 2016

Accepted: July 20, 2016

Article in press: July 22, 2016

Published online: September 16, 2016

### Abstract

Paediatric Chance fracture are rare lesions but often associated with abdominal injuries. We herein present the case of a seven years old patient who sustained an entrapment of small bowel and an ureteropelvic disruption associated with a Chance fracture and spine dislocation following a traffic accident. Initial X-rays and computed tomographic (CT) scan showed a Chance fracture with dislocation of L3 vertebra, with an incarceration of a small bowel loop in the spinal canal and a complete section of the left lumbar ureter. Paraplegia was noticed on the initial neurological examination. A posterior L2-L4 osteosynthesis was performed firstly. In a second time she underwent a sus umbilical laparotomy to release the incarcerated jejunum loop in the spinal canal. An end-to-end anastomosis was performed on a JJ probe to suture the left injured ureter. One month after the traumatism, she started to complain of severe headaches related to a leakage of cerebrospinalis fluid. Three months after the traumatism there was a clear regression of the leakage. One year after the trauma, an anterior intervertebral fusion was done. At final follow-up, no neurologic recovery was noticed. In case of Chance fracture, all physicians should think about abdominal injuries even if the patient is asymptomatic. Initial abdominal CT scan and magnetic resonance imaging provide in such case crucial info for management of the spine and the associated lesions.

**Key words:** Chance fracture; Uretero-pelvic disruption; Small bowel injuries; Seatbelt; Dural tear

© The Author(s) 2016. Published by Baishideng Publishing Group Inc. All rights reserved.

**Core tip:** We report the case of a 7 years old patient with a Chance fracture and dislocation of the 3rd lumbar vertebra associated with abdominal injuries and cauda equina syndrome. Initial radiological examinations led to a multidisciplinary surgical management. Particular attention must be paid to these lesions in the initial evaluation.

Pesenti S, Blondel B, Faure A, Peltier E, Launay F, Jouve JL. Small bowel entrapment and ureteropelvic junction disruption associated with L3 Chance fracture-dislocation. *World J Clin Cases* 2016; 4(9): 264-268 Available from: URL: <http://www.wjgnet.com/2307-8960/full/v4/i9/264.htm> DOI: <http://dx.doi.org/10.12998/wjcc.v4.i9.264>

## INTRODUCTION

Bowel injuries may be seen in conjunction with spinal fractures, especially in patients who have been involved in motor vehicle accidents. The seat belt, while preventing some types of injuries, may predispose to serious injuries by rapid angulation of the spine and compression of the abdominal contents<sup>[1]</sup>. We report a unique case of preoperative diagnosis of jejunum entrapment into the vertebral body of L3, associated with ureteropelvic junction disruption and fracture-dislocation of the L3 vertebra.

## CASE REPORT

A seven years old girl was sitting in the rear seat of a car with her abdominal seatbelt fastened when the vehicle was involved in a high speed head-on collision. The grandmother, rear sitting too, had an ankle fracture.

When arriving at the emergency department, physical examination of the patient revealed lumbar pain, abdominal pain and paraplegia. The abdomen was diffusely tender and neurologic examination showed a cauda equina syndrome with a sensory deficit corresponding to level L3, a decreased rectal tone and paraplegia.

Radiologic evaluation included X-rays, computed tomographic (CT)-scan and magnetic resonance imaging (MRI). These examinations showed a Chance type fracture with dislocation of vertebra L3 (Figure 1) with entrapment of a small bowel loop in the spinal canal (Figure 2), a splenic subhilar fracture with perisplenic free fluid, difficulty to follow the left ureter at the lumbar level and a fracture of the right ischiopubic branch. MRI confirmed the aspect of small bowel loop into the spinal canal.

She underwent a two-stage emergency surgery. Firstly, the patient was placed in a prone position. A prophylactic antibiotic treatment was performed, using a 3<sup>rd</sup> generation cephalosporin. The Chance fracture was treated by open reduction and osteosynthesis by pedicular fixation from L2 to L4. Secondary she underwent left transverse susombilical laparotomy. It

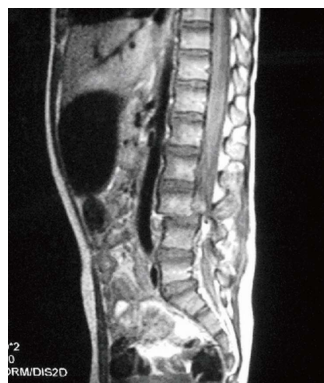

Figure 1 Initial magnetic resonance imaging, sagittal view T1-weighted, showing Chance fracture with dislocation of the 3<sup>rd</sup> lumbar vertebra and neurological compression.

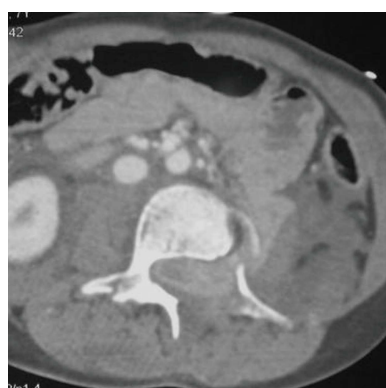


Figure 2 Initial axial computed tomographic scan showing entrapment of small bowel loop in the spinal canal. No air was seen in the spinal canal.

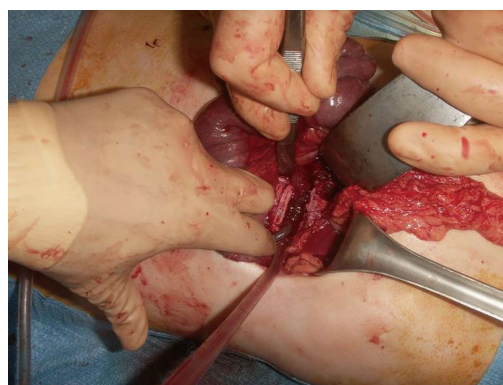


Figure 3 Intra-operative view of the jejunum loop during the second time surgical procedure. Due to the necrotic aspect of the bowel, resection and anastomosis was performed.

revealed the intracanalicular incarceration of a jejunum loop (Figure 3), an injury of the ascending colon, a large section of the retroperitoneum at L3 level, a section of the left psoas muscle, a complete section of the left lumbar ureter and a left lumbar arterial wound. No obvious sign of hepatic or pancreatic injury were observed. The L3-L4 discectomy was performed to release the incarcerated bowel loop. A 10 cm-small

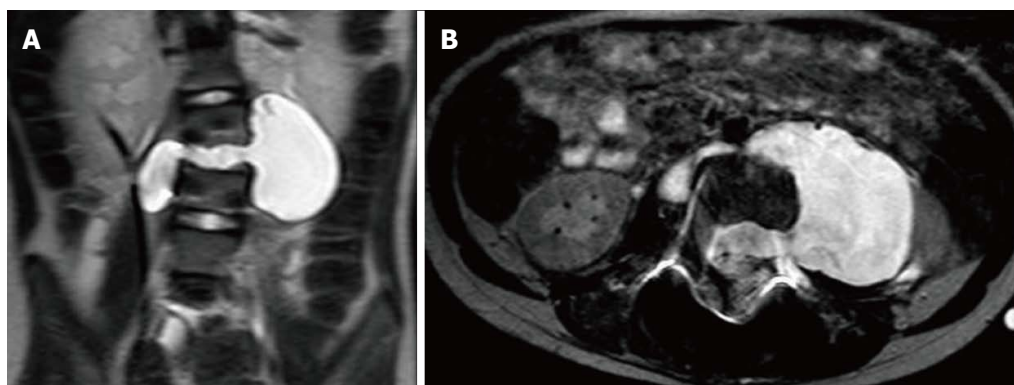


Figure 4 T2-weighted coronal (A) and axial (B) magnetic resonance imaging one month after the trauma showing LCS leakage in the abdominal cavity.

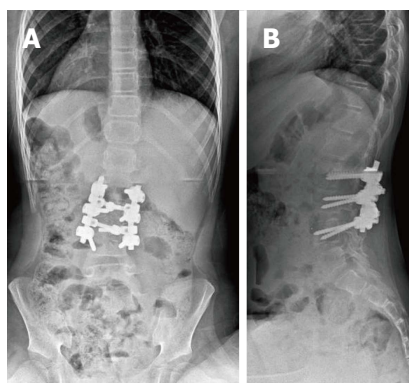


Figure 5 AP (A) and lateral (B) X-rays at two years follow-up showing L2-L4 vertebral fusion after posterior and anterior procedures.

bowel resection was performed because of the suffering aspect of the incarcerated bowel fragment. A primary end-to-end anastomosis was performed and the peri-vertebral space was irrigated. The injured left ureter was then sutured end-to-end on a JJ probe (18 cm, 4.7 Charriere). The right colonic serosa wound was closed and the retroperitoneum was drained.

Antibiotics were continued postoperatively to prevent meningitis and peritonitis. A removable thoracolumbar brace was prescribed. She didn't show any neurologic recovery after surgery.

This young girl was discharged from the hospital on day 12. The JJ probe was removed one month after the traumatism and intermittent bladder catheterization were initiated.

She started to complain of severe headaches in sitting position that completely resolved with recumbent position. An MRI was performed for a suspicion of dural tear. It showed a leakage of cerebrospinal fluid (CSF) from the medullary canal to the abdominal cavity, through the L3-L4 intervertebral disc and the left L3-L4 intervertebral foramen (Figure 4). The abdominal meningocele was developed along the left psoas muscle. It was decided to follow up this collection by ultrasonography. After one week, the patient could tolerate the seated position without any complain. Ultrasonography controls didn't show any increase of

the meningocele. The patient was discharged from the hospital and was asked to wear a full time brace. Three and a half months after the traumatism, an MRI showed a clear decrease of the meningocele. Three months after, CSF signal was only visible at the level of the L3-L4 intervertebral disc space, and disappeared 6 mo later.

One year after the traumatism, the patient finally underwent an anterior L2-L4 anterior interbody fusion through a standard left lobotomy. No LCS leakage was identified during this surgical procedure. The L2-L3 intervertebral disc and the remnants of the L3-L4 intervertebral disc were removed and replaced by cancellous bone grafts, without osteosynthesis.

At last follow up (9 mo after the second surgical procedure), the patient still did not show any neurologic recovery. The evoked somatosensory potentials didn't show any neurologic activity in both legs. The AP and lateral full spine x-rays performed in the seated position showed satisfactory spine morphology (Figure 5).

## DISCUSSION

The optimal seatbelt links the thorax to the pelvis. In children, the shoulder restraint is usually in front of the face or neck and therefore often removed. The lap belt is frequently placed alone directly across the abdomen, creating an axis of rotation near the level of the umbilicus during a collision<sup>[2,3]</sup>. The hyperflexion of the upper body over the lapbelt produces flexion-distraction forces and classically causes a Chance fracture of the spine. Nonetheless, 40% of these injuries occur while wearing a combined shoulder and lap belt<sup>[4]</sup>. Nance *et al*<sup>[5]</sup> had showed that optimally restrained children were at a significantly lower risk of abdominal injury (5%) than children suboptimally restrained (17%) for their age.

The exact mechanism of traumatic incarceration of bowel in the spine is unclear. Nowadays two theories are proposed. According to some authors, an anterior force pushes the bowel while other authors explain the bowel incarceration by a posterior vacuum responsible of a traction force<sup>[6-11]</sup>. In our case, the findings support the concept that the anterior dislocation of the L3 vertebra



tore up the posterior peritoneum and brought back the jejunum loop in the spinal canal.

Small bowel injury in children is uncommon with an incidence estimated between 1% to 7%<sup>[12]</sup>. The most common injuries are duodenal perforation or haematoma, mesenteric contusions, avulsion of the jejunum at the duodenal jejunal flexure, ileal or jejunal perforations and evisceration of the small bowel<sup>[13]</sup>.

Ureteric injury following abdominal trauma represents less than 1% of all urologic trauma. Avulsion of the ureteropelvic junction is the most common injury in children<sup>[14,15]</sup> as the pelvis and the psoas muscles provide protection to the distal collecting system. A hypothesis to explain the avulsion of the ureteropelvic junction is that acceleration-deceleration forces provoke an anterosuperior displacement of the kidney while the ureter remains in a fixed position<sup>[16]</sup>. The hyperextension of the trunk stretches the ureter and a rapid deceleration compresses the ureter against the vertebral column.

Delayed diagnosis appears to cause significant morbidity and mortality in children with blunt abdominal trauma<sup>[17,18]</sup>. The main problem is the difficulty to diagnose associated lesions. The pain relative to the spine fracture often conceals abdominal signs. Abdominal wall haematoma may alter clinical examination and hide intra-abdominal injuries. CT-scan and abdominal ultrasound are often used to screen these injuries before surgical exploration. CT-scan is already a relatively non-invasive modality that provides data on any concomitant abdominal, spinal or retroperitoneal injuries. Although delayed diagnosis of visceral injuries after abdominal CT scanning has been reported in 10% to 50% of such patients<sup>[19]</sup>. In the other hand, in most cases abdominal symptoms dominate and the diagnosis of Chance fracture is delayed. In our case, the association of neurological and abdominal symptoms after a high-speed head-on car collision led us to realize urgent CT-scan and MRI. This attitude allowed a rapid diagnosis. It is interesting to point out that the diagnosis of this association of injuries before surgery has never been described, even if cases of pneumorachis has been published<sup>[20,21]</sup>.

Concerning the surgical management, we think that performing the laparotomy first could have been dangerous because of the major instability of the spine. Indeed, there would have been a high risk of iatrogenic injuries while mobilizing the patient. For this reason, the posterior arthrodesis was done firstly, in order to stabilize the spine, the hemodynamic stability and the absence of vascular emergency allowed to proceed this way. Moreover, Crawford *et al.*<sup>[21]</sup> think that the reduction and stabilization of the spinal injuries should be performed as early as possible. Spine stabilization facilitates safe mobilization of the patient and avoids potential secondary injury to intra-abdominal structures. In our case, anterior spinal stabilization was not immediately performed because of the high infectious risk (osteitis, meningitis) in the context of bowel injury.

During the postoperative course, our patient pre-

sented a delayed CSF leakage. The time interval was 30 d. Most of post-traumatic CSF leakage resolves within 6 mo after the traumatism without surgical management. The rate of spontaneous healing of traumatic CSF leaks has been reported around 53%<sup>[22]</sup>.

The appropriate timing for surgical intervention is also unclear. In our case we decided to treat the persistent post-traumatic CSF leak conservatively with bed rest in Trendelenburg position. We did not perform an anterior spinal stabilization at month 1 because lumbar spine injuries were stable. Overall management results were quite satisfactory, with no mortality or wound infections.

In case of spinal trauma caused by head-on collision despite of seat belt wearing, all physicians should think about abdominal injuries even if the patient is asymptomatic, and perform an abdominal CT scan and MRI as soon as possible. An early diagnosis of associated injuries contributes to the optimal management of this kind of patients.

Intracanal entrapment of jejunum loop in children is an uncommon but serious injury following blunt abdominal trauma. This attitude seems the most appropriate for a multidisciplinary management of these lesions.

## COMMENTS

### Case characteristics

Paraplegia, back pain and abdominal pain in a 7 years old patient after a high-speed car accident.

### Clinical diagnosis

Chance fracture of the 3<sup>rd</sup> lumbar vertebra dislocation of the spine associated with small bowel entrapment and disruption of the ureteropelvic junction.

### Differential diagnosis

Systematic computed tomographic (CT)-scan and magnetic resonance imaging (MRI) in cases of blunt abdominal trauma allow a complete diagnosis and avoid to miss abdominal or bony injuries.

### Laboratory diagnosis

Off topic in this case.

### Imaging diagnosis

CT-scan and MRI are useful in this case, both for the diagnosis of intra-abdominal injuries and bony lesions of the spine.

### Pathological diagnosis

While abdominal injuries are often associated with Chance fracture, the entrapment of a small bowel loop into the medullary canal is uncommon and must be diagnosed preoperatively.

### Treatment

A two-time surgical management was performed initially, a posterior decompression and osteosynthesis of the spine firstly and then a resection-anastomosis of the small bowel and an end-to-end anastomosis of the ureteropelvic junction.

### Experiences and lessons

After a high-speed car accident, physicians must pay attention to abdominal

symptoms associated to back pain. Chance fractures are often associated with abdominal injuries. All the lesions must be managed at the same time. The cerebrospinal fluid leakage that appeared after surgery has been watched and was resolved at one-year follow-up.

### Peer-review

The present manuscript is a first report about pre-operative diagnosis of both Chance fracture and small bowel entrapment at the fracture site in a 7 years old child. The case report is simply and clearly exposed, the documentation is fine, and the discussion is also well developed.

## REFERENCES

- 1 **Appleby JP**, Nagy AG. Abdominal injuries associated with the use of seatbelts. *Am J Surg* 1989; **157**: 457-458 [PMID: 2712201 DOI: 10.1016/0002-9610(89)90633-8]
- 2 **Gumley G**, Taylor TK, Ryan MD. Distraction fractures of the lumbar spine. *J Bone Joint Surg Br* 1982; **64**: 520-525 [PMID: 7142258]
- 3 **Smith MD**, Camp E, James H, Kelley HG. Pediatric seat belt injuries. *Am Surg* 1997; **63**: 294-298 [PMID: 9036903]
- 4 **Mulpuri K**, Jawadi A, Perdios A, Choit RL, Tredwell SJ, Reilly CW. Outcome analysis of chance fractures of the skeletally immature spine. *Spine (Phila Pa 1976)* 2007; **32**: E702-E707 [PMID: 18007230 DOI: 10.1097/BRS.0b013e31815a5986]
- 5 **Nance ML**, Lutz N, Arbogast KB, Cornejo RA, Kallan MJ, Winston FK, Durbin DR. Optimal restraint reduces the risk of abdominal injury in children involved in motor vehicle crashes. *Ann Surg* 2004; **239**: 127-131 [PMID: 14685110 DOI: 10.1097/01.sla.0000103068.51037.20]
- 6 **Beaunoyer M**, St-Vil D, Lallier M, Blanchard H. Abdominal injuries associated with thoraco-lumbar fractures after motor vehicle collision. *J Pediatr Surg* 2001; **36**: 760-762 [PMID: 11329583 DOI: 10.1053/jpsu.2001.22954]
- 7 **Davis RE**, Mittal SK, Perdakis G, Richards AT, Fitzgibons RJ. Traumatic hyperextension/hyperflexion of the lumbar vertebrae with entrapment and strangulation of small bowel: case report. *J Trauma* 2000; **49**: 958-959 [PMID: 11086794 DOI: 10.1097/00005373-200011000-00029]
- 8 **Eldridge TJ**, McFall TM, Peoples JB. Traumatic incarceration of the small bowel: case report. *J Trauma* 1993; **35**: 960-961 [PMID: 8264001 DOI: 10.1097/00005373-199312000-00028]
- 9 **Patterson R**, Temple WJ, Tranmer B, Miller SD. Traumatic intervertebral incarceration of ileum: a unique lap belt injury. *Injury* 1996; **27**: 596-598 [PMID: 8994570 DOI: 10.1016/S0020-1383(96)00065-4]
- 10 **Reid AB**, Letts RM, Black GB. Pediatric Chance fractures: association with intra-abdominal injuries and seatbelt use. *J Trauma* 1990; **30**: 384-391 [PMID: 2325168 DOI: 10.1097/00005373-199030040-00003]
- 11 **Rodger RM**, Missiuna P, Ein S. Entrapment of bowel within a spinal fracture. *J Pediatr Orthop* 1991; **11**: 783-785 [PMID: 1960207 DOI: 10.1097/01241398-199111000-00017]
- 12 **Mercer S**, Legrand L, Stringel G, Soucy P. Delay in diagnosing gastrointestinal injury after blunt abdominal trauma in children. *Can J Surg* 1985; **28**: 138-140 [PMID: 3971239]
- 13 **Holland AJ**, Cass DT, Glasson MJ, Pitkin J. Small bowel injuries in children. *J Paediatr Child Health* 2000; **36**: 265-269 [PMID: 10849230 DOI: 10.1046/j.1440-1754.2000.00502.x]
- 14 **Mollitt DL**, Ballantine TV, DeRosa GP. Jejuno-renal injury following traumatic hyperextension. *J Trauma* 1980; **20**: 996-998 [PMID: 7431460 DOI: 10.1097/00005373-198011000-00019]
- 15 **Palmer JM**, Drago JR. Ureteral avulsion from non-penetrating trauma. *J Urol* 1981; **125**: 108-111 [PMID: 7463564]
- 16 **Slobogean GP**, Tredwell SJ, Masterson JS. Ureteropelvic junction disruption and distal ureter injury associated with a Chance fracture following a traffic accident: a case report. *J Orthop Surg (Hong Kong)* 2007; **15**: 248-250 [PMID: 17709873]
- 17 **Bensard DD**, Beaver BL, Besner GE, Cooney DR. Small bowel injury in children after blunt abdominal trauma: is diagnostic delay important? *J Trauma* 1996; **41**: 476-483 [PMID: 8810966 DOI: 10.1097/00005373-199609000-00015]
- 18 **Meyer DM**, Thal ER, Coln D, Weigelt JA. Computed tomography in the evaluation of children with blunt abdominal trauma. *Ann Surg* 1993; **217**: 272-276 [PMID: 8452405 DOI: 10.1097/00000658-199303000-00009]
- 19 **Tso EL**, Beaver BL, Haller JA. Abdominal injuries in restrained pediatric passengers. *J Pediatr Surg* 1993; **28**: 915-919 [PMID: 8229568 DOI: 10.1016/0022-3468(93)90696-I]
- 20 **Silver SF**, Nadel HR, Flodmark O. Pneumorrhachis after jejunal entrapment caused by a fracture dislocation of the lumbar spine. *AJR Am J Roentgenol* 1988; **150**: 1129-1130 [PMID: 3258716 DOI: 10.2214/ajr.150.5.1129]
- 21 **Kara H**, Akinci M, Degirmenci S, Bayir A, Ak A. Traumatic pneumorrhachis: 2 cases and review of the literature. *Am J Emerg Med* 2015; **33**: 861.e1-861.e3 [PMID: 25595271 DOI: 10.1016/j.ajem.2014.12.040]
- 22 **Friedman JA**, Ebersold MJ, Quast LM. Persistent posttraumatic cerebrospinal fluid leakage. *Neurosurg Focus* 2000; **9**: e1 [PMID: 16859263 DOI: 10.3171/foc.2000.9.5.4]

**P- Reviewer:** Narayanan SK, Vannucci L **S- Editor:** Ji FF  
**L- Editor:** A **E- Editor:** Lu YJ





## Incidentally detected hydatid cyst of the adrenal gland: A case report

Sami Akbulut

Sami Akbulut, Department of Surgery and Liver Transplant Institute, Inonu University Faculty of Medicine, 44280 Malatya, Turkey

**Author contributions:** Akbulut S contributed to concept and design of this case report.

**Institutional review board statement:** This case report was exempt from the Institutional Review Board standards at Diyarbakir Education and Research Hospital, Diyarbakir, Turkey.

**Informed consent statement:** The patient involved in this study gave his informed written consent prior to study enrollment, authorizing the use and disclosure of his protected health information.

**Conflict-of-interest statement:** The author declares no potential conflict of interest.

**Open-Access:** This article is an open-access article which was selected by an in-house editor and fully peer-reviewed by external reviewers. It is distributed in accordance with the Creative Commons Attribution Non Commercial (CC BY-NC 4.0) license, which permits others to distribute, remix, adapt, build upon this work non-commercially, and license their derivative works on different terms, provided the original work is properly cited and the use is non-commercial. See: <http://creativecommons.org/licenses/by-nc/4.0/>

**Manuscript source:** Invited manuscript

**Correspondence to:** Sami Akbulut, FICS, FACS, Associate Professor, Department of Surgery and Liver Transplant Institute, Inonu University Faculty of Medicine, Turgut Ozal Medical Center, Elazig Yolu 15. Km, 44280 Malatya, Turkey. [akbulutsami@gmail.com](mailto:akbulutsami@gmail.com)  
Telephone: +90-422-3410660  
Fax: +90-422-3410036

Received: February 26, 2016  
Peer-review started: February 26, 2016  
First decision: April 15, 2016  
Revised: May 17, 2016  
Accepted: June 27, 2016  
Article in press: June 29, 2016

Published online: September 16, 2016

### Abstract

Hydatid cysts are a zoonotic disease that can involve many organs and tissues in the human body but primarily involve the liver and lungs. Of the main organs, adrenal glands are those seldom affected by hydatid cysts. The purpose of this study was to present a case with an incidentally detected hydatid cyst of the right adrenal gland on computed tomography, and a positive echinococcus IgG enzyme-linked immunosorbent assay test on top of a toxic multinodular thyroid goiter for which thyroidectomy was indicated.

**Key words:** Hydatid cyst; Unusual location; Adrenal gland; Surgical approach

© **The Author(s) 2016.** Published by Baishideng Publishing Group Inc. All rights reserved.

**Core tip:** With an incidence of about 0.5%, Adrenal hydatid cyst disease is rarely seen, even in geographical areas where the disease is endemic, commonly occurring in the body as part of disseminated hydatid disease. Herein, we present an incidentally detected case of hydatid cyst in the right adrenal gland in a patient with hyperthyroidism secondary to toxic multinodular goiter.

Akbulut S. Incidentally detected hydatid cyst of the adrenal gland: A case report. *World J Clin Cases* 2016; 4(9): 269-272  
Available from: URL: <http://www.wjgnet.com/2307-8960/full/v4/i9/269.htm> DOI: <http://dx.doi.org/10.12998/wjcc.v4.i9.269>

### INTRODUCTION

Hydatid cysts are a zoonotic disease caused by echino-

coccal parasites from the taeniidae family<sup>[1-4]</sup>. In humans, four different types of echinococci have been identified as causing hydatid disease; however, the most frequently presented types are *E. granulosus*, which causes cystic echinococcosis and *E. multilocularis*, which causes alveolar echinococcosis<sup>[1,5-7]</sup>. *E. granulosus* accounts for 95% of all echinococcal diseases that occur in humans<sup>[1]</sup>. Hydatid cysts can involve almost all the organs and tissues; however, in the human body, the liver (45%-77%) and the lungs (10%-50%) are the two organs that are most frequently involved<sup>[2,4,7,8]</sup>. Even in regions where the disease is endemic, hydatid cyst disease is rarely seen in the adrenal glands. Hydatid cysts may occur in the adrenal glands as a primary (isolated) or secondary (associated with the other organs) disease. Cysts may remain asymptomatic for years, or they may be detected incidentally, during the course of radiological examinations conducted for other reasons<sup>[3]</sup>. Depending on the size, adrenal hydatid cysts can sometimes lead to complications. In this study, we present an incidentally detected case of hydatid cyst in the right adrenal gland.

## CASE REPORT

A 64-year-old male patient was admitted to a private hospital with complaints of palpitation, sweating, weight loss, nausea and non-specific abdominal pain. The examination revealed a mass in the right adrenal gland, and hyperthyroidism secondary to toxic multinodular goiter. The patient's medical history revealed no systemic diseases other than the hypertension regulated by medication. Tachycardia, tremor and mild exophthalmos were established during his physical examination. The patient's arterial blood pressure and pulse were 150/90 mmHg and 100/min, respectively. An examination for pheochromocytoma, carried out at the other center, had not revealed any pathological result. Blood analysis at our clinic indicated the following: TSH 0.005 (0.27-4.2  $\mu$ IU/mL), fT4 0.68 (0.93-1.7 ng/dL), fT3 2.36 (2-4.4 pg/mL), Na 145 (136-145 mmol/L), and K 4.7 (3.5-5.5 mmol/L). Thyroid ultrasonography revealed multiple heterogeneous nodules with solid-cystic components, the largest of which was in the left lobe-isthmus intersection (25 mm  $\times$  18 mm). Hyperactive nodular lesions were detected in the thyroid scintigraphy undertaken using 3 mCi Tc-99m pertechnetate.

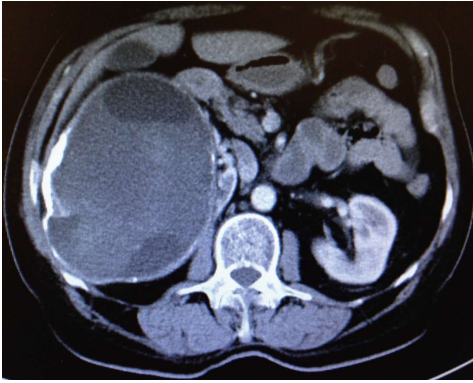Serological analysis of the blood was reported to be *Echinococcus* IgG (+++). Abdominal ultrasonography revealed a lesion of heterogeneous hypoechoic solid mass of 170 mm  $\times$  120 mm originating from the right kidney, which included cystic areas. For advanced investigation, the patient initially underwent contrast-enhanced abdominal computed tomography (CT). CT revealed a 150 mm  $\times$  120 mm mass with peripheral calcification associated with multicentric hypodense cystic necrotic areas, originating from the right adrenal gland and which pressed minimally on the vena cava inferior, gallbladder and choledochus (hydatid cyst? RCC?) (Figure 1). In order to exclude malignancy potential of the mass, the

patient underwent positron emission tomography/CT (PET/CT). In images obtained following an injection of 6.8 mCi F18-fluorodeoxyglucose (FDG), trapping of the FDG was not seen in the 142 mm  $\times$  121 mm mass with a calcified wall and multilocular solid-cystic components extending exophytically from the upper pole of the right kidney. Radiological signs and laboratory results indicated that the lesion in adrenal gland was in accordance with a hydatid cyst. Prior to controlling the clinical manifestations of hyperthyroidism, the patient underwent treatment with propylthiouracil (3  $\times$  100 mg) and propranolol (1  $\times$  50 mg). To maintain the euthyroid state, the patient initially underwent a total thyroidectomy, which was followed by daily Levothyroxine therapy of 100 mg. Based on positive echinococcus IgG enzyme-linked immunosorbent assay (ELISA) serology the patient was treated with albendazole (2  $\times$  400 mg/d) therapy for two weeks. After prophylactic albendazole therapy, patient underwent laparotomy with right subcostal incision. No cystic lesion was seen during exploration of the liver. Surgical sponges, impregnated with 3% NaCl, were positioned in the operating site and 20 cc of 3% NaCl was injected into the cyst for about 10 min. Following this, a partial cystectomy was applied so that only the posterior wall of the cyst remained in its localization. Postoperative albendazole therapy was administered for six weeks, beginning on the post-operative 2<sup>nd</sup> day. During the post-operative 24<sup>th</sup> month control period, the disease was not seen to recur.

## DISCUSSION

Hydatid cyst disease is a serious problem for public health in many parts of the world where sheep and cattle farming is the main livelihood<sup>[1,2]</sup>. Turkey is geographically equidistant between the Middle East and Mediterranean countries where hydatid cyst disease is endemic<sup>[1,2]</sup>. Although humans have no active role in the biological cycle of the disease, they can become infected accidentally by swallowing echinococcus eggs found in dog feces. After swallowing, the eggs are degraded in the digestive system and larvae are freed, which then pass through the hepatic filtration system and reach the lungs<sup>[1]</sup>. Larvae that are not trapped by the lungs' filtration system can be established in other organs of the body such as the spleen, kidneys, brain, heart, bones, muscle tissue, pancreas, breasts, retroperitoneum, thyroid and adrenal glands, via the arterial circulation<sup>[1,5]</sup>. Sometimes larvae may directly enter the systemic circulation via the lymphatic vessels, without entering the portal vein. Rarely, they can also enter the surrounding tissue by adjacent contact<sup>[1]</sup>.

With an incidence of about 0.5%, adrenal hydatid cyst (AHC) disease is rarely seen, even in geographical areas where the disease is endemic<sup>[3,4]</sup>, commonly occurring in the body as part of disseminated hydatid disease. In other words, primary (isolated) AHC is an extremely rare disease<sup>[8,9]</sup>. AHCs are generally asymptomatic lesions, and are commonly detected incidentally, during radiological



**Figure 1** Contrast-enhanced abdominal computed tomography revealed a 150 mm × 120 mm mass with peripheral calcification associated with multicentric hypodense cystic necrotic areas, originating from the right adrenal gland.

examinations conducted for other reasons. AHCs are rarely complicated and become symptomatic most due to symptoms developing as a result of pressure. The most frequent symptoms are pain existing due to inflammation in the adjacent tissues caused by the cyst, and those connected with the gastrointestinal system, such as distension, fullness, nausea, vomiting, constipation and loss of appetite<sup>[4]</sup>. The most severe complication of AHC disease is the rupture of cyst, causing anaphylaxis and bleeding<sup>[3]</sup>. AHC may press on the renal artery externally, but this depends on its size and localization. This condition is called Goldblatt phenomenon, and may lead to arterial hypertension<sup>[3,4,7,8]</sup>. An AHC may press on the adrenal medulla, causing pheochromocytoma-like symptoms, such as headache, palpitation and hypertension<sup>[10,11]</sup>. Another severe complication is the fistulization of AHC to the adjacent intestinal structures<sup>[5]</sup>.

Because adrenal cystic lesions are extremely rare, and most of them are detected incidentally<sup>[4,6]</sup>, the real incidence of it is not known, but reports suggest 0.06% to 0.18% in some autopsy series with about 92% of these lesions being unilateral<sup>[4,6,7]</sup>. With regard to morphology and etiology, these cystic lesions are separated into two groups, non-neoplastic and neoplastic. Adrenal cortical adenomas, cortical carcinomas and pheochromocytomas, may occur as cystic lesions of benign appearance<sup>[4,8]</sup>. Endothelial cysts, pseudocysts, epithelial, and parasitic cysts (6%-7%), are the most commonly occurring non-neoplastic cystic lesions<sup>[3,4,8]</sup>. AHCs account for most of the parasitic cysts. Diagnosis of AHC disease can be made by visualization methods, such as US, CT and MRI, and also by serological tests such as indirect hemagglutination test (IHA) and enzyme-linked immunosorbent assay (IgG, IgE)<sup>[6]</sup>. In the recent years, 18F-FDG PET/CT analyses are also used to exclude malignancy in adrenal lesions, as we've also applied in the case presented in this study.

There are only a limited number of studies in the literature relating to AHC disease, a great many of which are case reports. Therefore we have quite limited experience about the treatment of AHC disease. According

to our experience, the size and localization of the cyst together with the presence of complications are the most important parameters that must be taken into consideration as the main approach to establishing hydatid cyst disease.

The most frequently applied classical method of treatment for AHC disease is the partial or total extraction of the cystic lesion using the open surgical approach, and the application of medical treatment (albendazole, mebendazole, praziquantel) in the preoperative (2-4 wk) and post-operative (4-6 wk) periods. The medical treatment aims to lower cystic pressure, to reduce the viability of cystic components, to decrease the existence of anaphylaxis, and to prevent the development of post-operative recurrence. In keeping with technological improvements, in the cases of uncomplicated AHC disease, the current tendency is to apply this method of treatment using transperitoneal or retroperitoneal laparoscopic techniques<sup>[7]</sup>. PAIR (Puncture, Aspiration, Injection and Respiration) is commonly and successfully applied in treating WHO classification stages CE1 and CE3a cysts, and in the treatment of CE1 and CE3a cysts that have recurred following medical intervention<sup>[2,4]</sup>. To the best of our knowledge, there is no study in the literature about the use of PAIR in treating AHC disease, except for the case report of Akhan *et al*<sup>[4]</sup>; however, in most of the studies related to AHC, it has been claimed that the PAIR method is a technique that should be avoided<sup>[10]</sup>. In our opinion, the most important reason to avoid the use of PAIR in AHC disease is leakage of cyst components from the defect on the cyst wall made by the catheter into the internal environment, with the risk of an anaphylactic reaction. However, with cysts on the parenchymal organs, such as liver, kidneys and spleen, the risk of leakage of the cyst components to the environment is fairly low, since the catheter passes through the parenchyma. We suggest the other reason is the possibility of the cystic lesion being a pheochromocytoma<sup>[4,8]</sup>. Nevertheless, we propose that it may be applied by the experienced radiologists in selected cases that have been proven, by preoperative analyses not to be malign, and in association with prophylactic albendazole therapy. Akhan *et al*<sup>[4]</sup>, who are extremely experienced in PAIR, have also reported that PAIR could obtain successful outcomes in the cases of AHC disease when the main principles are taken into account. Another approach to AHC disease is the principle of "watch and wait". It has been claimed that the "watch and wait" principle could be applied in the WHO Stages VCE4 and CE5 AHCs, or in cases where no complications have developed.

In the present study, we decided to apply surgical treatment, since the size of the cyst was > 10 cm, it was located in the adrenal gland, which is principally responsible for hormone synthesis, and the application of PAIR was inappropriate. An open surgical approach was also preferred due to a lack of experience regarding laparoscopic adrenal surgery. Whichever surgical treatment is applied, in a benign disease such as hydatid cyst, a resection of the cyst by protecting the adrenal

gland should be attempted whenever possible<sup>[3]</sup>. Some authors claim that AHCs commonly grow to enormous sizes, leading to the destruction of the adrenal gland, and they therefore recommend a resection of the adrenal gland together with the cyst<sup>[5]</sup>. Contrary to this, some authors recommend an adrenalectomy but only in the cases where the destruction of the adrenal gland is certain<sup>[7]</sup>.

As a conclusion, hydatid disease rarely occurs in the adrenal glands. Almost all of the papers related with AHC disease are case reports. When a cystic lesion is detected in the adrenal glands, hydatid cyst disease should be considered in differential diagnosis, particularly in patients living in endemic areas. Treatment should be decided by taking into consideration the parameters, such as the size of the cyst, and whether or not it is complicated. If a surgical approach is planned, we suggest that to protect the adrenal gland the cystic components should be drained and, if possible, the cyst wall should be completely resected.

## COMMENTS

### Case characteristics

A 64-year-old male patient was admitted to a private hospital with complaints of palpitation, sweating, weight loss, nausea and non-specific abdominal pain.

### Clinical diagnosis

Hyperthyroidism, adrenal hydatid cyst disease.

### Differential diagnosis

Neoplastic and non-neoplastic adrenal cystic lesions, renal cell carcinoma.

### Laboratory diagnosis

Biochemical blood analysis revealed hyperthyroidism and echinococcus IgG positivity.

### Imaging diagnosis

Contrast-enhanced abdominal computed tomography revealed a mass (150 mm × 120 mm) with peripheral calcification associated with multicentric hypodense cystic necrotic areas, originating from the right adrenal gland. 18F-fluorodeoxyglucose positron emission tomography/computed tomography revealed that a multilocular solid-cystic components (142 mm × 121 mm) extending exophytically from the upper pole of the right kidney.

### Pathological diagnosis

Hydatid cyst disease.

### Treatment

Partial cystectomy + albendazole.

### Related reports

Hydatid cyst disease is a serious problem for public health in many parts of the world where sheep and cattle farming is the main livelihood. Cystic lesions

occur more frequently in the liver, followed by the lungs. This entity is rarely seen in the adrenal glands.

### Term explanation

AHC: Adrenal hydatid cyst; CT: Computed tomography; PET/CT: Positron emission tomography/computed tomography hybrid imaging system.

### Experiences and lessons

When a cystic lesion is detected in the adrenal glands, hydatid cyst disease should be considered in differential diagnosis, particularly in patients living in endemic areas.

### Peer-review

It is a nice work except for a few missing. In this picture there is a huge cyst inferior of liver and gallbladder.

## REFERENCES

- 1 Akbulut S, Yavuz R, Sogutcu N, Kaya B, Hatipoglu S, Senol A, Demircan F. Hydatid cyst of the pancreas: Report of an undiagnosed case of pancreatic hydatid cyst and brief literature review. *World J Gastrointest Surg* 2014; **6**: 190-200 [PMID: 25346801 DOI: 10.4240/wjgs.v6.i10.190]
- 2 Sozuer E, Akyuz M, Akbulut S. Open surgery for hepatic hydatid disease. *Int Surg* 2014; **99**: 764-769 [PMID: 25437585 DOI: 10.9738/INTSURG-D-14-00069.1]
- 3 Nardi W, Buero A, Lozano S, Porto EA. Laparoscopic resection of a bulky primary adrenal hydatid cyst. *J Minim Access Surg* 2015; **11**: 279-281 [PMID: 26622122 DOI: 10.4103/0972-9941.152103]
- 4 Akhan O, Canyigit M, Kaya D, Koksall A, Akgoz A, Yucesoy C, Akinci D. Long-term follow-up of the percutaneous treatment of hydatid cyst in the adrenal gland: a case report and review of the literature. *Cardiovasc Intervent Radiol* 2011; **34** Suppl 2: S256-S259 [PMID: 19669833 DOI: 10.1007/s00270-009-9672-x]
- 5 Ruiz-Rabelo JF, Gomez-Alvarez M, Sanchez-Rodriguez J, Rufian Peña S. Complications of extrahepatic echinococcosis: fistulization of an adrenal hydatid cyst into the intestine. *World J Gastroenterol* 2008; **14**: 1467-1469 [PMID: 18322969 DOI: 10.3748/wjg.14.1467]
- 6 Uludokumaci A, Canberk S, Elcin BB, Uygun N, Cakalir C, Canberk M. Hydatid disease limited to bilateral adrenal glands mimicking tuberculosis. *Cytojournal* 2014; **11**: 20 [PMID: 25191513 DOI: 10.4103/1742-6413.137761]
- 7 Kumar S, Nanjappa B, Gowda KK. Laparoscopic management of a hydatid cyst of the adrenal gland. *Korean J Urol* 2014; **55**: 493-495 [PMID: 25045450 DOI: 10.4111/kju.2014.55.7.493]
- 8 Geramizadeh B, Maghbou M, Ziyaian B. Primary hydatid cyst of the adrenal gland: a case report and review of the literature. *Iran Red Crescent Med J* 2011; **13**: 346-347 [PMID: 22737492]
- 9 Babinska A, Peksa R, Swiatkowska-Stodulska R, Sworczak K. The collection of five interesting cases of adrenal tumors from one medical center. *World J Surg Oncol* 2014; **12**: 377 [PMID: 25487416 DOI: 10.1186/1477-7819-12-377]
- 10 Tazi F, Ahsaini M, Khalouk A, Mellas S, Stuurman-Wieringa RE, Elfassi MJ, Farih MH. Giant primary adrenal hydatid cyst presenting with arterial hypertension: a case report and review of the literature. *J Med Case Rep* 2012; **6**: 46 [PMID: 22297078 DOI: 10.1186/1752-1947-6-46]
- 11 Mokhtari M, ZeraatianNejadDavani S. Primary adrenal hydatid cyst presenting with arterial hypertension. *Arch Iran Med* 2012; **15**: 328-330 [PMID: 22519386]

P- Reviewer: Akoh JA, Taheri S, Yavuz A S- Editor: Ji FF

L- Editor: A E- Editor: Lu YJ





## Tuberculosis terminal ileitis: A forgotten entity mimicking Crohn's disease

Simona Gurzu, Calin Molnar, Anca Otilia Contac, Annamaria Fetyko, Ioan Jung

Simona Gurzu, Calin Molnar, Anca Otilia Contac, Annamaria Fetyko, Ioan Jung, Department of Pathology, University of Medicine and Pharmacy, 540139 Tirgu-Mures, Romania

**Author contributions:** Gurzu S wrote the manuscript and carried out the study design; Molnar C handled the clinical aspects of the case; Contac AO performed the autopsy and interpretation of the macroscopic data; Fetyko A interpreted the histological data and checked the English quality; Jung I performed the histological examination and coordinated the study design and the draft of the manuscript.

**Institutional review board statement:** This case report was exempt from the Institutional Review Board standards at University of Medicine and Pharmacy, Tirgu-Mures, Romania.

**Informed consent statement:** The patient involved in this study gave his written informed consent authorizing use and disclosure of his protected health information.

**Conflict-of-interest statement:** All the authors have no conflicts of interests to declare.

**Open-Access:** This article is an open-access article which was selected by an in-house editor and fully peer-reviewed by external reviewers. It is distributed in accordance with the Creative Commons Attribution Non Commercial (CC BY-NC 4.0) license, which permits others to distribute, remix, adapt, build upon this work non-commercially, and license their derivative works on different terms, provided the original work is properly cited and the use is non-commercial. See: <http://creativecommons.org/licenses/by-nc/4.0/>

**Manuscript source:** Invited manuscript

**Correspondence to:** Simona Gurzu, MD, PhD, Professor, Head of Research Laboratory, Department of Pathology, University of Medicine and Pharmacy, 38 Ghe Marinescu Street, 540139 Tirgu-Mures, Romania. [simonagurzu@yahoo.com](mailto:simonagurzu@yahoo.com)  
Telephone: +40-745-673550  
Fax: +40-265-210407

Received: April 23, 2016  
Peer-review started: April 24, 2016  
First decision: June 6, 2016

Revised: June 8, 2016  
Accepted: July 11, 2016  
Article in press: July 13, 2016  
Published online: September 16, 2016

### Abstract

Intestinal tuberculosis (TB) is an uncommon lesion for which differential diagnosis can be difficult. We present a case of a 53-year-old male and a systematic review of the literature, from clinical symptoms to differential diagnosis, unusual complications and therapy. The patient was admitted to the hospital with signs of acute abdomen as a result of a perforated terminal ileitis. Based on the skip lesions of the terminal ileum and cecum, Crohn's disease (CD) was clinically suspected. An emergency laparotomy and right colectomy with terminal ileum resection was performed and systematic antibiotherapy was prescribed. The patient's status deteriorated and he died 4 d after the surgical intervention. At the autopsy, TB ileotyphlitis was discovered. The clinical criteria of the differential diagnosis between intestinal TB and CD are not very well established. Despite the large amount of published articles on this subject, only 50 papers present new data regarding intestinal TB. Based on these studies and our experience, we present an update focused on the differential diagnosis and therapy of intestinal TB. We highlight the importance of considering intestinal TB as a differential diagnosis for inflammatory bowel disease. Despite the modern techniques of diagnosis and therapy, the fulminant evolution of TB can still lead to a patient's death.

**Key words:** Ileitis; Autopsy; Ileotyphlitis; Crohn's disease; Tuberculosis; Inflammatory bowel disease; Ischemic colitis

© The Author(s) 2016. Published by Baishideng Publishing Group Inc. All rights reserved.

**Core tip:** In this paper, we performed a case-based up-



date of data regarding intestinal tuberculosis. In the case the patient was hospitalized with suspicion of Crohn's disease and ileal perforation but the autopsy revealed a tuberculous ileotyphlitis. The necessity of a complete differential diagnosis and not forgotten the tuberculosis as a potential cause of death was highlighted in the paper.

Gurzu S, Molnar C, Contac AO, Fetyko A, Jung I. Tuberculosis terminal ileitis: A forgotten entity mimicking Crohn's disease. *World J Clin Cases* 2016; 4(9): 273-280 Available from: URL: <http://www.wjgnet.com/2307-8960/full/v4/i9/273.htm> DOI: <http://dx.doi.org/10.12998/wjcc.v4.i9.273>

## INTRODUCTION

Intestinal tuberculosis (TB) is a very rare disease of the twenty-first century that has almost been forgotten in the daily practice of medicine, although the incidence of abdominal TB has increased over the past two decades, especially in the United Kingdom, Asia and other tropical regions<sup>[1-3]</sup>. About 36%-90% of all cases of abdominal TB involve the ileocecal junction and/or jejunoleum (due to the high density of lymphoid aggregates and physiologic stasis in these segments), followed by peritoneal involvement (33%)<sup>[1,4]</sup>. In contrast, the number of reports related to the non-tuberculous inflammatory bowel diseases (IBD), especially ulcerative colitis and Crohn's disease (CD), is increasing and new drugs are being discovered for their therapy.

In this paper, we present a life-threatening case of TB ileotyphlitis that was clinically misdiagnosed as CD. A review of data from the literature regarding the incidence of TB ileotyphlitis and criteria for differential diagnosis of this lesion are also synthesized in the discussion.

### Methodology for the literature review

Using the term "tuberculous ileotyphlitis", only four papers were identified in the PubMed database, being published in the years 1957<sup>[5,6]</sup>, 1982<sup>[7]</sup> and 1999<sup>[8]</sup>. Using the term "tuberculous ileitis", another 68 were identified but only seven were representative and they were included in the present systematic review<sup>[1,2,9-13]</sup>. Using the term "ileal tuberculosis" and "ileocecal tuberculosis" another 605 papers were identified, only 27 of which provided supplementary data. The date of the last search was March 21, 2016. After careful revision, the 34 selected papers were used for the systematic review of the literature that is presented in the discussion, adding another nine new references<sup>[14-41]</sup> (Figure 1).

## CASE REPORT

A 53-year-old healthy Romanian male, without prior medical disorders, was admitted to the hospital complaining of diffuse abdominal pain for the two weeks previous to admission and subfertility. No changes in

bowel habits, weight loss or gastrointestinal bleeding were declared. No chronic use of medications such non-steroidal anti-inflammatory drugs (NSAIDs) or antihypertensive substances were noted.

At the time of admission, severe abdominal pain and signs of acute abdomen, with tenderness and guarding of the abdominal wall and no intestinal sounds was found. The computed tomography (CT)-scan of the abdominal cavity indicated suspicion of peritonitis as result of perforation of the terminal ileum. Multiple skip lesions were also described in the terminal ileum and cecum. An emergency laparotomy was performed. Blood analysis showed anemia [Hemoglobin 9.6 g/dL (normal values 12-17 g/dL), hematocrit 29.8% (normal values 36%-54%)], thrombocytopenia [platelets 87000/ $\mu$ L (normal values 150000-450000/ $\mu$ L)] and leukocytosis [total leukocytes:  $16 \times 10^9$ /L (normal values  $3.6-10 \times 10^9$ /L)].

The intraoperative exploration of the abdominal cavity revealed skip perforations of the terminal ileum and diffuse peritonitis with fibrin membranes that mimicked a CD. A right hemicolectomy with a terminal ileum resection was performed. The other gastrointestinal segments did not show modifications. The postoperative status of the patient deteriorated and, despite undergoing antibiotherapy, the patient died four days after surgery. The clinical diagnosis was septic shock and bilateral bronchopneumonia.

Gross examination of the surgical specimen revealed in the terminal ileum and cecum multiple skip transverse ulcerations 1-2 cm in length with strictures and multiple perforations (Figure 2).

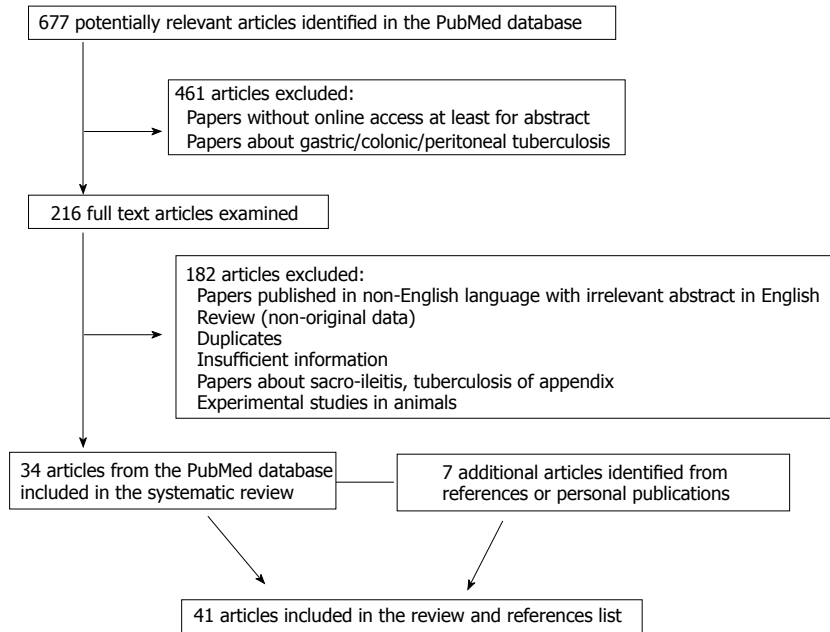
At autopsy, diffuse peritonitis was confirmed. The rest of the gastrointestinal tract presented no modifications. In the lungs, in the upper lobes, multiple small yellowish nodules were found bilaterally (Figure 3). A few nodules were also found in the liver and spleen. No lesions of the kidney, adrenal glands or bone were detected.

Histopathological examination of the surgical specimen revealed tuberculous granulomas in both terminal ileum and cecum. These granulomas presented minimal central caseous necrosis surrounded by epithelioid cells and a few Langhans giant cells. Granulomas were also found in the mesenteric lymph nodes, lung parenchyma, liver and spleen (Figure 3).

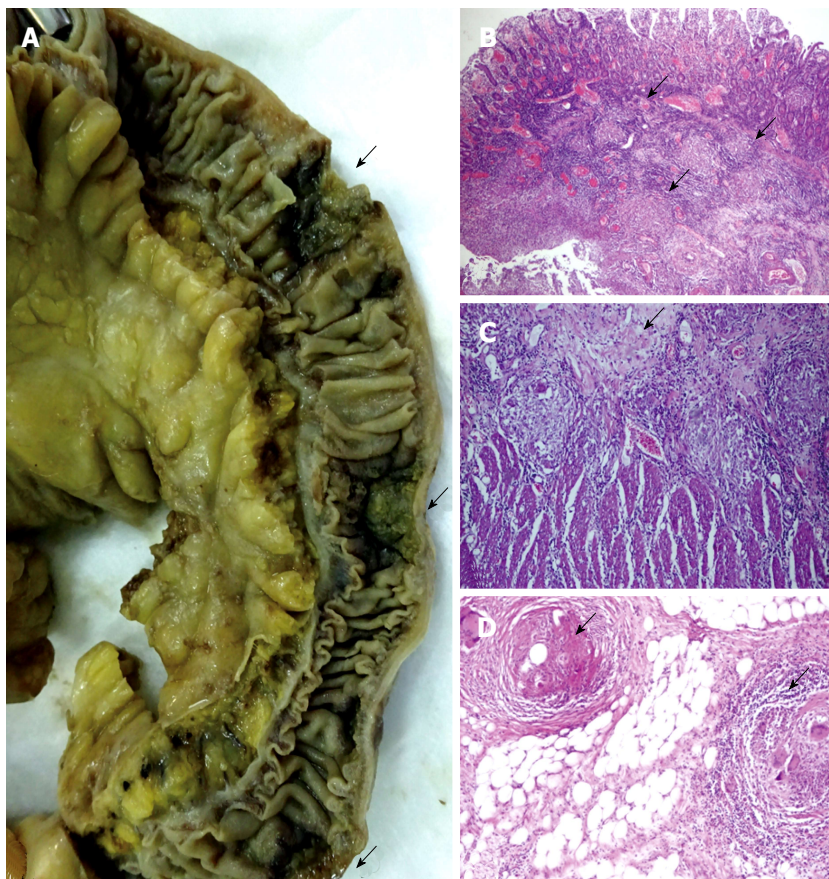
Based on the macroscopically and microscopically derived findings, the final diagnosis was "Miliary TB of the lung, liver and spleen, with transmural tuberculous ileotyphlitis". The death was established as a result of peritonitis-related septic shock.

## DISCUSSION

Despite the improvements in diagnosis and therapy, no specific guidelines have been elaborated for the diagnosis and therapy of symptomatic terminal ileitis<sup>[1,9]</sup>. In patients with isolated terminal ileitis or ileotyphlitis, the differential diagnosis should include CD, TB (*Mycobacterium*



**Figure 1** Preferred reported items for systematic reviews and meta-analyses flow diagram adapted for data about tuberculous ileitis in the PubMed database between 1980 and 2016 (March 21).

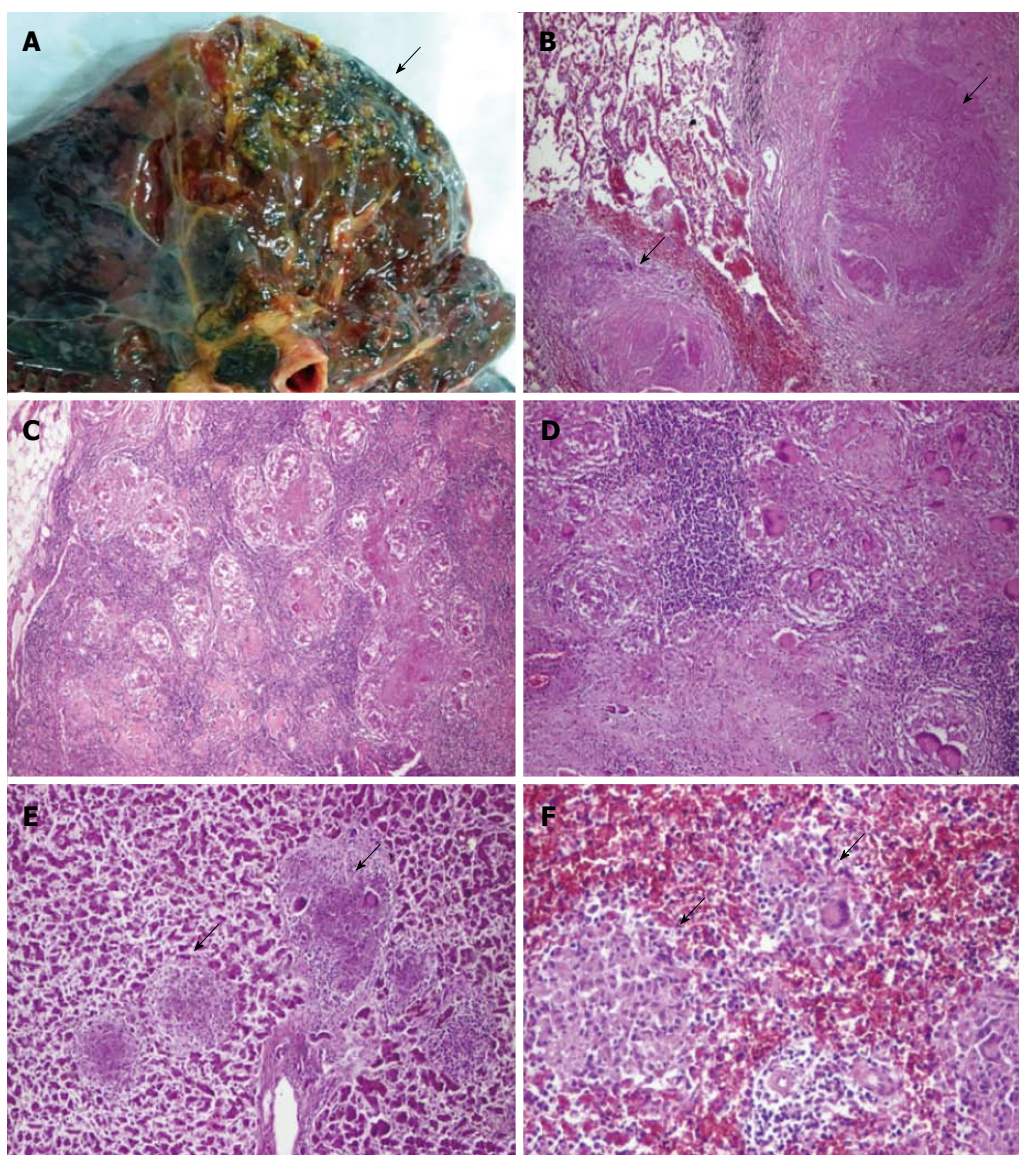


**Figure 2** Tuberculous ileitis show transmuralskip lesions (A) with granulomas in submucosa (B), muscularis propria (C) and serosa (D).

*tuberculosis* or *bovis*), sarcoidosis, non-specific IBD (e.g., *Yersinia* and *Salmonella* infections for ileitis and amebiasis, and *Clostridium* infection for ileocolonic ulcers, ischemia, eosinophilic enteritis and amyloidosis), drug-induced ileitis (e.g., NSAIDs, parenteral gold therapy, oral contraceptives, ergotamine, digoxin, diuretics, antihypertensives, potassium chloride, etc.), radiation ileitis, other granulomatous inflammations (arteritis,

spondyloarthropathies, actinomycosis, infection with *Mycobacterium avium*, *Mycobacterium paratuberculosis* or cytomegalovirus), endometriosis, backwash ileitis in patients with ulcerative colitis, enteric fever, diverticula including Meckel's diverticulum, ileal or colonic angiodysplasia, Behçet's disease, tumors, typhoid fever and foreign-body granulomas determined by the non-absorbable suture materials<sup>[1,2,4,9-11,14,22,23,25,30,35]</sup>. In some





**Figure 3** Miliary tuberculosis with yellowish nodules in the superior lobes of the lung (A) and tuberculous granulomas in lung (B, Ob 2 ×), mesenteric lymph nodes (C, Ob 2 ×, D, Ob 4 ×), liver (E, Ob 4 ×), and spleen (F, Ob 10 ×).

cases, two of these lesion types can be found together. A case of miliary TB with intestinal involvement was recently reported in a patient with Behçet's disease<sup>[25]</sup>. Coexisting intestinal and pulmonary TB should also be explored to sustain the diagnosis<sup>[38]</sup>.

For a proper differential diagnosis, geographical differences must be taken into account. TB is more frequent in tropical countries when compared with Western regions and Saudi Arabia (Table 1)<sup>[1,2,12,16,23,38,39]</sup>. In China, there is an increasing incidence of intestinal TB in parallel with a three-fold increase in the incidence of CD, which was reported in the last two decades<sup>[38,39]</sup>.

The symptoms are relatively similar in both CD and TB and mainly refer to diffuse abdominal-, right iliac fossa- or periumbilical-pain. However, the duration of symptoms (longer in CD and shorter in TB), some particular features, and the associated extra-intestinal disorders may be indicators for a presumptive diagnosis

(Table 1)<sup>[1,2,4,9,12,14,19,23,25,36,38]</sup>. Lower gastrointestinal hemorrhages are more frequent in CD than intestinal TB and the small bowel is the main source of hemorrhage in one third of patients suffering from rectal bleeding (hematochezia)<sup>[1,2,4,9,12,14,19,23,25,36,38]</sup>. However, intestinal hemorrhages can also occur in patients with other IBD types, vascular malformations, aorto-enteric fistula, and tumors<sup>[13]</sup>.

In children with ileal TB, the abdominal mass can be palpated in the right-lower quadrant (67%) and weight loss, malnutrition, abdominal colic, changes of the bowel habits and vomiting are associated symptoms<sup>[17,20,25,36]</sup>. In patients with CD and vasculitis, the extra-intestinal symptoms (Table 1) are associated in 61% of the cases, whereas drug-induced ileitis and spondyloarthropathies are mostly asymptomatic<sup>[4,12]</sup>.

During the colonoscopy and macroscopic examination, both CD and TB showed similar features. They

**Table 1** Criteria of differential diagnosis of intestinal tuberculosis vs Crohn's disease<sup>[1-41]</sup>

Parameter	Tuberculosis	Crohn's disease
Geographic predominance	Asia, India, Pakistan	Western regions, Saudi Arabia
Symptoms		
Duration of symptoms	Short (about 7 mo)	Long (about 58 mo)
Abdominal pain	18%-90%	18%-90%
Acute abdomen	67%	Rare
Weight loss	55%-80%	55%-80%
Anorexia	45%	Frequent
Hematochezia	4%-18%	31%
Diarrhea	35%-55%	69% (bloody diarrhea)
Diarrhea alternating with constipation	38%	Rare
Ascites	Frequent	Rare
Anemia	45%-64%	Frequent
Fever	55%-69%	23%-45%
Night sweats	31%	Rare
Intra-abdominal abscesses	Frequent	Frequent (fistula)
Perianal disease	Rare	Frequent (25%-50%)
Extra-intestinal disorders	Pulmonary tuberculosis (60%), neuropathies (vitamin B12 deficiency)	pyoderma gangrenosum, uveitis, primary sclerosing cholangitis, aphthous stomatitis, arthritis, etc.
CT-scan	Thickening of the ileocecal valve and of the medial wall of the cecum and a retracted, conical, and shrunken cecum	Minimal and uniform intestinal wall thickening, mural stratification, vascular jejunitis or the comb sign, mesenteric fibrofatty proliferation and skip lesions
Colonoscopy	Transverse and rodent-like ulcers with a patulous ileocecal valve	Longitudinal ulcers and a comb sign
Therapy		
Medications	Anti-TB agents (isoniazid, rifampicin, pyrazinamide, streptomycin, ethambutol, etc.)	Steroids anti-tumor-necrosis-factor agents (infliximab)
Surgery	Laparoscopic-assisted ileocelectomies	Usually open surgery

CT: Computed tomography; TB: Tuberculosis.

are characterized by isolated ulcerations (deep or superficial, skip or continuous), hypertrophic/nodular, ulcero-constrictive/ulcero-hypertrophic lesions or fibrous strictures<sup>[4,9,18,38]</sup>. The ileal TB, in most of the cases, is an transverse ulcerative lesion (53%), followed by ulcero-proliferative (27%) and proliferative (20%) features<sup>[38,39]</sup>. The longitudinal ulcers rather indicate CD (Table 1)<sup>[39]</sup>. In a few cases, the colonoscopy is normal<sup>[1]</sup>. Due to an increased incidence of ileitis and to avoid misdiagnoses, routine terminal ileoscopies and biopsies are suggested in symptomatic patients with suspected IBD, as a part of colonoscopy<sup>[2,23]</sup>. Performing a terminal ileoscopy takes three minutes without having any associated complications<sup>[2]</sup>. Moreover, from all unselected patients who undergo colonoscopies, 2%-10% present macroscopic or microscopic abnormalities of the terminal ileum and most of them have Crohn's ileitis<sup>[2]</sup>. For those with normal macroscopic aspects, 3%-14% of them present microscopic changes<sup>[1,2]</sup>.

Microbiological cultures lack a high specificity and/or sensitivity for *Mycobacterium tuberculosis* or acid-fast bacilli because they are positive only in 71% of the cases<sup>[1]</sup>. TB-PCR seems to be specific for TB but low sensitivity was reported<sup>[2,12,30]</sup>. Raised values of serum inflammatory markers do not contribute information about the IBD type<sup>[2]</sup>. The anti-neutrophil cytoplasmic antibodies and anti-*Saccharomyces cerevisiae* antibodies are considered specific to CD but can also be high in TB cases<sup>[12]</sup>. The newest laboratory tests considered to be

diagnostic tools for differentiating TB from CD are the serum-based T-SPOT<sup>[39]</sup> and the immunohistochemical antibodies against *Mycobacterium tuberculosis*<sup>[40]</sup>.

Although most cases of TB ileitis (70%) are the result of the ingestion of infected sputum from an active pulmonary TB, and are rarer as a result of systemic spreading, the chest radiography result is normal in 70% of the cases<sup>[4]</sup>. The histological assessment helps to establish the diagnosis in 66%-86% of the cases<sup>[4,23,38]</sup>. A barium examination shows shallow ulcers, thickened folds and spasticity<sup>[18]</sup>. The CT-scan can also be used for the differential diagnosis between intestinal TB and CD (Table 1)<sup>[18,39]</sup>. In the present case, TB-related skip lesions increased the difficulty of the diagnosis. In the literature, skip ulcers were reported in 14% of patients with intestinal TB<sup>[23]</sup>.

The main complications of ileal TB are: Massive hematochezia (that can be controlled by endoscopic coagulation therapy), bowel obstruction (14%-32% of the cases), necrosis and intestinal perforation (1%-15%), enterocutaneous fistula (2%), ileoileal fistula, mesenteric lymphadenitis with intussusception, ileal loops or intestinal volvulus (2%), ascites, purulent or stercoral peritonitis (1%-10%), septicemia, psoas abscess, liver abscess, portal hypertension in children<sup>[14-17,19,20,23,24,26,31,33,35]</sup>, etc. TB-related intestinal perforation is responsible for 4%-30% of all the non-traumatic terminal ileal perforations<sup>[22,37]</sup> and for 10% of all perforation peritonitis<sup>[35]</sup>. Solitary intestinal perforation occurs in 90% of the cases, but 10%-40% of



the patients can present multiple perforations<sup>[16,24,33]</sup>, such as in our patient's case. The rate of mortality in patients with TB-induced diffuse peritonitis is between 13% and 100%<sup>[16,33,35]</sup>.

In patients receiving anti-TB therapy, paradoxical intestinal perforation was reported 14-270 d from the initiation of the therapeutic regimen, probably as a result of a delayed hypersensitivity response<sup>[24,33]</sup>. This paradoxical phenomenon is more frequent in patients with primary or acquired immunodeficiency diseases, such as defective mitogen-induced interleukin-12 production<sup>[33]</sup> and human immunodeficiency virus-infected patients receiving active anti-retroviral therapy<sup>[24]</sup>.

Another unusual complication of the distal ileum TB, which especially occurs in children, is that of B12 deficiency. It can induce macrocytic anemia and neuropathy with brain atrophy and seizures. The main clinical symptoms are paraplegia, ataxia, fever, fatigue, urinary incontinence and dysarthria<sup>[28]</sup>. Chronic inflammatory demyelinating polyneuropathy was also seen to be associated with intestinal TB<sup>[41]</sup>. In patients with neurological abnormalities, the following conditions (except TB) should be also taking into account: Malnutrition, regional enteritis, Whipple's disease and other gastrointestinal disorders, abuse of valproic acid and paraneoplastic syndromes should be excluded<sup>[28,29]</sup>.

The correct etiological diagnosis of IBD is indispensable for proper therapy (Table 1) because unnecessary anti-TB therapy increases the risk of toxicity and multi-drug resistance and delays the treatment of CD, whereas steroids and infliximab (usually used for CD) can accelerate the TB's dissemination and favor intestinal perforation<sup>[12,33,34,39]</sup>. In patients with neurological abnormalities, administration of vitamin B12 can accelerate the evolution of an undiagnosed tumor, which can be responsible for paraneoplastic neuropathy. Moreover, because TB responds to anti-TB agents, extensive surgical interventions should be avoided, especially in children<sup>[17,20,21,24]</sup>. In patients with CD, the therapeutically management should also taken into account the immune-induced endothelial modifications and vascular dysfunctions<sup>[42,43]</sup>. Due to the higher percentage of atherosclerosis-related complications in these patients<sup>[42,43]</sup>, a complex cardiovascular investigation is mandatory before establishing the therapeutically regimen.

In patients that do not undergo surgery, ileocecal stricture and luminal stenosis are the main late complications. These complications appear in one third of the patients and can be treated using endoscopic balloon dilatation<sup>[27,38]</sup>. They predispose to enterolithiasis in 3% of the patients, with further intestinal strictures, obstructions, perforations, or hematochezia<sup>[32]</sup>.

This case highlights the necessity of including TB enterocolitis as a differential diagnosis in patients with non-specific abdominal symptoms and the difficulty inherent in the differentiation of gastrointestinal TB from CD. In a child with prolonged fever of an unknown origin, TB suspicions should be taken into account.

It can also be considered as a contributing factor in patients with neuropathies.

## COMMENTS

### Case characteristics

A 53-year-old male with acute peritonitis as result of ileal perforation.

### Clinical diagnosis

Skip ulcerations of the terminal ileum, probably Crohn's disease, peritonitis and septic shock.

### Differential diagnosis

Other inflammatory bowel diseases, including ischemic colitis, indeterminate enterocolitis, tuberculosis, angiodysplasia.

### Laboratory diagnosis

Non-specific - slight anemia and leukocytosis.

### Imaging diagnosis

Thoracic radiography - bilateral bronchopneumonia.

### Pathological diagnosis

Postmortem examination of surgical specimens revealed tuberculous ileotyphlitis with tuberculous mesenteric lymphadenopathy and miliary tuberculous granulomas in upper lobes of the lungs, liver and spleen.

### Treatment

Right hemicolectomy with terminal ileum resection. Death was installed 4 d postoperatively.

### Related reports

Few than 50 reports add new data in field of intestinal tuberculosis. Its incidence increased in the last two decades and most of the cases are improper diagnosed. An incorrect diagnosis increases the severity of this disease.

### Term explanation

Tuberculous ileotyphlitis is also known as intestinal tuberculosis involving the terminal ileus and cecum. Hematochezia represents rectal bleeding and can be a sign of an intestinal inflammatory bowel disease.

### Experiences and lessons

This case report shows the necessity of complete exploration of the patient, to identify the associated lesions, and the difficulty of differential diagnosis of terminal ileitis.

### Peer-review

A very good presentation of a case of intestinal tuberculosis which is often forgotten in differential diagnosis clinically.

## REFERENCES

- 1 **Burke KA**, Patel A, Jayaratnam A, Thirupathy K, Snooks SJ. Diagnosing abdominal tuberculosis in the acute abdomen. *Int J Surg* 2014; **12**: 494-499 [PMID: 24560849 DOI: 10.1016/j.ijssu.2014.02.006]
- 2 **Wijewantha HS**, de Silva AP, Niriella MA, Wijesinghe N, Waraketiya P, Kumarasena RS, Dassanayake AS, Hewawisenth Jde S, de Silva HJ. Usefulness of Routine Terminal Ileoscopy and Biopsy during Colonoscopy in a Tropical Setting: A Retrospective Record-Based Study. *Gastroenterol Res Pract* 2014; **2014**: 343849 [PMID: 24550980 DOI: 10.1155/2014/343849]
- 3 **Niriella MA**, De Silva AP, Dayaratne AH, Ariyasinghe MH, Navarathne MM, Peiris RS, Samarasekara DN, Satharasinghe RL,



- Rajindrajith S, Dassanayake AS, Wickramasinghe AR, de Silva HJ. Prevalence of inflammatory bowel disease in two districts of Sri Lanka: a hospital based survey. *BMC Gastroenterol* 2010; **10**: 32 [PMID: 20302651 DOI: 10.1186/1471-230X-10-32]
- 4 **Dilauro S**, Crum-Cianflone NF. Ileitis: when it is not Crohn's disease. *Curr Gastroenterol Rep* 2010; **12**: 249-258 [PMID: 20532706 DOI: 10.1007/s11894-010-0112-5]
  - 5 **Mirzozian EZ**. [Differential diagnosis of tuberculous ileo-typhlitis with non-specific diseases of the abdominal cavity]. *Sov Med* 1957; **21**: 87-91 [PMID: 13455113]
  - 6 **Mirzozian EZ**. [Experience in the use of antibacterial chemotherapy in treatment of ileotyphlitis without active lung process]. *Probl Tuberk* 1957; **35**: 47-53 [PMID: 13441626]
  - 7 **Schwarz KO**, Cohen A, Hertz IH. Tuberculous ileotyphlitis with formation of large ileal pseudopolyp mimicking tumor. *Mt Sinai J Med* 1982; **49**: 421-425 [PMID: 6983654]
  - 8 **Dantsig II**, Loseva TL, Levin NF. [Tuberculous ileotyphlitis]. *Khirurgiia* (Mosk) 1999; **(6)**: 64 [PMID: 10410522]
  - 9 **Kedia S**, Kurrey L, Pratap Mouli V, Dhingra R, Srivastava S, Pradhan R, Sharma R, Das P, Tiwari V, Makharia G, Ahuja V. Frequency, natural course and clinical significance of symptomatic terminal ileitis. *J Dig Dis* 2016; **17**: 36-43 [PMID: 26670338 DOI: 10.1111/1751-2980.12307]
  - 10 **Ng SC**, Chan FK. Infections and inflammatory bowel disease: challenges in Asia. *J Dig Dis* 2013; **14**: 567-573 [PMID: 23875824 DOI: 10.1111/1751-2980.12091]
  - 11 **Hermion-Taylor J**, Barnes N, Clarke C, Finlayson C. Mycobacterium paratuberculosis cervical lymphadenitis, followed five years later by terminal ileitis similar to Crohn's disease. *BMJ* 1998; **316**: 449-453 [PMID: 9492675 DOI: 10.1136/bmj.316.7129.449]
  - 12 **Amarapurkar DN**, Patel ND, Rane PS. Diagnosis of Crohn's disease in India where tuberculosis is widely prevalent. *World J Gastroenterol* 2008; **14**: 741-746 [PMID: 18205265 DOI: 10.3748/wjg.14.741]
  - 13 **Briley CA**, Jackson DC, Johnsrude IS, Mills SR. Acute gastrointestinal hemorrhage of small-bowel origin. *Radiology* 1980; **136**: 317-319 [PMID: 6967614 DOI: 10.1148/radiology.136.2.6967614]
  - 14 **Anand AC**, Patnaik PK, Bhalla VP, Chaudhary R, Saha A, Rana VS. Massive lower intestinal bleeding--a decade of experience. *Trop Gastroenterol* 2001; **22**: 131-134 [PMID: 11681104]
  - 15 **Sefr R**, Rotterová P, Konečný J. Perforation peritonitis in primary intestinal tuberculosis. *Dig Surg* 2001; **18**: 475-479 [PMID: 11799299 DOI: 10.1159/000050197]
  - 16 **Al Salamah SM**, Bismar H. Acute ileal tuberculosis perforation: a case report. *Saudi J Gastroenterol* 2002; **8**: 64-66 [PMID: 19861794]
  - 17 **Ozbey H**, Tireli GA, Salman T. Abdominal tuberculosis in children. *Eur J Pediatr Surg* 2003; **13**: 116-119 [PMID: 12776244 DOI: 10.1055/s-2003-39588]
  - 18 **Engin G**, Balk E. Imaging findings of intestinal tuberculosis. *J Comput Assist Tomogr* 2005; **29**: 37-41 [PMID: 15665681 DOI: 10.1097/01.rct.0000151935.52808.0c]
  - 19 **Park JK**, Lee SH, Kim SG, Kim HY, Lee JH, Shim JH, Kim JS, Jung HC, Song IS. [A case of intestinal tuberculosis presenting massive hematochezia controlled by endoscopic coagulation therapy]. *Korean J Gastroenterol* 2005; **45**: 60-63 [PMID: 15665569]
  - 20 **Boukthir S**, Mrad SM, Becher SB, Khaldi F, Barsaoui S. Abdominal tuberculosis in children. Report of 10 cases. *Acta Gastroenterol Belg* 2004; **67**: 245-249 [PMID: 15587330]
  - 21 **Balsara KP**, Shah CR, Maru S, Sehgal R. Laparoscopic-assisted ileo-colectomy for tuberculosis. *Surg Endosc* 2005; **19**: 986-989 [PMID: 15868250 DOI: 10.1007/s00464-004-9196-z]
  - 22 **Wani RA**, Parray FQ, Bhat NA, Wani MA, Bhat TH, Farzana F. Nontraumatic terminal ileal perforation. *World J Emerg Surg* 2006; **1**: 7 [PMID: 16759405 DOI: 10.1186/1749-7922-1-7]
  - 23 **Leung VK**, Law ST, Lam CW, Luk IS, Chau TN, Loke TK, Chan WH, Lam SH. Intestinal tuberculosis in a regional hospital in Hong Kong: a 10-year experience. *Hong Kong Med J* 2006; **12**: 264-271 [PMID: 16912352]
  - 24 **Leung VK**, Chu W, Lee VH, Chau TN, Law ST, Lam SH. Tuberculosis intestinal perforation during anti-tuberculosis treatment. *Hong Kong Med J* 2006; **12**: 313-315 [PMID: 16912360]
  - 25 **Kapan M**, Karabacak I, Aydogan F, Kusanlan R, Kisacik B. Intestinal perforation due to miliary tuberculosis in a patient with Behcet's disease. *Mt Sinai J Med* 2006; **73**: 825-827 [PMID: 17008948]
  - 26 **Polat KY**, Aydinli B, Yilmaz O, Aslan S, Gursan N, Ozturk G, Onbas O. Intestinal tuberculosis and secondary liver abscess. *Mt Sinai J Med* 2006; **73**: 887-890 [PMID: 17117317]
  - 27 **Akarsu M**, Akpinar H. Endoscopic balloon dilatation applied for the treatment of ileocecal valve stricture caused by tuberculosis. *Dig Liver Dis* 2007; **39**: 597-598 [PMID: 17420160 DOI: 10.1016/j.dld.2007.02.008]
  - 28 **Toosi TD**, Shahi F, Afshari A, Roushan N, Kermanshahi M. Neuropathy caused by B12 deficiency in a patient with ileal tuberculosis: a case report. *J Med Case Rep* 2008; **2**: 90 [PMID: 18355418 DOI: 10.1186/1752-1947-2-90]
  - 29 **Jung I**, Gurzu S, Balasa R, Motataianu A, Contac AO, Halmaciu I, Popescu S, Simu I. A coin-like peripheral small cell lung carcinoma associated with acute paraneoplastic axonal Guillain-Barre-like syndrome. *Medicine* (Baltimore) 2015; **94**: e910 [PMID: 26039124 DOI: 10.1097/MD.0000000000000910]
  - 30 **Surlin V**, Georgescu E, Comănescu V, Mogoantă SS, Georgescu I. Ileal iterative spontaneous perforation from foreign body granuloma: problems of histopathologic diagnosis. *Rom J Morphol Embryol* 2009; **50**: 749-752 [PMID: 19942978]
  - 31 **Miura T**, Shimizu T, Nakamura J, Yamada S, Yanagi M, Usuda H, Emura I, Takahashi T. [A case of intestinal tuberculosis associated with ileo-ileal fistula]. *Nihon Shokakibyo Gakkai Zasshi* 2010; **107**: 416-426 [PMID: 20203445]
  - 32 **Negi SS**, Sud R, Chaudhary A. Tubercular ileal stricture with enterolithiasis presenting as massive lower gastrointestinal bleed. *Trop Gastroenterol* 2010; **31**: 47-48 [PMID: 20860228]
  - 33 **Law ST**, Chiu SC, Li KK. Intestinal tuberculosis complicated with perforation during anti-tuberculous treatment in a 13-year-old girl with defective mitogen-induced IL-12 production. *J Microbiol Immunol Infect* 2014; **47**: 441-446 [PMID: 22841619 DOI: 10.1016/j.jmii.2012.06.004]
  - 34 **Cappell MS**, Saad A, Bortman JS, Amin M. Ileocolonic tuberculosis clinically, endoscopically, and radiologically mimicking Crohn's disease: disseminated infection after treatment with infliximab. *J Crohns Colitis* 2014; **8**: 560-562 [PMID: 24360259 DOI: 10.1016/j.crohns.2013.11.022]
  - 35 **Yadav D**, Garg PK. Spectrum of perforation peritonitis in delhi: 77 cases experience. *Indian J Surg* 2013; **75**: 133-137 [PMID: 24426408 DOI: 10.1007/s12262-012-0609-2]
  - 36 **Surewad G**, Lobo I, Shanbag P. Pulmonary and ileal tuberculosis presenting as Fever of undetermined origin. *J Clin Diagn Res* 2014; **8**: PD01-PD02 [PMID: 25478420 DOI: 10.7860/JCDR/2014/9695.4998]
  - 37 **Khalid S**, Burhanulhuq AA. Non-traumatic spontaneous ileal perforation: experience with 125 cases. *J Ayub Med Coll Abbottabad* 2014; **26**: 526-529 [PMID: 25672180]
  - 38 **Gan H**, Mely M, Zhao J, Zhu L. An Analysis of the Clinical, Endoscopic, and Pathologic Features of Intestinal Tuberculosis. *J Clin Gastroenterol* 2016; **50**: 470-475 [PMID: 26974755]
  - 39 **Zhang T**, Fan R, Wang Z, Hu S, Zhang M, Lin Y, Tang Y, Zhong J. Differential diagnosis between Crohn's disease and intestinal tuberculosis using integrated parameters including clinical manifestations, T-SPOT, endoscopy and CT enterography. *Int J Clin Exp Med* 2015; **8**: 17578-17589 [PMID: 26770348]
  - 40 **Ihama Y**, Hokama A, Hibiya K, Kishimoto K, Nakamoto M, Hirata T, Kinjo N, Cash HL, Higa F, Tateyama M, Kinjo F, Fujita J. Diagnosis of intestinal tuberculosis using a monoclonal antibody to Mycobacterium tuberculosis. *World J Gastroenterol* 2012; **18**: 6974-6980 [PMID: 23322996 DOI: 10.3748/wjg.v18.i47.6974]
  - 41 **Chong VH**, Joseph TP, Telisinghe PU, Jaliha A. Chronic inflammatory demyelinating polyneuropathy associated with intestinal tuberculosis. *J Microbiol Immunol Infect* 2007; **40**: 377-380 [PMID: 17712474]
  - 42 **Cicccone MM**, Principi M, Ierardi E, Di Leo A, Ricci G, Carbonara S, Gesualdo M, Devito F, Zito A, Cortese F, Scicchitano P. Inflammatory

bowel disease, liver diseases and endothelial function: is there a linkage? *J Cardiovasc Med* (Hagerstown) 2015; **16**: 11-21 [PMID: 25427048 DOI: 10.2459/JCM.0000000000000149]

43 **Principi M**, Mastrodonato M, Scicchitano P, Gesualdo M, Sassara

M, Guida P, Bucci A, Zito A, Caputo P, Albano F, Ierardi E, Di Leo A, Ciccone MM. Endothelial function and cardiovascular risk in active inflammatory bowel diseases. *J Crohns Colitis* 2013; **7**: e427-e433 [PMID: 23473915 DOI: 10.1016/j.crohns.2013.02.001]

**P- Reviewer:** Cao SS, Ciccone MM, Matsuda A, Pearson JS, Saniabadi AR, Smids C **S- Editor:** Gong XM **L- Editor:** A  
**E- Editor:** Lu YJ



## Cystic jejunal duplication with Heinrich's type I ectopic pancreas, incidentally discovered in a patient with pancreatic tail neoplasm

Simona Gurzu, Tivadar Bara Jr, Tivadar Bara, Annamaria Fetyko, Ioan Jung

Simona Gurzu, Annamaria Fetyko, Ioan Jung, Department of Pathology, University of Medicine and Pharmacy, 540139 Tirgu-Mures, Romania

Tivadar Bara Jr, Tivadar Bara, Department of Surgery, University of Medicine and Pharmacy, 540139 Tirgu-Mures, Romania

**Author contributions:** Gurzu S wrote the manuscript and carried out the study design; Bara Jr T participated at the surgical intervention and interpretation of clinical data; Bara T participated at the surgical intervention and interpretation of the data from literature; Fetyko A checked the English quality; Jung I contributed to the histological assessment of the surgical specimens and coordinated the study design and the draft of the manuscript.

**Institutional review board statement:** This case report was exempt from the Institutional Review Board standards at University of Medicine and Pharmacy, Tirgu-Mures, Romania.

**Informed consent statement:** The patient involved in this study gave his written informed consent authorizing use and disclosure of his protected health information.

**Conflict-of-interest statement:** All the authors have no conflicts of interests to declare.

**Open-Access:** This article is an open-access article which was selected by an in-house editor and fully peer-reviewed by external reviewers. It is distributed in accordance with the Creative Commons Attribution Non Commercial (CC BY-NC 4.0) license, which permits others to distribute, remix, adapt, build upon this work non-commercially, and license their derivative works on different terms, provided the original work is properly cited and the use is non-commercial. See: <http://creativecommons.org/licenses/by-nc/4.0/>

**Manuscript source:** Invited manuscript

**Correspondence to:** Simona Gurzu, MD, PhD, Professor, Head of Research Laboratory, Department of Pathology, University of Medicine and Pharmacy, 38 Ghe Marinescu Street, 540139 Tirgu Mures, Romania. [simonagurzu@yahoo.com](mailto:simonagurzu@yahoo.com)  
Telephone: +40-74-5673550

Fax: +40-26-5210407

Received: April 29, 2016

Peer-review started: April 29, 2016

First decision: May 17, 2016

Revised: June 3, 2016

Accepted: July 11, 2016

Article in press: July 13, 2016

Published online: September 16, 2016

### Abstract

The aim of this study was to present a case of enteric duplication cyst and criteria for a proper differential diagnosis. A 51-year-old male was hospitalized for pancreatic tail neoplasm and distal pancreatectomy with splenectomy was performed. During surgery, a jejunal cystic lesion was incidentally detected and jejunectomy was performed. Microscopically, the cyst was observed to be covered by Keratin 7/Keratin 20 positive intestinal type epithelium and the muscularis layer was shared by the cyst and adjacent jejunum, without a cleavage plane between the cyst wall and jejunal muscularis propria. In the deep muscularis propria, a Heinrich's type I ectopic pancreas was also noted. In the pancreatic tail, a low grade intraepithelial lesion (panIN-1a) was diagnosed. This case highlights the necessity for a correct differential diagnosis of such rare lesions. Roughly 30 cases of jejunal duplication cysts have been reported to date in the PubMed database.

**Key words:** Intestine; Duplication; Embryogenesis; Ectopic pancreas

© **The Author(s) 2016.** Published by Baishideng Publishing Group Inc. All rights reserved.

**Core tip:** In this paper we presented a very rare case of an incidentally diagnosed jejunal duplication cyst in a patient with a pancreatic tail neoplasm. The association

between duplication cyst and ectopic pancreas supports the theory of an embryonal development disorder.

Gurzu S, Bara Jr T, Bara T, Fetyko A, Jung I. Cystic jejunal duplication with Heinrich's type I ectopic pancreas, incidentally discovered in a patient with pancreatic tail neoplasm. *World J Clin Cases* 2016; 4(9): 281-284 Available from: URL: <http://www.wjgnet.com/2307-8960/full/v4/i9/281.htm> DOI: <http://dx.doi.org/10.12998/wjcc.v4.i9.281>

## INTRODUCTION

Cystic subepithelial lesions of the gastrointestinal (GI) tract are uncommon in adults and can be indicators of an ectopic pancreas, Meckel's diverticulum, duplication cysts, cystic GI stromal tumors, neuroendocrine tumors and lymphangiomas<sup>[1-6]</sup>. An ectopic pancreas, which is defined as the presence of pancreatic tissue in abnormal locations without anatomical and vascular continuity with the pancreas, can occur as a nodular or cystic lesion confined to the submucosa and muscularis propria<sup>[1]</sup>. Based on the von Heinrich classification (1909), the ectopic pancreas can be composed of ducts, acini and Langerhans islands (Heinrich's type I), duct and acini without islands (Heinrich's type II), or only several ducts, some of them cystically dilated without exocrine or endocrine components (Heinrich's type III heterotopy)<sup>[3]</sup>. Meckel's diverticulum occurs as a result of cystic dilatation of the omphalomesenteric duct remnants and arises from the antimesenteric border of the small intestine<sup>[4]</sup>.

Enteric duplication cysts are primarily diagnosed during early childhood and supposedly the result of developmental anomalies<sup>[4-7]</sup>. They represent 60% of all the cystic lesions of the GI tract<sup>[4]</sup>. Roughly 75% of the duplication cysts have been reported in the abdominal cavity, the most frequent location being the ileum (22%-60% of abdominal cavity duplication cysts), followed by the jejunum (8%-16%), colon (7%), stomach (2%-9%) and appendix<sup>[1,2,5-8]</sup>. The remaining 25% of cysts can involve the intrathoracic or thoracoabdominal organs<sup>[7]</sup>. In contrast to Meckel's diverticulum, it develops along the mesenteric border of the adjacent intestine and shares the mesenteric blood supply<sup>[4,6]</sup>. Macroscopically, the duplication cysts are classified as spherical or tubular cysts that can communicate (or not) with the GI lumen<sup>[4,8]</sup>.

In this paper, we present a rare case of a spherical, communicating duplication cyst of the jejunum associated with pancreatic heterotopy.

## CASE REPORT

A 51-year-old male with chronic alcohol abuse was admitted to hospital with intermittent abdominal pain that increased in intensity after meals and jaundice

of the mucosae and skin. He had a two-year history of steatohepatitis, chronic pancreatitis, as well as secondary insulin-dependent diabetes mellitus.

The ultrasonographic examination revealed enlargement of the pancreatic tail. Blood analysis showed slight anemia (hemoglobin 9.8 g/dL; hematocrit 29.2%), normal glycemia, and slightly increased serum levels of amylase (141 u/L).

Due to magnetic resonance imaging (MRI)-based suspecting a pancreatic tumor and mechanical jaundice, it was decided to perform a laparotomy. A splenectomy and pancreatic tail resection was performed. No gallstones were identified. The intraoperative exploration of the abdominal cavity also revealed a well-defined jejunal cystic swelling. The resection of the jejunum (135 mm in length) and end-to-end anastomosis was performed.

Gross examination of the surgical specimens showed a fibrotic pancreatic tail. The round-shaped cystic lesion of the jejunum had a diameter of 20 mm and was covered by intact jejunal mucosa. The serosal surface was intact. On the cut section, the monolocular cyst was filled with serous fluid and had a smooth inner surface. The cystic wall thickness was roughly 2-3 mm (Figure 1).

Histopathological examination revealed large fibrotic areas in the pancreatic tail and pancreatic ducts with focal dysplasia (panIN-1a). The jejunal cyst was covered by Keratin 20 positive intact jejunal mucosa. It was located in the submucosa and muscularis propria. A cystic denuded inner surface with fragmented flat epithelium, marked by both Keratin 20 and Keratin 7 was noted and the capillary rich granulation tissue dissociated the underlying smooth muscle fibers. The muscularis layer was shared by the cyst and adjacent jejunum. The communication area was also lined by granulation tissue. In the deep muscularis propria, proliferation of pancreatic-type Keratin 7 positive/Keratin 20 negative ducts and acini, without cytological atypia, as well as rare Langerhans islands were also observed. No positivity for c-KIT or DOG-1 was noted.

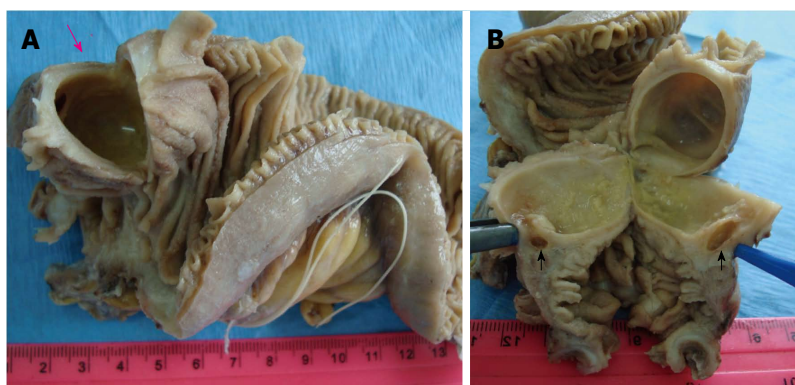
Based on the macroscopic and microscopic findings, the final diagnosis was "jejunal duplication cysts, with synchronous Heinrich's type I ectopic pancreas<sup>[3]</sup> and low grade intraepithelial neoplasia of the pancreatic tail".

Postoperative evolution was uneventful. The patient refused to stop alcohol consumption. At 27 mo after surgery he was admitted to hospital with scleral jaundice and a 7 mm large gallstone was found in the common bile duct. Laparoscopic choledochoduodenostomy was performed without postoperative complications.

## DISCUSSION

Due to its unusual occurrence, no diagnosis guidelines or therapy have been elaborated for GI cystic duplications. Most of these are found incidentally during surgery for other abdominal conditions<sup>[1,4-7]</sup>, similar to the present case.





**Figure 1** Macroscopic findings of the jejunal spherical duplication cyst. The submucosal cystic tumor is covered by intact jejunal mucosa and is filled with clear fluid (pink arrow, A). Its wall shares the muscularis layer of the adjacent jejunum and a communication with the intestinal lumen is seen (black arrows, B).

In the intestine, spherical type cysts are predominant<sup>[4,6]</sup>. They have thick walls and are filled with clear secretions or mucus and generally do not communicate with the intestinal lumen<sup>[6]</sup>. Tubular duplications are long cystic lesions, involving more than one GI segment, with possible communication with the adjacent intestine<sup>[6]</sup>. In the present case, the spherical cyst contained serous fluid and there was communication with the intestinal lumen that favored the inflammatory process.

Where the jejunum is concerned, the first two reports of cystic lesions were published in 1950<sup>[9,10]</sup> and roughly 30 cases of jejunal duplication cysts have been reported to date in the PubMed database.

The microscopic diagnosis of a GI duplication cyst is based on the following features: A well-defined cyst firmly attached to the adjacent GI segment, lined by gastric or intestinal mucosa, surrounded by at least one well-developed smooth muscle layer, without a cleavage plane between the cyst and muscularis propria<sup>[4-7]</sup>.

Pathogenesis appears to be related to embryonic development disorders. Due to frequent localization of these lesions in the stomach on the greater curvature (95% of all gastric cysts), it was assumed that they develop during embryogenesis dorsally to the primitive gut<sup>[4]</sup>. In some patients, heterotopic gastric, intestinal, or respiratory mucosa, but also annular or an ectopic pancreas (similar to the present case) was associated<sup>[4-6,8]</sup>. In other cases, communication between the cyst and the vertebral canal, spina bifida, or involvement of the mesenteric arteries was seen<sup>[8]</sup>. Based on these facts, etiopathogenetic theories include disorders of the embryonal development of the digestive system similar to the persistence of embryonic diverticula, partial twinning, vascular malformations, a split notochord (which explains association of spina bifida) and aberrant re-canalization following the solid phase of fetal enteric mucosal development<sup>[6,7]</sup>. Intrauterine hypoxia- or trauma-related division of the intestinal lumen can also be involved<sup>[6,7]</sup>.

In the present case, the asymptomatic jejunal duplication cyst was incidentally found intraoperatively in a patient diagnosed with intraepithelial neoplasia of the pancreatic tail, developed as part of a background that included chronic alcoholic pancreatitis. The association between duplication cyst and ectopic pancreas supports the theory of an embryonal development disorder.

## COMMENTS

### Case characteristics

A 51-year-old male with recurrent abdominal pain.

### Clinical diagnosis

Pancreatic tail neoplasm in a patient with chronic alcohol-related pancreatitis.

### Differential diagnosis

Other cystic lesions of the gastrointestinal (GI) tract including ectopic pancreas in the jejunum.

### Laboratory diagnosis

Non-specific - slight anemia and increased level of amylases.

### Imaging diagnosis

Computed tomography-scan-pancreatic tail neoplasia.

### Pathological diagnosis

Intraepithelial neoplasia of the pancreas associated with incidentally discovered jejunal cystic duplication with Heinrich's type I ectopic pancreas.

### Treatment

Splenectomy, pancreatic tail resection and resection of the jejunum.

### Related reports

About 30 cases of jejunal duplication cysts.

### Term explanation

Enteric duplication cyst is a well defined cystic malformation, which can involve any of the GI segments. It is firmly attached to the adjacent GI segment, lined by gastric or intestinal mucosa, and surrounded by at least one well developed smooth muscle layer, without a cleavage plane between the cyst and muscularis propria.

### Experiences and lessons

This case report shows the criteria used for differential diagnosis of cystic lesions of the jejunum and summarizes the hypotheses about the origin of these cysts.

### Peer review

The case is very well presented.

## REFERENCES

- 1 Hirasaki S, Kubo M, Inoue A, Miyake Y, Oshiro H. Jejunal small ectopic pancreas developing into jejunojejunal intussusception: a rare cause of ileus. *World J Gastroenterol* 2009; **15**: 3954-3956

- [PMID: 19701981 DOI: 10.3748/wjg.15.3954]
- 2 **Deesomsak M**, Aswakul P, Junyangdikul P, Prachayakul V. Rare adult gastric duplication cyst mimicking a gastrointestinal stromal tumor. *World J Gastroenterol* 2013; **19**: 8445-8448 [PMID: 24363539 DOI: 10.3748/wjg.v19.i45.8445]
  - 3 **von Heinrich H**. Ein Beitrag zur Histologie des sogen: Akzessorischen Pankreas. *Virchows Arch A Pathol Anat Histopathol* 1909; **198**: 392-401 [DOI: 10.1007/BF02085327]
  - 4 **Ogino H**, Ochiai T, Nakamura N, Yoshimura D, Kabemura T, Kusumoto T, Matsuura H, Nakashima A, Honda K, Nakamura K. Duplication cyst of the small intestine found by double-balloon endoscopy: a case report. *World J Gastroenterol* 2008; **14**: 3924-3926 [PMID: 18609722 DOI: 10.3748/wjg.14.3924]
  - 5 **Scatizzi M**, Calistri M, Feroci F, Girardi LR, Moraldi L, Rubio CA, Moretti R, Nesi G. Gastric duplication cyst in an adult: case report. *In Vivo* 2000; **19**: 975-978 [PMID: 16277009]
  - 6 **Curci MR**, Compton CC. Case records of the Massachusetts General Hospital. Weekly clinicopathological exercises. Case 8-2000. An 8 1/2 year-old girl with a painful abdominal mass. *N Engl J Med* 2000; **342**: 801-806 [PMID: 10717016 DOI: 10.1056/NEJM200003163421108]
  - 7 **Sharma S**, Yadav AK, Mandal AK, Zaheer S, Yadav DK, Samie A. Enteric Duplication Cysts in Children: A Clinicopathological Dilemma. *J Clin Diagn Res* 2015; **9**: EC08-EC11 [PMID: 26435952 DOI: 10.7860/JCDR/2015/12929.6381]
  - 8 **Stringer MD**, Spitz L, Abel R, Kiely E, Drake DP, Agrawal M, Stark Y, Brereton RJ. Management of alimentary tract duplication in children. *Br J Surg* 1995; **82**: 74-78 [PMID: 7881964 DOI: 10.1002/bjs.1800820126]
  - 9 **Oyama Valenzuela E**. [Obstruction of the jejunum by a chyloferous cyst of the mesentery]. *Rev Med Chil* 1950; **78**: 280-281 [PMID: 15441455]
  - 10 **van der Hal I**, Mooy GS. [Intra-abdominal and intrathoracic macrodiverticulum of the jejunum of gastrogenic origin; relation to mediastinal gastrogenic cysts]. *Ned Tijdschr Geneesk* 1950; **94**: 2533-2538 [PMID: 14775773]

**P- Reviewer:** Lassandro F, Wani IA    **S- Editor:** Ji FF    **L- Editor:** A  
**E- Editor:** Lu YJ



## Tooth loss caused by displaced elastic during simple preprosthetic orthodontic treatment

Simona Dianiskova, Chiara Calzolari, Marco Migliorati, Armando Silvestrini-Biavati, Gaetano Isola, Fabio Savoldi, Domenico Dalessandri, Corrado Paganelli

Simona Dianiskova, Orthodontic Postgraduate Programme, Dental School, Slovak Medical University, 83303 Bratislava, Slovakia

Chiara Calzolari, Marco Migliorati, Armando Silvestrini-Biavati, Orthodontics Department, School of Dentistry, University of Genova, 16132 Genova, Italy

Gaetano Isola, Department of Biomedical, Odontostomatological Sciences and of Morphological and Functional Images, University of Messina, 98122 Messina, Italy

Gaetano Isola, Department of Neurosciences, Reproductive and Odontostomatological Sciences, School of Medicine, University "Federico II", 80131 Napoli, Italy

Fabio Savoldi, Domenico Dalessandri, Corrado Paganelli, Department of Orthodontics, School of Dentistry, University of Brescia, 25123 Brescia, Italy

**Author contributions:** Dianiskova S and Migliorati M conceived the study; Calzolari C and Dalessandri D did the study design and drafting of the manuscript; Savoldi F and Isola G did the literature review and provided additional information; Silvestrini-Biavati A and Paganelli C contributed in revision and approval of the final draft of the manuscript.

**Institutional review board statement:** This case report was exempt by the Institutional Review Board Standards of the School of Dentistry of University of Brescia.

**Informed consent statement:** The authors certify that they have obtained the appropriate patient consent form. In the form the patient gave his consent for his images and other clinical information to be reported in the journal. The patient understands that his name and initials will not be published, and his anonymity will be guaranteed.

**Conflict-of-interest statement:** The authors declare the absence of conflicting interests.

**Open-Access:** This article is an open-access article which was selected by an in-house editor and fully peer-reviewed by external

reviewers. It is distributed in accordance with the Creative Commons Attribution Non Commercial (CC BY-NC 4.0) license, which permits others to distribute, remix, adapt, build upon this work non-commercially, and license their derivative works on different terms, provided the original work is properly cited and the use is non-commercial. See: <http://creativecommons.org/licenses/by-nc/4.0/>

**Manuscript source:** Invited manuscript

**Correspondence to:** Domenico Dalessandri, DDS, MS (Ortho), PhD, Adjunct Assistant Professor, Department of Orthodontics, School of Dentistry, University of Brescia, 1 p.le Spedali Civili, 25123 Brescia, Italy. [dalessandridomenico@libero.it](mailto:dalessandridomenico@libero.it)  
**Telephone:** +39-030-3995783  
**Fax:** +39-030-3996097

**Received:** April 27, 2016  
**Peer-review started:** April 28, 2016  
**First decision:** May 17, 2016  
**Revised:** June 4, 2016  
**Accepted:** July 11, 2016  
**Article in press:** July 13, 2016  
**Published online:** September 16, 2016

### Abstract

The use of elastics to close a diastema or correct tooth malpositions can create unintended consequences if not properly controlled. The American Association of Orthodontists recently issued a consumer alert, warning of "a substantial risk for irreparable damage" from a new trend called "do-it-yourself" orthodontics, consisting of patients autonomously using elastics to correct tooth position. The elastics can work their way below the gums and around the roots of the teeth, causing damage to the periodontium and even resulting in tooth loss. The cost of implants to replace these teeth would well exceed the cost of proper orthodontic care. This damage could

also occur in a dental office, when a general dentist tries to perform a simplified orthodontic correction of a minor tooth malposition. The present case report describes a case of tooth loss caused by a displaced intraoral elastic, which occurred during a simple preprosthetic orthodontic treatment.

**Key words:** Orthodontics; Intraoral elastics; Periodontal damage; Tooth extraction; Pre-prosthetic treatment

© **The Author(s) 2016.** Published by Baishideng Publishing Group Inc. All rights reserved.

**Core tip:** This article describes the harmful effects caused by the subgingival displacement of an intraoral elastic during a simple preprosthetic orthodontic treatment. The paper highlights the importance of being referred to an orthodontist to correct malocclusions, warning general dentists against undertaking complex orthodontic treatments without having the necessary orthodontic skills. This work also describes a phenomenon called, “do-it-yourself orthodontics”, which is gaining in popularity amongst adolescents thanks to the tutorials available on various websites such as YouTube, and strongly warns against this practice because it may cause irreparable periodontal damage and tooth loss.

Dianiskova S, Calzolari C, Migliorati M, Silvestrini-Biavati A, Isola G, Savoldi F, Dalessandri D, Paganelli C. Tooth loss caused by displaced elastic during simple preprosthetic orthodontic treatment. *World J Clin Cases* 2016; 4(9): 285-289 Available from: URL: <http://www.wjgnet.com/2307-8960/full/v4/i9/285.htm> DOI: <http://dx.doi.org/10.12998/wjcc.v4.i9.285>

## INTRODUCTION

Orthodontic treatments represent a major investment in the future dental health and appearance of adolescent smiles. Teeth move as a reaction to forces applied to them, and in many cases orthodontists use different teeth in the same jaw to give the resistance or anchorage needed to provide the required forces.

During some phases of an orthodontic treatment, elastics or rubber bands are used to move teeth or jaws, or sometimes both. By careful treatment planning and controlling the strength, direction, and duration of forces, orthodontists aim to minimize the use of elastics, which requires patients' active cooperation and could be harmful if improperly controlled. Unfortunately, there are cases in which good treatment outcomes would be impossible without the use of elastics<sup>[1-8]</sup>.

In 1728, Pierre Fouchard proposed a method to close an anterior diastema using a silk ligature. From this moment, on the history of using elastics in orthodontics has abounded in literature, culminating with Ricketts in 1970, who applied a bioprogressive segmented light square wire technique in open bite cases, and

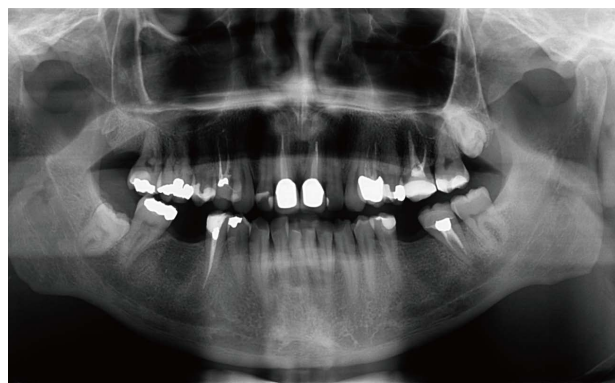

Figure 1 Pretreatment orthopantomography.

suggested the use of anterior vertical elastics to close the bite. In other cases, Roth recommended short Class II intermaxillary elastics to help level the curve of Spee in association with extraoral forces, and Langlade developed clinical guidelines for elastics applications in different situations, proposing helpful guides for biomechanics management<sup>[8-15]</sup>.

Today, an odd new craze is taking over the Internet, with YouTube videos of teenagers making “do-it-yourself” (DIY) orthodontics. Youngsters are sticking elastic bands around their teeth in a bid to help straighten wonky teeth or to close gaps, a practice becoming known as a “gap band”, but dentists have warned against people adopting this gap band as they could cause damage to their gums and are potentially lose their teeth entirely.

## CASE REPORT

A 37-year-old male underwent a simple orthodontic pre-prosthetic treatment, after signing informed consent, with the aim to correct a scissor-bite between the upper second molar and the lower second molar on the right side (Figure 1).

A general dentist placed a buccal orthodontic button in the centre of the crown of the upper second molar and another button on the lower second molar lingual surface, and then instructed the patient to wear an orthodontic elastic to correct the scissor bite. The patient had to wear the elastic all day, except during meals and oral hygiene.

The patient was recalled monthly in order to check tooth movements, but after a few months he experienced discomfort in the gum at the level of the second lower molar, where the rubber band was applied. During a clinical examination, slight mobility of the lower molar was observed, which was attributed to the orthodontic force application, even if in presence of augmented periodontal probing (7 mm). A periapical radiograph revealed the presence of a small periodontal angular defect mesial to the molar, in absence of foreign bodies or tartar (Figure 2). The elastic use was immediately suspended and the lingual button removed, in order to avoid any interference with oral hygiene maintenance.



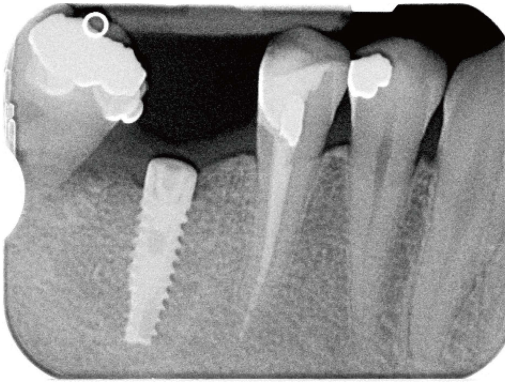


Figure 2 Lower second molar mesial angular periodontal defect.

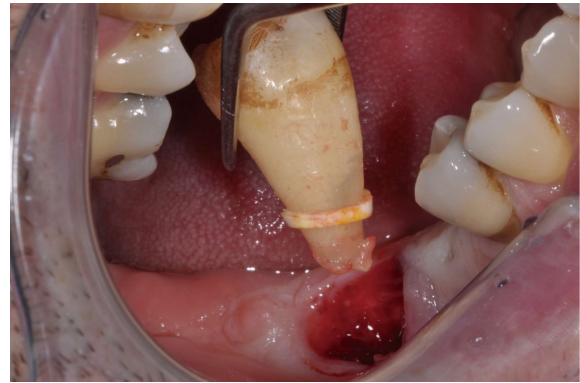


Figure 4 Lower second molar extraction.

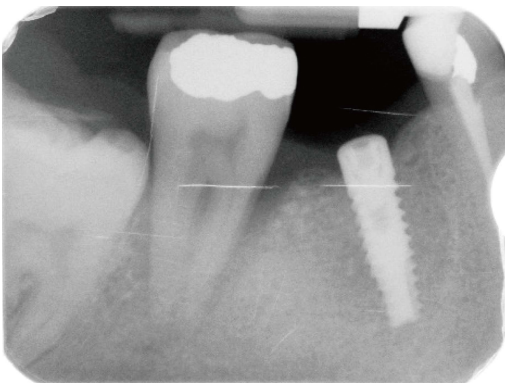


Figure 3 Worsening of lower second molar mesial angular periodontal defect.

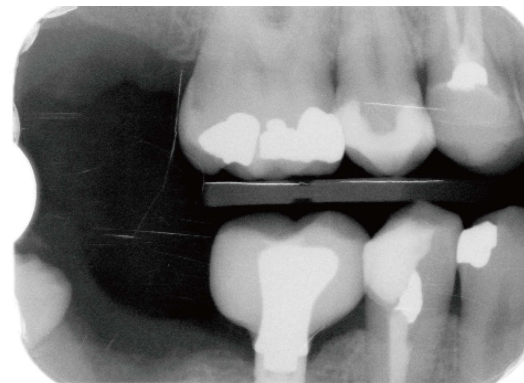


Figure 5 Post-treatment radiograph after second molar extraction.

After consultation with a periodontist, subgingival root planning under anaesthesia, followed by chlorhexidine gel insertion and a systemic antibiotic therapy, was performed. The patient was then recalled one week later, at which point no improvement was found, but rather a significant mobility increase was noted. Periodontal probing was 12 mm all around the tooth. In a periapical radiograph, worsening of the mesial angular defect was observed, affecting the root length (Figure 3). The dentist then decided to extract the second molar.

During the extraction procedure, the dentist found an intraoral elastic around the root, in proximity to the apex (Figure 4). It was not possible to visualize this elastic in the radiological exams because this type of elastic is, unlike separator elastics, not radiopaque. After treatment failure, considering that the second upper molar was very buccally inclined and that the patient did not want to undergo a complete orthodontic treatment, the dentist decided to extract the molar to avoid occlusal interference and accumulation of food between 16 and 17, with the risk of upper first molar loss (Figure 5).

Three years later, a good bone level was noticed around the implant and the teeth adjacent to the 2<sup>nd</sup> molars extraction sites (Figure 6).

## DISCUSSION

The popularity of peer-to-peer education, employing powerful diffusion channels such as YouTube, makes it possible for people to find instructions to create everything from home decorations and recipes to home repairs and design inspiration based on a DIY approach. The DIY pins and videos most often shared make a complex task seem effortless, like anyone can do it.

The practice of closing an interincisal diastema as shown in several YouTube tutorials is gaining more and more interest, with emulation between adolescents now causing several dental associations to issue severe warnings about this dangerously growing trend that sees young people using cheap elastics to straighten their teeth, a procedure that could cause permanent damage to their gums and even result in tooth loss. For example, the American Association of Orthodontists (AAO) has issued a series of television and radio public service announcements (PSAs) as part of a public health campaign to inform consumers about the risks associated with DIY orthodontics. AAO provides a simple message to the viewing and listening audiences: "Moving teeth is a medical procedure and needs personal supervision by an orthodontist. Orthodontists are specialists who, after graduating from dental school,

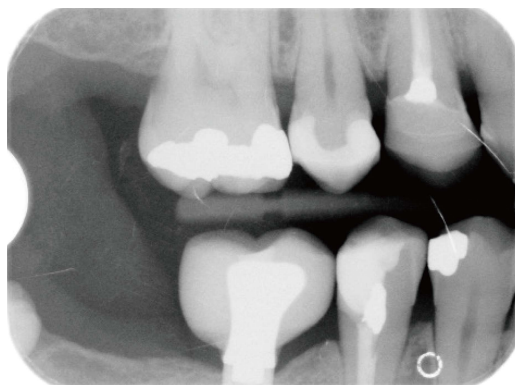


Figure 6 Three-year follow-up.

receive two to three years of additional education in orthodontics at an accredited orthodontic residency program<sup>1-8</sup>.

Though approximately 60% of Americans have dental coverage as part of their insurance plan, many are not covered for orthodontic procedures, and this lack of coverage is a concern—especially for young people, whose insecurities about the appearance of their smile cause some to resort to a dangerous short cut in order to achieve “perfect” straight teeth.

Unfortunately, DIY orthodontics have taken on a whole new life, over the last couple of years. DIY can be a scary trend, especially in terms of self-diagnosing or self-treating dental health problems: After reading some articles on DIY teeth straightening, people may believe that they can safely straighten their own teeth without oversight from an orthodontist, based on the advice from a young blogger, who has tens of thousands of viewers watching her enthusiastically describe how to use elastic rubber bands to fix a gap in her teeth. A simple search on YouTube shows many others who have filmed their DIY teeth-straightening journey.

Even if conducted by a general dentist, a superficial approach to an excessively simplified “orthodontic” treatment could be dangerous if not properly controlled, potentially leading to more harm than benefit.

In the present case report, the absence of a radiopaque elastic did not allow the dentist to detect the elastic that was in the periodontal pocket, which was not even clinically identified during initial periodontal probing. Effectively, the early identification of it would avoid tooth loss: The absence of a correct differential diagnosis between severe and aggressive periodontitis and the presence of the elastic in the pocket, together with the lack of orthodontic experience and competence, is the real cause of the tooth loss.

A qualified orthodontist creates a unique individualized treatment plan that takes into account an individual patient’s needs and objectives, strategically placing braces for tooth movement in a structured and biologically sensible manner. This placement typically involves several different movements and force levels, moving certain teeth into different places to allow other

teeth to move correctly, thereby allowing each tooth the necessary room to move, leading to the creation of a straight, beautiful, and healthy smile. The orthodontist monitors tooth movement and makes necessary adjustments to advance the process; they assess the health of the patient’s teeth and gums at regular appointments and alerts the patient about actions to take if anything is amiss<sup>16-26</sup>.

Indeed, even if performing simply teeth position corrections, appropriate orthodontic oversight in conjunction with regular in-person visits is needed, because an overly simplified approach could easily become an uncontrolled treatment that could then lead to important side effects.

The aim of this case report was to warn both general dentists and patients against undertaking a simplified orthodontic treatment, without the appropriate oversight of a well-trained orthodontist, showing the possible consequences and damages to dental structures. Furthermore, this article highlights the importance of producing radiopaque intraoral orthodontic elastics that could be easily detected in the case of unexpected subgingival displacement.

## ACKNOWLEDGMENTS

The authors are grateful to Dr. Piero Rossi for the clinical documentation of this case report.

## COMMENTS

### Case characteristics

A 37-year-old male underwent a simple orthodontic preprosthetic treatment using an intraoral elastic that was anchored to a vestibular button that was placed on the upper right second molar, and a lingual button placed on the lower right second molar. After few months the patient reported significant pain and presented with impressive bone loss around the lower right second molar.

### Clinical diagnosis

Tooth mobility accompanied with periodontal probing on the right-side lower second molar.

### Differential diagnosis

Aggressive periodontitis.

### Laboratory diagnosis

All laboratory values were within normal limits.

### Imaging diagnosis

Periapical radiography revealed an angular bone defect around the tooth.

### Pathological diagnosis

Loss of periodontal attachment.

### Treatment

Tooth extraction.

### Related reports

Tooth loss caused by displaced elastic should be suspected if a significant periodontal defect suddenly appears that involves only one or two teeth, for no

other apparent reason.

### Term explanation

Preprosthetic orthodontic treatment is an orthodontic treatment performed to allow a better restorative solution that ameliorates the position of teeth that must be restored.

### Experiences and lessons

Appropriate orthodontic oversight in conjunction with regular in-person visits is needed even if performing simple tooth position corrections. In addition, this article highlights the importance of producing radiopaque intraoral orthodontic elastics in order to better visualize them during a radiological exam, especially cases in which they become displaced under the gingival level.

### Peer-review

This is a very good case report, which describes a severe periodontal destruction caused by an orthodontic elastic displacement.

## REFERENCES

- Bratu CD, Fleser C, Glavan F. The effect of intermaxillary elastics in orthodontic therapy. *Timisoara Medical J* 2004; **54**: 406-409
- Nelson B, Hansen K, Hägg U. Class II correction in patients treated with class II elastics and with fixed functional appliances: a comparative study. *Am J Orthod Dentofacial Orthop* 2000; **118**: 142-149 [PMID: 10935954 DOI: 10.1067/mod.2000.104489]
- Kersey ML, Glover KE, Heo G, Raboud D, Major PW. A comparison of dynamic and static testing of latex and nonlatex orthodontic elastics. *Angle Orthod* 2003; **73**: 181-186 [PMID: 12725375]
- Parikakis KA, Moberg S, Hellsing E. Evaluation of the variable anchorage straightwire technique using Ricketts' growth prediction. *Eur J Orthod* 2009; **31**: 76-83 [PMID: 18832190 DOI: 10.1093/ejo/cjn038]
- Hocevar RA. Begg-edgewise diagnosis-determined totally individualized orthodontic technique: introduction to clinical applications. *Am J Orthod Dentofacial Orthop* 1987; **92**: 50-69 [PMID: 3474885 DOI: 10.1016/0002-9416(85)90105-8]
- Mittal M, Thiruvengatchari B, Sandler PJ, Benson PE. A three-dimensional comparison of torque achieved with a preadjusted edgewise appliance using a Roth or MBT prescription. *Angle Orthod* 2015; **85**: 292-297 [PMID: 24978676 DOI: 10.2319/122313-941]
- Moysi B, Dyer F, Benson PE. Roth versus MBT: does bracket prescription have an effect on the subjective outcome of pre-adjusted edgewise treatment? *Eur J Orthod* 2013; **35**: 236-243 [PMID: 22051535 DOI: 10.1093/ejo/cjr126]
- Egolf RJ, BeGole EA, Upshaw HS. Factors associated with orthodontic patient compliance with intraoral elastic and headgear wear. *Am J Orthod Dentofacial Orthop* 1990; **97**: 336-348 [PMID: 2321602 DOI: 10.1016/0889-5406(90)70106-M]
- Langlade M. Optimization of Orthodontic elastics. New York: GAC International Ed, 2000
- McSherry PF, Bradley H. Class II correction-reducing patient compliance: a review of the available techniques. *J Orthod* 2000; **27**: 219-225 [PMID: 11099554 DOI: 10.1179/ortho.27.3.219]
- Rock WP, Wilson HJ, Fisher SE. Force reduction of orthodontic elastomeric chains after one month in the mouth. *Br J Orthod* 1986; **13**: 147-150 [PMID: 3460631 DOI: 10.1179/bjo.13.3.147]
- Aras A, Cinsar A, Bulut H. The effect of zigzag elastics in the treatment of Class II division 1 malocclusion subjects with hypo- and hyperdivergent growth patterns. A pilot study. *Eur J Orthod* 2001; **23**: 393-402 [PMID: 11544789 DOI: 10.1093/ejo/23.4.393]
- Reddy P, Kharbanda OP, Duggal R, Parkash H. Skeletal and dental changes with nonextraction Begg mechanotherapy in patients with Class II Division 1 malocclusion. *Am J Orthod Dentofacial Orthop* 2000; **118**: 641-648 [PMID: 11113799 DOI: 10.1067/mod.2000.110584]
- Gracco A, Siviero L, de Stefani A, Bruno G, Stellini E. Anterior open-bite orthodontic treatment in an adult patient: A clinical case report. *Int Orthod* 2016; **14**: 171-183 [PMID: 27080595 DOI: 10.1016/j.ortho.2016.03.011]
- Dalessandri M, Buffoli B, Scavia S, Dalessandri D, Di Rosario F, Rodella LF, Salgarello S. Socket and ridge preservation using a mixture of nano-hydroxyapatite, polylactic and polyglycolic acid: histological evaluation. *Dental Cadmos* 2015; **83**: 472-484 [DOI: 10.1016/S0011-8524(15)30065-9]
- Buffoli B, Dalessandri M, Favero G, Mensi M, Dalessandri D, Di Rosario F, Stacchi C, Rezzani R, Salgarello S, Rodella LF. AQP1 expression in human gingiva and its correlation with periodontal and peri-implant tissue alterations. *Acta Histochem* 2014; **116**: 898-904 [PMID: 24698289 DOI: 10.1016/j.acthis.2014.02.010]
- Pacheco AA, Saga AY, de Lima KF, Paese VN, Tanaka OM. Stress Distribution Evaluation of the Periodontal Ligament in the Maxillary Canine for Retraction by Different Alveolar Corticotomy Techniques: A Three-dimensional Finite Element Analysis. *J Contemp Dent Pract* 2016; **17**: 32-37 [PMID: 27084860 DOI: 10.5005/jp-journals-10024-1799]
- Castelli A, Le Gall M, Monnet-Corti V. [Behavior of the periodontium during leveling of the mandibular incisors: what precautions are needed?]. *Orthod Fr* 2016; **87**: 99-102 [PMID: 27083231 DOI: 10.1051/orthodfr/2016006]
- Pignoly M, Monnet-Corti V, Le Gall M. [Reason for failure in the treatment of impacted and retained teeth]. *Orthod Fr* 2016; **87**: 23-38 [PMID: 27083220 DOI: 10.1051/orthodfr/2016001]
- Silvestrini-Biavati A, Migliorati M, Demarziari E, Tecco S, Silvestrini-Biavati P, Polimeni A, Saccucci M. Clinical association between teeth malocclusions, wrong posture and ocular convergence disorders: an epidemiological investigation on primary school children. *BMC Pediatr* 2013; **13**: 12 [PMID: 23343244 DOI: 10.1186/1471-2431-13-12]
- Agarwal A, Mahajan S, Verma S, Bhardwaj P, Sharma G. Evaluation of the Stress Induced in Tooth, Periodontal Ligament & Alveolar Bone with Varying Degrees of Bone Loss During Various Types of Orthodontic Tooth Movements. *J Clin Diagn Res* 2016; **10**: ZC46-ZC52 [PMID: 27042585 DOI: 10.7860/JCDR/2016/17206.7235]
- Livada R, Shiloah J, Hottel TL. Non-Orthodontic, Non-Restorative Closure of Acquired Diastemata. *J Tenn Dent Assoc* 2015; **95**: 34-36; quiz 37-38 [PMID: 27008768]
- Cui J, Li J, Wang W, Han X, Du J, Sun J, Feng W, Liu B, Liu H, Amizuka N, Li M. The effect of calcitriol on high mobility group box 1 expression in periodontal ligament cells during orthodontic tooth movement in rats. *J Mol Histol* 2016; **47**: 221-228 [PMID: 26956363 DOI: 10.1007/s10735-016-9669-0]
- Migliorati M, Isaia L, Cassaro A, Rivetti A, Silvestrini-Biavati F, Gastaldo L, Piccardo I, Dalessandri D, Silvestrini-Biavati A. Efficacy of professional hygiene and prophylaxis on preventing plaque increase in orthodontic patients with multibracket appliances: a systematic review. *Eur J Orthod* 2015; **37**: 297-307 [PMID: 25246605 DOI: 10.1093/ejo/cju044]
- Feng X, Oba T, Oba Y, Moriyama K. An interdisciplinary approach for improved functional and esthetic results in a periodontally compromised adult patient. *Angle Orthod* 2005; **75**: 1061-1070 [PMID: 16448256]
- Janson M, Janson G, Murillo-Goizueta OE. A modified orthodontic protocol for advanced periodontal disease in Class II division 1 malocclusion. *Am J Orthod Dentofacial Orthop* 2011; **139**: S133-S144 [PMID: 21435531 DOI: 10.1016/j.ajodo.2009.03.053]

P- Reviewer: Siqueira SRDT, Yuan K S- Editor: Ji FF L- Editor: A E- Editor: Lu YJ





## Surgical treatment of cementoblastoma associated with apicoectomy and endodontic therapy: Case report

Bernardo Cesar Costa, Guilherme José Pimentel Lopes de Oliveira, Maria das Graças Afonso Miranda Chaves, Renan Roberto da Costa, Mário Francisco Real Gabrielli, Juliane Maria Guerreiro-Tanomaru, Mário Tanomaru-Filho

Bernardo Cesar Costa, Guilherme José Pimentel Lopes de Oliveira, Maria das Graças Afonso Miranda Chaves, Renan Roberto da Costa, Mário Francisco Real Gabrielli, Juliane Maria Guerreiro-Tanomaru, Mário Tanomaru-Filho, Foor-UNESP, Faculdade de Odontologia de Araraquara, Universidade Estadual Paulista, Araraquara, SP 14801-903, Brasil

Peer-review started: April 6, 2016  
 First decision: May 17, 2016  
 Revised: June 8, 2016  
 Accepted: July 11, 2016  
 Article in press: July 13, 2016  
 Published online: September 16, 2016

**Author contributions:** Costa BC and da Costa RR performed the treatments and collected the patients' clinical data; Costa BC, de Oliveira GJPL and Tanomaru-Filho M analyzed the data and wrote the paper; all authors contributed to this paper.

**Institutional review board statement:** The dental school Araraquara encourages research and this agreement clinical management conducted in this case report.

**Informed consent statement:** The patient was informed and signed a term of free and informed consent in order to approve the publication of this clinical case.

**Conflict-of-interest statement:** The authors declare they have no conflict of interest.

**Open-Access:** This article is an open-access article which was selected by an in-house editor and fully peer-reviewed by external reviewers. It is distributed in accordance with the Creative Commons Attribution Non Commercial (CC BY-NC 4.0) license, which permits others to distribute, remix, adapt, build upon this work non-commercially, and license their derivative works on different terms, provided the original work is properly cited and the use is non-commercial. See: <http://creativecommons.org/licenses/by-nc/4.0/>

**Manuscript source:** Invited manuscript

**Correspondence to:** Mário Tanomaru-Filho, DDS, Foor-UNESP, Faculdade de Odontologia de Araraquara, Universidade Estadual Paulista, Rua Humaitá, 1680, Araraquara, SP 14801-903, Brasil. [tanomaru@uol.com.br](mailto:tanomaru@uol.com.br)  
 Telephone: +55-16-33016390  
 Fax: +55-16-33016390

Received: April 2, 2016

### Abstract

This case report describes the surgical removal of cementoblastoma associated with apicoectomy and endodontic therapy. The patient, an 18-year-old man, presented pain in the region of the mandibular body on the right side. On clinical exam, bone expansion was observed in the region at the bottom of the vestibular sulcus, pain on palpation, slight extrusion of tooth 46 with presence of pulp vitality. Radiographic exams demonstrated the presence of a radiopaque area and discrete radiolucent halo associated with the root of tooth 46, suggesting the diagnosis of cementoblastoma. Endodontic treatment of tooth 46 was performed and exeresis of the lesion by apicoectomy. Twelve months after the first surgery, recurrence of the lesion was observed, and a new apicoectomy was necessary, this time up to the middle third of the root. Clinical radiographic control 12 mo after the second surgical intervention demonstrated absence of signs and symptoms, radiographic repair, with tooth 46 shown to be fully functional.

**Key words:** Endodontic treatment; Cementoblastoma; Apicoectomy

© The Author(s) 2016. Published by Baishideng Publishing Group Inc. All rights reserved.

**Core tip:** The present clinical case demonstrated that surgical treatment associated with endodontic treatment was effective for the treatment of cementoblastoma.



However, the patient must be followed-up due to the possibility of recurrence of this lesion. The importance of these findings demonstrated that the treatment of cementoblastoma may be conservative with maintenance of the affected teeth.

Costa BC, de Oliveira GJPL, Chaves MGAM, da Costa RR, Gabrielli MFR, Guerreiro-Tanomaru JM, Tanomaru-Filho M. Surgical treatment of cementoblastoma associated with apicoectomy and endodontic therapy: Case report. *World J Clin Cases* 2016; 4(9): 290-295 Available from: URL: <http://www.wjgnet.com/2307-8960/full/v4/i9/290.htm> DOI: <http://dx.doi.org/10.12998/wjcc.v4.i9.290>

## INTRODUCTION

The cementoblastoma is a benign odontogenic tumor of ectomesenchymal origin that preferentially affects the roots of mandibular molars or premolars, in patients in the age range of 20-30 years, with slight prevalence in the male sex<sup>[1-3]</sup>. Its low prevalence (less than 6% of all odontogenic tumors)<sup>[4,5]</sup>, generates difficulties with documentation about the standard treatment for this tumor<sup>[1-3,6]</sup>.

Due to the high rates of recurrence (approximately 31.7%) associated with incomplete removal of the lesion<sup>[1]</sup>, the treatment of cementoblastoma most indicated in the literature, is removal of the tooth together with the tumor<sup>[6,7]</sup>. However, endodontic treatment of the affected tooth associated with apicoectomy during removal of the lesion is cited as an alternative<sup>[1]</sup>, allowing the tooth to be maintained in function<sup>[1]</sup>.

Conservative treatment of cementoblastoma lesions allows the tooth to be maintained. However, this has rarely been documented in the literature. Therefore, the aim of this case report was to demonstrate the treatment of cementoblastoma by means of endodontic treatment and removal of the lesion associated with apicoectomy and maintenance of the affected tooth after two surgical interventions. Follow-up of one year after the second surgical intervention showed clinical and radiographic success.

## CASE REPORT

The patient, an 18-year-old man, presented to the service of the Endodontic Clinic at the Dental School of Araraquara (FOAr-Unesp) with complaints of pain in the mandibular body on the right side for the past 3 mo. On clinical exam, the patient presented with discrete facial asymmetry, bone expansion in the region at the bottom of the vestibular sulcus, pain on palpation, slight extrusion of tooth 46, and positive response to the pulp vitality test. In the imaging exams, a radiopaque mass was observed, measuring approximately 1.5 mm in diameter, with discrete radiolucent halo associated with the root apex of tooth 45 (Figure 1A).

Considering the clinical and imaging exams, the treatment initially proposed was worn of the occlusal surface of the tooth involved, to alleviate the painful symptoms. After 30 d of follow-up, the patient returned because of the pain. In view of the new situation, and considering the diagnostic hypothesis of cementoblastoma, the option taken was to perform endodontic treatment of tooth 46 and exeresis of the lesion by apicoectomy and peripheral osteotomy (Figure 1B-G).

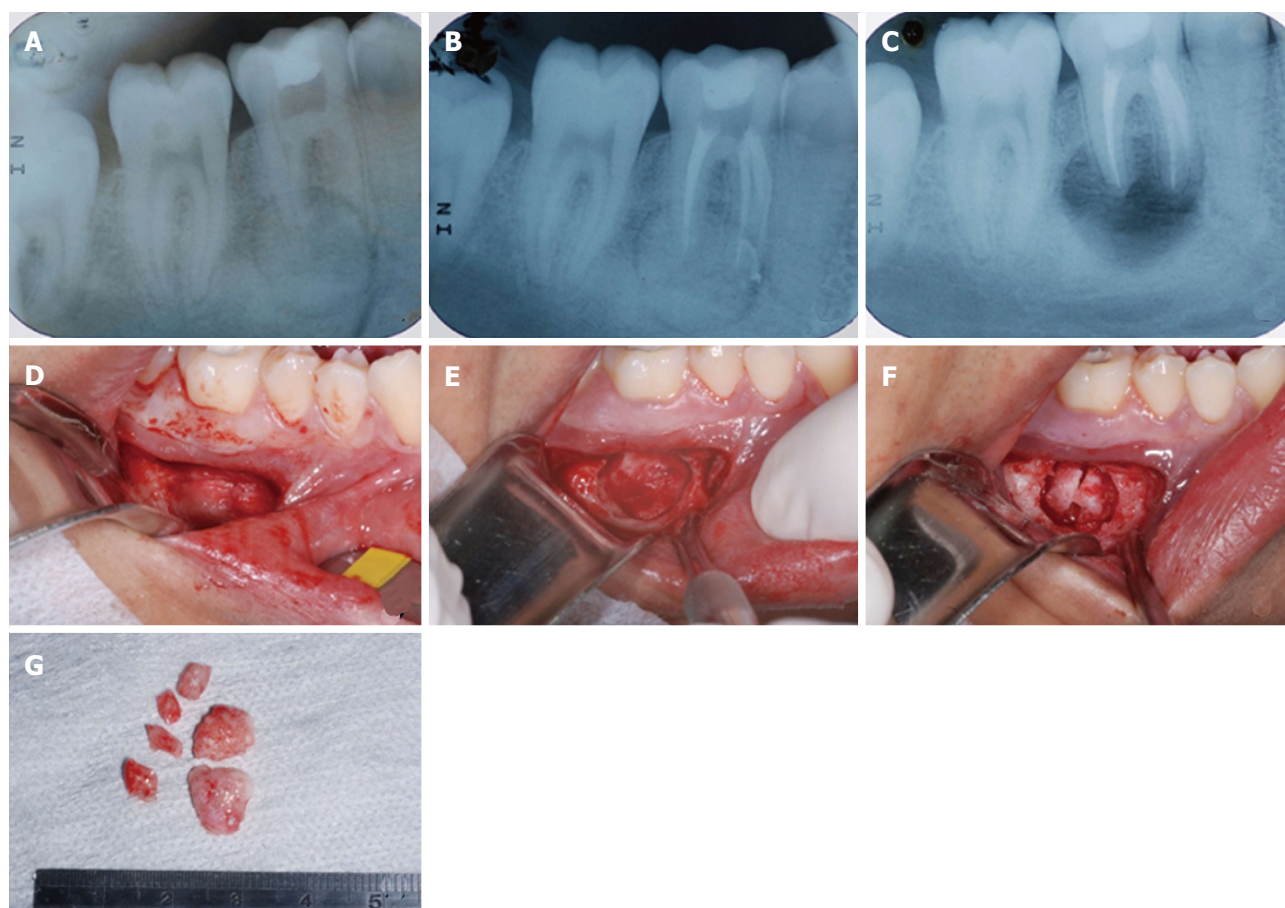
Endodontic treatment (pulpectomy) was performed in two sessions with the use of a calcium hydroxide-based intracanal dressing. Biomechanical preparation was performed by using crown-down technique, and manual instruments (K files 10 and 15) associated with rotary instrumentation, by using an electric motor and ProDesign S files of the Easy® System, in accordance with the protocol of the manufacturer (Easy Equipamentos Odontológicos®, Belo Horizonte - MG, Brazil). Surgical intervention was performed to remove the lesion in the apical third portion of the root associated with the lesion.

The lesion removed had the aspect of a rounded mass of hardened consistency, measuring 1.3 mm in diameter. The tissue was sent for histopathological exam that provided description of the material as being calcified, presenting superimposed lamellae and presence of dentin united to cementoid material. In the central portion of the lesion, a cementoid structure with blood vessels was verified, presenting superimposed lamellae and basophilic material, while the peripheral portion of the lesion presented irregular fibrous tissue, with an aspect of cementoid tissue and presence of blood vessels (Figure 2A and B). According to the histopathological report, the diagnosis presented was that of cementoblastoma.

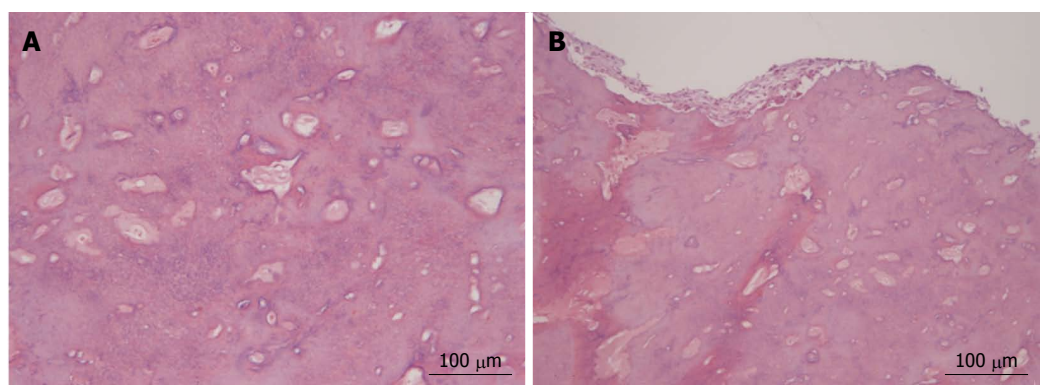
In the cone beam computed tomography exam performed during follow-up of the case after one year, recurrence of the lesion was observed (Figure 3). In view of the new condition, the option taken was to perform a second paraendodontic surgery. In this procedure, a more aggressive root section was performed up to the middle level of the roots affected by the lesion (Figure 4A). At present the patient is undergoing post-operative follow-up of 12 mo, without painful symptoms and showing complete remission of the lesion (Figure 4B). The Table 1 shows the different types of treatment and recurrence rates of the cementoblastoma demonstrated in case series previously reported in the literature.

## DISCUSSION

The cementoblastoma is a rare benign odontogenic lesion, and reports of cases documented represent a large part of the information with regard to therapeutic conduct<sup>[2,3,8]</sup>. Diagnosis of this lesion must be made by association of clinical, radiographic and histopathological methods<sup>[9,10]</sup>. It is important to perform differential diagnosis with other lesions that present characteristics to those of the cementoblastoma, such as cement-bone dysplasia, ossifying fibroma, hypercementosis and osteoblastoma<sup>[9,11]</sup>.



**Figure 1 Initial diagnosis and treatment of the lesion.** A: Initial radiographic exam showing radiopaque lesion with radiolucent halo involving the distal root of tooth 46; B: Endodontic treatment; C: Radiographic aspect after the first surgical intervention, with removal of the lesion and apical third of the root involved with the lesion; D: Access to the vestibular region of tooth 46; E: Exposure of the lesion; F: Fragmentation of the lesion to facilitate its removal; G: Aspect of the lesion removed.

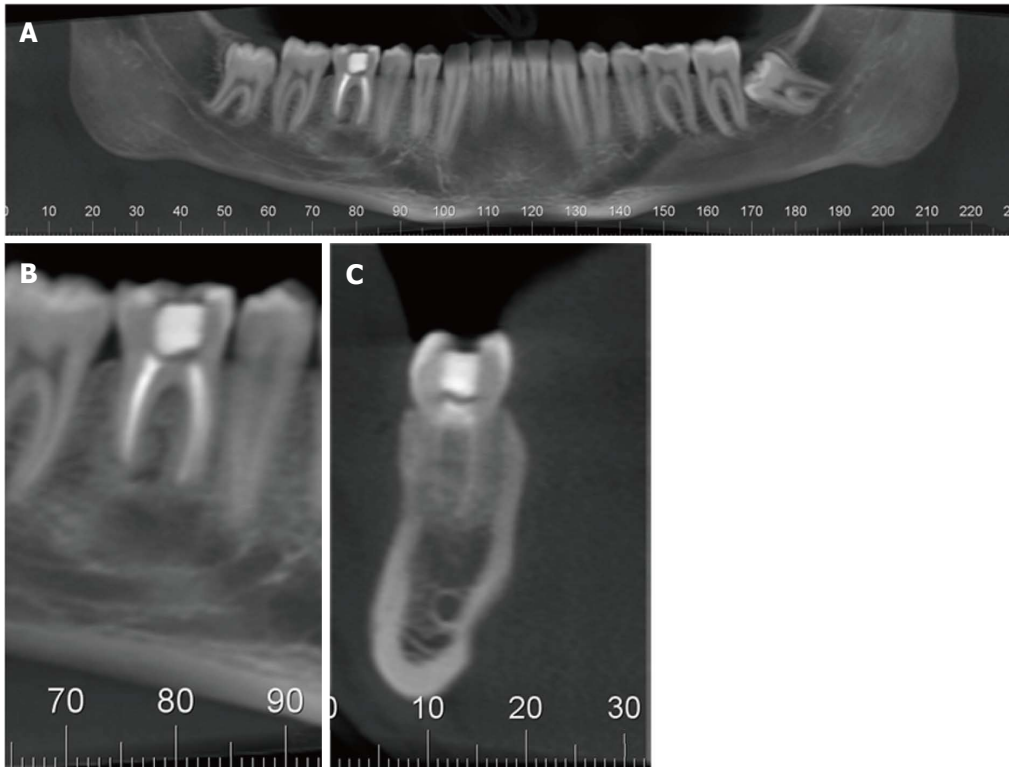


**Figure 2 Histological analysis of the lesion.** A: Central region of the lesion, where a cementoid structure with blood vessels was observed, presenting superimposed lamellae and basophilic material; B: Peripheral region of the lesion that presented irregular fibrous tissue, with tissue having a cementoid aspect and presence of blood vessels (HE-50 × magnification).

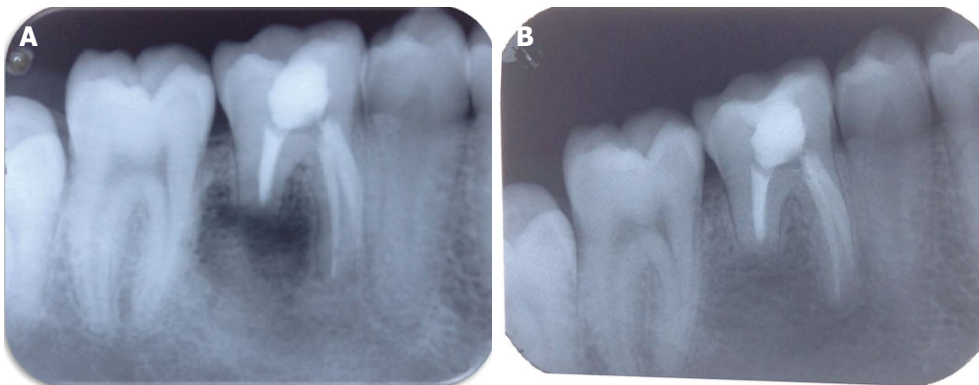
In the case reported, all the methods cited were used to identify the lesion. Clinical exam demonstrated that the lesion promoted painful symptoms, increase in volume associated with the vestibule of tooth 46, and presence of pulp vitality. Radiographic exam detected the presence of a radiopaque lesion with radiolucent halo associated with the root of tooth 46. The histopathological exam

demonstrated that the lesion presented a dense central region, with birefringent material similar to that of bone, with the presence of lines of reversion, while the peripheral portion presented foci of vascularization and connective tissue. All of these signs have been reported in the diagnostic reports of cementoblastoma<sup>[1-3,6,8,9,12]</sup>.

The treatment applied in the case was removal of the



**Figure 3** Tomographic aspect of tooth 46, one year after the first surgical procedure. A: General panoramic image; B: Image of the sagittal plane, in which tooth 46 is pointed out, with presence of the recurrence of cementoblastoma lesion associated with the distal root; C: Image of the coronal plane in which it is possible to observe a radiopaque alteration associated with tooth 46.



**Figure 4** Second surgical intervention and follow-up one year after this procedure. A: Radiographic aspect after removal of the lesion; B: Radiographic aspect after 1 year, in which it is possible to visualize a normal radiographic aspect around the root of the previously affected tooth.

lesion associated with a portion of the root surface after endodontic treatment. In spite of the presence of pulp vitality, in cases of cementoblastoma, the surgical act of removing the lesion and part of the tooth root must be performed after endodontic treatment<sup>[6]</sup>. This treatment has been applied in other studies with good clinical results and absence<sup>[13,14]</sup> of recurrence or rate of recurrence similar to that of treatment by tooth extraction<sup>[1]</sup>. However, removal of the affected tooth is still the option most indicated in case reports and previous studies<sup>[2,7,15]</sup>.

One of the reasons proposed for applying removal of the tooth as treatment for cementoblastoma is the high rate of recurrence of these lesions, associated with its

incomplete removal<sup>[1]</sup>. A series of cases has described that cases of cementoblastoma treated with a protocol similar to that performed in the present report may present recurrence of the lesion<sup>[6]</sup>, as verified in this clinical case after one year of follow-up. Considering that the cementoblastoma arises from the uncontrolled proliferation of the cementoid matrix by cementoblasts<sup>[16]</sup> and that these cells are not present in the middle and cervical portions of the root<sup>[17]</sup>, in the second surgical approach, removal of the root was performed up to the middle third, thereby eliminating all the cellular cement that could have led to the origin of the second lesion. However, this procedure may not eliminate the possibility



**Table 1** Different types of treatment and recurrence rates of the cementoblastoma

Ref.	No. of cases	Type of treatment	Recurrence rates
Abrams <i>et al</i> <sup>[9]</sup> , 1974	7	Extraction of the affected tooth	No recurrences after 6-10 yr
Ulmansky <i>et al</i> <sup>[6]</sup> , 1994	5	Extraction of the affected tooth in two cases Association between the surgical enucleation of the lesion associated and the treatment in three cases	No recurrences after two years
Brannon <i>et al</i> <sup>[1]</sup> , 2004	44	<i>En bloc</i> resection in 5 cases Extraction of the involved tooth with concurrent tumor removal in 26 cases Root amputation with tumor removal in 2 cases Curettage of the lesion without tooth extraction in 6 cases Extraction of the involved tooth with no attempt to remove the tumor in four cases	There were recurrences in 13 cases (37.1%) between 4-24 mo after the treatment
Prakash <i>et al</i> <sup>[2]</sup> , 2013	3	Extraction of the affected tooth	No recurrences

of the lesion recurrence since other ethological factors as the uncontrolled induction of the cementoblasts differentiation by the epithelial rests of Malassez cells can be the trigger of the cementoblastoma lesions<sup>[18]</sup>. After one year of follow-up of this surgical procedure, repair with bone neoformation was verified in the region of the lesion.

Therefore, the authors concluded that the surgical treatment associated with endodontic treatment was effective for the treatment of cementoblastoma. However, follow-up must be performed due to the possibility of recurrence of this lesion. Moreover, apicoectomy must be performed at the level of the middle third of the root to prevent the remaining cementoblasts from inducing recurrence of the lesion.

## COMMENTS

### Case characteristics

The patient, an 18-year-old man with complaints of pain in the mandibular body on the right side for the past 3 mo.

### Clinical diagnosis

Cementoblastoma.

### Differential diagnosis

Cement-bone dysplasia, ossifying fibroma, hypercementosis and osteoblastoma.

### Imaging diagnosis

A radiopaque mass was observed, measuring approximately 1.5 mm in diameter, with discrete radiolucent halo associated with the root apex of tooth 45.

### Pathological diagnosis

Cementoblastoma.

### Treatment

Endodontic treatment and surgical removal of the lesion.

### Related reports

The treatment of this condition normally is the tooth extraction. In this case report we propose a more conservative therapy. The association of the endodontic treatment and surgical removal of the lesion permits the maintenance of the tooth.

## Experiences and lessons

Apicoectomy must be performed at the level of the middle third of the root to prevent the remaining cementoblasts from inducing recurrence of the lesion.

## Peer-review

The authors report on a surgical treatment of a cementoblastoma associated with apicoectomy and endodontic therapy. The case report is well written and Brannon's series is reported as well as satisfactory literature review.

## REFERENCES

- 1 Brannon RB, Fowler CB, Carpenter WM, Corio RL. Cementoblastoma: an innocuous neoplasm? A clinicopathologic study of 44 cases and review of the literature with special emphasis on recurrence. *Oral Surg Oral Med Oral Pathol Oral Radiol Endod* 2002; **93**: 311-320 [PMID: 11925541 DOI: 10.1067/moe.2002.121993]
- 2 Prakash R, Gill N, Goel S, Verma S. Cementoblastoma. A report of three cases. *N Y State Dent J* 2013; **79**: 41-43 [PMID: 23691728]
- 3 Jeyaraj CP. Clinicopathological study of a case of cementoblastoma and an update on review of literature. *J Oral Maxillofac Surg Med Pathol* 2014; **26**: 415-420 [DOI: 10.1016/j.ajoms.2013.05.010]
- 4 Ohki K, Kumamoto H, Nitta Y, Nagasaka H, Kawamura H, Ooya K. Benign cementoblastoma involving multiple maxillary teeth: report of a case with a review of the literature. *Oral Surg Oral Med Oral Pathol Oral Radiol Endod* 2004; **97**: 53-58 [PMID: 14716256 DOI: 10.1016/j.tripleo.2003.08.012]
- 5 Avelar RL, Antunes AA, Santos Tde S, Andrade ES, Dourado E. Odontogenic tumors: clinical and pathology study of 238 cases. *Braz J Otorhinolaryngol* 2008; **74**: 668-673 [PMID: 19082347 DOI: 10.1016/S1808-8694(15)31375-6]
- 6 Ulmansky M, Hjørtting-Hansen E, Praetorius F, Haque MF. Benign cementoblastoma. A review and five new cases. *Oral Surg Oral Med Oral Pathol* 1994; **77**: 48-55 [PMID: 8108097 DOI: 10.1016/S0030-4220(06)80106-4]
- 7 Iannaci G, Luise R, Iezzi G, Piattelli A, Salerno A. Multiple cementoblastoma: a rare case report. *Case Rep Dent* 2013; **2013**: 828373 [PMID: 24027644 DOI: 10.1155/2013/828373]
- 8 Sharma N. Benign cementoblastoma: A rare case report with review of literature. *Contemp Clin Dent* 2014; **5**: 92-94 [PMID: 24808704]
- 9 Abrams AM, Kirby JW, Melrose RJ. Cementoblastoma. A clinical-pathologic study of seven new cases. *Oral Surg Oral Med Oral Pathol* 1974; **38**: 394-403 [PMID: 4528461]
- 10 de Noronha Santos Netto J, Machado Cerri J, Miranda AM, Pires FR. Benign fibro-osseous lesions: clinicopathologic features from 143 cases diagnosed in an oral diagnosis setting. *Oral Surg Oral Med Oral Pathol Oral Radiol* 2013; **115**: e56-e65 [PMID: 22981804 DOI: 10.1016/j.oooo.2012.05.022]
- 11 Rao GS, Kamalapur MG, Acharya S. Focal cemento-osseous dysplasia masquerading as benign cementoblastoma: A diagnostic



- dilemma. *J Oral Maxillofac Pathol* 2014; **18**: 150 [PMID: 24959061 DOI: 10.4103/0973-029X.131949]
- 12 **Mortazavi H**, Baharvand M, Rahmani S, Jafari S, Parvaei P. Radiolucent rim as a possible diagnostic aid for differentiating jaw lesions. *Imaging Sci Dent* 2015; **45**: 253-261 [PMID: 26730374 DOI: 10.5624/isd.2015.45.4.253]
  - 13 **Biggs JT**, Benenati FW. Surgically treating a benign cementoblastoma while retaining the involved tooth. *J Am Dent Assoc* 1995; **126**: 1288-1290 [PMID: 7560589]
  - 14 **Gulsels A**, Bayar GR, Aydin C, Sencimen M. A case of a benign cementoblastoma treated by enucleation and apicoectomy. *Gen Dent* 2012; **60**: e380-e382 [PMID: 23220315]
  - 15 **Harada H**, Omura K, Mogi S, Okada N. Cementoblastoma arising in the maxilla of an 8-year-old boy: a case report. *Int J Dent* 2011; **2011**: 384578 [PMID: 21747857 DOI: 10.1155/2011/384578]
  - 16 **Dadhich AS**, Nilesh K. Cementoblastoma of posterior maxilla involving the maxillary sinus. *Ann Maxillofac Surg* 2015; **5**: 127-129 [PMID: 26389052 DOI: 10.4103/2231-0746.161135]
  - 17 **Nanci A**, Bosshardt DD. Structure of periodontal tissues in health and disease. *Periodontol 2000* 2006; **40**: 11-28 [PMID: 16398683 DOI: 10.1111/j.1600-0757.2005.00141.x]
  - 18 **Farea M**, Husein A, Halim AS, Berahim Z, Nurul AA, Mokhtar KI, Mokhtar K. Cementoblastic lineage formation in the cross-talk between stem cells of human exfoliated deciduous teeth and epithelial rests of Malassez cells. *Clin Oral Investig* 2016; **20**: 1181-1191 [PMID: 26392396 DOI: 10.1007/S.00784-015-1601-6]

**P- Reviewer:** Razek AAKA, Yura S, Zhang ZM **S- Editor:** Ji FF

**L- Editor:** A **E- Editor:** Lu YJ



## Unique case of oligoastrocytoma with recurrence and grade progression: Exhibiting differential expression of high mobility group-A1 and human telomerase reverse transcriptase

Puneet Gandhi, Richa Khare, Kavita Niraj, Nitin Garg, Sandeep K Sorte, Hanni Gulwani

Puneet Gandhi, Richa Khare, Kavita Niraj, Department of Research, Bhopal Memorial Hospital and Research Centre, Bhopal 462038, India

Nitin Garg, Sandeep K Sorte, Department of Neurosurgery, Bhopal Memorial Hospital and Research Centre and Bansal Hospital, Bhopal 462038, India

Hanni Gulwani, Department of Pathology, Bhopal Memorial Hospital and Research Centre, Bhopal 462038, India

**Author contributions:** Gandhi P and Niraj K designed the report; Khare R performed the IF-IHC; Khare R, Garg N and Sorte SK collected and analyzed clinical data; Gulwani H analyzed conventional pathological parameters; Gandhi P, Khare R and Niraj K performed immune-marker analysis, statistics and wrote the manuscript.

**Supported by** M.P. Biotech Council, M.P. for financial assistance; and BMHRC for infrastructural facilities, No. 249.

**Institutional review board statement:** The present case report is a part of project IEC/21/Res/11, which was reviewed and approved by BMHRC institutional review board.

**Informed consent statement:** Written informed consent as per institutional ethics committee (IEC/21/Res/11) was obtained from the legal authorised representative prior to study inclusion.

**Conflict-of-interest statement:** All authors state that they have no financial or any other conflict of interest to declare.

**Open-Access:** This article is an open-access article which was selected by an in-house editor and fully peer-reviewed by external reviewers. It is distributed in accordance with the Creative Commons Attribution Non Commercial (CC BY-NC 4.0) license, which permits others to distribute, remix, adapt, build upon this work non-commercially, and license their derivative works on different terms, provided the original work is properly cited and the use is non-commercial. See: <http://creativecommons.org/licenses/by-nc/4.0/>

Manuscript source: Invited manuscript

**Correspondence to:** Dr. Puneet Gandhi, Professor, Head, Department of Research, Bhopal Memorial Hospital and Research Centre, Raisen Bypass Road, Bhopal 462038, India. [puneetgandhi67@yahoo.com](mailto:puneetgandhi67@yahoo.com)  
Telephone: +91-755-2742152

Received: April 26, 2016

Peer-review started: April 28, 2016

First decision: May 17, 2016

Revised: May 29, 2016

Accepted: June 27, 2016

Article in press: June 29, 2016

Published online: September 16, 2016

### Abstract

Mixed gliomas, primarily oligoastrocytomas, account for about 5%-10% of all gliomas. Distinguishing oligo-astrocytoma based on histological features alone has limitations in predicting the exact biological behavior, necessitating ancillary markers for greater specificity. In this case report, human telomerase reverse transcriptase (hTERT) and high mobility group-A1 (HMGA1); markers of proliferation and stemness, have been quantitatively analyzed in formalin-fixed paraffin-embedded tissue samples of a 34 years old patient with oligoastrocytoma. Customized florescence-based immunohistochemistry protocol with enhanced sensitivity and specificity is used in the study. The patient presented with a history of generalized seizures and his magnetic resonance imaging scans revealed infiltrative ill-defined mass lesion with calcified foci within the left frontal white matter, suggestive of glioma. He was surgically treated at our center for four consecutive clinical events. Histopathologically, the tumor was identified as oligoastrocytoma-grade II followed by

two recurrence events and final progression to grade III. Overall survival of the patient without adjuvant therapy was more than 9 years. Glial fibrillary acidic protein, p53, Ki-67, nuclear atypia index, pre-operative neutrophil-lymphocyte ratio, are the other parameters assessed. Findings suggest that hTERT and HMGA1 are linked to tumor recurrence and progression. Established markers can assist in defining precise histopathological grade in conjunction with conventional markers in clinical setup.

**Key words:** Human telomerase reverse transcriptase; High mobility group-A1; Oligoastrocytoma; Recurrence; Tumor grade

© **The Author(s) 2016.** Published by Baishideng Publishing Group Inc. All rights reserved.

**Core tip:** The clinical relevance of defining precise histological grade II and III in glioma subtypes is crucial for intervention. This case report presents two new prospective markers high mobility group-A1 and human telomerase reverse transcriptase which can be used to assess stemness and proliferation, with greater sensitivity and specificity, through fluorescence based immunohistochemistry; and demarcate malignancy grade in oligoastrocytoma.

Gandhi P, Khare R, Niraj K, Garg N, Sorte SK, Gulwani H. Unique case of oligoastrocytoma with recurrence and grade progression: Exhibiting differential expression of high mobility group-A1 and human telomerase reverse transcriptase. *World J Clin Cases* 2016; 4(9): 296-301 Available from: URL: <http://www.wjgnet.com/2307-8960/full/v4/i9/296.htm> DOI: <http://dx.doi.org/10.12998/wjcc.v4.i9.296>

## INTRODUCTION

Mixed gliomas, primarily oligoastrocytomas (OA) account for about 5%-10% of all gliomas<sup>[1]</sup>, are an aggressive type and their usual fate is to recur. Criteria for the reappearance of tumors include radiological features like tumor location, extent of surgical resection<sup>[2]</sup> and proliferation indices<sup>[3]</sup> with median survival being 3 to > 10 years in oligoastrocytoma<sup>[4]</sup>.

Ki-67 and CD133 are taken as standard tissue based molecular markers in clinical set-up, for proliferation index and cancer stemness, respectively. However, Skjulsvik *et al*<sup>[5]</sup>, stated that although Ki-67/MIB-1 proliferation indices correlate well with histological malignancy grade in all glioma subtypes, a considerable overlap is observed between these subtypes. Consequently, Ki-67/MIB-1 immunostaining alone is not sufficient to adequately determine the grade accurately. Similarly, CD133 is considered as a putative marker for stem cells, but because of varying expression in mixed gliomas, it needs to be interpreted with caution<sup>[6]</sup>. This scenario necessitates identification of new molecular markers of clinical relevance, which can help delineate grade progression as well as recurrence related to stemness

in glial tumor sub-types.

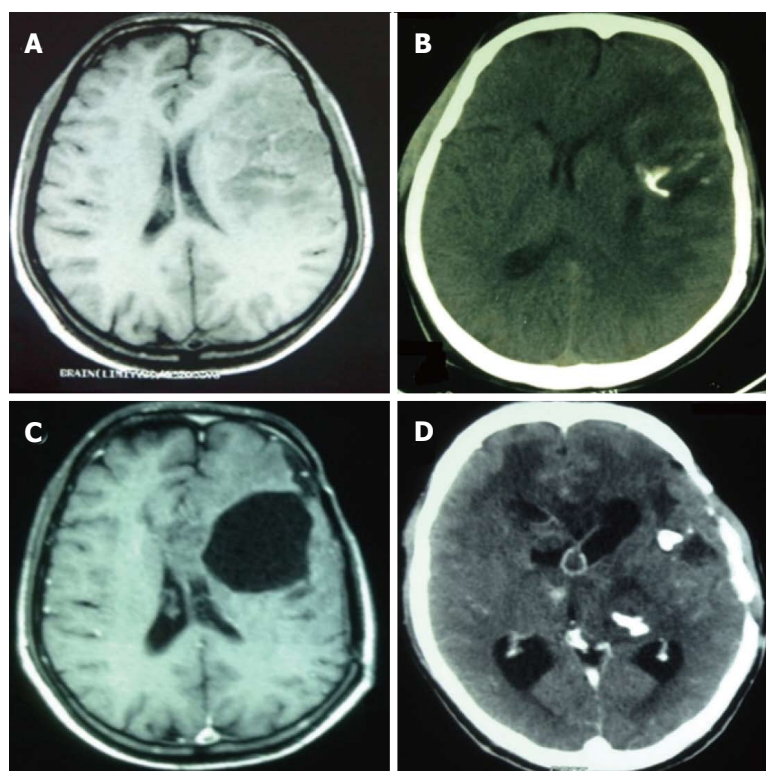
*In situ* hybridization based study, suggested a correlation of human telomerase reverse transcriptase (hTERT) expression with malignant transformation of gliocytes and degree of malignancy<sup>[7]</sup>. Similarly, expression of high mobility group-A1 (HMGA1) protein, an architectural transcription factor, has been shown to closely relate to malignant proliferation, invasion and differentiation of tumor from the perspective of tumor stem cells<sup>[8]</sup>.

In this case report, immunofluorescence (IF) based expression of HMGA1 and hTERT in formalin-fixed-paraffin-embedded (FFPE) tissue samples of a patient with oligoastrocytoma, has been evaluated quantitatively in reference to tumor recurrence as well as grade progression.

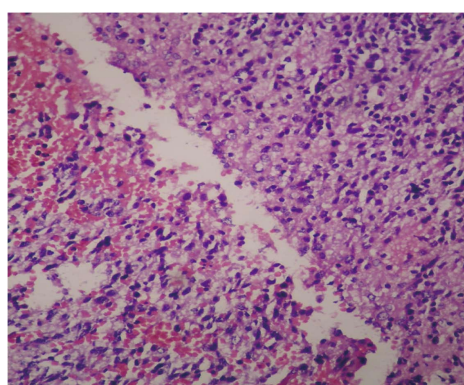
## CASE REPORT

A 34 years old male was referred to the Neurosurgery Department with a history of generalized seizures and 4 recurrent episodes, in three months. The patient had no neurological deficit. Magnetic resonance imaging (MRI) scans revealed infiltrative ill-defined mass lesion within the left frontal white matter, suggestive of glioma (Figure 1A). Left fronto-temporal awake craniotomy and near total excision of the tumor was done. In regular follow-up, patient was observed to be symptom free. After 43 mo, he had recurrent seizures and computed tomography (CT) scan showed an increase in size of the residual tumor with mass effect and calcified foci (Figure 1B). Re-exploration and decompression of the tumor was done, but a part of the tumor near the motor strip and deep eloquent areas was left behind. CT scans during follow ups revealed residual tumor without any significant mass effect. Patient led a neurologically asymptomatic life on regular antiepileptics for the next 48 mo. When presented again with recurrence of seizures, unconsciousness and multiple episodes of vomiting, MRI showed large fronto-temporal lesion causing significant mass effect and midline shift (Figure 1C). The patient was effectively mobilized, improved neurologically and became conscious and obeying. He was advised adjuvant therapy considering the residual tumor, with no histological change in the grade of tumor. However, patient deferred adjuvant therapy and again presented after 11 mo in altered sensorium. This time CT exam revealed an increase in size of the left temporal-parietal lesion with large cystic component and intraslesional hemorrhage with transtentorial herniation, also involving the brain stem (Figure 1D). Life saving re-exploration craniotomy with decompression and left temporal-parietal lobectomy was done. After a month long stay in the hospital, patient was discharged with strong advice for adjuvant therapy along with other medications and supportive care, making his overall survival at 9 years and 3 mo at the time of the study.

Written informed consent as per institutional ethics committee (IEC/21/Res/11) was obtained. Reported histopathological grades for all resections were noted from medical records and re-analyzed. The first resection was



**Figure 1** Radiological scans and findings before each surgical resection. A: MRI scans at initial diagnosis suggestive of glioma; B: CT scans at first recurrence showing calcification indicative of oligo-component presence; C: MRI scans just before third surgical intervention; D: CT scans before last resection confirming increased calcification. MRI: Magnetic resonance imaging; CT: Computed tomography.



**Figure 2** Perinuclear halo and honeycomb appearance in oligodendroglial component.

oligo-astrocytoma (grade- II ). Histological examination showed diffused infiltrating glioma composed of sheets of atypical astrocytic and oligodendroglial cells arranged against a fibrillary background. Cells had scant light eosinophilic cytoplasm with condensed, pleomorphic, vesicular nucleus. Characteristic perinuclear halo (honeycomb appearance) (Figure 2) and regions of small laminated calcification; were seen in oligodendroglial component. Large areas of hemorrhage, microcystic changes, arborizing thin capillaries (chicken wire pattern) were also noted. Immunohistochemical analysis of this patient's tumor revealed approximately 45% oligodendroglial and 55% astrocytic cells, with tumor cell expression of p53 and GFAP, indicating that the patient had an OA. On first and second recurrence the resected sample persisted as oligoastrocytoma-grade II . Histo-pathologically last resection was reported as

anaplastic oligo-astrocytoma (grade III ) indicative of grade progression and intense invasiveness in terms of increased Ki-67 index.

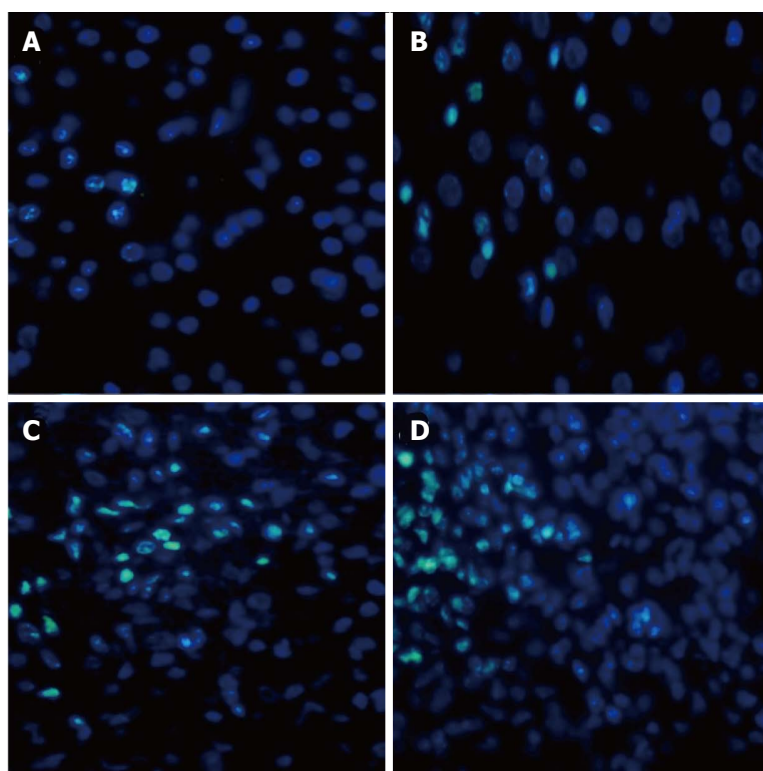
IF based expression of HMGA1 and hTERT in FFPE tissue was assessed in the areas with the highest degree of malignancy, while glial fibrillary acidic protein (GFAP), p53, neutrophil-lymphocyte ratio (NLR), nuclear atypia index (NAI) and Ki-67 proliferation index were the other parameters evaluated.

#### **hTERT and HMGA1 by IF**

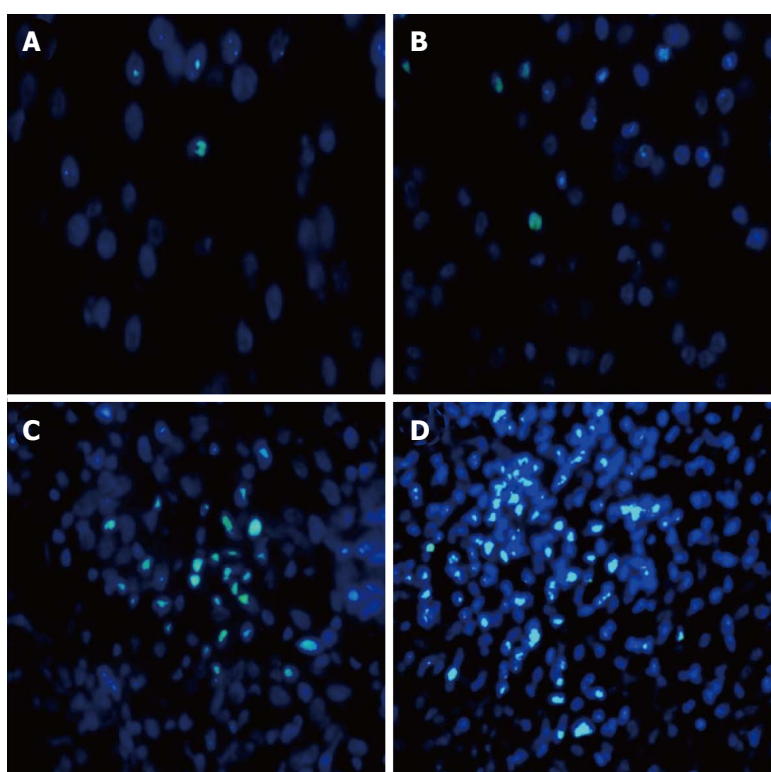
The expression of HMGA1 and hTERT molecules in FFPE glioma tissue by florescence based immunohistochemistry (IF-IHC) was carried out as per protocol described here. In brief, sequential deparaffinization and hydration of slides was followed by treatment with 0.1% sodium borohydride and 0.05% crystal violet consecutively. Antigen retrieval was performed in sodium citrate buffer (pH 6.0) followed by permeabilization with 0.2% Triton X-100. Sections were blocked for 60 min, and incubated with primary antibody hTERT (Abcam 1:750) or HMGA1 (Abcam 1:1000) overnight at 4 °C . Slides were then treated with host specific secondary antibodies (FITC labelled, 1:300 dilution), counterstained with 4', 6-diamidino-2-phenylindol (DAPI). Sections were then slaked with 0.1% Sudan black B, washed and mounted using antifade. Images were captured at 40X and digitalized using Zeiss AxioPlan 2 epifluorescent microscope and ASI imaging system (Case Data Manager Expo 4.5 software). At least 1000 cells/section were enumerated for each marker, using Image J-derivate "Fiji" software.

Evaluation of results showed that the expression of





**Figure 3** Florescence based immunohistochemistry for analysis and interpretation of human telomerase reverse transcriptase expression. A: Expression of marker in the first resected sample (grade II); B: Signal intensity of the marker at first recurrence (grade II); C: Increased hTERT expression at second recurrence (grade II); D: Intense immune-reactivity at confined foci in last surgical sample resected classified as histopathological grade III. hTERT: Human telomerase reverse transcriptase.



**Figure 4** The figure depicts differential high mobility group-A1 immunostaining. A: Minimal immune-expression in initial sample (grade II); B: At first recurrence (grade II); C: Increased signal intensity of the marker in sample from second recurrence (grade II); D: HMGA1 expression highly up-regulated with progression to histopathological grade III. HMGA1: High mobility group-A1.

proliferative marker hTERT (Figure 3) and stemness marker HMGA1 (Figure 4) increased with each resection I, II, III and IV; concurrent with tumor recurrence and grade progression (Table 1).

#### Ki-67

Ki-67 proliferation index, GFAP and p53 were evaluated

using peroxidase-IHC based routine lab protocol. Ki-67 labelling indices were found to be concomitant with an expression of both our tissue markers (Table 1).

#### NAI

Nuclear atypia, evaluated in DAPI stained cells, was recorded in 500 cells per section. NAI increased with

**Table 1** Evaluated tissue markers

S. No.	Markers	I resection	II resection	III resection	IV resection
1	hTERT	1.23%	2.05%	2.71%	4.50%
2	HMGA1	0.50%	0.87%	1.09%	2.62%
3	Ki-67 INDEX	1.00%	4.00%	7.00%	8.50%
4	NAI	6.30%	12.94%	16.06%	31.01%

hTERT: Human telomerase reverse transcriptase; HMGA1: High mobility group-A1; NAI: Nuclear atypia index.

recurrence; highest value being at 4<sup>th</sup> resection when tumor grade progressed (Table 1).

### NLR

Value of NLR was calculated from pre-surgery full blood count using Leishman stain. The patient had been on steroids for 24 h prior to surgery and did not present clinical signs of sepsis at the time of blood sampling for NLR. The pre-operative NLR value in the therapy naive sample was 2.17 which increased to 7.81 in resection IV with change in histological grade from low to high.

## DISCUSSION

Although tissue based molecular markers like mitotic count, Ki67/MIB1, PCNA, CD133 are being used for enumeration of proliferation index and stemness in glioma sub-types, the clinical outcome based on these markers singularly, still remains controversial. This variable functionality led us to investigate two tissue based molecular markers: hTERT and HMGA1, to enumerate proliferation and stemness in OA.

Cellular and molecular basis of cell proliferation is vital to diagnostics, in dealing with this malignancy. Our results revealed that expression of hTERT in each resection increased because of proliferation in residual tumor, leading to recurrence (Table 1). A study by Shervington *et al*<sup>[9]</sup> in glioma patients, showed a significant difference in telomerase protein levels between cancerous and normal tissues. Also, in line with our finding, IHC based hTERT expression pattern has been reported on low and high grade glioma samples, indicating higher expression to be linked with grade progression<sup>[10]</sup>. The analysis of our marker indicates that measurement of precise proliferative activity is crucial to delineate the transition from low to high grade OA.

Cancer stem cells are known to be responsible for tumor recurrence. As can be deduced from clinical history of the patient, recurrence of tumor was initiated because of the presence of stem cell(s) in the tumor mass left behind since gross total resection could not be clinically achieved in any of the surgical interventions. Increase in expression of stemness marker HMGA1 relates to tumor recurrence with a marked difference in expression when grade progressed, as evident from IF based quantitative analysis (Table 1) and our further work validates these markers in a bigger cohort (data under publication).

Results are concomitant with earlier studies, one which revealed that expression of HMGA1 significantly correlates with malignancy, proliferation, invasion and angiogenesis in 60 glioma samples<sup>[11]</sup>; and also with another study that showed a differential IHC expression of HMGA1 in patients with primary and recurrent GBM<sup>[12]</sup>. Our study technique was IF based, with greater sensitivity, specificity for the epitopes in question and the evaluation was quantitative. Although our patient deferred adjuvant therapy; a positive prognosis in terms of 112 mo of overall survival is recorded. This is augmented by Ki67, hTERT and HMGA1 indices; values of which are less than our in-house established thresholds for low and high grade. In the present case of OA, the percentage expression of our markers HMGA1 and hTERT is concomitant with Ki67 index making these two newly established markers prospective candidates in assisting precise grading of cases such as OA.

## COMMENTS

### Case characteristics

A 34 years old male was referred to the Neurosurgery department with a history of general seizures and 4 recurrent episodes of seizures in three months.

### Clinical diagnosis

History of 4 episodes of recurrent seizures with normal neurological examination.

### Differential diagnosis

The cause of seizures could not be ascertained clinically and required further evaluation by imaging. Seizures were not characteristic of a particular location and patient had a normal neurological examination.

### Laboratory diagnosis

All labs were within normal limits.

### Imaging diagnosis

Magnetic resonance imaging (MRI) scans revealed infiltrative ill-defined mass lesion within the left frontal white matter, suggestive of glioma. Follow-up computed tomography scan/MRI, showed increase in size of the residual tumor with mass effect and calcified foci. Imaging indicated increasing invasiveness as the disease progressed.

### Pathological diagnosis

Haematoxylin and eosin staining showed diffused infiltrating glioma composed of sheets of atypical astrocytic and oligodendroglial cells arranged against a fibrillary background, indicative of oligo-astrocytoma (grade-II). Peroxidase-immunohistochemistry (IHC) was used to assess Ki-67, glial fibrillary acidic protein, p53 and immunofluorescence (IF) based IHC was used to evaluate human telomerase reverse transcriptase (hTERT) and high mobility group-A1 (HMGA1).

### Treatment

Near/sub total excision of the tumor was done at first resection and also when increase in size of the residual tumor with mass effect was observed; however, patient deferred suggested adjuvant therapy.

### Related reports

Oligoastrocytoma (mixed glioma) is an aggressive, highly infiltrating glioma type. Distinguishing oligoastrocytomas (OA) based on histological features alone has limitations in predicting the exact biological behavior, necessitating ancillary markers for greater specificity.

**Term explanation**

Nuclear atypia index (NAI) is a count of abnormal cell nuclei, in most cases indicative of malignancy. Nuclear lymphocyte ratio (NLR) is a marker of subclinical inflammation and a factor of poor prognosis in various cancers. hTERT and HMGA1 are markers of proliferation and stemness, respectively.

**Experiences and lessons**

The study technique was IF based, with greater sensitivity and specificity for the epitopes in question and the evaluation was quantitative. In the present case of OA, the percentage expression of our markers HMGA1 and hTERT is concomitant with Ki67 index making these two newly established markers prospective candidates in assisting precise grading of cases such as OA.

**Peer-review**

An interesting case presentation.

**REFERENCES**

- 1 **American Brain Tumor Association.** Oligodendroglioma and Oligoastrocytoma. [retrieved 2015 Dec 7]. Available from: URL: <http://www.abta.org>
- 2 **Nestler U,** Lutz K, Pichlmeier U, Stummer W, Franz K, Reulen HJ, Bink A. Anatomic features of glioblastoma and their potential impact on survival. *Acta Neurochir (Wien)* 2015; **157**: 179-186 [PMID: 25391974 DOI: 10.1007/s00701-014-2271-x]
- 3 **Louis DN,** Ohgaki H, Wiestler OD, Cavenee WK, Burger PC, Jouvet A, Scheithauer BW, Kleihues P. The 2007 WHO classification of tumours of the central nervous system. *Acta Neuropathol* 2007; **114**: 97-109 [PMID: 17618441 DOI: 10.1007/s00401-007-0278-6]
- 4 **Vigneswaran K,** Neill S, Hadjipanayis CG. Beyond the World Health Organization grading of infiltrating gliomas: advances in the molecular genetics of glioma classification. *Ann Transl Med* 2015; **3**: 95 [PMID: 26015937 DOI: 10.3978/j.issn.2305-5839.2015.03.57]
- 5 **Skjulsvik AJ,** Mørk JN, Torp MO, Torp SH. Ki-67/MIB-1 immunostaining in a cohort of human gliomas. *Int J Clin Exp Pathol* 2014; **7**: 8905-8910 [PMID: 25674263]
- 6 **Beier D,** Wischhusen J, Dietmaier W, Hau P, Proescholdt M, Brawanski A, Bogdahn U, Beier CP. CD133 expression and cancer stem cells predict prognosis in high-grade oligodendroglial tumors. *Brain Pathol* 2008; **18**: 370-377 [PMID: 18371181 DOI: 10.1111/j.1750-3639.2008.00130.x]
- 7 **Wang DL,** Wang YF, Shi GS, Huang H. [Correlation of hTERT expression to maspin and bFGF expression and their significance in glioma]. *Ai Zheng* 2007; **26**: 601-606 [PMID: 17562265]
- 8 **Fan H,** Guo H, Zhang IY, Liu B, Luan L, Xu S, Hou X, Liu W, Zhang R, Wang X, Pang Q. The different HMGA1 expression of total population of glioblastoma cell line U251 and glioma stem cells isolated from U251. *Brain Res* 2011; **1384**: 9-14 [PMID: 21300033 DOI: 10.1016/j.brainres.2011.01.105]
- 9 **Shervington A,** Patel R. Differential hTERT mRNA processing between young and older glioma patients. *FEBS Lett* 2008; **582**: 1707-1710 [PMID: 18435920 DOI: 10.1016/j.febslet.2008.04.027]
- 10 **Yang K,** Liu Y, Liu Z, Liu J, Liu X, Chen X, Li C, Zeng Y. p38γ overexpression in gliomas and its role in proliferation and apoptosis. *Sci Rep* 2013; **3**: 2089 [PMID: 23807566 DOI: 10.1038/srep02089]
- 11 **Pang B,** Fan H, Zhang IY, Liu B, Feng B, Meng L, Zhang R, Sadeghi S, Guo H, Pang Q. HMGA1 expression in human gliomas and its correlation with tumor proliferation, invasion and angiogenesis. *J Neurooncol* 2012; **106**: 543-549 [PMID: 21984063 DOI: 10.1007/s11060-011-0710-6]
- 12 **Liang Z.** The Expression and Significance of HMGA1, TROP2 in Malignant Gliomas. *J Shandong Univ Health Sci* 2013; **51**: 59-61

**P- Reviewer:** Lakatos PL, Tsikouras PPT, Yao D **S- Editor:** Ji FF  
**L- Editor:** A **E- Editor:** Lu YJ



## Gliosarcoma: A rare variant of glioblastoma multiforme in paediatric patient: Case report and review of literature

Ugan Singh Meena, Sumit Sharma, Sanjeev Chopra, Shashi Kant Jain

Ugan Singh Meena, Sumit Sharma, Sanjeev Chopra, Shashi Kant Jain, Department of Neurosurgery, Swai Man Singh Medical College, Rajasthan 302004, India

**Author contributions:** Meena US involved in majority of work including concept, design, literature search, clinical studies, manuscript preparation, manuscript editing; Sharma S helps in data collection and manuscript preparation; Chopra S helps in manuscript editing; Jain SK helps in manuscript editing and reviewing.

**Institutional review board statement:** Not available.

**Informed consent statement:** Not available.

**Conflict-of-interest statement:** The authors declare no conflicts of interest regarding this manuscript.

**Open-Access:** This article is an open-access article which was selected by an in-house editor and fully peer-reviewed by external reviewers. It is distributed in accordance with the Creative Commons Attribution Non Commercial (CC BY-NC 4.0) license, which permits others to distribute, remix, adapt, build upon this work non-commercially, and license their derivative works on different terms, provided the original work is properly cited and the use is non-commercial. See: <http://creativecommons.org/licenses/by-nc/4.0/>

**Manuscript source:** Invited manuscript

**Correspondence to:** Dr. Ugan Singh Meena, Mch, Senior Registrar (Neurosurgery), Department of Neurosurgery, Swai Man Singh Medical College, Jaipur, Rajasthan 302004, India. [uganmamc@gmail.com](mailto:uganmamc@gmail.com)  
Telephone: +91-0141-2518801

Received: January 23, 2016  
Peer-review started: January 24, 2016  
First decision: April 18, 2016  
Revised: May 8, 2016  
Accepted: July 14, 2016  
Article in press: July 16, 2016  
Published online: September 16, 2016

### Abstract

Gliosarcoma is rare central nervous system tumour and a variant of glioblastoma multiforme with bimorphic histological pattern of glial and sarcomatous differentiation. It occurs in elderly between 5<sup>th</sup> and 6<sup>th</sup> decades of life and extremely rare in children. It is highly aggressive tumour and managed like glioblastoma multiforme. A 12-year-old female child presented with complaints of headache and vomiting from 15 d and blurring of vision from 3 d. Magnetic resonance imaging of brain shows heterogeneous mass in right parieto-occipital cortex. A right parieto-occipito-temporal craniotomy with complete excision of mass revealed a primary glioblastoma on histopathological investigation. Treatment consists of maximum surgical excision followed by adjuvant radiotherapy. The etiopathogenesis, treatment modalities and prognosis is discussed. The available literature is also reviewed.

**Key words:** Paediatric gliosarcoma; Surgery; Glioblastoma multiforme; Radiotherapy

© The Author(s) 2016. Published by Baishideng Publishing Group Inc. All rights reserved.

**Core tip:** We report a rare case of primary gliosarcoma right parieto-occipital cortex in a 12-year-old girl with review of available literature. The etiopathogenesis, treatment modalities and prognosis is discussed in view of the literature.

Meena US, Sharma S, Chopra S, Jain SK. Gliosarcoma: A rare variant of glioblastoma multiforme in paediatric patient: Case report and review of literature. *World J Clin Cases* 2016; 4(9): 302-305 Available from: URL: <http://www.wjgnet.com/2307-8960/full/v4/i9/302.htm> DOI: <http://dx.doi.org/10.12998/wjcc.v4.i9.302>



## INTRODUCTION

Gliosarcoma was first time reported by Stroebe<sup>[1]</sup>. It is a rare cerebral tumour consist of bimorphic histological pattern of glial and sarcomatous differentiation. It is considered as grade 4 tumour according to WHO classification and variant of glioblastoma multiforme<sup>[2]</sup>. Incidence of gliosarcoma is 1.8%-2.8% of glioblastoma<sup>[3]</sup>. It usually affects elderly in 5<sup>th</sup> and 6<sup>th</sup> decades of life with slight male predominance and extremely rare in paediatric population<sup>[4]</sup>. So far only few cases of paediatric gliosarcoma have been reported. We report a case of primary gliosarcoma in 12-year-old girl.

## CASE REPORT

A 12-year-old girl was admitted in our institute with history of headache and vomiting from 15 d and blurring of vision from 3 d. Her general and systemic examination was unremarkable. Neurologically Glasgow coma scale was 15/15, pupil were equal and reactive bilaterally. Left side hemiparesis was present with 4/5 power in left upper and lower limb. CECT brain was done which shows large intra axial SOL in right parieto-occipital lobe with perifocal edema, producing mass effect, causing effaced adjacent sulci gyri and ipsilateral lateral ventricle. Lesion shows solid cystic component with intense enhancement after contrast. Midline shift of 8 mm to left side. MRI brain with GD shows similar findings (Figure 1). Antiedema measures were started and early surgery was planned. She underwent right parieto-occipito-temporal craniotomy with complete excision of mass. Mass was greyish brown, avascular and firm in consistency. Post operative period was uneventful. Post operative MRI shows macroscopically complete excision of mass with reduction in mass effect and midline shift (Figure 2). Histopathological examination of the mass shows biphasic pattern comprising of alternating areas of mesenchymal and glial pattern. Mesenchymal component comprise of streaming spindle shape cells with nuclear atypia and many mitotic figures. At one focus pseudopalisading type of necrosis is also seen. In immunohistochemistry spindle shape cells show high MIB labelling index and vimentin positivity and glial cells shows GFAP positivity. Foci of reticulin-rich tumor cells also suggest sarcomatous component (Figure 3).

Patient was discharged on 7<sup>th</sup> post-operative day in good general and neurological condition with advice to attend radiotherapy clinic.

## DISCUSSION

Gliosarcoma is a rare CNS tumour with incidence of 1.8%-2.8% of glioblastomas<sup>[3]</sup>. It usually occurs in elderly between 5<sup>th</sup> and 6<sup>th</sup> decades of life and extremely rare in paediatric population. Okami *et al*<sup>[5]</sup> reported eight cases of paediatric gliosarcoma, Sarkar *et al*<sup>[6]</sup> described three cases and Salvati *et al*<sup>[7]</sup> also reported three cases. Malde *et al*<sup>[8]</sup> reported one case of radiation

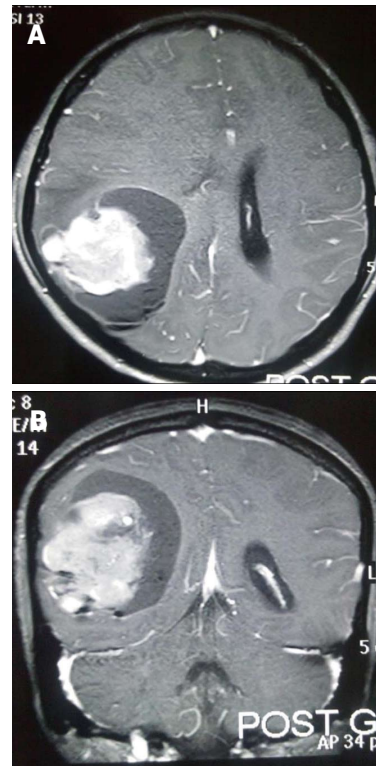


Figure 1 Post contrast magnetic resonance imaging axial (A) and coronal (B) images shows large heterogeneous lesion in right parieto-occipital region with effacement of ipsilateral lateral ventricle.

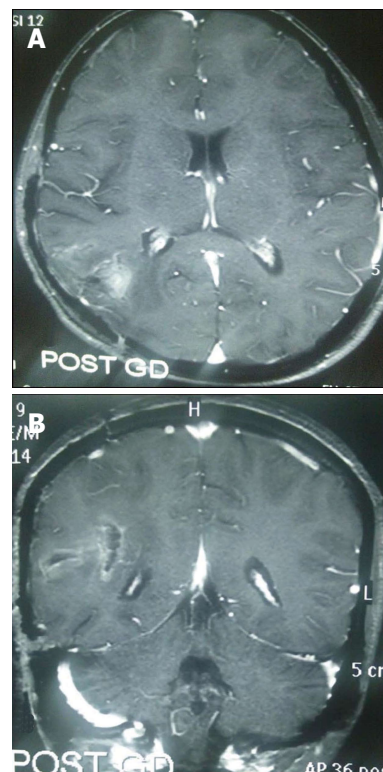
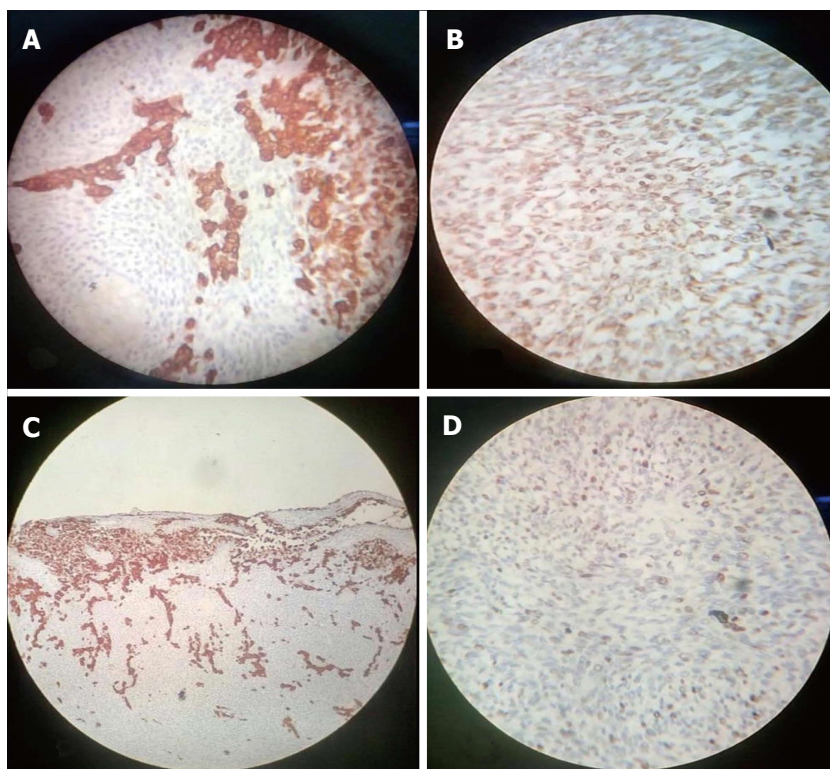


Figure 2 Post-operative contrast magnetic resonance imaging axial (A) and (B) images shows complete excision of tumor.

induced gliosarcoma in literature.

Temporal lobe is most commonly involved followed



**Figure 3** Foci of reticulin-rich tumor cells also suggest sarcomatous component. A: Spindle shape tumor cell shows high MIB labelling index (MIB, × 400); B: Spindle shape tumor cell positive for vimentin (vimentin, × 400); C: Glial cell positive for glial fibrillary acidic protein (GFAP, × 400); D: Glial cell positive for glial fibrillary acidic protein (GFAP, × 100).

by parietal and frontal lobe and can metastasize to extracranial structures like spinal cord, lung, pleura, liver, bone marrow and lymph nodes with increased frequency as compared to glioblastomas<sup>[7]</sup>. Pathogenesis of gliosarcoma is controversial topic and various studies have been proposed. The recent theory suggests monoclonal origin of gliosarcoma. The sarcomatous component originates from aberrant mesenchymal differentiation of the malignant glial cells during tumour progression<sup>[7]</sup>. Meis *et al*<sup>[9]</sup> laid down the criteria's for the diagnosis of gliosarcoma on the basis of histological features: (1) the tumor should be bimorphic, and composed of two morphologically distinct populations of malignant cells (2) one component should be glial in nature with necrotic areas and must fulfil criteria adopted for defining glioblastoma (3) the sarcomatous component should resemble a spindle-cell sarcoma; and must fill one medium power field under (10 × objective with 10 × eyepiece).

The computed tomography findings of gliosarcoma is extremely variable and generally these lesions appear hyperdense mass with heterogeneous thick ring enhancement surrounded by intense peritumoural edema. On magnetic resonance imaging gliosarcoma appear as heterogeneous mass lesion in T1 and T2 weighted sequences with irregular contrast enhancement and intense peritumoural edema. Management of gliosarcoma consist of maximum surgical excision followed by adjuvant radiotherapy. The role chemotherapy in gliosarcoma is still poorly defined although Morantz *et al*<sup>[10]</sup> reported a slight improvement in survival. The average survival in gliosarcoma after diagnosis is less than one year (6 to 14.8 mo) with few case reports of long survivors<sup>[7,11]</sup>.

Prognosis in gliosarcoma depends on histological and radiological features of mass lesion and is slightly better in lesions with predominant sarcomatous component along with meningioma like features in radiology<sup>[7]</sup>.

In conclusion, Gliosarcoma is an aggressive tumor with propensity to recur and re-grow with poor outcome. Although it occurs more commonly in the 5<sup>th</sup> and 6<sup>th</sup> decades of life with temporal lobe predilection, but can occur in any age group or any region. Further studies are needed to understand the biphasic nature of these tumours.

## COMMENTS

### Case characteristics

Patient presented with h/o of headache, vomiting and blurring of vision.

### Clinical diagnosis

She was conscious with left hemiparesis (4/5 power).

### Differential diagnosis

DD Includes malignant meningioma and central nervous system lymphoma and ruled out IHC marker studies.

### Laboratory diagnosis

All routine blood investigations (CBC, RFT, LFT and SE) were normal.

### Imaging diagnosis

Contrast-enhanced computed tomography and magnetic resonance imaging GD Brain show heterogenous mass with intense contrast enhancement surrounded by peritumoural edema.

### Pathological diagnosis

HPE shows biphasic pattern of mesenchymal(spindle cells) and glial cells.

Glial cells show glial fibrillary acidic protein positivity while spindle cells shows vimentin positivity and high MIB index.

### Treatment

Microscopic complete excision of mass done. Patient was advised to attend radiotherapy clinic for adjuvant radiotherapy.

### Related reports

Salvati M, Lenzi J, Brogna C, Frati A, Piccirilli M, Giangaspero F, Raco A. Childhood's gliosarcomas: pathological and therapeutical considerations on three cases and critical review of the literature. *Childs Nerv Syst* 2006; **22**: 1301-1306; Gajendra Singh, Kuntal K. Das, Pradeep Sharma, B. Guruprasad, Sushila Jaiswal, Anant Mehrotra, Arun K. Srivastava, Rabi N. Sahu, Awadhesh K. Jaiswal, and Sanjay Behari: Cerebral gliosarcoma: Analysis of 16 patients and review of literature. *Asian Journal Of Neurosurgery* 2015; **10**: 195-202.

### Experiences and lessons

Although it occurs more commonly in the 5<sup>th</sup> and 6<sup>th</sup> decades of life with temporal lobe predilection, but can occur in any age group or any region.

### Peer-review

It is an interesting topic with only few case reports in literature.

## REFERENCES

- 1 **Stroebe H.** Über Entstehung und Bau der Gehirngliome. *Beitr Pathol Anat Allg Pathol* 1895; **18**: 405-486
- 2 **Louis DN,** Ohgaki H, Wiestler OD, Cavenee WK, Burger PC, Jouvet A, Scheithauer BW, Kleihues P. The 2007 WHO classification of tumours of the central nervous system. *Acta Neuropathol* 2007; **114**: 97-109 [PMID: 17618441 DOI: 10.1007/s00401-007-0243-4]
- 3 **Parekh HC,** O'Donovan DG, Sharma RR, Keogh AJ. Primary cerebral gliosarcoma: report of 17 cases. *Br J Neurosurg* 1995; **9**: 171-178 [PMID: 7632363 DOI: 10.1080/02688699550041511]
- 4 **di Norcia V,** Piccirilli M, Giangaspero F, Salvati M. Gliosarcomas in the elderly: analysis of 7 cases and clinico-pathological remarks. *Tumori* 2008; **94**: 493-496 [PMID: 18822684]
- 5 **Okami N,** Kawamata T, Kubo O, Yamane F, Kawamura H, Hori T. Infantile gliosarcoma: a case and a review of the literature. *Childs Nerv Syst* 2002; **18**: 351-355 [PMID: 12172946 DOI: 10.1007/s00381-002-0602-3]
- 6 **Sarkar C,** Sharma MC, Sudha K, Gaikwad S, Varma A. A clinico-pathological study of 29 cases of gliosarcoma with special reference to two unique variants. *Indian J Med Res* 1997; **106**: 229-235 [PMID: 9378529]
- 7 **Salvati M,** Lenzi J, Brogna C, Frati A, Piccirilli M, Giangaspero F, Raco A. Childhood's gliosarcomas: pathological and therapeutical considerations on three cases and critical review of the literature. *Childs Nerv Syst* 2006; **22**: 1301-1306 [PMID: 16541294 DOI: 10.1007/s00381-006-0057-z]
- 8 **Malde R,** Jalali R, Muzumdar D, Shet T, Kurkure P. Gliosarcoma occurring 8 years after treatment for a medulloblastoma. *Childs Nerv Syst* 2004; **20**: 243-246 [PMID: 14704813 DOI: 10.1007/s00381-003-0850-x]
- 9 **Meis JM,** Ho KL, Nelson JS. Gliosarcoma: a histologic and immunohistochemical reaffirmation. *Mod Pathol* 1990; **3**: 19-24 [PMID: 2155418]
- 10 **Morantz RA,** Feigin I, Ransohoff J. Clinical and pathological study of 24 cases of gliosarcoma. *J Neurosurg* 1976; **45**: 398-408 [PMID: 956876 DOI: 10.3171/jns.1976.45.4.0398]
- 11 **Martin J,** Devadoss P, Kannan K, Kumar Sundarraj S. Malignant pediatric gliosarcoma defies general survival data. *Case Rep Med* 2014; **2014**: 175679 [PMID: 25580128 DOI: 10.1155/2014/175679]

**P- Reviewer:** Mocellin S, Yamagata M **S- Editor:** Qiu S  
**L- Editor:** A **E- Editor:** Lu YJ





# Huge peripheral primitive neuroectodermal tumor of the small bowel mesentery at nonage: A case report and review of the literature

Zhe Liu, Yuan-Hong Xu, Chun-Lin Ge, Jin Long, Rui-Xia Du, Ke-Jian Guo

Zhe Liu, Yuan-Hong Xu, Chun-Lin Ge, Jin Long, Ke-Jian Guo, Department of Pancreatic Surgery, the First Hospital of China Medical University, Shenyang 110001, Liaoning Province, China

Rui-Xia Du, Department of Otorhinolaryngology, Fengtian Hospital, Shenyang Medical University, Shenyang 110001, Liaoning Province, China

**Author contributions:** All authors contributed to the acquisition of data, writing and revision of the manuscript.

**Institutional review board statement:** This case report is retrospective and was not antecedently reviewed by the Local Ethics committee of China Medical University.

**Informed consent statement:** The patient involved in this study gave his written informed consent authorizing use and disclosure of his protected health information.

**Conflict-of-interest statement:** The authors declared that they have no conflicts of interest to this work.

**Open-Access:** This article is an open-access article which was selected by an in-house editor and fully peer-reviewed by external reviewers. It is distributed in accordance with the Creative Commons Attribution Non Commercial (CC BY-NC 4.0) license, which permits others to distribute, remix, adapt, build upon this work non-commercially, and license their derivative works on different terms, provided the original work is properly cited and the use is non-commercial. See: <http://creativecommons.org/licenses/by-nc/4.0/>

**Manuscript source:** Invited manuscript

**Correspondence to:** Zhe Liu, MD, Department of Pancreatic Surgery, the First Hospital of China Medical University, Heping District, Nanjing Road No. 155, Shenyang 110001, Liaoning Province, China. [liuzhe4321@126.com](mailto:liuzhe4321@126.com)  
Telephone: +86-24-83283330  
Fax: +86-24-83283350

Received: January 25, 2016

Peer-review started: January 26, 2016

First decision: May 17, 2016

Revised: May 25, 2016

Accepted: June 14, 2016

Article in press: June 16, 2016

Published online: September 16, 2016

## Abstract

Extraskelatal Ewing's sarcoma/peripheral primitive neuroectodermal tumor (E-EWS/pPNET) is a rare aggressive malignant small round cell tumor. In this report, we present the case of a 15-year-old boy who suffered from acute abdominal pain accompanied by hematemesis and melena, and was eventually diagnosed with E-EWS/pPNET. To date, there have been only five reported cases of E-EWS/pPNET of the small bowel including the patient in this report. To the best of our knowledge, this is the first documentation of a pPNET of the small bowel mesentery at nonage. All these have made this report rare and significant.

**Key words:** Extraskelatal Ewing's sarcoma; Peripheral primitive neuroectodermal tumor; Nonage; Small bowel mesentery; Spontaneous rupture

© **The Author(s) 2016.** Published by Baishideng Publishing Group Inc. All rights reserved.

**Core tip:** Extraskelatal Ewing's sarcoma/peripheral primitive neuroectodermal tumors (E-EWS/pPNETs) are rare aggressive malignant small round cell tumors that are derived from the outer central and autonomic nervous systems. To date, there have been only five reported cases of E-EWS/pPNET of the small bowel including the patient presented in this report. The patient presented in this report is the youngest and had the worst prognosis.



Liu Z, Xu YH, Ge CL, Long J, Du RX, Guo KJ. Huge peripheral primitive neuroectodermal tumor of the small bowel mesentery at nonage: A case report and review of the literature. *World J Clin Cases* 2016; 4(9): 306-309 Available from: URL: <http://www.wjgnet.com/2307-8960/full/v4/i9/306.htm> DOI: <http://dx.doi.org/10.12998/wjcc.v4.i9.306>

## INTRODUCTION

Extraskelatal Ewing's sarcoma/peripheral primitive neuroectodermal tumor (E-EWS/pPNET) of the small bowel is an extremely rare soft tissue neoplasm that tends to strike children and young adults<sup>[1-4]</sup>. It is a highly malignant small round cell tumor that has been thought to be of neural crest origin. It is known that primitive neuroectodermal tumors (PNET) show bidirectional or multidirectional differentiation<sup>[5]</sup>. In this report, we present a young patient who had a gigantic abdominal tumor, which is a condition commonly misdiagnosed; and describe the specific clinical manifestations associated with his condition.

## CASE REPORT

A 15-year-old boy was transferred to our emergency unit from his local hospital due to acute gastrointestinal hemorrhage. He suffered from acute abdominal pain, accompanied by hematemesis and melena. At the time of admission, the patient denied having any symptoms before the current episode of bleeding. We initially postulated that his bleeding was more likely due to duodenal ulcer bleeding. He was given blood and fresh frozen plasma transfusions. Abdominal enhanced computed tomography (CT) revealed a large ovoid solid and cystic tumor (20 cm × 20 cm × 10 cm), which was observed at the left upper quadrant, with a rupture within the mass (Figure 1). It was discovered that there was a translocation of the peripheral organ and vasculature under pressure. During emergency surgery, a giant mass was noted in the jejunal mesenteric region, which was located 15 cm from the ligament of Treitz. The tumor involved the full-thickness of the jejunal wall and was closely associated with the left ureter, kidney, psoas major and spleen. Resection of the tumor and partial resection of the small intestine were performed. Macroscopically, the size of the tumor was 20 cm × 20 cm × 10 cm (Figure 2). An incision on the surface of the tumor revealed sclerotic tissue and bleeding regions inside the tumor. The tumor had infiltrated the full-thickness wall of the jejunum (Figure 3). Small round cells containing uniform vesicular and Homer-Wright rosettes were found microscopically (Figure 4). Erythrocytes were also found between tumor cells (Figure 5). Postoperative laboratory examination revealed that the patient's serum levels of carcinoembryonic antigen, CA19-9, CA12-5 and CA15-3 were normal. When

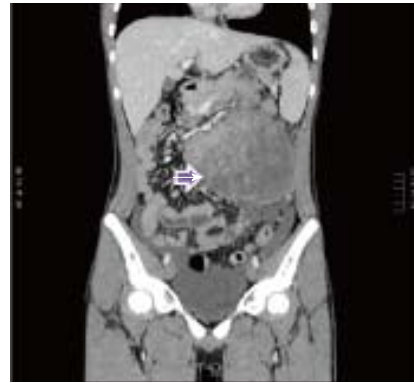


Figure 1 Computerized tomography scan revealing a large ovoid solid and cystic tumor (17 cm × 15 cm × 10 cm) at the left upper quadrant (right arrow).

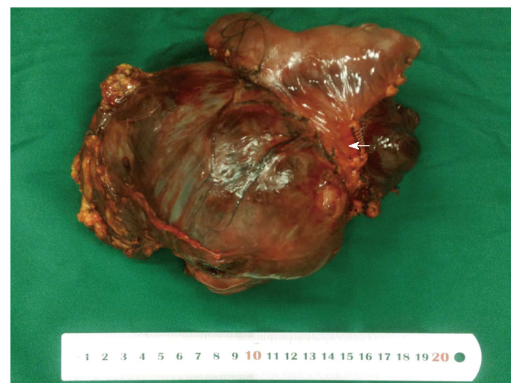


Figure 2 Macroscopically, a large ovoid solid and cystic tumor (20 cm × 20 cm × 10 cm) was observed at the left upper quadrant, and the tumor infiltrated the full-thickness wall of the jejunum (left arrow).

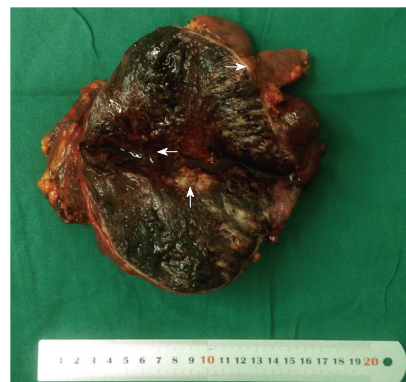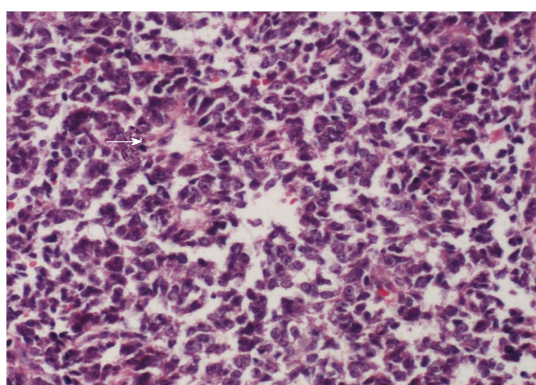
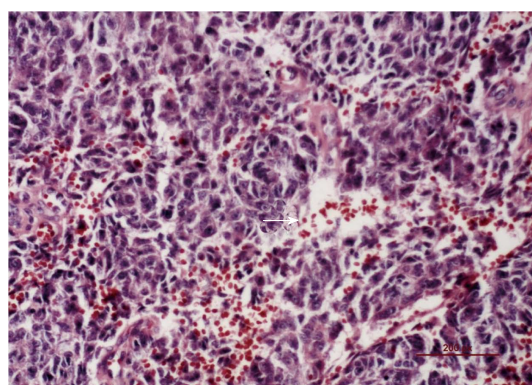


Figure 3 Macroscopically, an incision into the surface of the tumor revealed sclerotic tissue (up arrow) and bleeding regions inside the tumor (left arrow). The tumor had infiltrated the full-thickness wall of the jejunum (right arrow).

examined by immunohistochemistry, the excised tumor cells stained positive for CD99, vimentin, synaptophysin, CD56 and NSE, while they were negative for CK20, CD3, chromogranin-A and S-100. Postoperatively, the patient received systemic chemotherapy. However, the patient died of intra-abdominal recurrence three months later.

**Table 1** Reported cases of primary primitive neuroectodermal tumors of the small bowel mesentery

Ref.	Year of publication	Age/gender	Liposarcoma size (cm)	Treatment	Outcome
Kim <i>et al</i> <sup>[4]</sup>	2013	23/M	11.0 × 6.0	Segmental resection of the small intestine and omentectomy	Recurrence after one year
Bala <i>et al</i> <sup>[3]</sup>	2006	57/F	7.5 × 6.5	Resection of the tumor <i>en bloc</i> with 90 cm of the ileum and cecum	8 mo
Balasubramanian <i>et al</i> <sup>[2]</sup>	2002	53/F	25 × 20	Resection of the tumor <i>en bloc</i>	No data
Horie <i>et al</i> <sup>[1]</sup>	2000	40/M	11.0 × 8.0	Resection of the tumor <i>en bloc</i> and partial resection of the small intestine	Died of massive intra-abdominal recurrence 7 mo later
Present case (Liu <i>et al</i> )	2015	15/M	20 × 20	Resection of the tumor and partial resection of the small intestine	Died of intra-abdominal recurrence 3 mo later

**Figure 4** Small round cells containing uniform vesicular and Homer-Wright rosettes were found microscopically (right arrow, × 200).**Figure 5** Red blood cells were found between the tumor cells (right arrow, × 200).

## DISCUSSION

PNET may occur anywhere in the body<sup>[5]</sup>. Batsakis *et al*<sup>[6]</sup> divided PNET into three groups based on the tissue of origin. Thiostrepton diminishes FOXM1 expression in Ewing cell lines and reduces cell viability through an apoptotic mechanism<sup>[7]</sup>. E-EWS/pPNET is a rare aggressive malignant small round cell tumor derived from the outer central and autonomic nervous systems. In ascending order by morbidity, the primary sites of pPNET are located in the neck, abdomen, retroperitoneum, pelvis and the chest wall. Particularly, E-EWS/pPNET of the small bowel is extremely rare. In addition, there are many patients who suffer from huge abdominal tumors, but do not have any clinical symptoms. Most of these patients die, because they do not receive treatment on time. In this study, we report a patient with a huge abdominal E-EWS/pPNET tumor and reviewed the other four cases (Table 1). In this case, the patient was brought to the attention of clinicians due to abnormal clinical manifestations (hematemesis and melena). As a result of these special clinical symptoms, the patient received timely intervention and the tumor was surgically removed. pPNET is a rare tumor, which can be found in a wide variety of tissues including the pancreas<sup>[8]</sup>, neck<sup>[9]</sup>, spine<sup>[10]</sup>, prostate<sup>[11]</sup> and parotid<sup>[12]</sup>. It is categorized in the Ewing family of tumors and is composed of malignant small round cells<sup>[13-16]</sup>. The solid component of the tumors

was enhanced on contrast-enhanced CT, but the cystic component was not<sup>[17]</sup>. According to the published medical literature, there have been only five cases of E-EWS/pPNET of the small bowel including the patient presented in this report<sup>[1-4]</sup>. pPNET is a rare malignant tumor that usually occurs in children<sup>[18-20]</sup>. Interestingly, compared to the other four documented cases, our 15-year-old patient, who had the second largest tumor in terms of diameter, is the only patient diagnosed at nonage. The tumor was found to have infiltrated the full-thickness of the jejunal wall, accompanied by hematemesis and melena, due to spontaneous rupture. However, the patient died of intra-abdominal recurrence three months later. In summary, such huge abdominal mass often disqualifies patients from surgical intervention with the exception of spontaneous rupture or hematemesis. However, without intervention, these masses would continue to grow and cause significant morbidity. Choosing not to surgically intervene and remove the neoplastic mass inevitably leads to a poor prognosis; and although risky, surgery can sometimes be beneficial in these cases. Therefore, we firmly believe that surgery should be considered a feasible option in such cases.

## COMMENTS

### Case characteristics

A 15-year-old boy suffered from acute abdominal pain, accompanied by

hematemesis and melena.

### Clinical diagnosis

Abdominal tumor.

### Differential diagnosis

Perirenal liposarcoma and gastrointestinal stromal tumor.

### Laboratory diagnosis

Most laboratory data are normal, except for anemia.

### Imaging diagnosis

Abdominal enhanced CT revealed a large ovoid solid and cystic tumor (20 cm × 20 cm × 10 cm), which was observed at the left upper quadrant.

### Pathological diagnosis

Small round cells containing uniform vesicular and Homer-Wright rosettes were found microscopically.

### Treatment

Resection of the tumor and partial resection of the small bowel.

### Related reports

*En bloc* resection of the tumor is required.

### Experiences and lessons

Surgery can sometimes be beneficial in these cases.

### Peer-review

This is an interesting case that deserves to be published in the journal.

## REFERENCES

- 1 Horie Y, Kato M. Peripheral primitive neuroectodermal tumor of the small bowel mesentery: a case showing perforation at onset. *Pathol Int* 2000; **50**: 398-403 [PMID: 10849329 DOI: 10.1046/j.1440-1827.2000.01045.x]
- 2 Balasubramanian B, Dinakarababu E, Molyneux AJ. Primary primitive neuroectodermal tumour of the small bowel mesentery: case report. *Eur J Surg Oncol* 2002; **28**: 197-198 [PMID: 11884059 DOI: 10.1053/ejso.2001.1155]
- 3 Bala M, Maly A, Remo N, Gimmon Z, Almog G. Peripheral primitive neuroectodermal tumor of bowel mesentery in adults. *Isr Med Assoc J* 2006; **8**: 515-516 [PMID: 16889176]
- 4 Kim JM, Chu YC, Choi CH, Kim L, Choi SJ, Park IS, Han JY, Kim KR, Choi YL, Kim T. Peripheral primitive neuroectodermal tumor with osseous component of the small bowel mesentery: a case study. *Korean J Pathol* 2013; **47**: 77-81 [PMID: 23482293 DOI: 10.4132/KoreanJPathol.2013.47.1.77]
- 5 Kushner BH, Hajdu SI, Gulati SC, Erlandson RA, Exelby PR, Lieberman PH. Extracranial primitive neuroectodermal tumors. The Memorial Sloan-Kettering Cancer Center experience. *Cancer* 1991; **67**: 1825-1829 [PMID: 1848468]
- 6 Batsakis JG, Mackay B, el-Naggar AK. Ewing's sarcoma and peripheral primitive neuroectodermal tumor: an interim report. *Ann Otol Rhinol Laryngol* 1996; **105**: 838-843 [PMID: 8865780 DOI: 10.1177/000348949610501014]
- 7 Christensen L, Joo J, Lee S, Wai D, Triche TJ, May WA. FOXM1 is an oncogenic mediator in Ewing Sarcoma. *PLoS One* 2013; **8**: e54556 [PMID: 23365673 DOI: 10.1371/journal.pone.0054556]
- 8 Nishizawa N, Kumamoto Y, Igarashi K, Nishiyama R, Tajima H, Kawamata H, Kaizu T, Watanabe M. A peripheral primitive neuroectodermal tumor originating from the pancreas: a case report and review of the literature. *Surg Case Rep* 2015; **1**: 80 [PMID: 26380804 DOI: 10.1186/s40792-015-0084-7]
- 9 Bishop JA, Alaggio R, Zhang L, Seethala RR, Antonescu CR. Adamantinoma-like Ewing family tumors of the head and neck: a pitfall in the differential diagnosis of basaloid and myoepithelial carcinomas. *Am J Surg Pathol* 2015; **39**: 1267-1274 [PMID: 26034869 DOI: 10.1097/PAS.0000000000000460]
- 10 Tong X, Deng X, Yang T, Yang C, Wu L, Wu J, Yao Y, Fu Z, Wang S, Xu Y. Clinical presentation and long-term outcome of primary spinal peripheral primitive neuroectodermal tumors. *J Neurooncol* 2015; **124**: 455-463 [PMID: 26186903 DOI: 10.1007/s11060-015-1859-1]
- 11 Liao C, Wu X, Wang X, Li H. Primitive neuroectodermal tumor of the prostate: Case report from China. *J Cancer Res Ther* 2015; **11**: 668 [PMID: 26458691 DOI: 10.4103/0973-1482.140759]
- 12 Kalantari M, Deyhimi P, Kalantari P. Peripheral Primitive Neuroectodermal Tumor (pPNET) of the Parotid: Report of a Rare Case. *Arch Iran Med* 2015; **18**: 858-860 [PMID: 26621020]
- 13 Wang C, Li B, Yu X, Xuan M, Gu QQ, Qian W, Qiu TT, Shen ZJ, Zhang MM. Radiological and clinical findings of osseous peripheral primitive neuroectodermal tumors. *Oncol Lett* 2015; **10**: 553-559 [PMID: 26171068 DOI: 10.3892/ol.2015.3233]
- 14 West DC, Grier HE, Swallow MM, Demetri GD, Granowetter L, Sklar J. Detection of circulating tumor cells in patients with Ewing's sarcoma and peripheral primitive neuroectodermal tumor. *J Clin Oncol* 1997; **15**: 583-588 [PMID: 9053480]
- 15 Thorner P, Squire J, Chilton-MacNeil S, Marrano P, Bayani J, Malkin D, Greenberg M, Lorenzana A, Zielenska M. Is the EWS/FLI-1 fusion transcript specific for Ewing sarcoma and peripheral primitive neuroectodermal tumor? A report of four cases showing this transcript in a wider range of tumor types. *Am J Pathol* 1996; **148**: 1125-1138 [PMID: 8644855]
- 16 Votta TJ, Fantuzzo JJ, Boyd BC. Peripheral primitive neuroectodermal tumor associated with the anterior mandible: a case report and review of the literature. *Oral Surg Oral Med Oral Pathol Oral Radiol Endod* 2005; **100**: 592-597 [PMID: 16243245 DOI: 10.1016/j.tripleo.2005.03.015]
- 17 Tan Y, Zhang H, Ma GL, Xiao EH, Wang XC. Peripheral primitive neuroectodermal tumor: dynamic CT, MRI and clinicopathological characteristics--analysis of 36 cases and review of the literature. *Oncotarget* 2014; **5**: 12968-12977 [PMID: 25587032 DOI: 10.18632/oncotarget.2649]
- 18 Sorensen PH, Liu XF, Delattre O, Rowland JM, Biggs CA, Thomas G, Triche TJ. Reverse transcriptase PCR amplification of EWS/FLI-1 fusion transcripts as a diagnostic test for peripheral primitive neuroectodermal tumors of childhood. *Diagn Mol Pathol* 1993; **2**: 147-157 [PMID: 7506981 DOI: 10.1097/00019606-199309000-00002]
- 19 Alexiou GA, Sfakianos G, Dimitriadis E, Stefanaki K, Anastasopoulos J, Matsinos G, Prodromou N. Spinal dumbbell-shaped peripheral primitive neuroectodermal tumor in a child. *Pediatr Neurosurg* 2013; **49**: 119-120 [PMID: 24401730 DOI: 10.1159/000356932]
- 20 Kushner BH, Meyers PA, Gerald WL, Healey JH, La Quaglia MP, Boland P, Wollner N, Casper ES, Aledo A, Heller G. Very-high-dose short-term chemotherapy for poor-risk peripheral primitive neuroectodermal tumors, including Ewing's sarcoma, in children and young adults. *J Clin Oncol* 1995; **13**: 2796-2804 [PMID: 7595741]

P- Reviewer: Amaro F S- Editor: Gong ZM L- Editor: Wang TQ  
E- Editor: Lu YJ





Published by **Baishideng Publishing Group Inc**

8226 Regency Drive, Pleasanton, CA 94588, USA

Telephone: +1-925-223-8242

Fax: +1-925-223-8243

E-mail: [bpgoffice@wjgnet.com](mailto:bpgoffice@wjgnet.com)

Help Desk: <http://www.wjgnet.com/esps/helpdesk.aspx>

<http://www.wjgnet.com>

