ISSN 2307-8960 (online)

World Journal of *Clinical Cases*

World J Clin Cases 2016 December 16; 4(12): 385-422

Published by Baishideng Publishing Group Inc

WJCC World Journal of Clinical Cases

A peer-reviewed, online, open-access journal of Clinical Cases

Editorial Board

2012-2016

The *World Journal of Clinical Cases* Editorial Board consists of 503 members, representing a team of worldwide experts in clinical medical research. They are from 57 countries, including Albania (1), Australia (7), Bangladesh (3), Belgium (3), Brazil (9), Bulgaria (1), Canada (10), China (45), Colombia (2), Croatia (4), Cuba (1), Czech Republic (2), Egypt (5), France (4), Germany (12), Greece (15), Hungary (2), India (53), Indonesia (1), Iran (12), Iraq (1), Ireland (1), Israel (5), Italy (55), Japan (34), Jordan (1), Kazakhstan (1), Kuwait (1), Lebanon (3), Malaysia (1), Mexico (1), Morocco (2), Nepal (1), Netherlands (2), New Zealand (2), Nigeria (1), Oman (1), Pakistan (1), Peru (1), Poland (4), Portugal (3), Qatar (1), Romania (3), Saudi Arabia (3), Serbia (4), Singapore (3), Slovakia (2), Slovenia (1), South Korea (27), Spain (9), Sudan (1), Thailand (2), Trinidad and Tobago (1), Tunisia (1), Turkey (29), United Kingdom (22), United States (80).

WJCC World Journal of Clinical Cases

Contents

Monthly Volume 4 Number 12 December 16, 2016

World Journal of Clinical Cases
Volume 4 Number 12 December 16, 2016

Contents

EDITORS FOR THIS ISSUE

Responsible Assistant Editor: *Xiang Li*
Responsible Electronic Editor: *Huan-Liang Wu*
Proofing Editor-in-Chief: *Lian-Sheng Ma*
Responsible Science Editor: *Xue-Mei Gong*
Proofing Editorial Office Director: *Xiu-Xia Song*

NAME OF JOURNAL
World Journal of Clinical Cases

ISSN
ISSN 2307-8960 (online)

LAUNCH DATE
April 16, 2013

FREQUENCY
Monthly

EDITORS-IN-CHIEF
Giuseppe Di Lorenzo, MD, PhD, Professor, Genitourinary Cancer Section and Rare-Cancer Center, University Federico II of Napoli, Via Sergio Pansini, 5 Ed. 1, 80131, Naples, Italy

Jan Jacques Michiels, MD, PhD, Professor, Primary Care, Medical Diagnostic Center Rijnmond Rotterdam, Bloodcoagulation, Internal and Vascular Medicine, Erasmus University Medical Center, Rotterdam, Goodheart Institute and Foundation, Erasmus Tower, Veenmos 13, 3069 AT, Erasmus City, Rotterdam, The Netherlands

Sandro Vento, MD, Department of Internal Medicine, University of Botswana, Private Bag 00713, Gaborone, Botswana

Shuhei Yoshida, MD, PhD, Division of Gastroenterology, Beth Israel Deaconess Medical Center, Dana 509, Harvard Medical School, 330 Brookline Ave, Boston, MA 02215, United States

EDITORIAL BOARD MEMBERS
All editorial board members resources online at http://www.wjgnet.com/2307-8960/editorialboard.htm

EDITORIAL OFFICE
Xiu-Xia Song, Director
Fang-Fang Ji, Vice Director
World Journal of Clinical Cases
Baishideng Publishing Group Inc
8226 Regency Drive, Pleasanton, CA 94588, USA
Telephone: +1-925-2238242
Fax: +1-925-2238243
E-mail: editorialoffice@wjgnet.com
Help Desk: http://www.wjgnet.com/esps/helpdesk.aspx
http://www.wjgnet.com

PUBLISHER
Baishideng Publishing Group Inc
8226 Regency Drive,
Pleasanton, CA 94588, USA
Telephone: +1-925-2238242
Fax: +1-925-2238243
E-mail: bpgoffice@wjgnet.com

Help Desk: http://www.wjgnet.com/esps/helpdesk.aspx
http://www.wjgnet.com

PUBLICATION DATE
December 16, 2016

INSTRUCTIONS TO AUTHORS
http://www.wjgnet.com/bpg/gerinfo/204

ONLINE SUBMISSION
http://www.wjgnet.com/esps/

World Journal of Clinical Cases

Submit a Manuscript: http://www.wjgnet.com/esps/
Help Desk: http://www.wjgnet.com/esps/helpdesk.aspx
DOI: 10.12998/wjcc.v4.i12.385

World J Clin Cases 2016 December 16; 4(12): 385-389
ISSN 2307-8960 (online)

EDITORIAL

Primary splenic lymphoma: Current diagnostic trends

Sachin B Ingle, Chitra R Hinge (Ingle)

Sachin B Ingle, Department of Pathology, MIMSR Medical College, Latur, Maharashtra 4132512, India

Chitra R Hinge (Ingle), Department of Physiology, MIMSR Medical College, Latur, Maharashtra 4132512, India

Author contributions: Ingle SB prepared the first draft of the manuscript; Hinge (Ingle) CR critically revised the manuscript, added intellectual content and approved the final draft of the manuscript.

Conflict-of-interest statement: All the authors hereby declare that they have no any conflicts of interests.

Manuscript source: Invited manuscript

Correspondence to: Sachin B Ingle, Professor, Department of Pathology, MIMSR Medical College, Ambajogai Road, vishwanathpuram, Latur, Maharashtra 4132512, India. dr.sachiningle@gmail.com
Telephone: +91-2382-227424
Fax: +91-2382-228939

Received: March 13, 2016
Peer-review started: March 14, 2016
First decision: April 20, 2016
Revised: October 9, 2016
Accepted: October 22, 2016
Article in press: October 24, 2016
Published online: December 16, 2016

Abstract

The primary splenic lymphoma is extremely uncommon, can present with grave complications like hypersplenism and splenic rupture. In view of vague clinical presentation, it is difficult to arrive at the diagnosis. In such circumstances, histopathological diagnosis is very important. A precise diagnosis can only be made on histopathology and confirmed on immunohistochemistry. Emergency splenectomy is preferred as an effective therapeutic and diagnostic tool in cases with giant splenomegaly. Core biopsy is usually not advised due to a high risk of post-core biopsy complications in view of its high vascularity and fragility. Aim behind highlighting the topic is to specify that core biopsy/ fine needle aspiration cytology can be used as an effective diagnostic tool to arrive at correct diagnosis to prevent untoward complications related to disease and treatment. Anticoagulation therapy is vital after splenectomy to avoid portal splenic vein thrombosis.

Key words: Splenic lymphoma; Biopsy; Immunohistochemistry

Core tip: Primary splenic lymphoma is a rare entity, has vague clinical presentation and can present with grave complications like hypersplenism and splenic rupture. In such circumstances, core biopsy/fine needle aspiration cytology can hit the correct pathological diagnosis. Emergency splenectomy is an effective therapeutic and diagnostic tool in cases with massive splenomegaly with features of hypersplenism.

Ingle SB, Hinge (Ingle) CR. Primary splenic lymphoma: Current diagnostic trends. *World J Clin Cases* 2016; 4(12): 385-389 Available from: URL: http://www.wjgnet.com/2307-8960/full/v4/i12/385.htm DOI: http://dx.doi.org/10.12998/wjcc.v4.i12.385

INTRODUCTION

Primary splenic lymphoma (PSL) is very unusual

entities if strict diagnostic criteria are applied[1]. As per previous studies the final diagnosis of PSL should be made only when the disease is limited to spleen or involving hilar lymph nodes without any recurrence after splenectomy[1-4]. In patients with PSL, therapeutic splenectomy is to be done. However, presently ultrasound guided core biopsy is a safe and efficient diagnostic investigation, can be used routinely. Therapeutic splenectomy is to be followed by anticoagulation therapy and chemotherapy[5].

EPIDEMIOLOGY

Incidence

PSL is a rare neoplasm of the spleen, probably comprising less than 2% of all the lymphomas[6,7] and 1% of all the non-Hodgkin's lymphomas[2,8-10].

Types

There are two main types: (1) splenic lymphoma with circulating villous lymphocytes[6]; and (2) marginal zone splenic lymphoma originating from a peculiar splenic B-cell structure separated by the mantle zone.

CLINICAL PRESENTATIONS

Nonspecific symptoms

Clinical presentations of nonspecific symptoms are weight loss, weakness, fever, and lower upper quadrant pain or discomfort due to enlarged spleen.

Specific symptoms

Clinical presentations of specific symptoms are mainly due to invasion of lymphoma cells in to adjacent organs stomach, pancreas, diaphragm, colon, or mesentery[11-16].

Hematological parameters

Cytopaenia can also be a presenting feature[7]. The complete blood count and peripheral smear (PS) findings are mostly unremarkable[17]. Elevation of ESR may be noted[7].

Other presentations

PSL presenting as splenic abscess although uncommon, is associated with high morbidity and death rates due to delayed diagnosis and management[18]. Due to vague presentation, the clinical diagnosis is difficult[19]. Splenic lymphomas usually present as space occupying solid lesions and when present as splenic abscesses are usually encountered in patients with underlying disorders, including infections, emboli, trauma, recent surgery, malignant hematologic conditions and immunosuppression[20].

DIAGNOSTIC APPROACH

The nonspecific clinical presentation of PSL creates the real diagnostic dilemma.

Reference criteria for diagnosis/staging PSL

Dasgupta *et al*[1] reported that Lymphoma restricted to the spleen and hilar lymph nodes. Further confirmed following a 6-mo relapse-free period following splenectomy. Skarin *et al*[21] reported that lymphoma with splenic involvement in which splenomegaly is the dominant feature. Dachman *et al*[14] reported that splenic lesions with hypodensity on contrast enhanced Computed tomography scans or lesions with hypoechogenecity on ultrasound (USG) studies. Ahmann *et al*[11] reported that stage Ⅰ refers to disease confined to the spleen; Stage Ⅱ refers to splenic involvement along with hilar lymph nodes; Stage Ⅲ refers to extra-splenic nodal or hepatic involvement.

Peripheral blood smear evaluation

Most of the patients we can reveal neoplastic lymphoid cells on peripheral blood smear, *i.e.*, hairy cells, prolymphocytes, villous lymphocytes, basophilic villous lymphocytes, *etc.*, which may raise the suspicion of neoplastic lymphoid disease in the mind of pathologist (Figure 1).

Biopsy

Core biopsy/fine needle aspiration cytology (FNAC) are traditionally not recommended in view of high fragility of splenic tissue leading to hemorrhagic complications. However, currently it can be used as a routine diagnostic test[22].

In diffuse large B cell lymphoma: Microscopy predominantly shows monotonous population of large neoplastic lymphoid cells with large areas of necrosis[5]. The individual cells essentially demonstrated a large atypical nucleus, irregular nuclear borders with vesicular chromatin and prominent nuclei. Histopathological examination reported as Non-Hodgkin's Lymphoma of diffuse large B cell phenotype[5] (Figure 2).

Hairy cell leukemia: Shows the small to medium sized lymphocytic infiltrate more clearly. Round to kidney-shaped with abundant clear cytoplasm are usually revealed (Figure 3).

Marginal zone splenic lymphoma: Splenic white pulp reactive germinal centres show small neoplastic lymphoid cells almost replacing the mantle zone with occasional large blast like malignant lymphoid cells. Other points we have to reveal are epithelial histocytes, sinus invasion, and plasmacytic differentiation of proliferating cells[5] (Figure 4).

PSL (follicular type): It is neoplastic proliferation of follicle center B-cells, *i.e.*, centrocytes and centroblasts exhibiting follicular pattern (Figure 5).

Immunohistochemistry

Histopathology report is to be confirmed by IHC. The tumor cells are immunopositive for B cell markers, *e.g.*,

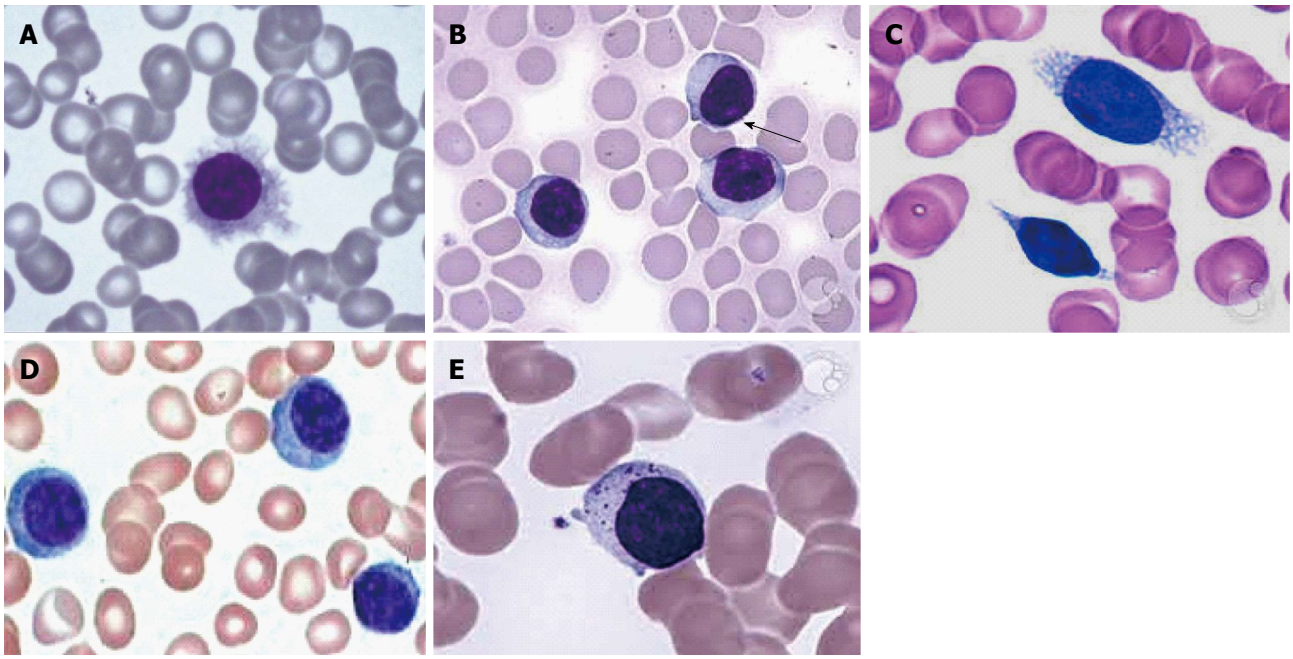

Figure 1 Peripheral blood smear. A: Hairy cells; B: Prolymphocytes; C: Villous lymphocytes; D: Plasmacytoid lymphocytes; E: Granular lymphocytes.

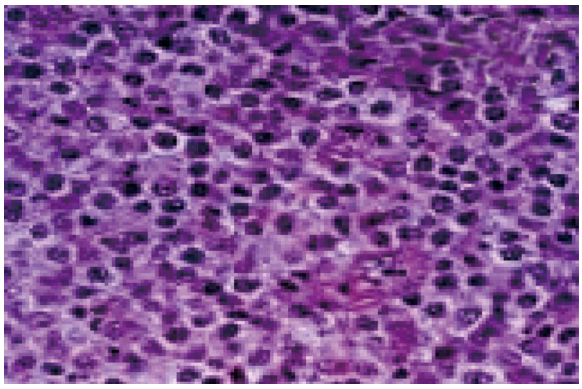

Figure 2 Diffuse large B cell lymphoma showing monotonous population of large neoplastic lymphoid cells.

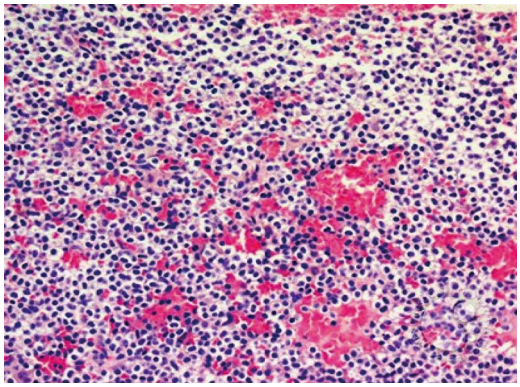

Figure 3 Small to medium sized lymphocytic infiltrate.

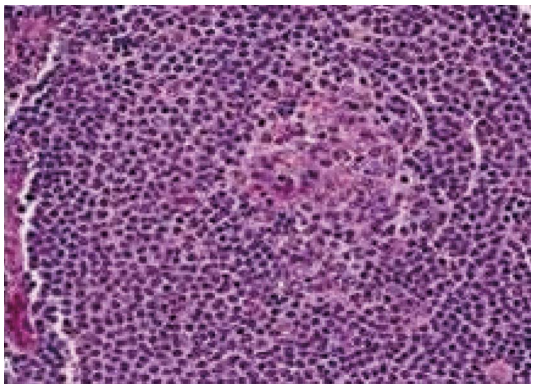

Figure 4 Splenic white pulp are replaced by small neoplastic lymphocytes.

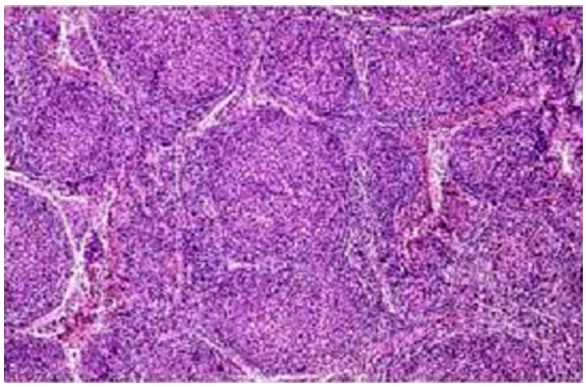

Figure 5 Neoplastic lymphoid cells arranged predominantly in follicular pattern.

CD 20 and immunonegative for T cell markers (Figure 6).

B cell lymphoma: B cell lymphoma-2 (BCL-2) immunoreactivity is useful to differentiate malignant lymphoma (BCL-2 positive) from reactive (BCL-2 negative) B cells in the marginal zone (Figure 7).

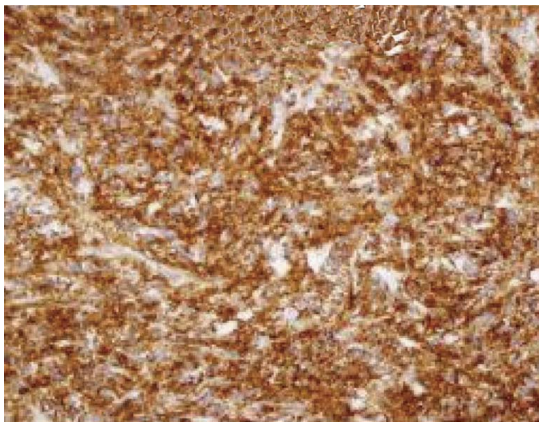

Figure 6 CD20 immunopositivity in neoplastic lymphoid B cells.

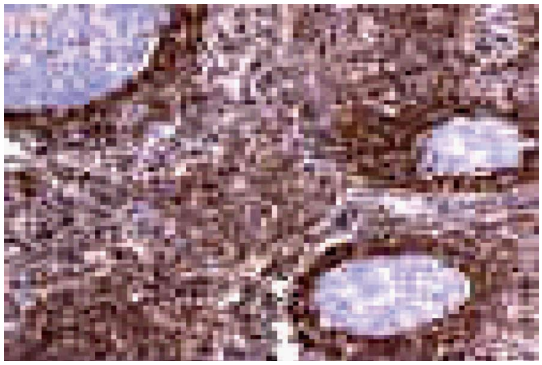

Figure 7 B cell lymphoma-2 expression in follicular lymphoma.

Diagnostic imaging

US imaging of the abdomen and whole-body computed tomography (Figure 8) scan are to be done in each and every case with splenomegaly. The B mode USG determines the actual size of spleen and computed tomography confirms the involvement of hilar lymph nodes[23,24].

DIAGNOSTIC AND THERAPEUTIC SPLENECTOMY

The previous workers suggested splenectomy as an effective diagnostic and therapeutic tool[25,26]. It has morbidity and mortality rates accounting for approximately 12% and less than 1%, respectively[27]; Now a days, laparoscopic splenectomy can be used as a safe and efficient method, reducing both the mortality and morbidity significantly[28]. In this the distortion of the samples should be strictly avoided.

Needle core biopsy is more efficient and safe and can be used in high risk patients also. Previous studies[29,30] concluded that splenic needle biopsy has low complication rates with high diagnostic utility. Recently, laparoscopic splenectomy has often been used for splenic masses because of fewer complications and since it is rather appropriate for moderate splenomegaly[30,31].

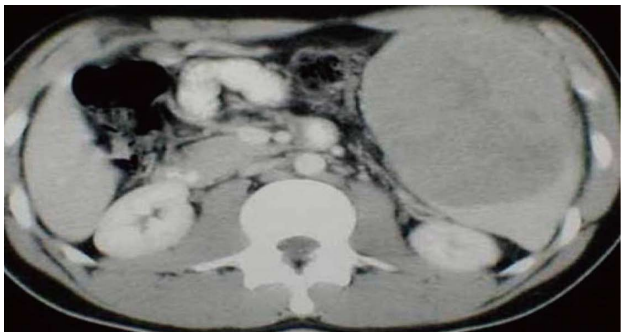

Figure 8 Computed tomography showing massive splenomegaly on ultrasonography.

Echo-guided splenic biopsy and FNAC are effective in peripherally located lesions[32].

Splenic DLBCLs are clinically aggressive neoplasms. So, line of treatment of such SLs should be same as DLBCLS[33]. Splenic form of the micronodular T-cell/histiocyte-rich DLBCL subtype presents with micronodules in the spleen with involvement of bone marrow or other extranodal sites[34,35].

Gastrosplenic fistula is associated with benign peptic ulcer disease, gastric Crohn's disease, gastric adenocarcinoma, and primary gastric and splenic lymphomas. There occurs hemorrhage due to erosion by primary splenic lesion in the stomach. Upper intestinal hemorrhage can be successfully treated with splenic artery embolization, followed by splenectomy and gastric resection[35].

To conclude, splenic needle biopsy or core biopsy can be used as an effective diagnostic tool now days to hit the correct histological diagnosis to avoid untoward complications related to disease and treatment in search of accurate pathological diagnosis.

REFERENCES

1 **Dasgupta T**, Coombes B, Brasfield rd. primary malignant neoplasms of the spleen. *Surg Gynecol Obstet* 1965; **120**: 947-960 [PMID: 14269844]

2 **Cavanna L**, Artioli F, Vallisa D, Di Donato C, Bertè R, Carapezzi C, Foroni R, Del Vecchio C, Lo Monaco B, Prati R. Primary lymphoma of the spleen. Report of a case with diagnosis by fine-needle guided biopsy. *Haematologica* 1995; **80**: 241-243 [PMID: 7672717]

3 **Harris NL**, Aisenberg AC, Meyer JE, Ellman L, Elman A. Diffuse large cell (histiocytic) lymphoma of the spleen. Clinical and pathologic characteristics of ten cases. *Cancer* 1984; **54**: 2460-2467 [PMID: 6388805 DOI: 10.1002/1097-0142(19841201)54:11<2460::AID-CNCR2820541125>3.0.CO;2-K]

4 **Burke JS**. Surgical pathology of the spleen: an approach to the differential diagnosis of splenic lymphomas and leukemias. Part II. Diseases of the red pulp. *Am J Surg Pathol* 1981; **5**: 681-694 [PMID: 7039375]

5 **Ingle SB**, Ingle CR. Splenic lymphoma with massive splenomegaly: Case report with review of literature. *World J Clin Cases* 2014; **2**: 478-481 [PMID: 25232555 DOI: 10.12998/wjcc.v2.i9.478]

6 **Gobbi PG**, Grignani GE, Pozzetti U, Bertoloni D, Pieresca C, Montagna G, Ascari E. Primary splenic lymphoma: does it exist? *Haematologica* 1994; **79**: 286-293 [PMID: 7926983]

7 **Healy NA**, Conneely JB, Mahon S, O'Riardon C, McAnena OJ.

Primary splenic lymphoma presenting with ascites. *Rare Tumors* 2011; **3**: e25 [PMID: 21769324 DOI: 10.4081/rt.2011.e25]

8 **Kraemer BB**, Osborne BM, Butler JJ. Primary splenic presentation of malignant lymphoma and related disorders. A study of 49 cases. *Cancer* 1984; **54**: 1606-1619 [PMID: 6548171 DOI: 10.1002/1097-0142(19841015)54:8<1606::AID-CNCR2820540823>3.0.CO;2-5]

9 **Kehoe J**, Straus DJ. Primary lymphoma of the spleen. Clinical features and outcome after splenectomy. *Cancer* 1988; **62**: 1433-1438 [PMID: 3416282 DOI: 10.1002/1097-0142(19881001)62:7<1433::AID-CNCR2820620731>3.0.CO;2-V]

10 **Falk S**, Stutte HJ. Primary malignant lymphomas of the spleen. A morphologic and immunohistochemical analysis of 17 cases. *Cancer* 1990; **66**: 2612-2619 [PMID: 2249201 DOI: 10.1002/1097-0142(19901215)66:12<2612::AID-CNCR2820661225>3.0.CO;2-Q]

11 **Ahmann DL**, Kiely JM, Harrison EG, Payne WS. Malignant lymphoma of the spleen. A review of 49 cases in which the diagnosis was made at splenectomy. *Cancer* 1966; **19**: 461-469 [PMID: 5327041 DOI: 10.1002/1097-0142(196604)19:4<461::AID-CNCR2820190402>3.0.CO;2-X]

12 **Kim KH**, Cho CK, Choo SW, Kim HJ, Kim KS. Primary lymphoma of the spleen- a case report. *Korean J Surg* 1997; **52**: 912-917

13 **Hahn JS**, Lee S, Chong SY, Min YH, Ko YW. Eight-year experience of malignant lymphoma--survival and prognostic factors. *Yonsei Med J* 1997; **38**: 270-284 [PMID: 9409190 DOI: 10.3349/ymj.1997.38.5.270]

14 **Dachman AH**, Buck JL, Krishnan J, Aguilera NS, Buetow PC. Primary non-Hodgkin's splenic lymphoma. *Clin Radiol* 1998; **53**: 137-142 [PMID: 9502091 DOI: 10.1016/S0009-9260(98)80061-5]

15 **Xiros N**, Economopoulos T, Christodoulidis C, Dervenoulas J, Papageorgiou E, Mellou S, Styloyiannis S, Tsirigotis P, Raptis SA. Splenectomy in patients with malignant non-Hodgkin's lymphoma. *Eur J Haematol* 2000; **64**: 145-150 [PMID: 10997879 DOI: 10.1034/j.1600-0609.2000.90079.x]

16 **Brox A**, Bishinsky JI, Berry G. Primary non-Hodgkin lymphoma of the spleen. *Am J Hematol* 1991; **38**: 95-100 [PMID: 1951314 DOI: 10.1002/ajh.2830380205]

17 **Izzo L**, Binda B, Boschetto A, Carmanico L, Galati G, Fior E, Marini M, Mele LL, Stasolla A. Primary Splenic Lymphoma; the diagnostic and therapeutic value of splenectomy. *Haematologica* 2002; **87**; ECR 20

18 **Agrawal SC**, Bharucha MA, Deo A, Velling K. Post surgical diagnosis of primary DLBCL presenting as Splenic abscess. *Austral - Asian Journal of Cancer* 2012; **11**: 217-220

19 **Konstantiadou I**, Mastoraki A, Papanikolaou IS, Sakorafas G, Safioleas M. Surgical approach of primary splenic lymphoma: report of a case and review of the literature. *Indian J Hematol Blood Transfus* 2009; **25**: 120-124 [PMID: 23100989 DOI: 10.1007/s12288-009-0025-3]

20 **Thanos L**, Dailiana T, Papaioannou G, Nikita A, Koutrouvelis H, Kelekis DA. Percutaneous CT-guided drainage of splenic abscess. *AJR Am J Roentgenol* 2002; **179**: 629-632 [PMID: 12185032 DOI: 10.2214/ajr.179.3.1790629]

21 **Skarin AT**, Davey FR, Moloney WC. Lymphosarcoma of the spleen. Results of diagnostic splenectomy in 11 patients. *Arch Intern Med* 1971; **127**: 259-265 [PMID: 5101153]

22 **López JI**, Del Cura JL, De Larrinoa AF, Gorriño O, Zabala R, Bilbao FJ. Role of ultrasound-guided core biopsy in the evaluation of spleen pathology. *APMIS* 2006; **114**: 492-499 [PMID: 16907854 DOI: 10.1111/j.1600-0463.2006.apm_378.x]

23 **Lamb PM**, Lund A, Kanagasabay RR, Martin A, Webb JA, Reznek RH. Spleen size: how well do linear ultrasound measurements correlate with three-dimensional CT volume assessments? *Br J Radiol* 2002; **75**: 573-577 [PMID: 12145129 DOI: 10.1259/bjr.75.895.750573]

24 **Peddu P**, Shah M, Sidhu PS. Splenic abnormalities: a comparative review of ultrasound, microbubble-enhanced ultrasound and computed tomography. *Clin Radiol* 2004; **59**: 777-792 [PMID: 15351243 DOI: 10.1016/j.crad.2004.01.007]

25 **Iannitto E**, Tripodo C. How I diagnose and treat splenic lymphomas. *Blood* 2011; **117**: 2585-2595 [PMID: 21119113 DOI: 10.1182/blood-2010-09-271437]

26 **Vander Walt JD**. Lymphomas in the bone marrow. *Diagn Histopathol* 2010; **16**: 125-142 [DOI: 10.1016/j.mpdhp.2009.12.008]

27 **Baccarani U**, Terrosu G, Donini A, Zaja F, Bresadola F, Baccarani M. Splenectomy in hematology. Current practice and new perspectives. *Haematologica* 1999; **84**: 431-436 [PMID: 10329922]

28 **Grahn SW**, Alvarez J, Kirkwood K. Trends in laparoscopic splenectomy for massive splenomegaly. *Arch Surg* 2006; **141**: 755-761; discussion 761-762 [PMID: 16924082 DOI: 10.1001/archsurg.141.8.755]

29 **Tam A**, Krishnamurthy S, Pillsbury EP, Ensor JE, Gupta S, Murthy R, Ahrar K, Wallace MJ, Hicks ME, Madoff DC. Percutaneous image-guided splenic biopsy in the oncology patient: an audit of 156 consecutive cases. *J Vasc Interv Radiol* 2008; **19**: 80-87 [PMID: 18192471 DOI: 10.1016/j.jvir.2007.08.025]

30 **Gómez-Rubio M**, López-Cano A, Rendón P, Muñoz-Benvenuty A, Macías M, Garre C, Segura-Cabral JM. Safety and diagnostic accuracy of percutaneous ultrasound-guided biopsy of the spleen: a multicenter study. *J Clin Ultrasound* 2009; **37**: 445-450 [PMID: 19582827 DOI: 10.1002/jcu.20608]

31 **Armitage JO**. How I treat patients with diffuse large B-cell lymphoma. *Blood* 2007; **110**: 29-36 [PMID: 17360935 DOI: 10.1182/blood-2007-01-041871]

32 **Tessier DJ**, Pierce RA, Brunt LM, Halpin VJ, Eagon JC, Frisella MM, Czerniejewski S, Matthews BD. Laparoscopic splenectomy for splenic masses. *Surg Endosc* 2008; **22**: 2062-2066 [PMID: 18246392 DOI: 10.1007/s00464-008-9748-8]

33 **Shimizu I**, Ichikawa N, Yotsumoto M, Sumi M, Ueno M, Kobayashi H. Asian variant of intravascular lymphoma: aspects of diagnosis and the role of rituximab. *Intern Med* 2007; **46**: 1381-1386 [PMID: 17827836 DOI: 10.2169/internalmedicine.46.0066]

34 **Kan E**, Levy I, Benharroch D. Splenic micronodular T-cell/histiocyte-rich large B-cell lymphoma: effect of prior corticosteroid therapy. *Virchows Arch* 2009; **455**: 337-341 [PMID: 19763612 DOI: 10.1007/s00428-009-0830-y]

35 **Bird MA**, Amjadi D, Behrns KE. Primary splenic lymphoma complicated by hematemesis and gastric erosion. *South Med J* 2002; **95**: 941-942 [PMID: 12190240]

P- Reviewer: Chan EL, Liu QD **S- Editor**: Kong JX **L- Editor**: A
E- Editor: Wu HL

World Journal of Clinical Cases

Submit a Manuscript: http://www.wjgnet.com/esps/
Help Desk: http://www.wjgnet.com/esps/helpdesk.aspx
DOI: 10.12998/wjcc.v4.i12.390

World J Clin Cases 2016 December 16; 4(12): 390-400
ISSN 2307-8960 (online)

CASE REPORT

Paclitaxel-associated reticulate hyperpigmentation: Report and review of chemotherapy-induced reticulate hyperpigmentation

Philip R Cohen

Philip R Cohen, Department of Dermatology, University of California San Diego, San Diego, CA 92131-3643, United States

Author contributions: Cohen PR designed the report, performed the research, collected the patient's clinical data, analyzed the data, and wrote the paper.

Institutional review board statement: The study was reviewed and approved by the University of California San Diego Institutional Review Board.

Informed consent statement: The study participant provided informed written consent prior to study enrollment.

Conflict-of-interest statement: Philip R Cohen has no conflicts of interest. He has received no fees for serving as a speaker, a consultant or an advisory board member. Philip R Cohen has received no research funding. Philip R Cohen is an employee of the University of California San Diego. Philip R Cohen owns no stocks or shares in any organization. Philip R Cohen owns no patents.

Manuscript source: Invited manuscript

Correspondence to: Philip R Cohen, MD, Department of Dermatology, University of California San Diego, 10991 Twinleaf Court, San Diego, CA 92131-3643, United States. mitehead@gmail.com
Telephone: +1-858-6578322

Received: June 26, 2016
Peer-review started: June 29, 2016
First decision: September 5, 2016
Revised: September 26, 2016
Accepted: October 22, 2016
Article in press: October 24, 2016
Published online: December 16, 2016

Abstract

Drug-induced reticulate hyperpigmentation is uncommon. Including the patient described in this report, chemotherapy-associated reticulate hyperpigmentation has only been described in ten individuals. This paper describes the features of a woman with recurrent and metastatic breast cancer who developed paclitaxel-induced reticulate hyperpigmentation and reviews the characteristics of other oncology patients who developed reticulate hyperpigmentation from their antineoplastic treatment. A 55-year-old Taiwanese woman who developed reticulate hyperpigmentation on her abdomen, back and extremities after receiving her initial treatment for metastatic breast cancer with paclitaxel is described. The hyperpigmentation became darker with each subsequent administration of paclitaxel. The drug was discontinued after five courses and the pigment faded within two months. PubMed was searched with the key words: Breast, cancer, chemotherapy, hyperpigmentation, neoplasm, reticulate, tumor, paclitaxel, taxol. The papers generated by the search, and their references, were reviewed. Chemotherapy-induced reticulate hyperpigmentation has been described in four men and six women. Bleomycin, cytoxan, 5-fluorouracil, idarubacin, and paclitaxel caused the hyperpigmentation. The hyperpigmentation faded in 83% of the patients between two to six months after the associated antineoplastic agent was discontinued. In conclusion, chemotherapy-induced reticulate hyperpigmentation is a rare reaction that may occur during treatment with various antineoplastic agents. The hyperpigmentation fades in most individuals once the

treatment is discontinued. Therefore, cancer treatment with the associated drug can be continued in patients who experience this cutaneous adverse event.

Key words: Breast; Cancer; Chemotherapy; Hyperpigmentation; Neoplasm; Reticulate; Tumor; Paclitaxel; Taxol

Core tip: Chemotherapy-induced reticulate hyperpigmentation has been described in four men and six women being treated for either a hematologic malignancy or a solid tumor. Associated drugs included cytoxan (with or without idarubicin), paclitaxel, 5-fluorouracil and bleomycin. The skin lesions were usually asymptomatic and appeared as linear macular hyperpigmention that was lacy, net-like, or both on the patient's back. The hyperpigmentation appeared within 3 d to 18 wk after starting the drug and faded within 2 to 6 mo after stopping the medication. Chemotherapy-induced reticulate hyperpigmentation did not require dose reduction or discontinuation of the associated antineoplastic treatment.

Cohen PR. Paclitaxel-associated reticulate hyperpigmentation: Report and review of chemotherapy-induced reticulate hyperpigmentation. *World J Clin Cases* 2016; 4(12): 390-400 Available from: URL: http://www.wjgnet.com/2307-8960/full/v4/i12/390.htm DOI: http://dx.doi.org/10.12998/wjcc.v4.i12.390

INTRODUCTION

Reticulate pigmentary disorders can be congenital or acquired[1]. Drug-induced reticulate hyperpigmentation is uncommon[2]. A woman with paclitaxel-associated reticulate hyperpigmentation is described and antineoplastic therapy-related linear and reticulate hyperpigmentation is reviewed.

CASE REPORT

A 55-year-old Taiwanese woman with metastatic breast cancer to her lungs and bones presented for evaluation of a new asymptomatic rash on her abdomen, back and legs. She had a prior allergic reaction, in 2014, to zoledronic acid after the initial intravenous infusion; non-tender, non-pruritic erythematous patches developed on her proximal medial thighs and inguinal regions, axilla, antecubital fossa and popliteal fossa. The lesions resolved spontaneously and there was no reaction when an alternative agent, denasumab, was given.

In 2004, she was diagnosed with invasive mixed ductal and lobular carcinoma (grade 2, T3N3 with lymphatic vessel invasion, estrogen receptor positive, progesterone receptor negative, and HER2/neu negative) right breast cancer. Treatment included right breast lumpectomy, chemotherapy (adriamycin and cytoxan, followed by taxol), radiation therapy, and hormonal therapy (for five years); her treatment finished in February 2010.

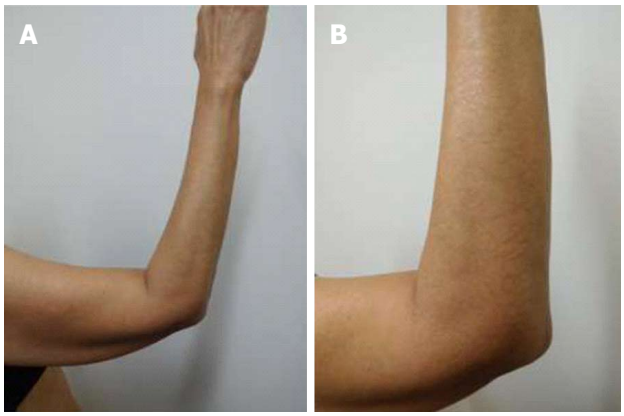

Figure 1 Distant (A) and closer (B) views of paclitaxel-induced reticulate hyperpigmentation on the elbow and extensor right arm.

Follow up workup in July 2014 revealed biopsy-confirmed recurrence of her breast cancer characterized by hilar adenopathy, multiple pulmonary nodules and bony metastases. She began daily letrozole that month.

Restaging, in May 2015 showed disease progression. During the next few months, she was unsuccessfully treated initially with an oral selective estrogen receptor degrader and subsequently with a combination of abemaciclib, exemestane and everolimus. Capecitabine was started in September 2015; erythema appeared on the sun-exposed areas of her face. Subsequently, diffuse and confluent malar postinflammatory hyperpigmentation developed. Increased tumor burden was observed after 4 mo of treatment and the drug was discontinued.

Paclitaxel (80 mg/m^2) intravenous weekly therapy was initiated in January 2016. She was premeditated prior to each treatment to prevent hypersensitivity reactions. She received intravenous dexamethasone (10 mg) and famotidine (20 mg) and intramuscular diphenhydramine (25 mg).

Hyperpigmentation on her abdomen, back and extremities was noted to initially appear during the week after receiving her first infusion of paclitaxel and prior to her second treatment. She also noted that the new hyperpigmentation appeared darker (and provided greater contrast with the normal appearing skin of her abdominal striae) on the day of each paclitaxel infusion. In contrast, her facial hyperpigmentation-secondary to capecitabine - was fading.

She was examined after her fifth weekly treatment of paclitaxel. She had dark brown linear and reticulate hyperpigmentation, more prominent proximally than distally, on the extensor arms (Figure 1) and legs (Figure 2), on the back (Figure 3), and on the abdomen (Figure 4). The net-like hyperpigmentation did not occur in the abdominal striae (Figure 4).

Microscopic examination of hyperpigmented skin

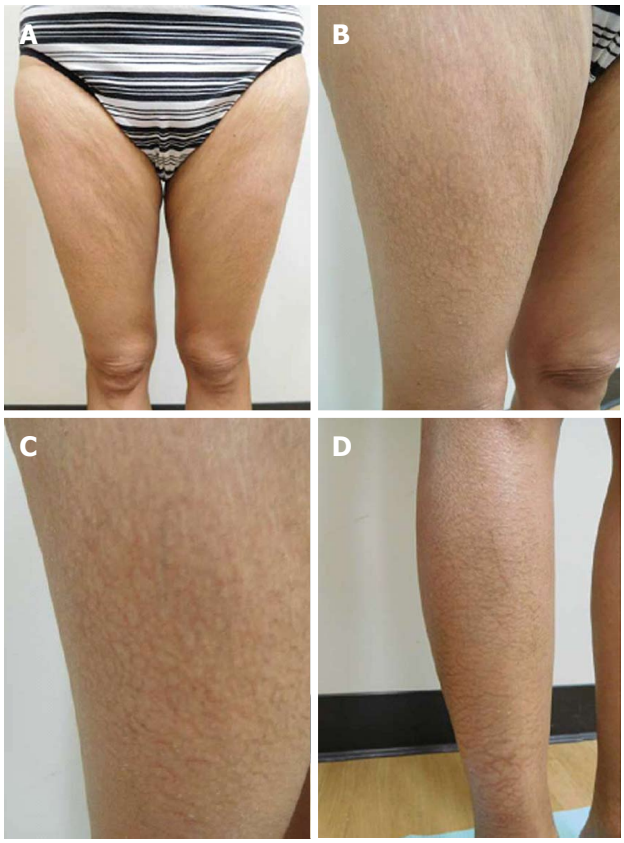

Figure 2 Paclitaxel-associated reticulate hyperpigmentation on the lower extremities. Linear and net-like hyperpigmentation is noted on distant (A), intermediate (B and D) and closer (C) views of the right thigh (B and C) and right pretibial area (D).

and normal appearing skin (for comparison) from the abdomen was performed. The hyperpigmented skin showed not only prominent melanin deposited within the basal layer of the epidermis but also incontinence of melanin pigment and melanophages in the upper dermis (Figure 5); a Fontana-Masson stain confirms the presence of melanin at these locations (Figure 6). In contrast, the normal-appearing skin only showed slight hyperpigmentation of the epidermal basal layer (Figure 7); a Fontana-Masson stain confirmed the sparse presence of melanin in the basal layer of the epidermis and focally in the papillary dermis (Figure 8). A Perl's iron stain, to detect iron, was negative in both the hyperpigmented skin and the normal appearing skin.

In summary, in comparison to the normal-appearing skin, the deposition of melanin in the epidermis and dermis was significantly greater in the areas of hyperpigmentation.

She received two additional courses of paclitaxel. After her seventh treatment, she developed painful and swollen, erythematous scaling plaques on her wrists, posterior neck and right ankle (Figure 9). The right ankle lesion progressed and a similar lesion appeared on her left ankle (Figure 10). Biopsy demonstrated an interface dermatitis. Her ankle lesions prevented her from being able to walk; therefore, her paclitaxel treatments were discontinued. Her symptoms and skin changes completely resolved.

The reticulate hyperpigmentation had completely faded on her abdomen and legs at follow up 2 mo after stopping the paclitaxel. There was also significant fading of the pigmentation on her back and arms. She is currently being treated with a monthly infusion of faslodex and palbociclib daily for 3 consecutive weeks each month and has not developed chemotherapy-induced reticulate hyperpigmentation.

DISCUSSION

Widespread reticulate hyperpigmentation has, albeit rarely, been observed following exposure to medications[2]. Reticulate hyperpigmentation has been described in single individuals who have received topical benzoyl peroxide[3], oral diltiazim[4], or intravenous regional anesthesia with prilocaine and methylprednisolone[5]. This pattern of hyperpigmentation has also been observed in individuals receiving antineoplastic therapy.

PubMed was used to search the following terms: Breast, cancer, chemotherapy, hyperpigmentation, neoplasm, reticulate, tumor, paclitaxel, taxol. All papers were reviewed and relevant manuscripts, along with their reference citations, were evaluated. Including the patient reported in this paper, chemotherapy-induced reticulate hyperpigmentation has occurred in 10 individuals (Table 1)[6-9].

Wright *et al*[6] initially described reticulate hyperpigmentation resulting from chemotherapy in 1990. Their patient was a 55-year-old man with non-Hodkins lymphoma who "developed striking hyperpigmentation of the skin, consisting of widespread symmetrical reticulate streaks of hyperpigmentation in a racemose pattern on the trunk and limbs". He had received several antineoplastic agents, including bleomycin; the hyperpigmentation developed after 6 wk of treatment and a total dose of 75 mg of bleomycin[6].

Five years later, in 1995, Allen *et al*[7] reported a 61-year-old man with metastatic cancer from a bowel primary who "developed an asymptomatic eruption consisting of widespread reticulate erythema and pigmentation" one day after finishing a 48 h intravenous infusion of 680 mg (400 mg/m^2) of 5-fluorouracil. His next 5-fluorouracil treatment, three weeks later at half the dose, did not result in recurrence of the eruption. Neither the erythema nor the hyperpigmentation recurred during subsequent treatments at full dose and the hyperpigmentation gradually faded over a period of 16 wk[7].

A decade would pass before the next descriptions of chemotherapy-associated reticulate hyperpigmentation by Jogi *et al*[9]. The first patient reported by the investigators was a 63-year-old woman with mucoid epidermoid carcinoma of the parotic gland who was receiving concomitant chemoradiotherapy; three days into her third cycle, which consisted of carboplatin and 5-fluorouracil, she developed a reticulated erythematous

Table 1 Characteristics of patients with chemotherapy-induced reticulate hyperpigmentation

Case	Age (yr) Race Sex	Chemo	Onset (d)	OCF	Site	Histo	Cancer	Seq	Ref.
1	55 NR M	Adria Bleo[1] Cyclo MTX Vin	42	None	Arms Back Legs[2]	DM MBaK MSBaK EM[3]	NHL	Persists	6
2	61 Ca M	5-FU[1,4]	3	CAE	Back[2]	NR	GIT	Faded[5]	7
3	64 Ca M	Cyt[1] Ida[1] Lo	21	None	Back Butt	NR	AML	UK	8C5
4	74 Ca M	Cyclo Cyt[1] Dexa Ida[1] Vin	28	Mild Pru	Back Shdr	MBaK MPaD PI	ALL	Faded[6]	8C2
5	49 Ca W	Pac[1]	126	None	Back Thi	MBaK MPaD PI	BC	Faded[7]	8C1
6	51 NR W	Cyt[1] Ida[1]	> 28	None	Back (low)	NR	AML	NR	9C2
7	55 Ta W	Pac[1]	< 7	None	Abd Back Legs	DM MBaK PI	BC[8]	Faded[9]	CR
8	61 Ca W	Cyt[1] Top	28	None	Back Butt Thi	RCM[10]	AML	UK	8C4
9	63 NR W	Carbo 5-FU[1]	3[11]	PAE	Back Butt Thi	NR	MEC	NR	9C1
10	74 Ca W	Carbo Pac[1]	42	PAE Pru	Back	RCM[10]	OC	Faded[12]	8C3

[1]Suspected chemotherapeutic agent causing reticulate hyperpigmentation; [2]The hyperpigmentation was widespread; [3]Electron microscopy showed: (1) a normal number of melanocytes and (2) an increased number of melanosomes in keratinocytes; [4]Pigmentation occurred at 400 mg/m^3 (680 mg). It did not occur at 200 mg/m^3 (340 mg). The dose was increased to 400 mg/m^3 and there was no subsequent recurrence; [5]The hyperpigmentation faded over 16 wk; [6]The hyperpigmentation faded within 6 mo; [7]The hyperpigmentation faded within 3 mo; [8]The patient had mixed lobular and ductal breast cancer metastatic to bone, liver and lungs; [9]Paclitaxel was discontinued after her 7th weekly treatment. At follow-up 2 mo after stopping paclitaxel, the hyperpigmentation was completely faded on her abdomen and legs. There was also significant fading on her back and arms; [10]Reflectance confocal microscopy showed increased amount of melanin in basal keratinocytes; [11]Hyperpigmentation appeared 3 d after starting cycle 3 of chemotherapy; [12]Slight regression of the hyperpigmentation was observed. Abd: Abdomen; Adria: Adriamycin; ALL: Acute lymphoblastic leukemia; AML: Acute myelogenous leukemia; BC: Breast cancer (metastatic); Bleo: Bleomycin; Butt: Buttocks; Ca: Caucasian; CAE: Concurrent asymptomatic erythema; Carbo: Carboplatin; Chemo: Chemotherapy patient was being treated with; CR: Current report; Cyclo: Cyclophosphamide; Cyt: Cytarabine; Dexa: Dexamethasone; DM: Dermal (papillary) melanophages; EM: Electron microscopy; 5-FU: 5-fluorouracil; GIT: Gastrointestinal carcinoma (metastatic); Histo: Histopathology (hematoxylin and eosin or Fontana Masson or both); Ida: Idarubicin; Lo: Lomustine; Low: Lower; M: Man; MEC: Mucoid epidermoid carcinoma of the parotic gland; MBaK: Melanin increased in basal keratinocytes; MPaD: Melanin in papillary dermis; MSBaK: Melanin increased in suprabasal keratinocytes; MTX: Methotrexate; NHL: Non-Hodgkin lymphoma; NR: Not reported; OC: Ovarian cancer (metastatic); OCF: Other clinical features; Pac: Paclitaxel; PAE: Preexisting asymptomatic erythema; PI: Pigmentary incontinence into the papillary dermis; Pru: Pruritus; RCM: Reflectance confocal microscopy; Seq: Sequellae; Shdr: Shoulders; Symp: Symptoms; Ta: Taiwanese; Thi: Thighs; Top: Topoisomerase II inhibitor; UK: Unknown; Vin: Vincristine; W: Woman.

rash on her back and legs. The erythema eventually changed first to a violaceous and then to a brownish discoloration. During her fourth cycle she was noted to have a reticulated, hyperpigmented macular eruption on her back, posterior thighs, and popliteal fossa[9].

The second patient reported by Jogi *et al*[9] in 2005 was a 51-year-old woman with acute myelogenous leukemia. She had received induction chemotherapy with cytarabine and idarubicin. More than four weeks later, when she returned for a bone marrow biopsy, "she was found to have reticulated hyperpigmented patches on her lower back[9]".

More recently, after another decade, in 2015 Masson Regnault *et al*[8] described chemotherapy-related reticulated hyperpigmentation in five oncology patients. Their case series included two men with leukemia, and three women with breast cancer, leukemia, or ovarian carcinoma. The implicated antineoplastic agents-

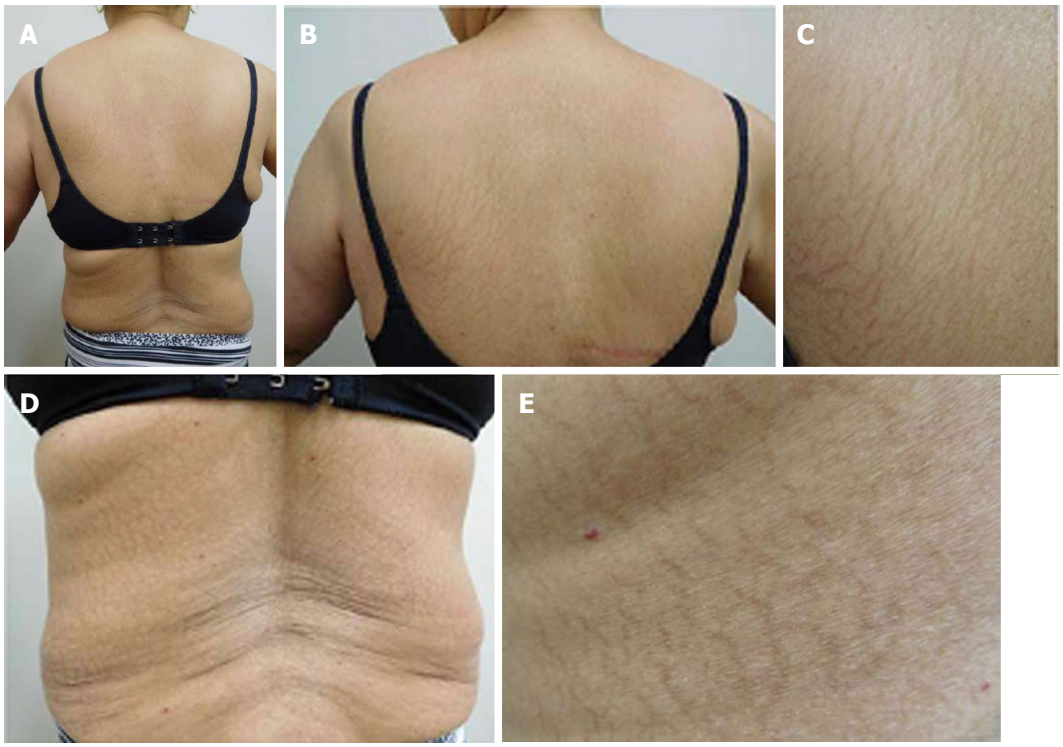

Figure 3 Paclitaxel-associated reticulate hyperpigmentation on the back. Distant (A) view of the back shows reticulate hyperpigmentation following treatment with paclitaxel. Intermediate (B and D) and closer (C and E) views of the upper (B and C) and lower (D and E) back show the linear and net-like hyperpigmentation.

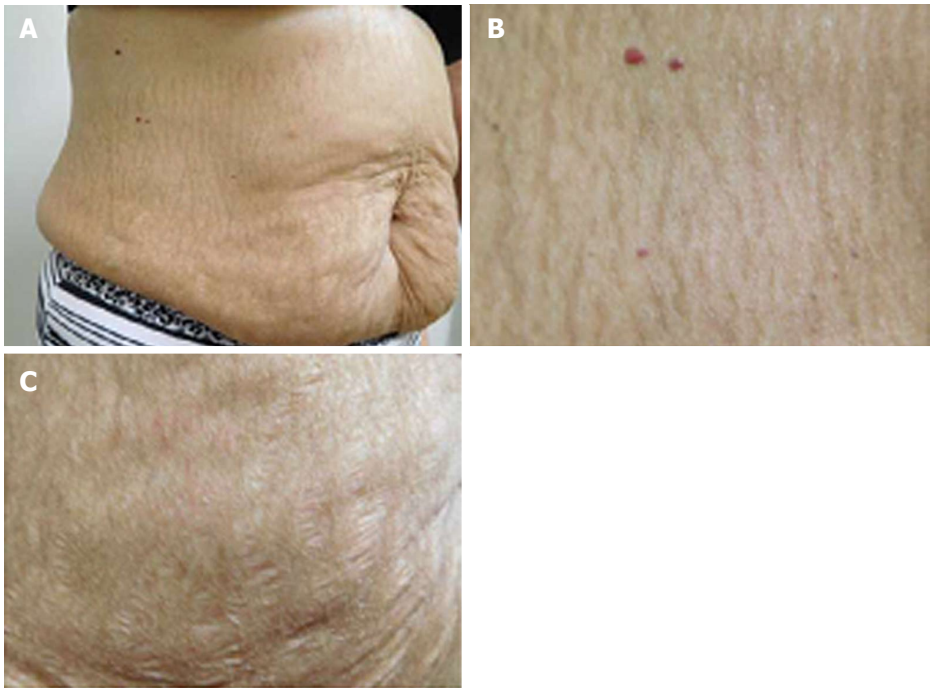

Figure 4 Paclitaxel-associated reticulate hyperpigmentation on the abdomen. Distant (A) and closer (B) views of paclitaxel-induced reticulate hyperpigmentation on the abdomen. The hyperpigmentation spares the stretch marks on the abdomen (C).

received either alone or concurrently-were cytarabine, idarubicin, and paclitaxel[8].

A reliable and valid method for estimating the probability of adverse drug reactions was established by Naranjo *et al*[10] in 1981. The current report describes a woman with metastatic breast cancer. In this patient, chemotherapy-associated reticulate hyperpigmentation developing as an adverse drug reaction induced by paclitaxel would be assigned to a definite probability category according to Naranjo *et al*[10]'s adverse drug

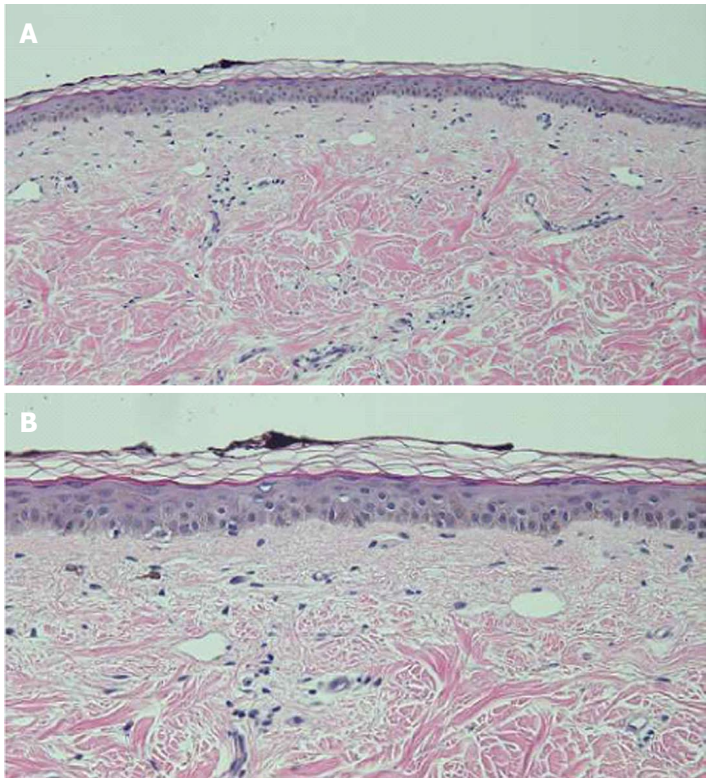

Figure 5 Distant (A) and closer (B) views of a hematoxylin and eosin stained biopsy specimen of the reticulate hyperpigmentation show confluent basilar hyperpigmentation with increased melanin in the basal layers of the epidermis. Melanin is also present in melanophages in the papillary dermis (hematoxylin and eosin; A: × 10; B: × 20).

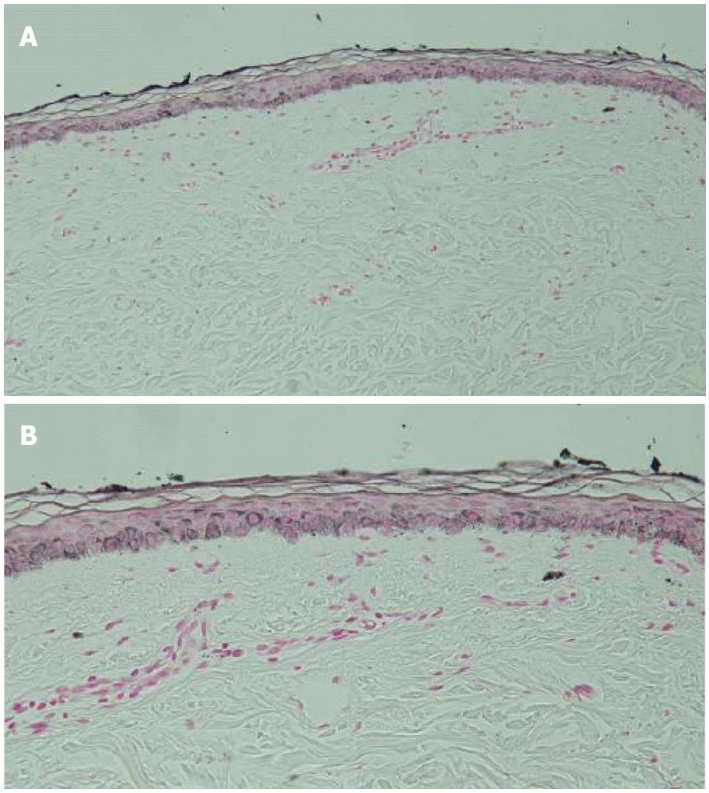

Figure 6 Distant (A) and closer (B) views of a Fontana-Masson stained biopsy specimen of the reticulate hyperpigmentation confirms the increased presence of melanin in the basal keratinocytes of the epidermis and within papillary dermis melanophages (Fontana-Masson; A: × 10; B: × 20).

reaction probability scale (Table 2).

In summary, four men and six women with chemotherapy-induced reticulate hyperpigmentation have been described; the oncology patients ranged from 49 years to 74 years (median = 61 years). The men ranged in age from 55 years to 74 years (median = 63 years). The women ranged in age from 49 years to 74 years (median = 58 years).

Most of the individuals were Caucasian (6/7, 86%). One woman was Taiwanese. The race was not provided for 3 individuals.

Reticulate hyperpigmentation occurred in five patients with hematopoietic malignancies and five individuals with solid tumors. Acute myelogenous leuke-

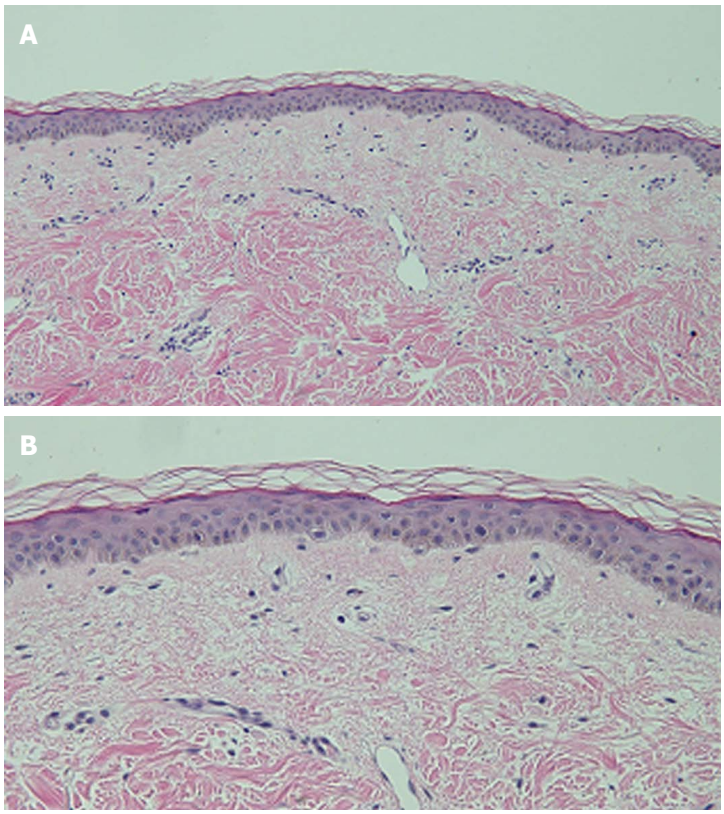

Figure 7 Distant (A) and closer (B) views of a hematoxylin and eosin stained biopsy specimen of normal appearing skin (adjacent to the hyperpigmentation) only shows minimal hyperpigmentation of the basal layer of the epidermis (hematoxylin and eosin; A: × 10; B: × 20).

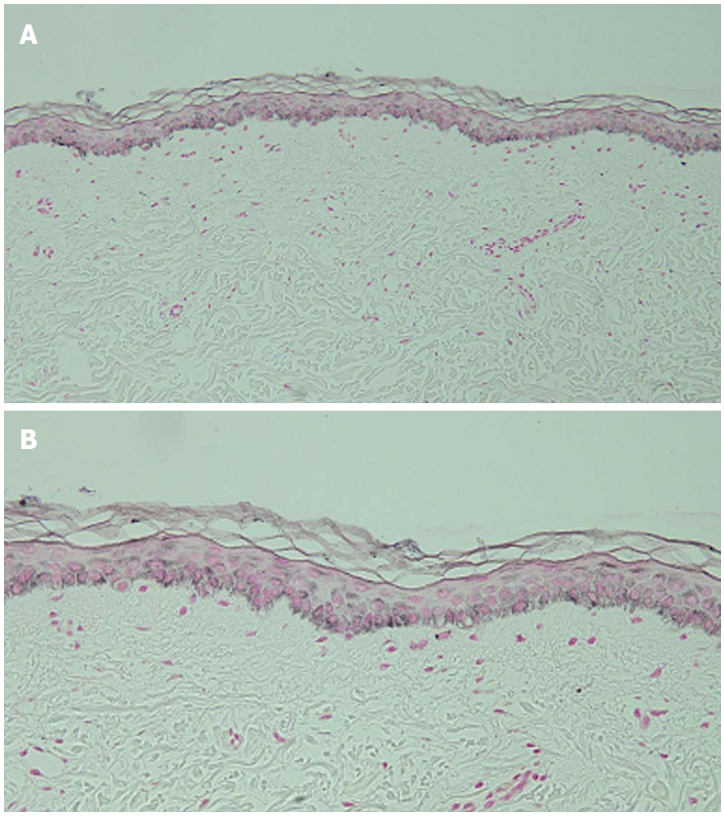

Figure 8 Distant (A) and closer (B) views of a Fontana-Masson stained biopsy specimen of normal appearing skin (adjacent to the hyperpigmentation) confirms the sparse presence of melanin in the epidermal basal layer and focally in the papillary dermis (Fontana-Masson; A: × 10; B: × 20).

mia was the most common cancer (3 patients); other lymphoproliferative disorders included acute lymphoblastic leukemia and non-Hodgkin lymphoma. Breast cancer was the underlying neoplasm in two women; other metastatic solid tumors, each in one patient, were gastrointestinal tract cancer, mucoid epidermoid carcinoma of the parotid gland, and ovarian carcinoma.

The patients were receiving between one (3 individuals, 30%) to five (2 individuals, 20%) antineoplastic agents. Four patients (40%) were receiving

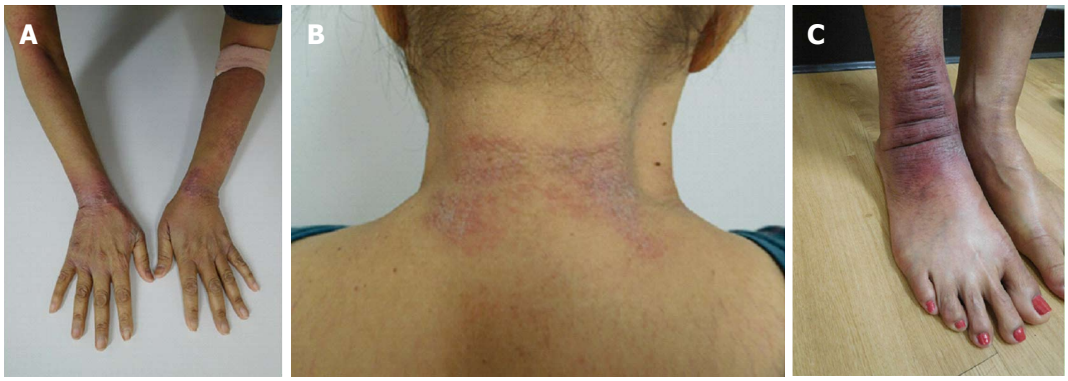

Figure 9 Paclitaxel-associated interface dermatitis presenting as tender and edematous red scaling plaques on the dorsal wrists (A), the posterior neck (B), and the right ankle (C).

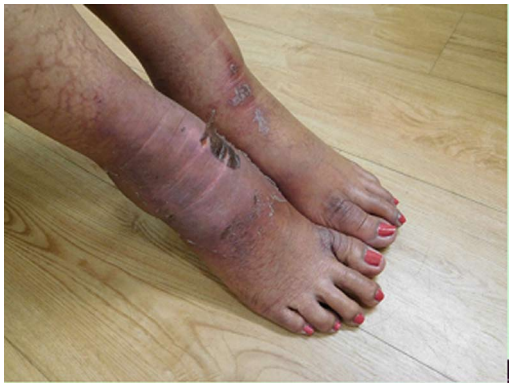

Figure 10 The paclitaxel-associated interface dermatitis lesion on the right ankle progressed in severity and distribution. A similar lesion also developed on the left ankle.

two drugs and one person (10%) was receiving three medications. For all individuals, either one agent (seven patients) or two drugs-cytoxan and idarubicin - (three patients) were considered to be the cause of the hyperpigmentation.

Reticulate hyperpigmentation was associated with Cytoxan-either alone (in one individual) or concurrent with idarubicin (in three patients). Paclitaxel was the causative agent in three women. Two patients' reticulate hyperpigmentation was related to 5-fluorouracil; bleomycin was the implicated drug in one man.

Paclitaxel is a taxane. It is derived from the bark of the Pacific yew tree (Taxus brevifolia). Paclitaxel acts by stabilizing microtubules; this action not only promotes the assembly of tubulin but also prevents the depolymerization of formed polymers. Subsequently, microtubule bundles accumulate and cell death occurs since cell division is interrupted[11-14].

Paclitaxel is used not only in the management of breast cancer, but also other cancers, such as lung and ovary[11-15]. Cutaneous adverse effects of paclitaxel (and nab-paclitaxel) include alopecia, erythema multiforme, hand-foot syndrome (acral erythema), hypersensitivity reaction, mucositis, nail changes, photosensitivity reactions, and subacute lupus erythematosus[15-22]. In addition to the woman with metastatic breast cancer described in this report, paclitaxel-induced reticulate hyperpigmentation occurred in another woman with metastatic breast cancer and a woman with metastatic ovarian cancer.

The onset of reticulate hyperpigmentation following initiation of the associated chemotherapy ranged from 3 d to 18 wk (median = 28 d). Both patients receiving 5-fluorouracil has the most rapid onset of hyperpigmentation. The appearance of hyperpigmentation in women receiving paclitaxel ranged from less than 7 d in the currently described patient to 126 d in another women with breast cancer; the third woman receiving paclitaxel for ovarian cancer developed hyperpigmentation after 6 wk of treatment.

Associated pruritus or erythema or both were described in 40% (4/10 patients) of the individuals with chemotherapy-induced reticulate hyperpigmentation. Asymptomatic erythema was noted in two patients who had received 5-fluorouracil (one man and one woman) and one woman who had been treated with paclitaxel; the paclitaxel treated woman also had pruritus. Another man who was treated with cytarabine and idarubicin also had mild pruritus.

Chemotherapy-related reticulate hyperpigmentation appears as brown colored macular hyperpigmentation without scaling or other epidermal change that is linear, lacy and/or net-like. It was located on the back of all 10 patients. It was also present on the legs (5 patients), the buttocks (3 patients), the shoulders (2 patients) and the abdomen (1 patient). In the reported patient, the hyperpigmentation was not only on her back, but also on her anterior thighs and abdomen; the pigmentation on her abdomen spared her striae.

Microscopic examination was performed in only four patients[6,8]. Common histologic features in all of these individuals included increased melanin in the basal layer of the epidermis and melanophages in the papillary dermis. Increased melanin in the suprabasilar keratinocytes was observed in one patient[6], and melanin pigment incontinence into the upper dermis was noted in three patients[8]. These pathologic changes are similar to those that have been observed in patients with pigment changes from other chemotherapies[8].

Table 2 Adverse drug reaction probability scale[1,2,3,4]

Question	PA	PS
Are there previous conclusive reports on this reaction? Answer score: Yes = +1; No = 0	Yes	1
Did the adverse event appear after the suspected drug was administered? Answer score: Yes = +2; No = -1	Yes	2
Did the adverse reaction improve when the drug was discontinued or a specific antagonist was administered? Answer score: Yes = +1; No = 0	Yes	1
Did the adverse reaction reappear when the drug was readministered? Answer score: Yes = +2; No = -1	Yes	2
Are there alternative causes (other than the drug) that could on their own have caused the reaction? Answer score: Yes = -1; No = +2	No	2
Did the reaction reappear when a placebo was given? Answer score: Yes = -1; No = +1	DNK	0
Was the drug detected in the blood (or other fluids) in concentrations known to be toxic? Answer score: Yes = +1; No = 0	DNK	0
Was the reaction more severe when the dose was increased, or less severe when the dose was decreased? Answer score: Yes = +1; No = 0	DNK	0
Did the patient have a similar reaction to the same or similar drugs in any previous exposure? Answer score: Yes = +1; No = 0	DNK	0
Was the adverse event confirmed by any objective evidence? Answer score: Yes = +1; No = 0	Yes	1
Total score		9

[1]An answer is provided for all questions (PA) and a determination of score is provided (PS) to assess the adverse drug reaction; [2]An answer of "Do not know" = 0 score; [3]From the total score, the adverse drug reaction is assigned a probability category: Definite (greater than or equal to 9), probable (5 to 8), possible (1 to 4), doubtful (less than or equal to 0); [4]Drug = paclitaxel. DNK: Do not know; PA: Patient answer; PS: Patient score.

Dermoscopy analysis was conducted in a 61-year-old woman with acute myelogenous leukemia. Her reticulate hyperpigmentation appeared 4 wk after treatment with cytarabine and a topoisomerase Ⅱ inhibitor and showed a hyperpigmented reticulate network; reflectance confocal microscopy of the lesions demonstrated an increased amount of pigment in the basal layer of the epidermis[8]. Reflectance confocal microscopy was also performed in a 74-year-old woman with ovarian carcinoma; 6 wk after receiving paclitaxel and carboplatin, her hyperpigmentation appeared and showed increased content of melanin in basal keratinocytes[8].

Electron microscopy studies were performed in one patient-the 55-year-old man with non-Hodgkin lymphoma who received not only bleomycin, but also adriamycin, cyclophosphamide, methotrexate and vincristine. His reticulate hyperpigmentation showed both a marked increase of singly arranged melanosomes in the basal keratinocytes and lipid vacuoles (along with damage to subcellular organelles) in not only the basal keratinocytes but also the melanocytes. In the upper papillary dermis, melanosomal complexes were found in endothelial cells and macrophages[6].

The pathogenesis of chemotherapy-induced reticulate hyperpigmentation remains to be established. All of the previous investigators-based on dermoscopy, confocal reflectance microscopy, pathology, and electron microscopy findings-hypothesize that the hyperpigmentation results from a secondary increase in melanogenesis caused by a direct toxic effect of the chemotherapy on the melanocytes[6-9]. Masson Regnault *et al*[8] also suggest that, in susceptible individuals, local changes in blood flow may partially account for the lesions being located in areas of contact, such as the back and buttocks.

The reticulate hyperpigmentation persisted while the patients continued to receive the associated antineoplastic agent. Subsequent follow-up was provided for 6 individuals. The hyperpigmentation partially or completed resolved in 83% (5/6) of the patients after the chemotherapy has been discontinued. Fading occurred within 2 to 6 mo.

Chemotherapy-induced reticulate hyperpigmentation is a cutaneous reaction that has been described in ten individuals: Four men and six women. The patients were being treated for hematologic malignancies [acute myelogenous leukemia (3 patients), acute lymphoblastic leukemia (1 patient) and non-Hodgkins lymphoma (1 patient)] or solid tumors [breast cancer (2 patients), gastrointestinal carcinoma (1 patient) mucoid epidermal carcinoma of the parotid gland (1 patient) and ovarian cancer (1 patient)]. Cytoxan [alone (1 patient) or concurrent with idarubicin (3 patients)] was the most commonly associated drug. Other causative antineoplastic agents included paclitaxel (3 patients), 5-fluorouracil (2 patients) and bleomycin (1 patient). The skin lesions were asymptomatic in most of the oncology patients; pruritus, erythema, or both were noted in four individuals. The linear macular hyperpigmention was lacy, net-like, or both. It appeared on the back of all patients; other sites included the legs (5 patients), buttocks (3 patients), shoulders (2 patients) and abdomen (1 patient). The hyperpigmentation appeared within 3 d to 18 wk after starting the drug and faded within 2 to 6 mo after stopping the medication. Chemotherapy-induced reticulate hyperpigmentation

does not require dose reduction or discontinuation of the associated antineoplastic treatment.

COMMENTS

Case characteristics

A woman with metastatic breast cancer developed a new asymptomatic rash on her abdomen, back and legs after beginning intravenous weekly therapy with paclitaxel.

Clinical diagnosis

The patient's paclitaxel-induced reticulate hyperpigmentation presented as dark brown linear and net-like hyperpigmentation on the extensor arms and legs, on the back, and on the abdomen with sparing of the abdominal striae.

Differential diagnosis

The clinical differential diagnosis of the patient's chemotherapy-induced reticulate hyperpigmentation includes cutis marmorata, erythema ab igne, livedo reticularis, and vasculitis.

Laboratory diagnosis

Laboratory studies - including complete blood cell counts with platelets and serum chemistries - were normal.

Imaging diagnosis

Imaging studies - including computerized axial tomography scans and positron emission tomography scans - confirmed the presence of metastatic breast cancer in the patient's lungs and bones.

Pathological diagnosis

Hematoxylin and eosin stained sections of a biopsy from the hyperpigmented skin showed deposits of melanin within the basal layer of the epidermis in addition to incontinence of melanin pigment and melanophages in the upper dermis; Fontana-Masson stained sections confirmed the presence of melanin at these locations.

Treatment

The patient's chemotherapy-induced reticulate hyperpigmentation had either completely (on her abdomen and legs) or significantly (on her back and arms) faded by 2 mo after stopping the paclitaxel.

Related reports

Chemotherapy-induced reticulate hyperpigmentation has been described in four men and six women. Five patients had hematopoietic malignancies and five individuals had solid tumors. Reticulate hyperpigmentation was associated with Cytoxan-either alone or concurrent with idarubicin, paclitaxel, 5-fluorouracil or bleomycin.

Term explanation

Reticulate hyperpigmentation refers to the pattern of linear and flat darkening of the skin being either net-like or lacy or both.

Experiences and lessons

Chemotherapy-induced reticulate hyperpigmentation is a morphologically distinctive and clinically benign cutaneous reaction to various antineoplastic agents in oncology patients with either hematologic malignancies or solid tumors that does not require dose reduction or discontinuation of the associated antineoplastic treatment and typically resolves or fades spontaneously within 2 to 6 mo after stopping the medication.

Peer-review

This manuscript reported a case pigmentation after treatment with paclitaxel. The author also reviewed the literature on this phenotype, and provided some pathological examination of the pigmentation area. The manuscript is well written and is worthy of publication.

REFERENCES

1 **Sardana K**, Goel K, Chugh S. Reticulate pigmentary disorders. *Indian J Dermatol Venereol Leprol* 2013; **79**: 17-29 [PMID: 23254725 DOI: 10.4103/0378-6323.104665]

2 **Zhang X**, Khimji I, Gurkan UA, Safaee H, Catalano PN, Keles HO, Kayaalp E, Demirci U. Lensless imaging for simultaneous microfluidic sperm monitoring and sorting. *Lab Chip* 2011; **11**: 2535-2540 [PMID: 21677993 DOI: 10.1111/j.1365-2230.2011.04100.x]

3 **Weinberg JM**, Moss T, Gupta SM, White SM, Don PC. Reticulate hyperpigmentation of the skin after topical application of benzoyl peroxide. *Acta Derm Venereol* 1998; **78**: 301-302 [PMID: 9689304 DOI: 10.1080/000155598441954]

4 **Jaka A**, López-Pestaña A, Tuneu A, Lobo C, López-Núñez M, Ormaechea N. Letter: Photodistributed reticulated hyperpigmentation related to diltiazem. *Dermatol Online J* 2011; **17**: 14 [PMID: 21810399]

5 **Patel AN**, Perkins W, Ravenscroft A, Varma S. Extraordinary reticulate hyperpigmentation occurring after Bier block. *Clin Exp Dermatol* 2013; **38**: 94-95 [PMID: 22831778 DOI: 10.1111/j.1365-2230.2012.04431.x]

6 **Wright AL**, Bleehen SS, Champion AE. Reticulate pigmentation due to bleomycin: light- and electron-microscopic studies. *Dermatologica* 1990; **180**: 255-257 [PMID: 1694148 DOI: 10.1159/000248042]

7 **Allen BJ**, Parker D, Wright AL. Reticulate pigmentation due to 5-fluorouracil. *Int J Dermatol* 1995; **34**: 219-220 [PMID: 7538496 DOI: 10.1111/j.1365-4362.1995.tb01579.x]

8 **Masson Regnault M**, Gadaud N, Boulinguez S, Tournier E, Lamant L, Gladieff L, Roche H, Guenounou S, Recher C, Sibaud V. Chemotherapy-Related Reticulate Hyperpigmentation: A Case Series and Review of the Literature. *Dermatology* 2015; **231**: 312-318 [PMID: 26422424 DOI: 10.1159/000439047]

9 **Jogi R**, Garman M, Pielop J, Orengo I, Hsu S. Reticulate Hyperpigmentation secondary to 5-fluorouracil and idarubicin. *J Drugs Dermatol* 2005; **4**: 652-656 [PMID: 16167426]

10 **Naranjo CA**, Busto U, Sellers EM, Sandor P, Ruiz I, Roberts EA, Janecek E, Domecq C, Greenblatt DJ. A method for estimating the probability of adverse drug reactions. *Clin Pharmacol Ther* 1981; **30**: 239-245 [PMID: 7249508 DOI: 10.1038/cipt.1981.154]

11 **Bachegowda LS**, Makower DF, Sparano JA. Taxanes: impact on breast cancer therapy. *Anticancer Drugs* 2014; **25**: 512-521 [PMID: 24552749 DOI: 10.1097/CAD.0000000000000090]

12 **Binder S**. Evolution of taxanes in the treatment of metastatic breast cancer. *Clin J Oncol Nurs* 2013; **17** Suppl: 9-14 [PMID: 23360698 DOI: 10.1188/13.CJON.S1.9-14]

13 **Gradishar WJ**. Taxanes for the treatment of metastatic breast cancer. *Breast Cancer* (Auckl) 2012; **6**: 159-171 [PMID: 23133315 DOI: 10.4137/BCBCR.S8205]

14 **Pazdur R**, Kudelka AP, Kavanagh JJ, Cohen PR, Raber MN. The taxoids: paclitaxel (Taxol) and docetaxel (Taxotere). *Cancer Treat Rev* 1993; **19**: 351-386 [PMID: 8106152 DOI: 10.1016/0305-7372(93)90010-O]

15 **Donati A**, Castro LG. Cutaneous adverse reactions to chemotherapy with taxanes: the dermatologist's point of view. *An Bras Dermatol* 2011; **86**: 755-758 [PMID: 21987144 DOI: 10.1590/S0365-05962011000400020]

16 **Payne AS**, James WD, Weiss RB. Dermatologic toxicity of chemotherapeutic agents. *Semin Oncol* 2006; **33**: 86-97 [PMID: 16473647 DOI: 10.1053/j.seminoncol.2005.11.004]

17 **Reyes-Habito CM**, Roh EK. Cutaneous reactions to chemotherapeutic drugs and targeted therapies for cancer: part I. Conventional chemotherapeutic drugs. *J Am Acad Dermatol* 2014; **71**: 203.e1-203.e12; quiz 215-216 [PMID: 25037800 DOI: 10.1016/j.jaad.2014.04.014]

18 **Heidary N**, Naik H, Burgin S. Chemotherapeutic agents and the skin: An update. *J Am Acad Dermatol* 2008; **58**: 545-570 [PMID: 18342708 DOI: 10.1016/j.jaad.2008.01.001]

19 **Payne JY**, Holmes F, Cohen PR, Gagel R, Buzdar A, Dhingra K. Paclitaxel: severe mucocutaneous toxicity in a patient with

hyperbilirubinemia. *South Med J* 1996; **89**: 542-545 [PMID: 8638189 DOI: 10.1097/00007611-199605000-00022]

20 **Cohen PR**. Photodistributed erythema multiforme: paclitaxel-related, photosensitive conditions in patients with cancer. *J Drugs Dermatol* 2009; **8**: 61-64 [PMID: 19180897]

21 **Paul LJ**, Cohen PR. Paclitaxel-associated subungual pyogenic granuloma: report in a patient with breast cancer receiving paclitaxel and review of drug-induced pyogenic granulomas adjacent to and beneath the nail. *J Drugs Dermatol* 2012; **11**: 262-268 [PMID: 22270214]

22 **Beutler BD**, Cohen PR. Nab-paclitaxel-associated photosensitivity: report in a woman with non-small cell lung cancer and review of taxane-related photodermatoses. *Dermatol Pract Concept* 2015; **5**: 121-124 [PMID: 26114068 DOI: 10.5826/dpc.0502a24]

P- Reviewer: Fang BL, Higa GM, Hakenberg OW, Sugawara I, Shimoyama S, Takahashi T **S- Editor**: Ji FF **L- Editor**: A **E- Editor**: Wu HL

World Journal of Clinical Cases

Submit a Manuscript: http://www.wjgnet.com/esps/
Help Desk: http://www.wjgnet.com/esps/helpdesk.aspx
DOI: 10.12998/wjcc.v4.i12.401

World J Clin Cases 2016 December 16; 4(12): 401-408
ISSN 2307-8960 (online)

CASE REPORT

Rare case of tibial hemimelia, preaxial polydactyly, and club foot

Guinevere Granite, John E Herzenberg, Ronald Wade

Guinevere Granite, Department of Anatomy and Neurobiology, School of Medicine, University of Maryland, Baltimore, MD 21201, United States

John E Herzenberg, Rubin Institute for Advanced Orthopedics, Sinai Hospital of Baltimore, Baltimore, MD 21215, United States

Ronald Wade, Department of Anatomical Services, University of Maryland, Baltimore, MD 21201, United States

Author contributions: Granite G acquired the specimen data, analyzed and interpreted the data, drafted the article, and made critical revisions related to important intellectual manuscript content; Herzenberg JE provided case material for analysis and made the final approval of the version of the article to be published; Wade R acquired the case material and specimen for article.

Institutional review board statement: The study did not need to be reviewed and approved by the University of Maryland, Baltimore Institutional Review Board because the case did not involve a living human being but a specimen from one that had been donated by the family for research purposes.

Informed consent statement: We have obtained the parent of the patients' written informed consent for print and electronic publication of the report, as well as for reprinting in foreign editions of the journal.

Conflict-of-interest statement: The authors certify that they have no affiliations with or involvement in any organization or entity with any financial interest (such as honoria; education grants; participation in speakers' bureaus; membership, employment, consultancies, stock ownership, or other equity interest; and expert testimony or patent-licensing arrangements), or non-financial interest (such as personal or professional relationships, affiliations, knowledge or beliefs) in the subject matter or materials discussed in this manuscript. The authors declare that there is no conflict of interest regarding the publication of this article.

Manuscript source: Invited manuscript

Correspondence to: Guinevere Granite, PhD, Adjunct Professor, Department of Anatomy and Neurobiology, School of Medicine, University of Maryland, 655 West Baltimore Street, Baltimore, MD 21201,
United States. guin.granite@gmail.com
Telephone: +1-301-3957147
Fax: +1-410-7062512

Received: May 2, 2016
Peer-review started: May 6, 2016
First decision: July 25, 2016
Revised: August 5, 2016
Accepted: September 21, 2016
Article in press: September 22, 2016
Published online: December 16, 2016

Abstract

A seven-month old female presented with left tibial hemimelia (or congenital tibial aplasia; Weber type VIIb, Jones *et al* type 1a), seven-toed preaxial polydactyly, and severe club foot (congenital talipes equinovarus). Definitive amputation surgery disarticulated the lower limb at the knee. This case report describes the anatomical findings of a systematic post-amputation examination of the lower limb's superficial dissection, X-rays, and computed tomography (CT) scans. From the X-rays and CT scans, we found curved and overlapping preaxial supernumerary toes, hypoplastic first metatarsal, lack of middle and distal phalanges in one supernumerary toe, three tarsal bones, hypoplastic middle phalanx and no distal phalanx for fourth toe, and

no middle or distal phalanges for fifth toe. The fibula articulated with the anteromedial calcaneus and the tibia was completely absent. We identified numerous muscles and nerves in the superficial dissection that are described in the results section of the case report. Due to the rarity of this combination of anatomical findings, descriptions of such cases are very infrequent in the literature.

Key words: Club foot; Congenital talipes equinovarus; Preaxial polydactyly; Tibial hemimelia; Congenital tibial aplasia

Core tip: This case report analyzes the anatomical findings associated with systematic post-surgical examination of the amputated lower leg of a seven-month old female presenting with a very rare combination of lower limb malformations. These include left tibial hemimelia (or congenital tibial aplasia; Weber type VIIb, Jones *et al* type 1a), seven-toed preaxial polydactyly, and severe club foot (congenital talipes equinovarus). This case report describes the results of the amputated limb's superficial dissection, X-rays, and computed tomography scans. Due to the rarity of this combination of anatomical findings, descriptions of such cases are very infrequent in the literature.

Granite G, Herzenberg JE, Wade R. Rare case of tibial hemimelia, preaxial polydactyly, and club foot. *World J Clin Cases* 2016; 4(12): 401-408 Available from: URL: http://www.wjgnet.com/2307-8960/full/v4/i12/401.htm DOI: http://dx.doi.org/10.12998/wjcc.v4.i12.401

INTRODUCTION

Tibial hemimelia (TH), also known as congenital tibial aplasia, is a rare congenital anomaly characterized by deficiency of the tibia with a relatively intact fibula[1-4]. The incidence of TH in the United States is approximately one in 1000000 live births[1-3]. It is further subdivided into different types, making each subtype even rarer.

TH can occur as an isolated hereditary malformation as well as a feature of several autosomal recessive and autosomal dominant syndromes, involving accompanying congenital defects[2,4,5]. Weber[3] has created the most detailed classification system for tibial malformations to date, classifying and scoring the main pathological findings of the complete leg, which include coxa, femur, patella, tibia, fibula, and pes. Potential causes of TH include errors in several different aspects of limb development[5]. Other known causes of TH are ingestion of thalidomide or inheritance of an autosomal dominant gene; more sporadic cases are idiopathic[6].

Polydactyly is a common congenital hand and/or foot anomaly that is characterized by the presence of supernumerary digits[7]. This condition has an incidence rate of 1.7 per 1000 births. It may be isolated or associated with established genetic syndromes[7,8]. Several morphologic classification types for polydactyly exist, including those based on metatarsal variations with duplicated distal phalangeal segments[7,9], those expanding the two preaxial types to four[7,10], and those that add mirror foot or diplopodia[7,11].

Club foot or congenital talipes equinovarus (CTEV) is a complex, fixed deformity of the lower limb that is always present at birth and can be unilateral or bilateral[12] CTEV is a multiplanar deformity of the lower leg with a prevalence of one to three per 1000 live births[13,14]. It is twice as common in males and at least half the cases are bilateral[14-16].

There are three basic components of CTEV: Equinus, varus, and adduction deformities[14]. The severity of the club foot deformity is classified according to the Pirani scoring system[17]. There are three classifications of CTEV: Postural, idiopathic, and teratogenic or syndromic[15,16]. The cause of CTEV is unknown[14,16,18,19], although there is a clear multifactorial inheritance pattern with many potential environmental influences[16], including amniotic injury or hemorrhage, and positioning *in utero*[14], and retracting fibrosis[18].

Although each of the aforementioned syndromes is relatively rare, comorbidity of all three of these disorders is even rarer, if not unique. This case report discusses the anatomical findings associated with a 7-mo old female presenting with all three of these conditions occurring simultaneously.

CASE REPORT

A seven-month old female presented with TH, seven-toed preaxial polydactyly and severe left CTEV. There was also medial contracture of the left foot and lower leg with left congenital hip dysplasia. In addition to having no left tibia, she also did not have a left patella or an active quadriceps mechanism. The left fibula was bowed and articulated with the lateral side of the femur. Due to the severity of the deformity, and the unlikelihood of a successful limb salvage procedure, amputation was advised.

Definitive amputation surgery was performed; the amputation involved a left knee disarticulation of the lower limb. During the surgery, the musculature of the anterior, lateral, and posterior compartments of the left lower leg was transected to provide coverage to the stump. This made post-mortem identification of muscles and vessels that were present prior to surgery challenging. The operative report described the presence of the posterior tibial nerve and deep peroneal nerve with the absence of a posterior tibial artery.

The family of the child elected to donate the amputated specimen to the Maryland State Anatomy

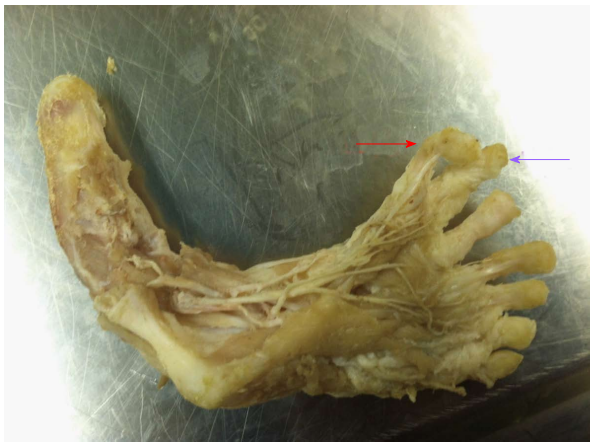

Figure 1 Post-amputation superficial dissection demonstrating complete fibula, and supernumerary toes with toe A (purple arrow) and toe B (red arrow), with toe A being closest to the hallux.

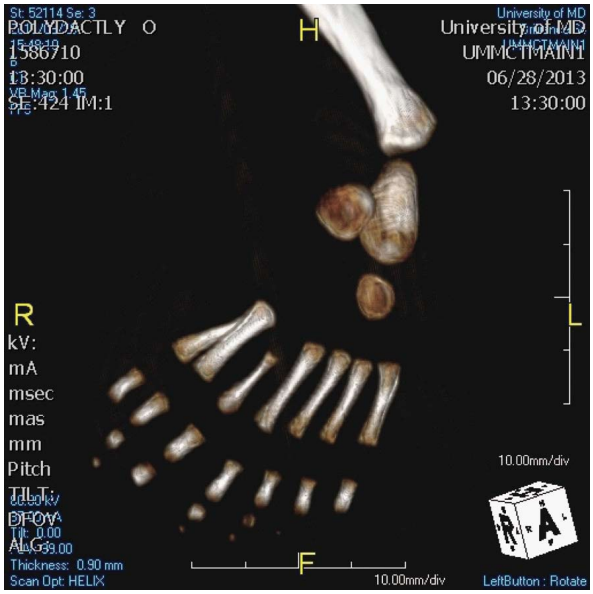

Figure 2 Computed tomography scan demonstrating skeletal characteristics with regard to the fibula, tarsal bones, metatarsals, and phalanges.

Board and releases were obtained. A post-amputation superficial dissection on the amputated lower limb of the child was followed by X-rays and CT scans. A detailed superficial dissection was conducted to identify any and all anatomical structures present.

For description purposes, the supernumerary toes were identified as toe A and toe B, with toe A being closest to the hallux (Figure 1). Using the Weber method, the child's TH condition can be classified as type VIIb, class 4 (total points 8)[3]. Using the classification of Jones *et al*[20], this child's TH condition can be classified as type 1a[2]. Using Venn-Watson and Watanabe method, the polydactyly exhibited can be categorized as a complete medial ray duplication with a hypoplastic medial member[7,9,21].

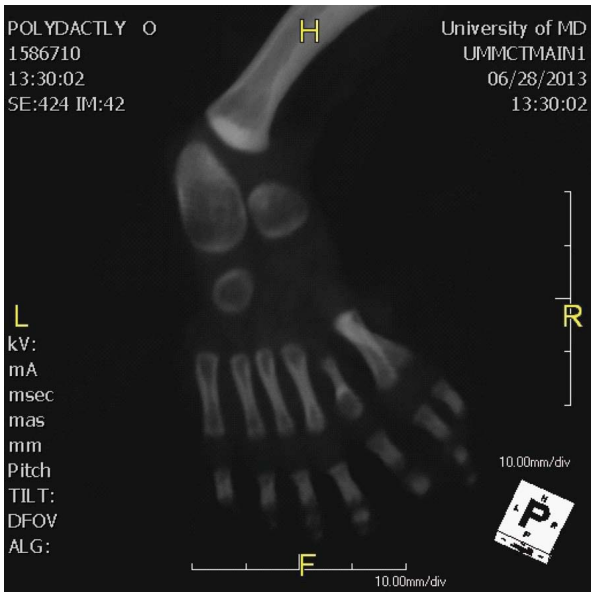

Figure 3 Plain radiograph showing skeletal characteristics with regard to the fibula, tarsal bones, metatarsals, and phalanges.

From studying the plain X-rays and CT scans, we found the following skeletal characteristics with regard to the fibula, tarsal bones, metatarsals and foot phalanges: Curved and overlapping supernumerary toes, hypoplastic first metatarsal, lack of middle and distal phalanges in toe B, only three tarsal bones present: Calcaneus, talus, and navicular, no distal phalanx for fourth toe, hypoplastic middle phalanx for 4th toe, and no middle or distal phalanges for fifth toe. The fibula articulated with the anteromedial portion of the calcaneus (Figures 2 and 3).

The extensor muscles visible after superficial dissection of the lower leg and foot include peroneus longus, peroneus brevis, and peroneus tertius. Extensor digitorum longus is present with its tendons connecting to between toes one and two, and three through five. The extensor digitorum brevis is also present with its tendons connecting to toes two through five, and extensor hallicus longus with its tendon connecting to toe A and not the hallux (Figure 4).

The flexor muscles visible include a portion of the gastrocnemius that is attached to the Achilles tendon. The Achilles tendon itself appears to be attached to the medial side of the calcaneus. Flexor digitorum brevis appears to connect with toes A and B then toes two through four. The flexor hallicus longus tendon does not appear to be present. These two characteristics may contribute to the hyperextensability of the hallux on manipulation. We were unable to find the tendons of flexor digitorum longus, the muscle bellies of quadratus plantae, or the muscle belly of flexor hallicus brevis. Due to transection during surgery, we cannot identify tibialis anterior as being present. The tendon to tibialis posterior is visible running alongside the medial plantar nerve and deep to the flexor digitorum brevis muscle.

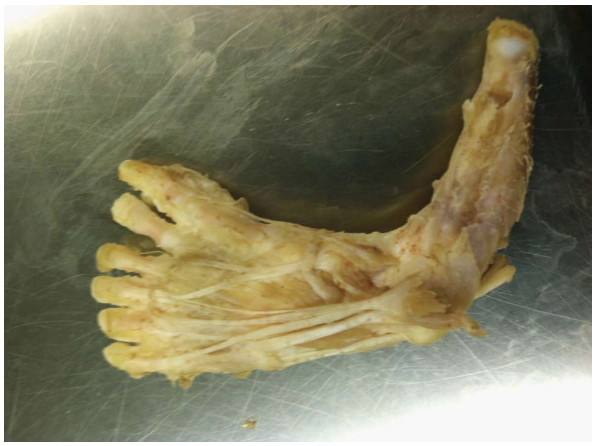

Figure 4 Superficial dissection demonstrating extensor muscles visible in the lower leg and foot.

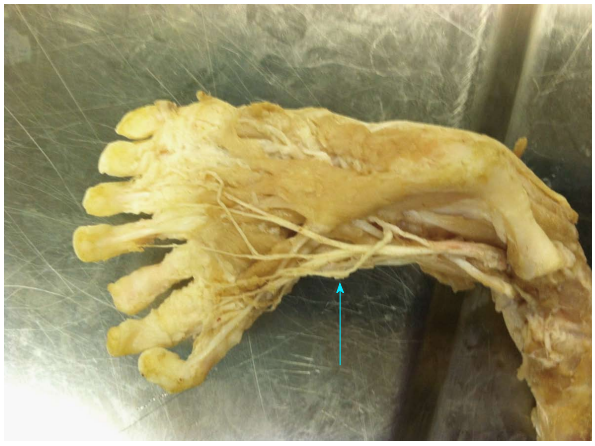

Figure 5 Superficial dissection demonstrating flexor muscles visible in the lower leg and foot, and nerves showing a supernumerary branch of the lateral plantar nerve connecting to toe A (light blue arrow).

The transverse and oblique heads of the adductor hallicus muscle appear to span the supernumerary toes and hallux. In addition, the following muscles appear to be present: Abductor hallicus, flexor digiti minimi, abductor digiti minimi. Lumbricals appear to be present and there is a possible supernumerary lumbrical connecting with toe A and/or B. From this superficial dissection, none of the interossei is visible (Figure 5).

Nerves visible include posterior tibial, medial and lateral plantar nerves, with lateral plantar nerve having a supernumerary branch to Toe A while Toe B has a medial plantar nerve branch (Figure 5). Deep peroneal nerve is not visible within the superficial dissection but is apparently present as stated in operative report. Superficial peroneal nerve is not visible and is not mentioned in the operative report.

The vessels visible upon dissection are the components of the superficial venous arch (Figure 6). We have also identified a structure that could be dorsalis pedis due to the following characteristics: It penetrates into the deep compartment of the foot and it has a lumen with a relatively thick wall suggestive of an artery (Figure 7). We cannot determine if the deep venous arch is present from the superficial dissection. Posterior tibial artery is not visible and is also specifically described as absent in the operative report.

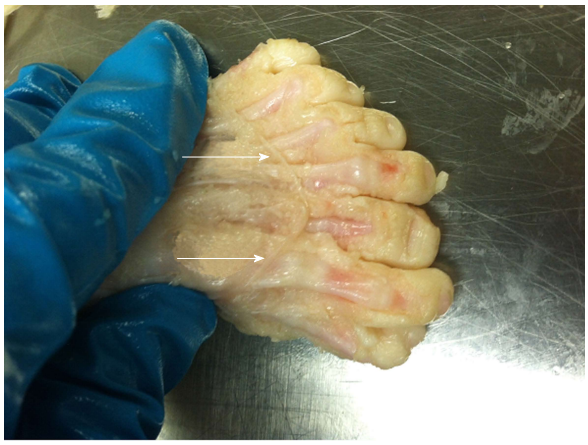

Figure 6 Superficial venous arch visible upon initial superficial dissection (white arrows).

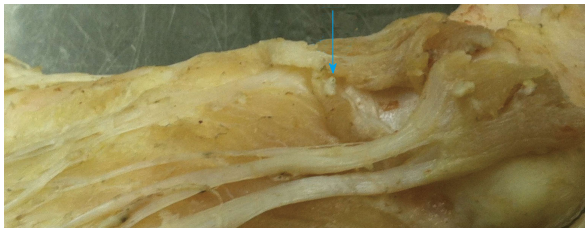

Figure 7 Dorsalis pedis artery penetrating into the deep compartment of the foot (blue arrow).

DISCUSSION

TH, also known as congenital tibial aplasia, is a rare congenital anomaly characterized by variable degrees of deficiency of the tibia with a relatively intact fibula[1-6]. The incidence of TH in the United States is approximately one in 1000000 live births[1-3]. Children born with this abnormality usually exhibit marked shortening and bowing of the involved leg. There is also pronounced flexion contracture and instability of the knee, variable leg rotation, and marked inversion and adduction of the foot[1,2]. The first metatarsal is usually hypoplastic or markedly shortened and frequently associated with other medial ray defects and/or preaxial polydactyly[1,11].

TH can occur as an isolated hereditary malformation as well as a feature of several autosomal recessive and autosomal dominant syndromes[4,5]. Seventy-five percent of patients who have TH have accompanying congenital defects. These can include congenital hip dislocation, polydactyly, medial foot defects, severe club foot, bifurcated femur, central hand defects, cleft palate, spinal anomalies, and a wide range of congenital

anomalies of the cardiovascular, gastrointestinal, and genitourinary systems[2,4].

Weber[3] has created the most detailed classification system for tibial malformations to date. He classified and scored the main pathological findings of the entire leg, which include coxa, femur, patella, tibia, fibula, and pes. Tibial malformations are divided into seven main groups and five of them are divided further into two subgroups. The seven main groups are: Type-Ⅰ, hypoplasia; type-Ⅱ, diastasis; type-Ⅲ, distal aplasia; type-Ⅳ, proximal aplasia; type-Ⅴ, bifocal aplasia; type-Ⅵ, agenesia with double fibula; type-Ⅶ, agenesia with a single fibula. The subgroup for types Ⅲ through Ⅶ are a (with cartilaginous anlage), and b (without cartilaginous anlage). Three types of muscle function are described as +, present; (+), partly present; and -, absent for the coxa, femur, and tibia. Scoring of the various types ranges from zero to 39; the higher the score, the less the impairment grade[3].

There is an older TH classification system described by Jones *et al*[2,20]. In type 1a, the tibia is completely absent and the distal end of the femur is hypoplastic. In type 1b, a rudimentary tibia articulates with the distal end of a relatively normal femur. In type 2, the proximal end of the tibia is well developed and the distal end of the tibia is absent. In type 3, the tibia is represented by a characteristically amorphous bone segment that can be present more distally than proximally. In type 4, the proximal end of the tibia is normal with a shortened distal end and a characteristic congenital diastasis of the ankle joint[2].

Potential causes of TH include errors in several different aspects of limb development. Cells from the primitive streak have been shown to migrate to the lateral plate mesoderm. Such an abnormality of this process could affect the limb bud which forms from the mesenchyme cells in the lateral plate mesoderm[5]. Other known causes of TH are ingestion of thalidomide or inheritance of an autosomal dominant gene; more sporadic cases are idiopathic[6].

Polydactyly is a common congenital hand and/or foot anomaly that is characterized by the presence of supernumerary digits. It is classified as preaxial, central, or postaxial depending on the location of the duplication. Approximately 15% of all toe duplications are preaxial at the first ray, about 79% of duplications are postaxial and involve the lateral-most rays of the foot, and the remaining 6% are central including the second through fourth rays[7]. This condition has an incidence rate of 1.7 per 1000 births. It may be isolated or associated with established genetic syndromes. If polydactyly is non-syndromic, 30% of patients have a positive family history, which is most often expressed as autosomal-dominant inheritance with variable penetrance. No sex predilections have been identified[7,8].

Several researchers have devised morphologic classification types for polydactyly. Venn-Watson[9] created a classification system based upon the anatomic configuration of the fifth and first metatarsals and the duplicated bony parts. It recognized six metatarsal variations with duplicated distal phalangeal segments: Y-shaped fifth metatarsal; T-shaped fifth metatarsal; widened fifth metatarsal head; complete fifth metatarsal duplication; short, block first metatarsal; and widened first metatarsal head[7,9]. Masada *et al*[10] created a variation of the Venn-Watson classification, expanding the two preaxial types to four: Type 1, complete metatarsal (ray) duplication; type 2, complete phalangeal duplication; type 3, incomplete metatarsal duplication; and type 4, incomplete phalangeal duplication[7,10]. Watanabe *et al*[21] devised their own morphologic classification based upon ray involvements and levels of duplication. They classified foot polydactyly into three broad groups: Medial ray, central ray, and lateral ray with each group further subdivided into tarsal, metatarsal, proximal phalangeal, and distal phalangeal subgroups[7,21]. Belthur *et al*[7] includes an additional categorization to that of the Watanabe *et al*[21]'s morphologic classification known as mirror foot or diplopodia[7,11].

Club foot or CTEV is a complex, fixed deformity of the lower limb that is always present at birth and can be unilateral or bilateral[12]. CTEV is a multiplanar deformity of the lower leg with a prevalence of one to three per 1000 live births[13,14]. It is twice as common in males and at least half the cases are bilateral[14-16]. Most occurrences of CTEV are sporadic, but cases of families with CTEV as an autosomal dominant trait have been reported[14]. In addition, the risk of having a child with CTEV is around 20 to 30 times greater when a first-degree relative is affected[16]. Approximately 20% of CTEV cases are associated with other congenital abnormalities[19].

There are three basic components of CTEV: Equinus, varus, and adduction deformities[14]. The talus is severely flexed, causing the calcaneus, and subsequently the entire foot, to adopt an equinus (horse-foot) posture. In this adducted and inverted position, the anterior portion of the calcaneus is lying directly beneath the head of the talus[16,18]. This displacement is responsible for the severe varus deformity or oblique displacement toward the midline of the heel[18,22]. The navicular is smaller than normal and articulates with the medial aspect of the neck of the talus, which forces the forefoot to adduct toward the midline. In addition, the cuboid is medially displaced and inverted in front of the calcaneus[16,18,22]. The cuneiforms are displaced downward and inward in front of the navicular. The medial displacements of the navicular, cuboid, cuneiforms, and metatarsals contribute in varying degrees to the severe adduction of the club foot. The varus deformity of the calcaneus and the adducted mid-tarsometatarsal bones together are the cause of the foot inversion[18,22]. Generalized hypoplasia of the major foot bones causes the affected foot to be smaller than normal[16,19]. Commonly, the first

metatarsal ray is short[12]. Hypoplasia of the calf muscles is another well-recognized anatomical abnormality of CTEV[19]. In addition, the abnormal positioning of the foot can create a deep medial and/or posterior foot crease on the plantar aspect of the foot[15,16,23].

The severity of the club foot deformity may be classified according to the Pirani scoring system[16]. It includes six clinical features to describe the abnormality, with each being graded as 0, 0.5, or 1 depending on its severity. The scores are summed to give a score between zero and six with six being the most severe[17]. Clinical characteristics of children with CTEV include a hypotrophic anterior tibial artery and atrophy of the musculature around the calf[14]. In many patients, the dorsalis pedis artery is also affected or even absent[24].

There are three classifications of CTEV: Postural, idiopathic, and teratogenic or syndromic. Postural foot is a molding abnormality that is resolved with simple maternal manipulation shortly after birth. Idiopathic CTEV represents the majority of cases and has no known cause. Teratogenic or syndromic CTEV is associated with other diagnoses, such as arthrogryposis, spina bifida, and/or chromosomal anomalies[15,16].

The cause of CTEV is unknown[16,19]. There is a clear multifactorial inheritance pattern with many potential environmental influences[16]. Possible causes of CTEV include an arrest during fetal development, a primary germ plasm defect in the talus causing continued plantar flexion and inversion of this bone with subsequent soft tissue changes in the joints and musculotendinous complexes, or an enteroviral infection affecting anterior horn cells resulting in club foot. Other potential causes include attempted abortion causing amniotic injury or hemorrhage which affect bone development, positioning *in utero*, or primary soft tissue abnormalities within the neuromuscular units causing secondary bony changes[14]. Retracting fibrosis has also been identified as a primary etiological factor of the club foot deformity[18].

Although each of the aforementioned syndromes is relatively rare, comorbidity of all three of these disorders is even rarer, if not unique ($1.7\text{-}5.1 \times 10^{12}$). In this individual, all three of these conditions occurred simultaneously. One other study (Hootnick *et al*[6]) with similar presentation was found in our literature search. Both similarities and differences were observed and noted.

Similar to the findings of Hootnick *et al*[6], we found the limb displayed hip dysplasia with equal femur lengths. The femur displayed no visible condyles or epiphyses on the radiographs. The tibia was absent (TH), and the fibula was complete, but bowed, shortened, and thickened. The navicular was small and deficient. There were three tarsal bones identifiable, but no cuboid or cuneiforms were visible on the radiographs.

Our findings differ from those of Hootnick *et al*[6] in that our case involved a seven-month old female; theirs, a 15-mo old male. In our case, the left limb was affected; in theirs, the right limb was affected. In our case, there was proximal articulation of the fibula and femur; in theirs, there was no evident proximal articulation. In our case, there was no tendinous band in place of the tibia; in theirs, a tendinous band connected the medial head of the fibula to the medial side of the lateral malleolus. In our case, there were seven metatarsals; in theirs, there were six. In our case, the metatarsals and phalanges two and three were normal, but four and five were abnormal; in theirs, metatarsals and phalanges were normal for digits three through five, with a normal second metatarsal with bifid proximal phalanx. In our case, there were seven digits with a hallux; in theirs, no hallux was identifiable. In our case, there were two supernumerary toes: Toes A and B; in theirs, three supernumerary toes: Toes A, B, and C, with partial syndactyly between toes two, A, and B. In our case, toe A was normal, but toe B was missing the middle and distal phalanges; in theirs, the second metatarsal was normal, except a medial bony projection.

Thus, this child seems to have partial mirror foot polydactyly consisting of only mirrored copies of the second and third toes, but not the hallux. This child exhibited preaxial polydactyly and CTEV as a result of having TH. As a result of the absence of the tibia, the foot became severely inverted and adducted as it articulated with the fibula. Since the patient's parents had no identifiable limb or other malformations, it is most likely that this disorder may have been the result of a rare autosomal recessive gene[12], *de novo* dominant mutation, or localized vascular malformation during limb formation. A possible teratogenic event may have occurred in the affected leg at a time when limb developmental specifications had proceeded to the lower leg and foot[5].

In conclusion, this case report analyzes the anatomical findings associated with systematic post-surgical examination of the foot of a seven-month old female presenting with a very rare combination of lower limb malformations. These observations include superficial dissection, X-rays and CT scans. Hootnick *et al*[6] also described a similar case in the right lower limb of a 15-mo old male with comparable rare findings to our case, but with some notable and noteworthy differences. Due to the rarity of this combination of anatomical findings, descriptions of such cases are very infrequent in the literature.

ACKNOWLEDGMENTS

The authors would like to thank the family for this generous donation.

COMMENTS

Case characteristics

A seven-month-old female presented with tibial hemimelia (TH), seven-toed

preaxial polydactyly, and severe left congenital talipes equinovarus (CTEV).

Clinical diagnosis
Medial contracture of the left foot and lower leg with left congenital hip dysplasia, the absence of the left tibia, patella, active quadriceps mechanism and posterior tibial artery, and left fibular bowing with articulation to the lateral side of the left femur.

Differential diagnosis
Interuterine toxic exposure to an agent, such as thalidomide; no evidence of such exposure, amniotic band stricture syndrome, rare autosomal recessive genetic mutation, *de novo* dominant, or localized vascular malformation during limb formation.

Laboratory diagnosis
All labs are within normal limits.

Imaging diagnosis
X-rays and computed tomography scans showed curved and overlapping preaxial supernumerary toes, hypoplastic first metatarsal, lack of middle and distal phalanges in one supernumerary toe, three tarsal bones, hypoplastic middle phalanx and no distal phalanx for fourth toe, no middle or distal phalanges for fifth toe, and the fibula articulated with the anteromedial calcaneus with an absent tibia.

Pathological diagnosis
TH with preaxial polydactyly and CTEV of the left lower limb.

Treatment
Due to the severity of the deformity, and the unlikelihood of a successful limb salvage procedure, amputation was advised and performed.

Related reports
Hootnick's article (1983) also described a similar case in the right lower limb of a 15-mo old male with comparable rare findings to our case, but with some notable and noteworthy differences.

Term explanation
TH or congenital tibial aplasia is a rare congenital anomaly characterized by variable degrees of deficiency of the tibia with a relatively intact fibula. Preaxial polydactyly is a congenital physical anomaly involving superfluous digits found on the lateral aspect of the affected upper limb or medial aspect of the affected lower limb. Club foot or CTEV is a complex, fixed deformity of the lower limb that is always present at birth and can be unilateral or bilateral.

Experiences and lessons
Although each of the aforementioned syndromes is relatively rare, comorbidity of all three disorders is even rarer, if not unique (1.7-5.1 × 10^{12}).

Peer-review
The authors describe a rare and very interesting case of a longitudinal deficiency of the lower extremity including a clubfoot-like deformity and polydactyly. The manuscript is well written and easy to understand, despite the complexity of the topic. The discussion is comprehensive, which enables the reader to understand the three components of the deformity. This case adds valuable information to the current literature that might help in decision making and counseling in similar cases.

REFERENCES

1 **Kalamchi A**, Dawe RV. Congenital deficiency of the tibia. *J Bone Joint Surg Br* 1985; **67**: 581-584 [PMID: 4030854 DOI: 10.1007/978-1-4613-8882-1_8]

2 **Schoenecker PL**, Capelli AM, Millar EA, Sheen MR, Haher T, Aiona MD, Meyer LC. Congenital longitudinal deficiency of the tibia. *J Bone Joint Surg Am* 1989; **71**: 278-287 [PMID: 2918013]

3 **Weber M**. New classification and score for tibial hemimelia. *J Child Orthop* 2008; **2**: 169-175 [PMID: 19308574 DOI: 10.1007/s11832-008-0081-5]

4 **Wolfgang GL**. Complex congenital anomalies of the lower extremities: femoral bifurcation, tibial hemimelia, and diastasis of the ankle. Case report and review of the literature. *J Bone Joint Surg Am* 1984; **66**: 453-458 [PMID: 6699064]

5 **Holmes LB**, Redline RW, Brown DL, Williams AJ, Collins T. Absence/hypoplasia of tibia, polydactyly, retrocerebellar arachnoid cyst, and other anomalies: an autosomal recessive disorder. *J Med Genet* 1995; **32**: 896-900 [PMID: 8592337]

6 **Hootnick DR**, Packard DS, Levinsohn EM. Congenital tibial aplasia with preaxial polydactyly: soft tissue anatomy as a clue to teratogenesis. *Teratology* 1983; **27**: 169-179 [PMID: 6867939 DOI: 10.1002/tera.1420270205]

7 **Belthur MV**, Linton JL, Barnes DA. The spectrum of preaxial polydactyly of the foot. *J Pediatr Orthop* 2011; **31**: 435-447 [PMID: 21572282 DOI: 10.1097/bpo.0b013e3182199a68]

8 **Drennan JC**. Congenital Deformities of the Foot and Ankle. In: Myerson MS, editor. Foot and Ankle Disorders, Vol 1. Philadelphia, PA: W.B. Saunders Company, 2000: 648-649

9 **Venn-Watson EA**. Problems in polydactyly of the foot. *Orthop Clin North Am* 1976; **7**: 909-927 [PMID: 185565]

10 **Masada K**, Tsuyuguchi Y, Kawabata H, Ono K. Treatment of preaxial polydactyly of the foot. *Plast Reconstr Surg* 1987; **79**: 251-258 [PMID: 3809271 DOI: 10.1097/00006534-198702000-00018]

11 **Verghese R**, Shah H, Rebello G, Joseph B. Pre-axial mirror polydactyly associated with tibial deficiency: a study of the patterns of skeletal anomalies of the foot and leg. *J Child Orthop* 2007; **1**: 49-54 [PMID: 19308506 DOI: 10.1007/s11832-006-0001-5]

12 **Helfet AJ**, Greubel Lee DM. Congenital Deformities of the Feet. Philadelphia, PA: J.B. Lippincott Company, 1980: 83-84

13 **Bar-On E**, Mashiach R, Inbar O, Weigl D, Katz K, Meizner I. Prenatal ultrasound diagnosis of club foot: outcome and recommendations for counselling and follow-up. *J Bone Joint Surg Br* 2005; **87**: 990-993 [PMID: 15972918 DOI: 10.1302/0301-620x.87b7.16076]

14 **Beaty JH**. Congenital Foot Deformities. In: Coughlin MJ, Mann RA, Saltzman CL, editors. Surgery of the Foot and Ankle, Volume 2. Philadelphia, PA: Mosby, 2007: 1729-1760

15 **Bass A**. Update on Club Foot. *Paediatr Child Healt* 2012; **22**: 239-242 [DOI: 10.1016/j.paed.2011.11.007]

16 **Sullivan RJ**. Congenital Talipes Equinovarus. In: Myerson MS, editor. Foot and Ankle Disorders, Vol. 1. Philadelphia, PA: W.B. Saunders Company, 2000: 693-698

17 **Shaheen S**, Jaiballa H, Pirani S. Interobserver reliability in Pirani clubfoot severity scoring between a paediatric orthopaedic surgeon and a physiotherapy assistant. *J Pediatr Orthop B* 2012; **21**: 366-368 [PMID: 22343939 DOI: 10.1097/BPB.0b013e3283514183]

18 **Ponseti IV**. Congenital Clubfoot: Fundamentals of Treatment. New York, NY: Oxford Medical Publications, 1996: 8-35

19 **Siapkara A**, Duncan R. Congenital talipes equinovarus: a review of current management. *J Bone Joint Surg Br* 2007; **89**: 995-1000 [PMID: 17785734 DOI: 10.1302/0301-620X.89B8.19008]

20 **Jones D**, Barnes J, Lloyd-Roberts GC. Congenital aplasia and dysplasia of the tibia with intact fibula. Classification and management. *J Bone Joint Surg Br* 1978; **60**: 31-39 [PMID: 627576 DOI: 10.1016/S0022-3468(78)80365-0]

21 **Watanabe H**, Fujita S, Oka I. Polydactyly of the foot: an analysis of 265 cases and a morphological classification. *Plast Reconstr Surg* 1992; **89**: 856-877 [PMID: 1561258 DOI: 10.1097/00006534-199205000-00014]

22 **Ponseti IV**, Smoley EN. The classic: congenital club foot: the results of treatment. 1963. *Clin Orthop Relat Res* 2009; **467**: 1133-1145 [PMID: 19219519 DOI: 10.1007/s11999-009-0720-2]

23 **Jain M**, Dhande S, Vyas N. Biomodeling of club foot deformity of babies. *Rapid Prototyping J* 2009; **15**: 164-170 [DOI: 10.1108/13552540910960253]

24 **Kruse L**, Gurnett CA, Hootnick D, Dobbs MB. Magnetic resonance angiography in clubfoot and vertical talus: a feasibility study. *Clin Orthop Relat Res* 2009; **467**: 1250-1255 [PMID: 19127394 DOI: 10.1007/s11999-008-0673-x]

P- Reviewer: Radler C **S- Editor**: Kong JX **L- Editor**: A
E- Editor: Wu HL

World Journal of Clinical Cases

Submit a Manuscript: http://www.wjgnet.com/esps/
Help Desk: http://www.wjgnet.com/esps/helpdesk.aspx
DOI: 10.12998/wjcc.v4.i12.409

World J Clin Cases 2016 December 16; 4(12): 409-412
ISSN 2307-8960 (online)

CASE REPORT

Granulomatous lobular mastitis secondary to *Mycobacterium fortuitum*

Armin Kamyab

Armin Kamyab, Department of Surgery, Cox Monett Hospital, Monett, MO 65708, United States

Author contributions: Kamyab A solely contributed to this paper.

Institutional review board statement: This case report was exempt from the Institutional Review Board standards as it is a case report.

Informed consent statement: The patient involved in this study gave her written informed consent authorizing use and disclosure of her protected health information.

Conflict-of-interest statement: The author has no conflicts of interest to disclose.

Manuscript source: Unsolicited manuscript

Correspondence to: Armin Kamyab, MD, Chief of Surgery, Department of Surgery, Cox Monett Hospital, 801 N Lincoln, Monett, MO 65708,
United States. armin.kamyab@coxhealth.com
Telephone: +1-417-2362440
Fax: +1-417-3541458

Received: February 22, 2016
Peer-review started: February 24, 2016
First decision: April 26, 2016
Revised: April 29, 2016
Accepted: June 1, 2016
Article in press: June 3, 2016
Published online: December 16, 2016

Abstract

Granulomatous lobular mastitis is a rare inflammatory disease of the breast of unknown etiology. Most present as breast masses in women of child-bearing age. A 29-year-old female presented with a swollen, firm and tender right breast, initially misdiagnosed as mastitis. Core needle biopsy revealed findings consistent with granulomatous lobular mastitis, and cultures were all negative for an infectious etiology. She was started on steroid therapy to which she initially responded well. A few weeks later she deteriorated and was found to have multiple breast abscesses. She underwent operative drainage and cultures grew *Mycobacterium fortuitum*. Granulomatous lobular mastitis is a rare inflammatory disease of the breast. The definitive diagnose entails a biopsy. Other causes of chronic or granulomatous mastitis should be ruled out, including atypical or rare bacteria such as *Mycobacterium fortuitum*. This is the first reported case of granulomatous mastitis secondary to *Mycobacterium fortuitum*. With pathologic confirmation of granulomatous mastitis, an infectious etiology must be ruled out. Atypical bacteria such as *Mycobacterium fortuitum* may not readily grow on cultures, as with our case. Medical management is appropriate, with surgical excision reserved for refractory cases or for drainage of abscesses.

Key words: Breast; Granulomatous; Lobular; Mastitis; Breast mass; *Mycobacterium fortuitum*

Core tip: Granulomatous mastitis is a rare inflammatory disease of the breast, that often presents as a breast mass. The exact etiology is unkown. We report a rare presentation of this conditions arising in the right breast of a 29-year-old female. The treatment if granulomatous mastitis is yet to be defined, but literature supports non operative management with steroids, with surgery

reserved for failure of medical management. Failure of steroid therapy should raise the suspicion of an underlying misdiagnosed infectious etiology. If an infectious etiology is identified however, medical management with antibiotics remains the mainstay for treatment.

Kamyab A. Granulomatous lobular mastitis secondary to *Mycobacterium fortuitum*. *World J Clin Cases* 2016; 4(12): 409-412 Available from: URL: http://www.wjgnet.com/2307-8960/full/v4/i12/409.htm DOI: http://dx.doi.org/10.12998/wjcc.v4.i12.409

INTRODUCTION

Granulomatous lobular mastitis is a rare inflammatory disease of the breast[1]. Although it was first described in 1972[2] and has been a recognized disease for over 40 years, it remains an overall rare entity. The exact etiology remains unknown. The clinical presentation is often similar to that of breast cancer[1], with a unilateral breast mass being most common[2]. Pathologic findings include non-necrotizing granulomatous inflammation of the lobules[1,2].

Treatment is based on the suspected etiology. For idiopathic granulomatous mastitis, excision has been proposed by some[3], whereas medical management with repeated courses of steroid therapy has been proposed by others[1]. Published cases reveal opposing outcomes to different treatment algorithms and modalities. The optimal treatment of granulomatous lobular mastitis therefore remains complex and there is currently no standard of care for its management. In cases where an infection has been identified, the standard treatment remains antibiotic therapy.

CASE REPORT

We report the case of a 29-year-old female eleven months postpartum, no longer breast feeding, who presented to her primary care provider with the complaint of a swollen and tender right breast, with a large area of firmness. She had no personal or family history of breast cancer, had no previous breast masses or biopsies, no previous breast surgeries, and had no history of chest radiation. Due to the degree of swelling and tenderness, a presumptive diagnosis of an infectious mastitis was made and the patient was prescribed a course of antibiotics. She subsequently failed to improve and was referred for a surgical evaluation.

On examination she was found to have a visibly swollen right breast, tender to touch, and with a large approximately 10 by 10 cm firm mass in the superior and outer portion of the breast. An ultrasound was performed to rule out abscess formation or fluid collection as well as to further characterize the mass (Figure 1), which revealed a large irregular hypoechoic mass without any evidence of abscess or fluid collection. A core-needle biopsy was therefore performed to rule out breast cancer, as well as for cultures to definitively rule out an infectious mastitis. Cultures at this time were negative for bacterial, fungal, acid fast staining, or mycobacterial growth. Histologic evaluation of the biopsy revealed granulomatous inflammatory reaction centered on lobules, with granulomas composed of epithelioid histiocytes, Landerhans giant cells accompanied by lymphocytes, plasma cells and occasional eosinophils (Figure 2), consistent with granulomatous lobular mastitis.

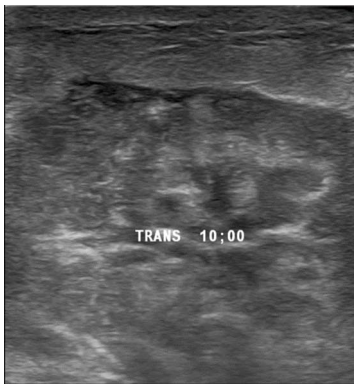

Figure 1 Ultrasound of the area of concern in the right breast reveals a large irregular hypoechoic mass without any evidence of abscess or fluid collection.

The patient was given a course of oral steroids starting with an initial Prednisone dose of 60 mg/d and tapering thereafter, and given a period of observation. Her condition began to improve after 2 wk on steroids, and on a 1-mo follow-up she remained free of any symptoms.

She then presented approximately 3 wk later with recurrent redness and tenderness of the right breast. A repeat ultrasound in the office revealed multiple fluid collections within the breast. A diagnostic needle aspiration of one of the fluid collections was performed and revealed purulent fluid consistent with abscesses. The collections were therefore all aspirated and the patient given repeat antibiotics and observed. Cultures of this purulent fluid were once again all negative for any bacterial growth or for acid fast staining.

Her condition continued to deteriorate and the abscesses enlarged and increase in number. She therefore underwent operative incision and drainage of her multiple abscesses, as well as a third set of bacterial cultures. This time, the cultures grew *Mycobacterium fortuitum*. She was referred to an infectious disease specialist for treatment, and was prescribed a long term course of multiple antibiotics, consisting of Ciprofloxacin, Linezolid, and Sulfamethoxazole/Trimethoprim as per their recommendations for the treatment of her *Mycobacterium fortuitum* causing granulomatous mastitis.

DISCUSSION

Granulomatous lobular mastitis is a rare and benign inflammatory disease of the breast first described in

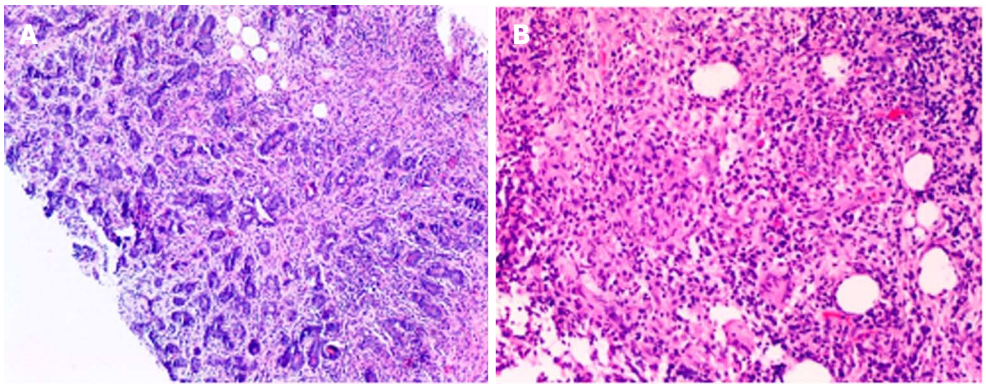

Figure 2 Core biopsy of the mass, 4 × (A) and 10 × (B) magnification, reveals granulomatous inflammatory reaction centered on lobules, with granulomas composed of epithelioid histiocytes, Landerhans giant cells accompanied by lymphocytes, plasma cells and occasional eosinophils.

1972[2]. The clinical findings and presentation is often reported as mimicking that of breast cancer[1], however in our case it initially resembled an infectious mastitis.

Most published cases of granulomatous mastitis in the literature have no identifiable causative bacteria, and the etiology therefore remains unclear. An autoimmune etiology has proposed[4] however no specific antibodies have been recognized. In published cases, it typically affects women of child bearing age[1,5], and it has no propensity to favor the right or left breast[5].

As with the workup of any other breast mass, the physician must remain vigilant and ruling out cancer remains the utmost priority. Mammographic findings are non-specific, yet ultrasound identifies a hypoechoic mass in the majority of cases[1], including ours. The definitive diagnose entails a biopsy. Core-needle is favored over fine-needle aspiration since it carries a higher diagnostic yield. Surgical excision or open biopsy is not required for diagnosis.

Pathologically, it is characterized by non-necrotizing lobular granulomatous inflammation[5], originating in the breast lobules[1]. Certain pathologic features can overlap with other breast conditions, and therefore other causes of chronic or granulomatous mastitis should be ruled out, such as sarcoidosis, fungal infections, and Wegener's granulomatosis[1,4].

There is no definitive consensus on the appropriate treatment for granulomatous mastitis. Once an infectious etiology has been ruled out, a course of steroid therapy appears to be appropriate in most studies. Satisfactory results have been published with an initial dose of Prednisone at 60 mg/d[1]. In a recent study reviewing 50 female patients with granulomatous mastitis, steroid therapy was not found to be effective, and many patients ultimately required surgical excision either due to failed treatment or abscess collection after steroid treatment[6]. We suspect in such cases of failure of steroid treatment, that an underlying infection was pre-existent despite negative cultures, as was the case with our patient.

Mycobacterium fortuitum is a rapidly growing group of nontuberculous mycobacteria more common in patients with genetic or acquired causes of immune deficiency[7]. It is commonly associated with surgical procedures, and is known to infect implanted medical devices, cause injection site abscesses, and also seen with breast implants[7]. There have been previously reported cases of breast abscesses secondary to *Mycobacterium fortuitum*, but this is the first reported case of a granulomatous mastitis secondary to *Mycobacterium fortuitum,* in an immunocompetent patient without foreign body in her breast.

A granulomatous response is a known protective immune response against Mycobacterial infections[8]. We suspect that in many of the previously reported cases of granulomatous mastitis, especially in those in whom steroid therapy had failed, that an underlying atypical bacterium was the cause. In our case, two different sets of tissue cultures, including Mycobacterial cultures and acid-fast staining, had failed to grow *Mycobacterium fortuitum*, further demonstrating how inconspicuous such an infection can be.

Such a variety in outcomes of published cases further outlines the complexity of granulomatous lobular mastitis. The proper treatment should be chosen on a case-by-case basis[6], but ruling out a neoplastic and infectious etiology are of utmost importance. Failure of steroid treatment should raise the suspicion of a misdiagnosed underlying pathogen.

ACKNOWLEDGMENTS

Dr. Jami R Skrade, MD and Dr. Kyle Noskoiviak, MD, Pathologists, CoxHealth, Springfield, MO, for the pathologic findings on histology, as well as the histologic picture.

COMMENTS

Case characteristics

A 29-year-old woman with no significant medical history presented with a painless left breast mass.

Clinical diagnosis

Right breast swelling and redness in the upper outer portion of the right breast.

Differential diagnosis
Infectious mastitis, inflammatory breast cancer, granulomatous mastitis.

Laboratory diagnosis
All labs were within normal limits.

Imaging diagnosis
Ultrasound showed a large irregular hypoechoic mass without any evidence of abscess or fluid collection.

Pathological diagnosis
Granulomatous inflammatory reaction centered on lobules, with granulomas composed of epithelioid histiocytes, Landerhans giant cells accompanied by lymphocytes, plasma cells and occasional eosinophils, consistent with granulomatous lobular mastitis.

Treatment
Oral steroid therapy.

Related reports
Granulomatous lobular mastitis is a rare and benign inflammatory disease of the breast. The etiology remains unclear. An autoimmune etiology has proposed, however no specific antibodies have been recognized.

Term explanation
Granulomatous mastitis is a benign inflammatory disease of the breast.

Experiences and lessons
This entity is commonly confused with an infectious mastitis or inflammatory breast cancer. Ruling out cancer is of utmost importance in any breast mass. There is no definitive consensus on the appropriate treatment. Most studies however favor medical management over surgical excision.

Peer-review
The authors report a rare breast granulomatous lobular mastitis in a young woman. This paper is valuable due to a rarity of this disease. This manuscript provides useful information to the medical students, clinicians, and researchers in this field.

REFERENCES

1 **Hovanessian Larsen LJ**, Peyvandi B, Klipfel N, Grant E, Iyengar G. Granulomatous lobular mastitis: imaging, diagnosis, and treatment. *AJR Am J Roentgenol* 2009; **193**: 574-581 [PMID: 19620458 DOI: 10.2214/AJR.08.1528]

2 **Kessler E**, Wolloch Y. Granulomatous mastitis: a lesion clinically simulating carcinoma. *Am J Clin Pathol* 1972; **58**: 642-646 [PMID: 4674439 DOI: 10.1093/ajcp/58.6.642]

3 **Miliauskas JR**, Pieterse AS, Williams RS. Granulomatous lobular mastitis. *Aust N Z J Surg* 1995; **65**: 139-141 [PMID: 7857229 DOI: 10.1111/j.445-2791.1995.tb07281.x]

4 **Imoto S**, Kitaya T, Kodama T, Hasebe T, Mukai K. Idiopathic granulomatous mastitis: case report and review of the literature. *Jpn J Clin Oncol* 1997; **27**: 274-277 [PMID: 9379518]

5 **Going JJ**, Anderson TJ, Wilkinson S, Chetty U. Granulomatous lobular mastitis. *J Clin Pathol* 1987; **40**: 535-540 [PMID: 3584506 DOI: 10.1136/jcp.40.5.535]

6 **Hur SM**, Cho DH, Lee SK, Choi MY, Bae SY, Koo MY, Kim S, Choe JH, Kim JH, Kim JS, Nam SJ, Yang JH, Lee JE. Experience of treatment of patients with granulomatous lobular mastitis. *J Korean Surg Soc* 2013; **85**: 1-6 [PMID: 23833753 DOI: 10.4174/jkss.2013.85.1.1]

7 **Betal D**, Macneill FA. Chronic breast abscess due to Mycobacterium fortuitum: a case report. *J Med Case Rep* 2011; **5**: 188 [PMID: 21592364 DOI: 10.1186/1752-1947-5-188]

8 **Co DO**, Hogan LH, Kim SI, Sandor M. Mycobacterial granulomas: keys to a long-lasting host-pathogen relationship. *Clin Immunol* 2004; **113**: 130-136 [PMID: 15451467 DOI: 10.1016/j.clim.2004.08.012]

P- Reviewer: Song J, Sonoda K, Zhang XQ **S- Editor**: Ji FF
L- Editor: A **E- Editor**: Wu HL

World Journal of Clinical Cases

Submit a Manuscript: http://www.wjgnet.com/esps/
Help Desk: http://www.wjgnet.com/esps/helpdesk.aspx
DOI: 10.12998/wjcc.v4.i12.413

World J Clin Cases 2016 December 16; 4(12): 413-418
ISSN 2307-8960 (online)

CASE REPORT

Lymphocytic esophagitis: Report of three cases and review of the literature

Bilel Jideh, Andrew Keegan, Martin Weltman

Bilel Jideh, Andrew Keegan, Martin Weltman, Department of Gastroenterology and Hepatology, Nepean Hospital, New South Wales, Sydney 2747, Australia

Author contributions: Weltman M designed the report, was the attending gastroenterologist of one of the clinical cases, and edited the draft manuscript; Keegan A was the attending gastroenterologist of two of the clinical cases and edited the draft manuscript; Jideh B reviewed the literature and wrote the paper.

Institutional review board statement: Nepean Hospital institutional review board gave consent for anonymous description of the clinical case series presented.

Informed consent statement: The three patients described in the case reports gave verbal consent for anonymous description of their case.

Conflict-of-interest statement: None of the authors have any conflict of interest to declare.

Manuscript source: Unsolicited manuscript

Correspondence to: Bilel Jideh, Gastroenterology Trainee, Department of Gastroenterology and Hepatology, Nepean Hospital, Derby Street, Kingswood, New South Wales, Sydney 2747, Australia. bjid7747@uni.sydney.edu.au
Telephone: +61-413-724433
Fax: +61-247-341313

Received: April 10, 2016
Peer-review started: April 12, 2016
First decision: May 19, 2016
Revised: September 7, 2016
Accepted: September 21, 2016
Article in press: September 22, 2016

Published online: December 16, 2016

Abstract

Lymphocytic esophagitis (LyE) is a rare condition characterised histologically by high numbers of esophageal intraepithelial lymphocytes without significant granulocytes infiltration, in addition to intercellular edema ("spongiosis"). The clinical significance and natural history of LyE is poorly defined although dysphagia is reportedly the most common symptom. Endoscopic features range from normal appearing esophageal mucosa to features similar to those seen in eosinophilic esophagitis, including esophageal rings, linear furrows, whitish exudates, and esophageal strictures/stenosis. Symptomatic gastroesophageal reflux disease is an inconsistent association. LyE has been associated in paediatric Crohn's disease, and recently in primary esophageal dysmotility disorder in adults. There are no studies assessing effective treatment strategies for LyE; empirical therapies have included use of proton pump inhibitor and corticosteroids. Esophageal dilatation have been used to manage esophageal strictures. LyE has been reported to run a benign course; however there has been a case of esophageal perforation associated with LyE. Here, we describe the clinical, endoscopic and histopathological features of three patients with lymphocytic esophagitis along with a review of the current literature.

Key words: Esophagitis; Lymphocytes; Gastroesophageal reflux disease; Eosinophilic esophagitis; Esophageal dysmotility

Core tip: Lymphocytic esophagitis (LyE) is a histological subset of esophagitis that is rare with poorly defined clinical significance and associations. We present the

clinical, endoscopic and histopathological features of three patients with LyE followed by the most up-to-date literature on the condition, including description of the newly postulated association of primary esophageal dysmotility.

Jideh B, Keegan A, Weltman M. Lymphocytic esophagitis: Report of three cases and review of the literature. *World J Clin Cases* 2016; 4(12): 413-418 Available from: URL: http://www.wjgnet.com/2307-8960/full/v4/i12/413.htm DOI: http://dx.doi.org/10.12998/wjcc.v4.i12.413

INTRODUCTION

Lymphocytic esophagitis (LyE) is an uncommon histologic phenotype of esophagitis first described by Rubio *et al*[1]. Its histology is characterised by a high numbers of intraepithelial lymphocytes mainly in a peripapillary distribution with the absence of significant granulocytes (neutrophils and eosinophils), along with intercellular edema ("spongiosis"). The clinical significance and natural history of LyE is unknown. In this case series we highlight the clinical, endoscopic, histopathologic features and outcome of three patients with lymphocytic esophagitis followed by a review of the current literature. This includes the associations of LyE with other disease entities including gastroesophageal reflux disease (GERD), Crohn's disease and most recently primary esophageal dysmotility; the endoscopic features which may range from normal mucosa to features observed in eosinophilic esophagitis (EoE); the management of LyE and its natural history.

CASE REPORT

Case 1

An 85-year-old lady presented with progressive dysphagia to solids. Background history included proton pump inhibitor (PPI)-refractory GERD and chronic airway limitation with recurrent exacerbations requiring corticosteroids and antibiotics. Upper endoscopy revealed a 5 cm sliding hiatus hernia with otherwise normal appearing oesophagus; there was no macroscopic evidence of esophagitis or strictures. The stomach and duodenum were unremarkable. Biopsies from the middle and lower esophagus revealed prominent basal cell hyperplasia with intercellular edema and a heavy intra-epithelial lymphocytic infiltrate (up to 60 per high power fields) in a peripapillary distribution without granulocytes. A diagnosis of LyE was made. Therapy including escalating doses of PPI, a histamine receptor antagonist and a course of corticosteroids provided minimal symptomatic relief.

Case 2

A 51-year-old gentleman presented with 12 mo of dysphagia to solids and a recent episode of food bolus impaction that cleared spontaneously. He was on no regular medications. A barium swallow revealed transient hold-up of a marshmallow bolus suggesting dysmotility but no stricture. An upper endoscopy demonstrated decreased motility of the esophageal body with macroscopically normal esophageal mucosa. The stomach and duodenum appeared unremarkable. Mid esophageal mucosal histology revealed spongiosis and a heavy lymphocytic infiltrate with occasional neutrophils and eosinophils, consistent with LyE. Gastric biopsies did not reveal any abnormalities. The patient reported spontaneous resolution of his dysphagia with no further episodes of food bolus impaction without the need for further intervention.

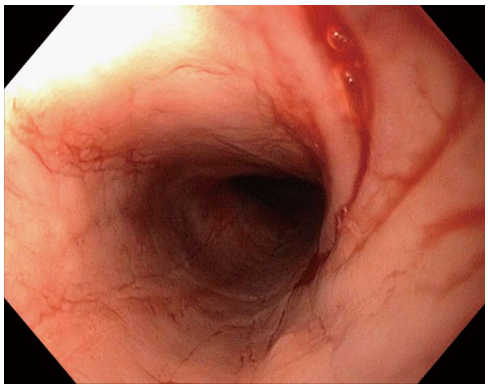

Figure 1 Linear esophageal furrows and a tight benign appearing esophageal stricture in the proximal esophagus (25 cm from incisors). Mild self-limiting blood ooze following esophageal dilatation. Mucosa biopsies were suggestive of lymphocytic esophagitis.

Case 3

A 59-year-old lady presented with fluctuating dysphagia to solids and globus sensation over the past few months. There were no other symptoms reported. Past medical history included irritable bowel syndrome and hypothyroidism. Upper endoscopy revealed linear furrows and a tight benign appearing esophageal stricture in the proximal esophagus (25 cm from the incisors) that was dilated (Figure 1). There was no macroscopic evidence of esophagitis. The stomach and examined duodenum appeared normal. Biopsies from the mid esophagus demonstrated mucosal spongiosis with significant intraepithelial lymphocytic infiltrate and minimal eosinophils or neutrophils, consistent with LyE. Biopsies of the stomach and duodenum were unremarkable. Patient reported immediate improvement of symptoms following esophageal dilatation, but has required repeat dilatations over the years at approximately 12 mo intervals. This is in addition to high doses of acid suppression therapy (proton pump inhibitor). On subsequent esophageal biopsies the histopathological findings remained unchanged.

DISCUSSION

LyE is an uncommon and poorly defined histological

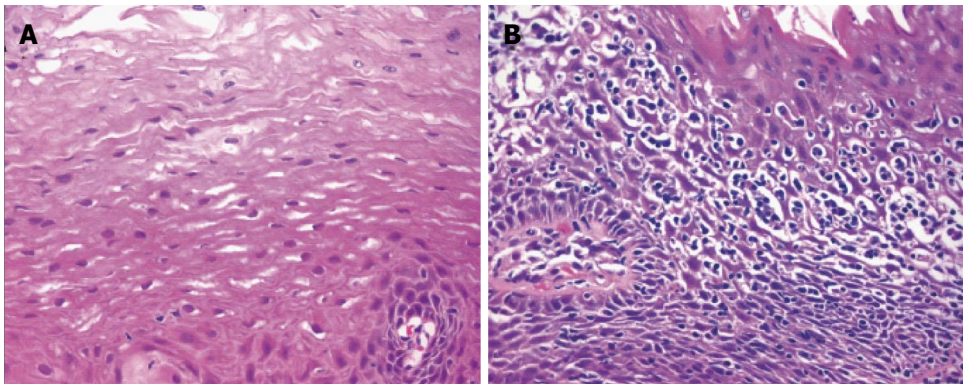

Figure 2 Histopathologic findings. A: Normal esophageal mucosa with stratified squamous epithelium and no inflammatory cells present; B: Lymphocytic esophagitis with marked spongiosis and intraepithelial lymphocyte infiltration in basal and peripapillary fields. No granulocytes present (reproduced from ref. [3]).

subset of esophagitis first described by Rubio *et al*[1] in 2006. Whilst small numbers of intraepithelial lymphocytes are normal constituents of the esophageal mucosa[2], the histological hallmarks of LyE noted by Rubio *et al*[1] includes increased number of intraepithelial lymphocytes with few or no associated intraepithelial granulocytes (neutrophils and eosinophils) in addition to intercellular edema ("spongiosis") (Figure 2)[3]. The intraepithelial infiltrate most densely in peripapillary fields and express CD3, CD4 and CD8 markers. This is in contrast with the distribution of intraepithelial lymphocytes in GERD, radiation and Candida albicans esophagitis where the number of interpapillary intraepithelial lymphocytes highly exceeds that recorded in peripapillary areas.

Various thresholds for the number of intraepithelial lymphocytes required for the diagnosis of LyE have been proposed[4] contributing to differences in reported incidence of LyE. The original work of Rubio *et al*[1] proposed at least greater than 20 lymphocytes per high power field. In the study by Haque *et al*[5] it was believed that stipulating a required minimum lymphocyte count could be potentially misleading and would not necessarily increase the specificity of the diagnosis. In their analysis of 129252 esophageal biopsies, LyE was detected in approximately one in a thousand patients when LyE was defined histopathologically as the presence of dense lymphocytic infiltrate (without a minimum number required) in the peripapillary esophageal squamous mucosa and marked spongiosis without significant number of eosinophils or neutrophils.

LyE appears to be localised to the esophagus when biopsies from other sites of the gastrointestinal tract have been concurrently analysed. In the study by Rubio *et al*[1], none of the biopsy specimens obtained from sites other than the esophagus showed intraepithelial lymphocytes in any of the 20 patients studied. Similarly, in a separate study by Purdy *et al*[6], the most common finding was normal mucosa when concurrent biopsies were taken from sites other than the esophagus including the stomach, small bowel and colon. This finding is true for all three cases in the present series.

The clinical presentation of LyE is inconsistent across different studies. Cohen *et al*[7] in their study cohort of 81 patients found the presentation of LyE was highest in females in the 6th deciles of life and most commonly presenting with symptoms of dysphagia, chest discomfort, heartburn, and less frequently food impaction. This was corroborated in a recent study by Xue *et al*[8]. However, this was not true in an earlier study by Purdy *et al*[6] that compared 42 patients with LyE to 34 control patients and no differences were found between the two groups in the rates of the above reported symptoms. In our case series, all three patients presented with dysphagia to solids.

The association between GERD and LyE has been of particular interest with conflicting reports in the literature. In GERD, none to small numbers of intraepithelial lymphocytes admixed with neutrophils and/or eosinophils has been the traditional observation[2]. In some studies, no association was found between LyE and symptoms or endoscopic findings consistent with GERD[4]. This was supported by Haque *et al*[5] who reviewed biopsy specimens from 129252 patients and found symptoms of GERD were significantly less frequent (18%) in patients with LyE compared to patients with normal esophageal biopsies (37%). This finding however was contradicted by Cohen *et al*[7] who reported GERD to be the most common association (49%) in their study cohort of 81 patients with LyE. In an assessment of the histologic importance of lymphocytes in EoE and reflux esophagitis, there were similar number of patient with GERD and intraepithelial lymphocytosis[9] prompting some to postulate that perhaps LyE is an extreme spectrum of GERD[10]. In support of this view, a recent study by Conner *et al*[11] described LyE in patients with Barrett esophagus and more severe reflux disease. Only one of our three cases described above complained of GERD symptoms, and on endoscopy there was no evidence of esophagitis noting that the patient was on high doses of PPI.

An interesting association between LyE and Crohn's disease was first suggested by Rubio *et al*[1] in their initial description of LyE. In their study cohort of 20 patients

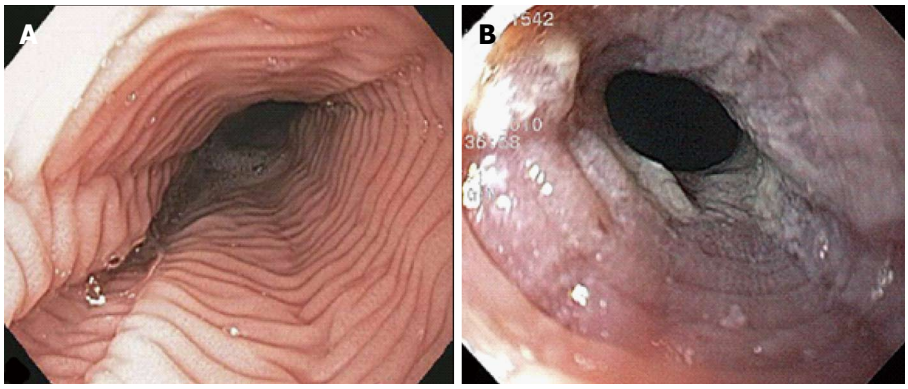

Figure 3 Upper gastrointestinal findings in two patients with eosinophilic esophagitis. A: Lymphocytic esophagitis esophageal rings; B: Esophageal rings, linear furrows and whitish exudates. In both cases the clinical suspicion was eosinophilic esophagitis but biopsies were consistent with lymphocytic esophagitis (reproduced from ref. [4]).

(9 adults and 11 paediatric), 42% of the patients had Crohn's disease. This prompted subsequent studies in both adult and paediatric patient populations. In the adult cohort, various studies the most recent by Xue *et al*[8] found no association of LyE with Crohn's disease. This is similar to other reports describing adult patients including subjects with advanced Crohn's disease[4-6]. In contrast, an association between LyE and Crohn's disease in children is supported by several studies that demonstrated 12% to 28% prevalence of LyE in children with Crohn's disease compared with 4% to 5% in children without Crohn's disease[1,12,13].

LyE has most recently been associated with primary esophageal dysmotility disorder. In the study by Xue *et al*[8], primary esophageal motility abnormalities evident on esophageal manometry or barium swallow were found in 91% (10/11) of patients with LyE that had no identifiable granulocytes, and in 60% (6/10) of patients with LyE that had few granulocytes. This was compared to the control group of 28 patients with active esophagitis consistent with reflux disease and overtly increased intraepithelial lymphocytes. In those that had motility testing, 54% (6/11) were found to have primary esophageal motility abnormalities. In this study lymphocyte subsets were analysed, and the prevalence of primary motility abnormalities was significantly higher in patients with CD4-predominant esophagitis than in patients with CD8-predominant esophagitis from all groups. This led the authors to postulate that a distinctive type of LyE with CD4-predominant lymphocytes is associated with primary esophageal dysmotility, and there is good clinical utility in evaluating lymphocytes subsets in LyE. Further studies are needed to characterise this possible distinct clinicopathologic entity. In one of our cases (case 2), there was an impression of esophageal dysmotility at both upper endoscopy and barium swallow, but it was not further assessed with manometry as the patient's symptoms resolved spontaneously.

The endoscopic findings in LyE have been described in only a few reports and they can often mimics EoE[1,5,14,15]. Features include esophageal rings, linear furrows, whitish exudates, and esophageal strictures/stenosis (Figure 3). Normal esophageal mucosa is found in 23%-55% of cases on conventional endoscopy[1,5]. Attempts have been made to characterise the endoscopic features of both LyE and EoE using narrow band imaging magnifying endoscopy (NBI-ME). In the study by Tanaka *et al*[14], three features were identified on NBI-ME in their cohort of 21 patients (11 patients with LyE, 10 patients with EoE): (1) beige coloured mucosa (normal mucosa has light green colour); (2) increased and dot-shaped congested intrapapillary capillary loop; and (3) invisibility of submucosal vessels (normal mucosa has cyna-coloured vessels). In the LyE group, at least one of the above finding was evident in 91% (10/11) of patients, and all three findings were present in 82% (9/11) of patients. In the group with EoE, all patients had all three abnormalities. Compared with the control group with GERD, at least one of the three abnormal findings was seen in 30% (3/10) patients and none had all three features. The authors therefore proposed that coexistence of these three NBI-ME findings may indicate suspicion of LyE or EoE. Larger studies are required to further evaluate the diagnostic value of these criteria.

The management of LyE has not been addressed by any studies in the literature thus far. This may be in part due to the low prevalence of LyE. In the study by Cohen *et al*[7] most patients had an improvement in their symptoms with a PPI. However, it is unclear if the symptom improvement associated with PPI therapy was due to treatment of LyE or related to treatment of concomitant GERD. Haque *et al*[5] found widespread use of PPIs in their study subjects and therefore were unable to make any associations. However, it would not be unreasonable to initiate a trial course of PPI or to increase the dose when a diagnosis of LyE is made as it may provide symptomatic benefits. Topical corticosteroids (*e.g.,* fluticasone) is another proposed course of treatment[16]. This is because corticosteroids are beneficial in other gastrointestinal lymphocytic and

autoimmune diseases[17-19], and swallowed fluticasone in particular has been shown to induce histological remission in EoE[18]. Prospective studies are required to assess for appropriate and effective therapy for LyE. In our case series, one patient failed multiple lines of therapy, one patient had spontaneous resolution of symptoms, and the other patient required repeat esophageal dilatation for structuring disease.

The natural history of LyE has been specifically assessed in one study by Cohen *et al*[7] who found it to be a relatively benign disease in their retrospective study cohort of 29 patients who had follow-up surveys. In 59% (17/29) of patients, there was improvement in symptoms with escalating medical therapy, most commonly with a PPI and there was no significant adverse effect on their health-related quality of life. The highest rates of symptomatic improvement were seen in patients with dysphagia and the lowest rates were in patients with chest pain. In this study, follow-up endoscopy was performed in 22 patients, of which 9 had LyE on repeat biopsies. This finding suggests that the histological changes seen in LyE can potentially normalise, which was also observed in another study by Purdy *et al*[6]. However, these were retrospective studies with small numbers of study patients. A case report of spontaneous esophageal perforation attributed to LyE has been described[20], although the strength of the association is uncertain. Larger studies are necessary to clarify the natural history and disease course of LyE.

In conclusion, LyE is a rare histologic subset of esophagitis with uncertain clinical significance and associations. Primary esophageal dysmotility is a newly postulated association. Large prospective studies are required to further characterise this disease entity including an assessment of appropriate and effective treatment strategies.

COMMENTS

Case characteristics

The authors report three cases of esophageal dysphagia that had a histological diagnosis of lymphocytic esophagitis.

Clinical diagnosis

The case presentations were non-specific raising a number of possible aetiologies including gastroesophageal reflux disease (GERD), eosinophilic esophagitis, esophageal stricture, esophageal dysmotility, and esophageal tumour.

Differential diagnosis

The case presentations were non-specific raising a number of possible aetiologies including GERD, eosinophilic esophagitis, esophageal stricture, esophageal dysmotility, and esophageal tumour.

Imaging diagnosis

The first case had evidence of a hiatus hernia on upper endoscopy with an otherwise normal appearing esophagus. The second case revealed decreased esophageal motility on upper endoscopy with a macroscopically normal mucosa; a barium swallow demonstrated transient hold-up of a marshmallow suggesting esophageal dysmotility. The third case had evidence of a tight benign-appearing esophageal stricture in the proximal esophagus that was dilated.

Pathological diagnosis

Lymphocytic esophagitis in all three cases.

Treatment

First case did not respond to multiple medical therapies including acid suppression, histamine receptor antagonist and corticosteroids; the second case had spontaneous resolution of symptoms; and the third case required repeat esophageal dilatations in addition to acid suppressive therapy.

Related reports

There have been various case reports of lymphocytic esophagitis with a lack of large prospective studies on this rare disease entity.

Experiences and lessons

Management of lymphocytic esophagitis can be difficult in the absence of evidence-based diagnostic criteria and management algorithms.

Peer-review

This is a nice and well-structured manuscript describing the new entity among esophageal diseases. In addition there are descriptions of three patients with lymphocytic esophagitis. The topic is very interesting for readers.

REFERENCES

1 **Rubio CA**, Sjödahl K, Lagergren J. Lymphocytic esophagitis: a histologic subset of chronic esophagitis. *Am J Clin Pathol* 2006; **125**: 432-437 [PMID: 16613348]

2 **Geboes K**, De Wolf-Peeters C, Rutgeerts P, Janssens J, Vantrappen G, Desmet V. Lymphocytes and Langerhans cells in the human oesophageal epithelium. *Virchows Arch A Pathol Anat Histopathol* 1983; **401**: 45-55 [PMID: 6412448]

3 **Dunbar KB**, Ayyar B, Spechler SJ, Genta R, Melton S. Clinical, endoscopic and histological features of patients with lymphocytic esophagitis compared to patients with GERD. Poster presentation at the 45th Annual Digestive Disease Week; Chicago, IL, 2014. Abstract Mo1846. Available from: URL: http://www.gastrojournal.org/article/S0016-5085(14)62437-9/pdf

4 **Basseri B**, Vasiliauskas EA, Chan O, Wang HL, Basseri RJ, Pimentel M, Soffer E, Conklin JL. Evaluation of peripapillary lymphocytosis and lymphocytic esophagitis in adult inflammatory bowel disease. *Gastroenterol Hepatol* (N Y) 2013; **9**: 505-511 [PMID: 24719598]

5 **Haque S**, Genta RM. Lymphocytic oesophagitis: clinicopathological aspects of an emerging condition. *Gut* 2012; **61**: 1108-1114 [PMID: 22157333 DOI: 10.1136/gutjnl-2011-301014]

6 **Purdy JK**, Appelman HD, Golembeski CP, McKenna BJ. Lymphocytic esophagitis: a chronic or recurring pattern of esophagitis resembling allergic contact dermatitis. *Am J Clin Pathol* 2008; **130**: 508-513 [PMID: 18794041 DOI: 10.1309/D3PCF6D6YYMQRX9A]

7 **Cohen S**, Saxena A, Waljee AK, Piraka C, Purdy J, Appelman H, McKenna B, Elmunzer BJ, Singal AG. Lymphocytic esophagitis: a diagnosis of increasing frequency. *J Clin Gastroenterol* 2012; **46**: 828-832 [PMID: 22751335 DOI: 10.1097/MCG.0b013e3182500de8]

8 **Xue Y**, Suriawinata A, Liu X, Li Z, Gabbard S, Rothstein R, Lacy B, Lisovsky M. Lymphocytic Esophagitis With CD4 T-cell-predominant Intraepithelial Lymphocytes and Primary Esophageal Motility Abnormalities: A Potential Novel Clinicopathologic Entity. *Am J Surg Pathol* 2015; **39**: 1558-1567 [PMID: 26379147 DOI: 10.1097/PAS.0000000000000493]

9 **Basseri B**, Levy M, Wang HL, Shaye OA, Pimentel M, Soffer EE, Conklin JL. Redefining the role of lymphocytes in gastroesophageal reflux disease and eosinophilic esophagitis. *Dis Esophagus* 2010; **23**: 368-376 [PMID: 20353445 DOI: 10.1111/j.1442-2050.2010.01050.x]

10 **Ronkainen J**, Walker MM, Aro P, Storskrubb T, Talley NJ, Ahmed ZB, Salter V, Vieth M, Agréus L. Lymphocytic oesophagitis, a condition in search of a disease? *Gut* 2012; **61**: 1776 [PMID: 22490527 DOI: 10.1136/gutjnl-2012-302329]

11 **Conner JR**, Sanchez CA, Reid BJ, Vaughan TL, Blount PL, Wang

HH, Odze RD, Srivastava A. Lymphocytic esophagitis in Barrett's esophagus: correlation with patient symptoms and risk factors. *Mod Pathol* 2014; **27**: 169A

12 **Ebach DR**, Vanderheyden AD, Ellison JM, Jensen CS. Lymphocytic esophagitis: a possible manifestation of pediatric upper gastrointestinal Crohn's disease. *Inflamm Bowel Dis* 2011; **17**: 45-49 [PMID: 20848529 DOI: 10.1002/ibd.21347]

13 **Sutton LM**, Heintz DD, Patel AS, Weinberg AG. Lymphocytic esophagitis in children. *Inflamm Bowel Dis* 2014; **20**: 1324-1328 [PMID: 24983984 DOI: 10.1097/MIB.0000000000000100]

14 **Tanaka K**, Rubio CA, Dlugosz A, Truskaite K, Befrits R, Lindberg G, Schmidt PT. Narrow-band imaging magnifying endoscopy in adult patients with eosinophilic esophagitis/esophageal eosinophilia and lymphocytic esophagitis. *Gastrointest Endosc* 2013; **78**: 659-664 [PMID: 23827349 DOI: 10.1016/j.gie.2013.05.025]

15 **Mandaliya R**, Dimarino AJ, Cohen S. Lymphocytic esophagitis mimicking eosinophilic esophagitis. *Ann Gastroenterol* 2012; **25**: 355-357 [PMID: 24714246]

16 **Kasirye Y**, John A, Rall C, Resnick J. Lymphocytic esophagitis presenting as chronic dysphagia. *Clin Med Res* 2012; **10**: 83-84 [PMID: 22031480 DOI: 10.3121/cmr.2011.1009]

17 **Chande N**, McDonald JW, Macdonald JK. Interventions for treating lymphocytic colitis. *Cochrane Database Syst Rev* 2008; **(2)**: CD006096 [PMID: 18425936 DOI: 10.1002/14651858.CD006096.pub3]

18 **Konikoff MR**, Noel RJ, Blanchard C, Kirby C, Jameson SC, Buckmeier BK, Akers R, Cohen MB, Collins MH, Assa'ad AH, Aceves SS, Putnam PE, Rothenberg ME. A randomized, double-blind, placebo-controlled trial of fluticasone propionate for pediatric eosinophilic esophagitis. *Gastroenterology* 2006; **131**: 1381-1391 [PMID: 17101314 DOI: 10.1053/j.gastro.2006.08.033]

19 **Miehlke S**, Madisch A, Karimi D, Wonschik S, Kuhlisch E, Beckmann R, Morgner A, Mueller R, Greinwald R, Seitz G, Baretton G, Stolte M. Budesonide is effective in treating lymphocytic colitis: a randomized double-blind placebo-controlled study. *Gastroenterology* 2009; **136**: 2092-2100 [PMID: 19303012 DOI: 10.1053/j.gastro.2009.02.078]

20 **Hendy PJ**, Wong DS, Florin TH. Spontaneous oesophageal perforation: an unreported complication of lymphocytic oesophagitis. *Gut* 2013; **62**: 1668-1669 [PMID: 23850714 DOI: 10.1136/gutjnl-2013-305455]

P- Reviewer: Homan M, Quigley E, Romano C **S- Editor**: Kong JX
L- Editor: A **E- Editor**: Wu HL

World Journal of Clinical Cases

Submit a Manuscript: http://www.wjgnet.com/esps/
Help Desk: http://www.wjgnet.com/esps/helpdesk.aspx
DOI: 10.12998/wjcc.v4.i12.419

World J Clin Cases 2016 December 16; 4(12): 419-422
ISSN 2307-8960 (online)

CASE REPORT

Primary pediatric mid-brain lymphoma: Report of a rare pediatric tumor in a rare location

Rony Benson, Supriya Mallick, Suvendu Purkait, Vaishali Suri, K P Haresh, Subhash Gupta, Dayanand Sharma, Pramod Kumar Julka, Goura Kishore Rath

Rony Benson, K P Haresh, Subhash Gupta, Dayanand Sharma, Pramod Kumar Julka, Goura Kishore Rath, Department of Radiotherapy, All India Institute of Medical Sciences, New Delhi 110029, India

Supriya Mallick, Department of Radiation Oncology, All India Institute of Medical Sciences, New Delhi 110029, India

Suvendu Purkait, Vaishali Suri, Department of Pathology, All India Institute of Medical Sciences, New Delhi 110029, India

Author contributions: All the authors contributed to the paper.

Institutional review board statement: The study was cleared by Institutional Review Board (IRB-AIIMS, New Delhi).

Informed consent statement: Consent was obtained from patient before starting treatment.

Conflict-of-interest statement: None of the authors have any conflict of interest.

Manuscript source: Unsolicited manuscript

Correspondence to: Dr. Supriya Mallick, MD, Senior Research Associate, Department of Radiation Oncology, All India Institute of Medical Sciences, Ansari Nagar, New Delhi 110029, India. drsupriyamallick@gmail.com
Telephone: +91-98-99448450
Fax: +91-11-26589243

Received: May 15, 2016
Peer-review started: May 17, 2016
First decision: July 11, 2016
Revised: August 16, 2016
Accepted: September 21, 2016
Article in press: September 22, 2016
Published online: December 16, 2016

Abstract

Primary central nervous system lymphoma (PCNSL) is a rare disease in pediatric age group. A thirteen-year-old male child presented with complaints of headache for six months, vomiting and diplopia for three days. Magnetic resonance imaging of the brain showed a single lesion of 1.7 cm × 1.6 cm × 1.6 cm in the mid brain and tectum. He underwent a gross total resection of the tumor. The histopathological evaluation revealed B cell high grade non Hodgkin lymphoma. The patient was treated with High dose methotrexate and cranio spinal radiation. The patient was alive without disease 12 mo after completion of treatment. This case highlights importance of keeping PCNSL as differential in brain stem lesions of pediatric patients also. Radiation and chemotherapy remains the most important treatment for such patients.

Key words: Primary; Midbrain; Lymphoma; Paediatric

Core tip: Primary central nervous system lymphoma (PCNSL) in pediatric population is an uncommon disease. In addition location in the brainstem is far less common. We are reporting a rare case of PCNSL in the brain stem location in a 13-year-old patient. Brain stem lesions are not generally considered for lymphoma. This case highlights importance of keeping brainstem lymphoma as a differential.

Benson R, Mallick S, Purkait S, Suri V, Haresh KP, Gupta S, Sharma D, Julka PK, Rath GK. Primary pediatric mid-brain lymphoma: Report of a rare pediatric tumor in a rare location. *World J Clin Cases* 2016; 4(12): 419-422 Available from: URL: http://www.wjgnet.com/2307-8960/full/v4/i12/419.htm DOI: http://dx.doi.org/10.12998/wjcc.v4.i12.419

INTRODUCTION

Primary central nervous system lymphoma (PCNSL) most commonly occurs in the age group of 50-70 years and is rare in pediatric age group[1,2]. Tectum (midbrain) is a very rare site of PCNSL. Here were report a case of primary midbrain lymphoma in a 13-year-old child.

CASE REPORT

A 13-year-old male child was evaluated with complaints of headache for six months, vomiting and diplopia for three days. The child was evaluated with a contrast enhanced magnetic resonance imaging (MRI) of the brain which showed a single lesion 1.7 cm × 1.6 cm × 1.6 cm in the mid brain and tectum with intense contrast enhancement and hydrocephalus. The lesion was mildly hypo-intense in T1 and heterogeneously hyper-intense on T2W image with few hypo-intense areas. There was edema extending to mid part of pons (Figure 1). With a diagnosis of focal midbrain glioma, the patient underwent a ventriculo-peritoneal shunt and gross total excision of the tumor. Light microscopic examination of the lesion showed diffuse infiltration by atypical large lymphoid cells (immunopositive for leukocyte common antigen) having round nucleus with scanty cytoplasm. The cells are immunopositive for CD20 and CD79a (B-Cell markers) while negative for CD3 (T-Cell marker) and MPO (Myeloid marker). The histopathological evaluation revealed B cell high grade non Hodgkin lymphoma (Figure 2).

Postoperative MRI revealed no residual mass. MRI screening of the spine did not reveal any drop metastasis or lesion. Cerebro spinal fluid (CSF) cytology was done and showed lymphoma deposits. The bone marrow biopsy showed normal hematopoesis cell. Ophthalmic evaluation did not reveal any vitreous lesions and serology for HIV 1 and 2 was negative. Whole body positron emission tomography (PET-CT) showed no abnormal fluro-deoxy glucose avid areas except inflammatory lymph node in mesentery.

Patient was planned for adjuvant chemotherapy with high dose methotrexate. Methotrexate was given at a dose of 3.5 g/m^2 with adequate hydration and Leucovorin rescue. The patient received 6 cycles of chemotherapy with high dose methotrexate and craniospinal irradiation. The dose of craniospinal irradiation planned was 36 Gray in 18 fractions over 3.5 wk followed by boost to the whole cranium for 9 Gray in 5 fractions over 1 wk. The patient is surviving without disease 1 year after treatment.

DISCUSSION

PCNSL is a very rare tumor in children. Pediatric cases account for about 1.5% of cases of primary CNS lymphoma reported to the brain tumor registry of Japan (1969-1990)[2]. Patients with human immune deficiency virus infection are at a higher risk for development of primary CNS lymphoma[3].

Pediatric PCNSL are different from adult group in that they are more frequently occurring in the posterior fossa (33.5% *vs* 9%) and have higher incidence of meningeal metastasis[4].

The majority of the patients of PCNSL have histology of diffuse large B-cell lymphoma (DLBCL). About 10% of the patients may have other histologies like Burkitts Lymphoma, indolent B-cell lymphomas and T cell lymphoma[1]. EBV may be seen associated with DLBCL of the CNS and may be more commonly associated in non-immune compromised patients[5]. Contrast enhanced MRI of the brain, spine screening MRI, CSF cytology, ophthalmic evaluation whole body CT/PET CT, viral markers are the important investigations in management of PCNSL.

It has been reported that adult PCNSL occurs in supra tentorial location in majority of patients with posterior fossa as a location of tumor only in 7% of the cases[6]. Only 3% cases have been reported to have a brainstem involvement and majority of such lesions are of T-cell lineage. Contrast enhanced MRI is the preferred imaging modality in these cases of PCNSL. Approximately 90% of these cases present with contrast enhancing lesions[6]. Ring like enhancement is rarely observed in immune competent patients, but commonly found in immune compromised patients[7]. The lesions may be multiple especially in immune compromised patients.

PCNSL is a highly radiosensitive and chemo sensitive infiltrative tumor. Steroids may be deferred till the diagnosis of PCNSL is confirmed. Surgery is helpful in confirming the diagnosis. A median survival of 4.6 mo has been reported for patients treated with surgical excision alone. Whole brain radiotherapy has conferred a median survival of 14.5-18 mo and a 5-year survival of 35%. However, patients treated with radiation alone experience early local failure. This finding paved for the combined modality therapy of chemotherapy and radiation therapy in sequential manner. Presently, high dose methotrexate forms the back bone of therapy in PCNSL with low dose whole brain radiation having important role in long term disease control[8]. Cytosine arabinoside has been added to high dose methotrexate to improve survival in this group of patients[9]. In another series 5-year event free survival was reported to be 70% in patients treated with combination chemotherapy of high dose methotrexate and Cytosine arabinoside without radiotherapy[10]. A radiation dose

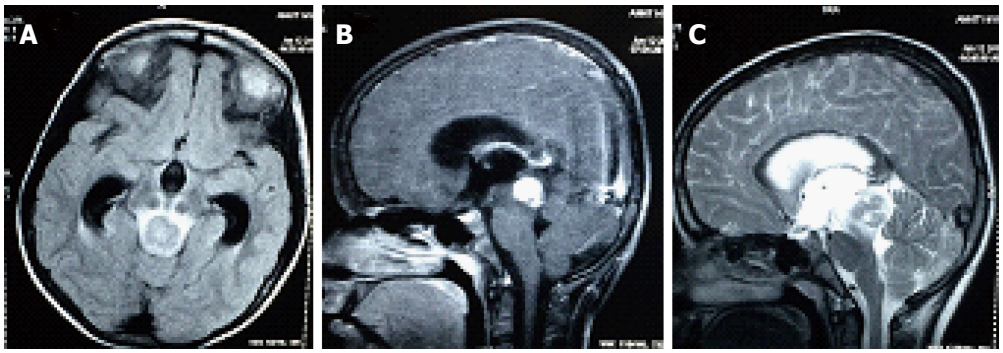

Figure 1 Axial and sagittal section of contrast enhanced magnetic resonance imaging. It shows a lesion 1.7 cm × 1.6 cm × 1.6 cm in the mid brain and tectum with intense contrast enhancement. The lesion was mildly hypo-intense in T1 and heterogeneously hyper-intense on T2W image with few hypo-intense areas. There edema was extending to mid part of pons.

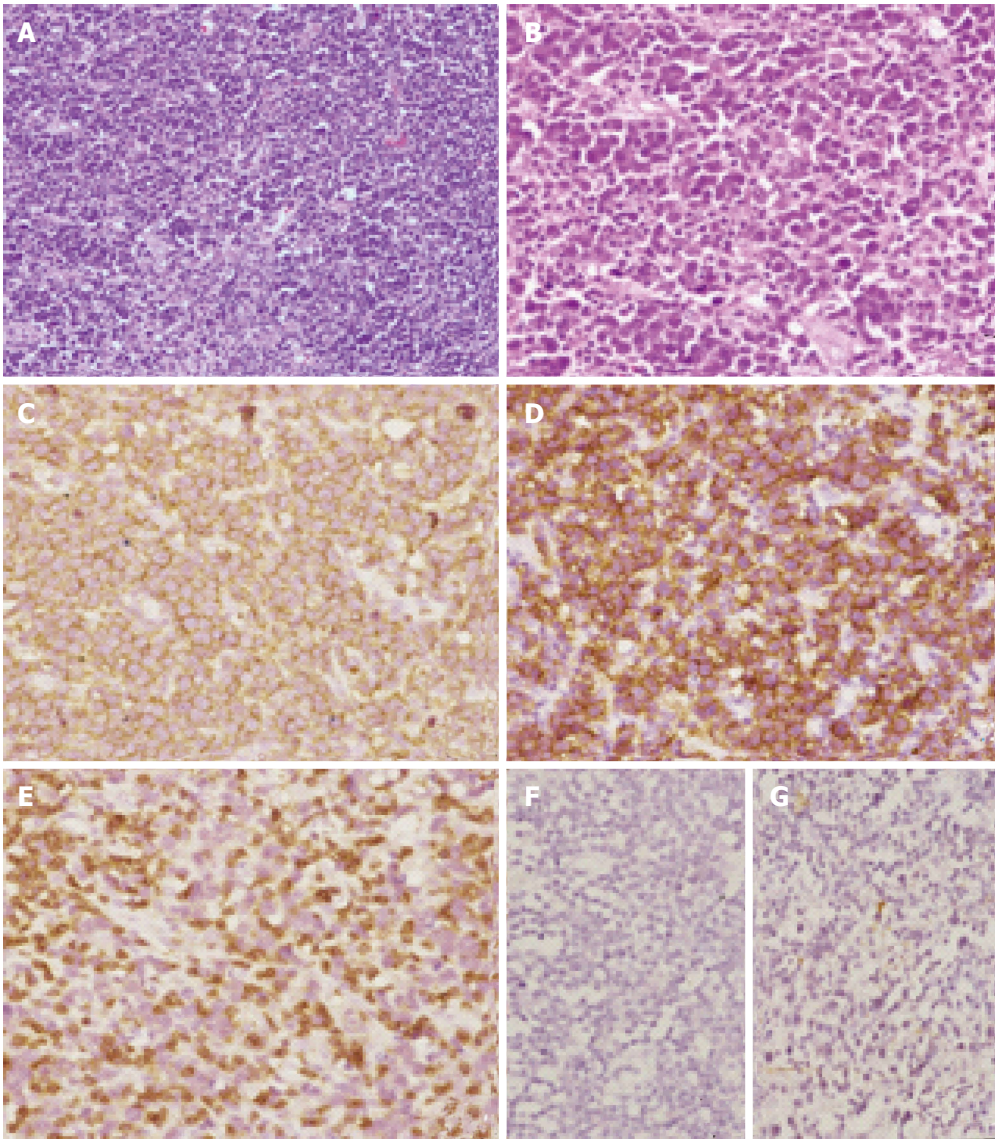

Figure 2 The histopathological evaluation revealed B cell high grade non Hodgkin lymphoma. A, B: Photomicrograph showing infiltration of large atypical lymphoid cell with interspersed lymphocytes; C: The tumor cells were immunopositive for LCA; D: CD20; E: While negative for CD3; F: Synaptophysin.

of 40-45 Gray to the whole cranium is recommended. Cranio spinal irradiation and intra thecal methotrexate is useful in patients with spinal drop metastasis or CSF dissemination. But this aggressive treatment approach is associated with significant toxicity. Neuro cognitive effects, hormonal imbalances, growth abnormalities and

secondary malignancies are very important when we treat a pediatric case with such aggressive approach[2].

In conclusion, lymphoma in mid brain in pediatric age group is extremely rare. Chemotherapy forms the most important part of therapy for such cases. Low dose whole brain radiotherapy may be considered for improving long term disease control.

COMMENTS

Clinical diagnosis

Focal midbrain glioma.

Differential diagnosis

Tectal glioma, primitive neuro ectodermal tumor.

Laboratory diagnosis

B cell lymphoma (DLBCL).

Imaging diagnosis

Focal midbrain glioma.

Pathological diagnosis

DLBCL.

Treatment

Gross total excision, high dose methotrexate based 6 cycles of chemotherapy, cranio spinal irradiation.

Peer-review

This is a very rare location of a lymphoma in a teenager. The case presentation is interesting.

REFERENCES

1 **Korfel A**, Schlegel U. Diagnosis and treatment of primary CNS lymphoma. *Nat Rev Neurol* 2013; **9**: 317-327 [PMID: 23670107 DOI: 10.1038/nrneurol.2013.83]

2 **Abla O**, Weitzman S, Blay JY, O'Neill BP, Abrey LE, Neuwelt E, Doolittle ND, Baehring J, Pradhan K, Martin SE, Guerrera M, Shah S, Ghesquieres H, Silver M, Betensky RA, Batchelor T. Primary CNS lymphoma in children and adolescents: a descriptive analysis from the International Primary CNS Lymphoma Collaborative Group (IPCG). *Clin Cancer Res* 2011; **17**: 346-352 [PMID: 21224370 DOI: 10.1158/1078-0432.CCR-10-1161]

3 **Rodriguez MM**, Delgado PI, Petito CK. Epstein-Barr virus-associated primary central nervous system lymphoma in a child with the acquired immunodeficiency syndrome. A case report and review of the literature. *Arch Pathol Lab Med* 1997; **121**: 1287-1291 [PMID: 9431321]

4 **Kai Y**, Kuratsu J, Ushio Y. Primary malignant lymphoma of the brain in childhood. *Neurol Med Chir* (Tokyo) 1998; **38**: 232-237 [PMID: 9631639 DOI: 10.2176/nmc.38.232]

5 **Preusser M**, Woehrer A, Koperek O, Rottenfusser A, Dieckmann K, Gatterbauer B, Roessler K, Slavc I, Jaeger U, Streubel B, Hainfellner JA, Chott A. Primary central nervous system lymphoma: a clinicopathological study of 75 cases. *Pathology* 2010; **42**: 547-552 [PMID: 20854073 DOI: 10.3109/00313025.2010.508786]

6 **Sutherland T**, Yap K, Liew E, Tartaglia C, Pang M, Trost N. Primary central nervous system lymphoma in immunocompetent patients: a retrospective review of MRI features. *J Med Imaging Radiat Oncol* 2012; **56**: 295-301 [PMID: 22697326 DOI: 10.1111/j.1754-9485.2012.02366.x]

7 **Johnson BA**, Fram EK, Johnson PC, Jacobowitz R. The variable MR appearance of primary lymphoma of the central nervous system: comparison with histopathologic features. *AJNR Am J Neuroradiol* 1997; **18**: 563-572 [PMID: 9090424]

8 **Milgrom SA**, Yahalom J. The role of radiation therapy in the management of primary central nervous system lymphoma. *Leuk Lymphoma* 2015; **56**: 1197-1204 [PMID: 25219590 DOI: 10.3109/10428194.2014.961014]

9 **DeAngelis LM**, Yahalom J, Heinemann MH, Cirrincione C, Thaler HT, Krol G. Primary CNS lymphoma: combined treatment with chemotherapy and radiotherapy. *Neurology* 1990; **40**: 80-86 [PMID: 2296388 DOI: 10.1212/WNL.40.1.80]

10 **Abla O**, Sandlund JT, Sung L, Brock P, Corbett R, Kirov I, Griffin TC, Blaser S, Weitzman S. A case series of pediatric primary central nervous system lymphoma: favorable outcome without cranial irradiation. *Pediatr Blood Cancer* 2006; **47**: 880-885 [PMID: 16365864 DOI: 10.1002/pbc.20736]

P- Reviewer: Alshehabi Z, Delwail V, Kupeli S, Mihaila RG
S- Editor: Qiu S **L- Editor**: A **E- Editor**: Wu HL

Published by **Baishideng Publishing Group Inc**
8226 Regency Drive, Pleasanton, CA 94588, USA
Telephone: +1-925-223-8242
Fax: +1-925-223-8243
E-mail: bpgoffice@wjgnet.com
Help Desk: http://www.wjgnet.com/esps/helpdesk.aspx
http://www.wjgnet.com