


World Journal of *Clinical Cases*

World J Clin Cases 2015 October 16; 3(10): 861-925



Editorial Board

2012-2016

The *World Journal of Clinical Cases* Editorial Board consists of 519 members, representing a team of worldwide experts in clinical medical research. They are from 55 countries, including Albania (1), Australia (8), Bangladesh (3), Belgium (3), Botswana (1), Brazil (10), Bulgaria (1), Canada (11), China (24), Colombia (2), Croatia (4), Cuba (1), Czech (2), Egypt (5), France (5), Germany (14), Greece (15), Hungary (1), India (56), Indonesia (1), Iran (11), Iraq (1), Ireland (1), Israel (5), Italy (56), Japan (33), Lebanon (3), Malaysia (2), Mexico (1), Morocco (2), Netherlands (3), New Zealand (1), Nigeria (1), Oman (1), Pakistan (1), Peru (2), Poland (4), Portugal (3), Qatar (1), Romania (3), Saudi Arabia (4), Serbia (6), Singapore (3), Slovakia (2), Slovenia (1), South Korea (27), Spain (11), Sudan (1), Taiwan (21), Thailand (2), Trinidad and Tobago (1), Tunisia (1), Turkey (28), United Kingdom (26), and United States (82).

EDITORS-IN-CHIEF

Giuseppe Di Lorenzo, *Naples*
Jan Jacques Michiels, *Rotterdam*
Sandro Vento, *Gaborone*
Shuhei Yoshida, *Boston*

GUEST EDITORIAL BOARD MEMBERS

Hung-Yang Chang, *Hsinchu*
Ning-Chia Chang, *Kaohsiung*
Yao-Lung Chang, *Taoyuan*
Chang-Han Chen, *Kaohsiung*
Shao-Tsu Chen, *Hualien*
Yen-Hsu Chen, *Kaohsiung*
Kuen-Bao Chen, *Taichung*
Yi-Ming Chen, *Taipei*
Chih-Chien Chin, *Taoyuan*
I-Ching Chou, *Taichung*
Jun-Te Hsu, *Taoyuan*
Shu-Pin Huang, *Kaohsiung*
Chi-Wen Juan, *Taichung*
Chih-Yuan Lin, *Taipei*
Chiung-Chyi Shen, *Taichung*
Jim Jinn-Chyuan Sheu, *Taichung*
Bing-Wen Soong, *Taipei*
Hwei-Fang Tien, *Taipei*
Rong Kung Tsai, *Hualien*
Han-Ping Wu, *Taichung*
Hsu-Heng Yen, *Changhua*

MEMBERS OF THE EDITORIAL BOARD



Albania

Ridvan Hamid Alimehmeti, *Tirana*



Australia

Roy Gary Beran, *Sydney*
Jian Cheng, *Melbourne*
Devang Jitendra Desai, *Brisbane*
Manuel B Graeber, *Sydney*
Finlay Alistair Macrae, *Victoria*
Harrison Scott Weisinger, *Victoria*
Harunor Rashid, *Sydney*



Bangladesh

Forhad Hossain Chowdhury, *Dhaka*
Md Jafrul Hannan, *Chittagong*
Aliya Naheed, *Dhaka*



Belgium

Guy Cheron, *Brussels*
Yves Jacquemyn, *Edegem*
Jean-Yves Luc Reginster, *Angleur*



Botswana

Guy Cheron, *Brussels*



Brazil

Everson Luiz De Almeida Artifon, *Sao Paulo*
Juliano Julio Cerci, *Curitiba*

Luciano Pamplona de Góes, *Fortaleza*
Márcio Ajudarte Lopes, *Piracicaba*
Jose Mario Franco de Oliveira, *Rio de Janeiro*
Daniel Cesar de Araujo Santos, *Rio de Janeiro*
Hélio Afonso Ghizoni Teive, *Curitiba*
Eduardo Neubarth Trindade, *Porto Alegre*
Fabio Francesconi do Valle, *Manaus*
Flavia Mariana Valente, *Sao Jose do Rio Preto*



Bulgaria

Plamen Kostov Nedev, *Varna*



Canada

Mark Otto Baerlocher, *Barrie*
Kunihiko Hiraiwa, *Vancouver*
Ali Izadpanah, *Quebec*
Gang Li, *Vancouver*
Habib-Ur-Rehman, *Regina*
Abdul Qayyum Rana, *Toronto*
Consolato Sergi, *Alberta*
Rashmi Singh, *Vancouver*
Jennifer L Spratlin, *Alberta*
Ted L Tewfik, *Montreal*
Sam Wiseman, *Vancouver*



China

Shiu-Yin Cho, *Hong Kong*
Lian Duan, *Beijing*
Lee Fung Yee Janet, *Hong Kong*
David Harolo Garfield, *Shanghai*

Yong-Song Guan, *Chengdu*
 Guo-Rong Han, *Nanjing*
 Bin Jiang, *Beijing*
 Alice Pik Shan Kong, *Hong Kong*
 Jian-Jun Li, *Beijing*
 De-Zhi Mu, *Chengdu*
 Simon Siu-Man Ng, *Hong Kong*
 Shi-Su Sheng, *Beijing*
 Huai-Yin Shi, *Beijing*
 Xue-Ying Sun, *Harbin*
 Xue-Rui Tan, *Shantou*
 Gang Wang, *Chengdu*
 Feng Wang, *Shanghai*
 Nian-Song Wang, *Shanghai*
 Ge Xiong, *Beijing*
 Zheng-Feng Yin, *Shanghai*
 Qing Zhang, *Jingzhou*
 Ming-Hua Zheng, *Wenzhou*
 Jun Zhong, *Shanghai*
 Yan-Ming Zhou, *Xiamen*



Colombia

Iván Darío Vélez Bernal, *Medellín*
 Carlos Alberto Calderón-Ospina, *Bogota*



Croatia

Iva Brcic, *Zagreb*
 Srđana Čulić, *Spinciceva*
 Tomislav Kulis, *Zagreb*
 Zvonimir Lovrić, *Zagreb*



Cuba

Alain Cruz Portelles, *Holguin*



Czech

David Bludovský, *Plzen*
 Antonin Marik, *Prague*



Egypt

Farid Mohammed Sabry El-Askary, *Cairo*
 Reda Abd Elhady Hemida, *Mansoura*
 Sherifa Ahmad Hamed, *Assiut*
 Ahmad Abd-Elgawad Nofal, *Zagazig*
 Mohamed Ismail Seleem, *Cairo*



France

I Alain Braillon, *Amiens*
 Jean-François Bosset, *Besançon*
 Isabelle Andrée Chemin, *Lyon*
 Emile Jean-François, *Boulogne*
 Christophe Martinaud, *Clamart*



Germany

Sebastian Decker, *Hannover*
 Andreas Martin Fette, *Weissach im Tal*
 Michael Froehner, *Dresden*
 Wolf Christoph Mueller, *Leipzig*
 Andres Hao Ming Neuhaus, *Berlin*
 Arndt Hartmann, *Erlangen*
 Dirk M Hermann, *Essen*
 Karl-Anton Kreuzer, *Berlin*
 Ingo Stefan Nölte, *Mannheim*
 Andreas G Schreyer, *Regensburg*
 Crispin Schneider, *Bristol*
 Hans-Joachim Schmoll, *Halle*
 Martin Paul Schencking, *Witten*
 Mathias Z Strowski, *Berlin*



Greece

Andrew P Andonopoulos, *Patras*
 Dimitrios Daoussis, *Patras*
 Ioanna Dimopoulou, *Athens*
 Moses S Elisaf, *Ioannina*
 Costas Fourtounas, *Rio-Patras*
 Olga-Elpis Kolokitha, *Thessaloniki*
 Sophia Lionaki, *Athens*
 Marilita M Moschos, *Athens*
 Michail N Varras, *Athens*
 Nikolaos Papanas, *Alexandroupolis*
 Athanasios Papatsoris, *Athens*
 Zervoudis Stephane, *Athens*
 Konstantinos Tepetes, *Larissa*
 Apostolos Tsapas, *Thessaloniki*
 Dimitrios Vavilis, *Thessaloniki*



Hungary

Tibor Hortobágyi, *Debrecen*



India

Subrat Kumar Achaya, *New Delhi*
 Amit Arvind Agrawal, *Nasik*
 Hena A Ansari, *Aligarh*
 MS Ansari, *Lucknow*
 Laxminarayan Bhadrani, *Calicut*
 Ashu Seith Bhalla, *New Delhi*
 Sachin Anil Borkar, *New Delhi*
 Bhuvan Chanana, *New Delhi*
 Kanishka Das, *Bangalore*
 Reena Das, *Chandigarh*
 Nilay Kanti Das, *Kolkata*
 Deep Dutta, *Kolkata*
 Mimi Gangopadhyay, *Siliguri*
 Rakesh Garg, *New Delhi*
 Sandeep Grover, *Chandigarh*
 Mahendra Singh Hada, *Rajasthan*
 P Hazarika, *Manipal*
 Sachin Bhalchandra Ingle, *Latur*
 Parwez Sajad Khan, *Srinagar*
 Pradeep Kumar, *Bangalore*
 Amol Lunkad, *Pune*

Dale A Maharaj, *Trinidad*
 Nikhil Marwah, *Rajasthan*
 Meena Gupta, *New Delhi*
 Amit Kumar Mishra, *Indore*
 Soma Mukherjee, *Mumbai*
 Deb Sanjay Nag, *Jamshedpur*
 Kushal Naha, *Karnataka*
 Janardhanan C Narayanaswamy, *Bangalore*
 Soubhagya Ranjan Nayak, *Nadia*
 Narendra Pamidi, *Karnataka*
 Murali Prabhakaran Vettath, *Kerala*
 Samir Kumar Praharaj, *Karnataka*
 Peralam Yegneswaran Prakash, *Manipal*
 C S Pramesh, *Mumbai*
 Kishore Puthezhath, *Kerala*
 Harbans Singh Randhawa, *Delhi*
 M Rangarajan, *Coimbatore*
 Sayantan Ray, *Kolkata*
 Bharat Rekhi, *Maharashtra*
 S Sharija, *Thiruvananthapuram*
 Dhananjaya Sabat, *New Delhi*
 Sachin Chakradhar Sarode, *Pune*
 Ashish Sharma, *Coimbatore*
 Hakim Irfan Showkat, *Srinagar*
 Rikki Singal, *Mullana*
 Deepak Kumar Singh, *Lucknow*
 Yashpal Singh, *Meerut*
 Naorem Gopendro Singh, *New Delhi*
 Shyam Sundar, *Varanasi*
 Naveen S Tahasildar, *Hubli*
 Devinder Mohan Thappa, *Pondicherry*
 Pradeep Vaideeswar, *Mumbai*
 Mukul Vij, *Kanpur*
 Rajesh Vijayvergiya, *Chandigarh*
 B Viswanatha, *Bangalore*



Indonesia

Coen Pramono, *Surabaya*



Iran

Masoud Amiri, *Shahrekord*
 Mostafa Ghanei, *Tehran*
 Mahdi Malekpour, *Tehran*
 Setareh Mamishi, *Tehran*
 Afshin Mohammadi, *Urmia*
 Seyyed Amin Ayatollahi Mousavi, *Kerman*
 Mohammad Taher Rajabi, *Tehran*
 Amin Saburi, *Tehran*
 Maryam Sahebari, *Mashhad*
 Payman Vahedi, *Mashad*
 Amir Reza Vosoughi, *Shiraz*



Iraq

Bassim Irheim Mohammad, *Al-Qadisiya*



Ireland

Robbie Seton Rowan Woods, *Dublin*

**Israel**

Nimer Najib Assy, *Safed*
 Gil Bar-Sela, *Haifa*
 Itzhak Braverman, *Hadera*
 Eyal Itshayek, *Jerusalem*
 Gary Michael Ginsberg, *Jerusalem*

**Italy**

Giovanni Addolorato, *Rome*
 Piero Luigi Almasio, *Palermo*
 Francesco Angelico, *Rome*
 Marialuisa Appetecchia, *Rome*
 Valeria Barresi, *Messina*
 Gabrio Bassotti, *Roma Sisto*
 Paolo Boffano, *Turin*
 Maria Luisa Brandi, *Florence*
 Michelangelo Buonocore, *Pavia*
 Giovanni Cammarota, *Rome*
 Isidoro Di Carlo, *Catania*
 Andrea Ciorba, *Ferrara*
 Lucio Cocco, *Bologna*
 Carlo Colosimo, *Rome*
 Alfredo Conti, *Messina*
 Giovanni Conzo, *Naples*
 Gennaro Cormio, *Bari*
 Alessandro Federico, *Naples*
 Gabriella Maria Ferrandina, *Rome*
 Davide Firinu, *Cagliari*
 Caterina Foti, *Bari*
 Gennaro Galizia, *Naples*
 Silvio Garattini, *Milan*
 Giampietro Gasparini, *Roma*
 Luigi De Gennaro, *Rome*
 Giorgio Ghilardi, *Milano*
 Domenico Girelli, *Verona*
 Biondi Zoccai Giuseppe, *Latina*
 Carlo Lajolo, *Rome*
 Alessandro Landi, *Rome*
 Salvatore Leonardi, *Catania*
 Carmela Loguerzio, *Naples*
 Marianna Luongo, *Potenza*
 Zippi Maddalena, *Rome*
 Roberto Manfredini, *Ferrara*
 Annunziato Mangiola, *Roma*
 Elia De Maria, *Carpi*
 Marco Mazzocchi, *Perugia*
 Roberto Luca Meniconi, *Rome*
 Marco Milone, *Naples*
 Paolo Nozza, *Genoa*
 Pier Paolo Panciani, *Brescia*
 Desire' Pantalone, *Firenze*
 Raffale Pezzilli, *Bologna*
 Giorgina Barbara Piccoli, *Torino*
 Roberto Pola, *Rome*
 Marco Romano, *Napoli*
 Gianantonio Saviola, *Castel Goffredo*
 Stefania Scala, *Naples*
 Leonardo A Sechi, *Udine*
 Matteo Tebaldi, *Ferrara*
 Riccardina Tesse, *Bari*

Tiziano Testori, *Milano*
 Gian Vincenzo Zuccotti, *Milan*

**Japan**

Ukei Anazawa, *Ichikwa-shi*
 Junichi Asaumi, *Okayama*
 Takashi Asazuma, *Saitama-ken*
 Norihiro Furusyo, *Fukuoka*
 Masaru Ishida, *Yokohama*
 Tatsuaki Ishiguro, *Tokyo*
 Hajime Isomoto, *Nagasaki*
 Yokoyama Junkichi, *Sendai*
 Keita Kai, *Saga*
 Terumi Kamisawa, *Tokyo*
 Tatsuo Kanda, *Niigata*
 Shigeyuki Kawa, *Matsumoto*
 Kazushi Kishi, *Wakayama-city*
 Satoru Kyo, *Ishikawa*
 Nozomi Majima, *Osaka*
 Kenji Miki, *Tokyo*
 Atsushi Nakajima, *Tokyo*
 Rui Niimi, *Tsu city*
 Masaharu Nomura, *Tokyo*
 Kenoki Ohuchida, *Fukuoka*
 Morishita Ryuichi, *Osaka*
 Yosuke Sato, *Niigata*
 Mitsushige Sugimoto, *Hamamatsu*
 Haruhiko Sugimura, *Hamamatsu*
 Keisuke Uehara, *Nagoya*
 Manabu Watanabe, *Tokyo*
 Takayuki Yamamoto, *Yokkaichi*
 Yoshihito Yokoyama, *Hiroaki*
 Junkichi Yokoyama, *Tokyo*
 Han-Seung Yoon, *Nagano*
 Kiyoshi Yoshino, *Osaka*
 Yuichi Kasai, *Tsu city*
 Yuzuru Niibe, *Sagamihara-shi*

**Lebanon**

Maroun Miled Abou-Jaoude, *Beirut*
 Kassem A Barada, *Beirut*
 Raja Sawaya, *Beirut*

**Malaysia**

Iman Salahshourifar, *Kubang Kerian*
 Mohamad Nasir Shafiee, *Kuala Lumpur*

**Mexico**

Ernesto Roldan-Valadez, *Mexico*

**Morocco**

Alae El Koraichi, *Rabat*
 Faycal Lakhdar, *Rabat*

**Netherlands**

Sijens Paul Eduard, *Groningen*
 Paul E Sijens, *Groningen*

**New Zealand**

Rita Rita Krishnamurthi, *Auckland*

**Nigeria**

Shamsideen Abayomi Ogun, *Lagos*

**Oman**

Itrat Mehdi, *Muscat*

**Pakistan**

Sabiha Anis, *Karachi*

**Peru**

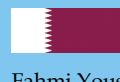Eduardo Gotuzzo, *Lima*
 Eduardo Salazar-Lindo, *Lima*

**Poland**

Łukasz Stanisław Matuszewski, *Lublin*
 Tadeusz Robak, *Ciolkowskiego*
 Adam Wysokiński, *Lodz*
 Witold Antoni Zatoński, *Warsaw*

**Portugal**

Jorge Alves, *Braga*
 Gustavo Marcondes Rocha, *Porto*
 Zacharoula Sidiropoulou, *Barreiro*

**Qatar**

Fahmi Yousef Khan, *Doha*

**Romania**

Simona Gurzu, *Targu-Mures*
 Doina Piciu, *Cluj-Napoca*
 Mugurel Constantin Rusu, *Bucharest*

**Saudi Arabia**

Ahmed Alkhani, *Riyadh*
 Iqbal Abdulaziz Bukhari, *Alkhobar*
 Mohamed Fahmy Ibrahim, *Riyadh*

Jyothi Tadakamadla, *Hyderabad*



Serbia

Ivona Milorad Djordjevic, *Nis*
Jelena Lazar Lazic, *Belgrade*
Djordje Radak, *Beograd*
Boban Stanojevic, *Belgrade*
Mihailo Ilija Stjepanovic, *Belgrade*
Momcilo Pavlovic, *Subotica*



Singapore

Wei-Sheng Chong, *Singapore*
Khek-Yu Ho, *Singapore*
Yong Kuei Lim, *Singapore*



Slovakia

Michal Mego, *Bratislava*
Ivan Varga, *Bratislava*



Slovenia

Pavel Skok, *Maribor*



South Korea

Young-Seok Cho, *UiJeongbu*
Tae Hyun Choi, *Seoul*
Yeun-Jun Chung, *Seoul*
Ki-Baik Hahm, *Seoul*
Seung-Jae Hyun, *Seongnam*
Soo Bin Im, *Bucheon*
Soung Won Jeong, *Seoul*
Choun-Ki Joo, *Seoul*
Chang Moo Kang, *Seoul*
Seung Taik Kim, *Chungbuk*
Byung-Wook Kim, *Incheon*
Myoung Soo Kim, *Seoul*
Gwi Eon Kim, *Seoul*
Gyeong-Moon Kim, *Seoul*
Hahn Young Kim, *Seoul*
Won Seog Kim, *Seoul*
Yoon Jun Kim, *Seoul*
Yun-Hee Kim, *Seoul*
Sun-Young Lee, *Seoul*
Sang Chul Lim, *Hwasun-gun*
Seung Sam Paik, *Seoul*
Jae Yong Park, *Daegu*
Jong-Ho Park, *Goyang*
Jun-Beom Park, *Seoul*
Songhae Hae Ryong, *Seoul*
Chan Sup Shim, *Seoul*
Hwaseung Yoo, *Daejeon*



Spain

Adrià Arboix, *Barcelona*

FJA Artiles, *Las Palmas de Gran Canaria*

Manuel Benito, *Madrid*

Vicente Carreño, *Madrid*

Rosa Corcoy, *Barcelona*

Exuperio Díez-Tejedor, *Madrid*

Luis Ignacio González Granado, *Madrid*

Carlos Alberto Dussan Luberth, *Torre Vieja*

Juan de Dios Molina Martín, *Madrid*

Sergio Fernández-Pello Montes, *Gijón*

Tomás Sobrino, *Santiago de Compostela*



Sudan

Samir MH Shaheen, *Khartoum*



Thailand

Sarunyou Chusri, *Songkhla*

Weekitt Kittisupamongkol, *Bangkok*



Trinidad and Tobago

Dale Andrew Maharaj, *Port of Spain*



Tunisia

Makram Koubaa, *Sfax*



Turkey

Sami Akbulut, *Diyarbakir*

Tamer Akça, *Mersin*

Cengiz Akkaya, *Bursa*

Ahmet Baydin, *Samsun*

Hasan Belli, *Istanbul*

Serbüent Gökhan Beyaz, *Sakarya*

GK Cakmak, *Kozlu Zonguldak*

Turgay Celik, *Ankara*

Yasemin Benderli Cihan, *Kayseri*

Ömür Dereci, *Ankara*

Mehmet Doganay, *Kayseri*

F Neslihan İnal Emiroğlu, *İzmir*

Aylin Türel Ermercan, *Manisa*

Kadir Ertem, *Malatya*

Aydın Gulses, *Canakkale*

Mustafa Koray Gumus, *Kayseri*

Ramazan Kahveci, *Kırıkkale*

Saadettin Kiliçkap, *Ankara*

Fatih Kucukdurmaz, *Istanbul*

Ashhan Küçükler, *Ankara*

Nuray Bayar Muluk, *Ankara*

Orhan Veli Ozkan, *Sakarya*

Zeynep Özkurt-Kayahant, *Istanbul*

Mustafa Sahin, *Ankara*

İbrahim Sakçak, *Ankara*

Feyzi Birol Sarica, *Adana*

Selim Sözen, *Kayseri*

Murat Ugurlucan, *Istanbul*



United Kingdom

Henry Dushan Atkinson, *London*

Ioannis G Baraboutis, *Cambridgeshire*

I Beegun, *London*

Ricky Harminder Bhogal, *Birmingham*

Kuntal Chakravarty, *Romford*

Deyaa Elsandabese, *Harlow*

Radwan Faraj, *Moorgate Road-Rotherham*

Babatunde Abiodun Gbolade, *Leeds*

Sanju George, *Birmingham*

David Julian Alexander Goldsmith, *London*

Nadey S Hakim, *London*

Koshy Jacob, *Boston*

Anastasios Koulaouzidis, *Edinburgh*

Andrew Richard Lisle Medford, *Bristol*

Panagiotis Peitsidis, *Southend Essex*

Rahul Tony Rao, *London*

Francis Paul Rugman, *Preston*

Khaled Maher Sarraf, *London*

Yousef Shahin, *Hull*

Alexa Shipman, *Birmingham*

Badri Man Shrestha, *Sheffield*

Herrick J Siegel, *Birmingham*

Leonello Tacconi, *London*

Jagdeep Singh Virk, *Harrow*

James Chiun Lon Wong, *Manchester*

Kimia Ziahosseini, *Liverpool*



United States

Doru Traian Alexandrescu, *San Diego*

Naim Alkhouri, *Cleveland*

Mohammad M Alsolaiman, *Orem Utah*

Bhupinder S Anand, *Houston*

Suresh J Antony, *Oregon*

Normadeane Armstrong, *Rockville Centre*

Wilbert Solomon Aronow, *Valhalla*

Hossam M Ashour, *Detroit*

Rajendra Badgaiyan, *Buffalo*

Joseph Robert Berger, *Lexington*

Dennis A Bloomfield, *New York*

Neil Box, *Denver*

Jeffrey Alan Breall, *Indianapolis*

Susana M Campos, *Boston*

Robert Carter III, *San Antonio*

Kaisorn Lee Chaichana, *Baltimore*

Antonio Joseph Chamoun, *Coatesville*

Vince Clark, *Albuquerque*

C Donald Combs, *Norfolk*

Suzanne Marie Crumley, *Houston*

Parakkal Deepak, *Evanston*

Yuchuan Ding, *Detroit*

Konstantin Hristov Dragnev, *Lebanon*

Cecilia Luminita Dragomir, *New York*

Konstantinos P Economopoulos, *Boston*

James M Ford, *Stanford*

Yun Gong, *Houston*

Zeba Hasan Hafeez, *Novato*

Ardeshtir Hakam, *Tampa*

Jaclyn Frances Hechtman, *New York*

T Patrick Hill, *New Brunswick*

Hitoshi Hirose, *Philadelphia*

Elias Jabbour, *Houston*

Robert Thomas Jensen, *Bethesda*

Huanguang Jia, *Florida*
Zhong Jiang, *Worcester*
Theodoros Kelesidis, *Los Angeles*
Kusum K Kharbanda, *Omaha*
Praveen Kumar, *Chicago*
Julius Gene Silva Latorre, *Syracuse*
Guojun Li, *Houston*
Yaling Liu, *Rochester*
Marios-Nikolaos Lykissas, *New York*
Kenneth Maiese, *Newark*
Serge Peter Marinkovic, *Lafayette*
Charles Christian Matouk, *New Haven*
Kapil Mehta, *Houston*
Zaher Merhi, *Burlington*
Ayse Leyla Mindikoglu, *Baltimore*
Roberto Nicolas Miranda, *Houston*

Majaz Moonis, *Worcester*
Assad Movahed, *Greenville*
Mohammad Reza Movahed, *Tucson*
Saleh A Naser, *Orlando*
Srinivasan Paramasivam, *New York*
Edwin Melencio Posadas, *Los Angeles*
Xiaofa Qin, *Newark*
Michel Elias Rivlin, *Jackson*
Jae Y Ro, *Houston*
Bruce Samuel Rudy, *Hershey*
Abdulaziz Sachedina, *Charlottesville*
Ravi Prakash Sahu, *Indiana*
Michael William Schlund, *Baltimore*
Eric Lee Scott, *Indianapolis*
Volney Leo Sheen, *Boston*
Ilke Sipahi, *Cleveland*

Subbaya Subramanian, *Minneapolis*
Jessica D Sun, *South San Francisco*
Ulas Sunar, *Buffalo*
Scott Tenner, *Brooklyn*
Diana Olguta Treaba, *Providence*
Richard Gary Trohman, *Chicago*
Ming C Tsai, *New York*
Vassiliy Tsytsarev, *Baltimore*
Howard J Worman, *New York*
Jun Yao, *Naperville*
Shahram Yazdani, *Los Angeles*
Panitan Yossuck, *Morgantown*
Stanley Zaslau, *Morgantown*
Sheng Zhang, *New Haven*
Xinmin Zhang, *Philadelphia*

**EDITORIAL**

- 861 Proliferative verrucous leukoplakia may initially mimic lichenoid reactions
Lopes MA, Feio P, Santos-Silva AR, Vargas PA

REVIEW

- 864 Port site infection in laparoscopic surgery: A review of its management
Sasmal PK, Mishra TS, Rath S, Meher S, Mohapatra D

MINIREVIEWS

- 872 Arrhythmogenic epilepsy and pacing need: A matter of controversy
Kepez A, Erdogan O
- 876 Disease that should be remembered: Sacrococcygeal pilonidal sinus disease and short history
Kanat BH, Sözen S

ORIGINAL ARTICLE**Retrospective Study**

- 880 Improved bowel preparation increases polyp detection and unmasks significant polyp miss rate
Papanikolaou IS, Sioulas AD, Magdalinos N, Beintaris I, Lazaridis LD, Polymeros D, Malli C, Dimitriadis GD, Triantafyllou K

Prospective Study

- 887 New tapered metallic stent for unresectable malignant hilar bile duct obstruction
Sakai Y, Tsuyuguchi T, Nishikawa T, Sugiyama H, Sasaki R, Sakamoto D, Watanabe Y, Nakamura M, Yasui S, Mikata R, Yokosuka O

CASE REPORT

- 894 Littoral cell angioma: A case report
Bailey A, Vos J, Cardinal J
- 900 Acute hepatitis after amiodarone infusion
Fonseca P, Dias A, Gonçalves H, Albuquerque A, Gama V
- 904 Novel variant syndrome associated with congenital hepatic fibrosis
Bayraktar Y, Yonem O, Varlı K, Taylan H, Shorbagi A, Sokmensuer C
- 911 Acute dapsone poisoning in a 3-year-old child: Case report with review of literature
Sunilkumar MN, Ajith TA, Parvathy VK

- 915** Mediastinal small cell carcinoma with liver and bone marrow metastasis, mimicking lymphoma
Nawarawong N, Pongpruttipan T, Aswakul P, Prachayakul V
- 920** Repeated pancreatitis-induced splenic vein thrombosis leads to intractable gastric variceal bleeding: A case report and review
Tang SH, Zeng WZ, He QW, Qin JP, Wu XL, Wang T, Wang Z, He X, Zhou XL, Fan QS, Jiang MD

Contents

World Journal of Clinical Cases
Volume 3 Number 10 October 16, 2015

ABOUT COVER

Editorial Board Member of *World Journal of Clinical Cases*, Mihailo Ilija Stjepanovic, MD, PhD, Specijalist of Pulmonary Medicine, Clinic of Pulmology, Clinical Center of Serbia, 11000 Belgrade, Serbia

AIM AND SCOPE

World Journal of Clinical Cases (*World J Clin Cases*, *WJCC*, online ISSN 2307-8960, DOI: 10.12998) is a peer-reviewed open access academic journal that aims to guide clinical practice and improve diagnostic and therapeutic skills of clinicians.

The primary task of *WJCC* is to rapidly publish high-quality Autobiography, Case Report, Clinical Case Conference (Clinicopathological Conference), Clinical Management, Diagnostic Advances, Editorial, Field of Vision, Frontier, Medical Ethics, Original Articles, Clinical Practice, Meta-Analysis, Minireviews, Review, Therapeutics Advances, and Topic Highlight, in the fields of allergy, anesthesiology, cardiac medicine, clinical genetics, clinical neurology, critical care, dentistry, dermatology, emergency medicine, endocrinology, family medicine, gastroenterology and hepatology, geriatrics and gerontology, hematology, immunology, infectious diseases, internal medicine, obstetrics and gynecology, oncology, ophthalmology, orthopedics, otolaryngology, pathology, pediatrics, peripheral vascular disease, psychiatry, radiology, rehabilitation, respiratory medicine, rheumatology, surgery, toxicology, transplantation, and urology and nephrology.

INDEXING/ABSTRACTING

World Journal of Clinical Cases is now indexed in PubMed Central, PubMed, Digital Object Identifier.

FLYLEAF

I-V

Editorial Board

EDITORS FOR THIS ISSUE

Responsible Assistant Editor: *Xiang Li*
Responsible Electronic Editor: *Xiao-Kang Jiao*
Proofing Editor-in-Chief: *Lian-Sheng Ma*

Responsible Science Editor: *Xue-Mei Gong*
Proofing Editorial Office Director: *Xiu-Xia Song*

NAME OF JOURNAL

World Journal of Clinical Cases

ISSN

ISSN 2307-8960 (online)

LAUNCH DATE

April 16, 2013

FREQUENCY

Monthly

EDITORS-IN-CHIEF

Giuseppe Di Lorenzo, MD, PhD, Professor, Genitourinary Cancer Section and Rare-Cancer Center, University Federico II of Napoli, Via Sergio Pansini, 5 Ed. 1, 80131, Naples, Italy

Jan Jacques Michiels, MD, PhD, Professor, Primary Care, Medical Diagnostic Center Rijnmond Rotterdam, Bloodcoagulation, Internal and Vascular Medicine, Erasmus University Medical Center, Rotterdam, Goodheart Institute and Foundation, Erasmus Tower, Veennos 13, 3069 AT, Erasmus City, Rotterdam, The Netherlands

Sandro Vento, MD, Department of Internal Medicine, University of Botswana, Private Bag 00713, Gaborone,

Botswana

Shuhei Yoshida, MD, PhD, Division of Gastroenterology, Beth Israel Deaconess Medical Center, Dana 509, Harvard Medical School, 330 Brookline Ave, Boston, MA 02215, United States

EDITORIAL OFFICE

Jin-Lei Wang, Director
Xiu-Xia Song, Vice Director
World Journal of Clinical Cases
Room 903, Building D, Ocean International Center, No. 62 Dongsihuan Zhonglu, Chaoyang District, Beijing 100025, China
Telephone: +86-10-85381891
Fax: +86-10-85381893
E-mail: editorialoffice@wjnet.com
Help Desk: <http://www.wjnet.com/esps/helpdesk.aspx>
<http://www.wjnet.com>

PUBLISHER

Baishideng Publishing Group Inc
8226 Regency Drive,
Pleasanton, CA 94588, USA
Telephone: +1-925-223-8242
Fax: +1-925-223-8243
E-mail: bpgoffice@wjnet.com
Help Desk: <http://www.wjnet.com/esps/helpdesk.aspx>

<http://www.wjnet.com>

PUBLICATION DATE

October 16, 2015

COPYRIGHT

© 2015 Baishideng Publishing Group Inc. Articles published by this Open Access journal are distributed under the terms of the Creative Commons Attribution Non-commercial License, which permits use, distribution, and reproduction in any medium, provided the original work is properly cited, the use is non commercial and is otherwise in compliance with the license.

SPECIAL STATEMENT

All articles published in journals owned by the Baishideng Publishing Group (BPG) represent the views and opinions of their authors, and not the views, opinions or policies of the BPG, except where otherwise explicitly indicated.

INSTRUCTIONS TO AUTHORS

Full instructions are available online at http://www.wjnet.com/2307-8960/g_info_20100722180909.htm

ONLINE SUBMISSION

<http://www.wjnet.com/esps/>

Proliferative verrucous leukoplakia may initially mimic lichenoid reactions

Marcio Ajudarte Lopes, Patricia Feio, Alan Roger Santos-Silva, Pablo Agustin Vargas

Marcio Ajudarte Lopes, Patricia Feio, Alan Roger Santos-Silva, Pablo Agustin Vargas, Oral Diagnosis Department, Semiology and Oral Pathology, Piracicaba Dental School, State University of Campinas (UNICAMP), Piracicaba, Sao Paulo 13083-970, Brazil

Author contributions: Lopes MA designed the research and wrote the paper; Feio P wrote the paper; Santos-Silva AR and Vargas PA attended the patient and reviewed the paper.

Conflict-of-interest statement: The authors declare no conflict-of-interest.

Open-Access: This article is an open-access article which was selected by an in-house editor and fully peer-reviewed by external reviewers. It is distributed in accordance with the Creative Commons Attribution Non Commercial (CC BY-NC 4.0) license, which permits others to distribute, remix, adapt, build upon this work non-commercially, and license their derivative works on different terms, provided the original work is properly cited and the use is non-commercial. See: <http://creativecommons.org/licenses/by-nc/4.0/>

Correspondence to: Marcio Ajudarte Lopes, DDS, PhD, Oral Diagnosis Department, Semiology and Oral Pathology, Piracicaba Dental School, State University of Campinas (UNICAMP), Av. Limeira, 901, Bairro Areão, Piracicaba, Sao Paulo 13083-970, Brazil. malopes@fop.unicamp.br
Telephone: +55-19-21065320
Fax: +55-19-21065218

Received: February 11, 2015
Peer-review started: February 12, 2015
First decision: May 13, 2015
Revised: June 29, 2015
Accepted: September 7, 2015
Article in press: September 8, 2015
Published online: October 16, 2015

Abstract

Proliferative verrucous leukoplakia is an intriguing disease, which occurs particularly in women aged greater

than 60 years, is not associated with tobacco and alcohol, and has a high risk of recurrence and malignant transformation. Although it is well known that the typical presentation is characterized by multifocal and verrucous white lesions, there is no description that its initial clinical presentation may simulate a lichenoid reaction.

Key words: Proliferative verrucous leukoplakia; Lichenoid reactions; Diagnosis

© **The Author(s) 2015.** Published by Baishideng Publishing Group Inc. All rights reserved.

Core tip: Although uncommon, it is important for the clinician to recognize the main features of proliferative verrucous leukoplakia in order to provide the correct diagnosis and appropriate management.

Lopes MA, Feio P, Santos-Silva AR, Vargas PA. Proliferative verrucous leukoplakia may initially mimic lichenoid reactions. *World J Clin Cases* 2015; 3(10): 861-863 Available from: URL: <http://www.wjgnet.com/2307-8960/full/v3/i10/861.htm> DOI: <http://dx.doi.org/10.12998/wjcc.v3.i10.861>

PROLIFERATIVE VERRUCOUS LEUKOPLAKIA WITH LICHENOID ASPECT

Proliferative verrucous leukoplakia (PVL) was first described in 1985 as a rare form of oral leukoplakia with a distinct clinical presentation and outcome^[1]. This condition more commonly affects non-smoking and non-drinking women, aged greater than 60 years. PVL clinically begins as flat homogenous leukoplakia, becomes multifocal and tends to develop exophytic, wart-like and verrucous areas. Besides this clinical progression, PVL also has a high tendency to recur after treatment and has a high risk of malignant

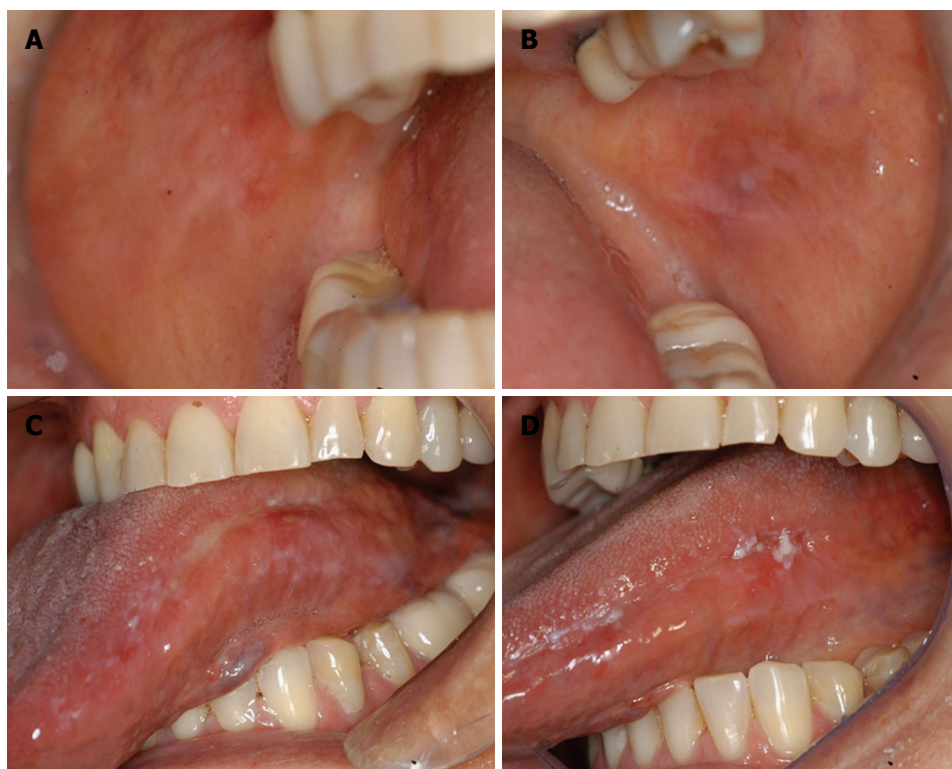

Figure 1 Lichenoid aspect on the right buccal mucosa (A), left buccal mucosa (B) and on the left lateral border of the tongue (C), leukoplakic lesions on the lateral border of the tongue (D).

transformation. According to several reports, malignant transformation rates vary between 33.3% and 100% and depend on many factors, particularly the number of patients and time of follow-up^[2-4].

The characteristics reported above are well known and well accepted by the scientific community. However, there are many doubts and controversies particularly regarding etiology, diagnostic criteria and treatment^[5]. The diagnosis of PVL is based on the retrospective association of clinical and histopathological features, which basically consist of observing progressive evolution of the lesions from a homogeneous and isolated area to a multifocal presentation with a verrucous appearance. As these manifestations take time, the diagnosis of PVL is often late.

In order to better recognize this condition, diagnostic criteria were recently proposed, which included 5 major and 4 minor criteria, as well as various combinations of these criteria^[6]. In this proposal, one of the major criteria is "the presence of verrucous area". However, according to Aguirre-Urizar^[7], the diagnosis of PVL may be delayed if verrucous appearance is considered a main diagnostic feature. In this author's opinion, the most important diagnostic criteria for this type of leukoplakia are the "proliferative" and the "multifocal" aspects. Thus, he proposed a new name for this entity: "Proliferative Multifocal Leukoplakia" with the aim of reducing under-diagnosis^[7].

When attending patients with this disorder we observed that in some cases it was very clear and simple to establish the diagnosis of PVL as the patients

had lesions with peculiar aspects. However, in other situations the lesions may have different clinical features such as erythroplakic changes^[8], which may cause some difficulty in diagnosis. In this scenario, close follow-up is necessary and will permit observation of the development of more characteristic lesions such as in the patient presented below.

In May 2011, a non-smoking and non-drinking 64-year-old female patient was referred to our oral diagnosis service complaining of a painful area on the tongue. She reported the onset of a white lesion on the left lateral border of the tongue 3 years before attending our Clinic. At that time, she had been seen by another dental team and it was initially thought to be a fungal infection and she received treatment based on topical antifungals. As no improvement was observed, a lichenoid reaction was suspected and her dental metallic (gold) restorations were replaced and a partial fixed prosthesis was inserted. However, no improvement was observed. As the lesion persisted, an incisional biopsy was performed by an otorhinolaryngologist. Microscopically, the lesion showed moderate epithelial dysplasia and a chronic inflammatory infiltrate in the underlying connective tissue. The patient was then referred for our evaluation and the first visit to our service revealed white striations with atrophic areas on the buccal mucosa bilaterally. She also had similar alterations on the left lateral border of the tongue (Figure 1). An incisional biopsy was performed on the left lateral border of the tongue and another on the right buccal mucosa. Histopathological analysis of

both sites revealed hyperkeratosis and acanthosis with mild epithelial dysplasia. According to these clinical features and the patient's symptoms, she was treated with topical clobetasol 0.05% three times a day. After 3 wk, pain relief was observed. During the follow-up period, areas of leukoplakia were observed on the left lateral border of the tongue (Figure 1). Taking these findings into account, the diagnosis of possible PVL was suggested and the patient was advised about the need for close observation. The patient remained on regular follow-up without clinical modifications. However, after 15 mo the white lesion on the left lateral border of the tongue became more diffuse and another incisional biopsy was performed and the diagnosis of squamous cell carcinoma was established. The patient was then referred to a head and neck surgeon and a partial glossectomy was performed disclosing free surgical margins.

Recently, it was reported that the clinical presentation of oral lichen planus (OLP) has similarities to PVL based on the facts that most patients are females, without a history of tobacco or alcohol use and the presence of multifocal white lesions. In addition, as in OLP, the lesions have a predilection for the gingiva, tongue and buccal mucosa^[9]. In addition to the above-mentioned similarities, we noted that some older female patients without tobacco or alcohol habits had lesions that were similar to lichenoid reactions, but the histopathological analysis proved to be hyperkeratosis and acanthosis with variable degrees of epithelial dysplasia. However, the diagnosis of lichen planus or lichenoid reaction was ruled out microscopically, and these patients later developed more leukoplakic lesions consistent with multifocal leukoplakia.

Therefore, we suggest that the initial clinical manifestation in some cases of PVL may mimic OLP or oral

lichenoid reaction, and both biopsy and microscopic analysis are mandatory in order to avoid misdiagnosis, and consequently provide better patient management.

REFERENCES

- 1 **Hansen LS**, Olson JA, Silverman S. Proliferative verrucous leukoplakia. A long-term study of thirty patients. *Oral Surg Oral Med Oral Pathol* 1985; **60**: 285-298 [PMID: 3862042 DOI: 10.1016/0030-4220(85)90313-5]
- 2 **Bagan JV**, Jimenez Y, Sanchis JM, Poveda R, Milian MA, Murillo J, Scully C. Proliferative verrucous leukoplakia: high incidence of gingival squamous cell carcinoma. *J Oral Pathol Med* 2003; **32**: 379-382 [PMID: 12846783 DOI: 10.1034/j.1600-0714.2003.00167.x]
- 3 **Morton TH**, Cabay RJ, Epstein JB. Proliferative verrucous leukoplakia and its progression to oral carcinoma: report of three cases. *J Oral Pathol Med* 2007; **36**: 315-318 [PMID: 17448142 DOI: 10.1111/j.1600-0714.2007.00499.x]
- 4 **Gouvêa AF**, Vargas PA, Coletta RD, Jorge J, Lopes MA. Clinico-pathological features and immunohistochemical expression of p53, Ki-67, Mcm-2 and Mcm-5 in proliferative verrucous leukoplakia. *J Oral Pathol Med* 2010; **39**: 447-452 [PMID: 20412398 DOI: 10.1111/j.1600-0714.2010.00889.x]
- 5 **Bishen KA**, Sethi A. Proliferative Verrucous Leukoplakia--diagnostic pitfalls and suggestions. *Med Oral Patol Oral Cir Bucal* 2009; **14**: E263-E264 [PMID: 19300373]
- 6 **Cerero-Lapiedra R**, Baladé-Martínez D, Moreno-López LA, Esparza-Gómez G, Bagán JV. Proliferative verrucous leukoplakia: a proposal for diagnostic criteria. *Med Oral Patol Oral Cir Bucal* 2010; **15**: e839-e845 [PMID: 20173704 DOI: 10.4317/medoral.15.e839]
- 7 **Aguirre-Urizar JM**. Proliferative multifocal leukoplakia better name than proliferative verrucous leukoplakia. *World J Surg Oncol* 2011; **9**: 122 [PMID: 21985464 DOI: 10.1186/1477-7819-9-122]
- 8 **Bagan J**, Scully C, Jimenez Y, Martorell M. Proliferative verrucous leukoplakia: a concise update. *Oral Dis* 2010; **16**: 328-332 [PMID: 20233330 DOI: 10.1111/j.1601-0825.2009.01632.x]
- 9 **Müller S**. Oral manifestations of dermatologic disease: a focus on lichenoid lesions. *Head Neck Pathol* 2011; **5**: 36-40 [PMID: 21221868 DOI: 10.1007/s12105-010-0237-8]

P- Reviewer: Hu R, Teoh AYB, Voutsas V

S- Editor: Tian YL **L- Editor:** A **E- Editor:** Jiao XK



Port site infection in laparoscopic surgery: A review of its management

Prakash K Sasmal, Tushar S Mishra, Satyajit Rath, Susanta Meher, Dipti Mohapatra

Prakash K Sasmal, Tushar S Mishra, Satyajit Rath, Susanta Meher, Department of Surgery, All India Institute of Medical Sciences, Bhubaneswar, Odisha 751019, India

Dipti Mohapatra, Department of Physiology, IMS and SUM Hospital, Bhubaneswar, Odisha 751030, India

Author contributions: Sasmal PK prepared the manuscript; Mishra TS, Rath S, Meher S and Mohapatra D contributed to the collecting and critical reviewing of the articles; all the authors have read and approved the final version of the manuscript.

Conflict-of-interest statement: Authors declare no conflict of interests for this article.

Open-Access: This article is an open-access article which was selected by an in-house editor and fully peer-reviewed by external reviewers. It is distributed in accordance with the Creative Commons Attribution Non Commercial (CC BY-NC 4.0) license, which permits others to distribute, remix, adapt, build upon this work non-commercially, and license their derivative works on different terms, provided the original work is properly cited and the use is non-commercial. See: <http://creativecommons.org/licenses/by-nc/4.0/>

Correspondence to: Dr. Prakash K Sasmal, MS (Surgery), FNB (Min. Access Surgery), FAIS, Assistant Professor, Department of Surgery, All India Institute of Medical Sciences, Room No. 402, 4th floor Academic Block, Bhubaneswar, Odisha 751019, India. drpkasasmal@gmail.com
Telephone: +91-94-38884255

Received: April 28, 2015
Peer-review started: April 30, 2015
First decision: June 24, 2015
Revised: July 8, 2015
Accepted: July 24, 2015
Article in press: July 27, 2015
Published online: October 16, 2015

Abstract

Laparoscopic surgery (LS), also termed minimal access

surgery, has brought a paradigm shift in the approach to modern surgical care. Early postoperative recovery, less pain, improved aesthesia and early return to work have led to its popularity both amongst surgeons and patients. Its application has progressed from cholecystectomies and appendectomies to various other fields including gastrointestinal surgery, urology, gynecology and oncosurgery. However, LS has its own package of complications. Port site infection (PSI), although infrequent, is one of the bothersome complications which undermine the benefits of minimal invasive surgery. Not only does it add to the morbidity of the patient but also spoils the reputation of the surgeon. Despite the advances in the field of antimicrobial agents, sterilization techniques, surgical techniques, operating room ventilation, PSIs still prevail. The emergence of rapid growing atypical mycobacteria with multidrug resistance, which are the causative organism in most of the cases, has further compounded the problem. PSIs are preventable if appropriate measures are taken preoperatively, intraoperatively and postoperatively. PSIs can often be treated non-surgically, with early identification and appropriate management. Macrolides, quinolones and aminoglycosides antibiotics do show promising activity against the atypical mycobacteria. This review article highlights the clinical burden, presentations and management of PSIs in LS as shared by various authors in the literature. We have given emphasis to atypical mycobacteria, which are emerging as a common etiological agent for PSIs in LS. Although the existing literature lacks consensus regarding PSI management, the complication can be best avoided by strictly abiding by the commandments of sterilization techniques of the laparoscopic instruments with appropriate sterilizing agent.

Key words: Laparoscopic surgery; Port site infection; Atypical mycobacteria; Sterilization; Surgical site infections

© The Author(s) 2015. Published by Baishideng Publishing

Group Inc. All rights reserved.

Core tip: Laparoscopic surgery has brought about a paradigm shift in the approach to various surgical diseases. Port site infection, although infrequent, is a complication which can undermine the benefits of the surgery. The complication is not life threatening, but definitely adds a lot to the morbidity, affects the postoperative quality of life, and spoils the aesthesis of the surgery. Leaving aside the bacterial causes, the rapidly emerging multidrug resistant atypical mycobacteria are a constant threat. By doing a thorough review of this topic, this paper aims to present the relevant literature regarding the diagnosis, currently available treatment options and commandments to prevent the occurrence of this somewhat preventable complication.

Sasmal PK, Mishra TS, Rath S, Meher S, Mohapatra D. Port site infection in laparoscopic surgery: A review of its management. *World J Clin Cases* 2015; 3(10): 864-871 Available from: URL: <http://www.wjgnet.com/2307-8960/full/v3/i10/864.htm> DOI: <http://dx.doi.org/10.12998/wjcc.v3.i10.864>

INTRODUCTION

Rapid growths in health care technology have given the surgeon the power of not only treating diseases surgically but also limiting surgical invasiveness. The greatest example is minimal access surgery (MAS) also commonly termed laparoscopic surgery (LS) or keyhole surgery, which has caused a paradigm shift in the approach to modern surgery, by limiting the access related morbidities.

LS involves the use of reusable metallic or disposable plastic trocars inserted through small skin incisions or ports made on the skin away from the site of surgery. This ports form the portal of entry to perform the surgical procedure by means of specially devised instruments and telescope. It has gained popularity due to better aesthesis, lesser pain, early ambulation and discharge from the hospital with early return to work, minimizing the financial burden to the patient. Ever since Philips Mouret reported the first laparoscopic cholecystectomy in 1987, the approach has been adopted for many other surgical procedures including appendectomy, herniorrhaphy, colonic surgery, gastric surgery, urological and gynaecological surgery^[1-5]. This is because of the combination of advancement in technology with the increasing acceptance of MAS by patients, which has led to the expansion of the horizon of LS.

LS, however, has its package of unique complications. One such complication, which is preventable although, is the port site infection (PSI). PSI soon erodes the advantages of LS, with the patient becoming worried with the indolent and nagging infection and losing confidence on the operating surgeon. There

occurs a significant increase in the morbidity, hospital stay and financial loss to the patient. The whole purpose of MAS to achieve utmost cosmesis is turned into an unsightly wound, and the quality of life of patients is seriously affected.

In this article we review the current literature regarding the incidence, clinical presentation, etiopathogenesis, management and methods of prevention of PSI in LS. We emphasize on the management of PSI due to the emerging rapid growing atypical mycobacteria that do not respond to the standard anti-tubercular drugs.

Incidence of PSIs

No surgical wound is completely immune to infections. Despite the advances in the fields of antimicrobial agents, sterilization techniques, surgical techniques, and operating room ventilation, PSIs still prevail. Incidence of SSI after elective laparoscopic cholecystectomy is less than that after open elective cholecystectomy due to shorter length of incision^[6]. The technique of primary port entry to the peritoneum does not show any difference in umbilical PSIs in patients undergoing laparoscopic cholecystectomy^[7]. The umbilical PSI rate in LS has been reported to be 8% with 89% of the infections occurring after laparoscopic cholecystectomy, whereas 11% after laparoscopic appendectomy^[8]. Francis *et al*^[9] studied the factors predicting 30-d readmission after laparoscopic colorectal cancer surgery. Out of 268 patients in their study who underwent laparoscopic colorectal surgery, 48 (18%) were readmitted with surgical site infection (SSI)^[9]. Several other authors have found that SSI rate is much higher in conventional surgical procedures than in MAS^[10-12]. The immune functions are less affected in LS as compared to open surgery^[13]. The incidences of PSI in laparoscopic cholecystectomy as per various studies^[14-22] are illustrated in Table 1.

SSIs and PSIs

SSIs are infections consequent to the surgery that are present within a month of the operative procedure. Surveillance in surgeries, such as breast, cardiac, cranial, spinal and bone surgeries, with use of prosthetic material, extends to 90 d after surgery^[23-25].

PSI is a type of SSI but limited to LS. The same criteria for SSIs are applicable to PSIs, but the infections are limited to superficial and deep surgical sites only as detailed below.

According to the definitions developed by the United States Centre for Disease Control (CDC), SSIs were categorized into^[25]: (1) Superficial SSIs which involve skin and subcutaneous tissue; (2) Deep SSIs which involve fascia and muscle layers; and (3) Organ/Space SSIs.

Wounds are classified as (as per CDC criteria for SSI 2015)^[25]: (1) Clean: A surgical wound that is neither exposed to any inflamed tissue nor has breached the gastrointestinal, respiratory, genital, or uninfected

Table 1 Studies showing frequency of port site infection following laparoscopic cholecystectomy

No.	Ref.	Year of publication	Type of study	Total number of patients	Frequency of infection
1	Karthik <i>et al</i> ^[14]	2013	Prospective	570	10 (1.8%)
2	Mir <i>et al</i> ^[15]	2013	Prospective	675	45 (6.7%)
3	Yanni <i>et al</i> ^[16]	2013	Prospective	100	4 (4%)
4	Taj <i>et al</i> ^[17]	2012	Observational	492	27 (5.48%)
5	Yi <i>et al</i> ^[18]	2012	NA	400	11 (2.75%)
6	Triantafyllidis <i>et al</i> ^[19]	2009	Retrospective	1009	14 (1.39%)
7	Chuang <i>et al</i> ^[20]	2004	NA	420	6 (1.4%)
8	Shindholimath <i>et al</i> ^[21]	2003	Prospective	113	7 (6.3%)
9	den Hoed <i>et al</i> ^[22]	1998	Prospective	189	10 (5.3%)

NA: Not available.

urinary tract; (2) Clean-Contaminated: Surgical wounds where there is controlled entry into the gastrointestinal, respiratory, genital, or uninfected urinary tract with minimal contamination; (3) Contaminated: Fresh wounds related to trauma, surgical wounds with major breach in sterile technique or gross contamination from the gastrointestinal tract, and incisions through nonpurulent inflammatory tissues; and (4) Dirty or Infected: Old wounds following trauma having devitalized tissue and surgical procedure performed in the presence of active infection or visceral perforation.

Most of the surgical procedures done by laparoscopy belong to Classes 1 and 2 wounds. The human body hosts a variety of microbes which can cause infections. When the host systemic immunity is suppressed due to any disease, medications or disruptions of the integrity of the skin or mucous membranes secondary to surgical insult, patients' own commensal microbial flora may cause infection. The PSIs in LS manifest in the form of seropurulent discharge from the port sites with surrounding skin inflammation or symptoms related to the organ/space infection.

The active surveillance for PSIs in LS remains a challenge, due to the early discharge and day care setting^[10,12]. In the absence of post-discharge surveillance, it is estimated that a third of all SSIs will be missed^[26]. The reported incidence of SSIs varies in various regions of the world. The reported incidence of SSIs in a recent article from Turkey was higher than the CDC National Healthcare Safety Network (NHSN) rates^[27]. Hence, the actual incidence of the PSIs may be much higher than revealed.

There is a higher incidence of superficial incisional SSIs as compared to that of deep incisional SSIs in LS^[12]. The PSI after a LS should be promptly diagnosed and treated appropriately. Although it may not be possible to achieve zero percent PSI, every attempt should be made to prevent it. Insight into the pathophysiology of incision site infections, pathogens involved and knowledge of the appropriate antibiotic is essential for successful management of PSI in LS.

Risk factors for PSIs

A number of contributing factors are somewhat responsible for the emergence of postoperative PSIs.

Antibiotics always may not be the answer to this problem. Thus, using them irrationally, as is often done will only result in the emergence of multidrug resistant microbes. The majority of the reports of postoperative wound infection are of SSIs. PSIs following LS have been less reported. The risk factors for SSIs, however, may be applicable to PSIs.

Preoperative stay in hospital: Lilani *et al*^[10] reported a significant increase in the incidence of SSIs with preoperative stay of more than 2 d for open surgical procedures.

Duration of operation: The study by Lilani *et al*^[10] reported a nil infection rate in surgeries of less than 30 min duration. There was a significant increase in SSIs for operations of prolonged duration for two hours or more.

Other factors: Obesity, prophylactic antibiotics, and drains have no effect on the rate of SSIs following laparoscopic cholecystectomy^[28]. Factors like emergency/multi-procedure surgery and surgery in acutely inflamed organs adversely affect the rate of SSIs^[20,22]. The risk of SSIs increases in patients with a history of nicotine or steroid usage, diabetes, malnutrition, long preoperative hospital stay, preoperative colonization of nares with *Staphylococcus aureus*, or perioperative blood transfusion^[29,30].

PSIs are more common in the umbilical port^[12]; the infection rate may depend upon the port through which the specimen is extracted. The infected specimen should be removed in an endobag in order to prevent wound infection and accidental spillage of contents or occult malignant cells. An improvised endobag can be prepared from a simple surgical glove which is easy to make, cheap, readily available and disposable^[17].

Microbial flora causing PSIs in LS

PSIs occur due to exposure of surgical wound to microbes which may be from an endogenous or exogenous source. The source of endogenous flora usually is from the patient's skin, mucous membranes or any of the viscera. The exogenous flora may be from any contaminated sources present in the sterile surgical

field including surgeon and team, instruments, room air, etc^[31].

The pathogenic organisms causing SSIs differ with the surgical procedure performed. Clean surgical wounds usually harbor *Staphylococcus aureus* which may have an exogenous origin or may be from the patient's native flora. Infections in clean-contaminated, contaminated and dirty surgical wounds are polymicrobial, resembling the endogenous flora of the target organ^[32].

PSIs are of two broad varieties based on the timing when they are present. The more common type manifests early, within a week of the surgical procedure. Gram positive or negative bacteria are the usual offending organisms which are contracted from the native skin or infected surgical site. They usually respond well to the commonly used antimicrobial agents. The other variety is caused by rapid growing atypical mycobacterium species, which has an incubation period of 3 to 4 wk. They show a poor response to the usual antimicrobial agents^[33].

Non-mycobacterial isolates: Kownhar *et al.*^[34] reported superficial SSIs as the most common in both MAS and open surgical procedures, with *Staphylococcus aureus* as the most common isolate. They studied the SSIs and found various common bacteria isolated as *Staphylococcus aureus* (37%) and *Pseudomonas aeruginosa* (37%), followed by *Klebsiella pneumonia* (8%), *Acinetobacter spp.* (3.2%), *Proteus spp.* (4.8%), *Escherichia coli* (4.8%), *Citrobacter freundii* (1.6%), *Edwardsiella tarda* (1.6%) and *Enterococcus faecalis* (1.6%). *Klebsiella sp.* is the most common offending organism in deep SSIs irrespective of the surgical approach^[34]. Usually hospital acquired skin flora cause superficial SSIs. Organisms causing deep SSIs usually are endogenous in origin or may be the skin commensals which reach the fascia or muscle layers through surgical incision^[23]. *Bacteroides sp.* was the predominant flora (60%) causing SSIs, in a study reported by Wolcott *et al.*^[35]. *Bacterioides fragilis* may originate from intraoperative visceral spillage. Mir *et al.*^[15] in their series found pseudomonas (42.2%) as the common offending organism in PSIs following laparoscopic cholecystectomy. They found that the organisms isolated were resistant to commonly used antibiotics in their hospital^[15].

Mycobacterial isolates: Several reports have established the role of rapid growing mycobacteria (RGM), particularly *M. fortuitum* and *M. chelonae* which together have been termed as *M. fortuitum-chelonae complex* that is known to cause disease in humans as well as animals^[36]. The endospores of this non-tuberculous mycobacterial (NTM) complex are usually considered saprophytes which colonize in sewage, soil and even tap water. This often cause localized skin infections 3-4 wk post-surgery^[37,38]. The NTM complex can cause disseminated disease in immunosuppressive

diseases. These atypical mycobacteria have a predilection to involve the skin and subcutaneous tissue. *M. chelonae* and *M. abscessus* have similar characteristics, and hence together were addressed as *M. chelonae/abscessus* group. Vijayaraghavan *et al.*^[39] reported an outbreak of laparoscopic PSIs due to *M. chelonae* at their center. They had 145 PSIs in 35 patients in a period of 6 wk. The contaminating source was found to be the water being used for washing instruments after chemical disinfection^[39]. A series of eight cases of port site tuberculosis after laparoscopy was reported by Ramesh *et al.*^[40] from India, caused by *M. tuberculosis*.

A case of PSI following laparoscopic cholecystectomy caused by *M. flavescens* has been reported^[41]. Duarte *et al.*^[42] reported an epidemic (74 cases) of postsurgical infections in Brazil, due to *M. massiliense*, after video assisted surgery, which had similar characteristics to *M. abscessus*. Recently, there have been reports of rapid growing mycobacterial infection following laparoscopic gastric banding in obesity^[43,44]. Atypical mycobacteria infections following surgery, although rare, are known to occur when a prosthetic material has been used^[45].

Clinical presentations of PSIs

Wound discharge and erythema around the port site are the most common presentation of non-mycobacterial infection usually occurring within a week of the surgery. They are usually limited to the skin and subcutaneous tissue^[12,14]. There may be surrounding tissue inflammation with pain or tenderness and low grade fever^[31].

The delayed type of presentation commonly caused by mycobacteria manifests nearly a month after surgery, in the form of persistent multiple discharging sinuses or lumps/nodules, not responding to antibiotics. There may be pigmentation and induration at the port site starting in a single port and spreading to others.

There are five clinical stages of atypical mycobacterial PSI^[46].

First stage: A tender nodule appears in the vicinity of the port site, and its usual timing of appearance is around four weeks following the surgery.

Second stage: Increase in the size of the nodule, and increased tenderness of the site along with other signs of inflammation with eventual formation of a discharging sinus.

Third stage: Reduced pain sensation following discharge of the purulent material and necrosis of the skin surrounding the port site.

Fourth stage: Chronic sinus discharging white or serous fluid.

Fifth stage: Hyper-pigmentation of the skin surrounding the sinus and appearance of multiple nodules at different places.

Diagnosis of the etiological agent with early management

Early PSIs: Gram stains and culture sensitivity of the pus from port site wounds are to be taken. The swabs obtained are processed aerobically and anaerobically by standard methods to find the non-mycobacterial isolates. *Staphylococcus aureus* strains are usually isolated from clean wounds. Their status of β -lactamase production and methicillin resistance needs to be assessed^[10]. Daily dressing, cleaning of the wound and a course of empirical antibiotic are started. Specific antibiotics as per the culture and sensitivity report are to be given subsequently. Drainage and debridement may sometimes be required for assisting in wound healing. There are reports of port site abscess presenting as discharging sinus months after surgery due to retained stone at the port site. Wound exploration and removal of the stone is necessary for the healing of such wound^[47,48]. Samel *et al.*^[49] reported a case of gas gangrene of the abdominal wall due to *Clostridial* agents centering around right lateral port following laparoscopic cholecystectomy. There are also reports of life threatening necrotizing fasciitis of the abdominal wall following LS. Significant erythema and wound discharge around the port site along with fever are signs of necrotizing fasciitis^[50,51]. A high grade of suspicion and aggressive management are necessary to deal with these life threatening bacterial infections.

Delayed PSIs: Chaudhuri *et al.*^[46] have shown a raised C-reactive protein level without leukocytosis and a normal differential count in patients with atypical mycobacterial infection^[46,52]. Tissue or fluid obtained by biopsy or aspiration needs to be processed for bacilloscopy, culture in Lowenstein-Jensen medium and BACTEC technique (Becton-Dickinson Diagnostic Instrument Systems, Sparks, Md). Isolation of the atypical mycobacteria by tissue culture is possible, although it takes time to grow. Moreover, maintaining the stringent environment for its culture is difficult. The most accurate method for rapid presumptive identification of *M. chelonae* is detecting resistance to polymyxin B disc (300 μ g)^[53]. The routine culture of pus does not grow any bacteria. The diagnosis is often based on the clinical signs and a high index of suspicion^[52]. In case of growth of the organism, the isolate is to be confirmed by either biochemical reactions or the more recent nucleic acid amplification tests. Other investigations like tissue culture, real time-PCR, and serology for antitubercular antibody can support the diagnosis^[53]. Even these reports are not full proof, as these tests could give a false positive result. The histopathological examination at times may reveal chronic granulomatous inflammation, comprising of epithelioid cells and lympho-plasmacytic infiltration^[40].

Treatment of PSIs

Early PSIs, with bacterial isolates, are best managed

with local wound care and antibiotics as per antibiogram. The study by Lilani *et al.*^[10] in clean and clean contaminated cases revealed *Staphylococcal sp.* as the most common isolate, which was resistant to penicillin. The isolates of *Pseudomonas aeruginosa* were totally resistant to gentamicin^[10]. Mir *et al.*^[15] found most of the isolated strains of organisms causing SSI in elective laparoscopic cholecystectomy were resistant to antibiotics used in the hospital. They found the *Pseudomonas sp.* to be sensitive to imipenem in 89.47% of cases, but there was complete resistance to the combination of ampicillin and sulbactam and ceftriaxone^[15].

Management of PSIs with atypical mycobacteria lacks consensus. They respond poorly to first line anti-tubercular drug treatment. Second line anti-tubercular drugs including macrolides (clarithromycin), quinolones (ciprofloxacin), tetracyclines (doxycycline) and aminoglycosides (amikacin and tobramycin) in various combinations have been used with promising results^[37,46,54]. Macrolides including clarithromycin are the only group of antimicrobials active against *M. chelonae* and *M. abscessus*^[54]. *Mycobacterium fortium-chelonae* complex has shown resistance to antibiotics because of mutation in the porin channels present in the bacterial wall, which is the site for entry of antibiotic molecules for antimicrobial activity^[46,55]. Linezolid was found to be active against *M. chelonae* and has been successfully used for treatment, alone or as combination therapy^[56]. The various antibiotics effectively used against the mycobacterial PSIs, as reported in various studies, are described in Table 2.

Prevention of PSIs

The million dollar question is why at all there occur PSIs in clean and clean contaminated wounds after LS. Is it because of the contamination from the endogenous source or through exogenous source? The endogenous source of infection cannot be avoided. But the incidence of PSIs after LS due to endogenous cause can be reduced by using sterile endobag for specimen retrieval.

The exogenous source of infection, however, is avoidable. Non-tuberculous mycobacteria may be present in water from various sources and soil which can contaminate hospital instruments. A breach in sterilization protocol of laparoscopic instruments is the most common cause of PSI with atypical mycobacteria^[46]. The infection with atypical mycobacteria is usually limited to the laparoscopic procedure, as most of laparoscopic instruments are not autoclavable because of the heat sensitive outer insulation sheath. Moreover, as most of the laparoscopic instruments have multiple joints and crevices, where blood and tissue can collect. Frequent use of the instrument without optimal cleaning potentially results in contamination with organisms such as atypical mycobacteria. Endospores in the contaminated instrument get deposited in the subcutaneous tissue, which germinate in three to four

Table 2 Different antibiotics effectively used against *Mycobacterial sp.* in port site infections

Ref.	Type of study	Mycobacteria isolated	Treatment given
Ramesh <i>et al</i> ^[40]	Case series in 8 patients	<i>M. tuberculosis</i>	Standard first line antitubercular regimen Rifampicin, isoniazid, pyrazinamide and ethambutol for 2 mo followed by rifampicin and isoniazid for 9 mo
Chaudhuri <i>et al</i> ^[46]	Case series in 19 patients	Clinically suspected atypical mycobacterial infection. No isolates in culture	Clarithromycin and ciprofloxacin (500 mg each, twice daily) for 28 d to 3 mo For persistent local nodules, direct injection of amikacin injections into the nodules daily for 5 d (500 mg twice daily)
Vergheese <i>et al</i> ^[37]	Case report	<i>M. chelonae</i>	Amikacin 750 mg/d and azithromycin 500 mg BD for 2 wk, followed by linezolid 500 mg BD and azithromycin 500 mg BD for 6 wk
Duarte <i>et al</i> ^[42]	Case series in 74 patients	<i>M. massiliense</i>	Sensitive to amikacin and clarithromycin, but resistant to ciprofloxacin, cefoxitine and doxycycline
Sethi <i>et al</i> ^[41]	Case report	<i>M. flavescens</i>	Ofloxacin and amikacin for 6 mo
Shah <i>et al</i> ^[61]	Case series in 7 patients	<i>M. fortuitum</i> <i>M. chelonae</i>	Clarithromycin and ciprofloxacin (500 mg each, twice daily) for 6-9 mo
Rajini <i>et al</i> ^[62]	Case report	<i>M. chelonae</i>	Clarithromycin 500 mg BD and doxycycline 100 mg OD for 4 wk

weeks to produce clinical signs and symptoms^[42]. A study by Lorena *et al*^[57] on *M. massiliense* BRA100 strain showed that it is resistant to even higher concentration of glutaraldehyde (GTA, 7%). Hence, they proved that GTA may not be effective for RGM. Other liquid sterilizing agents like orthophthaldehyde and per acetic acid may substitute GTA for high level disinfection with good efficacy^[57].

Ten commandments for preventing PSI^[58-61]: (1) Use of disposable trocars and instruments, and adequate availability of properly sterilised reusable trocars to cover all the surgical procedures in a day; (2) Use of autoclavable laparoscopic hand instruments; (3) Use of instruments with good ergonomics, limited joints and facility for proper cleaning of the debris collected in its crevices; (4) A proper cleaning of the instrument is best achieved by ultrasonic technology. Use of autoclaved water for cleaning the instruments after dismantling; (5) Proper guidelines should be followed regarding the concentration, contact time and cycles of use for instrument sterilization with liquid sterilizing agents; (6) Use of plasma sterilizer or ethylene oxide in between the consecutive surgery for instrument sterilization; (7) Avoiding inter-departmental sharing of instruments, such as using instruments used for gynecological or urological procedures; (8) Avoiding spillage of bile or gut content in the operative area or the port site; (9) Use of non-porous specimen retrieval bags for retrieving the specimen; and (10) Thorough irrigation and cleaning of the port site before wound closure.

CONCLUSION

PSI, although infrequent, can be a frustrating complication in MAS, both for the patient as well as the operating surgeon. Leaving aside the bacterial causes, the emerging rapid growing multidrug resistant non-tuberculous mycobacteria are a new threat to the surgical fraternity. Strictly abiding by the commandments of cleaning and sterilization of the laparoscopic instru-

ments, with the appropriate sterilizing agent, the complication can be best avoided.

This review is likely to aid in understanding the relevant studies regarding the appropriate management of PSIs in LS. All the cases of PSI, especially of the atypical mycobacterium should be notified to know the exact incidence, etiology and the sensitivity pattern to various antibiotics. Macrolides, quinolones and aminoglycosides do show promising activity against the atypical mycobacterium. Further research is needed to find out appropriate guidelines for the diagnosis and treatment of this emerging problem.

REFERENCES

1. Lei QC, Wang XY, Zheng HZ, Xia XF, Bi JC, Gao XJ, Li N. Laparoscopic Versus Open Colorectal Resection Within Fast Track Programs: An Update Meta-Analysis Based on Randomized Controlled Trials. *J Clin Med Res* 2015; **7**: 594-601 [PMID: 26124904 DOI: 10.14740/jocmr2177w]
2. Deng Y, Zhang Y, Guo TK. Laparoscopy-assisted versus open distal gastrectomy for early gastric cancer: A meta-analysis based on seven randomized controlled trials. *Surg Oncol* 2015; **24**: 71-77 [PMID: 25791201 DOI: 10.1016/j.suronc.2015.02.003]
3. Mehrabi A, Hafezi M, Arvin J, Esmailzadeh M, Garoussi C, Emami G, Kössler-Ebs J, Müller-Stich BP, Büchler MW, Hackert T, Diener MK. A systematic review and meta-analysis of laparoscopic versus open distal pancreatectomy for benign and malignant lesions of the pancreas: it's time to randomize. *Surgery* 2015; **157**: 45-55 [PMID: 25482464 DOI: 10.1016/j.surg.2014.06.081]
4. Bhav Chittawar P, Franik S, Pouwer AW, Farquhar C. Minimally invasive surgical techniques versus open myomectomy for uterine fibroids. *Cochrane Database Syst Rev* 2014; **10**: CD004638 [PMID: 25331441 DOI: 10.1002/14651858.CD004638.pub3]
5. Esposito C, St Peter SD, Escolino M, Juang D, Settini A, Holcomb GW. Laparoscopic versus open inguinal hernia repair in pediatric patients: a systematic review. *J Laparoendosc Adv Surg Tech A* 2014; **24**: 811-818 [PMID: 25299121 DOI: 10.1089/lap.2014.0194]
6. Zacks SL, Sandler RS, Rutledge R, Brown RS. A population-based cohort study comparing laparoscopic cholecystectomy and open cholecystectomy. *Am J Gastroenterol* 2002; **97**: 334-340 [PMID: 11866270]
7. Molloy D, Kaloo PD, Cooper M, Nguyen TV. Laparoscopic entry: a literature review and analysis of techniques and complications of primary port entry. *Aust N Z J Obstet Gynaecol* 2002; **42**: 246-254 [PMID: 12230057]

- 8 **Hamzaoglu I**, Baca B, Böler DE, Polat E, Ozer Y. Is umbilical flora responsible for wound infection after laparoscopic surgery? *Surg Laparosc Endosc Percutan Tech* 2004; **14**: 263-267 [PMID: 15492655]
- 9 **Francis NK**, Mason J, Salib E, Allanby L, Messenger D, Allison AS, Smart NJ, Ockrim JB. Factors predicting 30-day readmission after laparoscopic colorectal cancer surgery within an enhanced recovery programme. *Colorectal Dis* 2015; **17**: O148-O154 [PMID: 25988303 DOI: 10.1111/codi.13002]
- 10 **Lilani SP**, Jangale N, Chowdhary A, Daver GB. Surgical site infection in clean and clean-contaminated cases. *Indian J Med Microbiol* 2005; **23**: 249-252 [PMID: 16327121]
- 11 **Brill A**, Ghosh K, Gunnarsson C, Rizzo J, Fullum T, Maxey C, Brossette S. The effects of laparoscopic cholecystectomy, hysterectomy, and appendectomy on nosocomial infection risks. *Surg Endosc* 2008; **22**: 1112-1118 [PMID: 18297345 DOI: 10.1007/s00464-008-9815-1]
- 12 **Richards C**, Edwards J, Culver D, Emori TG, Tolson J, Gaynes R. Does using a laparoscopic approach to cholecystectomy decrease the risk of surgical site infection? *Ann Surg* 2003; **237**: 358-362 [PMID: 12616119]
- 13 **Redmond HP**, Watson RW, Houghton T, Condron C, Watson RG, Bouchier-Hayes D. Immune function in patients undergoing open vs laparoscopic cholecystectomy. *Arch Surg* 1994; **129**: 1240-1246 [PMID: 7986152 DOI: 10.1001/archsurg.1994.01420360030003]
- 14 **Karthik S**, Augustine AJ, Shibumon MM, Pai MV. Analysis of laparoscopic port site complications: A descriptive study. *J Minim Access Surg* 2013; **9**: 59-64 [PMID: 23741110 DOI: 10.4103/0972-9941.110964]
- 15 **Mir MA**, Malik UY, Wani H, Bali BS. Prevalence, pattern, sensitivity and resistance to antibiotics of different bacteria isolated from port site infection in low risk patients after elective laparoscopic cholecystectomy for symptomatic cholelithiasis at tertiary care hospital of Kashmir. *Int Wound J* 2013; **10**: 110-113 [PMID: 22414004 DOI: 10.1111/j.1742-481X.2012.00963.x]
- 16 **Yanni F**, Mekhail P, Morris-Stiff G. A selective antibiotic prophylaxis policy for laparoscopic cholecystectomy is effective in minimising infective complications. *Ann R Coll Surg Engl* 2013; **95**: 345-348 [PMID: 23838497 DOI: 10.1308/003588413X13629960045959]
- 17 **Taj MN**, Iqbal Y, Akbar Z. Frequency and prevention of laparoscopic port site infection. *J Ayub Med Coll Abbottabad* 2012; **24**: 197-199 [PMID: 24669653]
- 18 **Yi F**, Jin WS, Xiang DB, Sun GY, Huaguo D. Complications of laparoscopic cholecystectomy and its prevention: a review and experience of 400 cases. *Hepatogastroenterology* 2012; **59**: 47-50 [PMID: 22260821 DOI: 10.5754/hge11232]
- 19 **Triantafyllidis I**, Nikoloudis N, Sapidis N, Chrissidou M, Kalaitzidou I, Chrissidis T. Complications of laparoscopic cholecystectomy: our experience in a district general hospital. *Surg Laparosc Endosc Percutan Tech* 2009; **19**: 449-458 [PMID: 20027087 DOI: 10.1097/SLE.0b013e3181bd8f6d]
- 20 **Chuang SC**, Lee KT, Chang WT, Wang SN, Kuo KK, Chen JS, Sheen PC. Risk factors for wound infection after cholecystectomy. *J Formos Med Assoc* 2004; **103**: 607-612 [PMID: 15340659]
- 21 **Shindholimath VV**, Seenu V, Parshad R, Chaudhry R, Kumar A. Factors influencing wound infection following laparoscopic cholecystectomy. *Trop Gastroenterol* 2003; **24**: 90-92 [PMID: 14603831]
- 22 **den Hoed PT**, Boelhouwer RU, Veen HF, Hop WC, Bruining HA. Infections and bacteriological data after laparoscopic and open gallbladder surgery. *J Hosp Infect* 1998; **39**: 27-37 [PMID: 9617682]
- 23 **Rubin RH**. Surgical wound infection: epidemiology, pathogenesis, diagnosis and management. *BMC Infect Dis* 2006; **6**: 171 [PMID: 17129369 DOI: 10.1186/1471-2334-6-171]
- 24 **Horan TC**, Andrus M, Dudeck MA. CDC/NHSN surveillance definition of health care-associated infection and criteria for specific types of infections in the acute care setting. *Am J Infect Control* 2008; **36**: 309-332 [PMID: 18538699 DOI: 10.1016/j.ajic.2008.03.002]
- 25 **Centers for Disease Control and Prevention**. The National Healthcare Safety Network (NHSN) Manual: Patient Safety Component Atlanta, GA: Division of Healthcare Quality Promotion, National Center for Emerging and Zoonotic Infections Diseases. Available from: URL: <http://www.cdc.gov/nhsn/acute-care-hospital/index.html>
- 26 **Stockley JM**, Allen RM, Thomlinson DF, Constantine CE. A district general hospital's method of post-operative infection surveillance including post-discharge follow-up, developed over a five-year period. *J Hosp Infect* 2001; **49**: 48-54 [PMID: 11516186 DOI: 10.1053/jhin.2001.1029]
- 27 **Leblebicioglu H**, Erben N, Rosenthal VD, Sener A, Uzun C, Senol G, Ersoz G, Demirdal T, Duygu F, Willke A, Sirmatel F, Oztoprak N, Koksali I, Oncul O, Gurbuz Y, Güçlü E, Turgut H, Yalcin AN, Ozdemir D, Kendirli T, Aslan T, Esen S, Ulger F, Dilek A, Yilmaz H, Sunbul M, Ozgunes I, Usluer G, Otkun M, Kaya A, Kuyucu N, Kaya Z, Meric M, Azak E, Yılmaz G, Kaya S, Ulusoy H, Haznedaroglu T, Gorenk L, Acar A, Tutuncu E, Karabay O, Kaya G, Sacar S, Sungurtekin H, Ugurcan D, Turhan O, Kaya S, Gumus E, Dursun O, Geyik MF, Şahin A, Erdogan S, Ince E, Karbuz A, Çiftçi E, Taşyapar N, Güneş M. Surgical site infection rates in 16 cities in Turkey: findings of the International Nosocomial Infection Control Consortium (INICC). *Am J Infect Control* 2015; **43**: 48-52 [PMID: 25564124 DOI: 10.1016/j.ajic.2014.09.017]
- 28 **Scott JD**, Forrest A, Feuerstein S, Fitzpatrick P, Schentag JJ. Factors associated with postoperative infection. *Infect Control Hosp Epidemiol* 2001; **22**: 347-351 [PMID: 11519911 DOI: 10.1086/501911]
- 29 **Owens CD**, Stoessel K. Surgical site infections: epidemiology, microbiology and prevention. *J Hosp Infect* 2008; **70** Suppl 2: 3-10 [PMID: 19022115 DOI: 10.1016/S0195-6701(08)60017-1]
- 30 **Boni L**, Benevento A, Rovera F, Dionigi G, Di Giuseppe M, Bertoglio C, Dionigi R. Infective complications in laparoscopic surgery. *Surg Infect (Larchmt)* 2006; **7** Suppl 2: S109-S111 [PMID: 16895490 DOI: 10.1089/sur.2006.7.s2-109]
- 31 **Mangram AJ**, Horan TC, Pearson ML, Silver LC, Jarvis WR. Guideline for Prevention of Surgical Site Infection, 1999. Centers for Disease Control and Prevention (CDC) Hospital Infection Control Practices Advisory Committee. *Am J Infect Control* 1999; **27**: 97-132; quiz 133-134; discussion 96 [PMID: 10196487]
- 32 **Nichols RL**. Surgical wound infection. *Am J Med* 1991; **91**: 54S-64S [PMID: 1928192]
- 33 **Falkinham JO**. Epidemiology of infection by nontuberculous mycobacteria. *Clin Microbiol Rev* 1996; **9**: 177-215 [PMID: 8964035]
- 34 **Kownhar H**, Shankar EM, Vignesh R, Sekar R, Velu V, Rao UA. High isolation rate of Staphylococcus aureus from surgical site infections in an Indian hospital. *J Antimicrob Chemother* 2008; **61**: 758-760 [PMID: 18199563 DOI: 10.1093/jac/dkm519]
- 35 **Wolcott RD**, Gontcharova V, Sun Y, Zischkau A, Dowd SE. Bacterial diversity in surgical site infections: not just aerobic cocci any more. *J Wound Care* 2009; **18**: 317-323 [PMID: 19862869 DOI: 10.12968/jowc.2009.18.8.43630]
- 36 **Muthusami JC**, Vyas FL, Mukundan U, Jesudason MR, Govil S, Jesudason SR. Mycobacterium fortuitum: an iatrogenic cause of soft tissue infection in surgery. *ANZ J Surg* 2004; **74**: 662-666 [PMID: 15315567 DOI: 10.1111/j.1445-1433.2004.03018.x]
- 37 **Verghese S**, Agrawal P, Benjamin S. Mycobacterium chelonae causing chronic wound infection and abdominal incisional hernia. *Indian J Pathol Microbiol* 2014; **57**: 335-337 [PMID: 24943783 DOI: 10.4103/0377-4929.134736]
- 38 **Khan IU**, Selvaraju SB, Yadav JS. Occurrence and characterization of multiple novel genotypes of Mycobacterium immunogenum and Mycobacterium chelonae in metalworking fluids. *FEMS Microbiol Ecol* 2005; **54**: 329-338 [PMID: 16332331 DOI: 10.1016/j.femsec.2005.04.009]
- 39 **Vijayaraghavan R**, Chandrashekar R, Sujatha Y, Belagavi CS. Hospital outbreak of atypical mycobacterial infection of port sites after laparoscopic surgery. *J Hosp Infect* 2006; **64**: 344-347 [PMID: 16332331 DOI: 10.1016/j.femsec.2005.04.009]

- 17046106]
- 40 **Ramesh H**, Prakash K, Lekha V, Jacob G, Venugopal A, Venugopal B. Port-site tuberculosis after laparoscopy: report of eight cases. *Surg Endosc* 2003; **17**: 930-932 [PMID: 12618936 DOI: 10.1007/s00464-002-9057-6]
 - 41 **Sethi S**, Gupta V, Bhattacharyya S, Sharma M. Post-laparoscopic wound infection caused by scotochromogenic nontuberculous Mycobacterium. *Jpn J Infect Dis* 2011; **64**: 426-427 [PMID: 21937826]
 - 42 **Duarte RS**, Lourenço MC, Fonseca Lde S, Leão SC, Amorim Ede L, Rocha IL, Coelho FS, Viana-Niero C, Gomes KM, da Silva MG, Lorena NS, Pitombo MB, Ferreira RM, Garcia MH, de Oliveira GP, Lupi O, Vilaça BR, Serradas LR, Chebabo A, Marques EA, Teixeira LM, Dalcolmo M, Senna SG, Sampaio JL. Epidemic of postsurgical infections caused by Mycobacterium massiliense. *J Clin Microbiol* 2009; **47**: 2149-2155 [PMID: 19403765 DOI: 10.1128/JCM.00027-09]
 - 43 **Callen EC**, Kessler TL. Mycobacterium fortuitum infections associated with laparoscopic gastric banding. *Obes Surg* 2011; **21**: 404-406 [PMID: 20336391 DOI: 10.1007/s11695-010-0123-1]
 - 44 **Wright HL**, Thomson RM, Reid AB, Carter R, Bartley PB, Newton P, Coulter C. Rapidly growing mycobacteria associated with laparoscopic gastric banding, Australia, 2005-2011. *Emerg Infect Dis* 2014; **20**: 1612-1619 [PMID: 25279450 DOI: 10.3201/eid2010.140077]
 - 45 **Phillips MS**, von Reyn CF. Nosocomial infections due to nontuberculous mycobacteria. *Clin Infect Dis* 2001; **33**: 1363-1374 [PMID: 11550115 DOI: 10.1086/323126]
 - 46 **Chaudhuri S**, Sarkar D, Mukerji R. Diagnosis and management of atypical mycobacterial infection after laparoscopic surgery. *Indian J Surg* 2010; **72**: 438-442 [PMID: 22131651 DOI: 10.1007/s12262-010-0164-7]
 - 47 **Dreznik Z**, Soper NJ. Trocar site abscess due to spilled gallstones: an unusual late complication of laparoscopic cholecystectomy. *Surg Laparosc Endosc* 1993; **3**: 223-224 [PMID: 8111563]
 - 48 **Narreddy SR**, Guleria S, Agarwal S, Svr CM, Mandal S. Recurrent abscess at site of laparoscopic cholecystectomy port due to spilled gallstones. *Indian J Gastroenterol* 2001; **20**: 161 [PMID: 11497181]
 - 49 **Samel S**, Post S, Martell J, Becker H. Clostridial gas gangrene of the abdominal wall after laparoscopic cholecystectomy. *J Laparoendosc Adv Surg Tech A* 1997; **7**: 245-247 [PMID: 9448120 DOI: 10.1089/lap.1997.7.245]
 - 50 **Raghavendra GK**, Mills S, Carr M. Port site necrotising fasciitis following laparoscopic appendectomy. *BMJ Case Rep* 2010; **2010**: pii [PMID: 22778196 DOI: 10.1136/bcr.10.2009.2375]
 - 51 **Losanoff JE**, Richman BW, Jones JW. Trocar-site hernia complicated by necrotizing fasciitis--case report and review of the literature. *Hernia* 2003; **7**: 220-223 [PMID: 12687429 DOI: 10.1007/s10029-003-0133-1]
 - 52 **Jayashree KV**, Appalaraju B, Jayalakshmi J, Sowmya N, Jayachandran K, Balashanmugam TS, Ramanathan RM. When molecular diagnosis went wrong. *Indian J Pathol Microbiol* 2011; **54**: 418-419 [PMID: 21623117 DOI: 10.4103/0377-4929.81605]
 - 53 **Park SH**, Kim CK, Jeong HR, Son H, Kim SH, Park MS. Evaluation and comparison of molecular and conventional diagnostic tests for detecting tuberculosis in Korea, 2013. *Osong Public Health Res Perspect* 2014; **5**: S3-S7 [PMID: 25861577 DOI: 10.1016/j.phrp.2014.10.006]
 - 54 **Wallace RJ**, Meier A, Brown BA, Zhang Y, Sander P, Onyi GO, Böttger EC. Genetic basis for clarithromycin resistance among isolates of Mycobacterium chelonae and Mycobacterium abscessus. *Antimicrob Agents Chemother* 1996; **40**: 1676-1681 [PMID: 8807061]
 - 55 **Svetlíková Z**, Skovierová H, Niederweis M, Gaillard JL, McDonnell G, Jackson M. Role of porins in the susceptibility of Mycobacterium smegmatis and Mycobacterium chelonae to aldehyde-based disinfectants and drugs. *Antimicrob Agents Chemother* 2009; **53**: 4015-4018 [PMID: 19581465 DOI: 10.1128/AAC.00590-09]
 - 56 **Wallace RJ**, Brown-Elliott BA, Ward SC, Crist CJ, Mann LB, Wilson RW. Activities of linezolid against rapidly growing mycobacteria. *Antimicrob Agents Chemother* 2001; **45**: 764-767 [PMID: 11181357 DOI: 10.1128/AAC.45.3.764-767.2001]
 - 57 **Lorena NS**, Pitombo MB, Côrtes PB, Maya MC, Silva MG, Carvalho AC, Coelho FS, Miyazaki NH, Marques EA, Chebabo A, Freitas AD, Lupi O, Duarte RS. Mycobacterium massiliense BRA100 strain recovered from postsurgical infections: resistance to high concentrations of glutaraldehyde and alternative solutions for high level disinfection. *Acta Cir Bras* 2010; **25**: 455-459 [PMID: 20877958 DOI: 10.1590/S0102-86502010000500013]
 - 58 **Rutala WA**, Weber DJ. Disinfection and sterilization in health care facilities: what clinicians need to know. *Clin Infect Dis* 2004; **39**: 702-709 [PMID: 15356786 DOI: 10.1086/423182]
 - 59 **Mukhopadhyay S**, Basu D, Chakrabarti P. Characterization of a porin from Mycobacterium smegmatis. *J Bacteriol* 1997; **179**: 6205-6207 [PMID: 9324274]
 - 60 **Daniilchanka O**, Pavlenok M, Niederweis M. Role of porins for uptake of antibiotics by Mycobacterium smegmatis. *Antimicrob Agents Chemother* 2008; **52**: 3127-3134 [PMID: 18559650 DOI: 10.1128/AAC.00239-08]
 - 61 **Shah AK**, Gambhir RP, Hazra N, Katoch R. Non tuberculous mycobacteria in surgical wounds- a rising cause of concern? *Indian J Surg* 2010; **72**: 206-210 [PMID: 23133248 DOI: 10.1007/s12262-010-0057-9]
 - 62 **Rajini M**, Prasad SR, Reddy RR, Bhat RV, Vimala KR. Postoperative infection of laparoscopic surgery wound due to Mycobacterium chelonae. *Indian J Med Microbiol* 2007; **25**: 163-165 [PMID: 17582193 DOI: 10.4103/0255-0857.32729]

P- Reviewer: Khan FY, Said ZNA, Surlin V

S- Editor: Ji FF **L- Editor:** Wang TQ **E- Editor:** Jiao XK



Arrhythmogenic epilepsy and pacing need: A matter of controversy

Alper Kepez, Okan Erdogan

Alper Kepez, Okan Erdogan, Marmara University Training and Research Hospital, Cardiology Clinic, 34890 Istanbul, Turkey

Author contributions: Kepez A performed the majority of writing and data accusation; Erdogan O designed the outline and coordinated the writing of the paper.

Conflict-of-interest statement: There is no conflict of interest associated with any of the authors contributed their efforts in this manuscript.

Open-Access: This article is an open-access article which was selected by an in-house editor and fully peer-reviewed by external reviewers. It is distributed in accordance with the Creative Commons Attribution Non Commercial (CC BY-NC 4.0) license, which permits others to distribute, remix, adapt, build upon this work non-commercially, and license their derivative works on different terms, provided the original work is properly cited and the use is non-commercial. See: <http://creativecommons.org/licenses/by-nc/4.0/>

Correspondence to: Alper Kepez, Associate Professor, Marmara University Training and Research Hospital, Cardiology Clinic, Pendik, 34890 Istanbul, Turkey. alperkepez@yahoo.com
Telephone: +90-532-2201899

Received: May 24, 2015
Peer-review started: May 26, 2015
First decision: July 10, 2015
Revised: July 21, 2015
Accepted: August 20, 2015
Article in press: August 21, 2015
Published online: October 16, 2015

Abstract

There is increasing awareness among the cardiology community regarding ictal bradyarrhythmias as a cause of loss of consciousness. A high degree of suspicion is necessary when diagnosing ictal bradyarrhythmias, and delay in diagnosing this condition may lead to morbidity associated with falls and trauma. Ictal bradyarrhythmias

have also been suggested to be associated with sudden unexplained death in epilepsy, although evidence related to this association is limited. There is no guideline-directed therapy for symptomatic ictal bradyarrhythmias due to a lack of randomized, controlled trials. Cardiac pacemaker therapy is commonly used for these patients; however, currently, there is no universal agreement on the pacing indications for these patients. In this review, we focus on the pathophysiology and clinical presentation of ictal bradyarrhythmias and then discuss the pacing need based on the available literature data.

Key words: Arrhythmogenic epilepsy; Syncope; Ictal bradyarrhythmia; Pacemaker; Anticonvulsive therapy

© **The Author(s) 2015.** Published by Baishideng Publishing Group Inc. All rights reserved.

Core tip: There is increasing awareness among the cardiology community regarding ictal bradyarrhythmias as a cause of loss of consciousness. Pacing is commonly used therapy for symptomatic ictal bradyarrhythmias. However, currently, there is no universal agreement on the pacing indications for these patients due to lack of randomized, controlled trials. In this review we will first focus on pathophysiology and clinical presentation of ictal bradyarrhythmias and then try to discuss the pacing need based on the available literature data.

Kepez A, Erdogan O. Arrhythmogenic epilepsy and pacing need: A matter of controversy. *World J Clin Cases* 2015; 3(10): 872-875
Available from: URL: <http://www.wjgnet.com/2307-8960/full/v3/i10/872.htm> DOI: <http://dx.doi.org/10.12998/wjcc.v3.i10.872>

INTRODUCTION

Epileptic seizures have been associated with a variety of systemic and autonomic manifestations.

Cardiovascular autonomic manifestations include alterations in heart rate and rhythm, blood pressure and electrocardiography (ECG)^[1].

Sinus tachycardia is the most frequently observed arrhythmia in patients with epilepsy, with a reported a frequency of 60%-100%^[1-3]. Heart rate acceleration has been shown to precede, follow or coincide with seizure^[1]. Bradyarrhythmias are rarely observed, occurring in less than 5% of all seizures^[1,4]. Sinus bradycardia, AV block and prolonged asystole have been reported in a variety of case reports and case studies^[1]. Most episodes have been shown to occur in the ictal state by simultaneous electroencephalography (EEG) and ECG monitoring systems. Ictal asystole (IA) has been reported to be observed in 0.27%-0.4% of patients during prolonged video EEG telemetry^[5,6]. Although rare, ictal bradyarrhythmias have substantial morbidity because they are related with sudden loss of consciousness (LOC), which may lead to falls and traumatic injuries. Ictal bradycardia (IB) and IA have also been suggested to be associated with sudden unexplained death in epilepsy (SUDEP), although evidence of association is limited^[7-9].

This review will focus on the pathophysiology and clinical presentation of ictal bradyarrhythmias and discuss the pacing need based on the available literature.

PATHOPHYSIOLOGY

The pathophysiology of ictal bradyarrhythmias is not entirely clear, and complex pathways have been believed to be involved in the central nervous system. Most seizure-related bradyarrhythmias have been observed in individuals with temporal lobe epilepsy and appear to be less frequent in patients with seizures originating from the frontal lobes and other brain regions^[8]. It has been hypothesized that seizure-related stimulation of certain brain regions, such as insular cortex, cingulate cortex, amygdala and hypothalamus, interferes with autonomic control of the heart *via* connections with autonomic nuclei of the brain stem and spinal cord^[10]. Seizure-induced stimulation of the central nervous system has been suggested to directly affect postganglionic discharges on the heart^[11]. A recent comprehensive review of literature data on seizure-related cardiac arrhythmias reported that ictal bradyarrhythmias have been observed during focal dyscognitive seizures and that they were mostly commonly observed in individuals with temporal lobe epilepsy^[12]. Some studies have suggested lateralization of foci related to ictal arrhythmias; *i.e.*, seizures originating from the right hemisphere have been suggested to be more frequently associated with ictal tachycardia and seizures originating from left hemisphere with ictal bradyarrhythmias^[5,13,14]. However, there are inconsistent data in the literature on this lateralization hypothesis^[15,16].

CLINICAL PRESENTATION

Sudden LOC is the major manifestation of prolonged IA

related to complex partial seizures. Clinical presentation with sudden LOC and related falls, as well as subsequent trauma, may be similar in clinical presentation to vasovagal syncope. Schuele *et al.*^[17] described similar heart rate patterns during asystolic events in patients with IA and vasovagal asystole, with a tendency for tachycardia preceding the asystolic event, which then evolved into progressive bradycardia and asystole. Based on these observations, the authors suggested that both IA and vasovagal asystole might be mediated through a similar mechanism, leading to increase in vagal tone. Cerebral hypoperfusion related to prolonged asystole appears to be responsible for sudden LOC in patients with IA rather than seizure-induced activation of cortical or subcortical regions. However, absence epilepsy should also be considered in patients with sudden impairments of consciousness. Absence epilepsy is primarily observed in children and adolescent patients and is characterized by sudden cessation of movement without convulsions, impairment of consciousness, fixation of gaze and sudden termination of the epileptic episode without postictal depression^[18]. Absence seizures are typically accompanied by bilateral 3-4 Hz spike-wave discharges on EEG^[18].

Arrhythmogenic epilepsy should be considered in the differential diagnosis of patients with syncope^[10,19]. Ictal bradyarrhythmias should particularly be suspected in patients with epilepsy and syncopal episodes^[10]. IA and symptomatic IB are commonly associated with complex partial seizures. Patients commonly present with seizure-related symptoms, such as staring, unresponsiveness, epigastric aura and oroalimentary and manual automatisms, preceding the syncope^[20]. Thus, patients with atypical signs and symptoms before a syncopal episode should also be evaluated for the presence of arrhythmogenic epilepsy. IA or symptomatic IB may also be the first ictal manifestation of new onset epilepsy, and a high degree of suspicion is necessary for diagnosis. Recently, Giovannini *et al.*^[21] published a literature review on IA cases (31 patients from 21 articles) in the context of new-onset/newly diagnosed epilepsy. They reported that symptoms suggestive of partial seizures preceding syncope were absent for most patients. Only 7 patients have been reported to display symptoms such as visual illusion, hallucinations, jamais vu, fear, psychic aura and epigastric aura prior to syncope. Four patients have been reported to display seizure-related motor activities, such as tonic-clonic contractions and automatisms. Simultaneous long-term video EEG and ECG recording appears to be the key diagnostic modality for arrhythmogenic epilepsy^[21]. Long-term subcutaneous implantable loop recorders have also been useful in selected cases^[22,23].

LITERATURE DISCUSSION

There is no guideline-directed therapy for IA or symptomatic IB due to the lack of randomized controlled trials^[24]. Therapeutic options for symptomatic ictal

bradyarrhythmias include anticonvulsive medications, epileptic surgery and/or cardiac pacemaker implantation. Currently, there is no universal agreement on the pacing indications for these patients. Some authors have suggested that IA is a benign phenomenon, and long-term data regarding the effectiveness of pacemaker therapy for IA are missing due to low recurrence rates^[17]. Schuele *et al.*^[25] and Moseley *et al.*^[26] suggested that IA promotes seizure termination by causing cerebral ischemia/anoxia. However, case studies have indicated that pacemaker implantation may reduce seizure-related falls and injuries^[24,27-29]. Giovannini *et al.*^[21] reported that most patients (21 of 31 patients) with IA in the context of new-onset/newly diagnosed epilepsy had undergone pacemaker implantation at the time of case report publications, although outcome data for these patients are unknown. Other studies have reported some discordant outcome findings after pacemaker implantation in patients with ictal bradyarrhythmias. Ghearing *et al.*^[27,28] reported outcome data for 7 patients with IA who had falls and LOC prior to pacemaker implantation. Only one patient experienced seizure-related falls after pacemaker implantation at a mean follow-up duration of 27 mo. Schuele *et al.*^[6] performed a database search for 6825 patients undergoing long-term video EEG monitoring for episodes of IA and found that IA was recorded in 10 patients (0.27% of all patients with epilepsy). Pacemaker implantation had been performed in 6 of these patients, and none of these patients reported recurrent IA or significant bradycardia leading to pacemaker activation. However, 4 patients had been reported to have recurrent and multiple seizures after pacemaker implantation. Moseley *et al.*^[29] reported the outcome data of seven patients with IA who had a pacemaker implanted in their institution between 1990 and 2004. The authors stated that the mean fall rate was significantly reduced from 3.28 to 0.005 falls/month after pacemaker implantation. Seizure-related fractures and motor vehicle accidents were also reduced following pacemaker implantation.

Strzelczyk *et al.*^[24] reviewed 16 patients with IA or IB from 4 epilepsy centers who had been evaluated between 2002 and 2009. They reported that pacemaker implantation had been performed in 7 of these patients (43.8%). Outcome data were available for 43 patient-years. Accordingly, 5 patients (31.3%) were seizure-free in the follow-up period; 2 of these patients had experienced epilepsy surgery, 2 had received anticonvulsive therapy, and 1 had received pacemaker implantation. Nine patients (56.3%) had persisting seizures but without seizure-associated falls; 3 of these patients had received anticonvulsive therapy, and 6 had received pacemaker implantation. Two patients (12.5%) who denied epileptic surgery and did not receive pacemaker implantation had persisting seizures and continuous falls. Based on these observations, the authors proposed a clinical algorithm for treating patients with symptomatic ictal bradyarrhythmias. They recommend that cardiac pacemaker should be

considered for symptomatic patients after optimizing antiepileptic therapy and discontinuing any coexisting arrhythmogenic medications. Recently, Bestawros *et al.*^[30] reported outcome data of 8 patients with IA who received pacemaker therapy. The authors stated that all patients remained free of syncope during a follow-up of 72 ± 95 mo.

Although most patients continued to have seizures after pacemaker implantation in the above-mentioned studies, some papers have suggested decreases in the number of seizures and in seizure intensity after pacemaker implantation^[31,32]. The mechanism of this unexpected finding is unclear; however, it has been suggested to be related to the effect of cardiac pacing on cardiac vagal afferents and their connections to the brain^[29]. However, in our opinion, a placebo effect of cardiac pacemaker implantation cannot be excluded, similar to the suggestion for vasovagal syncope^[33].

CONCLUSION

There is increasing awareness for ictal bradyarrhythmias as a cause of LOC in the cardiology community. A high degree of suspicion is necessary for diagnosing ictal bradyarrhythmias, and a delay in diagnosing this condition may lead to substantial morbidity for the patient. Based on the available data, a cardiac pacemaker might be related to decreased morbidity associated with falls and trauma. However, literature data also suggest that optimization of anticonvulsive therapy might be effective in preventing ictal bradyarrhythmias. In our opinion, pacemaker therapy should be reserved for patients who remain symptomatic after optimizing anticonvulsive therapy. Currently, no data are available related to any effect of cardiac pacemaker implantation on preventing SUDEP. Such evidence would be very useful for a potential indication of pacemaker therapy. The results of a randomized controlled study are urgently needed to clarify the pacemaker need in patients with ictal bradyarrhythmias.

REFERENCES

- 1 **Freeman R.** Cardiovascular manifestations of autonomic epilepsy. *Clin Auton Res* 2006; **16**: 12-17 [PMID: 16477490 DOI: 10.1007/s10286-006-0278-y]
- 2 **Blumhardt LD,** Smith PE, Owen L. Electrocardiographic accompaniments of temporal lobe epileptic seizures. *Lancet* 1986; **1**: 1051-1056 [PMID: 2871334 DOI: 10.1016/S0140-6736(86)91328-0]
- 3 **Keilson MJ,** Hauser WA, Magrill JP. Electrocardiographic changes during electrographic seizures. *Arch Neurol* 1989; **46**: 1169-1170 [PMID: 2818251 DOI: 10.1001/archneur.1989.00520470023018]
- 4 **Leutmezer F,** Scherthaner C, Lurger S, Pötzelberger K, Baumgartner C. Electrocardiographic changes at the onset of epileptic seizures. *Epilepsia* 2003; **44**: 348-354 [PMID: 12614390 DOI: 10.1046/j.1528-1157.2003.34702.x]
- 5 **Rocamora R,** Kurthen M, Lickfett L, Von Oertzen J, Elger CE. Cardiac asystole in epilepsy: clinical and neurophysiologic features. *Epilepsia* 2003; **44**: 179-185 [PMID: 12558571 DOI: 10.1046/j.1528-1157.2003.15101.x]
- 6 **Schuele SU,** Bermeo AC, Alexopoulos AV, Locatelli ER, Burgess

- RC, Dinner DS, Foldvary-Schaefer N. Video-electrographic and clinical features in patients with ictal asystole. *Neurology* 2007; **69**: 434-441 [PMID: 17664402 DOI: 10.1212/01.wnl.0000266595.77885.7f]
- 7 **Nei M.** Cardiac effects of seizures. *Epilepsy Curr* 2009; **9**: 91-95 [PMID: 19693322 DOI: 10.1111/j.1535-7511.2009.01303.x]
- 8 **Leung H, Kwan P, Elger CE.** Finding the missing link between ictal bradyarrhythmia, ictal asystole, and sudden unexpected death in epilepsy. *Epilepsy Behav* 2006; **9**: 19-30 [PMID: 16809068 DOI: 10.1016/j.yebeh.2006.05.009]
- 9 **Tu E, Bagnall RD, Dufflou J, Semsarian C.** Post-mortem review and genetic analysis of sudden unexpected death in epilepsy (SUDEP) cases. *Brain Pathol* 2011; **21**: 201-208 [PMID: 20875080 DOI: 10.1111/j.1750-3639.2010.00438.x]
- 10 **Britton JW, Benarroch E.** Seizures and syncope: anatomic basis and diagnostic considerations. *Clin Auton Res* 2006; **16**: 18-28 [PMID: 16477491 DOI: 10.1007/s10286-006-0277-z]
- 11 **Hilz MJ, Devinsky O, Doyle W, Mauerer A, Dütsch M.** Decrease of sympathetic cardiovascular modulation after temporal lobe epilepsy surgery. *Brain* 2002; **125**: 985-995 [PMID: 11960889 DOI: 10.1093/brain/awf092]
- 12 **van der Lende M, Surges R, Sander JW, Thijs RD.** Cardiac arrhythmias during or after epileptic seizures. *J Neurol Neurosurg Psychiatry* 2015; pii: jnnp-2015-310559 [PMID: 26038597 DOI: 10.1136/jnnp-2015-310559]
- 13 **Oppenheimer SM, Gelb A, Girvin JP, Hachinski VC.** Cardiovascular effects of human insular cortex stimulation. *Neurology* 1992; **42**: 1727-1732 [PMID: 1513461 DOI: 10.1212/WNL.42.9.1727]
- 14 **Tinuper P, Bisulli F, Cerullo A, Carcangiu R, Marini C, Pierangeli G, Cortelli P.** Ictal bradycardia in partial epileptic seizures: Autonomic investigation in three cases and literature review. *Brain* 2001; **124**: 2361-2371 [PMID: 11701591 DOI: 10.1093/brain/124.12.2361]
- 15 **Britton JW, Ghearing GR, Benarroch EE, Cascino GD.** The ictal bradycardia syndrome: localization and lateralization. *Epilepsia* 2006; **47**: 737-744 [PMID: 16650140 DOI: 10.1111/j.1528-1167.2006.00509.x]
- 16 **Jallon P.** Arrhythmogenic seizures. *Epilepsia* 1997; **38**: S43-S47 [PMID: 19909326 DOI: 10.1111/j.1528-1157.1997.tb06127.x]
- 17 **Schuele SU, Bermeo AC, Locatelli E, Burgess RC, Lüders HO.** Ictal asystole: a benign condition? *Epilepsia* 2008; **49**: 168-171 [PMID: 17900291 DOI: 10.1111/j.1528-1167.2007.01330.x]
- 18 **Lenkov DN, Volnova AB, Pope AR, Tsytsarev V.** Advantages and limitations of brain imaging methods in the research of absence epilepsy in humans and animal models. *J Neurosci Methods* 2013; **212**: 195-202 [PMID: 23137652 DOI: 10.1016/j.jneumeth.2012.10.018]
- 19 **Novy J, Carruzzo A, Pascale P, Maeder-Ingvar M, Genné D, Pruvot E, Despland PA, Rossetti AO.** Ictal bradycardia and asystole: an uncommon cause of syncope. *Int J Cardiol* 2009; **133**: e90-e93 [PMID: 18191241 DOI: 10.1016/j.ijcard.2007.11.038]
- 20 **Duplyakov D, Golovina G, Lyukshina N, Surkova E, Elger CE, Surges R.** Syncope, seizure-induced bradycardia and asystole: two cases and review of clinical and pathophysiological features. *Seizure* 2014; **23**: 506-511 [PMID: 24680552 DOI: 10.1016/j.seizure.2014.03.004]
- 21 **Giovannini G, Meletti S.** Ictal asystole as the first presentation of epilepsy: A case report and systematic literature review. *Epilepsy Behav Case Rep* 2014; **2**: 136-141 [PMID: 25667892 DOI: 10.1016/j.ebcr.2014.06.001]
- 22 **Zaidi A, Clough P, Cooper P, Scheepers B, Fitzpatrick AP.** Misdiagnosis of epilepsy: many seizure-like attacks have a cardiovascular cause. *J Am Coll Cardiol* 2000; **36**: 181-184 [PMID: 10898432 DOI: 10.1016/S0735-1097(00)00700-2]
- 23 **Rugg-Gunn FJ, Simister RJ, Squirrell M, Holdright DR, Duncan JS.** Cardiac arrhythmias in focal epilepsy: a prospective long-term study. *Lancet* 2004; **364**: 2212-2219 [PMID: 15610808 DOI: 10.1016/S0140-6736(04)17594-6]
- 24 **Strzelczyk A, Cenusa M, Bauer S, Hamer HM, Mothersill IW, Grunwald T, Hillenbrand B, Ebner A, Steinhoff BJ, Krämer G, Rosenow F.** Management and long-term outcome in patients presenting with ictal asystole or bradycardia. *Epilepsia* 2011; **52**: 1160-1167 [PMID: 21320110 DOI: 10.1111/j.1528-1167.2010.02961.x]
- 25 **Schuele SU, Bermeo AC, Alexopoulos AV, Burgess RC.** Anoxia-ischemia: a mechanism of seizure termination in ictal asystole. *Epilepsia* 2010; **51**: 170-173 [PMID: 19490047 DOI: 10.1111/j.1528-1167.2009.02168.x]
- 26 **Moseley BD, Ghearing GR, Benarroch EE, Britton JW.** Early seizure termination in ictal asystole. *Epilepsy Res* 2011; **97**: 220-224 [PMID: 21899987 DOI: 10.1016/j.eplepsyres.2011.08.008]
- 27 **Ghearing GR, Munger TM, Jaffe AS, Benarroch EE, Britton JW.** Ictal bradycardia: seizure semiology and treatment with cardiac pacing. *Ann Neurol* 2006; **60** Suppl 10: S-111
- 28 **Ghearing GR, Munger TM, Jaffe AS, Benarroch EE, Britton JW.** Clinical cues for detecting ictal asystole. *Clin Auton Res* 2007; **17**: 221-226 [PMID: 17636369 DOI: 10.1007/s10286-007-0429-9]
- 29 **Moseley BD, Ghearing GR, Munger TM, Britton JW.** The treatment of ictal asystole with cardiac pacing. *Epilepsia* 2011; **52**: e16-e19 [PMID: 21463267 DOI: 10.1111/j.1528-1167.2010.02972.x]
- 30 **Bestawros M, Darbar D, Arain A, Abou-Khalil B, Plummer D, Dupont WD, Raj SR.** Ictal asystole and ictal syncope: insights into clinical management. *Circ Arrhythm Electrophysiol* 2015; **8**: 159-164 [PMID: 25391254 DOI: 10.1161/CIRCEP.114.001667]
- 31 **Locatelli ER, Varghese JP, Shuaib A, Potolicchio SJ.** Cardiac asystole and bradycardia as a manifestation of left temporal lobe complex partial seizure. *Ann Intern Med* 1999; **130**: 581-583 [PMID: 10189328 DOI: 10.7326/0003-4819-130-7-199904060-00018]
- 32 **Rossetti AO, Dworetzky BA, Madsen JR, Golub O, Beckman JA, Bromfield EB.** Ictal asystole with convulsive syncope mimicking secondary generalisation: a depth electrode study. *J Neurol Neurosurg Psychiatry* 2005; **76**: 885-887 [PMID: 15897520 DOI: 10.1136/jnnp.2004.051839]
- 33 **Meissner K.** The placebo effect and the autonomic nervous system: evidence for an intimate relationship. *Philos Trans R Soc Lond B Biol Sci* 2011; **366**: 1808-1817 [PMID: 21576138 DOI: 10.1098/rstb.2010.0403]

P- Reviewer: Tsytsarev V

S- Editor: Ji FF **L- Editor:** A **E- Editor:** Jiao XK



Disease that should be remembered: Sacrococcygeal pilonidal sinus disease and short history

Burhan Hakan Kanat, Selim Sözen

Burhan Hakan Kanat, Department of General Surgery, Elazığ Training and Research Hospital, 23000 Elazığ, Turkey

Selim Sözen, Department of General Surgery, Medical Faculty, Namık Kemal University, 59000 Tekirdağ, Turkey

Author contributions: Kanat BH and Sözen S contributed equally to this work; Kanat BH and Sözen S designed the research; Kanat BH and Sözen S performed research; Kanat BH and Sözen S contributed new reagents or analytic tools; Kanat BH and Sözen S analyzed data; Kanat BH and Sözen S wrote the paper.

Conflict-of-interest statement: No conflict of interest was declared by the authors.

Open-Access: This article is an open-access article which was selected by an in-house editor and fully peer-reviewed by external reviewers. It is distributed in accordance with the Creative Commons Attribution Non Commercial (CC BY-NC 4.0) license, which permits others to distribute, remix, adapt, build upon this work non-commercially, and license their derivative works on different terms, provided the original work is properly cited and the use is non-commercial. See: <http://creativecommons.org/licenses/by-nc/4.0/>

Correspondence to: Burhan Hakan Kanat, MD, Department of General Surgery, Elazığ Training and Research Hospital, Rızaie neighborhood, İnönü street, Number:74, 23000 Elazığ, Turkey. burhankanat@hotmail.com
Telephone: +90-424-2381000
Fax: +90-424-2381000

Received: February 20, 2015
Peer-review started: February 22, 2015
First decision: April 10, 2015
Revised: May 8, 2015
Accepted: August 30, 2015
Article in press: August 31, 2015
Published online: October 16, 2015

Abstract

Pilonidal sinus disease has led to heated debates

since it was first described in the medical literature. Although a consensus has been built on its etiology and pathogenesis, the same course has not progressed for treatment modality. This review is a short article about the process of pilonidal sinus disease from past to present. Some important points were mentioned between the years 1833, which is accepted as the milestone for the awareness of the disease, in which it was first reported until the year of 1880, in which it was given its name. Although its name has been the same for about two centuries, some other names such as "Jeep Disease" have also been used depending on the population affected by the disease. At present, it is indisputable that the disease is acquired. Large series were presented about the treatment in the last two decades. Some surgical methods were even named after the ones who first described them and they have many supporters. However, since the treatment modalities have some advantages and disadvantages and they do not have marked superiority over others, debates still continue. We hope that pilonidal sinus disease will not lose its significance and be underrated in parallel with the developments in technology and specialization in medicine.

Key words: Pilonidal sinus; History; Anorectal disease

© **The Author(s) 2015.** Published by Baishideng Publishing Group Inc. All rights reserved.

Core tip: Pilonidal sinus disease has been a debate for about 2 centuries, about which many articles and reviews have been written until now. In this paper, some points that can be accepted as milestones were chronologically presented from the date in which it was first described until today. Since the debates still continue and there is no consensus on the treatment, we suggest that the debates will continue. For this reason and since this article shortly and clearly explains pilonidal sinus disease milestones, we think that it will contribute to the surgeons dealing with the issue.

Kanat BH, Sözen S. Disease that should be remembered: Sacrococcygeal pilonidal sinus disease and short history. *World J Clin Cases* 2015; 3(10): 876-879 Available from: URL: <http://www.wjgnet.com/2307-8960/full/v3/i10/876.htm> DOI: <http://dx.doi.org/10.12998/wjcc.v3.i10.876>

INTRODUCTION

Science, medicine in particular, cannot be evaluated without writing. Unwritten things are unreadable. Therefore, unread science and interventions cannot be learned and cannot be known. The basic rules of knowledge of medical experiences and interventions are written. It should be published for people to reach, after it is written; so the information can be transferred to the new generations.

HISTORICAL OVERVIEW

Therefore, the beginning dates of many diseases as old as the history of humans is the date that they were written for the first time. This date is 1833 for pilonidal sinus disease. Herbert Mayo, British Physiologist, Anatomist and Surgeon (3rd April 1796-28th June 1852), described it as a sinus containing hair follicles located in the sacrococcygeal region in a woman, in 1833^[1,2].

Afterwards, an article named "Hair Extracted from an Ulcer" published by Anderson^[3] in "Boston Medical Surgical Journal" in 1847 was found. He reported a case of a 21-year-old male with a Scrophuloderma on his back, in his article written as a letter to the editor. He reported that he drained the cavity after 3 wk and a structure looking like a mesh made of multiple hairs of 2 inches long and after complete drainage and cleaning of the hair in the cavity, the wound healed quickly^[3,4]. Seven years later, in 1854 Warren reported 3 similar cases and this study is the first case series known in the history of pilonidal sinus disease^[5].

The disease was given many names until 1880. Widely used ones are; sacral, coccygeal or sacrococcygeal infundibulum, dermoid and dermoid fistula, congenital dermal sinus and sacrococcygeal ectodermal sinus^[6].

Eventually, in 1880, Hodges^[7] named the disease with the statement of "I venture to give the name of pilo-nidal (pilus, a hair; nidus, a nest) sinus to this rather singular lesion." He produced the word "pilonidal" by conjoining the word "pilus" which means hair in Latin and "nidus" which means nest^[8].

ETIOLOGY AND PATHOGENESIS

Discussions about pilonidal sinus disease are still hot even though it was described 200 years ago. In the previous years, there were many fevered arguments and many theories to describe whether the disease is congenital or acquired.

80 years ago, Gage^[9] reported that pilonidal cyst and sinuses are congenital and he was supported. According to the congenital disease theory, it might have originated from caudal remnants of the neural tube, dermal inclusions produced by sequestered epithelial structures or dermal tractions that are produced during the involution of the tail during embryonic development^[9-11].

The disease was a commonly seen problem among soldiers in World War II, during which important explorations and developments were seen in medicine. It was detected to be particularly common among jeep drivers. It was emphasized that compression and irritation reaching the coccyx is important in the etiology and Buie^[12] stated that the disease is acquired in his article named "The Jeep Disease".

In 1946, after the war, Patey and Scarff^[13] demonstrated that it might be seen in other regions of the body. He wrote that a granulomatous reaction takes place following hair penetration of sub dermal tissue. In addition, he claimed that it is acquired, as it is also seen in the hands of barbers. Afterwards the idea of the disease being acquired became stronger with articles written by King^[14,15] in 1947 and 1950.

Two important names that shook the last 20 years of modern surgery in pilonidal disease supported and explained acquired disease theory as the discussions go on. Bascom^[16-19] says: "Only the bones get up when people stand up. Sacrum has to stick on to and pull up skin, fat and muscles to move the buttocks. This pulling process produces a vacuum effect all over the gluteal region. Hair enters the pit in case of a minor folliculitis as a result of the vacuum produced by the movement of the gluteal region".

Karydakos^[20], who published the largest pilonidal sinus case series in 1992, developed the most logical theory about the etiology and etiopathogenesis of the disease. He reported as a result of his 35 years of work on pilonidal sinus that the etiology is acquired. Especially minor local trauma is the most important predisposing factor of the disease. Hair penetration process is the basis of pilonidal sinus according to Karydakos^[21]. Three main factors play a role in embedding of hair: Invaders formed by free hair (H-hair), the force that provides hair embedding the (F-force), and the vulnerability of the skin that lets the embedding of the hair deeper in the gluteal region (V-vulnerability). Pilonidal sinus disease develops in cases in which these three factors are present together and the disease development possibility could be calculated with HxFxV formula^[20,21]. As a result, recently most of surgeons are in the opinion that the disease is acquired.

TREATMENT

What about the treatment besides the discussions about the name and etiology? No consensus is obtained about the treatment even though tens of treatment options are written and discussed.

One might think who cares about the treatment of a pilonidal sinus as there are many life threatening diseases in the field of general surgery. However tens of surgical and non-surgical treatment options are described. Discussions continue as the treatment options have advantages and disadvantages, and no option is preferable to the other ones significantly. Different surgical procedure descriptions and modification of surgeons' different procedures, lead to increase the numbers of surgical techniques^[22].

The ideal treatment for pilonidal disease should be simple, with short hospitalization, less pain, local anesthesia if possible, low cost, the patient should go back to daily activities in a short time and recurrence rates should be low after treatment. Combination of all these measures is not possible for all treatment options. Therefore, treatment procedures must be planned according to the patient.

Conservation or a surgical method should be chosen when the treatment is planned according to the patient. Unnecessary surgical operations should be avoided for patients that could be treated conservatively and also time and workforce waste should be avoided for a patient that requires surgical treatment by trying a conservative treatment.

Many surgical techniques are present from simple surgical treatment methods such as incision, drainage, unroofing, curettage, and secondary healing, to the described and modified techniques such as excision flap, Karydakís, Bascom, MacFee^[16-23]. In addition, conservative methods such as phenol solution, crystalized phenol technique, cauterization, and alcohol injection have also been used^[24-27]. No consensus was obtained as all authors advocate their own method. Treatment has to be planned according to the disease and the patient. Natural evaluation, recurrence reasons of the disease must be known very well and the state of the sacrococcygeal region should be evaluated carefully.

Pilonidal sinus caused interest in many aspects. Many materials such as the effect on quality of life and relationship with hormones were investigated and found place in the literature^[25,28]. Besides all these processes there is consensus about the symptoms and clinical presentation of the disease. Patients present with 4 different forms as symptomatic, acute pilonidal abscess, chronic fistulizing form or complex pilonidal sinus disease. Chronic fistulizant form is the most common clinical presentation^[26].

Where and how does the pilonidal sinus disease stand in general surgery? General surgeons used to take care of orthopedic emergencies, plastic, cardiovascular and thoracic surgery in 1950s. However, increased number of specializations emerged with the development of technology. Today, especially after the millennium a big portion of general surgeons in academic field are interested in specific fields of general surgery. Pilonidal sinus became a part of colorectal surgery as many diseases are addressed to specific fields. For example surgeons and centres interested in

hepatobiliary surgery, peripheric vascular surgery or transplantation surgery are distant to the subject.

I hope, surgeons working outside of big centres with specialization in specific surgical fields and colorectal surgeons will continue to pay adequate attention and each of us will take his/her part.

In surgery, there is no such thing as major or minor. Therefore, pilonidal sinus disease should not be underestimated. Sometimes treatment might disappoint both the surgeon and the patient. At a point that you think everything is going very well, you are face to face with repeating surgeries, insecurity and dissatisfaction of the patient, and fear of surgical failure.

With the hope that pilonidal sinus is never underestimated nor forgotten...

REFERENCES

- 1 **Mayo OH.** Observations on Injuries and Diseases of the Rectum. London: Burgess and Hill, 1833
- 2 **Khanna A, Rombeau JL.** Pilonidal disease. *Clin Colon Rectal Surg* 2011; **24**: 46-53 [PMID: 22379405 DOI: 10.1055/s-0031-1272823]
- 3 **Anderson AW.** Hair extracted from an ulcer. *Boston Med Surg J* 1847; **36**: 74-76 [DOI: 10.1056/NEJM184702240360402]
- 4 **Marvin L, editor.** Colon and Rectal Surgery. Corman, 2005: 616
- 5 **Warren JM.** Abscess containing hair on the nates. *Am Jour Med Sci* 1854; **28**: 113
- 6 **Kooistra HP.** Pilonidal sinuses Review of the literature and report of three hundred fifty cases. *Amer J Surg* 1942; **55**: 3-17
- 7 **Hodges RM.** Pilonidal sinus. *Boston Med Surg J* 1880; **103**: 485-486 [DOI: 10.1056/NEJM188011181032101]
- 8 **de Parades V, Bouchard D, Janier M, Berger A.** Pilonidal sinus disease. *J Visc Surg* 2013; **150**: 237-247 [PMID: 23911903 DOI: 10.1016/j.jvisc Surg.2013.05.006]
- 9 **Gage M.** Pilonidal sinuses: an explanation of its embryologic development. *Arch Surg* 1935; **31**: 175-189 [DOI: 10.1001/archsurg.1935.01180140003001]
- 10 **Gage M.** Pilonidal sinus: sacrococcygeal ectodermal cysts and sinuses. *Ann Surg* 1939; **109**: 291-303 [PMID: 17857325 DOI: 10.1097/00000658-193902000-00012]
- 11 **Stone HB.** The origin of Pilonidal Sinus. *Ann Surg* 1931; **94**: 311-315
- 12 **Buie LA.** Jeep disease. *South Med J* 1944; **37**: 103-109 [DOI: 10.1097/00007611-194402000-00012]
- 13 **Patey DH, Scarff RW.** Pathology of postanal pilonidal sinus; its bearing on treatment. *Lancet* 1946; **2**: 484-486 [PMID: 20998923 DOI: 10.1016/S0140-6736(46)91756-4]
- 14 **King ES.** The nature of the pilonidal sinus. *Aust N Z J Surg* 1947; **16**: 182-192 [PMID: 20295740 DOI: 10.1111/j.1445-2197.1947.tb03632.x]
- 15 **King ES.** The interdigital pilonidal sinus. *Aust N Z J Surg* 1949; **19**: 29-33 [PMID: 18138086 DOI: 10.1111/j.1445-2197.1949.tb03674.x]
- 16 **Bascom J.** Pilonidal disease: origin from follicles of hairs and results of follicle removal as treatment. *Surgery* 1980; **87**: 567-572 [PMID: 7368107]
- 17 **Bascom J, Bascom T.** Utility of the cleft lift procedure in refractory pilonidal disease. *Am J Surg* 2007; **193**: 606-609; discussion 609 [PMID: 17434365 DOI: 10.1016/j.amjsurg.2007.01.008]
- 18 **Bascom J.** Pilonidal disease: long-term results of follicle removal. *Dis Colon Rectum* 1983; **26**: 800-807 [PMID: 6641463 DOI: 10.1007/BF02554755]
- 19 **Bascom J.** The pathophysiology of pilonidal disease. The surgical treatment of pilonidal disease. Tezel E, editor. Nobel Tıp Kitapevleri Ankara, 2011
- 20 **Karydakís GE.** New approach to the problem of pilonidal sinus. *Lancet* 1973; **2**: 1414-1415 [PMID: 4128725 DOI: 10.1016/s0140-

- 6736(73)92803-1]
- 21 **Karydakis GE**. Easy and successful treatment of pilonidal sinus after explanation of its causative process. *Aust N Z J Surg* 1992; **62**: 385-389 [PMID: 1575660 DOI: 10.1111/j.1445-2197.1992.tb07208.x]
- 22 **Maurice BA**, Greenwood RK. A conservative treatment of pilonidal sinus. *Br J Surg* 1964; **51**: 510-512 [PMID: 14199061 DOI: 10.1002/bjs.1800510711]
- 23 **Girgin M**, Kanat BH, Ayten R, Cetinkaya Z, Kanat Z, Bozdağ A, Turkoglu A, Ilhan YS. Minimally invasive treatment of pilonidal disease: crystallized phenol and laser depilation. *Int Surg* 2012; **97**: 288-292 [PMID: 23294066 DOI: 10.9738/CC130.1]
- 24 **Girgin M**, Kanat BH. The results of a one-time crystallized phenol application for pilonidal sinus disease. *Indian J Surg* 2014; **76**: 17-20 [PMID: 24799778 DOI: 10.1007/s12262-012-0548-y]
- 25 **Emir S**, Topuz O, Kanat BH, Bali I. Sinotomy technique versus surgical excision with primary closure technique in pilonidal sinus disease. *Bosn J Basic Med Sci* 2014; **14**: 263-267 [PMID: 25428682 DOI: 10.17305/bjbms.2014.4.139]
- 26 **Kanat BH**, Bozan MB, Yazar FM, Yur M, Erol F, Özkan Z, Emir S, Urfalıoğlu A. Comparison of early surgery (unroofing-curettage) and elective surgery (Karydakis flap technique) in pilonidal sinus abscess cases. *Ulus Travma Acil Cerrahi Derg* 2014; **20**: 366-370 [PMID: 25541849 DOI: 10.5505/tjtes.2014.62547]
- 27 **Kayaalp C**, Olmez A, Aydın C, Piskin T, Kahraman L. Investigation of a one-time phenol application for pilonidal disease. *Med Princ Pract* 2010; **19**: 212-215 [PMID: 20357505 DOI: 10.1159/000285291]
- 28 **Özkan Z**, Aksoy N, Emir S, Kanat BH, Gönen AN, Yazar FM, Çimen AR. Investigation of the relationship between serum hormones and pilonidal sinus disease: a cross-sectional study. *Colorectal Dis* 2014; **16**: 311-314 [PMID: 24330514 DOI: 10.1111/codi.12520]

P- Reviewer: Fourtounas C, Hortobagyi T, Tan XR
S- Editor: Tian YL **L- Editor:** A **E- Editor:** Jiao XK



Retrospective Study

Improved bowel preparation increases polyp detection and unmasks significant polyp miss rate

Ioannis S Papanikolaou, Athanasios D Sioulas, Nektarios Magdalinos, Iosif Beintaris, Lazaros-Dimitrios Lazaridis, Dimitrios Polymeros, Chrysoula Malli, George D Dimitriadis, Konstantinos Triantafyllou

Ioannis S Papanikolaou, Athanasios D Sioulas, Iosif Beintaris, Lazaros-Dimitrios Lazaridis, Dimitrios Polymeros, Chrysoula Malli, George D Dimitriadis, Konstantinos Triantafyllou, Hepatogastroenterology Unit, Second Department of Internal Medicine and Research Institute, Attikon University General Hospital, Medical School, Athens University, 12462 Haidari, Greece

Nektarios Magdalinos, Salamina General Private Clinic, 18900 Salamina, Greece

Author contributions: Papanikolaou IS, Polymeros D, Dimitriadis GD and Triantafyllou K conceived the idea and designed the study; Papanikolaou IS and Magdalinos N performed the research; Beintaris I, Lazaridis LD and Malli C collected the data; Triantafyllou K analyzed the data; Papanikolaou IS, Sioulas AD and Triantafyllou K drafted the manuscript; all authors read and approved the final manuscript.

Institutional review board statement: IRBS was considered to be non-obligatory given that patients received the standard-of-care treatment in both endoscopic departments. Additionally, our retrospective research project involves use of existing information collected from human participants, but there are not any identifiers linking individuals to the data.

Informed consent statement: Patients were not required to give informed consent to the study because the analysis used anonymous clinical data that were obtained after each patient agreed to treatment by written consent.

Conflict-of-interest statement: None to declare.

Data sharing statement: There is no additional data available.

Open-Access: This article is an open-access article which was selected by an in-house editor and fully peer-reviewed by external reviewers. It is distributed in accordance with the Creative Commons Attribution Non Commercial (CC BY-NC 4.0) license, which permits others to distribute, remix, adapt, build upon this work non-commercially, and license their derivative works on different terms, provided the original work is properly cited and the use is non-commercial. See: <http://creativecommons.org/licenses/by-nc/4.0/>

Correspondence to: Athanasios D Sioulas, MD, PhD, Hepatogastroenterology Unit, Second Department of Internal Medicine and Research Institute, Attikon University General Hospital, Medical School, Athens University, Rimini 1, 12462 Haidari, Greece. athsioulas@yahoo.gr
Telephone: +30-697-4840723
Fax: +30-210-5832090

Received: January 31, 2015

Peer-review started: February 2, 2015

First decision: July 6, 2015

Revised: July 26, 2015

Accepted: September 16, 2015

Article in press: September 18, 2015

Published online: October 16, 2015

Abstract

AIM: To retrospectively compare previous-day *vs* split-dose preparation in terms of bowel cleanliness and polyp detection in patients referred for polypectomy.

METHODS: Fifty patients underwent two colonoscopies: one diagnostic in a private clinic and a second for polypectomy in a University Hospital. The latter procedures were performed within 12 wk of the index ones. Examinations were accomplished by two experienced endoscopists, different in each facility. Twenty-seven patients underwent screening/surveillance colonoscopy, while the rest were symptomatic. Previous day bowel preparation was utilized initially and split-dose for polypectomy. Colon cleansing was evaluated using the Aronchick scale. We measured the number of detected polyps, and the polyp miss rates per-polyp.

RESULTS: Excellent/good preparation was reported in 38 cases with previous-day preparation (76%) *vs* 46 with split-dose (92%), respectively ($P = 0.03$). One

hundred and twenty-six polyps were detected initially and 169 subsequently ($P < 0.0001$); 88 *vs* 126 polyps were diminutive ($P < 0.0001$), 25 *vs* 29 small ($P = 0.048$) and 13 *vs* 14 equal or larger than 10 mm. The miss rates for total, diminutive, small and large polyps were 25.4%, 30.1%, 13.7% and 6.6%, respectively. Multivariate analysis revealed that split-dose preparation was significantly associated (OR, P) with increased number of polyps detected overall (0.869, $P < 0.001$), in the right (0.418, $P = 0.008$) and in the left colon (0.452, $P = 0.02$).

CONCLUSION: Split-dose preparation improved colon cleansing, enhanced polyp detection and unmasked significant polyp miss rates.

Key words: Colonoscopy; Bowel preparation; Polyp miss rate; Polyp detection; Colorectal cancer

© The Author(s) 2015. Published by Baishideng Publishing Group Inc. All rights reserved.

Core tip: Colonoscopy and polypectomy are currently considered as the gold standard to prevent colorectal cancer. However, a significant proportion of precancerous lesions are missed during the procedure, limiting its efficacy and giving rise to interval cancers. Adequate bowel cleanliness represents a major factor with regards to colonoscopy quality. This study demonstrates that split-dose bowel preparation results to significantly better mucosal cleansing compared to previous-day preparation. Moreover, we showed that preparation with the split-dose regimen significantly enhanced polyp detection, especially of the diminutive ones. Finally, better inspection of the colonic epithelium unmasked a notable polyp miss rate.

Papanikolaou IS, Sioulas AD, Magdalinos N, Beintaris I, Lazaridis LD, Polymeros D, Malli C, Dimitriadis GD, Triantafyllou K. Improved bowel preparation increases polyp detection and unmasks significant polyp miss rate. *World J Clin Cases* 2015; 3(10): 880-886 Available from: URL: <http://www.wjgnet.com/2307-8960/full/v3/i10/880.htm> DOI: <http://dx.doi.org/10.12998/wjcc.v3.i10.880>

INTRODUCTION

Colonoscopy is currently regarded as the modality of choice, in order to reduce the incidence of colorectal cancer (CRC) and its associated mortality^[1]. The rationale behind this is its ability to detect and remove polyps that represent precancerous lesions^[2,3]. However, interval CRC, namely cases that are diagnosed between screening and post-screening surveillance examinations, do exist^[4,5]. The majority of them are thought to originate from missed polyps during colonoscopy. Polyp and adenoma miss rates reach 28% and 24%, respectively, in several studies reducing colonoscopy preventive

efficacy against CRC^[6,7].

Numerous technical-, patient- and endoscopist-related factors influence the detection of polyps during colonoscopy^[8-11]. In this setting, international associations of endoscopy include adenoma detection rate (ADR) among principal colonoscopy quality indicators^[12,13]. Poor bowel preparation is regarded as an impediment to the detection of both small and large polyps^[14]. Therefore, multiple interventions have been proposed to improve bowel cleansing and thus increase the quality of colonoscopy^[15-17].

Using a tandem colonoscopic evaluation we investigated the impact of different timing of purgative administration in colon cleansing and polyp detection. Polyp miss rates, as well as variables affecting polyp detection were also assessed.

MATERIALS AND METHODS

Study population

This retrospective study was performed on a consecutive series of patients from January to December 2012. All patients were diagnosed with colon polyps during colonoscopy in a small private clinic on an island near Athens and were referred for polypectomy in the Endoscopy Unit of "Attikon" University General Hospital. Exclusion criteria included: (1) age less than 18 or more than 80 years; (2) history of bowel resection; (3) history of inflammatory bowel diseases; (4) suspicion of polyposis syndrome; (5) incomplete colonoscopy (in one of the two examinations); (6) poor bowel preparation as assessed with the Aronchick scale; and (7) ongoing anticoagulation treatment.

Bowel preparation

Prior to the index colonoscopies, patients received the full dose of a 4-L polyethylene glycol (PEG) regimen (Fortrans, Ipsen, Athens, Greece) in the previous day. On the other hand, split dosing (3 L on the previous and 1 L on the same day) was preferred for the subsequent colonoscopies. In all cases patients were advised to maintain a low-fiber diet during the day preceding the examinations.

The quality of bowel cleansing was evaluated by the performing endoscopists using the Aronchick scale. This assesses the preparation quality of the entire colon as excellent (a small volume of clear liquid or greater than 95% of the surface seen), good (a large volume of clear liquid covering 5% to 25% of the surface but greater than 90% of the surface was seen), fair (some semisolid stool that could be suctioned or washed away, but greater than 90% of the surface was seen), poor (semisolid stool that could not be suctioned or washed away and less than 90% of the surface was seen), or inadequate (repeat preparation and colonoscopy was needed)^[18]. The evaluations of bowel cleanliness were further summarized as adequate (excellent/good) and inadequate (fair/poor).

Colonoscopy procedure

Two equally experienced endoscopists with experience of more than 5000 colonoscopies each did all the examinations. Specifically, one endoscopist conducted the diagnostic examinations using uniquely previous-day preparation and the other performed the second series with split-dose preparation. The endoscopist who performed the polypectomies was not aware of the number, size and location of polyps detected during the first colonoscopies and had no data regarding the quality of bowel preparation during index colonoscopies. Procedures were done using Olympus CF-Q145L standard-definition white-light colonoscopes (Olympus Corporation, Tokyo, Japan). Polypectomies were accomplished by means of forceps, snares or endoscopic mucosal resection, as needed.

All patients signed a standard informed consent form prior to the exam. Institutional ethics committee approval for our study was not needed, since all patients received the standard-of-care without reference to any study.

During the examinations, pulse rate, arterial blood pressure, oxygen saturation and consciousness level were monitored. Supplemental oxygen was routinely delivered *via* nasal catheters at 2 L/min. Intravenous conscious sedation and analgesia including midazolam (Dormicum, Roche Hellas, Athens, Greece) and pethidine hydrochloride (Petidina cloridrato, Molteni Farmaceutici Cilteni, Scandicci, Firenze, Italy) was administered depending on patient's willingness along with comorbidities and baseline vital signs assessment. Reversal agents including flumazenil (Anexate, Roche Hellas, Athens, Greece) and naloxone (Naloxon, B. Brown Melsungen AG, Melsungen, Germany) were available in case of sedation-related complications. No antispasmodics were administered.

In the first colonoscopies, the colonoscopes were advanced to the cecum and polyps were identified during both insertion and withdrawal, counted, but not removed. In the second examinations, all detected polyps were resected and sent for histologic evaluation. Adenomas larger than 1 cm and/or with high-grade dysplasia or a villous component more than 25% were defined as advanced adenomas. To note, numerous tiny hyperplastic polyps in the rectosigmoid area were not subject to assessment.

For each procedure eligible for analysis, the following data were collected: (1) patients' characteristics (age, gender, American Society of Anesthesiologists-ASA grade); (2) indication for colonoscopy; (3) sedation and oxygen administration; (4) bowel preparation quality; (5) polyp features (size, location, shape); and (6) other findings. According to their size, polyps were categorized as diminutive (≤ 5 mm), small (6-9 mm) and large (≥ 10 mm). Polyp size was determined by comparison with opened biopsy forceps. All colonoscopies were performed between 8:00 a.m. and 2:00 p.m.

Statistical analysis

Polyps per patient were calculated as number of detected polyps/number of patients. Polyp miss rates were calculated as: number of missed polyps/total number of missed polyps + total number of polyps on initial examination and presented as percentages. Both parameters were calculated overall and within strata of polyp size and location. Ideally, a third gold-standard preparation methodology against which comparisons regarding polyp miss rates were applied should be available. Since that was not the case in our retrospective trial we decided to use as reference the type of bowel preparation that showed better results regarding colon cleanliness. Therefore, no OR (95%CI) were calculated in the univariate analysis.

Continuous variables were presented as means or medians and standard deviations, while categorical ones were expressed as absolute values and percentages. Differences in the number of detected colon polyps (overall, right- and left-sided) between the two endoscopic procedures were examined using non-parametric related samples (Wilcoxon Signed Rank Test) tests.

A multivariate linear regression analysis model was constructed to examine variables associated with the number of polyps (overall, right- and left-sided) detected at colonoscopies (dependent variable). Independent variables include: patients' age; sex (male vs female), ASA grade (1 vs 2), indication for colonoscopy (screening/surveillance vs symptoms evaluation) and the quality of bowel preparation (adequate vs inadequate). The OR (95%CI) and the level of significance were calculated. A *P* value of less than 0.05 indicated statistical significance.

Statistical analysis of data was carried out by international business machines corporation (IBM) SPSS Statistics Client for Trial 32. bit 22.0 Microsoft Windows Multilingual (IBM, New York, USA).

RESULTS

Clinical characteristics

A total of 50 patients (28 male) completed both examinations; 4 patients were excluded. Reasons for exclusion were poor bowel preparation ($n = 3$) and failure to complete the second colonoscopy secondary to sedation-related hypoxemia ($n = 1$). Mean age was 58.4 ± 11.1 years. Indication for the index colonoscopies were: screening ($n = 22$), blood in stool ($n = 7$), abdominal pain ($n = 12$), family history of CRC ($n = 2$), altered bowel habits ($n = 4$) and post-polypectomy surveillance ($n = 3$). Median interval period between the two exams was 6 wk (range: 1-12).

Bowel preparation quality

Bowel preparation according to the Aronchick scale in the 2 series of colonoscopies was described as excellent in 17 (34%) vs 24 (48%) patients, good in 21 (42%)

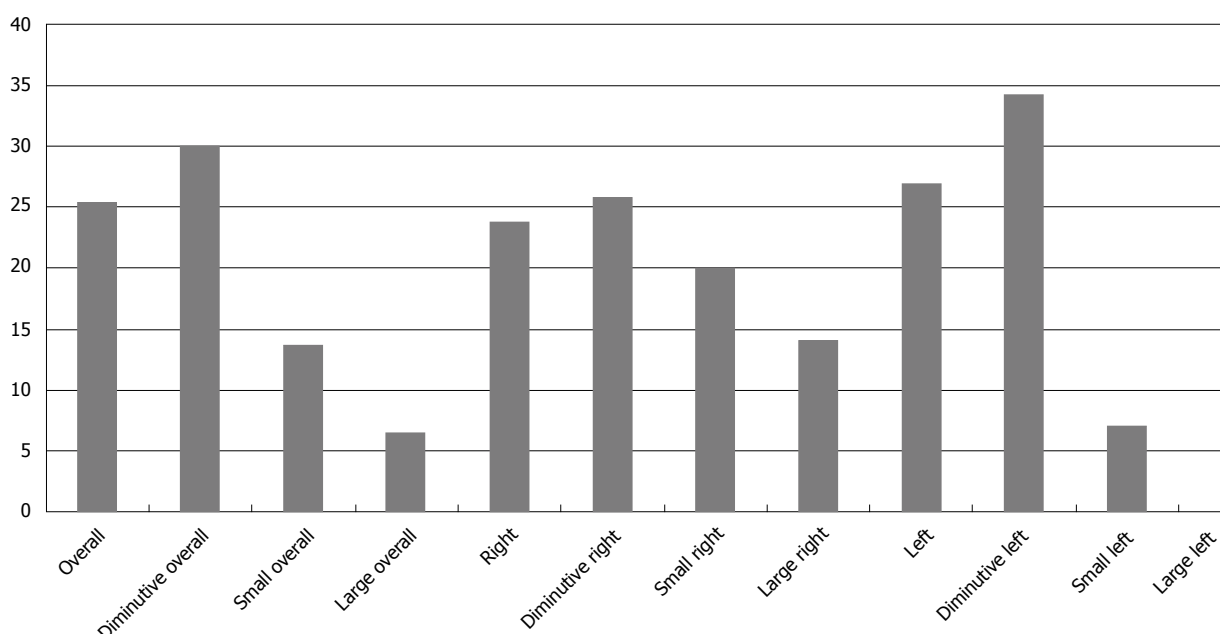


Figure 1 Polyp miss rates (as % percentages).

Table 1 Differences in number of detected polyps between the 2 colonoscopies

	Previous day	Split-dose	P value
Overall	126	169	< 0.001
Diminutive overall	88	126	< 0.001
Small overall	25	29	0.046
Large overall	13	14	0.317
Right	64	84	< 0.001
Diminutive right	46	62	< 0.001
Small right	12	15	0.083
Large right	6	7	0.317
Left	62	85	< 0.001
Diminutive left	42	64	< 0.001
Small left	13	14	0.317
Large left	7	7	1.000

vs 22 (44%) patients and fair in 12 (24%) vs 4 (8%) patients, respectively. When the evaluations of bowel cleanliness were classified as adequate (excellent/good) and inadequate (fair/poor), the second group of colonoscopies showed a significant increased rate of adequate preparations (92% vs 76%, $P = 0.03$).

Polyp detection and polyp miss rates

One hundred and twenty-six polyps were detected during the first examinations. Of those, 88 were diminutive, 25 small and 13 large; 43 additional polyps were identified during the tandem colonoscopies divided in 38 diminutive, 4 small and 1 large. Importantly, better colonic cleansing with the split-dose preparation contributed to significantly increased numbers of identified overall, right- and left-sided polyps ($P < 0.0001$). Significantly more diminutive polyps were detected throughout the colon ($P < 0.001$), while a marginal increase in the number of small polyps was

also revealed (Table 1).

The calculated miss rates regarding overall, diminutive, small and large polyps were 25.4%, 30.1%, 13.7% and 6.6%, respectively. The overall miss rates for polyps located in the right colon (cecum, ascending and transverse colon) was 23.8% compared with 27% in the left colon (distal to splenic flexure). Based on size, the miss rates for right-sided diminutive, small and large polyps were 25.8%, 20% and 14.2%, respectively, in comparison to 34.3%, 7.1% and 0%, respectively, for left-sided ones (Figure 1).

Linear regression analysis revealed that increased patients' age and split-dose bowel preparation were the only variables associated with the number of polyps detected overall. Split-dose bowel preparation entered the model first [OR = 0.869 (95%CI: 0.456-1.283); $P < 0.001$], followed by increased age [OR = 0.054 (95%CI: 0.017-0.092); $P = 0.005$]. The same variables were also associated with the number of polyps detected in the right colon. Split-dose bowel preparation entered the model first [OR = 0.418 (95%CI: 0.111-0.724); $P = 0.008$], followed by increased age [OR = 0.032 (95%CI: 0.004-0.060); $P = 0.024$]. Split-dose bowel preparation was the only variable associated with the number of polyps detected in the left colon [OR = 0.452 (95%CI: 0.076-0.828); $P = 0.02$].

Polyp histology

A total of 169 polyps were found and resected in 50 patients during the second series of colonoscopies. Histologic examination of resected polyps revealed tubular adenomas ($n = 110$), advanced adenomas ($n = 18$), serrated lesions ($n = 7$), hyperplastic polyps ($n = 51$) and adenocarcinoma ($n = 1$). Of note, 9 advanced adenomas and 4 serrated lesions were detected in the

right colon, while 9 and 3 respectively, similar lesions, were located in the left colon.

DISCUSSION

This study demonstrates that split-dose bowel preparation results to significantly better mucosal cleansing compared to previous-day preparation. Moreover, we showed that better preparation with the split-dose regimen significantly enhanced overall, right- and left-sided polyp detection, especially referring to diminutive ones. Furthermore, improved view of the colonic epithelium unmasked a noteworthy polyp miss rate, inversely linked to their size.

Colonoscopy is currently considered as the gold standard for the detection of colonic neoplasia. However, emerging data demonstrate that a significant proportion of precancerous lesions are missed during the procedure, limiting its efficacy and leading to interval cancers^[19].

It is established that variations in colonoscopy quality reflect differences in numerous patient-, procedure- and endoscopist-related parameters. Taking that into consideration, a great body of interventions has been conducted aiming to decrease colonoscopy's native imperfections, including internal audits and feedback to individual endoscopists, education in quality indicators, implementation of mandatory withdrawal times, bowel preparation modifications, discussion with poor-performers, introduction to emerging technologies, routine sedation administration, repeat attempts for cecal intubation and report card utilization^[20-22].

In terms of pre-colonoscopy bowel preparation, numerous interventions have been suggested. These include dietary modifications and various purgatives alone or combined with adjunctive agents (e.g., prokinetics, enemas, simethicone). Timing of bowel preparation administration has been tested in several randomized controlled trials focusing on bowel cleanliness and lesion detection. Recently, the European Society of Gastrointestinal Endoscopy adopted the results of a meta-analysis recommending split dose preparation for morning colonoscopies^[10,23,24]. In line with this, our study highlights the significantly better colon cleansing achieved with split-dose preparation, as well as its contribution to increase polyp detection. However, our splitting of PEG dose was 3:1, in contrast to the recommended 2:2. Additionally, we did not collect data with respect to patients' satisfaction, impact on daily activities and willingness to repeat the same bowel preparation in the future, if indicated.

Our data supports the importance of better bowel preparation in the detection of additional polyps. This finding is in line with the results of Gurudu *et al.*^[21] demonstrating improved polyp detection rates (PDR) and ADR with split-dosing. Unfortunately, we cannot provide information for possible differences in adenoma detection in the present study, as the index series of colonoscopies was diagnostic. However, PDR and ADR seem to correlate well, at least in segments proximal to

the splenic flexure^[25].

Miss rates for total, diminutive, small and large polyps were 25.4%, 30.1%, 13.7% and 6.6% respectively. These results indicate that the smaller the polyp size, the higher the polyp miss rate, which is in accordance to findings of previous studies^[6,26]. Location did not affect the polyp miss rates similarly to a recent study conducted by Ahn *et al.*^[27]. Interestingly, other data suggests that the risk of missing a polyp is related to left colon location^[28]. However, it should be clearly stated that no gold-standard bowel preparation method against which our studied alternatives (i.e., previous-day vs split-dose preparation) were compared in terms of polyp miss rates was available. Therefore, we favored split-dose preparation's findings to serve as comparator given that it yielded significantly better results as regards colon cleanliness. This reflects the current knowledge that the risk of missing polyps and adenomas during colonoscopy is affected by bowel preparation quality^[29]. Nevertheless, our assumption encompasses a disadvantage of this study and weakens its conclusions.

As obvious, this study bears several limitations. First, we enrolled a small number of patients, which limits the power of our results. Second, we used as reference methodology the results of the split-dose examination to calculate miss rates, as presented above. Third, we did not assess the inter-observer agreement considering bowel preparation status evaluation. Our results could have been affected by a possible significant discrepancy between the two examiners in rating preparation quality. Fourth, we could not provide data regarding histological features of polyps identified in the first series of colonoscopies (as they were not removed). Fifth, no reports of patients' preference in terms of timing of purgatives administration and comfort during the examinations were collected (the majority of patients had received sedation). Sixth, we did not capture data regarding withdrawal times which seem to influence ADRs. Additionally, we did not utilize validated scales such as Boston or Ottawa scales to assess the quality of cleansing in each bowel segment, as the Aronchick scale is closer to what an endoscopy unit uses in its "normal" -outside a study-practice, which was what we actually wanted to assess. Finally, we are not aware of the true polyp miss rate, since we considered the second colonoscopy as the gold standard.

In conclusion, our results support that split-dose bowel preparation improves the quality of colonoscopy in terms of mucosal cleanliness and polyp detection. However, future efforts to identify barriers and develop interventions aiming to further enhance colonoscopy effectiveness in the prevention of CRC are also necessary, as there are many factors that contribute to a high-quality examination.

COMMENTS

Background

Several factors influence colonoscopy quality and affect its potential to decrease

colorectal cancer incidence. Quality of bowel preparation represents one of the most studied ones. In this setting, numerous regimens, combinations and administration timings have been tested. Apart from rating bowel cleanliness achieved, polyp and adenoma detection seems to improve in parallel to the quality of preparation. This retrospective study assesses two different schedules of preparation regimen administration in terms of bowel cleansing and polyp detection.

Research frontiers

In this study it is suggested that splitting preparation regimen results in better quality of colon cleanliness than that achieved by previous-day dosing and leads to improved polyp detection.

Innovations and breakthroughs

The authors' 3:1 splitting of polyethylene glycol (PEG) regimen is shown to significantly improve the adequacy of bowel preparation and increase the number of detected polyps in both entire and colon segments. A remarkable polyp miss rate is substantially unmasked.

Applications

The results of this study serve as additional evidence aiming to improve colon cleanliness and polyp detection rates in every day clinical practice.

Terminology

Polyps per patient: number of detected polyps/number of patients. Polyp miss rates: number of missed polyps/total number of missed polyps + total number of polyps on initial examination. PEG is an osmotic laxative containing PEG, water and added electrolytes that is used in bowel preparation prior to colonoscopy and surgery.

Peer-review

The manuscript "Improved bowel preparation increases polyp detection and unmasks significant polyp miss rate" is clear and well-written. The manuscript reports on the comparison of two methodologies, full dose vs split dose, in colonoscopy and concludes with the report, that split-dose regimen enhanced polyp detection and reduced polyp miss rate.

REFERENCES

- Rex DK, Johnson DA, Anderson JC, Schoenfeld PS, Burke CA, Inadomi JM. American College of Gastroenterology guidelines for colorectal cancer screening 2009 [corrected]. *Am J Gastroenterol* 2009; **104**: 739-750 [PMID: 19240699 DOI: 10.1038/ajg.2009.104]
- Winawer SJ, Zauber AG, Ho MN, O'Brien MJ, Gottlieb LS, Sternberg SS, Wayne JD, Schapiro M, Bond JH, Panish JF. Prevention of colorectal cancer by colonoscopic polypectomy. The National Polyp Study Workgroup. *N Engl J Med* 1993; **329**: 1977-1981 [PMID: 8247072 DOI: 10.1056/NEJM199312303292701]
- Citarda F, Tomaselli G, Capocaccia R, Barcherini S, Crespi M. Efficacy in standard clinical practice of colonoscopic polypectomy in reducing colorectal cancer incidence. *Gut* 2001; **48**: 812-815 [PMID: 11358901 DOI: 10.1136/gut.48.6.812]
- Robertson DJ, Lieberman DA, Winawer SJ, Ahnen DJ, Baron JA, Schatzkin A, Cross AJ, Zauber AG, Church TR, Lance P, Greenberg ER, Martinez ME. Colorectal cancers soon after colonoscopy: a pooled multicohort analysis. *Gut* 2014; **63**: 949-956 [PMID: 23793224 DOI: 10.1136/gutjnl-2012-303796]
- Huang Y, Gong W, Su B, Zhi F, Liu S, Jiang B. Risk and cause of interval colorectal cancer after colonoscopic polypectomy. *Digestion* 2012; **86**: 148-154 [PMID: 22889865 DOI: 10.1159/000338680]
- van Rijn JC, Reitsma JB, Stoker J, Bossuyt PM, van Deventer SJ, Dekker E. Polyp miss rate determined by tandem colonoscopy: a systematic review. *Am J Gastroenterol* 2006; **101**: 343-350 [PMID: 16454841 DOI: 10.1111/j.1572-0241.2006.00390.x]
- Rex DK, Cutler CS, Lemmel GT, Rahmani EY, Clark DW, Helper DJ, Lehman GA, Mark DG. Colonoscopic miss rates of adenomas determined by back-to-back colonoscopies. *Gastroenterology* 1997; **112**: 24-28 [PMID: 8978338 DOI: 10.1016/S0016-5085(97)70214-2]
- Benson ME, Reichelderfer M, Said A, Gaumnitz EA, Pfau PR. Variation in colonoscopic technique and adenoma detection rates at an academic gastroenterology unit. *Dig Dis Sci* 2010; **55**: 166-171 [PMID: 19156519 DOI: 10.1007/s10620-008-0703-2]
- Long MD, Martin C, Sandler RS, Herfarth HH, Shaheen NJ, Dellon ES. Reduced polyp detection as endoscopy shift progresses: experience with screening colonoscopy at a tertiary-care hospital. *J Clin Gastroenterol* 2011; **45**: 253-258 [PMID: 21085007 DOI: 10.1097/MCG.0b013e3181fd2998]
- Kilgore TW, Abdinoor AA, Szary NM, Schowengerdt SW, Yust KB, Choudhary A, Matteson ML, Puli SR, Marshall JB, Bechtold ML. Bowel preparation with split-dose polyethylene glycol before colonoscopy: a meta-analysis of randomized controlled trials. *Gastrointest Endosc* 2011; **73**: 1240-1245 [PMID: 21628016 DOI: 10.1016/j.gie.2011.02.007]
- Lee TJ, Rees CJ, Blanks RG, Moss SM, Nickerson C, Wright KC, James PW, McNally RJ, Patnick J, Rutter MD. Colonoscopic factors associated with adenoma detection in a national colorectal cancer screening program. *Endoscopy* 2014; **46**: 203-211 [PMID: 24473907 DOI: 10.1055/s-0033-1358831]
- Rex DK, Petrini JL, Baron TH, Chak A, Cohen J, Deal SE, Hoffman B, Jacobson BC, Mergener K, Petersen BT, Safdi MA, Faigel DO, Pike IM. Quality indicators for colonoscopy. *Gastrointest Endosc* 2006; **63**: S16-S28 [PMID: 16564908 DOI: 10.1016/j.gie.2006.02.021]
- Rembacken B, Hassan C, Riemann JF, Chilton A, Rutter M, Dumonceau JM, Omar M, Ponchon T. Quality in screening colonoscopy: position statement of the European Society of Gastrointestinal Endoscopy (ESGE). *Endoscopy* 2012; **44**: 957-968 [PMID: 22987217 DOI: 10.1055/s-0032-1325686]
- Harewood GC, Sharma VK, de Garmo P. Impact of colonoscopy preparation quality on detection of suspected colonic neoplasia. *Gastrointest Endosc* 2003; **58**: 76-79 [PMID: 12838225 DOI: 10.1067/mge.2003.294]
- Brahmania M, Ou G, Bressler B, Ko HK, Lam E, Telford J, Enns R. 2 L versus 4 L of PEG3350 + electrolytes for outpatient colonic preparation: a randomized, controlled trial. *Gastrointest Endosc* 2014; **79**: 408-416.e4 [PMID: 24206747 DOI: 10.1016/j.gie.2013.08.035]
- de Leone A, Tamayo D, Fiori G, Ravizza D, Trovato C, De Roberto G, Fazzini L, Dal Fante M, Crosta C. Same-day 2-L PEG-citrate-simethicone plus bisacodyl vs split 4-L PEG: Bowel cleansing for late-morning colonoscopy. *World J Gastrointest Endosc* 2013; **5**: 433-439 [PMID: 24044042 DOI: 10.4253/wjge.v5.i9.433]
- Park JJ, Lee SK, Jang JY, Kim HJ, Kim NH. The effectiveness of simethicone in improving visibility during colonoscopy. *Hepatogastroenterology* 2009; **56**: 1321-1325 [PMID: 19950784]
- Aronchick CA. Bowel preparation scale. *Gastrointest Endosc* 2004; **60**: 1037-1038; author reply 1038-1039 [PMID: 15605036 DOI: 10.1016/S0016-5107(04)02213-8]
- Kaminski MF, Regula J, Kraszewska E, Polkowski M, Wojciechowska U, Didkowska J, Zwierko M, Rupinski M, Nowacki MP, Butruk E. Quality indicators for colonoscopy and the risk of interval cancer. *N Engl J Med* 2010; **362**: 1795-1803 [PMID: 20463339 DOI: 10.1056/NEJMoa0907667]
- Taber A, Romagnuolo J. Effect of simply recording colonoscopy withdrawal time on polyp and adenoma detection rates. *Gastrointest Endosc* 2010; **71**: 782-786 [PMID: 20363418 DOI: 10.1016/j.gie.2009.12.008]
- Gurudu SR, Ramirez FC, Harrison ME, Leighton JA, Crowell MD. Increased adenoma detection rate with system-wide implementation of a split-dose preparation for colonoscopy. *Gastrointest Endosc* 2012; **76**: 603-8.e1 [PMID: 22732876]
- Imperiali G, Minoli G, Meucci GM, Spinzi G, Strocchi E, Terruzzi V, Radaelli F. Effectiveness of a continuous quality improvement program on colonoscopy practice. *Endoscopy* 2007; **39**: 314-318 [PMID: 17273959 DOI: 10.1055/s-2006-945196]

- 23 **Parra-Blanco A**, Nicolas-Perez D, Gimeno-Garcia A, Grosso B, Jimenez A, Ortega J, Quintero E. The timing of bowel preparation before colonoscopy determines the quality of cleansing, and is a significant factor contributing to the detection of flat lesions: a randomized study. *World J Gastroenterol* 2006; **12**: 6161-6166 [PMID: 17036388]
- 24 **Hassan C**, Bretthauer M, Kaminski MF, Polkowski M, Rembacken B, Saunders B, Benamouzig R, Holme O, Green S, Kuiper T, Marmo R, Omar M, Petruzzello L, Spada C, Zullo A, Dumonceau JM. Bowel preparation for colonoscopy: European Society of Gastrointestinal Endoscopy (ESGE) guideline. *Endoscopy* 2013; **45**: 142-150 [PMID: 23335011 DOI: 10.1055/s-0032-1326186]
- 25 **Boroff ES**, Gurudu SR, Hentz JG, Leighton JA, Ramirez FC. Polyp and adenoma detection rates in the proximal and distal colon. *Am J Gastroenterol* 2013; **108**: 993-999 [PMID: 23567353 DOI: 10.1038/ajg.2013.68]
- 26 **Heresbach D**, Barrioz T, Lapalus MG, Coumaros D, Bauret P, Potier P, Sautereau D, Boustière C, Grimaud JC, Barthélémy C, Sée J, Serraj I, D'Halluin PN, Branger B, Ponchon T. Miss rate for colorectal neoplastic polyps: a prospective multicenter study of back-to-back video colonoscopies. *Endoscopy* 2008; **40**: 284-290 [PMID: 18389446 DOI: 10.1055/s-2007-995618]
- 27 **Ahn SB**, Han DS, Bae JH, Byun TJ, Kim JP, Eun CS. The Miss Rate for Colorectal Adenoma Determined by Quality-Adjusted, Back-to-Back Colonoscopies. *Gut Liver* 2012; **6**: 64-70 [PMID: 22375173 DOI: 10.5009/gnl.2012.6.1.64]
- 28 **Leufkens AM**, van Oijen MG, Vleggaar FP, Siersema PD. Factors influencing the miss rate of polyps in a back-to-back colonoscopy study. *Endoscopy* 2012; **44**: 470-475 [PMID: 22441756 DOI: 10.1055/s-0031-1291666]
- 29 **Hong SN**, Sung IK, Kim JH, Choe WH, Kim BK, Ko SY, Lee JH, Seol DC, Ahn SY, Lee SY, Park HS, Shim CS. The Effect of the Bowel Preparation Status on the Risk of Missing Polyp and Adenoma during Screening Colonoscopy: A Tandem Colonoscopic Study. *Clin Endosc* 2012; **45**: 404-411 [PMID: 23251889 DOI: 10.5946/ce.2012.45.4.404]

P- Reviewer: Berkemeyer S, Sidiropoulou Z

S- Editor: Song XX **L- Editor:** A **E- Editor:** Jiao XK



Prospective Study

New tapered metallic stent for unresectable malignant hilar bile duct obstruction

Yuji Sakai, Toshio Tsuyuguchi, Takao Nishikawa, Harutoshi Sugiyama, Reina Sasaki, Dai Sakamoto, Yuto Watanabe, Masato Nakamura, Shin Yasui, Rintaro Mikata, Osamu Yokosuka

Yuji Sakai, Toshio Tsuyuguchi, Takao Nishikawa, Harutoshi Sugiyama, Reina Sasaki, Dai Sakamoto, Yuto Watanabe, Masato Nakamura, Shin Yasui, Rintaro Mikata, Osamu Yokosuka, Department of Gastroenterology and Nephrology, Graduate School of Medicine, Chiba University, Chiba City 260-8670, Japan

Author contributions: Sakai Y, Tsuyuguchi T and Yokosuka O were responsible for the study design, data analysis, and manuscript preparation; Sakai Y wrote the paper; Sakai Y, Tsuyuguchi T, Nishikawa T, Sugiyama H, Sasaki R, Watanabe Y, Yasui S and Mikata R performed endoscopic treatment; Sakamoto D and Nakamura M were responsible for data collection.

Institutional review board statement: This study was conducted under approval of our ethical committee, and was registered as prospective clinical trial.

Clinical trial registration statement: UMIN Clinical Trial Registry (UMIN000004758).

Informed consent statement: All the treatment procedures were performed after obtaining the informed consent in writing from the patients.

Conflict-of-interest statement: The authors have no other disclosures.

Data sharing statement: I share data in the group of us.

Open-Access: This article is an open-access article which was selected by an in-house editor and fully peer-reviewed by external reviewers. It is distributed in accordance with the Creative Commons Attribution Non Commercial (CC BY-NC 4.0) license, which permits others to distribute, remix, adapt, build upon this work non-commercially, and license their derivative works on different terms, provided the original work is properly cited and the use is non-commercial. See: <http://creativecommons.org/licenses/by-nc/4.0/>

Correspondence to: Yuji Sakai, MD, Department of Gastroen-

terology and Nephrology, Graduate School of Medicine, Chiba University, Inohana 1-8-1, Chuou-ku, Chiba City 260-8670, Japan. sakai4754@yahoo.co.jp
Telephone: +81-43-2262083
Fax: +81-43-2262088

Received: April 6, 2015
Peer-review started: April 8, 2015
First decision: June 4, 2015
Revised: July 12, 2015
Accepted: August 10, 2015
Article in press: August 11, 2015
Published online: October 16, 2015

Abstract

AIM: To examine the usefulness of a new tapered metallic stent (MS) in patients with unresectable malignant hilar bile duct obstruction.

METHODS: This new tapered MS was placed in 11 patients with Bismuth II or severer unresectable malignant hilar bile duct obstruction, as a prospective study. The subjects were six patients with bile duct carcinoma, three with gallbladder cancer, and two with metastatic bile duct obstruction. Stenosis morphology was Bismuth II : 7, IIIa: 3, and IV: 1. UMIN Clinical Trial Registry (UMIN000004758).

RESULTS: MS placement was 100% (11/11) successful. There were no procedural accidents. The mean patency period was 208.401 d, the median survival period was 142.000 d, and the mean survival period was 193.273 d. Occlusion rate was 36.4% (4/11); the causes of occlusion were ingrowth and overgrowth in 2 patients each, 18.2%, respectively. Patients with occlusion underwent endoscopic treatment one more time and all

were treatable.

CONCLUSION: The tapered MS proved useful in patients with unresectable malignant hilar bile duct obstruction because it provided a long patency period, enabled re-treatment by re-intervention, and no procedural accidents occurred.

Key words: Malignant hilar bile duct obstruction; Metallic stent; Tapered metallic stent

© **The Author(s) 2015.** Published by Baishideng Publishing Group Inc. All rights reserved.

Core tip: Placement of a tapered metallic stent in patients with unresectable malignant hilar bile duct obstruction proved useful because it allowed a longer patency period without procedural accidents.

Sakai Y, Tsuyuguchi T, Nishikawa T, Sugiyama H, Sasaki R, Sakamoto D, Watanabe Y, Nakamura M, Yasui S, Mikata R, Yokosuka O. New tapered metallic stent for unresectable malignant hilar bile duct obstruction. *World J Clin Cases* 2015; 3(10): 887-893 Available from: URL: <http://www.wjgnet.com/2307-8960/full/v3/i10/887.htm> DOI: <http://dx.doi.org/10.12998/wjcc.v3.i10.887>

INTRODUCTION

The guidelines for biliary cancer diagnosis recommend drainage as frequent as possible in patients with unresectable malignant hilar bile duct obstruction for improvement of patient's quality of life or when performing chemotherapy^[1]. As an approach route for hilar bile duct occlusion, there are surgical, percutaneous, and transpapillary routes; and the region where drainage can be carried out differs depending on the location of the tumor, thus it is very difficult to establish treatment strategies. An endoscopic approach is recommended as the drainage route because of the low invasiveness and high success rate of internal drainage^[1]. Metallic stents (MSs) are considered useful for internal drainage in terms of patency period^[1]. Even past randomized controlled trials reported that MSs are associated with a longer patency period and lower occlusion rate than plastic stents (PSs)^[2,3]. Under such considerations, it may be necessary to set the strategies to use MSs in patients with unresectable malignant hilar bile duct obstruction. In this study we examine the usefulness of a new tapered MS developed for exclusive use in patients with unresectable malignant hilar bile duct obstruction.

MATERIALS AND METHODS

The patients with unresectable malignant hilar bile duct obstruction and showed a remarkable increase of hepatobiliary enzymes, had Bismuth II or higher

degree stenosis according to Bismuth classification^[4] and had been treated between July 2011 to December 2012 were included in this study (Table 1). There were 11 patients (7 men and 4 women) aged 72.273 ± 10.771 (59-85) years. The diagnosis was established based on a combination of images plus pathological findings. The cause of obstruction was bile duct carcinoma in 6, gallbladder cancer in 3, and metastatic bile duct obstruction in 2 patients. We evaluated the intrahepatic bile duct with a little contrast media. Stenosis morphology was Bismuth II in 7, IIIa in 3, and IV in 1 patient. The stenosis was 22.727 ± 8.545 (10-35) mm long. Remarkable increase of hepatobiliary enzymes was defined as a value double or more the normal value of ALT (IU/L), ALP (IU/L), or T-Bil (mg/dL), or a combination of them. ALT (IU/L) was 114.055 ± 96.915 , ALP (IU/L) was 1157.09 ± 420.250 , and T-Bil (mg/dL) was 5.427 ± 4.4365 prior to drainage. Inclusion criteria were: (1) Patients with unresectable malignant hilar bile duct obstruction; (2) No criteria on underlying disease, age or sex; and (3) Patients who gave their informed consent. Exclusion criteria were: (1) Patients in whom the endoscopic approach was difficult; (2) Patients with a bleeding tendency; (3) Patients who had suffered serious procedural accidents; (4) Patients who did not provide their informed consent; and (5) Patients who were determined not to be appropriate by the physician in charge. The MS was placed in all the patients *via* the endoscopic retrograde cholangiopancreatography (ERCP) route. Magnetic resonance cholangiopancreatography was performed in all of them before drainage. There was no case of cholangitis. Chemotherapy was performed in 6 patients and 5 received the best supportive care. The patients were followed up from MS placement to their death, and if patients were alive by March 2014 they were evaluated. Before ERCP, all patients were given the standard premedication consisting of intravenous administration of midazolam (3 to 10 mg), and the dose depended on age and tolerance. Scopolamine butylbromide or glucagon was used for duodenal relaxation. During ERCP, arterial oxygen saturation was continuously monitored using a pulse oximeter. Patients were kept fasting after the procedure for at least 24 h with drip infusion of 2000 mL and stayed in the hospital for at least 72 h. They received 8-h infusion of a protease inhibitor (nafamostat mesilate, 20 mg/d) and were prescribed antibiotics (SBT/CPZ, 2 g/d) for 2 d. For cannulation, catheters PR-104Q, R110Q-1 and PR233Q were used. Wire-guided cannulation was not performed. A 0.025-inch or 0.035-inch guidewire (Jagwire: Microvasive, Boston Scientific Corp., Natick, MA, Revo Wave: PIOLAX, or VisiGlide: Olympus Corp., Tokyo, Japan) was used. The endoscopes used were JF240, JF260V, TJF260V (Olympus Corp.), backward side-viewing endoscopes. After cholangiography, a guidewire was placed in the bile duct to conduct endoscopic sphincterotomy (EST). Clever-Cut3V

Table 1 Patient background

Case	Sex	Age	Disease	Stent no.	Stenosis morphology	Stenosis length (mm)	Treatment
1	Male	60	Intrahepatic bile duct carcinoma	2	Bismuth II	25	BSC
2	Male	59	Colon cancer	1	Bismuth IIIa	33	Chemotherapy
3	Female	85	Intrahepatic bile duct carcinoma	1	Bismuth IIIa	28	Chemotherapy
4	Female	85	Bile duct carcinoma	2	Bismuth IV	35	BSC
5	Male	67	Intrahepatic bile duct carcinoma	2	Bismuth II	18	Chemotherapy
6	Female	61	Gallbladder cancer	2	Bismuth II	17	BSC
7	Male	65	Gallbladder cancer	1	Bismuth II	18	Chemotherapy
8	Female	85	Gallbladder cancer	2	Bismuth II	22	BSC
9	Male	81	Colon cancer	1	Bismuth II	32	BSC
10	Male	79	Bile duct carcinoma	1	Bismuth IIIa	10	Chemotherapy
11	Male	68	Bile duct carcinoma	1	Bismuth II	12	Chemotherapy

BSC: Best supportive care.




Figure 1 The metallic stent at the top is the ordinary laser-cut uncovered metallic stent. The one at the bottom is the laser-cut uncovered metallic stent (PIOLAX: Japan) created for exclusive use in the liver. This metallic stent is 8 cm in full size with a 3-cm tapered tip and a mesh space of 6-8 mm in the center of the stent; its internal diameter is 10 mm in the papillary side and 8 mm in the hepatic side.

(Olympus Corp.) was used as the knife for EST. EST was conducted using a single electrosurgical current generator (PSD-20, Olympus Corp.) at a power of 25 watts. EST was carried out in all the patients. The effect of drainage was determined by placing an endoscopic nasobiliary drainage (ENBD), or a PS in either the right or left bile duct. The effect of drainage was evaluated 7 d after drainage placement, and it was determined effective if the T-Bil was normal or 2/3 or less; then a tapered MS was placed. In patients without effective drainage, ENBD or PS was placed in the bile duct in the side where the drainage is not placed. An ENBD tube of 7 Fr. was used (FLEXIMA: Boston Scientific Corp., Natick, MA, or SD9: SILUX Straight type). Tube stents of 7 Fr., 8.5 Fr. and 10 Fr. were used (FLEXIMA: Boston Scientific Corp., or SD9: SILUX Straight type). And if the drainage was effective, the new tapered MS was placed in the region. As for tapered MSs, the delivery system

is a laser-cut MS created for use exclusively in the liver. These MSs are 7 Fr in size, with a full length of 8 cm and a 3-cm tapered tip. The mesh space is 6-8 mm at the center of the stent, and its internal diameter in the papillary side is 10 mm, while in the hepatic side it is 8 mm (PIOLAX: Japan) (Figure 1). In patients for whom two tapered MSs were required, stenting was performed in the partial stent-in-stent manner^[5-7]. The axial force and radial force of this MS were evaluated as follows. Axial force is the unbending force of the MS from the curved part. To measure the axial force, a portion of the stent was pushed perpendicularly by a force gauge (model DPX-5TR, Imada, Tokyo) until the angle became 60 degrees, and the force necessary to keep it in place was recorded. The measurement was made in an oven at 37 °C for 3 points distant 20, 40, and 60 mm from the bending point. Radial force is the dilating force of the MS. Radial force was measured using a radial force

Table 2 Comparison of alanine transaminase values before drainage and after metallic stent insertion

Case	ALT before drainage (IU/L)	ALT after MS insertion (IU/L)	P-value
1	63	54	
2	165	26	
3	182	32	
4	263	53	
5	75	14	
6	326	52	
7	69	25	
8	37	25	
9	115	25	
10	39	22	
11	212	35	
Average	114.055 ± 96.915	33.00 ± 13.892	P < 0.05

MS: Metallic stent; ALT: Alanine transaminase.

Table 3 Comparison of alkaline phosphatase values before drainage and after metallic stent insertion

Case	ALP before drainage (IU/L)	ALP after MS insertion (IU/L)	P-value
1	1524	1288	
2	1113	490	
3	1200	386	
4	1726	775	
5	605	354	
6	1289	254	
7	1524	956	
8	638	256	
9	1611	956	
10	610	238	
11	888	283	
Average	1157.09 ± 420.250	566.91 ± 365.157	P < 0.05

MS: Metallic stent; ALP: Alkaline phosphatase.

measurement machine (RX 500, Machine Solutions, Flagstaff, Ariz) in an oven at 37 °C. An MS sample in a fully expanded state was placed in the cylindric space of the machine, and the cylinder was contracted to shrink the MS to its minimum size of 2 mm. Then the force on the cylinder was reserved by an expansion force of the MS until it achieved its fully expanded state of 10 mm in diameter. The placement success rate, patency period, occlusion rate, and success rate of re-intervention of this MS were examined. Procedural accidents during ERCP-related procedures were evaluated according to Cotton's classification^[8]. When the jaundice level was T-Bil 3 mg/dL less, we started chemotherapy. This study was conducted under approval of our ethical committee, and was registered as prospective clinical trial. UMIN Clinical Trial Registry (UMIN000004758).

Statistical analysis

Fisher's exact probability test, student's *t*-test, and the Mann-Whitney *U*-test were used for statistical analyses to compare the blood test findings prior to drainage

Table 4 Comparison of T-Bil values before drainage and after metallic stent insertion

Case	T-Bil before drainage (mg/dL)	T-Bil after MS insertion (mg/dL)	P-value
1	13.9	3.8	
2	3	1	
3	12	1	
4	1.4	0.7	
5	3.1	0.9	
6	10.2	2.1	
7	2.3	1.3	
8	3	1	
9	1.8	1.3	
10	3.8	1	
11	5.2	1	
Average	5.427 ± 4.4365	1.373 ± 0.8833	P < 0.05

MS: Metallic stent.

insertion and post MS insertion. A *P* value < 0.05 was regarded as significant. Cumulative stent patency and survival were estimated using the Kaplan-Meier estimator. Data were analyzed using SPSS software version 17 (SPSS, Chicago, IL).

RESULTS

Initial drainage was successful in 6 (54.5%) of the eleven patients, and the remaining 5 (45.5%) had poor drainage thus drainage in the right and left bile ducts was performed. In the end, drainage was successful in all the patients. Since drainage was effective, MS was placed in all of them. In the six patients who underwent unilateral bile duct drainage one MS was placed, while in the five patients who underwent right and left bile duct drainage, two MS were placed; stenting was successful in all the patients. The mean number of MSs used was 1.545 ± 0.522 (1-2). All the parameters assessed at one week after stenting showed significant improvement compared with those before drainage insertion: ALT 33.00 ± 13.892 (IU/L), ALP 566.91 ± 365.157 (IU/L), and T-Bil 1.373 ± 0.8833 (mg/dL) (Tables 2-4). There were no procedural accidents due to stenting. The axial force of this MS was 0.156 ± 0.017 N when evaluated at bending point 20 mm, and radial force was 4.76 ± 0.18 N when evaluated at a dilated diameter of 4 mm. The patency of MS is shown in Table 5. The mean patency period was 208.401 d, the median survival period was 142.000 d (mean 193.273 d). The occlusion rate was 36.4% (4/11), and the occlusion causes were ingrowth in 2 (18.2%) patients and overgrowth in another 2 (18.2%). Patients with occlusion underwent endoscopic treatment one more time and in all of them it was 100% (4/4) successful. In patients who developed overgrowth in the contralateral hepatic side, an MS was placed in the partial stent-in-stent manner. In patients with an MS in each bile duct who developed overgrowth, an MS was additionally placed. In two patients with two MSs in the right and

Table 5 Achievements of metallic stent placement

Case	Survival period (d)	Alive or dead	Patency period (d)	Absence or presence of occlusion	Occlusion cause	Re-intervention
1	142	Dead	126	+	Ingrowth	PS
2	122	Dead	86	+	Ingrowth	PS
3	213	Dead	213	-	-	-
4	93	Dead	93	-	-	-
5	245	Dead	245	-	-	-
6	78	Dead	78	-	-	-
7	533	Alive	130	+	Overgrowth	MS
8	123	Dead	123	-	-	-
9	145	Dead	75	+	Overgrowth	MS
10	127	Dead	127	-	-	-
11	305	Dead	305	-	-	-
Mean	142		208.401	-	-	-
Median	193.273		-	-	-	-

MS: Metallic stent; PS: Plastic stent.

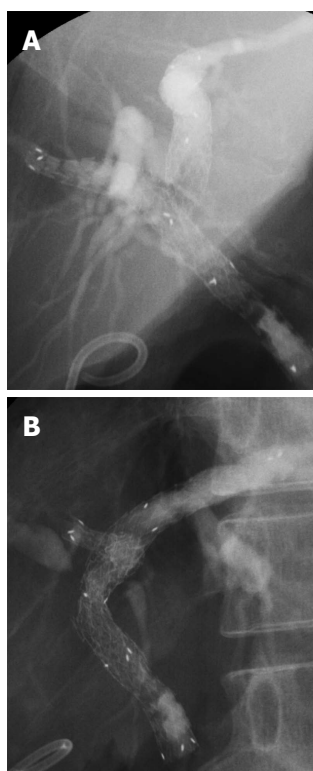


Figure 2 New tapered metallic stent (fluoroscopic image). A: Tapered laser-cut metallic stent placed in the liver. Stenting along the shape of the bile duct was possible (fluoroscopic image: front view); B: Fluoroscopic image: oblique view.

left bile duct who developed ingrowth, two PSs were placed in the right and left bile duct in the stent-in-stent manner. Re-treatment was successful in all the occlusion patients. The accidental occurrence symptom about the ERCP related procedures did not accept it.

DISCUSSION

In this study we evaluated a new tapered MS for unresectable malignant hilar bile duct obstruction. The MS used in this study was the laser-cut MS that enables precise stenting because shortening is structurally

less^[5]. Although evaluation may be partially difficult due to the small sample size, we experienced no procedural accidents during insertion, the patency period was long, and re-intervention was successful in all the patients; thus we consider this is a useful stent. This MS has moderate radial force at low axial force^[9]. With regard to procedural accidents, this MS has low axial force, which enables stenting along the bile duct and may prevent kinking. When an MS is placed, usually procedural accidents such as acute pancreatitis or acute cholecystitis do not occur, however, abdominal pain may occur^[10]. There may be various causes for this, including stress on the bile duct due to high axial force or strong radial force of the MS, or to a mismatch of the bile duct and MS regarding diameter, especially if the MS is of a diameter larger than that of the hepatic bile duct. The MS used in this study has a low axial force and a moderate radial force as shown in past reports; thus it is useful to treat stenosis and carry out stenting while applying low pressure on the bile duct. Furthermore, the tip is tapered, enabling good positioning of the stent (Figure 2). This may reduce the risk of abdominal pain due to stenting and of procedural complications such as hepatic abscess because the Glisson's sheath is not compressed. In this study no procedural accidents occurred; still if pancreatography is performed frequently during the procedure or it is difficult to catheterize the bile duct, pancreatitis might occur after ERCP^[11,12].

As for the patency period, the sample size was small and thus evaluation is difficult. However, the patency period was in the same range as that found in a previous report of similar sample size, and which was considered as satisfactory^[13]. The nature of the tumor, effect of chemotherapy, and characteristics of the MS itself may influence the patency period; yet, these should be evaluated in a study involving a large number of patients in the future.

Re-treatment was 100% (4/4) successful. Recent advancement of endoscopes and medical devices has enabled re-treatment in a comparatively easy




Figure 3 Laser-cut metallic stent with a comparatively large mesh space of about 6.8 mm × 8.0 mm in the center.

way. This MS has a large mesh space that facilitates re-intervention. Indeed, Mukai *et al.*^[14] reported that in the liver MSs with a large mesh space were an excellent choice because it was easier to re-intervene. Furthermore, other authors have also reported on the usefulness of MSs with a large mesh space that were created for exclusive use in the liver in patients with unresectable malignant hilar bile duct obstruction^[13,15]. The MSs used in these reports were of the braided type with a mesh space of 7 mm; that is, a space similar to that of the mesh space of the laser-cut tapered MS used in this study (Figure 3). The laser-cut tapered MS used in this study has a large mesh space, which facilitates manipulation through the mesh and re-intervention. From such results and reports, it is currently considered that MSs with a large mesh space may be an excellent choice for use in the liver. Compared with the braided MS, the laser-cut MS used in this study hardly suffered shortening and enabled precise placement. However, in the future it may be necessary a randomized clinical trial to assess which one is best regarding placement success rate and patency period.

Our results suggested that the new tapered MS was useful for patients with unresectable malignant hilar bile duct obstruction because the patency period was long, re-treatment was possible, and there were no

procedural accidents during their insertion.

COMMENTS

Background

Even past randomized controlled trials reported that metallic stents (MSs) are associated with a longer patency period and lower occlusion rate than plastic stents. Under such considerations, it may be necessary to set the strategies to use MSs in patients with unresectable malignant hilar bile duct obstruction.

Research frontiers

In this study, the authors examine the usefulness of a new tapered MS developed for exclusive use in patients with unresectable malignant hilar bile duct obstruction.

Innovations and breakthroughs

It may be necessary to set the strategies to use MSs in patients with unresectable malignant hilar bile duct obstruction.

Applications

A new tapered MS developed for exclusive use in patients with unresectable malignant hilar bile duct obstruction.

Terminology

The results suggested that the new tapered MS was useful for patients with unresectable malignant hilar bile duct obstruction because the patency period was long, re-treatment was possible, and there were no procedural accidents during their insertion.

Peer-review

This study prospectively estimated the efficacy of an uncovered metal stent with slightly tapered shape in its distal end for the patients with malignant biliary obstruction at the liver hilum.

REFERENCES

- 1 **Tsuyuguchi T**, Takada T, Miyazaki M, Miyakawa S, Tsukada K, Nagino M, Kondo S, Furuse J, Saito H, Suyama M, Kimura F, Yoshitomi H, Nozawa S, Yoshida M, Wada K, Amano H, Miura F. Stenting and interventional radiology for obstructive jaundice in patients with unresectable biliary tract carcinomas. *J Hepatobiliary Pancreat Surg* 2008; **15**: 69-73 [PMID: 18274846 DOI: 10.1007/s00534-007-1282-x]
- 2 **Wagner HJ**, Knyrim K, Vakil N, Klose KJ. Plastic endoprotheses versus metal stents in the palliative treatment of malignant hilar biliary obstruction. A prospective and randomized trial. *Endoscopy* 1993; **25**: 213-218 [PMID: 7686100]
- 3 **Mukai T**, Yasuda I, Nakashima M, Doi S, Iwashita T, Iwata K, Kato T, Tomita E, Moriwaki H. Metallic stents are more efficacious than plastic stents in unresectable malignant hilar biliary strictures: a randomized controlled trial. *J Hepatobiliary Pancreat Sci* 2013; **20**: 214-222 [PMID: 22415652 DOI: 10.1007/s00534-012-0508-8]
- 4 **Bismuth H**, Nakache R, Diamond T. Management strategies in resection for hilar cholangiocarcinoma. *Ann Surg* 1992; **215**: 31-38 [PMID: 1309988]
- 5 **Kawamoto H**, Tsutsumi K, Harada R, Fujii M, Kato H, Hirao K, Kurihara N, Nakanishi T, Mizuno O, Ishida E, Ogawa T, Fukatsu H, Sakaguchi K. Endoscopic deployment of multiple JOSTENT SelfX is effective and safe in treatment of malignant hilar biliary strictures. *Clin Gastroenterol Hepatol* 2008; **6**: 401-408 [PMID: 18328793 DOI: 10.1016/j.cgh.2007.12.036]
- 6 **Kawamoto H**, Tsutsumi K, Fujii M, Harada R, Kato H, Hirao K, Kurihara N, Nakanishi T, Mizuno O, Ishida E, Ogawa T, Fukatsu H, Sakaguchi K. Endoscopic 3-branched partial stent-in-stent deployment of metallic stents in high-grade malignant hilar biliary stricture (with videos). *Gastrointest Endosc* 2007; **66**: 1030-1037 [PMID: 17963891]
- 7 **Kawamoto H**, Tsutsumi K, Fujii M, Harada R, Kato H, Hirao K, Kurihara N, Nakanishi T, Mizuno O, Ishida E, Ogawa T, Fukatsu H, Sakaguchi K. Multiple stenting in a patient with a high-grade malignant hilar biliary stricture: endoscopic four-branched partial stent-in-stent deployment of metallic stents. *Endoscopy* 2007; **39** Suppl 1: E167-E168 [PMID: 17614071]
- 8 **Cotton PB**, Lehman G, Vennes J, Geenen JE, Russell RC, Meyers WC, Liguory C, Nickl N. Endoscopic sphincterotomy complications and their management: an attempt at consensus. *Gastrointest Endosc* 2009; **37**: 383-393 [PMID: 2070995]
- 9 **Isayama H**, Nakai Y, Toyokawa Y, Togawa O, Gon C, Ito Y, Yashima Y, Yagioka H, Kogure H, Sasaki T, Arizumi T, Matsubara S, Yamamoto N, Sasahira N, Hirano K, Tsujino T, Toda N, Tada M, Kawabe T, Omata M. Measurement of radial and axial forces of biliary self-expandable metallic stents. *Gastrointest Endosc* 2009; **70**: 37-44 [PMID: 19249766]
- 10 **Ho H**, Mahajan A, Gosain S, Jain A, Brock A, Rehan ME, Ellen K, Shami VM, Kahaleh M. Management of complications associated with partially covered biliary metal stents. *Dig Dis Sci* 2010; **55**: 516-522 [PMID: 19267200]
- 11 **Freeman ML**, Nelson DB, Sherman S, Haber GB, Herman ME, Dorsher PJ, Moore JP, Fennerty MB, Ryan ME, Shaw MJ, Lande JD, Pheley AM. Complications of endoscopic biliary sphincterotomy. *N Engl J Med* 1996; **335**: 909-918 [PMID: 8782497]
- 12 **Freeman ML**, DiSario JA, Nelson DB, Fennerty MB, Lee JG, Bjorkman DJ, Overby CS, Aas J, Ryan ME, Bochna GS, Shaw MJ, Snady HW, Erickson RV, Moore JP, Roel JP. Risk factors for post-ERCP pancreatitis: a prospective, multicenter study. *Gastrointest Endosc* 2001; **54**: 425-434 [PMID: 11577302]
- 13 **Kogure H**, Isayama H, Nakai Y, Tsujino T, Ito Y, Yamamoto K, Mizuno S, Yagioka H, Kawakubo K, Sasaki T, Hirano K, Sasahira N, Tada M, Omata M, Koike K. Newly designed large cell Niti-S stent for malignant hilar biliary obstruction: a pilot study. *Surg Endosc* 2011; **25**: 463-467 [PMID: 20602139]
- 14 **Mukai T**, Yasuda I, Isayama H, Nakashima M, Doi S, Iwashita T, Iwata K, Kato T, Tomita E, Moriwaki H. Comparison of axial force and cell width of self-expandable metallic stents: which type of stent is better suited for hilar biliary strictures? *J Hepatobiliary Pancreat Sci* 2011; **18**: 646-652 [PMID: 21647558]
- 15 **Kogure H**, Isayama H, Nakai Y, Tsujino T, Matsubara S, Yashima Y, Ito Y, Hamada T, Takahara N, Miyabayashi K, Mizuno S, Mohri D, Kawakubo K, Sasaki T, Yamamoto N, Hirano K, Sasahira N, Tada M, Koike K. High single-session success rate of endoscopic bilateral stent-in-stent placement with modified large cell Niti-S stents for malignant hilar biliary obstruction. *Dig Endosc* 2014; **26**: 93-99 [PMID: 23517109 DOI: 10.1111/den.12055]

P- Reviewer: Kanno Y, Singh V

S- Editor: Ji FF L- Editor: A E- Editor: Jiao XK



Littoral cell angioma: A case report

Amanda Bailey, Jeffrey Vos, Jon Cardinal

Amanda Bailey, Jon Cardinal, Department of Surgery, West Virginia University, Morgantown, WV 26508-9238, United States

Jeffrey Vos, Department of Pathology, West Virginia University, Morgantown, WV 26508-9238, United States

Author contributions: Bailey A wrote the case report and compiled the table; Vos J contributed the pathology analysis and provided the collection of pathological images; Cardinal J critically revised the intellectual content and contributed to the design of the table.

Institutional review board statement: This study has been approved by West Virginia University.

Conflict-of-interest statement: There are no conflicts of interest to be declared by the authors of this paper.

Open-Access: This article is an open-access article which was selected by an in-house editor and fully peer-reviewed by external reviewers. It is distributed in accordance with the Creative Commons Attribution Non Commercial (CC BY-NC 4.0) license, which permits others to distribute, remix, adapt, build upon this work non-commercially, and license their derivative works on different terms, provided the original work is properly cited and the use is non-commercial. See: <http://creativecommons.org/licenses/by-nc/4.0/>

Correspondence to: Amanda Bailey, DO (General Surgery Resident), Department of Surgery, West Virginia University, P.O. Box 9238 HSCS, Morgantown, WV 26508-9238, United States. aobailey@hsc.wvu.edu
Telephone: +1-904-3030223

Received: April 14, 2015

Peer-review started: April 14, 2015

First decision: June 3, 2015

Revised: June 21, 2015

Accepted: August 4, 2015

Article in press: August 7, 2015

Published online: October 16, 2015

Abstract

Primary splenic lesions are rare entities among which

littoral cell angioma (LCA) is a recently described, uncommon vascular lesion that is unique to the spleen. It has heretofore been described primarily in pathologic series and has been found mostly to behave as a benign entity. A few reports of malignant variants have been reported. We present a case report of a solitary LCA discovered after splenectomy for an incidentally discovered splenic lesion, along with a literature review.

Key words: Littoral cell angioma; Splenic tumor

© **The Author(s) 2015.** Published by Baishideng Publishing Group Inc. All rights reserved.

Core tip: Littoral cell angioma (LCA) is a rare benign vascular lesion of the spleen. LCA can range from no symptoms to a vague set of symptoms such as: abdominal pain, splenomegaly, thrombocytopenia, anemia, fever, chills, weakness and fatigue. Diagnosis is made by histopathology after splenectomy.

Bailey A, Vos J, Cardinal J. Littoral cell angioma: A case report. *World J Clin Cases* 2015; 3(10): 894-899 Available from: URL: <http://www.wjgnet.com/2307-8960/full/v3/i10/894.htm> DOI: <http://dx.doi.org/10.12998/wjcc.v3.i10.894>

INTRODUCTION

Primary splenic tumors are uncommon and are classified as lymphoid tumors, non-lymphoid tumors, and tumor like lesions^[1-12] (Table 1). Among non-lymphoid tumors, vascular neoplasms are the most common and arise from the vascular elements that compose the splenic red pulp. Conversely, the lymphatic tissue containing splenic white pulp is from where lymphoid neoplasms arise. In regards to vascular tumors of the spleen, the biologic behavior can be both benign and malignant.

Littoral cell angioma (LCA) of the spleen is a rare vascular tumor that was first described in 1991 by Bhatt *et al*^[13]. Initially thought to be benign, the biologic

Table 1 Classification of splenic tumors with associated clinical, pathological and radiological factors^[11-12]

Category	Type	Clinical	Pathological	Radiological
Lymphoid	Non Hodgkin lymphoma	Fevers, sweats, change in weight are common symptoms	Derived from B or T cells, lympho-proliferative	CT: Hypodense nodules, diffuse or military distribution MRI: Isotense on precontrast images, hypotense on postcontrast images
	Hodgkins lymphoma	Spleen is a rare primary site	Nodular sclerosis subtype, Reed-Sternberg cells	CT: Hypodense nodules with nodular sclerosis
	Inflammatory pseudotumor	Secondary to inflammatory response to infection or injury Benign	Spindle cells, lymphocytes in fibroblastic stroma	CT: Well circumscribed +/- calcifications, hypoattenuating MRI: Hypo- or isointense on T1 images. Variable signaling on T2 images
	Plasmacytoma	Rare diagnosis	Diffuse infiltration of plasma cells	Not well categorized findings
	Histiocytic lymphoma	Non specific symptoms, elevated ESR	Nodules with central necrosis	US: Cystic appearance CT: Sharply demarcated with central necrosis
	Hemangioma	Benign, slow growth, asymptomatic	Sinusoidal epithelium, proliferation of vascular channels	Solid to cystic components US: Echogenic solid to complex mass CT: Iso- to hypoattenuation associated with calcification MRI: Hypo- to isointense on T1 images, hyperintense on T2 images
	Hamartoma	Benign, asymptomatic. Associated with tuberous sclerosis and Wiskott Aldrich	Solid nodules, well circumscribed, well defined gross appearance. Unorganized vascular channels with fibrotic cords	US: More sensitive than CT, solid mass +/- calcification CT: Isoattenuating MRI: Isointense on T1 images, hyperintense on T2 images
Vascular	Lymphangioma	Asymptomatic, benign, mostly in children	Multiple solitary nodules, Flattened endothelium with proteinaceous material in a capillary, cavernous or cystic presentation	US: Splenic cysts hypoechoic septations CT: Thin walled low attenuation masses, subcapsular location MRI: Hypointense on T1 images, hyperintense on T2 images
	Littoral cell angioma	Asymptomatic, benign with malignant potential	Well delineated nodules of anastomosing vascular channels with endothelial cells	US: Hypoechoic to hyperechoic CT: Iso to hypoattenuating with contrast enhancement MRI: Low intensity lesions
	Angiosarcoma	Older patients, malignant, nonspecific symptoms	Diffuse involvement of spleen arises from sinus endothelial cells, high mitotic rate	US: Complex mass, heterogenous, necrotic degeneration CT: Ill-defined mass with heterogenous enhancement, punctate calcification MRI: Mixed signal intensity on T1 and T2
	Hemangioendothelioma	Nonspecific symptoms, young adults	Variable morphologic appearance	US: Hypoechoic mass CT: Low attenuated mass with enhancement of solid portions MRI: Heterogenous solid mass. Hypointense on T1 and T2 images
Non-lymphoid	Fibrosarcoma	Asymptomatic	Well differentiated, spindle shaped, fibroblasts, collagen is commonly present	Non specific imaging findings
	Lipoma	Asymptomatic	Adipose tissue, no atypia, cytoplasmic vacuoles	CT: Well defined fat density mass
	Kaposi sarcoma	Associated with HIV/AIDS +/- skin lesions	Spindle cell proliferation, spongelike vascular channels	CT: Ill-defined nodules, homogeneous US: Hyperechoic nodules
	Peliosis	Associated with anabolic steroid, TB, AIDS, cancer. Asymptomatic	Cyst like blood filled cavities within splenic parenchyma	US: Echogenic mass CT: Hypoattenuating, multiloculated with septa
Tumor like	Nonparasitic cysts	Congenital or neoplastic in origin. Benign.	Varies according to type of cyst including dermoid cyst	US: Cystic lesions with solid components CT: Hypoattenuating lesions, well defined
	Granulomas	Associated with chronic granulomatous disease and sarcoidosis	Granulomas non-necrotizing or necrotizing	CT: Hypodense nodules MRI: Hypointense T1 and T2

ESR: Erythrocyte sedimentation rate; CT: Computed tomography; MRI: Magnetic resonance imaging; US: Ultrasound; HIV: Human immunodeficiency virus; AIDS: Acquired immunodeficiency syndrome; TB: Tuberculosis.

behavior of LCA has not been firmly established, as there have been several reports of LCA with malignant features^[14,15]. LCA may occur at any age and has no gender predilection. To date, a total of 110 cases have

been reported in the literature with 4 published pathologic series and 3 published case series^[13,16-32].

LCA is discovered as a splenic lesion in patients who are undergoing a workup for laboratory evidence

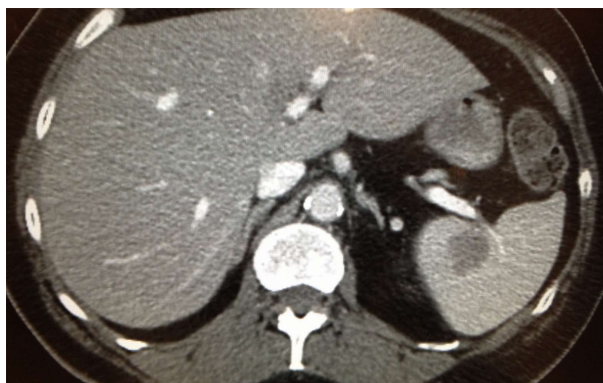

Figure 1 Computed tomography abdomen and pelvis, axial view of hypodense splenic lesion.

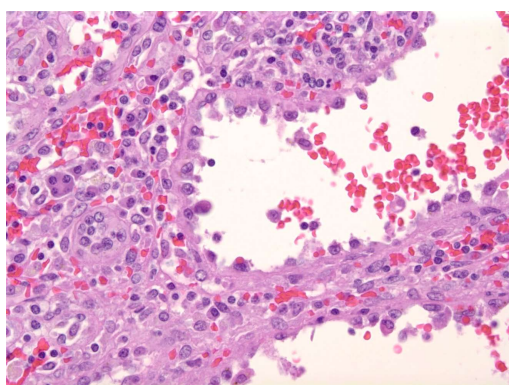


Figure 2 High power view of the tumor demonstrates tall columnar endothelial cells that line the cyst-like spaces. These cells show no cytologic, nuclear atypia or mitotic figures (H and E stain, $\times 400$).

of anemia or thrombocytopenia^[33-36]. Imaging findings of LCA are nonspecific and splenomegaly, to a varying degree, is a common finding. Due to the nonspecific findings that often result from the diagnostic workup, splenectomy is often performed for both diagnostic and therapeutic purposes. In the present report, a case of an incidentally discovered LCA is described.

CASE REPORT

A 65-year-old female presented to the outpatient oncology surgery clinic for surgical evaluation of a 2.2 cm splenic lesion. The lesion was discovered incidentally on a computed tomography (CT) abdomen/pelvis study to evaluate recurrent urinary tract infections (Figure 1). Also, the CT scan revealed a second incidental finding of a 1.1 cm right adrenal nodule. The patient was asymptomatic without abdominal pain, persistent fever, chills, weight loss, or other constitutional symptoms. Her past medical history included hypertension, diabetes mellitus, gout and peripheral neuropathy. Physical examination was unremarkable except for abdominal wall scars from prior open hysterectomy, cholecystectomy and left nephrectomy, the latter of which was performed at a young age for a nonfunctioning

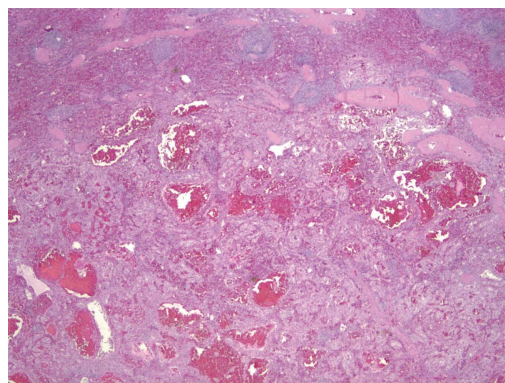


Figure 3 Low power view of the well-demarcated tumor with uninvolved spleen. The tumor has anastomosing vascular channels and cyst-like hemorrhagic spaces.

left kidney secondary to congenital ureteropelvic junction obstruction. A biochemical workup to exclude a functioning adrenal tumor was performed and included serum renin and aldosterone levels as well as 24 h urinary fractionated metanephrine and cortisol levels, all of which were within the limits of normal. Of note, she was not leukopenic, anemic or thrombocytopenic.

Given the size of her incidentally discovered splenic lesion, she was offered operative resection for diagnostic purposes. Based on her extensive prior surgical history, an open approach to the splenectomy was planned. The patient received preoperative pneumococcal, meningococcal and haemophilus B vaccinations. The operation and recovery were uneventful and the patient was discharged to home on postoperative day four.

Grossly, the spleen weighed 270 g and measured 23.3 cm \times 18.1 cm \times 7.2 cm. The splenic lesion measured 2 cm \times 2 cm \times 2 cm. Histopathologically, the tumor was found to have anastomosing vascular channels with large cyst formations which were lined predominately by tall, histiocytoid cells which projected into the vascular spaces along with interspersed flat endothelial cells (Figures 2 and 3). Immunohistochemically, the cells comprising the tumor stained positive for CD68 and lysozyme (Figures 4A and B). The specimen also showed variable expression of S100. CD34 and CD31 stains were positive on the endothelial cells, however negative on the histiocytoid cells (Figures 4C and D). Final pathologic diagnosis was littoral cell angioma.

DISCUSSION

LCA is a rare vascular neoplasm of the spleen. It has been found to affect both men and women in an equal distribution. Given the relative lack of symptom specificity, LCA is most often found incidentally as a splenic mass on abdominal imaging; however, two cases of LCA presenting with splenic rupture and hemoperitoneum have been reported^[37,38]. The sonographic appearance of LCA is variable, and ranges from a hypoechoic to a hyperechoic mass with a mottled texture^[14]. On contrast

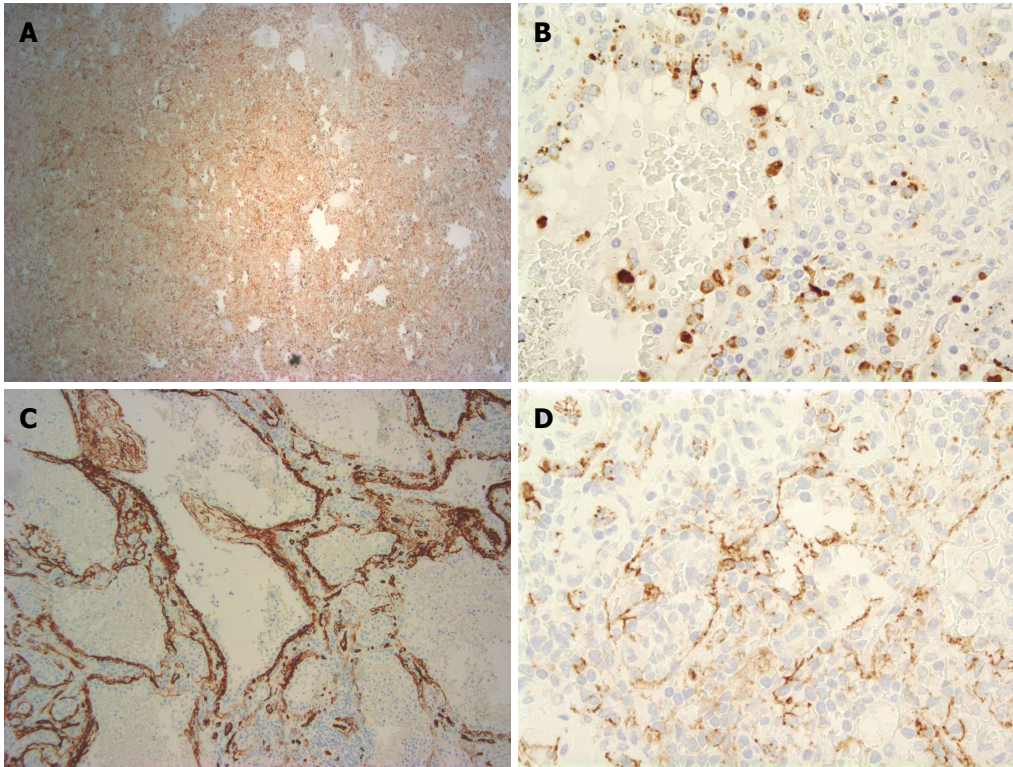


Figure 4 Endothelial cells lining the cyst-like spaces are immunoreactive. A: CD68 (CD68 stain, $\times 100$); B: Histiocytic marker lysozyme (lysozyme stain, $\times 400$); C: Endothelial marker CD34 and the histiocytoid cells are negative for CD34 (CD34 stain, $\times 400$); D: Endothelial marker CD31 (CD31 stain, $\times 400$).

enhanced CT, LCA is isodense to slightly hypodense as related to the surrounding splenic parenchyma in both the arterial and early portal venous phase^[39,40]. Magnetic resonance imaging characteristically shows a T1 and T2 hypointense mass. LCA is often multifocal and lesions can be variable in size^[14]. The differential diagnosis of lesions that can mimic LCA on imaging includes lymphangioma, hamartoma, lymphoma, Kaposi's sarcoma, and hemangioma. Therefore, a definitive diagnosis can only be obtained pathologically^[41].

Pathologically, LCA is a vascular tumor of the spleen that represents a tumoral counterpart of the normally present littoral cells that line the splenic sinus channels of the red pulp^[30]. First described by Falk *et al*^[33] in 1991 in a pathologic series of 17 cases, this new entity was described histologically as consisting of anastomosing vascular channels with cyst like spaces and papillary projections. The endothelial cells lining the channels are tall and plump compared to the flat endothelial cells lining the channels in a normal spleen. Immunohistochemically, LCA is characteristically CD 34 negative, CD 68 positive, CD 21 positive and CD 8 negative^[22]. Additionally, the epithelial cells in LCA do occasionally express S-100 protein^[16]. High expression of formin homology domain protein 1 (FHOD1) distinguished littoral cells from LCA. FHOD1 protein is expressed by normal littoral cells, not by LCA^[42]. Further research has been done evaluating molecular markers and LCA to help aid in the accurate diagnosis of LCA tumors. O'Malley *et al*^[43], looked at splenic lesions and the activity

of the Ets Related Gene (*ERG*) and the Wilms Tumor-1 gene (*WT-1*). They found that LCA splenic lesions had a pattern of ERG positive and WT-1 negative^[43]. Of the other types of splenic lesions evaluated cavernous hemangiomas were found to have the same pattern, therefore these markers are not specific enough alone to make the diagnosis of LCA.

LCA has most commonly been described as a benign process. However, observations of malignant behavior have been described^[41]. In one case, metastatic lesions were found in the liver and retroperitoneum four years after splenectomy for LCA^[44]. This case initially had symptoms of ureteral obstruction and renal failure. In comparison, our patient did not have ureteral obstruction however did have recurrent UTI's and a history of congenital ureteropelvic junction obstruction. Kranzfelder *et al*^[45], showed a case of familial individuals with LCA and primary splenic angiosarcoma, raising the question of possible malignant transformation. There were no similar signs and symptoms between their case and the presented case. Harmon *et al*^[17], published a case report of a patient with transitional cell carcinoma of the bladder with suspected splenic metastasis. The pathology revealed LCA and not splenic metastasis. Ben-Izhak *et al*^[14], showed a case of malignant littoral cell tumor naming it littoral cell hemangioendothelioma. This case report featured a symptomatic patient with liver metastasis eight years after splenectomy. In reviewing all of these cases, the immunohistochemical pattern was similar giving the diagnosis of LCA.

LCA has been shown to be rarely associated with visceral malignancies including colorectal adenocarcinoma, pancreatic cystadenocarcinoma, pancreatic neuroendocrine tumor, renal cell cancer, hepatocellular carcinoma, non-small cell lung cancer, seminoma, ovarian cystadenocarcinoma, papillary thyroid cancer and transitional cell carcinoma of the bladder^[17]. Furthermore, there have been a few reports describing an association of LCA with immunological disorders, such as, ankylosing spondylitis, myelodysplastic syndrome, non-Hodgkin lymphoma, Crohn's disease, Wiskott Aldrich syndrome, chronic glomerulonephritis, aplastic anemia and Gaucher's disease^[17,22,46]. Given the association of LCA with other malignancies as well as the few reported cases of malignant behavior, patients should undergo close follow up after splenectomy; however, no established postoperative surveillance guidelines exist.

Littoral cell angioma is a rare vascular tumor of the splenic red pulp, and is typically an incidental finding on abdominal imaging. The splenic lesion can only truly be differentiated from other splenic masses by histologic examination. Splenectomy is the appropriate treatment, as LCA has a variable behavior pattern of which malignant tendencies are worrisome. Furthermore, longitudinal surveillance in the postoperative phase is recommended.

COMMENTS

Case characteristics

Littoral cell angioma (LCA) can range from no symptoms to a vague set of symptoms such as: abdominal pain, splenomegaly, thrombocytopenia, anemia, fever, chills, weakness and fatigue.

Clinical diagnosis

The main clinical finding is a splenic lesion.

Differential diagnosis

The differential diagnosis of a splenic lesion is lymphoid, vascular, non lymphoid and tumor like which can be distinguished by pathology.

Imaging diagnosis

Ultrasound, computed tomography and magnetic resonance imaging are all acceptable modalities for imaging and diagnosing a splenic tumor; all of which are non-specific for LCA.

Pathological diagnosis

The splenic specimen is analyzed for abnormal littoral cells along with immunohistochemical stains to provide definitive diagnosis of LCA.

Treatment

Treatment is surgical resection with close surveillance as a malignant variant is possible.

Related reports

Over a hundred cases of LCA have been reported since 1991, research continues into the realm of pathological markers and surveillance is new territory with cases of malignant variants being reported.

Term explanation

Hemangioendothelioma is a term to describe a vascular neoplasm that may be

considered benign as well as malignant.

Experiences and lessons

This case teaches that there is malignant potential for LCA lesions of the spleen.

Peer-review

This is the well-written case report of LCA.

REFERENCES

- 1 **Abbott RM**, Levy AD, Aguilera NS, Gorospe L, Thompson WM. From the archives of the AFIP: primary vascular neoplasms of the spleen: radiologic-pathologic correlation. *Radiographics* 2004; **24**: 1137-1163 [PMID: 15256634 DOI: 10.1148/rg.244045006]
- 2 **Fotiadis C**, Georgopoulos I, Stoidis C, Patapis P. Primary tumors of the spleen. *Int J Biomed Sci* 2009; **5**: 85-91 [PMID: 23675122]
- 3 **Kaza RK**, Azar S, Al-Hawary MM, Francis IR. Primary and secondary neoplasms of the spleen. *Cancer Imaging* 2010; **10**: 173-182 [PMID: 20713317 DOI: 10.1102/1470-7330.2010.0026]
- 4 **Rajabi P**, Noorollahi H, Hani M, Bagheri M. Inflammatory pseudotumor of spleen. *Adv Biomed Res* 2014; **3**: 29 [PMID: 24592376 DOI: 10.4103/2277-9175.124679]
- 5 **Perry-Thornton E**, Verly GP, Karkala J, Walker M. An unusual presentation of multiple myeloma: primary plasmacytoma of the spleen. *J Natl Med Assoc* 1989; **81**: 1095-1096, 1099 [PMID: 2681801]
- 6 **Popp JA**, Jones TC. Fibrosarcoma, Spleen. In: Hemopoietic System. Berlin: Springer, 1990: 216-219 [DOI: 10.1007/978-3-642-84110-1_34]
- 7 **Lee JKT**, Sagel S, Stanley RJ, Heiken JP. Computed Body Tomography with MRI Correlation. 4th ed. Lippincott William and Wilkins, 2006: 984-991
- 8 **Palas J**, Matos AP, Ramalho M. The spleen revisited: an overview on magnetic resonance imaging. *Radiol Res Pract* 2013; **2013**: 219297 [PMID: 24377046]
- 9 **Mikami T**, Saegusa M, Akino F, Machida D, Iwabuchi K, Hagiwara S, Okayasu I. A Kaposi-like variant of splenic angiosarcoma lacking association with human herpesvirus 8. *Arch Pathol Lab Med* 2002; **126**: 191-194 [PMID: 11825116]
- 10 **Valls C**, Cañas C, Turell LG, Pruna X. Hepatosplenic AIDS-related Kaposi's sarcoma. *Gastrointest Radiol* 1991; **16**: 342-344 [PMID: 1936779 DOI: 10.1007/BF01887385]
- 11 **Colović MD**, Janković GM, Colović RB, Martinović-Cemerikić VM. Non-secretory solitary plasmacytoma of the spleen. *Med Oncol* 1998; **15**: 286-288 [PMID: 9951695 DOI: 10.1007/BF02787215]
- 12 **Harris NL**, Aisenberg AC, Meyer JE, Ellman L, Elman A. Diffuse large cell (histiocytic) lymphoma of the spleen. Clinical and pathologic characteristics of ten cases. *Cancer* 1984; **54**: 2460-2467 [PMID: 6388805 DOI: 10.1002/1097-0142(19841201)54:11<2460::AID-CNCR2820541125>3.0.CO;2-K]
- 13 **Bhatt S**, Huang J, Dogra V. Littoral cell angioma of the spleen. *AJR Am J Roentgenol* 2007; **188**: 1365-1366 [PMID: 17449783 DOI: 10.2214/AJR.06.1157]
- 14 **Ben-Izhak O**, Bejar J, Ben-Eliezer S, Vlodavsky E. Splenic littoral cell haemangioendothelioma: a new low-grade variant of malignant littoral cell tumour. *Histopathology* 2001; **39**: 469-475 [PMID: 11737304 DOI: 10.1046/j.1365-2559.2001.01242.x]
- 15 **Meybehm M**, Fischer HP. [Littoral cell angiosarcoma of the spleen. Morphologic, immunohistochemical findings and consideration of histogenesis of a rare splenic tumor]. *Pathologe* 1997; **18**: 401-405 [PMID: 9432677 DOI: 10.1007/s002920050233]
- 16 **Bhatt S**, Simon R, Dogra VS. Littoral cell angioma: sonographic and color Doppler features. *J Ultrasound Med* 2007; **26**: 539-542 [PMID: 17384054]
- 17 **Harmon RL**, Cerruto CA, Scheckner A. Littoral cell angioma: a case report and review. *Curr Surg* 2006; **63**: 345-350 [PMID: 16971207 DOI: 10.1016/j.cursur.2006.06.011]
- 18 **Ramdall RB**, Alasio TM, Cai G, Yang GC. Primary vascular

- neoplasms unique to the spleen: littoral cell angioma and splenic hamartoma diagnosis by fine-needle aspiration biopsy. *Diagn Cytopathol* 2007; **35**: 137-142 [PMID: 17304535 DOI: 10.1002/dc.20568]
- 19 **Rana N**, Ming Z, Hui MS, Bin Y. Case Report: Littoral cell angioma of spleen. *Indian J Radiol Imaging* 2009; **19**: 210-212 [PMID: 19881088 DOI: 10.4103/0971-3026.54886]
 - 20 **Tee M**, Vos P, Zetler P, Wiseman SM. Incidental littoral cell angioma of the spleen. *World J Surg Oncol* 2008; **6**: 87 [PMID: 18713469 DOI: 10.1186/1477-7819-6-87]
 - 21 **Chourmouzi D**, Psoma E, Drevelegas A. Littoral cell angioma, a rare cause of long standing anaemia: a case report. *Cases J* 2009; **2**: 9115 [PMID: 20062692 DOI: 10.1186/1757-1626-2-9115]
 - 22 **Johnson C**, Goyal M, Kim B, Wasdahl D, Nazinitsky K. Littoral cell angioma. *Clin Imaging* 2007; **31**: 27-31 [PMID: 17189843 DOI: 10.1016/j.clinimag.2006.09.021]
 - 23 **Cosme A**, Tejada A, Bujanda L, Vaquero M, Elorza JL, Ojeda E, Goikoetxea U. Littoral-cell angioma of the spleen: a case report. *World J Gastroenterol* 2007; **13**: 6603-6604 [PMID: 18161935 DOI: 10.3748/wjg.13.6603]
 - 24 **Qu ZB**, Liu LX, Wu LF, Zhao S, Jiang HC. Multiple littoral cell angioma of the spleen: a case report and review of the literature. *Onkologie* 2007; **30**: 256-258 [PMID: 17460421]
 - 25 **Tatli S**, Cizginer S, Wiczorek TJ, Ashley SW, Silverman SG. Solitary littoral cell angioma of the spleen: computed tomography and magnetic resonance imaging features. *J Comput Assist Tomogr* 2008; **32**: 772-775 [PMID: 18830109 DOI: 10.1097/RCT.0b013e31815614a2]
 - 26 **Ertan G**, Tekes A, Mitchell S, Keefer J, Huisman TA. Pediatric littoral cell angioma of the spleen: multimodality imaging including diffusion-weighted imaging. *Pediatr Radiol* 2009; **39**: 1105-1109 [PMID: 19597808 DOI: 10.1007/s00247-009-1339-x]
 - 27 **Suvajdžić N**, Cemerikić-Martinović V, Saranović D, Petrović M, Popović M, Artiko V, Cupić M, Elezović I. Littoral-cell angioma as a rare cause of splenomegaly. *Clin Lab Haematol* 2006; **28**: 317-320 [PMID: 16999722 DOI: 10.1111/j.1365-2257.2006.00801.x]
 - 28 **Priego P**, Rodríguez Velasco G, Griffith PS, Fresneda V. Littoral cell angioma of the spleen. *Clin Transl Oncol* 2008; **10**: 61-63 [PMID: 18208795 DOI: 10.1007/s12094-008-0155-3]
 - 29 **Mac New HG**, Fowler CL. Partial splenectomy for littoral cell angioma. *J Pediatr Surg* 2008; **43**: 2288-2290 [PMID: 19040956 DOI: 10.1016/j.jpedsurg.2008.07.031]
 - 30 **Wang YJ**, Li F, Cao F, Sun JB, Liu JF, Wang YH. Littoral cell angioma of the spleen. *Asian J Surg* 2009; **32**: 167-171 [PMID: 19656757 DOI: 10.1016/S1015-9584(09)60389-4]
 - 31 **Bi CF**, Jiang LL, Li Z, Liu WP. [Littoral cell angioma of spleen: a clinicopathologic study of 17 cases]. *Zhonghua Binglixue Zazhi* 2007; **36**: 239-243 [PMID: 17706114]
 - 32 **Nagarajan P**, Cai G, Padda MS, Selbst M, Kowalski D, Proctor DD, Chhieng D, Aslanian HR, Harigopal M. Littoral cell angioma of the spleen diagnosed by endoscopic ultrasound-guided fine-needle aspiration biopsy. *Diagn Cytopathol* 2011; **39**: 318-322 [PMID: 21488173 DOI: 10.1002/dc.21384]
 - 33 **Falk S**, Stutte HJ, Frizzera G. Littoral cell angioma. A novel splenic vascular lesion demonstrating histiocytic differentiation. *Am J Surg Pathol* 1991; **15**: 1023-1033 [PMID: 1928554 DOI: 10.1097/00000478-199111000-00001]
 - 34 **Levy AD**, Abbott RM, Abbondanzo SL. Littoral cell angioma of the spleen: CT features with clinicopathologic comparison. *Radiology* 2004; **230**: 485-490 [PMID: 14752189 DOI: 10.1148/radiol.2302030196]
 - 35 **Ziske C**, Meybehm M, Sauerbruch T, Schmidt-Wolf IG. Littoral cell angioma as a rare cause of splenomegaly. *Ann Hematol* 2001; **80**: 45-48 [PMID: 11233776 DOI: 10.1007/s002770000223]
 - 36 **Goldfeld M**, Cohen I, Loberant N, Mugrabi A, Katz I, Papura S, Noi I. Littoral cell angioma of the spleen: appearance on sonography and CT. *J Clin Ultrasound* 2002; **30**: 510-513 [PMID: 12242742 DOI: 10.1002/jcu.10101]
 - 37 **Pilz JB**, Sperschneider T, Lutz T, Loosli B, Maurer CA. Littoral cell angioma in main and accessory intrapancreatic spleen presenting as splenic rupture. *Am J Surg* 2011; **201**: e15-e17 [PMID: 20409532 DOI: 10.1016/j.amjsurg.2009.11.013]
 - 38 **Yamane H**, Ohashi K, Suwaki T, Takigawa N. Ruptured littoral cell angiosarcoma causing hemoperitoneum. *Intern Med* 2012; **51**: 337-338 [PMID: 22293817 DOI: 10.2169/internalmedicine.51.6663]
 - 39 **Bisceglia M**, Sickel JZ, Giangaspero F, Gomes V, Amini M, Michal M. Littoral cell angioma of the spleen: an additional report of four cases with emphasis on the association with visceral organ cancers. *Tumori* 1998; **84**: 595-599 [PMID: 9862523]
 - 40 **Hanna T**, Baumgarten D, Friedman T. Littoral Cell Angioma: a case and review of the literature. *Radiology Case reports* 2011; **6**: 324-326
 - 41 **Arber DA**, Strickler JG, Chen YY, Weiss LM. Splenic vascular tumors: a histologic, immunophenotypic, and virologic study. *Am J Surg Pathol* 1997; **21**: 827-835 [PMID: 9236839 DOI: 10.1097/0000478-199707000-00011]
 - 42 **Ogembo JG**, Milner DA, Mansfield KG, Rodig SJ, Murphy GF, Kutok JL, Pinkus GS, Fingerhuth JD. SIRPa/CD172a and FHOD1 are unique markers of littoral cells, a recently evolved major cell population of red pulp of human spleen. *J Immunol* 2012; **188**: 4496-4505 [PMID: 22490440 DOI: 10.4049/jimmunol.1103086]
 - 43 **O'Malley DP**, Kim YS, Weiss LM. Distinctive immunohistochemical staining in littoral cell angioma using ERG and WT-1. *Ann Diagn Pathol* 2015; **19**: 143-145 [PMID: 25792460 DOI: 10.1016/j.anndiagpath.2015.02.007]
 - 44 **Fernandez S**, Cook GW, Arber DA. Metastasizing splenic littoral cell hemangioendothelioma. *Am J Surg Pathol* 2006; **30**: 1036-1040 [PMID: 16861977 DOI: 10.1097/00000478-200608000-00016]
 - 45 **Kranzfelder M**, Bauer M, Richter T, Rudelius M, Huth M, Wagner P, Friess H, Stadler J. Littoral cell angioma and angiosarcoma of the spleen: report of two cases in siblings and review of the literature. *J Gastrointest Surg* 2012; **16**: 863-867 [PMID: 22068970 DOI: 10.1007/s11605-011-1773-6]
 - 46 **Rosso R**, Paulli M, Gianelli U, Boveri E, Stella G, Magrini U. Littoral cell angiosarcoma of the spleen. Case report with immunohistochemical and ultrastructural analysis. *Am J Surg Pathol* 1995; **19**: 1203-1208 [PMID: 7573679 DOI: 10.1097/00000478-199510000-00011]

P- Reviewer: Kai K, Mueller WC, Sergi C

S- Editor: Tian YL **L- Editor:** A **E- Editor:** Jiao XK



Acute hepatitis after amiodarone infusion

Paulo Fonseca, Adelaide Dias, Helena Gonçalves, Aníbal Albuquerque, Vasco Gama

Paulo Fonseca, Adelaide Dias, Helena Gonçalves, Aníbal Albuquerque, Vasco Gama, Cardiology Department, Gaia Hospital Center, 4434-502 Vila Nova de Gaia, Portugal

Author contributions: Fonseca P, Dias A and Gonçalves H wrote the case report; Albuquerque A and Gama V revised the manuscript.

Institutional review board statement: IRB approval was not required for this case report.

Informed consent statement: The patient gave his informed consent to the publication of this clinical case.

Conflict-of-interest statement: The authors declare that there is no conflict of interests regarding the publication of this article.

Open-Access: This article is an open-access article which was selected by an in-house editor and fully peer-reviewed by external reviewers. It is distributed in accordance with the Creative Commons Attribution Non Commercial (CC BY-NC 4.0) license, which permits others to distribute, remix, adapt, build upon this work non-commercially, and license their derivative works on different terms, provided the original work is properly cited and the use is non-commercial. See: <http://creativecommons.org/licenses/by-nc/4.0/>

Correspondence to: Paulo Fonseca, MD, Cardiology Department, Gaia Hospital Center, Rua Conceição Fernandes, 4434-502 Vila Nova de Gaia, Portugal. paulobarbosafonseca@hotmail.com
Telephone: +351-22-7865100
Fax: +351-22-7830209

Received: January 20, 2015

Peer-review started: January 21, 2015

First decision: March 6, 2015

Revised: April 18, 2015

Accepted: August 10, 2015

Article in press: August 11, 2015

Published online: October 16, 2015

a case of an 88-year-old man with history of ischemic dilated cardiomyopathy and severely depressed left ventricular function that was admitted to our coronary care unit with diagnosis of decompensated heart failure and non-sustained ventricular tachycardia. A few hours after the beginning of intravenous amiodarone he developed an acute hepatitis. There was a completely recovery within the next days after amiodarone withdrawn and other causes of acute hepatitis have been ruled out. This case highlights the need for close monitoring of hepatic function during amiodarone infusion in order to identify any potential hepatotoxicity and prevent a fatal outcome. Oral amiodarone is, apparently, a safe option in these patients.

Key words: Polysorbate 80; Hepatitis; Hepatotoxicity; Idiosyncratic reactions; Amiodarone

© **The Author(s) 2015.** Published by Baishideng Publishing Group Inc. All rights reserved.

Core tip: We report a rare case of acute hepatitis induced by intravenous amiodarone in a patient with non-sustained ventricular tachycardia. The physiopathology of this adverse effect is still unclear. Close monitoring of hepatic function during amiodarone infusion is essential to avoid any potential hepatotoxicity.

Fonseca P, Dias A, Gonçalves H, Albuquerque A, Gama V. Acute hepatitis after amiodarone infusion. *World J Clin Cases* 2015; 3(10): 900-903 Available from: URL: <http://www.wjgnet.com/2307-8960/full/v3/i10/900.htm> DOI: <http://dx.doi.org/10.12998/wjcc.v3.i10.900>

INTRODUCTION

Long-term oral amiodarone therapy is associated with many extracardiac adverse effects, such as thyroid dysfunction, photosensitivity, corneal microdeposits and pulmonary and hepatic toxicities. The frequency

Abstract

Acute hepatitis is a very rare, but potentially fatal, adverse effect of intravenous amiodarone. We present

of most adverse effects is related to the total drug exposure. Hepatic toxicity in these patients ranges from an asymptomatic elevation of serum aminotransferases (in approximately 25%) that is usually transient and resolves after dose reduction or withdrawal, to severe liver disease (1%-3%)^[1]. Acute hepatic toxicity during intravenous amiodarone has been rarely described^[2-6].

CASE REPORT

An 88-year-old man with history of ischemic dilated cardiomyopathy and severely depressed left ventricular function presented at Emergency Department due to progressive worsening of dyspnea, orthopnea and peripheral edema during the previous week. He was on long-term treatment with aspirin, ramipril, furosemide, transdermal nitroglycerin, simvastatin and pantoprazole. He had no history of alcohol abuse or chronic acetaminophen intake.

On physical examination, blood pressure was 110/60 mmHg and percutaneous peripheral oxygen saturation was 87% on air. He had bilateral basilar rales on pulmonary auscultation and moderate lower leg edema. Arterial gasometry confirmed type 1 respiratory failure and blood tests were unremarkable, including liver function. Electrocardiogram monitoring revealed periods of non-sustained ventricular tachycardia (NSVT).

He was admitted to our coronary care unit with the diagnosis of acute decompensated heart failure and NSVT. He was started on intravenous amiodarone with a bolus dose of 300 mg followed by a continuous infusion of 900 mg over 24 h. Control blood tests performed 18 h after starting amiodarone showed an abrupt elevation of aminotransferases (aspartate aminotransferase 3398 U/L, alanine aminotransferase 1964 U/L), lactate dehydrogenase (2127 U/L), direct bilirubin (2.47 mg/dL) and international normalized ratio (2.79). Gamma-GT and alkaline phosphatase were normal. Despite hemodynamic and ventricular electric stability, he evolved with worsening of hepatic function associated with thrombocytopenia, metabolic acidosis and acute kidney injury. Abdominal ultrasonography showed a liver with normal appearance and excluded hepatic artery and vein thrombosis and any bile duct abnormalities. Viral hepatitis serologies (hepatitis B and C, cytomegalovirus, Epstein-Barr and herpes zoster viruses) and autoimmune markers (antinuclear antibody, anti-smooth muscle antibody, anti-liver/kidney microsomal antibody type 1) were negative.

Drug-induced liver injury secondary to amiodarone was the main diagnostic hypothesis and amiodarone was withdrawn about 40 h after its beginning (total dose of 1800 mg). Since then, he improved gradually with progressive normalization of renal and hepatic function (Figures 1 and 2). At day 4, he restarted amiodarone in oral form, at loading doses of 200 mg three times daily, without any additional liver injury. There was no recurrence of VT and he was discharged on day 12 with nearly normal hepatic tests.

DISCUSSION

This report describes a severe acute hepatitis induced by intravenous amiodarone. Among the few cases reported in literature of idiosyncratic reactions to intravenous amiodarone, some had a fatal outcome^[4-6].

American College of Gastroenterology guidelines recommends that the causality assessment in patients with drug-induced hepatic injury should rely primarily on consensus expert opinion following a thorough evaluation for competing etiologies^[7]. The causal relationship between intravenous amiodarone exposure and acute hepatitis has been established based on the following principles: (1) Sudden hepatic tests abnormalities within 24 h after starting amiodarone administration; (2) Presence of a pattern of hepatocellular injury with peak aminotransferases levels of more than 50 times the upper limit of normal; (3) Rapid improvement after amiodarone withdrawal; and (4) Exclusion of other causes.

It's often difficult to distinguish between this entity and acute hepatic ischemia since many of these patients on intravenous amiodarone present hemodynamic instability. In this case, the patient was under invasive monitoring and maintained mean arterial pressure superior to 75 mmHg, which makes the diagnosis of ischemic hepatitis unlikely. He also didn't have a severe congestive heart failure that could possibly explain a congestive hepatopathy. Thrombocytopenia and acute kidney injury were assumed to be secondary to acute hepatic injury. Because of his favorable evolution, we did not perform a hepatic biopsy.

According to the Council for International Organizations of Medical Sciences/Roussel Uclaf Causality Assessment Method scale^[8] this case fulfilled the criteria of a highly probable amiodarone adverse effect.

The physiopathology of this adverse effect is still unclear. Different potential mechanisms have been proposed, including an immunologically mediated mechanism^[9,10], a free radical mechanism, in which formation of free radicals leads to peroxidative injury of membrane lipids and necrosis^[11,12] and a mechanism based in increased expression of the *PPAR-α* gene secondary to disrupted hepatic lipid homeostasis^[13]. The mechanism of oral amiodarone induced hepatotoxicity seems to be different from that induced by intravenous amiodarone. Some reports, including our own, showed that introduction of oral amiodarone in these patients did not result in any additional liver injury. Based on this observation, Rhodes *et al.*^[14] proposed that polysorbate 80, the solvent of intravenous formulation of amiodarone, could be involved in this adverse effect since it is present in the intravenous but not in the oral form of amiodarone. Polysorbate 80 has been implicated in the E-ferol syndrome, which has been described in infants after intravenous administration of E vitamin with this component^[15]. The E-ferol syndrome shows significant similarities to the cases of liver toxicity due to amiodarone^[14]. In addition, polysorbate 80 has a short

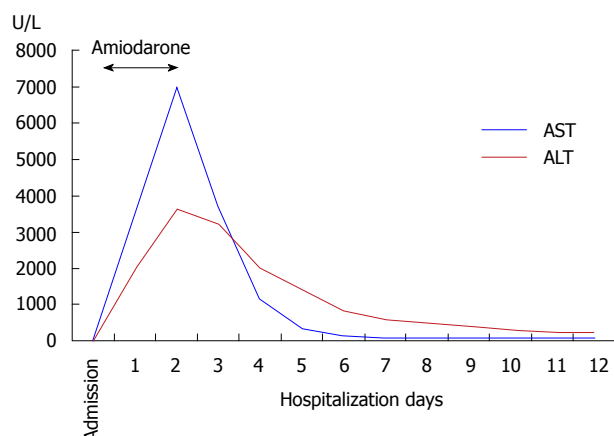


Figure 1 Evolution of aminotransferases levels during hospitalization. AST: Aspartate aminotransferase; ALT: Alanine aminotransferase.

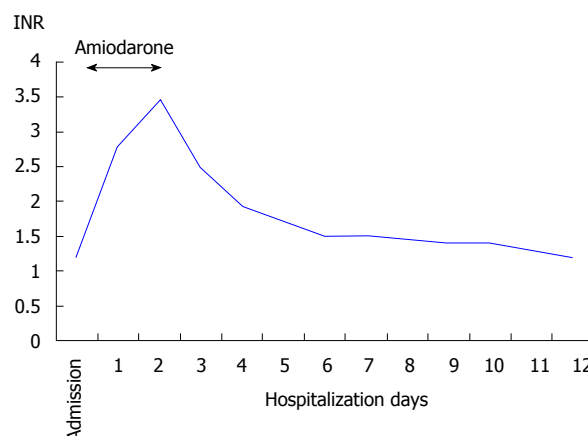


Figure 2 Evolution of international normalized ratio levels during hospitalization. INR: International normalized ratio.

plasma half life, which could justify the rapid recover of hepatic failure after discontinuation of intravenous amiodarone. In 2008 Food and Drug Administration approved a polysorbate-free formulation of amiodarone (Nexterone, Baxter Healthcare Corporation, Deerfield, IL), however it's still not available in several hospitals.

In conclusion, acute hepatotoxicity is a rare, but potentially fatal, adverse effect of intravenous amiodarone. This case highlights the need for close monitoring of hepatic function during amiodarone infusion in order to identify any potential hepatotoxicity and prevent a fatal outcome. If available, it should be considered the use of polysorbate-free formulation of intravenous amiodarone. Oral amiodarone is, apparently, a safe option in these patients.

COMMENTS

Case characteristics

An 88-year-old man admitted with acute decompensated heart failure and non-sustained ventricular tachycardia underwent intravenous amiodarone.

Clinical diagnosis

The patient developed severe acute hepatitis induced by intravenous amiodarone.

Differential diagnosis

Acute viral hepatitis, autoimmune hepatitis, ischemic liver injury, congestive hepatopathy.

Laboratory diagnosis

Aspartate aminotransferase 3398 U/L, alanine aminotransferase 1964 U/L, lactate dehydrogenase 2127 U/L, direct bilirubin 2.47 mg/dL and international normalized ratio 2.79; viral hepatitis serologies and autoimmune markers were negative.

Imaging diagnosis

Abdominal ultrasonography showed a liver with normal appearance and excluded hepatic artery and vein thrombosis and any bile duct abnormalities.

Pathological diagnosis

Hepatic biopsy was not performed due to favorable evolution after amiodarone withdrawal.

Treatment

The treatment was mainly supportive after amiodarone withdrawal.

Related reports

Few cases of acute hepatic injury after intravenous amiodarone have been reported in literature. Some of them had a fatal outcome.

Term explanation

Idiosyncratic reactions are unpredictable adverse drug reactions that do not occur in most patients, but can be life-threatening.

Experiences and lessons

This case highlights the need for close monitoring of hepatic function during amiodarone infusion in order to identify any potential hepatotoxicity and prevent a fatal outcome. Oral amiodarone is, apparently, a safe option in these patients.

Peer-review

This is a well written case report on a serious complication following *iv* amiodarone administration.

REFERENCES

- 1 **Lewis JH**, Ranard RC, Caruso A, Jackson LK, Mullick F, Ishak KG, Seeff LB, Zimmerman HJ. Amiodarone hepatotoxicity: prevalence and clinicopathologic correlations among 104 patients. *Hepatology* 1989; **9**: 679-685 [PMID: 2785079 DOI: 10.1002/hep.1840090504]
- 2 **Rizzioli E**, Incasa E, Gamberini S, Savelli S, Zangirolami A, Tampieri M, Manfredini R. Acute toxic hepatitis after amiodarone intravenous loading. *Am J Emerg Med* 2007; **25**: 1082.e1-1082.e4 [PMID: 18022508 DOI: 10.1016/j.ajem.2007.02.045]
- 3 **Chen CC**, Wu CC. Acute Hepatotoxicity of Intravenous Amiodarone: Case Report and Review of the Literature. *Am J Ther* 2014 Sep 24; Epub ahead of print [PMID: 25259952 DOI: 10.1097/mjtt.0000000000000149]
- 4 **Kalantzis N**, Gabriel P, Mouzas J, Tiniakos D, Tsigas D, Tiniakos G. Acute amiodarone-induced hepatitis. *Hepatogastroenterology* 1991; **38**: 71-74 [PMID: 2026392]
- 5 **MacFadyen RJ**, Palmer TJ, Hisamuddin K. Rapidly fatal acute amiodarone hepatitis occurring in the context of multiple organ failure. *Int J Cardiol* 2003; **91**: 245-247 [PMID: 14559139 DOI: 10.1016/s0167-5273(02)00613-7]
- 6 **Chan AL**, Hsieh HJ, Hsieh YA, Lin SJ. Fatal amiodarone-induced hepatotoxicity: a case report and literature review. *Int J Clin Pharmacol Ther* 2008; **46**: 96-101 [PMID: 18218290 DOI: 10.5414/cpp46096]

- 7 **Chalasani NP**, Hayashi PH, Bonkovsky HL, Navarro VJ, Lee WM, Fontana RJ. ACG Clinical Guideline: the diagnosis and management of idiosyncratic drug-induced liver injury. *Am J Gastroenterol* 2014; **109**: 950-966; quiz 967 [PMID: 24935270 DOI: 10.1038/ajg.2014.131]
- 8 **Danan G**, Benichou C. Causality assessment of adverse reactions to drugs--I. A novel method based on the conclusions of international consensus meetings: application to drug-induced liver injuries. *J Clin Epidemiol* 1993; **46**: 1323-1330 [PMID: 8229110 DOI: 10.1016/0895-4356(93)90101-6]
- 9 **Breuer HW**, Bossek W, Haferland C, Schmidt M, Neumann H, Gruszka J. Amiodarone-induced severe hepatitis mediated by immunological mechanisms. *Int J Clin Pharmacol Ther* 1998; **36**: 350-352 [PMID: 9660045]
- 10 **Lupon-Rosés J**, Simó-Canonge R, Lu-Cortez L, Permanyer-Miralda G, Allende-Monclús H. Probable early acute hepatitis with parenteral amiodarone. *Clin Cardiol* 1986; **9**: 223-225 [PMID: 3708949 DOI: 10.1002/clc.4960090512]
- 11 **Sarma JS**, Pei H, Venkataraman K. Role of Oxidative Stress in Amiodarone-induced Toxicity. *J Cardiovasc Pharmacol Ther* 1997; **2**: 53-60 [PMID: 10684442 DOI: 10.1177/107424849700200107]
- 12 **Kaufmann P**, Török M, Hänni A, Roberts P, Gasser R, Krähenbühl S. Mechanisms of benzarone and benzbromarone-induced hepatic toxicity. *Hepatology* 2005; **41**: 925-935 [PMID: 15799034 DOI: 10.1002/hep.20634]
- 13 **McCarthy TC**, Pollak PT, Hanniman EA, Sinal CJ. Disruption of hepatic lipid homeostasis in mice after amiodarone treatment is associated with peroxisome proliferator-activated receptor-alpha target gene activation. *J Pharmacol Exp Ther* 2004; **311**: 864-873 [PMID: 15265979 DOI: 10.1124/jpet.104.072785]
- 14 **Rhodes A**, Eastwood JB, Smith SA. Early acute hepatitis with parenteral amiodarone: a toxic effect of the vehicle? *Gut* 1993; **34**: 565-566 [PMID: 8491409 DOI: 10.1136/gut.34.4.565]
- 15 **Balistreri WF**, Farrell MK, Bove KE. Lessons from the E-Ferol tragedy. *Pediatrics* 1986; **78**: 503-506 [PMID: 3748688]

P- Reviewer: De Ponti F, Ghinolfi D, Lankarani KB
S- Editor: Gong XM **L- Editor:** A **E- Editor:** Jiao XK



Novel variant syndrome associated with congenital hepatic fibrosis

Yusuf Bayraktar, Ozlem Yonem, Kubilay Varlı, Hande Taylan, Ali Shorbagi, Cenk Sokmensuer

Yusuf Bayraktar, Ali Shorbagi, Department of Gastroenterology, Faculty of Medicine, Hacettepe University, Ankara 312, Turkey

Ozlem Yonem, Department of Gastroenterology, Cumhuriyet University, Sivas 346, Turkey

Kubilay Varlı, Department of Neurology, Hacettepe University, Ankara 312, Turkey

Hande Taylan, Department of Ophthalmology, Hacettepe University, Ankara 312, Turkey

Cenk Sokmensuer, Department of Pathology, Hacettepe University, Ankara 312, Turkey

Author contributions: All authors contributed to this manuscript.

Institutional review board statement: The study was reviewed and approved by the Hacettepe University Institutional Review Board.

Informed consent statement: All study participants, or their legal guardian, provided informed written consent prior to study enrollment.

Conflict-of-interest statement: The authors declare no conflict of interest.

Open-Access: This article is an open-access article which was selected by an in-house editor and fully peer-reviewed by external reviewers. It is distributed in accordance with the Creative Commons Attribution Non-commercial (CC BY-NC 4.0) license, which permits others to distribute, remix, adapt, build upon this work non-commercially, and license their derivative works on different terms, provided the original work is properly cited and the use is non-commercial. See: <http://creativecommons.org/licenses/by-nc/4.0/>

Correspondence to: Yusuf Bayraktar, MD, Department of Gastroenterology, Faculty of Medicine, Hacettepe University, sıhhiye yerleşesi 06100, Ankara, Turkey. bayrak@hacettepe.edu.tr
Telephone: +90-532-4323966
Fax: +90-312-4429429

Received: February 28, 2015
Peer-review started: March 1, 2015
First decision: April 23, 2015
Revised: May 3, 2015
Accepted: July 15, 2015
Article in press: July 22, 2015
Published online: October 16, 2015

Abstract

Congenital hepatic fibrosis is part of many different malformation syndromes, of which oculo-encephalo-hepato-renal syndrome is the most common. These syndromes largely overlap, and so accurate classification of individual patients may be difficult. We present herein three syndromic siblings who were products of a consanguineous marriage. We investigated in detail at least six organ systems in these patients, namely the liver, brain, eye, kidneys, skeleton, and gonads. The common features observed in these three cases were congenital hepatic fibrosis, retinitis pigmentosa, truncal obesity, rotatory nystagmus, mental retardation, advanced myopia, and high-arched palate. The clinical dysmorphism in these patients was distinct and lacked the major features of the known syndromes associated with congenital hepatic fibrosis. Although some features of these presented cases are similar to those found in Bardet-Biedl syndrome (BBS), the absence of some major criteria of BBS (polydactyly, renal abnormality, and hypogonadism) suggests that this may be a new syndrome. All three patients remain under follow-up in the departments of Gastroenterology, Ophthalmology, and Neurology at Hacettepe University.

Key words: Congenital hepatic fibrosis; Nystagmus; Mental retardation; Retinitis pigmentosa; High-arched palate

© The Author(s) 2015. Published by Baishideng Publishing Group Inc. All rights reserved.

Core tip: Congenital hepatic fibrosis is an inherited disorder that may also accompany other congenital syndromes. Here, we present three siblings with a new variant syndrome characterized by congenital hepatic fibrosis, retinitis pigmentosa, mental retardation, nystagmus, high-arched palate, truncal obesity, and advanced myopia.

Bayraktar Y, Yonem O, Varlı K, Taylan H, Shorbagi A, Sokmensuer C. Novel variant syndrome associated with congenital hepatic fibrosis. *World J Clin Cases* 2015; 3(10): 904-910 Available from: URL: <http://www.wjgnet.com/2307-8960/full/v3/i10/904.htm> DOI: <http://dx.doi.org/10.12998/wjcc.v3.i10.904>

INTRODUCTION

Congenital hepatic fibrosis (CHF) is an autosomal recessive inherited malformation defined pathologically by a variable degree of periportal fibrosis and irregularly-shaped proliferating bile ducts^[1,2]. The exact incidence and prevalence of CHF are not known, but it is a rare disease. By 1981, only 200 patients with CHF had been reported in the literature^[3]. The first manifestations of the disease in most patients are signs or symptoms related to portal hypertension, especially splenomegaly and varices, often with gastrointestinal bleeding^[4]. The clinical manifestations of CHF are non-specific, making the diagnosis of this disorder difficult. Although the onset of symptoms and signs is highly variable (ranging from early childhood to the 6th decade of life), CHF is most frequently diagnosed during adolescence or young adulthood^[4]. The late appearance of symptoms and their clinical evolution suggest that CHF is a dynamic and progressive condition.

CHF occurs in association with a range of both inherited and non-inherited disorders. Described herein are three siblings from consanguineous parents, all of whom had CHF in conjunction with retinitis pigmentosa, truncal obesity, rotatory nystagmus, mental retardation, advanced myopia, and high-arched palate. The aim of this report was to evaluate the clinical findings of these three cases and to compare these findings with relevant syndromes; Joubert, Bardet-Biedl, cerebellar vermis hypoplasia, oligophrenia, ataxia, coloboma, hepatic fibrosis (COACH), Arima, and Meckel, among others.

CASE REPORT

Patient 1

The eldest child of the family is a 34-year-old female patient who presented with nystagmus, truncal obesity [body mass index (BMI): 29, waist circumference: 97 cm], and blurred vision. The family history was unremarkable, with the exception that her parents were first cousins. She reported that her liver disease and splenomegaly were discovered when she presented

to the hospital for pneumonia at the age of seven, whereupon she underwent splenectomy and then cholecystectomy.

Laboratory studies revealed the following: hemoglobin 13.4 g/dL, white blood cell count 9200/mm³, platelet count 246000/mm³, international normalized ratio 1.09, partial thromboplastin time 28.3 s, aspartate aminotransferase (AST) 27 U/L, alanine aminotransferase (ALT) 25 U/L, gamma glutamyl transpeptidase (GGT) 32 U/L, total bilirubin 0.59 mg/dL, and albumin 3.4 g/dL. Serum electrolytes, renal function, and urinary examination were normal. The real time and Doppler ultrasonographic examination revealed portal vein cavernous transformation, a heterogeneous liver, and normal kidneys. A needle biopsy of the liver showed an increased number of irregularly-shaped bile ducts, with nodularity of the liver parenchyma accentuated by fibrous septa typical of CHF (Figure 1).

Her neurological examination demonstrated mild mental retardation, normal motor examination aside from hypoactive deep tendon reflexes (+1), and normal cerebellar tests. She had a high-arched palate, dystonia in her hands, and pes planus. Her vibration and position senses were decreased. Brain magnetic resonance imaging (MRI) revealed bilateral substance deposition in the globus pallidus, suggesting the presence of chronic liver disease.

She had exhibited signs of blurred vision in infancy/childhood, but her family was not concerned until she attended primary school. She had significant myopia and rotatory nystagmus with normal facial expression (Figures 2 and 3). Fundus examination revealed a pale optic disc, abundant bone spicules involving even the macula, and advanced arterial sclerosis. She also had myopia and rotatory nystagmus. Her bilateral visual acuity was restricted to hand movements only. Electroretinography yielded findings of retinitis pigmentosa (Figure 4). Examination of other cranial nerves yielded normal findings. No respiratory or cardiac abnormalities were found, and she had normal secondary sex characteristics.

Patient 2

The second patient, a 31-year-old female and the sister of the first patient, also presented with blurred vision, nystagmus, and truncal obesity (BMI: 33, waist circumference: 107 cm).

Laboratory tests revealed the following: hemoglobin 13.4 g/dL, white blood cell count 6600/mm³, platelet count 223000/mm³, ALT 19 U/L, AST 23 U/L, GGT 64 U/L, alkaline phosphatase 70 U/L, total bilirubin 0.72 mg/dL, blood urea nitrogen (BUN) 8 mg/dL, creatinine 0.69 mg/dL, and albumin 4.2 g/dL. Urinary examination was normal. Findings of a liver biopsy of this patient were also consistent with CHF (Figure 5).

Her neurological examination showed mental retardation, normal motor examination aside from hypoactive deep tendon reflexes, normal cerebellar tests, and a

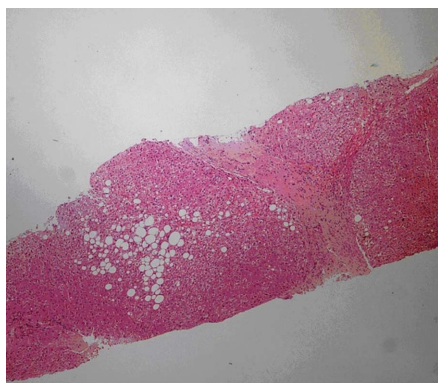


Figure 1 Liver biopsy showing an increased number of abnormal bile ducts, with nodularity of liver parenchyma accentuated by fibrous septa.

negative Romberg test. Her sensation of vibration and position was decreased. Her brain MRI yielded normal findings. She had a high-arched palate.

The patient's blurred vision was noticed while in primary school. Although decreased, her visual acuity was better than her elder sister; 2/20 with significant myopia bilaterally. Fundus examination revealed a pale optic disc, abundant bone spicules involving even the macula, and advanced arterial sclerosis. She also had rotatory nystagmus. Electroretinography yielded findings of retinitis pigmentosa. Examination of other cranial nerves yielded normal findings. No respiratory, cardiac, or renal abnormalities were found, and she had normal secondary sex characteristics with regular menses.

Patient 3

The third patient, a 30-year-old male and the brother of the first two patients, also presented with blurred vision, nystagmus, and truncal obesity (BMI: 28, waist circumference: 97 cm). Laboratory tests revealed the following: hemoglobin 15.3 g/dL, white blood cell count 5900/mm³, platelet count 92000/mm³, ALT 67 U/L, AST 46 U/L, GGT 122 U/L, alkaline phosphatase 107 U/L, total bilirubin 1 mg/dL, BUN 14 mg/dL, creatinine 0.85 mg/dL, and albumin 4.6 g/dL. Urinary examination was normal. Liver biopsy of this patient was also consistent with CHF (Figure 6).

Patient 3 also had mental retardation, although less pronounced than his sisters. He did not have any motor deficit, aside from hypoactive deep tendon reflexes (+2). His cerebellar tests were normal and Romberg test was negative. His brain MRI revealed normal findings.

The patient's blurred vision and night blindness were noticed while in primary school. He managed to finish primary school in a special facility for mentally retarded children. His visual acuity was 1/20 bilaterally, with significant myopia. Fundus examination revealed a pale optic disc, abundant bone spicules involving even the macula, and advanced arterial sclerosis. He also had rotatory nystagmus. Electroretinography yielded findings of retinitis pigmentosa. Examination of other

cranial nerves yielded normal findings. No respiratory, cardiac, or renal abnormalities were found. He had normal secondary sex characteristics, was married, and had one child.

DISCUSSION

CHF has been described frequently in combination with other abnormalities, such as renal disease, cerebellar malformations, and mental retardation^[5,6]. The term oculo-encephalo-hepato-renal syndrome is currently employed to report this association. This syndrome is not a single entity, but rather a group of disorders including COACH^[7], Meckel^[5], Joubert^[8], and Arima syndromes^[9] (Table 1). These syndromes largely overlap, and so accurate classification of individual patients may be difficult. It has been suggested that the basic defect in COACH, Joubert syndromes, and other similar conditions might be a disturbance in normal epithelial-mesenchymal interactions due to different genetic mutations^[8].

A special subgroup of CHF is COACH syndrome, which is characterized by hypoplasia of the cerebellar vermis, oligophrenia, congenital ataxia, coloboma, and hepatic fibrosis^[7]. The abnormalities observed in this syndrome appear to be variable. Numerous congenital anomalies were reported to accompany this syndrome, including slender long bones, postaxial polydactyly, pulmonary stenosis, and atrial septal defect. We found no anomalies involving the kidneys, lungs, or heart in any of our patients, and they did not have ataxia. Furthermore, the absence of the primary features of COACH syndrome (*i.e.*, oligophrenia and ocular coloboma, polydactyly, ataxia, and cerebellar vermis hypoplasia) in our patients excludes that diagnosis.

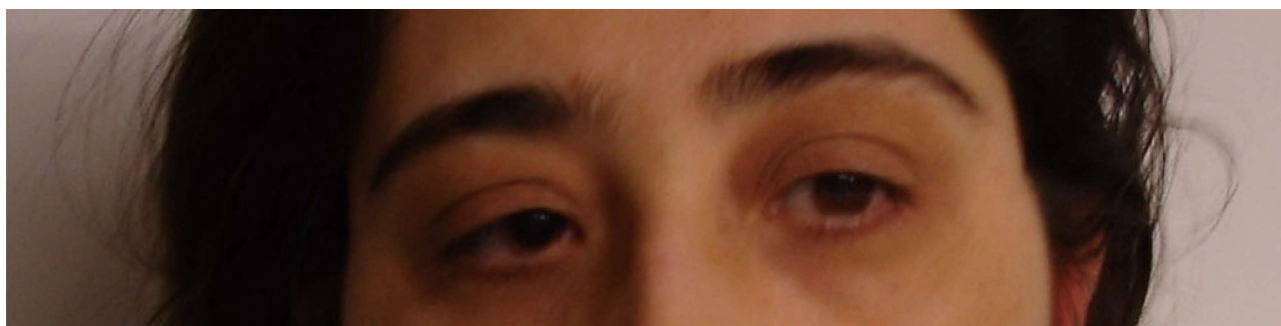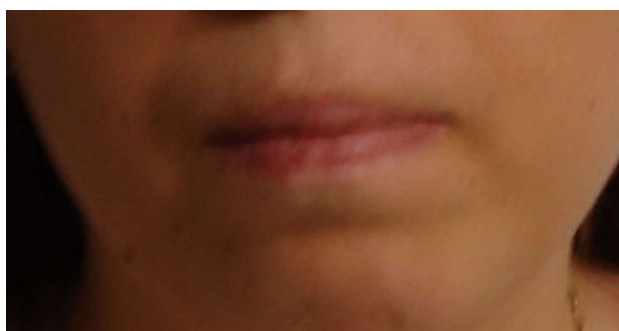
Another member of this group of disorders, Arima syndrome, is characterized by cerebellar vermis hypoplasia, psychomotor retardation, ocular abnormalities including nystagmus, and polycystic kidneys. Of those, only mental retardation and nystagmus was evident in our patients. Moreover, death in infancy is common in this syndrome, usually due to respiratory failure, and survivors usually have severe mental retardation^[10].

Joubert syndrome is an autosomal recessive condition distinguished by hypoplasia of the cerebellar vermis, hypotonia, retinal dystrophy characterized by abnormal eye movements, and impaired psychomotor development together with an abnormal respiratory pattern^[11]. This syndrome is genetically heterogeneous with mutations in two genes (*AHI-1* and *CEP290*) identified to date^[12]. Although not a constant feature, CHF has also been reported to co-exist with Joubert syndrome. Molar tooth sign (MRI appearance of hypoplasia of the cerebellar vermis and accompanying brainstem abnormalities in an axial plane through the junction of the midbrain and pons) is nearly a pathognomonic finding for this syndrome. In our previous study, we reported two sisters with Joubert syndrome and CHF

Table 1 Comparison of our cases with other related syndromes

	Joubert syndrome	Bardet-Biedl syndrome	COACH syndrome	Arima syndrome	Meckel syndrome	Our cases
Cerebellar vermis hypoplasia	¹		¹	¹		
Ataxia	¹		¹			
Abnormal breathing pattern	¹					
Abnormal eye movements	¹					
Hypotonia	¹					
Retinitis pigmentosa	³	¹				+
Polydactyly		¹	³		¹	
Truncal obesity		¹				+
Mental retardation		¹				+
Psychomotor retardation				¹		
Hypogonadism/genital abnormalities		¹				
Renal abnormalities		¹		¹	¹	
Speech disorder/delay		²				
Strabismus/cataract/astigmatism		²				
Brachydactyly/syndactyly		²				
Mild hypertonia		²				
Dental abnormalities		²				
High-arched palate		²				+
Cardiovascular abnormalities		²	³			
Encephalocele					¹	
Diabetes mellitus		²				
Oligophrenia			¹			
Ocular coloboma			¹			
Nystagmus	³			¹		+
Hepatic fibrosis	³	³	¹	¹	³	+
Advanced myopia						+

¹One of the primary features of this syndrome; ²One of the secondary features of this syndrome; ³Not a constant feature but has been reported in the literature.


Figure 2 Eyes of the first patient.

Figure 3 Mouth of the first patient. This appearance helps us to make a differential diagnosis of Cohen's syndrome, in which a distinct cheerful facial expression is noted.

disorder, and mental motor retardation. Their MRIs were suggestive of Joubert syndrome^[6]. However, none of the current three patients had molar tooth sign on MRI, essentially excluding Joubert syndrome. The overlapping features of our patients with Joubert syndrome included poor vision, nystagmus, retinitis pigmentosa, and CHF. These are not constant findings for Joubert syndrome, but have been reported in the literature as co-existent.

Cohen's syndrome is one of the rare autosomal recessive disorders that are over-represented in the Finnish population^[13]. The phenotype in Finnish patients is highly homogenous, consisting of non-progressive mild to severe psychomotor retardation, motor clumsiness, microcephaly, characteristic facial features, childhood hypotonia and joint laxity, progressive retinochoroidal dystrophy, myopia, intermittent isolated neutropenia,

who presented with abnormal eye movements, speech

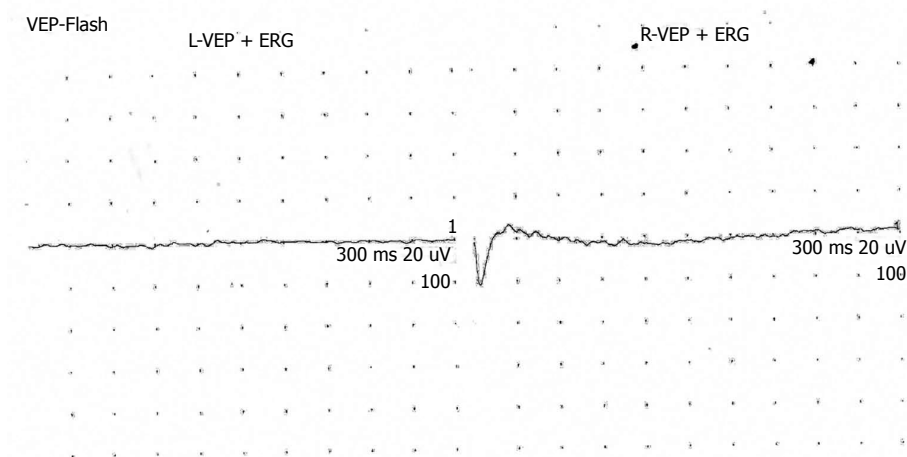


Figure 4 Electrophysiology of case 3 showing no response in eyes bilaterally. VEP: Visual evoked potential; ERG: Electroretinography.

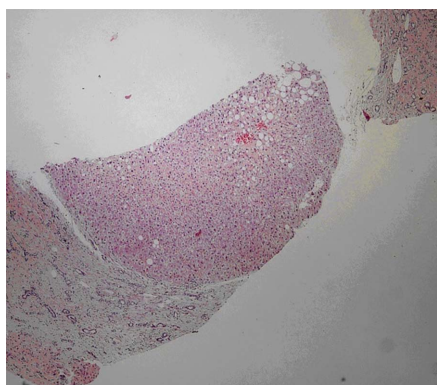


Figure 5 Liver showing nodular appearance due to fibrous bands in which elongated and angulated bile ducts are seen.

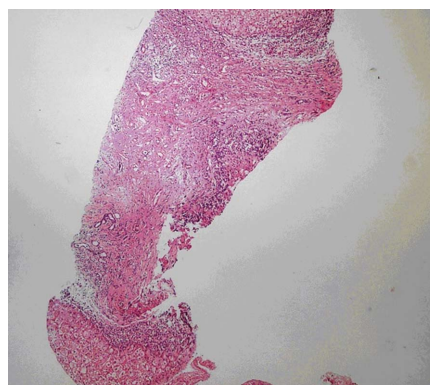

Figure 6 Liver showing nodular appearance due to fibrous bands in which bile ducts are elongated and periportal ductular proliferation is seen.

and a cheerful disposition. The characteristic facial features include high-arched or wave-shaped eyelids, a short philtrum, thick hair, and low hairline. Truncal obesity appearing during or after mid-childhood can be seen in a minority of individuals with the syndrome^[14]. Our cases share some features of Cohen's syndrome, such as retinitis pigmentosa, myopia, mental retardation, and obesity, but facial dysmorphism and the other aforementioned features which are highly typical for Cohen's syndrome were absent in our cases.

Retinitis pigmentosa is the term given to a set of hereditary retinal diseases that feature degeneration of rod and cone photoreceptors^[15]. A major form of syndromic retinitis pigmentosa, Bardet-Biedl syndrome (BBS), is variably associated with obesity, cognitive impairment, polydactyly, hypogenitalism, and renal disease^[16]. BBS has also been found to be associated with CHF. Three families with BBS mapped to the BBS2, BBS3, and BBS4 loci of 2q31 were recruited in one study for a comprehensive eye exam and, in selected cases, electroretinography testing. The results of that study suggested that BBS3 and BBS4 mutations may play a role in the development of myopia^[17]. Our patients share primary (truncal obesity and retinitis pigmentosa)

and secondary (high-arched palate and CHF) features of BBS. Truncal obesity was defined in our patients according to the International Diabetes Federation 2005 criteria^[18]. However, the primary features of BBS, such as postaxial polydactyly, hypogonadism, and renal abnormalities, were absent in the presented cases. Different mutations in unknown genes could possibly be responsible for the advanced myopia in our patients, similar to the situation in BBS. Although myopia has been rarely reported in BBS, advanced myopia was noted in our cases.

In forming the diagnostic criteria for each syndrome, it is important to consider anatomical malformations in conjunction with the clinical signs and symptoms. We investigated six organs in detail, namely the liver, brain, eye, kidneys, skeleton, and gonads. There are major anatomical malformations of the kidney, hands (polydactyly), and gonads in BBS, and of the brain in Joubert, Arima, COACH, and Meckel syndromes. As shown in Table 1, our cases, who presented with CHF, advanced myopia, rotatory nystagmus, truncal obesity, retinitis pigmentosa, mental retardation, and high-arched palate, did not have all or even at least three major components of any listed syndrome. The authors

entertain the possibility that our cases may represent a new syndrome. As shown in Table 1, the presented cases most closely resemble BBS. Beales *et al.*^[16] reviewed the diagnostic criteria of BBS after evaluating 112 cases based on their clinical findings and they added new criteria; however, liver fibrosis was not included as part of BBS. The predominance of liver fibrosis and the absence of polydactyly, renal abnormality, and hypogonadism in our cases distinguish them from BBS. These clinical findings suggest that our patients might represent a new syndrome.

Our report may contribute to a better delineation of the variable clinical expression of cases within the spectrum of oculo-encephalo-hepato-renal syndromes.

COMMENTS

Case characteristics

Three patients presented with blurred vision and truncal obesity.

Clinical diagnosis

Abnormal signs on physical examination were mental retardation, high-arched palate, pes planus, myopia, rotatory nystagmus, and retinitis pigmentosa on electroretinography.

Differential diagnosis

Cerebellar vermis hypoplasia, oligophrenia, ataxia, coloboma, hepatic fibrosis (COACH), Meckel, Joubert, Arima, Cohen, Bardet-Biedl syndromes.

Laboratory diagnosis

Laboratory test results were essentially within normal limits, with the exception of mildly-elevated alanine aminotransferase in two patients and mild thrombocytopenia in one patient.

Imaging diagnosis

Doppler examination in one patient revealed portal cavernous transformation, while magnetic resonance imaging of the brain was within normal limits in all patients.

Pathological diagnosis

Liver biopsy revealed an increased number of irregularly-shaped bile ducts, with nodularity of the liver parenchyma accentuated by fibrous septa typical of congenital hepatic fibrosis (CHF) in all patients.

Treatment

The patients did not require immediate treatment, but were treated for their ophthalmological disturbances.

Related reports

The co-existence of CHF, retinitis pigmentosa, mental retardation, nystagmus, high-arched palate, truncal obesity, and advanced myopia in the patients may indicate a new variant syndrome different from the known oculo-encephalo-hepato-renal syndromes (*i.e.*, COACH, Meckel and Joubert).

Term explanation

CHF has been described frequently in combination with other abnormalities, such as renal diseases, cerebellar malformations, and mental retardation. The term oculo-encephalo-hepato-renal syndrome is currently employed to report this association.

Experiences and lessons

CHF may present as part of a syndrome affecting the central nervous system

and eyes.

Peer-review

The authors have described three cases of CHF associated with ophthalmological and neurological findings which could represent a new syndrome.

REFERENCES

- Dobbs RH.** Congenital hepatic fibrosis with portal hypertension. *Proc R Soc Med* 1960; **53**: 327-328 [PMID: 13817041]
- Kerr DN,** Harrison CV, Sherlock S, Walker RM. Congenital hepatic fibrosis. *Q J Med* 1961; **30**: 91-117 [PMID: 13752660]
- De Vos M,** Barbier F, Cuvelier C. Congenital hepatic fibrosis. *J Hepatol* 1988; **6**: 222-228 [PMID: 3411102 DOI: 10.1016/S0168-8278(88)80036-9]
- Di Bisceglie A,** Befeler A. Cystic and nodular diseases on the liver. In: Schiff ER, Madderey W, Sorrell M, editors. *Schiff's Diseases of the Liver*. 10th ed. Philadelphia: Lippincott Williams and Wilkins, 2007: 1231-1251
- Salonen R.** The Meckel syndrome: clinicopathological findings in 67 patients. *Am J Med Genet* 1984; **18**: 671-689 [PMID: 6486167 DOI: 10.1002/ajmg.1320180414]
- Yönem O,** Ozkayar N, Balkanci F, Harmanci O, Sökmensüer C, Ersoy O, Bayraktar Y. Is congenital hepatic fibrosis a pure liver disease? *Am J Gastroenterol* 2006; **101**: 1253-1259 [PMID: 16771946 DOI: 10.1111/j.1572-0241.2006.00642.x]
- Kirchner GI,** Wagner S, Flemming P, Bleck JS, Gebel M, Schedel I, Schüller A, Galanski M, Manns MP. COACH syndrome associated with multifocal liver tumors. *Am J Gastroenterol* 2002; **97**: 2664-2669 [PMID: 12385458 DOI: 10.1111/j.1572-0241.2002.06051.x]
- Saraiva JM,** Baraitser M. Joubert syndrome: a review. *Am J Med Genet* 1992; **43**: 726-731 [PMID: 1341417 DOI: 10.1002/ajmg.1320430415]
- Matsuzaka T,** Sakuragawa N, Nakayama H, Sugai K, Kohno Y, Arima M. Cerebro-oculo-hepato-renal syndrome (Arima's syndrome): a distinct clinicopathological entity. *J Child Neurol* 1986; **1**: 338-346 [PMID: 3598133 DOI: 10.1177/088307388600100404]
- Satran D,** Pierpont ME, Dobyns WB. Cerebello-oculo-renal syndromes including Arima, Senior-Löken and COACH syndromes: more than just variants of Joubert syndrome. *Am J Med Genet* 1999; **86**: 459-469 [PMID: 10508989 DOI: 10.1002/(SICI)1096-8628(19991029)86:5<459::AID-AJMG12>3.3.CO;2-3]
- Silverstein DM,** Zacharowicz L, Edelman M, Lee SC, Greifer I, Rapin I. Joubert syndrome associated with multicystic kidney disease and hepatic fibrosis. *Pediatr Nephrol* 1997; **11**: 746-749 [PMID: 9438658 DOI: 10.1007/s004670050381]
- Baala L,** Romano S, Khaddour R, Saunier S, Smith UM, Audollent S, Ozilou C, Faivre L, Laurent N, Foliguet B, Munnich A, Lyonnet S, Salomon R, Encha-Razavi F, Gubler MC, Boddaert N, de Lonlay P, Johnson CA, Vekemans M, Antignac C, Attie-Bitach T. The Meckel-Gruber syndrome gene, MKS3, is mutated in Joubert syndrome. *Am J Hum Genet* 2007; **80**: 186-194 [PMID: 17160906 DOI: 10.1086/510499]
- Cohen MM,** Hall BD, Smith DW, Graham CB, Lampert KJ. A new syndrome with hypotonia, obesity, mental deficiency, and facial, oral, ocular, and limb anomalies. *J Pediatr* 1973; **83**: 280-284 [PMID: 4717588 DOI: 10.1016/S0022-3476(73)80493-7]
- Kolehmainen J,** Black GC, Saarinen A, Chandler K, Clayton-Smith J, Träskelin AL, Perveen R, Kivitie-Kallio S, Norio R, Warburg M, Fryns JP, de la Chapelle A, Lehesjoki AE. Cohen syndrome is caused by mutations in a novel gene, COH1, encoding a transmembrane protein with a presumed role in vesicle-mediated sorting and intracellular protein transport. *Am J Hum Genet* 2003; **72**: 1359-1369 [PMID: 12730828 DOI: 10.1086/375454]
- Hartong DT,** Berson EL, Dryja TP. Retinitis pigmentosa. *Lancet* 2006; **368**: 1795-1809 [PMID: 17113430 DOI: 10.1016/

S0140-6736(06)69740-7]

- 16 **Beales PL**, Elcioglu N, Woolf AS, Parker D, Flinter FA. New criteria for improved diagnosis of Bardet-Biedl syndrome: results of a population survey. *J Med Genet* 1999; **36**: 437-446 [PMID: 10874630]
- 17 **Héon E**, Westall C, Carmi R, Elbedour K, Pantan C, Mackeen L, Stone EM, Sheffield VC. Ocular phenotypes of three genetic variants of Bardet-Biedl syndrome. *Am J Med Genet A* 2005; **132A**: 283-287 [PMID: 15690372 DOI: 10.1002/ajmg.a.30466]
- 18 **Holt RI**. International Diabetes Federation re-defines the metabolic syndrome. *Diabetes Obes Metab* 2005; **7**: 618-620 [PMID: 16050956 DOI: 10.1111/j.1463-1326.2005.00519.x]

P- Reviewer: Gao RP
S- Editor: Yu J **L- Editor:** Rutherford A **E- Editor:** Jiao XK



Acute dapsone poisoning in a 3-year-old child: Case report with review of literature

Menon Narayanankutty Sunilkumar, Thekkuttuparambil Ananthanarayanan Ajith, Vadakut Krishnan Parvathy

Menon Narayanankutty Sunilkumar, Vadakut Krishnan Parvathy, Department of Paediatrics, Amala Institute of Medical Sciences, Amala Nagar, Thrissur 680555, Kerala, India

Thekkuttuparambil Ananthanarayanan Ajith, Department of Biochemistry, Amala Institute of Medical Sciences, Amala Nagar, Thrissur 680555, Kerala, India

Author contributions: Sunilkumar MN collected the clinical data and prepared the case report; Ajith TA had edited and critically revised the intellectual content; Parvathy VK approved the final version of the manuscript to be published.

Institutional review board statement: This case report was approved by the Institutional Ethics Committee, Amala Institute of Medical Sciences, Amala Nagar, Thrissur, Kerala, India.

Informed consent statement: The subject had given verbal consent for publishing this case report.

Conflict-of-interest statement: The authors declare that they have no conflicting interests including but not limited to commercial, personal, political, intellectual, or religious.

Open-Access: This article is an open-access article which was selected by an in-house editor and fully peer-reviewed by external reviewers. It is distributed in accordance with the Creative Commons Attribution Non Commercial (CC BY-NC 4.0) license, which permits others to distribute, remix, adapt, build upon this work non-commercially, and license their derivative works on different terms, provided the original work is properly cited and the use is non-commercial. See: <http://creativecommons.org/licenses/by-nc/4.0/>

Correspondence to: Dr. Menon Narayanankutty Sunilkumar, Associate Professor, Department of Paediatrics, Amala Institute of Medical Sciences, Amala Nagar, Thrissur 680555, Kerala, India. sunilsree99@gmail.com
Telephone: +91-487-2304116
Fax: +91-487-2307969

Received: May 15, 2015
Peer-review started: May 24, 2015
First decision: June 24, 2015

Revised: July 24, 2015

Accepted: August 13, 2015

Article in press: August 14, 2015

Published online: October 16, 2015

Abstract

Dapsone (DDS-diamino diphenyl sulphone) is a sulfone antibiotic being used for a variety of clinical conditions. Poisoning in children by DDS is rarely reported. Poisoning in acute cases will be frequently unrecognized due to relative lack of severe signs and symptoms. Methemoglobinemia is the major life-threatening situation associated with poisoning of DDS. Hence, any delay for medical attention can lead to increased rate of mortality. In this case, we describe acute DDS poisoning in a 3-year-old child and the successful management using intravenous methylene blue.

Key words: Dapsone; Methemoglobinemia; Ascorbic acid; Methylene blue; Hemolysis

© The Author(s) 2015. Published by Baishideng Publishing Group Inc. All rights reserved.

Core tip: Dapsone (DDS-diamino diphenyl sulphone), a sulfone antibiotic poisoning in children is rarely reported. Methemoglobinemia is the major life-threatening situation associated with DDS poisoning. Delay in seeking medical attention can lead to increased rate of mortality. Methylene blue 0.1% (2 mg/kg) as slow *iv* is the first line therapy. Furthermore, therapies like exchange transfusions and hyperbaric oxygen therapy are options especially in cases where contraindicated in glucose-6-phosphate dehydrogenase deficiency or if methylene blue therapy is ineffective.

Sunilkumar MN, Ajith TA, Parvathy VK. Acute dapsone

poisoning in a 3-year-old child: Case report with review of literature. *World J Clin Cases* 2015; 3(10): 911-914 Available from: URL: <http://www.wjgnet.com/2307-8960/full/v3/i10/911.htm> DOI: <http://dx.doi.org/10.12998/wjcc.v3.i10.911>

INTRODUCTION

Dapsone (DDS-diamino diphenyl sulphone), a sulfone antibiotic being used for the prophylactic therapy of various infections in an immunocompromised individual^[1]. DDS poisoning in children are rarely reported. In initial stages of acute poisoning, there will not be any major manifestations and hence there may be delay in seeking medical attention. The life threatening events occur as a result of DDS-induced methemoglobinemia which will eventually affect the oxygen delivery to cells^[2]. Hence, it will be worthwhile to discuss the manifestations and managements of DDS poisoning in order to prevent its adverse effects. In this case study, we present a 3-year-old child with accidental ingestion of DDS.

CASE REPORT

A 3-year-old boy brought to the hospital with complaints of accidental ingestion of DDS. At the onset of admission, the symptoms were lethargy, vomiting and unsteadiness. The child had persisted vomiting and later developed lethargy. He was conscious with blood pressure 106/68 mmHg, respiration rate 68/min, temperature 98.6 °F and pulse rate 150 beats/min. Oxygen saturation (SpO₂) was 91%. He had mild peripheral cyanosis, ataxia and nystagmus. Pupils were equally reacting to light; reflexes were brisk with plantar withdrawal with tone increased in all limbs. Later, the child becomes agitated and stuporous. Arterial blood gas (ABG) analysis showed pO₂ 84 mmHg with hematocrit 29% and SpO₂ 91.6% (Table 1). Evidence for hemolysis characterized by progressive drop in haemoglobin levels and hematocrit values. Packed red cell transfusion was given on 2nd and 3rd day as there was ongoing hemolysis. The initial methemoglobin (MHbA) level was 19.4%. Acute DDS-induced methemoglobinemia and CNS involvement was confirmed. O₂ inhalation and ascorbic acid (CELIN-1000 mg) was administered *via* nasogastric tube along with ranitidine and ondansetron as *iv* Methylene blue 0.1% (2 mg/kg) as slow *iv* was given. SpO₂ was increased to 96%, pO₂ 88 mmHg with hematocrit 29%. Liver function test showed abnormal rise in enzymes till 5th day (Table 1). The renal function test and urinalysis were normal. On 5th day, the MHbA level was found to be 10.2%. On the day 7, another dose of methylene blue was given as he became lethargic with SpO₂ of 82%. The child was improved and discharged on day 14th after admission. During the follow-up, he had no neurological deficits and haemoglobin level was 11.8 g/dL.

DISCUSSION

DDS is an antimicrobial used to treat leprosy, dermatoses, malaria, *etc*^[1]. The most frequent reaction that occur with higher doses of DDS toxicity is hemolytic anemia and methemoglobinemia^[3]. Landers *et al*^[4] reported decrease in hemoglobin (1-2 g/dL) and reticulocyte count (2%-12%) levels in patient with DDS toxicity. Therefore, when the methemoglobinemia causes symptomatic hemodynamic instability, discontinuation of DDS therapy is recommended.

The possibilities for DDS ingestion and poisoning in children are high. The blood MHbA level determines the clinical severity of the symptoms and signs. Most of the patients are found to be asymptomatic until approximately 30% of hemoglobin is presented as MHbA^[1]. However, levels especially greater than 15% may be associated with cyanosis. In this child, the initial MHbA was 19.4%. Headache, lethargy, tachycardia and dizziness may be presented at levels between 20%-45%, whereas dyspnea, acidosis, seizures, cardiac dysrhythmias, heart failure and coma may occur at level above 45%. Furthermore, high mortality rate is associated with levels above 70%^[5]. The patient in this case study had metabolic acidosis as evidenced from the lowered blood pH and bicarbonate level one day after the admission.

Acquired methemoglobinemia can be caused by nitrites and nitrates, nitric oxide, sulphones (*e.g.*, dapsone), local anesthetics (*e.g.*, benzocaine), aniline dyes, chlorates, pyridium, phenacetin, sulphonamides, *etc*^[6]. Use of topical DDS as treatment for acne vulgaris has also been associated with MHbA levels as high as 20%^[7]. In oxygenated and deoxygenated hemoglobin, iron remains in the ferrous (Fe²⁺) form which is essential for the oxygen transportation. Oxidation of Fe²⁺ to ferric form yields MHbA, which does not bind to oxygen. Followed by the MHbA formation, the oxygen affinity of any remaining Fe²⁺-hemes in the hemoglobin tetramer is increased and the oxygen dissociation curve is "left-shifted". Therefore, the circulating MHbA as well as the remaining oxyhemoglobin which has increased oxygen affinity can cause impaired oxygen delivery to the tissues. The net effect is that patients with acutely increased concentrations of MHbA have a functional anemia (*i.e.*, the amount of functional hemoglobin is less than the measured level of total hemoglobin). The existence of underlying diseases of lung, heart or blood may exacerbate the toxicity of MHbA. About 3% of the Fe²⁺ of deoxy Hb is slowly oxidized to MHbA per day. The intra-erythrocytic MHbA reducing enzyme systems such as NADH-dependant cytochrome b5 reductase, mainly and NADPH-MHbA reductase and NADPH-glutathione reductase, to a lesser extent help to keep its level below 1%. Level of MHbA above 2% is abnormal.

Management of DDS includes oral administration of activated charcoal and intravenous treatment with methylene blue. In this patient, we could not administer activated charcoal due to persistent vomiting. The

Table 1 Laboratory investigations

Investigations	1 d after admission	5 d after admission
Hemoglobin (g/dL)	10.5	9.7
Platelet count/ μ L	250000	210000
Total WBC count/ μ L	10760	14094
Differential leucocyte count (%): Neutrophils; Lymphocytes; Eosinophils; Monocytes; Basophils	65; 26; 3.3; 2.5; 2	48; 43; 5; 2; 2
Serum Na ⁺ (mmol/L); K ⁺ (mmol/L)	137; 4.3	138; 4.1
Bicarbonate (mmol/L)	17	23
Serum glutamic-pyruvic transaminase (U/L)	150	162
Blood gas analysis pH; pCO ₂ (mmHg); pO ₂ (mmHg); hematocrit (%) and SpO ₂ (%)	7.37; 16; 84; 29; 91.6	7.41; 22; 88; 29; 96.6
Methaemoglobin (%)	19.4	10.2

plasma elimination half-life of DDS was found to be dose dependent which varies from 10 to 80 h. The renal excretion of unchanged DDS is limited to approximately 20% of the administered dose. DDS is metabolised in the liver for its elimination resulted a moderate elevation of SGPT (150-162 U/L) during the initial few days but normalised on 14th day (45 U/L). After the initial dosage of methylene blue, an additional dose may be repeated if there is an insufficient response. In this case, an additional dose of methylene blue was given since the MHbA level was high on 5th day. This may be due to the enterohepatic circulation of DDS which resulted in a rebound methemoglobinemia as high as 60% up to 18 h of methylene blue injection.

Treatment with methylene blue can be complicated by the presence of underlying glucose-6-phosphate dehydrogenase deficiency. Therefore, alternative therapies like exchange transfusions and hyperbaric oxygen therapy are the remaining options in patients with glucose-6-phosphate dehydrogenase deficiency or if methylene blue therapy is ineffective^[8]. But the efficacy of these therapies not yet been elucidated. Ascorbic acid rarely reduces the cyanosis associated with chronic methemoglobinemia but has no role in treatment of acute acquired methemoglobinemia. Furthermore, Cimetidine, used as a selective inhibitor of N-hydroxylation, may be effective in increasing patient tolerance to dapsone, chronically lowering the MHbA level by more than 25%. Since it works slowly, cimetidine is not helpful for the management of acute symptomatic methemoglobinemia arising from the use of DDS.

Methylene blue is a phenothiazine-related heterocyclic aromatic molecule most commonly used as a reducing agent in the treatment of methemoglobinemia and for the treatment of cyanide and carbon monoxide poisoning^[3,9]. It has dose-dependent effect on cardiac index and pulmonary artery occlusion pressure as well as oxygen delivery and lactate concentrations. The dosing of methylene blue is not entirely clear, but 1-2 mg/kg is used for the treatment of methemoglobinemia. However, methylene blue above 7 mg/kg is associated with adverse effects such as paradoxical induction of MHbA, hemolytic anemia and detrimental effects on pulmonary function^[10,11]. Therefore, methylene blue

should not be recommended in patients with pulmonary hypertension, underlying glucose-6-phosphate dehydrogenase deficiency and acute lung injury^[11]. Clinicians should also be aware of potential adverse effects and drug interactions with serotonergic agents when considering therapy with methylene blue^[12].

According to Wright *et al.*^[13], the diagnosis may be complicated by the effect of MHbA on arterial blood gas and pulse oximeter oxygen saturation results. In the presence of the increased MHbA fraction, pulse oximeter values will trend toward 85% underestimating the actual oxygen saturation. Guay^[14] demonstrated the discrepancy between the pulse oximeter saturation ($\leq 90\%$) and the arterial oxygen partial pressure (≤ 70 mmHg) in subjects with MHbA. Therefore, the routine pulse oximetry is generally inaccurate for monitoring oxygen saturation in the presence of methemoglobinemia. Acute hemolytic anemia in DDS can be explained with the DDS-induced continued oxidative stress or may also be due to the doses of methylene blue^[15]. Charcoal hemoperfusion has also been reported for the rapid clearing of dapsone^[16].

This case report concluded that patient with dapsone poisoning should be evaluated for serial measurements of methemoglobin levels following treatment with methylene blue in order to evaluate for the subsequent worsening and the need for additional treatment.

COMMENTS

Case characteristics

A 3-year-old boy presented with persisted vomiting and lethargy.

Clinical diagnosis

The patient had mild peripheral cyanosis, ataxia and nystagmus.

Differential diagnosis

Other causes for the drug induced acquired methemoglobinemia.

Laboratory diagnosis

Methemoglobinemia greater than 2% and lowered haematocrit value.

Treatment

Methylene blue 0.1% (2 mg/kg) as *iv*.

Related reports

Accidental acute dapsone poisoning in children are rarely reported. Management includes charcoal hemoperfusion, exchange transfusions and hyperbaric oxygen therapy.

Term explanation

Dapsone, a sulfone antibiotic being used for the prophylactic therapy of various infections in an immunocompromised individual, induces methemoglobinemia at higher doses. The level of methemoglobin in the blood determines the clinical severity of the symptoms and signs.

Experiences and lessons

Patient with dapsone-induced methemoglobinemia required serial measurements of methemoglobin levels following treatment with methylene blue in order to evaluate the subsequent worsening and the need for additional treatment. Routine pulse oximetry is generally inaccurate for monitoring oxygen saturation in the presence of methemoglobinemia.

Peer-review

This is a useful review of dapsone poisoning and its treatment.

REFERENCES

- 1 **Turner MD**, Karlis V, Glickman RS. The recognition, physiology, and treatment of medication-induced methemoglobinemia: a case report. *Anesth Prog* 2007; **54**: 115-117 [PMID: 17900210 DOI: 10.2344/0003-3006(2007)54[115:TRPATO]2.0.CO;2]
- 2 **Plotkin JS**, Buell JF, Njoku MJ, Wilson S, Kuo PC, Bartlett ST, Howell C, Johnson LB. Methemoglobinemia associated with dapsone treatment in solid organ transplant recipients: a two-case report and review. *Liver Transpl Surg* 1997; **3**: 149-152 [PMID: 9346728 DOI: 10.1002/lt.500030207]
- 3 **Barclay JA**, Ziemba SE, Ibrahim RB. Dapsone-induced methemoglobinemia: a primer for clinicians. *Ann Pharmacother* 2011; **45**: 1103-1115 [PMID: 21852596 DOI: 10.1345/aph.1Q139]
- 4 **Landers D**, Bergin C, O'Leary A, Merry C, Keating S, Mulcahy F. Dapsone induced methaemoglobinaemia. *Int J STD AIDS* 1996; **7**: 445-447 [PMID: 8940676 DOI: 10.1258/0956462961918293]
- 5 **Curry S**. Methemoglobinemia. *Ann Emerg Med* 1982; **11**: 214-221 [PMID: 7073040 DOI: 10.1016/S0196-0644(82)80502-7]
- 6 **Hall AH**, Kulig KW, Rumack BH. Drug- and chemical-induced methaemoglobinaemia. Clinical features and management. *Med Toxicol* 1986; **1**: 253-260 [PMID: 3537620]
- 7 **Swartzentruber GS**, Yanta JH, Pizon AF. Methemoglobinemia as a complication of topical dapsone. *N Engl J Med* 2015; **372**: 491-492 [PMID: 25629756 DOI: 10.1056/NEJMc1408272]
- 8 **Ward KE**, McCarthy MW. Dapsone-induced methemoglobinemia. *Ann Pharmacother* 1998; **32**: 549-553 [PMID: 9606476 DOI: 10.1345/aph.17003]
- 9 **Hanzlik PJ**. Subject of This Letter: Methylene Blue as Antidote for Cyanide Poisoning. *Cal West Med* 1933; **38**: 225-226 [PMID: 18742459]
- 10 **Gachot B**, Bedos JP, Veber B, Wolff M, Regnier B. Short-term effects of methylene blue on hemodynamics and gas exchange in humans with septic shock. *Intensive Care Med* 1995; **21**: 1027-1031 [PMID: 8750129 DOI: 10.1007/BF01700666]
- 11 **Weingartner R**, Oliveira E, Oliveira ES, Sant'Anna UL, Oliveira RP, Azambuja LA, Friedman G. Blockade of the action of nitric oxide in human septic shock increases systemic vascular resistance and has detrimental effects on pulmonary function after a short infusion of methylene blue. *Braz J Med Biol Res* 1999; **32**: 1505-1513 [PMID: 10585632 DOI: 10.1590/S0100-879X1999001200009]
- 12 **Jang DH**, Nelson LS, Hoffman RS. Methylene blue for distributive shock: a potential new use of an old antidote. *J Med Toxicol* 2013; **9**: 242-249 [PMID: 23580172 DOI: 10.1007/s13181-013-0298-7]
- 13 **Wright RO**, Lewander WJ, Woolf AD. Methemoglobinemia: etiology, pharmacology, and clinical management. *Ann Emerg Med* 1999; **34**: 646-656 [PMID: 10533013 DOI: 10.1016/S0196-0644(99)70167-8]
- 14 **Guay J**. Methemoglobinemia related to local anesthetics: a summary of 242 episodes. *Anesth Analg* 2009; **108**: 837-845 [PMID: 19224791 DOI: 10.1213/ane.0b013e318187c4b1]
- 15 **Erstad BL**. Dapsone-induced methemoglobinemia and hemolytic anemia. *Clin Pharm* 1992; **11**: 800-805 [PMID: 1521404]
- 16 **Endre ZH**, Charlesworth JA, Macdonald GJ, Woodbridge L. Successful treatment of acute dapsone intoxication using charcoal hemoperfusion. *Aust N Z J Med* 1983; **13**: 509-512 [PMID: 6228217]

P- Reviewer: Boucek C, Nakos G, Willms D
S- Editor: Ji FF L- Editor: A E- Editor: Jiao XK



Mediastinal small cell carcinoma with liver and bone marrow metastasis, mimicking lymphoma

Napaporn Nawarawong, Tawatchai Pongpruttipan, Pitulak Aswakul, Varayu Prachayakul

Napaporn Nawarawong, Varayu Prachayakul, Siriraj GI Endoscopy Center, Division of Gastroenterology, Department of Internal Medicine, Siriraj Hospital, Mahidol University, Bangkok 10700, Thailand

Tawatchai Pongpruttipan, Division of Hematopathology, Department of Pathology, Faculty of Medicine, Siriraj Hospital, Mahidol University, Bangkok 10700, Thailand

Pitulak Aswakul, Liver and Digestive Institute, Samitivej Sukhumvit Hospital, Bangkok 10120, Thailand

Author contributions: Nawarawong N and Pongpruttipan T performed the data collection; Nawarawong N, Aswakul P, and Prachayakul V drafted and reviewed the article; Aswakul P and Prachayakul V revised the article and approved the version to be published.

Institutional review board statement: This article was approved by the Siriraj Internal Review Board.

Informed consent statement: The patient provided written informed consent before this procedure was performed.

Conflict-of-interest statement: The authors have no conflicts of interest related to this article.

Open-Access: This article is an open-access article which was selected by an in-house editor and fully peer-reviewed by external reviewers. It is distributed in accordance with the Creative Commons Attribution Non Commercial (CC BY-NC 4.0) license, which permits others to distribute, remix, adapt, build upon this work non-commercially, and license their derivative works on different terms, provided the original work is properly cited and the use is non-commercial. See: <http://creativecommons.org/licenses/by-nc/4.0/>

Correspondence to: Varayu Prachayakul, Associate Professor, Siriraj GI Endoscopy Center, Division of Gastroenterology, Department of Internal Medicine, Siriraj Hospital, Mahidol University, 2 Prannok Road, Bangkok 10700, Thailand. kaiyjr@gmail.com
Telephone: +66-818654646
Fax: +66-24115013

Received: February 8, 2015

Peer-review started: February 10, 2015

First decision: April 24, 2015

Revised: June 12, 2015

Accepted: August 28, 2015

Article in press: September 7, 2015

Published online: October 16, 2015

Abstract

Primary mediastinal neuroendocrine tumors are a rare malignancy that accounts for < 10% of all mediastinal tumors. The case presented here involves a 52-year-old man who had been suffering for 3 mo from chronic cough, anorexia and substantial weight loss, as well as 2 wk of jaundice prior to his admission. A computed tomography scan showed a 4.3 cm × 6.6 cm mediastinal mass with multiple liver nodules scattered along both hepatic lobes. Endoscopic ultrasound showed a large heterogeneous hypoechoic mass at the mediastinum with multiple target-like nodules in the liver. Fine-needle aspiration specimens revealed numerous, small, round cells with hyperchromatic nuclei, scarce cytoplasm, and frequent mitotic features. Immunohistochemical study revealed positive results for AE1/AE3, CD56 and chromogranin A, with negative findings for synaptophysin, CK20, vimentin, CK8/18 and CD45. The patient was subsequently diagnosed with a poorly differentiated neuroendocrine carcinoma, small cell type. A bone marrow biopsy also revealed extensive involvement by the carcinoma.

Key words: Bone marrow metastasis; Liver metastasis; Lymphoma; Mediastinal mass; Neuroendocrine tumor

© The Author(s) 2015. Published by Baishideng Publishing Group Inc. All rights reserved.

Core tip: Neuroendocrine tumors are rare tumors that arise from the gastrointestinal tract and broncho-pulmonary system. Primary mediastinal neuroendocrine

tumors are exceptionally rare malignancies, accounting for < 10% of all mediastinal tumors. The common clinical manifestation of this rare tumor is a mediastinal mass, but the condition can mimic lymphoma in advanced cases. The liver is the most common site of metastasis.

Nawarawong N, Pongpruttipan T, Aswakul P, Prachayakul V. Mediastinal small cell carcinoma with liver and bone marrow metastasis, mimicking lymphoma. *World J Clin Cases* 2015; 3(10): 915-919 Available from: URL: <http://www.wjgnet.com/2307-8960/full/v3/i10/915.htm> DOI: <http://dx.doi.org/10.12998/wjcc.v3.i10.915>

INTRODUCTION

The most common malignancy of the mediastinum is Hodgkin's lymphoma, which usually involves the anterior mediastinum and typically presents as adjacent organ invasion, superior vena cava obstruction, pleural effusion, or erosion of the sternum. The most common site of metastasis for Hodgkin's disease is the liver^[1]. In contrast, primary mediastinal neuroendocrine tumors are a rare malignancy that account for < 10% of all mediastinal tumors, with a reported incidence of 0.2-2.0 per 100000 people. These tumors are typically detected as incidental findings from chest radiography, as 40%-70% of advanced cases present with chronic cough, chest pain, dyspnea, or superior vena cava obstruction syndrome^[2].

According to Travis^[3], pulmonary neuroendocrine tumors are classified as: (1) typical carcinoid tumors; (2) atypical carcinoid tumors; (3) large cell neuroendocrine carcinomas; and (4) small cell neuroendocrine carcinomas. The prognoses of these mediastinal neuroendocrine tumors differ, with typical carcinoids associated with the best prognosis due to their slow growth and late metastasis, and the worst prognosis found with small cell neuroendocrine tumors^[4]. Only a few cases of these tumors have been reported, with the liver as the most common site of metastasis^[5,6]. This report describes a rare case involving a mediastinal mass with clinical manifestations mimicking lymphoma. To our knowledge, this is the first case report of primary neuroendocrine carcinoma with bone marrow and liver metastases.

CASE REPORT

A 52-year-old man presented to our hospital with a chronic cough, anorexia and substantial weight loss that had occurred over the previous 3 mo. He also presented with painless jaundice that had appeared 2 wk prior to his admission. He reported that he was a heavy smoker and had not experienced fever or shivering. His physical exam showed marked pallor and moderate jaundice, with a normal chest examination. The abdominal examination revealed hepatomegaly

without splenomegaly and a negative finding for peripheral lymphadenopathy. Laboratory blood tests showed marked anemia with 6.8 g/dL hemoglobin (reference range: 12.0-18.0 g/dL), and normal white blood cell (7.7×10^3 cells/ μ L; reference range: $4-11 \times 10^3$ cells/ μ L) and reduced platelet (139×10^3 cells/ μ L; reference range: $150-440 \times 10^3$ cells/ μ L) counts. Liver chemistry results were as follows: total bilirubin, 4.2 mg/dL (reference range: 0-1.2 mg/dL); direct bilirubin, 3.7 mg/dL (reference range: 0-0.3 mg/dL); aspartate transaminase, 138 U/L (reference range: 0-32 U/L); alanine transaminase, 141 U/L (reference range: 0-32 U/L); and alkaline phosphatase, 403 U/L (reference range: 35-105 U/L). A markedly elevated lactate dehydrogenase level was noted at 3971 U/L (reference range: 240-480 U/L). Carcinoembryonic antigen measured 3.1 ng/mL (reference range: 0-5.0 ng/mL), with carbohydrate antigen 19-9 at 60.6 U/mL (reference range: 0-37.0 U/mL) and alpha-fetoprotein at 3.02 ng/mL (reference range: 1.09-8.04 ng/mL). The anti-HIV test was negative.

A computed tomography (CT) scan of the chest and upper abdomen showed a 4.3 cm \times 6.6 cm mediastinal mass (Figure 1) with multiple liver nodules scattered along both hepatic lobes without any noteworthy pulmonary lesions. The provisional diagnosis was lymphoma, and the patient was therefore scheduled for endoscopic ultrasound and tissue sample collection. After deep sedation was induced using intravenous propofol with full anesthetic monitoring, a curvilinear endoscopic ultrasound scope (EG530UT2; Fujifilm, Minato-ku, Tokyo, Japan) was used for scanning. The echoview showed a large heterogeneous hypoechoic mass > 6 cm in diameter at the mediastinum, with multiple target-like nodules in the liver (Figure 2). Next, fine-needle aspiration of the mediastinal mass was performed with four passes using a 22-gauge needle (EchoTip Procore; Cook Group Inc., Bloomington, IN, United States) (Figure 3). A diagnosis of primary mediastinal lymphoma with liver metastasis was strongly suspected.

The patient's clinical status worsened despite administration of intravenous corticosteroids. The histopathologic results finally revealed numerous small, individual, round cells with hyperchromatic nuclei, scarce cytoplasm, and frequent mitotic features. An immunohistochemical study was positive for AE1/AE3, CD56 and chromogranin A (Figure 4), but negative for synaptophysin, CK20, vimentin, CK8/18 and CD45. Based on these findings, a diagnosis of poorly differentiated neuroendocrine carcinoma, small cell type was made.

A bone marrow biopsy was also performed, which showed extensive involvement by the carcinoma (Figure 5). However, intravenous chemotherapy was not administered due to the poor performance status at this point. The patient subsequently died a few weeks later, after developing progressive liver failure, edema in both legs, and a sudden onset of dyspnea and cyanosis, due

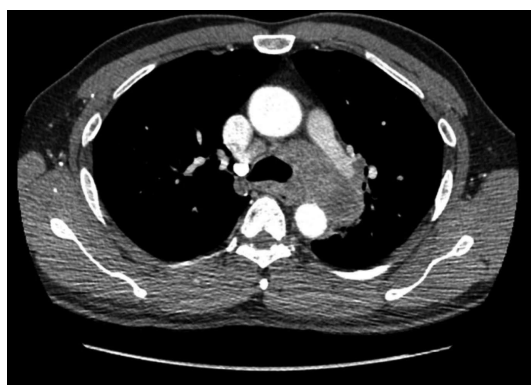

Figure 1 Computed tomography findings. A 6.6 cm × 4.3 cm mediastinal mass was observed.

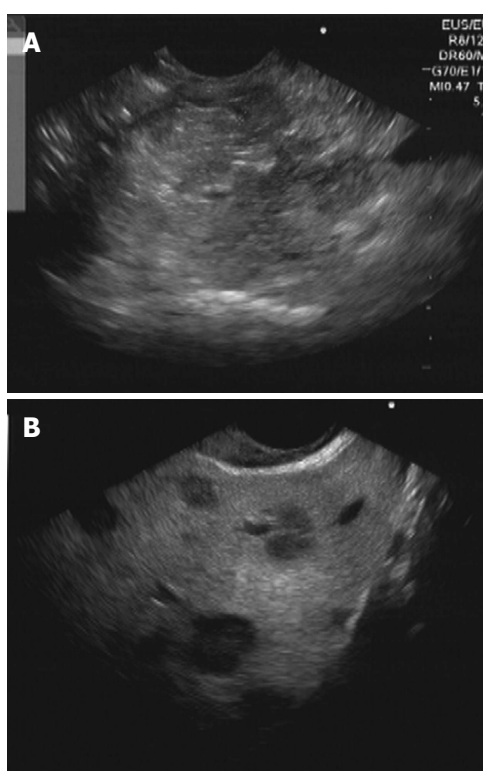


Figure 2 Endoscopic ultrasound findings. A: Echoview showed a large mediastinal mass; B: Liver nodules with target-like appearance were also observed.

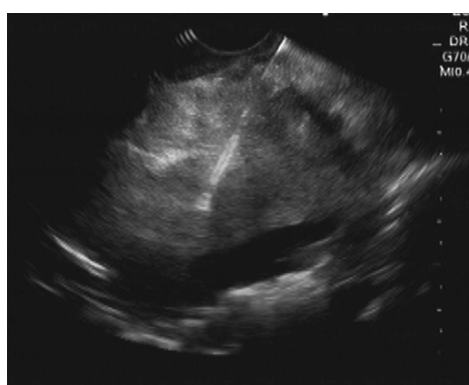


Figure 3 Fine-needle aspiration cytology was performed.

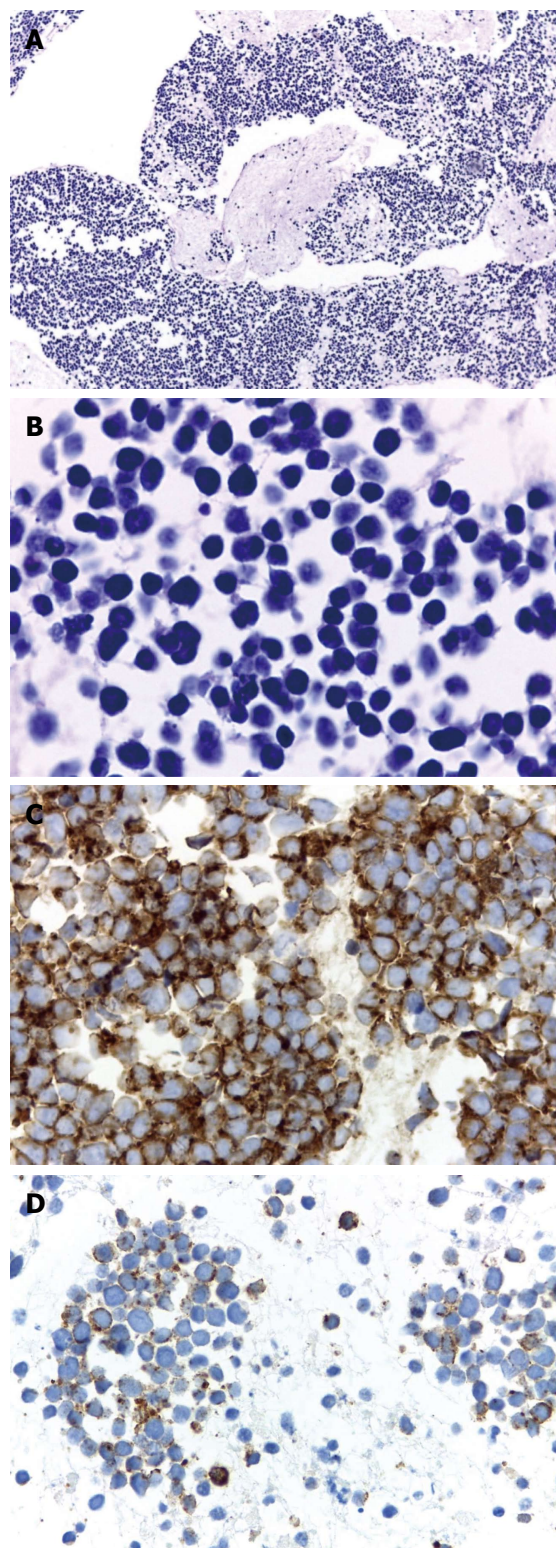


Figure 4 Histopathologic findings. A and B: Cell-block preparation from fine-needle aspiration of the mediastinal mass showed numerous small, individual, round cells with hyperchromatic nuclei, scarce cytoplasm, and frequent mitotic features. Rare instances of nuclear molding were also observed (hematoxylin-eosin staining, magnification × 10 and × 40, respectively); C and D: Immunohistochemical study revealed that the tumor cells were positive for AE1/AE3 (C) and chromogranin A (D; magnifications × 40).

to a suspected acute pulmonary embolism. No autopsy was performed in this case.

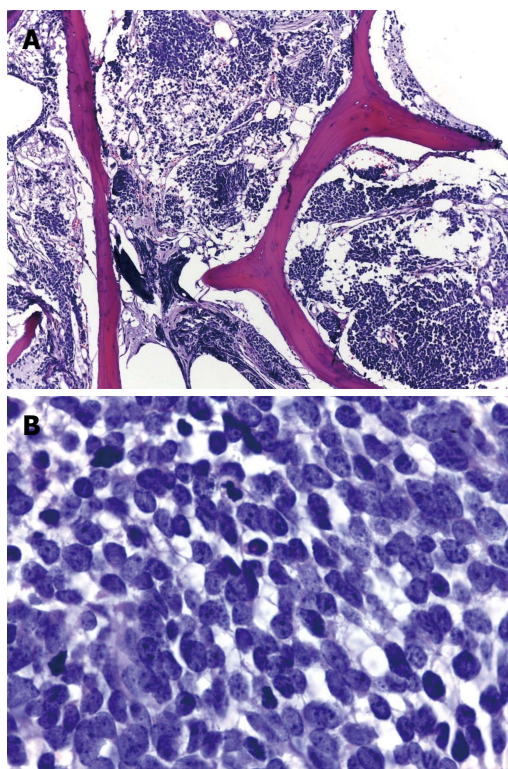


Figure 5 Bone marrow biopsy showed extensive infiltration by cohesive sheets of small, round cells with fine granular chromatin and scarce cytoplasm.

DISCUSSION

Neuroendocrine tumors are rare tumors that typically involve the gastrointestinal tract and the broncho-pulmonary system. Primary mediastinal neuroendocrine tumors are extremely rare^[7-13], and can present as lymphoma, particularly Hodgkin's type. Indeed, the case described here initially presented with similar clinical symptoms, such as chronic cough, anorexia, weight loss, and a bulky mediastinal mass with liver metastasis. However, a final diagnosis of a poorly differentiated neuroendocrine tumor, small cell type was made after histopathologic and immunohistochemical study. The multiple liver nodules were strong indicators of liver metastasis, and this is the first reported case of mediastinal neuroendocrine tumor with liver and bone marrow metastases.

Li *et al.*^[14] reported a case series of six patients with primary small cell neuroendocrine carcinoma and found that most of the cases were in advanced stages, with tumors > 6 cm. Moreover, more than two-thirds of those cases involved the anterior-middle mediastinum with 44% scattered punctate calcification on CT. However, the immunohistochemical studies were positive for different markers, indicating the tumors had differentiated from a carcinoid tumor, mediastinal lymphoma, germ cell tumor of mediastinum, and thymoma. The poor prognosis for primary small cell neuroendocrine carcinoma was demonstrated by only half of the cases responding to chemotherapy, and the 2-year mortality rate of 50%^[14].

The patient described in this case report had an advanced stage neuroendocrine tumor with fatal outcome. Definitive treatment for this small cell carcinoma should be guided by the definite histopathological and immunohistochemistry results.

COMMENTS

Case characteristics

A 52-year-old man presented with a chronic cough, weight loss, anemia and progressive jaundice.

Clinical diagnosis

Metastatic small cell neuroendocrine tumor with liver and bone marrow involvement.

Differential diagnosis

Lymphoma; Carcinoid tumor; Mediastinal lymphoma; Germ cell tumor of mediastinum; Thymoma.

Laboratory diagnosis

Hemoglobin, 6.8 g/dL; White blood cell count, 7.7×10^3 cells/ μ L; Platelet count, 139×10^3 cells/ μ L; Total bilirubin, 4.2 mg/dL; Direct bilirubin, 3.7 mg/dL; Aspartate transaminase, 138 U/L; Alanine transaminase, 141 U/L; Alkaline phosphatase, 403 U/L; Lactate dehydrogenase, 3971 U/L; Carcinoembryonic antigen, 3.11 ng/mL; Carbohydrate antigen 19-9, 60.62 U/mL; Alpha-fetoprotein, 3.02 ng/mL.

Imaging diagnosis

Computed tomography scan of the chest and upper abdomen showed a 4.3 cm \times 6.6 cm mediastinal mass with multiple liver nodules scattered along both hepatic lobes without any marked pulmonary lesions.

Pathological diagnosis

Poorly differentiated neuroendocrine carcinoma, small cell type.

Treatment

Palliative treatment.

Related reports

Neuroendocrine tumors are a very rare malignancy of the mediastinum, and there are very few reports in the literature.

Experiences and lessons

Mediastinal neuroendocrine tumors may have a clinical presentation similar to lymphoma of the mediastinum. Histologic diagnosis and immunohistochemical study are crucial for definite diagnosis.

Peer-review

The authors describe a case of primary mediastinal neuroendocrine tumor with liver and bone marrow metastases, which mimicked lymphoma. This is a rare tumor with malignant lymphoma as the primary differential diagnosis.

REFERENCES

- 1 Macchiarini P, Ostertag H. Uncommon primary mediastinal tumours. *Lancet Oncol* 2004; **5**: 107-118 [PMID: 14761815 DOI: 10.1016/S1470-2045(04)01385-3]
- 2 Caplin ME, Baudin E, Ferolla P, Filosso P, Garcia-Yuste M, Lim E, Oberg K, Pelosi G, Perren A, Rossi RE, Travis WD. Pulmonary neuroendocrine (carcinoid) tumors: European Neuroendocrine Tumor Society expert consensus and recommendations for best practice for typical and atypical pulmonary carcinoids. *Ann Oncol* 2015; **26**: 1604-1620 [PMID: 25646366 DOI: 10.1093/annonc/mdv041]

- 3 **Travis WD.** Pathology and diagnosis of neuroendocrine tumors: lung neuroendocrine. *Thorac Surg Clin* 2014; **24**: 257-266 [PMID: 25065926 DOI: 10.1016/j.thorsurg.2014.04.001]
- 4 **Chong S, Lee KS, Chung MJ, Han J, Kwon OJ, Kim TS.** Neuroendocrine tumors of the lung: clinical, pathologic, and imaging findings. *Radiographics* 2006; **26**: 41-57; discussion 57-58 [PMID: 16418242 DOI: 10.1148/rg.261055057]
- 5 **Wick MR, Rosai J.** Neuroendocrine neoplasms of the mediastinum. *Semin Diagn Pathol* 1991; **8**: 35-51 [PMID: 1646476]
- 6 **Del Vescovo R, Cazzato RL, Battisti S, D'Agostino F, Vincenzi B, Grasso RF, Zobel BB.** Neuroendocrine tumor presenting like lymphoma: a case report. *J Med Case Rep* 2011; **5**: 506 [PMID: 21974797 DOI: 10.1186/1752-1947-5-506]
- 7 **Cheung TT, Chok KS, Chan AC, Tsang S, Dai JW, Lang BH, Yau T, Chan SC, Poon RT, Fan ST, Lo CM.** Long term survival analysis of hepatectomy for neuroendocrine tumour liver metastases. *ScientificWorldJournal* 2014; **2014**: 524045 [PMID: 24526905]
- 8 **Modlin IM, Lye KD, Kidd M.** A 5-decade analysis of 13,715 carcinoid tumors. *Cancer* 2003; **97**: 934-959 [PMID: 12569593 DOI: 10.1002/cncr.11105]
- 9 **Lim KH, Huang MJ, Yang S, Hsieh RK, Lin J.** Primary carcinoid tumor of prostate presenting with bone marrow metastases. *Urology* 2005; **65**: 174 [PMID: 15667891 DOI: 10.1016/j.urology.2004.07.010]
- 10 **Khan M, Nizami S, Mirrakhimov AE, Maughan B, Bishop JA, Sharfman WH.** Primary small cell neuroendocrine carcinoma of paranasal sinuses. *Case Rep Med* 2014; **2014**: 874719 [PMID: 25057271 DOI: 10.1155/2014/874719]
- 11 **Wang HY, Zou J, Zhou GY, Yan JQ, Liu SX.** Primary small cell neuroendocrine carcinoma of the tonsil: a case report and review of the literature. *Int J Clin Exp Pathol* 2014; **7**: 2678-2682 [PMID: 24966986]
- 12 **Case Reports In Dentistry. Retracted: Primary small cell undifferentiated (neuroendocrine) carcinoma of the maxillary sinus.** *Case Rep Dent* 2014; **2014**: 609802 [PMID: 25374701 DOI: 10.1155/2014/609802]
- 13 **Koo YJ, Kim DY, Kim KR, Kim JH, Kim YM, Kim YT, Nam JH.** Small cell neuroendocrine carcinoma of the endometrium: a clinicopathologic study of six cases. *Taiwan J Obstet Gynecol* 2014; **53**: 355-359 [PMID: 25286790 DOI: 10.1016/j.tjog.2013.05.006]
- 14 **Li J, Xia T, Zhang W, He P, Guan Y.** Primary small cell neuroendocrine carcinoma of the mediastinum: computed tomography and histopathological correlation. *J Comput Assist Tomogr* 2014; **38**: 174-178 [PMID: 24625609 DOI: 10.1097/RCT.0b013e3182ab21fe]

P- Reviewer: Moyana TN, Zhao HD

S- Editor: Yu J **L- Editor:** O'Neill M **E- Editor:** Jiao XK



Repeated pancreatitis-induced splenic vein thrombosis leads to intractable gastric variceal bleeding: A case report and review

Shan-Hong Tang, Wei-Zheng Zeng, Qian-Wen He, Jian-Ping Qin, Xiao-Ling Wu, Tao Wang, Zhao Wang, Xuan He, Xiao-Lei Zhou, Quan-Shui Fan, Ming-De Jiang

Shan-Hong Tang, Wei-Zheng Zeng, Jian-Ping Qin, Xiao-Ling Wu, Zhao Wang, Xuan He, Xiao-Lei Zhou, Ming-De Jiang, Department of Digestion, General Hospital of Chengdu Military Command, Chengdu 610083, Sichuan Province, China

Shan-Hong Tang, Quan-Shui Fan, Center for Disease Prevention and Control of Chengdu Military Command, Chengdu 610083, Sichuan Province, China

Qian-Wen He, Department of Radiology, General Hospital of Chengdu Military Command, Chengdu 610083, Sichuan Province, China

Tao Wang, Department of General Surgery, General Hospital of Chengdu Military Command, Chengdu 610083, Sichuan Province, China

Author contributions: All authors contributed to this paper.

Supported by National Natural Science Foundation of China, No. 81401993 (to Tang SH).

Conflict-of-interest statement: The authors have no conflicts of interest to declare.

Open-Access: This article is an open-access article which was selected by an in-house editor and fully peer-reviewed by external reviewers. It is distributed in accordance with the Creative Commons Attribution Non Commercial (CC BY-NC 4.0) license, which permits others to distribute, remix, adapt, build upon this work non-commercially, and license their derivative works on different terms, provided the original work is properly cited and the use is non-commercial. See: <http://creativecommons.org/licenses/by-nc/4.0/>

Correspondence to: Dr. Wei-Zheng Zeng, Department of Digestion, General Hospital of Chengdu Military Command, No. 270 Tianhui Road, Chengdu 610083, Sichuan Province, China. 15928956390@163.com
 Telephone: +86-4006996681

Received: March 27, 2015

Peer-review started: March 28, 2015

First decision: May 18, 2015

Revised: June 11, 2015

Accepted: September 2, 2015

Article in press: September 25, 2015

Published online: October 16, 2015

Abstract

Gastric varices (GV) are one of the most common complications for patients with portal hypertension. Currently, histoacryl injection is recommended as the initial treatment for bleeding of GV, and this injection has been confirmed to be highly effective for most patients in many studies. However, this treatment might be ineffective for some types of GV, such as splenic vein thrombosis-related localized portal hypertension (also called left-sided, sinistral, or regional portal hypertension). Herein, we report a case of repeated pancreatitis-induced complete splenic vein thrombosis that led to intractable gastric variceal bleeding, which was treated by splenectomy. We present detailed radiological and pathological data and blood rheology analysis (the splenic artery - after a short gastric vein or stomach vein - gastric coronary vein - portal vein). The pathophysiology can be explained by the abnormal direction of blood flow in this patient. To our knowledge, this is the first reported case for which detailed pathology and blood rheology data are available.

Key words: Splenic vein thrombosis; Intractable gastric variceal bleeding; Recurrent pancreatitis; Review

© **The Author(s) 2015.** Published by Baishideng Publishing Group Inc. All rights reserved.

Core tip: Here, we report a case in which chronic

pancreatitis-induced complete splenic vein thrombosis led to intractable gastric variceal bleeding, which is effectively treated by splenectomy. We have provided details regarding the imaging and pathology data, and we describe the hemodynamic characteristics. Then, we reviewed the disease onset and treatment methods, which may provide a reference for the clinical diagnosis and treatment of similar patients.

Tang SH, Zeng WZ, He QW, Qin JP, Wu XL, Wang T, Wang Z, He X, Zhou XL, Fan QS, Jiang MD. Repeated pancreatitis-induced splenic vein thrombosis leads to intractable gastric variceal bleeding: A case report and review. *World J Clin Cases* 2015; 3(10): 920-925 Available from: URL: <http://www.wjgnet.com/2307-8960/full/v3/i10/920.htm> DOI: <http://dx.doi.org/10.12998/wjcc.v3.i10.920>

INTRODUCTION

Gastric varices (GV) are among the most common complications affecting patients with portal hypertension, which has a mortality rate that can reach as high as 20% within 6 wk^[1]. Currently, histoacryl injection is recommended as the initial treatment for bleeding GV, and this approach has been confirmed to be highly effective for most patients in many studies^[2-5]. However, this treatment might be ineffective for some types of GV, such as splenic vein thrombosis-related localized portal hypertension (also called left-sided sinistral or regional portal hypertension). Herein, we report a case of recurrent pancreatitis-induced complete splenic vein thrombosis that led to intractable gastric variceal bleeding, which was treated by splenectomy. We present detailed radiological and pathological data and blood rheology analysis results (splenic artery - after a short gastric vein or stomach vein - gastric coronary vein - portal vein). The pathophysiology can be explained by the abnormal direction of blood flow in this patient. To our knowledge, this is the first reported case for which detailed pathology and blood rheology data are available.

CASE REPORT

A 58-year-old man was admitted to our hospital due to recurrent melena lasting for over a month and vomiting lasting for two hours. His past history revealed a history of heavy drinking of at least 200 g daily that exceeded 30 years; however, approximately 7 years before, his alcohol consumption had decreased. Over the past 7 years, he had experienced recurrent pancreatitis five times, and all incidences resolved. Approximately one month prior to admission, this patient began to experience melena with no obvious cause. Endoscopy showed that the gastric mucosa was elevated with fundal varices without active bleeding. After conservative treatment, the melena became intermittent. Then,

another endoscopic examination revealed severe GV, and the patient received five histoacryl injections. Subsequently, he experienced intermittent melena and vomited approximately 200 mL of blood. Physical examination showed anemia, splenomegaly spanning three ribs across the liver, and active bowel sounds (7/min). Blood examinations revealed the following: Red blood cell, $2.98 \times 10^{12}/L$; hemoglobin concentration, 67 g/L; and platelet count, $90 \times 10^9/L$. Both liver and kidney functions were normal. Abdominal enhanced computed tomography (CT) showed cirrhosis and an enlarged portal vein.

The patient was diagnosed with alcoholic cirrhosis, portal hypertension, splenomegaly and GV. Then, emergency endoscopy revealed bleeding GV, and a second histoacryl injection treatment was performed. However, this patient was also experiencing intermittent vomiting, which had become more frequent because the histoacryl injection did not effectively stop the bleeding from fundus varices. Emergency transjugular intrahepatic portosystemic shunt placement was performed as a hemostatic treatment. Portal vein puncture was successful, and portal vein radiography showed an enlarged portal vein; however, the splenic vein and gastric coronary vein were not imaged (Figure 1). Then, another abdominal enhanced CT and portal systemic vascular reconstruction were performed. The enhanced CT scan revealed an enlarged portal vein from the origin of the gastric coronary vein and an enlarged and circuitous gastric coronary vein (Figure 2A). The splenic vein did not show any flow signals in the portal venous phase (Figure 2B). The portal systemic vascular reconstruction image did not show the splenic vein or spleen signals. These data indicated that the intractable gastric variceal bleeding was not induced by alcoholic cirrhosis or portal hypertension but rather by regional portal hypertension promoted by complete splenic vein thrombosis after recurrent pancreatitis.

Taking into account the poor general condition of the patient, splenic artery embolization could have led to serious complications. Therefore, laparotomy was performed for splenectomy. After opening the abdomen, normal liver size, color and texture were observed. During surgery, we found adhesions of the spleen to organs and tissues, such as the stomach, transverse colon and kidney. Approximately two hours were spent separating the extensive adhesions.

After separation of the surrounding tissues and ligation of the splenic artery and short gastric vessels, we successfully removed the spleen and found that the pancreas was very hard to the touch. After anatomical resection of the spleen, we found that the splenic vein was completely blocked by thrombosis (Figure 3A), and the pathology results further confirmed splenic vein thrombosis (Figure 3B). One month after splenectomy, endoscopic examination revealed that the fundal varices had markedly reduced, and ultrasound examination revealed a normal-sized portal vein.

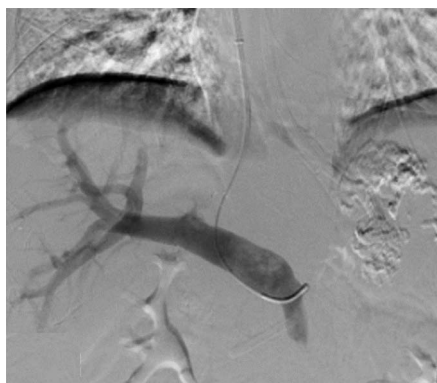

Figure 1 Direct portal vein radiography shows an enlarged portal vein; however, the splenic vein and gastric coronary vein could not be imaged.

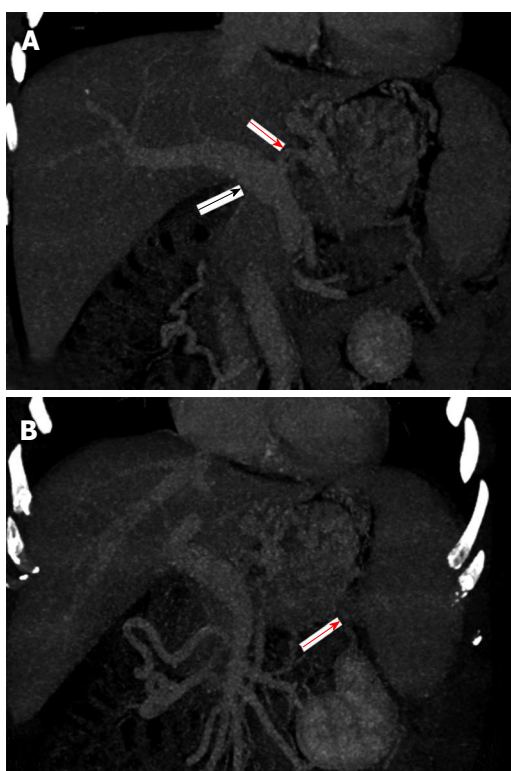


Figure 2 Enhanced computed tomography scan. A: An enlarged portal vein from the origin of the gastric coronary vein and an enlarged, circuitous gastric coronary vein; B: Splenic vein flow signals in the portal venous phase are absent.

DISCUSSION

Gastric variceal bleeding due to regional portal hypertension with splenic vein thrombosis is a severe, life-threatening condition, which is very difficult to control^[6]. Patients with splenic vein thrombosis-induced GV, who usually have normal hepatic function, are unlike those with generalized portal hypertension^[7], and their mortality risk is higher than that of patients with variceal hemorrhage due to other causes^[6,8]. A previous study has shown that as many as 37 different specific etiologies lead to splenic vein thrombosis^[9], the most common of which is pancreatitis^[10]. The rate of splenic

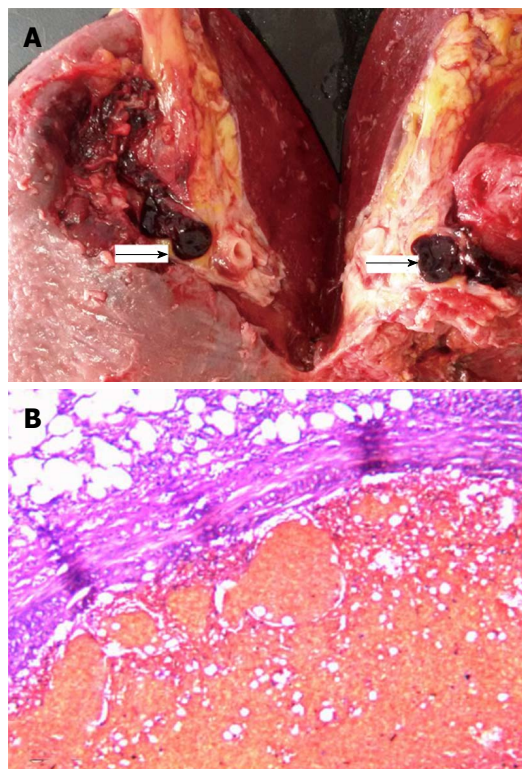


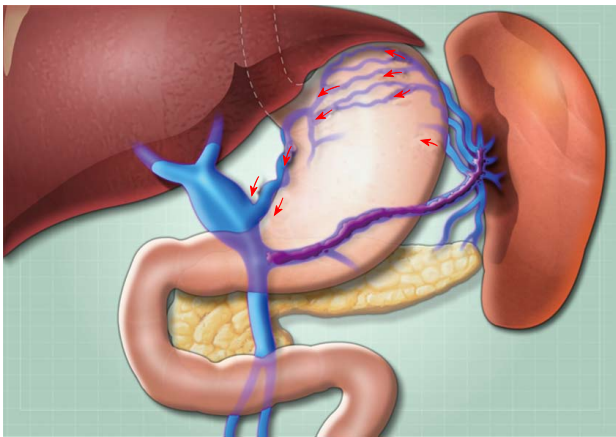
Figure 3 Anatomical resection of the spleen and hematoxylin-eosin staining. A: The splenic vein is completely blocked by thrombosis; B: The splenic vein is completely filled by thrombosis.

vein thrombosis is 7% to 20% in patients who have previously suffered from pancreatitis^[11]. Splenic vein thrombosis induced by pancreatitis was first reported by Hirschfeldt^[12]. Other causes of this disease include myeloproliferative neoplasm^[13,14], gastrointestinal, pancreatic and hepatobiliary cancers, liver cirrhosis^[15], abdominal compression and vibration^[16], pancreatic exocrine cancer^[17], factors secondary to splenic metastatic cancer^[18], minimally invasive distal pancreatectomy^[19], and splenic laceration^[20].

The splenic vein originates in a large and non-tortuous vessel from the spleen, lies inferior to the splenic artery, and runs behind the pancreatic body and tail. Therefore, the splenic vein endothelium can be damaged by inflammation in the nearby pancreatitis, which can induce splenic vein thrombosis and obstruction. Since the first report of splenic vein thrombosis induced by pancreatitis in 1920^[12], five types of pancreatitis have been identified, including chronic, familial, traumatic and autoimmune pancreatitis (Table 1), the most common of which is chronic pancreatitis^[11,21-24]. Recently, we have reported a patient with chronic pancreatitis-associated splenic vein thrombosis caused by regional portal hypertension who was treated by partial splenic artery embolization^[25]. Acute pancreatitis has been reported to be another common cause of splenic vein thrombosis^[23,26,27]. In addition, familial^[28], traumatic^[29] and autoimmune^[30] pancreatitis-induced splenic vein thrombosis and GV have been reported.

Table 1 Etiologies of pancreatitis-induced splenic vein thrombosis

Chronic pancreatitis
Longstreth <i>et al</i> ^[21] , 1971
Little <i>et al</i> ^[22] , 1981
Moossa <i>et al</i> ^[23] , 1985
Bernades <i>et al</i> ^[24] , 1992
Heider <i>et al</i> ^[11] , 2004
Tang <i>et al</i> ^[25] , 2015
Acute pancreatitis
Moossa <i>et al</i> ^[23] , 1985
Madsen <i>et al</i> ^[26] , 1986
Rogers <i>et al</i> ^[27] , 1989
Familial pancreatitis
McElroy <i>et al</i> ^[28] , 1972
Traumatic pancreatitis
Salam <i>et al</i> ^[29] , 1973
Autoimmune pancreatitis
Ishikawa <i>et al</i> ^[30] , 2012

**Figure 4** A schematic diagram of the pathophysiological and blood flow changes in this patient.

Herein, we report a case of pancreatitis-induced complete splenic vein thrombosis that led to intractable gastric variceal bleeding. This patient was first misdiagnosed with alcoholic cirrhosis-induced portal hypertension. After direct portal venography and portal vein reconstruction, the patient was finally diagnosed with regional portal hypertension induced by complete splenic vein thrombosis after pancreatitis. Normally, blood flows through the splenic artery and short gastric vein from the fundus back to the portal vein. After passing through the spleen, blood flows through the splenic vein^[31]. However, when the splenic vein is completely blocked, splenic artery blood cannot flow back through the splenic vein, which causes the spleen to become congested and enlarged. Blood must reflux to the gastric fundus vein through the short gastric vein, which results in a significant increase in gastric fundus pressure, varices, and reflux to the vena cava through the stomach, the renal vein shunt and other branches. When the pressure of the gastric fundus vein is higher than that of the portal vein, the gastric coronary vein will become enlarged, and blood will reflux to the portal

vein through the gastric coronary vein, inducing portal vein enlargement (Figure 4). Therefore, these blood rheology findings explain all of the symptoms, signs, laboratory test results and imaging data of the patient.

Antithrombotic therapy has been recommended for venous thromboembolic disease^[32–34]. An institutional (Mayo clinic) database search has revealed that a total of 2454 patients were diagnosed with acute pancreatitis from January 1996 to December 2006, with splenic vein thrombosis noted in 45 (1.8%) patients, and the use of oral anticoagulation was considered to be reasonably safe in these patients^[35]. However, for chronic pancreatitis, the incidence of splenic vein thrombosis can reach 20% to 40%^[36–38]. For complete splenic vein thrombosis patients, antithrombotic therapy may aggravate the risk of bleeding due to fundal varices. Therefore, splenic artery embolization is one of the best treatments for bleeding GV induced by splenic vein thrombosis^[14,39–42]. However, “post-embolization syndrome” is a common side effect experienced after splenic artery embolization and includes abdominal pain, fever, vomiting, and purulent infection depending on the arterial embolism size and the patient’s condition. Another study has suggested that transjugular endovascular recanalization of the splenic vein is a safe and effective therapeutic option in patients with regional portal hypertension and is not associated with an increased risk of procedure-related complications^[43]. As the condition of the patient in the present report was poor due to massive blood loss, we chose splenectomy via laparotomy, which was successful.

This paper describes a case of chronic pancreatitis-induced complete splenic vein thrombosis, which led to intractable gastric variceal bleeding. We have provided details regarding the imaging and pathology data and have described the hemodynamic characteristics. In addition, we have reviewed the disease onset and treatment methods, which may provide a reference for the clinical diagnosis and treatment of similar patients.

COMMENTS

Case characteristics

A 58-year-old man with recurrent melena lasting for over a month and vomiting lasting for 2 h.

Clinical diagnosis

Chronic pancreatitis-induced complete splenic vein thrombosis led to intractable gastric variceal bleeding.

Laboratory diagnosis

Red blood cell, $2.98 \times 10^{12}/L$; hemoglobin concentration, 67 g/L; and platelet count, $90 \times 10^9/L$.

Imaging diagnosis

Enhanced computed tomography scan revealed an enlarged portal vein from the origin of the gastric coronary vein and an enlarged and circuitous gastric coronary vein. The splenic vein did not show any flow signals in the portal venous phase.

Treatment

Laparotomy was performed for splenectomy.

Experiences and lessons

This is the first reported case for which detailed pathology and blood rheology data are available.

Peer-review

A very interesting paper.

REFERENCES

- Sarin SK**, Kumar A. Gastric varices: profile, classification, and management. *Am J Gastroenterol* 1989; **84**: 1244-1249 [PMID: 2679046]
- Huang YH**, Yeh HZ, Chen GH, Chang CS, Wu CY, Poon SK, Lien HC, Yang SS. Endoscopic treatment of bleeding gastric varices by N-butyl-2-cyanoacrylate (Histoacryl) injection: long-term efficacy and safety. *Gastrointest Endosc* 2000; **52**: 160-167 [PMID: 10922085 DOI: 10.1067/mge.2000.104976]
- Chang CJ**, Hou MC, Lin HC, Lee HS, Liao WC, Su CW, Lee SD. The safety and probable therapeutic effect of routine use of antibiotics and simultaneously treating bleeding gastric varices by using endoscopic cyanoacrylate injection and concomitant esophageal varices with banding ligation: a pilot study. *Gastrointest Endosc* 2010; **71**: 1141-1149 [PMID: 20362285 DOI: 10.1016/j.gie.2009.12.010]
- Mishra SR**, Sharma BC, Kumar A, Sarin SK. Primary prophylaxis of gastric variceal bleeding comparing cyanoacrylate injection and beta-blockers: a randomized controlled trial. *J Hepatol* 2011; **54**: 1161-1167 [PMID: 21145834 DOI: 10.1016/j.jhep.2010.09.031]
- Sharma BC**, Banka AK, Rawat A, Srivastava S. Gastric Varices in Cirrhosis versus Extrahepatic Portal Venous Obstruction and Response to Endoscopic N-Butyl-2-cyanoacrylate Injection. *J Clin Exp Hepatol* 2013; **3**: 19-23 [PMID: 25755467 DOI: 10.1016/j.jceh.2013.01.002]
- Sato T**, Yamazaki K, Toyota J, Karino Y, Ohmura T, Suga T. Gastric varices with splenic vein occlusion treated by splenic arterial embolization. *J Gastroenterol* 2000; **35**: 290-295 [PMID: 10777159 DOI: 10.1007/s005350050348]
- Trudeau W**, Prindiville T. Endoscopic injection sclerosis in bleeding gastric varices. *Gastrointest Endosc* 1986; **32**: 264-268 [PMID: 3488937 DOI: 10.1016/S0016-5107(86)71843-9]
- Köklü S**, Coban S, Yüksel O, Arhan M. Left-sided portal hypertension. *Dig Dis Sci* 2007; **52**: 1141-1149 [PMID: 17385040 DOI: 10.1007/s10620-006-9307-x]
- Lareo J**, Gea F, Abreu C, Barrios A, Garrido A, Albillos C. Isolated splenic vein thrombosis. *J Clin Nutr Gastroenterol* 1986; **1**: 221-224
- Köklü S**, Yüksel O, Arhan M, Coban S, Başar O, Yolcu OF, Uçar E, Ibiş M, Ertugrul I, Sahin B. Report of 24 left-sided portal hypertension cases: a single-center prospective cohort study. *Dig Dis Sci* 2005; **50**: 976-982 [PMID: 15906778 DOI: 10.1007/s10620-005-2674-x]
- Heider TR**, Azeem S, Galanko JA, Behrns KE. The natural history of pancreatitis-induced splenic vein thrombosis. *Ann Surg* 2004; **239**: 876-880; discussion 880-882 [PMID: 15166967 DOI: 10.1097/01.sla.0000128685.74686.1e]
- Hirschfeldt H**. Die Erkrankungen der Milz: Die Hepatolienale Erkrankungen. Berlin: Publisher, 1920: 384 [DOI: 10.1007/978-3-642-90696-1]
- De Stefano V**, Martinelli I. Splanchic vein thrombosis: clinical presentation, risk factors and treatment. *Intern. Emerg Med* 2010; **5**: 487-494 [PMID: 20532730 DOI: 10.1007/s11739-010-0413-6]
- Gianotti R**, Charles H, Hymes K, Chandarana H, Sigal S. Treatment of gastric varices with partial splenic embolization in a patient with portal vein thrombosis and a myeloproliferative disorder. *World J Gastroenterol* 2014; **20**: 14495-14499 [PMID: 25339837 DOI: 10.3748/wjg.v20.i39.14495]
- Thatipelli MR**, McBane RD, Hodge DO, Wysokinski WE. Survival and recurrence in patients with splanchic vein thromboses. *Clin Gastroenterol Hepatol* 2010; **8**: 200-205 [PMID: 19782767 DOI: 10.1016/j.cgh.2009.09.019]
- Tzur I**, Almozino-Sarafian D, Dotan E, Copel L, Gorelik O, Shteinshneider M, Cohen N. Splenic vein thrombosis following abdominal compression and vibration: a case report. *Angiology* 2008; **59**: 514-516 [PMID: 18388070 DOI: 10.1177/0003319707305403]
- Dedania N**, Agrawal N, Winter JM, Koniaris LG, Rosato EL, Sauter PK, Leiby B, Pequignot E, Yeo CJ, Lavu H. Splenic vein thrombosis is associated with an increase in pancreas-specific complications and reduced survival in patients undergoing distal pancreatectomy for pancreatic exocrine cancer. *J Gastrointest Surg* 2013; **17**: 1392-1398 [PMID: 23797883 DOI: 10.1007/s11605-013-2260-z]
- Hiraiwa K**, Morozumi K, Miyazaki H, Sotome K, Furukawa A, Nakamaru M, Tanaka Y, Iri H. Isolated splenic vein thrombosis secondary to splenic metastasis: a case report. *World J Gastroenterol* 2006; **12**: 6561-6563 [PMID: 17072993]
- Kang CM**, Chung YE, Jung MJ, Hwang HK, Choi SH, Lee WJ. Splenic vein thrombosis and pancreatic fistula after minimally invasive distal pancreatectomy. *Br J Surg* 2014; **101**: 114-119 [PMID: 24327328 DOI: 10.1002/bjs.9366]
- Nomura T**, Keira N, Urakabe Y, Naito D, Enomoto S, Nishikawa S, Matsubara H, Tatsumi T. Fatal splenic laceration in a young woman caused by idiopathic isolated splenic vein thrombosis. *Intern Med* 2009; **48**: 907-910 [PMID: 19483359 DOI: 10.2169/internalmedicine.48.1843]
- Longstreth GF**, Newcomer AD, Green PA. Extrahepatic portal hypertension caused by chronic pancreatitis. *Ann Intern Med* 1971; **75**: 903-908 [PMID: 5316320 DOI: 10.7326/0003-4819-75-6-903]
- Little AG**, Moossa AR. Gastrointestinal hemorrhage from left-sided portal hypertension. An unappreciated complication of pancreatitis. *Am J Surg* 1981; **141**: 153-158 [PMID: 6970001 DOI: 10.1016/0002-9610(81)90029-5]
- Moossa AR**, Gadd MA. Isolated splenic vein thrombosis. *World J Surg* 1985; **9**: 384-390 [PMID: 4013353 DOI: 10.1007/BF01655272]
- Bernades P**, Baetz A, Lévy P, Belghiti J, Menu Y, Fékété F. Splenic and portal venous obstruction in chronic pancreatitis. A prospective longitudinal study of a medical-surgical series of 266 patients. *Dig Dis Sci* 1992; **37**: 340-346 [PMID: 1735356 DOI: 10.1007/BF01307725]
- Tang S**, He X, Wang Z. Partial splenic artery embolization treatment of chronic pancreatitis associated splenic vein thrombosis caused regional portal hypertension: a case report. *Linchuang Gandanbing Zazhi* 2015; **31**: 771-772
- Madsen MS**, Petersen TH, Sommer H. Segmental portal hypertension. *Ann Surg* 1986; **204**: 72-77 [PMID: 3729585 DOI: 10.1097/0000658-198607000-00010]
- Rogers C**, Klatt EC. Splenic vein thrombosis in patients with acute pancreatitis. *Int J Pancreatol* 1989; **5**: 117-121 [PMID: 2600451]
- McElroy R**, Christiansen PA. Hereditary pancreatitis in a kinship associated with portal vein thrombosis. *Am J Med* 1972; **52**: 228-241 [PMID: 5062005 DOI: 10.1016/0002-9343(72)90072-1]
- Salam AA**, Warren WD, Tyras DH. Splenic vein thrombosis: a diagnosable and curable form of portal hypertension. *Surgery* 1973; **74**: 961-972 [PMID: 4542994]
- Ishikawa T**, Itoh A, Kawashima H, Ohno E, Itoh Y, Nakamura Y, Hiramatsu T, Miyahara R, Ohmiya N, Haruta J, Goto H, Hirooka Y. Peripancreatic vascular involvements of autoimmune pancreatitis. *J Gastroenterol Hepatol* 2012; **27**: 1790-1795 [PMID: 22849535 DOI: 10.1111/j.1440-1746.2012.07248.x]
- Butler JR**, Eckert GJ, Zyromski NJ, Leonardi MJ, Lillemoe KD, Howard TJ. Natural history of pancreatitis-induced splenic vein thrombosis: a systematic review and meta-analysis of its incidence and rate of gastrointestinal bleeding. *HPB (Oxford)* 2011; **13**: 839-845 [PMID: 22081918 DOI: 10.1111/j.1477-2574.2011.00375.x]

- 32 **de Franchis R.** Evolving consensus in portal hypertension. Report of the Baveno IV consensus workshop on methodology of diagnosis and therapy in portal hypertension. *J Hepatol* 2005; **43**: 167-176 [PMID: 15925423 DOI: 10.1016/j.jhep.2005.05.009]
- 33 **Condat B,** Pessione F, Helene Denninger M, Hillaire S, Valla D. Recent portal or mesenteric venous thrombosis: increased recognition and frequent recanalization on anticoagulant therapy. *Hepatology* 2000; **32**: 466-470 [PMID: 10960436 DOI: 10.1053/jhep.2000.16597]
- 34 **Kearon C,** Kahn SR, Agnelli G, Goldhaber S, Raskob GE, Comerota AJ. Antithrombotic therapy for venous thromboembolic disease: American College of Chest Physicians Evidence-Based Clinical Practice Guidelines (8th Edition). *Chest* 2008; **133**: 454S-545S [PMID: 18574272 DOI: 10.1378/chest.08-0658]
- 35 **Harris S,** Nadkarni NA, Naina HV, Vege SS. Splanchic vein thrombosis in acute pancreatitis: a single-center experience. *Pancreas* 2013; **42**: 1251-1254 [PMID: 24152951 DOI: 10.1097/MPA.0b013e3182968ff5]
- 36 **Sakorafas GH,** Sarr MG, Farley DR, Farnell MB. The significance of sinistral portal hypertension complicating chronic pancreatitis. *Am J Surg* 2000; **179**: 129-133 [PMID: 10773149 DOI: 10.1016/S0002-9610(00)00250-6]
- 37 **Weber SM,** Rikkers LF. Splenic vein thrombosis and gastrointestinal bleeding in chronic pancreatitis. *World J Surg* 2003; **27**: 1271-1274 [PMID: 14502405 DOI: 10.1007/s00268-003-7247-6]
- 38 **Agarwal AK,** Raj Kumar K, Agarwal S, Singh S. Significance of splenic vein thrombosis in chronic pancreatitis. *Am J Surg* 2008; **196**: 149-154 [PMID: 18585674 DOI: 10.1016/j.amjsurg.2007.07.039]
- 39 **Stone PA,** Phang D, Richmond B, Gill G, Campbell JE. Splenic artery embolization for the treatment of bleeding gastric varices secondary to splenic vein thrombosis. *Ann Vasc Surg* 2014; **28**: 737.e7-737.11 [PMID: 24495333]
- 40 **Sankararaman S,** Velayuthan S, Veal R, Herbst J. Severe gastric variceal bleeding successfully treated by emergency splenic artery embolization. *Pediatr Int* 2013; **55**: e42-e45 [PMID: 23782376 DOI: 10.1111/ped.12014]
- 41 **Saugel B,** Gaa J, Phillip V, Schmid RM, Huber W. Splenic artery embolization in a woman with bleeding gastric varices and splenic vein thrombosis: a case report. *J Med Case Rep* 2010; **4**: 247 [PMID: 20684784 DOI: 10.1186/1752-1947-4-247]
- 42 **Paramythiotis D,** Papavramidis TS, Giavroglou K, Potsi S, Girtovitis F, Michalopoulos A, Papadopoulos VN, Prousalidis J. Massive variceal bleeding secondary to splenic vein thrombosis successfully treated with splenic artery embolization: a case report. *J Med Case Rep* 2010; **4**: 139 [PMID: 20482817 DOI: 10.1186/1752-1947-4-139]
- 43 **Luo X,** Nie L, Wang Z, Tsao J, Tang C, Li X. Transjugular endovascular recanalization of splenic vein in patients with regional portal hypertension complicated by gastrointestinal bleeding. *Cardiovasc Intervent Radiol* 2014; **37**: 108-113 [PMID: 23636249 DOI: 10.1007/s00270-013-0625-z]

P- Reviewer: Del Chiaro M, Yoshida H

S- Editor: Yu J **L- Editor:** Wang TQ **E- Editor:** Jiao XK





Published by **Baishideng Publishing Group Inc**

8226 Regency Drive, Pleasanton, CA 94588, USA

Telephone: +1-925-223-8242

Fax: +1-925-223-8243

E-mail: bpgoffice@wjgnet.com

Help Desk: <http://www.wjgnet.com/esps/helpdesk.aspx>

<http://www.wjgnet.com>

