

World Journal of *Virology*

World J Virol 2020 May 25; 9(1): 1-4



**LETTER TO THE EDITOR**

- 1 Case of COVID-19 presenting with gastrointestinal symptoms
Kant R, Chandra L, Antony MA, Verma V

ABOUT COVER

Editorial Board Member of *World Journal of Virology*, Mahmoud El-Bendary, MD, Professor, Tropical Medicine and Hepatology, Faculty of Medicine, Mansoura University, Mansoura, Mansoura 35111, Dakahlia, Egypt

AIMS AND SCOPE

The primary aim of *World Journal of Virology* (WJV, *World J Virol*) is to provide scholars and readers from various fields of virology with a platform to publish high-quality basic and clinical research articles and communicate their research findings online.

WJV mainly publishes articles reporting research results obtained in the field of virology and covering a wide range of topics including arbovirus infections, viral bronchiolitis, central nervous system viral diseases, coinfection, DNA virus infections, viral encephalitis, viral eye infections, chronic fatigue syndrome, animal viral hepatitis, human viral hepatitis, viral meningitis, opportunistic infections, viral pneumonia, RNA virus infections, sexually transmitted diseases, viral skin diseases, slow virus diseases, tumor virus infections, viremia, and zoonoses.

INDEXING/ABSTRACTING

The *WJV* is now abstracted and indexed in PubMed, PubMed Central, China National Knowledge Infrastructure (CNKI), and Superstar Journals Database.

RESPONSIBLE EDITORS FOR THIS ISSUE

Responsible Electronic Editor: *Yan-Xia Xing*

Proofing Production Department Director: *Yun-Xiaojian Wu*

Responsible Editorial Office Director: *Jia-Ping Yan*

NAME OF JOURNAL

World Journal of Virology

ISSN

ISSN 2220-3249 (online)

LAUNCH DATE

February 12, 2012

FREQUENCY

Irregular

EDITORS-IN-CHIEF

En-Qiang Chen, Mahmoud El-Bendary

EDITORIAL BOARD MEMBERS

<https://www.wjgnet.com/2220-3249/editorialboard.htm>

PUBLICATION DATE

May 25, 2020

COPYRIGHT

© 2020 Baishideng Publishing Group Inc

INSTRUCTIONS TO AUTHORS

<https://www.wjgnet.com/bpg/gerinfo/204>

GUIDELINES FOR ETHICS DOCUMENTS

<https://www.wjgnet.com/bpg/GerInfo/287>

GUIDELINES FOR NON-NATIVE SPEAKERS OF ENGLISH

<https://www.wjgnet.com/bpg/gerinfo/240>

PUBLICATION ETHICS

<https://www.wjgnet.com/bpg/GerInfo/288>

PUBLICATION MISCONDUCT

<https://www.wjgnet.com/bpg/gerinfo/208>

ARTICLE PROCESSING CHARGE

<https://www.wjgnet.com/bpg/gerinfo/242>

STEPS FOR SUBMITTING MANUSCRIPTS

<https://www.wjgnet.com/bpg/GerInfo/239>

ONLINE SUBMISSION

<https://www.f6publishing.com>



Case of COVID-19 presenting with gastrointestinal symptoms

Ravi Kant, Lakshya Chandra, Mc Anto Antony, Vipin Verma

ORCID number: Ravi Kant (0000-0002-9599-8082); Lakshya Chandra (0000-0003-2836-5434); Mc Anto Antony (0000-0002-2232-0078); Vipin Verma (0000-0001-5370-3146).

Author contributions: Kant R and Verma V designed the outline; Kant R, Chandra L and Verma V performed the majority of writing; Kant R, Chandra L, Antony MA and Verma V wrote and edited the letter.

Conflict-of-interest statement: The authors have nothing to declare.

Open-Access: This article is an open-access article that was selected by an in-house editor and fully peer-reviewed by external reviewers. It is distributed in accordance with the Creative Commons Attribution NonCommercial (CC BY-NC 4.0) license, which permits others to distribute, remix, adapt, build upon this work non-commercially, and license their derivative works on different terms, provided the original work is properly cited and the use is non-commercial. See: <http://creativecommons.org/licenses/by-nc/4.0/>

Manuscript source: Unsolicited manuscript

Received: April 9, 2020

Peer-review started: April 9, 2020

First decision: April 18, 2020

Revised: April 19, 2020

Accepted: May 12, 2020

Article in press: May 12, 2020

Published online: May 25, 2020

P-Reviewer: Chen YD, Rajcani J, Toyoda T

S-Editor: Tang JZ

L-Editor: A

Ravi Kant, Mc Anto Antony, Division of Endocrinology, Diabetes and Metabolism, Medical University of South Carolina/AnMed Campus, Anderson, SC 29621, United States

Lakshya Chandra, Department of Medicine, Bon Secours Saint Francis Health System, Greenville, South Carolina, SC 29601, United States

Vipin Verma, Department of Medicine, Medical University of South Carolina/AnMed Campus, Anderson, SC 29621, United States

Corresponding author: Ravi Kant, MD, Affiliate Associate Professor, Doctor, Division of Endocrinology, Diabetes and Nutrition, Medical University of South Carolina/AnMed Campus, 2000 E. Greenville Street, Suite # 3100, Anderson, SC 29621, United States. kant.ravi.md@gmail.com

Abstract

Patients with coronavirus disease 2019 (COVID-19) predominantly present with the pulmonary symptoms such as fever, cough, and shortness of breath. We present a case of an 83 years old patient with COVID-19 who presented with only gastrointestinal symptoms without respiratory complaints. Our case raises the concern regarding our current lack of understanding of extrapulmonary manifestations of COVID-19. Given genetic homology between 2019 severe acute respiratory syndrome coronavirus (SARS-CoV) 2 and SARS-CoV, our case underscores the urgent need for further studies to understand the role of the gastrointestinal system in 2019 SARS-CoV-2 transmission and COVID-19 pathogenesis.

Key words: COVID-19; SARS-CoV-2; Coronavirus; Gastrointestinal; Diarrhea; Pandemic

©The Author(s) 2020. Published by Baishideng Publishing Group Inc. All rights reserved.

Core tip: We present a case of an 83 years old patient with coronavirus disease 2019 (COVID-19) who presented with only gastrointestinal symptoms without respiratory complaints. Our case raises the concern regarding our current lack of understanding of extrapulmonary manifestations of COVID-19 and underscores the urgent need for further studies to understand the role of the gastrointestinal system in 2019 severe acute respiratory syndrome coronavirus 2 transmission and COVID-19 pathogenesis.

Citation: Kant R, Chandra L, Antony MA, Verma V. Case of COVID-19 presenting with gastrointestinal symptoms. *World J Virol* 2020; 9(1): 1-4

URL: <https://www.wjnet.com/2220-3249/full/v9/i1/1.htm>

DOI: <https://dx.doi.org/10.5501/wjv.v9.i1.1>

E-Editor: Li X



TO THE EDITOR

Coronavirus disease 2019 (COVID-19) pandemic has resulted in a public health emergency unlike we have seen in generations. Patients with COVID-19 predominantly present with pulmonary symptoms such as fever, cough, and shortness of breath^[1]. We present a case of COVID-19 who presented with only gastrointestinal (GI) symptoms without any respiratory complaints.

An 83 years old African American woman with a prior history of hypertension, type-2 diabetes mellitus and chronic kidney disease presented to the emergency department with diarrhea and nausea for 3 d. The patient reported 3-5 episodes/d of watery, non-mucoid, and non-bloody diarrhea. Her GI symptoms progressively worsened warranting a visit to the emergency department. The patient denied fever, cough, chills, rigors, night sweats, headache, sore throat, rhinorrhea, dyspnea, orthopnea, recent travel or sick contact. Patient was hemodynamically stable [blood pressure 116/56 mmHg, heart rate 63 beats per minute, respiratory rate 19 per minute, temperature 100.3, and oxygen saturation (O₂ sat) 94%], but noted to have O₂ sat of 90%-91% on room air (RA) with ambulation. Labs showed normal white blood cells of 5.6 K/ μ L (Ref: 4.3 -11.1 K/ μ L) with differential showing normal lymphocyte of 25% (Ref: 13%-44%) and procalcitonin level of 0.10 ng/mL (Ref: \leq 0.50 ng/mL). On further evaluation, chest X-ray revealed evidence of multifocal opacities suspicious for pneumonia. Computed tomography chest, abdomen and pelvis showed bilateral ground glass opacities (Figure 1). No acute pathologic findings were identified in the abdomen or pelvis including colitis, diverticulitis, appendicitis or small bowel obstruction.

Patient was admitted under droplet, contact and airborne isolation. Given high suspicion of COVID-19 with superimposed community bacterial pneumonia, she was treated with intravenous ceftriaxone (1 mg daily) and azithromycin (500 mg daily) for 7 d. Meanwhile, emergent disease panel (reverse transcription polymerase chain reaction on nasopharyngeal and oropharyngeal swab) performed by the Department of Health and Environmental Control tested positive for COVID-19. During the hospital stay, patient stayed afebrile without any respiratory distress. She had a benign hospital course and was discharged after 7 d of intravenous antibiotics. Her O₂ sat was 98% on RA at rest and 94%-96% on RA with ambulation, and the GI symptoms resolved by discharge.

Our case had a unique presentation with digestive symptoms and raises the concern regarding our current lack of understanding of extrapulmonary manifestations of COVID-19. Diagnosis of COVID-19 cases with predominant extrapulmonary symptoms may be delayed as these symptoms currently may not be on the clinician's radar. A recent report on 204 patients positive for COVID-19 in Hubei, China showed that approximately 18% of patients had digestive symptoms such as abdominal pain, diarrhea or vomiting^[2]. In fact, 6 patients presented just with GI symptoms without respiratory complaints, similar to our patient. In addition, patients with GI symptoms had a longer time from illness onset to admission compared to patients without GI symptoms (8.95 ± 5.40 d *vs* 7.26 ± 4.20 d)^[2].

Genome sequences of 2019 severe acute respiratory syndrome coronavirus 2 (2019 SARS-CoV-2) have demonstrated 79% sequence identity with the severe acute respiratory syndrome-like coronaviruses (SARS-CoV) and 50% sequence identity with the Middle East respiratory syndrome-like coronaviruses^[3]. Patients infected with SARS-CoV and Middle East respiratory syndrome-like coronaviruses are known to have digestive symptoms^[4-6]. Similar to SARS-CoV, the 2019 SARS-CoV-2 uses the angiotensin-converting enzyme 2 receptors^[7]. Presence of angiotensin-converting enzyme 2 protein on small intestine erythrocytes along with epithelia of lung also supports the hypothesis that SARS-CoV-2 may shed through GI tract^[8]. Moreover, SARS-CoV-2 was present on fecal swabs and blood samples from patients positive for COVID-19^[9]. Intestinal biopsy specimens of patients with SARS have also shown active viral replication suggesting the role of fecal-oral route in SARS-CoV transmission^[10].

Several antiviral and antimicrobial drugs such as hydroxychloroquine, remdesivir, lopinavir-ritonavir, and favipiravir are currently being studied for efficacy in patients with COVID-19 but at present, no drug is approved by United States Food and Drug Administration for COVID-19^[11,12]. Supportive treatment is the mainstay of COVID-19 management. Azithromycin has been used in some protocols as adjunct therapy, and may benefit from its immunomodulatory properties and/or by preventing bacterial superinfection^[11].

Given genetic homology and other similarities between 2019 SARS-CoV2 and SARS-CoV, our case underscores the urgent need for further studies to understand the role of the GI system in 2019 SARS-CoV-2 transmission and COVID-19 pathogenesis. During these unprecedented times, where the primary focus is to screen

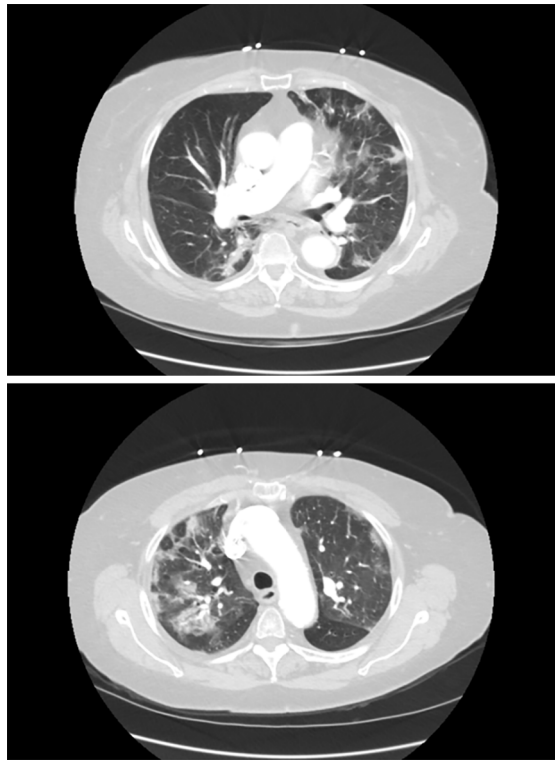


Figure 1 Computed tomography chest showing bilateral ground glass opacities.

patients with respiratory symptoms for COVID-19, our case also underscores the importance of maintaining a low threshold of suspicion for COVID-19 in patients presenting with GI symptoms which will not only help with early diagnosis and intervention but may also reduce its associated morbidity and mortality.

REFERENCES

1. Arentz M, Yim E, Klaff L, Lokhandwala S, Riedo FX, Chong M, Lee M. Characteristics and Outcomes of 21 Critically Ill Patients With COVID-19 in Washington State. *JAMA* 2020 [PMID: 32191259 DOI: 10.1001/jama.2020.4326]
2. Pan L, Mu M, Yang P, Sun Y, Wang R, Yan J, Li P, Hu B, Wang J, Hu C, Jin Y, Niu X, Ping R, Du Y, Li T, Xu G, Hu Q, Tu L. Clinical Characteristics of COVID-19 Patients With Digestive Symptoms in Hubei, China: A Descriptive, Cross-Sectional, Multicenter Study. *Am J Gastroenterol* 2020; 115: 766-773 [PMID: 32287140 DOI: 10.14309/ajg.0000000000000620]
3. Lu R, Zhao X, Li J, Niu P, Yang B, Wu H, Wang W, Song H, Huang B, Zhu N, Bi Y, Ma X, Zhan F, Wang L, Hu T, Zhou H, Hu Z, Zhou W, Zhao L, Chen J, Meng Y, Wang J, Lin Y, Yuan J, Xie Z, Ma J, Liu WJ, Wang D, Xu W, Holmes EC, Gao GF, Wu G, Chen W, Shi W, Tan W. Genomic characterisation and epidemiology of 2019 novel coronavirus: implications for virus origins and receptor binding. *Lancet* 2020; 395: 565-574 [PMID: 32007145 DOI: 10.1016/S0140-6736(20)30251-8]
4. Chiu YC, Wu KL, Chou YP, Fong TV, Tsai TL, Kuo CM, Kuo CH, Chiu KW, Liu JW, Eng HL, Jawan B, Cheng YF, Chen CL. Diarrhea in medical care workers with severe acute respiratory syndrome. *J Clin Gastroenterol* 2004; 38: 880-882 [PMID: 15492605 DOI: 10.1097/00004836-200411000-00009]
5. Assiri A, Al-Tawfiq JA, Al-Rabieah AA, Al-Rabiah FA, Al-Hajjar S, Al-Barrak A, Flemman H, Al-Nassir WN, Balkhy HH, Al-Hakeem RF, Makhdoom HQ, Zumla AI, Memish ZA. Epidemiological, demographic, and clinical characteristics of 47 cases of Middle East respiratory syndrome coronavirus disease from Saudi Arabia: a descriptive study. *Lancet Infect Dis* 2013; 13: 752-761 [PMID: 23891402 DOI: 10.1016/S1473-3099(13)70204-4]
6. Dawson P, Malik MR, Parvez F, Morse SS. What Have We Learned About Middle East Respiratory Syndrome Coronavirus Emergence in Humans? A Systematic Literature Review. *Vector Borne Zoonotic Dis* 2019; 19: 174-192 [PMID: 30676269 DOI: 10.1089/vbz.2017.2191]
7. Guo YR, Cao QD, Hong ZS, Tan YY, Chen SD, Jin HJ, Tan KS, Wang DY, Yan Y. The origin, transmission and clinical therapies on coronavirus disease 2019 (COVID-19) outbreak - an update on the status. *Mil Med Res* 2020; 7: 11 [PMID: 32169119 DOI: 10.1186/s40779-020-00240-0]
8. Hamming I, Timens W, Bulthuis ML, Lely AT, Navis G, van Goor H. Tissue distribution of ACE2 protein, the functional receptor for SARS coronavirus. A first step in understanding SARS pathogenesis. *J Pathol* 2004; 203: 631-637 [PMID: 15141377 DOI: 10.1002/path.1570]
9. Zhang W, Du RH, Li B, Zheng XS, Yang XL, Hu B, Wang YY, Xiao GF, Yan B, Shi ZL, Zhou P. Molecular and serological investigation of 2019-nCoV infected patients: implication of multiple shedding routes. *Emerg Microbes Infect* 2020; 9: 386-389 [PMID: 32065057 DOI: 10.1080/22221751.2020.1729071]
10. Leung WK, To KF, Chan PK, Chan HL, Wu AK, Lee N, Yuen KY, Sung JJ. Enteric involvement of

- severe acute respiratory syndrome-associated coronavirus infection. *Gastroenterology* 2003; **125**: 1011-1017 [PMID: 14517783 DOI: 10.1016/s0016-5085(03)01215-0]
- 11 **Smith T**, Bushek J, LeClaire A, Prosser T. COVID-19 Drug Therapy – Potential Options. Elsevier ©, 2020. Available from: http://www.aesculapseguridaddelpaciente.org.mx/alianzapsqx/docs/informacion-cientifica/clinicadiagnostico/COVID-19-Drug-Therapy_Mar-2020.pdf
 - 12 **Singhal T**. A Review of Coronavirus Disease-2019 (COVID-19). *Indian J Pediatr* 2020; **87**: 281-286 [PMID: 32166607 DOI: 10.1007/s12098-020-03263-6]



Published by Baishideng Publishing Group Inc
7041 Koll Center Parkway, Suite 160, Pleasanton, CA 94566, USA
Telephone: +1-925-3991568
E-mail: bpgoffice@wjgnet.com
Help Desk: <https://www.f6publishing.com/helpdesk>
<https://www.wjgnet.com>

