

World Journal of *Clinical Infectious Diseases*

World J Clin Infect Dis 2017 November 25; 7(4): 50-57





Editorial Board

2016-2019

The World Journal of Clinical Infectious Diseases Editorial Board consists of 284 members, representing a team of worldwide experts in infectious diseases. They are from 55 countries, including Argentina (5), Australia (8), Austria (1), Belgium (2), Bosnia and Herzegovina (1), Brazil (6), Brunei Darussalam (1), Bulgaria (1), Cameroon (1), Canada (7), China (17), Colombia (1), Costa Rica (1), Cuba (1), Denmark (2), Egypt (2), Ethiopia (1), Finland (1), France (11), Germany (3), Greece (8), Hungary (5), India (14), Iran (6), Israel (10), Italy (20), Japan (3), Jordan (1), Kosovo (1), Kuwait (1), Lebanon (3), Lithuania (1), Malawi (1), Mexico (5), Morocco (2), Netherlands (3), Nigeria (1), Pakistan (1), Peru (1), Portugal (5), Russia (1), Saudi Arabia (2), Singapore (3), South Africa (2), South Korea (5), Spain (24), Switzerland (2), Tanzania (1), Thailand (4), Tunisia (1), Turkey (5), United Arab Emirates (1), United Kingdom (10), United States (57), and Venezuela (1).

EDITORS-IN-CHIEF

Shyam Sundar, *Varanasi*
Lihua Xiao, *Atlanta*

GUEST EDITORIAL BOARD MEMBERS

Huan-Tsung Chang, *Taipei*
Jia-Ming Chang, *Taipei*
Kuo-Chin Huang, *Chiayi*
Wei-Chen Lee, *Taoyuan*
Hsiu-Jung Lo, *Miaoli*
Jin-Town Wang, *Taipei*
Deng-Chyang Wu, *Kaohsiung*
Jiunn-Jong Wu, *Tainan*

MEMBERS OF THE EDITORIAL BOARD



Argentina

Sergio O Angel, *Chascomus*
Luis A Diaz, *Córdoba*
Gustavo D Lopardo, *Vicente Lopez*
Emilio L Malchiodi, *Buenos Aires*
Victor D Rosenthal, *Buenos Aires*



Australia

David L Gordon, *South Australia*
Asad Khan, *Queensland*
Ruiting Lan, *Randwick*
John McBride, *Cairns*

David L Paterson, *Herston*
Nitin K Saksena, *Sydney*
Andrew T Slack, *Brisbane*
Thea van de Mortel, *Lismore*



Austria

Bernhard Resch, *Graz*



Belgium

Mickael Aoun, *Bruxelles*
Paul M Tulkens, *Leuven*



Bosnia and Herzegovina

Selma Uzunovic, *Zenica*



Brazil

Gerly AC Brito, *Fortaleza*
Jane Costa, *Rio de Janeiro*
Pedro A d'Azevedo, *Sao Paulo*
Ricardo Luiz D Machado, *Sao Paulo*
Leandro RR Perez, *Porto Alegre*
Maria de Nazaré C Soeiro, *Rio de Janeiro*



Brunei Darussalam

Vui H Chong, *Bandar Seri Begawan*



Bulgaria

Iva Christova, *Sofia*



Cameroon

Richard Njouom, *Yaounde*



Canada

Aranka Anema, *Vancouver*
Horacio Bach, *Vancouver*
Peter C Coyte, *Ontario*
Pavel Gershkovich, *Vancouver*
Marina Ulanova, *Thunder Bay*
Jude E Uzonna, *Winnipeg*
Jun Wang, *Halifax*



China

Xi-Tai Huang, *Tianjin*
Dong-Ming Li, *Beijing*
Xin-Yong Liu, *Jinan*
Wu-Bin Pan, *Taichang*
Kai Wang, *Jinan*
Patrick CY Woo, *Hong Kong*
Yong-Feng Yang, *Nanjing*
Chi-Yu Zhang, *Zhenjiang*
Li-Juan Zhang, *Beijing*



Colombia

Jorge E Gomez-Marin, *Armenia*

**Costa Rica**Adriano Gerardo Arguedas Mohs, *San José***Cuba**Maria G Guzman, *Havana***Denmark**Janne K Klitgaard, *Odense*
Henrik Torkil Westh, *Hvidovre***Egypt**Tarek M Diab, *Giza*
Olfat G Shaker, *Cairo***Ethiopia**Solomon A Yimer, *Oslo***Finland**Jari TJ Nuutila, *Turku***France**Hassane Adakal, *Bobo-Dioulasso*
Pascal Bigey, *Paris*
Philippe Brouqui, *Marseille*
Christophe Chevillard, *Marseille*
Raphaelé Girard, *Pierre Bénite*
Vincent Jarlier, *Paris*
Sandrine Marquet, *Marseille*
Thierry Naas, *Bicetre*
Saad Nseir, *Lille*
Philippe Seguin, *Rennes*
Muriel Vayssier-Taussat, *Maisons-Alfort***Germany**Stefan Borgmann, *Ingolstadt*
Georg Harter, *Ulm*
Matthias Imohl, *Aachen***Greece**Apostolos Beloukas, *Athens*
Alex P Betrosian, *Athens*
George L Daikos, *Athens*
Helena C Maltezou, *Athens*
Argyris S Michalopoulos, *Athens*
Maria A Moschovi, *Goudi*
George Petrikos, *Athens*
Athanassios Tragiannidis, *Thessaloniki***Hungary**László Galgoczy, *Szeged*
Ferenc Orosz, *Budapest*
Ferenc Rozgonyi, *Budapest*
Jozsef Soki, *Szeged*
Dezso P Virok, *Szeged***India**Ritesh Agarwal, *Chandigarh*
Syed I Alam, *Gwalior*
Atmaram H Bandivdekar, *Mumbai*
Runu Chakravarty, *Kolkata*
Dipshikha Chakravorty, *Bangalore*
Mamta Chawla-Sarkar, *Kolkata*
Sanjay Chhibber, *Chandigarh*
Belgode N Harish, *Pondicherry*
Triveni Krishnan, *Kolkata*
Rashmi Kumar, *Lucknow*
Mohammad Owais, *Aligarh*
Banwarilal Sarkar, *Kolkata*
Akashdeep Singh, *Ludhiana***Iran**Parissa Farnia, *Tehran*
Seyed M Jazayeri, *Tehran*
Morteza Pourahmad, *Jahrom*
Mohammad R Pourshafie, *Tehran*
Mohammad H Salari, *Tehran*
Hasan Shojaei, *Isfahan***Israel**Jacob Amir, *Petach Tikvah*
Shai Ashkenazi, *Petach Tikva*
Gadi Borkow, *Gibton*
Raul Colodner, *Afula*
Jacob M Gilad, *Tel-Aviv*
Noah Isakov, *Beer Sheva*
Michal Mandelboim, *Tel-Hashomer*
Shifra Shvarts, *Omer*
Oshri Wasserzug, *Tel-Aviv*
Pablo V Yagupsky, *Beer-Sheva***Italy**Giuseppe Barbaro, *Rome*
Paolo Bonilauri, *Reggio Emilia*
Guido Calleri, *Torino*
Mario Cruciani, *Verona*
Antonella d'Arminio Monforte, *Milan*
Silvano Esposito, *Salerno*
Marco Falcone, *Rome*
Antonio Fasanella, *Foggia*
Daniele Focosi, *Pisa*
Delia Goletti, *Roma*
Guido Grandi, *Siena*
Fabio Grizzi, *Rozzano*Giuseppe Ippolito, *Rome*
Roberto Manfredi, *Bologna*
Claudio M Mastroianni, *Rome*
Ivano Mezzaroma, *Rome*
Giuseppe Micali, *Catania*
Annamaria Passantino, *Messina*
Mariagrazia Perilli, *L'Aquila*
Patrizia Pontisso, *Padova***Japan**Emoto Masashi, *Gunma*
Toshi Nagata, *Hamamatsu*
Ryohei Yamasaki, *Tottori***Jordan**Asem A Shehabi, *Amman***Kosovo**Lul Raka, *Prishtina***Kuwait**Willias Masocha, *Safat***Lebanon**Ziad Daoud, *Tripoli*
Ghassan M Matar, *Beirut*
Sami Ramia, *Beirut***Lithuania**Gazim Bizanov, *Vilnius***Malawi**Adamson S Muula, *Zomba***Mexico**Agnes Fleury, *Mexico City*
Guadalupe García-Elorriaga, *Mexico City*
Alejandro Macias, *Mexico City*
Mussaret Zaidi, *Merida*
Roberto Zenteno-Cuevas, *Veracruz***Morocco**Redouane Abouqal, *Rabat*
Sayeh Ezzikouri, *Casablanca***Netherlands**John Hays, *Rotterdam*

Nisar A Khan, *Rotterdam*
Rogier Louwen, *Rotterdam*



Nigeria

Samuel S Taiwo, *Osogbo*



Pakistan

Muhammad Idrees, *Lahore*



Peru

Salim Mohanna, *Lima*



Portugal

Ricardo Araujo, *Porto*
Manuela Canica, *Lisboa*
Francisco Esteves, *Lisboa*
Fernando Rodrigues, *Braga*
Nuno Taveira, *Lisbon*



Russia

Alexander M Shestopalov, *Novosibirsk*



Saudi Arabia

Jaffar A Al-Tawfiq, *Dhahran*
Atef M Shibl, *Riyadh*



Singapore

Yee S Leo, *Singapore*
Laurent CS Renia, *Singapore*
Richard J Sugrue, *Singapore*



South Africa

Carolina H Pohl, *Bloemfontein*
Natasha Potgieter, *Louis Trichardt*



South Korea

Yong-Hyun Cho, *Seoul*
Sang-Ho Choi, *Seoul*
Ju-Young Chung, *Seoul*
Jung Mogg Kim, *Seoul*
Kyongmin Kim, *Suwon*



Spain

Alberto Arnedo-Pena, *Castellon*
Alfredo Berzal-Herranz, *Granada*
Vicente Boix, *Alicante*
Enrique Calderon, *Seville*
Rafael Canton, *Madrid*

Jose M Cuevas, *Valencia*
Laila Darwich, *Barcelona*
Pere Domingo, *Barcelona*
Tahia D Fernandez, *Malaga*
Lucia Gallego, *Leioa*
Adela González de la Campa, *Madrid*
Luis I Gonzalez-Granado, *Madrid*
Bruno Gonzalez-Zorn, *Madrid*
Eduardo Lopez-Collazo, *Madrid*
Miguel Marcos, *Salamanca*
Antonio T Martí, *Barcelona*
Andrés Moya, *València*
Rafael Najera, *Madrid*
Maria-Mercedes Nogueras-Mas, *Sabadell*
Jose A Oteo, *La Rioja*
Pilar Perez-Romero, *Sevilla*
Ruth G Prieto, *Alcorcon*
Eduardo Reyes, *Alcala de Henares*
Francisco Soriano, *Madrid*



Switzerland

Stephen Hawser, *Epalinges*
Andrew Hemphill, *Bern*



Tanzania

John PA Lusingu, *Tanga*



Thailand

Kosum Chansiri, *Bangkok*
Subsai Kongsangdao, *Bangkok*
Niwat Maneekarn, *Chiang Mai*
Viroj Wiwanitkit, *Bangkok*



Tunisia

Aouni Mahjoub, *Monastir*



Turkey

Oguz Karabay, *Sakarya*
Uner Kayabas, *Malatya*
Gokhan Metan, *Kayseri*
Oral Oncul, *Uskudar*
Mesut Yilmaz, *Istanbul*



United Arab Emirates

Muhammad Mukhtar, *Ras Al Khaimah*



United Kingdom

Zainab Al-Doori, *Glasgow*
David Carmena, *London*
Ronald A Dixon, *Lincoln*
Vanya A Gant, *London*
Robin Goodwin, *Coventry*
Andrew C Hayward, *London*
Laura A Hughes, *Cheshire*

Michele E Murdoch, *Herts*
Harunor Rashid, *London*
Craig W Roberts, *Glasgow*



United States

Majdi N Al-Hasan, *Lexington*
Ibne KM Ali, *Charlottesville*
Hossam M Ashour, *Detroit*
Joseph U Becker, *Palo Alto*
M Eric Benbow, *Dayton*
Eliahu Bishburg, *Newark*
Luz P Blanco, *Ann Arbor*
Robert Bucki, *Philadelphia*
Steven D Burdette, *Dayton*
Archana Chatterjee, *Omaha*
Pai-Lien Chen, *Durham*
Pawel S Ciborowski, *Omaha*
Michael Cynamon, *Syracuse*
Siddhartha Das, *El Paso*
Ralph J DiClemente, *Atlanta*
Noton K Dutta, *Baltimore*
Garth D Ehrlich, *Pittsburgh*
Michael S Firstenberg, *Akron*
Walter A Hall, *Syracuse*
Yongqun He, *Ann Arbor*
Brenda L Helms, *Plano*
Joseph U Igietsame, *Atlanta*
Mohammad K Ijaz, *Montvale*
Suresh G Joshi, *Philadelphia*
Christian Joukhadar, *Boston*
Thomas F Kresina, *Rockville*
Alain B Labrique, *Baltimore*
Shenghan Lai, *Baltimore*
Benfang Lei, *Bozeman*
Jeff G Leid, *Flagstaff*
Vladimir Leontiev, *St.Louis*
James M McMahon, *Rochester*
Geraldine M McQuillan, *Hyattsville*
Lawrence F Muscarella, *Ivyland*
Daniel Musher, *Houston*
Stella Nowicki, *Nashville*
M Jacques Nsuami, *New Orleans*
Phillipe N Nyambi, *New York*
Raymund R Razonable, *Rochester*
Anand Reddi, *Denver*
William R Schwan, *La Crosse*
Richard A Slayden, *Fort Collins*
Theodore J Standiford, *Ann Arbor*
William M Switzer, *Atlanta*
Ashutosh Tamhane, *Birmingham*
Giorgio E Tarchini, *Weston*
Carmen Taype, *New York*
Barbara Van Der Pol, *Bloomington*
Jose A Vazquez, *Detroit*
Fernando Villalta, *Nashville*
Haider J Warraich, *Boston*
Xianfu Wu, *Atlanta*
X Frank Yang, *Indianapolis*
Genyan Yang, *Atlanta*
Hong Zhang, *Rockville*
Lyna Zhang, *Atlanta*



Venezuela

Alfonso J Rodriguez-Morales, *Caracas*



CASE REPORT

- 50** Autoimmune hepatitis in human immunodeficiency virus infection: Case report and literature review

Noreña I, Morantes-Caballero JA, Garcés A, Gómez BJ, Rodríguez G, Saavedra C, Otero W

Contents

World Journal of Clinical Infectious Diseases
Volume 7 Number 4 November 25, 2017

ABOUT COVER

Editorial Board Member of *World Journal of Clinical Infectious Diseases*, Steven D Burdette, MD, Associate Professor, School of Medicine, Wright State University Boonshoft, Dayton, OH 45409, United States

AIM AND SCOPE

World Journal of Clinical Infectious Diseases (*World J Clin Infect Dis*, *WJCID*, online ISSN 2220-3176, DOI: 10.5495) is a peer-reviewed open access (OA) academic journal that aims to guide clinical practice and improve diagnostic and therapeutic skills of clinicians.

WJCID will focus on a broad spectrum of topics on infectious diseases that will cover epidemiology, immune-pathogenesis, genetic factors, host susceptibility to infection, vector control, novel approaches of treatment, molecular diagnostic and vaccines. It will provide a common stage to share the visions, new approaches, most advanced techniques, and to discuss research problems that will help everyone working in the field of various infections to exchange their views and to improve public health. *WJCID* will also focus on broad range of infections like opportunistic infections, zoonotic infections, tropical and neglected tropical diseases, emerging infections, *etc.* and following topics related to these issues: (1) Causative agents discussing various pathogens; (2) Vectors and Mode of transmission; (3) Host-pathogen interaction and immune-pathogenesis of the disease; (4) Epidemiology of the infection and vector control strategies; (5) Genetic factors covering both host and pathogen; (6) Molecular diagnostic techniques vaccines; and (7) Recent advances in cell tissue culture, lab techniques, *etc.* Various other related fields like medical microbiology, pharmacology of herbs, bioinformatics, *etc.* will be included.

We encourage authors to submit their manuscripts to *WJCID*. We will give priority to manuscripts that are supported by major national and international foundations and those that are of great basic and clinical significance.

INDEXING/ABSTRACTING

World Journal of Clinical Infectious Diseases is now indexed in China National Knowledge Infrastructure (CNKI).

FLYLEAF

I-III Editorial Board

EDITORS FOR THIS ISSUE

Responsible Assistant Editor: *Xiang Li*
Responsible Electronic Editor: *Ya-Jing Lu*
Proofing Editor-in-Chief: *Lian-Sheng Ma*

Responsible Science Editor: *Fang-Fang Ji*
Proofing Editorial Office Director: *Xiu-Xia Song*

NAME OF JOURNAL
World Journal of Clinical Infectious Diseases

ISSN
ISSN 2220-3176 (online)

LAUNCH DATE
December 30, 2011

FREQUENCY
Quarterly

EDITORS-IN-CHIEF
Shyam Sundar, MD, FRCP (London), FAMS, FNA Sc, FASc, FNA, Professor, Department of Medicine, Institute of Medical Sciences, Banaras Hindu University, Varanasi 221005, India

Lihua Xiao, DVM, PhD, Senior Scientist, Division of Foodborne, Waterborne, and Environmental Diseases, National Center for Emerging and Zoonotic Infectious Diseases, Centers for Disease Control and Prevention, Bldg 23, Rm 9-168, MS D66, 1600 Clifton Rd, Atlanta, GA 30333, United States

EDITORIAL BOARD MEMBERS
All editorial board members resources online at <http://www.wjgnet.com/2220-3176/editorialboard.htm>

EDITORIAL OFFICE
Fang-Fang Ji, Director
World Journal of Clinical Infectious Diseases
Baishideng Publishing Group Inc
7901 Stoneridge Drive, Suite 501,
Pleasanton, CA 94588, USA
Telephone: +1-925-2238242
Fax: +1-925-2238243
E-mail: editorialoffice@wjgnet.com
Help Desk: <http://www.f6publishing.com/helpdesk>
<http://www.wjgnet.com>

PUBLISHER
Baishideng Publishing Group Inc
7901 Stoneridge Drive, Suite 501,
Pleasanton, CA 94588, USA
Telephone: +1-925-2238242
Fax: +1-925-2238243
E-mail: bpgoffice@wjgnet.com
Help Desk: <http://www.f6publishing.com/helpdesk>
<http://www.wjgnet.com>

PUBLICATION DATE
November 25, 2017

COPYRIGHT
© 2017 Baishideng Publishing Group Inc. Articles published by this Open-Access journal are distributed under the terms of the Creative Commons Attribution Non-commercial License, which permits use, distribution, and reproduction in any medium, provided the original work is properly cited, the use is non commercial and is otherwise in compliance with the license.

SPECIAL STATEMENT
All articles published in journals owned by the Baishideng Publishing Group (BPG) represent the views and opinions of their authors, and not the views, opinions or policies of the BPG, except where otherwise explicitly indicated.

INSTRUCTIONS TO AUTHORS
<http://www.wjgnet.com/bpg/geninfo/204>

ONLINE SUBMISSION
<http://www.f6publishing.com>

Autoimmune hepatitis in human immunodeficiency virus infection: Case report and literature review

Ivan Noreña, Jairo A Morantes-Caballero, Andrés Garcés, Brian José Gómez, Gabriel Rodríguez, Carlos Saavedra, William Otero

Ivan Noreña, Gabriel Rodríguez, Carlos Saavedra, Infectious Diseases Section, Department of Internal Medicine, Universidad Nacional de Colombia and Hospital Universitario Nacional de Colombia, Bogotá 11321, Colombia

Jairo A Morantes-Caballero, Andrés Garcés, Brian José Gómez, Department of Internal Medicine, Universidad Nacional de Colombia and Hospital Universitario Nacional de Colombia, Bogotá 11321, Colombia

William Otero, Gastroenterology Section, Department of Internal Medicine, Universidad Nacional de Colombia and Hospital Universitario Nacional de Colombia, Bogotá 11321, Colombia

ORCID number: Ivan Noreña (0000-0001-5092-2589); Jairo A Morantes-Caballero (0000-0001-5273-0580); Andrés Garcés (0000-0001-7577-1326); Brian José Gómez (0000-0002-1896-1016); Gabriel Rodríguez (0000-0003-3929-0933); Carlos Saavedra (0000-0003-0068-6631); William Otero (0000-0002-6825-9014).

Author contributions: All authors contributed to the acquisition of data, writing, and revision of this manuscript.

Institutional review board statement: This case report was exempt from the Institutional Review Board standards at Universidad Nacional de Colombia.

Informed consent statement: The patient gave his written informed consent authorizing use and disclosure of his protected health information.

Conflict-of-interest statement: All the authors have no conflicts of interests to declare.

Open-Access: This article is an open-access article which was selected by an in-house editor and fully peer-reviewed by external reviewers. It is distributed in accordance with the Creative Commons Attribution Non Commercial (CC BY-NC 4.0) license, which permits others to distribute, remix, adapt, build upon this work non-commercially, and license their derivative works on different terms, provided the original work is properly cited and the use is non-commercial. See: <http://creativecommons.org/licenses/by-nc/4.0/>

Manuscript source: Unsolicited manuscript

Correspondence to: Jairo A Morantes-Caballero, Professor of Internal Medicine I, Department of Internal Medicine, Universidad Nacional de Colombia and Hospital Universitario Nacional de Colombia, Carrera 30 No. 45-03. Facultad de Medicina, Edificio 471, Oficina 510, Bogotá 111321, Colombia. jamorantesc@unal.edu.co
Telephone: +57-1-3165000
Fax: +57-1-3165000

Received: June 12, 2017

Peer-review started: June 15, 2017

First decision: July 20, 2017

Revised: August 2, 2017

Accepted: September 12, 2017

Article in press: September 13, 2017

Published online: November 25, 2017

Abstract

The infection due to human immunodeficiency virus (HIV) is characterized by the progressive reduction of CD4⁺ T lymphocytes and the compromise of other cell lines of the immune system, resulting in immunosuppression. In this context, autoimmune diseases could be considered contradictory, however, cases of autoimmune diseases during this infection have been described, including autoimmune hepatitis (AIH), which is uncommon and has few case reports within medical literature, none of them from Latin America. In this case report where a patient with an HIV infection on combined antiretroviral treatment developed acute elevation of transaminases, hyperbilirubinemia, and deterioration in hepatic synthetic function. Although initially an antiretroviral drug-induced liver injury was suspected, during the study a diagnosis of autoimmune hepatitis was proven, which required treatment with corticosteroid and azathioprine, obtaining a satisfactory response and managing to continue the

antiretroviral therapy. Autoimmune diseases in HIV infection must be taken into account. In the case of hepatitis in patients with HIV on antiretroviral treatment, the differentiation between viral hepatitis caused by autoimmune diseases or medications is essential to establish an adequate treatment, and avoid the suspension of the antiretroviral therapy.

Key words: Autoimmunity; Autoimmune hepatitis; Human immunodeficiency virus; Anti-human immunodeficiency virus agents; Drug-induced liver injury

© **The Author(s) 2017.** Published by Baishideng Publishing Group Inc. All rights reserved.

Core tip: In the combined antiretroviral therapy era, human immunodeficiency virus (HIV) infection can show diverse manifestations others than infections, been autoimmunity a paradoxical but well described phenomena in this scenario. The objective of this case report is to illustrate a rare condition as autoimmune hepatitis in HIV infected patients on therapy, with an additional literature review, to help clinicians in the approach of this disease and the differentiation with drug induced liver injury related to antiretroviral therapy.

Noreña I, Morantes-Caballero JA, Garcés A, Gómez BJ, Rodríguez G, Saavedra C, Otero W. Autoimmune hepatitis in human immunodeficiency virus infection: Case report and literature review. *World J Clin Infect Dis* 2017; 7(4): 50-57 Available from: URL: <http://www.wjgnet.com/2220-3176/full/v7/i4/50.htm> DOI: <http://dx.doi.org/10.5495/wjcid.v7.i4.50>

INTRODUCTION

The global incidence of infection due to human immunodeficiency virus (HIV) reached its peak in 1997. Since then it has remained relatively constant. However, the prevalence has increased as the survival rate has improved thanks to the combination antiretroviral therapy (cART)^[1]. With these therapies there is a reduction of the mortality as well as the risk of developing severe events related to the acquired immune deficiency syndrome (AIDS) in 57% of cases, regardless of age, gender and CD4⁺ T lymphocyte count^[1,2], and constitutes the most effective strategy for preventing onwards HIV-1 infections^[3]. The early onset of therapy results in better outcomes for patients, even with an advanced disease^[2]. In 2%-18% of patients, treatment must be discontinued due to adverse effects, especially in the liver, preventing patients to benefit from this treatment^[4]. Drug induced liver injury (DILI) manifests itself through hepatitis and an increase of the aminotransferases, making it indistinguishable from any other hepatitis^[5].

HIV affects the CD4⁺ lymphocytes and alters other cell lines of the innate immune system (macrophages, monocytes and dendritic cells)^[6]. This can lead to

autoimmune diseases^[5-7]. So far, few cases have been published of HIV/AIDS patients with concomitant autoimmune diseases, such as vasculitis, systemic lupus erythematosus, psoriasis, Graves' disease, and less commonly, autoimmune hepatitis (AIH)^[5-9]. After reviewing the literature, there were only 22 cases of autoimmune hepatitis described in patients with HIV, in the described cases the CD4⁺ lymphocyte count was above 100 cells/mm³, and was initially considered as liver toxicity caused as a side effect of the antiretroviral therapy^[10-18]. Taking into account the little information on these two entities occurring simultaneously, the case of a patient with HIV, who, in the course of their disease, developed AIH, is presented.

CASE REPORT

A 26-year-old male, student by occupation, who due to a self-suspicion screening for syphilis was diagnosed with a 2-year HIV infection; he was infected by a former partner in an unprotected man-man relation. In addition, he had a history of intravenous drug use, and no family history was identified. The initial study found an HIV viral load of 179488 copies/mL and a CD4⁺ T lymphocyte count of 298 cells/mm³ and CD8⁺ of 2067 cells/mm³. The complete blood count and liver and kidney profiles were normal. The serology for hepatitis A, B and C were negative, as well as the tuberculin test and the serology for syphilis. No opportunistic infections were documented. Treatment was started using Efavirenz/Tenofovir disoproxil fumarate/Emtricitabine, having a good tolerance and achieving a lower HIV viral load and satisfactory CD4⁺ T lymphocyte recovery. One year after starting the treatment, in a follow-up appointment clinical hypothyroidism of an autoimmune etiology was documented (anti-microsomal antibodies, anti-thyroglobulin and positive anti-thyroid peroxidase), and treatment with levothyroxine was started.

Several months later he was admitted to the emergency room due to jaundice. Hyperbilirubinemia (> 15 mg/dL) was found, with a predominance of direct bilirubin, severe elevation of transaminases (> 2000 IU/L), prolongation of the prothrombin time INR (1.95), and a discrete increase of alkaline phosphatase and gamma glutamyl transferase. Among other differential diagnostics, hepatotoxicity by cART was suspected, and this therapy was immediately discontinued. During hospitalization, the serology for hepatotropic viruses was negative (A, B, C and E), viral loads for virus B, C, Epstein Bar (EBV) and cytomegalovirus (CMV) were undetectable. The hepato-biliary ultrasound and portal doppler were normal. The antinuclear antibodies were positive 1:160 dilutions, with mottled pattern, and negative anti-mitochondrial and anti-muscle antibodies. High levels of immunoglobulin G were found. A liver biopsy was performed, which reported a lymphoplasmacytic inflammatory infiltration with eosinophils and severe interface activity, hepatocytes with peri-central inflammation and focal necrosis ("compatible with

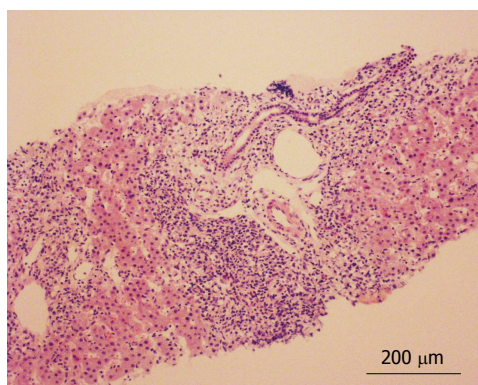


Figure 1 Histologic findings. Histological section, H and E staining (scale bar $\times 10$). Liver fragment with the presence of abundant inflammatory lymphoplasmacytic infiltrate with eosinophils and severe interface activity.

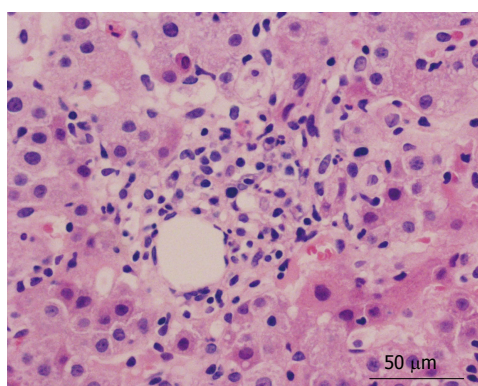


Figure 2 Histologic findings. Histological section H and E staining (scale bar $\times 40$). Presence of lymphoplasmacytic infiltrate with eosinophils and hepatocytes with pericentral fibrosis inflammation.

autoimmune hepatitis”) (Figures 1 and 2). Treatment with oral prednisolone 1 mg/kg per day was started, with a significant improvement and a quick normalization of amino transferases and bilirubin, and was discharged without restarting antiretroviral therapy.

As an outpatient, there was a gradual reduction of the prednisolone dose, until leaving a minimum dose of 10 mg/qd. With normal liver profile, cART treatment was restarted, replacing efavirenz with raltegravir and continuing Tenofovir disoproxil fumarate/Emtricitabine. A month later, the patient went again to the emergency room for recurrence of jaundice; increased serum transaminase levels greater than 2000 mg/dL were documented as well as bilirubin of 18 mg/dL at the expense of the direct bilirubin and the prolongation of prothrombin time and INR. He was hospitalized, cART therapy was once again suspended and doses of prednisolone of 1 mg/kg qd, were started, adding Azathioprine 25 mg/qd, and achieving a progressive reduction of transaminase and bilirubin. There was confusion to determine if the worsening of the hepatitis was due to the decrease of prednisolone (due to autoimmune hepatitis) or when the cART started (due to DILI). A Medical Board was held between the services of gastroenterology, internal medicine and

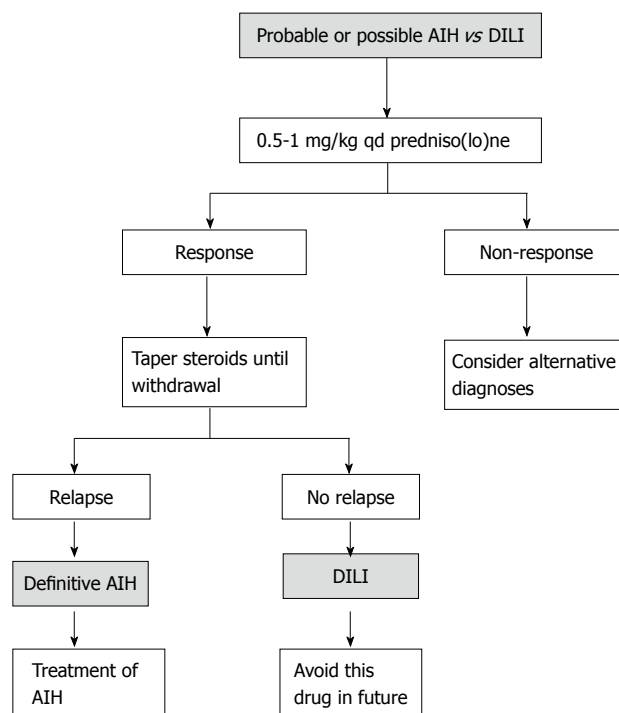


Figure 3 Diagnostic algorithm suggested. Diagnostic algorithm suggested to differentiate between autoimmune hepatitis (AIH) of drug-induced liver injury (DILI). Following the suspension of the steroid, a long-term follow-up is recommended (6 mo to 3 year) so as not to lose a late relapse of autoimmune hepatitis. Adapted from EASL Clinical Practice Guidelines: Autoimmune hepatitis, 2015.

infectious diseases, and based on the current guidelines for the diagnosis of autoimmune hepatitis and their differentiation with hepatitis due to medications (Table 1 and Figure 3), autoimmune hepatitis was defined as the definitive diagnosis^[19]. To completely rule out DILI, in a hospital environment, antiretroviral therapy was restarted and the liver profile monitored, which continued to improve until it was normal and the patient discharged.

After six months of follow-up, the patient was asymptomatic, receiving maintenance therapy for AIH only with azathioprine 100 mg/qd, HIV treatment and replacement hormone therapy with levothyroxine. The liver profile has remained unchanged. Figure 4, shows the evolution of the liver profile before and during treatment.

DISCUSSION

A case of autoimmune hepatitis in a patient with HIV infection has been presented. The coexistence of these diseases is rare: Three independent reviewers conducted the literature search in different electronic databases (PubMed, Science Direct, EBSCO and ProQuest), the search terms used were a combination of keywords and MeSH terms and included “HIV”, “AIDS”, “Human immunodeficiency virus”, “Autoimmune disease” “Autoimmunity”, “Autoimmune Hepatitis”, “Anti-HIV Agents”, “Anti-Retroviral Therapy” and “Drug-

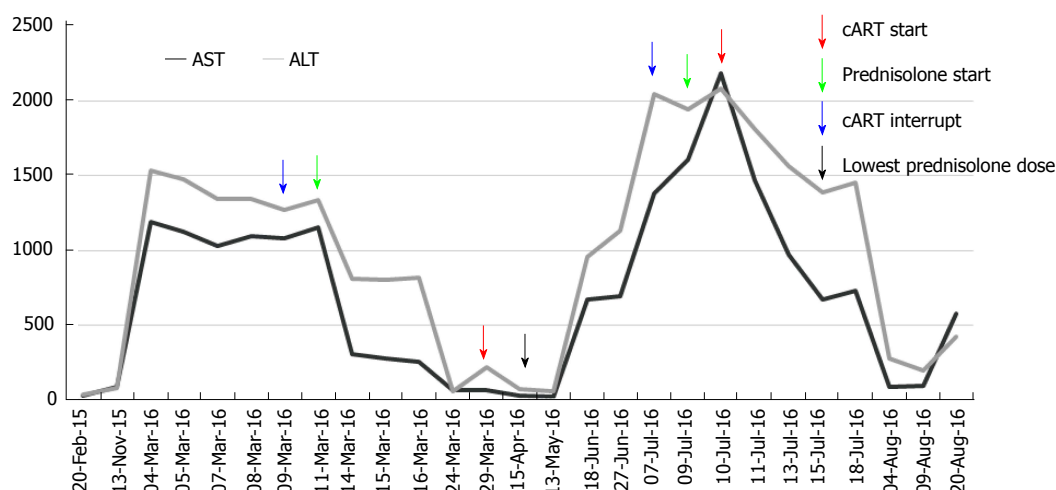


Figure 4 Transaminase values during follow-up. Aspartate transaminase (AST) and alanine transaminase (ALT) values (U/L) and their relationship with the interventions carried out and date (DD/MM): At the start of the follow-up, the patient was already receiving antiretroviral therapy, in the first interventions there is some confusion that does not allow to differentiate whether the decrease in serum transaminase levels was due to the onset of immunosuppressive therapy or the interruption of the antiretroviral therapy; also there is no indication to show if the second peak elevation of transaminases was due to the resumption of the antiretroviral therapy or due to the decrease in the dose of immunosuppressive therapy. In the end, it may be noted that, although the antiretroviral therapy was reset, the decline of transaminases continued with the immunosuppressive therapy, which helped to confirm the diagnosis of autoimmune hepatitis. cART: Combination antiretroviral therapy.

Table 1 Simplified diagnostic criteria for autoimmune hepatitis, adapted from EASL Clinical Practice Guidelines: Autoimmune hepatitis, 2015

Parameter	Discriminator	Score
ANA or ASMA ⁺	≥ 1:40	1
ANA or ASMA ⁺	≥ 1:80	2
ANA or LKM ⁺	≥ 1:40	2
ANA or SLA/LP ⁺	Any title	2
IgG or gamma globulins	> ULN	1
	> 1.1 × ULN	2
Liver biopsy	Compatible with AIH	1
	Typical AIH	2
	Atypical	0
Absence of viral hepatitis	No	0
	Yes	2

Definitive autoimmune hepatitis ≥ 7; probable autoimmune hepatitis ≥ 6. Typical liver biopsy for autoimmune hepatitis: Each one of the following characteristics must be present: Interface hepatitis, lymphocytic/lymphoplasmacytic infiltrates in the portal tracts, and extending toward the lobes, emperipolesis (active penetration by a cell within another cell), hepatocyte rosettes formations. Liver biopsy consistent with autoimmune hepatitis: Chronic hepatitis with lymphoplasmacytic infiltrate without all the characteristics considered typical. Atypical liver biopsy: Signs of another diagnosis. ANA: Anti-nuclear antibodies; ASMA: Anti-smooth muscle antibodies; LKM: Liver kidney microsomal antibodies; SLA/LP: Antibodies to soluble liver antigen/pancreas; IgG: Immunoglobulin G; ULN: Upper limit of normal; AIH: Autoimmune hepatitis.

Induced Liver Injury” in the title, abstract, or keywords with no limit in dates, types of publication or language. Nine reports with only 22 cases of patients with both entities were found, none of them described in Latin America^[10-18], their characteristics can be seen in Table 2. However, in patients with HIV, AIH can be under-diagnosed because of the complexity of the diagnosis and the confounding factors present in patients with HIV

(adverse effects to medications, hidden viral hepatitis, opportunistic infections, neoplasms)^[14,16,20].

The exact mechanisms by which patients with HIV may present AIH are unknown. However, an HIV infection is related to various autoimmunity phenomena^[5,9]. The direct damage caused by the virus, the molecular mimicry, the deregulation of T/B cells, the generation of immune complexes and auto-antibodies can trigger damage to its own tissues^[8,21]. AIH stands out due to the presence of autoreactive CD4⁺ and CD8⁺ T lymphocytes, and a cellular response mediated by antibodies with a particular increase in the Th17 subtype and IL17 release. This can be silent in stages of deep immunosuppression, with similar clinical and paraclinical reactivations similar to the immune reconstitution inflammatory syndrome (IRIS-like) that occurs with the immunological recovery associated with the effective antiretroviral therapy^[18]. Four immunological stages have been described in HIV infection^[9,10], the acute infection-latency (stage I - II) stage and the immune restoration related to antiretroviral therapy (stage IV) are the most likely to develop autoimmune disorders, furthermore, some disorders mediated by CD8⁺ cytotoxicity are present in the AIDS phase (stage III)^[8].

Based on the hypotheses set forth, it is considered that, in the case described above, the immune restoration by antiretroviral therapy, in addition to the predisposition to autoimmune disorders, were the triggers of the hepatitis, the thrombocytopenia, and Hashimoto's thyroiditis. This is consistent with the reports described in literature that supports the association between AIH and other autoimmune diseases, mainly Hashimoto's thyroiditis^[14].

The AIH is a disease common in women, however, it can occur in males, as has been reported in other

Table 2 Clinical characteristics of the cases reported

Author	Vasilios	Wan	Daas	Coriat	Puius	O'Leary	Hagel	Cazanave	Murunga
Patients reported (n)	1	4	1	1	3	1	1	1	9
Age (min/max) (yr)	38	49-56	42	48	29-65	44	52	43	23-45
Gender (M/F)	M	1-3	F	F	1-3	F	M	F	1-8
CD4 ⁺ cell count (cells/ μ L) (min/max)	216	174-357	157	250	200-259	269	641	500	253-876
HIV viral load at presentation (min/max) (copies/mL)	81000	< 50-232734	120000	No data	< 75-8687	< 50	UD	< 1000	UD-8
AST (min/max) (IU/L)	120	45-186	1526	No data	20-500	NO DATA	343	No data	13-34
ALT (min/max) (IU/L)	274	45-167	777	355	12-641	26-940	192	500	10-39
cART	Z, L, Nelfinavir	No data	F, T, Etravirine	R, E, Atazanavir	L (2), Z, E (3), F (1), T (1), stavudine	T, F, E	Didanosine, stavudine, E	L, Stavudine, E	E (7) F (6) T (8) L (3) N (1) Z (1) L/R (1)
Positive autoantibodies (n) dils	ANA 1:320 ASMA 1:40	ANA 1:20-40 ASMA(1)	ANA: 1:1280 ASMA(-)	ANA: 1:80 LKM: 1:320	ANA (2) 1:80-640 ASMA (1)	ANA 1:160	ANA: 1:2560 ASMA: 1: 4000	ANA: 1:8000 ASMA: 1: 4000	ANA (4), ASMA (6), ALKM (1)
Immunoglobulin G (g/L)	29.25	639-2020	46	30	3050-7500	2640	39	Normal	16.5-55.2
Fibrosis	No	No	Yes	No	Yes	No	No	Yes	Yes
International AIH group score (min/max)	15	10-18	19	No data	10-15	22	15	No data	12-20
Treatment	No data	Prednisolone (4) Azathioprine (3)	Prednisone	Prednisolone	Prednisolone, Azathioprine	Prednisolone, Azathioprine	Prednisolone	Prednisolone, Azathioprine	Prednisolone
Publication Year	2005	2009	2011	2008	2008	2008	2012	2006	2016
Ref.	[10]	[11]	[12]	[13]	[14]	[15]	[16]	[17]	[18]

M: Male; F: Female; UD: Undetectable; ARV: Antiretroviral therapy; L: Lamivudine; E: Efavirenz; F: Emtricitabine (FTC); L/R: Lopinavir/Ritonavir; T: Tenofovir disoproxil fumarate; N: Nevirapine; Z: Zidovudine; ANA: Anti-nuclear antibodies; ASMA: Anti-smooth muscle antibodies; ALKM: Anti-liver kidney microsomal antibodies.

cases (Table 2), and is characterized by an injury with hepatocellular pattern, circulating autoantibodies (anti-nuclear, anti-smooth muscle, or anti-microsomal liver-kidney), elevated levels of immunoglobulin G and a consistent liver biopsy. Histologically, there are characteristic changes (non pathognomonic) that include interface hepatitis, plasmacytic infiltration and regenerative hepatocyte rosettes^[14].

The diagnosis is established by combining criteria and discarding other entities that cause hepatitis (Table 2)^[17,19]. The acute case this patient developed occurs only in 25% of AIH, and makes diagnosis difficult, being that the negativity of the anti-smooth muscle antibodies is frequent^[17]. In this patient, the diagnosis of AIH was achieved by the combination of clinical, paraclinical and histological findings, the good response to immunomodulatory therapy and the exclusion of other causes.

Once there is suspicion of an AIH diagnosis in a patient with HIV, they should be treated in a similar manner to immune competent patients. The first line includes prednisone or prednisolone (0.5-1 mg/kg per

day), and azathioprine (1-2 mg/kg per day), gradually decreasing steroid doses and continuing maintenance treatment based on azathioprine. It is essential to continue antiretroviral therapy^[19].

As in this case, in all reported AIH and HIV cases in literature, the development of hepatitis generated a suspicion of toxicity caused by antiretroviral therapy. In the recent AIH guide^[19], a protocol was proposed in order to differentiate it from DILI (Figure 3). Typically, the antiretroviral therapy has a pattern of hepatocellular or cytolytic injury^[13,14,22]. The most common histologic findings in hepatotoxicity related to drugs are micro-vesicular steatosis, acute hepatitis, eosinophilic infiltration and cholestatic injury^[23]. DILI associated with antiretroviral therapy is a major problem; some of the nucleoside reverse transcriptase inhibitors (zidovudine, didanosine, stavudine, abacavir) are associated with mitochondrial toxicity and hepatic steatosis. The non-nucleoside inhibitors, such as Efavirenz and Nevirapine are associated with an increase of liver enzymes, and the latter to hypersensitivity reactions. Protease inhibitors (Indinavir, Saquinavir, Nelfinavir, Ritonavir, Lopinavir-

ritonavir, Fosamprenavir, Atazanavir and Tipranavir) are associated with an increase of transaminases, and some, such as Indinavir and Atazanavir to indirect hyperbilirubinemia^[24].

Upon suspicion of DILI, suspicious medication should be removed and the liver profile monitored until recovery, later each potentially involved medication reapplied. There are frequent difficulties in identifying the medications that are responsible, since several suspects can coexist, as happens with antituberculosis drugs (Rifampin, Isoniazid, Pyrazinamide), antiretroviral drugs (Efavirenz, Nevirapine, protease inhibitors) and other therapies such as Trimetoprim-sulfamethoxazole. If necessary, an attempt should be made to reintroduce the medications, avoiding the more suspicious agent, as there is a possibility of DILI with greater severity^[25].

This is a case in point that does not fully represent the behavior of the autoimmune hepatitis in HIV patients. Therefore, more studies are needed in this population in order to achieve a better understanding of these illnesses.

In conclusion, autoimmune diseases should be taken into consideration in patients with HIV infection, especially those who receive cART therapy, as the immunological recovery can be unleashing them. Likewise, for patients with HIV who show elevated aminotransferase levels, autoimmune hepatitis should be taken into account as one of the possible causes and perform a diagnostic approach to differentiate it from other etiologies. This allows the appropriate treatment and avoids the prolonged suspension of antiretrovirals, and the complications arising from poor virologic control.

ARTICLE HIGHLIGHTS

Case characteristics

A 26-year-old male, diagnosed with human immunodeficiency virus (HIV) infection and treated with Efavirenz/Tenofovir disoproxil fumarate/Emtricitabine, was admitted to the emergency room due to jaundice, anti-retroviral treatment was suspended.

Clinical diagnosis

Jaundice without right upper quadrant pain or hepatomegaly.

Differential diagnosis

Drug-induced liver injury, viral hepatitis, alcoholic liver disease, neoplasm, acquired immune deficiency syndrome cholangiopathy.

Laboratory diagnosis

Hyperbilirubinemia with a predominance of direct bilirubin, severe elevation of transaminases and prolongation of the prothrombin time. The serology for hepatotropic viruses was negative (A, B, C and E), viral loads for virus B viral hepatitis, C viral hepatitis, Epstein Bar and cytomegalovirus were undetectable. The antinuclear antibodies were positive with mottled pattern, negative anti-mitochondrial and anti-muscle antibodies and high levels of immunoglobulin G.

Imaging diagnosis

The hepato-biliary ultrasound and portal doppler were normal.

Pathological diagnosis

Lymphoplasmacytic inflammatory infiltration with eosinophils and severe

interface activity, hepatocytes with peri-central inflammation and focal necrosis ("compatible with autoimmune hepatitis").

Treatment

Prednisolone of 1 mg/kg per day following tapered doses, Azathioprine 100 mg/qd and cART (Tenofovir disoproxil fumarate/Emtricitabine and Raltegravir).

Related reports

After literature search, nine reports with only 22 cases of patients with both entities were found, none of them described in Latin America.

Term explanation

Autoimmune hepatitis is a chronic inflammation of the liver of unknown cause, pathogenesis includes environmental triggers, failure of immune tolerance mechanisms, and a genetic predisposition that induce a T cell-mediated immune attack characterized with continuing hepatocellular necroinflammatory and fibrotic process. The diagnosis is based on histologic abnormalities, clinical and laboratory findings, abnormal levels of immunoglobulin G, and one or more characteristic autoantibodies.

Experiences and lessons

Autoimmunity in patients with HIV infection on cART is uncommon, nevertheless in some clinical scenarios should be considered. The differentiation among autoimmune hepatitis (AIH), drug induced liver injury or infectious hepatitis can be challenging and needs an extensive work-up.

ACKNOWLEDGMENTS

To Jacqueline Mugnier MD pathologist of the Fundación Cardioinfantil (Bogotá, Colombia) for the histopathology images of the case, and to Ximena Castaneda MD of the Infectious Disease service of the Fundación Cardioinfantil (Bogotá, Colombia) for helping us to collect part of the information from the first hospitalization of the case.

REFERENCES

- 1 **GBD 2015 HIV Collaborators**, Wang H, Wolock TM, Carter A, Nguyen G, Kyu HH, Gakidou E, Hay SI, Mills EJ, Trickey A, Msemburi W, Coates MM, Mooney MD, Fraser MS, Sligar A, Salomon J, Larson HJ, Friedman J, Abajobir AA, Abate KH, Abbas KM, Razek MM, Abd-Allah F, Abdulle AM, Abera SF, Abubakar I, Abu-Raddad LJ, Abu-Rmeileh NM, Abyu GY, Adebisi AO, Adedeji IA, Adelekan AL, Adofu K, Adou AK, Ajala ON, Akinyemiju TF, Akseer N, Lami FH, Al-Aly Z, Alam K, Alam NK, Alasfoor D, Aldahri SF, Aldridge RW, Alegretti MA, Aleman AV, Alemu ZA, Alfonso-Cristancho R, Ali R, Alkerwi A, Alla F, Mohammad R, Al-Raddadi S, Alsharif U, Alvarez E, Alvis-Guzman N, Amare AT, Amberbir A, Amegah AK, Ammar W, Amrock SM, Antonio CA, Anwari P, Ärnlöv J, Artaman A, Asayesh H, Asghar RJ, Assadi R, Atique S, Atkins LS, Avokpaho EF, Awasthi A, Quintanilla BP, Bacha U, Badawi A, Barac A, Bärnighausen T, Basu A, Bayou TA, Bayou YT, Bazargan-Hejazi S, Beardsley J, Bedi N, Bennett DA, Bensenor IM, Betsu BD, Beyene AS, Bhatia E, Bhutta ZA, Biadgilign S, Bikbov B, Birlik SM, Bisanzio D, Brainin M, Brazinova A, Breitborde NJ, Brown A, Burch M, Butt ZA, Campuzano JC, Cárdenas R, Carrero JJ, Castañeda-Orjuela CA, Rivas JC, Catalá-López F, Chang HY, Chang JC, Chavan L, Chen W, Chiang PP, Chibalabala M, Chisumpa VH, Choi JY, Christopher DJ, Ciobanu LG, Cooper C, Dahiru T, Damtew SA, Dandona L, Dandona R, das Neves J, de Jager P, De Leo D, Degenhardt L, Dellavalle RP, Deribe K, Deribew A, Des Jarlais DC, Dharmaratne SD, Ding EL, Doshi PP, Driscoll TR, Dubey M, Elshrek YM, Elyazar I, Endries AY, Ermakov SP, Eshrati B, Esteghamati A, Faghmous ID, Farinha CS, Faro A, Farvid MS, Farzadfar F, Fereshtehnejad SM, Fernandes JC, Fischer F, Fitchett JR, Foigt N, Fullman N, Fürst T, Gankpé FG, Gebre T, Gebremedhin

- AT, Gebru AA, Geleijnse JM, Gessner BD, Gething PW, Ghiwot TT, Giroud M, Gishu MD, Glaser E, Goenka S, Goodridge A, Gopalani SV, Goto A, Gughani HC, Guimaraes MD, Gupta R, Gupta R, Gupta V, Haagsma J, Hafezi-Nejad N, Hagan H, Hailu GB, Hamadeh RR, Hamidi S, Hammami M, Hankey GJ, Hao Y, Harb HL, Harikrishnan S, Haro JM, Harun KM, Havmoeller R, Hedayati MT, Heredia-Pi IB, Hoek HW, Horino M, Horita N, Hosgood HD, Hoy DG, Hsairi M, Hu G, Huang H, Huang JJ, Iburg KM, Idrisov BT, Innos K, Iyer VJ, Jacobsen KH, Jahanmehr N, Jakovljevic MB, Javanbakht M, Jayatilake AU, Jeemon P, Jha V, Jiang G, Jiang Y, Jibat T, Jonas JB, Kabir Z, Kamal R, Kan H, Karch A, Karema CK, Karletos D, Kasaeian A, Kaul A, Kawakami N, Kayibanda JF, Keiyoro PN, Kemp AH, Kengne AP, Kesavachandran CN, Khader YS, Khalil I, Khan AR, Khan EA, Khang YH, Khubchandani J, Kim YJ, Kinfu Y, Kivipelto M, Kokubo Y, Kosen S, Koul PA, Koyanagi A, Defo BK, Bicer BK, Kulkarni VS, Kumar GA, Lal DK, Lam H, Lam JO, Langan SM, Lansingh VC, Larsson A, Leigh J, Leung R, Li Y, Lim SS, Lipshultz SE, Liu S, Lloyd BK, Logroscino G, Lotufo PA, Lunevicius R, Razek HM, Mahdavi M, Majdan M, Majeed A, Makhlouf C, Malekzadeh R, Mapoma CC, Marcenés W, Martínez-Raga J, Marzan MB, Masiye F, Mason-Jones AJ, Mayosi BM, McKee M, Meaney PA, Mehndiratta MM, Mekonnen AB, Melaku YA, Memiah P, Memish ZA, Mendoza W, Meretoja A, Meretoja TJ, Mhimbira FA, Miller TR, Mikesell J, Mirarefin M, Mohammad KA, Mohammed S, Mokdad AH, Monasta L, Moradi-Lakeh M, Mori R, Mueller UO, Murimira B, Murthy GV, Naheed A, Naldi L, Nangia V, Nash D, Nawaz H, Nejari C, Ngalesoni FN, de Dieu Ngaribega J, Nguyen QL, Nisar MI, Norheim OF, Norman RE, Nyakarahuka L, Ogbo FA, Oh IH, Ojelabi FA, Olusanya BO, Olusanya JO, Opio JN, Oren E, Ota E, Padukudru MA, Park HY, Park JH, Patil ST, Patten SB, Paul VK, Pearson K, Peprah EK, Pereira CC, Perico N, Pesudovs K, Petzold M, Phillips K, Pillay JD, Plass D, Polinder S, Pourmalek F, Prokop DM, Qorbani M, Rafay A, Rahimi K, Rahimi-Movaghar V, Rahman M, Rahman MH, Rahman SU, Rai RK, Rajic S, Ram U, Rana SM, Rao PV, Remuzzi G, Rojas-Rueda D, Ronfani L, Roshandel G, Roy A, Ruhago GM, Saeedi MY, Sagar R, Saleh MM, Sanabria JR, Santos IS, Sarmiento-Suarez R, Sartorius B, Sawhney M, Schutte AE, Schwebel DC, Seedat S, Sepanlou RS, Servan-Mori EE, Shaikh MA, Sharma R, She J, Sheikhbahaei S, Shen J, Shibuya K, Shin HH, Sigfusdottir ID, Silpakit N, Silva DA, Silveira DG, Simard EP, Sindi S, Singh JA, Singh OP, Singh PK, Skirbekk V, Sliwa K, Soneji S, Sorensen RJ, Soriano JB, Soti DO, Sreeramareddy CT, Stathopoulou V, Steel N, Sunguya BF, Swaminathan S, Sykes BL, Tabarés-Seisdedos R, Talongwa RT, Tavakkoli M, Taye B, Tedla BA, Tekle T, Shifa GT, Temesgen AM, Terkawi AS, Tesfay FH, Tessema GA, Thapa K, Thomson AJ, Thorne-Lyman AL, Tobe-Gai R, Topor-Madry R, Towbin JA, Tran BX, Dimbuene ZT, Tsilimparis N, Tura AK, Ukwaja KN, Uneke CJ, Uthman OA, Venketasubramanian N, Vladimirov SK, Vlassov VV, Vollset SE, Wang L, Weiderpass E, Weintraub RG, Werdecker A, Westerman R, Wijeratne T, Wilkinson JD, Wiyongse CS, Wolfe CD, Won S, Wong JQ, Xu G, Yadav AK, Yakob B, Yalew AZ, Yano Y, Yaseri M, Yebo HG, Yip P, Yonemoto N, Yoon SJ, Younis MZ, Yu C, Yu S, Zaidi Z, Zaki Mel S, Zeeb H, Zhang H, Zhao Y, Zodpey S, Zoeckler L, Zuhlke LJ, Lopez AD, Murray CJ. Estimates of global, regional, and national incidence, prevalence, and mortality of HIV, 1980-2015: the Global Burden of Disease Study 2015. *Lancet HIV* 2016; **3**: e361-e387 [PMID: 27470028 DOI: 10.1016/S2352-3018(16)30087-X]
- 2 **INSIGHT START Study Group**, Lundgren JD, Babiker AG, Gordin F, Emery S, Grund B, Sharma S, Avihingsanon A, Cooper DA, Fätkenheuer G, Libbre JM, Molina JM, Munderi P, Schechter M, Wood R, Klingman KL, Collins S, Lane HC, Phillips AN, Neaton JD. Initiation of Antiretroviral Therapy in Early Asymptomatic HIV Infection. *N Engl J Med* 2015; **373**: 795-807 [PMID: 26192873 DOI: 10.1056/NEJMoal506816]
- 3 **Rodger AJ**, Cambiano V, Bruun T, Vernazza P, Collins S, van Lunzen J, Corbelli GM, Estrada V, Geretti AM, Beloukas A, Asboe D, Viciano P, Gutiérrez F, Clotet B, Pradier C, Gerstoft J, Weber R, Westling K, Wandeler G, Prins JM, Rieger A, Stoeckle M, Kümmerle T, Bini T, Ammassari A, Gilson R, Krznaric I, Ristola M, Zangerle R, Handberg P, Antela A, Allan S, Phillips AN, Lundgren J, PARTNER Study Group. Sexual Activity Without Condoms and Risk of HIV Transmission in Serodifferent Couples When the HIV-Positive Partner Is Using Suppressive Antiretroviral Therapy. *JAMA* 2016; **316**: 171-181 [PMID: 27404185 DOI: 10.1001/jama.2016.5148]
- 4 **Núñez M**. Hepatotoxicity of antiretrovirals: incidence, mechanisms and management. *J Hepatol* 2006; **44**: S132-S139 [PMID: 16364487 DOI: 10.1016/j.jhep.2005.11.027]
- 5 **Reveille JD**, Williams FM. Infection and musculoskeletal conditions: Rheumatologic complications of HIV infection. *Best Pract Res Clin Rheumatol* 2006; **20**: 1159-1179 [PMID: 17127202 DOI: 10.1016/j.berh.2006.08.015]
- 6 **Maartens G**, Celum C, Lewin SR. HIV infection: epidemiology, pathogenesis, treatment, and prevention. *Lancet* 2014; **384**: 258-271 [PMID: 24907868 DOI: 10.1016/S0140-6736(14)60164-1]
- 7 **Zandman-Goddard G**, Shoenfeld Y. HIV and autoimmunity. *Autoimmun Rev* 2002; **1**: 329-337 [PMID: 12848988]
- 8 **Iordache L**, Launay O, Bouchaud O, Jeantils V, Goujard C, Boue F, Cacoub P, Hanslik T, Mahr A, Lambotte O, Fain O; Associated authors. Autoimmune diseases in HIV-infected patients: 52 cases and literature review. *Autoimmun Rev* 2014; **13**: 850-857 [PMID: 24747058 DOI: 10.1016/j.autrev.2014.04.005]
- 9 **Walker UA**, Tyndall A, Daikeler T. Rheumatic conditions in human immunodeficiency virus infection. *Rheumatology (Oxford)* 2008; **47**: 952-959 [PMID: 18413346 DOI: 10.1093/rheumatology/ken132]
- 10 **German V**, Vassiloyanopoulos A, Sampaziotis D, Giannakos G. Autoimmune hepatitis in an HIV infected patient that responded to antiretroviral therapy. *Scand J Infect Dis* 2005; **37**: 148-151 [PMID: 15764206 DOI: 10.1080/00365540510026841]
- 11 **Wan DW**, Marks K, Yantiss RK, Talal AH. Autoimmune hepatitis in the HIV-infected patient: a therapeutic dilemma. *AIDS Patient Care STDs* 2009; **23**: 407-413 [PMID: 19405870 DOI: 10.1089/apc.2008.0149]
- 12 **Daas H**, Khatib R, Nasser H, Kamran F, Higgins M, Saravolatz L. Human immunodeficiency virus infection and autoimmune hepatitis during highly active anti-retroviral treatment: a case report and review of the literature. *J Med Case Rep* 2011; **5**: 233 [PMID: 21702972 DOI: 10.1186/1752-1947-5-233]
- 13 **Coriat R**, Podevin P. Fulminant autoimmune hepatitis after successful interferon treatment in an HIV-HCV co-infected patient. *Int J STD AIDS* 2008; **19**: 208-210 [PMID: 18397566 DOI: 10.1258/ijsa.2007.007185]
- 14 **Puius YA**, Dove LM, Brust DG, Shah DP, Lefkowitz JH. Three cases of autoimmune hepatitis in HIV-infected patients. *J Clin Gastroenterol* 2008; **42**: 425-429 [PMID: 18277893 DOI: 10.1097/01.mcg.0000225591.08825.3e]
- 15 **O'Leary JG**, Zachary K, Misdrapi J, Chung RT. De novo autoimmune hepatitis during immune reconstitution in an HIV-infected patient receiving highly active antiretroviral therapy. *Clin Infect Dis* 2008; **46**: e12-e14 [PMID: 18171203 DOI: 10.1086/524082]
- 16 **Hagel S**, Bruns T, Herrmann A, Tannapfel A, Stallmach A. Autoimmune hepatitis in an HIV-infected patient: an intriguing association. *Int J STD AIDS* 2012; **23**: 448-450 [PMID: 22807544 DOI: 10.1258/ijsa.2009.009337]
- 17 **Cazanave C**, Rakotondravelo S, Morlat P, Blanco P, Bonnet F, Beylot J. [Autoimmune hepatitis in a HIV-HCV co-infected patient: diagnostic and therapeutic difficulties]. *Rev Med Interne* 2006; **27**: 414-419 [PMID: 16545501 DOI: 10.1016/j.revmed.2006.01.016]
- 18 **Murunga E**, Andersson M, Rensburg Cv. Autoimmune hepatitis: a manifestation of immune reconstitution inflammatory syndrome in HIV infected patients? *Scand J Gastroenterol* 2016; **51**: 814-818 [PMID: 27000683 DOI: 10.3109/00365521.2016.1157888]
- 19 **European Association for the Study of the Liver**. EASL Clinical Practice Guidelines: Autoimmune hepatitis. *J Hepatol* 2015; **63**: 971-1004 [PMID: 26341719 DOI: 10.1016/j.jhep.2015.06.030]
- 20 **Caplan M**, Trivedi A, McLaughlin M, Hebou A, Kleiner DE, Heller T, Morse CG. Primary Biliary Cirrhosis Overlapping with Autoimmune Hepatitis in an HIV-Infected Patient on Antiretroviral Therapy. *J Interdiscip Histopathol* 2013; **1**: 270-273 [PMID: 26807302 DOI: 10.5455/jihp.20130624104921]
- 21 **Stratton R**, Slapak G, Mahungu T, Kinloch-de Loes S. Autoimmunity

- and HIV. *Curr Opin Infect Dis* 2009; **22**: 49-56 [PMID: 19532080 DOI: 10.1097/QCO.0b013e3283210006]
- 22 **Amacher DE**. Female gender as a susceptibility factor for drug-induced liver injury. *Hum Exp Toxicol* 2014; **33**: 928-939 [PMID: 24299907 DOI: 10.1177/0960327113512860]
 - 23 **Navarro VJ**, Senior JR. Drug-related hepatotoxicity. *N Engl J Med* 2006; **354**: 731-739 [PMID: 16481640 DOI: 10.1056/NEJMra052270]
 - 24 **Jain MK**. Drug-induced liver injury associated with HIV medications. *Clin Liver Dis* 2007; **11**: 615-639, vii-viii [PMID: 17723923 DOI: 10.1016/j.cld.2007.06.008]
 - 25 **Chughlay M**, Blockman M, Cohen K. A clinical approach to drug-induced liver injury. *Curr Allergy Clin Immunol* 2015; **28**: 252-256

P- Reviewer: Beloukas AI, Maggi F **S- Editor:** Kong JX

L- Editor: A **E- Editor:** Lu YJ





Published by **Baishideng Publishing Group Inc**
7901 Stoneridge Drive, Suite 501, Pleasanton, CA 94588, USA
Telephone: +1-925-223-8242
Fax: +1-925-223-8243
E-mail: bpgoffice@wjgnet.com
Help Desk: <http://www.f6publishing.com/helpdesk>
<http://www.wjgnet.com>

