

# World Journal of *Critical Care Medicine*

*World J Crit Care Med* 2018 October 16; 7(5): 52-72





**Review**

- 52 Vitamin C in the critically ill - indications and controversies  
*Nabzyk CS, Bittner EA*
- 62 Respiratory failure in the hematopoietic stem cell transplant recipient  
*Wieruszewski PM, Herasevich S, Gajic O, Yadav H*

## Contents

*World Journal of Critical Care Medicine*  
Volume 7 Number 5 October 16, 2018

### ABOUT COVER

Editorial Board Member of *World Journal of Critical Care Medicine*, David C Willms, MD, Doctor, Department of Critical Care, Sharp Memorial Hospital, San Diego, CA 92123, United States

### AIM AND SCOPE

*World Journal of Critical Care Medicine* (*World J Crit Care Med*, *WJCCM*, online ISSN 2220-3141, DOI: 10.5492) is a peer-reviewed open access academic journal that aims to guide clinical practice and improve diagnostic and therapeutic skills of clinicians.

*WJCCM* covers topics concerning severe infection, shock and multiple organ dysfunction syndrome, infection and anti-infection treatment, acute respiratory distress syndrome and mechanical ventilation, acute kidney failure, continuous renal replacement therapy, rational nutrition and immunomodulation in critically ill patients, sedation and analgesia, cardiopulmonary cerebral resuscitation, fluid resuscitation and tissue perfusion, coagulant dysfunction, hemodynamic monitoring and circulatory support, ICU management and treatment control, and application of bronchofiberscopy in critically ill patients.

We encourage authors to submit their manuscripts to *WJCCM*. We will give priority to manuscripts that are supported by major national and international foundations and those that are of great clinical significance.

### INDEXING/ABSTRACTING

*World Journal of Critical Care Medicine* (*WJCCM*) is now indexed in PubMed, PubMed Central, China National Knowledge Infrastructure (CNKI), and Superstar Journals Database.

### EDITORS FOR THIS ISSUE

Responsible Assistant Editor: *Xiang Li*  
Responsible Electronic Editor: *Shu-Yu Yin*  
Proofing Editor-in-Chief: *Lian-Sheng Ma*

Responsible Science Editor: *Fang-Fang Ji*  
Proofing Editorial Office Director: *Jin-Lei Wang*

#### NAME OF JOURNAL

*World Journal of Critical Care Medicine*

#### ISSN

ISSN 2220-3141 (online)

#### LAUNCH DATE

February 4, 2012

#### EDITORIAL BOARD MEMBERS

All editorial board members resources online at <http://www.wjgnet.com/2220-3141/editorialboard.htm>

#### EDITORIAL OFFICE

Jin-Lei Wang, Director  
*World Journal of Critical Care Medicine*  
Baishideng Publishing Group Inc  
7901 Stoneridge Drive, Suite 501, Pleasanton, CA 94588, USA  
Telephone: +1-925-2238242

Fax: +1-925-2238243

E-mail: [editorialoffice@wjgnet.com](mailto:editorialoffice@wjgnet.com)

Help Desk: <http://www.f6publishing.com/helpdesk>

<http://www.wjgnet.com>

#### PUBLISHER

Baishideng Publishing Group Inc  
7901 Stoneridge Drive,  
Suite 501, Pleasanton, CA 94588, USA  
Telephone: +1-925-223-8242

Fax: +1-925-223-8243

E-mail: [bpgoffice@wjgnet.com](mailto:bpgoffice@wjgnet.com)

Help Desk: <http://www.f6publishing.com/helpdesk>

<http://www.wjgnet.com>

#### PUBLICATION DATE

October 16, 2018

#### COPYRIGHT

© 2018 Baishideng Publishing Group Inc. Articles

published by this Open-Access journal are distributed under the terms of the Creative Commons Attribution Non-commercial License, which permits use, distribution, and reproduction in any medium, provided the original work is properly cited, the use is non commercial and is otherwise in compliance with the license.

#### SPECIAL STATEMENT

All articles published in journals owned by the Baishideng Publishing Group (BPG) represent the views and opinions of their authors, and not the views, opinions or policies of the BPG, except where otherwise explicitly indicated.

#### INSTRUCTIONS TO AUTHORS

<http://www.wjgnet.com/bpg/gerinfo/204>

#### ONLINE SUBMISSION

<http://www.f6publishing.com>

## Vitamin C in the critically ill - indications and controversies

Christoph S Nabzdyk, Edward A Bittner

Christoph S Nabzdyk, Edward A Bittner, Department of Anesthesia, Critical Care and Pain Medicine, Massachusetts General Hospital, Harvard Medical School, Boston, MA 02114, United States

ORCID number: Christoph S Nabzdyk (0000-0002-9849-6221); Edward A Bittner (0000-0002-0159-2373).

**Author contributions:** Both authors equally contributed to this paper with conception, literature review, drafting and critical revision and editing, and final approval of the final version.

**Conflict-of-interest statement:** No potential conflicts of interest. No financial support.

**Open-Access:** This article is an open-access article which was selected by an in-house editor and fully peer-reviewed by external reviewers. It is distributed in accordance with the Creative Commons Attribution Non Commercial (CC BY-NC 4.0) license, which permits others to distribute, remix, adapt, build upon this work non-commercially, and license their derivative works on different terms, provided the original work is properly cited and the use is non-commercial. See: <http://creativecommons.org/licenses/by-nc/4.0/>

**Manuscript source:** Invited manuscript

**Correspondence to:** Edward A Bittner, MD, PhD, MEd, Associate Professor, Department of Anesthesia, Critical Care and Pain Medicine, Massachusetts General Hospital, Harvard Medical School, 55 Fruit St, Boston, MA 02114, United States. [ebittner@partners.org](mailto:ebittner@partners.org)  
Telephone: +1-617-7263030  
Fax: +1-617-7267536

Received: June 24, 2018

Peer-review started: June 25, 2018

First decision: July 9, 2018

Revised: August 4, 2018

Accepted: August 21, 2018

Article in press: August 21, 2018

Published online: October 16, 2018

### Abstract

Ascorbic acid (vitamin C) elicits pleiotropic effects in the

body. Among its functions, it serves as a potent anti-oxidant, a co-factor in collagen and catecholamine synthesis, and a modulator of immune cell biology. Furthermore, an increasing body of evidence suggests that high-dose vitamin C administration improves hemodynamics, end-organ function, and may improve survival in critically ill patients. This article reviews studies that evaluate vitamin C in pre-clinical models and clinical trials with respect to its therapeutic potential.

**Key words:** Ascorbic acid; vitamin C; Sepsis; Shock; Critical care medicine; Vasopressors; Cardiovascular

© **The Author(s) 2018.** Published by Baishideng Publishing Group Inc. All rights reserved.

**Core tip:** An increasing body of evidence suggests that high-dose vitamin C administration improves hemodynamics, end-organ function, and may improve survival in critically ill patients. This article reviews studies that evaluate vitamin C in pre-clinical models and clinical trials with respect to its therapeutic potential.

Nabzdyk CS, Bittner EA. Vitamin C in the critically ill - indications and controversies. *World J Crit Care Med* 2018; 7(5): 52-61 Available from: URL: <http://www.wjgnet.com/2220-3141/full/v7/i5/52.htm> DOI: <http://dx.doi.org/10.5492/wjccm.v7.i5.52>

### INTRODUCTION

Vitamin C is one of the most well-known essential nutrients and is believed by many to confer a litany of health benefits (Figure 1). The Nobel Prize Winner Linus Pauling may have been the foremost ambassador to date who suggested that vitamin C would enhance cardiovascular health, improve the body's immune function to overcome infections, and even help abate cancer<sup>[1-4]</sup>. These health claims created significant controversies that lasted for decades. While many of Pauling's "more is better" claims have not been supported by rigorous scientific

Effects of vitamin C
<b>Antioxidant</b> Radical oxygen scavenger protecting cells from oxidative stress
<b>Steroid- and catecholamine synthesis</b> Cofactor in catecholamine, vasopressin and steroid synthesis Improves hemodynamics; may accelerate resolution of shock
<b>Immune cell function</b> Increases neutrophil phagocytosis and chemotaxis Affects macrophage migration Enhances T and NK cell proliferation, modulates their function May increase antibody formation
<b>Endothelial cell function</b> Decreases endothelial ICAM expression and leukocyte adhesion Improves endothelial barrier function Decreases fluid requirements in burn patients Improves microcirculation
<b>Carnitine production</b> Modulates fatty acid metabolism May improve microcirculation and cardiac function
<b>Wound healing</b> Cofactor of collagen production Mitogen for fibroblasts

**Figure 1 Biological functions of vitamin C.** NK: Natural killer cells; ICAM: Intercellular adhesion molecule.

investigation, a growing number of benefits of vitamin C administration have been identified for medical treatment, including in the field of critical care. This mini-review will examine the evidence in support of vitamin C administration for critically ill patients and provide general recommendations for use by intensive care unit practitioners.

## VITAMIN C LEVELS IN THE CRITICALLY ILL

Vitamin C is water-soluble and circulates in the plasma. It is freely filtered by the glomerulus and reabsorbed in the proximal tubule *via* the first sodium-dependent vitamin C transporter (SVCT1). In the setting of hypovitaminosis C, its urinary excretion is minimal<sup>[5]</sup>. While SVCT1 regulates whole-body homeostasis of vitamin C, a high-affinity, low-capacity sodium-dependent vitamin C transporter SVCT2 protects metabolically-active cells against oxidative stress, which facilitates vitamin C accumulation where it is needed<sup>[6]</sup>. The recommended daily oral dose of vitamin C is 75 mg (adult female)/90 mg (adult male), and only ten mg of daily oral vitamin C is necessary to prevent scurvy (plasma level < 0.1 mg/dL; normal range 0.8-1.6 mg/dL). Despite meeting these recommended daily intakes, many critically ill patients exhibit decreased vitamin C plasma levels. Carr *et al*<sup>[7]</sup> reported hypovitaminosis C in 44 critically ill patients receiving standard intensive care unit nutrition, of which one-third had vitamin C deficiency. The degree of vitamin C deficiency was more pronounced

in the septic population as compared to the non-septic critically ill. Continuous renal replacement is commonly utilized in critically ill patients and is believed to lead to a depletion of water-soluble vitamins<sup>[8-10]</sup>. A retrospective study of critically ill patients receiving continuous renal replacement revealed that 87% (13 out of 15) had vitamin C deficiencies<sup>[9]</sup>.

## BIOLOGICAL EFFECTS OF VITAMIN C

Among vitamin C's pleiotropic functions that are of relevance to critical illness are its immune-enhancing effects, anti-oxidant properties, and potential anti-mutagenic effects<sup>[11,12]</sup>. Vitamin C has been shown to enhance neutrophil chemotaxis, phagocytosis, and thus microbial clearance<sup>[13,14]</sup>. In addition, vitamin C promotes T cell and natural killer cell proliferation and modulates their functions<sup>[13,15]</sup>. Studies on vitamin C's effects on B cells have revealed conflicting data with regard to proliferation and differentiation<sup>[13,15]</sup>. Vitamin C appears to induce antibody production in human lymphocytes and those of guinea pigs<sup>[16,17]</sup>. In a mouse model of abdominal sepsis induced by cecal-puncture ligation, parenteral vitamin C administration improved sepsis outcomes through reversal of regulatory T cell inhibitory function<sup>[18]</sup>. Hypovitaminosis C in a sepsis model using guinea pigs was also associated with fewer macrophages in the peritoneal cavity and impaired macrophage migration<sup>[19,20]</sup>. Interestingly, the adverse effects of vitamin C deficiency were more pronounced in elderly guinea pigs<sup>[19]</sup>.

In cell culture and rodent experiments, vitamin C has been shown to decrease lipid peroxidation, prevent occludin dephosphorylation, and thus diminish the loosening of tight junctions<sup>[5,21-23]</sup>. Vitamin C also improves microcirculatory flow impairment by inhibiting tumor-necrosis-factor (TNF)-induced intercellular adhesion molecule 1 expression, thereby decreasing leukocyte adhesiveness<sup>[5,24,25]</sup>. In smokers, a single bolus administration of vitamin C (3 g IV) was found to increase coronary flow reserve, which is an integrated parameter of endothelial function and vascular smooth muscle relaxation. This effect was not seen in healthy control patients<sup>[26]</sup>.

Vitamin C is a cofactor in collagen synthesis, a mitogen for fibroblasts, and is believed to positively modulate proinflammatory signaling and inflammation resolution that occur in wound beds<sup>[27,28]</sup>. Vitamin C supplementation in deficient mice promotes wound healing through enhanced matrix deposition and fibroblast proliferation<sup>[27]</sup>. In addition, topical vitamin C increases dermal collagen biosynthesis in healthy volunteers<sup>[29,30]</sup>. However, vitamin C supplementation does not consistently improve pressure ulcer healing in nursing homes and hospitalized patients, and recent systematic reviews have concluded that vitamin C (often administered in conjunction with zinc and other nutrients) is ineffective in treatment for this condition<sup>[31-35]</sup>.

Vitamin C is a cofactor in carnitine synthesis, a molecule that facilitates fatty acid shuttling into mitochondria,



reduces oxidative stress, and promotes endothelial sprouting<sup>[36,37]</sup>. Its deficiency has been linked to cardiomyopathy and neurometabolic disease<sup>[38,39]</sup>. Despite carnitine's essential metabolic roles, clinical data to date have not yielded convincing evidence that supplementation in critically ill patients will improve outcomes<sup>[40-42]</sup>.

Vitamin C is also a cofactor in catecholamine synthesis and adrenal steroidogenesis<sup>[43,44]</sup>. Vitamin C contributes to the conversion of dopamine to norepinephrine by dopamine beta-hydroxylase<sup>[45]</sup>. Vitamin C enhances norepinephrine synthesis both by recycling tetrahydrobiopterin, a critical cofactor in catecholamine synthesis, and increasing tyrosine hydroxylase expression<sup>[46]</sup>. Furthermore, vitamin C is a cofactor for the peptidylglycine  $\alpha$ -amidating monooxygenase that is required for the endogenous synthesis of vasopressin<sup>[47]</sup>. One study in cardiac surgical patients has suggested that pre-operative administration of vitamin C mitigates etomidate-induced adrenal suppression<sup>[48]</sup>. Thus, there has been significant interest in utilizing vitamin C for the management of hemodynamically-unstable patients<sup>[49]</sup>.

## VITAMIN C IN CARDIOVASCULAR PATIENTS

While a recent review concluded that there is insufficient evidence to support the use of vitamin C to reduce cardiovascular disease risk or mortality in the general population, increasing evidence suggests that it may have a beneficial role in patients with acute coronary syndromes or undergoing cardiac surgical procedures<sup>[50]</sup>. Cardiac surgery, extracorporeal membrane oxygenation and hemodialysis produce oxidative stress, which negatively impacts morbidity and mortality<sup>[51]</sup>. Vitamin C's ability to scavenge reactive oxygen species and increase nitric oxide production through induction of endothelial nitric oxide synthase have made it a focus of interest as a cardiovascular therapy adjunct<sup>[52]</sup>. In one study of cardiac surgical patients undergoing cardiopulmonary bypass, statistically significant reductions in plasma levels of vitamin C were found intraoperatively compared to preoperative levels, even prior to initiation of cardiopulmonary bypass ( $\Delta 16.3\%$  compared to baseline). This decrease in vitamin C plasma levels continued after cardiopulmonary bypass and lasted for at least six days<sup>[53]</sup>.

Perioperative vitamin C administration has also been shown to prevent post-operative atrial fibrillation in the majority of the studies<sup>[54-59]</sup>. Its effects appear to result in reductions in the duration of hospital and intensive care unit patient stay following cardiac surgery<sup>[54-57]</sup>.

Other studies examining the effects of vitamin C administration on patients with acute myocardial infarction and undergoing coronary revascularization procedures have reported improved left ventricular ejection fraction, microcirculation, and limited infarct size in patients with acute myocardial infarction<sup>[60-62]</sup>. One recent randomized multicenter clinical trial on patients with myocardial infarction undergoing percutaneous coronary angioplasty

did not show a significant improvement in infarct size or ejection fraction at the time of the intervention with vitamin C administration. However, a decline in the LVEF between 7-15 d and 2-3 mo noted in the control group was not seen in the vitamin C group<sup>[63]</sup>. The authors of this study suggested that vitamin C may have ameliorated myocardial reperfusion injury<sup>[63]</sup>.

In addition to potential beneficial effects on microperfusion and myocardial protection, a growing body of evidence suggests that vitamin C administration may positively affect hemodynamic parameters and hasten freedom from vasopressors in critically ill patients<sup>[64-67]</sup>. Interestingly, some evidence suggests that vitamin C's effects on hemodynamics may have a ceiling effect. A recently reported pharmacokinetic study by de Grooth *et al.*<sup>[68]</sup> only found a minimal reduction in heart rate among critically ill patients randomized to receive 2 g/d vs 10 g/d of vitamin C. However, only the treatment group that received the 2 g/d of vitamin C, but not the 10 g/d treatment regimen, had a clinically-relevant decrease in norepinephrine requirements over 48 h<sup>[68]</sup>.

## VITAMIN C IN BURN-INJURED PATIENTS

Increased capillary leakage is a clinical hallmark of burn injury. It is associated with significant fluid and protein extravasation. The term "fluid creep" was coined to describe the phenomenon that burn patients often receive significantly more resuscitation fluid than anticipated based on Parkland formula calculations<sup>[69]</sup>. This excess fluid resuscitation can be associated with edema-related complications<sup>[70]</sup>. Endothelial damage leading to increased permeability in patients with burn injury may partly be mediated by reactive oxygen species-induced lipid peroxidation. As an antioxidant, vitamin C has been evaluated as a therapy to decrease fluid resuscitation requirements<sup>[71,72]</sup>. In a rodent model of burn injury, high-dose vitamin C appeared to improve microvascular barrier dysfunction, without affecting leukocyte activation<sup>[73]</sup>. In a study of guinea pigs with 70% third-degree burns given high dose vitamin C (170, 340 and 680 mg/kg per day), fluid requirements were significantly reduced while stable cardiac outputs were maintained<sup>[74]</sup>. In a study of dogs with burn injuries, vitamin C administration (14 mg/kg per hour) decreased lipid peroxidation and microvascular protein and fluid leakage<sup>[75]</sup>. A burn study in sheep provided additional evidence that high-dose vitamin C (250 mg/kg bolus plus 15 mg/kg per hour) could reduce fluid requirements and lipid peroxidation, as well as improve antioxidant status<sup>[76]</sup>. Preliminary studies in humans have also been promising. In a study of 37 patients with > 30% total body surface area burns, vitamin C administration (66 mg/kg per hour) reduced fluid requirements, wound edema, and increased the ratio of PaO<sub>2</sub> to a fraction of inspired oxygen<sup>[66]</sup>. In a retrospective review of 40 patients with > 20% total body surface area, vitamin C (66 mg/kg per hour) was associated with increased urine output and decreased fluid requirements, but no change in outcomes or incidence of acute kidney injury<sup>[77]</sup>. In another small

study ( $n = 30$ ) of patients with second degree burns, topical vitamin C accelerated formation of granulation tissue<sup>[78]</sup>.

## VITAMIN C IN SEPTIC PATIENTS

There has recently been a surge of interest in the use of vitamin C as an adjuvant treatment for sepsis. This interest was stimulated by the findings of a cohort study by Marik *et al.*<sup>[64]</sup> that administered a cocktail of vitamin C (1.5 g IV every 6 h), hydrocortisone (50 mg IV every 6 h) and thiamine (200 mg IV every 12 h) to 47 septic patients and found a significant reduction in SOFA scores, dependence on vasopressors, and most importantly in hospital mortality to 8.5% in the treatment arm vs 40.4% in a historic control group. These findings were consistent with small phase I double-blinded placebo-controlled trials suggesting the beneficial effects of vitamin C in patients with sepsis<sup>[67]</sup>. This trial, which randomized 24 septic patients with documented hypovitaminosis C to receive placebo, low-dose (50 mg/kg per day) or high-dose (200 mg/kg per day) parental vitamin C for four days, found significant reductions in SOFA scores and CRP plasma levels in the vitamin C-treated groups<sup>[67]</sup>. In another small trial of critically ill surgical patients, Zabet *et al.*<sup>[65]</sup> reported a significant reduction in 28 d mortality in 14 patients with septic shock who were randomized to receive 25 mg/kg per day of ascorbic acid every 6 h for 72 h, when compared to 14 patients with septic shock who received placebo. Despite these promising findings, there are potential safety concerns worthy of consideration with vitamin C administration in the critically ill population. A recent study by De Grooth *et al.*<sup>[68]</sup> evaluated four parenteral vitamin C repletion regimens (2 g/d vs 10 g/d; bolus vs continuous infusion) administered for 48 h to critically ill patients with multiple organ dysfunction. The patients receiving 10 g vitamin C per day had supraphysiologic vitamin C levels and hyperoxaluria, oxalate being a metabolite of vitamin C. These findings raise concern for an increased risk of oxalate nephropathy, as has been reported with high-dose vitamin C administration and more prolonged administration in the noncritically ill population<sup>[68,79,80]</sup>. This theoretical risk of oxalate nephropathy stands in contrast with the mostly reassuring data about the safety of short-term high-dose vitamin C administration<sup>[64,65,67]</sup>.

At present, multiple ongoing randomized controlled trials, including the VICTAS, ACTS, and HYVCTSSS trials, are aimed at confirming the beneficial effects of vitamin C and adjuncts in critically ill patients with sepsis<sup>[81-83]</sup>.

## VITAMIN C IN HEMORRHAGIC SHOCK

Trauma and hemorrhagic shock can lead to significant coagulopathy and inflammation, and both are associated with increased mortality and morbidity. Given its antioxidant effects, vitamin C has long been evaluated as a protective agent to mitigate effects on proinflammatory and procoagulant pathways caused by trauma and hemor-

rhagic shock<sup>[84-88]</sup>.

In a swine model of acute hemorrhagic shock, animals were randomized to receive either intravenous normal saline, low-dose Vitamin C (50 mg/kg), or high-dose Vitamin C (200 mg/kg). The group of animals receiving normal saline (control) showed significantly greater histological end-organ damage, including elevated acute lung injury scores and increased mRNA levels of interleukin (IL)-1 $\beta$ , IL-8, TNF- $\alpha$ , plasminogen activation inhibitor-1 and tissue factor compared with the groups receiving vitamin C. Furthermore, only a modest correction of coagulopathy was observed in the vitamin C group when compared to the normal saline group<sup>[88]</sup>. Similarly, in a rat model of hemorrhagic shock, vitamin C administration (low 100 mg/kg or high 500 mg/kg) was shown to attenuate renal injury, possibly *via* a SIRT1-mediated mechanism. Levels of serum creatinine, BUN, TNF- $\alpha$ , and IL-1 $\beta$  were lower in the vitamin C group when compared to a sham group. Conversely, levels of hemoxygenase-1 (HO-1), a stress-response protein believed to play key roles in mediating protection against oxidant-mediated lung injury, were higher in kidneys treated with vitamin C. This effect appeared to occur irrespective of the vitamin C dose administered<sup>[89]</sup>. Another study of the effects of vitamin C administration (100 mg/kg) on renal function found a decrease in expression of the induced dendritic cell-specific intercellular adhesion molecule 3-grabbing nonintegrin protein in the tubular epithelial cells of rat kidneys. Levels of this protein are believed to correlate with the occurrence of kidney injury. Vitamin C administration prior to resuscitation was also found to decrease proinflammatory cytokine production, which mitigated renal injury<sup>[90]</sup>. Another rat model of hemorrhagic shock found that vitamin C treatment induced HO-1 expression in a variety of tissues, including kidney, lung and liver, with decreased organ injury and proinflammatory responses<sup>[91]</sup>. Likewise, vitamin C pretreatment in the setting of hemorrhagic shock appears to protect the intestinal epithelium by decreased proinflammatory cytokine expression and neutrophil infiltration. This effect was also believed to be mediated by HO-1 and was abrogated by pharmacological HO-1 inhibition<sup>[92]</sup>. Prior studies have suggested that pretreatment of rats with vitamin C (1 mg/100 g or 5 mg/100 g) decreases gastric mucosal bleeding after induction of hemorrhagic shock and retransfusion<sup>[93]</sup>. Lastly, the combination of vitamin C administration (50 mg/kg per day for 3 d) prior to inducing hemorrhage together with intravenous infusion vitamin C (50 mg/kg) following hemorrhage improved cardiovascular parameters, such as blood pressure and LV dp/dt, and decreased free radical production in a rat model of hemorrhagic hypotension<sup>[94]</sup>.

These beneficial effects of vitamin C stand in contrast with those obtained in a rat model of liver injury and hemorrhagic shock, in which vitamin C preconditioning (10 mg/kg) did not improve the recovery of animals after resuscitation<sup>[95]</sup>. Likewise, a survival study in rats with hemorrhagic shock did not show a difference when lactated Ringer's solution plus vitamin C (50 mg/kg) was administered for resuscitation, compared with lactated

Ringer's solution alone<sup>[96]</sup>.

These preclinical studies point out multiple mechanisms by which vitamin C may serve as an antioxidant in hemorrhagic shock and thus could provide organ protection. However, evidence suggesting a vitamin C-mediated survival benefit is missing. To our knowledge, there is thus far no human trial data available that demonstrate a clinical benefit of vitamin C administration as an adjunct for the treatment of trauma and hemorrhagic shock.

## VITAMIN C AND PAIN

Pain is a common problem in critically ill patients, either due to injuries secondary to infection, inflammation, trauma, surgery, cancer, or in the setting of the reactivation of herpes zoster. Evidence suggests that vitamin C acts as a cofactor for the biosynthesis of opioid peptides and as a potent anti-inflammatory agent<sup>[97,98]</sup>.

Several case reports and a cohort study have reported clinical improvement in relief for patients with acute herpes zoster exacerbation who were administered vitamin C<sup>[99-101]</sup>. While a recent randomized controlled trial of high dose intravenous vitamin C (5 g *iv* bolus per day on day 1, 3 and 5) failed to find a reduction in acute herpes zoster pain, there was a decrease in the incidence of post-herpetic neuropathy<sup>[102]</sup>. A similarly designed study found lower plasma concentrations of vitamin C in patients with post-herpetic neuropathy than in healthy volunteers, and a reduction in spontaneous post-herpetic neuropathy pain after high-dose vitamin C treatment<sup>[103]</sup>.

Several trials have found reductions in the development of complex regional pain syndrome after wrist and ankle surgery with vitamin C<sup>[104-107]</sup>. A study of patients with osteoarthritis-related hip or knee joint pain found that vitamin C that was administered enterally for 14 d provided modest pain relief, equivalent to approximately half the effect of nonsteroidal anti-inflammatory drugs<sup>[108]</sup>. In a randomized controlled trial of vitamin C in patients undergoing single-level posterior lumbar interbody fusion, there was no difference in postoperative pain intensity between the two groups, but vitamin C administration was associated with improved functional status<sup>[109]</sup>.

A majority of the prospective and case studies of vitamin C administration for cancer-related pain have reported improvements in quality-of-life indicators such as pain, fatigue, insomnia, nausea and vomiting<sup>[110-115]</sup>. However, clinical trial data regarding vitamin C-related opioid-sparing effects in cancer patients have yielded mixed results<sup>[116-119]</sup>.

## VITAMIN C IN CANCER PATIENTS

Perhaps more widely investigated than any other vitamin C-related claim is the assertion of benefit for patients with cancer. In fact, a quick PubMed search of "ascorbic acid + cancer" yielded 4,376 items, 247 of which were clinical trials (as of May 2018).

Cancer patients have been recognized to have low vitamin C levels compared with healthy controls<sup>[120]</sup>. In a large randomized, placebo-controlled trial, daily intake of antioxidants, vitamins and minerals, a combination of vitamin C (120 mg/d), vitamin E, zinc, beta carotene and selenium lowered total cancer incidence and all-cause mortality in men but not women at 7.5 years<sup>[121]</sup>. A similar regimen of vitamin C and E supplementation with beta carotene did not, however, prevent the formation of colon adenomas in a randomized trial of 864 patients<sup>[122]</sup>. Another study of vitamin C and E supplementation for cancer prevention did not identify immediate or long-term effects on the risk of total cancers, prostate cancer, or other site-specific cancers<sup>[123]</sup>.

A randomized clinical trial examining different doses of vitamin C (1, 2 or 4 g/d) failed to find a dose-response relationship or an association between serum ascorbic acid levels and mutagen sensitivity, which has been described as a risk factor for tobacco-related epithelial cancers<sup>[124]</sup>. Despite these clinical findings, basic science data suggest that vitamin C may have a beneficial role in cancer progression through several different mechanisms. Vitamin C was recently found to restore Tet methylcytosine dioxygenase 2 function, one of the most frequently mutated genes in hematopoietic malignancies. Through this mechanism, vitamin C may block aberrant self-renewal and leukemia progression<sup>[125]</sup>. Vitamin C also facilitates DNA oxidation in leukemia cells, rendering them more sensitive to poly ADP ribose polymerase inhibitors<sup>[125]</sup>.

In cholangiocarcinoma, SVCT2 expression levels have been shown to correlate with susceptibility to vitamin C-induced cancer cell death *in vitro* and *in vivo*<sup>[126]</sup>. In separate experiments, Vitamin C has been shown to increase methotrexate-mediated hepatocellular carcinoma cell death<sup>[127]</sup>. Furthermore, vitamin C enhances the effectiveness of radiation therapy for glioblastoma and gemcitabine/epigallocatechin-3-gallate treatment for mesothelioma<sup>[128,129]</sup>. These findings are in contrast to data showing that vitamin C interferes with chemotherapy drugs such as doxorubicin, methotrexate, and cisplatin<sup>[128-131]</sup>. Moreover, vitamin C may enhance the growth of some cancers. For example, plasmacytoma cell growth is dependent on the presence of vitamin C<sup>[132]</sup>. Vitamin C exposure showed differential effects in an *in vitro* model of colony-forming bone marrow cell growth in patients with myelodysplastic syndrome. In this model, vitamin C responsiveness (both growth enhancement or inhibition) was associated with shorter survival when compared to patients with no response to vitamin C<sup>[133]</sup>. Adding to this complex picture is data derived from *in vitro* work that examined the response of HL-60 cells from an acute myeloid leukemia cell line to vitamin C. Vitamin C administration decreased oxidative stress and thus protected HL-60 cells from H<sub>2</sub>O<sub>2</sub>-induced cell death<sup>[134]</sup>.

Curiously, high-dose vitamin C (0.5-5 mmol/L) has also been shown to increase the procoagulant properties of freshly isolated red blood cells *via* externalization of phosphatidylserine, a mechanism known to lead to throm-



bus formation. Interestingly, this effect was more pronounced in red blood cells from cancer patients and could be confirmed in a rat model of thrombus formation<sup>[135]</sup>.

In one study in terminal cancer patients, vitamin C was associated with increased quality-of-life and survival<sup>[116]</sup>. In contrast, in two double-blinded randomized controlled trials that included patients with advanced cancers (stomach, colon, pancreas, lung, breast and others), vitamin C (10 g/d) did not improve survival<sup>[136,137]</sup>.

Given the complexities of cancer biology and vitamin C, the risks and benefits of initiating high-dose vitamin C therapy in critically ill oncology patients should be carefully weighed and discussed with the oncology consultant.

## CONCLUSION

Vitamin C is once again a focus of intense interest with respect to its role in the treatment of critically ill patients. Evidence suggests that vitamin C administration may have a variety of beneficial effects in patients undergoing cardiac surgical procedures, during resuscitation with acute burn injury, for the treatment of sepsis, in reducing pain, and in the treatment of cancer. While many questions have yet to be answered, there is little data to suggest that short-term high-dose vitamin C would elicit major harm, except for the risk of oxalate nephropathy. In fact, evidence suggests that short-term high-dose vitamin C in selected patients may improve hemodynamic parameters, decrease fluid resuscitation requirements, reduce the incidence of perioperative atrial fibrillation, improve pain and potentially reduce sepsis-associated mortality. We eagerly await additions to the growing body of evidence that examine the role of vitamin C administration for improving outcomes for our sickest patients.

## REFERENCES

- 1 Pauling L. Vitamin C therapy of advanced cancer. *N Engl J Med* 1980; **302**: 694-695 [PMID: 7354772 DOI: 10.1056/NEJM198003203021219]
- 2 Pauling L. Diet, nutrition, and cancer. *Am J Clin Nutr* 1977; **30**: 661-663 [PMID: 324260 DOI: 10.1093/ajcn/30.5.661]
- 3 Cameron E, Pauling L. Ascorbic acid and the glycosaminoglycans. An orthomolecular approach to cancer and other diseases. *Oncology* 1973; **27**: 181-192 [PMID: 4267127 DOI: 10.1159/000224733]
- 4 Pauling L. Vitamin C and common cold. *JAMA* 1971; **216**: 332 [PMID: 5107925 DOI: 10.1001/jama.1971.03180280086025]
- 5 Berger MM, Oudemans-van Straaten HM. Vitamin C supplementation in the critically ill patient. *Curr Opin Clin Nutr Metab Care* 2015; **18**: 193-201 [PMID: 25635594 DOI: 10.1097/MCO.0000000000000148]
- 6 Savini I, Rossi A, Pierro C, Avigliano L, Catani MV. SVCT1 and SVCT2: key proteins for vitamin C uptake. *Amino Acids* 2008; **34**: 347-355 [PMID: 17541511 DOI: 10.1007/s00726-007-0555-7]
- 7 Carr AC, Rosengrave PC, Bayer S, Chambers S, Mehrtens J, Shaw GM. Hypovitaminosis C and vitamin C deficiency in critically ill patients despite recommended enteral and parenteral intakes. *Crit Care* 2017; **21**: 300 [PMID: 29228951 DOI: 10.1186/s13054-017-1891-y]
- 8 Honoré PM, De Waele E, Jacobs R, Mattens S, Rose T, Joannes-Boyau O, De Regt J, Verfaillie L, Van Gorp V, Boer W, Collin V, Spapen HD. Nutritional and metabolic alterations during continuous renal replacement therapy. *Blood Purif* 2013; **35**: 279-284 [PMID: 23689499 DOI: 10.1159/000350610]
- 9 Kamel AY, Dave NJ, Zhao VM, Griffith DP, Connor MJ Jr, Ziegler TR. Micronutrient Alterations During Continuous Renal Replacement Therapy in Critically Ill Adults: A Retrospective Study. *Nutr Clin Pract* 2018; **33**: 439-446 [PMID: 28727945 DOI: 10.1177/0885433617716618]
- 10 Story DA, Ronco C, Bellomo R. Trace element and vitamin concentrations and losses in critically ill patients treated with continuous venovenous hemofiltration. *Crit Care Med* 1999; **27**: 220-223 [PMID: 9934919 DOI: 10.1097/00003246-199901000-00057]
- 11 Frei B, Stocker R, England L, Ames BN. Ascorbate: the most effective antioxidant in human blood plasma. *Adv Exp Med Biol* 1990; **264**: 155-163 [PMID: 2244489 DOI: 10.1007/978-1-4684-5730-8\_24]
- 12 Dennis JM, Witting PK. Protective Role for Antioxidants in Acute Kidney Disease. *Nutrients* 2017; **9**: E718 [PMID: 28686196 DOI: 10.3390/nu9070718]
- 13 Carr AC, Maggini S. Vitamin C and Immune Function. *Nutrients* 2017; **9**: E1211 [PMID: 29099763 DOI: 10.3390/nu9111211]
- 14 Ames AM, Nungester WJ. The relationship between ascorbic acid and phagocytic activity. *J Bacteriol* 1947; **54**: 53 [PMID: 20255149]
- 15 van Gorkom GNY, Klein Wolterink RGJ, Van Elssen CHMJ, Wieten L, Germeraad WTV, Bos GMJ. Influence of Vitamin C on Lymphocytes: An Overview. *Antioxidants (Basel)* 2018; **7**: E41 [PMID: 29534432 DOI: 10.3390/antiox7030041]
- 16 Tanaka M, Muto N, Gohda E, Yamamoto I. Enhancement by ascorbic acid 2-glucoside or repeated additions of ascorbate of mitogen-induced IgM and IgG productions by human peripheral blood lymphocytes. *Jpn J Pharmacol* 1994; **66**: 451-456 [PMID: 7723222 DOI: 10.1254/jjp.66.451]
- 17 Feigen GA, Smith BH, Dix CE, Flynn CJ, Peterson NS, Rosenberg LT, Pavlovic S, Leibovitz B. Enhancement of antibody production and protection against systemic anaphylaxis by large doses of vitamin C. *Res Commun Chem Pathol Pharmacol* 1982; **38**: 313-333 [PMID: 7163630 DOI: 10.1016/S0022-5347(17)52586-0]
- 18 Gao YL, Lu B, Zhai JH, Liu YC, Qi HX, Yao Y, Chai YF, Shou ST. The Parenteral Vitamin C Improves Sepsis and Sepsis-Induced Multiple Organ Dysfunction Syndrome via Preventing Cellular Immunosuppression. *Mediators Inflamm* 2017; **2017**: 4024672 [PMID: 28210072 DOI: 10.1155/2017/4024672]
- 19 Ganguly R, Waldman RH. Macrophage functions in aging: effects of vitamin C deficiency. *Allerg Immunol (Leipz)* 1985; **31**: 37-43 [PMID: 2986438]
- 20 Ganguly R, Durieux MF, Waldman RH. Macrophage function in vitamin C-deficient guinea pigs. *Am J Clin Nutr* 1976; **29**: 762-765 [PMID: 937230 DOI: 10.1093/ajcn/29.7.762]
- 21 Han M, Pendem S, Teh SL, Sukumaran DK, Wu F, Wilson JX. Ascorbate protects endothelial barrier function during septic insult: Role of protein phosphatase type 2A. *Free Radic Biol Med* 2010; **48**: 128-135 [PMID: 19840845 DOI: 10.1016/j.freeradbiomed.2009.10.034]
- 22 Fisher BJ, Kraskauskas D, Martin EJ, Farkas D, Wegelin JA, Brophy D, Ward KR, Voelkel NF, Fowler AA 3rd, Natarajan R. Mechanisms of attenuation of abdominal sepsis induced acute lung injury by ascorbic acid. *Am J Physiol Lung Cell Mol Physiol* 2012; **303**: L20-L32 [PMID: 22523283 DOI: 10.1152/ajplung.00300.2011]
- 23 Al-Shmangani HS, Moate RM, Macnaughton PD, Sneyd JR, Moody AJ. Effects of hyperoxia on the permeability of 16HBE14o- cell monolayers—the protective role of antioxidant vitamins E and C. *FEBS J* 2013; **280**: 4512-4521 [PMID: 23809212 DOI: 10.1111/febs.12413]
- 24 Mo SJ, Son EW, Rhee DK, Pyo S. Modulation of TNF- $\alpha$ -induced ICAM-1 expression, NO and H<sub>2</sub>O<sub>2</sub> production by alginate, allicin and ascorbic acid in human endothelial cells. *Arch Pharm Res* 2003; **26**: 244-251 [PMID: 12723939 DOI: 10.1007/BF02976837]
- 25 Scioli MG, Bielli A, Agostinelli S, Tarquini C, Arcuri G, Ferlosio A, Costanza G, Doldo E, Orlandi A. Antioxidant treatment prevents serum deprivation- and TNF- $\alpha$ -induced endothelial dysfunction through the inhibition of NADPH oxidase 4 and the restoration of  $\beta$ -oxidation. *J Vasc Res* 2014; **51**: 327-337 [PMID: 25401479 DOI: 10.1159/000365926]
- 26 Kaufmann PA, Gnecci-Ruscone T, di Terlizzi M, Schäfers KP, Lüscher TF, Camici PG. Coronary heart disease in smokers: vitamin C restores coronary microcirculatory function. *Circulation* 2000; **102**:

- 1233-1238 [PMID: 10982536 DOI: 10.1161/01.CIR.102.11.1233]
- 27 **Mohammed BM**, Fisher BJ, Kraskauskas D, Ward S, Wayne JS, Brophy DF, Fowler AA 3rd, Yager DR, Natarajan R. Vitamin C promotes wound healing through novel pleiotropic mechanisms. *Int Wound J* 2016; **13**: 572-584 [PMID: 26290474 DOI: 10.1111/iwj.12484]
- 28 **Duarte TL**, Cooke MS, Jones GD. Gene expression profiling reveals new protective roles for vitamin C in human skin cells. *Free Radic Biol Med* 2009; **46**: 78-87 [PMID: 18973801 DOI: 10.1016/j.freeradbiomed.2008.09.028]
- 29 **Nusgens BV**, Humbert P, Rougier A, Richard A, Lapière CM. Stimulation of collagen biosynthesis by topically applied vitamin C. *Eur J Dermatol* 2002; **12**: XXXII-XXXIV [PMID: 12120619 DOI: 10.1016/j.jaad.2006.10.175]
- 30 **Fitzpatrick RE**, Rostan EF. Double-blind, half-face study comparing topical vitamin C and vehicle for rejuvenation of photodamage. *Dermatol Surg* 2002; **28**: 231-236 [PMID: 11896774 DOI: 10.1046/j.1524-4725.2002.01129.x]
- 31 **ter Riet G**, Kessels AG, Knipschild PG. Randomized clinical trial of ascorbic acid in the treatment of pressure ulcers. *J Clin Epidemiol* 1995; **48**: 1453-1460 [PMID: 8543959 DOI: 10.1016/0895-4356(95)00053-4]
- 32 **Taylor TV**, Rimmer S, Day B, Butcher J, Dymock IW. Ascorbic acid supplementation in the treatment of pressure-sores. *Lancet* 1974; **2**: 544-546 [PMID: 4140267 DOI: 10.1016/S0140-6736(74)91874-1]
- 33 **Desneves KJ**, Todorovic BE, Cassar A, Crowe TC. Treatment with supplementary arginine, vitamin C and zinc in patients with pressure ulcers: a randomised controlled trial. *Clin Nutr* 2005; **24**: 979-987 [PMID: 16297506 DOI: 10.1016/j.clnu.2005.06.011]
- 34 **Ubbink DT**, Santema TB, Stoekenbroek RM. Systemic wound care: a meta-review of cochrane systematic reviews. *Surg Technol Int* 2014; **24**: 99-111 [PMID: 24700218]
- 35 **Langer G**, Fink A. Nutritional interventions for preventing and treating pressure ulcers. *Cochrane Database Syst Rev* 2014; **(6)**: CD003216 [PMID: 24919719 DOI: 10.1002/14651858.CD003216.pub2]
- 36 **Pekala J**, Patkowska-Sokoła B, Bodkowski R, Jamroz D, Nowakowski P, Lochyński S, Librowski T. L-carnitine--metabolic functions and meaning in humans life. *Curr Drug Metab* 2011; **12**: 667-678 [PMID: 21561431 DOI: 10.2174/138920011796504536]
- 37 **Teuwen LA**, Draoui N, Dubois C, Carmeliet P. Endothelial cell metabolism: an update anno 2017. *Curr Opin Hematol* 2017; **24**: 240-247 [PMID: 28212191 DOI: 10.1097/MOH.0000000000000335]
- 38 **Wang ZY**, Liu YY, Liu GH, Lu HB, Mao CY. L-Carnitine and heart disease. *Life Sci* 2018; **194**: 88-97 [PMID: 29241711 DOI: 10.1016/j.lfs.2017.12.015]
- 39 **Ribas GS**, Vargas CR, Wajner M. L-carnitine supplementation as a potential antioxidant therapy for inherited neurometabolic disorders. *Gene* 2014; **533**: 469-476 [PMID: 24148561 DOI: 10.1016/j.gene.2013.10.017]
- 40 **Puskarich MA**, Finkel MA, Karnovsky A, Jones AE, Trexel J, Harris BN, Stringer KA. Pharmacometabolomics of L-carnitine treatment response phenotypes in patients with septic shock. *Ann Am Thorac Soc* 2015; **12**: 46-56 [PMID: 25496487 DOI: 10.1513/AnnalsATS.201409-415OC]
- 41 **Puskarich MA**, Kline JA, Krabill V, Claremont H, Jones AE. Preliminary safety and efficacy of L-carnitine infusion for the treatment of vasopressor-dependent septic shock: a randomized control trial. *JPEN J Parenter Enteral Nutr* 2014; **38**: 736-743 [PMID: 23851424 DOI: 10.1177/0148607113495414]
- 42 **Hatamkhani S**, Karimzadeh I, Elyasi S, Farsaie S, Khalili H. Carnitine and sepsis: a review of an old clinical dilemma. *J Pharm Pharm Sci* 2013; **16**: 414-423 [PMID: 24021290 DOI: 10.18433/J3JS4C]
- 43 **Patak P**, Willenberg HS, Bornstein SR. Vitamin C is an important cofactor for both adrenal cortex and adrenal medulla. *Endocr Res* 2004; **30**: 871-875 [PMID: 15666839 DOI: 10.1081/ERC-200044126]
- 44 **Stone KJ**, Townsley BH. The effect of L-ascorbate on catecholamine biosynthesis. *Biochem J* 1973; **131**: 611-613 [PMID: 4146453 DOI: 10.1042/bj1310611]
- 45 **Bornstein SR**, Yoshida-Hiroi M, Sotiriou S, Levine M, Hartwig HG, Nussbaum RL, Eisenhofer G. Impaired adrenal catecholamine system function in mice with deficiency of the ascorbic acid transporter (SVCT2). *FASEB J* 2003; **17**: 1928-1930 [PMID: 12897061 DOI: 10.1096/fj.02-1167fje]
- 46 **May JM**, Qu ZC, Meredith ME. Mechanisms of ascorbic acid stimulation of norepinephrine synthesis in neuronal cells. *Biochem Biophys Res Commun* 2012; **426**: 148-152 [PMID: 22925890 DOI: 10.1016/j.bbrc.2012.08.054]
- 47 **Prigge ST**, Mains RE, Eipper BA, Amzel LM. New insights into copper monooxygenases and peptide amidation: structure, mechanism and function. *Cell Mol Life Sci* 2000; **57**: 1236-1259 [PMID: 11028916 DOI: 10.1007/PL00000763]
- 48 **Das D**, Sen C, Goswami A. Effect of Vitamin C on adrenal suppression by etomidate induction in patients undergoing cardiac surgery: A randomized controlled trial. *Ann Card Anaesth* 2016; **19**: 410-417 [PMID: 27397444 DOI: 10.4103/0971-9784.185522]
- 49 **Carr AC**, Shaw GM, Fowler AA, Natarajan R. Ascorbate-dependent vasopressor synthesis: a rationale for vitamin C administration in severe sepsis and septic shock? *Crit Care* 2015; **19**: 418 [PMID: 26612352 DOI: 10.1186/s13054-015-1131-2]
- 50 **Moser MA**, Chun OK. Vitamin C and Heart Health: A Review Based on Findings from Epidemiologic Studies. *Int J Mol Sci* 2016; **17**: E1328 [PMID: 27529239 DOI: 10.3390/ijms17081328]
- 51 **McDonald CI**, Fraser JF, Coombes JS, Fung YL. Oxidative stress during extracorporeal circulation. *Eur J Cardiothorac Surg* 2014; **46**: 937-943 [PMID: 24482384 DOI: 10.1093/ejcts/etz637]
- 52 **Wilson JX**. Mechanism of action of vitamin C in sepsis: ascorbate modulates redox signaling in endothelium. *Biofactors* 2009; **35**: 5-13 [PMID: 19319840 DOI: 10.1002/biof.7]
- 53 **Rodemeister S**, Duquesne M, Adolph M, Nohr D, Biesalski HK, Unertl K. Massive and long-lasting decrease in vitamin C plasma levels as a consequence of extracorporeal circulation. *Nutrition* 2014; **30**: 673-678 [PMID: 24631388 DOI: 10.1016/j.nut.2013.10.026]
- 54 **Hu X**, Yuan L, Wang H, Li C, Cai J, Hu Y, Ma C. Efficacy and safety of vitamin C for atrial fibrillation after cardiac surgery: A meta-analysis with trial sequential analysis of randomized controlled trials. *Int J Surg* 2017; **37**: 58-64 [PMID: 27956113 DOI: 10.1016/j.ijsu.2016.12.009]
- 55 **Hemilä H**, Suonsyrjä T. Vitamin C for preventing atrial fibrillation in high risk patients: a systematic review and meta-analysis. *BMC Cardiovasc Disord* 2017; **17**: 49 [PMID: 28143406 DOI: 10.1186/s12872-017-0478-5]
- 56 **Antonic M**, Lipovec R, Gregorcic F, Juric P, Kosir G. Perioperative ascorbic acid supplementation does not reduce the incidence of postoperative atrial fibrillation in on-pump coronary artery bypass graft patients. *J Cardiol* 2017; **69**: 98-102 [PMID: 26917198 DOI: 10.1016/j.jjcc.2016.01.010]
- 57 **Baker WL**, Coleman CI. Meta-analysis of ascorbic acid for prevention of postoperative atrial fibrillation after cardiac surgery. *Am J Health Syst Pharm* 2016; **73**: 2056-2066 [PMID: 27806938 DOI: 10.2146/ajhp160066]
- 58 **Dehghani MR**, Majidi N, Rahmani A, Asgari B, Rezaei Y. Effect of oral vitamin C on atrial fibrillation development after isolated coronary artery bypass grafting surgery: A prospective randomized clinical trial. *Cardiol J* 2014; **21**: 492-499 [PMID: 24293167 DOI: 10.5603/CJ.a2013.0154]
- 59 **Carnes CA**, Chung MK, Nakayama T, Nakayama H, Baliga RS, Piao S, Kanderian A, Pavia S, Hamlin RL, McCarthy PM, Bauer JA, Van Wagoner DR. Ascorbate attenuates atrial pacing-induced peroxynitrite formation and electrical remodeling and decreases the incidence of postoperative atrial fibrillation. *Circ Res* 2001; **89**: E32-E38 [PMID: 11557745 DOI: 10.1161/hh1801.097644]
- 60 **Valls N**, Gormaz JG, Aguayo R, González J, Brito R, Hasson D, Libuy M, Ramos C, Carrasco R, Prieto JC, Dussaillant G, Puentes Á, Noriega V, Rodrigo R. Amelioration of persistent left ventricular function impairment through increased plasma ascorbate levels following myocardial infarction. *Redox Rep* 2016; **21**: 75-83 [PMID: 26066587 DOI: 10.1179/1351000215Y.0000000018]
- 61 **Basili S**, Tanzilli G, Mangieri E, Raparelli V, Di Santo S, Pignatelli P, Violi F. Intravenous ascorbic acid infusion improves myocardial

- perfusion grade during elective percutaneous coronary intervention: relationship with oxidative stress markers. *JACC Cardiovasc Interv* 2010; **3**: 221-229 [PMID: 20170881 DOI: 10.1016/j.jcin.2009.10.025]
- 62 **Wang ZJ**, Hu WK, Liu YY, Shi DM, Cheng WJ, Guo YH, Yang Q, Zhao YX, Zhou YJ. The effect of intravenous vitamin C infusion on periprocedural myocardial injury for patients undergoing elective percutaneous coronary intervention. *Can J Cardiol* 2014; **30**: 96-101 [PMID: 24365194 DOI: 10.1016/j.cjca.2013.08.018]
- 63 **Ramos C**, Brito R, González-Montero J, Valls N, Gormaz JG, Prieto JC, Aguayo R, Puentes Á, Noriega V, Pereira G, Palavecino T, Rodrigo R. Effects of a novel ascorbate-based protocol on infarct size and ventricle function in acute myocardial infarction patients undergoing percutaneous coronary angioplasty. *Arch Med Sci* 2017; **13**: 558-567 [PMID: 28507569 DOI: 10.5114/aoms.2016.59713]
- 64 **Marik PE**, Khangoora V, Rivera R, Hooper MH, Catravas J. Hydrocortisone, Vitamin C, and Thiamine for the Treatment of Severe Sepsis and Septic Shock: A Retrospective Before-After Study. *Chest* 2017; **151**: 1229-1238 [PMID: 27940189 DOI: 10.1016/j.chest.2016.11.036]
- 65 **Zabet MH**, Mohammadi M, Ramezani M, Khalili H. Effect of high-dose Ascorbic acid on vasopressor's requirement in septic shock. *J Res Pharm Pract* 2016; **5**: 94-100 [PMID: 27162802 DOI: 10.4103/2279-042X.179569]
- 66 **Tanaka H**, Matsuda T, Miyagantani Y, Yukioka T, Matsuda H, Shimazaki S. Reduction of resuscitation fluid volumes in severely burned patients using ascorbic acid administration: a randomized, prospective study. *Arch Surg* 2000; **135**: 326-331 [PMID: 10722036 DOI: 10.1001/archsurg.135.3.326]
- 67 **Fowler AA**, Syed AA, Knowlson S, Sculthorpe R, Farthing D, DeWilde C, Farthing CA, Larus TL, Martin E, Brophy DF, Gupta S; Medical Respiratory Intensive Care Unit Nursing, Fisher BJ, Natarajan R. Phase I safety trial of intravenous ascorbic acid in patients with severe sepsis. *J Transl Med* 2014; **12**: 32 [PMID: 24484547 DOI: 10.1186/1479-5876-12-32]
- 68 **de Grooth HJ**, Manubulu-Choo WP, Zandvliet AS, Spoelstra-de Man AME, Girbes AR, Swart EL, Oudemans-van Straaten HM. Vitamin C Pharmacokinetics in Critically Ill Patients: A Randomized Trial of Four IV Regimens. *Chest* 2018; **153**: 1368-1377 [PMID: 29522710 DOI: 10.1016/j.chest.2018.02.025]
- 69 **Saffle JL**. The phenomenon of "fluid creep" in acute burn resuscitation. *J Burn Care Res* 2007; **28**: 382-395 [PMID: 17438489 DOI: 10.1097/BCR.0b013e318053D3A1]
- 70 **Saffle JR**. Fluid Creep and Over-resuscitation. *Crit Care Clin* 2016; **32**: 587-598 [PMID: 27600130 DOI: 10.1016/j.ccc.2016.06.007]
- 71 **Rizzo JA**, Rowan MP, Driscoll IR, Chung KK, Friedman BC. Vitamin C in Burn Resuscitation. *Crit Care Clin* 2016; **32**: 539-546 [PMID: 27600125 DOI: 10.1016/j.ccc.2016.06.003]
- 72 **Cartotto R**, Greenhalgh DG, Cancio C. Burn State of the Science: Fluid Resuscitation. *J Burn Care Res* 2017; **38**: e596-e604 [PMID: 28328669 DOI: 10.1097/BCR.0000000000000541]
- 73 **Kremer T**, Harenberg P, Hernekamp F, Riedel K, Gebhardt MM, Germann G, Heitmann C, Walther A. High-dose vitamin C treatment reduces capillary leakage after burn plasma transfer in rats. *J Burn Care Res* 2010; **31**: 470-479 [PMID: 20354446 DOI: 10.1097/BCR.0b013e3181db5199]
- 74 **Matsuda T**, Tanaka H, Williams S, Hanumadass M, Abcarian H, Reyes H. Reduced fluid volume requirement for resuscitation of third-degree burns with high-dose vitamin C. *J Burn Care Rehabil* 1991; **12**: 525-532 [PMID: 1779006 DOI: 10.1097/00004630-199111000-00007]
- 75 **Matsuda T**, Tanaka H, Yuasa H, Forrest R, Matsuda H, Hanumadass M, Reyes H. The effects of high-dose vitamin C therapy on postburn lipid peroxidation. *J Burn Care Rehabil* 1993; **14**: 624-629 [PMID: 8300697 DOI: 10.1097/00004630-199311000-00007]
- 76 **Dubick MA**, Williams C, Eljio GI, Kramer GC. High-dose vitamin C infusion reduces fluid requirements in the resuscitation of burn-injured sheep. *Shock* 2005; **24**: 139-144 [PMID: 16044084 DOI: 10.1097/01.shk.0000170355.26060.e6]
- 77 **Kahn SA**, Beers RJ, Lentz CW. Resuscitation after severe burn injury using high-dose ascorbic acid: a retrospective review. *J Burn Care Res* 2011; **32**: 110-117 [PMID: 21131846 DOI: 10.1097/BCR.0b013e318204b336]
- 78 **Hrsfmmy T**. The Effects of Topical Vitamin C Solution on Burn Wounds Granulation: A Randomized Clinical Trial. *J Biomed Health* 2016; **1**: 1-5 [DOI: 10.5812/JMB.8301]
- 79 **Lamarche J**, Nair R, Peguero A, Courville C. Vitamin C-induced oxalate nephropathy. *Int J Nephrol* 2011; **2011**: 146927 [PMID: 21603151 DOI: 10.4061/2011/146927]
- 80 **Rathi S**, Kern W, Lau K. Vitamin C-induced hyperoxaluria causing reversible tubulointerstitial nephritis and chronic renal failure: a case report. *J Med Case Rep* 2007; **1**: 155 [PMID: 18042297 DOI: 10.1186/1752-1947-1-155]
- 81 **Donnino M**. Ascorbic Acid, Corticosteroids, and Thiamine in Sepsis (ACTS) Trial. [accessed 2018 Aug 8]. In: ClinicalTrials.gov [Internet]. Bethesda (MD): U.S. National Library of Medicine. Available from: URL: <https://clinicaltrials.gov/ct2/show/NCT03389555> ClinicalTrials.gov Identifier: NCT01750697
- 82 **Stefanovic S**. The Effect of Vitamin C, Thiamine and Hydrocortisone on Clinical Course and Outcome in Patients With Severe Sepsis and Septic Shock. [accessed 2018 Aug 8]. In: ClinicalTrials.gov [Internet]. Bethesda (MD): U.S. National Library of Medicine. Available from: URL: <https://clinicaltrials.gov/ct2/show/NCT03335124> ClinicalTrials.gov Identifier: NCT03335124
- 83 **Zhujiang Hospital**. Hydrocortisone, Vitamin C, and Thiamine for the Treatment of Sepsis and Septic Shock (HYVCTSSS). [accessed 2018 Aug 8]. In: ClinicalTrials.gov [Internet]. Bethesda (MD): U.S. National Library of Medicine. Available from: URL: <https://clinicaltrials.gov/ct2/show/NCT03258684> ClinicalTrials.gov Identifier: NCT03258684
- 84 **De Pasqualini CD**. The effect of ascorbic acid on hemorrhagic shock in the guinea pig. *Am J Physiol* 1946; **147**: 598-601 [PMID: 21002954 DOI: 10.1152/ajplegacy.1946.147.3.598]
- 85 **Strawitz JG**, Temple RL, Hift H. The effect of methylene blue and ascorbic acid in hemorrhagic shock. *Surg Forum* 1958; **9**: 54-58 [PMID: 13635308]
- 86 **Gomez OA**, Santome JA. ASCORBIC Acid And Hemorrhagic Shock. II. Changes In The Whole Adrenal Gland And In The Adrenal Cortex. *Acta Physiol Lat Am* 1963; **13**: 155-158 [PMID: 14098044]
- 87 **Santome JA**, Gomez OA. Ascorbic Acid And Hemorrhagic Shock. I. Changes In Plasma And In Whole Blood. *Acta Physiol Lat Am* 1963; **13**: 150-154 [PMID: 14098043]
- 88 **Reynolds PS**, Fisher BJ, McCarter J, Sweeney C, Martin EJ, Middleton P, Ellenberg M, Fowler E, Brophy DF, Fowler AA 3rd, Spiess BD, Natarajan R. Interventional vitamin C: A strategy for attenuation of coagulopathy and inflammation in a swine multiple injuries model. *J Trauma Acute Care Surg* 2018; **85**: S57-S67 [PMID: 29538225 DOI: 10.1097/TA.0000000000001844]
- 89 **Qi MZ**, Yao Y, Xie RL, Sun SL, Sun WW, Wang JL, Chen Y, Zhao B, Chen EZ, Mao EQ. Intravenous Vitamin C attenuates hemorrhagic shock-related renal injury through the induction of SIRT1 in rats. *Biochem Biophys Res Commun* 2018; **501**: 358-364 [PMID: 29673592 DOI: 10.1016/j.bbrc.2018.04.111]
- 90 **Ma L**, Fei J, Chen Y, Zhao B, Yang ZT, Wang L, Sheng HQ, Chen EZ, Mao EQ. Vitamin C Attenuates Hemorrhagic Shock-induced Dendritic Cell-specific Intercellular Adhesion Molecule 3-grabbing Nonintegrin Expression in Tubular Epithelial Cells and Renal Injury in Rats. *Chin Med J (Engl)* 2016; **129**: 1731-1736 [PMID: 27411463 DOI: 10.4103/0366-6999.185868]
- 91 **Zhao B**, Fei J, Chen Y, Ying YL, Ma L, Song XQ, Huang J, Chen EZ, Mao EQ. Vitamin C treatment attenuates hemorrhagic shock related multi-organ injuries through the induction of heme oxygenase-1. *BMC Complement Altern Med* 2014; **14**: 442 [PMID: 25387896 DOI: 10.1186/1472-6882-14-442]
- 92 **Zhao B**, Fei J, Chen Y, Ying YL, Ma L, Song XQ, Wang L, Chen EZ, Mao EQ. Pharmacological preconditioning with vitamin C attenuates intestinal injury via the induction of heme oxygenase-1 after hemorrhagic shock in rats. *PLoS One* 2014; **9**: e99134 [PMID: 24927128 DOI: 10.1371/journal.pone.0099134]
- 93 **Ekman T**, Risberg B, Bagge U. Ascorbate reduces gastric bleeding after hemorrhagic shock and retransfusion in rats. *Eur Surg Res* 1994;



- 26: 187-193 [PMID: 8005179 DOI: 10.1159/000129335]
- 94 **Bhandari B**, Kohli SK, Lal V. Protective role of ascorbic acid in hemorrhage-induced cardiovascular depression. *Indian J Physiol Pharmacol* 2014; **58**: 371-375 [PMID: 26215003]
- 95 **Minor T**, Niessen F, Klauke H, Isselhard W. No evidence for a protective effect of ascorbic acid on free radical generation and liver injury after hemorrhagic shock in rats. *Shock* 1996; **5**: 280-283 [PMID: 8721388 DOI: 10.1097/00024382-199604000-00008]
- 96 **Daughters K**, Waxman K, Gassel A, Zommer S. Anti-oxidant treatment for shock: vitamin E but not vitamin C improves survival. *Am Surg* 1996; **62**: 789-792 [PMID: 8813156]
- 97 **Carr AC**, McCall C. The role of vitamin C in the treatment of pain: new insights. *J Transl Med* 2017; **15**: 77 [PMID: 28410599 DOI: 10.1186/s12967-017-1179-7]
- 98 **Mikirova N**, Casciari J, Rogers A, Taylor P. Effect of high-dose intravenous vitamin C on inflammation in cancer patients. *J Transl Med* 2012; **10**: 189 [PMID: 22963460 DOI: 10.1186/1479-5876-10-189]
- 99 **Schencking M**, Sandholzer H, Frese T. Intravenous administration of vitamin C in the treatment of herpetic neuralgia: two case reports. *Med Sci Monit* 2010; **16**: CS58-CS61 [PMID: 20424557]
- 100 **Byun SH**, Jeon Y. Administration of Vitamin C in a Patient with Herpes Zoster - A case report -. *Korean J Pain* 2011; **24**: 108-111 [PMID: 21716609 DOI: 10.3344/kjp.2011.24.2.108]
- 101 **Schencking M**, Vollbracht C, Weiss G, Lebert J, Biller A, Goyvaerts B, Kraft K. Intravenous vitamin C in the treatment of shingles: results of a multicenter prospective cohort study. *Med Sci Monit* 2012; **18**: CR215-CR224 [PMID: 22460093 DOI: 10.12659/MSM.882621]
- 102 **Kim MS**, Kim DJ, Na CH, Shin BS. A Study of Intravenous Administration of Vitamin C in the Treatment of Acute Herpetic Pain and Postherpetic Neuralgia. *Ann Dermatol* 2016; **28**: 677-683 [PMID: 27904265 DOI: 10.5021/ad.2016.28.6.677]
- 103 **Chen JY**, Chang CY, Feng PH, Chu CC, So EC, Hu ML. Plasma vitamin C is lower in postherpetic neuralgia patients and administration of vitamin C reduces spontaneous pain but not brush-evoked pain. *Clin J Pain* 2009; **25**: 562-569 [PMID: 19692796 DOI: 10.1097/AJP.0b013e318193cf32]
- 104 **Besse JL**, Gadeyne S, Galand-Desmé S, Lerat JL, Moyen B. Effect of vitamin C on prevention of complex regional pain syndrome type I in foot and ankle surgery. *Foot Ankle Surg* 2009; **15**: 179-182 [PMID: 19840748 DOI: 10.1016/j.fas.2009.02.002]
- 105 **Zollinger PE**, Tuinebreijer WE, Kreis RW, Breederveld RS. Effect of vitamin C on frequency of reflex sympathetic dystrophy in wrist fractures: a randomized trial. *Lancet* 1999; **354**: 2025-2028 [PMID: 10636366 DOI: 10.1016/S0140-6736(99)03059-7]
- 106 **Cazeneuve JF**, Leborgne JM, Kermad K, Hassan Y. [Vitamin C and prevention of reflex sympathetic dystrophy following surgical management of distal radius fractures]. *Acta Orthop Belg* 2002; **68**: 481-484 [PMID: 12584978]
- 107 **Zollinger PE**, Tuinebreijer WE, Breederveld RS, Kreis RW. Can vitamin C prevent complex regional pain syndrome in patients with wrist fractures? A randomized, controlled, multicenter dose-response study. *J Bone Joint Surg Am* 2007; **89**: 1424-1431 [PMID: 17606778 DOI: 10.2106/JBJS.F.01147]
- 108 **Jensen NH**. [Reduced pain from osteoarthritis in hip joint or knee joint during treatment with calcium ascorbate. A randomized, placebo-controlled cross-over trial in general practice]. *Ugeskr Laeger* 2003; **165**: 2563-2566 [PMID: 12854267]
- 109 **Lee GW**, Yang HS, Yeom JS, Ahn MW. The Efficacy of Vitamin C on Postoperative Outcomes after Posterior Lumbar Interbody Fusion: A Randomized, Placebo-Controlled Trial. *Clin Orthop Surg* 2017; **9**: 317-324 [PMID: 28861199 DOI: 10.4055/cios.2017.9.3.317]
- 110 **Carr AC**, Vissers MC, Cook J. Relief from cancer chemotherapy side effects with pharmacologic vitamin C. *N Z Med J* 2014; **127**: 66-70 [PMID: 24481389]
- 111 **Carr AC**, Vissers MC, Cook J. Parenteral vitamin C for palliative care of terminal cancer patients. *N Z Med J* 2014; **127**: 84-86 [PMID: 24997468]
- 112 **Ma Y**, Chapman J, Levine M, Polireddy K, Drisko J, Chen Q. High-dose parenteral ascorbate enhanced chemosensitivity of ovarian cancer and reduced toxicity of chemotherapy. *Sci Transl Med* 2014; **6**: 222ra18 [PMID: 24500406 DOI: 10.1126/scitranslmed.3007154]
- 113 **Hoffer LJ**, Robitaille L, Zakarian R, Melnychuk D, Kavan P, Agulnik J, Cohen V, Small D, Miller WH Jr. High-dose intravenous vitamin C combined with cytotoxic chemotherapy in patients with advanced cancer: a phase I-II clinical trial. *PLoS One* 2015; **10**: e0120228 [PMID: 25848948 DOI: 10.1371/journal.pone.0120228]
- 114 **Stephenson CM**, Levin RD, Spector T, Lis CG. Phase I clinical trial to evaluate the safety, tolerability, and pharmacokinetics of high-dose intravenous ascorbic acid in patients with advanced cancer. *Cancer Chemother Pharmacol* 2013; **72**: 139-146 [PMID: 23670640 DOI: 10.1007/s00280-013-2179-9]
- 115 **Ragnhammar P**, Hafström L, Nygren P, Glimelius B; SBU-group. Swedish Council of Technology Assessment in Health Care. A systematic overview of chemotherapy effects in colorectal cancer. *Acta Oncol* 2001; **40**: 282-308 [PMID: 11441937 DOI: 10.1080/02841860151116367]
- 116 **Murata A**, Morishige F, Yamaguchi H. Prolongation of survival times of terminal cancer patients by administration of large doses of ascorbate. *Int J Vitam Nutr Res Suppl* 1982; **23**: 103-113 [PMID: 6811475]
- 117 **Pinkerton E**, Good P, Gibbons K, Hardy J. An open-label pilot study of oral vitamin C as an opioid-sparing agent in patients with chronic pain secondary to cancer. *Support Care Cancer* 2017; **25**: 341-343 [PMID: 27815713 DOI: 10.1007/s00520-016-3472-z]
- 118 **Cameron E**, Campbell A. The orthomolecular treatment of cancer. II. Clinical trial of high-dose ascorbic acid supplements in advanced human cancer. *Chem Biol Interact* 1974; **9**: 285-315 [PMID: 4430016 DOI: 10.1016/0009-2797(74)90019-2]
- 119 **Günes-Bayır A**, Kiziltan HS. Palliative Vitamin C Application in Patients with Radiotherapy-Resistant Bone Metastases: A Retrospective Study. *Nutr Cancer* 2015; **67**: 921-925 [PMID: 26168394 DOI: 10.1080/01635581.2015.1055366]
- 120 **Mayland CR**, Bennett MI, Allan K. Vitamin C deficiency in cancer patients. *Palliat Med* 2005; **19**: 17-20 [PMID: 15690864 DOI: 10.1191/0269216305pm9700a]
- 121 **Herberg S**, Galan P, Preziosi P, Bertrais S, Mennen L, Malvy D, Roussel AM, Favier A, Briançon S. The SU.VI.MAX Study: a randomized, placebo-controlled trial of the health effects of antioxidant vitamins and minerals. *Arch Intern Med* 2004; **164**: 2335-2342 [PMID: 15557412 DOI: 10.1001/archinte.164.21.2335]
- 122 **Greenberg ER**, Baron JA, Tosteson TD, Freeman DH Jr, Beck GJ, Bond JH, Colacchio TA, Collier JA, Frankl HD, Haile RW. A clinical trial of antioxidant vitamins to prevent colorectal adenoma. Polyp Prevention Study Group. *N Engl J Med* 1994; **331**: 141-147 [PMID: 8008027 DOI: 10.1056/NEJM199407213310301]
- 123 **Wang L**, Sesso HD, Glynn RJ, Christen WG, Bubes V, Manson JE, Buring JE, Gaziano JM. Vitamin E and C supplementation and risk of cancer in men: posttrial follow-up in the Physicians' Health Study II randomized trial. *Am J Clin Nutr* 2014; **100**: 915-923 [PMID: 25008853 DOI: 10.3945/ajcn.114.085480]
- 124 **King TM**, Trizna Z, Wu X, Amos CI, Fueger RH, Fueger JJ, Fritsche HA, Hsu TC, Winn R, Spitz MR. A clinical trial to evaluate the effect of vitamin C supplementation on in vitro mutagen sensitivity. The University of Texas M. D. Anderson Clinical Community Oncology Program Network. *Cancer Epidemiol Biomarkers Prev* 1997; **6**: 537-542 [PMID: 9232342]
- 125 **Cimmino L**, Dolgalev I, Wang Y, Yoshimi A, Martin GH, Wang J, Ng V, Xia B, Witkowski MT, Mitchell-Flack M, Grillo I, Bakogianni S, Ndiaye-Lobry D, Martin MT, Guillamot M, Banh RS, Xu M, Figueroa ME, Dickens RA, Abdel-Wahab O, Park CY, Tsigos A, Neel BG, Aifantis I. Restoration of TET2 Function Blocks Aberrant Self-Renewal and Leukemia Progression. *Cell* 2017; **170**: 1079-1095.e20 [PMID: 28823558 DOI: 10.1016/j.cell.2017.07.032]
- 126 **Wang C**, Lv H, Yang W, Li T, Fang T, Lv G, Han Q, Dong L, Jiang T, Jiang B, Yang G, Wang H. SVCT-2 determines the sensitivity to ascorbate-induced cell death in cholangiocarcinoma cell lines and patient derived xenografts. *Cancer Lett* 2017; **398**: 1-11 [PMID: 28385602 DOI: 10.1016/j.canlet.2017.03.039]
- 127 **Yang GT**, Chou PL, Hung YT, Chen JN, Chang WJ, Yu YL, Wei



- CW. Vitamin C enhances anticancer activity in methotrexate-treated Hep3B hepatocellular carcinoma cells. *Oncol Rep* 2014; **32**: 1057-1063 [PMID: 24969544 DOI: 10.3892/or.2014.3289]
- 128 **Martinotti S**, Ranzato E, Burlando B. In vitro screening of synergistic ascorbate-drug combinations for the treatment of malignant mesothelioma. *Toxicol In Vitro* 2011; **25**: 1568-1574 [PMID: 21645609 DOI: 10.1016/j.tiv.2011.05.023]
- 129 **Herst PM**, Broadley KW, Harper JL, McConnell MJ. Pharmacological concentrations of ascorbate radiosensitize glioblastoma multiforme primary cells by increasing oxidative DNA damage and inhibiting G2/M arrest. *Free Radic Biol Med* 2012; **52**: 1486-1493 [PMID: 22342518 DOI: 10.1016/j.freeradbiomed.2012.01.021]
- 130 **Ong PS**, Chan SY, Ho PC. Differential augmentative effects of buthionine sulfoximine and ascorbic acid in As2O3-induced ovarian cancer cell death: oxidative stress-independent and -dependent cytotoxic potentiation. *Int J Oncol* 2011; **38**: 1731-1739 [PMID: 21455570 DOI: 10.3892/ijo.2011.986]
- 131 **Heaney ML**, Gardner JR, Karasavvas N, Golde DW, Scheinberg DA, Smith EA, O'Connor OA. Vitamin C antagonizes the cytotoxic effects of antineoplastic drugs. *Cancer Res* 2008; **68**: 8031-8038 [PMID: 18829561 DOI: 10.1158/0008-5472.CAN-08-1490]
- 132 **Park CH**, Bergsagel DE, McCulloch EA. Ascorbic acid: a culture requirement for colony formation by mouse plasmacytoma cells. *Science* 1971; **174**: 720-722 [PMID: 5123422 DOI: 10.1126/science.174.4010.720]
- 133 **Park CH**, Kimler BF, Bodensteiner D, Lynch SR, Hassanein RS. In vitro growth modulation by L-ascorbic acid of colony-forming cells from bone marrow of patients with myelodysplastic syndromes. *Cancer Res* 1992; **52**: 4458-4466 [PMID: 1643638]
- 134 **Guaiquil VH**, Vera JC, Golde DW. Mechanism of vitamin C inhibition of cell death induced by oxidative stress in glutathione-depleted HL-60 cells. *J Biol Chem* 2001; **276**: 40955-40961 [PMID: 11533037 DOI: 10.1074/jbc.M106878200]
- 135 **Kim K**, Bae ON, Koh SH, Kang S, Lim KM, Noh JY, Shin S, Kim I, Chung JH. High-Dose Vitamin C Injection to Cancer Patients May Promote Thrombosis Through Procoagulant Activation of Erythrocytes. *Toxicol Sci* 2015; **147**: 350-359 [PMID: 26139164 DOI: 10.1093/toxsci/kfv133]
- 136 **Creagan ET**, Moertel CG, O'Fallon JR, Schutt AJ, O'Connell MJ, Rubin J, Frytak S. Failure of high-dose vitamin C (ascorbic acid) therapy to benefit patients with advanced cancer. A controlled trial. *N Engl J Med* 1979; **301**: 687-690 [PMID: 384241 DOI: 10.1056/NEJM197909273011303]
- 137 **Moertel CG**, Fleming TR, Creagan ET, Rubin J, O'Connell MJ, Ames MM. High-dose vitamin C vs placebo in the treatment of patients with advanced cancer who have had no prior chemotherapy. A randomized double-blind comparison. *N Engl J Med* 1985; **312**: 137-141 [PMID: 3880867 DOI: 10.1056/NEJM198501173120301]

**P- Reviewer:** Lin JA, Llompert-Pou JA, Kumar N, Willms DC  
**S- Editor:** Ma YJ **L- Editor:** Filipodia **E- Editor:** Yin SY



## Respiratory failure in the hematopoietic stem cell transplant recipient

Patrick M Wieruszewski, Svetlana Herasevich, Ognjen Gajic, Hemang Yadav

Patrick M Wieruszewski, Department of Pharmacy, Mayo Clinic, Rochester, MN 55905, United States

Patrick M Wieruszewski, Svetlana Herasevich, Ognjen Gajic, Hemang Yadav, Multidisciplinary Epidemiology and Translational Research in Intensive Care Group, Mayo Clinic, Rochester, MN 55905, United States

Svetlana Herasevich, Department of Anesthesiology, Mayo Clinic, Rochester, MN 55905, United States

Ognjen Gajic, Hemang Yadav, Division of Pulmonary and Critical Care Medicine, Mayo Clinic, Rochester, MN 55905, United States

ORCID number: Patrick M Wieruszewski (0000-0002-5871-5186); Svetlana Herasevich (0000-0003-0525-9364); Ognjen Gajic (0000-0003-4218-0890); Hemang Yadav (0000-0002-1889-2524).

**Author contributions:** Wieruszewski PM generated the figures and wrote the manuscript; Herasevich S, Gajic O and Yadav H contributed to writing of the manuscript, provided intellectual contribution to the content, and made critical revisions; all authors reviewed and approved the final version of the manuscript.

**Conflict-of-interest statement:** Authors declare no conflict of interests for this article.

**Open-Access:** This article is an open-access article which was selected by an in-house editor and fully peer-reviewed by external reviewers. It is distributed in accordance with the Creative Commons Attribution Non Commercial (CC BY-NC 4.0) license, which permits others to distribute, remix, adapt, build upon this work non-commercially, and license their derivative works on different terms, provided the original work is properly cited and the use is non-commercial. See: <http://creativecommons.org/licenses/by-nc/4.0/>

**Manuscript source:** Invited manuscript

**Correspondence to:** Hemang Yadav, MBBS, MSc, Assistant Professor, Division of Pulmonary and Critical Care Medicine, Mayo Clinic, 200 First Street SW, Rochester, MN 55905, United States. [yadav.hemang@mayo.edu](mailto:yadav.hemang@mayo.edu)

Telephone: +1-507-2663958

Fax: +1-507-2664372

Received: August 2, 2018

Peer-review started: August 3, 2018

First decision: August 24, 2018

Revised: September 4, 2018

Accepted: October 10, 2018

Article in press: October 10, 2018

Published online: October 16, 2018

### Abstract

The number of patients receiving hematopoietic stem cell transplantation (HSCT) is rapidly rising worldwide. Despite substantial improvements in peri-transplant care, pulmonary complications resulting in respiratory failure remain a major contributor to morbidity and mortality in the post-transplant period, and represent a major barrier to the overall success of HSCT. Infectious complications include pneumonia due to bacteria, viruses, and fungi, and most commonly occur during neutropenia in the early post-transplant period. Non-infectious complications include idiopathic pneumonia syndrome, peri-engraftment respiratory distress syndrome, diffuse alveolar hemorrhage, pulmonary veno-occlusive disease, delayed pulmonary toxicity syndrome, cryptogenic organizing pneumonia, bronchiolitis obliterans syndrome, and post-transplant lymphoproliferative disorder. These complications have distinct clinical features and risk factors, occur at differing times following transplant, and contribute to morbidity and mortality.

**Key words:** Respiratory failure; Pulmonary complications; Hematopoietic stem cell transplantation; Stem cell transplant; Immunocompromised host

© The Author(s) 2018. Published by Baishideng Publishing Group Inc. All rights reserved.

**Core tip:** Respiratory failure in the hematopoietic stem cell transplant recipient is common and is a major contributor of morbidity, mortality, and healthcare utilization. Etiology may be infectious or non-infectious in nature, and in some cases these may coexist. While identification remains challenging, infectious and non-infectious syndromes have distinct clinical features and risks.

Wieruszewski PM, Herasevich S, Gajic O, Yadav H. Respiratory failure in the hematopoietic stem cell transplant recipient. *World J Crit Care Med* 2018; 7(5): 62-72 Available from: URL: <http://www.wjgnet.com/2220-3141/full/v7/i5/62.htm> DOI: <http://dx.doi.org/10.5492/wjccm.v7.i5.62>

## INTRODUCTION

Hematopoietic stem cell transplantation (HSCT) is increasingly utilized worldwide for definitive treatment of hematologic malignancy and other conditions, with over 50000 transplants performed annually<sup>[1]</sup>. During HSCT, patients undergo high dose conditioning chemotherapy and/or radiation therapy with a view to eradicate their immune system along with any residual malignant cells. Stem cells are collected beforehand and are administered after conditioning is complete to reconstitute the immune system. HSCT may be autologous (where the donor stem cells are the patient's own) or allogeneic (where the donor stem cells are from an appropriately matched donor).

The post-transplantation period is temporally separated into three phases and represents a dynamic, individualized spectrum of risk (Figure 1). The first phase is the pancytopenic phase immediately following transplantation, typically lasting 10-21 d following HSCT. Autologous transplant recipients typically engraft before allogeneic, and several peri-transplant factors such as peripheral stem cell harvest and the use of granulocyte stimulating factors in the post-transplant period promote earlier marrow recovery. The second phase occurs after neutrophil engraftment, once the absolute neutrophil count consistently exceeds 500 cells per mm<sup>3</sup>. The second phase typically lasts for the first 100 or so days following transplantation. The third phase can be considered "late" complications of transplantation, occurring more often in allogeneic transplantation where graft-versus-host effects have pulmonary manifestations. Pulmonary complications and respiratory failure are common, occurring in up to two-thirds of HSCT recipients, and are associated with significant morbidity and mortality<sup>[2-4]</sup>. These pulmonary complications can be characterized by the phase of the post-transplant period when they are most likely to occur (Figure 1). The purpose of this mini-review is to highlight the infectious and non-infectious sources of respiratory failure in the HSCT recipient.

## INITIAL APPROACH IN THE ACUTELY ILL PATIENT

Respiratory failure following HSCT presents on a spectrum

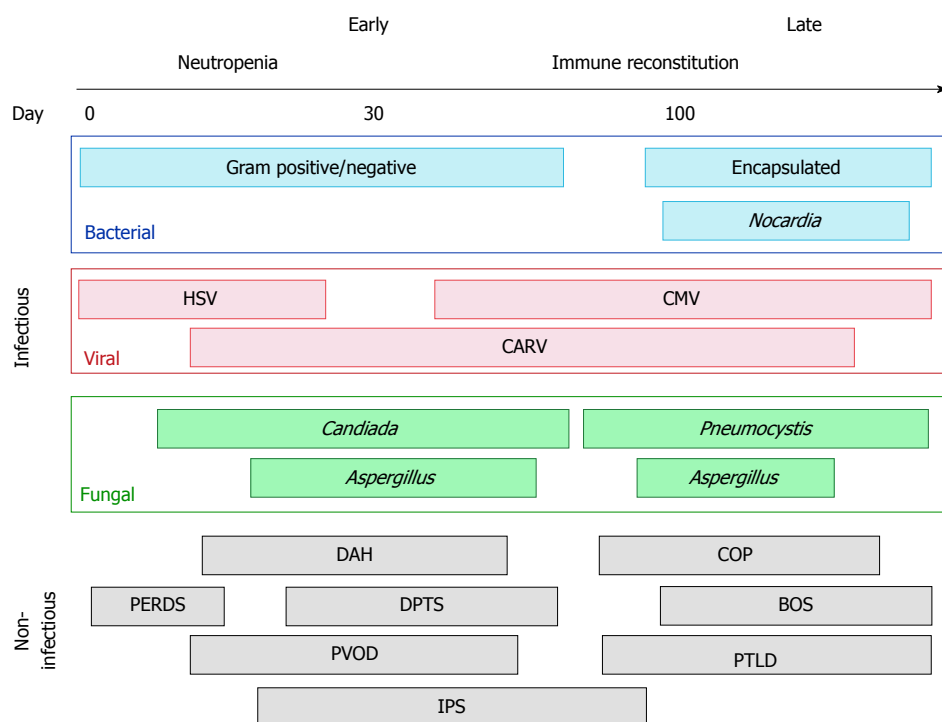
of severity. Several aspects of the clinical presentation provide clues about possible etiologies: acute versus subacute, early post-HSCT or late post-HSCT, diffuse versus focal. A substantial number of patients on the more severe end of this spectrum present with acute hypoxemic respiratory failure and diffuse pulmonary infiltrates, meeting criteria for the acute respiratory distress syndrome (ARDS)<sup>[2]</sup>. While the underlying etiology is often not known at the time of presentation, the principles of ARDS management and prevention are equally valid in this population. Specifically, this includes lung-protective mechanical ventilation with low tidal volume strategies, appropriate recruitment, and use of neuromuscular blockade where appropriate<sup>[5-7]</sup>. In addition, there should be a focus on preventing iatrogenic "second-hits" through judicious fluid and blood product administration, aspiration precautions, and early focus on mobilization and ventilator liberation<sup>[7-10]</sup>. These lung injury prevention guidelines have been conceptualized into the Checklist for Lung Injury Prevention, which was recently implemented as part of an ARDS prevention clinical trial<sup>[7,11]</sup>. Patients with pre-existing pulmonary disease are more susceptible to pulmonary complications, particularly those receiving high dose radiation to the lungs as part of their conditioning program<sup>[12,13]</sup>. Concurrently, patients should be evaluated for possible etiologies for their presentation. These can be divided broadly into infectious and non-infectious causes.

## INFECTIOUS RESPIRATORY FAILURE

Infectious pulmonary complications are most common in the immediate post-transplant period during neutropenia. Recipients of allogeneic HSCT are typically more prone to infectious pulmonary complications due to a longer period of neutropenia and the need for immunosuppressant medication administration to prevent graft-versus-host disease<sup>[14]</sup>. Routine infectious prophylaxis during neutropenia has dramatically reduced the burden of infectious complications. However, breakthrough infections can occur from a variety of causative organisms and vary dependent on patient and transplant characteristics, and time elapsed following transplant (Figure 1)<sup>[3]</sup>.

### Bacterial

Bacterial pneumonias most commonly occur in the early transplant period<sup>[15]</sup>. Risk for bacterial pneumonias in allotransplants is greater if myeloablative (as opposed to non-myeloablative or reduced intensity) conditioning is used, the patient has graft-versus-host disease, there is delayed engraftment and a prolonged period of neutropenia, or if there are indwelling devices<sup>[16-18]</sup>. In the early post-transplant period, gram-negative organisms such as *Pseudomonas aeruginosa* and *Klebsiella pneumoniae* should be suspected, whereas encapsulated organisms are a concern late after HSCT<sup>[19]</sup>. When patients develop hypoxemic respiratory failure and new pulmonary infiltrates following HSCT, infection is typically presumed. This approach is reasonable given the substantial mortality associated with delayed antimicrobial therapy in immunocompromised patients. Ideally, microbiological sampling from bronchoalveolar lavage (BAL) is preferred,



**Figure 1 Time-course of pulmonary complications following hematopoietic stem cell transplantation.** BOS: Bronchiolitis obliterans syndrome; CARV: Community-acquired respiratory viruses; CMV: Cytomegalovirus; COP: Cryptogenic organizing pneumonia; DAH: Diffuse alveolar hemorrhage; DPTS: Delayed pulmonary toxicity syndrome; HSV: Herpes simplex virus; IPS: Idiopathic pneumonia syndrome; PERDS: Peri-engraftment respiratory distress syndrome; PTLD: Post-transplant lymphoproliferative disorder; PVOD: Pulmonary veno-occlusive disease.

although the risk and benefits of invasive sampling need to be individually assessed. If patients are on antibacterial infectious prophylaxis when pneumonia is suspected, antibacterial agents should be broadened to cover nosocomial pathogens<sup>[20,21]</sup>.

Certain infectious syndromes are worthy of additional discussion. Encapsulated bacteria, particularly *Streptococcus pneumoniae*, should be suspected later following HSCT, most commonly after 6 mo<sup>[22]</sup>. Invasive pneumococcal disease has been reported to be 30 times more prevalent in HSCT recipients compared to the general population<sup>[15]</sup>, and up to 88% of cases have bacteremia<sup>[23]</sup>. *Nocardia* pneumonia can occur in the late post-transplant period, usually after 6 mo<sup>[24]</sup>. While nocardial infection is uncommon after HSCT, it should be suspected in non-responders to initial antimicrobial therapy. Sulfamethoxazole-trimethoprim is the treatment of choice and response to therapy is typically robust<sup>[24,25]</sup>. Routine use of sulfamethoxazole-trimethoprim for *Pneumocystis* prophylaxis does not adequately protect against nocardiosis. Mycobacterial pneumonia is rare, but can occur in the late post-transplant period, and typically presents one year after HSCT<sup>[26,27]</sup>. Incidence of *Mycobacteria tuberculosis* among HSCT recipients is higher in endemic areas and those receiving allogeneic grafts<sup>[27]</sup>. Presentation and management of these infections and non-tuberculous *Mycobacteria* are similar to that of the general population<sup>[27,28]</sup>.

### Viral

Herpes simplex virus (HSV) infection is relatively uncommon following HSCT due to routine infectious prophylaxis

with acyclovir<sup>[29]</sup>. HSV pneumonia typically occurs in the early post-transplant period and is a result of latent reactivation (Figure 1). Allotransplants receiving grafts from seropositive donors and those with graft-versus-host disease are at increased risk of HSV<sup>[29,30]</sup>. Diagnosis of HSV pneumonia can be challenging since low-grade HSV reactivation and viral shedding is not uncommon in critical illness, and qualitative polymerase chain reaction (PCR) on BAL samples is exquisitely sensitive.

Cytomegalovirus (CMV) pneumonia occurs in up to 30% of allotransplants and typically presents after engraftment until around 4 mo (Figure 1)<sup>[31,32]</sup>. It occurs most commonly when a seropositive allograft recipient receives a seronegative transplant. Pulmonary imaging findings are nonspecific, typically bilateral and diffuse, with both alveolar and nodular opacities<sup>[33]</sup>. BAL fluid should be analyzed to confirm the presence of CMV by PCR (most common), shell assay, or viral culture. Again, low grade CMV shedding is not uncommon in critical illness and doesn't necessarily indicate pneumonitis. Definitive diagnosis requires demonstration of tissue involvement on lung biopsy<sup>[34]</sup>, but this is rarely performed. In the presence of CMV in BAL and a compatible clinical/radiographic picture, supportive evidence of widespread CMV reactivation is usually needed before initiation of treatment. Elevated and escalating quantitative serum PCR, or evidence of CMV involvement in other organs (e.g. gut, CNS) all support systemic CMV infection. Ganciclovir is the treatment of choice for invasive CMV disease, though treatment can be limited by leukopenia,



particularly problematic among the HSCT population<sup>[35]</sup>. The epidemiology of post-HSCT CMV pneumonitis may change if novel CMV prophylactic agents are routinely administered<sup>[36]</sup>.

The community-acquired respiratory viruses (CARV) including influenza virus, parainfluenza virus, respiratory syncytial virus (RSV), adenovirus, rhinovirus, enterovirus, and coronavirus, can occur during the entire post-transplant period (Figure 1)<sup>[37]</sup>. Diagnosis occurs most commonly by nasal PCR-amplification assays, or with BAL. RSV is the most commonly isolated CARV, and is estimated to be recovered in up to a third of patients undergoing HSCT in the first three years<sup>[37-39]</sup>. In addition to hypoxia, patients typically present with fever, productive cough, and dyspnea<sup>[37,40]</sup>. Chest imaging findings include diffuse patchy alveolar opacities<sup>[40]</sup>. RSV in the HSCT population is highly morbid and has mortality rates reported up to 80%. Beyond supportive care no specific therapy has shown consistent benefit. Given the high mortality rates in HSCT recipients, high RSV titer immune globulin or aerosolized ribavirin may be considered<sup>[41]</sup>.

### Fungal

Pulmonary aspergillosis effects up to two-thirds of HSCT recipients, although incidence is declining with routine anti-*Aspergillus* prophylaxis during neutropenia and more effective treatment of graft-versus-host disease<sup>[42-44]</sup>. Pulmonary aspergillosis has been reported in upwards of 30% of HSCT recipients<sup>[3,42]</sup>. Risk factors include allogeneic transplant, unrelated donors, prolonged neutropenia, immunosuppressant use for graft-versus-host disease, and CMV infection<sup>[45-47]</sup>. Most common findings radiologically include pulmonary nodules with or without halo sign, ground glass opacities, and an air crescent sign from necrotic tissue in advanced cases<sup>[47-49]</sup>. Hemoptysis can be present and is typically associated with poor prognosis<sup>[50-52]</sup>. Diagnosis is confirmed by *Aspergillus*-specific PCR or *Aspergillus* sp. antigen in BAL<sup>[53,54]</sup>. Monotherapy with isavuconazole or voriconazole is the preferred first-line treatment and therapeutic drug monitoring should be utilized to ensure adequacy of dosing<sup>[55]</sup>. Severe cases refractory to medical therapy or recurrent hemoptysis may be considered for surgical evaluation, though lung resection is highly morbid and associated with significant mortality in this population<sup>[56]</sup>.

Incidence of *Pneumocystis jirovecii* pneumonia (PCP) has marginally declined in recent years as the use of prophylaxis has increased<sup>[57,58]</sup>. However, there is limited guidance and no consensus on which patients outside of HIV-positive individuals should receive prophylaxis, and therefore PCP remains highly relevant in HSCT recipients. Our institution routinely implements prophylaxis from engraftment until the first 100 d (or longer if patients are immunosuppressed for graft-versus host disease). PCP occurs late after HSCT and presents with acute onset severe respiratory failure<sup>[58-60]</sup>. Diagnosis is confirmed by the identification of *Pneumocystis* organisms in respiratory samples by PCR or fungal smear<sup>[58,61]</sup>. Sulfamethoxazole-trimethoprim is the treatment of choice and is highly

effective in killing *Pneumocystis* sp<sup>[58]</sup>. Patients with PCP typically die due to refractory hypoxemia from severe respiratory failure, and corticosteroids have failed to demonstrate benefit outside of the HIV population<sup>[62,63]</sup>. Nonetheless, adjunctive corticosteroids are typically administered in individuals with HSCT who develop PCP.

## NON-INFECTIOUS RESPIRATORY FAILURE

Noninfectious respiratory failure syndromes are common throughout the entire post-HSCT period, and our understanding of them remains incomplete. The risks of these syndromes vary based on transplant type, and a variety of modifiable and non-modifiable transplant and patient characteristics. In addition to key distinguishing clinical criteria, non-infectious complications are categorized by when they occur temporally following HSCT (Figure 1). Often infection cannot be ruled out at the time of initial presentation and should be concurrently treated given the substantial mortality associated with delayed antimicrobial administration.

### Peri-engraftment respiratory distress syndrome

The peri-engraftment respiratory distress syndrome (PERDS) is a pulmonary subset of the engraftment syndrome, a systemic capillary leak disorder that develops around the time of immune system reconstitution early after autologous HSCT (Figure 1)<sup>[64]</sup>. PERDS is defined as hypoxemic respiratory failure and bilateral pulmonary infiltrates that occur in the 5 d surrounding neutrophil engraftment, not fully explained by cardiac dysfunction or infection.

Focused studies of PERDS patients found an incidence of nearly 5% in autotransplants<sup>[65,66]</sup>. Case-fatality rates in excess of 20% nearly two decades ago have substantially reduced to 6% in the current era<sup>[65,66]</sup>. Risk factors include female gender, blood product administration, rapid engraftment, and HSCT for the POEMS syndrome. We recently found radiographic changes consistent with lung injury precede neutrophil engraftment and may aid in early identification of the syndrome<sup>[66]</sup>. Treatment consists of short courses of high dose corticosteroids, most commonly 1 to 2 mg/kg methylprednisolone twice daily for 3 d, followed by a rapid taper<sup>[65,67]</sup>. Response is typically prompt with improvements in oxygenation in most within 24 h of steroid initiation.

### Diffuse alveolar hemorrhage

Diffuse alveolar hemorrhage (DAH) is a syndrome characterized by diffuse, bilateral pulmonary infiltrates, progressively bloody return during BAL, and presence of > 20% hemosiderin-laden macrophages in alveolar lavage fluid<sup>[64]</sup>. While hemoptysis can be seen, it is often absent<sup>[68]</sup>. DAH mainly occurs during the early post-transplant period (Figure 1).

DAH occurs in 5%-12% of HSCT recipients and is highly morbid with reported mortality rates as high as

60% to 100%<sup>[68-72]</sup>. Risk factors include age over 40 years, higher intensity conditioning therapies, total body irradiation, and HSCT for acute leukemia and myelodysplastic syndrome<sup>[69,70,73]</sup>. Our understanding of DAH following HSCT is limited. While some cases of alveolar hemorrhage occur during the thrombocytopenic period following transplant, many cases occur after platelet counts are adequate. Also, while DAH may occur in the setting of ARDS or pneumonia, some DAH cases occur in the absence of both.

Treatment of DAH consists of high-dose corticosteroids, most commonly 500 to 1000 mg methylprednisolone per day for 5 d<sup>[70,72,74-76]</sup>. While one study showed improved survival in 8 patients treated with anti-fibrinolytic aminocaproic acid<sup>[70]</sup>, a subsequent larger study failed to show benefit<sup>[75]</sup>. Further, even in the presence of thrombocytopenia, platelet transfusion did not affect morbidity or mortality in DAH<sup>[68]</sup>.

### **Idiopathic pneumonia syndrome**

Idiopathic pneumonia syndrome (IPS) is an umbrella term for widespread alveolar injury occurring in the absence of cardiac or renal dysfunction, iatrogenic-induced circulatory overload, and infection<sup>[64]</sup>. Symptoms are consistent with ARDS and pulmonary imaging typically reveals diffuse, bilateral pulmonary infiltrates. There are many similarities and overlap in the clinical presentation of IPS and other non-infectious complications discussed in this review. Those conditions have key distinguishing features and are therefore discussed separately.

IPS effects up to 10% of HSCT recipients, more so allotransplants, and typically occurs during the early post-transplant period (Figure 1)<sup>[64]</sup>. Mortality is as high as 80% and even greater in those requiring respiratory support with the mechanical ventilator<sup>[45,64]</sup>. Risk factors include higher intensity conditioning therapies, radiation administration, allogeneic transplant, age, and the presence of graft-versus-host disease.

Treatment of IPS is controversial, and no therapy has shown favorable outcome. Corticosteroids may be administered, though while some studies have shown benefit<sup>[45,77]</sup>, others have not<sup>[78,79]</sup>. When given, higher doses (4 mg/kg per day, prednisolone equivalent) have been shown to be no better than lower doses (2 mg/kg per day or less, prednisolone equivalent), but have the potential to carry greater risk of adverse effects<sup>[45]</sup>. There has been an ongoing interest in tumor necrosis factor (TNF)- $\alpha$  inhibition due to the observation that patients with IPS have cytokine-rich BAL fluid<sup>[64]</sup>. Preliminary retrospective studies have shown promise with increased response rates and improved overall survival when TNF- $\alpha$  inhibitor, etanercept, was added to corticosteroid therapy<sup>[80,81]</sup>, though these findings were not replicated when a randomized controlled trial design as applied<sup>[82]</sup>. Further studies are needed to better phenotype what IPS truly represents, and whether any therapies can be effective.

### **Pulmonary veno-occlusive disease**

Pulmonary veno-occlusive disease (PVOD) is a rare com-

plication of HSCT with high associated mortality, typically occurring late after HSCT (Figure 1)<sup>[83-85]</sup>. PVOD should be suspected in those who are progressively dyspneic, have evidence of pulmonary hypertension in the absence of left heart failure, and imaging suggestive of pulmonary edema<sup>[64,83,85]</sup>. PVOD may occur in the absence of these and therefore, diagnosis must be confirmed by the presence of fibrous intimal proliferation of the pulmonary venules on open surgical lung biopsy<sup>[64,86]</sup>.

Due to the low incidence of PVOD following HSCT and inability to study large numbers of cases, risk factors are extrapolated from the non-HSCT population. These include viral infections, genetic predisposition, autoimmune disorders, and toxic insult to endothelia<sup>[86]</sup>. In the context of HSCT, these insults include conditioning chemotherapies bleomycin, mitomycin, and carmustine, and irradiation<sup>[86-89]</sup>. Despite their use in primary pulmonary hypertension, pulmonary vasodilators may be detrimental in PVOD and should be avoided. Dilating the pulmonary arterial vasculature in the setting of fixed venous resistance may precipitate pulmonary edema and worsen respiratory status<sup>[86]</sup>. Corticosteroids may be administered, though data is sparse<sup>[83,86]</sup>. Overall, prognosis is poor and patients may consider evaluation for lung transplantation if eligible.

### **Delayed pulmonary toxicity syndrome**

The delayed pulmonary toxicity syndrome (DPTS) is a constellation of interstitial pneumonitis and fibrosis occurring in the late transplant period, and can present years after HSCT<sup>[64]</sup>. Characteristically, DPTS appears to be confined to patients receiving high-dose chemotherapy followed by autologous stem cell rescue for breast cancer<sup>[90-93]</sup>. Accordingly, the incidence of DPTS in this specific population is reported to be as high as 72%<sup>[91]</sup>. Symptoms are non-specific and include dyspnea, fevers, and non-productive cough<sup>[64]</sup>. Similarly, chest imaging reveals bilateral interstitial infiltrates and ground glass opacities. DPTS occurs late following HSCT and can present several years following transplant (Figure 1)<sup>[90-93]</sup>. The syndrome is highly responsive to corticosteroids and typically associated with favorable outcomes<sup>[91,92]</sup>.

### **Cryptogenic organizing pneumonia**

Cryptogenic organizing pneumonia (COP) is an interstitial and airspace disease with symptoms mimicking classic pneumonia. Imaging findings include nodular lesions, ground glass attenuation, and patchy peribronchovascular, peripheral, band-like consolidative distributions<sup>[64,94]</sup>. Biopsy reveals chronic alveolar inflammation and extensive granulation of the alveolar ducts and small airways<sup>[94]</sup>. Bronchoscopy is useful to distinguish COP from infectious pneumonia, and analysis of lavage fluid reveals a predominant lymphocytosis<sup>[95]</sup>. Previously referred to as bronchiolitis obliterans-organizing pneumonia, COP is a distinct entity from the bronchiolitis obliterans syndrome (BOS), which is discussed separately and should not be confused.

COP occurs in up to 10% of HSCT recipients and typically presents late following transplant (Figure 1)<sup>[94,96]</sup>.

Risk factors include cyclophosphamide conditioning, total body irradiation, male allotransplants with a female cell donor, presence of graft-versus-host disease, and HSCT for leukemia<sup>[94,95,97]</sup>. Generally, COP is responsive to corticosteroid therapy and typical regimens include 1 mg/kg prednisone daily with an extended taper up to 6 mo<sup>[94]</sup>. Case fatality rates are reported up to 20%, and are usually due to respiratory failure in the setting of relapsed, steroid-refractory disease<sup>[97,98]</sup>.

## BOS

BOS is a slow progression of small airway obstruction believed to be a consequence of graft-versus-host disease<sup>[99]</sup>. While BOS classically manifests over months to years, abrupt decompensation and severe respiratory failure is not uncommon<sup>[100-102]</sup>. Histology will reveal intraluminal fibrosis, however yield on transbronchial biopsy is highly dependent on disease presence in the area sampled and open surgical biopsy is very high risk in this population<sup>[64,103]</sup>. Therefore in the acute setting, diagnosis is established on the basis of reduced expiratory flow with obstructive airflow and radiologic findings include hyperinflation, air trapping, and a mosaic pattern of attenuation<sup>[64,95,103]</sup>.

The incidence of BOS is estimated to be up to 20% and more likely associated with the presence of chronic graft-versus-host disease<sup>[99,104,105]</sup>. Other risk factors include elder age, reduced expiratory capacity pre-transplantation, unrelated graft donor, irradiation, and viral infection post-HSCT<sup>[99,105,106]</sup>. High-dose corticosteroids administered for weeks to months are the mainstay of treatment, though response rates are poor as BOS is irreversible, and mortality rates can be as high as 40%<sup>[4,95,99,103]</sup>. Despite extensive extrapolated use from solid organ transplant patients, macrolides have shown to worsen airflow decline-free survival in HSCT recipients<sup>[107]</sup>. Other therapies with inconclusive utility include inhaled corticosteroids, intravenous immune globulin, TNF- $\alpha$  inhibitors, cyclosporine, and tacrolimus<sup>[4]</sup>. Extracorporeal photophoresis is a promising therapy with increasing evidence suggesting its potential benefit<sup>[108,109]</sup>. Lung transplantation for advanced BOS has been reported<sup>[110-113]</sup>.

## Post-transplant lymphoproliferative disorder

Post-transplant lymphoproliferative disorder (PTLD) is a rare form of malignancy secondary to Epstein Barr virus (EBV)-infected B lymphocytes occurring in the first six months following allotransplant (Figure 1)<sup>[64,114,115]</sup>. Risk factors include T-cell depleted donors, HLA donor mismatch, T-cell depleting therapies including antithymocyte globulin and anti-CD3 antibodies, and CMV antigens<sup>[114,115]</sup>. In addition to hypoxia, symptoms are consistent with viral illness, and chest imaging reveals diffuse basal and subpleural infiltrates<sup>[64,114]</sup>. Definitive diagnosis is established when EBV-associated lymphoid proliferation is demonstrated on biopsy<sup>[64,116]</sup>. Treatment includes modulation of T-cell depleting immunosuppression and administration of rituximab, an anti-B cell antibody<sup>[117,118]</sup>.

Preliminary reports demonstrate promise of infusion of EBV-specific T-cells as a therapeutic for PTLD, though others have demonstrated resistance to such therapy<sup>[119]</sup>.

## CONCLUSION

Respiratory failure due to infectious and non-infectious complications is common following HSCT and is associated with significant mortality, especially in those necessitating mechanical ventilation. Pulmonary complications are differentiated by key distinguishing features and their time-course following transplantation. In acutely ill patients meeting ARDS criteria, routine use of best-practice lung-protective strategies is recommended even once the underlying explanation for the respiratory failure is identified.

## REFERENCES

- 1 **Niederwieser D**, Baldomero H, Szer J, Gratwohl M, Aljurf M, Atsuta Y, Bouzas LF, Confer D, Greinix H, Horowitz M, Iida M, Lipton J, Mohty M, Novitzky N, Nunez J, Passweg J, Pasquini MC, Koder A, Apperley J, Seber A, Gratwohl A. Hematopoietic stem cell transplantation activity worldwide in 2012 and a SWOT analysis of the Worldwide Network for Blood and Marrow Transplantation Group including the global survey. *Bone Marrow Transplant* 2016; **51**: 778-785 [PMID: 26901703 DOI: 10.1038/bmt.2016.18]
- 2 **Yadav H**, Nolan ME, Bohman JK, Cartin-Ceba R, Peters SG, Hogan WJ, Gajic O, Kor DJ. Epidemiology of Acute Respiratory Distress Syndrome Following Hematopoietic Stem Cell Transplantation. *Crit Care Med* 2016; **44**: 1082-1090 [PMID: 26807683 DOI: 10.1097/CCM.0000000000001617]
- 3 **Chi AK**, Soubani AO, White AC, Miller KB. An update on pulmonary complications of hematopoietic stem cell transplantation. *Chest* 2013; **144**: 1913-1922 [PMID: 24297123 DOI: 10.1378/chest.12-1708]
- 4 **Soubani AO**, Pandya CM. The spectrum of noninfectious pulmonary complications following hematopoietic stem cell transplantation. *Hematol Oncol Stem Cell Ther* 2010; **3**: 143-157 [PMID: 20890072 DOI: 10.1016/S1658-3876(10)50025-6]
- 5 **Acute Respiratory Distress Syndrome Network**, Brower RG, Matthay MA, Morris A, Schoenfeld D, Thompson BT, Wheeler A. Ventilation with lower tidal volumes as compared with traditional tidal volumes for acute lung injury and the acute respiratory distress syndrome. *N Engl J Med* 2000; **342**: 1301-1308 [PMID: 10793162 DOI: 10.1056/NEJM200005043421801]
- 6 **Amato MB**, Meade MO, Slutsky AS, Brochard L, Costa EL, Schoenfeld DA, Stewart TE, Briel M, Talmor D, Mercat A, Richard JC, Carvalho CR, Brower RG. Driving pressure and survival in the acute respiratory distress syndrome. *N Engl J Med* 2015; **372**: 747-755 [PMID: 25693014 DOI: 10.1056/NEJMsa1410639]
- 7 **Lee MJ**, Gergshengorn HB, Dinkels M, Hou P, Talmor DS, Gajic O, Gong MN, Group LIPS. Checklist for lung injury prevention (CLIP): A pilot study on implementation across multiple hospitals and multiple clinical areas. *Am J Respir Crit Care Med* 2012; **185**: A6567 [DOI: 10.1164/ajrccm-conference.2012.185.1\_MeetingAbstracts.A6567]
- 8 **Yadav H**, Thompson BT, Gajic O. Fifty Years of Research in ARDS. Is Acute Respiratory Distress Syndrome a Preventable Disease? *Am J Respir Crit Care Med* 2017; **195**: 725-736 [PMID: 28040987 DOI: 10.1164/rccm.201609-1767CI]
- 9 **Gong MN**, Schenk L, Gajic O, Mirhaji P, Sloan J, Dong Y, Festic E, Herasevich V. Early intervention of patients at risk for acute respiratory failure and prolonged mechanical ventilation with a checklist aimed at the prevention of organ failure: protocol for a pragmatic stepped-wedged cluster trial of PROOFCheck. *BMJ Open* 2016; **6**: e011347 [PMID: 27288382 DOI: 10.1136/bmjopen-2016-011347]
- 10 **National Heart, Lung, and Blood Institute Acute Respiratory**



- Distress Syndrome (ARDS) Clinical Trials Network**, Wiedemann HP, Wheeler AP, Bernard GR, Thompson BT, Hayden D, deBoisblanc B, Connors AF Jr, Hite RD, Harabin AL. Comparison of two fluid-management strategies in acute lung injury. *N Engl J Med* 2006; **354**: 2564-2575 [PMID: 16714767 DOI: 10.1056/NEJMoa062200]
- 11 **Kor DJ**, Carter RE, Park PK, Festic E, Banner-Goodspeed VM, Hinds R, Talmor D, Gajic O, Ware LB, Gong MN; US Critical Illness and Injury Trials Group: Lung Injury Prevention with Aspirin Study Group (USCITG: LIPS-A). Effect of Aspirin on Development of ARDS in At-Risk Patients Presenting to the Emergency Department: The LIPS-A Randomized Clinical Trial. *JAMA* 2016; **315**: 2406-2414 [PMID: 27179988 DOI: 10.1001/jama.2016.6330]
  - 12 **Singh AK**, Karimpour SE, Savani BN, Guion P, Hope AJ, Mansueti JR, Ning H, Altemus RM, Wu CO, Barrett AJ. Pretransplant pulmonary function tests predict risk of mortality following fractionated total body irradiation and allogeneic peripheral blood stem cell transplant. *Int J Radiat Oncol Biol Phys* 2006; **66**: 520-527 [PMID: 16965994 DOI: 10.1016/j.ijrobp.2006.05.023]
  - 13 **Parimon T**, Madtes DK, Au DH, Clark JG, Chien JW. Pretransplant lung function, respiratory failure, and mortality after stem cell transplantation. *Am J Respir Crit Care Med* 2005; **172**: 384-390 [PMID: 15894602 DOI: 10.1164/rccm.200502-212OC]
  - 14 **Coomes SM**, Hubbard LL, Moore BB. Impaired pulmonary immunity post-bone marrow transplant. *Immunol Res* 2011; **50**: 78-86 [PMID: 21170739 DOI: 10.1007/s12026-010-8200-z]
  - 15 **Kumar D**, Humar A, Plevneshi A, Siegal D, Franke N, Green K, McGeer A; Toronto Invasive Bacterial Diseases Network. Invasive pneumococcal disease in adult hematopoietic stem cell transplant recipients: a decade of prospective population-based surveillance. *Bone Marrow Transplant* 2008; **41**: 743-747 [PMID: 18176614 DOI: 10.1038/sj.bmt.1705964]
  - 16 **Soubani AO**, Miller KB, Hassoun PM. Pulmonary complications of bone marrow transplantation. *Chest* 1996; **109**: 1066-1077 [PMID: 8635332 DOI: 10.1378/chest.109.4.1066]
  - 17 **Poutsiaa DD**, Price LL, Ucuzian A, Chan GW, Miller KB, Snyderman DR. Blood stream infection after hematopoietic stem cell transplantation is associated with increased mortality. *Bone Marrow Transplant* 2007; **40**: 63-70 [PMID: 17468772 DOI: 10.1038/sj.bmt.1705690]
  - 18 **Sirithanakul K**, Salloum A, Klein JL, Soubani AO. Pulmonary complications following hematopoietic stem cell transplantation: diagnostic approaches. *Am J Hematol* 2005; **80**: 137-146 [PMID: 16184594 DOI: 10.1002/ajh.20437]
  - 19 **Lossos IS**, Breuer R, Or R, Strauss N, Elishoov H, Naparstek E, Aker M, Nagler A, Moses AE, Shapiro M. Bacterial pneumonia in recipients of bone marrow transplantation. A five-year prospective study. *Transplantation* 1995; **60**: 672-678 [PMID: 7570975 DOI: 10.1097/00007890-199510150-00010]
  - 20 **Freifeld AG**, Bow EJ, Sepkowitz KA, Boeckh MJ, Ito JI, Mullen CA, Raad II, Rolston KV, Young JA, Wingard JR; Infectious Diseases Society of America. Clinical practice guideline for the use of antimicrobial agents in neutropenic patients with cancer: 2010 update by the infectious diseases society of america. *Clin Infect Dis* 2011; **52**: e56-e93 [PMID: 21258094 DOI: 10.1093/cid/cir073]
  - 21 **Klastersky J**, de Naurois J, Rolston K, Rapoport B, Maschmeyer G, Aapro M, Herrstedt J; ESMO Guidelines Committee. Management of febrile neutropenia: ESMO Clinical Practice Guidelines. *Ann Oncol* 2016; **27**: v111-v118 [PMID: 27664247 DOI: 10.1093/annonc/mdw325]
  - 22 **Olarte L**, Lin PL, Barson WJ, Romero JR, Tan TQ, Givner LB, Hoffman JA, Bradley JS, Hultén KG, Mason EO, Kaplan SL. Invasive pneumococcal infections in children following transplantation in the pneumococcal conjugate vaccine era. *Transpl Infect Dis* 2017; **19**: e12630 [PMID: 27862712 DOI: 10.1111/tid.12630]
  - 23 **Torda A**, Chong Q, Lee A, Chen S, Dodds A, Greenwood M, Larsen S, Gilroy N. Invasive pneumococcal disease following adult allogeneic hematopoietic stem cell transplantation. *Transpl Infect Dis* 2014; **16**: 751-759 [PMID: 25040633 DOI: 10.1111/tid.12268]
  - 24 **van Burik JA**, Hackman RC, Nadeem SQ, Hiemenz JW, White MH, Flowers ME, Bowden RA. Nocardiosis after bone marrow transplantation: a retrospective study. *Clin Infect Dis* 1997; **24**: 1154-1160 [PMID: 9195074 DOI: 10.1086/513654]
  - 25 **Daly AS**, McGeer A, Lipton JH. Systemic nocardiosis following allogeneic bone marrow transplantation. *Transpl Infect Dis* 2003; **5**: 16-20 [PMID: 12791070 DOI: 10.1034/j.1399-3062.2003.00007.x]
  - 26 **Akan H**, Arslan O, Akan OA. Tuberculosis in stem cell transplant patients. *J Hosp Infect* 2006; **62**: 421-426 [PMID: 16413085 DOI: 10.1016/j.jhin.2005.09.020]
  - 27 **Russo RL**, Dulley FL, Suganuma L, França IL, Yasuda MA, Costa SF. Tuberculosis in hematopoietic stem cell transplant patients: case report and review of the literature. *Int J Infect Dis* 2010; **14** Suppl 3: e187-e191 [PMID: 19819176 DOI: 10.1016/j.ijid.2009.08.001]
  - 28 **Al-Anazi KA**, Al-Jasser AM, Al-Anazi WK. Infections caused by non-tuberculous mycobacteria in recipients of hematopoietic stem cell transplantation. *Front Oncol* 2014; **4**: 311 [PMID: 25426446 DOI: 10.3389/fonc.2014.00311]
  - 29 **Styczynski J**, Reusser P, Einsele H, de la Camara R, Cordonnier C, Ward KN, Ljungman P, Engelhard D; Second European Conference on Infections in Leukemia. Management of HSV, VZV and EBV infections in patients with hematological malignancies and after SCT: guidelines from the Second European Conference on Infections in Leukemia. *Bone Marrow Transplant* 2009; **43**: 757-770 [PMID: 19043458 DOI: 10.1038/bmt.2008.386]
  - 30 **Przybylski M**, Majewska A, Dzieciatkowski T, Rusicka P, Basak GW, Nasilowska-Adamska B, Bilinski J, Jedrzejczak WW, Wroblewska M, Halaburda K, Mlynarczyk G, Tomaszewska A. Infections due to alphaherpesviruses in early post-transplant period after allogeneic haematopoietic stem cell transplantation: Results of a 5-year survey. *J Clin Virol* 2017; **87**: 67-72 [PMID: 28033514 DOI: 10.1016/j.jcv.2016.12.008]
  - 31 **Pergam SA**, Xie H, Sandhu R, Pollack M, Smith J, Stevens-Ayers T, Ilieva V, Kimball LE, Huang ML, Hayes TS, Corey L, Boeckh MJ. Efficiency and risk factors for CMV transmission in seronegative hematopoietic stem cell recipients. *Biol Blood Marrow Transplant* 2012; **18**: 1391-1400 [PMID: 22387334 DOI: 10.1016/j.bbmt.2012.02.008]
  - 32 **Konoplev S**, Champlin RE, Giralt S, Ueno NT, Khouri I, Raad I, Rolston K, Jacobson K, Tarrand J, Luna M, Nguyen Q, Whimbey E. Cytomegalovirus pneumonia in adult autologous blood and marrow transplant recipients. *Bone Marrow Transplant* 2001; **27**: 877-881 [PMID: 11477447 DOI: 10.1038/sj.bmt.1702877]
  - 33 **Leung AN**, Gosselin MV, Napper CH, Braun SG, Hu WW, Wong RM, Gasman J. Pulmonary infections after bone marrow transplantation: clinical and radiographic findings. *Radiology* 1999; **210**: 699-710 [PMID: 10207470 DOI: 10.1148/radiology.210.3.99mr39699]
  - 34 **Ljungman P**, Griffiths P, Paya C. Definitions of cytomegalovirus infection and disease in transplant recipients. *Clin Infect Dis* 2002; **34**: 1094-1097 [PMID: 11914998 DOI: 10.1086/339329]
  - 35 **Yoshikawa T**. Betaherpesvirus Complications and Management During Hematopoietic Stem Cell Transplantation. *Adv Exp Med Biol* 2018; **1045**: 251-270 [PMID: 29896671 DOI: 10.1007/978-981-10-7230-7\_12]
  - 36 **Chemaly RF**, Ullmann AJ, Stoelben S, Richard MP, Bornhäuser M, Groth C, Einsele H, Silverman M, Mullane KM, Brown J, Nowak H, Kölling K, Stobernack HP, Lischka P, Zimmermann H, Rübsamen-Schaeff H, Champlin RE, Ehninger G; AIC246 Study Team. Letermovir for cytomegalovirus prophylaxis in hematopoietic-cell transplantation. *N Engl J Med* 2014; **370**: 1781-1789 [PMID: 24806159 DOI: 10.1056/NEJMoa1309533]
  - 37 Community-acquired respiratory viruses. *Am J Transplant* 2004; **4** Suppl 10: 105-109 [PMID: 15504224 DOI: 10.1111/j.1600-6135.2004.00734.x]
  - 38 **Lavergne V**, Ghannoum M, Weiss K, Roy J, Béliveau C. Successful prevention of respiratory syncytial virus nosocomial transmission following an enhanced seasonal infection control program. *Bone Marrow Transplant* 2011; **46**: 137-142 [PMID: 20383207 DOI: 10.1038/bmt.2010.67]
  - 39 **Chatzis O**, Darbre S, Pasquier J, Meylan P, Manuel O, Aubert JD,



- Beck-Popovic M, Masouridi-Levrat S, Ansari M, Kaiser L, Posfay-Barbe KM, Asner SA. Burden of severe RSV disease among immunocompromised children and adults: a 10 year retrospective study. *BMC Infect Dis* 2018; **18**: 111 [PMID: 29510663 DOI: 10.1186/s12879-018-3002-3]
- 40 **Ebbert JO**, Limper AH. Respiratory syncytial virus pneumonitis in immunocompromised adults: clinical features and outcome. *Respiration* 2005; **72**: 263-269 [PMID: 15942295 DOI: 10.1159/000085367]
- 41 **Ghosh S**, Champlin RE, Englund J, Giral SA, Rolston K, Raad I, Jacobson K, Neumann J, Ippoliti C, Mallik S, Whimbey E. Respiratory syncytial virus upper respiratory tract illnesses in adult blood and marrow transplant recipients: combination therapy with aerosolized ribavirin and intravenous immunoglobulin. *Bone Marrow Transplant* 2000; **25**: 751-755 [PMID: 10745261 DOI: 10.1038/sj.bmt.1702228]
- 42 **Kontoyiannis DP**, Marr KA, Park BJ, Alexander BD, Anaissie EJ, Walsh TJ, Ito J, Andes DR, Baddley JW, Brown JM, Brumble LM, Freifeld AG, Hadley S, Herwaldt LA, Kauffman CA, Knapp K, Lyon GM, Morrison VA, Papanicolaou G, Patterson TF, Perl TM, Schuster MG, Walker R, Wannemuehler KA, Wingard JR, Chiller TM, Pappas PG. Prospective surveillance for invasive fungal infections in hematopoietic stem cell transplant recipients, 2001-2006: overview of the Transplant-Associated Infection Surveillance Network (TRANSNET) Database. *Clin Infect Dis* 2010; **50**: 1091-1100 [PMID: 20218877 DOI: 10.1086/651263]
- 43 **De Pauw B**, Walsh TJ, Donnelly JP, Stevens DA, Edwards JE, Calandra T, Pappas PG, Maertens J, Lortholary O, Kauffman CA, Denning DW, Patterson TF, Maschmeyer G, Bille J, Dismukes WE, Herbrecht R, Hope WW, Kibbler CC, Kullberg BJ, Marr KA, Muñoz P, Odds FC, Perfect JR, Restrepo A, Ruhnke M, Segal BH, Sobel JD, Sorrell TC, Viscoli C, Wingard JR, Zaoutis T, Bennett JE; European Organization for Research and Treatment of Cancer/Invasive Fungal Infections Cooperative Group; National Institute of Allergy and Infectious Diseases Mycoses Study Group (EORTC/MSG) Consensus Group. Revised definitions of invasive fungal disease from the European Organization for Research and Treatment of Cancer/Invasive Fungal Infections Cooperative Group and the National Institute of Allergy and Infectious Diseases Mycoses Study Group (EORTC/MSG) Consensus Group. *Clin Infect Dis* 2008; **46**: 1813-1821 [PMID: 18462102 DOI: 10.1086/588660]
- 44 **Neofytos D**, Horn D, Anaissie E, Steinbach W, Olyaei A, Fishman J, Pfäler M, Chang C, Webster K, Marr K. Epidemiology and outcome of invasive fungal infection in adult hematopoietic stem cell transplant recipients: analysis of Multicenter Prospective Antifungal Therapy (PATH) Alliance registry. *Clin Infect Dis* 2009; **48**: 265-273 [PMID: 19115967 DOI: 10.1086/595846]
- 45 **Fukuda T**, Hackman RG, Guthrie KA, Sandmaier BM, Boeckh M, Maris MB, Maloney DG, Deeg HJ, Martin PJ, Storb RF, Madtes DK. Risks and outcomes of idiopathic pneumonia syndrome after nonmyeloablative and conventional conditioning regimens for allogeneic hematopoietic stem cell transplantation. *Blood* 2003; **102**: 2777-2785 [PMID: 12855568 DOI: 10.1182/blood-2003-05-1597]
- 46 **Marr KA**, Carter RA, Boeckh M, Martin P, Corey L. Invasive aspergillosis in allogeneic stem cell transplant recipients: changes in epidemiology and risk factors. *Blood* 2002; **100**: 4358-4366 [PMID: 12393425 DOI: 10.1182/blood-2002-05-1496]
- 47 **Salman N**, Törün SH, Budan B, Somer A. Invasive aspergillosis in hematopoietic stem cell and solid organ transplantation. *Expert Rev Anti Infect Ther* 2011; **9**: 307-315 [PMID: 21417870 DOI: 10.1586/eri.11.13]
- 48 **Carvalho-Dias VM**, Sola CB, Cunha CA, Shimakura SE, Pasquini R, Queiroz-Telles Fd. Invasive aspergillosis in hematopoietic stem cell transplant recipients: a retrospective analysis. *Braz J Infect Dis* 2008; **12**: 385-389 [PMID: 19219277 DOI: 10.1590/S1413-86702008000500008]
- 49 **Greene RE**, Schlamm HT, Oestmann JW, Stark P, Durand C, Lortholary O, Wingard JR, Herbrecht R, Ribaud P, Patterson TF, Troke PF, Denning DW, Bennett JE, de Pauw BE, Rubin RH. Imaging findings in acute invasive pulmonary aspergillosis: clinical significance of the halo sign. *Clin Infect Dis* 2007; **44**: 373-379 [PMID: 17205443 DOI: 10.1086/509917]
- 50 **Cao Y**, Shao C, Song Y. Analysis of the clinical features of invasive bronchopulmonary aspergillosis. *Clin Respir J* 2018; **12**: 1635-1643 [PMID: 29052351 DOI: 10.1111/crj.12722]
- 51 **Herbrecht R**, Natarajan-Amé S, Letscher-Bru V, Canuet M. Invasive pulmonary aspergillosis. *Semin Respir Crit Care Med* 2004; **25**: 191-202 [PMID: 16088462 DOI: 10.1055/s-2004-824903]
- 52 **Jewkes J**, Kay PH, Paneth M, Citron KM. Pulmonary aspergilloma: analysis of prognosis in relation to haemoptysis and survey of treatment. *Thorax* 1983; **38**: 572-578 [PMID: 6612647 DOI: 10.1136/thx.38.8.572]
- 53 **Lehrnbecher T**, Robinson PD, Fisher BT, Castagnola E, Groll AH, Steinbach WJ, Zaoutis TE, Negeri ZF, Beyene J, Phillips B, Sung L. Galactomannan,  $\beta$ -D-Glucan, and Polymerase Chain Reaction-Based Assays for the Diagnosis of Invasive Fungal Disease in Pediatric Cancer and Hematopoietic Stem Cell Transplantation: A Systematic Review and Meta-Analysis. *Clin Infect Dis* 2016; **63**: 1340-1348 [PMID: 27567122 DOI: 10.1093/cid/ciw592]
- 54 **Sakata KK**, Klassen CL, Bollin KB, Grys TE, Slack JL, Wesselius LJ, Vikram HR. Microbiologic yield of bronchoalveolar lavage specimens from stem cell transplant recipients. *Transpl Infect Dis* 2017; **19**: e12684 [PMID: 28218980 DOI: 10.1111/tid.12684]
- 55 **Ullmann AJ**, Aguado JM, Arkan-Akdagli S, Denning DW, Groll AH, Lagrou K, Lass-Flörl C, Lewis RE, Munoz P, Verweij PE, Warris A, Ader F, Akova M, Arendrup MC, Barnes RA, Beigelman-Aubry C, Blot S, Bouza E, Brüggemann RJM, Buchheidt D, Cadranet J, Castagnola E, Chakrabarti A, Cuenca-Estrella M, Dimopoulos G, Fortun J, Gangneux JP, Garbino J, Heinz WJ, Herbrecht R, Heussel CP, Kibbler CC, Klimko N, Kullberg BJ, Lange C, Lehrnbecher T, Löffler J, Lortholary O, Maertens J, Marchetti O, Meis JF, Pagano L, Ribaud P, Richardson M, Roilides E, Ruhnke M, Sanguinetti M, Sheppard DC, Sinkó J, Skiada A, Vehreschild MJGT, Viscoli C, Cornely OA. Diagnosis and management of Aspergillus diseases: executive summary of the 2017 ESCMID-ECMM-ERS guideline. *Clin Microbiol Infect* 2018; **24** Suppl 1: e1-e38 [PMID: 29544767 DOI: 10.1016/j.cmi.2018.01.002]
- 56 **Wu GX**, Khojabekyan M, Wang J, Tegtmeyer BR, O'Donnell MR, Kim JY, Grannis FW, Raz DJ. Survival following lung resection in immunocompromised patients with pulmonary invasive fungal infection. *Eur J Cardiothorac Surg* 2016; **49**: 314-320 [PMID: 25732975 DOI: 10.1093/ejcts/ezv026]
- 57 **Festic E**, Gajic O, Limper AH, Aksamit TR. Acute respiratory failure due to pneumocystis pneumonia in patients without human immunodeficiency virus infection: outcome and associated features. *Chest* 2005; **128**: 573-579 [PMID: 16100140 DOI: 10.1378/chest.128.2.573]
- 58 **Carmona EM**, Limper AH. Update on the diagnosis and treatment of Pneumocystis pneumonia. *Ther Adv Respir Dis* 2011; **5**: 41-59 [PMID: 20736243 DOI: 10.1177/1753465810380102]
- 59 **Yale SH**, Limper AH. Pneumocystis carinii pneumonia in patients without acquired immunodeficiency syndrome: associated illness and prior corticosteroid therapy. *Mayo Clin Proc* 1996; **71**: 5-13 [PMID: 8538233 DOI: 10.4065/71.1.5]
- 60 **De Castro N**, Neuville S, Sarfati C, Ribaud P, Derouin F, Gluckman E, Socié G, Molina JM. Occurrence of Pneumocystis jiroveci pneumonia after allogeneic stem cell transplantation: a 6-year retrospective study. *Bone Marrow Transplant* 2005; **36**: 879-883 [PMID: 16151423 DOI: 10.1038/sj.bmt.1705149]
- 61 **Thomas CF Jr**, Limper AH. Current insights into the biology and pathogenesis of Pneumocystis pneumonia. *Nat Rev Microbiol* 2007; **5**: 298-308 [PMID: 17363968 DOI: 10.1038/nrmicro1621]
- 62 **Injean P**, Eells SJ, Wu H, McElroy I, Gregson AL, McKinnell JA. A Systematic Review and Meta-Analysis of the Data Behind Current Recommendations for Corticosteroids in Non-HIV-Related PCP: Knowing When You Are on Shaky Foundations. *Transplant Direct* 2017; **3**: e137 [PMID: 28361121 DOI: 10.1097/TXD.0000000000000642]
- 63 **Wieruszewski PM**, Barreto JN, Frazee E, Daniels CE, Tosh PK, Dierkhising RA, Mara KC, Limper AH. Early Corticosteroids for

- Pneumocystis Pneumonia in Adults Without HIV Are Not Associated With Better Outcome. *Chest* 2018; pii: S0012-3692(18)30648-2 [PMID: 29705221 DOI: 10.1016/j.chest.2018.04.026]
- 64 **Panoskaltis-Mortari A**, Griese M, Madtes DK, Belperio JA, Haddad IY, Folz RJ, Cooke KR; American Thoracic Society Committee on Idiopathic Pneumonia Syndrome. An official American Thoracic Society research statement: noninfectious lung injury after hematopoietic stem cell transplantation: idiopathic pneumonia syndrome. *Am J Respir Crit Care Med* 2011; **183**: 1262-1279 [PMID: 21531955 DOI: 10.1164/rccm.2007-413ST]
  - 65 **Capizzi SA**, Kumar S, Huneke NE, Gertz MA, Inwards DJ, Litzow MR, Lacy MQ, Gastineau DA, Prakash UB, Tefferi A. Peri-engraftment respiratory distress syndrome during autologous hematopoietic stem cell transplantation. *Bone Marrow Transplant* 2001; **27**: 1299-1303 [PMID: 11548849 DOI: 10.1038/sj.bmt.1703075]
  - 66 **Wieruszewski PM**, Personett HA, Peters SG, Gajic O, Hogan WJ, Dierkhising RA, Alkhateeb H, Yadav H. The Peri-Engraftment Respiratory Distress Syndrome Following Autologous Hematopoietic Cell Transplant. *Am J Respir Crit Care Med* 2018; **197**: A5161
  - 67 **Carreras E**, Fernández-Avilés F, Silva L, Guerrero M, Fernández de Larrea C, Martínez C, Rosiñol L, Lozano M, Marín P, Rovira M. Engraftment syndrome after auto-SCT: analysis of diagnostic criteria and risk factors in a large series from a single center. *Bone Marrow Transplant* 2010; **45**: 1417-1422 [PMID: 20062097 DOI: 10.1038/bmt.2009.363]
  - 68 **Robbins RA**, Linder J, Stahl MG, Thompson AB 3rd, Haire W, Kessinger A, Armitage JO, Arneson M, Woods G, Vaughan WP. Diffuse alveolar hemorrhage in autologous bone marrow transplant recipients. *Am J Med* 1989; **87**: 511-518 [PMID: 2816966 DOI: 10.1016/S0002-9343(89)80606-0]
  - 69 **Lewis ID**, DeFor T, Weisdorf DJ. Increasing incidence of diffuse alveolar hemorrhage following allogeneic bone marrow transplantation: cryptic etiology and uncertain therapy. *Bone Marrow Transplant* 2000; **26**: 539-543 [PMID: 11019844 DOI: 10.1038/sj.bmt.1702546]
  - 70 **Wanko SO**, Broadwater G, Folz RJ, Chao NJ. Diffuse alveolar hemorrhage: retrospective review of clinical outcome in allogeneic transplant recipients treated with aminocaproic acid. *Biol Blood Marrow Transplant* 2006; **12**: 949-953 [PMID: 16920561 DOI: 10.1016/j.bbmt.2006.05.012]
  - 71 **Majhail NS**, Parks K, Defor TE, Weisdorf DJ. Diffuse alveolar hemorrhage and infection-associated alveolar hemorrhage following hematopoietic stem cell transplantation: related and high-risk clinical syndromes. *Biol Blood Marrow Transplant* 2006; **12**: 1038-1046 [PMID: 17067910 DOI: 10.1016/j.bbmt.2006.06.002]
  - 72 **Afessa B**, Tefferi A, Litzow MR, Peters SG. Outcome of diffuse alveolar hemorrhage in hematopoietic stem cell transplant recipients. *Am J Respir Crit Care Med* 2002; **166**: 1364-1368 [PMID: 12406834 DOI: 10.1164/rccm.200208-792OC]
  - 73 **Afessa B**, Tefferi A, Litzow MR, Krowka MJ, Wylam ME, Peters SG. Diffuse alveolar hemorrhage in hematopoietic stem cell transplant recipients. *Am J Respir Crit Care Med* 2002; **166**: 641-645 [PMID: 12204858 DOI: 10.1164/rccm.200112-141CC]
  - 74 **Metcalf JP**, Rennard SI, Reed EC, Haire WD, Sisson JH, Walter T, Robbins RA. Corticosteroids as adjunctive therapy for diffuse alveolar hemorrhage associated with bone marrow transplantation. University of Nebraska Medical Center Bone Marrow Transplant Group. *Am J Med* 1994; **96**: 327-334 [PMID: 8166151 DOI: 10.1016/0002-9343(94)90062-0]
  - 75 **Rathi NK**, Tanner AR, Dinh A, Dong W, Feng L, Ensor J, Wallace SK, Haque SA, Rondon G, Price KJ, Popat U, Nates JL. Low-, medium- and high-dose steroids with or without aminocaproic acid in adult hematopoietic SCT patients with diffuse alveolar hemorrhage. *Bone Marrow Transplant* 2015; **50**: 420-426 [PMID: 25531284 DOI: 10.1038/bmt.2014.287]
  - 76 **Raptis A**, Mavroudis D, Suffredini A, Molldrem J, Rhee FV, Childs R, Phang S, Barrett A. High-dose corticosteroid therapy for diffuse alveolar hemorrhage in allogeneic bone marrow stem cell transplant recipients. *Bone Marrow Transplant* 1999; **24**: 879-883 [PMID: 10516700 DOI: 10.1038/sj.bmt.1701995]
  - 77 **Griese M**, Rampf U, Hofmann D, Führer M, Reinhardt D, Bender-Götze C. Pulmonary complications after bone marrow transplantation in children: twenty-four years of experience in a single pediatric center. *Pediatr Pulmonol* 2000; **30**: 393-401 [PMID: 11064430 DOI: 10.1002/1099-0496(200011)30:5<393::AID-PPUL5>3.0.CO;2-W]
  - 78 **Crawford SW**, Hackman RC. Clinical course of idiopathic pneumonia after bone marrow transplantation. *Am Rev Respir Dis* 1993; **147**: 1393-1400 [PMID: 8503550 DOI: 10.1164/ajrccm/147.6\_Pt\_1.1393]
  - 79 **Kantrow SP**, Hackman RC, Boeckh M, Myerson D, Crawford SW. Idiopathic pneumonia syndrome: changing spectrum of lung injury after marrow transplantation. *Transplantation* 1997; **63**: 1079-1086 [PMID: 9133468 DOI: 10.1097/00007890-199704270-00006]
  - 80 **Tizon R**, Frey N, Heitjan DF, Tan KS, Goldstein SC, Hexner EO, Loren A, Luger SM, Reshef R, Tsai D, Vogl D, Davis J, Vozniak M, Fuchs B, Stadtmauer EA, Porter DL. High-dose corticosteroids with or without etanercept for the treatment of idiopathic pneumonia syndrome after allo-SCT. *Bone Marrow Transplant* 2012; **47**: 1332-1337 [PMID: 22307018 DOI: 10.1038/bmt.2011.260]
  - 81 **Thompson J**, Yin Z, D'Souza A, Fenske T, Hamadani M, Hari P, Rizzo JD, Pasquini M, Saber W, Shah N, Shaw BE, Shahir K, Banerjee A, Drobyski WR. Etanercept and Corticosteroid Therapy for the Treatment of Late-Onset Idiopathic Pneumonia Syndrome. *Biol Blood Marrow Transplant* 2017; **23**: 1955-1960 [PMID: 28757436 DOI: 10.1016/j.bbmt.2017.07.019]
  - 82 **Yanik GA**, Horowitz MM, Weisdorf DJ, Logan BR, Ho VT, Soiffer RJ, Carter SL, Wu J, Wingard JR, Difronzo NL, Ferrara JL, Giralt S, Madtes DK, Drexler R, White ES, Cooke KR. Randomized, double-blind, placebo-controlled trial of soluble tumor necrosis factor receptor: enbrel (etanercept) for the treatment of idiopathic pneumonia syndrome after allogeneic stem cell transplantation: blood and marrow transplant clinical trials network protocol. *Biol Blood Marrow Transplant* 2014; **20**: 858-864 [PMID: 24607553 DOI: 10.1016/j.bbmt.2014.02.026]
  - 83 **Hackman RC**, Madtes DK, Petersen FB, Clark JG. Pulmonary venoocclusive disease following bone marrow transplantation. *Transplantation* 1989; **47**: 989-992 [PMID: 2660361 DOI: 10.1097/00007890-198906000-00014]
  - 84 **Williams LM**, Fussell S, Veith RW, Nelson S, Mason CM. Pulmonary veno-occlusive disease in an adult following bone marrow transplantation. Case report and review of the literature. *Chest* 1996; **109**: 1388-1391 [PMID: 8625695 DOI: 10.1378/chest.109.5.1388]
  - 85 **Troussard X**, Bernaudin JF, Cordonnier C, Fleury J, Payen D, Briere J, Vernant JP. Pulmonary veno-occlusive disease after bone marrow transplantation. *Thorax* 1984; **39**: 956-957 [PMID: 6393419 DOI: 10.1136/thx.39.12.956]
  - 86 **Mandel J**, Mark EJ, Hales CA. Pulmonary veno-occlusive disease. *Am J Respir Crit Care Med* 2000; **162**: 1964-1973 [PMID: 11069841 DOI: 10.1164/ajrccm.162.5.9912045]
  - 87 **Knight BK**, Rose AG. Pulmonary veno-occlusive disease after chemotherapy. *Thorax* 1985; **40**: 874-875 [PMID: 2416075 DOI: 10.1136/thx.40.11.874]
  - 88 **Joselson R**, Warnock M. Pulmonary veno-occlusive disease after chemotherapy. *Hum Pathol* 1983; **14**: 88-91 [PMID: 6187654 DOI: 10.1016/S0046-8177(83)80052-5]
  - 89 **Doll DC**, Yarbrow JW. Vascular toxicity associated with antineoplastic agents. *Semin Oncol* 1992; **19**: 580-596 [PMID: 1411655]
  - 90 **Cao TM**, Negrin RS, Stockerl-Goldstein KE, Johnston LJ, Shizuru JA, Taylor TL, Rizk NW, Wong RM, Blume KG, Hu WW. Pulmonary toxicity syndrome in breast cancer patients undergoing BCNU-containing high-dose chemotherapy and autologous hematopoietic cell transplantation. *Biol Blood Marrow Transplant* 2000; **6**: 387-394 [PMID: 10917574 DOI: 10.1016/S1083-8791(00)70015-2]
  - 91 **Bhalla KS**, Wilczynski SW, Abushamaa AM, Petros WP, McDonald CS, Loftis JS, Chao NJ, Vredenburgh JJ, Folz RJ. Pulmonary toxicity of induction chemotherapy prior to standard or high-dose

- chemotherapy with autologous hematopoietic support. *Am J Respir Crit Care Med* 2000; **161**: 17-25 [PMID: 10619792 DOI: 10.1164/ajrccm.161.1.9903059]
- 92 **Wilczynski SW**, Erasmus JJ, Petros WP, Vredenburgh JJ, Folz RJ. Delayed pulmonary toxicity syndrome following high-dose chemotherapy and bone marrow transplantation for breast cancer. *Am J Respir Crit Care Med* 1998; **157**: 565-573 [PMID: 9476874 DOI: 10.1164/ajrccm.157.2.9705072]
  - 93 **Todd NW**, Peters WP, Ost AH, Roggli VL, Piantadosi CA. Pulmonary drug toxicity in patients with primary breast cancer treated with high-dose combination chemotherapy and autologous bone marrow transplantation. *Am Rev Respir Dis* 1993; **147**: 1264-1270 [PMID: 8484641 DOI: 10.1164/ajrccm/147.5.1264]
  - 94 **Freudenberger TD**, Madtes DK, Curtis JR, Cummings P, Storer BE, Hackman RC. Association between acute and chronic graft-versus-host disease and bronchiolitis obliterans organizing pneumonia in recipients of hematopoietic stem cell transplants. *Blood* 2003; **102**: 3822-3828 [PMID: 12869516 DOI: 10.1182/blood-2002-06-1813]
  - 95 **Yoshihara S**, Yanik G, Cooke KR, Mineishi S. Bronchiolitis obliterans syndrome (BOS), bronchiolitis obliterans organizing pneumonia (BOOP), and other late-onset noninfectious pulmonary complications following allogeneic hematopoietic stem cell transplantation. *Biol Blood Marrow Transplant* 2007; **13**: 749-759 [PMID: 17580252 DOI: 10.1016/j.bbmt.2007.05.001]
  - 96 **Patriarca F**, Skert C, Sperotto A, Damiani D, Cerno M, Geromin A, Zaja F, Stocchi R, Prosdocimo S, Fili C, Fanin R. Incidence, outcome, and risk factors of late-onset noninfectious pulmonary complications after unrelated donor stem cell transplantation. *Bone Marrow Transplant* 2004; **33**: 751-758 [PMID: 14755316 DOI: 10.1038/sj.bmt.1704426]
  - 97 **Nakasone H**, Onizuka M, Suzuki N, Fujii N, Taniguchi S, Kakihana K, Ogawa H, Miyamura K, Eto T, Sakamaki H, Yabe H, Morishima Y, Kato K, Suzuki R, Fukuda T. Pre-transplant risk factors for cryptogenic organizing pneumonia/bronchiolitis obliterans organizing pneumonia after hematopoietic cell transplantation. *Bone Marrow Transplant* 2013; **48**: 1317-1323 [PMID: 23933758 DOI: 10.1038/bmt.2013.116]
  - 98 **Afessa B**, Peters SG. Chronic lung disease after hematopoietic stem cell transplantation. *Clin Chest Med* 2005; **26**: 571-586, vi [PMID: 16263397 DOI: 10.1016/j.ccm.2005.06.012]
  - 99 **Au BK**, Au MA, Chien JW. Bronchiolitis obliterans syndrome epidemiology after allogeneic hematopoietic cell transplantation. *Biol Blood Marrow Transplant* 2011; **17**: 1072-1078 [PMID: 21126596 DOI: 10.1016/j.bbmt.2010.11.018]
  - 100 **Chan CK**, Hyland RH, Hutcheon MA, Minden MD, Alexander MA, Kossakowska AE, Urbanski SJ, Fyles GM, Fraser IM, Curtis JE. Small-airways disease in recipients of allogeneic bone marrow transplants. An analysis of 11 cases and a review of the literature. *Medicine (Baltimore)* 1987; **66**: 327-340 [PMID: 3306259 DOI: 10.1097/00005792-198709000-00001]
  - 101 **Palmas A**, Tefferi A, Myers JL, Scott JP, Swensen SJ, Chen MG, Gastineau DA, Gertz MA, Inwards DJ, Lacy MQ, Litzow MR. Late-onset noninfectious pulmonary complications after allogeneic bone marrow transplantation. *Br J Haematol* 1998; **100**: 680-687 [PMID: 9531334 DOI: 10.1046/j.1365-2141.1998.00617.x]
  - 102 **Clark JG**, Crawford SW, Madtes DK, Sullivan KM. Obstructive lung disease after allogeneic marrow transplantation. Clinical presentation and course. *Ann Intern Med* 1989; **111**: 368-376 [PMID: 2669592 DOI: 10.7326/0003-4819-111-5-368]
  - 103 **Afessa B**, Litzow MR, Tefferi A. Bronchiolitis obliterans and other late onset non-infectious pulmonary complications in hematopoietic stem cell transplantation. *Bone Marrow Transplant* 2001; **28**: 425-434 [PMID: 11593314 DOI: 10.1038/sj.bmt.1703142]
  - 104 **Curtis DJ**, Smale A, Thien F, Schwarzer AP, Szer J. Chronic airflow obstruction in long-term survivors of allogeneic bone marrow transplantation. *Bone Marrow Transplant* 1995; **16**: 169-173 [PMID: 7581118]
  - 105 **Yoshihara S**, Tateishi U, Ando T, Kunitoh H, Suyama H, Onishi Y, Tanosaki R, Mineishi S. Lower incidence of Bronchiolitis obliterans in allogeneic hematopoietic stem cell transplantation with reduced-intensity conditioning compared with myeloablative conditioning. *Bone Marrow Transplant* 2005; **35**: 1195-1200 [PMID: 15852024 DOI: 10.1038/sj.bmt.1704985]
  - 106 **Chien JW**, Martin PJ, Flowers ME, Nichols WG, Clark JG. Implications of early airflow decline after myeloablative allogeneic stem cell transplantation. *Bone Marrow Transplant* 2004; **33**: 759-764 [PMID: 14968136 DOI: 10.1038/sj.bmt.1704422]
  - 107 **Bergeron A**, Chevret S, Granata A, Chevallier P, Vincent L, Huynh A, Tabrizi R, Labussiere-Wallet H, Bernard M, Chantepie S, Bay JO, Thiebaut-Bertrand A, Thepot S, Contentin N, Fomecker LM, Maillard N, Risso K, Berceanu A, Blaise D, Peffault de La Tour R, Chien JW, Coiteux V, Socié G; ALLOZITHRO Study Investigators. Effect of Azithromycin on Airflow Decline-Free Survival After Allogeneic Hematopoietic Stem Cell Transplant: The ALLOZITHRO Randomized Clinical Trial. *JAMA* 2017; **318**: 557-566 [PMID: 28787506 DOI: 10.1001/jama.2017.9938]
  - 108 **Del Fante C**, Galasso T, Bernasconi P, Scudeller L, Ripamonti F, Perotti C, Meloni F. Extracorporeal photopheresis as a new supportive therapy for bronchiolitis obliterans syndrome after allogeneic stem cell transplantation. *Bone Marrow Transplant* 2016; **51**: 728-731 [PMID: 26726939 DOI: 10.1038/bmt.2015.324]
  - 109 **Hefazi M**, Langer KJ, Khera N, Adamski J, Roy V, Winters JL, Gastineau DA, Jacob EK, Kreuter JD, Gandhi MJ, Hogan WJ, Litzow MR, Hashmi SK, Yadav H, Iyer VN, Scott JP, Wylam ME, Cartin-Ceba R, Patnaik MM. Extracorporeal Photopheresis Improves Survival in Hematopoietic Cell Transplant Patients with Bronchiolitis Obliterans Syndrome without Significantly Impacting Measured Pulmonary Functions. *Biol Blood Marrow Transplant* 2018; pii: S1083-8791(18)30193-9 [PMID: 29679771 DOI: 10.1016/j.bbmt.2018.04.012]
  - 110 **Redel-Montero J**, Bujalance-Cabrera C, Vaquero-Barrios JM, Santos-Luna F, Arenas-De Larriva M, Moreno-Casado P, Espinosa-Jiménez D. Lung transplantation for bronchiolitis obliterans after allogeneic bone marrow transplantation. *Transplant Proc* 2010; **42**: 3023-3025 [PMID: 20970599 DOI: 10.1016/j.transproceed.2010.07.086]
  - 111 **Cheng GS**, Edelman JD, Madtes DK, Martin PJ, Flowers ME. Outcomes of lung transplantation after allogeneic hematopoietic stem cell transplantation. *Biol Blood Marrow Transplant* 2014; **20**: 1169-1175 [PMID: 24727334 DOI: 10.1016/j.bbmt.2014.04.008]
  - 112 **Soubani AO**, Kingah P, Alshabani K, Muma G, Haq A. Lung transplantation following hematopoietic stem cell transplantation: report of two cases and systematic review of literature. *Clin Transplant* 2014; **28**: 776-782 [PMID: 24754643 DOI: 10.1111/ctr.12378]
  - 113 **Rabitsch W**, Deviatko E, Keil F, Herold C, Dekan G, Greinix HT, Lechner K, Klepetko W, Kalhs P. Successful lung transplantation for bronchiolitis obliterans after allogeneic marrow transplantation. *Transplantation* 2001; **71**: 1341-1343 [PMID: 11397974 DOI: 10.1097/00007890-200105150-00028]
  - 114 **Hou HA**, Yao M, Tang JL, Chen YK, Ko BS, Huang SY, Tien HF, Chang HH, Lu MY, Lin TT, Lin KH, Hsiao CH, Lin CW, Chen YC. Poor outcome in post transplant lymphoproliferative disorder with pulmonary involvement after allogeneic hematopoietic SCT: 13 years' experience in a single institute. *Bone Marrow Transplant* 2009; **43**: 315-321 [PMID: 18836488 DOI: 10.1038/bmt.2008.325]
  - 115 **Curtis RE**, Travis LB, Rowlings PA, Socié G, Kingma DW, Banks PM, Jaffe ES, Sale GE, Horowitz MM, Witherspoon RP, Shriner DA, Weisdorf DJ, Kolb HJ, Sullivan KM, Sobocinski KA, Gale RP, Hoover RN, Fraumeni JF Jr, Deeg HJ. Risk of lymphoproliferative disorders after bone marrow transplantation: a multi-institutional study. *Blood* 1999; **94**: 2208-2216 [PMID: 10498590]
  - 116 **Stevens SJ**, Verschuuren EA, Verkuuljen SA, Van Den Brule AJ, Meijer CJ, Middeldorp JM. Role of Epstein-Barr virus DNA load monitoring in prevention and early detection of post-transplant lymphoproliferative disease. *Leuk Lymphoma* 2002; **43**: 831-840 [PMID: 12153173 DOI: 10.1080/10428190290016971]
  - 117 **Kunitomi A**, Arima N, Ishikawa T. Epstein-Barr virus-associated post-transplant lymphoproliferative disorders presented as interstitial pneumonia; successful recovery with rituximab. *Haematologica*

- 2007; **92**: e49-e52 [PMID: 17562592 DOI: 10.3324/haematol.11142]
- 118 **Benkerrou M**, Jais JP, Leblond V, Durandy A, Sutton L, Bordigoni P, Garnier JL, Le Bidois J, Le Deist F, Blanche S, Fischer A. Anti-B-cell monoclonal antibody treatment of severe posttransplant B-lymphoproliferative disorder: prognostic factors and long-term outcome. *Blood* 1998; **92**: 3137-3147 [PMID: 9787149]
- 119 **McLaughlin LP**, Bollard CM, Keller MD. Adoptive T Cell Therapy for Epstein-Barr Virus Complications in Patients With Primary Immunodeficiency Disorders. *Front Immunol* 2018; **9**: 556 [PMID: 29616044 DOI: 10.3389/fimmu.2018.00556]

**P- Reviewer:** Cascella M, Grawish ME, Lin JA, Zhao L  
**S- Editor:** Ji FF **L- Editor:** A **E- Editor:** Yin SY







Published by **Baishideng Publishing Group Inc**  
7901 Stoneridge Drive, Suite 501, Pleasanton, CA 94588, USA  
Telephone: +1-925-223-8242  
Fax: +1-925-223-8243  
E-mail: [bpgoffice@wjgnet.com](mailto:bpgoffice@wjgnet.com)  
Help Desk: <http://www.f6publishing.com/helpdesk>  
<http://www.wjgnet.com>

