ISSN 2219-2832 (online)

World Journal of *Surgical Procedures*

World J Surg Proced 2015 November 28; 5(3): 217-234

Published by Baishideng Publishing Group Inc

WJSP World Journal of Surgical Procedures

A peer-reviewed, online, open-access journal of surgical procedures

Editorial Board

2011-2015

The *World Journal of Surgical Procedures* Editorial Board consists of 276 members, representing a team of worldwide experts in surgical procedures. They are from 35 countries, including Australia (10), Austria (3), Belgium (1), Brazil (4), Canada (5), China (23), Egypt (2), France (1), Germany (10), Greece (9), Hungary (1), India (6), Iran (3), Ireland (1), Israel (6), Italy (29), Japan (34), Lebanon (1), Lithuania (1), Mexico (2), Netherlands (2), Nigeria (1), Norway (1), Pakistan (1), Poland (1), Romania (2), Saudi Arabia (1), Singapore (2), South Korea (7), Spain (11), Switzerland (5), Thailand (1), Turkey (7), United Kingdom (11), and United States (71).

WJSP

World Journal of
Surgical Procedures

Contents

Four-monthly Volume 5 Number 3 November 28, 2015

World Journal of Surgical Procedures
Volume 5 Number 3 November 28, 2015

Contents

AIM AND SCOPE

World Journal of Surgical Procedures (*World J Surg Proced*, *WJSP*, online ISSN 2219-2832, DOI: 10.5412) is a peer-reviewed open access academic journal that aims to guide clinical practice and improve diagnostic and therapeutic skills of clinicians.

WJSP covers topics concerning ambulatory surgical procedures, cardiovascular surgical procedures, digestive system surgical procedures, endocrine surgical procedures, obstetric surgical procedures, neurosurgical procedures, ophthalmologic surgical procedures, oral surgical procedures, orthopedic procedures, otorhinolaryngologic surgical procedures, reconstructive surgical procedures, thoracic surgical procedures, urogenital surgical procedures, computer-assisted surgical procedures, elective surgical procedures, and minimally invasive, surgical procedures, specifically including ablation techniques, anastomosis, assisted circulation, bariatric surgery, biopsy, body modification, non-therapeutic, curettage, debridement, decompression, deep brain stimulation, device removal, dissection, drainage, electrosurgery, extracorporeal circulation, hemostasis, intraoperative care, laparotomy, ligation, lymph node excision, mastectomy, microsurgery, monitoring, intraoperative, ostomy, paracentesis, pelvic exenteration, perioperative care, postoperative care, preoperative care, prosthesis implantation, reoperation, second-look surgery, splenectomy, suture techniques, symphysiotomy, tissue and organ harvesting, transplantation, diagnostic imaging, and endoscopy.

We encourage authors to submit their manuscripts to *WJSP*. We will give priority to manuscripts that are supported by major national and international foundations and those that are of great basic and clinical significance.

NAME OF JOURNAL
World Journal of Surgical Procedures

ISSN
ISSN 2219-2832 (online)

LAUNCH DATE
December 29, 2011

FREQUENCY
Four-monthly

EDITORIAL OFFICE
Jin-Lei Wang, Director
Xiu-Xia Song, Vice Director
World Journal of Surgical Procedures
Room 903, Building D, Ocean International Center, No. 62 Dongsihuan Zhonglu, Chaoyang District, Beijing 100025, China
Telephone: +86-10-85381891
Fax: +86-10-85381893
E-mail: editorialoffice@wjgnet.com
Help Desk: http://www.wjgnet.com/esps/helpdesk.aspx
http://www.wjgnet.com

PUBLISHER
Baishideng Publishing Group Inc
8226 Regency Drive,
Pleasanton, CA 94588, USA
Telephone: +1-925-223-8242
Fax: +1-925-223-8243
E-mail: bpgoffice@wjgnet.com
Help Desk: http://www.wjgnet.com/esps/helpdesk.aspx
http://www.wjgnet.com

PUBLICATION DATE
November 28, 2015

INSTRUCTIONS TO AUTHORS
Full instructions are available online at http://www.wjgnet.com/2219-2832/g_info_20100722180909.htm.

ONLINE SUBMISSION
http://www.wjgnet.com/esps/

World Journal of Surgical Procedures

Submit a Manuscript: http://www.wjgnet.com/esps/
Help Desk: http://www.wjgnet.com/esps/helpdesk.aspx
DOI: 10.5412/wjsp.v5.i3.217

World J Surg Proced 2015 November 28; 5(3): 217-222
ISSN 2219-2832 (online)

THERAPEUTICS ADVANCES

Versatility of therapeutic reduction mammoplasty in oncoplastic breast conserving surgery

Fernando Hernanz, Mónica González-Noriega, Rocío Vázquez Pérez, Manuel Gómez-Fleitas

Fernando Hernanz, Mónica González-Noriega, Rocío Vázquez Pérez, Manuel Gómez-Fleitas, Department of Surgery, Valdecilla Hospital, 39008 Santander, Cantabria, Spain

Author contributions: Hernanz F contributed to the conception and design of the study, who carried out surgical procedures; González-Noriega M made acquisition of and analysis and interpretation of them; Pérez RV made acquisition of data; Gómez-Fleitas M made critical revision.

Conflict-of-interest statement: All authors disclose that they do not have any commercial associations or financial support.

Correspondence to: Fernando Hernanz, MD, PhD, Assistant Professor of Surgery, Department of Surgery, Valdecilla Hospital, Avenue Valdecilla sn., 39008 Santander, Cantabria, Spain. cgdhff@humv.es
Telephone: +34-942-203733
Fax: +34-942-202726

Received: February 28, 2015
Peer-review started: March 2, 2015
First decision: June 3, 2015
Revised: June 27, 2015
Accepted: July 21, 2015
Article in press: July 23, 2015
Published online: November 28, 2015

Abstract

Oncoplastic breast conserving surgery is the gold standard approach for the surgical treatment of early breast cancer. There is a well defined technique named "therapeutic mammoplasty" which is characterized for using a reduction mammaplasty technique to treat breast cancer conservatively. In our current practice, "therapeutic mammoplasty" or therapeutic reduction mammaplasty is our favorite oncoplastic breast conserving approach which it used in almost half of our patients. This technique is very versatile allows us the resection of tumors located in all breast quadrants of patients with moderate-to large-sized breasts. We describe a series of 57 patients who were treated using a therapeutic reduction mammaplasty. All surgical procedures were carried out by one comprehensive breast surgeon who planned and designed the surgery performing both oncologic and reconstructive procedures. Surgical margins were insufficient in eight patients (14%). Nine patients (15.8%) had a complication in early postoperative period and in one of them adjuvant radiotherapy was delayed four months due to a wound dehiscence. The rate of synchronous contralateral symmetrization was 31.6%. Our conclusion is that reduction mammaplasty is a useful and safe skill to treat breast cancer conservatively playing a very important role therefore it must be situated in the priority of learning objectives.

Key words: Breast conserving surgery; Oncoplastic; Oncoplastic breast surgery; Reduction mammoplasty; Therapeutic mammaplasty

Core tip: Reduction mammaplasty techniques are a really useful and safe skills to treat breast cancer conservatively allowing breast surgeons manage tumors located in all breast quadrants with low morbidity in moderate to large breasted patients, thanks their versatility they play a very important role in oncoplastic conservative surgery therefore they must be situated in the priority of learning objectives.

Hernanz F, González-Noriega M, Pérez RV, Gómez-Fleitas M. Versatility of therapeutic reduction mammoplasty in oncoplastic breast conserving surgery. *World J Surg Proced* 2015; 5(3): 217-222 Available from: URL: http://www.wjgnet.com/2219-2832/full/v5/i3/217.htm DOI: http://dx.doi.org/10.5412/wjsp.v5.i3.217

INTRODUCTION

Currently, oncoplastic breast conserving surgery (OBCS) should be the gold standard approach for the surgical treatment of early breast cancer[1-3]. Oncoplastic techniques (OT) offer clear advantages on nearly forty percent of patients in who common breast conserving treatment (BCT) (surgery plus radiotherapy) are followed by cosmetic sequelaes[4] besides the rest of the patients who also could be benefited from many surgical tricks which can improve aesthetic outcomes[5]. Since 1998, when Audretsch *et al*[6] described the use of plastic surgery techniques to reshape the breast at the time of lumpectomy or quadrantectomy introducing the term "oncoplastic", it has passed enough time to be able to evaluate long-term oncologic outcomes, therefore a meta-analysis gathering 3165 patients treated by OBCS *vs* 5494 treated BCT have demonstrated that OBCS obtain similar results to standard breast conserving surgery improving cosmetic outcome and patients' satisfaction[7].

There is a large amount of OT but these can be classified in two main groups: Volume replacement or displacement techniques. Nowadays, the last ones, which are more frequently used[8], have a broad technical variety with different patters incisions, pedicles used for nipple areola complex (NAC) movement, ways to fill tumor removal defect and their multiple combinations. Several authors[9-13] have created different algorithms attempting to optimize OT and offering us a method to select the most appropriate OT in each patient. These algorithms for immediate conservative surgery reconstruction are based on some aspects such as type and size of the breast, extent of tumor removal defect, ptosis degree, breast tissue density and location of the tumor in the breast. Other aspects very important in the process of decision are patient preferences and surgeon expertise.

In OT displacement volume group there is well defined technique a "therapeutic mammoplasty" term coined by McCulley *et al*[14,15] which is characterized for using a reduction mammaplasty technique and radiotherapy to treat breast cancer. These authors described two different scenarios depending if the tumor lies or not within the routine pattern incision and excision dividing the breast in nine areas with theirs corresponding approaches. Therapeutic mammaplasty is especially useful in large breasted patients in who a bilateral reduction mammaplasty offers clear advantages which are both oncological and functional which cause better radiation therapy and beside relieving the symptoms related to breast hypertrophy thus improves quality of life[16], even more, this approach is a better option than skin-sparing total mastectomy and immediate reconstruction having lower morbidity and more favorable cosmesis[17].

Munhoz *et al*[18], wrote that the main advantages of the therapeutic reduction mammaplasty (TRM) should include reproducibility, low interference with oncological treatment and long-term results. We agree completely with him and it is more, based on our experience, we would like to add that this technique is versatile because it could be used to treat tumors located in all breast quadrants with the condition that the patient having a moderate to large-sized breast.

The aim of this work was to communicate our experience with TRM showing the distribution of tumors into the breast, rate of affected margins, early surgical complications, and synchronous contralateral breast symmetrization.

PATIENTS AND METHODS

Between 2005 and 2013, 57 patients suffering from breast cancer suitable for BCT underwent TRM at our Oncoplastic Breast Unit, Hospital Valdecilla (Santander, Spain). All surgical procedures were carried out by one comprehensive breast surgeon (FH) who planned and designed the surgery performing both oncologic and reconstructive procedures. Data from patient and tumor characteristics, surgical procedures, early complications and pathological study were prospectively collected and stored in IBM SPSS statistics program.

RESEARCH RESULT

Characteristic of patients and tumours are described in Tables 1 and 2. Seven patients were treated before surgery with neoadjuvant chemotherapy. Most of tumor excisions were guided by needle-wires (84.2%) according to our method previously published[19]; wires were inserted 1 cm distant to radiologic tumors limits as markers of optimal limit resection, sufficiently of resection margins was per-operatively tested by X-ray analysis of surgical specimen. Biopsy of sentinel lymph node (49) and axillary linfadenectomy (10) was performed in mostly patients by the T inverted pattern incision. Opposite breast surgery by reduction mammaplasty was carried out in eighteen patients (31.6%).

Surgical margins status

Margins were insufficient in eight patients (14%), five affected and three with focal involvement. Two of them having affected margins underwent total mastectomy. Pathologic study of mastectomy showed residual invasive carcinoma and carcinoma *in situ* in one patient and residual ductal carcinoma *in situ* in the other.

Early surgical complications

Nine patients (15.8%) had a complication in early

Table 1 Characteristics of the series of 57 patients *n* (%)

Age (yr)	57, 8.9 SD
Status menstrual	
Premenopausal	13 (22.8)
Postmenopausal	44 (77.2)
Affected breast	
Right	19 (33.3)
Left	38 (66.7)
Tumour location through the breast (quadrant)	
Upper outer	16 (28.1)
Upper inner	3 (5.3)
Lower Inner	3 (5.3)
Central	12 (21.1)
Intersection upper quadrants	7 (12.3)
Intersection lower quadrants	5 (8.8)
Intersection inner quadrants	3 (5.3)
Intersection outer quadrants	7 (12.3)
Inframmary fold	1 (1.8)
Multifocal	14 (24.6)
Radiological tumour size (mm)	21.7, 12.58 SD

Table 2 Characteristic of 57 breast carcinomas *n* (%)

In situ	7 (12.3)
Invasive	50 (87.7)
Type of histology	
Ductal	39
Lobular	6
Mixed	1
Papilar	1
Others	3
Positive estrogenic receptors	38
Positive progesterone receptors	37
Positive Herb2 receptors	7
Ki67 (n = 42)	
> 10%	15
10%-50%	19
51%-75%	3
> 75%	4
Pathologic tumour size (mm)	17.1, 9.77 SD
Patients with lymph nodes positives	12 (14)

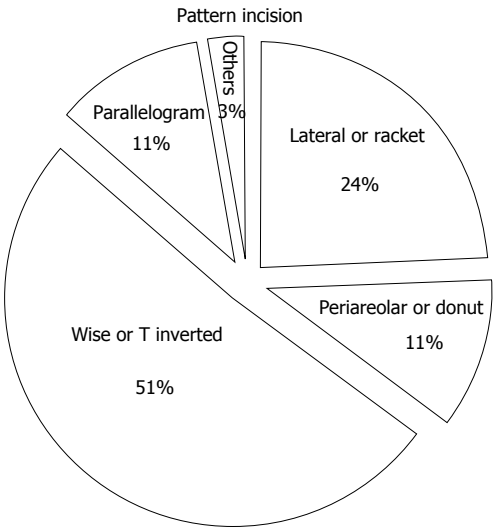

Figure 1 Distribution of the pattern incisions used in breast cancer patients treated using oncoplastic conservative approach at our unit.

postoperative period (five a hematoma, four a minor wound dehiscence) and three of them had to be re-operated for evacuating a hematoma. There were no major complications such necrosis of NAC or severe breast infections and only one adjuvant radiotherapy was delayed four months in one patient due to a wound dehiscence.

DISCUSSION

Although some OT are specifically useful to manage some determined tumor locations such as a lateral or tennis racket mammaplasty[20] for tumors located at upper outer quadrant or LIQ-V mammaplasties[21] for these located at lower inner quadrants, reduction mammaplasty with T inverted pattern incision appropriately adapted is be able to treat tumors situated at all breast quadrants. In a very large series of 540 consecutive cases published by Fitoussi *et al*[22] in which a variety of OT were used, T inverted pattern incision was the most frequently utilized in 40% of patients. Our current BCT entails 77.2% of breast cancer surgery and in oncoplatic breast conserving experience using volume displacement technique this pattern incision is the most common (Figure 1) used in 52% of cases, and our favorite approach (unpublished data).

As inner quadrants were the less frequent tumor localizations with 10.6% and the outer ones were the most frequent our first choice to move NAC was a superomedial pedicle but in this series we also used inferior and bipedicled ones. In those patients with central tumors in who NAC had to be removed we reconstructed NAC using different techniques, for example, contralateral areola (Figure 2) or skin graft plus arrow flap for nipple reconstruction. The variation of localizations shows the versatility of TRM in breast with moderate or large size.

Early complications rate was 15.8%, these were minor; our experience is similar to others authors such as Gulcelik *et al*[23] who reported a rate of minor early complications of 16.3% and major ones of 1.9% without differences between reduction mammaplasy used for macromastia treatment and breast cancer. A wide range of complications rate of therapeutic reduction mammaplasty has been reported[24] likely due to differences in criteria and collecting data but, one conclusion is uniform that they usually are minor not impacting seriously on delivery of adjuvant therapies unless they were severe, McIntosh *et al*[25] in a systematic review found that delayed adjuvant treatment in only 6% of cases.

The rate of synchronous contralateral symmetrization was 31.6% but most of these patients were operated in the first half of the series before 2011; like as Fitoussi *et al*[22] our current preference is delayed contralateral symmetrization. The reasons for that have been clearly exposed by Kaviani *et al*[26] who categorized the patients in three groups: Patients unwilling any contralateral

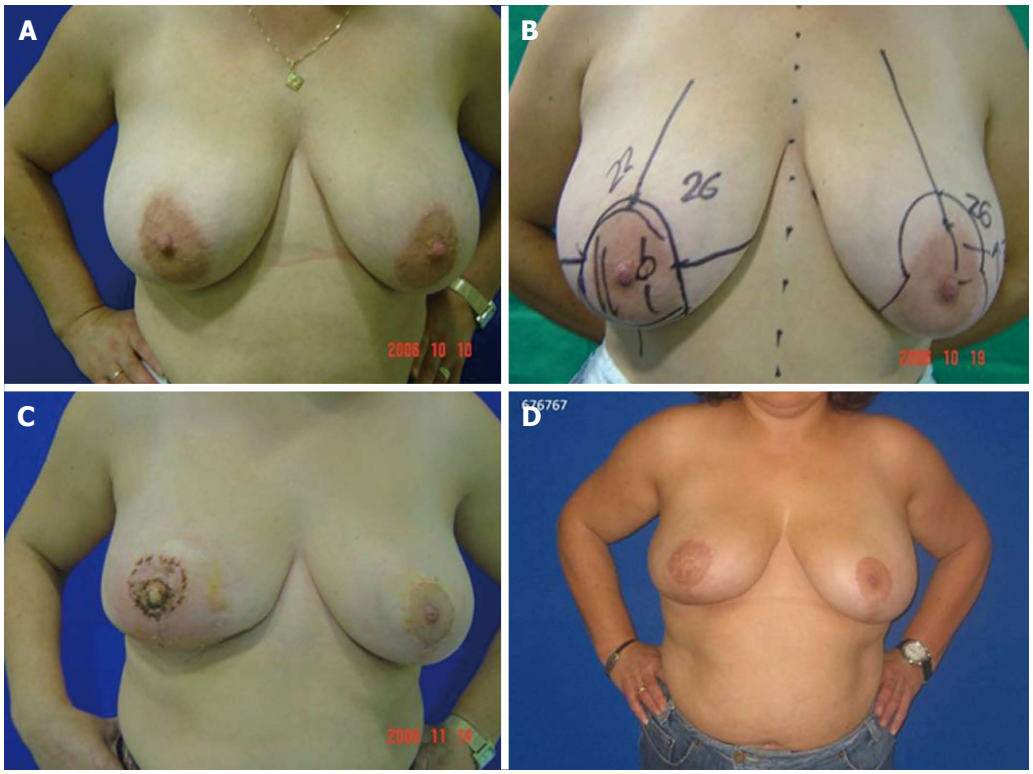

Figure 2 A 40-year-old postmenopausal woman with an invasive ductal carcinoma with positive estrogenic, progesterone and Herb2 receptors situated at central quadrant of right breast which sized 15 mm on mammograms. A and B: Appearance of patient. Design of pattern of therapeutic reduction mammaplasty; C and D: Nipple areola complex right reconstructed by contralateral areola graft. Long-term aesthetic outcome.

Figure 3 Appearance of a 49-year-old woman after underwent oncoplastic breast conserving surgery and posterior adjuvant chemotherapy and radiotherapy. She had a bifocal invasive lobulillar carcinoma situated at intersection of upper quadrants with positive estrogenic and progesterone receptors and $T_2N_0M_0$ pathological staging. She presents breast asymmetry which she wants it to be corrected.

procedures, patients preferring an all-in-one operation willing immediate symmetrization and patients desiring optimal aesthetic results; only patients belonging to the second group are candidates to immediate contralateral symmetization. In our experience, our average patient is in the first group. Figure 3 shows the appearance of a patient belonging to third group with breast asymmetry which she wants it to be corrected; we will carry out symmetrization of the right breast when she stabilized her weight because she put on weight during chemotherapy treatment.

Patient satisfaction and aesthetic outcomes reported are very high with a low rate of failure as which summarized by the fact that almost none patients regretted to chose this type of surgery[18]. Changes of aesthetic outcomes over the time after completing radiotherapy have been commented not affecting negatively patient satisfaction. In our experience, TRM as reduction mammaplasty technique has the same limitations and aesthetic outcomes can be deteriorated over the time by pseudoptosis (Figure 4) or excessive weight gain.

Finally, all OT and more specifically those of level Ⅱ are based on the knowledge of reduction mammaplasty techniques; independently, which model for oncoplastic approach can be chosen "comprehensive breast surgeon" or "oncologic and plastic team", skill sharing

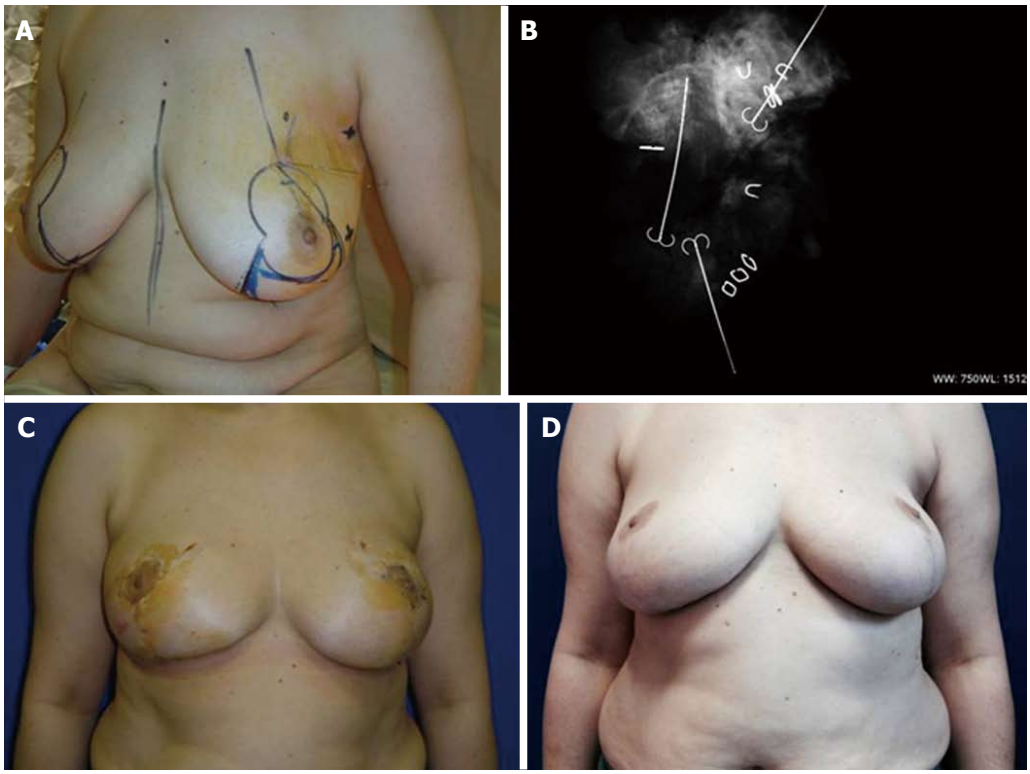

Figure 4 A 44-year-old premenopausal female with an invasive ductal carcinoma at upper outer quadrant of the left breast which sized 35 mm on mammograms who was treated with neoadjuvant chemotherapy before surgery. A therapeutic bilateral reduction mammaplasty with T inverted pattern incision and superomedial pedicle used for shifting nipple areola complex and an infero-lateral one to fill the breast defect caused by extirpation of a surgical specimen weighted 223 g was carried out. Pathological study showed a tumor size 12 mm, one negative sentinel lymph node and free surgical margins. A: Design of pattern incision with three wires inserted to guide tumor excision; B: X-ray of surgical specimen showed complete radiological removal of tumor; C: Appearance on early postoperative period; D: Long-term aesthetic outcome three years after breast conserving treatment shows both breasts with pseudotosis.

between breast unit members is eagerly desirable and, in our opinion, about reduction mammaplasty techniques the former statement is essential. Accepting the lack of oncoplastic training[27] and the fact that expertise requires long time[28], we proposed a management policy[29] to mitigate this situation incorporating the surgical treatment of symptomatic macromastia into Breast Cancer Unit[30]. One step in this direction is the inclusion of gynaecomastia and congenital asymmetry surgical treatment into several Oncoplastic Breast Surgery Units in United Kingdom.

CONCLUSION

Reduction mammaplasty technique is a useful and safe skill to treat breast cancer located in all breast quadrants with low morbidity playing a very important role in oncoplastic conservative surgery in moderate to large breasted patients therefore it must be situated in the priority of learning objectives.

REFERENCES

1 **Warren AG**, Morris DJ, Houlihan MJ, Slavin SA. Breast reconstruction in a changing breast cancer treatment paradigm. *Plast Reconstr Surg* 2008; **121**: 1116-1126 [PMID: 18349628 DOI: 10.1097/01.prs.0000305516.93441.fd]

2 **Spear SL**. Oncoplastic surgery. *Plast Reconstr Surg* 2009; **124**: 993-994 [PMID: 19730325 DOI: 10.1097/PRS.0b013e3181b17ab3]

3 **Silverstein MJ**, Mai T, Savalia N, Vaince F, Guerra L. Oncoplastic breast conservation surgery: the new paradigm. *J Surg Oncol* 2014; **110**: 82-89 [PMID: 24847860 DOI: 10.1002/jso.23641]

4 **Hernanz F**, Pérez-Cerdeira M, Sánchez S, Redondo-Figuero C. Cosmetic sequelae after breast-conserving treatment using conventional surgical techniques. *Breast J* 2013; **19**: 342-343 [PMID: 23600624 DOI: 10.1111/tbj.12113]

5 **Petit JY**, De Lorenzi F, Rietjens M, Intra M, Martella S, Garusi C, Rey PC, Matthes AG. Technical tricks to improve the cosmetic results of breast-conserving treatment. *Breast* 2007; **16**: 13-16 [PMID: 17070051]

6 **Audretsch WP**, Rezai M, Kolotas C, Zamboglou N, Schnabel T, Bojar H. Tumor-specif immediate reconstruction in breast cancer patients. *Perspect Plast Surg* 1998; **11**: 71

7 **Losken A**, Dugal CS, Styblo TM, Carlson GW. A meta-analysis comparing breast conservation therapy alone to the oncoplastic technique. *Ann Plast Surg* 2014; **72**: 145-149 [PMID: 23503430 DOI: 10.1097/SAP.0b013e3182605598]

8 **Haloua MH**, Krekel NM, Winters HA, Rietveld DH, Meijer S, Bloemers FW, van den Tol MP. A systematic review of oncoplastic breast-conserving surgery: current weaknesses and future prospects. *Ann Surg* 2013; **257**: 609-620 [PMID: 23470508 DOI: 10.1097/SL.A.0b013e3182888782]

9 **Churgin S**, Isakov R, Yetman R. Reconstruction options following breast conservation therapy. *Cleve Clin J Med* 2008; **75** Suppl 1: S24-S29 [PMID: 18457194]

10 **Munhoz AM**, Montag E, Arruda E, Pellarin L, Filassi JR, Piato JR, de Barros AC, Prado LC, Fonseca A, Baracat E, Ferreira MC. Assessment of immediate conservative breast surgery reconstruction: a classification system of defects revisited and an algorithm for selecting the appropriate technique. *Plast Reconstr Surg* 2008; **121**: 716-727 [PMID: 18317121 DOI: 10.1097/01.

prs.0000299295.74100.fa]
11 **Losken A**, Hamdi M. Partial breast reconstruction: current perspectives. *Plast Reconstr Surg* 2009; **124**: 722-736 [PMID: 19730292 DOI: 10.1097/PRS.0b013e3181b179d2]
12 **Clough KB**, Kaufman GJ, Nos C, Buccimazza I, Sarfati IM. Improving breast cancer surgery: a classification and quadrant per quadrant atlas for oncoplastic surgery. *Ann Surg Oncol* 2010; **17**: 1375-1391 [PMID: 20140531 DOI: 10.1245/s10434-009-0792-y]
13 **Urban C**, Lima R, Schunemann E, Spautz C, Rabinovich I, Anselmi K. Oncoplastic principles in breast conserving surgery. *Breast* 2011; **20** Suppl 3: S92-S95 [PMID: 22015301 DOI: 10.1016/S0960-9776(11)70302-2]
14 **McCulley SJ**, Macmillan RD. Planning and use of therapeutic mammoplasty--Nottingham approach. *Br J Plast Surg* 2005; **58**: 889-901 [PMID: 16043150 DOI: 10.1016/j.bjps.2005.03.008]
15 **McCulley SJ**, Macmillan RD. Therapeutic mammaplasty--analysis of 50 consecutive cases. *Br J Plast Surg* 2005; **58**: 902-907 [PMID: 16043153 DOI: 10.1016/j.bjps.2005.03.007]
16 **Hernanz F**, Regaño S, Vega A, Gómez Fleitas M. Reduction mammaplasty: an advantageous option for breast conserving surgery in large-breasted patients. *Surg Oncol* 2010; **19**: e95-e102 [PMID: 19716288 DOI: 10.1016/j.suronc.2009.08.001]
17 **Losken A**, Pinell XA, Eskenazi B. The benefits of partial versus total breast reconstruction for women with macromastia. *Plast Reconstr Surg* 2010; **125**: 1051-1056 [PMID: 20072088 DOI: 10.1097/PRS.0b013e3118d0ab08]
18 **Munhoz AM**, Montag E, Gemperli R. Current aspects of therapeutic reduction mammaplasty for immediate early breast cancer management: An update. *World J Clin Oncol* 2014; **5**: 1-18 [PMID: 24527398 DOI: 10.5306/wjco.v5.i1.1]
19 **Hernanz F**, Regaño S, Vega A, Alvarez A. Needle-wire-guided breast tumor excision. *J Surg Oncol* 2006; **94**: 165-166 [PMID: 16847825]
20 **Ballester M**, Berry M, Couturaud B, Reyal F, Salmon RJ, Fitoussi AD. Lateral mammaplasty reconstruction after surgery for breast cancer. *Br J Surg* 2009; **96**: 1141-1146 [PMID: 19787762 DOI: 10.1002/bjs.6696]
21 **Clough KB**, Oden S, Ihrai T, Massey E, Nos C, Sarfati I. Level 2 oncoplastic surgery for lower inner quadrant breast cancers: the LIQ-V mammoplasty. *Ann Surg Oncol* 2013; **20**: 3847-3854 [PMID: 23838910 DOI: 10.1245/s10434-013-3085-4]
22 **Fitoussi AD**, Berry MG, Famà F, Falcou MC, Curnier A, Couturaud B, Reyal F, Salmon RJ. Oncoplastic breast surgery for cancer: analysis of 540 consecutive cases [outcomes article]. *Plast Reconstr Surg* 2010; **125**: 454-462 [PMID: 20124831 DOI: 10.1097/PRS.0b013e3181c82d3e]
23 **Gulcelik MA**, Dogan L, Camlibel M, Karaman N, Kuru B, Alagol H, Ozaslan C. Early complications of a reduction mammoplasty technique in the treatment of macromastia with or without breast cancer. *Clin Breast Cancer* 2011; **11**: 395-399 [PMID: 21993009 DOI: 10.1016/j.clbc.2011.08.001]
24 **Iwuchukwu OC**, Harvey JR, Dordea M, Critchley AC, Drew PJ. The role of oncoplastic therapeutic mammoplasty in breast cancer surgery--a review. *Surg Oncol* 2012; **21**: 133-141 [PMID: 21411311 DOI: 10.1016/j.suronc.2011.01.002]
25 **McIntosh J**, O'Donoghue JM. Therapeutic mammaplasty--a systematic review of the evidence. *Eur J Surg Oncol* 2012; **38**: 196-202 [PMID: 22206704]
26 **Kaviani A**, Safavi A, Mirsharifi R. Immediate and delayed contralateral symmetrization in oncoplastic breast reduction: patients' choices and technique formulation. *Plast Reconstr Surg Glob Open* 2015; **3**: e286 [PMID: 25674367 DOI: 10.1197/GOX.0000000000000246]
27 **Andree C**, Farhadi J, Goossens D, Masia J, Sarfati I, Germann G, Macmillan RD, Scheflan M, Van Not HP, Catanuto G, Nava MB. A position statement on optimizing the role of oncoplastic breast surgery. *Eplasty* 2012; **12**: e40 [PMID: 22977675]
28 **Carty MJ**, Chan R, Huckman R, Snow D, Orgill DP. A detailed analysis of the reduction mammaplasty learning curve: a statistical process model for approaching surgical performance improvement. *Plast Reconstr Surg* 2009; **124**: 706-714 [PMID: 19730289 DOI: 10.1097/PRS.0b013e3181b17a13]
29 **Hernanz F**, Santos R. Incorporating the surgical treatment of symptomatic macromastia into a Breast Cancer Unit: could this be a useful management policy? *Breast* 2011; **20**: 190-191 [PMID: 21050760 DOI: 10.16/j.breast.2010.10.006]
30 **Hernanz F**, Santos R, Arruabarrena A, Schneider J, Gómez Fleitas M. Treatment of symptomatic macromastia in a breast unit. *World J Surg Oncol* 2010; **8**: 93 [PMID: 21040550 DOI: 10.1186/1477-7819-8-93]

P- Reviewer: Wang SK **S- Editor**: Ji FF
L- Editor: A **E- Editor**: Liu SQ

World Journal of Surgical Procedures

Submit a Manuscript: http://www.wjgnet.com/esps/
Help Desk: http://www.wjgnet.com/esps/helpdesk.aspx
DOI: 10.5412/wjsp.v5.i3.223

World J Surg Proced 2015 November 28; 5(3): 223-228
ISSN 2219-2832 (online)

ORIGINAL ARTICLE

Retrospective Study

Are stapler line reinforcement materials necessary in sleeve gastrectomy?

Ibrahim Sakcak

Ibrahim Sakcak, Department of General Surgery, Medicalpark Hospital, 06100 Ankara, Turkey

Ibrahim Sakcak, Department of General Surgery, Numune Education and Research Hospital, Sıhhiye, 06100 Ankara, Turkey

Author contributions: Sakcak I solely wrote this paper.

Institutional review board statement: Ethics committee approval is not obligatory in Turkey for retrospective studies (Clinical Study Regulation, Turkish Official Gazette, Date: April 13, 2013, No: 28617), therefore ethics committee approval was not obtained.

Informed consent statement: All patients provided their informed consent for surgery (informed consent could not be obtained for study due to its retrospective nature).

Conflict-of-interest statement: None.

Data sharing statement: Technical appendix, statistical code, and dataset available from the corresponding author at ibrahimsakcak66@gmail.com. Consent was not obtained but the presented data are anonymized and risk of identification is low.

Correspondence to: Ibrahim Sakcak, Associate Professor, Department of General Surgery, Medicalpark Hospital, Sihhiye, 06100 Ankara, Turkey. ibrahimsakcak66@gmail.com
Telephone: +90-312-6668000
Fax: +90-212-2273477

Received: May 5, 2015
Peer-review started: May 6, 2015
First decision: May 13, 2015
Revised: May 28, 2015
Accepted: July 16, 2015
Article in press: July 17, 2015
Published online: November 28, 2015

Abstract

AIM: To investigate the effect of staple line reinforcement materials on decreasing complications related to sleeve gastrectomy.

METHODS: In this retrospective study, we analyzed 84 patients who had sleeve gastrectomy due to obesity between April 2012 and April 2015. Sleeve gastrectomy procedure was performed in patients with a body mass index (BMI) more than 40 kg/m^2, and the ones with a BMI between 32 and 40 kg/m^2 in the presence of comorbid diseases. Reinforcement materials were used in 45 patients while they were not used in 39 patients. Materials such as Peristrip, 3/0 prolene, and V-lock were used for reinforcement in the reinforcement group (RG), and the materials used showed variations during the study period. The baseline characteristics, duration of surgery, hospital stay, comorbidities including hypertension, type 2 diabetes mellitus, hypertension, hepatosteatosis, gallstones, osteoarthritis, gastroesophageal reflux, sleep disorders, as well as the complications including leaks and bleeding after surgery were recorded and compared between the reinforcement and non-RGs (NRGs).

RESULTS: There were no differences between the reinforcement and NRGs for baseline characteristics including age (P = 0.689), gender (P = 0.057), height (P = 0.483), weight (P = 0.889), BMI (P = 0.971), hospital stay (P = 0.888), or duration of surgery (P = 0.229). The most common comorbidities in the RG were hypertension (24.4%) and hepatosteatosis (24.4%), while type 2 diabetes mellitus (28.2%) and

hepatosteatosis (28.2%) were the most frequent comorbidities in the NRG. There were no differences between the reinforcement and NRGs for the rates of comorbidities (P > 0.05). Leak was observed in one (2.2%) patient in the RG, and there was leak in 2 (5.1%), and bleeding in 2 (5.1%) patients in the NRG. There were no differences between the reinforcement and NRGs for the rate of staple line leaks (P = 0.446) or bleeding (P = 0.213). One of the patients with leak died in the NRG while there were no deaths in the RG.

CONCLUSION: Although staple line reinforcement materials decreased morbidity and mortality, the differences between the two groups were not statistically significant.

Key words: Obesity; Sleeve gastrectomy; Staple line; Reinforcement

Core tip: Sleeve gastrectomy is one of the most frequently performed surgical procedures in the treatment of obesity. In this study, we investigated the efficiency of use of staple line reinforcement materials in decreasing these complications. We included 84 patients in our study. Reinforcement materials were used in 45 patients while they were not used in 39 patients. Although we found that staple line reinforcement materials decreased morbidity and mortality, the differences between the two groups were not statistically significant for complications or mortality. There is a need for prospective randomized studies on larger patient populations to further clarify the subject.

Sakcak I. Are stapler line reinforcement materials necessary in sleeve gastrectomy? *World J Surg Proced* 2015; 5(3): 223-228 Available from: URL: http://www.wjgnet.com/2219-2832/full/v5/i3/223.htm DOI: http://dx.doi.org/10.5412/wjsp.v5.i3.223

INTRODUCTION

The data published by the World Health Organization in 2014 indicate that 39% of the world population over 18 years of age are overweight and 14% of them are obese, and some problems including hypertension, cardiovascular diseases and gastroesophageal reflux appear due to obesity[1]. Obesity is a significant health problem in the developed countries, and its prevalence has been increasing in the developing countries. In Turkey, which is a developing country, the prevalence of obesity in adults increased two-fold in the last 15 years, and reached 29.5%.

Laparoscopic sleeve gastrectomy is one of the most frequently performed bariatric procedures with an increasing popularity owing to its efficiency in weight loss, and its ability to improve comorbidities. Sleeve gastrectomy shows its effect on weight loss by three different mechanisms: (1) Stomach volume is decreased by 80%-85%; (2) The concentration of ghrelin, an ergogenic hormone, decreases; and (3) Gastric emptying rate increases[2].

The main disadvantages of sleeve gastrectomy are staple line leaks (SLLs) and bleeding. SLLs are seen in 1%-3% of patients after primary procedures[2]. Leaks subsequently result in abdominal sepsis, chronic gastric fistula, necrotizing fasciitis, multi-organ failure and eventually sepsis, and they are the most important causes of mortality[3,4]. A number of surgeons use staple line reinforcement materials (SLRMs) to decrease this complication while some others claim that those materials are not necessary, and use of them does not decrease SLLs[5,6].

In this study, we aimed to investigate whether use of SLRM in patients who had sleeve gastrectomy due to obesity decreased complications such as SLLs and bleeding.

MATERIALS AND METHODS

This retrospective study included 84 patients who had sleeve gastrectomy due to obesity at Ankara Numune Education and Research and Medicalpark Ankara Hospitals between April 2012 and April 2015. The patients were divided into two groups as the reinforcement group (RG) in which a reinforcement material was used to reinforce the staple line, and non-RG (NRG) in which a staple line reinforcement material was not used. Selection of the patients into the RG or NRG group was the surgeon's preference. Demographic characteristics, comorbidities, and morbidities of the patients were recorded.

Sleeve gastrectomy procedure was performed in patients with a body mass index (BMI) more than 40 kg/m^2, and in the ones with a BMI between 32 and 40 kg/m^2 in the presence of comorbid diseases.

Enoxaparin sodium (Sanofi Winthrop Industrie, Maisons-Alfort/France) 60 mg was injected subcutaneously 12 h before surgery for prophylaxis of venous thromboembolism, and the patients wore anti-embolism socks on the day of surgery. Surgery was performed in the supine position, and the surgeon performed the surgery standing between the legs of the patient. Procedure was performed through 5 trocars: One 15 mm trocar for stapler handle, one 10 mm trocar for the camera, and three 5 mm trocars for instruments and liver retractor. The greater omentum was separated from the greater curvature, starting 2 cm proximal to the pylorus with Harmonic (Ethicon, United States) or Ligasure (Covidien, United States). The stomach was divided approximately 3 cm proximal to pylorus, targeting 1 cm lateral to the esophagogastric junction. Echelon 60 (Ethicon-Mexico) and Covidien 60 (Covidien, United States) staplers were used to divide the stomach.

A thick tissue stapler was used in the antrum, a thin tissue stapler used in the fundus, and a medium-

Table 1 Baseline characteristics of 84 patients that had laparoscopic sleeve gastrectomy

	RG (n = 45)	NRG (n = 39)	P
Age (yr)			
Male, n (%)	9 (20.0)	7 (17.9)	0.811
Female, n (%)	36 (80.0)	32 (82.1)	
Height (cm)	167.1 ± 8.5	166.1 ± 8.1	0.483
Weight (kg)	122.3 ± 23.2	120.9 ± 20.6	0.889
BMI (kg/m^2)	43.1 ± 7.4	43.3 ± 8.2	0.971
Hospital stay (d)	5.0 ± 2.3	4.3 ± 2.3	0.888
Duration of surgery (min)	82.9 ± 33.2	78.2 ± 30.3	0.229

RG: Reinforcement group; NRG: Non-reinforcement group; BMI: Body mass index.

Table 2 Comorbidities of the patients n (%)

	RG (n = 45)	NRG (n = 39)	P
Hypertension	11 (24.4)	10 (25.6)	0.899
Hyperlipidemia	9 (20.0)	10 (25.6)	0.926
Type 2 diabetes mellitus	9 (20.0)	11 (28.2)	0.883
Sleep disorders	7 (15.6)	6 (15.4)	0.560
GERD	10 (22.2)	10 (25.6)	0.714
Depression	7 (15.6)	6 (15.4)	0.560
Hepatosteatosis	11 (24.4)	11 (28.2)	0.696
Gallstone	8 (17.8)	8 (20.5)	0.750
Osteoarthritis	4 (8.9)	4 (10.3)	0.560

RG: Reinforcement group; NRG: Non-reinforcement group; GERD: Gastroesophageal reflux disease.

Table 3 Staple-line bleeding and leaks after sleeve gastrectomy n (%)

	RG (n = 45)	NRG (n = 45)	P
Staple-line leaks	1 (2.2)	2 (5.1)	0.446
Staple-line bleeding	0	2 (5.1)	0.213

RG: Reinforcement group; NRG: Non-reinforcement group.

Table 4 Comparison of the groups for the complications other than staple line leaks and bleeding n (%)

	RG (n = 45)	NRG (n = 45)	P
Venous thromboembolism	0	1 (2.6)	0.464
Surgical field infection	3 (6.7)	2 (5.1)	0.568
Pulmonary complications	0	1 (2.6)	0.464

RG: Reinforcement group; NRG: Non-reinforcement group.

thick tissue stapler in the tissues between. An orogastric tube was inserted during surgery, the stomach contents were aspirated. The tube was then removed, and a 36 F calibration tube was inserted. Diluted methylene blue was given through the calibration tube to test the presence of any leak, and then the tube was removed. Materials such as Peristrip, 3/0 prolene, and V-lock were used for reinforcement in RG. The type of the material showed variations during the study period. Peristrip was used in 27 of 45 patients, 3/0 prolene was used in 12, and V-lock suture was used in 6 patients that had surgery after October 2014. The stomach tissue was removed through the 15-mm trocar incision. A Jackson-Pratt drain was placed, and it was removed when the drainage was less than 30 mL. The patient drank 100 mL methylene blue on postoperative day 1, and the drain was checked for the presence of methylene blue. The patient was given oral liquids after making sure that there was no leak.

Statistical analysis

SPSS version 22.0 (SPSS Inc, Chicago, IL) was used for statistical analyses. The categorical variables were compared by Fisher exact χ^2 test. Numerical data are presented as mean ± SD, and one sample t-test was used to determine whether they were parametric or not. Since the numerical data were determined to be non-parametric, Mann Whitney-U test was used to compare the two groups.

RESULTS

The baseline characteristics of 84 patients are presented in Table 1. There were no significant differences between the two groups.

There were 9 different comorbidities in the two groups. The most common comorbidities in RG were hypertension and hepatosteatosis (24.4%), while type 2 diabetes mellitus and hepatosteatosis were the most frequent comorbidities (28.2%) in NRG (Table 2).

Leak, which is the most distressing complication in sleeve gastrectomy, was seen in one patient in RG (2.2%), and in 2 (5.1%) patients in NRG (P = 0.446). Leaks were recognized within three days after surgery, and the patients were followed conservatively first. However, none of the patients responded to conservative treatment. The leak orifice was closed endoscopically with over-the-scope clips at postoperative 2nd-4th wk. All patients recovered with this intervention. There were no bleeding in RG, however, it developed in 2 (5.1%) patients in NRG. The difference between the groups was not statistically significant (P = 0.213) (Table 3).

Comparison of the groups for the complications other than SLLs and staple line bleeding is presented in Table 4. Infection of the surgical field was seen in 3 patients in RG. Venous thromboembolism was seen in 1, surgical field infection was seen in 2, and pulmonary complications were seen in 1 patient in NRG. One patient in RG and 2 patients in NRG also had SLLs. Antibiotics and conservative treatment were administered to those patients. One patient in NRG died despite all those treatments, and other patients recovered.

DISCUSSION

SLL is the most important cause of mortality and morbidity after sleeve gastrectomy. Stapler line is reinforced

in order to minimize this distressing complication[7]. Various SLRMs are used for this purpose, and the staple line is sutured. The primary SLRM used is a synthetic bioabsorbable material composed of the copolymer polyglycolic acid/trimethylene carbonate (GORE SEAM-GUARD Bioabsorbable Staple Line R, W.L. Gore and Associates, Elkton, MD, United States) put into the stapler cartridge, and Peri-Strips Dry with veritas. A recent meta-analysis including 56 studies and 6578 patients reported that SLRMs were used in 56% of the patients that had laparoscopic sleeve gastrectomy[8]. The results of this meta-analysis indicated that use of SLRMs decreased the leak rate from 3.2% to 2%, without any statistically significant difference in between. Knapps *et al*[4] reviewed 30 papers including 4881 patients, and did not find any statistically significant difference for leaks or bleeding with use of SLRM. Albanopoulos *et al*[9] performed a randomized study on 40 patients, and reported that use of SLRMs did not decrease the leak rate. On the other hand, some surgeons claimed that use of those materials decreased SLLs. Ser *et al*[10] performed a study on 118 patients, and reported the SLL rate as 10% without use of SLRMs, and as 0% with use of SLRMs. The results of that study reported a great difference between the two groups. However, it must be noted that the study of Ser *et al*[10] included smaller number of patients when compared to other meta-analyses and reviews. In our study, SLL was seen in 1 (2.2%) patient in RG, and in 2 (5.1%) patients in NRG, and bleeding was seen in 2 (5.1%) patients in NRG.

The pathophysiological basis of stapler line reinforcement is not clear. Poor blood flow at staple line, insufficient closure of stapler cartridge, postoperative gastroparesis and pyloric dysfunction have been accused for SLLs[11]. In addition, a staple line closure which is not straight is one of the most important causes for leaks.

Some stapler-related and tissue-related factors affect the morbidity of surgery. The stomach has the most variable wall thickness among the gastrointestinal system organs. Its wall is the thickest in prepyloric antrum, and the thinnest in the fundus. The thickness of the stomach wall decreases as one gets closer to the greater curvature, along the axis of the stomach[7]. The tissue thickness must be taken into consideration when performing sleeve gastrectomy. The most important features of staplers are their leg lengths, closing characteristics, and the type of metal. Tissue-related characteristics are viscosity and thickness. The risk for leaks and bleeding increases with a long leg length, on the other hand, the leak risk also increases with a short leg length due to tissue ischemia and necrosis[12]. Staplers with a long leg length must be used in the antrum, and those with a short leg length must be used in fundus. If a stapler with a short leg length is used in the antrum, this may cause dehiscence at the staple line[13]. We preferred staplers with a long leg length in the antrum, staplers with a medium leg length in the corpus, and staplers with a short leg length in the fundus.

The likelihood of leak through the cut edge of the stomach differs after sleeve gastrectomy. Of all leaks, 6.8%-14.3% were seen in distal 1/3 of the stomach while 75%-100% of them occurred in the proximal 1/3 of the stomach, particularly at the level of the esophagogastric junction[14]. The leaks occurring in 3 patients in our series were at the level of the esophagogastric junction, in other words, in the proximal 1/3 of the stomach. Thin walls and poor vascularity in this part of stomach may be responsible for the leaks.

Leaks usually occur due to mechanical and ischemic factors. Wrong firing of stapler, and cutting in irregular zig-zags are among the mechanical factors, and they usually cause leak in the first postoperative 2 d. Ischemic factors are dissection of the tissues excessively with energy devices (Harmonic, Ligasure) and disturbance of the vasculature[3]. Therefore, the tissues must be held carefully while using energy devices, and their use must be avoided in distal narrowings. Some surgeons wait for a while after squeezing the tissue with stapler in order to prevent leaks and bleeding, and they think that the fluid content of the tissue decreases and the vessels collapse in this way[15]. Our team also practices this method, and we think that it is effective.

The thickness of the bougies used in sleeve gastrectomy for calibration and standardization is still debated. Bariatric surgeons usually use bougies with a diameter of 32-40 F[16]. Some studies suggest that use of small-diameter bougies accelerates weight loss, however, increases the frequency of SLLs. The reference point here is higher intraluminal pressure in the stomach in case of a smaller diameter. Usually 34 and 36 F bougies have been recommended. Larger bougies may make reaching the ideal weight difficult[17]. We used 36 F bougies in our series.

The mechanism of leak and bleed prevention by SLRMs is not known. However, it is sure that the materials used show a compressive effect. It is not known how effective this compression is. Some argue that compressive materials shorten operation time more than oversewing sutures[18]. Durmush *et al*[19] studied 518 patients retrospectively, and reported that materials that were implanted to stapler cartridge shortened operation time by 13 min when compared to oversewing. Kasalicky *et al*[20] reported their experience on 207 patients, and stated that they did not use any reinforcement materials at the staple line or sutured it, the duration of operation shortened by 10 min, and the risk of bleeding did not increase. On the other hand, in their series with 100 patients, Shah *et al*[21] reported that SLRM shortened operation time by 14 min on average (58.8 ± 19.7 min *vs* 72.8 ± 25.8 min, P = 0.0153). In our series, the operation time was approximately 5 min longer in RG, however, the difference between the two groups was not statistically significant.

One of the reasons for increased SLLs is revision surgery. Revision surgery is usually performed in patients who had laparoscopic adjustable gastric band surgery, and later had band removal due to band-related problems. The risk of leak is higher than 10% in those

patients[22]. This high risk is due to insufficient stapler closure resulting from increased fibrosis and edema. Staged surgery was recommended to reduce this risk. Gastric band is removed in the first operation, and one week later, sleeve gastrectomy is performed[23]. Four of our patients had had laparoscopic gastric band before, and our team had removed the band. We performed staged surgery in all those patients, and no leaks were observed.

Early diagnosis and treatment of SLLs are important to decrease morbidity and mortality. Therefore, an appropriate method must be used to identify leaks. Methylene blue, air-liquid test, and observation of the staple line with endoscopes are used for this purpose[24,25]. In our study, leak test was performed by administration of diluted methylene blue both during surgery, and on postoperative day 1. A positive methylene blue test was confirmed in all of our patients by whole abdomen computerized tomography obtained after the patient was given an oral contrast material.

We could not have a final judgment on the use of SLRMs. The reasons for this is a small number of patients included in our study, retrospective and non-standardized study design, and no standardization of the materials used for reinforcement, which are limitations of our study. There is a need for further studies on a larger patient population with use of standard reinforcement materials.

In conclusion, sleeve gastrectomy is one of the most frequently performed bariatric procedures. Leak and bleeding are the most worrisome complications of this surgical technique. Various materials are used to reinforce the staple line to prevent those complications. However, there is no consensus in the literature on whether use of reinforcement materials decreased the complications or not. Although we could not have a final judgment in our study on use of SLRMs, we will go on using those materials in some patients depending on patient factors and course of surgery.

COMMENTS

Background

Sleeve gastrectomy is one of the most frequently performed surgical procedures in the treatment of obesity. However, it may result in some complications such as staple line leaks and bleeding, and even death.

Research frontiers

Reducing morbidities, particularly staple line leaks and bleeding, will increase the safety of the procedure. A number of surgeons use staple line reinforcement materials to decrease this complication while some others claim that those materials are not necessary, and use of then does not decrease staple line leak. There is still a need for research in this area.

Innovations and breakthroughs

In the authors' study, staple line leak was seen in 1 (2.2%) patient in the reinforcement group (RG), and in 2 (5.1%) patients in the non-RG (NRG), and bleeding was seen in 2 (5.1%) patients in the NRG, without any significant differences between the groups. The leaks occurred in 3 patients in their series were at the level of the esophagogastric junction, in other words, in the proximal 1/3 of the stomach. They preferred staplers with a long leg length in the antrum, staplers with a medium leg length in the corpus, and staplers with a short leg length in the fundus since the stomach wall is the thickest in the prepyloric antrum, and the thinnest in the fundus. They waited for a while after squeezing the tissue with stapler in order to prevent leaks and bleeding, and they think that the fluid content of the tissue decreases and the vessels collapse in this way. They performed staged surgery in gastric band patients, and no leaks were observed.

Applications

The authors could not have a final judgment on the use of staple line reinforcement materials. The reasons for this is a small number of patients included in their study, retrospective and non-standardized study design, and no standardization of the materials used for reinforcement. There is a need for further studies on a larger patient population with use of standard reinforcement materials.

Terminology

Laparoscopic sleeve gastrectomy was performed through 5 trocars: One 15 mm trocar for stapler handle, one 10 mm trocar for the camera, and three 5 mm trocars for instruments and liver retractor. The greater omentum was separated from the greater curvature, starting 2 cm proximal to the pylorus with Harmonic (Ethicon, United States) or Ligasure (Covidien, United States). The stomach was divided approximately 3 cm proximal to the pylorus, targeting 1 cm lateral to the esophagogastric junction. Echelon 60 stapler (Ethicon-Mexico) and Covidien 60 (Covidien, United States) stapler were used to divide the stomach, and a thick tissue stapler was used in the antrum, a thin tissue stapler was used in the fundus, and a medium-thick tissue stapler was used in the tissues between. A 36 F calibration tube was used to determine the width of the remaining stomach.

Peer-review

The manuscript on staple line reinforcement is well-written and thus, of interest for the readers of the journal.

REFERENCES

1 **World Health Organization**. Obesity and overweight, factsheet number 311, 2014. [Accessed 2015 April]. Available from: URL: http://www.who.int/mediacentre/factsheets/fs311/en/

2 **Melissas J**, Daskalakis M, Koukouraki S, Askoxylakis I, Metaxari M, Dimitriadis E, Stathaki M, Papadakis JA. Sleeve gastrectomy-a "food limiting" operation. *Obes Surg* 2008; **18**: 1251-1256 [PMID: 18663545 DOI: 10.1007/s11695-008-9634-4]

3 **Sakran N**, Goitein D, Raziel A, Keidar A, Beglaibter N, Grinbaum R, Matter I, Alfici R, Mahajna A, Waksman I, Shimonov M, Assalia A. Gastric leaks after sleeve gastrectomy: a multicenter experience with 2,834 patients. *Surg Endosc* 2013; **27**: 240-245 [PMID: 22752283 DOI: 10.1007/s00464-012-2426-x]

4 **Knapps J**, Ghanem M, Clements J, Merchant AM. A systematic review of staple-line reinforcement in laparoscopic sleeve gastrectomy. *JSLS* 2013; **17**: 390-399 [PMID: 24018075 DOI: 10.4293/108680813X13654754534639]

5 **Hady HR**, Dadan J, Gołaszewski P, Safiejko K. Impact of laparoscopic sleeve gastrectomy on body mass index, ghrelin, insulin and lipid levels in 100 obese patients. *Wideochir Inne Tech Maloinwazyjne* 2012; **7**: 251-259 [PMID: 23362424 DOI: 10.5114/wiitm.2011.28979]

6 **Langer FB**, Reza Hoda MA, Bohdjalian A, Felberbauer FX, Zacherl J, Wenzl E, Schindler K, Luger A, Ludvik B, Prager G. Sleeve gastrectomy and gastric banding: effects on plasma ghrelin levels. *Obes Surg* 2005; **15**: 1024-1029 [PMID: 16105401]

7 **Rawlins L**, Rawlins MP, Teel D. Human tissue thickness measurements from excised sleeve gastrectomy specimens. *Surg Endosc* 2014; **28**: 811-814 [PMID: 24196553 DOI: 10.1007/s00464-013-3264-1]

8 **Parikh M**, Issa R, McCrillis A, Saunders JK, Ude-Welcome A, Gagner M. Surgical strategies that may decrease leak after laparoscopic sleeve gastrectomy: a systematic review and meta-analysis of 9991 cases. *Ann Surg* 2013; **257**: 231-237 [PMID:

23023201 DOI: 10.1097/SLA.0b013e31826cc714]
9 **Albanopoulos K**, Alevizos L, Flessas J, Menenakos E, Stamou KM, Papailiou J, Natoudi M, Zografos G, Leandros E. Reinforcing the staple line during laparoscopic sleeve gastrectomy: prospective randomized clinical study comparing two different techniques. Preliminary results. *Obes Surg* 2012; **22**: 42-46 [PMID: 21533880 DOI: 10.1007/s11695-011-0421-2]
10 **Ser KH**, Lee WJ, Lee YC, Chen JC, Su YH, Chen SC. Experience in laparoscopic sleeve gastrectomy for morbidly obese Taiwanese: staple-line reinforcement is important for preventing leakage. *Surg Endosc* 2010; **24**: 2253-2259 [PMID: 20174931 DOI: 10.1007/s00464-010-0945-x]
11 **Chen B**, Kiriakopoulos A, Tsakayannis D, Wachtel MS, Linos D, Frezza EE. Reinforcement does not necessarily reduce the rate of staple line leaks after sleeve gastrectomy. A review of the literature and clinical experiences. *Obes Surg* 2009; **19**: 166-172 [PMID: 18795383 DOI: 10.1007/s11695-008-9668-7]
12 **Chekan E**, Whelan RL. Surgical stapling device-tissue interactions: what surgeons need to know to improve patient outcomes. *Med Devices* (Auckl) 2014; **7**: 305-318 [PMID: 25246812 DOI: 10.2147/MDER.S67338]
13 **Elariny H**, González H, Wang B. Tissue thickness of human stomach measured on excised gastric specimens from obese patients. *Surg Technol Int* 2005; **14**: 119-124 [PMID: 16525963]
14 **Abou Rached A**, Basile M, El Masri H. Gastric leaks post sleeve gastrectomy: review of its prevention and management. *World J Gastroenterol* 2014; **20**: 13904-13910 [PMID: 25320526 DOI: 10.3748/wjg.v20.i38.13904]
15 **Baker RS**, Foote J, Kemmeter P, Brady R, Vroegop T, Serveld M. The science of stapling and leaks. *Obes Surg* 2004; **14**: 1290-1298 [PMID: 15603641]
16 **Gagner M**. Leaks after sleeve gastrectomy are associated with smaller bougies: prevention and treatment strategies. *Surg Laparosc Endosc Percutan Tech* 2010; **20**: 166-169 [PMID: 20551815 DOI: 10.1097/SLE.0b013e3181e3d12b]
17 **Rosenthal RJ**, Diaz AA, Arvidsson D, Baker RS, Basso N, Bellanger D, Boza C, El Mourad H, France M, Gagner M, Galvao-Neto M, Higa KD, Himpens J, Hutchinson CM, Jacobs M, Jorgensen JO, Jossart G, Lakdawala M, Nguyen NT, Nocca D, Prager G, Pomp A, Ramos AC, Rosenthal RJ, Shah S, Vix M, Wittgrove A, Zundel N. International Sleeve Gastrectomy Expert Panel Consensus Statement: best practice guidelines based on experience of > 12,000 cases. *Surg Obes Relat Dis* 2012; **8**: 8-19 [PMID: 22248433 DOI: 10.1016/j.soard.2011.10.019]
18 **Gentileschi P**, Camperchioli I, D'Ugo S, Benavoli D, Gaspari AL. Staple-line reinforcement during laparoscopic sleeve gastrectomy using three different techniques: a randomized trial. *Surg Endosc* 2012; **26**: 2623-2629 [PMID: 22441975 DOI: 10.1007/s00464-012-2243-2]
19 **Durmush EK**, Ermerak G, Durmush D. Short-term outcomes of sleeve gastrectomy for morbid obesity: does staple line reinforcement matter? *Obes Surg* 2014; **24**: 1109-1116 [PMID: 24810764 DOI: 10.1007/s11695-014-1251-9]
20 **Kasalicky M**, Dolezel R, Vernerova E, Haluzik M. Laparoscopic sleeve gastrectomy without over-sewing of the staple line is effective and safe. *Wideochir Inne Tech Maloinwazyjne* 2014; **9**: 46-52 [PMID: 24729809 DOI: 10.5114/wiitm.2014.40387]
21 **Shah SS**, Todkar JS, Shah PS. Buttressing the staple line: a randomized comparison between staple-line reinforcement versus no reinforcement during sleeve gastrectomy. *Obes Surg* 2014; **24**: 2014-2020 [PMID: 25129485 DOI: 10.1007/s11695-014-1374-z]
22 **Fuks D**, Verhaeghe P, Brehant O, Sabbagh C, Dumont F, Riboulot M, Delcenserie R, Regimbeau JM. Results of laparoscopic sleeve gastrectomy: a prospective study in 135 patients with morbid obesity. *Surgery* 2009; **145**: 106-113 [PMID: 19081482 DOI: 10.1016/j.surg.2008.07.013]
23 **Acholonu E**, McBean E, Court I, Bellorin O, Szomstein S, Rosenthal RJ. Safety and short-term outcomes of laparoscopic sleeve gastrectomy as a revisional approach for failed laparoscopic adjustable gastric banding in the treatment of morbid obesity. *Obes Surg* 2009; **19**: 1612-1616 [PMID: 19711138 DOI: 10.1007/s11695-009-9941-4]
24 **Deitel M**, Crosby RD, Gagner M. The First International Consensus Summit for Sleeve Gastrectomy (SG), New York City, October 25-27, 2007. *Obes Surg* 2008; **18**: 487-496 [PMID: 18357494 DOI: 10.1007/s11695-008-9471-5]
25 **Gagner M**, Deitel M, Kalberer TL, Erickson AL, Crosby RD. The Second International Consensus Summit for Sleeve Gastrectomy, March 19-21, 2009. *Surg Obes Relat Dis* 2009; **5**: 476-485 [PMID: 19632647 DOI: 10.1016/j.soard.2009.06.001]

P- Reviewer: Kin T, Losanoff JE **S- Editor**: Tian YL
L- Editor: Wang TQ **E- Editor**: Liu SQ

World Journal of Surgical Procedures

Submit a Manuscript: http://www.wjgnet.com/esps/
Help Desk: http://www.wjgnet.com/esps/helpdesk.aspx
DOI: 10.5412/wjsp.v5.i3.229

World J Surg Proced 2015 November 28; 5(3): 229-234
ISSN 2219-2832 (online)

CASE REPORT

Malignant melanoma in the pediatric population

John Psaltis, Eric Reintgen, Ali Antar, Mark Giori, Leah Alvin, Alyssa Benjamin, Bridget Budny, Taylor Gianangelo, Aaron Gruman, Anna Stamas, Michael Reintgen, Rosemary Giuliano, Jeff Smith, Douglas Reintgen

John Psaltis, Eric Reintgen, Ali Antar, Mark Giori, Leah Alvin, Alyssa Benjamin, Bridget Budny, Taylor Gianangelo, Aaron Gruman, Anna Stamas, Michael Reintgen, Rosemary Giuliano, Douglas Reintgen, Department of Surgery, Morsani School of Medicine, University of South Florida, Tampa, FL 33612, United States

Jeff Smith, Department of Pathology, Florida Hospital - N Pinellas, Tarpon Springs, FL 34689, United States

Author contributions: All authors contributed to this manuscript.

Institutional review board statement: This study was approved by the University of South Florida Institutional Review Board - 6/2015.

Informed consent statement: Informed consent was obtained from the parents of the children described in the study.

Conflict-of-interest statement: All the authors have no conflicts of interests to declare.

Correspondence to: Douglas Reintgen, MD, Department of Surgery, Morsani School of Medicine, University of South Florida, MDC 52, 12901 Bruce B. Downs Blvd., Tampa, FL 33612, United States. dreintge@health.usf.edu
Telephone: +1-813-4408554
Fax: +1-813-9059891

Received: May 20, 2015
Peer-review started: May 21, 2015
First decision: June 18, 2015
Revised: July 1, 2015
Accepted: September 7, 2015
Article in press: September 8, 2015
Published online: November 28, 2015

Abstract

Controversial pigmented lesions in children are a problem for pathologist, clinicians and families that are confronted with this dilemma. Some skin lesions in this population defy diagnosis with pathologists split between a benign diagnosis and a cancer diagnosis. Three cases of controversial pigmented lesions in the pediatric population are presented. Three patients underwent radical resection of the controversial pigmented lesion, intra-operative lymphatic mapping and sentinel lymph node (SLN) biopsy. Due to the low morbidity of the SLN procedure a case is made to perform lymphatic mapping in this clinical scenario. If the SLNs are negative, not much is lost except for the scar and this becomes another line of evidence that perhaps the original lesion was benign. If the SLN shows metastatic cells, then the original skin lesion must be malignant and the patient is offered stage Ⅲ recommendations that would include complete node dissections and adjuvant Interferon therapy. This strategy provides for adequate treatment of the worse-case scenario, that the skin lesion is malignant. The cost to the patient is a low morbidity procedure, the SLN biopsy.

Key words: Pediatric pigmented skin lesions; Sentinel lymph node biopsy; Melanoma

Core tip: The sentinel lymph node staging procedure can be used to treat effectively pediatric patients with ambiguous pigmented skin lesions.

Psaltis J, Reintgen E, Antar A, Giori M, Alvin L, Benjamin A, Budny B, Gianangelo T, Gruman A, Stamas A, Reintgen M, Giuliano R, Smith J, Reintgen D. Malignant melanoma in the pediatric population. *World J Surg Proced* 2015; 5(3): 229-234 Available from: URL: http://www.wjgnet.com/2219-2832/full/v5/i3/229.htm DOI: http://dx.doi.org/10.5412/wjsp.v5.i3.229

INTRODUCTION

Malignant melanomas are remarkably rare in children. Roughly 2% of melanomas occur in children under the age of 20 and approximately 0.4% of cases occur in prepubescent children[1]. In the United States, childhood and adolescent melanoma accounts for only 1.3% of all cases of melanoma[2]. Nevertheless, malignant melanoma (MM) is a potentially fatal disease, and it is critical to consider MM as a differential diagnosis of any pigmented lesion in a child. Clinically, childhood melanoma presents similarly to adult melanoma, and the use of the asymmetry, borders, color, diameter, and evolution of early diagnosis criteria can be used to screen children as well[3]. It has been shown that children diagnosed with melanoma have the same prognostic outcomes as their adult counterparts, while those diagnosed with melanoma before the age of 10 have a better outcome than those diagnosed between the ages of 10 and 20[3].

Nevi can be a common finding amongst children. Depending on the size of the lesion, a congenital melanocytic nevus is one of the risk factors for developing childhood melanoma due to the potential malignant transformation[4]. In dealing with pigmented lesions in this population of particular concern is the Spitz nevus, a benign lesion with morphological features similar to malignant melanoma, first described by Sophie Spitz in 1948[5-9]. Spitz stated that although this type of nevus was histologically malignant, it behaved in a benign manner[10]. As such, one of the biggest difficulties in diagnosing melanoma in children is differentiating a malignant melanoma from a benign Spitz Nevus[7,8]. Such lesions of uncertain biological potential are termed atypical spitzoid melanocytic neoplasms[7]. One study demonstrated that even amongst an experienced panel of pathologists, the variability in diagnosis was still substantial[9]. The differential diagnosis between a melanoma and a dysplastic Spitz nevus was still confusing, with the most common error being an interpretation of a benign lesion when it was actually malignant[11]. In addition pathologists are wary of saddling a child with a malignant diagnosis if indeed the skin lesion behaves in a benign fashion. Under-diagnosing or over-diagnosing controversial pigmented lesions in the pediatric population have repercussions either way. If under-diagnosed, the patient may not receive the standard definitive cancer treatment, such as a radical resection and a sentinel lymph node (SLN) biopsy. Although somewhat controversial, this primary treatment has been associated with a survival benefit in adults if indeed the SLN is found to contain metastatic disease. By under-treating children with MM, life-saving treatment may be denied[4,12-15]. If over-diagnosed, the patient may have procedures that are not necessary, resulting in increased morbidity. In addition the children are then labeled with a cancer diagnosis for the remainder of their lives. Patients mistakenly diagnosed with melanoma may exhibit fear of relapse and may not be able to obtain life or health insurance[14].

The misdiagnosis of melanoma is the second most common reason for cancer malpractice claims in the United States, second only to mistakes in breast cancer diagnosis[16]. All these claims are involved in the under-diagnosis of melanoma and physicians have always been willing to practice defensive medicine, despite increasing the costs of care, to guard against under-diagnosis and less than standard treatment.

In this report we describe three patients with controversial pigmented lesions in the pediatric population. The reports have complete pathology that helps to define the difficulty of the diagnosis, and the full spectrum of issues that arise in dealing with atypical pigmented skin lesions in this population is illustrated. A case is made for lymphatic mapping and SLN biopsy in this setting since the procedure exhibits low morbidity and finding metastatic cells in the SLN can help with the primary diagnosis. Finally a "standard of care" treatment is given for the metastatic disease.

CASE REPORT

Case 1

A previously healthy 2-year-old girl presented to outside physicians with an irregular mole on her right calf. A biopsy was performed and pathology showed an atypical nevus (Spitz nevus) *vs* melanoma. The patient underwent a radical resection of the primary melanoma and SLN biopsy. Pathology showed a 4.1 mm melanoma with clear margins at the primary site. However 2/3 right groin SLNs were positive for metastatic melanoma. The patient underwent a complete lymph node dissection (CLND) of her right groin and all further nodes were negative. The patient was referred to St. Jude's Children Hospital where she received 1 year of adjuvant Interferon therapy.

Case 2

This case involves an otherwise healthy 4-year-old white male who presented with a solid mass in his pinna of the right ear that appeared mostly subcutaneous. It had increased in size and became painful and irritating to the patient.

The patient underwent an excisional biopsy of the mass and pathology revealed features of an intradermal Spitz nevus, with low mitotic rate, nuclear atypia and incomplete maturation of melanocytes at the base of the lesion. Local pathology showed an atypical nevus with the proliferation of large melanocytes. The lesion was positive for Melan-A and S-100 and negative for cytokeratin AE1/AE3, desmin, ESA, GFAP, muscle specific actin and Ki-67. Ki-67 stain was positive and showed increased proliferative activity in the tumor cells. The case was then sent for consultation with the Mayo Clinic, which reported a non-ulcerated malignant spitzoid melanoma with a Breslow thickness of 3.6 mm. The lesion was analyzed at UCSF and pathology was interpreted as an atypical compound proliferation

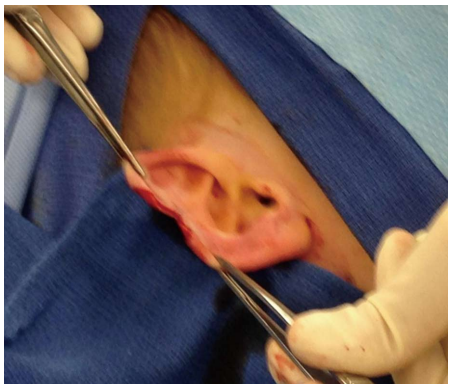

Figure 1 Intra-operative photograph of wedge resection of the right ear as a primary treatment of the melanoma from case 2.

Figure 2 Intra-operative photograph of repair of wedge resection of right ear and sentinel lymph node biopsy of the right posterior triangle.

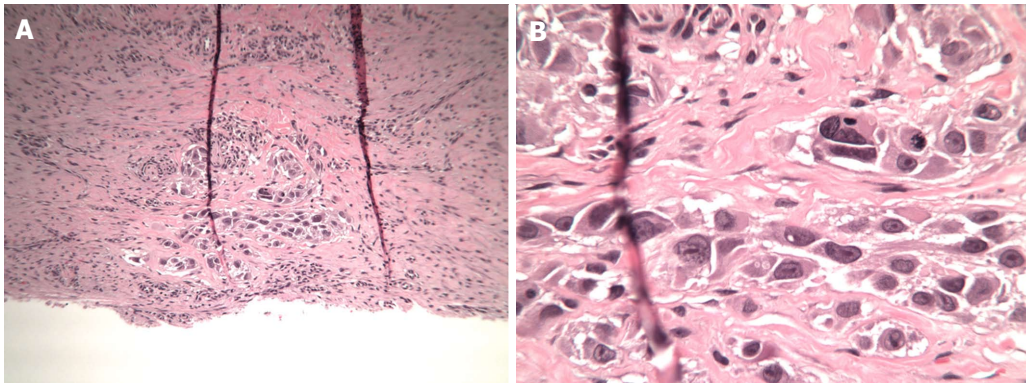

Figure 3 Photomicrography of the wedge resection of the right ear (H and E stain) (A) and higher magnification of malignant melanoma cells (B). In the deep dermis there were nests of large malignant appearing melanocytes with some mitotic figures.

of spitzoid melanocytes consistent with a spitzoid melanoma. Fluorescence *in situ* hybridization analysis of the tumor demonstrated gain in chromosomes 6p, 11q and 8q. These molecular findings favor interpretation as a spitzoid melanoma. Immunostaining for p16 demonstrated relative prominent positivity to verify no loss in chromosome 9p.

The patient was taken to the OR where, under general anesthesia, he underwent a radical resection of the melanoma of the right ear (wedge resection), intra-operative lymphatic mapping and SLN biopsy (Figures 1 and 2). Histologic examination revealed the SLNs to be negative for any evidence of metastatic disease. The wedge resection of the ear showed a nest of malignant appearing melanocytes deep within the dermis (Figure 3) and margins were free. The final diagnosis was residual malignant spitzoid melanoma with clear margins and negative SLNs.

Case 3

A previously healthy 12-year-old girl presented to her local dermatologist with an atypical nevus on her left forearm. A biopsy was performed that had the differential diagnosis of a dysplastic nevus *vs* melanoma (Figure 4A). The patient was treated under the melanoma protocol at USF with a radical resection of the primary site, intra-operative lymphatic mapping and SLN biopsy. Pathology showed clear margins from the primary site but the SLN was initially diagnosed as positive for micrometastatic disease (Figure 4B). A second opinion on the pathology showed a dysplastic nevus and benign nevus cells in the SLN (Figure 5). The patient is being observed.

The melanoma database at the University of South Florida (USF) and Florida Hospital - North Pinellas is a prospective database that is used for day-to-day clinical care and for clinical research. Under a USF IRB approval, all patients registered in the database are consented to have their data de-identified and used in future research projects. Case reports at USF do not require IRB approval.

DISCUSSION

Despite such difficulties in diagnosing malignant melanoma, it is important to avoid a delay in the diagnosis because early detection and aggressive treatment improves the patient' chances of survival[6,10,12]. The recommended course of action after detection and diagnosis of malignant melanoma is a radical resection of the primary site and if the melanoma is greater than 0.76 mm in thickness, a SLN biopsy. Complete lymph node dissections are reserved for those patients with a positive SLN[6-10]. The nosologic category of childhood

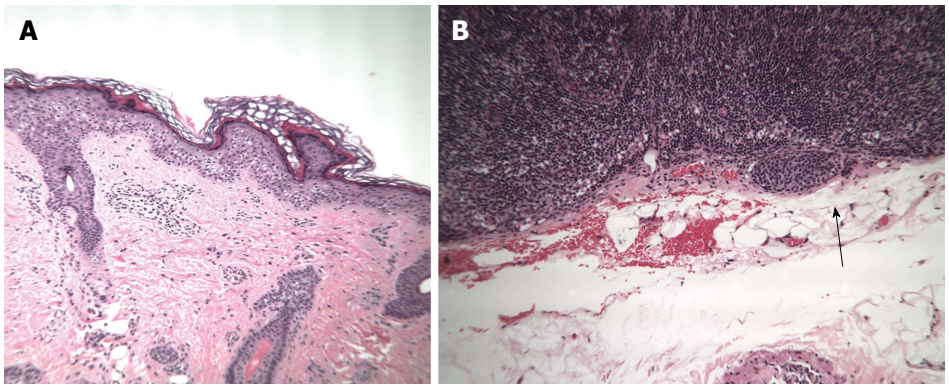

Figure 4 H and E stain. A: Photomicrograph of primary lesion removed from the left forearm from case 3; B: Photomicrograph of the sentinel lymph node from case 3 - H and E stain - showing subcapsular deposits of pigmented cells (arrow).

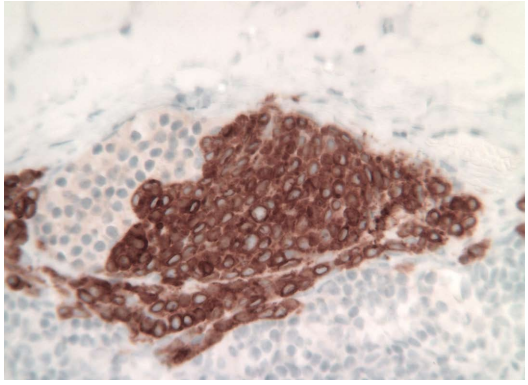

Figure 5 Immunostaining (MART-1) of the sentinel lymph node from case 3.

spitzoid melanoma refers to an emerging entity that seems distinct from conventional adult melanoma. Such tumors often lack BRAF mutations and are reported in the past literature under such flawed designations as malignant Spitz nevus. Findings to date suggest a small risk for metastases to regional lymph nodes with a low risk for widespread dissemination. It is thought that such lesions represent a low-grade form of melanoma[14]. Immunohistochemical differentiation with S-100 protein and HMB-45, although useful in identifying melanocytic cells, is not useful in distinguishing between malignant melanoma and Spitz Nevi, as both lesions stain positive with both markers[6,17]. A newer diagnostic assay using 5 markers (ARPC2, FN1, RGS1, SPP1 and WNT2) has been shown to be effective in differentiating between malignant melanoma and Spitz nevi[17]. Using an algorithm based on the pattern and intensity of these 5 markers with varying skin lesions, this multi-marker assay was able to correctly diagnose a high percentage of melanomas, Spitz nevi, dysplastic nevi, and other misdiagnosed lesions[17]. The multi-marker assay corrected three-quarters of cases in which incorrect pathological diagnosis were rendered, including melanomas initially diagnosed as nevi[17]. The test could be used to aid in the histologic diagnosis of melanoma, preventing errors in under diagnosis[17]. Regardless, it still remains difficult for clinicians and pathologists to differentiate between the two diagnoses (benign *vs* malignant), even for those who deal with such cases on a daily basis.

Performing a SLN biopsy after a wide local excision of the lesion can serve both a diagnostic and therapeutic purpose. Histopathological examination of the harvested SLNs can be used to support the diagnosis of the lesion as benign, helping to avoid incorrectly burdening a young patient with a lifelong diagnosis of malignancy as well as decrease the morbidity from subsequent and more invasive procedures such as a CLND. However, if the pathology reveals that the lesion is malignant, then the nodes can still serve a further diagnostic purpose by allowing clinicians to better stage and grade the harmful lesion, and determine if further surgery is indicated. In addition to these diagnostic benefits, the removal of the SLN can serve a therapeutic purpose by removing all disease, since in all stage Ⅲ patients (regional nodal disease), the metastatic disease is confined to the SLN 85% of the time. That is, the SLN acts as an effective trap in the regional basin to spread of the metastatic disease to higher non-SLNs[18].

Although controversy exists on whether performing the SLN procedure provides a survival benefit to the patient, we know that the best evidence of efficacy for the SLN procedure is displayed in those patients with documented stage Ⅲ disease, and a positive SLN[12-15].

Controversial pigmented lesions in children refer to the fact that some skin lesions in this population are problematic in trying to determine a benign pathology from a malignant. Many times multiple pathologists will render an opinion on the skin biopsy with some basing their benign reading on the prognosis for a Spitz nevus quoted in the literature for patients even though the cytology of the cells are malignant. Other pathologists prefer to interpret the skin histology based on what they observe with their microscopic examination. Newer genetic profiling of these skin lesions may be helpful in differentiating these lesions into appropriate benign *vs* malignant categories. However, clinicians are left with little guidance in trying to care for patients with this clinical scenario.

For the last 10 years the Cutaneous Oncology Pro-

gram at USF/FH-N Pinellas has implemented a protocol for dealing with these difficult cases. Since the lymphatic mapping and SLN procedure is a low morbidity procedure, pediatric patients with controversial pigmented lesions are treated as if they carry the melanoma diagnosis, and are considered candidates for a radical resection of the primary melanoma to obtain clear margins and SLN biopsy for nodal staging. This protocol can accomplish the following: (1) If the SLN is negative for metastases, then that data would be considered a line of evidence that the skin lesion is benign and the patient has a good prognosis; (2) If the SLN is positive for metastases, this is a good indication that the original skin lesion is malignant making the patient eligible for CLNDs and adjuvant Interferon therapy. Case 3 illustrates the fact that benign nevus cell rests in the SLN must be differentiated from metastatic melanoma cells in the SLN; and (3) Patients will not be under treated if indeed they have the malignant phenotype. Likewise any over treatment of the patients is associated with a low morbidity operation, the SLN biopsy.

Even though malignant melanoma diagnoses in children are rare, we must be cognizant of such a possibility because early diagnosis is crucial to patient outcome. Despite new methods used to distinguish nevi and melanoma from each other, a certain protocol system, such as that implemented at the Cutaneous Oncology Program at USF/FH-N Pinellas, is crucial in assuring the appropriate patient treatment.

As recurrences and melanoma-related death inevitably remain a possibility years after patient diagnosis, it is necessary for long-term patient follow-up, including full-body skin examination in this population for the remainder of their lives[3,19].

COMMENTS

Case characteristics

Pediatric patients with controversial pigmented skin lesions are problematic in treatment and for assigning prognosis.

Clinical diagnosis

Three patients are described with skin lesions where the histologic diagnosis of benign or malignant is in doubt.

Differential diagnosis

The differential diagnosis is between a benign dysplastic nevus and a malignant melanoma.

Laboratory diagnosis

Histologic examination using routine hematoxolin and eosin stain and immunohistochemistry with S-100 and HMB-45 stains was performed.

Imaging diagnosis

Pre-operative lymphoscintigraphy was performed to identify all nodal basins at risk for metastases.

Pathological diagnosis

The primary site differential was between dysplastic nevi *vs* malignant melanoma. The differential diagnosis in the sentinel lymph nodes (SLNs) was metastatic melanoma *vs* benign nevus cells.

Treatment

All 3 patients underwent radical resection of their primary sites and SLN biopsy. The patient with a positive SLN was administered adjuvant Interferon alfa-2b for 1 year.

Term explanation

The SLNs are all nodes in the regional basin that have a direct connection by way of afferent lymphatics to the primary melanoma site. SLNs are identified with either a blue dye or radiocolloid mapping technique.

Experiences and lessons

Since the lymphatic mapping and SLN procedure is a low morbidity procedure, pediatric patients with controversial pigmented lesions are treated as if they carry the melanoma diagnosis, and are considered candidates for a radical resection of the primary melanoma to obtain clear margins and SLN biopsy for nodal staging.

Peer-review

This article includes valuable information regarding the complexities of distinguishing benign nevi from malignant melanoma in the pediatric population.

REFERENCES

1 **Boddie AW**, Smith JL, McBride CM. Malignant melanoma in children and young adults: effect of diagnostic criteria on staging and end results. *South Med J* 1978; **71**: 1074-1078 [PMID: 684494 DOI: 10.1097/00007611-197809000-00009]

2 **Hamre MR**, Chuba P, Bakhshi S, Thomas R, Severson RK. Cutaneous melanoma in childhood and adolescence. *Pediatr Hematol Oncol* 2002; **19**: 309-317 [PMID: 12078862 DOI: 10.1080/08880010290057327]

3 **Ferrari A**, Bono A, Baldi M, Collini P, Casanova M, Pennacchioli E, Terenziani M, Marcon I, Santinami M, Bartoli C. Does melanoma behave differently in younger children than in adults? A retrospective study of 33 cases of childhood melanoma from a single institution. *Pediatrics* 2005; **115**: 649-654 [PMID: 15741367 DOI: 10.1542/peds.2004-0471]

4 **van der Ploeg AP**, Haydu LE, Spillane AJ, Quinn MJ, Saw RP, Shannon KF, Stretch JR, Uren RF, Scolyer RA, Thompson JF. Outcome following sentinel node biopsy plus wide local excision versus wide local excision only for primary cutaneous melanoma: analysis of 5840 patients treated at a single institution. *Ann Surg* 2014; **260**: 149-157 [PMID: 24633018 DOI: 10.1097/SLA.0000000000000500]

5 **Spitz S**. Melanomas of childhood. *Am J Pathol* 1948; **24**: 591-609 [PMID: 18859360 DOI: 10.3322/canjclin.41.1.40]

6 **Reintgen DS**, Vollmer R, Seigler HF. Juvenile malignant melanoma. *Surg Gynecol Obstet* 1989; **168**: 249-253 [PMID: 2919354]

7 **Ghazi B**, Carlson GW, Murray DR, Gow KW, Page A, Durham M, Kooby DA, Parker D, Rapkin L, Lawson DH, Delman KA. Utility of lymph node assessment for atypical spitzoid melanocytic neoplasms. *Ann Surg Oncol* 2010; **17**: 2471-2475 [PMID: 20224858 DOI: 10.1245/s10434-010-1022-3]

8 **Murali R**, Sharma RN, Thompson JF, Stretch JR, Lee CS, McCarthy SW, Scolyer RA. Sentinel lymph node biopsy in histologically ambiguous melanocytic tumors with spitzoid features (so-called atypical spitzoid tumors). *Ann Surg Oncol* 2008; **15**: 302-309 [PMID: 18000712 DOI: 10.1245/s10434-007-9577-3]

9 **Allen AC**, Spitz S. Histogenesis and clinicopathologic correlation of nevi and malignant melanomas; current status. *AMA Arch Derm Syphilol* 1954; **69**: 150-171 [PMID: 13123539 DOI: 10.1001/archderm.1954.01540140018002]

10 **Ceballos PI**, Ruiz-Maldonado R, Mihm MC. Melanoma in children. *N Engl J Med* 1995; **332**: 656-662 [PMID: 7845431 DOI: 10.1056/NEJM199503093321007]

11 **Barnhill RL**, Argenyi ZB, From L, Glass LF, Maize JC, Mihm MC, Rabkin MS, Ronan SG, White WL, Piepkorn M. Atypical Spitz nevi/tumors: lack of consensus for diagnosis, discrimination from melanoma, and prediction of outcome. *Hum Pathol* 1999; **30**: 513-520 [PMID: 10333219 DOI: 10.1016/S0046-8177(99)90193-4]

12 **Morton DL**, Thompson JF, Cochran AJ, Mozzillo N, Nieweg OE, Roses DF, Hoekstra HJ, Karakousis CP, Puleo CA, Coventry BJ, Kashani-Sabet M, Smithers BM, Paul E, Kraybill WG, McKinnon JG, Wang HJ, Elashoff R, Faries MB. Final trial report of sentinel-node biopsy versus nodal observation in melanoma. *N Engl J Med* 2014; **370**: 599-609 [PMID: 24521106 DOI: 10.1056/NEJMoa1310460]

13 **Coit D**. Sentinel lymph node biopsy for melanoma: a plea to let the data speak. *Ann Surg Oncol* 2014; **21**: 3359-3361 [PMID: 25059791 DOI: 10.1245/s10434-014-3947-4]

14 **Thompson JF**, Faries MB, Cochran AJ. Sentinel lymph node biopsy for melanoma: a plea to let the data be heard. *Ann Surg Oncol* 2014; **21**: 3362-3364 [PMID: 25103536 DOI: 10.1245/s10434-014-3967-0]

15 **Kachare SD**, Brinkley J, Wong JH, Vohra NA, Zervos EE, Fitzgerald TL. The influence of sentinel lymph node biopsy on survival for intermediate-thickness melanoma. *Ann Surg Oncol* 2014; **21**: 3377-3385 [PMID: 25063010 DOI: 10.1245/s10434-014-3954-5]

16 **Palazzo JP**, Duray PH. Congenital agminated Spitz nevi: immunoreactivity with a melanoma-associated monoclonal antibody. *J Cutan Pathol* 1988; **15**: 166-170 [PMID: 3397410 DOI: 10.1111/j.1600-0560.1988.tb00537.x]

17 **Kashani-Sabet M**, Rangel J, Torabian S, Nosrati M, Simko J, Jablons DM, Moore DH, Haqq C, Miller JR, Sagebiel RW. A multi-marker assay to distinguish malignant melanomas from benign nevi. *Proc Natl Acad Sci USA* 2009; **106**: 6268-6272 [PMID: 19332774 DOI: 10.1073/pnas.0901185106]

18 **Reintgen C**, Reintgen M, Reintgen D. Evidence for a Better Nodal Staging System for Cancers. The Importance of Non-Sentinel Lymph Node Metastases. Bassett Society, Durham, NC, 2014

19 **Larsen AK**, Jensen MB, Krag C. Long-term Survival after Metastatic Childhood Melanoma. *Plast Reconstr Surg Glob Open* 2014; **2**: e163 [PMID: 25289356 DOI: 10.1097/GOX.0000000000000122]

P- Reviewer: Mocellin S, de la Serna IL **S- Editor**: Ji FF
L- Editor: A **E- Editor**: Liu SQ

Published by **Baishideng Publishing Group Inc**
8226 Regency Drive, Pleasanton, CA 94588, USA
Telephone: +1-925-223-8242
Fax: +1-925-223-8243
E-mail: bpgoffice@wjgnet.com
Help Desk: http://www.wjgnet.com/esps/helpdesk.aspx
http://www.wjgnet.com