

World Journal of *Otorhinolaryngology*

World J Otorhinolaryngol 2019 December 20; 8(2): 12-18



CASE REPORT

- 12 Synovial osteochondromatosis of the temporomandibular joint: A case report
Romero N, Mulcahy CF, Barak S, Shand MF, Badger CD, Joshi AS

ABOUT COVER

Associate Editor of *World Journal of Otorhinolaryngology*, Tarek A Abulezz, MBChB, MD, MSc, Professor, Plastic Surgery Department, Faculty of Medicine, Sohag 82524, Egypt.

AIMS AND SCOPE

The primary aim of *World Journal of Otorhinolaryngology* (WJO, *World J Otorhinolaryngol*) is to provide scholars and readers from various fields of otorhinolaryngology with a platform to publish high-quality basic and clinical research articles and communicate their research findings online.

WJO mainly publishes articles reporting research results and findings obtained in the field of otorhinolaryngology and covering a wide range of topics including adenoidectomy, audiology, auditory brain stem implantation, ciliary motility disorders, cochlear implantation, ear diseases, endolymphatic shunt, fenestration, labyrinth, laryngeal diseases, laryngectomy, laryngoplasty, laryngoscopy, middle ear ventilation, myringoplasty, nasal surgical procedures, neck dissection, nose diseases, ossicular replacement, otologic surgical procedures, otorhinolaryngologic diseases, otorhinolaryngologic neoplasms, otorhinolaryngologic surgical procedures, pharyngeal diseases, pharyngectomy, pharyngostomy, rhinoplasty, stapes surgery, tonsillectomy, tracheostomy, transtympanic micropressure treatment, and tympanoplasty.

INDEXING/ABSTRACTING

The WJO is now indexed in China National Knowledge Infrastructure (CNKI), China Science and Technology Journal Database (CSTJ), and Superstar Journals Database.

RESPONSIBLE EDITORS FOR THIS ISSUE

Responsible Electronic Editor: *Lu-Lu Qi*
Proofing Production Department Director: *Xiang Li*

NAME OF JOURNAL

World Journal of Otorhinolaryngology

ISSN

ISSN 2218-6247 (online)

LAUNCH DATE

December 28, 2011

FREQUENCY

Irregular

EDITORS-IN-CHIEF

Amr El-Shazly

EDITORIAL BOARD MEMBERS

<https://www.wjnet.com/2218-6247/editorialboard.htm>

EDITORIAL OFFICE

Ya-Juan Ma, Director

PUBLICATION DATE

December 20, 2019

COPYRIGHT

© 2019 Baishideng Publishing Group Inc

INSTRUCTIONS TO AUTHORS

<https://www.wjnet.com/bpg/gerinfo/204>

GUIDELINES FOR ETHICS DOCUMENTS

<https://www.wjnet.com/bpg/GerInfo/287>

GUIDELINES FOR NON-NATIVE SPEAKERS OF ENGLISH

<https://www.wjnet.com/bpg/gerinfo/240>

PUBLICATION MISCONDUCT

<https://www.wjnet.com/bpg/gerinfo/208>

ARTICLE PROCESSING CHARGE

<https://www.wjnet.com/bpg/gerinfo/242>

STEPS FOR SUBMITTING MANUSCRIPTS

<https://www.wjnet.com/bpg/GerInfo/239>

ONLINE SUBMISSION

<https://www.f6publishing.com>



Synovial osteochondromatosis of the temporomandibular joint: A case report

Nahir Romero, Collin F Mulcahy, Stephanie Barak, Muhammed F Shand, Christopher D Badger, Arjun S Joshi

ORCID number: Nahir Romero (0000-0002-2699-3114); Collin F Mulcahy (0000-0002-1071-2138); Stephanie Barak (0000-0003-3966-1263); Muhammed F Shand (0000-0002-3481-2838); Christopher D Badger (0000-0002-3714-0272); Arjun S Joshi (0000-0002-9501-9067).

Author contributions: Romero N drafted the initial manuscript, reviewed and revised the manuscript and participated in the ancillary care of the patient as a clinical assistant; Mulcahy CF reviewed the and contributed to the manuscript; Barak S was the patient's clinical pathologist and as such analyzed and interpreted the pathologic process of the disease and reviewed the manuscript; Shand MF reviewed, revised and formatted the manuscript; Badger CD contributed to, reviewed, and revised the manuscript; Joshi AS was the patient's head and neck surgeon who developed the treatment plan, cared for the patient in the follow up period, reviewed and revised the manuscript; All authors approved the final manuscript for submission.

Informed consent statement: Informed written consent was obtained from the patient for display of case-related images for research purposes. This case contains no identifiable patient characteristics.

Conflict-of-interest statement: The authors declare they have no conflict of interest.

CARE Checklist (2016) statement:

Nahir Romero, Collin F Mulcahy, Christopher D Badger, Arjun S Joshi, Department of Surgery, Division of Otolaryngology, Head and Neck Surgery, George Washington University Hospital, Washington, DC 20037, United States

Stephanie Barak, Department of Pathology, George Washington University Hospital, Washington, DC 20037, United States

Muhammed F Shand, George Washington University School of Medicine and Health Sciences, Washington, DC 20037, United States

Corresponding author: Collin F Mulcahy, MD, Resident Physician, Department of Surgery, Division of Otolaryngology, Head and Neck Surgery, George Washington University Hospital, 2300 M Street NW, Washington, DC 20037, United States. cfmulcahy@gwu.edu

Telephone: +1-202-7413250

Fax: +1-202-7413382

Abstract

BACKGROUND

Synovial osteochondromatosis is a rare but benign condition that can result in significant impairment of joint functionality. This case report documents an uncommon presentation of this disorder occurring within the temporomandibular joint, causing the patient significant pain, trismus, and difficulty with daily activities such as eating and speaking. A review of the literature including disease mechanisms and previously documented cases is included to provide comprehensive background for clinical decision-making.

CASE SUMMARY

A 48-year-old male patient presented with a 3-mo history of trismus, crepitus with jaw movement and significant pain while chewing. Physical examination revealed a firm mass and tenderness to palpation at the right temporomandibular joint. Further workup revealed a bilobed mass extending into the joint space as well as significant bony erosion of the glenoid fossa. The patient underwent mass excision with joint reconstruction and pathology revealed synovial osteochondromatosis. The patient reported significant improvement in his symptoms postoperatively.

CONCLUSION

This report outlines the investigative approach and treatment course of synovial osteochondromatosis. The positive outcome following surgical intervention in this case emphasizes the importance of interdisciplinary collaboration and the potential for improvement in quality of life of this patient population.

The authors have read the CARE Checklist (2016), and the manuscript was prepared and revised according to the CARE Checklist (2016).

Open-Access: This article is an open-access article which was selected by an in-house editor and fully peer-reviewed by external reviewers. It is distributed in accordance with the Creative Commons Attribution Non Commercial (CC BY-NC 4.0) license, which permits others to distribute, remix, adapt, build upon this work non-commercially, and license their derivative works on different terms, provided the original work is properly cited and the use is non-commercial. See: <http://creativecommons.org/licenses/by-nc/4.0/>

Manuscript source: Unsolicited manuscript

Received: June 20, 2019

Peer-review started: June 27, 2019

First decision: August 7, 2019

Revised: August 26, 2019

Accepted: November 26, 2019

Article in press: November 26, 2019

Published online: December 20, 2019

P-Reviewer: Chhabra N, Ciunan RR, Dhiwakar M

S-Editor: Ma YJ

L-Editor: A

E-Editor: Qi LL



Key words: Osteochondromatosis; Temporomandibular joint; Mandible; Resection; Case report

©The Author(s) 2019. Published by Baishideng Publishing Group Inc. All rights reserved.

Core tip: Synovial osteochondromatosis is a rare condition that arises from metaplasia and proliferation of synovial cells lining a joint space, which can impair joint function. It can be easily overlooked when working up non-specific symptoms such as preauricular pain and swelling. We present the case of a 48-year-old man with a history of significant unilateral temporomandibular joint (TMJ) pain, trismus, and dysphagia who was found to have synovial osteochondromatosis of the TMJ with erosion of the glenoid fossa. The patient underwent resection of the mass and TMJ reconstruction with a rib cartilage graft, resulting in alleviation of symptoms.

Citation: Romero N, Mulcahy CF, Barak S, Shand MF, Badger CD, Joshi AS. Synovial osteochondromatosis of the temporomandibular joint: A case report. *World J Otorhinolaryngol* 2019; 8(2): 12-18

URL: <https://www.wjgnet.com/2218-6247/full/v8/i2/12.htm>

DOI: <https://dx.doi.org/10.5319/wjo.v8.i2.12>

INTRODUCTION

Synovial osteochondromatosis is a condition in which the synovial cells lining a joint space undergo metaplasia and proliferation, resulting in nodular masses, which may ossify within the joint capsule. Ultimately several loose or pedicled bodies form within the joint and cause significant symptoms and impairment of joint functionality. Affected regions most commonly occur within the axial skeleton, including the knee or shoulder capsule^[1]. The temporomandibular joint (TMJ) is rarely affected and has only been documented in about 100 cases over the last 20 years^[2,3]. Etiology of this condition is unknown, but it is hypothesized to involve abnormal expression of specific growth factors and cytokines^[4,5]. This disease is generally monoarticular and tends to present in adults. Involvement of the TMJ is more common in women than men, most often occurring between the ages of 30 and 60^[6]. Although considered a benign condition, synovial osteochondromatosis carries a risk of aggressive and progressive bone erosion which can extend intracranially and even invade the dura^[3]. There is also a small incidence of malignant transformation to chondrosarcoma^[7].

Patients with synovial osteochondromatosis of the TMJ often present with unilateral pain, malocclusion, and swelling^[8-10]. Evaluation of these patients should include comprehensive history, physical, imaging studies, and cytological studies of the joint capsule tissue or fluid. Definitive treatment for synovial osteochondromatosis is surgical removal of the nodules or loose bodies from the joint capsule and often partial synovectomy^[11]. Removal of the growths relieves symptoms as well as decreases the risk of possible progression to chondrosarcoma and further degeneration of the joint. In cases with concurrent bone erosion, surgical reconstruction of the mandible or temporal bones may also be required^[3].

CASE PRESENTATION

Chief complaints

A 48-year-old male patient was referred for otolaryngology evaluation by his dentist after complaining of trismus, crepitus with jaw movement, significant pain with chewing, and development of a right-sided facial mass.

History and physical exam

The patient's symptoms had started about three months ago and he had seen several physicians previously who provided reassurance and conservatively managed his symptoms. The pain was localized to the right side and aggravated by jaw movements, particularly opening the mouth. He had no constitutional symptoms. Clinical examination revealed a firm mass in the pre-auricular region with tenderness to palpation at the right temporomandibular joint. No obvious facial asymmetry was

present at rest. All cranial nerves appeared intact.

Imaging examinations

Several imaging studies were obtained. A CT scan of the face demonstrated a bilobed mass extending into the joint space on either side of the mandibular condyle measuring 1.7 cm by 1.2 cm medially and 2.6 cm by 1.6 cm laterally (Figure 1). Additional features included significant bony erosion of the middle fossa floor and glenoid fossa, as well as several cysts present in the subchondral bone on the temporal side of the TMJ. T1 and STIR magnetic resonance imaging (MRI) sequences also indicated marked joint capsule distention and joint effusion (Figure 2). The mass appeared to be well circumscribed and did not appear to invade adjacent soft tissue structures.

Laboratory examinations

A fine needle aspiration biopsy was performed, which revealed a matrix-producing lesion with osteoclast-like giant cells and cellular atypia of undetermined significance.

FINAL DIAGNOSIS

The final diagnosis of the presented case is synovial osteochondromatosis of the temporomandibular joint with significant erosion of the glenoid fossa.

TREATMENT

Surgical intervention was indicated for this patient given his failed response to medical management and aggressive nature of bony erosion displayed on imaging. The patient underwent surgical removal of the mass and reconstruction of the joint. A pre-auricular incision was made and a pedicled temporoparietal flap was used to fully expose the condylar mass and joint capsule. The TMJ capsule was opened and revealed well-formed pieces of cartilage which were removed. Circumferential subperiosteal resection of condylar neck was performed to completely remove the adherent mass. A freer elevator was utilized to circumferentially dissect the mass off of the condyle. Sharp excision was required to free the mass from surrounding soft tissue. Care was taken to preserve the external carotid artery. The mass was delivered in a complete, but piecemeal fashion. It became apparent that the mass had filled the superior aspect of the infratemporal fossa and extended into the parapharyngeal space. Following the resection, a rib cartilage graft was used to resurface the superior aspect of the glenoid fossa. The temporoparietal flap was wrapped around the cartilage graft for vascular support and the graft was inset into the joint defect. The condyle itself was preserved adequately preserved during excision of the mass so that condyle reconstruction was not necessary. Specimens acquired from within the TMJ capsule (Figure 3), the mandibular condyle, and surrounding soft tissue were sent for intraoperative frozen-section pathology analysis which showed no evidence of malignancy.

OUTCOME AND FOLLOW-UP

The postoperative course of this patient was uncomplicated. At his first post-operative visit two weeks after surgery, he reported significant improvement in symptoms, and his facial movement was symmetric. He was tolerating a soft diet with only moderate soreness. Physical exam revealed residual swelling and a well-healing facial incision. He was referred for physical therapy for restoration of joint motility. Final pathology of surgical specimens showed lobules of cartilaginous tissue, lacking cytologic atypia, hypercellularity or mitosis, consistent with synovial osteochondromatosis (Figures 4, 5). Unfortunately, after his first post-operative visit, the patient was lost to follow up.

DISCUSSION

Synovial osteochondromatosis is a non-neoplastic proliferation of joint cartilage, which results in the formation of nodular and sometimes ossified bodies within the joint space. Dysregulated tissue growth factors and cytokines such as TGF- β 3, FGFR-3 and IL-6 are involved in the proposed mechanism of over-stimulating active

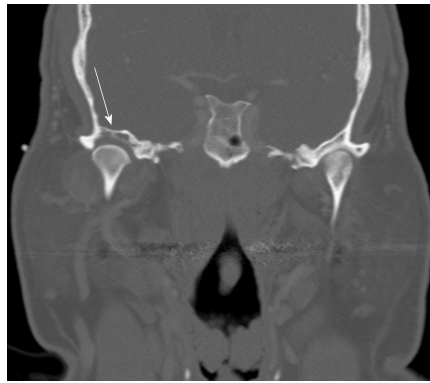

Figure 1 Coronal cut of computed tomography image (bone window) highlighting the erosion of the right glenoid fossa (arrow). A soft tissue mass can faintly be observed on either side of the mandibular condyle, which is better delineated in a soft tissue window (not pictured).

chondrocytes to proliferate and undergo metaplasia^[4,5]. The disease process can be divided into several stages of growth: (1) Proliferation of the synovial lining resulting in nodular pedicled growths; (2) Release of the nodules into the joint space, detachment from the synovium; and (3) Ossification of the nodules within the joint space, with concurrent decline in synovial proliferation^[12]. Symptoms most often present in the second and third phase of growth when the bodies become loose within the joint, ossify and cause impairment of joint functionality. Impairment of cranial nerve function generally indicates most advanced disease^[6,8,10].

Although synovial osteochondromatosis rarely occurs in the facial bones, the TMJ is an important region of occurrence, which requires special consideration when evaluating patients with a pre-auricular mass or symptoms of malocclusion, crepitus and jaw pain. In many cases, patients experience symptoms for years before correct diagnosis can be made and surgical intervention performed^[9]. Presenting complaints are often vague or non-specific, and late diagnosis occurs frequently due to symptom overlap with more common conditions such as temporomandibular joint disorder. Physical findings may include swelling and tenderness to palpation in the preauricular area, as well as decreased range of motion. Collaboration among colleagues in primary care, dentistry and surgery is therefore crucial to the timely diagnosis and proper management of these patients. Degenerative arthritis is a common complication due to the repeated injury of the joint^[13,14]. Delay in diagnosis has the potential to cause significant complications and morbidity for the patient due to the possibility of local or intracranial invasion as well as permanent loss of joint function^[8,11]. Invasion into the cranium can also result in permanent cranial nerve injuries, particularly facial nerve deficits^[15]. The differential diagnosis of a mass within the TMJ includes many types of neoplastic growths and it is therefore important to rule out malignancy when evaluating these patients.

Diagnosis of synovial osteochondromatosis of the TMJ requires multiple imaging modalities, typically including CT and MRI. Common findings include expansion and effusion within the joint space as well as cartilaginous nodules or loose bodies^[15]. MRI may be necessary for diagnosis of early disease in which the nodules have not yet ossified or calcified to better characterize joint effusion, capsular swelling and possible disruption of soft tissues^[9,16]. Surrounding bony structures should be carefully evaluated to identify the likelihood of intracranial erosion and dural involvement^[11,17]. Other degenerative changes such as subchondral cysts may also be evident within the joint, as in this case. Preoperative biopsy for tissue analysis to assess for malignancy is beneficial^[3]. Histologic findings can confirm loose bodies within the joint space or pedunculated masses attached to the joint capsule lining^[18].

Despite its classification as a benign condition, synovial osteochondromatosis occurring in the TMJ can lead to local erosion and complications from intracranial invasion^[11]. In addition, the disorder carries a small risk of progression to malignant chondrosarcoma, and therefore prompt diagnosis and treatment is crucial^[7,8]. Surgical intervention remains the most appropriate treatment due to the lack of effective medical management and the potentially aggressive nature of the disease process. Both arthroscopic and open technique surgeries have been utilized in the process of mass removal. Arthroscopic approaches are less morbid and may be useful for diagnosis, however an open arthrotomy may be more appropriate if the masses are large or numerous^[19,20]. Cases with intracranial invasion typically require open surgical excision and reconstruction^[3,15]. In this case as well as others, the extent and

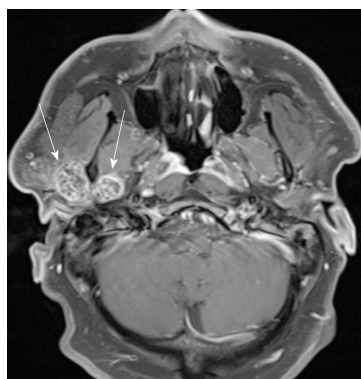


Figure 2 Axial cut of magnetic resonance imaging T1 weighted post-contrast image depicting the bilobed mass within the temporomandibular joint space on either side of the mandibular condyle (arrows) with associated joint capsule distention. On magnetic resonance imaging STIR sequence images (not pictured), significant joint effusion is noted.

stage of the disease may require condylectomy and reinforcement of the glenoid fossa to restore proper structural support^[9].

Outcomes following surgical intervention reported in the literature have been overwhelmingly positive. Patients tend to report significant improvement in symptoms and reduction in pain^[8,15]. Patients benefit from postoperative physical therapy to improve joint motility and help correct any previous malocclusion. Regular follow up should be encouraged for these patients due to the reported recurrence rate of approximately 11%^[12]. Recurring disease should increase clinical suspicion for malignant process and careful re-evaluation should be performed.

CONCLUSION

Synovial osteochondromatosis is a rare condition and is easily overlooked when working up non-specific symptoms such as preauricular pain and swelling. The lack of response to medical management and the positive outcomes following surgical intervention reinforce the potential benefit to patients suffering from this treatable disorder. Treatment not only provides symptomatic relief and improved quality of life, but also decreases likelihood of progressive joint injury, intracranial erosion, and malignant transformation.

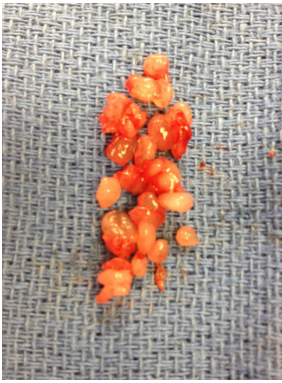

Figure 3 Multiple, irregular firm cartilaginous fragments removed from the temporomandibular joint space.

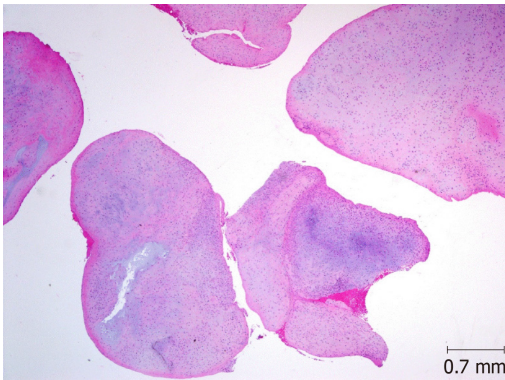


Figure 4 Multiple separate nodules of cartilaginous tissue (loose bodies) (HE, × 20).

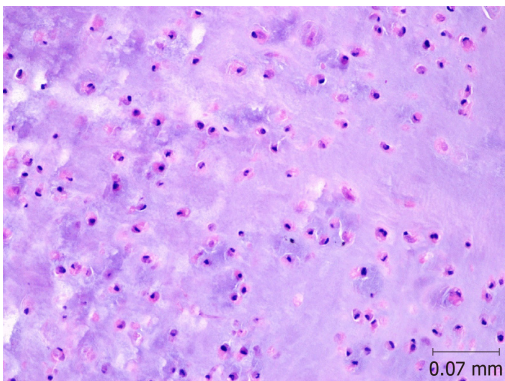


Figure 5 Lobules of hyaline cartilage. No atypia, hypercellularity or mitosis are noted (HE, × 200).

REFERENCES

- 1 **Miller MV**, King A, Mertens F. Pathology and Genetics of Tumors of Soft Tissue and Bone. 3rd ed. (Fletcher CDM, Unni KK, Mertens F, editors). Lyon, France: IARC Press, 2002
- 2 **Reed LS**, Foster MD, Hudson JW. Synovial chondromatosis of the temporomandibular joint: a case report and literature review. *Cranio* 2013; **31**: 309-313 [PMID: 24308105 DOI: 10.1179/crn.2013.31.4.009]
- 3 **Pau M**, Bicsák A, Reinbacher KE, Feichtinger M, Kärcher H. Surgical treatment of synovial chondromatosis of the temporomandibular joint with erosion of the skull base: a case report and review of the literature. *Int J Oral Maxillofac Surg* 2014; **43**: 600-605 [PMID: 24314559 DOI: 10.1016/j.ijom.2013.10.019]
- 4 **Li Y**, El Mozen LA, Cai H, Fang W, Meng Q, Li J, Deng M, Long X. Transforming growth factor beta 3 involved in the pathogenesis of synovial chondromatosis of temporomandibular joint. *Sci Rep* 2015; **5**: 8843 [PMID: 25742744 DOI: 10.1038/srep08843]
- 5 **Tojyo I**, Yamaguti A, Ozaki H, Yoshida H, Fujita S. The expression of fibroblast growth factor receptor-3 in synovial osteochondromatosis of the temporomandibular joint. *Arch Oral Biol* 2004; **49**: 591-594 [PMID: 15126141 DOI: 10.1016/j.archoralbio.2003.12.009]

- 6 **Mikami T**, Aomura T, Ohira A, Kumagai A, Hoshi H, Takeda Y. Three case reports of synovial chondromatosis of temporomandibular joint: histopathologic analyses of minute cartilaginous loose bodies from joint lavage fluid and comparison with phase II and III cases. *J Oral Maxillofac Surg* 2012; **70**: 2099-2105 [PMID: [22177806](#) DOI: [10.1016/j.joms.2011.09.016](#)]
- 7 **Coleman H**, Chandraratnam E, Morgan G, Gomes L, Bonar F. Synovial chondrosarcoma arising in synovial chondromatosis of the temporomandibular joint. *Head Neck Pathol* 2013; **7**: 304-309 [PMID: [23576196](#) DOI: [10.1007/s12105-013-0439-y](#)]
- 8 **Shah SB**, Ramanojam S, Gadre PK, Gadre KS. Synovial chondromatosis of temporomandibular joint: journey through 25 decades and a case report. *J Oral Maxillofac Surg* 2011; **69**: 2795-2814 [PMID: [21470750](#) DOI: [10.1016/j.joms.2010.12.029](#)]
- 9 **Guarda-Nardini L**, Piccotti F, Ferronato G, Manfredini D. Synovial chondromatosis of the temporomandibular joint: a case description with systematic literature review. *Int J Oral Maxillofac Surg* 2010; **39**: 745-755 [PMID: [20434884](#) DOI: [10.1016/j.ijom.2010.03.028](#)]
- 10 **Koyama J**, Ito J, Hayashi T, Kobayashi F. Synovial chondromatosis in the temporomandibular joint complicated by displacement and calcification of the articular disk: report of two cases. *AJNR Am J Neuroradiol* 2001; **22**: 1203-1206 [PMID: [11415920](#) DOI: [10.1016/S0925-4927\(01\)00086-5](#)]
- 11 **Campbell DI**, De Silva RK, De Silva H, Sinon SH, Rich AM. Temporomandibular joint synovial chondromatosis with intracranial extension: a review and observations of patient observed for 4 years. *J Oral Maxillofac Surg* 2011; **69**: 2247-2252 [PMID: [21292373](#) DOI: [10.1016/j.joms.2010.10.042](#)]
- 12 **Phelan E**, Griffin J, Timon C. Temporomandibular joint osteochondromatosis: an unusual cause of preauricular swelling. *Ann Otol Rhinol Laryngol* 2011; **120**: 63-65 [PMID: [21370682](#) DOI: [10.1177/000348941112000109](#)]
- 13 **Sink J**, Bell B, Mesa H. Synovial chondromatosis of the temporomandibular joint: clinical, cytologic, histologic, radiologic, therapeutic aspects, and differential diagnosis of an uncommon lesion. *Oral Surg Oral Med Oral Pathol Oral Radiol* 2014; **117**: e269-e274 [PMID: [23850367](#) DOI: [10.1016/j.oooo.2013.04.020](#)]
- 14 **Fuller E**, Bharatha A, Yeung R, Kassel EE, Aviv RI, Howard P, Symons SP. Case of the month #166: synovial chondromatosis of the temporal mandibular joint. *Can Assoc Radiol J* 2011; **62**: 151-153 [PMID: [21501795](#) DOI: [10.1016/j.carj.2009.12.004](#)]
- 15 **Holmlund AB**, Eriksson L, Reinholt FP. Synovial chondromatosis of the temporomandibular joint: clinical, surgical and histological aspects. *Int J Oral Maxillofac Surg* 2003; **32**: 143-147 [PMID: [12729773](#) DOI: [10.1054/ijom.2002.0300](#)]
- 16 **Wang P**, Tian Z, Yang J, Yu Q. Synovial chondromatosis of the temporomandibular joint: MRI findings with pathological comparison. *Dentomaxillofac Radiol* 2012; **41**: 110-116 [PMID: [22116129](#) DOI: [10.1259/dmfr/36144602](#)]
- 17 **Wang H**, Zhang J, He X, Niu Y. Synovial sarcoma in the oral and maxillofacial region: report of 4 cases and review of the literature. *J Oral Maxillofac Surg* 2008; **66**: 161-167 [PMID: [18083434](#) DOI: [10.1016/j.joms.2007.05.007](#)]
- 18 **Peyrot H**, Montoriol PF, Beziat JL, Barthelemy I. Synovial chondromatosis of the temporomandibular joint: CT and MRI findings. *Diagn Interv Imaging* 2014; **95**: 613-614 [PMID: [24560522](#) DOI: [10.1016/j.diii.2013.12.002](#)]
- 19 **Cai XY**, Yang C, Chen MJ, Jiang B, Zhou Q, Jin JM, Yun B, Chen ZZ. Arthroscopic management for synovial chondromatosis of the temporomandibular joint: a retrospective review of 33 cases. *J Oral Maxillofac Surg* 2012; **70**: 2106-2113 [PMID: [22177814](#) DOI: [10.1016/j.joms.2011.09.043](#)]
- 20 **Zhu Y**, Zheng C, Deng Y, Zhang Y, Hu X. Arthroscopic surgery for removal of 112 loose bodies of synovial chondromatosis of the temporomandibular joint. *J Craniofac Surg* 2013; **24**: 2166-2169 [PMID: [24220430](#) DOI: [10.1097/SCS.0b013e3182a2b82f](#)]



Published By Baishideng Publishing Group Inc
7041 Koll Center Parkway, Suite 160, Pleasanton, CA 94566, USA
Telephone: +1-925-223-8242
E-mail: bpgoffice@wjgnet.com
Help Desk: <https://www.f6publishing.com/helpdesk>
<https://www.wjgnet.com>

