

# World Journal of *Orthopedics*

*World J Orthop* 2014 November 18; 5(5): 557-698





# World Journal of Orthopedics

*A peer-reviewed, online, open-access journal of orthopedics*

## Editorial Board

2010-2014

The *World Journal of Orthopedics* Editorial Board consists of 433 members, representing a team of worldwide experts in orthopedics. They are from 42 countries, including Argentina (1), Australia (18), Austria (5), Bangladesh (1), Belgium (2), Brazil (4), Canada (11), China (42), Croatia (2), Denmark (2), Egypt (5), Finland (3), France (4), Germany (14), Greece (16), Hungary (1), India (12), Iran (4), Ireland (2), Israel (13), Italy (24), Japan (22), Morocco (1), Netherlands (14), New Zealand (1), Norway (4), Portugal (1), Qatar (1), Saudi Arabia (4), Serbia (3), Singapore (4), Slovenia (1), South Korea (21), Spain (5), Sri Lanka (1), Sweden (4), Switzerland (8), Thailand (3), Tunisia (2), Turkey (7), United Kingdom (17), and United States (123).

### EDITOR-IN-CHIEF

Bao-Gan Peng, *Beijing*

### STRATEGY ASSOCIATE

#### EDITORS-IN-CHIEF

Jenni M Buckley, *San Francisco*

Vijay K Goel, *Toledo*

James F Griffith, *Hong Kong*

Thomas W Kaminski, *Newark*

Enrico Pola, *Rome*

Masato Takao, *Tokyo*

### GUEST EDITORIAL BOARD

#### MEMBERS

Chih-Hwa Chen, *Keelung*

Ruei-Ming Chen, *Taipei*

Yen-Jen Chen, *Taichung*

Pang-Hsin Hsieh, *Taoyuan*

Kuo-Chin Huang, *Chia-Yi*

Tung-Fu Huang, *Taipei*

Shao-Hung Hung, *Tungshang Pingtung*

Chian-Her Lee, *Taipei*

Yih-Shiunn Lee, *Taichung*

Po-Chou Liliang, *Kaohsiung*

Feng-Huei Lin, *Taipei*

Jiu-jenq Lin, *Taipei*

Fu-Chan Wei, *Taoyuan*

Ta-Sen Wei, *Changhua*

Chih-Shung Wong, *Taipei*

Jui-Tien Shih, *Taoyuan*

Chen Yuk-Kwan, *Kaohsiung*

### MEMBERS OF THE EDITORIAL

#### BOARD



**Argentina**

Martin Alejandro Buttaró, *Aires*



**Australia**

Gerald James Atkins, *Adelaide*

Gregory Ian Bain, *Adelaide*

Darren John Beales, *Atwell*

Belinda R Beck, *Gold Coast*

Adam Leigh Bryant, *Melbourne*

Changhai Ding, *Hobart*

Ashish Dhar Diwan, *Sydney*

Herwig Drobetz, *Mackay*

Melanie Franklyn, *Melbourne*

Rana Shane Hinman, *Melbourne*

Konstantin I Momot, *Brisbane*

George Samuel Murley, *Melbourne*

Michael E Schneider-Kolsky, *Clayton*

Jerzy M Sikorski, *Perth*

Gordon L Slater, *Albury*

Lucian Bogdan Solomon, *Adelaide*

Mark Watsford, *Sydney*

Cory J Xian, *Adelaide*



**Austria**

Florian Kutscha-Lissberg, *Vienna*

Kevin Laudner, *Innsbruck*

Stefan Toegel, *Vienna*

Klemens Trieb, *Wels*

Heinz KL Winkler, *Wien*



**Bangladesh**

Saidur Rahman Mashreky, *Dhaka*



**Belgium**

Olivier Bruyere, *Liege*

Hendrik Pieter Delpont, *Sint Nikolaas*



**Brazil**

Djalma José Fagundes, *São Paulo*

Francisco Bandeira Farias, *Recife*

Eduardo Magalhaes, *São Paulo*

Luci F Teixeira-Salmela, *Minas Gerais*



**Canada**

Richard E Buckley, *Calgary*

Prince Francois, *Quebec*

Reggie Charles Hamdy, *Montreal*

Michael Anthony Hunt, *Columbia*

Richard Kremer, *Montreal*

Jean-Marc Mac-Thiong, *Montreal*

Fackson Mwale, *Montreal*

Vasileios Nikolaou, *Toronto*

Christy C Tomkins-Lane, *Calgary*

Robert E Turcotte, *Quebec*

Stephen D Waldman, *Kingston*



**China**

Yu-Ming Chen, *Guangzhou*

Wing-Hoi Cheung, *Hong Kong*

Hong-Bin Fan, *Xi'an*

Daniel YT Fong, *Hong Kong*

Li-Xin Guo, *Shenyang*

Xia Guo, *Hong Kong*

Xiong Guo, *Xi'an*

Lui-Tun Hing, *Hong Kong*

Jing Hu, *Chengdu*

Yong Hu, *Hong Kong*

Kai-Fu Huo, *Wuhan*

Xiang-Hang Luo, *Changsha*  
 Zhuo-Jing Luo, *Xi'an*  
 Marco YC Pang, *Hong Kong*  
 Ling Qin, *Hong Kong*  
 Jun Tan, *Shanghai*  
 Ricky WK Wong, *Hong Kong*  
 Tak-Chuen Wong, *Hong Kong*  
 Hua-Zi Xu, *Wenzhou*  
 Bin-Sheng Yu, *Guangzhou*  
 Ge Zhang, *Hong Kong*  
 Ming Zhang, *Hong Kong*  
 Jian-Hua Zhao, *Chongqing*



#### Croatia

Robert Kolundzic, *Zgareb*  
 Tomislav Smoljanovic, *Zagreb*



#### Denmark

Stig Brorson, *Copenhagen*  
 Morten Tange Kristensen, *Copenhagen*



#### Egypt

Khaled M Emara, *Cairo*  
 Mohamed Kenawey, *Sohag*  
 Wael MT Koptan, *Cairo*  
 Mahmoud Mahran, *Cairo*  
 Elsayed I Elsayed Massoud, *Elghad*



#### Finland

Timo Järvelä, *Tampere*  
 Yrjö T Konttinen, *Helsinki*  
 Petri Sillanpaa, *Tampere*



#### France

Federico Canavese, *Ferrand*  
 Jean-Alain Epinette, *Labuissiere*  
 Yiou Eric, *Paris*  
 Sebastien Zilber, *Paris*



#### Germany

Stefan Grote, *Munich*  
 Carl Haasper, *Hannover*  
 Jorn Kircher, *Düsseldorf*  
 Karsten Knobloch, *Hannover*  
 Philipp Kobbe, *Aachen*  
 Heinz Lohrer, *Main*  
 Olaf Lorbach, *Homburg*  
 Annegret Mündermann, *Radolfzell*  
 Markus Regauer, *München*  
 Volker Schoffl, *Bamberg*  
 Arndt P Schulz, *Lübeck*  
 Sebastian Seitz, *Hamburg*  
 Lars Victor Baron von Engelhardt, *Bochum*  
 Goetz Hannes Welsch, *Erlangen*



#### Greece

Evangelos C Alexopoulos, *Athens*

Stergioulas Thomas Apostolos, *Peloponnese*  
 Constantinos D Apostolou, *Attiki*  
 George C Babis, *Chaidari*  
 Georgios I Drosos, *Alexandroupolis*  
 Christos Garnavos, *Athens*  
 Panagiotis Korovessis, *Patras*  
 Marios Georgios Lykissas, *Ioannina*  
 Dimitrios N Lyras, *Alexandroupolis*  
 Konstantinos N Malizos, *Larissa*  
 Yannis Manios, *Athens*  
 Nikolaos G Papadimitriou, *Thessaloniki*  
 Vassilis Paschalis, *Trikala*  
 Lazaros I Sakkas, *Larissa*  
 Haris S Vasiliadis, *Ioannina*  
 Marianna Vlychou, *Thessaly*



#### Hungary

Andor Sebestyén, *Pécs*



#### India

Vaibhav Bagaria, *Ghaziabad*  
 Kemmannu Vikram Bhat, *Hubli*  
 Antony Gomes, *Calcutta*  
 Shah Alam Khan, *New Delhi*  
 Thomas Joseph Kishen, *Bangalore*  
 Pankaj Kumar, *Andhra Pradesh Pin*  
 Pramod V Lokhande, *Pune*  
 Devdatta Suhas Neogi, *Mumbai*  
 Mohamed Shafi, *Tamil Nadu State*  
 Kunal Sharan, *Lucknow*  
 Vidyadhara Srinivasa, *Karnataka*  
 Divya Vohora, *New Delhi*



#### Iran

Masood Mazaheri, *Isfahan*  
 Sayed Javad Mousavi, *Tehran*  
 Hossein Negahban, *Ahvaz*  
 Ali Razmkon, *Shiraz*



#### Ireland

Joseph S Butler, *Dublin*  
 Eamonn Delahun, *Dublin*



#### Israel

Itai A Bab, *Jerusalem*  
 Itzhak Binderman, *Tel Aviv*  
 Alexander Blankstein, *Ramat Hasharon*  
 Itay Fenichel, *Udim*  
 Aharon Finestone, *Reut*  
 Amir Herman, *Ramat-Gan*  
 Dror Lakstein, *Holon*  
 Yocheved Laufer, *Haifa*  
 Youssef Maher Masharawi, *Tel Aviv*  
 Francis B Mimouni, *Jerusalem*  
 Jacob Kobi Peleg, *Tel Hashomer*  
 Nahum Rosenberg, *Haifa*  
 Yehuda Ullmann, *Haifa*



#### Italy

Saverio Affatato, *Bologna*

Patrizia D Amelio, *Torino*  
 Giuseppe Banfi, *Milano*  
 Angelo Cacchio, *L'Aquila*  
 Giuseppe M Campo, *Messina*  
 Marco Crostelli, *Rome*  
 Pasquale De Negri, *Rionero in Vulture*  
 Alessandro de Stefano, *Bari*  
 Alberto Deganello, *Florence*  
 Costantino Errani, *Bologna*  
 Alessandro Geraci, *Feltre*  
 Andrea Giusti, *Genova*  
 Alberto Gobbi, *Milan*  
 Donatella Lippi, *Florence*  
 Marcello Maggio, *Parma*  
 Gian Luigi Marseglia, *Milano*  
 Monica Mattioli-Belmonte, *Ancona*  
 Claudia Mazzà, *Rome*  
 Marco Monticone, *Lissone*  
 Raoul Saggini, *Chieti*  
 Umberto Tarantino, *Rome*  
 Marco Giuseppe Angelo Teli, *Bergamo*  
 Tomaso Villa, *Milano*



#### Japan

Yoichi Aota, *Yokohama*  
 Jun Iwamoto, *Tokyo*  
 Shuichi Kaneyama, *Kobe*  
 Yuichi Kasai, *Tsu city*  
 Shigeru Kobayashi, *Fukui*  
 Tomihisa Koshino, *Yokohama*  
 Nobuyuki Kumahashi, *Shimane-ken*  
 Makoto Makishima, *Tokyo*  
 Toru Maruyama, *Saitama*  
 Kanji Mori, *Otsu*  
 Satoshi Mori, *Hamamatsu Shizuoka*  
 Ryuichi Morishita, *Suita*  
 Yasuharu Nagano, *Saitama*  
 Hideki Nagashima, *Tottori*  
 Mitsuo Ochi, *Hiroshima*  
 Akio Sakamoto, *Fukuoka*  
 Yasuaki Tokuhashi, *Tokyo*  
 Toshimasa Uemura, *Ibaraki*  
 Hisataka Yasuda, *Nagahama*  
 Takafumi Yoshikawa, *Nara*  
 Tadahiko Yotsumoto, *Higashisaka-city*



#### Morocco

Abdellah EI Maghraoui, *Rabat*



#### Netherlands

Taco Gosens, *Tilburg*  
 PE Huijsmans, *The Hague*  
 Paul C Jutte, *Groningen*  
 Claudine JC Lamoth, *Groningen*  
 Esther Maria Maartje, *Rotterdam*  
 RGH Nelissen, *Leiden*  
 Rob GH Nelissen, *Leiden*  
 Christiaan JA van Bergen, *Amsterdam*  
 Michel van den Bekerom, *Amsterdam*  
 PM van der Kraan, *Nijmegen*  
 BCH van der Wal, *Amersfoort*  
 TM van Raaij, *Groningen*

Barend J Van Royen, *Amsterdam*  
JJ Verlaan, *Utrecht*



#### **New Zealand**

Doug King, *Lower Hutt*



#### **Norway**

Jan Oxholm Gordeladze, *Oslo*  
Anne Keller, *Oslo*  
Gunnar Knutsen, *Tromsø*  
Inigo Martinez, *Tromsø*



#### **Portugal**

João F Mano, *Guimarães*



#### **Qatar**

Cristiano Eirale, *Doha*



#### **Saudi Arabia**

Sultan Abdulaziz Al Mubarak, *Riyadh*  
Einas Al-Eisa, *Riyadh*  
Mir Sadat Ali, *AlKhobar*  
Mohamed Zamzam, *Riyadh*



#### **Serbia**

Radica Dunjic, *Belgrade*  
Miroslav Z Milankov, *Novi Sad*  
Zoran Vukasinovic, *Serbia*



#### **Singapore**

Hwan Tak Hee, *Singapore*  
V Prem Kumar, *Singapore*  
Anselm Mak, *Singapore*  
Dongan Wang, *Singapore*



#### **Slovenia**

Matjaz Sajovic, *Celje*



#### **South Korea**

Seung-Hoon Baek, *Daegu*  
Gun Choi, *Seoul*  
Kook Jin Chung, *Seoul*  
Jae Taek Hong, *Suwon*  
Dae-Geun Jeon, *Seoul*  
Hyun Woo Kim, *Seoul*  
Jae Kwang Kim, *Seoul*  
Seok Woo Kim, *Gyeonggi*  
Shin-Yoon Kim, *Daegu*  
Young Hoon Kim, *Seoul*  
Sang-Hun Ko, *Ulsan City*  
Sung-Uk Kuh, *Seoul*  
Jaebeom Lee, *Miryang*

Sang Ki Lee, *Daejeon*  
Yong Seuk Lee, *Suwon*  
Jin-Young Park, *Seoul*  
Jong-Beom Park, *Kyunggi-do*  
Yang-Sik Shin, *Seoul*  
Eun Kyoo Song, *Jeonnam*  
Paul S Sung, *Seoul*  
Kyu Hyun Yang, *Seoul*



#### **Spain**

Enrique Gomez Barrena, *Madrid*  
Francisco J Blanco Garcia, *Coruna*  
Antonio Herrera, *Zaragoza*  
Daniel Hernandez Vaquero, *Aviles*  
Nuria Vilaboa, *Madrid*



#### **Sri Lanka**

Janaka Lenora, *Galle*



#### **Sweden**

Paul Ackermann, *Stockholm*  
Jan G Jakobsson, *Stockholm*  
Anna Nordström, *Umeå*  
Ola Rolfson, *Mölnådal*



#### **Switzerland**

Achim Elfering, *Bern*  
Peter Fennema, *Baar*  
Bruno Fuchs, *Zürich*  
Benjamin Gantenbein, *Bern*  
Michael Hirschmann, *Basel*  
Beat Knechtle, *St. Gallen*  
Nicola A Maffioletti, *Zurich*  
Elyazid Mouhsine, *Lausanne*



#### **Thailand**

Sittisak Honsawek, *Bangkok*  
Prachya Kongtawelert, *Chiang Mai*  
Boonsin Tangtrakulwanich, *Songkla*



#### **Tunisia**

Abdelkader Krichen, *Sfax*  
Lamia Rezgui-Marhouli, *Tunis*



#### **Turkey**

Bulent Daglar, *Ankara*  
Serkan Erkan, *Manisa*  
Serdar Kahraman, *Istanbul*  
Akmer Mutlu, *Samanpazari Ankara*  
Kemal NAS, *Diyarbakir*  
Salih Ozgocmen, *Kayseri*  
Haluk H Oztekin, *Izmir*



#### **United Kingdom**

Henry DE Atkinson, *London*  
Abhijit Manohar Bhosale, *South York-*

*shire*

Sarah Cartmell, *Manchester*  
David Chesney, *Scotland*  
Yogeesh D Kamat, *Surrey*  
Vikas Khanduja, *Cambridge*  
Ranjith Ravindran Kuzhupilly, *Basildon*  
Hammad Malik, *Manchester*  
Jitendra Mangwani, *Wiltshire*  
Ali Mobasheri, *Sutton Bonington*  
Tosan Okoro, *Bangor*  
Hemant G Pandit, *Oxford*  
Mathew Sewell, *Teddington*  
Eleftherios Tsiridis, *London*  
Charles Willis-Owen, *London*  
Vikki Wyld, *Bristol*  
Wei-Ya Zhang, *Nottingham*



#### **United States**

Joseph A Abboud, *Philadelphia*  
Matthew S Abrahams, *Portland*  
David S Bailie, *Scottsdale*  
B Sonny Bal, *Columbia*  
Matthew J Beckman, *Richmond*  
Inna Belfer, *Pittsburgh*  
Angie Botto-van Bemden, *Lauderdale*  
Srino Bharam, *New York*  
Anil Bhave, *Baltimore*  
Craig R Bottoni, *Honolulu*  
Adam Matthew Brufsky, *Pittsburgh*  
Lavjay Butani, *Sacramento*  
Edmund Y S Chao, *Corona*  
Chaoyang Chen, *Detroit*  
R Tong Chuanhe, *Chicago*  
Ock K Chun, *Storrs*  
Christopher J Colloca, *Chandler*  
Quanjun Cui, *Virginia*  
Scott D Daffner, *Morgantown*  
Nabanita S Datta, *Detroit*  
Paul E Di Cesare, *Sacramento*  
Clark Dickin, *Muncie*  
Matthew B Dobbs, *Saint Louis*  
Tammy L Haut Donahue, *Houghton*  
Zhenfeng Duan, *Boston*  
John S Early, *Dallas*  
Jason C Eck, *Worcester*  
Evan F Ekman, *Columbia*  
Steven Howard Elder, *Mississippi*  
John Elias, *Akron*  
David A Fisher, *Indianapolis*  
Michael Fredericson, *Redwood City*  
Joel J Gagnier, *Ann Arbor*  
Glen Michael Ginsburg, *Omaha*  
Federico P Girardi, *New York*  
Beril Gok, *Baltimore*  
Ashraf S Gorgey, *Richmond*  
David J Hak, *Denver*  
Sam Hakki, *Bay Pines*  
Sheri Hale, *Winchester*  
Kyung Mo Han, *Washington*  
James S Harrop, *Philadelphia*  
Erin Hartigan, *Portland*  
Brian Michael Haus, *Boston*  
David L Helfet, *New York*  
John H Hollman, *Rochester*  
Adam H Hsieh, *College Park*  
Johnny Huard, *Pittsburgh*  
G Russell Huffman, *Philadelphia*  
Mozammil Hussain, *Chesterfield*  
Stefan Judex, *Stony Brook*



David Hanwuk Kim, *Boston*  
 Kee D Kim, *Sacramento*  
 Gary Krishnan, *Fishers*  
 Michael A Kuhn, *North Carolina*  
 Shrawan Kumar, *Fort Worth*  
 Monroe Laborde, *New Orleans*  
 Kevin Laudner, *Normal*  
 Bingyun Li, *Morgantown*  
 Xiao-Juan Li, *San Francisco*  
 Ye-Fu Li, *Boston*  
 Zhongyu John Li, *Winston-Salem*  
 Zong-Ming Li, *Cleveland*  
 Chuanju Liu, *New York*  
 Richard M Lovering, *Baltimore*  
 Raman C Mahabir, *Temple*  
 Aditya V Maheshwari, *Brooklyn*  
 Kenneth Allen Mann, *Syracuse*  
 Lyle Joseph Micheli, *Boston*  
 Subburaman Mohan, *Loma Linda*  
 Arash Momeni, *Palo Alto*  
 Nader D Nader, *Buffalo*  
 Rahul Kumar Nath, *Houston*  
 John Nyland, *Louisville*

Brett D Owens, *New York*  
 Dror Paley, *Florida*  
 George Papaioannou, *Milwaukee*  
 Evangelos Pappas, *Brooklyn*  
 Paul Park, *Ann Arbor*  
 Javad Parvizi, *Philadelphia*  
 Ming Pei, *Morgantown*  
 Juan A Pretell, *Philadelphia*  
 Mark D Price, *Worcester*  
 R Lor Randall, *Salt Lake City*  
 Bruce M Rothschild, *Kansas*  
 David P Roye JR, *New York*  
 Thomas A Russell, *Tennessee*  
 G James Sammarco, *Cincinnati*  
 Aaron David Sciascia, *Lexington*  
 Jason Scott Scibek, *Pittsburgh*  
 David M Selkowitz, *Pomona*  
 Hassan Serhan, *Raynham*  
 Chwan-Li Shen, *Lubbock*  
 Francis H Shen, *Charlottesville*  
 Sorin Siegler, *Philadelphia*  
 Karin Gräware Silbernagel, *Newark*  
 David H Song, *Chicago*

Nelson F SooHoo, *Los Angeles*  
 David Andrew Spiegel, *Philadelphia*  
 SPA Stawicki, *Columbus*  
 Marcus B Stone, *Highland*  
 Ann Marie Swank, *Louisville*  
 James S Thomas, *Athens*  
 R Shane Tubbs, *Birmingham*  
 Victoria M Virador, *Bethesda*  
 Bing Wang, *Pittsburgh*  
 Jeffrey C Wang, *Monica*  
 Wenbao Wang, *New York*  
 Terry L Whipple, *Richmond*  
 Savio LY Woo, *Pittsburgh*  
 Dane K Wukich, *Pittsburgh*  
 Masayoshi Yamaguchi, *Atlanta*  
 Feng-Chun Yang, *Indianapolis*  
 Shang-You Yang, *Wichita*  
 Subhashini Yaturu, *Albany*  
 Hiroki Yokota, *Troy*  
 Charalampos Zalavras, *Los Angeles*  
 Li-Qun Zhang, *Chicago*  
 Chunfeng Zhao, *Rochester*  
 Nigel Zheng, *Charlotte*

**TOPIC HIGHLIGHT**

- 557 Arthroscopic treatment options for irreparable rotator cuff tears of the shoulder  
*Anley CM, Chan SKL, Snow M*
- 566 Utility of arthroscopic guided synovial biopsy in understanding synovial tissue pathology in health and disease states  
*Wechalekar MD, Smith MD*
- 574 Power Doppler ultrasonographic assessment of the ankle in patients with inflammatory rheumatic diseases  
*Suzuki T*
- 585 Worldwide spread of the Ponseti method for clubfoot  
*Shabtai L, Specht SC, Herzenberg JE*
- 591 Survival outcomes of cemented compared to uncemented stems in primary total hip replacement  
*Wyatt M, Hooper G, Frampton C, Rothwell A*
- 597 Degenerative meniscus: Pathogenesis, diagnosis, and treatment options  
*Howell R, Kumar NS, Patel N, Tom J*
- 603 Flap reconstruction of the knee: A review of current concepts and a proposed algorithm  
*Gravvanis A, Kyriakopoulos A, Kateros K, Tsoutsos D*
- 614 Management bone loss of the proximal femur in revision hip arthroplasty: Update on reconstructive options  
*Sakellariou VI, Babis GC*
- 623 Functional outcomes assessment in shoulder surgery  
*Wylie JD, Beckmann JT, Granger E, Tashjian RZ*
- 634 Eccentric training as a new approach for rotator cuff tendinopathy: Review and perspectives  
*Camargo PR, Alburquerque-Sendin F, Salvini TF*

- 645** Thromboembolic disease in patients with rheumatoid arthritis undergoing joint arthroplasty: Update on prophylaxes  
*Mameli A, Marongiu F*
- 653** Inhibition of rheumatoid arthritis by blocking connective tissue growth factor  
*Nozawa K, Fujishiro M, Takasaki Y, Sekigawa I*
- 660** Metallic debris from metal-on-metal total hip arthroplasty regulates periprosthetic tissues  
*Lohmann CH, Singh G, Willert HG, Buchhorn GH*

**REVIEW**

- 667** Treatment of acute periprosthetic infections with prosthesis retention: Review of current concepts  
*Kuiper JWP, Tjeenk Willink R, Moojen DJF, van den Bekerom MPJ, Colen S*
- 677** Treatment for cartilage injuries of the knee with a new treatment algorithm  
*Özmeriç A, Alemdaroğlu KB, Aydoğan NH*

**MINIREVIEWS**

- 685** Management of proximal humerus fractures in adults  
*Vachtsevanos L, Hayden L, Desai AS, Dramis A*
- 694** Vanishing bone disease (Gorham-Stout syndrome): A review of a rare entity  
*Nikolaou VS, Chytas D, Korres D, Efstathopoulos N*

## Contents

*World Journal of Orthopedics*  
Volume 5 Number 5 November 18, 2014

**APPENDIX** I-V Instructions to authors

**ABOUT COVER** Editorial Board Member of *World Journal of Orthopedics*, Melanie Franklyn, PhD, Research Scientist in Injury Biomechanics, Human Protection and Performance Division (HPPD), Defence Science and Technology Organisation (DSTO), 506 Lorimer St, Fishermans Bend, Melbourne, VIC 3207, Australia

**AIM AND SCOPE** *World Journal of Orthopedics* (*World J Orthop*, *WJO*, online ISSN 2218-5836, DOI: 10.5312) is a peer-reviewed open access academic journal that aims to guide clinical practice and improve diagnostic and therapeutic skills of clinicians.

*WJO* covers topics concerning arthroscopy, evidence-based medicine, epidemiology, nursing, sports medicine, therapy of bone and spinal diseases, bone trauma, osteoarthritis, bone tumors and osteoporosis, minimally invasive therapy, diagnostic imaging. Priority publication will be given to articles concerning diagnosis and treatment of orthopedic diseases. The following aspects are covered: Clinical diagnosis, laboratory diagnosis, differential diagnosis, imaging tests, pathological diagnosis, molecular biological diagnosis, immunological diagnosis, genetic diagnosis, functional diagnostics, and physical diagnosis; and comprehensive therapy, drug therapy, surgical therapy, interventional treatment, minimally invasive therapy, and robot-assisted therapy.

We encourage authors to submit their manuscripts to *WJO*. We will give priority to manuscripts that are supported by major national and international foundations and those that are of great basic and clinical significance.

**INDEXING/ABSTRACTING** *World Journal of Orthopedics* is now indexed in PubMed Central, PubMed, Digital Object Identifier, and Directory of Open Access Journals.

**FLYLEAF** I-IV Editorial Board

## EDITORS FOR THIS ISSUE

Responsible Assistant Editor: *Xiang Li*  
Responsible Electronic Editor: *Huan-Liang Wu*  
Proofing Editor-in-Chief: *Lian-Sheng Ma*

Responsible Science Editor: *Ling-Ling Wen*  
Proofing Editorial Office Director: *Jin-Lei Wang*

**NAME OF JOURNAL**  
*World Journal of Orthopedics*

**ISSN**  
ISSN 2218-5836 (online)

**LAUNCH DATE**  
November 18, 2010

**FREQUENCY**  
Bimonthly

**EDITOR-IN-CHIEF**  
**Bao-Gan Peng, MD, PhD, Professor**, Department of Spinal Surgery, General Hospital of Armed Police Force, 69 Yongding Road, Beijing 100039, China

**EDITORIAL OFFICE**  
Jin-Lei Wang, Director  
Xiu-Xia Song, Vice Director  
*World Journal of Orthopedics*

Room 903, Building D, Ocean International Center, No. 62 Dongsihuan Zhonglu, Chaoyang District, Beijing 100025, China  
Telephone: +86-10-59080039  
Fax: +86-10-85381893  
E-mail: [editorialoffice@wjnet.com](mailto:editorialoffice@wjnet.com)  
Help Desk: <http://www.wjnet.com/esps/helpdesk.aspx>  
<http://www.wjnet.com>

**PUBLISHER**  
Baishideng Publishing Group Inc  
8226 Regency Drive,  
Pleasanton, CA 94588, USA  
Telephone: +1-925-223-8242  
Fax: +1-925-223-8243  
E-mail: [bpgoffice@wjnet.com](mailto:bpgoffice@wjnet.com)  
Help Desk: <http://www.wjnet.com/esps/helpdesk.aspx>  
<http://www.wjnet.com>

**PUBLICATION DATE**  
November 18, 2014

## COPYRIGHT

© 2014 Baishideng Publishing Group Inc. Articles published by this Open-Access journal are distributed under the terms of the Creative Commons Attribution Non-commercial License, which permits use, distribution, and reproduction in any medium, provided the original work is properly cited, the use is non commercial and is otherwise in compliance with the license.

## SPECIAL STATEMENT

All articles published in journals owned by the Baishideng Publishing Group (BPG) represent the views and opinions of their authors, and not the views, opinions or policies of the BPG, except where otherwise explicitly indicated.

## INSTRUCTIONS TO AUTHORS

Full instructions are available online at [http://www.wjnet.com/2218-5836/g\\_info\\_20100722172650.htm](http://www.wjnet.com/2218-5836/g_info_20100722172650.htm)

## ONLINE SUBMISSION

<http://www.wjnet.com/esps/>

WJO 5<sup>th</sup> Anniversary Special Issues (2): Arthroscopic

## Arthroscopic treatment options for irreparable rotator cuff tears of the shoulder

Cameron M Anley, Samuel KL Chan, Martyn Snow

Cameron M Anley, Samuel KL Chan, Martyn Snow, Arthroscopy Division, The Royal Orthopaedic Hospital, Birmingham B31 2AP, United Kingdom

**Author contributions:** Anley CM designed and contributed to all the subsections and responsible for revisions and submission; Chan SKL contributed to the design all the subsections of the paper and reviewed the paper prior to submission; Snow M (senior author) contributed to the overall design and each section, final editing prior to submission.

**Correspondence to:** Cameron M Anley, MBChB, FCS (Ortho) SA, Arthroscopy Division, The Royal Orthopaedic Hospital, Bristol Road South, Birmingham B31 2AP, United Kingdom. [cam\\_anley@yahoo.com](mailto:cam_anley@yahoo.com)

Telephone: +44-121-6854000 Fax: +44-121-6854213

Received: December 29, 2013 Revised: May 9, 2014

Accepted: June 10, 2014

Published online: November 18, 2014

The aim of this review is to highlight and summarise arthroscopic procedures and the results thereof currently utilised in the management of these challenging patients.

© 2014 Baishideng Publishing Group Inc. All rights reserved.

**Key words:** Irreparable; Arthroscopy; Rotator cuff; Repair; Massive

**Core tip:** This paper reviews the current literature and available techniques to arthroscopically address irreparable rotator cuff tears. It includes all historic and recent innovative methods to address this difficult and challenging clinical problem. Readers of this article will be in a position to make an informed decision as to the most appropriate treatment for their patients based on the most up to date literature.

### Abstract

The management of patients with irreparable rotator cuff tears remains a challenge for orthopaedic surgeons with the final treatment option in many algorithms being either a reverse shoulder arthroplasty or a tendon transfer. The long term results of these procedures are however still widely debated, especially in younger patients. A variety of arthroscopic treatment options have been proposed for patients with an irreparable rotator cuff tear without the presence of arthritis of the glenohumeral joint. These include a simple debridement with or without a biceps tenotomy, partial rotator cuff repair with or without an interval slide, tuboplasty, graft interposition of the rotator cuff, suprascapular nerve ablation, superior capsule reconstruction and insertion of a biodegradable spacer (Inspace) to depress the humeral head. These options should be considered as part of the treatment algorithm in patients with an irreparable rotator cuff and could be used as either as an interim procedure, delaying the need for more invasive surgery in the physiologically young and active, or as potential definitive procedures in the medically unfit.

Anley CM, Chan SKL, Snow M. Arthroscopic treatment options for irreparable rotator cuff tears of the shoulder. *World J Orthop* 2014; 5(5): 557-565 Available from: URL: <http://www.wjgnet.com/2218-5836/full/v5/i5/557.htm> DOI: <http://dx.doi.org/10.5312/wjo.v5.i5.557>

### INTRODUCTION

The management of patients with irreparable rotator cuff tears (IRCT) without the presence of arthritis remains a challenge for orthopaedic surgeons. Currently, the reverse shoulder arthroplasty is advocated for patients with<sup>[1-3]</sup> and more recently without<sup>[4,5]</sup> glenohumeral arthritis in the presence of an IRCT. Although early to midterm results are promising, the long term results are still questioned<sup>[1]</sup> as highlighted by a recent paper reviewing the satisfaction in patients under 60 years of age<sup>[2]</sup>. In addition the complication rate varies from 4.3% to 50%<sup>[3,6]</sup> with a revision rate of 10%<sup>[6]</sup>. The subsequent treat-



ment options in a failed reverse shoulder arthroplasty are complex and limited. An alternative in younger patients with an IRCT without arthritis is a tendon transfer<sup>[7]</sup>. Although Gerber *et al*<sup>[8]</sup> have recently presented promising long term results (> 10 years) the overall outcome is still variable with unpredictable results<sup>[7]</sup>.

It is important to differentiate between massive and irreparable rotator cuff tears, as not all massive tears are irreparable<sup>[7]</sup>. By definition, massive tears have been described as > 5 cm<sup>[7,9]</sup> and tears involving two or more tendons<sup>[10]</sup>. An IRCT, as the name suggests, is any RCT which cannot be repaired back to the rotator cuff footprint on the greater tuberosity of the humerus or as Gerber *et al*<sup>[1]</sup> suggested, any repair that is successful but will almost certainly be associated with structural failure<sup>[1]</sup>. Reparability is influenced by a variety of factors and the exact incidence of IRCT is unknown<sup>[7]</sup>. Warner suggested that it may be as high as 30% in a dedicated shoulder practice<sup>[11]</sup>, while other studies have quoted an incidence of 6.5%-22.4%<sup>[12-14]</sup>.

Although the final decision on reparability of the rotator cuff is made intraoperatively, various symptoms, signs and radiology findings may suggest irreparability prior to surgery allowing for appropriate preoperative planning. Classically patients will present with pain and disability, these symptoms however do not correlate directly with the size or reparability of the tear. Clinical signs which suggest that a repair is unlikely to be successful include static anterosuperior subluxation and associated pseudoparalysis on anterior elevation<sup>[1]</sup>. Tears associated with dynamic anterosuperior subluxation of the humerus upon resisted abduction<sup>[1]</sup>, a lag sign and a positive Hornblowers sign<sup>[15,16]</sup> are also poor prognostic signs.

Superior migration of the humerus, with an acromiohumeral interval of < 7 mm on a standard anterior-posterior shoulder radiograph, is highly suggestive that a repair may fail<sup>[1,17]</sup>. Superior migration can be accentuated by taking the radiograph with the arm in slight abduction due to pull of the deltoid muscle overriding the deficient force coupling of the incompetent rotator cuff<sup>[7]</sup>. The amount of tendon retraction and fatty infiltration can be assessed on ultrasound<sup>[7,18]</sup>, Computed tomography (CT)<sup>[1,7]</sup> and/or magnetic resonance imaging (MRI)<sup>[1,7]</sup>. Grade 3 and 4 fatty infiltration according to the Goutallier is commonly considered irreparable<sup>[1,19]</sup>, although Burkhart has disputed this in a recent study<sup>[20]</sup>.

Once a rotator cuff is deemed irreparable, a variety of arthroscopic treatment options have been proposed to reduce pain and improve function in patients with IRCT. These options should be considered as part of the treatment algorithm and include simple debridement with or without a tenotomy, partial rotator cuff repair with or without interval slide, tuboplasty, graft interposition of the rotator cuff, suprascapular nerve ablation, superior capsule reconstruction and insertion of a biodegradable spacer (Inspace). Although these procedures vary in terms of outcome and operating time, they are generally considered less invasive with a lower complication rate compared to tendon transfers and reverse arthroplasty.

This paper reviews the current literature and available techniques to arthroscopically address irreparable rotator cuff tears. It includes all historic and recent innovative methods to address this difficult and challenging clinical problem.

## DEBRIDEMENT WITH OR WITHOUT BICEPS TENOTOMY

A debridement of the rotator cuff and subacromial decompression was first proposed by Rockwood *et al*<sup>[21]</sup> in 1995 as a treatment option for patients with an irreparable rotator cuff tear. In this study, 50 patients (53 shoulders) were followed up at an average of 6.5 years, with 83% of patients having a satisfactory outcome with a significant decrease in pain. The average active elevation improved from an average of 105° to 140°<sup>[21]</sup>. Further to this study, Kempf *et al*<sup>[22]</sup> showed a significant improvement in pain following a biceps tenotomy in a trial involving 210 patients. Although a variety of studies have shown that this remains a viable option in the elderly and low demand patient, it does not slow the progression of osteoarthritis<sup>[1]</sup>.

## PARTIAL ROTATOR CUFF REPAIR

In 1993, Burkhart *et al*<sup>[23]</sup> first introduced the biomechanical concept of the “suspension bridge” in the rotator cuff. This theory evolved into the functional rotator cuff and provided a rationale for partial repair of the rotator cuff. This involves the restoration of the cables involved in force transmission as well as force couples around the shoulder. The rotator cables have been defined anatomically at the level of the biceps tendon above supraspinatus anteriorly and the lower border of infraspinatus posteriorly. Most irreparable tears have a degree of extension anteriorly or posteriorly, which also affect the transverse couples. The importance of addressing the imbalance between the transverse couples (consisting of subscapularis and infraspinatus-teres minor complex) has been stressed. Repair must include all of subscapularis as well as the inferior half of infraspinatus as a minimum. This restores the transverse force couples and allows a stable fulcrum for normal shoulder kinematics. Burkhart *et al*<sup>[24]</sup> also warned against subscapularis tendon transposition to cover the residual defect as it alters the centroid (line of action) so that it lies above the centre of rotation and destroys the coronal plane force couple between subscapularis and deltoid, thus contributing to superior migration of the humeral head. In the context of the irreparable rotator cuff tear, it was felt that these tears could be partially repaired to fulfil the above criteria and hence, improve function<sup>[25]</sup>.

Suitable patients include those who clinically have an imbalance in subscapularis and infraspinatus function and have difficulty with overhead function. Burkhart identified this cohort using lift-off and resisted external rotation tests. There have been several studies assessing

the outcomes of partial repair although initial studies were performed as open procedures. Burkhart's original paper showed an improvement in various parameters including active elevation (improved from 59.6° to 150.4°), strength (0-5 scale) (improved from 2.1 to 4.4) and UCLA score (improved from 9.8 to 27.6). In his cohort of 14 patients, one patient had a poor result. Duralde *et al.*<sup>[26]</sup> reported similar outcomes to Burkhart in their retrospective study with statistically significant improvements in American Shoulder and Elbow (ASES) index, pain and active elevation.

Berth *et al.*<sup>[27]</sup> have since described arthroscopic partial repair of large and massive rotator cuff tears. In their series, partial repair was compared to debridement<sup>[27]</sup>. Both treatment arms showed similar improvements although several studies suggest that the partial repair provides a longer lasting improvement when compared to debridement alone<sup>[28]</sup>. It was noted that 52% had structurally failed when imaged using ultrasound at 24 mo, although this rate of failure is similar to the current literature for cuff repairs<sup>[29]</sup>. Therefore, partial repair represents a reasonable option in this challenging subset of patients by providing pain relief and restoring function<sup>[25]</sup>.

## INTERVAL SLIDE

Tauro<sup>[30]</sup> popularised the arthroscopic technique of the interval slide after it was originally described by Bigliani as an open procedure<sup>[31]</sup>. This involves release of the supraspinatus tendon from the rotator interval to improve mobility. Burkhart redefined this as the anterior interval slide and described a second interval slide between the supraspinatus and the infraspinatus tendon as the posterior interval slide<sup>[32]</sup>. These techniques allowed isolated mobilisation of the supraspinatus tendon laterally to its bony footprint and subsequent repair.

Lo *et al.*<sup>[32]</sup> showed statistically significant improvements in mean pain scores (from 2.1 to 8.7), forward elevation (108.9 to 146.1), mean strength (2.2 to 3.6) and UCLA score (10.0 to 28.3). Numerous studies have corroborated the results of arthroscopic interval slide repairs<sup>[33-35]</sup>. The advantages of this technique are thought to be a more anatomical and reliable repair. However, studies comparing the results of partial repair with interval slide and found no significant difference in outcomes<sup>[34,35]</sup>.

Concerns regarding this technique include devascularisation of the supraspinatus tendon and defunctioning of an already impaired muscle tendon unit from the interval slide<sup>[34]</sup>. Despite these concerns, Iagulli only had one re-tear secondary to trauma. This underwent revision repair with a fair result<sup>[34]</sup>. Although, Kim *et al.*<sup>[35]</sup> found that 91% of complete repairs had re-tears, this did not clinically correlate with outcomes in terms of pain or function.

## TUBEROPLASTY

The concept of tuberoplasty is to create an acromiohumeral articulation; it was first introduced by Fenlin *et al.*<sup>[36]</sup> as an open procedure in 2002. The goal is to contour and reshape the greater tuberosity to create a smooth and

congruent articulation between the greater tuberosity of the humerus and the under surface of the acromion. The initial study<sup>[36]</sup> in 2002 included 20 patients at an average age of 63 years (44-82 years), with a mean follow-up of 27 mo (7-58 mos). Overall the average UCLA scores improved from 9.3 to 27.7, with 95% satisfactory results (12 excellent, 6 good and 1 fair) and only one poor result.

Inevitably, an arthroscopic approach to this procedure was presented by Scheibel *et al.*<sup>[37]</sup> in 2004, who described the reversed arthroscopic subacromial decompression. This study presented the results in 23 patients with an average age of 69 years (range 60-81) at a mean follow-up of 40 mo (range 20-58). One patient who underwent revision surgery at 6 mo was excluded. The mean weighted Constant score improved significantly ( $P < 0.001$ ) from 65.9% to 90.6%, with significant improvements in pain, range of motion and activities of daily living. Although there was progression of osteoarthritis by 1 grade in the majority of patients, this was not reflected in the eventual outcome with 14 excellent, 5 good, 2 satisfactory and 1 poor results according to the Constant score.

Subsequently, two studies have been published confirming the benefits of an arthroscopic tuberoplasty with<sup>[38]</sup> and without acromioplasty<sup>[39]</sup> as a treatment option in patients with irreparable rotator cuff tears. Verhelst *et al.*<sup>[38]</sup> followed up 34 shoulders (33 patients) with an average age of 69.6 years at 38 mo (21-52), while Lee *et al.*<sup>[39]</sup> reported on 32 patients with an average age of 62.5 at 40 mo (24-63). Both studies showed a significant improvement in range of motion and decrease in pain following surgery with 84.4% and 81% patients reporting excellent or good results. While there was no significance difference in the improvement related to gender, age and preoperatively range of motion, poor outcomes were attributed to increased preoperative pain, patients with pseudoparalysis<sup>[38]</sup> and a disruption of the inferior scapulo-humeral line<sup>[39]</sup>.

The importance of maintaining the coracoacromial arch as a passive stabiliser to anterior and superior subluxation of the proximal humerus was highlighted in all 4 studies. These studies concluded that this remains an excellent treatment option in patients with an irreparable rotator cuff tear.

## GRAFT INTERPOSITION

The first reported use of a graft interposition in IRCT is by Neviaser *et al.*<sup>[40]</sup> in 1978, who used freeze-dried rotator cuff allograft to restore the continuity between the retracted irreparable rotator cuff tendon and the greater tuberosity in 16 patients. Although a standardised scoring system was not used, 13 of the 16 patients reported good to excellent results with all having pain relief at an average of 20 mo follow-up. These results were however contradicted a decade later by Nasca<sup>[41]</sup> in his report on 7 patients with a similar technique. Only 2 had reasonable function although 5 had pain relief following the surgery and the authors concluded that freeze dried allografts do not appear to be of significant value in patients with

chronic massive rotator cuff tears<sup>[41]</sup>.

A variety of biological and synthetic interposition grafts have been suggested. Biological grafts used include allografts such as freeze dried rotator cuff<sup>[41,42]</sup>, quadriceps tendon<sup>[12]</sup>, patellar tendon<sup>[12]</sup>, achilles tendon<sup>[12]</sup>, dermal matrix (Graftjacket)<sup>[12,42-46]</sup>, tensor fascia lata<sup>[47]</sup> and autografts such as the biceps tendon<sup>[48,49]</sup> and tensor fascia lata<sup>[50]</sup>. Xenografts have also been used for interposition and include porcine dermal collagen<sup>[51,52]</sup> and porcine small intestinal submucosa<sup>[53]</sup>. A variety of synthetic grafts have been researched including Polyester ligament (Dacron)<sup>[54]</sup>, Gore-Tex soft tissue patch<sup>[13]</sup>, Mersilene mesh<sup>[55]</sup>, Teflon felt<sup>[14]</sup> and Carbon fibre patches<sup>[56]</sup>.

In 2008, the Snyder group were the first to present results of an arthroscopic interposition technique using Human dermal allograft (Graftjacket)<sup>[42]</sup>. Graftjacket is currently only registered for augmentation of rotator cuff repairs and not interposition grafting to bridge gaps<sup>[44,57]</sup>. Despite this many of the studies on interposition have used Graftjacket as a graft. The choice of graft is influenced by a variety of factors including mechanical properties, host response and potential for ingrowth.

The mechanical properties of biological allografts have been shown to be inferior to both autografts and synthetic grafts<sup>[57]</sup>. With regards to host response, xenografts appear to induce the most significant hypersensitivity, thought to be related to the galactose- $\alpha$  (1,3)-galactose ( $\alpha$ -Gal) terminal disaccharide<sup>[57]</sup>. Although it appears to be low, more work is required to assess the host response to synthetic grafts. An important factor in the longevity and strength of a graft is the amount of ingrowth. This is thought to be influenced by the surface topography and porosity of the graft and been shown to be favourable in biological grafts, due to type 1 collagen, when compared to synthetic grafts.

The majority of the studies published on interposition grafting were performed via an open or mini open approach, a study<sup>[49]</sup> which included patients with both open and arthroscopic surgery showed there was no difference in outcome between the two approaches. Although Moore *et al.*<sup>[12]</sup> questioned the use of allograft interposition based on a high failure rate on MRI and results equivocal to a simple debridement, the majority of studies reporting the use of graft interposition as a treatment option for IRCT support their use with a statistically significant decrease in pain, improvement in subjective scores and improvement in Range of Motion (Tables 1-4).

Only one randomised prospective study<sup>[50]</sup> has compared interposition (done with autograft tensor fascia lata) and partial repair in irreparable rotator cuff tears. This randomised trial included 48 patients in two groups of similar demographics and tear patterns. Although there was a significant improvement in clinical outcomes in both groups, there were significantly less retears of the infraspinatus muscles in the patchgraft group (8.3% *vs* 41.7%)<sup>[50]</sup>. In addition, shoulders with retears of the ISP had significantly inferior clinical outcomes when compared to those without retears ( $P < 0.001$ ).

## SUPRASCAPULAR NERVE ABLATION

The suprascapular nerve is derived from the upper trunk of the brachial plexus and is a mixed motor and sensory nerve. It provides the main sensory innervation to the posterior shoulder joint capsule, acromioclavicular joint, subacromial bursa, coracoclavicular and coracohumeral ligament<sup>[58]</sup>. Blockade of the suprascapular nerve has been shown to improve chronic pain in numerous studies<sup>[59]</sup>.

In the irreparable rotator cuff, suprascapular nerve ablation is a salvage procedure. The main indication is in poor surgical candidates with significant medical comorbidities and/or poor glenoid bone stock and end-stage rotator cuff arthropathy. Patients are often considered for nerve ablation after conservative therapies have been exhausted<sup>[60]</sup>. Different techniques have been described including percutaneous SSN pulsed radiofrequency and arthroscopic SSN neurectomy<sup>[61]</sup>.

Pulsed radiofrequency techniques were originally described in the treatment of chronic back pain<sup>[62]</sup>. It is thought to be a non-destructive modality and works by delivering an electrical field to neural tissue rather than thermal coagulation<sup>[63]</sup>. The theoretical advantage is that it affects the smaller, pain fibres more than the larger motor fibres, thus preserving any residual motor function. Since its inception, pulsed radiofrequency has been applied to a wider range of clinical conditions including its use on the suprascapular nerve as a percutaneous technique<sup>[64]</sup>.

Shah *et al.*<sup>[65]</sup> first described this technique in a case report of a polytrauma patient with post-traumatic osteoarthritis, who had gained temporary pain relief after a suprascapular nerve block. The patient subsequently underwent four cycles of pulsed radiofrequency to the suprascapular nerve over 16 mo, with an improvement in numerical rating scale (NRS-11) score from 7-8 to 2-3. The duration of pain relief varied from 12-18 wk<sup>[65]</sup>.

Kane *et al.*<sup>[60]</sup> showed that pulsed radiofrequency to the suprascapular nerve in a cohort of twelve patients with painful cuff tear arthropathy resulted in a significant improvement in Constant, Oxford and Visual Analogue scores at three months. However, it was felt that efficacy of the treatment was wearing off by the six month end point in up to 50% of the patients<sup>[60]</sup>.

Nizlan *et al.*<sup>[66]</sup> described an arthroscopic SSN neurectomy technique in patients who were poor surgical candidates for shoulder arthroplasty with significant chronic pain. 75% of patients reported good to excellent pain relief and 80% noted an improvement in quality of life in this cohort. However, no assessment or comment was made with regard to outcomes due to loss of residual infraspinatus function<sup>[66]</sup>.

## ARTHROSCOPIC SUPERIOR CAPSULE RECONSTRUCTION

The superior capsule of the glenohumeral joint lies on the inferior surface of the supraspinatus and infraspinatus tendons and in conjunction with the rotator cuff plays a role in providing superior stability to the joint<sup>[67]</sup>. Rotator

**Table 1 Results of allograft interposition**

Study and graft	Number	Ave age (yr)	F/U (mo)	Outcome score Pre/post/ <i>P</i> value	ROM Pre/post/ <i>P</i> value	Conclusion
Neviaser <i>et al</i> <sup>[40]</sup> Freeze dried rotator cuff	16	58	20	13/16 excellent results Criteria used: Nocturnal pain Degree of abduction	> 160:6 120-160:3 90-120:5 < 90:2 Average: 122.5 FF: 78/90 Abd: 69.2/84	In our patients there has been no sign that the grafts were rejected and the goals of the procedure to improve motion and to relieve pain usually were attained
Nasca <i>et al</i> <sup>[41]</sup> Freeze dried rotator cuff	7	62	42	Good 2, fair 2, poor 3		Freeze dried rotator cuff allografts do not appear to be of significant value in the surgical management of chronic massive rotator cuff tears
Venouziou <i>et al</i> <sup>[43]</sup> HDA	14	54.6	30.2	ASES: 23.8/72.3/ <i>P</i> = 0.001	FF: 73.6/129.3/ <i>P</i> = 0.002 ABD: 67.5/117.9/ <i>P</i> = 0.002 ER: 7.9/ 43.2/ <i>P</i> = 0.001	The ROM and the functional outcome were all improved in the patients with less than 2 cm tendon gap. In the case of larger tendon defects the outcome is unpredictable
Moore <i>et al</i> <sup>[12]</sup> 26 Patellar 5 Achilles 1 Quadriceps	32	59.1	31.3	UCLA: 12.1/26.1/ <i>P</i> < 0.001 Excellent 3, good 12, fair 8, poor 5	Active FF UCLA: 3/3.8/ <i>P</i> < 0.17 Resisted FF UCLA: 2.9/3.7/ <i>P</i> < 0.002	15/15 showed failure on MRI. Allograft reconstruction for massive, irreparable rotator cuff tears is not recommended
Bond <i>et al</i> <sup>[42]</sup> HDA	16	54.4	28.8	UCLA: 18.4/30.4/ <i>P</i> = 0.0001 Excellent 4, good 9, Fair 3, Poor 0 53.8/84/ <i>P</i> = 0.0001	FF: 106/142/ <i>P</i> = 0.0001 ER: 43/47.2/NR	Our study supports the hypothesis that GJA is a viable treatment option for surgical salvage in select cases of symptomatic massive, irreparable rotator cuff pathology
Gupta <i>et al</i> <sup>[44]</sup> HDA	24	63	36	ASES: 66.6/88.7/ <i>P</i> = 0.003 SF-12: 48.8/56.8/ <i>P</i> = 0.03	FF: 111.7/157.3/ <i>P</i> = 0.0002 ABD: 105/151.7/ <i>P</i> = 0.0001 ER: 46.2/65.1/ <i>P</i> = 0.001	Human dermal interposition repair of massive rotator cuff tears through a mini-open approach is a reproducible technique that leads to significant improvement in pain, ROM, strength and subjective scores
Wong <i>et al</i> <sup>[45]</sup> HDA (Extreme)	45	53.6	24 min	UCLA: 18.4/27.5/ <i>P</i> < 0.001 ASES: 84.1 (post)		Arthroscopic rotator cuff reconstruction with GraftJacket (Human dermal allograft) is safe and is associated with high patient satisfaction, without the morbidity of tendon transfer or arthroplasty
Ito <i>et al</i> <sup>[47]</sup> Allograft fascia lata	9	62.8	35	JOA: 47.9/91.7/ <i>P</i> = 0.0059	FF: 84.4/159.6/ <i>P</i> < 0.005 ADB: 62.2/163.3/ <i>P</i> < 0.005 ER: 43.9/41.7/NR	Patch Grafts are considered to have the advantages of achieving anatomical repair with minimal restriction of range of motion and minimal occurrence of re-tearing
Modi <i>et al</i> <sup>[46]</sup> HDA	61	62.6	42	OSS: 26/42/ <i>P</i> = 0.001	FF: 97/160/ <i>P</i> = 0.001 ABD: 90/155/ <i>P</i> = 0.001 ER: 42/60/0.04	GraftJacket allograft regenerative tissue matrix provides a very good option for bridging irreparable rotator cuff tears in the short to medium term

HDA: Human Dermal allograft; FF: Forward flexion; Abd: Abduction; ER: External rotation; UCLA: University of California-Los Angeles; ASES: American Shoulder and Elbow Surgeon evaluation form; JOA: Japanese Orthopaedic Association; OSS: Oxford shoulder score.

cuff tears are therefore associated with a defect of the superior capsule. Mihata *et al*<sup>[67,68]</sup> recently described an arthroscopic technique to reconstruct the superior capsule in patients with an irreparable rotator cuff tear in order to prevent superior migration of the humeral head with associated impingement.

Although this procedure is presented as an arthroscopic technique, it can be performed via open surgery if preferred by the surgeon. After an acromioplasty to avoid abrasion of the graft, a partial repair of infraspinatus and a repair of the subscapularis should be undertaken. The reconstruction of the capsule is undertaken with a tensor fascia lata autograft, with thick (doubled or tripled to size of 6-8 mm) and large grafts being better. The graft is attached laterally to the greater tuberosity by using a double row anchor technique and medially to superior aspect of the glenoid. The graft is then sutured

to the residual infraspinatus posteriorly and if required to the subscapularis or subscapularis tendon anteriorly with side to side sutures. This is thought to restore the force coupling of the joint. Attention should be paid to the correct tension of the anterior sutures to prevent contractures. If the medial, lateral and posterior is satisfactory, the anterior suture is not necessary. Postoperative rehabilitation is required for 6-12 mo<sup>[68]</sup>.

In order to assess the superior stability provided by the Arthroscopic Superior Capsule Reconstruction the authors undertook a cadaver study<sup>[67]</sup> which concluded that superior capsular reconstruction completely restored superior stability and thus prevented impingement, while interposition patch grafting to the torn tendon only partially restored stability allowing impingement of the interposition<sup>[67]</sup>.

A clinical trial published by the same authors<sup>[68]</sup>, a to-



**Table 2 Results of autograft interposition**

Study and graft	Number	Ave age (yr)	F/U (mo)	Outcome Score Pre/post/ <i>P</i> value	ROM Pre/post/ <i>P</i> value	Conclusion
Mori <i>et al</i> <sup>[50]</sup> Tensor fascia	24	65.9	35.5	ASES: 40.8/94.1/ <i>P</i> < 0.001 Constant: 37.4/81.1/ <i>P</i> < 0.001 JOA: 13.1/22.9/ <i>P</i> = 0.0019	FF: 114/160.8 ER: 27.9/46	The patch graft procedure showed an 8.3% retear rate for the repaired ISP with improved clinical scores and recovery of muscle strength
Sano <i>et al</i> <sup>[48]</sup> Biceps	14	64	28	Constant 48.4/81.8/ <i>P</i> < 0.001 UCLA 12.5/31.1/ <i>P</i> < 0.001	Active elevation 69/149/ <i>P</i> = 0.0010	LHB tendon patch grafting provided significant improvement in both the active elevation angle and for the JOA score. The LHB tendon patch grafting seems to be one of the useful options for surgical treatment of irreparable massive rotator cuff tears
Rhee <i>et al</i> <sup>[49]</sup> Biceps	31 15 open 16 arthro	61	32	Constant 48.4/81.8/ <i>P</i> < 0.001 UCLA 12.5/31.1/ <i>P</i> < 0.001	FF: 124/162/ <i>P</i> < 0.001 ABD: 134/168/ <i>P</i> < 0.001 ER: 38/47/ <i>P</i> = 0.46	An augmentation technique using the tenotomised biceps as a potential graft for rotator cuff tears is particularly useful in bridging the gap in immobile massive rotator cuff tears with posterior defects and retraction. Differences in postoperative clinical results between the open and arthroscopic groups were not statistically significant

FF: Forward flexion; Abd: Abduction; ER: External rotation; UCLA: UCLA: University of California-Los Angeles; ASES: American shoulder and elbow surgeon evaluation form; JOA: Japanese orthopaedic association.

**Table 3 Results of Xenograft interposition**

Study	Number	Ave age (yr)	F/U (mo)	Outcome score Pre/post/ <i>P</i> value	ROM Pre/post/ <i>P</i> value	Conclusion
Badhe <i>et al</i> <sup>[51]</sup> PDC (Permacol)	10	65.7	54	Constant: 42/62/ <i>P</i> = 0.0004	Post-operative: Active abd: 89 Passive abd: 98	Porcine dermal collagen is effective as an augmentation graft in the treatment of chronic extensive rotator cuff tears, providing excellent pain relief with a moderate improvement in active ranges of motion and strength
Soler <i>et al</i> <sup>[52]</sup> PDC (Permacol)	4	76		Reduced range and strength, increased pain	Mean active ER: 50 Not recorded	While the use of porcine dermal collagen (Permacol) has many obvious advantages, we do not advocate using it to bridge irreparable defects

PDC: Porcine dermal collagen; FF: Forward flexion; Abd: Abduction; ER: External rotation.

tal of 23 patients (24 shoulders) with irreparable rotator cuff repair where reviewed between 24 and 51 mo (average 34.1) following an arthroscopic superior capsular repair. The average age of the patients was 65.1 years. Patients demonstrated a significant improvement in clinical scores, ASES 23.5 to 92.1 (*P* < 0.0001) and range of motion, elevation 84° to 148° (*P* < 0.001) and external rotation 26° to 40° (*P* < 0.01). Radiographically the acromiohumeral distance increased significantly from 4.6 mm to 8.7 mm (*P* < 0.0001) postoperatively, with no progression of osteoarthritis of the glenohumeral joint. A postoperative MRI scan confirmed that 20 patients (83.3%) had an intact graft, with no progression of muscle atrophy. The authors surmised that the reconstruction of the superior capsule restored the force coupling due to suturing the graft to the infraspinatus posteriorly and the residual supraspinatus or subscapularis anteriorly (Figure 1).

## BIODEGRADABLE SPACER

The most recent treatment modality proposed for an irreparable rotator cuff tear is the InSpace system<sup>[69]</sup>. This device is a biodegradable spacer (balloon shape) which is implanted between the acromion and the humeral head

in an attempt to restore the shoulder biomechanics by reducing subacromial friction through lowering the humeral head during abduction<sup>[69]</sup>. The spacer is made of a copolymer poly-L-lactide-co-ε-capro-lactone which biodegrades over 12 mo, during which stage the force coupling should return and allow for long term improvement in the glenohumeral joint movement.

The insertion method is reported to be simple, safe and reproducible<sup>[69]</sup>. After a standard arthroscopy including debridement and bursectomy, the rotator cuff is assessed for reparability. Once deemed irreparable, the correct size is selected by the measuring between the lateral border of the acromion and superior rim of the glenoid rim. The rolled up spacer is inserted through a lateral portal and inflated with saline to fill the subacromion space. The shoulder is then taken through a full range of motion to ensure stability. The InSpace system can be used in patients with tears of SST, IS although it is preferable for Subscapularis to be intact or repaired. Contraindications include arthritis, allergies to the device materials and active infections. Potential complications include foreign body response, local irritation or inflammation, tissue necrosis and device displacement.

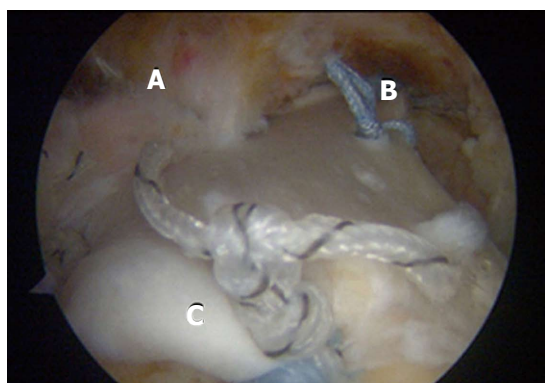
Senekovic *et al*<sup>[70]</sup> published their early results of 20



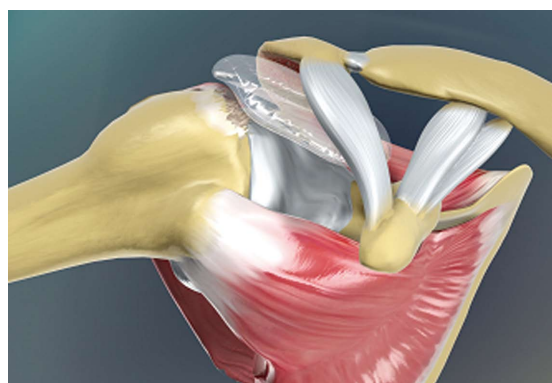
**Table 4 Results of Synthetic interposition**

Study	Number	Ave age (yr)	Follow-up (mo)	Outcome Score Pre/post/ <i>P</i> value	ROM Pre/post/ <i>P</i> value	Conclusion
Nada <i>et al</i> <sup>[54]</sup> Polyester ligament (Dacron)	21	66.5	36	Constant: 46.6/84.5/ <i>P</i> < 0.001 Excellent 17, good 2, fair 1, poor 1 JOA: 57.8/86/NR	FF: 65/120/ <i>P</i> < 0.001 Abd: 60/120/ <i>P</i> < 0.001 ER: 39/57/ <i>P</i> = 0.01	Polyester (Dacron) ligament augmentation can result in a pain free successful return of function in active symptomatic patients with massive chronic tears of the rotator cuff
Hirooka <i>et al</i> <sup>[13]</sup> Gore-Tex soft tissue patch	26	62	44			Good clinical results, especially pain relief, could be achieved with this procedure in both the small- and the large-patch groups, but good abduction strength was obtained only in the small-patch group
Audenaert <i>et al</i> <sup>[55]</sup> Mersilene mesh	41	67	43	Constant: 25.7/72.1/ <i>P</i> < 0.001	FF: 69.2/136/ <i>P</i> < 0.001 Abd: 68.4/133.7/ <i>P</i> < 0.001	A polyester patch for the closure of massive rotator cuff tears is a satisfying procedure in this complex and technically challenging group of patients
Ozaki <i>et al</i> <sup>[14]</sup> Teflon felt	25	67.3	42	23: No pain, 2: Some pain	ER: 32.4/38.2/ <i>P</i> < 0.05 16: Normal, 7: > 120, 2: < 30	Of 25 patients with massive rotator cuff tears, 23 had satisfactory functional results
Visuri <i>et al</i> <sup>[56]</sup> Carbon fibre patch	10	53.9	50.4	Excellent 7, good 2, poor 1	Abd: 73/166/NR	A carbon fiber tow application combined with Neer's anterior acromioplasty seems useful in the reconstruction of large tears of the rotator cuff

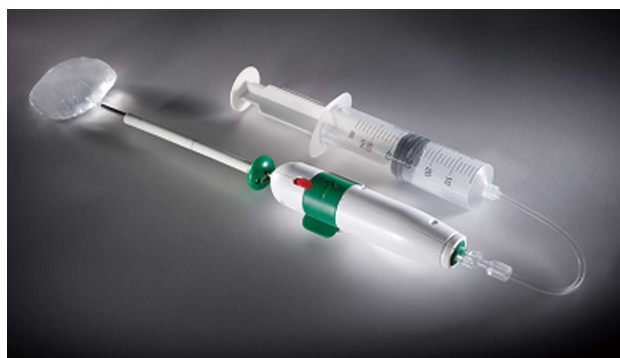FF: Forward flexion; Abd: Abduction; ER: External rotation; JOA: Japanese Orthopaedic Association.



**Figure 1** Arthroscopic view of a superior capsular repair with (A) the irreparable rotator cuff, (B) attachment of the Graftjacket to the superior glenoid and (C) Attachment of the Graftjacket to the rotator cuff footprint.



**Figure 3** An illustration of the InSpace balloon between the acromion and the humeral head.



**Figure 2** InSpace balloon insertion system.

patients treated with the InSpace system. The average age in this cohort was 70.5 years (range 54-85 years) and the follow up period was 34.7 mo (range 4-95 mo). The average total Constant score increased from 33.4 to 65.4 points, with a statistically significant improvement in all aspects

of the constant score. Although improvement in power became evident at 18 mo the improvement in shoulder function was sustained at 3 years. Once again, prospective randomised trials and longer follow up is required in order to confirm promising early results (Figures 2 and 3).

## CONCLUSION

The management of patients with an irreparable rotator cuff tear remains a challenge. A variety of less invasive arthroscopic techniques have been presented in the literature, the majority of which have reported satisfactory results. These treatments can be considered as a potential therapy with a decision as to which one based on a thorough clinical assessment, an individual's requirements and co-morbidities.

## REFERENCES

- 1 Gerber C, Wirth SH, Farshad M. Treatment options for massive rotator cuff tears. *J Shoulder Elbow Surg* 2011; **20**: S20-S29

- [PMID: 21281919 DOI: 10.1016/j.jse.2010.11.028]
- 2 **Muh SJ**, Streit JJ, Wanner JP, Lenarz CJ, Shishani Y, Rowland DY, Riley C, Nowinski RJ, Edwards TB, Gobeze R. Early follow-up of reverse total shoulder arthroplasty in patients sixty years of age or younger. *J Bone Joint Surg Am* 2013; **95**: 1877-1883 [PMID: 24132362 DOI: 10.2106/JBJS.L.10005]
- 3 **Groh GI**, Groh GM. Complications rates, reoperation rates, and the learning curve in reverse shoulder arthroplasty. *J Shoulder Elbow Surg* 2014; **23**: 388-394 [PMID: 24021159 DOI: 10.1016/j.jse.2013.06.002]
- 4 **Harreld KL**, Puskas BL, Frankle M. Massive rotator cuff tears without arthropathy: when to consider reverse shoulder arthroplasty. *J Bone Joint Surg Am* 2011; **93**: 973-984 [PMID: 21593377]
- 5 **Mulieri P**, Dunning P, Klein S, Pupello D, Frankle M. Reverse shoulder arthroplasty for the treatment of irreparable rotator cuff tear without glenohumeral arthritis. *J Bone Joint Surg Am* 2010; **92**: 2544-2556 [PMID: 21048173 DOI: 10.2106/JBJS.I.00912]
- 6 **Zumstein MA**, Pinedo M, Old J, Boileau P. Problems, complications, reoperations, and revisions in reverse total shoulder arthroplasty: a systematic review. *J Shoulder Elbow Surg* 2011; **20**: 146-157 [PMID: 21134666 DOI: 10.1016/j.jse.2010.08.001]
- 7 **Omid R**, Lee B. Tendon transfers for irreparable rotator cuff tears. *J Am Acad Orthop Surg* 2013; **21**: 492-501 [PMID: 23908255 DOI: 10.5435/JAAOS-21-08-492]
- 8 **Gerber C**, Rahm SA, Catanzaro S, Farshad M, Moor BK. Latissimus dorsi tendon transfer for treatment of irreparable posterosuperior rotator cuff tears: long-term results at a minimum follow-up of ten years. *J Bone Joint Surg Am* 2013; **95**: 1920-1926 [PMID: 24196461 DOI: 10.2106/JBJS.M.00122]
- 9 **Cofield RH**, Parvizi J, Hoffmeyer PJ, Lanzer WL, Ilstrup DM, Rowland CM. Surgical repair of chronic rotator cuff tears. A prospective long-term study. *J Bone Joint Surg Am* 2001; **83-A**: 71-77 [PMID: 11205861]
- 10 **Gerber C**, Fuchs B, Hodler J. The results of repair of massive tears of the rotator cuff. *J Bone Joint Surg Am* 2000; **82**: 505-515 [PMID: 10761941]
- 11 **Warner JJ**. Management of massive irreparable rotator cuff tears: the role of tendon transfer. *Instr Course Lect* 2001; **50**: 63-71 [PMID: 11372361]
- 12 **Moore DR**, Cain EL, Schwartz ML, Clancy WG. Allograft reconstruction for massive, irreparable rotator cuff tears. *Am J Sports Med* 2006; **34**: 392-396 [PMID: 16260463 DOI: 10.1177/0363546505281237]
- 13 **Hirooka A**, Yoneda M, Wakaitani S, Isaka Y, Hayashida K, Fukushima S, Okamura K. Augmentation with a Gore-Tex patch for repair of large rotator cuff tears that cannot be sutured. *J Orthop Sci* 2002; **7**: 451-456 [PMID: 12181658 DOI: 10.1007/s007760200078]
- 14 **Ozaki J**, Fujimoto S, Masuhara K, Tamai S, Yoshimoto S. Reconstruction of chronic massive rotator cuff tears with synthetic materials. *Clin Orthop Relat Res* 1986; (202): 173-183 [PMID: 3955946]
- 15 **Hertel R**, Ballmer FT, Lombert SM, Gerber C. Lag signs in the diagnosis of rotator cuff rupture. *J Shoulder Elbow Surg* 1996; **5**: 307-313 [PMID: 8872929]
- 16 **Walch G**, Boulahia A, Calderone S, Robinson AH. The 'dropping' and 'hornblower's' signs in evaluation of rotator-cuff tears. *J Bone Joint Surg Br* 1998; **80**: 624-628 [PMID: 9699824]
- 17 **Ellman H**, Hanker G, Bayer M. Repair of the rotator cuff. End-result study of factors influencing reconstruction. *J Bone Joint Surg Am* 1986; **68**: 1136-1144 [PMID: 3771595]
- 18 **Wall LB**, Teefey SA, Middleton WD, Dahiya N, Steger-May K, Kim HM, Wessell D, Yamaguchi K. Diagnostic performance and reliability of ultrasonography for fatty degeneration of the rotator cuff muscles. *J Bone Joint Surg Am* 2012; **94**: e83 [PMID: 22717835 DOI: 10.2106/JBJS.J.01899]
- 19 **Goutallier D**, Postel JM, Gleyze P, Leguilloux P, Van Driessche S. Influence of cuff muscle fatty degeneration on anatomic and functional outcomes after simple suture of full-thickness tears. *J Shoulder Elbow Surg* 2003; **12**: 550-554 [PMID: 14671517 DOI: 10.1016/S1058-2746(03)00211-8]
- 20 **Burkhart SS**, Barth JR, Richards DP, Zlatkin MB, Larsen M. Arthroscopic repair of massive rotator cuff tears with stage 3 and 4 fatty degeneration. *Arthroscopy* 2007; **23**: 347-354 [PMID: 17418325]
- 21 **Rockwood CA**, Williams GR, Burkhead WZ. Débridement of degenerative, irreparable lesions of the rotator cuff. *J Bone Joint Surg Am* 1995; **77**: 857-866 [PMID: 7782358]
- 22 **Kempf JF**, Gleyze P, Bonnomet F, Walch G, Mole D, Frank A, Beaufils P, Levigne C, Rio B, Jaffe A. A multicenter study of 210 rotator cuff tears treated by arthroscopic acromioplasty. *Arthroscopy* 1999; **15**: 56-66 [PMID: 10024034]
- 23 **Burkhart SS**, Esch JC, Jolson RS. The rotator crescent and rotator cable: an anatomic description of the shoulder's "suspension bridge". *Arthroscopy* 1993; **9**: 611-616 [PMID: 8305096]
- 24 **Burkhart SS**. Reconciling the paradox of rotator cuff repair versus debridement: a unified biomechanical rationale for the treatment of rotator cuff tears. *Arthroscopy* 1994; **10**: 4-19 [PMID: 8166901]
- 25 **Burkhart SS**, Nottage WM, Ogilvie-Harris DJ, Kohn HS, Pachelli A. Partial repair of irreparable rotator cuff tears. *Arthroscopy* 1994; **10**: 363-370 [PMID: 7945631]
- 26 **Duralde XA**, Bair B. Massive rotator cuff tears: the result of partial rotator cuff repair. *J Shoulder Elbow Surg* 2005; **14**: 121-127 [PMID: 15789003]
- 27 **Berth A**, Neumann W, Awiszus F, Pap G. Massive rotator cuff tears: functional outcome after debridement or arthroscopic partial repair. *J Orthop Traumatol* 2010; **11**: 13-20 [PMID: 20198404 DOI: 10.1007/s10195-010-0084-0]
- 28 **Melillo AS**, Savoie FH, Field LD. Massive rotator cuff tears: debridement versus repair. *Orthop Clin North Am* 1997; **28**: 117-124 [PMID: 9024436]
- 29 **Sugaya H**, Maeda K, Matsuki K, Moriishi J. Repair integrity and functional outcome after arthroscopic double-row rotator cuff repair. A prospective outcome study. *J Bone Joint Surg Am* 2007; **89**: 953-960 [PMID: 17473131]
- 30 **Tauro JC**. Arthroscopic "interval slide" in the repair of large rotator cuff tears. *Arthroscopy* 1999; **15**: 527-530 [PMID: 10424557]
- 31 **Bigliani LU**, Cordasco FA, McLlveen SJ, Musso ES. Operative repair of massive rotator cuff tears: Long-term results. *J Shoulder Elbow Surg* 1992; **1**: 120-130 [PMID: 22971604 DOI: 10.1016/1058-2746(92)90089]
- 32 **Lo IK**, Burkhart SS. Arthroscopic repair of massive, contracted, immobile rotator cuff tears using single and double interval slides: technique and preliminary results. *Arthroscopy* 2004; **20**: 22-33 [PMID: 14716275]
- 33 **Tauro JC**. Arthroscopic repair of large rotator cuff tears using the interval slide technique. *Arthroscopy* 2004; **20**: 13-21 [PMID: 14716274]
- 34 **Iagulli ND**, Field LD, Hobgood ER, Ramsey JR, Savoie FH. Comparison of partial versus complete arthroscopic repair of massive rotator cuff tears. *Am J Sports Med* 2012; **40**: 1022-1026 [PMID: 22415210 DOI: 10.1177/0363546512438763]
- 35 **Kim SJ**, Kim SH, Lee SK, Seo JW, Chun YM. Arthroscopic repair of massive contracted rotator cuff tears: aggressive release with anterior and posterior interval slides do not improve cuff healing and integrity. *J Bone Joint Surg Am* 2013; **95**: 1482-1488 [PMID: 23965698 DOI: 10.2106/JBJS.L.01193]
- 36 **Fenlin JM**, Chase JM, Rushton SA, Frieman BG. Tuberosplasty: creation of an acromioclavicular articulation-a treatment option for massive, irreparable rotator cuff tears. *J Shoulder Elbow Surg* 2002; **11**: 136-142 [PMID: 11988724]
- 37 **Scheibel M**, Lichtenberg S, Habermeyer P. Reversed arthroscopic subacromial decompression for massive rotator cuff tears. *J Shoulder Elbow Surg* 2004; **13**: 272-278 [PMID: 15111896]
- 38 **Verhelst L**, Vandekerckhove PJ, Sergeant G, Liekens K, Van

- Hoonacker P, Berghs B. Reversed arthroscopic subacromial decompression for symptomatic irreparable rotator cuff tears: mid-term follow-up results in 34 shoulders. *J Shoulder Elbow Surg* 2010; **19**: 601-608 [PMID: 20056453 DOI: 10.1016/j.jse.2009.10.001]
- 39 Lee BG, Cho NS, Rhee YG. Results of arthroscopic decompression and tuberosity for irreparable massive rotator cuff tears. *Arthroscopy* 2011; **27**: 1341-1350 [PMID: 21873021 DOI: 10.1016/j.arthro.2011.06.016]
- 40 Neviaser JS, Neviaser RJ, Neviaser TJ. The repair of chronic massive ruptures of the rotator cuff of the shoulder by use of a freeze-dried rotator cuff. *J Bone Joint Surg Am* 1978; **60**: 681-684 [PMID: 681390]
- 41 Nasca RJ. The use of freeze-dried allografts in the management of global rotator cuff tears. *Clin Orthop Relat Res* 1988; **(228)**: 218-226 [PMID: 3342571]
- 42 Bond JL, Dopirak RM, Higgins J, Burns J, Snyder SJ. Arthroscopic replacement of massive, irreparable rotator cuff tears using a GraftJacket allograft: technique and preliminary results. *Arthroscopy* 2008; **24**: 403-409.e1 [PMID: 18375271 DOI: 10.1016/j.arthro.2007.07.033]
- 43 Venouziou AI, Kokkalis ZT, Sotereanos DG. Human dermal allograft interposition for the reconstruction of massive irreparable rotator cuff tears. *Am J Orthop (Belle Mead NJ)* 2013; **42**: 63-70 [PMID: 23431549]
- 44 Gupta AK, Hug K, Berkoff DJ, Boggess BR, Gavigan M, Malley PC, Toth AP. Dermal tissue allograft for the repair of massive irreparable rotator cuff tears. *Am J Sports Med* 2012; **40**: 141-147 [PMID: 22215726 DOI: 10.1177/0363546511422795]
- 45 Wong I, Burns J, Snyder S. Arthroscopic GraftJacket repair of rotator cuff tears. *J Shoulder Elbow Surg* 2010; **19**: 104-109 [PMID: 20188275 DOI: 10.1016/j.jse.2009.12.017]
- 46 Modi A, Singh HP, Pandey R, Armstrong A. Management of irreparable rotator cuff tears with the GraftJacket allograft as an interpositional graft. *Shoulder and Elbow* 2013; **5**: 188-194 [DOI: 10.1111/sae.12021]
- 47 Ito J, Morioka T. Surgical treatment for large and massive tears of the rotator cuff. *Int Orthop* 2003; **27**: 228-231 [PMID: 12827299]
- 48 Sano H, Mineta M, Kita A, Itoi E. Tendon patch grafting using the long head of the biceps for irreparable massive rotator cuff tears. *J Orthop Sci* 2010; **15**: 310-316 [PMID: 20559798 DOI: 10.1007/s00776-010-1453-5]
- 49 Rhee YG, Cho NS, Lim CT, Yi JW, Vishvanathan T. Bridging the gap in immobile massive rotator cuff tears: augmentation using the tenotomized biceps. *Am J Sports Med* 2008; **36**: 1511-1518 [PMID: 18443279 DOI: 10.1177/0363546508316020]
- 50 Mori D, Funakoshi N, Yamashita F. Arthroscopic surgery of irreparable large or massive rotator cuff tears with low-grade fatty degeneration of the infraspinatus: patch autograft procedure versus partial repair procedure. *Arthroscopy* 2013; **29**: 1911-1921 [PMID: 24169146]
- 51 Badhe SP, Lawrence TM, Smith FD, Lunn PG. An assessment of porcine dermal xenograft as an augmentation graft in the treatment of extensive rotator cuff tears. *J Shoulder Elbow Surg* 2008; **17**: 35S-39S [PMID: 18201655 DOI: 10.1016/j.jse.2007.08.005]
- 52 Soler JA, Gidwani S, Curtis MJ. Early complications from the use of porcine dermal collagen implants (Permacol) as bridging constructs in the repair of massive rotator cuff tears. A report of 4 cases. *Acta Orthop Belg* 2007; **73**: 432-436 [PMID: 17939470]
- 53 Iannotti JP, Codsi MJ, Kwon YW, Derwin K, Ciccone J, Brems JJ. Porcine small intestine submucosa augmentation of surgical repair of chronic two-tendon rotator cuff tears. A randomized, controlled trial. *J Bone Joint Surg Am* 2006; **88**: 1238-1244 [PMID: 16757756]
- 54 Nada AN, Debnath UK, Robinson DA, Jordan C. Treatment of massive rotator-cuff tears with a polyester ligament (Dacron) augmentation: clinical outcome. *J Bone Joint Surg Br* 2010; **92**: 1397-1402 [PMID: 20884978 DOI: 10.1302/0301-620X.92B10.24299]
- 55 Audenaert E, Van Nuffel J, Schepens A, Verhelst M, Verdonk R. Reconstruction of massive rotator cuff lesions with a synthetic interposition graft: a prospective study of 41 patients. *Knee Surg Sports Traumatol Arthrosc* 2006; **14**: 360-364 [PMID: 16252125]
- 56 Visuri T, Kiviluoto O, Eskelin M. Carbon fiber for repair of the rotator cuff. A 4-year follow-up of 14 cases. *Acta Orthop Scand* 1991; **62**: 356-359 [PMID: 1882676]
- 57 Ricchetti ET, Aurora A, Iannotti JP, Derwin KA. Scaffold devices for rotator cuff repair. *J Shoulder Elbow Surg* 2012; **21**: 251-265 [PMID: 22244069 DOI: 10.1016/j.jse.2011.10.003]
- 58 Aszmann OC, Dellon AL, Birely BT, McFarland EG. Innervation of the human shoulder joint and its implications for surgery. *Clin Orthop Relat Res* 1996; **(330)**: 202-207 [PMID: 8804294]
- 59 Emery P, Bowman S, Wedderburn L, Grahame R. Suprascapular nerve block for chronic shoulder pain in rheumatoid arthritis. *BMJ* 1989; **299**: 1079-1080 [PMID: 2511970]
- 60 Kane TP, Rogers P, Hazelgrove J, Wimsey S, Harper GD. Pulsed radiofrequency applied to the suprascapular nerve in painful cuff tear arthropathy. *J Shoulder Elbow Surg* 2008; **17**: 436-440 [PMID: 18328740 DOI: 10.1016/j.jse.2007.10.007]
- 61 Talbot TC, Limb D. The management of irreparable rotator cuff tears. *Orthopaedics Trauma* 2012; **26**: 367-373
- 62 Sluijter ME. The role of radiofrequency in failed back surgery patients. *Curr Rev Pain* 2000; **4**: 49-53 [PMID: 10998715]
- 63 Munglani R. The longer term effect of pulsed radiofrequency for neuropathic pain. *Pain* 1999; **80**: 437-439 [PMID: 10204759]
- 64 Byrd D, Mackey S. Pulsed radiofrequency for chronic pain. *Curr Pain Headache Rep* 2008; **12**: 37-41 [PMID: 18417022]
- 65 Shah RV, Racz GB. Pulsed mode radiofrequency lesioning of the suprascapular nerve for the treatment of chronic shoulder pain. *Pain Physician* 2003; **6**: 503-506 [PMID: 16871304]
- 66 Nizlan NM, Skirving AP, Campbell PT. Arthroscopic suprascapular neurectomy for the management of severe shoulder pain. *J Shoulder Elbow Surg* 2009; **18**: 245-250 [PMID: 19081272 DOI: 10.1016/j.jse.2008.09.001]
- 67 Mihata T, McGarry MH, Pirolo JM, Kinoshita M, Lee TQ. Superior capsule reconstruction to restore superior stability in irreparable rotator cuff tears: a biomechanical cadaveric study. *Am J Sports Med* 2012; **40**: 2248-2255 [PMID: 22886689 DOI: 10.1177/0363546512456195]
- 68 Mihata T, Lee TQ, Watanabe C, Fukunishi K, Ohue M, Tsujimura T, Kinoshita M. Clinical results of arthroscopic superior capsule reconstruction for irreparable rotator cuff tears. *Arthroscopy* 2013; **29**: 459-470 [PMID: 23369443 DOI: 10.1016/j.arthro.2012.10.022]
- 69 Savarese E, Romeo R. New solution for massive, irreparable rotator cuff tears: the subacromial "biodegradable spacer". *Arthrosc Tech* 2012; **1**: e69-e74 [PMID: 23766979 DOI: 10.1016/j.eats.2012.02.002]
- 70 Senekovic V, Poberaj B, Kovacic L, Mikek M, Adar E, Dekel A. Prospective clinical study of a novel biodegradable subacromial spacer in treatment of massive irreparable rotator cuff tears. *Eur J Orthop Surg Traumatol* 2013; **23**: 311-316 [PMID: 23412287 DOI: 10.1007/s00590-012-0981-4]

P- Reviewer: Kumar VP, Shafi M S- Editor: Song XX

L- Editor: A E- Editor: Wu HL





## WJO 5<sup>th</sup> Anniversary Special Issues (2): Arthroscopic

# Utility of arthroscopic guided synovial biopsy in understanding synovial tissue pathology in health and disease states

Mihir D Wechalekar, Malcolm D Smith

Mihir D Wechalekar, Malcolm D Smith, Rheumatology Research Unit, Repatriation General Hospital, Daw Park SA 5041, Australia

Author contributions: Both authors contributed equally to this work.

Supported by National Health and Medical Research Council Medical and Dental Postgraduate Research Scholarship to Dr. Wechalekar, MD, No. APP1018009

Correspondence to: Malcolm D Smith, BSc (Hons), MBBS, FRACP, PhD, Professor of Medicine, Director of Rheumatology, Southern Adelaide Local Health Network, Rheumatology Research Unit, Repatriation General Hospital, Daws Road, Daw Park SA 5041, South Australia, Australia. [malcolm.smith@health.sa.gov.au](mailto:malcolm.smith@health.sa.gov.au)

Telephone: +61-8-82751819 Fax: +61-8-83744276

Received: February 23, 2014 Revised: April 30, 2014

Accepted: July 12, 2014

Published online: November 18, 2014

## Abstract

The synovium is the soft tissue lining diarthrodial joints, tendon sheaths and bursae and is composed of intimal and subintimal layers. The intimal layer is composed of type A cells (macrophages) and type B cells (fibroblasts); in health, the subintima has few inflammatory cells. The synovium performs several homeostatic functions and is the primary target in several inflammatory arthritides. Inflammatory states are characterised by thickening of the synovial lining, macrophage recruitment and fibroblast proliferation, and an influx of inflammatory cells including lymphocytes, monocytes and plasma cells. Of the various methods employed to perform synovial biopsies arthroscopic techniques are considered the "gold standard", and have an established safety record. Synovial biopsy has been of critical importance in understanding disease pathogenesis and has provided insight into mechanisms of action of targeted therapies by way of direct evidence about events

in the synovial tissue in various arthritides. It has been very useful as a research tool for proof of concept studies to assess efficacy and mechanisms of new therapies, provide tissue for *in vitro* studies, proteomics and microarrays and allow evaluation for biomarkers that may help predict response to therapy and identify new targets for drug development. It also has diagnostic value in the evaluation of neoplastic or granulomatous disease or infection when synovial fluid analysis is non-contributory.

© 2014 Baishideng Publishing Group Inc. All rights reserved.

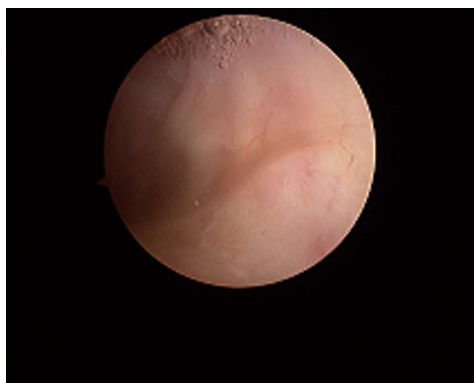**Key words:** Synovium; Synovial biopsy; Arthroscopy; Inflammatory arthritis; Synovial pathology

**Core tip:** The synovium is the soft tissue lining diarthrodial joints, tendon sheaths and bursae. Arthroscopic synovial biopsy techniques have an established safety record. Synovial biopsy has been of critical importance in understanding disease pathogenesis and mechanisms of action of targeted therapies; it has been invaluable as a research tool in proof of concept studies to assess mechanisms and efficacy of new therapies. It also has diagnostic value when synovial fluid analysis is non-contributory.

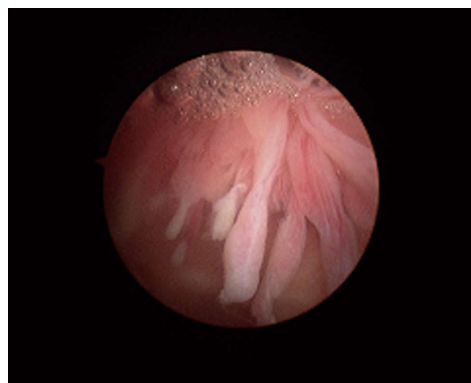
Wechalekar MD, Smith MD. Utility of arthroscopic guided synovial biopsy in understanding synovial tissue pathology in health and disease states. *World J Orthop* 2014; 5(5): 566-573 Available from: URL: <http://www.wjgnet.com/2218-5836/full/v5/i5/566.htm> DOI: <http://dx.doi.org/10.5312/wjo.v5.i5.566>

## INTRODUCTION

The synovium is the soft tissue lining diarthrodial joints,



**Figure 1** The normal synovium.



**Figure 2** The synovium in rheumatoid arthritis. Note the villous appearance and straight vessels.

tendon sheaths and bursae. The normal synovium has intimal and subintimal layers and performs the critical homeostatic functions of non-adherence, control of synovial fluid volume and composition and contributes to chondrocyte nutrition. The synovial membrane is involved in several rheumatic diseases including rheumatoid arthritis (RA), osteoarthritis (OA), the spondyloarthritides and the crystal induced arthropathies; and is the primary target of inflammation in RA. Analyses of the synovial membrane have been central to our current understanding of the pathogenetic mechanisms in the inflammatory arthritides in addition to having provided insight into mechanisms of action of targeted therapies.

## METHODS OF SYNOVIAL BIOPSY

The synovium is amenable to biopsy by arthroscopy or by using blind needle or ultrasound directed techniques<sup>[1]</sup>. Blind needle techniques have been established for decades and have a good safety and feasibility record<sup>[2]</sup>. They can be undertaken in an office setting, are relatively low-cost, and do not require special facilities. The major concerns of blind biopsy techniques lie in failure to obtain satisfactory samples, especially if the joint is clinically quiescent because of failure to visualize involved areas; in addition the joints that are amenable to biopsy by this technique are limited<sup>[2]</sup>. In one series with more than 800 Parker-Pearson biopsy procedures, sufficient tissue was obtained in about 85% of patients for histological examination; the authors found that the procedure failed especially in joints that were not swollen. There were no haemarthroses or infections reported in this series<sup>[3]</sup>. This failure rate, however would not be acceptable within the context of “proof of concept” phase I B or II RCTs in which arthroscopic synovial biopsy would be more acceptable<sup>[2]</sup>.

Arthroscopic synovial biopsy (usually done with a small-bore arthroscope) is the “gold standard”<sup>[2]</sup>; it has the advantage of macroscopic examination, visually directed biopsies with better sampling from areas of interest, its major disadvantages being the need for a “learning curve” and the requirement of a sterile area and operation theatre facilities<sup>[2]</sup>. In addition arthroscopic biopsy

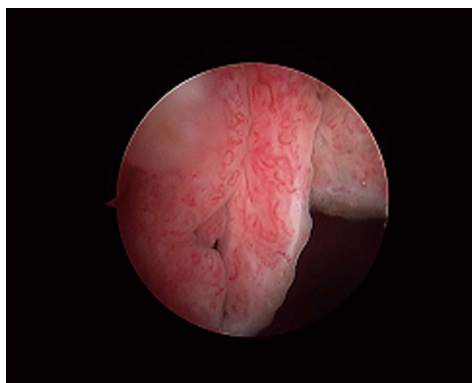
techniques allow biopsies from sites adjacent to cartilage (the “cartilage-pannus junction”), an area that differs quantitatively and qualitatively from the synovium as opposed to needle biopsies in which this area is difficult if not impossible to access<sup>[1]</sup>. Complications with arthroscopies performed by rheumatologists are similar to those reported in the orthopaedic literature: in a study evaluating 16532 arthroscopies in which 50.5% and 49.5% of the arthroscopies had a clinical and research indication respectively revealed a complication rate of joint infection in 0.1%, wound infection in 0.1%, haemarthrosis in 0.9%, deep venous thrombosis in 0.2% and neurological damage, thrombophlebitis and other complications in 0.02%, 0.08% and 0.06% respectively. Irrigation volume correlated with wound infection rate and centres that performed cartilage biopsy had a higher rate of haemarthrosis<sup>[4]</sup>. Further information on details of arthroscopic synovial biopsy performed as a day procedure has been reviewed elsewhere<sup>[5]</sup>.

Ultrasound guided synovial biopsy is a relatively recent technique which combines the advantage of being minimally invasive, enables sampling under guidance, and may be of particular utility in synovial biopsy of small joints<sup>[6,7]</sup>.

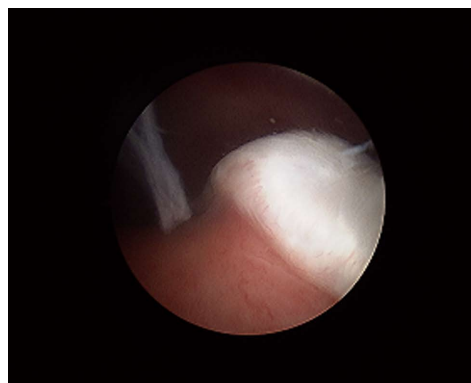
## MACROSCOPIC APPEARANCE OF THE SYNOVIUM

Macroscopically, the normal synovium (Figure 1) looks bland and devoid of villi, granularity or increased vascularity. In contrast, synovium in RA (Figure 2) has a distinct vascularity pattern with straight vessels as opposed to tortuous vessels or a mixed pattern seen in spondyloarthritides (SpA), reactive arthritis and psoriatic arthritis (Figure 3). The macroscopic appearance may predict histological changes (albeit with only a very moderate correlation) and clinical parameters with the straight pattern portending a worse outcome. However there is no widely accepted scoring system or well-validated method of description of macroscopic changes, and no reliable method to predict microscopic features, especially in an individual patient<sup>[1,6,8]</sup>.





**Figure 3** The synovium in psoriatic arthritis. Note the hypervascular villous hypertrophy and tortuous vessels.



**Figure 4** The cartilage-pannus junction.

## THE UNDERLYING DISEASE PROCESS AND REPRESENTATIVENESS OF SYNOVIAL TISSUE

A single study<sup>[9]</sup> has examined arthroscopic synovial biopsies from the knee joint and wrists or metacarpophalangeal joints in a small number of patients and found that the numerous biopsy specimens correlated well with regards to qualitative and quantitative markers of cellular infiltrate.

Various studies have also looked at whether there was significant variability of synovial tissue within regions of the same joint; this distinction is particularly relevant in the context of inflammatory arthritis such as RA where the cartilage-pannus (which is the inflamed tongue of abnormal synovium at the junction of the cartilage and bone and is thought to be central in causing bone destruction known as erosions; see Figure 4) junction may have a different cellular and cytokine profile as compared to synovium elsewhere. While some differences in certain cellular populations can be recognised, in general the features of inflammation and expression of mediators of inflammation and destruction are thought to be largely similar, though cellular markers responsible for bone destruction may be one notable exception<sup>[2,10,11]</sup>.

To minimise intra-joint variability and to maximise reliability it has been demonstrated that a minimum of six synovial biopsy specimens are necessary<sup>[2]</sup>.

## HANDLING OF SYNOVIAL TISSUE

The handling and processing of synovial tissue is largely dictated by the indication for the synovial biopsy. For routine histopathology by light microscopy, synovial biopsy samples should be fixed in 4% formalin and then embedded in paraffin. If infection is suspected, the tissue should be transported in suitable culture media. For detection of bacterial DNA using the PCR, it is critical to avoid contamination of the samples by foreign DNA and the samples should be snap frozen in liquid nitrogen<sup>[6]</sup>. The latter method is also preferred for synovial sample processing and storage in the research setting, and en-

ables immunohistochemical staining to be performed without the need for antigen retrieval. For detection of crystals, synovial tissue needs to be sent in absolute alcohol (as crystals dissolve in most other fixatives)<sup>[6]</sup>.

## METHODS OF QUANTIFICATION OF CELLULAR, CYTOKINE, CHEMOKINE AND RECEPTOR EXPRESSION IN SYNOVIAL BIOPSIES

The histological assessment of synovium in RA includes intimal thickness and density and composition of the cellular infiltrate<sup>[1]</sup>. The preferred method to analyse cellular infiltrate, cell phenotype, cell surface receptor expression and cellular adhesion molecule expression is by immunohistochemical techniques. Quantification can be performed using either manual counting (reliable but time consuming), semiquantitative scoring (the fastest of all techniques with proven intra- and inter-observer reliability) or digital image analysis (expensive and time consuming but has been validated with regards to inter- and intra-observer reliability for the widest range of biological variables including cytokines, metalloproteinases, vascular markers, adhesion molecules and chemokines)<sup>[2]</sup>. The synovium can also be subject to analyses, by real time quantitative polymerase chain reaction (PCR) for gene expression profiling, and to potentially analyse all genes, expression microarrays can be used; the latter method has revealed considerable heterogeneity and identified molecularly distinct forms of RA<sup>[12,13]</sup>.

## NORMAL SYNOVIAL

The normal synovium has an intimal layer, which is 20 to 40  $\mu$ m thick in cross section, and an areolar subintima, which can be up to 5 mm in thickness; considerable variability in this pattern exists and three main types of synovia have been described on the basis of their subintima: fibrous, areolar and adipose<sup>[14]</sup>. Of these, areolar synovium (Figure 5) is the most specialized form. Often crimped into folds, the lining consists of 2-3 layers of cells. Beneath this layer are capillaries and further down

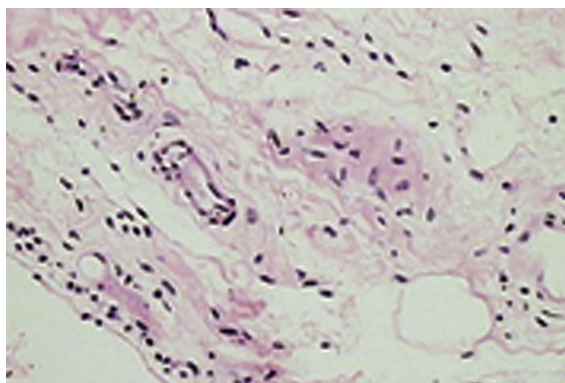


Figure 5 The normal (areolar) synovium.

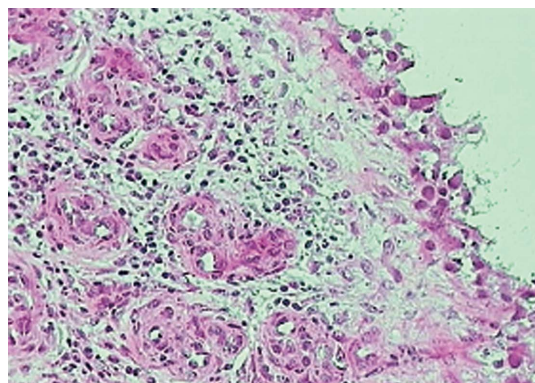


Figure 6 Lymphoid follicles in rheumatoid arthritis.

a network of arterioles, venules and lymphatic vessels. Nerve fibres are present in association with blood vessels. The supporting tissue matrix is rich in type I collagen which forms the physical membrane. Still deeper is a loose layer that enables the synovial membrane to move freely<sup>[15-18]</sup>. The adipose synovium occurs as fat pads and within villi; the deeper tissue is fat, there is a superficial net of capillaries and a complete intimal layer. Fibrous synovium can be difficult to accurately define and consists of fibrous tissue such as ligament or tendon on which lies an intimal layer of cells.

The synovium is devoid of a true basement membrane. Most of the soluble components and proteins in synovial fluid exit the synovial microcirculation through pores or fenestration in the vascular endothelium, traverse the interstitium and then enter the joint space. A rich microvascular network lies beneath the synovial surface with the larger venules, arterioles and lymphatics forming an anastomosing quadrilateral array<sup>[15,17,18]</sup>. The subintima in health, is generally devoid of inflammatory cells apart from a few macrophages and mast cells.

Recent evidence<sup>[19]</sup> from an animal model suggests that cadherin-11 (cadherins are cell-cell adhesion molecules controlling animal morphogenesis) on synovial fibroblasts may be critical in the development of a recognisable synovial lining by facilitation of cellular organization, compaction, and matrix development and may be critical for normal synovial tissue development.

Synovial intimal cells are of two types: type A cells (macrophages) and type B cells (fibroblasts). Evidence suggests that synovial macrophages are true macrophages derived from bone marrow derived precursors in contrast to synovial fibroblasts which are locally derived. In health, synovial fibroblasts are the dominant population (in disease states, macrophages may constitute as much as 80% of the intimal cells)<sup>[20-24]</sup>. Synovial fibroblasts are adapted to hyaluronan production and demonstrate high activity of the enzyme uridine diphosphoglucose dehydrogenase which is essential for synthesis of hyaluronan<sup>[25]</sup>. Synovial intimal fibroblasts express CD55; this feature distinguishes them from CD68 positive (but CD55 negative) intimal macrophages.

## SYNOVIUM IN DISEASE STATES

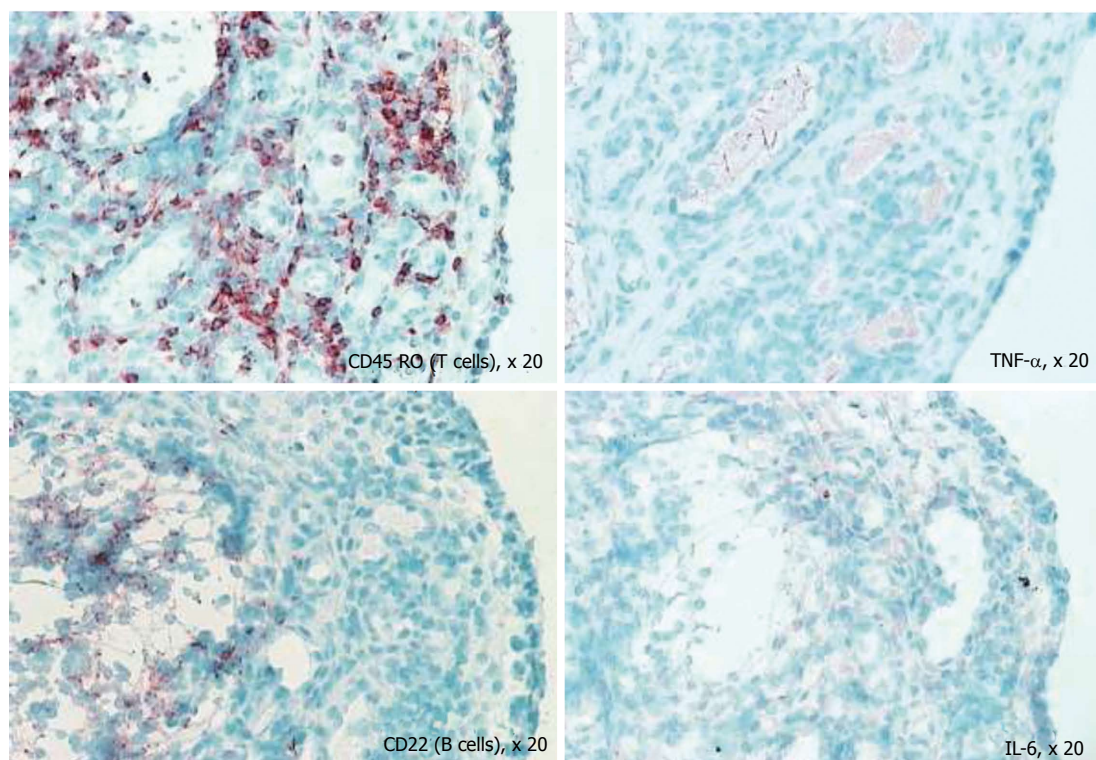
### RA

Microvascular changes occur very early in the course of the disease. As noted above, synovial blood vessels in RA are relatively straight in contrast to tortuous and bushy appearance in early psoriatic arthritis and SpA<sup>[26]</sup>.

As early as four to six weeks following the onset of symptoms of RA, synovial lining layer thickening of up to 10 cells is noted along with vascular proliferation and diffuse subintimal inflammatory infiltrate consisting of macrophages, lymphocytes, neutrophils, mast cells and dendritic cells (DCs)<sup>[27]</sup>. Synovial fibroblast proliferation and macrophage recruitment are both thought to be contributors to the lining layer thickening<sup>[28]</sup> and are of particular importance as they are both implicated in engendering joint damage<sup>[29-31]</sup>. Importantly, cellular changes in joints are well evident and established before the clinical onset of disease<sup>[32]</sup> and asymptomatic joints also show cellular changes mainly in the form of lining layer hyperplasia, though to a lesser degree than in clinically involved joints<sup>[33]</sup>. While most of the cellular subtypes (including monocytes, macrophages, lymphocytes and plasma cells thought to be more typical of established disease) are similar in early and late disease (including the degree of lymphocytic, plasma cell and neutrophil infiltration), lymphoid follicles (Figure 6) are generally a feature of established RA as compared to early disease<sup>[26,34,35]</sup>. Of note, “early” arthritis is a clinical and not a histological definition and changes at the synovial level precede clinical symptoms by an undetermined period of time<sup>[36]</sup>.

In general, there is no definite evidence to suggest a distinct histopathological pattern in early as opposed to late disease; the differences observed may relate not to disease duration but how active the disease was at the time of sampling; this was illustrated in a well-designed study<sup>[37]</sup> that included 16 patients with early RA (and similar numbers with late RA, early SpA and OA). In this study except for maximal synovial lining thickness, no difference was found between early and late RA, though differences were found between RA and SpA/OA.





**Figure 7** Differential staining of synovial biopsy for T cells, tumour necrosis factor, B cells (CD22), and interleukin-6 in a patient with active rheumatoid arthritis prior to disease-modifying therapy. TNF: Tumour necrosis factor; IL: Interleukin.

### **Spondyloarthritides including psoriatic arthritis**

In the study alluded to above<sup>[37]</sup>, patients with SpA showed similar degree of synovial villous hypertrophy in RA *vs* SpA, with a clear difference in vascular pattern. The mean synovial intimal layer thickness was similar. On microscopy vascularity was increased and few had lymphoid follicles. Another study<sup>[38]</sup> confirmed the increased vascularity of the psoriatic arthritic synovium as compared to RA and found less intimal layer hyperplasia, fewer macrophages but similar numbers of B cells, T cells and T cell subsets. There has been increasing interest recently in the Th-17 T cell pathway and related cytokines in the spondyloarthritides; despite therapeutic success of drugs targeting this pathway<sup>[39]</sup> and demonstration of increased frequency of IL-23 positive cells in facet joints of ankylosing spondylitis<sup>[40]</sup>, this pathway probably has diverse roles in the pathogenesis of psoriatic SpA, with little or no expression of IL-22 in the psoriatic synovium<sup>[41]</sup>.

### **Synovium as an immunologic target; synovial response to therapy in the inflammatory arthritides and targeted therapy**

Despite the fact that the synovium is the primary target of many inflammatory arthritides, synovial tissue specific antigens that may elicit an immune response *per se* are virtually unknown; when the rheumatic diseases are associated with autoantibodies, the antigens involved are ubiquitous. One of the most important reasons in undertaking a study of the synovium in health and disease is to

gain insight into immunopathologic processes that may suggest a therapeutic target in the inflammatory arthritides and identify biomarkers to predict outcomes in individual patients. Several studies have used serial synovial biopsies to attempt to identify biomarkers; these studies have evaluated responses to corticosteroids, gold, methotrexate, leflunomide, tumour necrosis factor inhibitors and rituximab, among others<sup>[42-46]</sup>. It is now well established that the inflammatory arthritides are very heterogeneous; indeed RA is now considered to be an umbrella term encompassing multiple disease subtypes with different phenotypes correlating to different genotypes. This heterogeneity<sup>[13,47]</sup> perhaps explains the variable response to therapy. It remains unexplained why some patients with RA fail to respond to standard and biologic disease modifying therapy; in addition, a proportion of patients initially respond only to lose response later. The exact reasons for this remain elusive. Studies in our laboratory (Figure 7) show that at the level of the synovial cellular infiltrate, the dominance of infiltrate is markedly heterogeneous and therapeutic selections that are not individualised may be one explanation for primary or secondary non-response to therapy.

### **Synovial proliferative conditions**

Pigmented villonodular synovitis (PVNS) is a nodular and villous thickening of the synovial membrane that affects males and females equally with the knee being the most commonly involved joint<sup>[48]</sup>. Microscopy reveals synovial intimal cells overlying a lobular and sheet-like

arrangement of mononuclear rounded (containing large hemosiderin granules) and epithelioid cells, multinucleated osteoclast-like giant cells, and lipid rich cells; an extra-articular analogue of PVNS is the giant cell tumour of the tendon sheath. Haemosiderotic synovitis (which usually happens as a complication of chronic intra-articular haemorrhage in haemophiliacs) differs from PVNS; the synovium lacks the thickened fronds and nodules of PVNS and becomes thickened and opaque due to repeated scarring<sup>[48]</sup>.

Synovial chondromatosis is characterised by multiple nodules of metaplastic hyaline cartilage that are present in the synovial sublining and often have foci of calcification or endochondral ossification<sup>[48]</sup>.

### **Crystal induced synovial disease: Gout and Calcium pyrophosphate dehydrate deposition disease (pseudogout)**

Monosodium urate crystal deposits in the synovium appear as creamy white tophi (which demonstrate needle shaped crystals that are strongly negatively birefringent on polarised light microscopy) and lead to membrane opacification and papillary thickening; histological examination of the synovial membrane in acute gout shows lining layer hyperplasia and intense infiltration with neutrophils, mononuclear cells and lymphocytes<sup>[48-50]</sup>. Synovial sections can also be stained with the DeGoltantal stain for urate to identify gouty synovitis<sup>[6]</sup>. Calcium pyrophosphate dehydrate (CPPD) disease, in contrast also involves cartilage; CPPD crystals are rhomboid shaped and positively birefringent on polarised light microscopy. Synovial deposits are usually smaller than gout, are associated with foci of metaplastic cartilage and usually elicit a histiocytic reaction<sup>[48]</sup>.

### **Infectious and granulomatous, infiltrating and other deposition diseases**

Synovial biopsies can assist in diagnosing bacterial species when blood and synovial cultures are negative especially when antibiotic treatment has been initiated<sup>[51]</sup> before culturing synovial fluid and with fastidious and difficult to grow bacteria<sup>[52]</sup>. Synovial biopsies may also help in diagnosis of granulomatous, infiltrating and deposition diseases including amyloidosis, sarcoidosis, arthritis caused by foreign body material and Erdheim-Chester disease<sup>[6]</sup>.

## **CONCLUSION**

Synovial biopsy is a safe and generally well-tolerated procedure; of the several methods used to obtain synovial biopsies, arthroscopic techniques, though more complicated, allow macroscopic examination and have a consistent and higher yield especially after effective therapy when synovial tissue volume has reduced.

Analyses of the synovial membrane provides useful insight into the etiopathogenesis of and direct evidence about events in the synovial tissue in various arthritides; in particular, evaluation of serial biopsy specimens has

been very useful in understanding the effects of targeted therapies. In addition, synovial biopsies have a role in the diagnostic evaluation of neoplastic or granulomatous disease or infection when synovial fluid analysis is non-contributory. Finally, synovial biopsies are invaluable as a research tool for proof of concept studies to assess efficacy and mechanisms of new therapies, provide tissue for in-vitro studies, proteomics and microarrays and allow evaluation for biomarkers that may help predict response to therapy and identify new targets for drug development.

## **REFERENCES**

- 1 **Vordenbäumen S**, Joosten LA, Friemann J, Schneider M, Ostendorf B. Utility of synovial biopsy. *Arthritis Res Ther* 2009; **11**: 256 [PMID: 19951395 DOI: 10.1186/ar2847]
- 2 **Smith MD**, Baeten D, Ulfgren AK, McInnes IB, Fitzgerald O, Bresnihan B, Tak PP, Veale D. Standardisation of synovial tissue infiltrate analysis: how far have we come? How much further do we need to go? *Ann Rheum Dis* 2006; **65**: 93-100 [PMID: 15975970 DOI: 10.1136/ard.2005.036905]
- 3 **Gerlag D**, Tak PP. Synovial biopsy. *Best Pract Res Clin Rheumatol* 2005; **19**: 387-400 [PMID: 15939365 DOI: 10.1016/j.berh.2005.01.005]
- 4 **Kane D**, Veale DJ, FitzGerald O, Reece R. Survey of arthroscopy performed by rheumatologists. *Rheumatology (Oxford)* 2002; **41**: 210-215 [PMID: 11886972]
- 5 **Smith MD**, Chandran G, Youssef PP, Darby T, Ahern MJ. Day case knee arthroscopy under regional anaesthesia, performed by rheumatologists. *Aust N Z J Med* 1996; **26**: 108-109 [PMID: 8775537]
- 6 **Gerlag DM**, Tak PP. How to perform and analyse synovial biopsies. *Best Pract Res Clin Rheumatol* 2013; **27**: 195-207 [PMID: 23731931 DOI: 10.1016/j.berh.2009.01.006]
- 7 **Scire CA**, Epis O, Codullo V, Humby F, Morbini P, Manzo A, Caporali R, Pitzalis C, Montecucco C. Immunohistological assessment of the synovial tissue in small joints in rheumatoid arthritis: Validation of a minimally invasive ultrasound-guided synovial biopsy procedure. *Arthritis Res Ther* 2007; **9**: R101 [DOI: 10.1186/ar2302]
- 8 **Reece RJ**, Canete JD, Parsons WJ, Emery P, Veale DJ. Distinct vascular patterns of early synovitis in psoriatic, reactive, and rheumatoid arthritis. *Arthritis Rheum* 1999; **42**: 1481-1484 [DOI: 10.1002/1529-0131(199907)42:7<1481::aid-anr23>3.0.co;2-e]
- 9 **Kraan MC**, Reece RJ, Smeets TJ, Veale DJ, Emery P, Tak PP. Comparison of synovial tissues from the knee joints and the small joints of rheumatoid arthritis patients: Implications for pathogenesis and evaluation of treatment. *Arthritis Rheum* 2002; **46**: 2034-2038 [PMID: 12209505 DOI: 10.1002/art.10556]
- 10 **Kane D**, Jensen LE, Grehan S, Whitehead AS, Bresnihan B, Fitzgerald O. Quantitation of metalloproteinase gene expression in rheumatoid and psoriatic arthritis synovial tissue distal and proximal to the cartilage-pannus junction. *J Rheumatol* 2004; **31**: 1274-1280 [PMID: 15229943]
- 11 **Crotti TN**, Ahern MJ, Lange K, Weedon H, Coleman M, Roberts-Thomson PJ, Haynes DR, Smith MD. Variability of RANKL and osteoprotegerin staining in synovial tissue from patients with active rheumatoid arthritis: quantification using color video image analysis. *J Rheumatol* 2003; **30**: 2319-2324 [PMID: 14677171]
- 12 **van der Pouw Kraan TC**, van Gaalen FA, Huizinga TW, Pieterman E, Breedveld FC, Verweij CL. Discovery of distinctive gene expression profiles in rheumatoid synovium using cDNA microarray technology: evidence for the existence of multiple pathways of tissue destruction and repair. *Genes Immun* 2003; **4**: 187-196 [PMID: 12700593 DOI: 10.1038/sj.gene.6363975]



- 13 **van der Pouw Kraan TC**, van Gaalen FA, Kasperkovitz PV, Verbeet NL, Smeets TJ, Kraan MC, Fero M, Tak PP, Huizinga TW, Pieterman E, Breedveld FC, Alizadeh AA, Verweij CL. Rheumatoid arthritis is a heterogeneous disease: evidence for differences in the activation of the STAT-1 pathway between rheumatoid tissues. *Arthritis Rheum* 2003; **48**: 2132-2145 [PMID: 12905466]
- 14 **Key JA**. The synovial membrane of joints and bursae. Special cytology. New York: PB Hoeber, 1932: 1055-1076
- 15 **Davies DV**. The structure and functions of the synovial membrane. *Br Med J* 1950; **1**: 92-95 [PMID: 15404164]
- 16 **Smith MD**, Barg E, Weedon H, Papangelis V, Smeets T, Tak PP, Kraan M, Coleman M, Ahern MJ. Microarchitecture and protective mechanisms in synovial tissue from clinically and arthroscopically normal knee joints. *Ann Rheum Dis* 2003; **62**: 303-307 [PMID: 12634226]
- 17 **Wilkinson LS**, Edwards JC. Microvascular distribution in normal human synovium. *J Anat* 1989; **167**: 129-136 [PMID: 2630527]
- 18 **Xu H**, Edwards J, Banerji S, Prevo R, Jackson DG, Athanasou NA. Distribution of lymphatic vessels in normal and arthritic human synovial tissues. *Ann Rheum Dis* 2003; **62**: 1227-1229 [PMID: 14644866]
- 19 **Lee DM**, Kiener HP, Agarwal SK, Noss EH, Watts GF, Chisaka O, Takeichi M, Brenner MB. Cadherin-11 in synovial lining formation and pathology in arthritis. *Science* 2007; **315**: 1006-1010 [PMID: 17255475 DOI: 10.1126/science.1137306]
- 20 **Edwards JC**. The nature and origins of synovium: experimental approaches to the study of synoviocyte differentiation. *J Anat* 1994; **184** (Pt 3): 493-501 [PMID: 7928638]
- 21 **Edwards JC**, Willoughby DA. Demonstration of bone marrow derived cells in synovial lining by means of giant intracellular granules as genetic markers. *Ann Rheum Dis* 1982; **41**: 177-182 [PMID: 7041832]
- 22 **Edwards JCW**, Wilkinson LS. Immunohistochemistry of synovium. In: Henderson B, Edwards JCW and Pettifer ER. Mechanisms and models in rheumatoid arthritis. New York: Academic Press, 1995: 133-150 [DOI: 10.1016/B978-012340440-4/50039-8]
- 23 **Ghadially FN**. Fine structure of joints. In: Sokoloff L. The joints and synovial fluid. New York: Academic Press, 1978: 105-176
- 24 **Henderson B**, Revell PA, Edwards JC. Synovial lining cell hyperplasia in rheumatoid arthritis: dogma and fact. *Ann Rheum Dis* 1988; **47**: 348-349 [PMID: 3284489]
- 25 **Wilkinson LS**, Pitsillides AA, Worrall JG, Edwards JC. Light microscopic characterization of the fibroblast-like synovial intimal cell (synoviocyte). *Arthritis Rheum* 1992; **35**: 1179-1184 [PMID: 1329776]
- 26 **Hitchon CA**, el-Gabalawy HS. The histopathology of early synovitis. *Clin Exp Rheumatol* 2003; **21**: S28-S36 [PMID: 14969047]
- 27 **Katirib A**, McNeil HP, Youssef PP. What can we learn from the synovium in early rheumatoid arthritis? *Inflamm Res* 2002; **51**: 170-175 [PMID: 12058953]
- 28 **Henderson B**. The synovial lining cell and synovitis. *Scand J Rheumatol Suppl* 1988; **76**: 33-38 [PMID: 3075086]
- 29 **Bartok B**, Firestein GS. Fibroblast-like synoviocytes: key effector cells in rheumatoid arthritis. *Immunol Rev* 2010; **233**: 233-255 [PMID: 20193003 DOI: 10.1111/j.0105-2896.2009.00859.x]
- 30 **Mulherin D**, Fitzgerald O, Bresnihan B. Synovial tissue macrophage populations and articular damage in rheumatoid arthritis. *Arthritis Rheum* 1996; **39**: 115-124 [PMID: 8546720]
- 31 **Yanni G**, Whelan A, Feighery C, Bresnihan B. Synovial tissue macrophages and joint erosion in rheumatoid arthritis. *Ann Rheum Dis* 1994; **53**: 39-44 [PMID: 8311554]
- 32 **Kraan MC**, Versendaal H, Jonker M, Bresnihan B, Post WJ, Hart BA, Breedveld FC, Tak PP. Asymptomatic synovitis precedes clinically manifest arthritis. *Arthritis Rheum* 1998; **41**: 1481-1488 [PMID: 9704648 DOI: 10.1002/1529-0131(199808)41]
- 33 **Soden M**, Rooney M, Cullen A, Whelan A, Feighery C, Bresnihan B. Immunohistological features in the synovium obtained from clinically uninvolved knee joints of patients with rheumatoid arthritis. *Br J Rheumatol* 1989; **28**: 287-292 [PMID: 2787183]
- 34 **Smeets TJ**, Dolhain RJEM AM, de Kuiper R, Breedveld FC, Tak PP. Poor expression of T cell-derived cytokines and activation and proliferation markers in early rheumatoid synovial tissue. *Clin Immunol Immunopathol* 1998; **88**: 84-90 [PMID: 9683554 DOI: 10.1006/clin.1998.4525]
- 35 **Tak PP**, Smeets TJ, Daha MR, Kluin PM, Meijers KA, Brand R, Meinders AE, Breedveld FC. Analysis of the synovial cell infiltrate in early rheumatoid synovial tissue in relation to local disease activity. *Arthritis Rheum* 1997; **40**: 217-225 [PMID: 9041933]
- 36 **Tarner IH**, Härle P, Müller-Ladner U, Gay RE, Gay S. The different stages of synovitis: acute vs chronic, early vs late and non-erosive vs erosive. *Best Pract Res Clin Rheumatol* 2005; **19**: 19-35 [PMID: 15588969 DOI: 10.1016/j.berh.2004.08.002]
- 37 **Baeten D**, Demetter P, Cuvelier C, Van Den Bosch F, Kruitthof E, Van Damme N, Verbruggen G, Mielants H, Veys EM, De Keyser F. Comparative study of the synovial histology in rheumatoid arthritis, spondyloarthropathy, and osteoarthritis: influence of disease duration and activity. *Ann Rheum Dis* 2000; **59**: 945-953 [PMID: 11087697 DOI: 10.1136/ard.59.12.945]
- 38 **Veale D**, Yanni G, Rogers S, Barnes L, Bresnihan B, Fitzgerald O. Reduced synovial membrane macrophage numbers, ELAM-1 expression, and lining layer hyperplasia in psoriatic arthritis as compared with rheumatoid arthritis. *Arthritis Rheum* 1993; **36**: 893-900 [PMID: 7686370 DOI: 10.1002/art.1780360705]
- 39 **Zaghi D**, Krueger GG, Callis Duffin K. Ustekinumab: a review in the treatment of plaque psoriasis and psoriatic arthritis. *J Drugs Dermatol* 2012; **11**: 160-167 [PMID: 22270196]
- 40 **Appel H**, Maier R, Bleil J, Hempfing A, Loddenkemper C, Schlichting U, Syrbe U, Sieper J. In situ analysis of interleukin-23- and interleukin-12-positive cells in the spine of patients with ankylosing spondylitis. *Arthritis Rheum* 2013; **65**: 1522-1529 [PMID: 23508523 DOI: 10.1002/art.37937]
- 41 **Benham H**, Norris P, Goodall J, Wechalekar MD, FitzGerald O, Szepietery A, Smith M, Thomas R, Gaston H. Th17 and Th22 cells in psoriatic arthritis and psoriasis. *Arthritis Res Ther* 2013; **15**: R136 [PMID: 24286492]
- 42 **Gerlag DM**, Haringman JJ, Smeets TJ, Zwinderman AH, Kraan MC, Laud PJ, Morgan S, Nash AF, Tak PP. Effects of oral prednisolone on biomarkers in synovial tissue and clinical improvement in rheumatoid arthritis. *Arthritis Rheum* 2004; **50**: 3783-3791 [PMID: 15593225 DOI: 10.1002/art.20664]
- 43 **Haringman JJ**, Gerlag DM, Zwinderman AH, Smeets TJ, Kraan MC, Baeten D, McInnes IB, Bresnihan B, Tak PP. Synovial tissue macrophages: a sensitive biomarker for response to treatment in patients with rheumatoid arthritis. *Ann Rheum Dis* 2005; **64**: 834-838 [PMID: 15576415 DOI: 10.1136/ard.2004.029751]
- 44 **Thurlings RM**, Vos K, Wijbrandts CA, Zwinderman AH, Gerlag DM, Tak PP. Synovial tissue response to rituximab: mechanism of action and identification of biomarkers of response. *Ann Rheum Dis* 2008; **67**: 917-925 [PMID: 17965121]
- 45 **van Kuijk AW**, Gerlag DM, Vos K, Wolbink G, de Groot M, de Rie MA, Zwinderman AH, Dijkman BA, Tak PP. A prospective, randomised, placebo-controlled study to identify biomarkers associated with active treatment in psoriatic arthritis: Effects of adalimumab treatment on synovial tissue. *Ann Rheum Dis* 2009; **68**: 1303-1309 [DOI: 10.1136/ard.2008.091389]
- 46 **Wijbrandts CA**, Vergunst CE, Haringman JJ, Gerlag DM, Smeets TJ, Tak PP. Absence of changes in the number of synovial sublining macrophages after ineffective treatment for



- rheumatoid arthritis: Implications for use of synovial sublining macrophages as a biomarker. *Arthritis Rheum* 2007; **56**: 3869-3871 [PMID: 17968928 DOI: 10.1002/art.22964]
- 47 **Weyand CM**, Klimiuk PA, Goronzy JJ. Heterogeneity of rheumatoid arthritis: from phenotypes to genotypes. *Springer Semin Immunopathol* 1998; **20**: 5-22 [PMID: 9836366]
- 48 **O'Connell JX**. Pathology of the synovium. *AM J Clin Pathol* 2000; **114**: 773-784 [DOI: 10.1309/lww3-5xk0-fkg9-hdrk]
- 49 **Dalbeth N**, Haskard DO. Mechanisms of inflammation in gout. *Rheumatology (Oxford)* 2005; **44**: 1090-1096 [PMID: 15956094 DOI: 10.1093/rheumatology/keh640]
- 50 **Schumacher HR**. Pathology of crystal deposition diseases. *Rheum Dis Clin North Am* 1988; **14**: 269-288 [PMID: 3051152]
- 51 **van der Heijden IM**, Wilbrink B, Vije AE, Schouls LM, Breedveld FC, Tak PP. Detection of bacterial DNA in serial synovial samples obtained during antibiotic treatment from patients with septic arthritis. *Arthritis Rheum* 1999; **42**: 2198-2203 [PMID: 10524694 DOI: 10.1002/1529-0131(199910)42: ]
- 52 **Jaulhac B**, Chary-Valckenaere I, Sibilia J, Javier RM, Piémont Y, Kuntz JL, Monteil H, Pourel J. Detection of *Borrelia burgdorferi* by DNA amplification in synovial tissue samples from patients with Lyme arthritis. *Arthritis Rheum* 1996; **39**: 736-745 [PMID: 8639170 DOI: 10.1002/art.1780390505]

**P- Reviewer:** Fenichel I, Malik MHA **S- Editor:** Song XX  
**L- Editor:** A **E- Editor:** Wu HL



## WJO 5<sup>th</sup> Anniversary Special Issues (2): Ankle

# Power Doppler ultrasonographic assessment of the ankle in patients with inflammatory rheumatic diseases

Takeshi Suzuki

Takeshi Suzuki, Division of Rheumatology, Mitsui Memorial Hospital, Tokyo 101-8643, Japan

Author contributions: Suzuki T was involved in the conception of this topic highlight article, the literature review process, the acquisition of ultrasound images and preparing the manuscript.

Correspondence to: Takeshi Suzuki, MD, Division of Rheumatology, Mitsui Memorial Hospital, 1 Kandaizumi-cho, Chiyoda-ku, Tokyo 101-8643, Japan. [suzuki-rheum@mitsuihosp.or.jp](mailto:suzuki-rheum@mitsuihosp.or.jp)

Telephone: +81-3-38629111 Fax: +81-3-56879765

Received: December 28, 2013 Revised: April 7, 2014

Accepted: May 29, 2014

Published online: November 18, 2014

## Abstract

Ankle involvement is frequent in patients with inflammatory rheumatic diseases, but accurate evaluation by physical examination is often difficult because of the complex anatomical structures of the ankle. Over the last decade, ultrasound (US) has become a practical imaging tool for the assessment of articular and periarticular pathologies, including joint synovitis, tenosynovitis, and enthesitis in rheumatic diseases. Progress in power Doppler (PD) technology has enabled evaluation of the strength of ongoing inflammation. PDUS is very useful for identifying the location and kind of pathologies in rheumatic ankles as well as for distinguishing between inflammatory processes and degenerative changes or between active inflammation and residual damage. The aim of this paper is to illustrate the US assessment of ankle lesions in patients with inflammatory rheumatic diseases, including rheumatoid arthritis, spondyloarthritis, and systemic lupus erythematosus, focusing on the utility of PDUS.

© 2014 Baishideng Publishing Group Inc. All rights reserved.

**Key words:** Ankle; Power Doppler; Ultrasound; Rheumatoid arthritis; Psoriatic arthritis; Spondyloarthritis; Tenosynovitis; Enthesitis

**Core tip:** Over the last decade, ultrasound (US) has become a practical imaging tool for the assessment of articular and periarticular pathologies in rheumatic diseases. Progress in power Doppler (PD) technology has enabled evaluation of the strength of ongoing inflammation. PDUS is useful not only for identifying the pathologies in rheumatic ankles, but also for distinguishing between inflammatory processes and degenerative changes or between active inflammation and residual damage. The aim of this paper is to illustrate the US assessment of ankle lesions in patients with inflammatory rheumatic diseases, including rheumatoid arthritis and spondyloarthritis, focusing on the utility of PDUS.

Suzuki T. Power Doppler ultrasonographic assessment of the ankle in patients with inflammatory rheumatic diseases. *World J Orthop* 2014; 5(5): 574-584 Available from: URL: <http://www.wjgnet.com/2218-5836/full/v5/i5/574.htm> DOI: <http://dx.doi.org/10.5312/wjo.v5.i5.574>

## INTRODUCTION

Many kinds of systemic arthritic diseases affect the ankle. Among them, there are also diseases for which ankle involvement is a hallmark. As the ankle is one of the major weight-bearing joints, it is prone to being affected by injury and/or by degenerative disorders. In the ankles of patients with inflammatory rheumatic diseases, this extrinsic damage commonly coexists, and it is not always easy to distinguish between them.

Anatomical structures in the ankle lie close together and are sometimes overlying, making differentiation between adjacent structures problematic<sup>[1]</sup>. Inflamed synovia are relatively small in size and located relatively deep beneath the skin. Obesity, peripheral edema, and predisposing degenerative conditions such as osteophytes, especially in elderly patients, also impede the detection of

**Table 1 The Outcome measures in rheumatology clinical trials definitions of ultrasound pathological findings**

RA bone erosion	An intra-articular discontinuity of the bone surface that is visible in two perpendicular planes
Synovial fluid	Abnormal hypoechoic or anechoic (relative to subdermal fat, but sometimes may be isoechoic or hyperechoic) intra-articular material that is displaceable and compressible, but does not exhibit a Doppler signal
Synovial hypertrophy	Abnormal hypoechoic (relative to subdermal fat, but sometimes may be isoechoic or hyperechoic) intra-articular tissue that is nondisplaceable and poorly compressible and which may exhibit a Doppler signal
Tenosynovitis	Hypoechoic or anechoic thickened tissue with or without fluid within the tendon sheath, which is seen in two perpendicular planes and which may exhibit a Doppler signal
Enthesopathy	Abnormally hypoechoic (loss of normal fibrillar architecture) and/or thickened tendon or ligament at its bony attachment (may occasionally contain hyperechoic foci consistent with calcification), seen in two perpendicular planes that may exhibit a Doppler signal and/or bony changes, including enthesophytes, erosions, or irregularity

RA: Rheumatoid arthritis.

synovitis.

In this context, a diagnostic imaging technique is important for the evaluation of ankle lesions. However, plain radiography has limited value for the detection of soft tissue changes, and it lacks tissue specificity. Although magnetic resonance (MR) imaging is a high resolution imaging method that can disclose both bone and soft tissue abnormalities, it involves problems such as MR-incompatible metallic implants, patient claustrophobia, accessibility issues, and high cost, all of which prevent it from being widely used for the examination of ankles in rheumatic diseases.

In contrast, ultrasound (US) is a versatile, accurate, safe, and relatively cheap modality that is increasingly used in daily rheumatologic practice. It offers multiplanar evaluation and allows parallel dynamic assessment of multiple target structures, including joints, tendons, ligaments, and bony cortex<sup>[2]</sup>.

In addition to the advantages of grey-scale ultrasound (GSUS), power Doppler (PD) technology has allowed the visualization of the hyperemia of soft tissues in inflammatory articular diseases<sup>[3]</sup>. A comparison of PDUS findings with histopathologic findings of synovial membrane vascularity in rheumatoid arthritis (RA) patients who have undergone knee arthroplasty has shown that PD signals represent abnormal hypervascularity in RA synovial tissue<sup>[4]</sup>. Many reports indicate that the intensity of PD signals in the synovium correlates with the intensity of articular and tenosynovial inflammation in RA patients<sup>[5,6]</sup>. Moreover, PD techniques seem to help differentiate inflammatory enthesitis diseases<sup>[7]</sup>.

The aim of this paper is to illustrate the US assessment of ankle lesions in patients with inflammatory rheumatic diseases, focusing on the utility of PDUS.

## US SCANNING TECHNIQUE FOR THE ANKLE REGION

The important pathologies addressed here are synovial inflammations, including articular synovitis and tenosynovitis, and enthesitis of tendon insertion, including subtendinous bursitis. Structural damage such as bone erosion and tendon degeneration are addressed collaterally and ligament lesions are not mentioned here.

The Outcome Measures in Rheumatology Clinical Trials (OMERACT) US definitions for the most common pathological findings occurring in inflammatory rheumatic diseases are presented in Table 1<sup>[8]</sup>. For detailed information regarding the US machine settings and fundamental scanning techniques, please refer to the relevant published papers<sup>[9]</sup>.

Data regarding the positioning of the patient and anatomical structures to be scanned in the ankle region are presented in Table 2<sup>[10]</sup>. An encompassing scanning technique makes it possible for the examiners not to overlook pathologies, regardless of whether they were symptomatic or asymptomatic<sup>[11,12]</sup>. Utilizing these techniques, we have shown the frequencies of various pathologies in symptomatic ankles with either early or established RA in a previous study (Table 3)<sup>[13]</sup>. This study revealed that ankle tenosynovitis is observed more frequently than ankle synovitis among early RA patients.

## US EVALUATION OF PATHOLOGIES IN ANKLES WITH RHEUMATIC DISEASES

The major inflammatory rheumatic diseases addressed in this paper are RA, psoriatic arthritis (PsA), reactive arthritis (ReA), undifferentiated spondyloarthritis (uSpA), and systemic lupus erythematosus (SLE). US assessment of crystal-associated diseases and degenerative disorders related to aging or trauma will be addressed elsewhere. Multiplanar scanning using both GSUS and PDUS should be carried out. Synovial fluid detected by GSUS and/or hyperemia detected in or adjacent to the synovial membrane by PDUS represents synovitis<sup>[14]</sup>. Although the degree of hyperemia is indicative of the extent of inflammation, hyperemia itself is not specific to a certain disease<sup>[15]</sup>.

Synovial hypertrophy detected by GSUS represents cellular infiltration into synovial tissues with or without synovial cell proliferation. Fine and slow blood flow detected in thickened synovium by PDUS represents proliferative synovitis associated with vascularization, which is a hallmark of the active synovitis observed in RA, PsA, and sometimes SLE<sup>[16]</sup>.

The respective features of the pathologies in inflammatory rheumatic disease depicted in each anatomical

**Table 2 Patient positions for ultrasound examination of ankle structures**

Supine, with flexed knee, foot on the examination bed
Tibiotalar joint: anterior recess
Talonavicular joint
Subtalar joint: lateral and medial recess
Tendon compartments
Anterior:
Tibialis anterior tendon
Extensor hallucis longus tendon
Extensor digitorum longus tendon
Lateral:
Peroneus brevis tendon
Peroneus longus tendon
Medial (frog position):
Tibialis posterior tendon
Flexor digitorum longus tendon
Flexor hallucis longus tendon
Prone, with the foot hanging over the examination bed
Achilles tendon
Superficial and retrocalcaneal bursae
Subtalar joint: posterior recess

**Table 3 The frequencies of various pathologies in the symptomatic ankles with either early or established rheumatoid arthritis**

	Early RA	Established RA	Overall
Number of ankles	62	38	100
Joint synovitis			
Talocrural joint synovitis	32.2%	39.5%	35.0%
Subtalar joint synovitis	30.7%	36.8%	33.0%
Talonavicular joint synovitis	27.4%	26.3%	27.0%
Overall	48.4%	68.4%	56.0%
Tenosynovitis			
Ankle flexors (TP, FDL, FHL)	54.8%	31.6%	46.0%
Peroneal tendons (PB, PL)	33.9%	21.1%	29.0%
Ankle extensors (TA, EHL, EDL)	12.9%	5.3%	10.0%
Overall	69.4%	47.4%	61.0%
Achilles tendon involvement			
Retrocalcaneal bursitis	35.5%	13.2%	27.0%
AT enthesitis	19.4%	26.3%	22.0%
AT tendonitis	12.9%	13.2%	13.0%
AT paratenonitis	8.1%	2.6%	6.0%
Overall	38.7%	39.5%	39.0%

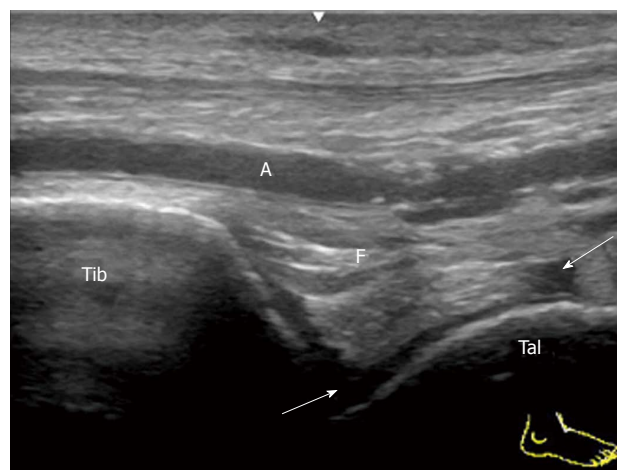
TP: Tibialis posterior; FDL: Flexor digitorum longus; FHL: Flexor hallucis longus; PB: Peroneus brevis; PL: Peroneus longus; TA: Tibialis anterior; EDL: Extensor digitorum longus; EHL: Extensor hallucis longus; AT: Achilles tendon; RA: Rheumatoid arthritis.

structure are addressed below.

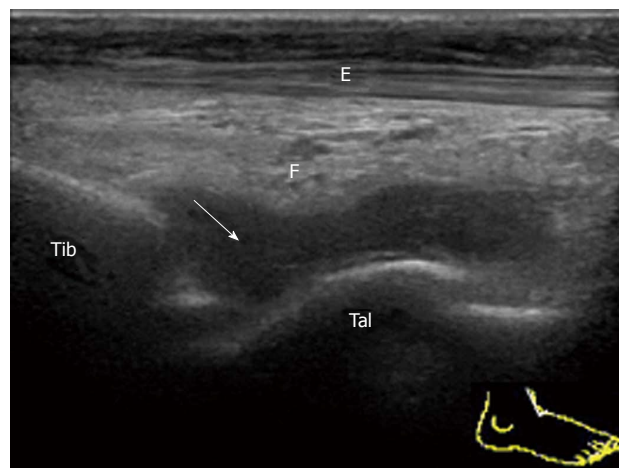
### Tibiotalar joint (talocrural joint)

To visualize the anterior recess of the tibiotalar joint, place the transducer in the sagittal plane distal to the tibia. In the normal joint, a hyperechoic anterior fat pad can be seen to fill the space between the tibia and the talus anteriorly with a layer of anechoic hyaline cartilage on the surface of the talar dome<sup>[17]</sup>.

A small simple effusion in mild acute synovitis of the tibiotalar joint in a patient with reactive arthritis is depicted as an anechoic area (Figure 1). Severe proliferative



**Figure 1 Mild tibiotalar joint synovitis in reactive arthritis.** Sagittal grey-scale sonogram of the anterior recess of the tibiotalar joint shows localized anechoic synovial effusion (arrow). Tib: Tibia; Tal: Talus; F: Fat pad; A: Dorsalis pedis artery.



**Figure 2 Severe tibiotalar joint synovitis in rheumatoid arthritis.** Sagittal grey-scale sonogram of the anterior recess of the tibiotalar joint shows that a normal hyperechoic anterior fat pad (F) is displaced anteriorly by hypoechoic synovium (arrow). Tib: Tibia; Tal: Talus; F: Fat pad; E: Extensor hallucis longus.

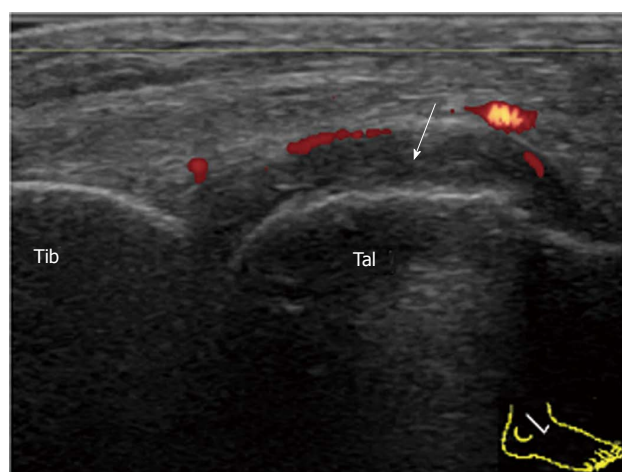
synovitis of the tibiotalar joint in rheumatoid arthritis is depicted as a hypoechoic area over the talar dome (Figure 2). Large effusion and/or proliferative synovium lead to the displacement of the fat pad covering the talus neck and creating capsule distension.

Complex joint fluid can be seen as a hypoechoic area. To distinguish synovium from complex joint fluid, blood flow detected by PD sonography is helpful<sup>[18]</sup>. However, PD sensitivity is relatively low at the median part of the anterior recess because the synovium is located deep beneath the tendons and the fat body. Strong blood flow in the dorsalis pedis artery also hinders the identification of the fine synovial vessels. In order to increase the sensitivity of the PD detection, scanning both lateral and medial sides of the anterior recess must be performed (Figure 3).

### Posterior subtalar joint

The subtalar or talocalcaneal joint is composed of three





**Figure 3 Synovial proliferation in rheumatoid arthritis.** Sagittal power Doppler sonogram of the lateral side of the anterior recess of the tibiotalar joint shows synovial thickening (arrow) with peripheral vascularization. Tib: Tibia; Tal: Talus.

facets: a broad posterior facet representing the primary articulating surface, a medially located middle facet in which the sustentaculum tali articulates with the medial process of the talus, and an anterior facet. There are limited sonographic windows for imaging the subtalar joint (STJ), and the posterior subtalar joint (PSTJ) is usually the target. Synovitis of the PSTJ is best evaluated by scanning its posterior recess. The joint space of the PSTJ is easy to determine in the sagittal view crossing the posterior talar process. In order to fully visualize the posterior recess, which tends to distend laterally, the transducer should be placed just lateral to the Achilles tendon in an anatomic parasagittal plane by medially angling the transducer face (Figure 4). Because synovium is depicted as relatively shallow through this posterolateral window, better detection of the PD signal and a safer route for aspiration are provided<sup>[19]</sup>.

The medial facet of the PSTJ can be partly observed in the coronal view crossing the medial malleolus. In the normal joint, the joint space between the talus and the sustentaculum tali can be depicted beneath the tibiocalcaneal ligament. In the case of synovitis, effusion and/or proliferated synovium stretch cranially along the tibiocalcaneal ligament (Figure 5).

### Talonavicular joint

The talonavicular joint (TNJ) is best evaluated by the longitudinal dorsal view of the joint. In the case of TNJ synovitis in RA patients, proliferated synovium bulges out of the joint space dorsally and the PD signal can be easily detected (Figure 6).

It has been reported that TNJ synovitis is frequently detected by US in both symptomatic and asymptomatic ankles in RA patients<sup>[13]</sup>. Similarly, proliferative synovitis of the TNJ can arise in PsA patients (Figure 7).

It has also been reported that TNJ synovitis is often detected by US in the ankles of healthy control subjects<sup>[20]</sup>. The ankle is one of the sites of predilection for

osteoarthritis. In long-standing RA patients, degenerative changes in the TNJ are frequently encountered (Figure 8). PDUS can add to the information regarding the activity of ongoing inflammation in the joint.

### Extensor tendons

The three tendons in the anterior aspect of the ankle from medial to lateral are the tibialis anterior (TA), extensor hallucis longus (EHL), and extensor digitorum longus (EDL)<sup>[17]</sup>. These extensor tendons pass beneath retinacula and have sheaths to protect them. The main pathology that occurs in inflammatory rheumatic diseases in this area is tenosynovitis. Tenosynovitis of the EDL is most frequently observed, followed by that of the TA. Tenosynovitis of the EHL seems to be less frequent while the myotendinous junction should not be confounded with dilated tenosynovium. These extensor tendons tend to present with serous tenosynovitis rather than proliferative tenosynovitis, unlike the medial flexors and lateral peroneal tendons, which frequently present with proliferative tenosynovitis (Figure 9)<sup>[21]</sup>.

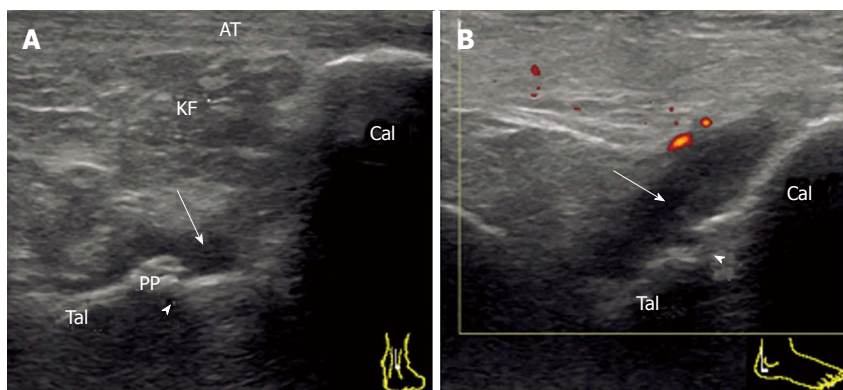
### Medial flexors

By transverse scanning of the medial ankle tendons, the tibialis posterior (TP) tendon, flexor digitorum longus (FDL) tendon, and flexor hallucis longus (FHL) tendon can be visualized from the anterior to the posterior side<sup>[22]</sup>.

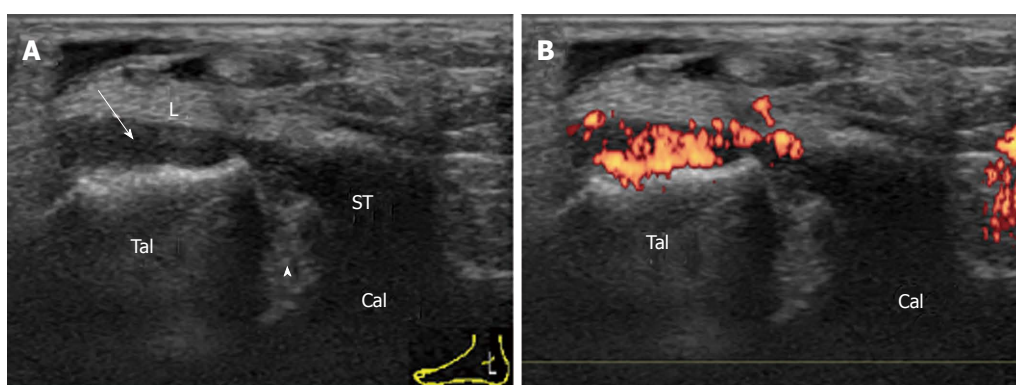
As the TP and FDL hook around the medial malleolus and the FHL runs in a groove along the calcaneus, all tendons have individual sheaths. Tenosynovitis frequently occurs in this area in inflammatory rheumatic diseases. Tenosynovitis of TP is most frequently observed, and is sometimes accompanied by FDL tenosynovitis (Figure 10). Pathology usually occurs at or distal to the medial malleolus. Fluid collection within the synovial sheath is predominantly observed near the distal end of the sheath, while small effusion often exists at the same site in the ankles of healthy subjects. Proliferative tenosynovitis of TP is frequently observed in RA patients<sup>[21]</sup>. Thickening and hyperemia of the sheath with or without fluid in it are the typical features. It has been reported that tenosynovitis is observed more frequently than joint synovitis in symptomatic ankles with early RA<sup>[13]</sup>.

The second site of pathology on the TP is where it inserts into the navicular bone. A longitudinal scan is more informative in proximity to its insertion. An important active inflammatory pathology in rheumatic diseases at tendon insertion is enthesitis. Enthesitis frequently occurs in patients with SpA (Figure 11A). The distal end of a normal TP tendon splays at the insertion and may appear hypoechoic due to anisotropy. Therefore, the presence of intratendinous hyperemia permits a more confident diagnosis of enthesitis.

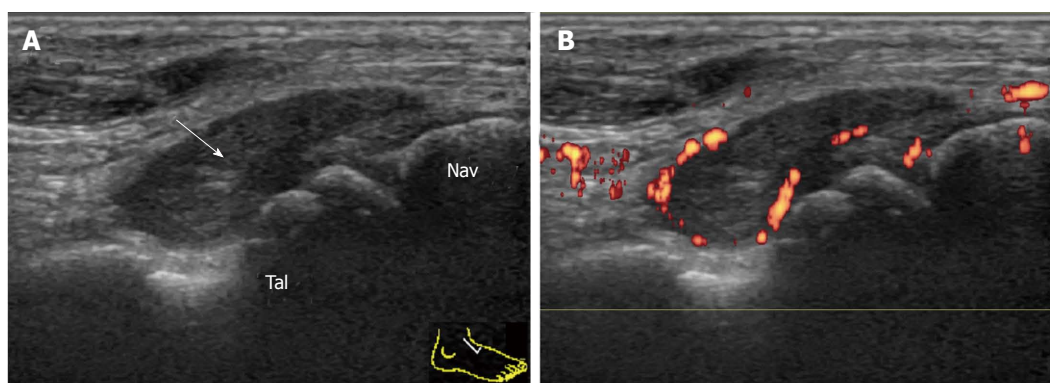
Although enthesitis is the hallmark of PsA, ankle tenosynovitis is also often observed in PsA patients. In some cases, the implication of enthesitis in a functional enthesis formed by fibrocartilage on the surface of bone



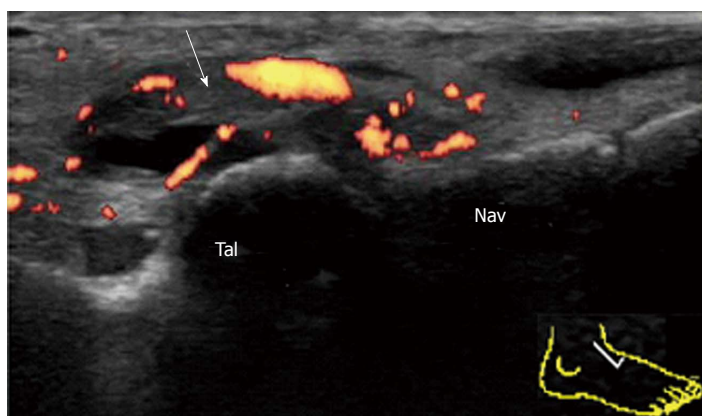
**Figure 4 Synovitis of the posterior subtalar joint in rheumatoid arthritis.** A: Sagittal grey-scale sonogram crossing the posterior talar process shows the edge of the distended posterior recess (arrow) of the PSTJ. B: Posterolateral view of the power Doppler sonogram fully depicting the distended posterior recess (arrow) of the PSTJ. Note the close relation of this recess with the superior margin of the calcaneus (Cal). Tib: Tibia; Tal: Talus; KF: Kager's fat pad; AT: Achilles tendon, arrowhead (joint space); PSTJ: Posterior subtalar joint; PP: Posterior talar process.



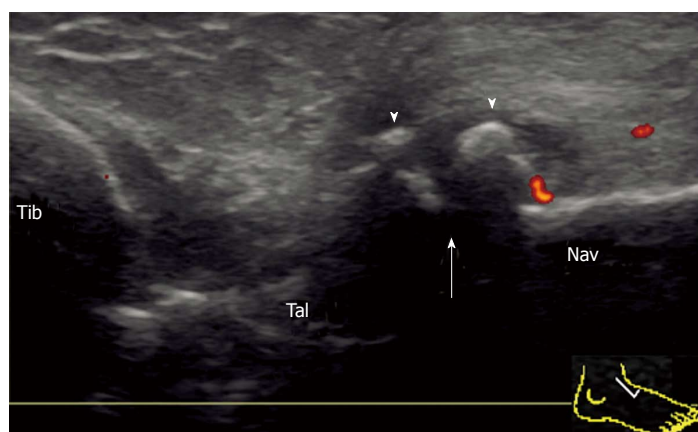
**Figure 5 Synovitis of the posterior subtalar joint in rheumatoid arthritis.** Coronal grey-scale (A) and power Doppler (B) sonogram of the medial facet (arrowhead) of the PSTJ. PD-signal-positive proliferated synovium (arrow) of the PSTJ stretches cranially along the tibio calcaneal ligament (L). Tal: Talus; Cal: Calcaneus; ST: Sustentaculum tali; PSTJ: Posterior subtalar joint.



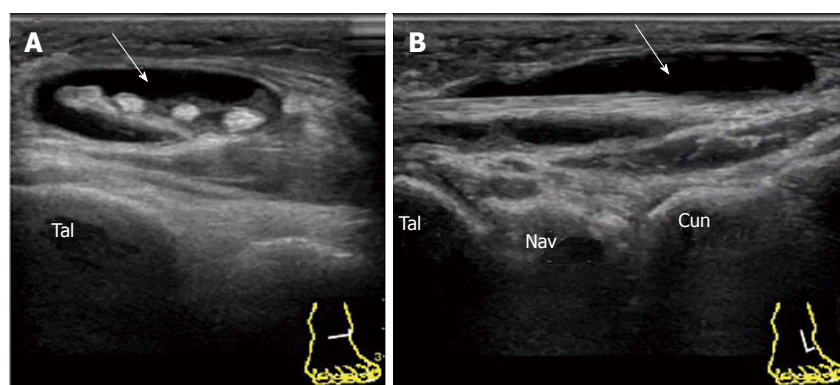
**Figure 6 Synovitis of the talonavicular joint in rheumatoid arthritis.** Longitudinal grey-scale (A) and power Doppler (B) sonogram of the dorsal aspect of the TNJ shows marked synovial thickening (arrow) with peripheral vascularization. Tal: Talus; Nav: Navicular; TNJ: Talonavicular joint.



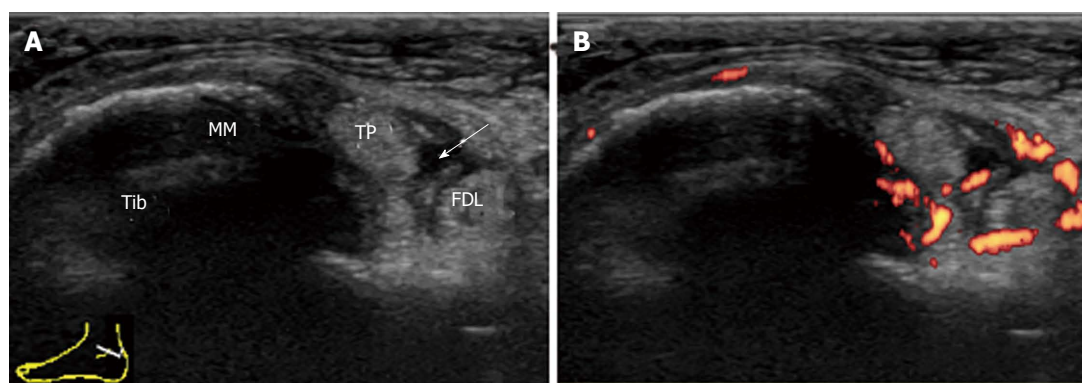
**Figure 7 Synovitis of the talonavicular joint in psoriatic arthritis.** Longitudinal power Doppler sonogram of the dorsal aspect of the TNJ shows synovial effusion and marked synovial thickening (arrow) with peripheral vascularization. TNJ: Talonavicular joint; Tal: Talus; Nav: navicular.



**Figure 8 Deformity of the talonavicular joint in rheumatoid arthritis.** Longitudinal power Doppler sonogram of the dorsal aspect of the TNJ shows joint space narrowing (arrow) and osteophyte formation (arrowhead) with minimum flow signal adjacent to an osteophyte. TNJ: Talonavicular joint; Tib: Tibia; Tal: Talus; Nav: Navicular.



**Figure 9 Serous tenosynovitis of the extensor digitorum longus in rheumatoid arthritis.** Transverse (A) and longitudinal (B) grey-scale sonogram of the dorsal aspect of the EDL shows marked expansion of the tendon sheath with anechoic synovial effusion (arrow). Tal: Talus; Nav: Navicular; Cun: Cuneiform; EDL: Extensor digitorum longus.



**Figure 10 Proliferative tenosynovitis of the tibialis posterior in rheumatoid arthritis.** A: Transverse grey-scale sonogram through the medial ankle at the level of the medial malleolus (MM). Hypoechoic thickened tenosynovium of the TP with anechoic effusion (arrow) within the sheath is depicted; B: Power Doppler sonogram shows hyperemia of the tenosynovium surrounding the TP and the FDL. Tib: Tibia; TP: Tibialis posterior; MM: Medial malleolus; FDL: Flexor digitorum longus.

and tendon is suggested (Figure 11B)<sup>[23]</sup>.

Periarticular involvement is an important characteristic of musculoskeletal manifestation in SLE patients<sup>[24]</sup>. In particular, tendinopathies including tendonitis, tenosynovitis and tendon rupture are thought to be common. Although there have only been a few reports about the sonographic feature of tenosynovitis only in hands or wrists with SLE, ankle tendinopathies do not seem to be rare (Figure 12). The appearance of tenosynovitis or enthesitis, however, seems to be unspecific.

### Peroneal tendons

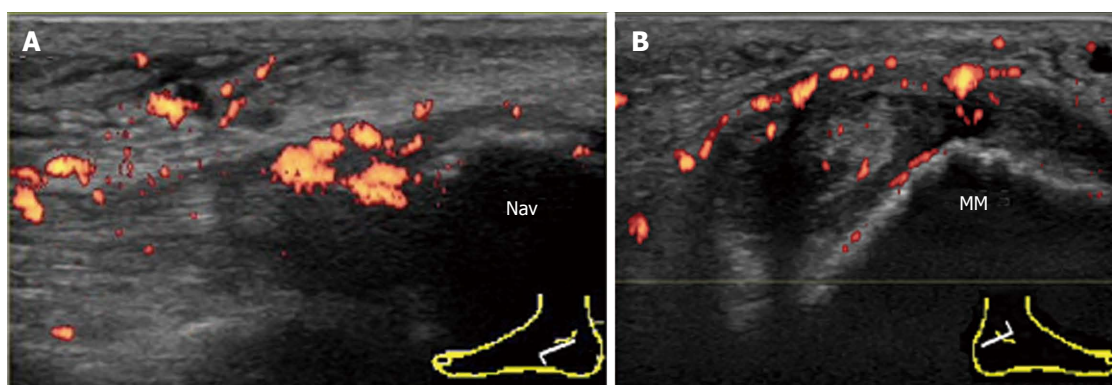
The lateral ankle tendons are the peroneus longus and

brevis. They hook behind the retromalleolar sulcus of the fibula and are stabilized by the superior peroneal retinaculum. At the level of the lateral malleolus, the peroneus longus and brevis share a common sheath. Distal to the lateral malleolus, the peroneals diverge<sup>[22]</sup>.

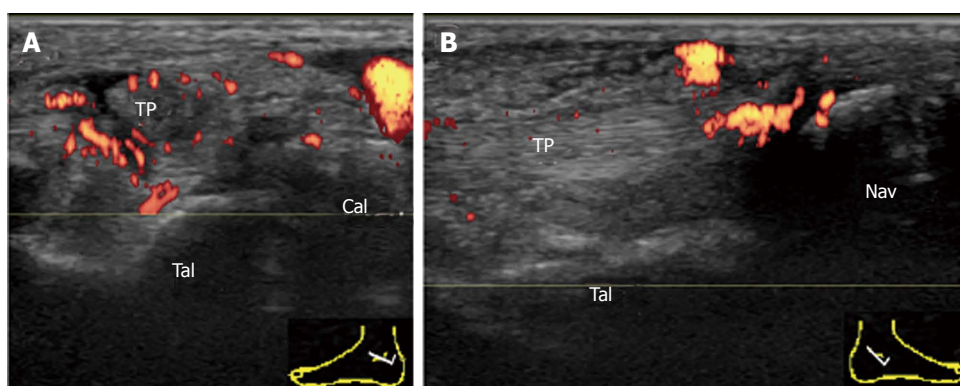
Pathology usually occurs at or distal to the lateral malleolus (Figure 13). Tenosynovitis of peroneus longus and brevis can occur either independently or concurrently. Proliferative tenosynovitis of peroneal tendons and TP is frequently observed in RA patients<sup>[21]</sup>. Thickening and hyperemia of the sheath with or without fluid in it are sonographic findings suggestive of active inflammation.

In addition to TP, enthesitis of PB at its insertion into

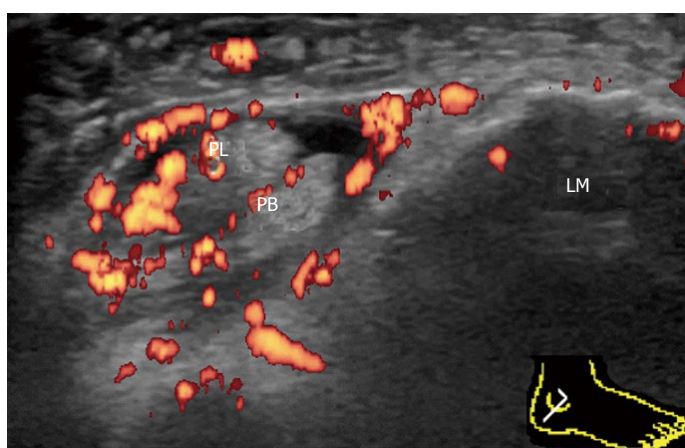



**Figure 11 Involvement of the tibialis posterior tendon in psoriatic arthritis.** A: Enthesitis of the TP at the navicular insertion in psoriatic arthritis. Longitudinal power Doppler sonogram of TP shows intratendinous hypoechoic change and loss of the fibrillar echoes with hyperemia adjacent to the insertion into the navicular bone. Cortical irregularities of the navicular bone at the insertion are also depicted; B: Tenosynovitis of the contralateral TP in the same patient. Transverse power Doppler sonogram at the level of the tip of the medial malleolus shows thickening and hyperemia of both the tendon sheath and the flexor retinaculum. Cortical irregularities of the medial malleolus are also depicted. Nav: Navicular bone; MM: Medial malleolus; TP: Tibialis posterior.



**Figure 12 Involvement of the tibialis posterior tendon in systemic lupus erythematosus.** A: Tenosynovitis of the TP in systemic lupus erythematosus. Transverse power Doppler sonogram over the inframalleolar area shows thickening and hyperemia of the tendon sheath with small synovial effusion; B: Enthesitis of the contralateral TP in the same patient. Longitudinal power Doppler sonogram of the TP shows intratendinous hyperemia adjacent to the insertion into the navicular bone. Tal: Talus; Cal: Calcaneus; TP: Tibialis posterior; Nav: Navicular bone.



**Figure 13 Proliferative tenosynovitis of the peroneus longus and brevis in rheumatoid arthritis.** Transverse power Doppler sonogram through the lateral ankle at the level of the lateral malleolus shows thickening and marked hyperemia of the tenosynovium surrounding the peroneus longus and peroneus brevis. PL: Peroneus longus; PB: Peroneus brevis; LM: Lateral malleolus.

the base of the fifth metatarsal is frequently observed in PsA patients (Figure 14A). Tenosynovitis of peroneal tendons is also commonly observed in PsA patients (Figure 14B).

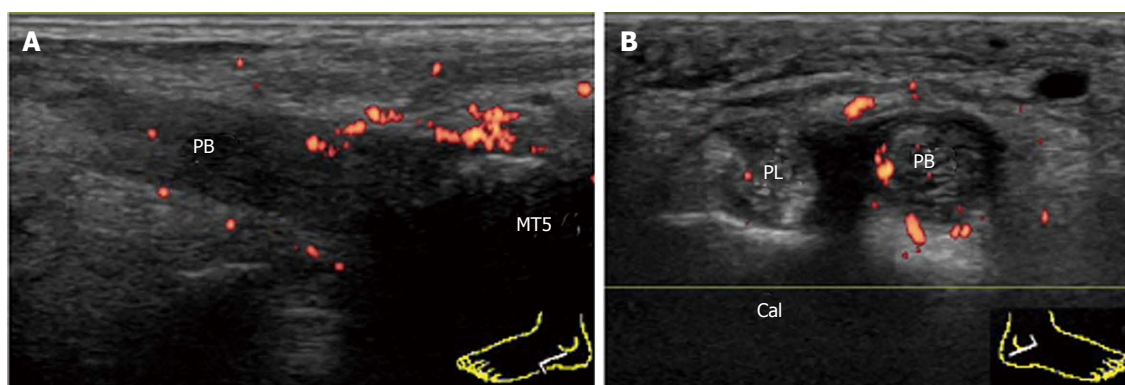
### Achilles tendon

The Achilles tendon is a typical tendon with a linear fi-

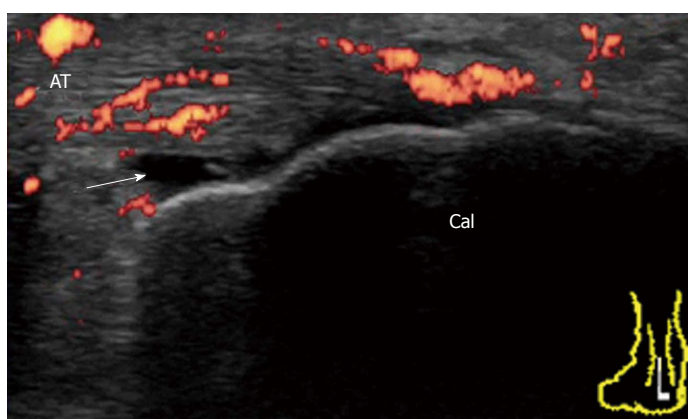
brillar pattern. It inserts into a relatively small footprint on the posterosuperior aspect of the calcaneus. Between the calcaneus and the Achilles tendon there is a retrocalcaneal bursa. A normal bursa is thin walled and contains only minimal fluid<sup>[25]</sup>.

Achilles tendon enthesopathy is a common finding in SpA, and can be present in both symptomatic and as-

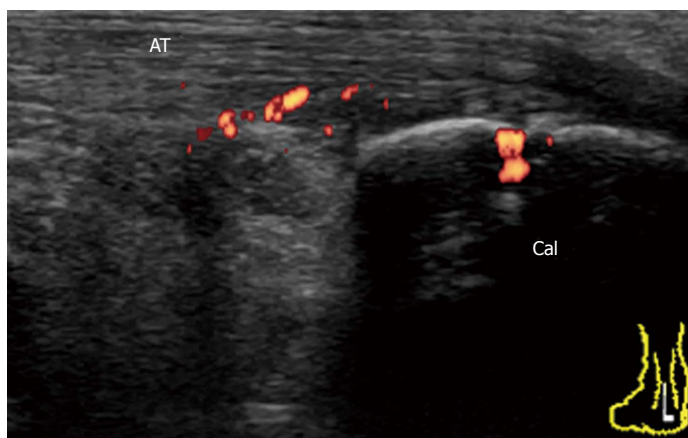




**Figure 14** Involvement of peroneal brevis tendon in psoriatic arthritis. A: Enthesitis of the PB in psoriatic arthritis. Longitudinal power Doppler sonogram of the PB shows intratendinous hypoechoic change and loss of the fibrillar echoes with hyperemia adjacent to the insertion into the base of MT5. Cortical irregularities of the bone at the insertion are also depicted; B: Tenosynovitis of the contralateral PB in the same patient. Transverse power Doppler sonogram at the level of the peroneal tubercle of the Cal shows thickening and hyperemia of the PB tendon sheath. PL: Peroneus longus; PB: Peroneus brevis; MT5: The fifth metatarsal bone; Cal: Calcaneus.



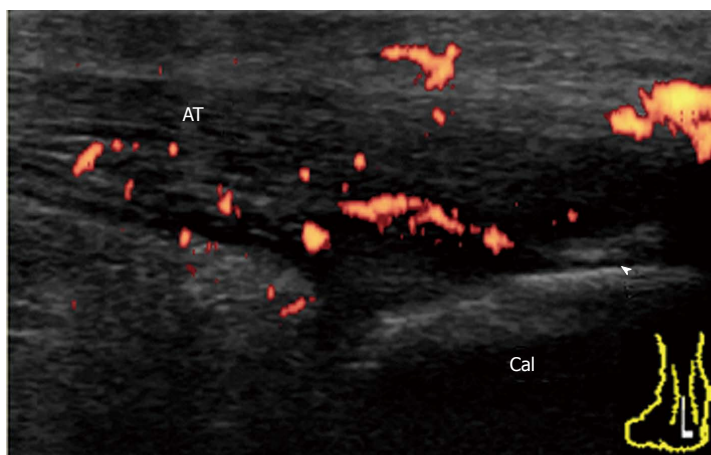
**Figure 15** Achilles tendon enthesitis in reactive arthritis. Longitudinal power Doppler sonogram of the AT shows enthesial and intratendinous hyperemia and a small amount of fluid in retrocalcaneal bursa (arrow) with minimal cortical irregularities and tendinosis. Cal: Calcaneus; AT: Achilles tendon.



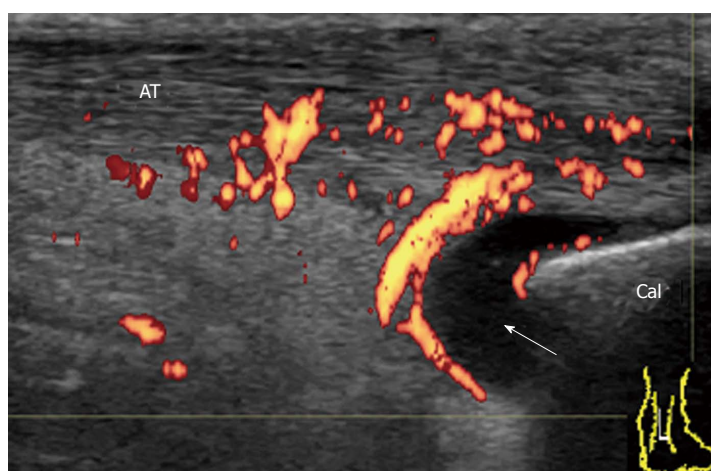
**Figure 16** Achilles tendon enthesitis in early undifferentiated spondyloarthritis. Longitudinal power Doppler sonogram of the AT shows abnormal vascularization at the enthesis insertion into the calcaneal bone with minimal tendinosis. Cal: Calcaneus; AT: Achilles tendon.

ymptomatic patients<sup>[7]</sup>. In the OMERACT definition (Table 1), acute and chronic inflammatory aspects in gray-scale US (*i.e.*, loss of normal echo structure, increased thickness, or focal calcific deposits) and Doppler US are combined with findings of structural damage (*i.e.*, enthesophytes and bony erosions). This combination may be helpful for diagnostic purposes (*i.e.*, presence or absence of enthesis involvement) but probably not for responsiveness or for the differential diagnosis of inflammatory diseases (*i.e.*, SpA or RA versus mechanical or metabolic

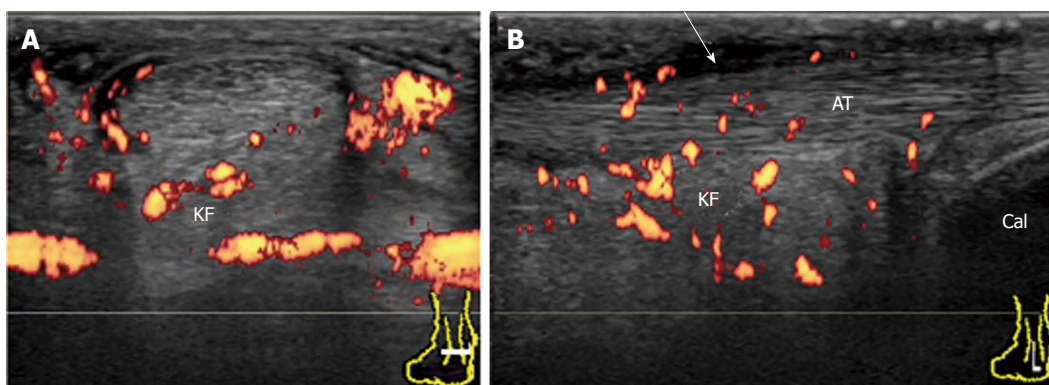
entheseal involvement). Enthesitis rather than enthesopathy is important to evaluate in inflammatory rheumatic diseases. For defining enthesitis, a Doppler signal should be detected at the cortical enthesis insertion and should be differentiated from a reflecting surface artifact or nutrition vessel signal<sup>[7]</sup>. A Doppler signal may be detected even in the absence of either bone changes (cortical irregularities, erosions, or enthesophytes) or tendon degeneration (tendinosis, tendon erosions and tears). For example, ReA patients with subacute enthesitis together with enthesial and intraten-



**Figure 17 Achilles tendon enthesitis in chronic active psoriatic arthritis.** Longitudinal power Doppler sonogram of AT shows increased thickness, hypoechogenicity, and loss of fibrillar pattern of AT with intratendinous hyperemia adjacent to the enthesis insertion into the calcaneal bone. Calcification (arrowhead) is also depicted. Cal: Calcaneus; AT: Achilles tendon.



**Figure 18 Retrocalcaneal bursitis in rheumatoid arthritis.** Longitudinal power Doppler sonogram of the AT shows distended retrocalcaneal bursa (arrow) associated with peribursal hyperemia. Increased thickness of the AT with intratendinous hyperemia adjacent to the bursa is also depicted. Cal: Calcaneus; AT: Achilles tendon.



**Figure 19 Achilles paratenonitis in early rheumatoid arthritis.** Transverse (A) and longitudinal (B) power Doppler sonogram of the AT shows thickened, hypoechoic, and hyperemic paratenon (arrow) at the level of the KF with minimal tendinopathy. Hyperemia in the KF is also depicted. AT: Achilles tendon; KF: Kager's fat pad; Cal: Calcaneus.

dinous hyperemia and a small amount of fluid in retrocalcaneal bursa with minimal structural damage (Figure 15).

It has been suggested that inflammation at the bursal part of the fibrocartilage is important for the pathogenesis of enthesitis in SpA patients<sup>[26]</sup>. Bone erosion that is cranially adjacent to the insertion is characteristic of enthesitis in SpA. In early undifferentiated SpA patients, a Doppler signal at the enthesis insertion that is associated with cortical erosion can be observed with minimal tendinosis (Figure 16). In chronic active enthesitis, increased thickness, hypoechogenicity, and loss of fibrillar pattern

of the Achilles tendon are associated with abnormal vascularization at the enthesis insertion with bone changes (Figure 17). Enthesitis is also often observed among RA patients. It has been suggested that retrocalcaneal bursa is primarily involved in the rheumatoid enthesitis symptom (Figure 18)<sup>[7]</sup>.

The Achilles tendon does not have a tendon sheath. Instead, it has a U-shaped paratenon wrapping around the tendon from its dorsal aspect, which is normally barely visible. Achilles paratenonitis is inflammation in the paratenon and can occur in isolation or in association

with tendinopathy. The paratenon becomes thickened, hypoechoic and hyperemic in the case of paratenonitis (Figure 19). Achilles paratenonitis is sometimes observed among RA patients, especially in the early stage of disease<sup>[13]</sup>.

## CONCLUSION

US is useful for identifying the location and kind of pathologies in rheumatic ankles. Furthermore, PDUS is useful for distinguishing between inflammatory processes and degenerative changes or between active inflammation and residual damage. PDUS is of vital use in the assessment of ankles in patients with inflammatory rheumatic diseases in daily practice.

## REFERENCES

- Wakefield RJ, Freeston JE, O'Connor P, Reay N, Budgen A, Hensor EM, Helliwell PS, Emery P, Woodburn J. The optimal assessment of the rheumatoid arthritis hindfoot: a comparative study of clinical examination, ultrasound and high field MRI. *Ann Rheum Dis* 2008; **67**: 1678-1682 [PMID: 18258710 DOI: 10.1136/ard.2007.079947]
- Szkudlarek M, Narvestad E, Klarlund M, Court-Payen M, Thomsen HS, Østergaard M. Ultrasonography of the metatarsophalangeal joints in rheumatoid arthritis: comparison with magnetic resonance imaging, conventional radiography, and clinical examination. *Arthritis Rheum* 2004; **50**: 2103-2112 [PMID: 15248207 DOI: 10.1002/art.20333]
- Schmidt WA, Völker L, Zacher J, Schläfke M, Ruhnke M, Gromnica-Ihle E. Colour Doppler ultrasonography to detect pannus in knee joint synovitis. *Clin Exp Rheumatol* 2000; **18**: 439-444 [PMID: 10949717]
- Walther M, Harms H, Krenn V, Radke S, Faehndrich TP, Gohlke F. Correlation of power Doppler sonography with vascularity of the synovial tissue of the knee joint in patients with osteoarthritis and rheumatoid arthritis. *Arthritis Rheum* 2001; **44**: 331-338 [PMID: 11229463 DOI: 10.1002/1529-0131(200102)44]
- Wakefield RJ, Brown AK, O'Connor PJ, Emery P. Power Doppler sonography: improving disease activity assessment in inflammatory musculoskeletal disease. *Arthritis Rheum* 2003; **48**: 285-288 [PMID: 12571834 DOI: 10.1002/art.10818]
- Hammer HB, Kvien TK. Ultrasonography shows significant improvement in wrist and ankle tenosynovitis in rheumatoid arthritis patients treated with adalimumab. *Scand J Rheumatol* 2011; **40**: 178-182 [PMID: 21091275 DOI: 10.3109/03009742.2010.517549]
- D'Agostino MA, Said-Nahal R, Hacquard-Bouder C, Brasseur JL, Dougados M, Breban M. Assessment of peripheral enthesitis in the spondylarthropathies by ultrasonography combined with power Doppler: a cross-sectional study. *Arthritis Rheum* 2003; **48**: 523-533 [PMID: 12571863 DOI: 10.1002/art.10812]
- Wakefield RJ, Balint PV, Szkudlarek M, Filippucci E, Backhaus M, D'Agostino MA, Sanchez EN, Iagnocco A, Schmidt WA, Bruyn GA, Kane D, O'Connor PJ, Manger B, Joshua F, Koski J, Grassi W, Lassere MN, Swen N, Kainberger F, Klauser A, Østergaard M, Brown AK, Machold KP, Conaghan PG. Musculoskeletal ultrasound including definitions for ultrasonographic pathology. *J Rheumatol* 2005; **32**: 2485-2487 [PMID: 16331793]
- Torp-Pedersen ST, Terslev L. Settings and artefacts relevant in colour/power Doppler ultrasound in rheumatology. *Ann Rheum Dis* 2008; **67**: 143-149 [PMID: 18055471 DOI: 10.1136/ard.2007.078451]
- Micu MC, Nestorova R, Petranova T, Porta F, Radunovic G, Vlad V, Iagnocco A. Ultrasound of the ankle and foot in rheumatology. *Med Ultrason* 2012; **14**: 34-41 [PMID: 22396937]
- Naredo E, Valor L, De la Torre I, Martínez-Barrio J, Hinojosa M, Aramburu F, Ovalles-Bonilla JG, Hernández D, Montoro M, González CM, López-Longo J, Monteagudo I, Carreño L. Ultrasound joint inflammation in rheumatoid arthritis in clinical remission: how many and which joints should be assessed? *Arthritis Care Res (Hoboken)* 2013; **65**: 512-517 [PMID: 23044729 DOI: 10.1002/acr.21869]
- Freeston JE, Coates LC, Nam JL, Moverley AR, Hensor EM, Wakefield RJ, Emery P, Helliwell PS, Conaghan PG. Is there subclinical synovitis in early psoriatic arthritis? A clinical comparison with gray-scale and power Doppler ultrasound. *Arthritis Care Res (Hoboken)* 2014; **66**: 432-439 [PMID: 24022986 DOI: 10.1002/acr.22158]
- Suzuki T, Okamoto A. Ultrasound examination of symptomatic ankles in shorter-duration rheumatoid arthritis patients often reveals tenosynovitis. *Clin Exp Rheumatol* 2013; **31**: 281-284 [PMID: 23295158]
- Brown AK, Wakefield RJ, Conaghan PG, Karim Z, O'Connor PJ, Emery P. New approaches to imaging early inflammatory arthritis. *Clin Exp Rheumatol* 2004; **22**: S18-S25 [PMID: 15552510]
- Hau M, Kneitz C, Tony HP, Keberle M, Jahns R, Jenett M. High resolution ultrasound detects a decrease in pannus vascularisation of small finger joints in patients with rheumatoid arthritis receiving treatment with soluble tumour necrosis factor alpha receptor (etanercept). *Ann Rheum Dis* 2002; **61**: 55-58 [PMID: 11779760]
- Hau M, Schultz H, Tony HP, Keberle M, Jahns R, Haerten R, Jenett M. Evaluation of pannus and vascularization of the metacarpophalangeal and proximal interphalangeal joints in rheumatoid arthritis by high-resolution ultrasound (multidimensional linear array). *Arthritis Rheum* 1999; **42**: 2303-2308 [PMID: 10555024 DOI: 10.1002/1529-0131(199911)42]
- Fessell DP, Jamadar DA, Jacobson JA, Caoili EM, Dong Q, Pai SS, van H, Marnix T. Sonography of Dorsal Ankle and Foot Abnormalities. *Am J Roentgenol* 2003; **181**: 1573-1581 [DOI: 10.2214/ajr.181.6.1811573]
- Newman JS, Adler RS, Bude RO, Rubin JM. Detection of soft-tissue hyperemia: value of power Doppler sonography. *AJR Am J Roentgenol* 1994; **163**: 385-389 [PMID: 8037037 DOI: 10.2214/ajr.163.2.8037037]
- Smith J, Finnoff JT, Henning PT, Turner NS. Accuracy of sonographically guided posterior subtalar joint injections: comparison of 3 techniques. *J Ultrasound Med* 2009; **28**: 1549-1557 [PMID: 19854970]
- Sant'Ana Petterle G, Natour J, Rodrigues da Luz K, Soares Machado F, dos Santos MF, da Rocha Correa Fernandes A, Vilar Furtado RN. Usefulness of US to show subclinical joint abnormalities in asymptomatic feet of RA patients compared to healthy controls. *Clin Exp Rheumatol* 2013; **31**: 904-912 [PMID: 24021273]
- Suzuki T, Tohda E, Ishihara K. Power Doppler ultrasonography of symptomatic rheumatoid arthritis ankles revealed a positive association between tenosynovitis and rheumatoid factor. *Mod Rheumatol* 2009; **19**: 235-244 [PMID: 19214653 DOI: 10.1007/s10165-009-0150-8]
- De Maeseneer M, Marcelis S, Jager T, Shahabpour M, Van Roy P, Weaver J, Jacobson JA. Sonography of the normal ankle: a target approach using skeletal reference points. *AJR Am J Roentgenol* 2009; **192**: 487-495 [PMID: 19155415 DOI: 10.2214/AJR.08.1316]
- Benjamin M, McGonagle D. The anatomical basis for disease localisation in seronegative spondyloarthropathy at entheses and related sites. *J Anat* 2001; **199**: 503-526 [PMID: 11760883]
- Grossman JM. Lupus arthritis. *Best Pract Res Clin Rheumatol* 2009; **23**: 495-506 [PMID: 19591780 DOI: 10.1016/j.berh.2009.04.003]

- 25 **Riente L**, Delle Sedie A, Iagnocco A, Filippucci E, Meenagh G, Valesini G, Grassi W, Bombardieri S. Ultrasound imaging for the rheumatologist V. Ultrasonography of the ankle and foot. *Clin Exp Rheumatol* 2006; **24**: 493-498 [PMID: 17181916]
- 26 **Balint PV**, Kane D, Wilson H, McInnes IB, Sturrock RD. Ultrasonography of enthesal insertions in the lower limb in spondyloarthropathy. *Ann Rheum Dis* 2002; **61**: 905-910 [PMID: 12228161]

P- Reviewer: Azzoni R S- Editor: Ji FF L- Editor: A  
E- Editor: Wu HL







## WJO 5<sup>th</sup> Anniversary Special Issues (3): Foot

# Worldwide spread of the Ponseti method for clubfoot

Lior Shabtai, Stacy C Specht, John E Herzenberg

Lior Shabtai, Stacy C Specht, John E Herzenberg, International Center for Limb Lengthening, Rubin Institute for Advanced Orthopedics, Sinai Hospital, Baltimore, MD 21215, United States  
Author contributions: Shabtai L, Specht SC and Herzenberg JE solely contributed to this paper.

Correspondence to: John E Herzenberg, MD, FRCSC, International Center for Limb Lengthening, Rubin Institute for Advanced Orthopedics, Sinai Hospital, 2401 West Belvedere Avenue, Baltimore, MD 21215, United States. [jherzenberg@lifebridgehealth.org](mailto:jherzenberg@lifebridgehealth.org)

Telephone: +1-410-6010894 Fax: +1-410-6019575

Received: January 8, 2014 Revised: April 10, 2014

Accepted: July 18, 2014

Published online: November 18, 2014

## Abstract

The Ponseti method has become the gold standard for the treatment of idiopathic clubfoot. Its safety and efficacy has been demonstrated extensively in the literature, leading to increased use around the world over the last two decades. This has been demonstrated by the increase in Ponseti related PubMed publications from many countries. We found evidence of Ponseti activity in 113 of 193 United Nations members. The contribution of many organizations which provide resources to healthcare practitioners in low and middle income countries, as well as Ponseti champions and modern communication technology, have helped to spread the Ponseti method around the world. Despite this, there are many countries where the Ponseti method is not being used, as well as many large countries in which the extent of activity is unknown. With its low rate of complication, low cost, and high effectiveness, this method has unlimited potential to treat clubfoot in both developed and undeveloped countries. Our listing of countries who have not yet shown presence of Ponseti activity will help non-governmental organizations to target those countries which still need the most help.

© 2014 Baishideng Publishing Group Inc. All rights reserved.

**Key words:** Ponseti; Clubfoot; World; Organization;

## Children

**Core tip:** The Ponseti method has become the gold standard for the treatment of idiopathic clubfoot. With its low rate of complication, low cost, and high effectiveness, this method has unlimited potential to treat clubfoot in both developed and undeveloped countries. Our listing of countries who have not yet shown presence of Ponseti activity will help organizations to target those countries which still need the most help.

Shabtai L, Specht SC, Herzenberg JE. Worldwide spread of the Ponseti method for clubfoot. *World J Orthop* 2014; 5(5): 585-590  
Available from: URL: <http://www.wjgnet.com/2218-5836/full/v5/i5/585.htm> DOI: <http://dx.doi.org/10.5312/wjo.v5.i5.585>

## INTRODUCTION

Ponseti developed his method for the conservative treatment of clubfoot at the University of Iowa in the 1950's, but it remained largely confined to Iowa until around 1997. It has since spread widely around the world.

Clubfoot (CF) is a common congenital deformity affecting approximately 1-2 per 1000 live births. The traditional treatment of congenital clubfoot has been mainly performed through complex surgical release procedures<sup>[1,2]</sup>. Common complications related to this extensive surgery included recurrence of the deformity, overcorrection, long-term joint stiffness, and pain<sup>[3,4]</sup>. The disappointing long term results inspired some to seek out less invasive, more conservative treatments typified by the Ponseti method, which involves serial casting and percutaneous Achilles tenotomy of the affected feet followed by bracing to maintain the correction.

Today, this method has become the de facto gold standard for the initial treatment of clubfoot. Its safety and efficacy has been demonstrated extensively in the literature<sup>[5-14]</sup>.

We performed a systematic review to determine the

**Table 1 Ponseti method journal articles and abstracts published between 1972 and 10/31/2013: Countries of origin (41)**

Albania	Malawi
Australia	Mexico
Austria	Nepal
Bangladesh	New Zealand
Belgium	Norway
Bosnia and Herzegovina	Pakistan
Brazil	Poland
Canada	Portugal
China	Romania
Czech Republic	Russian Federation
Egypt	Saudi Arabia
France	Spain
Germany	Sudan
India	Sweden
Iran	Taiwan
Ireland	Tunisia
Israel	Turkey
Italy	Uganda
Japan	United Kingdom
South Korea	United States
Kuwait	

exact penetration of the Ponseti method worldwide, and to examine the factors that lead to this spread. The additional goal of this study is to determine which countries are currently not using the Ponseti method, in order to help agencies such as Ponseti International and Miracle Feet to target new countries for expansion.

## LITERATURE SEARCH

The following databases were used for this search through October 31, 2013: The United States National Library of Medicine National Institutes of Health (PubMed), the Cochrane Library and the Excerpta Medica Database (EMBASE). We used “Ponseti” and “Ponseti method clubfoot” as key words in our search. We included publications in all languages where an English abstract was available. We used Google scholar to search for abstracts presented at various conferences such as the “5<sup>th</sup> and 6<sup>th</sup> International clubfoot congress”. Additionally, we searched in the web sites of “Ponseti International”, “Global Clubfoot Initiative”, “Miraclefeet” and “Cure Clubfoot” to determine which countries are using the method, though have not yet published their results<sup>[15-18]</sup> (Table 1). Additionally, “Ponseti method” and each of the 193 United Nations (UN) acknowledged countries were used as search words in Google to ensure that our information was as complete as possible.

Our results were separated into 2 categories: (1) Countries practicing the Ponseti method who have published results, in either paper or abstract form; and (2) Countries who demonstrate evidence of using the Ponseti method, though without publication of results.

Published articles were then categorized by number, year, and region.

Although the 193 members of the UN represent the vast majority of countries in the world, independent

countries such as Vatican City and Kosovo are not included. For the purpose of this review, we included only those 193 countries recognized by the UN.

## RESEARCH

We found more than 265 published papers discussing the Ponseti method for the treatment of clubfoot from 1950 until October 31, 2013. These papers originated from only 34 of the 193 UN countries using PubMed, the Cochrane Library and EMBASE. There were an additional 7 countries with abstracts from the 5<sup>th</sup> and 6<sup>th</sup> International Clubfoot congress (Table 1), and another 72 countries, so called, “low and middle income countries in which there was evidence of activity according to the “Ponseti International”, “Global Clubfoot Initiative”, “Miraclefeet” and “Cure Clubfoot” association websites. In these cases, we relied on confirmation from colleagues who are leaders in the dissemination of the Ponseti method globally.

With this evidence, we conclude that a total of 113 countries are currently using the Ponseti Method clinically. We further categorized those countries with published papers according to when the treatment occurred. These four epochs include; up to 2000, from 2001 to 2005, from 2006 to 2010 and after 2011 (Figure 1).

The number of publications across a wide variety of countries in PubMed has increased significantly over the past two decades suggesting an increase in those who are trained and using the method (Figure 2).

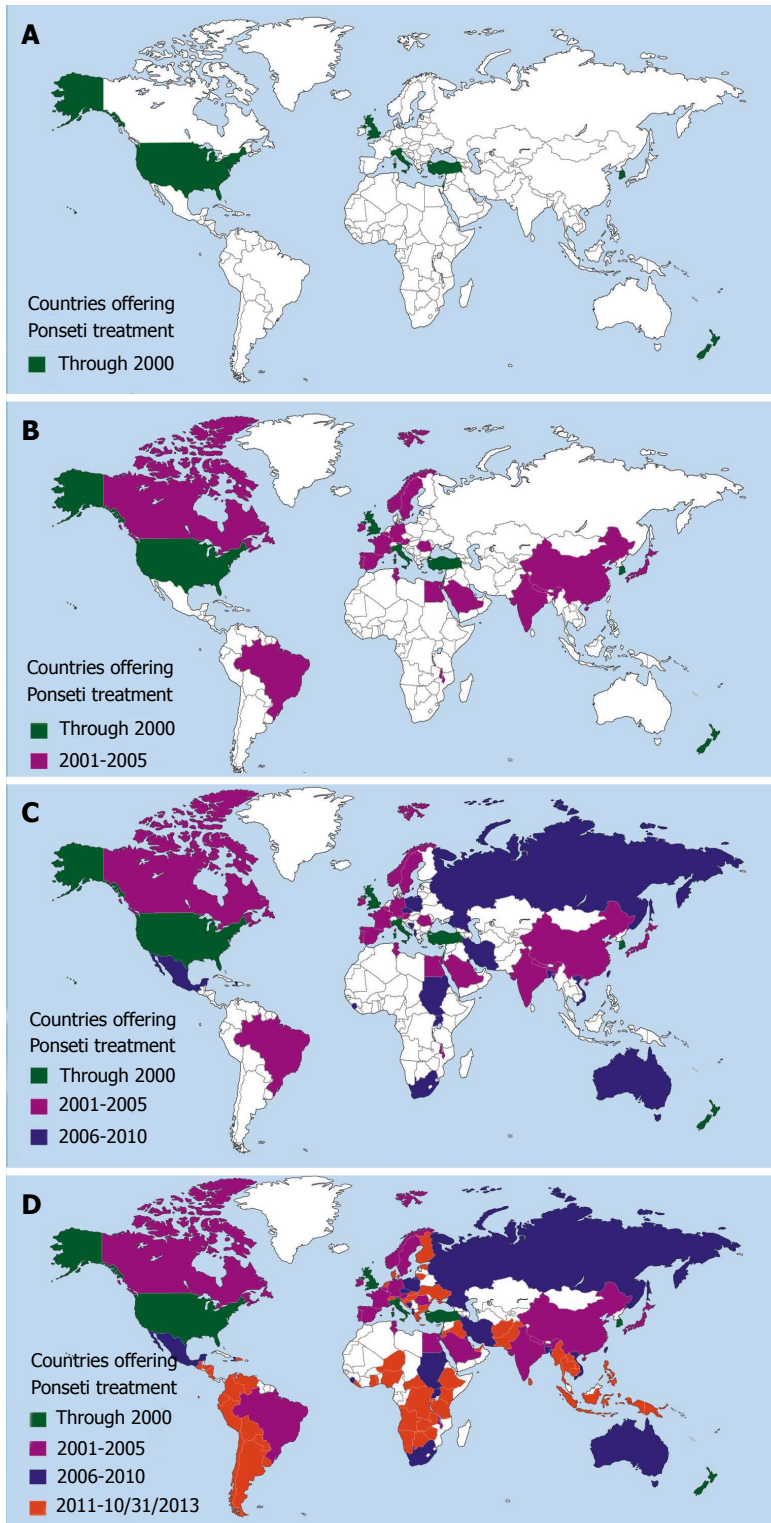
There are some countries where we know for certain the Ponseti method is being used, but could not find publications or Internet evidence (Table 2).

## DISCUSSION

Since Ponseti first introduced his method for the treatment of clubfoot in the 1950's, the method was relatively isolated and confined to Iowa until 1996 when Ponseti published his textbook. Since 1997, the efforts of Ponseti champions have led to a steady increase in clinical use and publication worldwide, especially over the last decade. This conservative method has been shown to be effective, safe, and cost-effective<sup>[5-14]</sup>. As this method is largely non-surgical, and requires only basic medical supplies, its potential to spread to both developed and undeveloped countries is unlimited. With proper training, this method can effectively be performed by a wide variety of medical personnel, including physiotherapists and orthopedic officers.

Despite the benefits of this technique, we found that only 34 of 193 (18%) UN countries have published their experience using the Ponseti method. In another 7 countries we found abstract submissions related to this topic and another 72 countries where the Ponseti method is apparently performed on a clinical basis. This total of 113 countries represents only 59% of the countries in the world.

One of the weaknesses of this study is that large



**Figure 1** Represents the world with the order of appearance of the Ponseti method. A: Through 2000; B: Through 2005; C: Through 2010; D: Until 10/31/2013. The countries still depicted in white are those that can be targeted for further penetration of the Ponseti method.

countries such as China and Russia have shown evidence of activity but the actual extent or penetrance of activity is unknown. Also, although various information gathering methods were used, it's possible that we omitted countries that may be already practicing the Ponseti method. For this we apologize and await remonstrative letters to the editor correcting our inaccuracies. Further studies need to be done to provide further information about the extent within these countries that the Ponseti method is being used.

More than 220000 children in developing countries are born with clubfoot every year<sup>[15-18]</sup>. Despite the efforts of some non-profit organizations, there are still many children with neglected clubfoot and disability caused by untreated or wrongly treated clubfoot. With proper training and education, we feel this method could be further spread, successfully treating patients in both developed and developing countries around the world. This review gives us some idea where this future training and education could be best targeted.

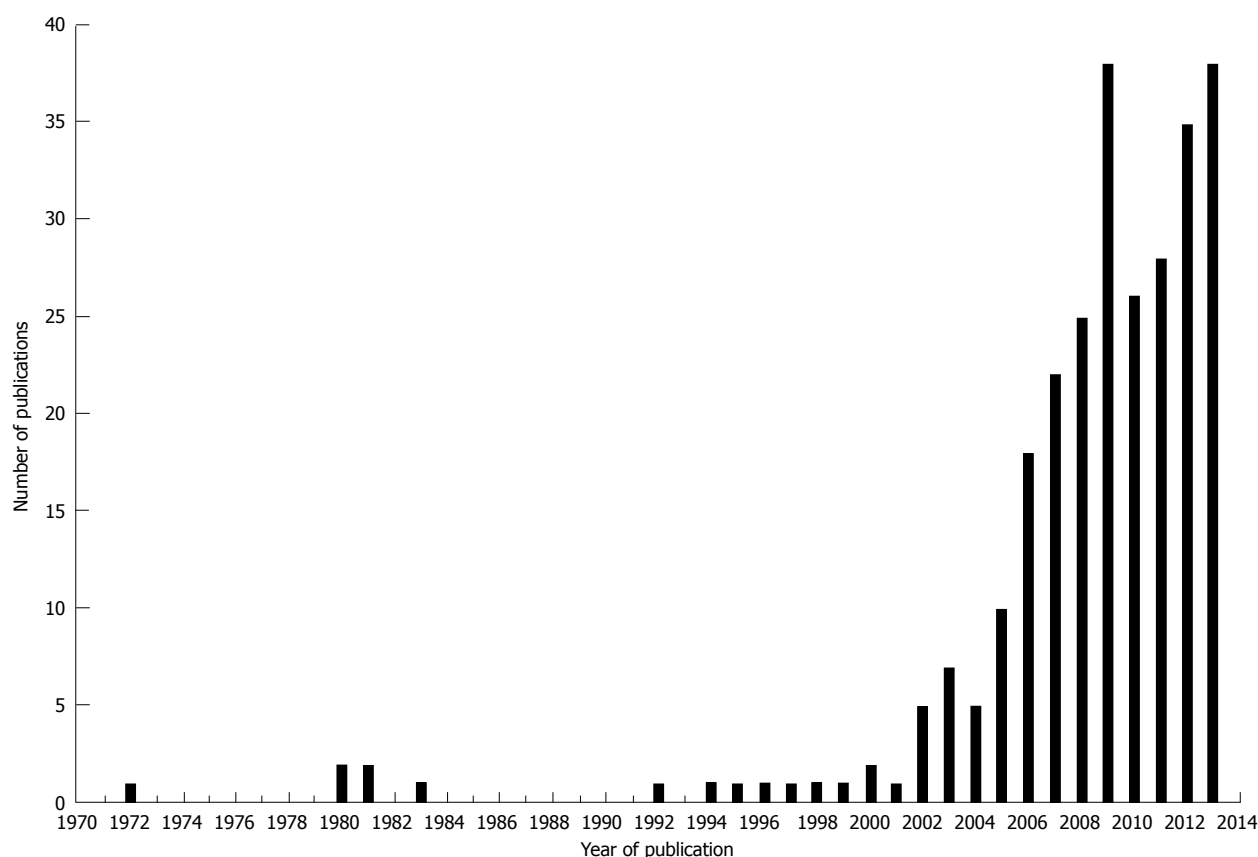


Figure 2 Demonstrates the increase in the number of Ponseti related articles in PubMed during the last two decades.

According to the Ponseti clubfoot management book<sup>[19]</sup>: more than 100000 downloads of the PDF edition in more than 30 languages have been performed in more than 150 countries.

What has helped this method to spread? (1) Evidence based results (publications) which detail the success of this method, in a wide variety of clinical practices. The Ponseti method was proven to be the gold standard treatment for CF patients; therefore many countries adopted this method as the initial treatment for newborn patients (Figure 2); (2) Recent studies have shown good results when the Ponseti method was performed by trained clinical specialists in either a teaching hospital setting or in the developing world. In countries in which there are fewer orthopedic surgeons, especially in low income countries, specially trained non-physician staff can successfully perform this method in a non-surgical environment<sup>[20-22]</sup>; (3) Non-governmental organizations such as the Global Clubfoot Initiative and the Ponseti International Association provide resources to health care practitioners in low and middle income countries<sup>[15-18]</sup>; (4) Ponseti champions, such as Jose Morcuende, Shafiq Pirani, Norgrove Penny, Fred Dietz, John Herzenberg and many others have made contributions by traveling to, and training staff in developing countries; (5) Technological advances such as the Internet helped to spread this method in two ways. First, parents today frequently searched the Internet for new, effective, minimally invasive techniques<sup>[23]</sup>. Second, physicians now can read free articles and learn the method

by watching demonstration videos. The internet is also a tool for transmission of the Ponseti method by the “Ponseti Virtual Forum” (PVF), which demonstrated its effectiveness in low income countries<sup>[24]</sup>; (6) The treatment is affordable as it uses inexpensive casting materials as its primary treatment. The Achilles tenotomy is typically done as an office procedure, thereby avoiding expensive surgical costs<sup>[25]</sup>; (7) Clubfoot: Ponseti Management book. This book provides information on all aspects of Ponseti management of Clubfoot, and is available as a free download in more than 30 different languages. More than 100000 downloads of the PDF have been performed in more than 150 countries; and (8) Meetings and training courses are available to practitioners in the United States and around the world. Jayawardena *et al.*<sup>[26]</sup> demonstrate the effectiveness of these courses in a study in which an online survey was sent to the participants in these training courses from 2001 to 2011. They found that prior to the course, surgical release was the primary method of treatment. Ninety-seven percent of respondents changed their practice as a result of attending the course.

## CONCLUSION

Since approximately 2000, there has been a spectacular increase in number of countries using the Ponseti method. The Internet, training courses, individuals and organizations have all helped to educate health care professionals as well as patients, increasing its impact worldwide.



**Table 2** Countries without evidence that the Ponseti method is being practiced

Country	Population	Country	Population
Algeria	37900000	Swaziland	1250000
Morocco	33113600	Bahrain	1234571
Uzbekistan	30183400	Djibouti	873000
Yemen	25235000	Fiji	858038
North Korea	24895000	Guyana	784894
Ivory Coast	23202000	Bhutan	741920
Syria	21898000	Comoros	724300
Madagascar	21263403	Montenegro	620029
Angola	20609294	Solomon Islands	561000
Burkina Faso	17322796	Luxembourg	537000
Senegal	13567338	Suriname	534189
Chad	12825000	Cape Verde	491875
Cuba	11167325	Malta	416055
Somalia	10496000	Brunei	393162
Benin	10323000	Bahamas	351461
Belarus	9467200	Iceland	325010
Azerbaijan	9235100	Maldives	317280
Tajikistan	8000000	Belize	312971
Libya	6202000	Barbados	274200
Kyrgyzstan	5747000	Vanuatu	264652
Slovakia	5412008	Samoa	187820
Turkmenistan	5240000	São Tomé and Príncipe	187356
Central African republic	4616000	Saint Lucia	166526
Georgia	4483800	Saint Vincent and Grenadines	109000
Oman	3929000	Kiribati	106461
Moldova	3559500	Grenada	103328
Mauritania	3461041	Tonga	103036
Armenia	3024100	Micronesia	101351
Mongolia	2754685	Seychelles	90945
Jamaica	2711476	Antigua and Barbuda	86295
Lesotho	2074000	Andorra	76246
Qatar	2068050	Dominica	71293
Macedonia	2062294	Marshall Islands	56086
Latvia	2008700	Saint Kitts and Nevis	54000
Gambia	1849000	Liechtenstein	36942
Guinea-Bissau	1704000	Monaco	36136
Gabon	1672000	San Marino	32509
Equatorial Guinea	1622000	Palau	20901
Trinidad and Tobago	1328019	Tuvalu	11323
Mauritius	1257900	Nauru	9945

This review identifies where this method is currently being used, as well as those areas (Table 2) that could benefit from targeted education and training. With its low rate of complication, low cost and high effectiveness, this method has unlimited potential for the treatment of clubfoot in both developed and undeveloped countries.

## ACKNOWLEDGMENTS

The authors thank Joy Marlowe for graphic assistance.

## REFERENCES

- 1 Dobbs MB, Morcuende JA, Gurnett CA, Ponseti IV. Treatment of idiopathic clubfoot: an historical review. *Iowa Orthop J* 2000; **20**: 59-64 [PMID: 10934626]
- 2 Laaveg SJ, Ponseti IV. Long-term results of treatment of congenital club foot. *J Bone Joint Surg Am* 1980; **62**: 23-31 [PMID: 7351412]
- 3 Ippolito E, Farsetti P, Caterini R, Tudisco C. Long-term comparative results in patients with congenital clubfoot treated with two different protocols. *J Bone Joint Surg Am* 2003; **85-A**: 1286-1294 [PMID: 12851354]
- 4 Dobbs MB, Nunley R, Schoenecker PL. Long-term follow-up of patients with clubfeet treated with extensive soft-tissue release. *J Bone Joint Surg Am* 2006; **88**: 986-996 [PMID: 16651573 DOI: 10.2106/JBJS.E.00114]
- 5 Abdelgawad AA, Lehman WB, van Bosse HJ, Scher DM, Sala DA. Treatment of idiopathic clubfoot using the Ponseti method: minimum 2-year follow-up. *J Pediatr Orthop B* 2007; **16**: 98-105 [PMID: 17273035 DOI: 10.1097/BPB.0b013e32801048bb]
- 6 Bor N, Coplan JA, Herzenberg JE. Ponseti treatment for idiopathic clubfoot: minimum 5-year followup. *Clin Orthop Relat Res* 2009; **467**: 1263-1270 [PMID: 19130158 DOI: 10.1007/s11999-008-0683-8]
- 7 Segev E, Keret D, Lokiec F, Yavor A, Wientroub S, Ezra E, Hayek S. Early experience with the Ponseti method for the treatment of congenital idiopathic clubfoot. *Isr Med Assoc J* 2005; **7**: 307-310 [PMID: 15909463]
- 8 Herzenberg JE, Radler C, Bor N. Ponseti versus traditional methods of casting for idiopathic clubfoot. *J Pediatr Orthop* 2002; **22**: 517-521 [PMID: 12131451 DOI: 10.1097/01241398-200207000-00019]
- 9 Morcuende JA, Abbasi D, Dolan LA, Ponseti IV. Results of an accelerated Ponseti protocol for clubfoot. *J Pediatr Orthop* 2005; **25**: 623-626 [PMID: 16199943 DOI: 10.1097/01.bpo.0000162015.44865.5e]
- 10 Göksan SB. Treatment of congenital clubfoot with the Ponseti method. *Acta Orthop Traumatol Turc* 2002; **36**: 281-287 [PMID: 12510061]
- 11 Changulani M, Garg NK, Rajagopal TS, Bass A, Nayagam SN, Sampath J, Bruce CE. Treatment of idiopathic club foot using the Ponseti method. Initial experience. *J Bone Joint Surg Br* 2006; **88**: 1385-1387 [PMID: 17012432 DOI: 10.1302/0301-620X.88B10.17578]
- 12 Abbas M, Qureshi OA, Jeelani LZ, Azam Q, Khan AQ, Sabir AB. Management of congenital talipes equinovarus by Ponseti technique: a clinical study. *J Foot Ankle Surg* 2008; **47**: 541-545 [PMID: 19239864 DOI: 10.1053/j.jfas]
- 13 Colburn M, Williams M. Evaluation of the treatment of idiopathic clubfoot by using the Ponseti method. *J Foot Ankle Surg* 2003; **42**: 259-267 [PMID: 14566717 DOI: 10.1016/S1067-2516(03)00312-0]
- 14 Sætersdal C, Fevang JM, Fosse L, Engesaeter LB. Good results with the Ponseti method: a multicenter study of 162 clubfeet followed for 2-5 years. *Acta Orthop* 2012; **83**: 288-293 [PMID: 22616746 DOI: 10.3109/17453674.2012.693015]
- 15 Available from: URL: <http://www.ponseti.info/>
- 16 Available from: URL: <http://www.globalclubfoot.org>
- 17 Available from: URL: <http://miraclefeet.org/>
- 18 Available from: URL: <http://cure.org/clubfoot>
- 19 Available from: URL: [http://www.global-help.org/publications/books/help\\_cfponseti.pdf](http://www.global-help.org/publications/books/help_cfponseti.pdf)
- 20 Shack N, Eastwood DM. Early results of a physiotherapist-delivered Ponseti service for the management of idiopathic congenital talipes equinovarus foot deformity. *J Bone Joint Surg Br* 2006; **88**: 1085-1089 [PMID: 16877611 DOI: 10.1302/0301-620X.88B8.17919]
- 21 Janicki JA, Narayanan UG, Harvey BJ, Roy A, Weir S, Wright JG. Comparison of surgeon and physiotherapist-directed Ponseti treatment of idiopathic clubfoot. *J Bone Joint Surg Am* 2009; **91**: 1101-1108 [PMID: 19411458 DOI: 10.2106/JBJS.H.00178]
- 22 Tindall AJ, Steinlechner CW, Lavy CB, Mannion S, Mkan-dawire N. Results of manipulation of idiopathic clubfoot deformity in Malawi by orthopaedic clinical officers using the Ponseti method: a realistic alternative for the developing

- world? *J Pediatr Orthop* 2005; **25**: 627-629 [PMID: 16199944 DOI: 10.1097/01.bpo.0000164876.97949.6b]
- 23 **Morcuende JA**, Egbert M, Ponseti IV. The effect of the internet in the treatment of congenital idiopathic clubfoot. *Iowa Orthop J* 2003; **23**: 83-86 [PMID: 14575256]
  - 24 **Jayawardena A**, Boardman A, Cook T, Oprescu F, Morcuende JA. Diffusion of innovation: enhancing the dissemination of the Ponseti method in Latin America through virtual forums. *Iowa Orthop J* 2011; **31**: 36-42 [PMID: 22096417]
  - 25 **Lebel E**, Karasik M, Bernstein-Weyel M, Mishukov Y, Peyser A. Achilles tenotomy as an office procedure: safety and efficacy as part of the Ponseti serial casting protocol for clubfoot. *J Pediatr Orthop* 2012; **32**: 412-415 [PMID: 22584844 DOI: 10.1097/BPO.0b013e31825611a6]
  - 26 **Jayawardena A**, Wijayasinghe SR, Tennakoon D, Cook T, Morcuende JA. Early effects of a 'train the trainer' approach to Ponseti method dissemination: a case study of Sri Lanka. *Iowa Orthop J* 2013; **33**: 153-160 [PMID: 24027476]

**P- Reviewer:** Lampasi M   **S- Editor:** Wen LL  
**L- Editor:** A   **E- Editor:** Wu HL



WJO 5<sup>th</sup> Anniversary Special Issues (4): Hip

## Survival outcomes of cemented compared to uncemented stems in primary total hip replacement

Michael Wyatt, Gary Hooper, Christopher Frampton, Alastair Rothwell

Michael Wyatt, Gary Hooper, Christopher Frampton, Alastair Rothwell, Department of Orthopaedic Surgery and Musculoskeletal Medicine, University of Otago, Christchurch, Canterbury 8011, New Zealand

Author contributions: Wyatt M, Hooper G and Rothwell A wrote article; Frampton C contributed to statistical analysis.

Correspondence to: Michael Wyatt, BSc(Hons), MBChB, MRCS(Ed), Department of Orthopaedic Surgery and Musculoskeletal Medicine, University of Otago, 2 Riccarton Avenue, Christchurch 4710, Canterbury 8011,

New Zealand. [mcwyatt@xtra.co.nz](mailto:mcwyatt@xtra.co.nz)

Telephone: +64-3-3640640 Fax: +64-3-3640806

Received: April 11, 2014 Revised: May 28, 2014

Accepted: June 18, 2014

Published online: November 18, 2014

© 2014 Baishideng Publishing Group Inc. All rights reserved.

**Key words:** Primary total hip replacement; Femoral fixation; Cemented; Uncemented; Joint replacement registry; Implant survival

**Core tip:** There has been a worldwide trend towards uncemented fixation in total hip replacement yet paradoxically cemented fixation has the highest survival rate when failure has been defined as a revision of the primary implant for aseptic loosening. However closer analysis of registry data shows that revision for aseptic loosening is low with uncemented total hip replacement, and in particular revision of uncemented stems is the lowest in young patients under 65 years, who would be expected to have higher physical demands with higher failure rates secondary to loosening.

### Abstract

Total hip replacement (THR) is a successful and reliable operation for both relieving pain and improving function in patients who are disabled with end stage arthritis. The ageing population is predicted to significantly increase the requirement for THR in patients who have a higher functional demand than those of the past. Uncemented THR was introduced to improve the long term results and in particular the results in younger, higher functioning patients. There has been controversy about the value of uncemented compared to cemented THR although there has been a world-wide trend towards uncemented fixation. Uncemented acetabular fixation has gained wide acceptance, as seen in the increasing number of hybrid THR in joint registries, but there remains debate about the best mode of femoral fixation. In this article we review the history and current world-wide registry data, with an in-depth analysis of the New Zealand Joint Registry, to determine the results of uncemented femoral fixation in an attempt to provide an evidence-based answer as to the value of this form of fixation.

Wyatt M, Hooper G, Frampton C, Rothwell A. Survival outcomes of cemented compared to uncemented stems in primary total hip replacement. *World J Orthop* 2014; 5(5): 591-596 Available from: URL: <http://www.wjgnet.com/2218-5836/full/v5/i5/591.htm> DOI: <http://dx.doi.org/10.5312/wjo.v5.i5.591>

### INTRODUCTION

The best mode of implant fixation in primary total hip replacement (THR) has been a source of debate. Cemented implants achieve stability from cement-bone mechanical interlock, once the polymethylmethacrylate has cured, whereas cementless fixation relies on primary press fit stability with long term stability occurring secondary to endosteal microfractures at the time of preparation and subsequent bone ongrowth or ingrowth. The optimum fixation choice should be guided by patient based outcomes, in particular the implant survivorship as measured by revision for aseptic loosening, as this was

a major reason for the introduction of uncemented implants.

Advocates of cemented implants cite the excellent and reliable long-term reported survivorship<sup>[1-3]</sup> whereas proponents of cementless fixation contend that this method is equally reliable<sup>[4-7]</sup> and in fact superior in younger, high-demand patients<sup>[8,9]</sup>. Furthermore, cementless implants provide a broader range of options especially for the acetabulum where liner exchange may be required for postoperative instability; the commonest cause for early re-operation in all primary THR<sup>[10]</sup>. Modular cups also offer the option for changing the femoral head diameter which may improve the functional outcome especially in the younger or more active patient. A hybrid THR, where the stem is cemented and the cup uncemented, has been suggested to provide the benefits of both fixation methods<sup>[11,12]</sup> although the reported results have been mixed<sup>[13-15]</sup>. Worldwide there has been an observed trend towards uncemented fixation with confirmatory joint registry results in Australia, New Zealand, England, Wales and Sweden. Both Canada and the United States have continued to have a predominant use of uncemented THR<sup>[14-18]</sup>.

One of the traditional arguments against uncemented THR has been the increased cost with implants often being 3-4 times more expensive than the cemented variety. In the immediate future, the burden of an ageing population with the projected increase in demand for THR will put considerable strain on health funding agencies requiring balanced economic arguments for the use of THR implants. There is also likely to be an increase in the absolute number of revision procedures which are approximately 4 times more expensive than primary procedures, especially when both the femoral and acetabular components are revised. This has implications if one form of fixation is inferior to the other. Those that advocate uncemented implants suggest that following successful bonding of both the femoral and acetabular components to bone then future revision procedures may only involve exchange of articulating surfaces, which is likely to be a procedure whereby patients recover rapidly with a lower overall health cost<sup>[19]</sup>.

Uncemented acetabular implants are widely used in all age groups with registry results showing satisfactory early and mid-term results<sup>[4,14-18]</sup>. However, uncemented femoral implants have been less widely accepted with several countries continuing to favour the cemented option as seen in the increasing number of hybrid THR performed in registries across the world<sup>[15,18]</sup>. We have reviewed the recent evidence supporting femoral implant fixation, in particular joint registry outcomes, in an attempt to provide sound recommendations for future practise.

## HISTORY OF FIXATION IN PRIMARY TOTAL HIP REPLACEMENT

The British Orthopaedic Association meeting in London, September 1964 was a turning point for the treat-

ment of patients with crippling osteoarthritis of the hip. McKee (Norwich) presented the results of the cemented metal-on-metal McKee-Farrar arthroplasty and Charnley (Wrightington) demonstrated the results of his cemented metal-on-polyethylene THR by having one of his patients walk normally across the stage. Widespread high rates of aseptic loosening of cemented THR during the 1960's and 1970's tempered enthusiasm and "Cement disease" was widely held as the cause of this loosening. Many surgeons began to favour the use of cementless fixation as recommended by Ring with his metal-on-metal replacement<sup>[2]</sup>. However excellent results with cemented fixation were maintained with the Charnley prosthesis. The Exeter group, who believed that poor cementing technique and not cement *per se* was the issue, developed their collarless, taper-slip cemented prosthesis specifically designed to subside into the cement mantle while providing even load. The early metal-on-metal design soon fell from favour with high failure rates, possibly related to poor manufacturing tolerances of the implant, and the improving results of cemented metal-on-polyethylene replacements.

The high rates of early loosening and failures observed in younger, active patients coupled with concerns regarding "cement disease" continued to drive a renewed interest in uncemented fixation<sup>[20-22]</sup>. Early failures of cemented implants in these younger patients were often associated with a varus positioning of the femoral stem whereas the acetabular component often failed after 12 years with polyethylene wear and loosening. The use of cementless components in this patient cohort initially established the wider use of these implants throughout the world in the hope that they would improve survivorship. Once it had been established that aseptic loosening was in fact due to the polyethylene debris and not 'cement disease' uncemented THR had become firmly established as a recognised and viable option for surgeons.

## MODERN PRIMARY FEMORAL STEM

Over the last 20 years significant attention has been paid to improving the cementing technique which has emphasised both the preparation of the femoral canal and the pressurisation of the cement on insertion. These changes have improved the cement-bone interface with more stable inter-locking and as a result the intermediate survival rates of cemented stems have improved. Current joint registries record between 92% at 11 years and 86% at 22 years survival for these implants<sup>[14,15,18]</sup>. These improved survival statistics have been interpreted as a cemented THR is likely to be a "life long" implant for patients aged sixty-two or older, whereas for a fifty-eight-year-old patient there is a 50:50 chance of undergoing a revision within their life time<sup>[23]</sup>.

There are currently two philosophies of cemented femoral fixation: composite beam and polished, tapered wedge. The former is predominant in North America whereas the latter is more widely used in Europe. A composite beam relies on rigid bonding to the cement and is



**Table 1** Thirteen year New Zealand Joint Registry results for revision rates *vs* fixation method

Fixation	Component years	Events	Rate/100 cy	95%CI
Cemented	149098	870	0.58	0.55-0.62
Hybrid	168604	117	0.66	0.62-0.70
Reverse hybrid	3124	19	0.61	0.37-0.95
Uncemented	148214	1313	0.89	0.84-0.94

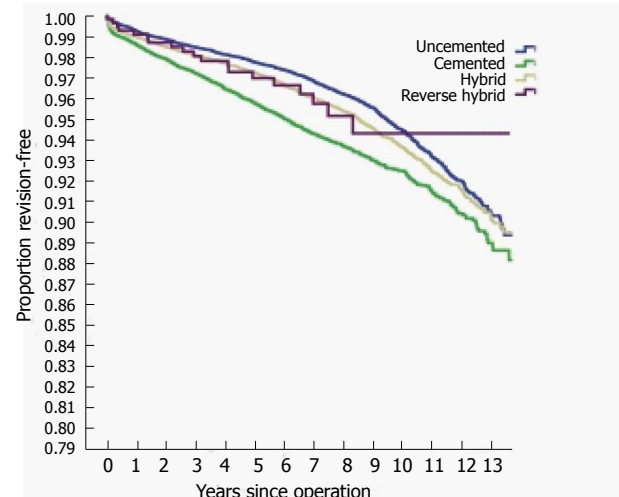
not intended to subside. This is in contrast to the loaded taper wedge which converts radial compression into hoop stresses within the cement mantle, and is expected to subside. The addition of cement around an implant provides an additional buffer that the surgeon can manipulate to control correcting leg length and version during insertion. Cement use has sporadically been reported as producing potentially fatal associated cardiovascular and embolic phenomena at implantation, especially in the elderly compromised patient<sup>[24]</sup>.

Cementless stems rely on bone on-growth or in-growth to provide stability. A roughened titanium stem has been shown to attract bone and provide early stability<sup>[25]</sup> and most uncemented stems today have this type of surface. The addition of hydroxyapatite to this surface has been shown to also stimulate bony fixation<sup>[26]</sup> without the initial early concern of producing ceramic particles in the joint that could cause third body wear.

There are two major uncemented stem designs: proximal (metaphyseal) loading or fully coated. Proximal loading has been advocated to avoid the stress shielding that was observed with early “distal fitting” implants<sup>[27]</sup>. Often these implants are bulky in the proximal metaphyseal region, which is responsible for the early resistance to subsidence and rotation, and smooth distally to prevent bone apposition. They are inserted following minimal reaming and are rarely associated with femoral fracture. On the other hand, fully coated stems rely on a graduated loading of the proximal femur, allow bone apposition throughout their length and provide stability by their wide, flat nature. Initial stability is achieved by reaming the femur to accept a maximally sized implant that undergoes three-point fixation in the proximal femur. These implants require exact sizing and significant reaming and are associated with a higher incidence of femoral fracture<sup>[28]</sup>.

## EUROPEAN JOINT REGISTRY OUTCOMES AND TRENDS IN FEMORAL FIXATION

The Swedish hip registry reports a gradual trend for the increased use of uncemented fixation although cemented THR's were used in 64% of all patients in 2011 regardless of age<sup>[14]</sup>. Overall cementless stem fixation was more common in the younger, active patient with good bone quality whereas cemented fixation was favoured for patients over seventy years of age. Cemented THR had a 90% 16-year survivorship and was 30%-80% less likely to be revised compared to uncemented and hybrid THR's

**Figure 1** Thirteen New Zealand Joint Registry Kaplan-Meier survival curve of total hip replacement by fixation type.

during the first 8 years, suggesting that early revision was more likely to be related to acetabular problems. After 8 years the survivorship of the uncemented group tended towards that of the cemented group. Up to age 70 years the uncemented hips had fewer revisions attributed to loosening. The hybrid combinations did not convey a clear advantage over either group.

The Norwegian Hip Registry also reported an overall trend towards less cemented fixation but in Norway this was largely due to an increase in hybrid THR<sup>[15]</sup>. Overall cemented THR's had a twenty-year survival rate of 85% compared to 50% for uncemented total hips. Hybrids had no clear advantage over either cemented or uncemented THR's in terms of implant survival during the same time period. Uncemented or hybrid fixation were preferred in patients under the age of 60 years whilst cemented fixation was used in the great majority > 60 years old.

In the National Joint Registry of England and Wales cemented THR represented only 33% of all primary THR's yet was used the majority of times for patients over eighty years of age<sup>[19]</sup>. Total cementless fixation was used in 43% of patients and was the major type of fixation for patients less than seventy years old. Hybrid THR's accounted for 20% of primary THR's. The cumulative percentage of revision (with 95%CI) at 9 years was 2.71% (2.57-2.87) for cemented, 6.71% (6.40-7.05) for uncemented and 3.42% (3.10-3.76) for hybrid THR.

## RESULTS FROM THE NEW ZEALAND JOINT REGISTRY

The data from the world-wide joint registries portray a similar pattern for the survival of cemented THR compared to uncemented THR, and these results are supported by those of the New Zealand Joint Registry (NZJR, Table 1 and Figure 1). On this basis it would be easy to dismiss the uncemented variety as inferior, but revision

**Table 2** Thirteen year New Zealand Joint Registry reasons for revision for loosening within 90 d *n* (%)

Fixation/ <i>n</i>	Loose cup	Loose stem	Unstable	Deep infection	Pain	Femoral fracture
Cemented/77	6 (7.8)	3 (3.9)	58 (75.3)	9 (11.7)	9 (2.6)	3 (3.9)
Hybrid/189	31 (16.4)	7 (3.7)	113 (59.8)	26 (13.8)	5 (2.6)	9 (4.8)
Reverse hybrid/2	0	1 (50)	0	0	0	1 (50)
Uncemented/270	23 (8.5)	23 (8.5)	108 (40)	26 (9.6)	5 (1.9)	81 (30)

as an end point is a “blunt tool” and needs to be interpreted in conjunction with several other factors. We have reviewed the results of the New Zealand joint Registry in detail to elucidate this and to look at confounding variables that may contribute to these revision rates.

One of the primary reasons for the introduction of the uncemented stem was to improve the outcome in younger, more active patients, particularly males. The New Zealand joint registry has shown a revision rate of 0.89/100 component years (cy) for uncemented THRs in patients under 55 years compared to 1.73/100 cy for cemented THR and 0.90/100 cy compared to 0.98/100 cy for those between 55-65 years ( $P < 0.001$ )<sup>[16]</sup>. Over 65 years this was reversed with the cemented THR surviving longer than the uncemented variety ( $P < 0.001$ ). The overall revision rate was significantly higher ( $P < 0.001$ ) in patients under 65 years (1.00-0.83/100 cy) compared to those over 65 years (0.65-0.45/100 cy) and an argument could be made that because of this the uncemented stem was more robust in a high demand patient. Hybrid fixation also showed poorer survival in the under 55 year group compared to uncemented THR (1.03/100 cy compared to 0.93/100 cy,  $P < 0.002$ ) suggesting that it may be the uncemented stem in this age group which has helped improve the survival statistics.

Early revision (within 90 d) was far more common ( $P < 0.001$ ) in the uncemented THR (0.899%) compared to cemented THR (0.353%) which continued across all age groups but only reached significance in those over 65 years ( $P < 0.001$ ). When the reason for revision was analysed the major cause for early revision in uncemented implants was either due to femoral fracture (30%) or dislocation (40%) whereas 75% of early revisions in the cemented group were secondary to dislocation (Table 2). Femoral fracture with uncemented stems has been identified as an early cause for failure by others<sup>[14]</sup>. Femoral fracture was shown to be age dependent, with older patients and presumably those with poorer bone density having a much higher incidence of this complication (Figure 2). This complication may be due to surgical inexperience and/or attempting to “over ream” the femur to insert the largest implant to avoid early subsidence or failure of bonding to the prosthesis. The early rate of femoral fracture did not continue beyond 90 d as the overall 13 year results showed there was no significant

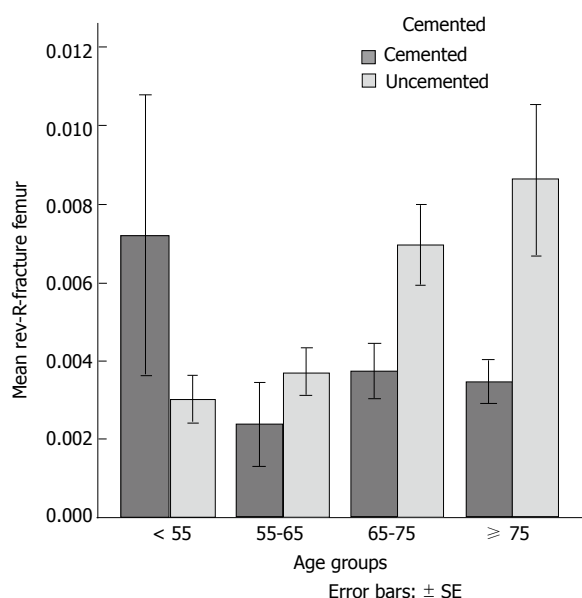
**Table 3** Thirteen year New Zealand Joint Registry reasons for revision for loosening by fixation method *n* (%)

Fixation/ <i>n</i>	Loose cup	Loose stem	Unstable	Deep infection	Pain	Femoral fracture
Cemented/870	415 (48)	148 (17)	200 (23)	105 (12)	86 (10)	74 (8.5)
Hybrid/1117	160 (14)	235 (21)	384 (34)	157 (14)	136 (12)	141 (11)
Reverse	4 (21)	1 (5)	5 (26)	4 (21)	2 (11)	3 (16)
Uncemented/1313	198 (15)	192 (15)	307 (24)	124 (9)	222 (17)	141 (11)
<i>P</i> value	$< 0.001$	$< 0.001$	$< 0.001$	0.003	$< 0.001$	0.208

difference in revision for femoral fracture between the fixation methods ( $P = 0.208$ ) (Table 3). This contradicts the Swedish registry results which show that uncemented stems are revised twice as frequently as cemented stems during the first five years and that cemented stems were ten times less likely to require revision for periprosthetic fracture. The reason for this discrepancy is not immediately apparent.

The rate of femoral loosening within 90 d was significantly higher in uncemented stems ( $P < 0.009$ ) but decreased over the 13-year period to become essentially the same as cemented stems (0.62% *vs* 0.66%). This early “loosening” of uncemented stems is likely to be associated with surgical technique and under sizing of the component, whereas the longer results are more likely to reflect the true aseptic loosening rate. Removing the early failures due to loosening makes the performance of the uncemented stem much more impressive and suggests that long term aseptic loosening may not affect it to the same extent as cemented THR. Figure 3 shows the increasing failure rate of cemented stem due to aseptic loosening compared to uncemented stems, suggesting that in the future this failure mode may remain static in uncemented stems but increase in the cemented variety. The fact that failure of hybrid fixation secondary to femoral loosening was 0.77% ( $P < 0.001$ ) adds evidence to the suggestion that the cemented femoral stem may be more likely to fail by this mechanism. These results are supported by the Swedish registry which showed that from eight to sixteen years cemented stems had a higher rate of revision over cementless stems and 80% of these were for loosening.

In the past there has been controversy over the use of antibiotic loaded cement and whether this would decrease revision for prosthetic infection. Most have accepted that it was unlikely to do any harm, however the results from the NZJR are interesting when you consider that the great majority ( $> 90\%$ ) of cemented implants are performed with antibiotic cement. The combined revision rate for infection for both cemented and hybrid THR was 0.50% compared to 0.40% for uncemented THR which suggests that antibiotic cement may not have the protective effect against infection that has been assumed. This result is similar to the Swedish registry which demonstrated that cemented stems were 1.4 times more likely



**Figure 2** The New Zealand Joint Registry results showing the comparison of the incidence of femoral fracture and age with cemented and uncemented stems (65-75 yr,  $P = 0.008$ ;  $\geq 75$  yr,  $P = 0.001$ ).

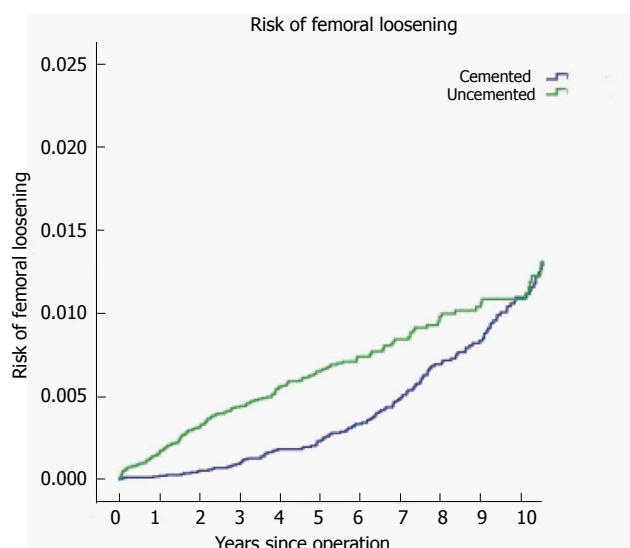
to be revised for infection.

In the past unexplained pain has been a feature of the uncemented femoral stem but with a move away from distal fixation the incidence of revision for this complication was low at 90 d, however by 13 years pain became the second commonest cause for revision surgery behind dislocation in this group of implants. Pain as a cause for revision was not specified and so may not have been due to femoral pain. Regardless it is encouraging to find that pain was now a low cause for early revision of uncemented stems.

Another complicating variable which is unique to uncemented THR has been the ability to use different bearing surfaces in an attempt to improve the wear associated with a polyethylene articulation. Both metal on metal and ceramic on ceramic surfaces however have been associated with early failures due to reasons not associated with cemented THR. However most of these complications have arisen from the articulating surface itself, with ceramic fracture and excessive metal ion debris two of the primary reasons for early failure. These problems have not necessarily resulted in failure of the uncemented stem secondary to loosening and as a result have almost certainly skewed the overall revision rates in favour of cemented THR. The problem can be illustrated in the 14-year NZJR report where the revision rate for metal on metal articulations with femoral head size  $> 36$  mm was 3.08/100 cy. The use of larger femoral head sizes is almost solely used in uncemented implants and those with a head size  $> 36$  mm had a combined revision rate of 2.75/100 cy, irrespective of the articulating surface. This offers a potential explanation for the different revision rates between the two forms of femoral fixation.

## IMPLANT COST

Although uncemented implants are more costly than ce-



**Figure 3** The New Zealand Joint Registry results showing the comparison between cemented and uncemented stems and the incidence of revision for aseptic loosening.

mented there have been studies suggesting that the overall cost differential between the two types of fixation is not dramatically different<sup>[29,30]</sup>. With the increasing use of hybrid fixation the cost difference between a cemented and uncemented stem is even smaller and likely to be less relevant in the overall economic assessment. Determining the exact cost of a femoral stem can be difficult as the list price may be significantly different from the purchase price after discounting for bulk purchases and other company driven incentives. We cannot make a comment about pricing in other countries but are aware that companies in our country are required to price their implants in reasonable price bands to remain commercially viable and competitive.

## CONCLUSION

Controversy continues to exist regarding the best form of fixation to use in THR. Often opinions are polarised by such factors as training, tradition, and personal preference with proponents of cemented fixation often citing the overall poorer revision rates for uncemented THR reported in the various national joint registries. This review has attempted to clarify the differences between cemented and uncemented THR, with the emphasis on femoral fixation, by analysing the reported joint registry data. There has been a world-wide trend towards uncemented THR over the last 10 years, and even countries who in the past have been the major proponents of cemented fixation have not been excluded from this trend.

Uncemented THR was introduced to address the poorer results observed with cemented THR in younger patients with higher functional requirements and to this end the registry results would confirm that inpatients  $< 65$  years have a lower revision rate with uncemented fixation. In particular the uncemented stem has performed better in this age group with a lower rate of aseptic loos-



ening compared to the cemented variety. Femoral fracture remains a significant reason for early revision with uncemented stems which is more likely to be related to surgical technique and potentially could be improved by increased exposure to this technique in surgical training.

## REFERENCES

- 1 **Wroblewski BM**, Siney PD, Fleming PA. Charnley low-friction arthroplasty: survival patterns to 38 years. *J Bone Joint Surg Br* 2007; **89**: 1015-1018 [PMID: 17785737 DOI: 10.1302/0301-620X.89B8.18387]
- 2 **Ling RSM**, Lee AJC, Gie GA, Timperley AJ, Hubble MJW, Howell JR and Whitehouse SL. The Exeter Hip: 40 years of Innovation in Total Hip Arthroplasty. Available from: URL: <http://www.amazon.co.uk/The-Exeter-Hip-Innovation-Arthroplasty/dp/0956452116>
- 3 **Burston BJ**, Barnett AJ, Amirfeyz R, Yates PJ, Bannister GC. Clinical and radiological results of the collarless polished tapered stem at 15 years follow-up. *J Bone Joint Surg Br* 2012; **94**: 889-894 [PMID: 22733941 DOI: 10.1302/0301-620X.94B7.28799]
- 4 **Gwynne-Jones DP**, Garneti N, Wainwright C, Matheson JA, King R. The Morscher Press Fit acetabular component: a nine- to 13-year review. *J Bone Joint Surg Br* 2009; **91**: 859-864 [PMID: 19567847 DOI: 10.1302/0301-620X.91B7.22013]
- 5 **Engl CA**, Massin P. Cementless total hip arthroplasty using the anatomic medullary locking stem. Results using a survivorship analysis. *Clin Orthop Relat Res* 1989; **(249)**: 141-158 [PMID: 2582665]
- 6 **Ihle M**, Mai S, Pfluger D, Siebert W. The results of the titanium-coated RM acetabular component at 20 years: a long-term follow-up of an uncemented primary total hip replacement. *J Bone Joint Surg Br* 2008; **90**: 1284-1290 [PMID: 18827236 DOI: 10.1302/0301-620X.90B10.20274]
- 7 **McAuley JP**, Moore KD, Culpepper WJ, Engl CA. Total hip arthroplasty with porous-coated prostheses fixed without cement in patients who are sixty-five years of age or older. *J Bone Joint Surg Am* 1998; **80**: 1648-1655 [PMID: 9840634]
- 8 **Hooper GJ**, Rothwell AG, Stringer M, Frampton C. Revision following cemented and uncemented primary total hip replacement: a seven-year analysis from the New Zealand Joint Registry. *J Bone Joint Surg Br* 2009; **91**: 451-458 [PMID: 19336803 DOI: 10.1302/0301-620X.91B4.21363]
- 9 **Kim YH**, Kim JS, Park JW, Joo JH. Comparison of total hip replacement with and without cement in patients younger than 50 years of age: the results at 18 years. *J Bone Joint Surg Br* 2011; **93**: 449-455 [PMID: 21464481 DOI: 10.1302/0301-620X.93B4.26149]
- 10 **Ulrich SD**, Seyler TM, Bennett D, Delanois RE, Saleh KJ, Thongtrangan I, Kuskowski M, Cheng EY, Sharkey PF, Parvizi J, Stiehl JB, Mont MA. Total hip arthroplasties: what are the reasons for revision? *Int Orthop* 2008; **32**: 597-604 [PMID: 17443324 DOI: 10.1007/s00264-007-0364-3]
- 11 **Clohisy JC**, Harris WH. Primary hybrid total hip replacement, performed with insertion of the acetabular component without cement and a precoat femoral component with cement. An average ten-year follow-up study. *J Bone Joint Surg Am* 1999; **81**: 247-255 [PMID: 10073588]
- 12 **Pennington M**, Grieve R, Sekhon JS, Gregg P, Black N, van der Meulen JH. Cemented, cementless, and hybrid prostheses for total hip replacement: cost effectiveness analysis. *BMJ* 2013; **346**: f1026 [PMID: 23447338 DOI: 10.1136/bmj.f1026]
- 13 **Horne G**, Culliford N, Adams K, Devane P. Hybrid total hip replacement: outcome after a mean follow up of 10 years. *ANZ J Surg* 2007; **77**: 638-641 [PMID: 17635275]
- 14 Swedish Hip Registry report 2011 (Accessed 6.11.2013). Available from: URL: <http://www.shpr.se/en>
- 15 Norwegian Joint Registry report 2010. Available from: URL: <http://nrlweb.ihelse.net/eng>
- 16 New Zealand Joint Registry report 2011 (Accessed 6.11.2013). Available from: URL: [http://www.nzoa.org.nz/system/files/NJR\\_14\\_Year\\_Report.pdf](http://www.nzoa.org.nz/system/files/NJR_14_Year_Report.pdf)
- 17 Australian Joint Registry report 2012 (Accessed 6.11.2013). Available from: URL: <http://aoanjrr.dmac.adelaide.edu.au>
- 18 **NJR Steering Committee**. National Joint Registry for England, Wales and Northern Ireland: 10th Annual Report (Hemel Hempstead; 2013 Sep). Available from: URL: [http://www.njrcentre.org.uk/njrcentre/Portals/0/Documents/England/Reports/10th\\_annual\\_report/NJR%2010th%20Annual%20Report%202013%20B.pdf](http://www.njrcentre.org.uk/njrcentre/Portals/0/Documents/England/Reports/10th_annual_report/NJR%2010th%20Annual%20Report%202013%20B.pdf)
- 19 Getting it right first time-Improving the quality of orthopaedic care within the National Health Service in England. Available from: URL: <http://www.mahsc.ac.uk/case-study/get-it-right-first-time-improving-the-quality-of-orthopaedic-care-within-the-national-health-service-in-england/>
- 20 **Dorr LD**, Kane TJ, Conaty JP. Long-term results of cemented total hip arthroplasty in patients 45 years old or younger. A 16-year follow-up study. *J Arthroplasty* 1994; **9**: 453-456 [PMID: 7807101]
- 21 **Joshi AB**, Porter ML, Trail IA, Hunt LP, Murphy JC, Harding K. Long-term results of Charnley low-friction arthroplasty in young patients. *J Bone Joint Surg Br* 1993; **75**: 616-623 [PMID: 8331119]
- 22 **Mulroy WF**, Harris WH. Acetabular and femoral fixation 15 years after cemented total hip surgery. *Clin Orthop Relat Res* 1997; **(337)**: 118-128 [PMID: 9137183]
- 23 **Wainwright C**, Theis JC, Garneti N, Melloh M. Age at hip or knee joint replacement surgery predicts likelihood of revision surgery. *J Bone Joint Surg Br* 2011; **93**: 1411-1415 [PMID: 21969444 DOI: 10.1302/0301-620X.93B10.27100]
- 24 **Parvizi J**, Holiday AD, Erath MH, Lewallen DG. The Frank Stinchfield Award. Sudden death during primary hip arthroplasty. *Clin Orthop Relat Res* 1999; **(369)**: 39-48 [PMID: 10611859]
- 25 **Wieland M**, Sittig C, Brunette DM, Textor M, Spencer ND. Measurement and evaluation of the chemical composition and topography of titanium implant surface. In: Davies JE, ed. *Bone Engineering*. Toronto: em squared, inc., 2000: 163
- 26 **Vidalain JP**. Twenty-year results of the cementless Corail stem. *Int Orthop* 2011; **35**: 189-194 [PMID: 20814676 DOI: 10.1007/s00264-010-1117-2]
- 27 **Chambers B**, St Clair SF, Froimson MI. Hydroxyapatite-coated tapered cementless femoral components in total hip arthroplasty. *J Arthroplasty* 2007; **22**: 71-74 [PMID: 17570282]
- 28 **Yoshihara Y**, Shiromoto Y, Kaneko M, Kono T, Ohashi K, Morita M. Change of bone absorption of proximal femur after AML: a cementless total hip arthroplasty. *Nippon Jinko Kansetsu Gakkaishi* 2006; **36**: 92
- 29 **Kallala R**, Anderson P, Morris S, Haddad FS. The cost analysis of cemented versus cementless total hip replacement operations on the NHS. *Bone Joint J* 2013; **95-B**: 874-876 [PMID: 23814235 DOI: 10.1302/0301-620X.95B7.26931]
- 30 **Yates P**, Serjeant S, Rushforth G, Middleton R. The relative cost of cemented and uncemented total hip arthroplasties. *J Arthroplasty* 2006; **21**: 102-105 [PMID: 16446193]

P- Reviewer: Maheshwari AV, Yamaguchi M  
S- Editor: Ji FF L- Editor: A E- Editor: Wu HL





## WJO 5<sup>th</sup> Anniversary Special Issues (5): Knee

# Degenerative meniscus: Pathogenesis, diagnosis, and treatment options

Richard Howell, Neil S Kumar, Nimit Patel, James Tom

Richard Howell, Neil S Kumar, Nimit Patel, James Tom, Department of Orthopedic Surgery, Drexel University College of Medicine, Hahnemann University Hospital, Philadelphia, PA 19102, United States

**Author contributions:** Howell R, Kumar NS, Patel N and Tom J designed the research, performed the research, analyzed the data; Howell R, Kumar NS and Patel N wrote the paper; all the authors approved the final manuscript.

**Correspondence to:** Richard Howell, MD, Department of Orthopedic Surgery, Drexel University College of Medicine, Hahnemann University Hospital, 245 N. 15th Street, Philadelphia, PA 19102, United States. [howellrichards@gmail.com](mailto:howellrichards@gmail.com)

Telephone: +1-215-7622663 Fax: +1-215-7622663

Received: January 24, 2014 Revised: April 6, 2014

Accepted: July 17, 2014

Published online: November 18, 2014

fractory to conservative therapy, arthroscopic partial meniscectomy can provide short-term gains regarding pain relief, especially when combined with an effective, regular physiotherapy program. Patients with clear mechanical symptoms and meniscal pathology may benefit from arthroscopic partial meniscectomy, but surgery is not a guaranteed success, especially with concomitant articular pathology. Ultimately, the long-term outcomes of either treatment arm provide similar results for most patients. Further study is needed regarding the short and long-term outcomes regarding conservative and surgical therapy, with a particular focus on the economic impact of treatment as well.

© 2014 Baishideng Publishing Group Inc. All rights reserved.

**Key words:** Meniscus; Degenerative joint disease; Meniscal tear; Osteoarthritis; Arthroscopy

## Abstract

The symptomatic degenerative meniscus continues to be a source of discomfort for a significant number of patients. With vascular penetration of less than one-third of the adult meniscus, healing potential in the setting of chronic degeneration remains low. Continued hoop and shear stresses upon the degenerative meniscus results in gross failure, often in the form of complex tears in the posterior horn and midbody. Patient history and physical examination are critical to determine the true source of pain, particularly with the significant incidence of simultaneous articular pathology. Joint line tenderness, a positive McMurray test, and mechanical catching or locking can be highly suggestive of a meniscal source of knee pain and dysfunction. Radiographs and magnetic resonance imaging are frequently utilized to examine for osteoarthritis and to verify the presence of meniscal tears, in addition to ruling out other sources of pain. Non-operative therapy focused on non-steroidal anti-inflammatory drugs and physical therapy may be able to provide pain relief as well as improve mechanical function of the knee joint. For patients re-

**Core tip:** The healing potential of chronic degenerative menisci remains poor. Persistent hoop and shear stresses create complex tears in the posterior horn and midbody. Conservative treatment with anti-inflammatory medications and physical therapy may provide pain relief and improve mechanical knee function. For patients refractory to conservative therapy, arthroscopic partial meniscectomy can provide short-term pain relief when combined with a physiotherapy program. Surgery, however, is not a guaranteed success, especially in the presence of articular pathology. Long-term outcomes of surgical or non-surgical treatment have been shown to be similar for most patient subsets.

Howell R, Kumar NS, Patel N, Tom J. Degenerative meniscus: Pathogenesis, diagnosis, and treatment options. *World J Orthop* 2014; 5(5): 597-602 Available from: URL: <http://www.wjgnet.com/2218-5836/full/v5/i5/597.htm> DOI: <http://dx.doi.org/10.5312/wjo.v5.i5.597>

## INTRODUCTION

Of the multitude of etiologies for knee pain, meniscal degeneration plays a significant role. The meniscus degenerates microscopically and macroscopically with the aging process, resulting in pain and knee dysfunction. This paper reviews the degenerative process of the meniscus as well as diagnostic modalities and treatment options.

## ANATOMY

### Gross anatomy

The human menisci are C-shaped or semicircular fibrocartilaginous structures with bony attachments on the tibial plateau. The menisci are essential for joint stability, shock absorption, distribution of contact forces, joint lubrication, and proprioception<sup>[1]</sup>. The medial meniscus is C-shaped, approximately 3 cm wide, and 4 to 5 cm long<sup>[2]</sup>. The posterior horn is larger than the anterior horn and various studies have described the different bony attachments. The anterior horn of the medial meniscus generally has a firm, bony attachment. Studies have shown that 3%-14% of medial menisci have no bony attachment for the anterior horn<sup>[3,4]</sup>. The insertion of the posterior horn lies anterior to the posterior cruciate ligament. The capsular attachments of the medial meniscus onto the tibia are known as the coronary ligaments, with a thickening along the midportion referred to as the deep medial collateral ligament<sup>[5]</sup>.

The lateral meniscus is semicircular in shape and covers a larger portion of the tibial articular surface than the medial meniscus. It is approximately 3 cm wide and 3 to 4 cm in length<sup>[2]</sup>. The lateral meniscus is anchored anteriorly and posteriorly; however, the capsular attachment is not as well developed as the medial side. As a result, there is increased translation and movement of the lateral meniscus throughout all ranges of motion<sup>[6]</sup>. The anterior horn inserts just adjacent to the anterior cruciate ligament. The posterior horn inserts behind the intercondylar eminence, anterior to the insertion site of the posterior horn of the medial meniscus. The posterior horn also has menisiofemoral ligaments known as the ligament of Humphries and ligament of Wrisberg, which connect posterior horn to the lateral aspect of the medial femoral condyle<sup>[7]</sup>.

### Microstructure and composition

Water makes up approximately 70%-75% of the normal meniscus<sup>[8]</sup>. The dry weight is comprised of collagen (60%-70%), noncollagenous proteins such as elastin (8%-13%), and proteoglycans (1%). The majority of collagen is type I (90%) with type II, III, V, and VI making up smaller amounts<sup>[8,9]</sup>. The orientation of collagen fibers is predominantly circumferential. A smaller amount of radially oriented fibers are located at the surface. In addition, a collagen fibrillar network organized into a mesh like matrix is at the surface to aid in distribution of shear forces<sup>[8,9]</sup>.

Fibrochondrocytes are the predominant cell type in

the meniscus, producing collagen and its extracellular matrix<sup>[8,9]</sup>. Along the inner avascular zone, cells are morphologically similar to articular chondrocytes; on the periphery, cells are more similar to fibroblasts. Arnoczky *et al.*<sup>[10]</sup> demonstrated that the outer 10% to 30% of the medial meniscus and 10% to 25% of the lateral meniscus is vascular. The medial and lateral geniculate arteries form a perimeniscal capillary plexus that supplies the outer surface of the menisci. The menisci have intrinsic innervation, which is most abundant on the periphery and the anterior and posterior horns<sup>[9]</sup>. Proprioception is believed to be obtained from free nerve endings that are activated on the anterior and posterior horns during flexion and extension of the knee<sup>[11,12]</sup>.

### Tear types

Meniscal tears can be classified as acute or degenerative. Acute tears are from excessive force applied to a normal knee and meniscus. This is different from a degenerative tear, which results from repetitive normal forces acting upon a worn down meniscus. Tears can also be described based on pattern and location. These tear patterns include vertical longitudinal, oblique, transverse (radial), horizontal, meniscal root, bucket-handle, and complex. Tears can be located in the avascular or vascular zone (*i.e.*, white, red-white, red-red), which influences healing potential either spontaneously or after surgical repair<sup>[13]</sup>. Degenerative tears generally have a complex tear pattern and are predominantly found in the posterior horn and midbody<sup>[14]</sup>. Previous studies have shown an increase in articular cartilage changes in the presence of degenerative meniscal tears<sup>[15,16]</sup>. In 44 patients, Mesiha *et al.*<sup>[17]</sup> showed that degenerative meniscal tears were associated with the presence of Outerbridge II chondral degeneration more than 85% of the time, compared to 12% for flap tears and 0% for longitudinal tears. Likewise, in a prospective study of 497 consecutive knee arthroscopies in patients with meniscus tears, Christoforakis *et al.*<sup>[18]</sup> found that patients with complex or horizontal tears were significantly more likely to have Outerbridge types III and IV chondral lesions. Additionally, patients with complex tears were significantly more likely to have a second chondral lesion than patients with flap, radial, or bucket handle tears. The literature; however, is not conclusive. In a multicenter cohort study, Badlani *et al.*<sup>[19]</sup> showed that the rate of medial meniscus degenerative tear was not significantly higher in those who developed osteoarthritis. However, meniscal extrusion and tears with a large radial involvement were, in fact, significantly associated with osteoarthritis. Osteoarthritis and degenerative meniscal tears share many of the same risk factors and biological processes. Therefore, it is difficult to definitively determine if one condition precedes the other, or if they both occur independently and/or simultaneously.

## DIAGNOSIS

### Presentation

Degenerative meniscal pathology typically presents as

knee pain accompanied by mechanical symptoms. Patients are typically over the age of 30 and often complain of insidious onset of symptoms with no known traumatic event. One should have a low threshold to consider meniscal injury in patients with knee osteoarthritis; Wang *et al*<sup>[20]</sup> diagnosed a 40% concomitant prevalence determined by arthroscopy. Typical mechanical symptoms include painful clicking, popping, locking, catching, and giving way. In addition, Lange *et al*<sup>[21]</sup> found meniscus tears to result in decreased walking endurance and balance performance.

### Physical exam

Several findings are suggestive of meniscus injury including joint line tenderness, positive McMurray's test, locking, and palpable or audible clicking. The examiner should also examine the contralateral knee for comparison. Initial visual inspection of the knee should investigate for evidence of infection or trauma, such as erythema, wound, ecchymosis, or gross deformity. Patients with degenerative meniscus pathology rarely present with joint effusion, unlike after acute meniscus or ligamentous injury. Range of motion may be decreased due to a physical block caused by displaced meniscal material. Most often, passive and active range of motion is full and equivalent to the contralateral knee. With range of motion, clicking may be heard or felt; this is suggestive of meniscal pathology, although osteoarthritis, patella-femoral syndrome, and loose bodies also cause this sign. Joint line tenderness and a positive McMurray test are described as highly suggestive of meniscus injury, though study results vary regarding their sensitivity and specificity. Joint line tenderness sensitivity ranges from 63%-87%, while specificity ranges from 30%-50%<sup>[22,23]</sup>. A positive McMurray test has a sensitivity of 32%-34% and specificity of 78%-86%<sup>[22,23]</sup>. Ercin *et al*<sup>[24]</sup> found physical examination by an experienced practitioner to have better specificity (90% *vs* 60%), positive predictive value (95% *vs* 83%), negative predictive value (90% *vs* 86%), and diagnostic accuracy (93% *vs* 83%) than MRI for medial meniscal tears. They assert that physical examination is sufficient to diagnose a meniscus tear and proceed with arthroscopy. Currently, however, most surgeons choose to obtain advanced imaging prior to arthroscopy.

### Radiology

Radiographic examination of the knee is of limited value in the patient suffering from degenerative meniscal pathology, as the menisci are not visualized with standard radiography. This modality is primarily used to exclude other sources of knee pain, such as osteoarthritis, which frequently occurs concurrently with meniscal degeneration. Traditionally, sonography has had low utilization as a tool in the diagnosis of degenerative meniscal pathology. However, De Flaviis *et al*<sup>[25]</sup> reported dynamic ultrasound to have 82% sensitivity for detecting degenerative meniscus changes based upon findings of border irregularity, cystic cavities, or calcification. Rutten *et al*<sup>[26]</sup> reported a sensitivity, specificity, and accuracy of sonography in the depiction of meniscal cysts as 97%, 86% and 94%,

respectively. The accuracy of ultrasound is dependent on technologist skill. In addition, sonography cannot examine deep structures of the knee with high accuracy. In centers where dynamic sonography is available and the patient's clinical presentation is specific for meniscal pathology, ultrasound presents a viable cost saving option.

Ultimately, magnetic resonance imaging (MRI) is the gold standard for soft-tissue imaging of the knee. MRI has an accuracy of 90%-95% for detecting meniscal injury<sup>[27]</sup>. Meniscal structure is well evaluated on proton density and T1 sequencing, while pathology is best identified on T2 sequencing. MRI signal changes indicative of meniscus pathology are graded I through III<sup>[28]</sup>. Grade I signal change is intrasubstance, globular, and does not intersect the articular surface. Grade II signal change is intrasubstance, linear, and does not intersect the articular surface. Grade I and II signal changes represent intrasubstance degeneration in adults or vascularity in children. Traditionally, grade I and II changes were not thought to correlate with a true tear. However, recent studies have found that some grade II changes may represent a true tear<sup>[29]</sup>. Grade III changes intersect the superior or inferior articular surface, or both, and represent a true tear. von Engelhardt *et al*<sup>[29]</sup> evaluated the sensitivity and specificity of 3 Tesla MRI using arthroscopy as the reference standard. It was found that accuracy varied based upon lesion grade. Grade I lesions identified by MRI were not associated with a torn meniscus at arthroscopy. In 24% of patients with a Grade II lesion, a true tear was identified by arthroscopy. Grade III lesions had an overall sensitivity and specificity of 79% and 95%, respectively: 86% and 100%, respectively, for the medial meniscus, and 57% and 92%, respectively, for the lateral meniscus. It should be noted that an MRI obtained postoperatively may be less accurate secondary to post surgical changes<sup>[27]</sup>. One must always remember to evaluate and treat the patient based upon the clinical presentation along with diagnostic findings, not by imaging alone. Fukuta *et al*<sup>[30]</sup> found a 50% incidence of grade III signal changes in clinically asymptomatic patients over the age of forty with osteoarthritis. Thus, the finding of a meniscal tear on MRI in a patient without clinical symptoms should not prompt the surgeon to proceed with arthroscopy.

## TREATMENT

Conservative and surgical modalities can be utilized in the treatment of the painful degenerative meniscal tear. No matter the method, the ultimate goal remains the same: to relieve acute symptomology and limit future recurrence. Nonoperative therapy is often times the mainstay of treatment, while surgical procedures are reserved for patients with symptoms resistant or recurrent to conservative management.

### Non-operative therapy

The initial focus of non-surgical supportive care is the relief of knee pain. Patients should limit activities that instigate or exacerbate symptoms, however complete rest is

not advised, as stiffness may result. Patients often present with incomplete symptom relief after non-steroidal anti-inflammatory drug (NSAID) use on an as-needed basis. If tolerable, such cases may warrant routine use over a period of up to 6 wk. Muscle relaxants and analgesics can also be used, although usually for a shorter period of time. Physical therapy and rehabilitation is a central aspect of conservative treatment, with exercises focused on maintaining range of motion (ROM), improve hip and hamstring flexibility, increase quadriceps and hip strength, and retain knee proprioception. Gait therapy, whether by exercise or supportive orthoses, may also improve knee function and provide pain relief<sup>[31]</sup>. A supervised exercise regimen lasting 8 to 12 wk, when combined with a home program, can provide immediate short-term benefits. In a small series, Østerås *et al.*<sup>[32]</sup> reported that with 36 sessions over a 3 mo period improved pain scores, quality-of-life scores, and reduced anxiety at 3 mo follow-up. Stensrud *et al.*<sup>[33]</sup> described a 3 mo protocol focused on dynamic neuromuscular training, which resulted in improved patient-reported outcomes and muscle performance up to 1 year. Physiotherapy can also reduce mechanical symptoms in addition to providing pain relief. In a prospective trial, 52 patients with degenerative meniscal tear underwent an exercise regimen; mechanical symptoms and knee pain were significantly reduced at final 2 year follow-up, even despite some advancement of osteoarthritic degeneration<sup>[34]</sup>. The benefits of physical therapy, even with radiographic evidence of worsening degeneration, has been found in studies with up to 3 year follow-up<sup>[35,36]</sup>. Herrlin *et al.*<sup>[37]</sup> followed 47 patients in a prospective trial up to 5 years. Visual analog scale (VAS) scores and knee function significantly improved at 2 and 5 years, however no difference was found between these two follow-up points. Ultimately, a regimented physiotherapy program can reduce knee pain and improve function in the presence of degenerative joint disease progression.

### Arthroscopic partial meniscectomy

While non-operative therapy provides some degree of symptom relief over the long-term, these benefits may wane with continued meniscal degeneration<sup>[38]</sup>. In such patients, arthroscopic partial meniscectomy can be effective in improving patient quality of life. A thorough arthroscopic examination of the chondral surfaces, joint spaces, and menisci are critical to document cartilage health, identify loose bodies, and localize meniscal tears. Partial meniscectomy attempts to debride the unstable degenerative tear in order to create a stable tear or a smooth rim of the remaining meniscus. The surgeon is tasked to remove the meniscal tear while simultaneously maintaining as much healthy meniscus as possible. Meniscectomy undoubtedly alters joint biomechanics; excessive debridement may lead to unnecessary load-induced chondral wear and shear-induced subchondral fracture, furthering joint and meniscal degeneration<sup>[39]</sup>. Relief from knee pain and improvement of function can be obtained quickly, as soon as 3 mo post-operatively<sup>[32]</sup>. Yim *et al.*<sup>[34]</sup> found significant improvement in knee pain, knee function,

and patient satisfaction scores in 50 patients at 2 years after arthroscopic partial meniscectomy; these results, however, were tempered by the finding that there was no difference at final follow-up in comparison with non-operatively treated patients. In another prospective study, Herrlin *et al.*<sup>[37]</sup> noted significant improvement in VAS and knee function scores up to 5 years post-operatively. They also found that a significant portion, one-third, of patients treated non-operatively required arthroscopy secondary to incomplete pain relief. Similar to Yim *et al.*<sup>[34]</sup>, however, Herrlin *et al.*<sup>[37]</sup> found no difference in pain and function scores at any point between operatively and nonoperatively treated patients. At this juncture, the long-term value of arthroscopic partial meniscectomy compared to non-operative physiotherapy is unknown.

### Post-operative rehabilitation

Most surgeons recommend a program of physical therapy post-operatively to reduce pain and swelling, promote full range-of-motion, and improve knee function. Modalities such as icing, joint mobilization, and massage can provide short-term pain relief and reduce swelling<sup>[40]</sup>. Beyond the immediate postoperative symptoms, extensor weakness remains the primary concern after surgical treatment of the degenerative meniscal tear. Moffet *et al.*<sup>[41]</sup> described the importance of physical therapy focused on extensor weakness, findings significant benefits in 31 patients. Østerås *et al.*<sup>[42]</sup> described a specific 3 mo postoperative rehabilitation program in a prospective study utilizing bicycling, resisted quadriceps exercises, and squats. They noted better pain relief, knee function, and strength at 1 year compared to patients without postoperative physiotherapy. Even with dedicated rehabilitation, recovery or preoperative extensor strength may take 4 to 6 wk, and can still be deficient compared to the non-operative extremity<sup>[43]</sup>. This discrepancy may place the active patient at risk for injury on return to sporting activity. Generally, the active patient may return to practice at 80% strength, typically 3 to 6 wk postoperatively, and return to game competition at 90% strength, typically 5 to 8 wk postoperatively<sup>[40,44]</sup>.

## CONCLUSION

The symptomatic degenerative meniscus continues to be a source of discomfort for a significant number of patients. Patients with clear mechanical symptoms and meniscal pathology may benefit from arthroscopic partial meniscectomy, but surgery is not a guaranteed success, especially with concomitant articular pathology. Patient history, physical examination, and radiographic imaging are critical to determine the true source of pain, meniscus or cartilage degeneration, and to eliminate other potential aggravants. Non-operative therapy focused on NSAID anti-inflammatories and physical therapy may be able to provide pain relief as well as improve mechanical function of the knee joint. For patients refractory to conservative therapy, arthroscopic partial meniscectomy can provide short-term gains regarding pain relief, es-



pecially when combined with an effective, regular physiotherapy program. Ultimately, the long-term outcomes of either treatment arm provide similar results for most patients. Further study is needed regarding the short and long-term outcomes regarding conservative and surgical therapy, with a particular focus on the economic impact of treatment as well.


## REFERENCES

- 1 **Fithian DC**, Kelly MA, Mow VC. Material properties and structure-function relationships in the menisci. *Clin Orthop Relat Res* 1990; **(252)**: 19-31 [PMID: 2406069]
- 2 **Athanasίου KA**, Sanchez-Adams J. Engineering The Knee Meniscus. *Synthesis Lectures Tissue Eng* 2009; **1**: 1-97 [DOI: 10.2200/S00186ED1V01Y200903TIS001]
- 3 **Berlet GC**, Fowler PJ. The anterior horn of the medical meniscus. An anatomic study of its insertion. *Am J Sports Med* 1998; **26**: 540-543 [PMID: 9689375]
- 4 **Nelson EW**, LaPrade RF. The anterior intermeniscal ligament of the knee. An anatomic study. *Am J Sports Med* 2000; **28**: 74-76 [PMID: 10653547]
- 5 **Johnson DL**, Swenson TM, Livesay GA, Aizawa H, Fu FH, Harner CD. Insertion-site anatomy of the human menisci: gross, arthroscopic, and topographical anatomy as a basis for meniscal transplantation. *Arthroscopy* 1995; **11**: 386-394 [PMID: 7575868]
- 6 **Thompson WO**, Thaete FL, Fu FH, Dye SF. Tibial meniscal dynamics using three-dimensional reconstruction of magnetic resonance images. *Am J Sports Med* 1991; **19**: 210-215; discussion 215-216 [PMID: 1867329]
- 7 **de Abreu MR**, Chung CB, Trudell D, Resnick D. Menis-cofemoral ligaments: patterns of tears and pseudotears of the menisci using cadaveric and clinical material. *Skeletal Radiol* 2007; **36**: 729-735 [PMID: 17483944 DOI: 10.1007/S00256-007-0298-2]
- 8 **McDevitt CA**, Webber RJ. The ultrastructure and biochemis-try of meniscal cartilage. *Clin Orthop Relat Res* 1990; **(252)**: 8-18 [PMID: 2406077]
- 9 **Fox AJ**, Bedi A, Rodeo SA. The basic science of human knee menisci: structure, composition, and function. *Sports Health* 2012; **4**: 340-351 [PMID: 23016106 DOI: 10.1177/1941738111429419]
- 10 **Arnoczky SP**, Warren RF. Microvasculature of the human meniscus. *Am J Sports Med* 1982; **10**: 90-95 [PMID: 7081532]
- 11 **O'Connor BL**. The mechanoreceptor innervation of the pos-terior attachments of the lateral meniscus of the dog knee joint. *J Anat* 1984; **138** (Pt 1): 15-26 [PMID: 6706833]
- 12 **O'Connor BL**, McConnaughey JS. The structure and in-nerivation of cat knee menisci, and their relation to a "sen-sory hypothesis" of meniscal function. *Am J Anat* 1978; **153**: 431-442 [PMID: 707322 DOI: 10.1002/Aja.1001530306]
- 13 **Laible C**, Stein DA, Kiridly DN. Meniscal repair. *J Am Acad Orthop Surg* 2013; **21**: 204-213 [PMID: 23545726 DOI: 10.5435/Jaaos-21-04-204]
- 14 **Metcalfe RWBR**, Metcalf MS, McGinty JB. Arthroscopic Meniscectomy. In: McGinty JB CR, Jackson RW, Poehling GG Editor Operative Arthroscopy. 2 Ed. Philadelphia, PA: Lippincott-Raven, 1996: 263-297
- 15 **Englund M**. Meniscal tear--a feature of osteoarthritis. *Acta Orthop Scand Suppl* 2004; **75**: 1-45, backcover [PMID: 15188684]
- 16 **Englund M**, Roos EM, Roos HP, Lohmander LS. Patient-rel-levant outcomes fourteen years after meniscectomy: influence of type of meniscal tear and size of resection. *Rheumatology (Oxford)* 2001; **40**: 631-639 [PMID: 11426019]
- 17 **Mesiha M**, Zurakowski D, Soriano J, Nielson JH, Zarins B, Murray MM. Pathologic characteristics of the torn human meniscus. *Am J Sports Med* 2007; **35**: 103-112 [PMID: 17092929 DOI: 10.1177/0363546506293700]
- 18 **Christoforakis J**, Pradhan R, Sanchez-Ballester J, Hunt N, Strachan RK. Is there an association between articular cartilage changes and degenerative meniscus tears? *Ar-throscopy* 2005; **21**: 1366-1369 [PMID: 16325089 DOI: 10.1016/J.Arthro.2005.08.031]
- 19 **Badlani JT**, Borrero C, Golla S, Harner CD, Irrgang JJ. The effects of meniscus injury on the development of knee osteo-arthritis: data from the osteoarthritis initiative. *Am J Sports Med* 2013; **41**: 1238-1244 [PMID: 23733830 DOI: 10.1177/0363546513490276]
- 20 **Wang DW**, Cai X, Liu YJ, Wang ZG, Gao L. Meniscus injury in osteoarthritis of knee joints: under arthroscopy. *Zhonghua Yixue Zazhi* 2005; **85**: 2425-2427 [PMID: 16321252]
- 21 **Lange AK**, Fiatarone Singh MA, Smith RM, Foroughi N, Baker MK, Shnier R, Vanwanseele B. Degenerative meniscus tears and mobility impairment in women with knee osteo-arthritis. *Osteoarthritis Cartilage* 2007; **15**: 701-708 [PMID: 17207645 DOI: 10.1016/J.Joca.2006.11.004]
- 22 **Galli M**, Ciriello V, Menghi A, Aulisa AG, Rabini A, Marzet-ti E. Joint line tenderness and McMurray tests for the detec-tion of meniscal lesions: what is their real diagnostic value? *Arch Phys Med Rehabil* 2013; **94**: 1126-1131 [PMID: 23154135 DOI: 10.1016/J.Apmr.2012.11.008]
- 23 **Couture JF**, Al-Juhani W, Forsythe ME, Lenczner E, Marien R, Burman M. Joint line fullness and meniscal pathology. *Sports Health* 2012; **4**: 47-50 [PMID: 23016068 DOI: 10.1177/1941738111422330]
- 24 **Ercin E**, Kaya I, Sungur I, Demirbas E, Ugras AA, Cetinus EM. History, clinical findings, magnetic resonance imaging, and arthroscopic correlation in meniscal lesions. *Knee Surg Sports Traumatol Arthrosc* 2012; **20**: 851-856 [PMID: 21833511 DOI: 10.1007/S00167-011-1636-4]
- 25 **De Flaviis L**, Scaglione P, Nessi R, Albisetti W. Ultrasound in degenerative cystic meniscal disease of the knee. *Skeletal Radiol* 1990; **19**: 441-445 [PMID: 2218594]
- 26 **Rutten MJ**, Collins JM, van Kampen A, Jager GJ. Meniscal cysts: detection with high-resolution sonography. *AJR Am J Roentgenol* 1998; **171**: 491-496 [PMID: 9694482 DOI: 10.2214/Ajr.171.2.9694482]
- 27 **Sanders TG**, Miller MD. A systematic approach to magnetic resonance imaging interpretation of sports medicine inju-ries of the knee. *Am J Sports Med* 2005; **33**: 131-148 [PMID: 15611010]
- 28 **Low AK**, Chia MR, Carmody DJ, Lucas P, Hale D. Clinical significance of intrasubstance meniscal lesions on MRI. *J Med Imaging Radiat Oncol* 2008; **52**: 227-230 [PMID: 18477116 DOI: 10.1111/J.1440-1673.2008.01951.X]
- 29 **von Engelhardt LV**, Schmitz A, Pennekamp PH, Schild HH, Wirtz DC, von Falkenhausen F. Diagnostics of degenera-tive meniscal tears at 3-Tesla MRI compared to arthroscopy as reference standard. *Arch Orthop Trauma Surg* 2008; **128**: 451-456 [PMID: 17968565 DOI: 10.1007/S00402-007-0485-6]
- 30 **Fukuta S**, Kuge A, Korai F. Clinical significance of meniscal abnormalities on magnetic resonance imaging in an older population. *Knee* 2009; **16**: 187-190 [PMID: 19179080 DOI: 10.1016/J.Knee.2008.11.006]
- 31 **Elbaz A**, Beer Y, Rath E, Morag G, Segal G, Debbi EM, Was-ser D, Mor A, Debi R. A unique foot-worn device for patients with degenerative meniscal tear. *Knee Surg Sports Traumatol Arthrosc* 2013; **21**: 380-387 [PMID: 22555568 DOI: 10.1007/S00167-012-2026-2]
- 32 **Østerås H**, Østerås B, Torstensen TA. Medical exercise ther-apy, and not arthroscopic surgery, resulted in decreased de-pression and anxiety in patients with degenerative meniscus injury. *J Bodyw Mov Ther* 2012; **16**: 456-463 [PMID: 23036877 DOI: 10.1016/J.Jbmt.2012.04.003]
- 33 **Stensrud S**, Roos EM, Risberg MA. A 12-week exercise therapy program in middle-aged patients with degenerative

- meniscus tears: a case series with 1-year follow-up. *J Orthop Sports Phys Ther* 2012; **42**: 919-931 [PMID: 22960783 DOI: 10.2519/Jospt.2012.4165]
- 34 **Yim JH**, Seon JK, Song EK, Choi JI, Kim MC, Lee KB, Seo HY. A comparative study of meniscectomy and nonoperative treatment for degenerative horizontal tears of the medial meniscus. *Am J Sports Med* 2013; **41**: 1565-1570 [PMID: 23703915 DOI: 10.1177/0363546513488518]
  - 35 **Neogi DS**, Kumar A, Rijal L, Yadav CS, Jaiman A, Nag HL. Role of nonoperative treatment in managing degenerative tears of the medial meniscus posterior root. *J Orthop Traumatol* 2013; **14**: 193-199 [PMID: 23532300 DOI: 10.1007/S10195-013-0234-2]
  - 36 **Rimington T**, Mallik K, Evans D, Mroczek K, Reider B. A prospective study of the nonoperative treatment of degenerative meniscus tears. *Orthopedics* 2009; **32**: [PMID: 19708634 DOI: 10.3928/01477447-20090624-06]
  - 37 **Herrlin SV**, Wange PO, Lapidus G, Hållander M, Werner S, Weidenhielm L. Is arthroscopic surgery beneficial in treating non-traumatic, degenerative medial meniscal tears? A five year follow-up. *Knee Surg Sports Traumatol Arthrosc* 2013; **21**: 358-364 [PMID: 22437659 DOI: 10.1007/S00167-012-1960-3]
  - 38 **Lim HC**, Bae JH, Wang JH, Seok CW, Kim MK. Non-operative treatment of degenerative posterior root tear of the medial meniscus. *Knee Surg Sports Traumatol Arthrosc* 2010; **18**: 535-539 [PMID: 19711053 DOI: 10.1007/S00167-009-0891-0]
  - 39 **Wilson W**, van Rietbergen B, van Donkelaar CC, Huijskes R. Pathways of load-induced cartilage damage causing cartilage degeneration in the knee after meniscectomy. *J Biomech* 2003; **36**: 845-851 [PMID: 12742452]
  - 40 **Frizziero A**, Ferrari R, Giannotti E, Ferroni C, Poli P, Masiere S. The meniscus tear. State of the art of rehabilitation protocols related to surgical procedures. *Muscles Ligaments Tendons J* 2012; **2**: 295-301 [PMID: 23738313]
  - 41 **Moffet H**, Richards CL, Malouin F, Bravo G. Impact of knee extensor strength deficits on stair ascent performance in patients after medial meniscectomy. *Scand J Rehabil Med* 1993; **25**: 63-71 [PMID: 8341993]
  - 42 **Østerås H**, Østerås B, Torstensen TA. Is postoperative exercise therapy necessary in patients with degenerative meniscus? A randomized controlled trial with one year follow-up. *Knee Surg Sports Traumatol Arthrosc* 2014; **22**: 200-206 [PMID: 23263261 DOI: 10.1007/S00167-012-2354-2]
  - 43 **Matthews P**, St-Pierre DM. Recovery of muscle strength following arthroscopic meniscectomy. *J Orthop Sports Phys Ther* 1996; **23**: 18-26 [PMID: 8749746 DOI: 10.2519/Jospt.1996.23.1.18]
  - 44 **Wheatley WB**, Krome J, Martin DF. Rehabilitation programmes following arthroscopic meniscectomy in athletes. *Sports Med* 1996; **21**: 447-456 [PMID: 8784964]

**P-Reviewer:** Kraniotis P **S-Editor:** Wen LL **L-Editor:** A  
**E-Editor:** Wu HL





## WJO 5<sup>th</sup> Anniversary Special Issues (5): Knee

# Flap reconstruction of the knee: A review of current concepts and a proposed algorithm

Andreas Gravvanis, Antonios Kyriakopoulos, Konstantinos Kateros, Dimosthenis Tsoutsos

Andreas Gravvanis, Antonios Kyriakopoulos, Dimosthenis Tsoutsos, Department of Plastic Surgery-Microsurgery and Burn Center, General State Hospital of Athens "G Gennimatas", 15343 Athens, Greece

Konstantinos Kateros, Orthopedic Surgery Department, General State Hospital of Athens "G Gennimatas", 15343 Athens, Greece

Author contributions: Gravvanis A designed the study and wrote the manuscript; Gravvanis A and Kateros K performed the majority of clinical cases; Kyriakopoulos A and Tsoutsos D contributed to the collection and critical review of the pertinent literature.

Correspondence to: Andreas Gravvanis, MD, PhD, FEBOPRAS, Department of Plastic Surgery-Microsurgery and Burn Center, General State Hospital of Athens "G Gennimatas", Patroklou 10, Agia Paraskevi, 15343 Athens, Greece. [gravvani@yahoo.com](mailto:gravvani@yahoo.com)

Telephone: +30-69-44455575 Fax: +30-21-07709851

Received: January 4, 2014 Revised: July 2, 2014

Accepted: July 15, 2014

Published online: November 18, 2014

flap; Free flap; Recipient vessels

**Core tip:** There is much controversy in the literature regarding the optimal management of skin necrosis around the knee. Muscle coverage remains the standard to which all other flaps should be compared. Perforator flaps have recently represented a true revolution in the soft tissue reconstruction around the knee, with peculiar advantages due to their low donor morbidity and long pedicles. In the case of free flap the choice of recipient vessels is the key point to the reconstruction. With meticulous preoperative planning, by identifying the reconstructive needs and by understanding the reconstructive algorithm, the surgeon should be able to manage knee defects with high success rate.

Gravvanis A, Kyriakopoulos A, Kateros K, Tsoutsos D. Flap reconstruction of the knee: A review of current concepts and a proposed algorithm. *World J Orthop* 2014; 5(5): 603-613 Available from: URL: <http://www.wjgnet.com/2218-5836/full/v5/i5/603.htm> DOI: <http://dx.doi.org/10.5312/wjo.v5.i5.603>

## Abstract

A literature search focusing on flap knee reconstruction revealed much controversy regarding the optimal management of around the knee defects. Muscle flaps are the preferred option, mainly in infected wounds. Perforator flaps have recently been introduced in knee coverage with significant advantages due to low donor morbidity and long pedicles with wide arc of rotation. In the case of free flap the choice of recipient vessels is the key point to the reconstruction. Taking the published experience into account, a reconstructive algorithm is proposed according to the size and location of the wound, the presence of infection and/or 3-dimensional defect.

© 2014 Baishideng Publishing Group Inc. All rights reserved.

**Key words:** Knee reconstruction; Local flap; Pedicled

## INTRODUCTION

The around the knee skin and soft tissue defects represents a challenge to the plastic surgeon. A thin, pliable coverage of the knee joint is a prerequisite to promote wound healing and to any concomitant orthopedic procedure. As a rule, the upper one third of the tibia can be covered effectively with rotational muscle flaps<sup>[1]</sup>. Nevertheless, complex lower limb wounds are best managed with a distant flap, because avoids additional skin incisions to the already damaged with impaired perfusion limb. Moreover, introduces a well-perfused tissue from an uninjured area, thus facilitating wound healing<sup>[2]</sup>. On the other hand, the free tissue transfer is more challenging option for around the knee, due to the difficulties in

recipient vessel selection positioned deeply around the knee<sup>[3]</sup>.

The purpose of this article is to analyze the reconstructive challenges and reconstructive options for around the knee defects and to propose a reconstructive algorithm.

## REVIEW OF THE LITERATURE

The literature search revealed 138 articles related to the reconstruction of soft tissue defects around the knee, whereas 124 articles consider the open and/or infected knee joint salvage with flaps. Thirteen articles are related to the use of local flaps and 51 articles are related to the use of pedicled flaps in peri-knee soft tissue reconstruction. Forty-one articles discuss the use of free flaps whilst 11 articles discuss the recipients' vessels that can be used.

Five review articles have been identified in English literature: 3 related to wound complications in total knee arthroplasty and flap reconstruction<sup>[4-6]</sup>, 1 related to the recipient vessel selection<sup>[3]</sup>, and 1 related to lateral genicular artery flap<sup>[7]</sup>.

One article proposes an algorithm of treatment of the exposed total knee prosthesis<sup>[8]</sup>, but no article has been identified proposing a reconstructive algorithm of the around the knee defects.

## THE CAUSES AND RISK FACTORS OF THE SOFT TISSUE DEFECT AROUND THE KNEE

Apart from posttraumatic defects<sup>[9,10]</sup> and oncological resections<sup>[11-14]</sup> knee soft tissue defects may arise from chronic infection, post surgical radiation<sup>[15]</sup>, or surgical release of postburn flexion contractures<sup>[16]</sup>. Moreover, can be caused by multiple previous operations<sup>[6,17,18]</sup>. Wound complications following total knee arthroplasty can occur up to 20% of patients, and are related to skin/soft tissue necrosis and possible exposure of the implant. Gross infection may lead to loss of the prosthesis or even of the limb<sup>[6,17,19]</sup>.

Risk factors for knee wound complications could be related to the patient's general status and to local wound factors<sup>[20]</sup>. Diabetes is associated with dehiscence and infection<sup>[19]</sup>, smoking is related to bleeding complications and infection<sup>[2]</sup>, obesity may induce dehiscence and deep-venous thrombosis<sup>[2]</sup>.

Local factors predisposing to complications are previous scars, major vessel trauma, hematoma, local infection, tension at the skin closure, and previous irradiated skin<sup>[20]</sup>.

## RECONSTRUCTIVE CHALLENGES

The knee is a hinge type synovial joint, which permits flexion and extension about a transverse axis, and a small medial and lateral rotation about the axis of the lower leg in the flexed position<sup>[21]</sup>. The total range of motion is dependent on several parameters such as active insuffi-

ciency, hamstring tightness and soft-tissue restraints. The overlying skin is thin and pliable with remarkable distensibility. The size of the skin defect should be estimated with the knee at maximum flexion, and the "like tissue replacement" principle should be ideally applied. In other words the defect should be replaced with plenty pliable skin from the adjacent area. In extensive or complex defects local flaps may not be available, therefore it requires either a distant muscle flap<sup>[2]</sup> or microvascular tissue transfers to aid in soft tissue reconstruction<sup>[22,23]</sup>. Distant muscle flaps are associated with variable morbidity and further trauma in the already traumatized limb, but is a fast procedure that requires less reconstructive expertise. Free tissue transfers offers less donor and recipient site morbidity, have the advantage of single stage, but requires expertise and infrastructure<sup>[22]</sup>. However, the main challenge is the proper selection of recipient vessels<sup>[3]</sup>. Some surgeons prefer to choose the suitable recipient vessels first allowing this choice to direct the proper flap choice<sup>[24,25]</sup>. Others advocate the selection of the proper flap first (according the size and depth of the defect), influencing the recipient vessels choice<sup>[26]</sup>. The fact is that in the severely damaged limb the recipient vessel selection is the main challenge and will determine the success of the reconstruction<sup>[3]</sup>.

## OPTIONS OF TREATMENT

The treatment of choice depends on the wound dimensions and geometry, presence of gross contamination and/or infection, and most importantly if there is bone, tendon or implant exposure<sup>[8]</sup>. The options are conservative wound management or debridement with reconstruction in the presence of necrotic tissues<sup>[23,25]</sup>. The cornerstone of the treatment is the thorough debridement and removal of any devitalized and infected tissue and/or infected foreign material.

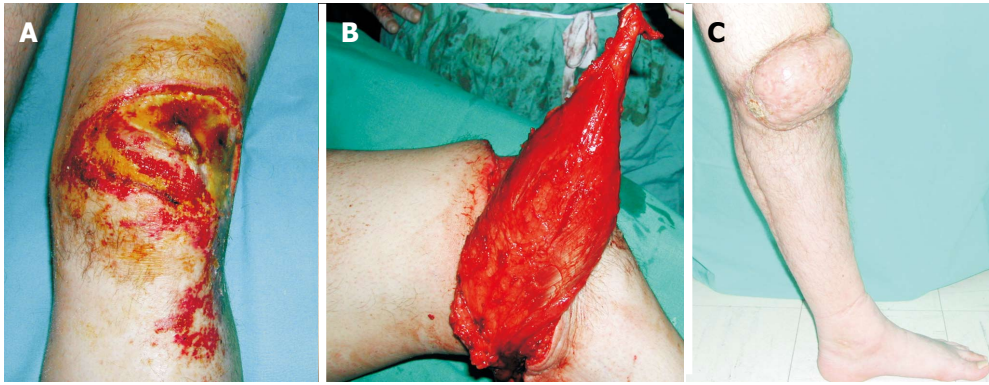
In cases of small split-thickness skin loss, early skin grafting is preferable to secondary healing, in order to avoid hypertrophic or contracted scars. In deep wounds (without exposure of the patella, bone or implant) associating the vacuum assisted closure (VAC) therapy reduces the wound exudate, controls the microbial load and the speeds the granulation tissue formation, thus facilitating secondary skin grafting<sup>[26]</sup>.

Nevertheless, if the resulting defect is deeper with exposed bone or hardware, or infection is documented, a flap is needed<sup>[23]</sup>. If the defect is associated with intra-articular infection, drainage through an arthrotomy and continuous irrigation could be indicated<sup>[27]</sup>.

## LOCAL FASCIOCUTANEOUS AND PERFORATOR FLAPS

Local skin are used in small skin defects (less than 4 cm). The prerequisite is the absence of infection and no bone or prosthesis exposure<sup>[23]</sup>. More recently, local perforator flaps have been used, with significant advantages due to





**Figure 1** A 28-year-old man suffered a postburn unhealed wound around the right knee that was managed with pedicled gastrocnemius flap. A: The exposed patella was associated with flexion contracture; B: A medial gastrocnemius muscle flap was elevated as an island flap based on the medial sural artery. The muscle was freed from its origin and its motor nerve, as well, to allow greater arc of rotation; C: Four weeks postoperatively, gait without external supports was achieved. From the cosmetic point of view, although the muscle was denervated, a bulky pivot point was present that resulted in a cosmetic deformity.

their low donor morbidity and better esthetic outcome<sup>[2]</sup>. Panni *et al*<sup>[4]</sup>, in their review paper, emphasized on the use of a flap from the inferomedial thigh based on perforators arising from the descending genicular artery. The preoperative investigation of the perforator vessels with color doppler is essential<sup>[28]</sup>. Occasionally the flap may suffer from venous congestion, and an additional venous microanastomosis with a local vein could be valuable. The flap presents wide arc of rotation and may cover the whole knee<sup>[29]</sup>.

## PEDICLED MUSCLE AND MUSCULOCUTANEOUS FLAPS

Pedicled muscle and musculocutaneous flaps still represent the workhorse for coverage of knee defects, because of the straightforwardness, and are specifically indicated more complex soft defects with joint and/or prosthesis exposure. Muscle flaps obliterate the three-dimensional defect and provide rich blood supply to the wound that facilitates the antibiotics delivery.

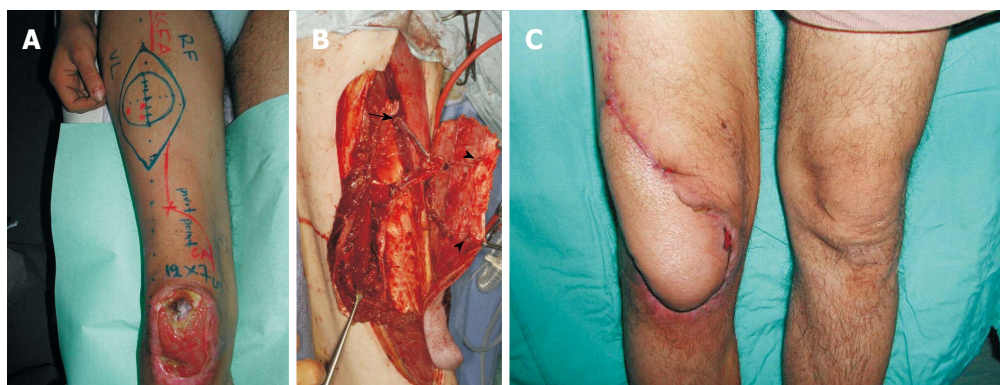
Although, gastrocnemius flap was introduced since 1978<sup>[30]</sup> is still the most commonly used flap for knee coverage, due to its reliable axial blood supply and ease of dissection. The gastrocnemius flap is a type I (single vascular pedicle) according to the Mathe *et al*<sup>[31]</sup> classification with dominant vessel in most patients the medial sural artery. The medial gastrocnemius is greater than the lateral one, with longer vascular pedicle and greater arc of rotation, reaching the knee easily and thus is more frequently used (Figure 1). The lateral gastrocnemius carries the risk of damaging the peroneal nerve while it turns around the neck of the fibula, and is used for lateral knee defects. The medial half musculotendinous unit has been used to reconstruct in one stage the extensor apparatus and to provide soft tissue cover in open knee joint<sup>[10]</sup>. The combined “gastrocnemius with soleus bi-muscle flap” has been introduced for large patella/infrapatella defects, and is based on the perforators of the distal half of the gastrocnemius muscle to the soleus muscle<sup>[32]</sup>.

The soleus muscle (Type II: dominant pedicles branches from popliteal artery, proximal two branches of posterior tibial, proximal two branches of peroneal artery and minor pedicle 3 or 4 segmental branches of the posterior tibial<sup>[31]</sup>), based proximally, can be reliably carried to a point approximately 5 cm above its tendinous insertion, thus to cover the lower portion of the knee<sup>[32]</sup>. The soleus is a “slow” muscle that aids in posture stabilization and slow gait. Transfer even of the entire soleus muscle creates little if any functional deficit. Gastrocnemius flap has been the workhorse in exposed total knee prosthesis with variable but generally good results<sup>[33-35]</sup>.

Recently, gracilis muscle that is also associated with negligible donor site morbidity has been described for knee resurfacing. Gracilis muscle is type II (dominant pedicle medial circumflex femoral artery and minor pedicle 1-2 branches from superficial femoral artery) according to the Mathes and Nahai classification<sup>[31]</sup>. The reversed gracilis pedicle flap has been suggested as a substitute to, or combination with a gastrocnemius for the treatment of large patella or suprapatella defects<sup>[36]</sup>.

The Sartorius muscle flap was first used in 1978 to close an exposed knee joint. The blood supply to this muscle is by numerous segmental vessels from the femoral artery (type IV according to the Mathes and Nahai classification<sup>[31]</sup>), and the main feeding vessel is located about 8 cm below the inguinal ligament<sup>[37]</sup>. The distally based Sartorius is best prefabricated by denervation and vascular delay and then transposed based on the distal pedicle to cover the defect<sup>[38]</sup>. In 2012 Shen *et al*<sup>[39]</sup> presented 12 cases of covering proximal tibia by the sartorius flap based on the rich anatomic network of the descending genicular artery, together with the perforators of the posterior tibial artery and the medial inferior genicular artery.

Arnold *et al*<sup>[40]</sup> in 1981 were the first to publish an article for Vastus medialis flap (type II: dominant pedicle branch from superficial femoral and minor pedicle branches of descending genicular artery<sup>[31]</sup>) to cover an exposed knee joint, and Swartz *et al*<sup>[41]</sup> in 1987 evaluated the blood supply to the vastus lateralis by dye injection



**Figure 2** A 24-year-old man suffered from skin and soft tissue defect over the right knee with exposure of the patella that was managed with a distally based anterolateral thigh flap. A: An anterolateral thigh flap was designed; B: The distally based flap was elevated, based on 2 perforators (arrowheads). Note the 20 cm length of the pedicle (perforator and descending branch of LCFA), as well as, the preservation of the proximal end of the LCFA (arrow) that was added to the flap; C: Satisfactory healing and contour achieved.

techniques in fresh cadaver type II: dominant pedicle descending branch of lateral circumflex femoral artery and minor pedicle branches of lateral superior genicular artery<sup>[31]</sup>). Thereafter, the authors have used successfully the distally based vastus lateralis muscle flap to cover defects above the knee. These two papers were the precursors of distally based antromedial and anteromedial thigh perforator flap, respectively<sup>[40,41]</sup>.

## PEDICLED PERFORATOR FLAPS

Zhang was the first to introduce the reversed anterolateral thigh island flap, and reported that the flap is reliable based on the anastomoses of the lateral superior genicular artery with the descending branch of the lateral circumflex femoris artery<sup>[42]</sup>. Nevertheless, Yildirim *et al.*<sup>[16]</sup> reported that the reliability of the flap is questionable. Gravvanis *et al.*<sup>[43]</sup> comparing the option of distally based ALT *vs* gastrocnemius flap concluded that the technical complexity of the former flap is justified by the greater flexibility of size and shape, and by the better color and texture match. ALT is less bulk as compared to gastrocnemius, has longer arc of rotation to reach above and below the knee defects, and provides enough skin to resurface the whole knee<sup>[44]</sup> (Figure 2). However, the authors emphasized that the reconstructive surgeon should always be alert for vascular compromise of the distally based flap, and thus for flap recharging<sup>[43]</sup>. Later, Gravvanis *et al.*<sup>[45]</sup> presented the successful use of a distally based ALT flap with a venous supercharge, to reconstruct the tibial tuberosity. They recommended the venous supercharging of this flap as a routine procedure because could eliminate any vascular problems<sup>[45]</sup>.

The Anteromedial thigh perforator flap is based on perforator of the descending branch of the lateral circumflex femoris artery that is perforating the rectus femoris muscle (instead of the vastus lateralis in the case of the ALT)<sup>[46]</sup>. As a knee defect coverage was presented in 2010 by Hupkens *et al.*<sup>[47]</sup> in a study on cadavers. Lu *et al.*<sup>[48]</sup> in 2011 applied this flap on eleven cases covering the exposed knee joint.

Peroneal Artery perforator flap based on perforators from the peroneal artery running in the posterior intermuscular septum can be designed and transferred in a propeller fashion to cover inferior knee defects. Yoshimura *et al.*<sup>[49]</sup> in 1985, first described this flap for knee defects and Ruan in 2009 presented the extended peroneal artery perforator (EPAP) flap<sup>[50,51]</sup>. The limitation of the peroneal flap in knee reconstruction is the variable number and location of the perforators. A dominant perforator should be located proximal enough to allow an adequate arc of rotation to cover the knee. Thus, a preoperative study with duplex ultrasound or CT-angiography is mandatory.

Li *et al.*<sup>[52]</sup> in 1990 was the first to describe the coverage of the knee with the lateral sural flap, based on sural cutaneous artery, preserving all the big vessels of the lower leg. Umemoto *et al.*<sup>[53]</sup> followed in 2005, and Shim *et al.*<sup>[54]</sup> in 2006 presented the medial sural artery flap on six patients, covering knee defects.

Nguyen *et al.*<sup>[55]</sup> described on cadaveric studies the lateral supragenicular pedicled perforator flap, and subsequently they used successfully this perforator flap in two patients with exposed knee joint.

Likewise, Rad *et al.*<sup>[56]</sup> described the anterior tibial artery perforator flap on cadavers, and then reported the management of four patients with good results. Adhikari *et al.*<sup>[57]</sup> has used the same flap to reconstruct post-burn flexion contractures in seven patients with excellent outcomes.

The introduction of free-style local perforator flaps<sup>[58]</sup> and propeller flaps<sup>[59]</sup> presented another reliable and predictable technique to cover skin defects over the knee with a low morbidity rate. The method is based on the use of Echo-Doppler Tracing of good perforator vessels around the knee defect and the administration of Free-style supero-medial or supero-lateral flaps<sup>[59]</sup>.

## FREE FLAPS

Free flaps are used for more extensive soft tissue defects. In the case of a complex, three-dimensional defect a free flap is a better option, because it avoids further scarring and trauma to an already injured limb. This well-perfused

tissue from outside the zone of injury brings stability to the wound and promotes healing. When considering free tissue transfer for around the knee defects, the recipient vessel selection is the main difficulty and challenge<sup>[3]</sup>.

## RECIPIENT VESSELS

The use of various vessels has been reported, however each has drawbacks. The popliteal artery, the continuation of the femoral, is the main vessel in the knee region, and divides into anterior tibial, posterior tibial and peroneal. Popliteal artery gives off branches such as sural, superior genicular, middle genicular and the inferior genicular artery. The size, position and depth of the soft tissue loss will change the normal anatomy of the region and will drive the surgeon to different options according to the quality of the available vessels.

The popliteal artery is a reliable choice of recipient vessels<sup>[60]</sup>, but is risky for free tissue transfer to the anterior surface of the knee-joint<sup>[3]</sup> due to potential compression of the vascular pedicle and/or microanastomosis. End-to-side anastomosis is necessary to preserve the distal flow of the major artery, and is associated with limb ischemia during microanastomosis. Tibial arteries can be used as recipient vessels but the anterior tibial artery is frequently involved in trauma as compared with the posterior artery<sup>[61]</sup>. Nevertheless, the smaller branches can reliably provide inflow, thus one does not have to isolate the popliteal or tibial system in the majority of cases.

The sural arteries are two branches that arise from the popliteal artery across the knee joint, and can be used as recipients when popliteal vessels are absent or severely damaged<sup>[62]</sup>. In trauma cases the gastrocnemius muscle heads may protect the sural vessels from injury. Therefore are preserved as reliable recipient vessels to simplify the required microanastomoses in an end-to-end fashion, instead of end-to-side to the popliteal system. Hallock proposed a medial approach to the sural vessels that permits the patient to remain in a supine or lateral position for simultaneous dissection of the donor and recipient site<sup>[63]</sup>. Beumer *et al.*<sup>[24]</sup> has proved that the interruption of medial sural artery has no subsequent functional effect to the gastrocnemius head, and indicated that should be used with confidence as recipient vessel for free flap to the knee.

In either side of the popliteal artery, two superior genicular arteries arise and wind around the femur above the condyles in front of the knee joint. Park *et al.*<sup>[25]</sup> used them successfully in four cases of soft tissue defect in the posterior region of the knee. Rees-Lee *et al.*<sup>[64]</sup> further popularized their use for anterior and medial knee defects. The middle genicular artery arises from the anterolateral surface of the popliteal artery, and generally presents short, intraarticular course. The descending genicular artery arises from the femoral artery and descends between the vastus medialis and the adductor magnus, and is used as a recipient vessel for the anterior knee defects<sup>[25,65]</sup>. Remarkably, Chien *et al.*<sup>[66]</sup> has used this vessel as recipient

for an ALT free flap in reverse flow pattern.

The descending branch of the lateral circumflex femoral vessels can be dissected out and serve as a recipient vessel after being placed adjacent to the defect for free tissue transfer to the difficult areas of the lower extremity<sup>[67-69]</sup> (Figure 3). However, the descending branch has variable anatomy and size, especially at its distal end, thus a meticulous preoperative imaging with duplex ultrasound and/or CT-angiography is mandatory.

The distal superficial femoral arterial branch was used as recipient vessel for a free flap reconstruction involving knee and proximal tibia<sup>[70]</sup>.

Suprafascial perforators of the knee area were also introduced as recipients, but this approach demands advanced microsurgical expertise. The random perforators were traced with Doppler sonography, computer tomography angiography or magnetic resonance angiography in 25 different cases<sup>[71]</sup>.

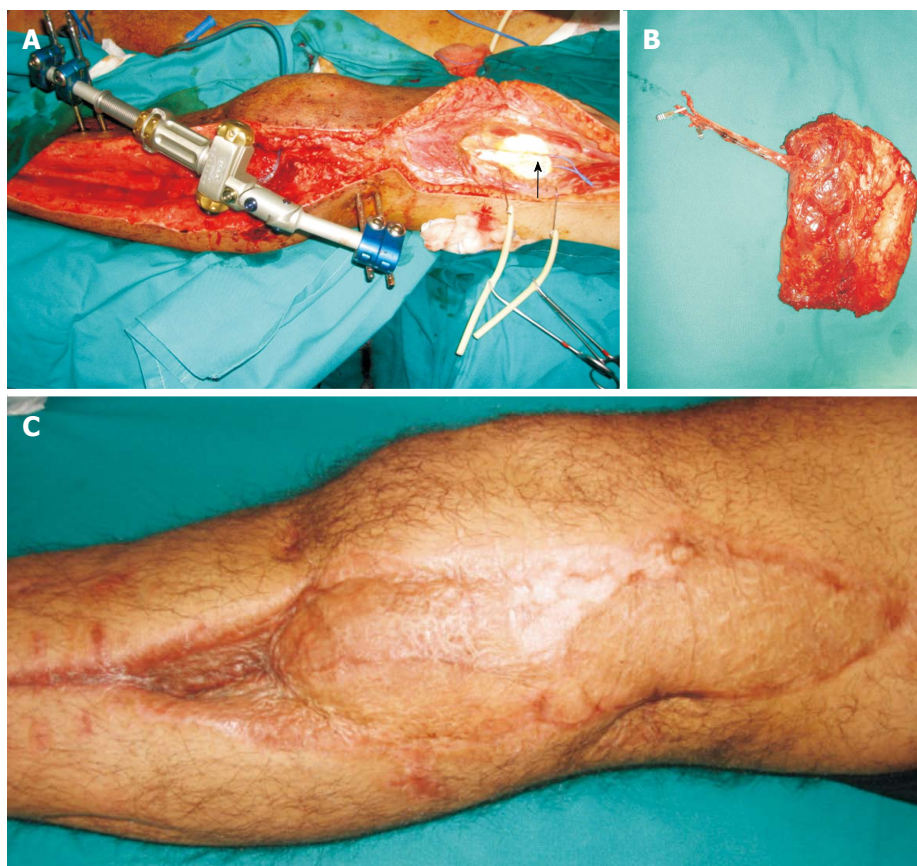
In high-energy injuries all superficial sited vessels may be involved, consequently their use is unreliable. Such cases require the use of vein grafts or long arteriovenous fistulas that are associated with higher failure rate<sup>[72]</sup>. Alternatively, the Superficial Femoral can be used as an ultimate recipient vessel. Gravvanis *et al.*<sup>[73]</sup> described a reproducible technique to use femoral vessels before the adductor canal as recipients (Figure 4). The femoral presents substantial advantages: constant anatomy, ease of dissection and learning curve, and most-importantly well-protected anastomoses that are not positional depended (*e.g.*, cannot be compressed due to the limb's position). The few drawbacks are: deep recipient vessel position that requires long pedicle or long flap to reach the defect and the temporal occlusion of limb's perfusion during anastomoses<sup>[73]</sup>.

## FREE MUSCLE FLAPS

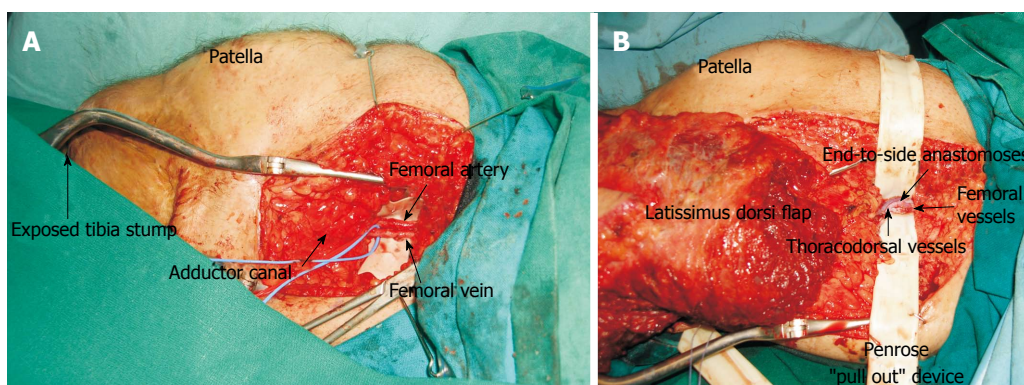
Free muscle flaps traditionally have been used to reconstruct lower extremity defects and are generally covered with skin grafts. They confront better the three-dimensional defect; they control infection and bring stability to the wound. On the other hand they are associated with variable donor site morbidity, and shorter vascular pedicle (as compared to perforator flaps). The latter may restrict the free tissue transfer, given that in the mobile knee area the selection of recipient vessels is critical.

The latissimus dorsi muscle flap (type V: dominant pedicle thoracodorsal artery and secondary segmental branches of posterior intercostal and lumbar artery<sup>[31]</sup>) is probably the most popular free flap in knee coverage, in the literature<sup>[26,74-79]</sup>, followed by rectus abdominis<sup>[76,79]</sup> (type III two dominant pedicles: superior and deep inferior epigastric artery) and fascia lata<sup>[80]</sup> (type I single vascular pedicle: ascending branch of lateral circumflex femoral artery). Rectus femoris muscle as a functional graft for restoration of knee extension and defect coverage after trauma was published by Wechselberger *et al.*<sup>[81]</sup> in 2006. Tibial composite bone and soft tissue defects of





**Figure 3** Patient with anterior compartment syndrome and vascular (femoral-popliteal) bypass, presented with skin and soft tissue defect over the lateral aspect of the knee. A: The descending branch of the lateral circumflex femoral vessels was dissected as recipients (arrow); B: The contralateral vastus lateralis muscle was dissected as a free flap and was anastomosed in end-to-end fashion to the distal end of the descending branch of the lateral circumflex femoral vessels; C: Satisfactory healing and contour achieved.



**Figure 4** The use of superficial femoral vessels as recipient in free tissue transfer for around the knee defects. A: Femoral vessels skeletonised and dissected free from surrounding fat of the area; B: Penrose "pull out" device in place facilitated the end to side anastomoses.

the knee were reconstructed with free composite serratus anterior and rib flaps by Lin *et al*<sup>[82]</sup> in 1997.

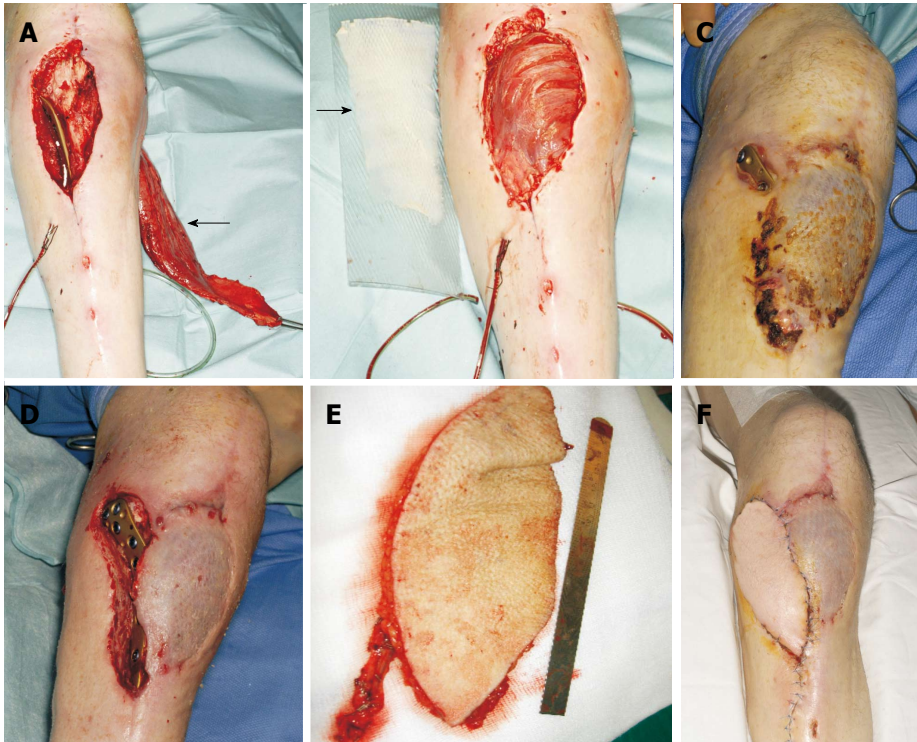
Taking into account the considerable morbidity of the aforementioned flaps, muscles with documented less morbidity can be used in the majority of cases. Vastus lateralis muscle flap<sup>[83]</sup> can be used in extended defects (Figure 3) instead of latissimus dorsi and gracilis muscle<sup>[84]</sup> can be used in smaller defects instead of rectus abdominis. Both muscles can be used as functional muscles

for knee extension.

## FREE PERFORATOR FLAPS

Free perforator flaps are cutaneous flaps without muscle that gave another rebirth to reconstructive surgery. The most commonly used in knee coverage are ALT (anterolateral thigh, Figure 5), TDAP (thoracodorsal artery perforator), and superficial iliac circumflex perforator





**Figure 5** Infrapatellar exposure of a poorly placed plate in a 60-year-old man. A: Due to the questionable viability of the lateral gastrocnemius head, the medial head was dissected (arrow); B: The flap was medially rotated and covered the defect. The muscle was resurfaced with a split-thickness skin graft (arrow); C: Two months later, the plate was exposed in a more proximal position; D: Defect following thorough debridement; E: A free Anterolateral thigh flap based on a single perforator was raised; F: The free flap was anastomosed on end-to-end fashion to the anterior tibial vessels, and a satisfactory healing was achieved.

flap<sup>[85]</sup>. Cavadas *et al*<sup>[86]</sup> reported the use of the medial sural artery perforator free flap and Herrera *et al*<sup>[70]</sup> the superficial artery epigastric flap. Among their advantages are reliability and the long pedicle that enables to easily reach the recipient vessels facilitating microanastomosis. Most importantly, perforator flaps are associated with low donor site morbidity<sup>[87]</sup>, given that no muscle is sacrificed and typically the donor site is closed directly resulting in a linear scar. They present great versatility and adaptability. They can be safely thinned in the plane immediately under the superficial fascia, in order to provide thin pliable coverage. On the other hand, if there is a three-dimensional defect or a grossly contaminated wound, part of the underlying muscle (*e.g.*, vastus lateralis, latissimus dorsi) may be included in a chimeric fashion<sup>[88]</sup>. Most importantly, complex knee trauma with knee joint exposure and patellar tendon deficiency can be reconstructed in a single stage with ALT myocutaneous flap combined with vascularized fascia lata<sup>[88]</sup>.

## RECONSTRUCTIVE ALGORITHM

Successful salvage of the lower extremity following flap reconstruction ranges from 75% to 100%, while salvage of the knee prosthesis is achieved in 75%-85% of patients<sup>[23]</sup>. Although effective treatment options of the exposed knee joint are available today, there is still no universally accepted management. This is mainly due to the lack of soft tissues over the knee joint that precludes the use of local flaps frequently, and due to the challeng-

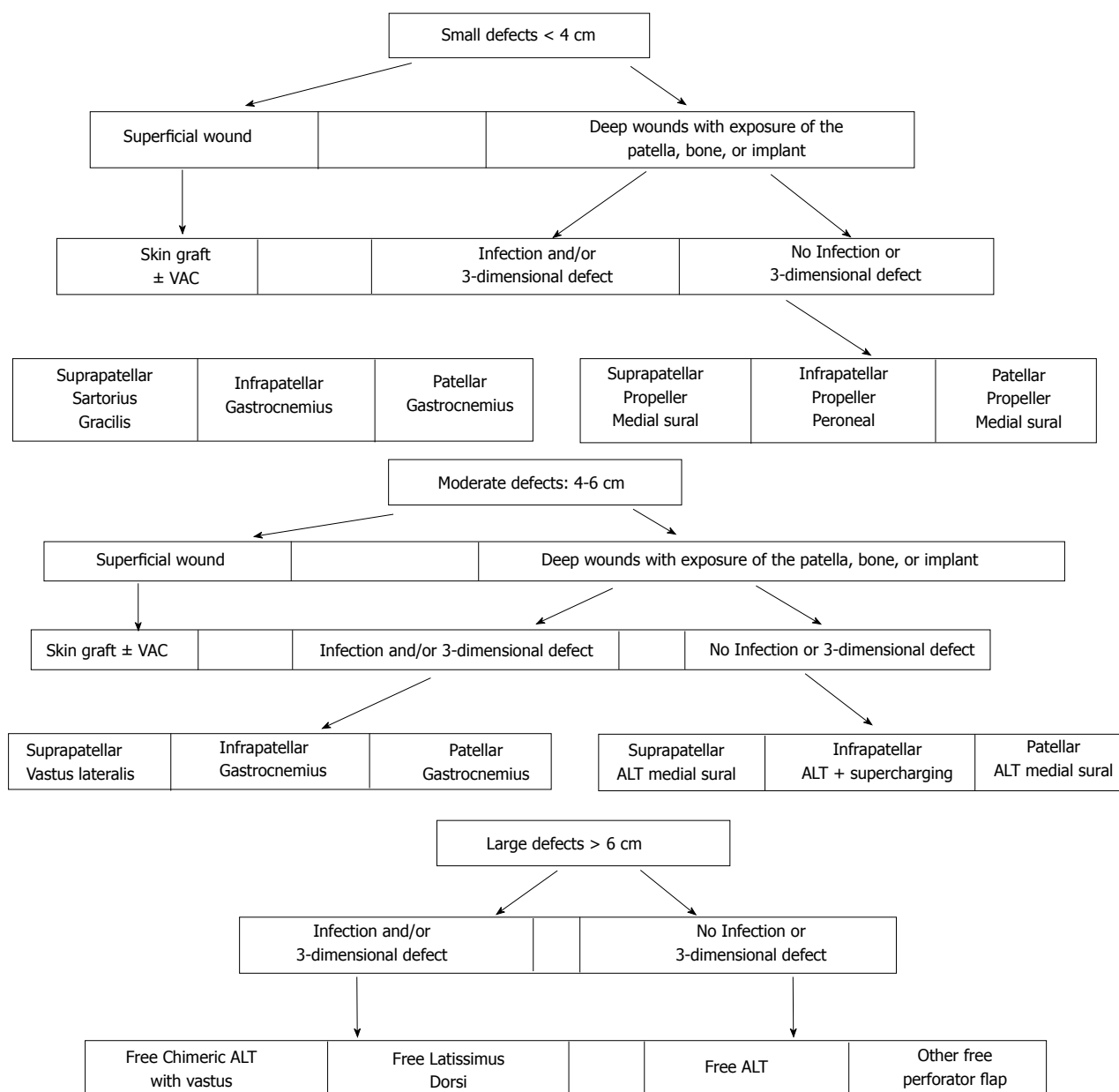
ing selection of recipient sites for microanastomoses. The optimal management of knee defects is still debated, depending on the size of the wound, location of the wound, presence of deep infection, and the level of microsurgical expertise. The decision either for pedicled or free flap should be based on the existing vascular anatomy, thus a meticulous preoperative vascular study either with Duplex ultrasound<sup>[28]</sup> or CT angiography<sup>[89,90]</sup> should be done.

Taking into account all the existed literature, a reconstructive algorithm is proposed (Figure 6).

For small (< 4 cm) defects without exposure of the patella, split thickness skin grafts with or without Vacuum Assisted Closure (VAC) therapy is the treatment of choice.

For deeper wounds with exposure of the patella, bone or the artificial joint, flap coverage is mandatory. For small defects (< 4 cm) without infection, skin flaps present the advantages of less morbidity, pliability and better cosmetic outcomes. Perforator flaps such as free style propeller perforator flaps and medial sural artery perforator flap are indicated for suprapatellar and patellar defects, whilst peroneal artery perforator flap is indicated for infrapatellar defects. Nevertheless, perforator flaps are more technically demanding and needs a significant amount of microsurgical expertise.

Therefore, pedicled muscle flaps have been the workhorses for decades. Moreover, muscle flaps are better indicated for deep infection because they obliterate the dead space arising from the debridement and bring stabil-



**Figure 6 Knee reconstructive algorithm.** VAC: Vacuum assisted closure; ALT: Alanine aminotransferase.

ity to the wound. Gastrocnemius flap has been proved to be reliable, safe and easy surgical option. Medial gastro head is more suitable for patellar, infrapatellar defects and tibial tuberosity. Lateral gastro head is more suitable for lateral defects. Distally based thigh muscle flaps, such as sartorius and gracilis, are suggested in the case of suprapatellar infected wounds or absent/traumatized sural arteries (not reliable gastrocnemius flap).

For moderate defects (4-6 cm) not excessively deep, medial sural artery perforator flap and distally based ALT flap is indicated. If the defect is extended to the infrapatellar area, ALT flap supercharging of the flap is considered. If the defect is deep and there is a space to fill gastrocnemius flap and distally based vastus lateralis muscle flap are suggested.

For large defects (> 6 cm) or severely damaged limb, a free flap is better solution. Anterolateral thigh as a per-

forator flap for superficial wounds or as a chimeric flap (with part of vastus lateralis muscle) for deeper wounds will be the flap of choice in the majority of cases. If the thickness of ALT is not suitable, vastus lateralis (associated with minimal morbidity) or latissimus dorsi muscle (associated with considerable morbidity) flap will reconstruct large, deep and infected wounds. The recipient vessel of choice will be identified by the preoperative vascular imaging<sup>[28,89,90]</sup>. If the study suggests a smaller branch (such as sural, genicular arteries) close to the defect with good inflow and outflow, this choice will enable straightforward end-to-end microanastomoses. Occasionally, smaller branches are absent or traumatized, then Superficial Femoral Vessels can be used in an end-to-side fashion. The choice of the recipient vessels may direct the choice of the most suitable flap, in order to ensure the highest success rate.

Above-the-knee amputation is considered only for life-threatening sepsis or massive bone and soft tissue loss in elderly patients.

## CONCLUSION

With the meticulous preoperative planning, by identifying the reconstructive needs, and by understanding the reconstructive algorithm, the surgeon should be able to manage knee defects with high success rate.

## REFERENCES

1. Asko-Seljavaara S, Kilpi ML, Hytönen M, Sundell B. The burned hand. Early treatment and surgery of scars and contractions. *Ann Chir Gynaecol* 1980; **69**: 224-231 [PMID: 7008687]
2. Andres LA, Casey WJ, Clarke HD. Techniques in Soft Tissue Coverage Around the Knee. *Techniques Knee Surg* 2009; **8**: 119-125 [DOI: 10.1097/BTK.0b013e3181a7eae]
3. Fang T, Zhang EW, Lineaweaver WC, Zhang F. Recipient vessels in the free flap reconstruction around the knee. *Ann Plast Surg* 2013; **71**: 429-433 [PMID: 23407250 DOI: 10.1097/SAP.0b013e31824e5e6e]
4. Panni AS, Vasso M, Cerciello S, Salgarello M. Wound complications in total knee arthroplasty. Which flap is to be used? With or without retention of prosthesis? *Knee Surg Sports Traumatol Arthrosc* 2011; **19**: 1060-1068 [PMID: 21161178 DOI: 10.1007/s00167-010-1328-5]
5. Hill DS, O'Neill JK, Toms A, Watts AM. Pyoderma gangrenosum: a report of a rare complication after knee arthroplasty requiring muscle flap cover supplemented by negative pressure therapy and hyperbaric oxygen. *J Plast Reconstr Aesthet Surg* 2011; **64**: 1528-1532 [PMID: 21514259 DOI: 10.1016/j.bjps.2011.03.024]
6. Vince KG, Abdeen A. Wound problems in total knee arthroplasty. *Clin Orthop Relat Res* 2006; **452**: 88-90 [PMID: 17079990]
7. Wiedner M, Koch H, Scharnagl E. The superior lateral genicular artery flap for soft-tissue reconstruction around the knee: clinical experience and review of the literature. *Ann Plast Surg* 2011; **66**: 388-392 [PMID: 21200309 DOI: 10.1097/SAP.0b013e3181e37627]
8. Laing JH, Hancock K, Harrison DH. The exposed total knee replacement prosthesis: a new classification and treatment algorithm. *Br J Plast Surg* 1992; **45**: 66-69 [PMID: 1737214]
9. Asko-Seljavaara S, Haajanen J. The exposed knee joint: five case reports. *J Trauma* 1982; **22**: 1021-1025 [PMID: 6754964]
10. Babu NV, Chittaranjan S, Abraham G, Bhattacharjee S, Prem H, Korula RJ. Reconstruction of the quadriceps apparatus following open injuries to the knee joint using pedicled gastrocnemius musculotendinous unit as bridge graft. *Br J Plast Surg* 1994; **47**: 190-193 [PMID: 8193858]
11. Manfrini M, Capanna R, Caldora P, Gaiani L. Gastrocnemius flaps in the surgical treatment of sarcomas of the knee. *Chir Organi Mov* 1993; **78**: 95-104 [PMID: 8344080]
12. El-Sherbiny M. Pedicled gastrocnemius flap: clinical application in limb sparing surgical resection of sarcoma around the knee region and popliteal fossa. *J Egypt Natl Canc Inst* 2008; **20**: 196-207 [PMID: 20029476]
13. Popov P, Barner-Rasmussen I, Tukiainen E. Microvascular flaps and collateral ligament reconstructions for soft tissue sarcomas at the knee joint. *Ann Plast Surg* 2010; **64**: 24-27 [PMID: 20023452 DOI: 10.1097/SAP.0b013e3181a20adf]
14. Wang TY, Dormans JP, Chang B. Soft-tissue optimization of limb salvage with knee endoprosthesis: the 10-year experience at the Children's Hospital of Philadelphia. *Ann Plast Surg* 2012; **69**: 560-564 [PMID: 21734550 DOI: 10.1097/SAP.0b013e3182223d5b]
15. Pu LL, Thomson JG. Salvage of the exposed irradiated knee joint with free tissue transfer. *Ann Plast Surg* 2000; **44**: 334-339 [PMID: 10735229]
16. Yildirim S, Avci G, Akan M, Misirlioğlu A, Aköz T. Anterolateral thigh flap in the treatment of postburn flexion contractures of the knee. *Plast Reconstr Surg* 2003; **111**: 1630-1637 [PMID: 12655208]
17. Dennis DA. Wound complications in TKA. *Orthopedics* 2002; **25**: 973-974 [PMID: 12269434]
18. Peters T, Fischer P, Lahoda LU, Niederbichler AD, Alkan-dari Q, Vogt PM. The free latissimus dorsi flap as primary free flap and crane flap with secondary pedicled transfer. *J Reconstr Microsurg* 2008; **24**: 73-77 [PMID: 18564441]
19. Galat DD, McGovern SC, Larson DR, Harrington JR, Hansen AD, Clarke HD. Surgical treatment of early wound complications following primary total knee arthroplasty. *J Bone Joint Surg Am* 2009; **91**: 48-54 [PMID: 19122078 DOI: 10.2106/JBJS.G.01371]
20. Jones RE, Russell RD, Huo MH. Wound healing in total joint replacement. *Bone Joint J* 2013; **95-B**: 144-147 [PMID: 24187374 DOI: 10.1302/0301-620X.95B11.32836]
21. Shinno N. Statico-dynamic analysis of movement of the knee. I. Modus of movement of the knee. *Tokushima J Exp Med* 1961; **8**: 101-110 [PMID: 13912033]
22. Louer CR, Garcia RM, Earle SA, Hollenbeck ST, Erdmann D, Levin LS. Free Flap Reconstruction of the Knee: An Outcome Study of 34 Cases. *Ann Plast Surg* 2013 Jun 12; Epub ahead of print [PMID: 23759972]
23. Nahabedian MY, Orlando JC, Delanois RE, Mont MA, Hungerford DS. Salvage procedures for complex soft tissue defects of the knee. *Clin Orthop Relat Res* 1998; **(356)**: 119-124 [PMID: 9917675]
24. Beumer JD, Karoo R, Caplash Y, Semmler JG, Taylor J. The medial sural artery as recipient vessel and the impact on the medial gastrocnemius. *Ann Plast Surg* 2011; **67**: 382-386 [PMID: 21540727 DOI: 10.1097/SAP.0b013e318209a761]
25. Park S, Eom JS. Selection of the recipient vessel in the free flap around the knee: the superior medial genicular vessels and the descending genicular vessels. *Plast Reconstr Surg* 2001; **107**: 1177-1182 [PMID: 11373558 DOI: 10.1016/j.bjps.2008.07.038]
26. Klayman MH, Trowbridge CC, Stammers AH, Wolfgang GL, Zijerdi DA, Bitterly TJ. Autologous platelet concentrate and vacuum-assisted closure device use in a nonhealing total knee replacement. *J Extra Corpor Technol* 2006; **38**: 44-47 [PMID: 16637523]
27. Schwabe P, Melcher I, Perka C, Krapohl B, Maeridian S, Schaser KD. [Flap coverage of soft tissue defects after total knee arthroplasty]. *Z Orthop Unfall* 2013; **151**: 488-496 [PMID: 24129719 DOI: 10.1055/s-0033-1350903]
28. Gravvanis A, Karakitsos D, Dimitriou V, Zogogiannis I, Katsikeris N, Karabinis A, Tsoutsos D. Portable duplex ultrasonography: A diagnostic and decision-making tool in reconstructive microsurgery. *Microsurgery* 2010; **30**: 348-353 [PMID: 20058299 DOI: 10.1002/micr.20752]
29. Moscattello F, Masià J, Carrera A, Clavero JA, Larrañaga JR, Pons G. The 'propeller' distal anteromedial thigh perforator flap. Anatomic study and clinical applications. *J Plast Reconstr Aesthet Surg* 2007; **60**: 1323-1330 [PMID: 17499568]
30. Feldman JJ, Cohen BE, May JW. The medial gastrocnemius myocutaneous flap. *Plast Reconstr Surg* 1978; **61**: 531-539 [PMID: 345305]
31. Mathes SJ, Nahai F. Classification of the vascular anatomy of muscles: experimental and clinical correlation. *Plast Reconstr Surg* 1981; **67**: 177-187 [PMID: 7465666]
32. Hyodo I, Nakayama B, Takahashi M, Toriyama K, Kamei Y, Torii S. The gastrocnemius with soleus bi-muscle flap. *Br J Plast Surg* 2004; **57**: 77-82 [PMID: 14672681]



- 33 **Bengtson S**, Carlsson A, Relander M, Knutson K, Lidgren L. Treatment of the exposed knee prosthesis. *Acta Orthop Scand* 1987; **58**: 662-665 [PMID: 3442216]
- 34 **Fansa H**, Plogmeier K, Schenk K, Schneider W. [Covering extensive soft tissue defects in infected knee endoprostheses by gastrocnemius flap]. *Chirurg* 1998; **69**: 1238-1243 [PMID: 9864636]
- 35 **Menderes A**, Demirdover C, Yilmaz M, Vayvada H, Barutcu A. Reconstruction of soft tissue defects following total knee arthroplasty. *Knee* 2002; **9**: 215-219 [PMID: 12126680]
- 36 **Tiengo C**, Macchi V, Vigato E, Porzionato A, Stecco C, Azzena B, Morra A, De Caro R. Reversed gracilis pedicle flap for coverage of a total knee prosthesis. *J Bone Joint Surg Am* 2010; **92**: 1640-1646 [PMID: 20595571 DOI: 10.2106/JBJS.100195]
- 37 **Petty CT**, Hogue RJ. Closure of an exposed knee joint by use of a sartorius muscle flap: case report. *Plast Reconstr Surg* 1978; **62**: 458-461 [PMID: 358229]
- 38 **Hong JP**, Lee HB, Chung YK, Kim SW, Tark KC. Coverage of difficult wounds around the knee joint with prefabricated, distally based sartorius muscle flaps. *Ann Plast Surg* 2003; **50**: 484-490 [PMID: 12792537]
- 39 **Shen YM**, Yu DN, Hu XH, Qin FJ, Li M, Ning FG. Repairing proximal and middle lower-leg wounds with retrograde sartorius myocutaneous flap pedicled by perforating branches of medial inferior genicular artery or posterior tibial artery. *J Plast Reconstr Aesthet Surg* 2012; **65**: 1158-1164 [PMID: 22531836 DOI: 10.1016/j.bjps.2012.03.041]
- 40 **Arnold PG**, Prunes-Carrillo F. Vastus medialis muscle flap for functional closure of the exposed knee joint. *Plast Reconstr Surg* 1981; **68**: 69-72 [PMID: 7244002]
- 41 **Swartz WM**, Ramasastry SS, McGill JR, Noonan JD. Distally based vastus lateralis muscle flap for coverage of wounds about the knee. *Plast Reconstr Surg* 1987; **80**: 255-265 [PMID: 3602175]
- 42 **Zhang G**. Reversed anterolateral thigh island flap and myocutaneous flap transplantation. *Zhonghua Yixue Zazhi* 1990; **70**: 676-668, 46 [PMID: 1963370]
- 43 **Gravvanis AI**, Iconomou TG, Panayotou PN, Tsoutsos DA. Medial gastrocnemius muscle flap versus distally based anterolateral thigh flap: conservative or modern approach to the exposed knee joint? *Plast Reconstr Surg* 2005; **116**: 932-934 [PMID: 16141853]
- 44 **Gravvanis AI**, Tsoutsos DA, Karakitsos D, Panayotou P, Iconomou T, Zografos G, Karabinis A, Papadopoulos O. Application of the pedicled anterolateral thigh flap to defects from the pelvis to the knee. *Microsurgery* 2006; **26**: 432-438 [PMID: 16924632]
- 45 **Gravvanis A**, Britto JA. Venous augmentation of distally based pedicled ALT flap to reconstruct the tibial tuberosity in a severely injured leg. *Ann Plast Surg* 2009; **62**: 290-292 [PMID: 19240527 DOI: 10.1097/SAP.0b013e31817d81fb]
- 46 **Koshima I**, Soeda S, Yamasaki M, Kyou J. The free or pedicled anteromedial thigh flap. *Ann Plast Surg* 1988; **21**: 480-485 [PMID: 2976584]
- 47 **Hupkens P**, Van Loon B, Lauret GJ, Kooloos JG, Vehof JW, Hartman EH, Spauwen PH. Anteromedial thigh flaps: an anatomical study to localize and classify anteromedial thigh perforators. *Microsurgery* 2010; **30**: 43-49 [PMID: 19774612 DOI: 10.1002/micr.20700]
- 48 **Lu LJ**, Gong X, Cui JL, Liu B. The anteromedial thigh fasciocutaneous flap pedicled on the supragenicular septocutaneous perforator: application in 11 patients. *Ann Plast Surg* 2011; **67**: 275-278 [PMID: 21407064 DOI: 10.1097/SAP.0b013e3181f89151]
- 49 **Yoshimura M**, Shimada T, Imura S, Shimamura K, Yamachi S. Peroneal island flap for skin defects in the lower extremity. *J Bone Joint Surg Am* 1985; **67**: 935-941 [PMID: 2862150]
- 50 **Ruan H**, Cai P, Fan C, Chai Y, Liu S. [Antegrade extended peroneal artery perforator flap for knee reconstruction]. *Zhongguo Xiufu Chongjian Waikexue Zazhi* 2009; **23**: 303-305 [PMID: 19366139]
- 51 **Ruan HJ**, Cai PH, Schleich AR, Fan CY, Chai YM. The extended peroneal artery perforator flap for lower extremity reconstruction. *Ann Plast Surg* 2010; **64**: 451-457 [PMID: 20224342 DOI: 10.1097/SAP.0b013e3181b0c4f6]
- 52 **Li Z**, Liu K, Lin Y, Li L. Lateral sural cutaneous artery island flap in the treatment of soft tissue defects at the knee. *Br J Plast Surg* 1990; **43**: 546-550 [PMID: 2224349]
- 53 **Umamoto Y**, Adachi Y, Ebisawa K. The sural artery perforator flap for coverage of defects of the knee and tibia. *Scand J Plast Reconstr Surg Hand Surg* 2005; **39**: 209-212 [PMID: 16208782]
- 54 **Shim JS**, Kim HH. A novel reconstruction technique for the knee and upper one third of lower leg. *J Plast Reconstr Aesthet Surg* 2006; **59**: 919-926; discussion 927 [PMID: 16920582]
- 55 **Nguyen AT**, Wong C, Mojallal A, Saint-Cyr M. Lateral supragenicular pedicle perforator flap: clinical results and vascular anatomy. *J Plast Reconstr Aesthet Surg* 2011; **64**: 381-385 [PMID: 20716494 DOI: 10.1016/j.bjps.2010.05.029]
- 56 **Rad AN**, Christy MR, Rodriguez ED, Brazio P, Rosson GD. The anterior tibialis artery perforator (ATAP) flap for traumatic knee and patella defects: clinical cases and anatomic study. *Ann Plast Surg* 2010; **64**: 210-216 [PMID: 20098108 DOI: 10.1097/SAP.0b013e3181a13dd6]
- 57 **Adhikari S**, Bandyopadhyay T, Saha JK. Anterior tibial artery perforator plus flaps for reconstruction of post-burn flexion contractures of the knee joint. *Ann Burns Fire Disasters* 2012; **25**: 86-91 [PMID: 23233827]
- 58 **Bravo FG**, Schwarze HP. Free-style local perforator flaps: concept and classification system. *J Plast Reconstr Aesthet Surg* 2009; **62**: 602-68; discussion 609 [PMID: 19181580 DOI: 10.1016/j.bjps.2008.11.086]
- 59 **Gobel F**, Pélissier P, Casoli V. Perforator propeller flap for cutaneous coverage of the knee. *Ann Chir Plast Esthet* 2011; **56**: 280-286 [PMID: 21719180 DOI: 10.1016/j.anplas.2011.05.005]
- 60 **Yuen JC**, Zhou AT. Free flap coverage for knee salvage. *Ann Plast Surg* 1996; **37**: 158-166 [PMID: 8863975]
- 61 **Chen HC**, Chuang CC, Chen S, Hsu WM, Wei FC. Selection of recipient vessels for free flaps to the distal leg and foot following trauma. *Microsurgery* 1994; **15**: 358-363 [PMID: 7934806]
- 62 **Johnson PE**, Harris GD, Nagle DJ, Lewis VL. The sural artery and vein as recipient vessels in free flap reconstruction about the knee. *J Reconstr Microsurg* 1987; **3**: 233-241 [PMID: 3598944]
- 63 **Hallock GG**. The medial approach to the sural vessels to facilitate microanastomosis about the knee. *Ann Plast Surg* 1994; **32**: 388-393 [PMID: 8210158]
- 64 **Rees-Lee JE**, Khan U. Superior medial genicular artery (SMGA): a recipient vessel for free-flap reconstruction of anterior and medial knee defects. *J Plast Reconstr Aesthet Surg* 2011; **64**: 1727-1729 [PMID: 21775235 DOI: 10.1016/j.bjps.2011.06.038]
- 65 **Venkatramani H**, Sabapathy SR, Nayak S. Free-flap cover of complex defects around the knee using the descending genicular artery as the recipient pedicle. *J Plast Reconstr Aesthet Surg* 2014; **67**: 93-98 [PMID: 24090722 DOI: 10.1016/j.bjps.2013.09.011]
- 66 **Chien WH**, Chen IC, Tan TS, Tang YW. Salvage of knee joint tumor prosthesis using turnover reverse-flow descending branch of lateral circumflex femoral artery as recipient vessel for the free ALT flap: a case report. *J Reconstr Microsurg* 2007; **23**: 505-509 [PMID: 17979068]
- 67 **Kim JS**, Lee HS, Jang PY, Choi TH, Lee KS, Kim NG. Use of the descending branch of lateral circumflex femoral artery as a recipient pedicle for coverage of a knee defect with free flap: anatomical and clinical study. *Microsurgery* 2010; **30**: 32-36 [PMID: 19774629 DOI: 10.1002/micr.20701]



- 68 **Wong CH**, Goh T, Tan BK, Ong YS. The anterolateral thigh perforator flap for reconstruction of knee defects. *Ann Plast Surg* 2013; **70**: 337-342 [PMID: 22214802 DOI: 10.1097/SAP.0b013e318234e8e2]
- 69 **Dorfman DW**, Pu LL. Using the Descending Branch of the Lateral Circumflex Femoral Artery and Vein as Recipient Vessel for Free Tissue Transfer to the Difficult Areas of the Lower Extremity. *Ann Plast Surg* 2013 Mar 11; Epub ahead of print [PMID: 23486134]
- 70 **Herrera FA**, Lee CK, Kiehn MW, Hansen SL. The distal superficial femoral arterial branch to the sartorius muscle as a recipient vessel for soft tissue defects around the knee: anatomic study and clinical applications. *Microsurgery* 2009; **29**: 425-429 [PMID: 19230004 DOI: 10.1002/micr.20620]
- 71 **Hong JP**, Koshima I. Using perforators as recipient vessels (supermicrosurgery) for free flap reconstruction of the knee region. *Ann Plast Surg* 2010; **64**: 291-293 [PMID: 20179475 DOI: 10.1097/SAP.0b013e3181ac4263]
- 72 **Lin CH**, Mardini S, Lin YT, Yeh JT, Wei FC, Chen HC. Sixty-five clinical cases of free tissue transfer using long arteriovenous fistulas or vein grafts. *J Trauma* 2004; **56**: 1107-1117 [PMID: 15179254]
- 73 **Gravvanis A**, Delikonstantinou I, Chatzigakis PK, Tsoutsos D. Femoral vessels as recipient for free tissue transfer coverage of around-the-knee defects. *Microsurgery* 2013; **33**: 333-334 [PMID: 23436380 DOI: 10.1002/micr.22094]
- 74 **Fansa H**, Plogmeier K, Feistner H, Schneider WJ. Plasticity and function--the fate of a free, neurovascular muscle graft ten years post-reconstruction. *J Reconstr Microsurg* 1997; **13**: 551-554 [PMID: 9401982]
- 75 **Liau JE**, Pu LL. Reconstruction of a large upper tibial wound extending to the knee with a free latissimus dorsi flap: Optimizing the outcomes. *Microsurgery* 2007; **27**: 548-552 [PMID: 17828785]
- 76 **Cetrulo CL**, Shiba T, Friel MT, Davis B, Buntic RF, Buncke GM, Brooks D. Management of exposed total knee prostheses with microvascular tissue transfer. *Microsurgery* 2008; **28**: 617-622 [PMID: 18844228 DOI: 10.1002/micr.20578]
- 77 **Zhang PH**, Huang XY, Long JH, Fan PJ, Ren LC, Zeng JZ, Xiao MZ. Application of latissimus dorsi flap in different forms in repair of skin and soft tissue defects in lower extremities. *Zhonghua Shaoshang Zazhi* 2009; **25**: 18-21 [PMID: 19588755]
- 78 **Muramatsu K**, Yoshida K, Fujii K, Okazaki T, Moriya A, Taguchi T. Anatomical reconstruction of the knee extensor apparatus for prepatellar myxofibrosarcoma. *Orthopedics* 2010; **33**: 773 [PMID: 20954649 DOI: 10.3928/01477447-20100826-32]
- 79 **Sönmez E**, Sönmez E, Kamburoğlu HO, Aksu AE, Nasir SN, Evrenos MK, Şafak T, Keçik A. Soft-tissue management with immediate free flap transfer in segmental prosthetic replacement of proximal tibia sarcomas. *Microsurgery* 2011; **31**: 620-627 [PMID: 21919053 DOI: 10.1002/micr.20937]
- 80 **Sulaiman AR**, Halim AS, Azman WS, Eskandar H. Reconstruction of severe patellar infera syndrome with free vascularised composite tensor fascia lata flap. *Singapore Med J* 2008; **49**: e205-e207 [PMID: 18756334]
- 81 **Wechselberger G**, Ninkovic M, Püzl P, Schoeller T. Free functional rectus femoris muscle transfer for restoration of knee extension and defect coverage after trauma. *J Plast Reconstr Aesthet Surg* 2006; **59**: 994-998 [PMID: 16920595]
- 82 **Lin CH**, Wei FC, Levin LS, Su JL, Fan KF, Yeh WL, Hsu DT. Free composite serratus anterior and rib flaps for tibial composite bone and soft-tissue defect. *Plast Reconstr Surg* 1997; **99**: 1656-1665 [PMID: 9145136]
- 83 **Lee MJ**, Yun IS, Rah DK, Lee WJ. Lower Extremity Reconstruction Using Vastus Lateralis Myocutaneous Flap versus Anterolateral Thigh Fasciocutaneous Flap. *Arch Plast Surg* 2012; **39**: 367-375 [PMID: 22872841 DOI: 10.5999/aps.2012.39.4.367]
- 84 **Beset M**, Penaud A, Quignon R, Bahe L, Brilhault J, Fouquet B. Donor site morbidity after free gracilis muscle flap. Report of 32 cases. *Ann Chir Plast Esthet* 2014; **59**: 53-60 [PMID: 23707083 DOI: 10.1016/j.anplas.2013.04.001]
- 85 **Blondeel PN**, Morris SF, Hallock GG, Neligan PC. Perforator flaps. Anatomy, technique and clinical applications. Missouri: Quality Medical Publishing Inc. St. Louis, 2006: 915-934
- 86 **Cavadas PC**, Sanz-Giménez-Rico JR, Gutierrez-de la Cámara A, Navarro-Monzonis A, Soler-Nomdedeu S, Martínez-Soriano F. The medial sural artery perforator free flap. *Plast Reconstr Surg* 2001; **108**: 1609-115; discussion 1609-115; [PMID: 11711936]
- 87 **Ulusal AE**, Ulusal BG, Lin YT, Lin CH. The advantages of free tissue transfer in the treatment of posttraumatic stiff knee. *Plast Reconstr Surg* 2007; **119**: 203-210 [PMID: 17255675]
- 88 **Kuo YR**, An PC, Kuo MH, Kueh NS, Yao SF, Jeng SF. Reconstruction of knee joint soft tissue and patellar tendon defects using a composite anterolateral thigh flap with vascularized fascia lata. *J Plast Reconstr Aesthet Surg* 2008; **61**: 195-199 [PMID: 18215803 DOI: 10.1016/j.bjps.2006.06.012]
- 89 **Gravvanis A**, Petrocheilou G, Tsoutsos D, Delikonstantinou I, Karakitsos D. Integrating imaging techniques in lower limb microsurgical reconstruction: focusing on ultrasonography versus computed tomography angiography. *In Vivo* 2013; **27**: 371-375 [PMID: 23606693]
- 90 **Herold C**, Steiert A, Knobloch K, Busche MN, Altintas MA, Vogt PM. Angiographic findings in patients with postoperative soft tissue defects following total knee arthroplasty. *Knee Surg Sports Traumatol Arthrosc* 2011; **19**: 2045-2049 [PMID: 21611782 DOI: 10.1007/s00167-011-1532-y]

**P- Reviewer:** Lorbach O, Sakamoto A, Willis-Owen CA

**S- Editor:** Wen LL **L- Editor:** A **E- Editor:** Wu HL



WJO 5<sup>th</sup> Anniversary Special Issues (6): Osteoporosis

## Management bone loss of the proximal femur in revision hip arthroplasty: Update on reconstructive options

Vasileios I Sakellariou, George C Babis

Vasileios I Sakellariou, First Department of Orthopaedics, Medical School, University of Athens, ATTIKON University General Hospital, Chaidari 12462, Greece

George C Babis, Second Department of Orthopaedics, Medical School, University of Athens, Nea Ionia General Hospital, Athens 14233, Greece

Author contributions: Sakellariou VI and Babis GC solely contributed to this paper.

Correspondence to: George C Babis, MD, PhD, Professor and Chairman of Orthopaedics, Second Department of Orthopaedics, Medical School, University of Athens, Nea Ionia General Hospital, 3-5 Ag. Olgas Street, Athens 14233, Greece. [george.babis@gmail.com](mailto:george.babis@gmail.com)

Telephone: +30-213-2057956 Fax: +30-213-2057783

Received: December 23, 2013 Revised: July 11, 2014

Accepted: July 18, 2014

Published online: November 18, 2014

### Abstract

The number of revision total hip arthroplasties is expected to rise as the indications for arthroplasty will expand due to the aging population. The prevalence of extensive proximal femoral bone loss is expected to increase subsequently. The etiology of bone loss from the proximal femur after total hip arthroplasty is multifactorial. Stress shielding, massive osteolysis, extensive loosening and history of multiple surgeries consist the most common etiologies. Reconstruction of extensive bone loss of the proximal femur during a revision hip arthroplasty is a major challenge for even the most experienced orthopaedic surgeon. The amount of femoral bone loss and the bone quality of the remaining metaphyseal and diaphyseal bone dictate the selection of appropriate reconstructive option. These include the use of impaction allografting, distal press-fit fixation, allograft-prosthesis composites and tumor megaprotheses. This review article is a concise review of the current literature and provides an algorithmic approach

for reconstruction of different types of proximal femoral bone defects.

© 2014 Baishideng Publishing Group Inc. All rights reserved.

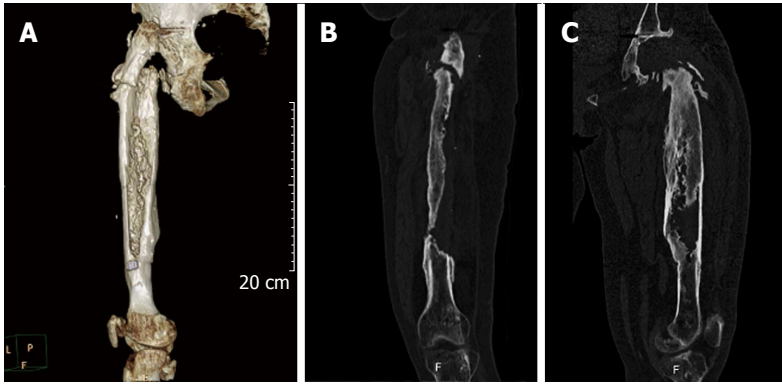
**Key words:** Arthroplasty; Proximal; Femur; Reconstruction; Bone loss

**Core tip:** Massive osteolysis, stress-shielding, periprosthetic infections or multiple revisions can consist the most common etiologies for extensive loss of bone stock of the proximal femur. The amount of femoral bone loss and the bone quality of the remaining metaphyseal and diaphyseal bone dictate the selection of appropriate reconstructive option. These include the use of impaction allografting, distal press-fit fixation, allograft-prosthesis composites and tumor megaprotheses. The present study is a concise review of the current literature presenting an algorithmic approach for reconstruction of different types of proximal femoral bone defects.

Sakellariou VI, Babis GC. Management bone loss of the proximal femur in revision hip arthroplasty: Update on reconstructive options. *World J Orthop* 2014; 5(5): 614-622 Available from: URL: <http://www.wjgnet.com/2218-5836/full/v5/i5/614.htm> DOI: <http://dx.doi.org/10.5312/wjo.v5.i5.614>

### INTRODUCTION

Approximately 250000 primary and over 50000 revision total hip arthroplasty procedures are performed in the United States each year<sup>[1]</sup>. The number of revision total hip arthroplasties is expected to rise as the indications for arthroplasty will expand due to the aging population and the continuous advances in technology and surgical techniques<sup>[1,2]</sup>. Massive osteolysis, stress-shielding, peripros-



**Figure 1** Computed tomography scan images with metallic artifact subtraction and three-dimensional reconstruction consist a useful tool for precise assessment of the amount of bone loss and the specific variations of the femoral anatomy preoperatively. A: Computed tomography scan image of the left femur (posterior projection) with metallic artifact subtraction and three-dimensional reconstruction showing precisely the amount of bone loss of the proximal part of the femur; B: Coronal; C: Sagittal view of the same case.

thetic infections or multiple revisions can eventually lead to extensive loss of bone stock in the proximal femur<sup>[2,3]</sup>. Additionally, osteolysis due to loosening and wear and pre-existing osteoporosis may result to deficient femoral bone stock. Femoral bone loss as a result of failed total hip arthroplasty is a problem that continues to challenge orthopaedic surgeons. The aim of the present study is to provide an algorithmic approach for reconstruction of different types of proximal femoral bone defects through a concise review of the current literature.

## CLASSIFICATION

Multiple systems have been used to classify the severity of bone loss of the proximal femur. Most of these classification systems are descriptive of the amount and the area of bone loss. Using a standardized approach the investigators try to accurately define the structural integrity of the metaphyseal and diaphyseal bone, suggesting the available options of implant fixation to the remaining host bone.

The classifications proposed by (1) the AAOS Committee on the Hip<sup>[4]</sup>; and (2) Della Valle and Paprosky<sup>[5]</sup> are most commonly used to describe the amount of femoral bone loss and propose guidelines for treatment of each type of proximal femoral bone deficiency.

The AAOS classification divides the femoral bone defects into segmental and cavitary<sup>[4]</sup>. Segmental defects include loss of supporting cortical bone, whereas the cavitary defects are defined as any bony loss of the cancellous medullary bone. Malalignment refers to any compromise of the femoral architecture and natural geometry resulting into angular or rotational deformities. Stenosis is the partial or complete occlusion of the femoral canal as a result of a previous trauma or hypertrophic bone reaction. Discontinuity is defined as the loss of cortical continuity due to pre-existing fracture or established non-union.

The Paprosky classification<sup>[5]</sup> of proximal femoral defects is used to assess the amount of bone loss and define the morphology of remaining proximal femoral bone stock; it also provides guidelines for treatment. Paprosky type I defects are characterized by minimal metaphyseal cancellous bone loss with intact diaphysis. Type II defects have more extensive cancellous bone loss including

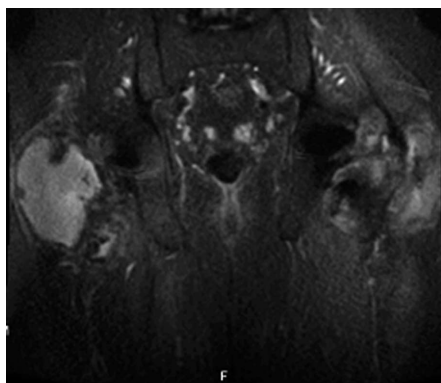
the whole metaphysis down to the level of the lesser trochanter. In type IIIA defects, there is an extensive bone deficit of the proximal femur; the metaphyseal bone is non-supportive; however, there is adequate diaphyseal bone (intact circumferential bone more than 4 cm in length) for distal fixation of a cementless stem. In Type IIIB defects the available diaphyseal bone is less than 4 cm in length. Type IV femora have a widened diaphysis that provides no support for cementless fixation.

## PREOPERATIVE PLANNING

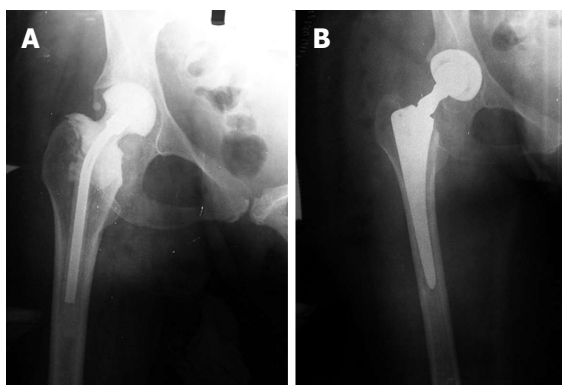
Meticulous preoperative planning is of paramount importance before proceeding to a complex revision surgery that includes exchange of the femoral component. Preoperative planning is helpful in assessing the type of proximal femur deficiency, evaluating the radiographic leg length discrepancy and selecting the proper implant in terms of size, length and offset. Calibrated X-rays of the pelvis and the affected hip in 2 projections (anteroposterior and lateral) are required in order to better evaluate the amount of bone loss, classify the bony defect and select the optimal reconstructive option<sup>[6]</sup>.

However, plain radiographs are not always sufficient to assess with accuracy the amount of bone loss and the quality of remaining bone. Computed tomography (CT) scans provide superior image quality and may be processed and reconstructed into 3 dimensional projections that are extremely valuable for preoperative planning and implant selection. However, metallic artifacts may limit the clarity of imaging especially in the presence of metal implants in the under-study area. In complex cases, CT scan images with metallic artifact subtraction and three-dimensional reconstruction consist a useful tool for precise assessment of the amount of bone loss and the specific variations of the femoral anatomy preoperatively (Figure 1).

Magnetic resonance imaging (MRI) has gained popularity in assessing the integrity of soft tissue and especially of the abductor musculature in a painful THA. Especially, in the presence of metal-on-metal articulation identification of potential adverse reaction to metal debris is of significant importance. Metal artifact reduction MRI appears to be the most useful tool for diagnosing, staging and monitoring these types of adverse reactions



**Figure 2** Metal artifact reduction magnetic resonance imaging (coronal view) showing the adverse reactions to metal debris and formation of pseudocapsules in both hips following bilateral total hip arthroplasties with modular necks.



**Figure 3** Anteroposterior radiograph of bone loss. A: Anteroposterior (AP) radiograph of the right hip showing minimal bone loss of the proximal metaphyseal bone secondary to periprosthetic hip infection. A antibiotic cement spacer was implanted after irrigation and debridement during the first stage of a two-stage exchange arthroplasty; B: AP radiograph of the same hip after the second stage. The metaphyseal bone loss was minimal and a cementless primary stems with common length and geometry was used.

to metal debris<sup>[7]</sup> (Figure 2).

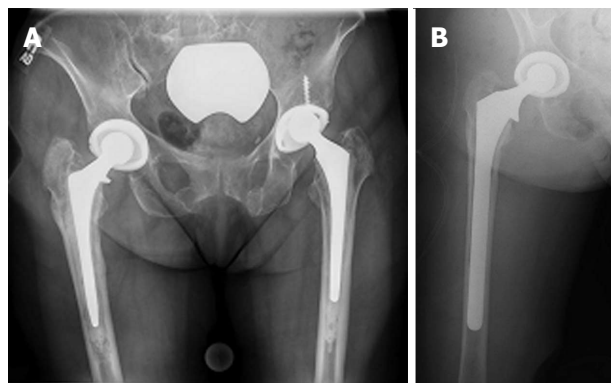
## RECONSTRUCTIVE OPTIONS

Revision of the femoral component and reconstruction of a femur with severe bone loss is a complex procedure. Improvements in prosthetic designs and implant materials have been associated with superior clinical outcomes and better implant survivorship.

The main objectives of femoral reconstruction during revision hip surgery are to preserve the remaining bone of the femur, as much as possible, and to provide a stable implant fixation. Restoration of hip function, joint stability and leg length equality are important goals of reconstructive procedure<sup>[3,5]</sup>.

An algorithmic approach to restore the bone defect of the proximal femur based on previously published classification systems is presented in Table 1<sup>[4,5]</sup>.

According to Paprosky classification<sup>[5]</sup>, type I proximal femoral defects that are characterized by minimal meta-



**Figure 4** Extensively porous coated stems. A: Anteroposterior (AP) radiograph of the pelvis demonstrating bilateral total hip arthroplasties. In right hip there is evident loosening of the femoral stem and extensive metaphyseal cancellous bone loss with some diaphyseal bone loss, which is limited to less than 4 cm of diaphyseal bone; B: AP radiograph of the same hip post revision using an extensively porous coated stem.

physeal cancellous bone loss with intact diaphysis may be easily reconstructed using cementless or cemented primary stems with common length and geometry (Figure 3). No additional mode of fixation (fully porous coating or distal fixation implants) is usually required.

In type II defects, with extensive metaphyseal bone loss and intact diaphysis, the reconstructive options are associated with the quality of metaphyseal bone. Modular stems with proximal fixation are preferred<sup>[8]</sup>. This permits load transfer through the proximal metaphyseal bone more physiologically. However, when the medial cortex of the femoral neck is compromised a calcar replacement stem may be used in order to provide a more secure proximal fixation and accurately restore leg length. In a recent study, Emerson *et al*<sup>[9]</sup> showed that calcar replacement stems with 40% porous-coating have excellent clinical outcome with a very low incidence of mechanical failure (3%). Ninety-four percent of these stems remain in-situ 11.5 years after implantation, which is a superior outcome comparing to most cemented femoral revision series<sup>[9]</sup>.

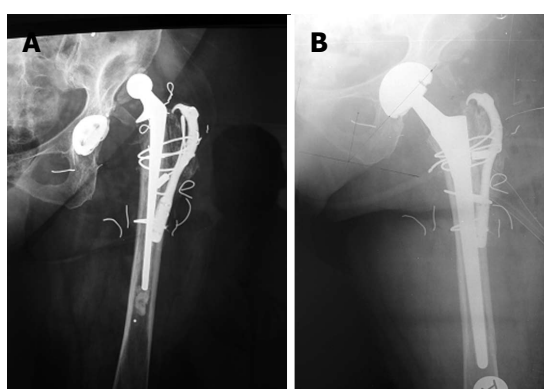
In type IIIA defects, the cancellous bone of the proximal femoral metaphysis is defective; However, the femoral diaphysis is still intact and more than 4 cm of cortical bone is available for distal fixation. This type of femoral defects requires the use of cementless stems with distal (diaphyseal) fixation<sup>[10-12]</sup>. Extensively porous coated stems (Figure 4) or modular stems (Figure 5), which are fluted distally and porous coated proximally, may be used to achieve adequate diaphyseal fixation<sup>[13,14]</sup>. Under-sizing of the femoral component is the most frequently referred cause of failure that leads to implant subsidence and loss of mechanical support<sup>[13,14]</sup>. Meticulous preparation of the femoral canal is of paramount importance in order to achieve optimal fit and fill of the stem to the femoral canal and secure fixation of the flutes into the cortical bone<sup>[13,14]</sup>.

In the type IIIB femoral defects, less than 4 cm of



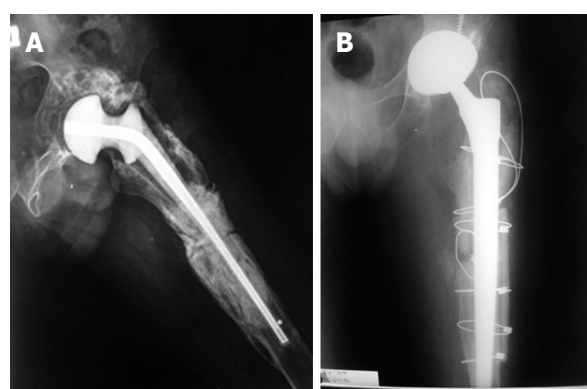
**Table 1** Algorithmic approach of proximal femur reconstruction according to Paprosky classification

Type	Description	Treatment option
I	Minimal metaphyseal cancellous bone loss Intact diaphysis	Cementless or cemented primary stems with common length and geometry
II	More extensive cancellous bone loss including the whole metaphysis down to the level of the lesser trochanter	Proximally fixed stem (usually modular) Calcar replacement stem if medial cortex of the femoral neck is compromised
III A	Extensive metaphyseal and diaphyseal bone loss of the femur; More than 4 cm of diaphyseal bone are available for distal fixation of cementless stem	Cementless stems with distal (diaphyseal) Extensively porous coated stems
III B	Available diaphyseal bone is less than 4 cm in length	Modular stems fluted distally and porous coated proximally Extensively porous-coated stems Impaction grafting + cemented stem Modular cementless tapered fluted stem
IV	Widened diaphysis that provides no support for cementless fixation	Impaction grafting + cemented stem Allograft prosthetic composite Tumor megaprosthesis

**Figure 5** Modular stems. A: Preoperative anteroposterior (AP) radiograph of a dislocated left hip with a paprosky type IIIA defect; B: Postoperative AP radiograph of the revised hip with a modular stem.

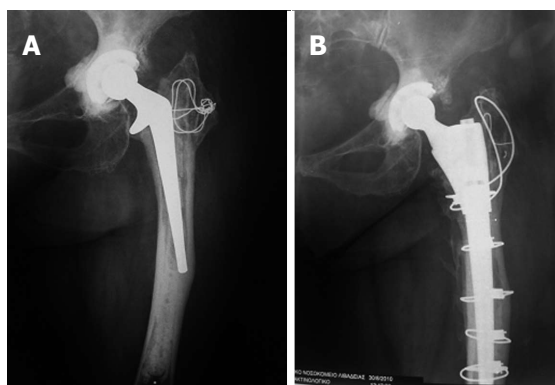
intact diaphysis is available for distal fixation. The use of extensively porous-coated stems have been associated with poor survivorship and therefore they are not recommended. The current literature includes a number of studies presenting cementless femoral revisions using extensively porous-coated stems. Lawrence *et al*<sup>[15]</sup> showed that 5.7% of these stems failed and needed revision of the femoral implant 7.4 years post operatively. In another study, Weeden and Paprosky found that extensively porous-coated revision stems are associated with an incidence of aseptic loosening and mechanical failure of 4.1% after a 14.2 years postoperatively<sup>[14]</sup>.

Impaction grafting of the defective femur and reconstruction using a cemented stem would be a favorable option for this setting<sup>[16-20]</sup>. In a study of Lamberton *et al.*, the technique of impaction allografting and use of cemented revision stem was presented<sup>[18]</sup>. The authors included a cohort 540 revision arthroplasties and showed that the survival rate of impaction grafting is approximately when considering the aseptic loosening and revision for any reason as the endpoints is 98% and 84% respectively after a mean 10 years of follow-up. Dislocation (4.1%) and femoral fracture (5.4%) were shown to be the most common complications of this procedure. In

**Figure 6** Newer stem designs with modular configuration have been associated with lower rates of subsidence and improved restoration of limb length and femoral offset. A: Anteroposterior (AP) radiograph of the left hip showing extensive bone loss of the proximal metaphyseal bone with significant diaphyseal bone loss (Paprosky type IIIB) secondary to periprosthetic hip infection. A antibiotic cement spacer was implanted after irrigation and debridement during the first stage of a two-stage exchange arthroplasty; B: AP radiograph of the same hip after the second stage using a distal fixation taper fluted stem.

another study, incorporating the data from the Swedish registry, that included 1305 revisions of the femoral component and reconstruction using the impaction grafting technique found that the survival rate at 15 years postoperatively was very high approaching 94%<sup>[21]</sup>. The effect of surface finish of the femoral components still remains debatable. Polished stems without collar and roughened stems with a collar have been both used. Studies from the current literature have failed to reveal any statistically significant difference on the clinical outcome and the survivorship of these arthroplasties<sup>[21]</sup>. However, the technique of impaction grafting is challenging and time consuming. Specialized instrumentation and a large volume of cancellous bone allografts are required<sup>[21]</sup>. Therefore, reconstruction with a modular cementless tapered fluted stem would be a viable alternative option.

Tapered fluted stems have been historically susceptible to subsidence and associated with high dislocation rates<sup>[22-25]</sup>. Newer stem designs with modular configuration, which allow independent size selection of the proxi-



**Figure 7 Multiple osteotomies allow for restoration of the anatomical axis of the femur, an easier access of the distal segment of the modular stem, thus reducing the risk of femoral fracture or perforation of the cortex. A:** Anteroposterior (AP) radiograph of the left hip showing a cemented femoral component that is failed in varus, resulting in a slight angular malalignment of femur; **B:** AP radiograph of the same hip after revision of the femoral component using a modular stem, which combines both proximal metaphyseal and distal fixation due to the taper design and the distal flutes. A healed corrective osteotomy at the level of the mid-diaphysis facilitated the insertion of the stem and correction of the angular deformity to its neutral axis.

mal and distal segments, have been associated with lower rates of subsidence and improved restoration of limb length and femoral offset (Figure 6). Mechanical failure of the modular taper due to fretting corrosion has been reported<sup>[26]</sup>. For this reason, several authors recommend the use of some kind of additional structural support to the proximal body of the prosthesis by using allografts or by wrapping the remaining host bone around the proximal segment of the modular stem<sup>[27]</sup>. A recent retrospective multicenter study that included a series of 143 hips reconstructed with the same modular fluted tapered stem, found that the mean survivorship of these stems reaches 97% at an average 40 mo follow-up while the mean subsidence was 2.1-mm<sup>[10]</sup>. These components may be combined with various types of single or multiple femoral osteotomies (*i.e.*, sish-kebab technique); multiple osteotomies allow for restoration of the anatomical axis of the femur, an easier access of the distal segment of the modular stem, thus reducing the risk of femoral fracture or perforation of the cortex<sup>[28]</sup> (Figure 7).

Type IV femoral defects are the most challenging subtype because there is no intact isthmus to provide adequate distal fixation of the component. For this reason, the treatment options include reconstruction of the femoral canal with impaction grafting and insertion of a cemented stem or using a tumor megaprosthesis to replace the defective proximal femur<sup>[3,29-33]</sup>.

The use of allograft prosthetic composite (*i.e.*, combination of a cemented long stem and a bulk allograft of the proximal femur) that is attached to the host bone distally is another reconstructive option<sup>[3,29-33]</sup>. This technique has attracted interest because it may potentially preserve the existing bone stock and establish a good bony foundation for future revisions, especially in younger patients. The allograft offers mechanical properties similar to the

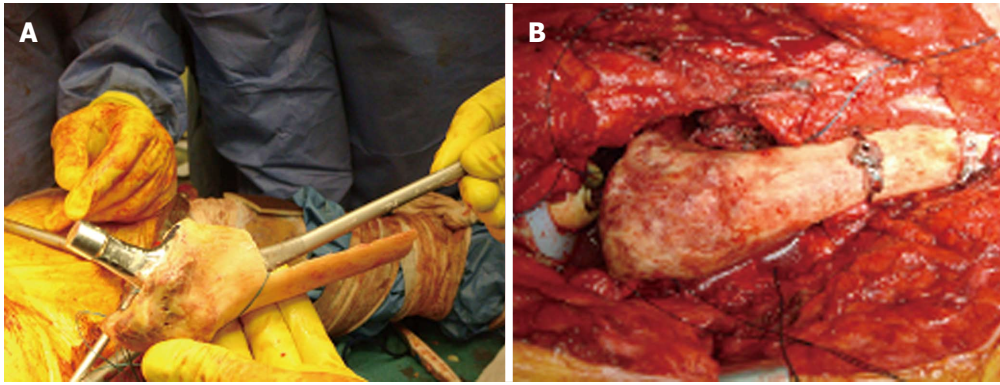
patient's own bone and allows reconstruction of sizeable deficits. This may be considered as a biologic reconstructive option; except for the preservation of bone stock, the use of a structural allograft may allow for reattachment of the hip abductors in an effort to preserve hip function and gait<sup>[3,29-33]</sup>.

The technique of reconstruction of large defects of the proximal femur using an allograft-prosthesis composite is very demanding. An appropriately sized allograft is osteotomized at the desired subtrochanteric level in order to match the bony defect of the proximal femur. Next, the allograft is reamed and broached and a long stem is cemented at the back table (Figure 8). Then, the allograft-prosthesis composite is implanted to the native femur with the use of cement or not, depending on the selected type of implant and the quality of host bone (Figure 9). Although the issue of proximal cementing of the stem into the proximal femoral allograft is well documented by Haddad *et al.*<sup>[34,35]</sup> and Gross *et al.*<sup>[36]</sup> showing that there is a high failure rate in cases of cementless fixation, there is no such a reconciliation regarding distal fixation into the host bone. In a recently published study, we have found that there is no statistically significant difference between cemented and cementless fixation regarding implant survivorship. Gross *et al.*<sup>[36]</sup> however have shown cementing the allograft-prosthesis composite distally into the host bone should probably be avoided because it might compromise the distal femur during future revision.

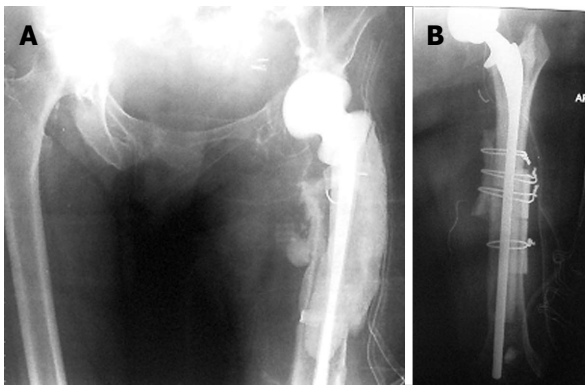
Size matching of the allograft to the host bone may be problematic, and has been addressed by the use of additional cortical struts and circumferential cables or wires. Intussusception of the allograft bone into the host bone has also been reported in cases of significant allograft-host canal mismatch<sup>[3,31]</sup>. When rigidly fixed, strut grafts may also provide an extensive surface area of contact with the host bone for supplemental union and incorporation<sup>[37]</sup>. Several techniques have been utilized in order to improve the rotational stability of the whole construct, including different types of osteotomies (oblique, step-cut, lateral sleeve) or stabilization with the use of additional hardware (plates and screws, plates and cables, strut grafts and cables).

While the published results of APC technique have been encouraging, they have generally involved relatively short-term follow-up. However, interpretation of many clinical studies is problematic because they use different (or no) classifications for proximal bone loss and utilize different surgical techniques of allograft fixation. The reported survival rates of APC reconstruction vary in the current literature, ranging from 72 to 90 percent at five years and 64 to 86 percent at ten years<sup>[35,38-41]</sup>. We have recently published a study with probably the longest clinical follow-up showing a survival rate that reaches 92.7 percent at two years 78.2 percent at five years, and 69 percent at ten years<sup>[3]</sup>.

Allograft resorption has been reported as the major concern, which has been occasionally associated with early failures and could be a significantly greater problem at



**Figure 8** The allograft is reamed and broached and a long stem is cemented at the back table. A: Intraoperative picture demonstrating the allograft-prosthesis composite preparation. An allograft of appropriate size is osteotomized at the desired subtrochanteric level in order to match the bony defect of the proximal femur. The allograft is reamed and broached and a long stem is cemented at the back table; B: Intraoperative picture showing the allograft-prosthesis composite with a lateral sleeve that offers a wide area of bone contact with the distal host femur. Circlage cables are used to secure the allograft-host bone fixation.



**Figure 9** The allograft-prosthesis composite is implanted to the native femur with the use of cement or not, depending on the selected type of implant and the quality of host bone. A: Anteroposterior (AP) radiograph of the pelvis demonstrating a Paprosky type IV femoral defect of the left hip as a result of a periprosthetic infection. The femoral canal is widened and there is no sufficient diaphyseal support for future cementless fixation; B: Postoperative AP radiograph of the left hip showing reconstruction of the proximal femoral defect with the use of an allograft-prosthesis composite. Remnants of the host bone are wrapped-around the femur at the level of the allograft-host bone junction in order to improve incorporation of the allograft to the host femur.

a longer follow-up<sup>[41,42]</sup>. Immunological matching between allograft and host femora, condition of the soft tissues attachments and vascularity of the host bed are other parameters that may affect incorporation of the allograft and could be related to the survivorship of the APC reconstructions<sup>[33,41,42]</sup>.

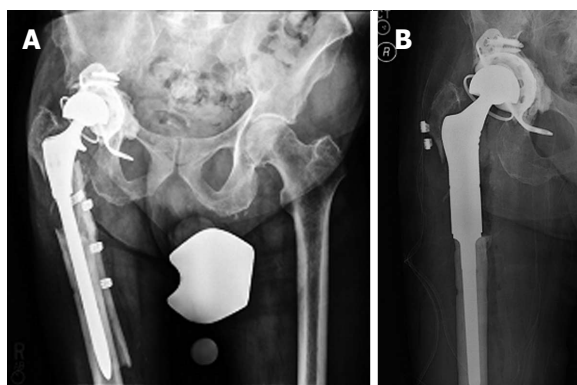
Resorption of the allograft is a potential complication. Resorption is usually found at the periosteal surface of the allograft<sup>[38,43,44]</sup>. A possible explanation is that the cement on the endosteal surface inhibits access by host granulation tissue<sup>[38,43,44]</sup>. Contrarily, on the periosteal surface there is access to host tissue and, therefore, neo-vascularization may lead to bone resorption<sup>[38,43,44]</sup>. By using strong cortical allograft bone, this process is expected to be evident at a later stage, and therefore composite graft-cement-implant reconstructions should last for an adequate period of time. Gross *et al*<sup>[45]</sup> reviewed 168 proximal

femoral allografts reporting only one significant and six minor resorptions at an average follow up of 4.8 years. In another study, Masri *et al*<sup>[46]</sup> found four mild and ten severe resorptions in thirty-nine cases at mean 5.1 years postoperatively. Haddad *et al*<sup>[41]</sup> used cementing technique to both proximal and distal femur in forty femoral revisions and found nine cases with mild resorption, four with moderate, and seven with severe resorption, which resulted in an overall 50 percent resorption rate at 8.8 years. Blackley *et al*<sup>[38]</sup> opted to wrap the remnants of the proximal femur around the allograft; the authors found twelve mild to moderate and only one severe resorption in forty-eight allograft-prosthesis composites eleven years post revision surgery. Safir *et al*<sup>[47]</sup> conducted a study with a minimum 15 year-follow-up, and showed that minor resorption was radiographically evident in 93 hips resulting in an overall resorption rate of 58%.

The literature shows a large variety of complications and a wide range of complication rates associated with proximal femur reconstructions using APCs. Hip dislocations, allograft-host bone junction non-unions, postoperative infections, periprosthetic fractures and aseptic loosening of the femoral components are the most significant complications. The incidence of these complications is quite variable: Hip dislocation is seen in 3.1% to 54% of cases, nonunion of the allograft host bone junction in 4.7% to 20%, trochanteric non union in 25% to 27%, postoperative infection in 3.3% to 8%, periprosthetic fracture in 2% to 5%, and aseptic loosening in 1 to 12 percent<sup>[3,29,30,32,33,35,36,38,41,45,48]</sup>.

Proximal femur replacement using the so-called “mega-prostheses” is an alternative option in cases of severe proximal femoral bone loss<sup>[49,50]</sup> (Figure 10). These implants are primarily designed for reconstruction of large bony defects after tumour resection, but they have also been utilized to replace the deficient proximal femur during hip revision surgery. In general, our philosophy is to use proximal femoral replacement implants in older, less active patients. The Mayo experience with proximal femoral replacement prostheses<sup>[50]</sup> showed survivorship





**Figure 10** Proximal femur replacement using the so-called “mega-prostheses” is an alternative option in cases of severe proximal femoral bone loss. A: Anteroposterior (AP) radiograph of the pelvis showing a left revision total hip arthroplasty in a 82-year-old male patient with an extensive structural defect of the lateral femoral cortex resulting in a painful and mechanically loose construct of a periprosthetic hip fracture; B: Postoperative AP radiograph of the right hip showing the replacement of the proximal femur with a megaprosthesis.

of the femoral component, with revision as the endpoint, of 81 per cent at eleven years. However, the improvement in function was not statistically significant. Deficiency of the abductor mechanism or inability to secure the abductor mechanism to the metal surface of the implant is a major concern associated with the use of megaprostheses<sup>[37]</sup>. New prosthetic designs offer several options for re-attachment of the abductors. However, insufficiency of their function is associated with high dislocation rates, which still remains the major drawback of this type of reconstruction. Nonetheless, current proximal femur replacement may be best suited for the elderly and inactive patients for whom resection arthroplasty would probably be the only alternative<sup>[49,50]</sup>.

## CONCLUSION

Reconstruction of the proximal femur during revision surgery is a challenging procedure. The remaining supportive bone of the metaphyseal and diaphyseal segments of the femur is the main contributing factors to determine the selection of the appropriate reconstructive option during revision surgery. Planning ahead is always essential to assure that multiple reconstructive techniques will be available at the time of surgery.

With regards to reconstruction of massive proximal femoral bone defects allograft-implant composites consist a more biologic reconstructive technique. This is a very demanding and challenging procedure that requires meticulous preoperative planning; it is time-consuming and potential intraoperative modifications may be needed. Ten-year survival rates reach 70%. Considering the complexity of these cases, the reported clinical and radiographic outcome of APCs is satisfactory. A stable allograft-host junction is essential for success. Allograft-host femoral canal mismatch can be managed with the intussusception technique, which is a good alternative over standard step-cut osteotomies. Distal fixation can

be achieved using either cemented or cementless stems without compromising total survivorship. Proximal femur replacement consists a viable alternative that is best suited for elderly and inactive patients.

## REFERENCES

- 1 Kurtz S, Mowat F, Ong K, Chan N, Lau E, Halpern M. Prevalence of primary and revision total hip and knee arthroplasty in the United States from 1990 through 2002. *J Bone Joint Surg Am* 2005; **87**: 1487-1497 [PMID: 15995115 DOI: 10.2106/JBJS.D.02441]
- 2 Lohmander LS, Engesaeter LB, Herberts P, Ingvarsson T, Lucht U, Puolakka TJ. Standardized incidence rates of total hip replacement for primary hip osteoarthritis in the 5 Nordic countries: similarities and differences. *Acta Orthop* 2006; **77**: 733-740 [PMID: 17068703 DOI: 10.1080/17453670610012917]
- 3 Babis GC, Sakellariou VI, O'Connor MI, Hanssen AD, Sim FH. Proximal femoral allograft-prosthesis composites in revision hip replacement: a 12-year follow-up study. *J Bone Joint Surg Br* 2010; **92**: 349-355 [PMID: 20190304 DOI: 10.1302/0301-620X.92B3.23112]
- 4 D'Antonio J, McCarthy JC, Bargar WL, Borden LS, Cappelo WN, Collis DK, Steinberg ME, Wedge JH. Classification of femoral abnormalities in total hip arthroplasty. *Clin Orthop Relat Res* 199; **(296)**: 133-139 [PMID: 8222415]
- 5 Valle CJ, Paprosky WG. Classification and an algorithmic approach to the reconstruction of femoral deficiency in revision total hip arthroplasty. *J Bone Joint Surg Am* 2003; **85-A** Suppl 4: 1-6 [PMID: 14652388]
- 6 Saleh KJ, Holtzman J, Gafni A, Saleh L, Davis A, Resig S, Gross AE. Reliability and intraoperative validity of preoperative assessment of standardized plain radiographs in predicting bone loss at revision hip surgery. *J Bone Joint Surg Am* 2001; **83-A**: 1040-1046 [PMID: 11451973]
- 7 Toms AP, Smith-Bateman C, Malcolm PN, Cahir J, Graves M. Optimization of metal artefact reduction (MAR) sequences for MRI of total hip prostheses. *Clin Radiol* 2010; **65**: 447-452 [PMID: 20451011 DOI: 10.1016/j.crad.2009.12.014]
- 8 Cameron HU. The long-term success of modular proximal fixation stems in revision total hip arthroplasty. *J Arthroplasty* 2002; **17**: 138-141 [PMID: 12068425 DOI: 10.1054/arth.2002.32462]
- 9 Emerson RH, Head WC, Higgins LL. Clinical and radiographic analysis of the Mallory-Head femoral component in revision total hip arthroplasty. A minimum 8.8-year and average eleven-year follow-up study. *J Bone Joint Surg Am* 2003; **85-A**: 1921-1926 [PMID: 14563799]
- 10 Kwong LM, Miller AJ, Lubinus P. A modular distal fixation option for proximal bone loss in revision total hip arthroplasty: a 2- to 6-year follow-up study. *J Arthroplasty* 2003; **18**: 94-97 [PMID: 12730939 DOI: 10.1054/arth.2003.50083]
- 11 McCarthy JC, Lee JA. Complex revision total hip arthroplasty with modular stems at a mean of 14 years. *Clin Orthop Relat Res* 2007; **465**: 166-169 [PMID: 17891035]
- 12 Paprosky WG, Aribindi R. Hip replacement: treatment of femoral bone loss using distal bypass fixation. *Instr Course Lect* 2000; **49**: 119-130 [PMID: 10829168]
- 13 Paprosky WG, Greidanus NV, Antoniou J. Minimum 10-year-results of extensively porous-coated stems in revision hip arthroplasty. *Clin Orthop Relat Res* 1999; **(369)**: 230-242 [PMID: 10611878 DOI: 10.1097/00003086-199912000-00024]
- 14 Weeden SH, Paprosky WG. Minimal 11-year follow-up of extensively porous-coated stems in femoral revision total hip arthroplasty. *J Arthroplasty* 2002; **17**: 134-137 [PMID: 12068424 DOI: 10.1054/arth.2002.32461]
- 15 Lawrence JM, Engh CA, Macalino GE, Lauro GR. Outcome



- of revision hip arthroplasty done without cement. *J Bone Joint Surg Am* 1994; **76**: 965-973 [PMID: 8027124]
- 16 **Duncan CP**, Masterson EL, Masri BA. Impaction allografting with cement for the management of femoral bone loss. *Orthop Clin North Am* 1998; **29**: 297-305 [PMID: 9553574 DOI: 10.1016/S0030-5898(05)70327-8]
  - 17 **Halliday BR**, English HW, Timperley AJ, Gie GA, Ling RS. Femoral impaction grafting with cement in revision total hip replacement. Evolution of the technique and results. *J Bone Joint Surg Br* 2003; **85**: 809-817 [PMID: 12931796]
  - 18 **Lamberton TD**, Kenny PJ, Whitehouse SL, Timperley AJ, Gie GA. Femoral impaction grafting in revision total hip arthroplasty: a follow-up of 540 hips. *J Arthroplasty* 2011; **26**: 1154-1160 [PMID: 21570802 DOI: 10.1016/j.arth.2011.03.028]
  - 19 **Morgan HD**, Leopold SS. Impaction allografting of the femur in revision total hip surgery. *Am J Orthop (Belle Mead NJ)* 2004; **33**: 381-383 [PMID: 15379231]
  - 20 **Morgan HD**, McCallister W, Cho MS, Casnellie MT, Leopold SS. Impaction allografting for femoral component revision: clinical update. *Clin Orthop Relat Res* 2004; **(420)**: 160-168 [PMID: 15057092 DOI: 10.1097/00003086-200403000-00022]
  - 21 **Ornstein E**, Linder L, Ranstam J, Lewold S, Eisler T, Torper M. Femoral impaction bone grafting with the Exeter stem - the Swedish experience: survivorship analysis of 1305 revisions performed between 1989 and 2002. *J Bone Joint Surg Br* 2009; **91**: 441-446 [PMID: 19336801 DOI: 10.1302/0301-620X.91B4.21319]
  - 22 **Regis D**, Sandri A, Bonetti I. Long-term results of femoral revision with the Wagner Self-Locking stem. *Surg Technol Int* 2013; **23**: 243-250 [PMID: 24081844]
  - 23 **Van Houwelingen AP**, Duncan CP, Masri BA, Greidanus NV, Garbuz DS. High survival of modular tapered stems for proximal femoral bone defects at 5 to 10 years followup. *Clin Orthop Relat Res* 2013; **471**: 454-462 [PMID: 22948527 DOI: 10.1007/s11999-012-2552-8]
  - 24 **Rodriguez JA**, Deshmukh AJ, Klauser WU, Rasquinha VJ, Lubinus P, Ranawat CS. Patterns of osseointegration and remodeling in femoral revision with bone loss using modular, tapered, fluted, titanium stems. *J Arthroplasty* 2011; **26**: 1409-1417.e1 [PMID: 21855273 DOI: 10.1016/j.arth.2011.06.021]
  - 25 **McInnis DP**, Horne G, Devane PA. Femoral revision with a fluted, tapered, modular stem seventy patients followed for a mean of 3.9 years. *J Arthroplasty* 2006; **21**: 372-380 [PMID: 16627145 DOI: 10.1016/j.arth.2005.08.022]
  - 26 **Kop AM**, Keogh C, Swarts E. Proximal component modularity in THA--at what cost? An implant retrieval study. *Clin Orthop Relat Res* 2012; **470**: 1885-1894 [PMID: 22048865 DOI: 10.1007/s11999-011-2155-9]
  - 27 **Pluhar GE**, Heiner JP, Manley PA, Bogdanske JJ, Vanderby R, Markel MD. Comparison of three methods of gluteal muscle attachment to an allograft/endoprosthesis composite in a canine model. *J Orthop Res* 2000; **18**: 56-63 [PMID: 10716279]
  - 28 **Dallari D**, Pignatti G, Stagni C, Giavaresi G, Del Piccolo N, Rani N, Veronesi F, Fini M. Total hip arthroplasty with shortening osteotomy in congenital major hip dislocation sequelae. *Orthopedics* 2011; **34**: e328-e333 [PMID: 21815571]
  - 29 **Donati D**, Giacomini S, Gozzi E, Mercuri M. Proximal femur reconstruction by an allograft prosthesis composite. *Clin Orthop Relat Res* 2002; **(394)**: 192-200 [PMID: 11795733 DOI: 10.1097/00003086-200201000-00023]
  - 30 **Farid Y**, Lin PP, Lewis VO, Yasko AW. Endoprosthetic and allograft-prosthetic composite reconstruction of the proximal femur for bone neoplasms. *Clin Orthop Relat Res* 2006; **442**: 223-229 [PMID: 16394765 DOI: 10.1097/01.blo.0000181491.39048.fe]
  - 31 **Lee SH**, Ahn YJ, Chung SJ, Kim BK, Hwang JH. The use of allograft prosthesis composite for extensive proximal femoral bone deficiencies: a 2- to 9.8-year follow-up study. *J Arthroplasty* 2009; **24**: 1241-1248 [PMID: 19646843 DOI: 10.1016/j.arth.2009.06.006]
  - 32 **Roque PJ**, Mankin HJ, Malchau H. Proximal femoral allograft: prognostic indicators. *J Arthroplasty* 2010; **25**: 1028-1033 [PMID: 19879727 DOI: 10.1016/j.arth.2009.07.018]
  - 33 **Wang JW**, Wang CJ. Proximal femoral allografts for bone deficiencies in revision hip arthroplasty: a medium-term follow-up study. *J Arthroplasty* 2004; **19**: 845-852 [PMID: 15483799 DOI: 10.1016/j.arth.2004.02.035]
  - 34 **Haddad FS**, Garbuz DS, Masri BA, Duncan CP, Hutchison CR, Gross AE. Femoral bone loss in patients managed with revision hip replacement: results of circumferential allograft replacement. *Instr Course Lect* 2000; **49**: 147-162 [PMID: 10829171]
  - 35 **Haddad FS**, Spangehl MJ, Masri BA, Garbuz DS, Duncan CP. Circumferential allograft replacement of the proximal femur. A critical analysis. *Clin Orthop Relat Res* 2000; **(371)**: 98-107 [PMID: 10693554 DOI: 10.1097/00003086-200002000-00011]
  - 36 **Gross AE**, Hutchison CR. Proximal femoral allografts for reconstruction of bone stock in revision hip arthroplasty. *Orthopedics* 1998; **21**: 999-1001 [PMID: 9769045]
  - 37 **Crawford SA**, Siney PD, Wroblewski BM. Revision of failed total hip arthroplasty with a proximal femoral modular cemented stem. *J Bone Joint Surg Br* 2000; **82**: 684-688 [PMID: 10963166 DOI: 10.1302/0301-620X.82B5.10685]
  - 38 **Blackley HR**, Davis AM, Hutchison CR, Gross AE. Proximal femoral allografts for reconstruction of bone stock in revision arthroplasty of the hip. A nine to fifteen-year follow-up. *J Bone Joint Surg Am* 2001; **83-A**: 346-354 [PMID: 11263637]
  - 39 **Head WC**, Berklacich FM, Malinin TI, Emerson RH. Proximal femoral allografts in revision total hip arthroplasty. *Clin Orthop Relat Res* 1987; **(225)**: 22-36 [PMID: 3315377]
  - 40 **Zmolek JC**, Dorr LD. Revision total hip arthroplasty. The use of solid allograft. *J Arthroplasty* 1993; **8**: 361-370 [PMID: 8409987 DOI: 10.1016/S0883-5403(06)80034-3]
  - 41 **Haddad FS**, Garbuz DS, Masri BA, Duncan CP. Structural proximal femoral allografts for failed total hip replacements: a minimum review of five years. *J Bone Joint Surg Br* 2000; **82**: 830-836 [PMID: 10990306 DOI: 10.1302/0301-620X.82B6.10485]
  - 42 **Chandler H**, Clark J, Murphy S, McCarthy J, Penenberg B, Danylchuk K, Roehr B. Reconstruction of major segmental loss of the proximal femur in revision total hip arthroplasty. *Clin Orthop Relat Res* 1994; **(298)**: 67-74 [PMID: 8118997]
  - 43 **Roos BD**, Roos MV, Camisa A. Circumferential proximal femoral allografts in revision hip arthroplasty: four to 20 years follow-up. *Hip Int* 2013; **23**: 66-71 [PMID: 23423656]
  - 44 **Sporer SM**, Paprosky WG. Femoral fixation in the face of considerable bone loss: the use of modular stems. *Clin Orthop Relat Res* 2004; **(429)**: 227-231 [PMID: 15577492 DOI: 10.1097/01.blo.0000150120.80409.0d]
  - 45 **Gross AE**, Hutchison CR. Proximal femoral allografts for reconstruction of bone stock in revision arthroplasty of the hip. *Orthop Clin North Am* 1998; **29**: 313-317 [PMID: 9553576 DOI: 10.1016/S0030-5898(05)70329-1]
  - 46 **Masri BA**, Masterson EL, Duncan CP. The classification and radiographic evaluation of bone loss in revision hip arthroplasty. *Orthop Clin North Am* 1998; **29**: 219-227 [PMID: 9553567 DOI: 10.1016/S0030-5898(05)70320-5]
  - 47 **Safir O**, Kellett CF, Flint M, Backstein D, Gross AE. Revision of the deficient proximal femur with a proximal femoral allograft. *Clin Orthop Relat Res* 2009; **467**: 206-212 [PMID: 18972178 DOI: 10.1007/s11999-008-0573-0]
  - 48 **Biau DJ**, Larousserie F, Thévenin F, Piperno-Neumann S, Anract P. Results of 32 allograft-prosthesis composite reconstructions of the proximal femur. *Clin Orthop Relat Res* 2010; **468**: 834-845 [PMID: 19851817 DOI: 10.1007/s11999-009-1132-z]
  - 49 **Parvizi J**, Sim FH. Proximal femoral replacements with

megaprotheses. *Clin Orthop Relat Res* 2004; **(420)**: 169-175  
[PMID: 15057093 DOI: 10.1097/00003086-200403000-00023]


50 **Parvizi J**, Tarity TD, Slenker N, Wade F, Trappier R, Hozack

WJ, Sim FH. Proximal femoral replacement in patients with non-neoplastic conditions. *J Bone Joint Surg Am* 2007; **89**: 1036-1043 [PMID: 17473141 DOI: 10.2106/JBJS.F.00241]

**P- Reviewer:** Cartmell S, Emara KM, Maheshwari AV, Vilaboa N

**S- Editor:** Song XX **L- Editor:** A **E- Editor:** Wu HL





WJO 5<sup>th</sup> Anniversary Special Issues (7): Shoulder

## Functional outcomes assessment in shoulder surgery

James D Wylie, James T Beckmann, Erin Granger, Robert Z Tashjian

James D Wylie, James T Beckmann, Erin Granger, Robert Z Tashjian, Department of Orthopaedic Surgery, University of Utah, Salt Lake City, UT 84108, United States

Author contributions: Wylie JD, Beckmann JT, Granger E and Tashjian RZ solely contributed to the concept, writing and editing of this paper.

Correspondence to: Robert Z Tashjian, MD, Department of Orthopaedic Surgery University of Utah, 590 Wakara Way, Salt Lake City, UT 84108,

United States. [robert.tashjian@hsc.utah.edu](mailto:robert.tashjian@hsc.utah.edu)

Telephone: +1-801-5875457 Fax: +1-801-5875411

Received: May 26, 2014 Revised: July 3, 2014

Accepted: July 18, 2014

Published online: November 18, 2014

in computer adaptive testing as it relates to assessing dysfunction in shoulder conditions will also be reviewed.

© 2014 Baishideng Publishing Group Inc. All rights reserved.

**Key words:** Shoulder; Functional outcome; Quality-of-life; Health utility measure; Patient reported outcome

**Core tip:** Health related quality of life evaluation includes general health measures, health utility measures, general shoulder measures and condition specific shoulder measures. A combination of a general/health utility measure with a shoulder measure or condition specific measure is needed to fully capture outcomes in the treatment of shoulder conditions.

### Abstract

The effective evaluation and management of orthopaedic conditions including shoulder disorders relies upon understanding the level of disability created by the disease process. Validated outcome measures are critical to the evaluation process. Traditionally, outcome measures have been physician derived objective evaluations including range of motion and radiologic evaluations. However, these measures can marginalize a patient's perception of their disability or outcome. As a result of these limitations, patient self-reported outcomes measures have become popular over the last quarter century and are currently primary tools to evaluate outcomes of treatment. Patient reported outcomes measures can be general health related quality of life measures, health utility measures, region specific health related quality of life measures or condition specific measures. Several patients self-reported outcomes measures have been developed and validated for evaluating patients with shoulder disorders. Computer adaptive testing will likely play an important role in the arsenal of measures used to evaluate shoulder patients in the future. The purpose of this article is to review the general health related quality-of-life measures as well as the joint-specific and condition specific measures utilized in evaluating patients with shoulder conditions. Advances

Wylie JD, Beckmann JT, Granger E, Tashjian RZ. Functional outcomes assessment in shoulder surgery. *World J Orthop* 2014; 5(5): 623-633 Available from: URL: <http://www.wjgnet.com/2218-5836/full/v5/i5/623.htm> DOI: <http://dx.doi.org/10.5312/wjo.v5.i5.623>

### INTRODUCTION

Measuring outcome of orthopedic procedures has changed remarkably over the last twenty to thirty years. Objective physician measurements in large part have given way to subjective patient reported outcome measures<sup>[1]</sup>. The driving force for this was the inherent bias in the clinician assessment along with how this assessment method marginalized the patient's perception of their outcome<sup>[2-4]</sup>. Quality of life is the main outcome measure in orthopedics due to the simple fact that most orthopaedic interventions do not increase a patient's life span, so survival is not a realistic outcome measure. A growing body of literature has evolved over the past 30 years regarding measurement of health related quality of life in orthopedic patients, and more specifically patients with

shoulder disorders, both at baseline and after operative or non-operative intervention.

Patient reported health related quality of life (HRQoL) can be measured in multiple ways. Activity level measures reflect the effect of a disease or intervention on a patient's ability to recreate; these are more commonly used in the evaluation of lower extremity disease because the lower extremity has a more profound effect upon patient activity<sup>[5]</sup>. However, a shoulder activity level questionnaire has been published but so far used sparingly in the literature<sup>[6,7]</sup>. General HRQoL measures evaluate the effect of a condition on the patients overall health. These measures may be less responsive to shoulder diseases and their treatment because they are designed to evaluate patients general well being<sup>[8]</sup>. Health utility measures allow calculation of quality adjusted life years (QALY) and are used to economically evaluate treatments<sup>[9]</sup>. Shoulder HRQoL measures are designed to either be general shoulder measures or condition specific measures that are validated only for certain diagnoses<sup>[10,11]</sup>. The more specific the measure, the more change that can be elucidated in treatment of a given shoulder condition, however the more general the measure the better it judges the patient's change in overall health. This article will review the various patient reported measures used to evaluate patients with shoulder disorders and the outcome of their treatment.

## GENERAL HRQOL AND HEALTH UTILITY MEASURES

General HRQoL measures are commonly used across medical specialties. This fact underscores their importance in the evaluation of patient outcomes from orthopedic conditions. Including general health measures in the evaluation of shoulder treatment allows the comparison of quality of life improvements from orthopedic intervention to those across other organ systems, and can be used to compare the effect of treatment of shoulder conditions to those of the lower extremities. In the current era of healthcare reform, using general HRQoL and health utility measures to evaluate the effect of shoulder treatment compared to that of other conditions across the body will be important to justify health care dollars for the treatment of shoulder disease<sup>[12]</sup>. This section will review the most commonly used general HRQoL and health utility measures in orthopaedics.

The medical outcomes study short form-36 (SF-36) was originally described in 1992 and is the most commonly used tool to assess general health-related quality of life<sup>[13,14]</sup>. The Sickness Impact Profile and the Nottingham Health Profile are other general health related quality of life measures that are less commonly used in the orthopaedic literature but their properties and usefulness in musculoskeletal conditions have been recently reviewed<sup>[15]</sup>. The SF-36 measures eight dimensions of general health [physical functioning (PF), Role Physical, Bodily Pain, General Health, Vitality, Social Functioning (SF), Role Emotional, and Mental Health] and has two

summary scores [physical component score (PCS) and mental -component score (MCS)]. The scales are scored based on general United States population norms with a mean of 50 and a standard deviation of 10, with a score of 50 for each scale representing "average" health. The Short-Form-12 (SF-12) was described shortly thereafter and is a validated brief subset of the SF-36 that provides good approximation of the SF-36 summary scores (PCS and MCS) and only moderate approximation of the eight SF-36 domains<sup>[16]</sup>.

The Short Forms are the most commonly used general health related quality of life measure in orthopedics and medical research at large<sup>[8,17]</sup>. It has been extensively validated and is responsive to treatment of many disease states. For detailed explanation, extensive references, and information on use of the Short Forms please visit [www.sf-36.org](http://www.sf-36.org). The SF-36 has been used to evaluate patients after a variety of shoulder surgical procedures including rotator cuff repair, anatomic shoulder arthroplasty and reverse total shoulder arthroplasty<sup>[18,19]</sup>. In general the PCS component of the SF-36 score improves after surgical treatment while the MCS component has little change<sup>[19,20]</sup>. Rotator cuff tears, glenohumeral arthritis, anterior glenohumeral instability, adhesive capsulitis and impingement have been determined to rank in severity with hypertension, congestive heart failure, acute myocardial infarction, diabetes mellitus and clinical depression as evaluated by the SF-36<sup>[21]</sup>. Boorman *et al*<sup>[22]</sup> has found that while anatomic total shoulder arthroplasty does not restore general health status to age adjusted controls it does provide improvement to the same level as seen after coronary artery bypass surgery. Finally, most shoulder outcome instruments do not adequately reflect general health-related quality of life<sup>[23,24]</sup>. Consequently, inclusion of general health-related quality of life measures in the evaluation of shoulder conditions is recommended not only because shoulder outcome instruments do not adequately capture general health status but also as a tool to compare the outcomes and utility of shoulder diseases and their treatments to other disease processes.

Health utility measures are another option for the measurement of general HRQoL. These measures were developed for use in health economics studies. They judge the patients health status on a scale that includes 1.0 as perfect health and 0.0 as death, however there are conditions that can be negative, as they are considered worse than death from a quality of life standpoint<sup>[12,25]</sup>. The reason that these are scaled from 0.0 to 1.0 is that this makes calculations for QALY easy for economic analyses and allows comparisons of cost per QALY between different conditions and treatments, for example justifying the cost of rotator cuff repair. Vitale *et al*<sup>[26]</sup> showed that the cost per improvement in quality of life from rotator cuff repair was the equivalent of total hip arthroplasty, coronary artery bypass, and more cost efficient than the medical treatment of hypertension. Commonly used health utility measures are the EuroQol 5-domain (EQ-5D) and the Short Form 6D (SF-6D), among others, whose properties are beyond the scope of this review but have been



recently reviewed<sup>[15]</sup>. Of note, the SF-6D can be calculated if either the SF-36 or the SF-12 is administered as a general HRQoL measure. Health utility measures are an important evaluation tool to include in the functional assessment of shoulder problems if the plan is to understand the financial implications of treatment.

## SHOULDER HRQOL MEASURES

While general HRQoL measures are an important part of evaluating patients with shoulder disease, they are not responsive enough to evaluate a patient's overall level of dysfunction in isolation<sup>[8]</sup>. Some patients with improvement in shoulder function show a decrease in their SF-36 scales after treatment, likely due to the deterioration of other conditions affecting their general health at the same time as their improvement in shoulder pain/function<sup>[27]</sup>. Because of this, tools evaluating the shoulder or specific disease affecting the shoulder need to be used to complement general HRQoL measures. There have been over thirty shoulder questionnaires described in the literature for evaluation of shoulder pathology<sup>[5]</sup>. These can be broken down into general shoulder measures and condition (disease) specific shoulder measures.

General shoulder measures are recommended for practice-based evaluation of a heterogeneous group of patients undergoing treatment for shoulder conditions. Condition or disease specific shoulder measures are designed to evaluate homogenous groups of patients with a specific diagnosis and are highly recommended for controlled trials evaluating a specific shoulder disorder. In general, condition specific shoulder measures are less commonly utilized in comparison to the general shoulder measures. The shoulder disorder requiring a condition specific measure the greatest is shoulder instability since many patients with symptomatic shoulder instability have a ceiling effect with general shoulder measures<sup>[28]</sup>. This section will outline the most commonly utilized general shoulder measures (Table 1) as well as condition specific measures for glenohumeral instability and rotator cuff disease (Table 2).

## GENERAL SHOULDER MEASURES

### *The Constant-Murley score*

The Constant-Murley score (CMS) was developed in 1986 and published in 1987 to better estimate the overall functional state of normal and diseased shoulders<sup>[29]</sup>. A higher score indicates better shoulder function. The CMS continues to be the most commonly reported outcome scale in Europe<sup>[11]</sup>. The scale combines two fundamentally different metrics: physical examination findings of motion and strength (65 points), and patient-reported subjective evaluation of shoulder function (35 points). In the original description of the CMS, there was no rationale reported for the development and selection of items, or the relative weighting of each component: 15% pain, 20% patient-reported function with activities of daily living, 40% range of motion, and 25% strength testing.

Combining performance-based measures with patient-reported outcomes could be considered an advantage of the CMS; however, it is likely that the reliability of the Constant-Murley score is reduced because patient assessment does not necessarily correlate with objective measurements of shoulder function<sup>[30-32]</sup>. Still, several studies evaluating the surgical treatment of rotator cuff tears and proximal humerus fractures have found satisfactory correlation between the Constant score and other patient-reported measures<sup>[33,34]</sup>.

The reliability of the Constant score has been questioned with a reported variation between observers as high as 10 units (out of a possible 100)<sup>[35]</sup>. Conboy *et al*<sup>[36]</sup> found a low interobserver reliability with 3 different observers evaluating 25 patients using the CMS. On average, these observers differed significantly with regards to total score; the 95% confidence interval that a single measurement represented the true score was 17.7 points. These large, unsatisfactory standard errors contrast the high reliability found in the original publication, where only a 3% interobserver error was reported between 3 observers in 100 abnormal shoulders<sup>[29]</sup>. Measurement error is most likely attributable to wide variations in strength testing methodology, which was inadequately explained in the original description. Constant *et al*<sup>[37]</sup> published modifications and guidelines for use of the CMS in 2008 to address these concerns.

Potential advantages of the CMS include its widespread use and prolonged existence, allowing for comparisons across procedure and time. Accordingly, population normative values of the CMS have been established, which aid in score interpretation<sup>[38]</sup>. Recently, minimum clinically important differences (MCIDs) for the CMS have been reported improving the ability to interpret the clinical relevance of the score as well as design studies using the CMS as the primary outcome tool<sup>[39]</sup>. The heavy weighting on range of motion and strength may be of benefit when assessing rotator cuff repairs and shoulder arthritis, but has been demonstrated to have problematic ceiling affects in instability patients<sup>[36,40]</sup>. Reliability, validity, and responsiveness of the CMS are detailed in Table 1.

### *The University of California Los Angeles shoulder score*

The University of California Los Angeles (UCLA) shoulder score was developed in 1981 before modern psychometric development was routinely used<sup>[41]</sup>. Consequently, the methods utilized in its development are not explained, including question development and weighting. The score is a combination of physical exam findings (active forward elevation and strength) and subjective patient-reported measures (pain, satisfaction, and function). Pain and function are preferentially weighted (20 out of 35 possible points). A higher score indicates better function. The UCLA score has been used to assess a variety of shoulder conditions including total shoulder arthroplasty, rotator cuff repair, and subacromial decompression<sup>[42,43]</sup>.

Limitations of the UCLA are inherent in its design. Many of the questions are double-barreled, meaning that multiple inquiries are combined within a single question.

**Table 1** General shoulder measures

Measure	Description	Validity	Reliability	Responsiveness	MCID
The constant score <sup>[36,39,74,75]</sup>	10 items: Physical Examination (4 motion, 1 strength) Subjective evaluation (1 pain, 4 ADL) Score: 0-100 (Higher = better) 65 points for physical examination 35 points for subjective evaluation	Criterion validity with WORC, Penn, SST, Oxford, and others. Weaker correlation with DASH, ASES, SF-36 Content validity - concern over methods for strength testing Construct validity high except for shoulder instability; scores and strength decrease with age for both sexes	Very good ICC for shoulder dysfunction 0.8-0.87 SEM 8.9	Excellent except for Shoulder instability Effect size: Arthroplasty: 2.23- 3.02 Rotator cuff repair: 1.92 Shoulder instability: 0.20	10.4
UCLA shoulder score <sup>[27,65,76-78]</sup>	5 items Likert pain scale (1) Function (1) Active forward elevation (1) Forward elevation strength (1) Patient satisfaction (yes/no) Score 0-35 10 pts for pain/function, 5 pts each for active forward elevation, strength, and satisfaction Can be converted to 0-100 pts for comparison	Criterion validity: Correlated sternly with Constant, ASES, and SF-36; fair to good correlation with SST; fair correlation with constant score; very good correlation with WOSI Construct validity: Demonstrated improvement after subacromial decompression; UCLA score had poor and fair correlation to forward motion and the abduction ratio respectively	Not evaluated	Limited Evaluation Effect size: Subacromial decompression 2.73 at 6 mo Proximal humerus fractures-moderate responsiveness	Not established
DASH <sup>[75,79]</sup>	30 items Physical activities in arm, shoulder, hand (21) symptoms of pain, tingling, weakness (5) Impact on social activities (4) Score: 0-100 (Lower = Better) Must answer 27 questions to be scored 4 optional sport/music/work items 12 yes/no items	Criterion validity: Correlated with other scores over different regions of the upper extremity and general outcome measures including the SF-36 Construct validity Difference between: working/not able to work; disease and health state; ability to do what they want versus not able	Excellent ICC: 0.77-0.98 SEM: 2.8-5.2	Excellent Effect size (all studies): 0.4-1.4	10 for shoulder complaints 17 for elbow, wrist and hand
SST <sup>[49,68,75]</sup>	11 items Pain VAS (1) Function (10) Score: 0-100 (Higher is better) 50 pts pain/50 pts function Physician assessment is not scored	Criterion validity: Strong correlation with ASES, moderately correlated with physical function portion of SF-12 Content validity Differences between: Age groups; shoulder instability versus rotator cuff injury; workers compensation status Criterion validity: Strong correlation with constant-Murley, UCLA, and SST; strong correlation with multiple rotator cuff specific scores; and highly correlated with the SF-12 functional domains, but not the emotional, mental health, and social portions. Content validity Differences found between: Gotten much better and slightly better; minimally, moderately, and maximally functionally limited	Excellent ICC: 0.97-0.99 SEM: N/E	Limited Evaluation Effect size 0.8 in shoulder instability and rotator cuff injuries	2 for rotator cuff disease
ASES evaluation form <sup>[55,56,75,80]</sup>	11 items Pain VAS (1) Function (10) Score: 0-100 (Higher is better) 50 pts pain/50 pts function Physician assessment is not scored	Criterion validity: Strong correlation with constant-Murley, UCLA, and SST; strong correlation with multiple rotator cuff specific scores; and highly correlated with the SF-12 functional domains, but not the emotional, mental health, and social portions. Content validity Differences found between: Gotten much better and slightly better; minimally, moderately, and maximally functionally limited	Excellent ICC: 0.84-0.96 SEM: 6.7	Excellent Effect size (all studies) 0.9-3.5	6.4 for various shoulder pathologies 12-17 for rotator cuff disease
PENN shoulder score <sup>[56,58,81-83]</sup>	24 items Pain VAS scales with rest, ADLs, strenuous activities (3) Patient satisfaction VAS (1) Functional assessment section (20) Score 0-100 (Higher = Better) Pain 30 pts Satisfaction 10 pts Function 60 pts	Criterion validity: Excellent correlation with constant; excellent to very good correlation with ASES; Content validity: PSS is negatively affected by chest related, but not other medical comorbidities; pain subscale was not responsive to surgical and nonsurgical treatments	Excellent ICC: 0.94 SEM: 8.5	Not rigorously evaluated Effect size of pain subscale 1.84 for all comers	11.4 for patients with shoulder problems undergoing physical therapy 21 for patients with impingement

UCLA: University of California Los Angeles; ASES: American shoulder and elbow surgeons; DASH: Disabilities of the arm, shoulder and hand; SST: Simple shoulder test; PENN: Pennsylvania; MCID: Minimum clinically important difference; SF-36: Short Form 36; SEM: Standard error of measurement; ICC: Intraclass correlation coefficient; VAS: Visual analog scale; ADL: Activity of daily living.

**Table 2 Condition specific shoulder measures**

Instability	Description	Validity	Reliability	Responsiveness	MCID
WOSI <sup>[62,63,84]</sup>	21 items: Physical symptoms (10) Sport/recreation/work function (4) Lifestyle function (4) Emotional function (3) Score: 0-2100 (Lower = Better) (can be converted into 0%-100% scale)	Content validity: Items established by experts and patients Criterion validity: Excellent Correlate: VAS Function and DASH, good with CMS and Rowe	Excellent ICC: 0.87-0.98	Excellent Effect size: 1.67 for stabilization	220/2100
OSIS <sup>[28,62]</sup>	12 Items: Score: 12-60 (Lower = Better)	Criterion validity: Correlated with rowe and constant scores	Excellent PCC: 0.97	Very good Effect size: 0.8	Not reported
MIIS <sup>[62,66]</sup>	22 items: Pain (4) Instability (5) Function (8) Occupation and sports (5) Score: 0-100 (lower = better)	Criterion validity: Low to moderate correlation with shoulder rating questionnaire. Otherwise untested	Excellent ICC: 0.98	Not reported	Not reported
Rowe score <sup>[63,64]</sup>	3 items: Stability (50 points) Motion (20 points) Function (30 points) Score: 0-100 (both subjective and examination dependant)	Content Validity: poorly described development and methodology Criterion Validity: Correlated with WOSI and CMS	Fair ICC 0.7	Very good Effect size 1.2	Not reported
Rotator cuff					
WORC <sup>[69]</sup>	21 items: Physical symptoms (10 items) Sport/recreation/work function (4 items) Lifestyle function (4 items) Emotional function (3 items) Score: 0-2100 (Lower = Better) (can be converted into 0%-100% scale)	Content validity: Items established by experts and patients Criterion validity: Correlated with ASES, DASH and UCLA	Excellent ICC: 0.96	Excellent Effect size: 0.96	245/2100
RCQoL <sup>[85]</sup>	34 items: Symptoms and physical complaints (16 items) Sport/recreation (4 items) Work related concerns (4 items) Lifestyle issues (5 items) -Social and Emotional Issues (5 items) Score: 0-3400 (Lower = Worse) (can be converted into 0-100 scale)	Content validity: Items established by experts and patients Criterion validity: Correlated with ASES. Construct validity: able to differentiate large and massive tears	Poor ICC: Not reported Reported as average difference of final score = 5%	Excellent Effect size: Not reported SRM: 1.43	Not reported

WOSI: The Western Ontario Shoulder Instability Index; OSIS: The Oxford Shoulder Instability Score; MIIS: The Melbourne Instability Shoulder Scale; WORC: The Western Ontario rotator cuff index; RCQoL: Rotator cuff quality-of-life measure; MCID: Minimum clinically important difference; ICC: Intra-class correlation coefficient; VAS: Visual analog scale; SRM: Standardized response mean.

For example, the pain scale responses address both frequency of pain along with analgesia type. Respondents might have difficulty picking an appropriate response to the question when they endorse only a portion of one selection, but not the entire response. Furthermore, the satisfaction portion of the instrument only allows for the UCLA score to be logically used post-intervention, making responsiveness impossible to determine. Like the Constant score, including both physical exam and patient self-assessment makes the UCLA multi-dimensional, meaning that it combines multiple domains into a single score. The reliability, validity, and responsiveness are poorly established compared to other outcome measures

(Table 1).

### **Disabilities of the arm, shoulder and hand**

The disabilities of the arm, shoulder and hand (DASH) was constructed in 1996 *via* a collaborative effort by the Council of musculoskeletal specialty societies, the American Academy of Orthopaedic Surgeons (AAOS), and the Institute for Work and Health<sup>[44]</sup>. Sophisticated psychometric techniques were used for item generation to help establish face validity. Lower scores are associated with improved function. The 30-question scale assesses multiple domains including physical function, symptoms, and social/psychological function.

The DASH is intended to measure shoulder, elbow, wrist, and hand function in one combined metric. By design, it does not discriminate between the affected and non-affected extremity. These two properties make the scale more generalizable, but could also be considered an inherent weakness. For example, functional items may not reflect a response to treatment if they mostly involve the dominant arm, especially when the non-dominant arm was treated. Despite the possible limitation of a more generalized score, Beaton *et al.*<sup>[45]</sup> found good correlation and responsiveness comparing the DASH and joint-specific measures in a combined population of shoulder, wrist, and hand patients; however, some studies have found only fair responsiveness with the DASH, especially regarding hand conditions<sup>[46]</sup>.

The DASH has been widely studied and offers several advantages. It has been validated in over 15 languages, and normative data has been established for American and Norwegian populations<sup>[5,47]</sup>. These normative values were 5 for both males and females between the ages of 20 and 29. They increased to 22 and 13 in females and males aged 70 to 79, respectively<sup>[47]</sup>. The MCID has been reported for both shoulder (MCID = 10) as well as elbow, wrist, and hand patients (MCID = 17)<sup>[48]</sup>. It is also freely distributed through the AAOS website and has been shown to be valid and reliable for many upper extremity conditions (Table 1). Even though the DASH has been rigorously correlated with shoulder-specific measures and has been shown to have sound psychometric properties, it has not been reported frequently in many shoulder-focused studies. Despite its psychometric properties, shoulder surgeons tend to favor more familiar scales such as the CMS, the American shoulder and Elbow surgeons (ASES), and the simple shoulder test (SST) allowing comparisons of outcomes with prior studies.

### The SST

SST was developed in 1992 to reduce responder burden and simplify the process of acquiring outcome information. Questions were developed from: (1) Neer's evaluation; (2) ASES evaluation; and (3) Patient complaints and inputs. All twelve questions require yes/no responses. Although this basic format simplifies the survey, the limited range of total points could limit the potential of the SST to detect small but clinically significant changes. The MCID for the SST has been found to be 2 points<sup>[49]</sup>.

The SST has overall sound psychometric properties. Known-group validity tests have shown that the SST can detect differences expected to be observed across different age groups, associated with different shoulder pathologies including instability and rotator cuff tears, and between worker's compensation patients and non-worker's compensation patients<sup>[50]</sup>. The test is responsive; patients with healed rotator cuff repairs score similarly to normal healthy controls with proven intact rotator cuff tendons by ultrasound<sup>[51]</sup>. The SST has also been able to distinguish between healthy patients and those with shoulder conditions including osteoarthritis, rheumatoid arthritis, rotator cuff tears, adhesive capsulitis, and instability. The

validity, reliability, and responsiveness of the SST are not as well developed as other measures, but it appears to be psychometrically sound based on available data (Table 1).

### The ASES

The ASES score was created by the Society of the American Shoulder and Elbow Surgeons to facilitate standardization of outcome measures and to promote multicenter trials in shoulder and elbow surgery<sup>[52]</sup>. The ASES score contains a physician-rated and patient-rated section; however, only the pain visual analog scale (VAS) and 10 functional questions are typically used to tabulate the reported ASES score. The total score - 100 maximum points - is weighted 50% for pain and 50% for function. Calculation of the ASES score is somewhat more arduous than other shoulder outcome measures<sup>[53]</sup>. The final pain score (maximum 50 points) is calculated by subtracting the VAS from 10 and multiplying by five. For the functional portion, each of 10 separate questions is scored on an ordinal scale from 0-3 for a maximal raw functional score of 30 points. The raw score is multiplied by 5/3 to make the maximal functional score out of 50 possible points. The pain and functional portions are then summed to obtain the final ASES score.

Psychometric properties of the ASES have been well established. The validity, reliability, and responsiveness have been assessed in a variety of shoulder problems including: rotator cuff disease, glenohumeral arthritis, shoulder instability, and shoulder arthroplasty<sup>[54,55]</sup>. The ASES score has also been shown to be valid, reliable, and responsive to non-operative treatments<sup>[56]</sup>. Minimal clinically important difference for the ASES ranges from 6.4 for various shoulder disorders to 12-17 points - depending on confidence level - in rotator cuff problems<sup>[49,56]</sup>. The ASES score has been translated into German and validated, but is not available in as many languages as the DASH. Correlation with other shoulder and upper extremity measures is high for the ASES score (Table 1).

Although the ASES score has been rigorously evaluated, some inherent limitations are noteworthy. Weighting of the ASES score favors the domains of pain and patient-reported function. Unlike the Constant-Murley score, physician assessment is not included in the final score. This could be considered both a strength and weakness of the ASES, but it should be noted in interpreting results. The shoulder instability VAS of the ASES has been removed in some versions, although the scale has still been responsive to instability treatments without this portion of the survey<sup>[55]</sup>. A final limitation is that higher functioning patients may experience ceiling effects due to the response structure<sup>[57]</sup>.

### Pennsylvania shoulder score

The Pennsylvania shoulder score (PSS) is a 100-point shoulder specific scale comprised of pain (30%), satisfaction (10%), and function (60%). There are three pain VAS scores: one each for pain at rest, pain with everyday activities, and pain with strenuous activities. Patient satisfaction is determined from 0-10 on numeric rating scale.



The remaining functional portion of the scale is comprised of 20 questions with maximal ordinal responses that are assigned a maximal value of 3 points each.

The psychometric properties of the PSS appear favorable, but this scale has not been rigorously tested in multiple investigations. Leggin *et al.*<sup>[58]</sup> performed the most thorough assessment of the PSS finding overall good reliability, internal consistency, and correlation with the ASES and CMS. The PSS was found to be responsive, and had an MCID of 11.4 in patients that underwent non-operative treatment of various shoulder problems.

The PSS has been used less frequently in the literature compared to other outcome scales discussed in this article. It seems that this outcome measure has been embraced regionally in the United States, with the majority of studies using the Penn shoulder scale originating out of only a handful of institutions. The PSS was used in one study that recommended against augmentation of large and massive rotator cuff tears with porcine xenografts<sup>[59]</sup>. Proximal humerus fractures, latissimus tendon transfers for irreparable rotator cuff, and non-operative therapies have all been evaluated with the PSS<sup>[58,60,61]</sup>.

## CONDITION SPECIFIC SHOULDER MEASURES

### **Instability**

Instability is the most common diagnosis in which condition specific measures are used. The presentation of patients with symptomatic instability is different from other shoulder pathology. After reduction of the acute dislocation, patients with symptomatic instability requiring treatment commonly present with recurrent instability or apprehension, not pain and decreased function as is more common with other shoulder diagnoses. This leads to poor responsiveness and significant ceiling effects when general shoulder measures are used for patients with instability<sup>[28]</sup>. Because of this, specific instability scores have been developed to study shoulder instability that are more responsive to treatment effects<sup>[62]</sup>. The most common validated patient reported outcome measures for shoulder instability are the Western Ontario Shoulder Instability Index (WOSI), the Oxford Shoulder Instability Score (OSIS), and the Melbourne Instability Shoulder Scale (MISS). However, the most commonly used evaluation is the Rowe score, which was also the first shoulder score described in 1978. The Rowe score, similar to the UCLA shoulder score, was first described before modern psychometric development was implemented limiting its psychometric properties<sup>[63,64]</sup>. The WOSI, MISS and OSIS have been developed with recent psychometric evaluations<sup>[28,65,66]</sup>. The properties of these scores are described in Table 2. The WOSI is more responsive to treatment of instability than the Rowe score in patients both non-operatively and operatively treated for traumatic instability<sup>[65,67]</sup>. Overall, the WOSI has the strongest psychometric properties and has undergone the most rigorous testing despite the fact that the Rowe is the most commonly re-

ported instability measure. Based upon the strength of its psychometric properties, the WOSI is the recommended condition specific instrument for shoulder instability.

### **Rotator cuff**

There had also been evaluation tools designed specifically for the evaluation of patients with rotator cuff disease. The two most common rotator cuff specific tools are the Western Ontario rotator cuff Index (WORC) and the rotator cuff quality-of-life measure (RCQoL). General shoulder measures are commonly used for patients with rotator cuff disease as well and these have been shown to be valid and responsive in this patient population<sup>[55,68]</sup>. Because of the utility of other general shoulder instruments the need for specific rotator cuff instruments is called into question. Overall, generalized shoulder instruments do not show the same kind of ceiling effect with rotator cuff disease that they do with instability. Again, the WORC has the strongest psychometric properties and has undergone the most rigorous testing<sup>[69]</sup>. This makes it the instrument of choice if a condition specific measure for rotator cuff disease is desired. The properties of these two scores are presented in Table 2.

## COMPUTER ADAPTIVE TESTING

The National Institutes of Health Roadmap Initiative has recently launched the Patient-Reported Outcomes Measurement Information System (PROMIS) that is available for clinical use for a variety of health domains, including physical function<sup>[70]</sup>. This novel instrument was developed to: (1) obtain precise estimations of specific health-related domains; (2) eliminate floor and ceiling effects by validating a large “bank” of questions; and (3) reduce patient respondent burden by minimizing the number of questions (typically only 3-5)<sup>[71]</sup>. PROMIS is made possible using computerized adaptive testing (CAT), which takes each individual’s previous answer into account when asking subsequent questions. By asking “intelligent” questions - *i.e.*, it is unnecessary to ask if a patient can comb their hair if they can throw a baseball - precise results can be achieved with only a few questions selected from a large item bank<sup>[72]</sup>. Therefore, different sets of questions will be administered to different individuals with the results reported on a common scale. This approach differs from classical test theory, where all (or nearly all) questions included in the static survey must be answered to use the metric<sup>[44]</sup>.

The PROMIS Physical Function CAT (PF-CAT) is designed to measure a single domain. This contrasts with commonly used shoulder scales such as the ASES, CMS, DASH, and UCLA that lump multiple domains (pain, physical function, and objective tests) into a single scale. This can be considered both an advantage and disadvantage; however, if desired, CAT tests that measure pain, anxiety, and depression are also available for administration. One concern regarding the PF-CAT is that it includes questions on both the upper and lower extremi-

ties that could limit the responsiveness of the metric. To address this concern, an upper extremity CAT (UE CAT) has been developed and has been shown to correlate strongly with the DASH in non-shoulder upper extremity patients<sup>[73]</sup>. An upper extremity specific CAT could eliminate small ceiling effects that were found when assessing the PF CAT in some upper extremity patients<sup>[72]</sup>.

In general, the psychometric properties of the PF and UE CAT have not yet been rigorously evaluated. The potential benefits of CAT testing include: reduced time to completion and decreased patient responder-burden; reducing or eliminating floor and ceiling effects; unidimensionality that could clarify interpretation of results; and the ability to add or subtract questions from the item bank without the need to recreate and validate an entirely new scale. It is likely that PROMIS PROs will be reported in studies evaluating shoulder outcomes going forward, and therefore the reader should become aware of this methodology.

## CONCLUSION

A variety of outcome assessment tools can be utilized to evaluate patients with shoulder disorders including general HRQoL measures, health utility measures, general shoulder HRQoL measures and, in the setting of instability, condition specific shoulder measures. The SF-36 and SF-12 are the most validated and commonly used general HRQoL measures in the orthopaedic literature. Utilizing one of these also allows for calculation of the SF-5D as a health utility measure for economic analysis. There are multiple general shoulder measures that are acceptable for use as a general shoulder measure including the ASES score, SST and CMS, however in the setting of instability it is recommended to use a condition specific measure due to the ceiling effects of general shoulder measures. The WOSI is the most rigorously tested and validated of the instability measures. Finally, computer adaptive testing and the PROMIS database is emerging as a unique and powerful tool in evaluating both general and joint specific HRQoL that may allow for more efficient evaluation of patient outcomes in the near future.

## REFERENCES

- 1 **Bayley KB**, London MR, Grunkemeier GL, Lansky DJ. Measuring the success of treatment in patient terms. *Med Care* 1995; **33**: AS226-AS235 [PMID: 7723451]
- 2 **Brokelman RB**, van Loon CJ, Rijnberg WJ. Patient versus surgeon satisfaction after total hip arthroplasty. *J Bone Joint Surg Br* 2003; **85**: 495-498 [PMID: 12793551]
- 3 **Noble PC**, Fuller-Lafreniere S, Meftah M, Dwyer MK. Challenges in outcome measurement: discrepancies between patient and provider definitions of success. *Clin Orthop Relat Res* 2013; **471**: 3437-3445 [PMID: 23955192 DOI: 10.1007/s11999-013-3198-x]
- 4 **Gartland JJ**. Orthopaedic clinical research. Deficiencies in experimental design and determinations of outcome. *J Bone Joint Surg Am* 1988; **70**: 1357-1364 [PMID: 3182887]
- 5 **Wright RW**, Baumgarten KM. Shoulder outcomes measures. *J Am Acad Orthop Surg* 2010; **18**: 436-444 [PMID: 20595136]
- 6 **Brophy RH**, Beauvais RL, Jones EC, Cordasco FA, Marx RG. Measurement of shoulder activity level. *Clin Orthop Relat Res* 2005; **439**: 101-108 [PMID: 16205147 DOI: 10.1097/01.blo.0000173255.85016.1f]
- 7 **Hepper CT**, Smith MV, Steger-May K, Brophy RH. Normative data of shoulder activity level by age and sex. *Am J Sports Med* 2013; **41**: 1146-1151 [PMID: 23524150 DOI: 10.1177/0363546513480613]
- 8 **Patel AA**, Donegan D, Albert T. The 36-item short form. *J Am Acad Orthop Surg* 2007; **15**: 126-134 [PMID: 17277259]
- 9 **Rihn JA**, Currier BL, Phillips FM, Glassman SD, Albert TJ. Defining the value of spine care. *J Am Acad Orthop Surg* 2013; **21**: 419-426 [PMID: 23818029 DOI: 10.5435/JAAOS-21-07-419]
- 10 **Smith MV**, Calfee RP, Baumgarten KM, Brophy RH, Wright RW. Upper extremity-specific measures of disability and outcomes in orthopaedic surgery. *J Bone Joint Surg Am* 2012; **94**: 277-285 [PMID: 22298061 DOI: 10.2106/JBJS.01744]
- 11 **Kirkley A**, Griffin S, Dainty K. Scoring systems for the functional assessment of the shoulder. *Arthroscopy* 2003; **19**: 1109-1120 [PMID: 14673454 DOI: 10.1016/j.arthro.2003.10.030]
- 12 **Brinker MR**, O'Connor DP. Stakeholders in outcome measures: review from a clinical perspective. *Clin Orthop Relat Res* 2013; **471**: 3426-3436 [PMID: 24072624 DOI: 10.1007/s11999-013-3265-3]
- 13 **McHorney CA**, Ware JE, Raczek AE. The MOS 36-Item Short-Form Health Survey (SF-36): II. Psychometric and clinical tests of validity in measuring physical and mental health constructs. *Med Care* 1993; **31**: 247-263 [PMID: 8450681 DOI: 10.1097/00005650-199303000-00006]
- 14 **Ware JE**, Sherbourne CD. The MOS 36-item short-form health survey (SF-36). I. Conceptual framework and item selection. *Med Care* 1992; **30**: 473-483 [PMID: 1593914 DOI: 10.1097/00005650-199206000-00002]
- 15 **Busija L**, Pausenberger E, Haines TP, Haymes S, Buchbinder R, Osborne RH. Adult measures of general health and health-related quality of life: Medical Outcomes Study Short Form 36-Item (SF-36) and Short Form 12-Item (SF-12) Health Surveys, Nottingham Health Profile (NHP), Sickness Impact Profile (SIP), Medical Outcomes Study Short Form 6D (SF-6D), Health Utilities Index Mark 3 (HUI3), Quality of Well-Being Scale (QWB), and Assessment of Quality of Life (AQoL). *Arthritis Care Res (Hoboken)* 2011; **63** Suppl 11: S383-S412 [PMID: 22588759 DOI: 10.1002/acr.20541]
- 16 **Ware J**, Kosinski M, Keller SD. A 12-Item Short-Form Health Survey: construction of scales and preliminary tests of reliability and validity. *Med Care* 1996; **34**: 220-233 [PMID: 8628042 DOI: 10.1097/00005650-199603000-00003]
- 17 **Garratt A**, Schmidt L, Mackintosh A, Fitzpatrick R. Quality of life measurement: bibliographic study of patient assessed health outcome measures. *BMJ* 2002; **324**: 1417 [PMID: 12065262 DOI: 10.1136/bmj.324.7351.1417]
- 18 **Castricini R**, Gasparini G, Di Luggo F, De Benedetto M, De Gori M, Galasso O. Health-related quality of life and functionality after reverse shoulder arthroplasty. *J Shoulder Elbow Surg* 2013; **22**: 1639-1649 [PMID: 23523306 DOI: 10.1016/j.jse.2013.01.020]
- 19 **Yoo JH**, Cho NS, Rhee YG. Effect of postoperative repair integrity on health-related quality of life after rotator cuff repair: healed versus retear group. *Am J Sports Med* 2013; **41**: 2637-2644 [PMID: 23942286 DOI: 10.1177/0363546513499152]
- 20 **Carter MJ**, Mikuls TR, Nayak S, Fehring E, Michaud K. Impact of total shoulder arthroplasty on generic and shoulder-specific health-related quality-of-life measures: a systematic literature review and meta-analysis. *J Bone Joint Surg Am* 2012; **94**: e127 [PMID: 22992856 DOI: 10.2106/JBJS.K.00204]
- 21 **Gartsman GM**, Brinker MR, Khan M, Karahan M. Self-assessment of general health status in patients with five common shoulder conditions. *J Shoulder Elbow Surg* 1998; **7**: 228-237 [PMID: 9658347 DOI: 10.1016/S1058-2746(98)90050-7]
- 22 **Boorman RS**, Kopjar B, Fehring E, Churchill RS, Smith

- K, Matsen FA. The effect of total shoulder arthroplasty on self-assessed health status is comparable to that of total hip arthroplasty and coronary artery bypass grafting. *J Shoulder Elbow Surg* 2003; **12**: 158-163 [PMID: 12700569 DOI: 10.1067/mse.2003.18]
- 23 **Beaton DE**, Richards RR. Measuring function of the shoulder. A cross-sectional comparison of five questionnaires. *J Bone Joint Surg Am* 1996; **78**: 882-890 [PMID: 8666606]
  - 24 **Oh JH**, Jo KH, Kim WS, Gong HS, Han SG, Kim YH. Comparative evaluation of the measurement properties of various shoulder outcome instruments. *Am J Sports Med* 2009; **37**: 1161-1168 [PMID: 19403837 DOI: 10.1177/0363546508330135]
  - 25 **Rudmik L**, Drummond M. Health economic evaluation: important principles and methodology. *Laryngoscope* 2013; **123**: 1341-1347 [PMID: 23483522 DOI: 10.1002/lary.23943]
  - 26 **Vitale MA**, Vitale MG, Zivin JG, Braman JP, Bigliani LU, Flatow EL. Rotator cuff repair: an analysis of utility scores and cost-effectiveness. *J Shoulder Elbow Surg* 2007; **16**: 181-187 [PMID: 17399623 DOI: 10.1016/j.jse.2006.06.013]
  - 27 **Gartsman GM**, Brinker MR, Khan M. Early effectiveness of arthroscopic repair for full-thickness tears of the rotator cuff: an outcome analysis. *J Bone Joint Surg Am* 1998; **80**: 33-40 [PMID: 9469306]
  - 28 **Dawson J**, Fitzpatrick R, Carr A. The assessment of shoulder instability. The development and validation of a questionnaire. *J Bone Joint Surg Br* 1999; **81**: 420-426 [PMID: 10872358 DOI: 10.1302/0301-620X.81B3.9044]
  - 29 **Constant CR**, Murley AH. A clinical method of functional assessment of the shoulder. *Clin Orthop Relat Res* 1987; **(214)**: 160-164 [PMID: 3791738]
  - 30 **Namdari S**, Donegan RP, Chamberlain AM, Galatz LM, Yamaguchi K, Keener JD. Factors affecting outcome after structural failure of repaired rotator cuff tears. *J Bone Joint Surg Am* 2014; **96**: 99-105 [PMID: 24430408 DOI: 10.2106/JBJS.M.00551]
  - 31 **Galatz LM**, Ball CM, Teefey SA, Middleton WD, Yamaguchi K. The outcome and repair integrity of completely arthroscopically repaired large and massive rotator cuff tears. *J Bone Joint Surg Am* 2004; **86-A**: 219-224 [PMID: 14960664]
  - 32 **Boileau P**, Brassart N, Watkinson DJ, Carles M, Hatzidakis AM, Krishnan SG. Arthroscopic repair of full-thickness tears of the supraspinatus: does the tendon really heal? *J Bone Joint Surg Am* 2005; **87**: 1229-1240 [PMID: 15930531 DOI: 10.2106/JBJS.D.02035]
  - 33 **Allom R**, Colegate-Stone T, Gee M, Ismail M, Sinha J. Outcome analysis of surgery for disorders of the rotator cuff: a comparison of subjective and objective scoring tools. *J Bone Joint Surg Br* 2009; **91**: 367-373 [PMID: 19258614 DOI: 10.1302/0301-620X.91B3.20714]
  - 34 **Baker P**, Nanda R, Goodchild L, Finn P, Rangan A. A comparison of the Constant and Oxford shoulder scores in patients with conservatively treated proximal humeral fractures. *J Shoulder Elbow Surg* 2008; **17**: 37-41 [PMID: 18036850 DOI: 10.1016/j.jse.2007.04.019]
  - 35 **Rocourt MH**, Radlinger L, Kalberer F, Sanavi S, Schmid NS, Leunig M, Hertel R. Evaluation of intratester and intertester reliability of the Constant-Murley shoulder assessment. *J Shoulder Elbow Surg* 2008; **17**: 364-369 [PMID: 18329560 DOI: 10.1016/j.jse.2007.06.024]
  - 36 **Conboy VB**, Morris RW, Kiss J, Carr AJ. An evaluation of the Constant-Murley shoulder assessment. *J Bone Joint Surg Br* 1996; **78**: 229-232 [PMID: 8666631]
  - 37 **Constant CR**, Gerber C, Emery RJ, Søjbjerg JO, Gohlke F, Boileau P. A review of the Constant score: modifications and guidelines for its use. *J Shoulder Elbow Surg* 2008; **17**: 355-361 [PMID: 18218327 DOI: 10.1016/j.jse.2007.06.022]
  - 38 **Katolik LI**, Romeo AA, Cole BJ, Verma NN, Hayden JK, Bach BR. Normalization of the Constant score. *J Shoulder Elbow Surg* 2005; **14**: 279-285 [PMID: 15889027 DOI: 10.1016/j.jse.2004.10.009]
  - 39 **Kukkonen J**, Kauko T, Vahlberg T, Joukainen A, Aärimaa V. Investigating minimal clinically important difference for Constant score in patients undergoing rotator cuff surgery. *J Shoulder Elbow Surg* 2013; **22**: 1650-1655 [PMID: 23850308 DOI: 10.1016/j.jse.2013.05.002]
  - 40 **Kemp KA**, Sheps DM, Beaupre LA, Styles-Tripp F, Luciak-Corea C, Balyk R. An evaluation of the responsiveness and discriminant validity of shoulder questionnaires among patients receiving surgical correction of shoulder instability. *ScientificWorldJournal* 2012; **2012**: 410125 [PMID: 23002386 DOI: 10.1100/2012/410125]
  - 41 **Amstutz HC**, Sew Hoy AL, Clarke IC. UCLA anatomic total shoulder arthroplasty. *Clin Orthop Relat Res* 1981; **(155)**: 7-20 [PMID: 7226634]
  - 42 **Fealy S**, Kingham TP, Altchek DW. Mini-open rotator cuff repair using a two-row fixation technique: outcomes analysis in patients with small, moderate, and large rotator cuff tears. *Arthroscopy* 2002; **18**: 665-670 [PMID: 12098132 DOI: 10.1053/jars.2002.32589]
  - 43 **O'Connor DA**, Chipchase LS, Tomlinson J, Krishnan J. Arthroscopic subacromial decompression: responsiveness of disease-specific and health-related quality of life outcome measures. *Arthroscopy* 1999; **15**: 836-840 [PMID: 10564861 DOI: 10.1053/ar.1999.v15.015083]
  - 44 **Hudak PL**, Amadio PC, Bombardier C. Development of an upper extremity outcome measure: the DASH (disabilities of the arm, shoulder and hand) [corrected]. The Upper Extremity Collaborative Group (UECG) *Am J Ind Med* 1996; **29**: 602-608 [PMID: 8773720 DOI: 10.1002/(SICI)1097-0274(199606)29: ]
  - 45 **Beaton DE**, Katz JN, Fossel AH, Wright JG, Tarasuk V, Bombardier C. Measuring the whole or the parts? Validity, reliability, and responsiveness of the Disabilities of the Arm, Shoulder and Hand outcome measure in different regions of the upper extremity. *J Hand Ther* 2001; **14**: 128-146 [PMID: 11382253 DOI: 10.1016/S0894-1130(01)80043-0]
  - 46 **Gabel CP**, Michener LA, Burkett B, Neller A. The Upper Limb Functional Index: development and determination of reliability, validity, and responsiveness. *J Hand Ther* 2006; **19**: 328-348; quiz 349 [PMID: 16861132 DOI: 10.1197/j.jht.2006.04.001]
  - 47 **Aasheim T**, Finsen V. The DASH and the QuickDASH instruments. Normative values in the general population in Norway. *J Hand Surg Eur Vol* 2014; **39**: 140-144 [PMID: 23520389 DOI: 10.1177/1753193413481302]
  - 48 **Schmitt JS**, Di Fabio RP. Reliable change and minimum important difference (MID) proportions facilitated group responsiveness comparisons using individual threshold criteria. *J Clin Epidemiol* 2004; **57**: 1008-1018 [PMID: 15528051 DOI: 10.1016/j.jclinepi.2004.02.007]
  - 49 **Tashjian RZ**, Deloach J, Green A, Porucznik CA, Powell AP. Minimal clinically important differences in ASES and simple shoulder test scores after nonoperative treatment of rotator cuff disease. *J Bone Joint Surg Am* 2010; **92**: 296-303 [PMID: 20124055 DOI: 10.2106/JBJS.H.01296]
  - 50 **Henn RF**, Tashjian RZ, Kang L, Green A. Patients with workers' compensation claims have worse outcomes after rotator cuff repair. *J Bone Joint Surg Am* 2008; **90**: 2105-2113 [PMID: 18829907 DOI: 10.2106/JBJS.F.00260]
  - 51 **Fehring EV**, Sun J, Cotton J, Carlson MJ, Burns EM. Healed cuff repairs impart normal shoulder scores in those 65 years of age and older. *Clin Orthop Relat Res* 2010; **468**: 1521-1525 [PMID: 19763715 DOI: 10.1007/s11999-009-1103-4]
  - 52 **Richards RR**, An KN, Bigliani LU, Friedman RJ, Gartsman GM, Gristina AG, Iannotti JP, Mow VC, Sidles JA, Zuckerman JD. A standardized method for the assessment of shoulder function. *J Shoulder Elbow Surg* 1994; **3**: 347-352 [PMID: 22958838 DOI: 10.1016/S1058-2746(09)80019-0]
  - 53 **Bot SD**, Terwee CB, van der Windt DA, Bouter LM, Dekker J, de Vet HC. Clinimetric evaluation of shoulder disability




- questionnaires: a systematic review of the literature. *Ann Rheum Dis* 2004; **63**: 335-341 [PMID: 15020324 DOI: 10.1136/ard.2003.007724]
- 54 **Angst F**, Pap G, Mannion AF, Herren DB, Aeschlimann A, Schwyzler HK, Simmen BR. Comprehensive assessment of clinical outcome and quality of life after total shoulder arthroplasty: usefulness and validity of subjective outcome measures. *Arthritis Rheum* 2004; **51**: 819-828 [PMID: 15478159 DOI: 10.1002/art.20688]
- 55 **Kocher MS**, Horan MP, Briggs KK, Richardson TR, O'Holleran J, Hawkins RJ. Reliability, validity, and responsiveness of the American Shoulder and Elbow Surgeons subjective shoulder scale in patients with shoulder instability, rotator cuff disease, and glenohumeral arthritis. *J Bone Joint Surg Am* 2005; **87**: 2006-2011 [PMID: 16140816 DOI: 10.2106/JBJS.C.01624]
- 56 **Michener LA**, McClure PW, Sennett BJ. American Shoulder and Elbow Surgeons Standardized Shoulder Assessment Form, patient self-report section: reliability, validity, and responsiveness. *J Shoulder Elbow Surg* 2002; **11**: 587-594 [PMID: 12469084 DOI: 10.1067/mse.2002.127096]
- 57 **Bryant D**, Litchfield R, Sandow M, Gartsman GM, Guyatt G, Kirkley A. A comparison of pain, strength, range of motion, and functional outcomes after hemiarthroplasty and total shoulder arthroplasty in patients with osteoarthritis of the shoulder. A systematic review and meta-analysis. *J Bone Joint Surg Am* 2005; **87**: 1947-1956 [PMID: 16140808 DOI: 10.2106/JBJS.D.02854]
- 58 **Leggin BG**, Michener LA, Shaffer MA, Brenneman SK, Iannotti JP, Williams GR. The Penn shoulder score: reliability and validity. *J Orthop Sports Phys Ther* 2006; **36**: 138-151 [PMID: 16596890 DOI: 10.2519/jospt.2006.36.3.138]
- 59 **Iannotti JP**, Codsi MJ, Kwon YW, Derwin K, Ciccone J, Brems JJ. Porcine small intestine submucosa augmentation of surgical repair of chronic two-tendon rotator cuff tears. A randomized, controlled trial. *J Bone Joint Surg Am* 2006; **88**: 1238-1244 [PMID: 16757756 DOI: 10.2106/JBJS.E.00524]
- 60 **Ricchetti ET**, Warrender WJ, Abboud JA. Use of locking plates in the treatment of proximal humerus fractures. *J Shoulder Elbow Surg* 2010; **19**: 66-75 [PMID: 20188270 DOI: 10.1016/j.jse.2010.01.001]
- 61 **Codsi MJ**, Hennigan S, Herzog R, Kella S, Kelley M, Leggin B, Williams GR, Iannotti JP. Latissimus dorsi tendon transfer for irreparable posterosuperior rotator cuff tears. Surgical technique. *J Bone Joint Surg Am* 2007; **89** Suppl 2 Pt.1: 1-9 [PMID: 17332121 DOI: 10.2106/JBJS.F.01160]
- 62 **Rouleau DM**, Faber K, MacDermid JC. Systematic review of patient-administered shoulder functional scores on instability. *J Shoulder Elbow Surg* 2010; **19**: 1121-1128 [PMID: 21070955 DOI: 10.1016/j.jse.2010.07.003]
- 63 **Rowe CR**, Patel D, Southmayd WW. The Bankart procedure: a long-term end-result study. *J Bone Joint Surg Am* 1978; **60**: 1-16 [PMID: 624747]
- 64 **Skare Ø**, Schrøder CP, Mowinckel P, Reikerås O, Brox JI. Reliability, agreement and validity of the 1988 version of the Rowe Score. *J Shoulder Elbow Surg* 2011; **20**: 1041-1049 [PMID: 21831671 DOI: 10.1016/j.jse.2011.04.024]
- 65 **Kirkley A**, Griffin S, McLintock H, Ng L. The development and evaluation of a disease-specific quality of life measurement tool for shoulder instability. The Western Ontario Shoulder Instability Index (WOSI). *Am J Sports Med* 1998; **26**: 764-772 [PMID: 9850776]
- 66 **Watson L**, Story I, Dalziel R, Hoy G, Shimmin A, Woods D. A new clinical outcome measure of glenohumeral joint instability: the MISS questionnaire. *J Shoulder Elbow Surg* 1998; **14**: 22-30 [PMID: 15723010 DOI: 10.1016/j.jse.2004.05.002]
- 67 **Kirkley A**, Griffin S, Richards C, Miniaci A, Mohtadi N. Prospective randomized clinical trial comparing the effectiveness of immediate arthroscopic stabilization versus immobilization and rehabilitation in first traumatic anterior dislocations of the shoulder. *Arthroscopy* 1999; **15**: 507-514 [PMID: 10424554 DOI: 10.1053/ar.1999.v15.015050]
- 68 **Godfrey J**, Hamman R, Lowenstein S, Briggs K, Kocher M. Reliability, validity, and responsiveness of the simple shoulder test: psychometric properties by age and injury type. *J Shoulder Elbow Surg* 2007; **16**: 260-267 [PMID: 17188906 DOI: 10.1016/j.jse.2006.07.003]
- 69 **de Witte PB**, Henseler JF, Nagels J, Vliet Vlieland TP, Nellissen RG. The Western Ontario rotator cuff index in rotator cuff disease patients: a comprehensive reliability and responsiveness validation study. *Am J Sports Med* 2012; **40**: 1611-1619 [PMID: 22582227 DOI: 10.1177/0363546512446591]
- 70 **Cella D**, Yount S, Rothrock N, Gershon R, Cook K, Reeve B, Ader D, Fries JF, Bruce B, Rose M. The Patient-Reported Outcomes Measurement Information System (PROMIS): progress of an NIH Roadmap cooperative group during its first two years. *Med Care* 2007; **45**: S3-S11 [PMID: 17443116 DOI: 10.1097/01.mlr.0000258615.42478.55]
- 71 **Chakravarty EF**, Björner JB, Fries JF. Improving patient reported outcomes using item response theory and computerized adaptive testing. *J Rheumatol* 2007; **34**: 1426-1431 [PMID: 17552069]
- 72 **Hung M**, Clegg DO, Greene T, Saltzman CL. Evaluation of the PROMIS physical function item bank in orthopaedic patients. *J Orthop Res* 2011; **29**: 947-953 [PMID: 21437962 DOI: 10.1002/jor.21308]
- 73 **Döring AC**, Nota SP, Hageman MG, Ring DC. Measurement of upper extremity disability using the Patient-Reported Outcomes Measurement Information System. *J Hand Surg Am* 2014; **39**: 1160-1165 [PMID: 24799143 DOI: 10.1016/j.jhbsa.2014.03.013]
- 74 **Roy JS**, MacDermid JC, Woodhouse LJ. A systematic review of the psychometric properties of the Constant-Murley score. *J Shoulder Elbow Surg* 2010; **19**: 157-164 [PMID: 19559630 DOI: 10.1016/j.jse.2009.04.008]
- 75 **Roy JS**, MacDermid JC, Woodhouse LJ. Measuring shoulder function: a systematic review of four questionnaires. *Arthritis Rheum* 2009; **61**: 623-632 [PMID: 19405008 DOI: 10.1002/art.24396]
- 76 **Romeo AA**, Mazzocca A, Hang DW, Shott S, Bach BR. Shoulder scoring scales for the evaluation of rotator cuff repair. *Clin Orthop Relat Res* 2004; **(427)**: 107-114 [PMID: 15552145 DOI: 10.1097/01.blo.0000142624.05526.dd]
- 77 **Roddey TS**, Olson SL, Cook KF, Gartsman GM, Hanten W. Comparison of the University of California-Los Angeles Shoulder Scale and the Simple Shoulder Test with the shoulder pain and disability index: single-administration reliability and validity. *Phys Ther* 2000; **80**: 759-768 [PMID: 10911414]
- 78 **van de Water AT**, Shields N, Davidson M, Evans M, Taylor NF. Reliability and validity of shoulder function outcome measures in people with a proximal humeral fracture. *Disabil Rehabil* 2014; **36**: 1072-1079 [PMID: 24001265 DOI: 10.3109/09638288.2013.829529]
- 79 **Franchignoni F**, Vercelli S, Giordano A, Sartorio F, Bravini E, Ferriero G. Minimal clinically important difference of the disabilities of the arm, shoulder and hand outcome measure (DASH) and its shortened version (QuickDASH). *J Orthop Sports Phys Ther* 2014; **44**: 30-39 [PMID: 24175606 DOI: 10.2519/jospt.2014.4893]
- 80 **Skutek M**, Fremerey RW, Zeichen J, Bosch U. Outcome analysis following open rotator cuff repair. Early effectiveness validated using four different shoulder assessment scales. *Arch Orthop Trauma Surg* 2000; **120**: 432-436 [PMID: 10968533 DOI: 10.1007/s004020000133]
- 81 **Wylie JD**, Bershadsky B, Iannotti JP. The effect of medical comorbidity on self-reported shoulder-specific health related quality of life in patients with shoulder disease. *J Shoulder Elbow Surg* 2010; **19**: 823-828 [PMID: 20303289 DOI: 10.1016/j.jse.2009.11.052]
- 82 **Michener LA**, Snyder AR, Leggin BG. Responsiveness of the numeric pain rating scale in patients with shoulder pain and the effect of surgical status. *J Sport Rehabil* 2011; **20**: 115-128



- [PMID: 21411827]
- 83 **Michener LA**, Snyder Valier AR, McClure PW. Defining substantial clinical benefit for patient-rated outcome tools for shoulder impingement syndrome. *Arch Phys Med Rehabil* 2013; **94**: 725-730 [PMID: 23164979 DOI: 10.1016/j.apmr.2012.11.011]
  - 84 **Angst F**, Schwyzer HK, Aeschlimann A, Simmen BR, Goldhahn J. Measures of adult shoulder function: Disabilities of the Arm, Shoulder, and Hand Questionnaire (DASH) and its short version (QuickDASH), Shoulder Pain and Disability Index (SPADI), American Shoulder and Elbow Surgeons (ASES) Society standardized shoulder assessment form, Constant (Murley) Score (CS), Simple Shoulder Test (SST), Oxford Shoulder Score (OSS), Shoulder Disability Questionnaire (SDQ), and Western Ontario Shoulder Instability Index (WOSI). *Arthritis Care Res (Hoboken)* 2011; **63** Suppl 11: S174-S188 [PMID: 22588743 DOI: 10.1002/acr.20630]
  - 85 **Hollinshead RM**, Mohtadi NG, Vande Guchte RA, Wadey VM. Two 6-year follow-up studies of large and massive rotator cuff tears: comparison of outcome measures. *J Shoulder Elbow Surg* 2000; **9**: 373-381 [PMID: 11075319 DOI: 10.1067/mse.2000.108389]

**P- Reviewer:** Daglar B, Regauer M, Scibek JS  
**S- Editor:** Ji FF **L- Editor:** A **E- Editor:** Wu HL





## WJO 5<sup>th</sup> Anniversary Special Issues (7): Shoulder

# Eccentric training as a new approach for rotator cuff tendinopathy: Review and perspectives

Paula R Camargo, Francisco Albuquerque-Sendín, Tania F Salvini

Paula R Camargo, Department of Physical Therapy, Federal University of São Carlos, São Carlos, SP 13565-905, Brazil  
Francisco Albuquerque-Sendín, Department of Physical Therapy, University of Salamanca, 37008 Salamanca, Spain  
Tania F Salvini, Department of Physical Therapy, Federal University of São Carlos, São Carlos, SP 13565-905, Brazil

Author contributions: All authors contributed to this work.

Correspondence to: Paula R Camargo, PT, PhD, Department of Physical Therapy, Federal University of São Carlos, Rodovia Washington Luis, km 235, São Carlos, SP 13565-905, Brazil. [prcamargo@ufscar.br](mailto:prcamargo@ufscar.br)

Telephone: +55-16-33066696 Fax: +55-16-33512081

Received: January 24, 2014 Revised: April 29, 2014

Accepted: July 17, 2014

Published online: November 18, 2014

## Abstract

Excessive mechanical loading is considered the major cause of rotator cuff tendinopathy. Although tendon problems are very common, they are not always easy to treat. Eccentric training has been proposed as an effective conservative treatment for the Achilles and patellar tendinopathies, but less evidence exists about its effectiveness for the rotator cuff tendinopathy. The mechanotransduction process associated with an adequate dose of mechanical load might explain the beneficial results of applying the eccentric training to the tendons. An adequate load increases healing and an inadequate (over or underuse) load can deteriorate the tendon structure. Different eccentric training protocols have been used in the few studies conducted for people with rotator cuff tendinopathy. Further, the effects of the eccentric training for rotator cuff tendinopathy were only evaluated on pain, function and strength. Future studies should assess the effects of the eccentric training also on shoulder kinematics and muscle activity. Individualization of the exercise prescription, comprehension and motivation of the patients, and the establishment of specific goals, practice and efforts should all

be considered when prescribing the eccentric training. In conclusion, eccentric training should be used aiming improvement of the tendon degeneration, but more evidence is necessary to establish the adequate dose-response and to determine long-term follow-up effects.

© 2014 Baishideng Publishing Group Inc. All rights reserved.

**Key words:** Cellular; Mechanotransduction; Rehabilitation; Shoulder Impingement; Supraspinatus; Tendon injuries

**Core tip:** Eccentric training can be considered a new and ambitious treatment approach for several tendinopathies. The paper establishes the basic principles for explaining the effects on the tendon of an intense mechanical load, as the eccentric training. Further, the authors bring other possible explanations of the success of this training for tendinopathies, as the individualization of the exercise programs and the motivation of the patients who reach specific goals. Negative and side effects are also identified. Finally, the main evidence afforded by original articles is commented and future research purposes are defined.

Camargo PR, Albuquerque-Sendín F, Salvini TF. Eccentric training as a new approach for rotator cuff tendinopathy: Review and perspectives. *World J Orthop* 2014; 5(5): 634-644 Available from: URL: <http://www.wjgnet.com/2218-5836/full/v5/i5/634.htm> DOI: <http://dx.doi.org/10.5312/wjo.v5.i5.634>

## INTRODUCTION

Tendon injuries in the shoulder account for overuse injuries in sports as well as in jobs that require repetitive activity<sup>[1-4]</sup>. Excessive mechanical loading is considered the major causation factor. Although tendon problems are very frequent, they are not always easy to manage.

Rehabilitation of shoulder tendinopathy can take several months and conservative treatment is usually used as it can help the healing of the tendon by changing its metabolism and their structural and mechanical properties<sup>[5]</sup>. The use of eccentric exercise in rehabilitation has increasingly gained attention in the literature as a specific training modality. The eccentric exercise is an overall lengthening of a muscle as it develops tension and contracts to control motion. This kind of training differs from conventional training regimen because the tension in muscle fibers when lengthening is considerably greater than when muscle fibers are shortening<sup>[6]</sup>. There is some evidence that eccentric training may be effective in the management of tendinopathy of the Achilles and patellar tendons<sup>[7-9]</sup>. Histological changes in the supraspinatus tendinosis have been found to have similarities with those of the Achilles and patellar tendinosis<sup>[10,11]</sup>. Collagenous changes, extracellular matrix changes, increased cellularity and increased vascularity are among the histological and molecular changes observed in rotator cuff tendinosis<sup>[12]</sup>. As such, few studies were done evaluating the effectiveness of eccentric training in subjects with this condition<sup>[13-16]</sup>.

The purpose of this paper is to review the studies that used eccentric training program in the treatment of rotator cuff tendinopathy as well as the tendon structure, the healing process and the possible mechanisms for why eccentric exercises can be effective in treating tendinopathy.

## TENDON STRUCTURE

Tendons are mechanically responsible for transmitting muscle forces to bone as they connect bone to muscle belly at their ends. Consequently, motion is allowed and joint stability is enhanced.

As a type of connective tissue, tendon properties are determined primarily by the amount, type and arrangement of an abundant extracellular matrix<sup>[17]</sup>. Thus, the tendon has a multi-unit hierarchical structure composed of collagen molecules, fibrils, fiber bundles, fascicles and tendon units that run parallel to the tendon's long axis<sup>[5,18]</sup>. The fibril is the smallest tendon structural unit consisted of collagen molecules<sup>[5]</sup>, which slide performing up to 50% of the longitudinal deformation of a tendon<sup>[19]</sup>. Fibers form the next level of tendon structure and are composed of collagen fibrils and are bound by endotenons, a thin layer of connective tissue<sup>[20,21]</sup>. They are responsible for the ability of the fascicles (fiber bundles) to slide independently against each other, transmitting tension despite the changing angles of a joint as it moves, and allowing tendons to change shape as their muscles contract<sup>[22]</sup>. Bundles of fascicles are enclosed by the epitendon, which is a fine, loose connective-tissue sheath<sup>[5]</sup>. More superficially, a third layer of connective tissue called the paratenon surrounds the tendon. Together, the epitendon and paratenon can also be called as the peritendon, which reduce friction with the adjacent tissue<sup>[23]</sup>. Vascular and nerve supply derive from all layers of the tendon and also

from the myotendinous and osteotendinous junctions<sup>[24]</sup>. In general, tendons have a less vascular supply than that of the muscles with which they are associated<sup>[25]</sup>.

The rotator cuff is composed of four tendons (supraspinatus, infraspinatus, teres minor and subscapularis) that blend into a single structure. First, the supraspinatus and infraspinatus bind 1.5 cm before insertion. Second, the infraspinatus and teres minor merge near its myotendinous union. Finally, the supraspinatus and subscapularis tendons also intertwine to form a sheath around the tendon of the biceps<sup>[26]</sup>. This sheath and the superior glenohumeral ligament and the coracohumeral ligament form the biceps pulley<sup>[27]</sup>. The supraspinatus, infraspinatus, subscapularis and the adjacent structures are strongly associated and form a capsule-cuff complex. The tendon proper acts with the capsule to transmit tensional force from the muscle to the bone<sup>[26]</sup>.

Specifically, the supraspinatus consists morphologically of two different sub-regions. Anterior muscle fiber bundles were found to be bipennate, while posterior fiber bundles demonstrated a more parallel disposition<sup>[28]</sup>. Further, the anterior sub-region tendon is thick and tubular while the posterior tendon is thin and strap-like. These sub-regions have shown different mechanical properties<sup>[29]</sup>. In fact, anterior tendon stress is significantly greater than posterior tendon stress<sup>[28]</sup>. Each of the two sub-regions could also be divided into superficial, middle, and deep parts. This division has been associated to the initiation and progression of supraspinatus tendon tears<sup>[30]</sup>.

Other authors have described four functional structurally independent parts in the supraspinatus tendon. The first part, also called the proper tendon, is extended from the musculotendinous junction to approximately 2.0 cm medial to the humerus insertion and it is composed of parallel collagen fascicles oriented along the tensional axis and separated by a prominent endotenon region. The second part is the attachment fibrocartilage that extends from the first part of the tendon to the greater tuberosity and it consists of a complex basket-weave of collagen fibers. The densely packed unidirectional collagen fibers of the rotator cable extend from the coracohumeral ligament posteriorly to the infraspinatus to form the third part, coursing both superficial and deep to the first part. Finally, the capsule is composed of thin uniform collagen sheets each, whose alignment differs slightly between sheets. This structure allows the tendon to adapt to tensional load dispersion and resistance to compression<sup>[22]</sup>.

The upper fibers of the subscapularis tendon interdigitate with the anterior fibers of the supraspinatus tendon and the other structures of the rotator cuff, such as the coracohumeral ligament and the superior glenohumeral ligament<sup>[29]</sup>.

The vascular anatomy of the healthy rotator cuff tendon has been controversial, with authors who have described a reduction in the number of capillaries<sup>[31]</sup>, while others support the absence of hypovascularity. However, the changes in blood supply could be a secondary phenomenon, instead of an etiologic phenomenon, in the

rotator cuff lesions<sup>[26]</sup>.

## TENDON COMPOSITION

Tendons are consisted of collagens, proteoglycans, glycoproteins, glycosaminoglycans, water and cells<sup>[5]</sup>. The predominant elements of the tendon are the fibrillar collagen molecules. Type I collagen (more rigid) constitutes about 95% of the total collagen and the remaining 5% consists of types III and V collagens<sup>[5,32]</sup>. Type III forms smaller and less organized fibrils, which may result in decreased mechanical strength. This type of collagen was found in highly stressed tendons such as the supraspinatus<sup>[33]</sup>. The principal role of the collagen fibers is to resist tension, although they still allow for a certain degree of compliance (*i.e.*, reversible longitudinal deformation). Such apparently conflicting demands are probably resolved because of the hierarchical architecture of tendons<sup>[25]</sup>. Proteoglycans, as highly hydrophilic molecules, are primarily responsible for the viscoelastic behavior of tendons, but do not make any major contribution to their tensile strength<sup>[34]</sup>. Aging can cause a decrease in mean collagen fibril diameter, which is possibly regulated by type V collagen. The size shift may be related to the reduced mechanical strength of older tendons<sup>[35]</sup>.

Fibroblasts are the dominant cell type in the tendon<sup>[5]</sup>. Tendon fibroblasts are responsible for the secretion of the extracellular matrix (*i.e.*, collagen orientation, assembly and turnover)<sup>[25]</sup>, being considered a key player in tendon maintenance, adaptation to changes in homeostasis and remodeling in case of minor or more severe disturbances to tendon tissues. These cells are aligned in rows between collagen fibers bundles. Fibroblasts surrounded by biglycan and fibromodulin within the tendon ("niched" fibroblasts) exhibit stem-cell-like properties<sup>[36]</sup>. They are scarce in tendon tissue and decrease with age, but their prolongations create a large net in healthy status<sup>[10]</sup>. Tenocytes, the tendon fibroblasts, are increasingly recognized as a defined cell population that is functionally and phenotypically distinct from other fibroblast-like cells<sup>[25]</sup>.

The supraspinatus tendon is a highly specialized inhomogeneous structure that is subjected to tension and compression<sup>[12]</sup>. The extracellular matrix composition of the insertion anatomy of the supraspinatus tendon has been categorized in four transition zones<sup>[37]</sup>. The first one is made up of largely type I collagen and small amounts of decorin, and could be considered as proper tendon. The second zone consists of largely types II and III collagen, with small amounts of types I, IX and X collagen forming a fibrocartilage. A mineralized fibrocartilage defines the third zone composed of type II and type X collagen and aggrecan. Finally, the fourth zone is bone with mineralised type I collagen. The mineral content and collagen fiber orientation define the effective bone-tendon attachment and are important in the appearance of rotator cuff tears<sup>[12]</sup>.

Histological analysis of the rotator cuff tendon shows layers of loosely organized glycosaminoglycans between the longitudinal collagen fiber fascicles, which are usually

undetectable in other tendons. These molecules, incorporated into collagen fibrils during the early, lateral assembly of fibrils<sup>[38]</sup>, may be necessary to allow transmission of inhomogeneous strains during glenohumeral stabilization. Further, the increased amount of glycosaminoglycans in the supraspinatus may serve to resist compression and to separate and lubricate collagen bundles as they move relative to each other (shear) during normal shoulder motion<sup>[39]</sup>. In fact, the kinematics of the shoulder joint and shape of the supraspinatus tendon dictate that different regions of the supraspinatus tendon move independently in relation to each other, providing a mechanism of compensation<sup>[22]</sup>. It should also be stated that the total collagen content of the normal supraspinatus tendon does not change significantly with age and was similar to other shoulder tendons as the biceps tendon<sup>[40]</sup>, for example.

## ETIOLOGY AND PATHOLOGIC PROCESSES OF TENDINOPATHIES

The supraspinatus tendon is the most common injured tendon of the shoulder due to its location just under the coracoacromial ligament<sup>[41]</sup>. Shoulder impingement is one of the most common causes of shoulder tendinopathy<sup>[42,43]</sup> and refers to the compression of the subacromial structures against the coracoacromial ligament during elevation of the arm<sup>[44]</sup>. Apoptosis<sup>[45]</sup>, vascular changes<sup>[26,31]</sup>, tears<sup>[46]</sup> and calcifications<sup>[47]</sup> of the supraspinatus tendon have already been described in subjects who were treated with subacromial decompression.

Tendinopathy is a term usually used to cover all pain conditions both in and around the tendon. Although the knowledge of the causes of the tendinopathies continues to evolve<sup>[48]</sup>, different intrinsic (anatomical variants and alterations, muscle tightness/imbalance/weakness, nutrition, age, joint laxity, systemic disease, vascular perfusion, overweight and all conditions linked to apoptosis<sup>[49]</sup>) and extrinsic factors (occupation, physical load and overuse, technical errors, inadequate equipment and environmental conditions) contributing to the pathologic processes have been identified. It is now recognized that most tendinopathies are rarely associated with any single factor, and the degenerative process that precedes tendon rupture may result from a variety of different pathways and etiology factors<sup>[50]</sup>.

Classically, pain in tendinopathy has been attributed to inflammatory processes and the patient would be diagnosed as having "tendinitis"<sup>[18]</sup>. However, there are evidences that tendinopathy could be considered a non-inflammatory injury of the tendon at the cellular level<sup>[51,52]</sup>, with absence of inflammatory precursors and cells in the tendon<sup>[48]</sup>. This condition is labeled as "tendinosis" and is defined from histopathologic findings involving widening of the tendon, disturbed collagen distribution, neovascularization and increased cellularity<sup>[53]</sup>. In fact, tendinopathies represent several degenerative processes mixed and, sometimes, overlapped. Tendinosis can lead to rupture of the tendon for vascular and/or mechanic reasons<sup>[50]</sup>.



Among the most common sites of tendinopathy are the Achilles tendon, the patellar tendon, the wrist extensors tendon and the supraspinatus tendon<sup>[7,13,54,55]</sup>. The degenerative changes found in these tendons are associated with old age and with the high physical demands (strain, compression or shear forces) at the neighboring joints<sup>[6,56]</sup> with high rates of matrix turnover<sup>[50]</sup>.

## TENOCYTES BIOLOGY:

### MECHANOTRANSDUCTION IN EXERCISE

Tendons are metabolically active<sup>[57]</sup>, but the mechanisms in transmitting/absorbing tensional forces within the tendon, and how tension affects the tendon, are not completely understood<sup>[58]</sup>. Nevertheless, tendons as a whole exhibit distinct structure-function relationships geared to the changing mechanical stresses to which they are subject<sup>[25]</sup>.

The activity and microscopy architecture of the tenocytes could be modified by mechanical factors<sup>[5,59]</sup>. Further, the local stimulation of the tenocytes, which depends on the load, is the main fact associated to the tendinosis apparition<sup>[50]</sup>, instead of apoptosis, that appears in more advanced stages<sup>[60]</sup>. In other words, the mechanical stress changes the cellular activity, and these changes alter the tendon structure<sup>[50]</sup> with a final negative balance of collagen<sup>[57]</sup>. However, different stress patterns provoke different cellular reactions depending on the amount and duration of the tensional stress applied<sup>[25]</sup>.

The tenocytes are also responsible for producing an organized collagen and remodeling it during tendon healing<sup>[3]</sup>. Tenocyte strain regulates the collagen protein synthesis response. The increase in collagen formation peaks around 24 h after exercise and remains elevated for about 3 d, which produces a positive balance of collagen formation<sup>[57]</sup>.

Kjaer *et al.*<sup>[61]</sup> have suggested that gender difference exists in collagen formation where females respond less than males with regard to an increase in collagen formation after exercise. Also, the adaptation time to chronic loading is longer in tendon when compared to contractile elements of skeletal muscle, and only very prolonged loading can change the gross dimensions of the tendon<sup>[61]</sup>.

In conclusion, the role of the tenocytes is relevant in both degeneration and healing processes of the tendon depending on the mechanical load applied<sup>[62]</sup>. The response of tendon cells to load is both frequency and amplitude dependent, and tendon cells appear to be “programmed” to sense a certain level of stress<sup>[62]</sup>. An adequate dose of mechanical load could improve the repairing, but an insufficient or inadequate stimulation could inhibit or prevent it.

## TENDON LESION AND HEALING

### PROCESSES

The tendon is submitted to a constant process of synthesis and proteolysis (matrix turnover). The main actions

of this cycle activity occur in the tendon matrix. Proteoglycan and glycoprotein activities are involved in the organization of the collagen fibers, and all their activities are mediated by the tenocytes. The changes in cellular activity in the extracellular matrix have been identified as a precursor of tendon lesion<sup>[61]</sup>. These changes include loss of matrix organization, high number of mechanoreceptors and fatty infiltration<sup>[12]</sup>.

Lesions of the rotator cuff typically start where the loads are presumably the greatest: at the deep surface of the anterior insertion of the supraspinatus<sup>[63]</sup>. In absence of a total tear, when the repetitive load exceeds the healing capacity of the tenocyte (overuse), the tendinopathy appears<sup>[60]</sup>. Although the precise mechanism of injury that leads to tendinopathy remains unknown, the proposed mechanisms imply that there are one or more “weak link” in the tendon structure that result in the pathological response of the tenocyte<sup>[57]</sup>.

Poor blood supply has also been implicated as a factor contributing to tendon injuries because it could delay the regeneration process, but tendon vascularization appears ample both around and inside the tendon in patients with tendinopathy<sup>[23,64]</sup>. Thus, tendinopathy itself is often associated with neovascularization and elevated intratendinous blood flow that seems to normalize during the course of exercise-based conservative treatment<sup>[65]</sup>.

Although other degenerative features are associated with tendinopathy, including glycosaminoglycan accumulation, calcification and lipid accumulation, many of these features are found in normal tendons and are not necessarily pathological<sup>[66,67]</sup>.

The role of each of the anatomical structures (*i.e.*, the supraspinatus tendon, the subacromial bursa and the glenohumeral joint capsule) are not completely known<sup>[12]</sup>, but the progressive histological changes in rotator cuff disease include a characteristic pattern, which includes thinning of the collagen fibres, a loss of collagen structure, myxoid degeneration, hyaline degeneration, chondroid metaplasia and fatty infiltration<sup>[68]</sup>. Total collagen content decreases, with a significant increase in the proportion of type II and III collagen relative to type I collagen, decreasing the mechanical tendon properties. As previously commented, the tendon matrix also changes, and its attempt to heal, leads to a mechanical weak scar tissue as part of this failing remodelling process<sup>[12]</sup>. The histopathology shows that severity of tendon matrix degeneration increased with age and that more severe degeneration is associated with the development of tendinopathy<sup>[67]</sup>.

For the supraspinatus tendon, extracellular matrix shows an increase of the concentrations of hyaluronan, chondroitin, and dermatan sulfate in chronic rotator cuff ruptures, that could represent an adaptation to an alteration in the types of loading (tension *vs* compression *vs* shear)<sup>[40]</sup>. Other pathologic factors such as low oxygen tension or the autocrine and paracrine influence of growth factors may also be important in the altered matrix following rupture<sup>[62]</sup>. In conclusion, higher rates of turnover in the nonruptured supraspinatus may be

part of an adaptive response to the mechanical demands on the tendon and to an imbalance in matrix synthesis and degradation. An increase in type III collagen in some “normal” cadaver supraspinatus tendons is evidence that changes in collagen synthesis and turnover may precede tendon rupture<sup>[40]</sup>.

The most common form of tendon healing is by scarring, which is inferior to healing by regeneration<sup>[6]</sup>. The contraction of tenocytes and the processes associated to its transformation in myofibroblasts seem to facilitate wound closure while minimizing scar tissue formation, playing an important role in tissue scarring<sup>[5]</sup>.

Tendon healing can be divided into 3 overlapping phases: the inflammatory, repairing and remodeling phases<sup>[69]</sup>. The inflammatory phase lasts from 1 to 7 d with the phagocytosis as the main activity in this phase<sup>[70]</sup>. The repairing phase starts a few days after the injury and may last a few weeks<sup>[5]</sup>. The tenocytes starts the synthesis of large amounts of collagen after the 5<sup>th</sup> day until 5<sup>th</sup> week at least<sup>[70]</sup>. Type III collagen is synthesized and then is gradually replaced by collagen type I with increase in tensile strength<sup>[71]</sup>. After about 6 wk the remodeling phase starts. This phase is characterized by decreased cellularity and decreased collagen. During this phase, the tissue becomes more fibrous and the fibrils become aligned in the direction of mechanical stress<sup>[72]</sup>. The final maturation stage occurs after 10 wk when there is an increase in crosslinking of the collagen fibrils, which causes the tissue to become stiffer. Gradually, over a time period of about one year, the tissue will turn from fibrous to scar-like<sup>[5]</sup>.

Although the injured tendon tends to heal, there is evidence that the healing tendon does not reach the biochemical and mechanical properties of the tendon prior to injury<sup>[6]</sup>. In fact, collagen fibrils can be reduced as a result of injury<sup>[73]</sup>. A specific treatment approach, which takes into account each healing phase, has been recommended for improving these results<sup>[74]</sup>.

The ability of the rotator cuff tendon to regenerate instead of repair is controversial, although the tendon heals better when good conditions are preserved. The functions of the subacromial bursa in healing include the gliding between two layers of tissue, the blood supply to the cuff tendons and the contribution of cells and vessels after surgical repair<sup>[12]</sup>. The changes in collagen composition in rotator cuff tendinopathy are consistent with new matrix synthesis, tissue remodelling and wound healing, attempting to repair the tendon defect even though when there is no visible evidence of a tendon fiber rupture. These changes may be the result of repeated minor injury and microscopic fiber damage or factors such as reduced vascular perfusion, tissue hypoxia, altered mechanical forces and the influence of cytokines, that could lead to tendon rupture<sup>[40]</sup>.

Sometimes, in the last period of the remodeling and maturation of the healing, calcium apatite crystals are deposited in the damaged tissues. The location of this is close to the greater tubercle of the humerus where is the supraspinatus insertion<sup>[75]</sup>.

When surgical treatment is necessary, the aim is to provide a better mechanical environment for tendon healing. Despite a normal response healing, the resultant tendon healing does not regenerate the tendon-bone architecture initially formed during prenatal development. Instead, a mechanically weaker, fibrovascular scar is formed, leading to suboptimal healing rates<sup>[76]</sup>.

## CLINICAL ASSESSMENT OF SHOULDER TENDINOPATHY

To diagnose tendinopathy, the anamnesis should include questions that allow the clinician to recognize if there is increase in inactivity and to identify which are the aggravating activities and also the relieving factors. The use of self-report questionnaires focused on the shoulder and upper extremity can be useful to quantify the patient's level of function in the shoulder, contributing for clinical decision-making process. Some of the commonly used questionnaires are the Disabilities of the Arm, Shoulder and Hand Questionnaire<sup>[77]</sup>, the Western Ontario Rotator Cuff Index<sup>[78]</sup>, the Shoulder Pain and Disability Index<sup>[79]</sup> and the Penn Shoulder Score<sup>[80]</sup>. Careful palpation helps in the search of points of tenderness that reproduce the pain of the patient. The clinician should use provocation tests that load the tendon to reproduce pain during the physical examination and other loading tests that load alternative structures<sup>[18]</sup>. The literature recommends that a combination of 3 positive of 5 tests (Neer, Hawkins-Kennedy, painful arc, empty can, and external rotation resistance tests)<sup>[81]</sup> can confirm the diagnosis of rotator cuff tendinopathy. Tendon pain itself usually does not radiate<sup>[18]</sup>, although referred pain can contribute to the development of a secondary muscle problem as occurs with myofascial pain<sup>[82,83]</sup>. Imaging assessment (ultrasound and magnetic resonance imaging) improves the diagnosis of tendinopathy as it provides morphological information<sup>[84]</sup> about the tendon leading to a better clinician's decision. The ultrasound may provide an appropriate quantitative measure of the thickness of supraspinatus tendon that is important for determining improvement or deterioration in muscle function<sup>[85]</sup>. Fatty infiltration and tear can be better analyzed in magnetic resonance imaging. The presence and severity of fatty infiltration have been associated with increasing age, tear size, degree of tendon retraction, number of tendons involved and traumatic tears<sup>[86]</sup>.

## CONSERVATIVE TREATMENT OF SHOULDER TENDINOPATHY

Treatment of any organic medical condition must be based on understanding of pathophysiology. In fact, the knowledge of connective tissue properties, mechanotransduction, types of lesions, and tissue healing are important aspects for the correct and safe development of an exercise program<sup>[87]</sup>. However, this guide has not always been attended, and nowadays more questions than

answers remain around tendon injury treatment<sup>[10]</sup>. For example, although there are no established rules about the magnitude of the tear and the treatment options, the presence and the size of the rotator cuff tears could limit the therapeutic capacity of the exercises that underline the necessity of a correct diagnostic<sup>[9,88]</sup>. Massive chronic rotator cuff tears are often associated to restricted or loss of active shoulder range of motion<sup>[89]</sup>. Further, size of the tears could be related to joint inflammation and tissue remodeling, both of which are important for the advancement of rotator cuff treatment<sup>[90]</sup>, but more research is necessary.

The common modalities used to treat a painful tendon include the use of anti-inflammatory drugs, rest and stretching and strengthening exercises<sup>[10]</sup>. It is important to highlight that the rest and anti-inflammatory are mainly used for the symptomatic relief with no direct effect in the tendinopathy as chronic tendon disorders are predominantly degenerative. Further, both non steroidal anti-inflammatory drugs<sup>[91]</sup> and corticosteroid drugs<sup>[92,93]</sup> could have deleterious effects on long-term tendon healing.

Another interesting point associated to rehabilitation process is the deterioration of the tendon after immobilization. A decrease of protein synthesis<sup>[94]</sup> and an increase of collagenase activity in damaged and not damaged fascicles<sup>[95]</sup> degenerate the immobilized tendon. Curiously, these deleterious processes have been stopped through cyclic stretching in *in vitro* studies<sup>[96,97]</sup>.

As such, stretching techniques must be applied in the correct dose because its capacity of turnover the collagen synthesis<sup>[10]</sup>. Stretching techniques can consist of 3 repetitions of 30 s with a 30-s rest between the repetitions<sup>[1,98]</sup>, 2 to 3 times per week<sup>[99]</sup>.

Ultrasound, laser and electrical stimulation improve biomechanical and biochemical factors of the tendons and could help to reverse the tendinosis by stimulating fibrosis and repair<sup>[10]</sup>. However, there is lack of randomized trials that confirm the efficacy of these therapeutic approaches.

An effective treatment strategy that stimulates a healing response of the injured tendon need to be developed. So, exercises with mechanical loading should be started as soon as the pain "allows". The mechanical loading stimulates the healing response of the tendon as it accelerates tenocytes metabolism and may speed repair<sup>[5,71,100]</sup>.

## ECCENTRIC TRAINING

The eccentric training consists of the contraction of a muscle for controlling or decelerating a load while the muscle and the tendon are stretching or remain stretched. This technique has been advocated as a treatment of tendinopathy, such as chronic Achilles, patellar, lateral humeral epicondylalgia and rotator cuff tendinopathies<sup>[18]</sup>. Good clinical results were already demonstrated<sup>[7,13,55,101]</sup>, although some controversies of this success also appears in the literature<sup>[102]</sup>. More evidence is necessary to support those results<sup>[103]</sup>. Currently, the eccentric training is included in algorithms of treatment<sup>[104]</sup> and has been con-

sidered a guiding principal of the rehabilitation<sup>[87,105]</sup>.

The high forces produced eccentrically seem to induce remodeling response when applied chronically and progressively<sup>[100]</sup>. However, the specific mechanisms as to why eccentric training seems to optimize the rehabilitation of painful tendons are not totally known.

Three basic principles in an eccentric loading regime have been proposed, but the use of them still requires confirmation<sup>[70]</sup>: (1) length of tendon: the tendon length increases when the tendon is pre-stretched, and less strain will happen on that tendon during movement; (2) load: the strength of the tendon should increase by progressively increasing the load exerted on the tendon; and (3) speed: by increasing the speed of contraction, a greater force will be developed.

It has been suggested that eccentric exercises expose the tendon to a greater load than concentric exercises<sup>[106]</sup>. So, the prescription of an eccentric exercise program could be the best mechanism for strengthening the tendon<sup>[107]</sup>. Nevertheless, Rees *et al*<sup>[8]</sup> reported that peak tendon forces in eccentric loading are of the same magnitude as those seen in concentric loading suggesting that the tendon force magnitude alone cannot be responsible for the therapeutic benefit seen in eccentric loading. Thus, another possible mechanism that might explain the efficacy of eccentric loading is the high-frequency oscillations in tendon force produced by eccentric contractions. It was proposed that these fluctuations in force may provide an important stimulus for the remodeling of the tendon<sup>[8]</sup>.

Other possible mechanisms may be related to the increase in fibroblast activity, acceleration of collagen formation, increase in type I collagen, collagen organization/alignment (remodeling of the tendon)<sup>[107,108]</sup> by muscular lengthening (stretching)<sup>[99,109]</sup> and increase in the number of sarcomeres in series<sup>[110]</sup>. Ohberg *et al*<sup>[84]</sup> have showed a localized decrease in tendon thickness and a normalized tendon structure in patients with chronic Achilles tendinosis after treatment with eccentric training. All these beneficial adaptations could allow proposing the eccentric training as a "tendon-strengthening" program<sup>[9]</sup>.

Finally, another explanation of the eccentric training effectiveness is the traction and consequent disappearance of neovessels<sup>[65]</sup> that could lead to a lack of perfusion produced by the tendinosis. Although the decreased capillary tendon blood associated with increasing age might imply a consecutive bad perfusion and leads to tendinopathy and finally to tendon rupture, it was found that neovascularization is associated with a significantly increased capillary blood flow at the point of pain in symptomatic tendinopathy.

In fact, it has been hypothesized that the resolution of the tendinosis neovascularization by eccentric training, closely associated with new nerve endings, will be disturbed or even destroyed due to a lack of perfusion by their nutrient neovessels<sup>[53]</sup>. These studies speculate that some of the good clinical effects of the eccentric training may be mediated through decreasing pathological increased capillary tendon flow without deterioration of

local tendon microcirculation, but more evidence is necessary.

Another mechanism of the well tolerated reactions of the patients under eccentric training treatment includes neuromuscular benefits through central adaptations<sup>[8]</sup> and pain habituation, but there are not high quality trials to support this<sup>[103]</sup>.

One of the most important aspects for the success of an exercise program is the individualization of the prescription. The exercise program should be as similar as possible to the usual mechanical stressors identified in each patient<sup>[87]</sup>. The comprehension and motivation of the patients, and the establishment of specific goals, practice and efforts could make easy the motor learning<sup>[111]</sup>. The more exhaustive process of the information (explanations, knowledge, motivation, attention), the deeper learning<sup>[112]</sup>. All these aspects, clearly linked to the eccentric training, could partially explain the effectiveness of this treatment approach.

It is well documented that the first bout of eccentric training could result in damage, including muscle pain, inflammation, cellular and subcellular alterations, force loss, blood markers of muscle damage<sup>[113]</sup>. The damage of eccentric contractions is related to a “mechanical insult”, because as muscle lengthens, the ability to generate tension increases and a higher load is distributed among the same number of fibers, resulting in a higher load per fiber ratio and, curiously, a lower muscle activity<sup>[114]</sup>. However, this fact is still controversial<sup>[115]</sup>.

Hypoxia has been described as a mechanism of tenocyte changes and death<sup>[76]</sup>. As previously commented, this is another controversial point because the intermittent capillary flow interruptions associated to eccentric training have been proposed as a benefic effect, but it could also produce tissue hypoxia and damage in capillaries<sup>[116]</sup>.

Nevertheless, these adverse effects are mainly associated to the first bout of eccentric exercise. In fact, the following bouts of eccentric exercises do not produce the same muscle soreness or alteration in blood markers, and the recovery of the strength is faster when compared to the first bout<sup>[113]</sup>.

In summary, eccentric training effects could be compared with the mechanical effects in tenocyte biology, where an adequate load increases healing and an inadequate (over or underuse) load can deteriorate the tendon structure.

Rotator cuff tendons attach the humerus very close to the glenohumeral joint, blending imperceptibly with the joint capsule. This increases the speed with which they can move the joint, producing a most effective moment arm<sup>[117]</sup>. The tendons “compete” with the glenohumeral capsule for bony anchorage, multiplying their functions. The conflict may be resolved by the fusion of the two structures<sup>[25]</sup>.

Although the literature supports the use of strengthening and stretching exercises to reduce pain and functional loss in subjects with shoulder impingement<sup>[1,118]</sup>, few studies have evaluated the effects of the eccentric training in subjects with this condition. Further, the

literature supporting the beneficial effects of eccentric training in Achilles and patellar tendinopathy is abundant, but these effects are less known in rotator cuff tendon disorders<sup>[9]</sup>.

Jonsson *et al*<sup>[13]</sup> have shown good clinical results of eccentric training for the supraspinatus and deltoid muscles in chronic painful subjects. The authors completed the study in 9 subjects that were on the waiting list for surgery. All subjects had to perform painful eccentric training for the supraspinatus and deltoid muscles for 12 wk, 7 d a week, 3 sets of 15 repetitions, twice a day. After this period of training and at 52-wk follow-up, 5 out of 9 subjects were satisfied with the result of the treatment and withdrew from the waiting list for surgical treatment.

Bernhardsson *et al*<sup>[14]</sup> have evaluated the effects of an exercise focusing on specific eccentric training for the rotator cuff on pain intensity and function in subjects with shoulder impingement. The training programme comprised 5 exercises, of which 2 were warm-up and scapular control (shoulder shrug and scapular retraction) exercises and stretching for the upper trapezius. The 2 main exercises were eccentric strengthening exercises for the supraspinatus and infraspinatus performed in a side-lying position and using dumbbells. The frequency of the protocol was the same as proposed by Jonsson *et al*<sup>[11]</sup>. The training was effective to decrease pain and increase function.

Camargo *et al*<sup>[15]</sup> had their patients with shoulder impingement to perform eccentric isokinetic training at 60°/s for shoulder abductors during 6 wk (3 sets of 10 reps, 2 d a week). Subjects improved pain and function, but isokinetic variables were only moderately changed after the intervention. This type of training may be difficult to be incorporated in a clinical setting, as it requires an isokinetic device.

The main limitation of the previous studies is that none of them included a control group. They all had one group performing the same exercises. The lack of control group does not allow us to completely rule out that the natural maturation of the condition may have influenced the results.

Based on this, Maenhout *et al*<sup>[16]</sup> investigated if adding heavy load eccentric training to rehabilitation of patients with shoulder impingement would result in better outcome. One group of patients performed the traditional rotator cuff training and the other group performed the same exercises combined with heavy load of eccentric training. The protocol consisted of 3 sets of ten reps, daily, for 12 wk. The eccentric exercises were performed twice a day. Adding heavy load of eccentric training resulted in higher gain in isometric strength, but was not superior for decreasing pain and improving shoulder function.

It is important to highlight that different doses of eccentric training were used in the previous studies. The lack of understanding about the basic pathophysiology of tendinopathy makes determining the optimal dosage of intervention difficult. Because the studies in this area have not used an underlying rationale to determine load-



ing parameters, progressions and frequency of treatment, further research needs to be undertaken before an optimal dosage can be determined.

Other studies have also incorporated the use of eccentric exercises along with other exercises in the rehabilitation protocol for subjects with shoulder impingement<sup>[119-121]</sup>, but they didn't intend to evaluate the effects of the eccentric training. The cited studies on eccentric training<sup>[13-16]</sup> only evaluated the effects of the eccentric training on shoulder pain, function and strength. None of the studies assessed the effects on the shoulder kinematics and muscle activity.

It is known that subjects with shoulder impingement present increased retraction and elevation of the clavicle, increased internal rotation and decreased upward rotation and posterior tilting of the scapula<sup>[122]</sup>, and increased anterior and superior translations of the humerus during elevation of the arm as compared to healthy subjects<sup>[123]</sup>. The literature also brings that these alterations are commonly associated with increased activity of the upper trapezius, decreased activity of the lower trapezius, serratus anterior and rotator cuff muscles<sup>[124]</sup>. Based on the alterations above, many protocols are proposed in an attempt to restore kinematics and muscle activity in these individuals. Most of the protocols include stretching exercises for the anterior and posterior shoulder, strengthening exercises for the lower trapezius, serratus anterior and rotator cuff muscles, relaxation for the upper trapezius and techniques of manual therapy<sup>[1,118,125-127]</sup>. Good clinical results were observed in these investigations.

Further clinical trials should be done to evaluate the effects of eccentric training programs on scapular and humeral kinematics and shoulder muscles activity<sup>[104]</sup>. Future investigations should include long-term follow-up of large groups, and the comparison of different eccentric training protocols. Imaging evaluation before and after the period of treatment is also necessary to check on possible improvements of the injured tendon.

Finally, there is still lack of evidence of the really benefits that the eccentric exercises may bring to subjects with shoulder tendinopathy. In the treatment of shoulder impingement, the approach should not only focus on decreasing the impingement, but should additionally address the tendon degeneration. As such, eccentric training should be used aiming improvement of the tendon degeneration, and usual stretching and strengthening exercises associated with manual therapy techniques to restore kinematics and muscle activity.

## REFERENCES

- 1 **Camargo PR**, Haik MN, Ludewig PM, Filho RB, Mattiello-Rosa SM, Salvini TF. Effects of strengthening and stretching exercises applied during working hours on pain and physical impairment in workers with subacromial impingement syndrome. *Physiother Theory Pract* 2009; **25**: 463-475 [PMID: 19925169 DOI: 10.3109/09593980802662145]
- 2 **Cools AM**, Declercq G, Cagnie B, Cambier D, Witvrouw E. Internal impingement in the tennis player: rehabilitation guidelines. *Br J Sports Med* 2008; **42**: 165-171 [PMID: 18070811]
- 3 **Martins LV**, Marziale MH. Assessment of proprioceptive exercises in the treatment of rotator cuff disorders in nursing professionals: a randomized controlled clinical trial. *Rev Bras Fisioter* 2012; **16**: 502-509 [PMID: 23117648]
- 4 **Marcondes FB**, de Jesus JF, Bryk FF, de Vasconcelos RA, Fukuda TY. Posterior shoulder tightness and rotator cuff strength assessments in painful shoulders of amateur tennis players. *Braz J Phys Ther* 2013; **17**: 185-194 [PMID: 23778770 DOI: 10.1590/S1413-35552012005000079]
- 5 **Wang JH**, Iosifidis MI, Fu FH. Biomechanical basis for tendinopathy. *Clin Orthop Relat Res* 2006; **443**: 320-332 [PMID: 16462458]
- 6 **Leadbetter WB**. Cell-matrix response in tendon injury. *Clin Sports Med* 1992; **11**: 533-578 [PMID: 1638640]
- 7 **Alfredson H**, Pietilä T, Jonsson P, Lorentzon R. Heavy-load eccentric calf muscle training for the treatment of chronic Achilles tendinosis. *Am J Sports Med* 1998; **26**: 360-366 [PMID: 9617396]
- 8 **Rees JD**, Lichtwark GA, Wolman RL, Wilson AM. The mechanism for efficacy of eccentric loading in Achilles tendon injury; an in vivo study in humans. *Rheumatology (Oxford)* 2008; **47**: 1493-1497 [PMID: 18647799 DOI: 10.1093/rheumatology/ken262]
- 9 **Murtaugh B**, Ihm JM. Eccentric training for the treatment of tendinopathies. *Curr Sports Med Rep* 2013; **12**: 175-182 [PMID: 23669088 DOI: 10.1249/JSR.0b013e318293761]
- 10 **Khan KM**, Cook JL, Bonar F, Harcourt P, Astrom M. Histopathology of common tendinopathies. Update and implications for clinical management. *Sports Med* 1999; **27**: 393-408 [PMID: 10418074]
- 11 **Fukuda H**. The management of partial-thickness tears of the rotator cuff. *J Bone Joint Surg Br* 2003; **85**: 3-11 [PMID: 12585570]
- 12 **Dean BJ**, Franklin SL, Carr AJ. A systematic review of the histological and molecular changes in rotator cuff disease. *Bone Joint Res* 2012; **1**: 158-166 [PMID: 23610686 DOI: 10.1302/2046-3758.17.2000115]
- 13 **Jonsson P**, Wahlström P, Ohberg L, Alfredson H. Eccentric training in chronic painful impingement syndrome of the shoulder: results of a pilot study. *Knee Surg Sports Traumatol Arthrosc* 2006; **14**: 76-81 [PMID: 15877219]
- 14 **Bernhardsson S**, Klintberg IH, Wendt GK. Evaluation of an exercise concept focusing on eccentric strength training of the rotator cuff for patients with subacromial impingement syndrome. *Clin Rehabil* 2011; **25**: 69-78 [PMID: 20713438 DOI: 10.1177/0269215510376005]
- 15 **Camargo PR**, Avila MA, Albuquerque-Sendin F, Asso NA, Hashimoto LH, Salvini TF. Eccentric training for shoulder abductors improves pain, function and isokinetic performance in subjects with shoulder impingement syndrome: a case series. *Rev Bras Fisioter* 2012; **16**: 74-83 [PMID: 22441232 DOI: 10.1590/S1413-35552012000100013]
- 16 **Maenhout AG**, Mahieu NN, De Mueynck M, De Wilde LF, Cools AM. Does adding heavy load eccentric training to rehabilitation of patients with unilateral subacromial impingement result in better outcome? A randomized, clinical trial. *Knee Surg Sports Traumatol Arthrosc* 2013; **21**: 1158-1167 [PMID: 22581193 DOI: 10.1007/s00167-012-2012-8]
- 17 **Culav EM**, Clark CH, Merrilees MJ. Connective tissues: matrix composition and its relevance to physical therapy. *Phys Ther* 1999; **79**: 308-319 [PMID: 10078774]
- 18 **Khan K**, Cook J. The painful nonruptured tendon: clinical aspects. *Clin Sports Med* 2003; **22**: 711-725 [PMID: 14560543]
- 19 **Screen HR**, Lee DA, Bader DL, Shelton JC. An investigation into the effects of the hierarchical structure of tendon fascicles on micromechanical properties. *Proc Inst Mech Eng H* 2004; **218**: 109-119 [PMID: 15116898]
- 20 **Kastelic J**, Galeski A, Baer E. The multicomposite structure of tendon. *Connect Tissue Res* 1978; **6**: 11-23 [PMID: 149646]
- 21 **Ochiai N**, Matsui T, Miyaji N, Merklin RJ, Hunter JM. Vascular anatomy of flexor tendons. I. Vincular system and

- blood supply of the profundus tendon in the digital sheath. *J Hand Surg Am* 1979; **4**: 321-330 [PMID: 469207]
- 22 **Fallon J**, Blevins FT, Vogel K, Trotter J. Functional morphology of the supraspinatus tendon. *J Orthop Res* 2002; **20**: 920-926 [PMID: 12382954]
  - 23 **Schatzker J**, Brånemark PI. Intravital observations on the microvascular anatomy and microcirculation of the tendon. *Acta Orthop Scand Suppl* 1969; **126**: 1-23 [PMID: 4912831]
  - 24 **Benjamin M**, Ralphs JR. Tendons in health and disease. *Man Ther* 1996; **1**: 186-191 [PMID: 11440506]
  - 25 **Benjamin M**, Kaiser E, Milz S. Structure-function relationships in tendons: a review. *J Anat* 2008; **212**: 211-228 [PMID: 18304204 DOI: 10.1111/j.1469-7580.2008.00864.x]
  - 26 **Carr A**, Harvie P. Rotator cuff tendinopathy. In: Maffulli N, Renström P, Leadbetter WB. Tendon injuries: Basic science and clinical medicine. London: Springer, 2005: 101-118
  - 27 **Choi CH**, Kim SK, Jang WC, Kim SJ. Biceps pulley impingement. *Arthroscopy* 2004; **20** Suppl 2: 80-83 [PMID: 15243433]
  - 28 **Roh MS**, Wang VM, April EW, Pollock RG, Bigliani LU, Flatow EL. Anterior and posterior musculotendinous anatomy of the supraspinatus. *J Shoulder Elbow Surg* 2000; **9**: 436-440 [PMID: 11075329]
  - 29 **Matsushashi T**, Hooke AW, Zhao KD, Goto A, Sperling JW, Steinmann SP, An KN. Tensile properties of a morphologically split supraspinatus tendon. *Clin Anat* 2014; **27**: 702-706 [PMID: 24214830 DOI: 10.1002/ca.22322]
  - 30 **Kim SY**, Boynton EL, Ravichandiran K, Fung LY, Bleakney R, Agur AM. Three-dimensional study of the musculotendinous architecture of supraspinatus and its functional correlations. *Clin Anat* 2007; **20**: 648-655 [PMID: 17352416]
  - 31 **Biberthaler P**, Wiedemann E, Nerlich A, Kettler M, Mussack T, Deckelmann S, Mutschler W. Microcirculation associated with degenerative rotator cuff lesions. In vivo assessment with orthogonal polarization spectral imaging during arthroscopy of the shoulder. *J Bone Joint Surg Am* 2003; **85-A**: 475-480 [PMID: 12637434]
  - 32 **Riley GP**, Harrall RL, Constant CR, Chard MD, Cawston TE, Hazleman BL. Glycosaminoglycans of human rotator cuff tendons: changes with age and in chronic rotator cuff tendinitis. *Ann Rheum Dis* 1994; **53**: 367-376 [PMID: 8037495]
  - 33 **Fan L**, Sarkar K, Franks DJ, Uthoff HK. Estimation of total collagen and types I and III collagen in canine rotator cuff tendons. *Calcif Tissue Int* 1997; **61**: 223-229 [PMID: 9262514]
  - 34 **Puxkandl R**, Zizak I, Paris O, Keckes J, Tesch W, Bernstorff S, Purslow P, Fratzl P. Viscoelastic properties of collagen: synchrotron radiation investigations and structural model. *Philos Trans R Soc Lond B Biol Sci* 2002; **357**: 191-197 [PMID: 11911776]
  - 35 **Dressler MR**, Butler DL, Wenstrup R, Awad HA, Smith F, Boivin GP. A potential mechanism for age-related declines in patellar tendon biomechanics. *J Orthop Res* 2002; **20**: 1315-1322 [PMID: 12472246]
  - 36 **Bi Y**, Ehrichtiou D, Kilts TM, Inkson CA, Embree MC, Sonoyama W, Li L, Leet AI, Seo BM, Zhang L, Shi S, Young MF. Identification of tendon stem/progenitor cells and the role of the extracellular matrix in their niche. *Nat Med* 2007; **13**: 1219-1227 [PMID: 17828274]
  - 37 **Thomopoulos S**, Genin GM, Galatz LM. The development and morphogenesis of the tendon-to-bone insertion - what development can teach us about healing. *J Musculoskelet Neural Interact* 2010; **10**: 35-45 [PMID: 20190378]
  - 38 **Canty EG**, Kadler KE. Collagen fibril biosynthesis in tendon: a review and recent insights. *Comp Biochem Physiol A Mol Integr Physiol* 2002; **133**: 979-985 [PMID: 12485687]
  - 39 **Berenson MC**, Blevins FT, Plaas AH, Vogel KG. Proteoglycans of human rotator cuff tendons. *J Orthop Res* 1996; **14**: 518-525 [PMID: 8764859]
  - 40 **Riley GP**, Harrall RL, Constant CR, Chard MD, Cawston TE, Hazleman BL. Tendon degeneration and chronic shoulder pain: changes in the collagen composition of the human rotator cuff tendons in rotator cuff tendinitis. *Ann Rheum Dis* 1994; **53**: 359-366 [PMID: 8037494]
  - 41 **Burke WS**, Vangsness CT, Powers CM. Strengthening the supraspinatus: a clinical and biomechanical review. *Clin Orthop Relat Res* 2002; **(402)**: 292-298 [PMID: 12218496]
  - 42 **Littlewood C**. Contractile dysfunction of the shoulder (rotator cuff tendinopathy): an overview. *J Man Manip Ther* 2012; **20**: 209-213 [PMID: 24179329]
  - 43 **Lewis JS**. Rotator cuff tendinopathy/subacromial impingement syndrome: is it time for a new method of assessment? *Br J Sports Med* 2009; **43**: 259-264 [PMID: 18838403 DOI: 10.1136/bjsm.2008.052183]
  - 44 **Neer CS**. Anterior acromioplasty for the chronic impingement syndrome in the shoulder: a preliminary report. *J Bone Joint Surg Am* 1972; **54**: 41-50 [PMID: 5054450]
  - 45 **Tuoheti Y**, Itoi E, Pradhan RL, Wakabayashi I, Takahashi S, Minagawa H, Kobayashi M, Okada K, Shimada Y. Apoptosis in the supraspinatus tendon with stage II subacromial impingement. *J Shoulder Elbow Surg* 2005; **14**: 535-541 [PMID: 16194748]
  - 46 **Bunker T**. Rotator cuff disease. *Curr Orthop* 2002; **16**: 223-233
  - 47 **Hughes PJ**, Bolton-Maggs B. Calcifying tendonitis. *Curr Orthop* 2002; **16**: 389-394
  - 48 **Fredberg U**, Stengaard-Pedersen K. Chronic tendinopathy tissue pathology, pain mechanisms, and etiology with a special focus on inflammation. *Scand J Med Sci Sports* 2008; **18**: 3-15 [PMID: 18294189 DOI: 10.1111/j.1600-0838.2007.00746.x]
  - 49 **Yuan J**, Wang MX, Murrell GA. Cell death and tendinopathy. *Clin Sports Med* 2003; **22**: 693-701 [PMID: 14560541]
  - 50 **Riley G**. The pathogenesis of tendinopathy. A molecular perspective. *Rheumatology (Oxford)* 2004; **43**: 131-142 [PMID: 12867575]
  - 51 **Puddu G**, Ippolito E, Postacchini F. A classification of Achilles tendon disease. *Am J Sports Med* 1976; **4**: 145-150 [PMID: 984291]
  - 52 **Futami T**, Itoman M. Extensor carpi ulnaris syndrome. Findings in 43 patients. *Acta Orthop Scand* 1995; **66**: 538-539 [PMID: 8553824]
  - 53 **Knobloch K**. The role of tendon microcirculation in Achilles and patellar tendinopathy. *J Orthop Surg Res* 2008; **3**: 18 [PMID: 18447938 DOI: 10.1186/1749-799X-3-18]
  - 54 **Potter HG**, Hannafin JA, Morwessel RM, DiCarlo EF, O'Brien SJ, Altchek DW. Lateral epicondylitis: correlation of MR imaging, surgical, and histopathologic findings. *Radiology* 1995; **196**: 43-46 [PMID: 7784585]
  - 55 **Visnes H**, Hoksrud A, Cook J, Bahr R. No effect of eccentric training on jumper's knee in volleyball players during the competitive season: a randomized clinical trial. *Clin J Sport Med* 2005; **15**: 227-234 [PMID: 16003036]
  - 56 **Järvinen M**, Józsa L, Kannus P, Järvinen TL, Kvist M, Leadbetter W. Histopathological findings in chronic tendon disorders. *Scand J Med Sci Sports* 1997; **7**: 86-95 [PMID: 9211609]
  - 57 **Magnusson SP**, Langberg H, Kjaer M. The pathogenesis of tendinopathy: balancing the response to loading. *Nat Rev Rheumatol* 2010; **6**: 262-268 [PMID: 20308995 DOI: 10.1038/nrrheum.2010.43]
  - 58 **Franchi M**, Trirè A, Quaranta M, Orsini E, Ottani V. Collagen structure of tendon relates to function. *ScientificWorldJournal* 2007; **7**: 404-420 [PMID: 17450305]
  - 59 **Maeda E**, Shelton JC, Bader DL, Lee DA. Differential regulation of gene expression in isolated tendon fascicles exposed to cyclic tensile strain in vitro. *J Appl Physiol* (1985) 2009; **106**: 506-512 [PMID: 19036888 DOI: 10.1152/jappphysiol.90981.2008]
  - 60 **Scott A**, Cook JL, Hart DA, Walker DC, Duronio V, Khan KM. Tenocyte responses to mechanical loading in vivo: a role for local insulin-like growth factor 1 signaling in early tendinosis in rats. *Arthritis Rheum* 2007; **56**: 871-881 [PMID: 17328060]
  - 61 **Kjaer M**, Langberg H, Heinemeier K, Bayer ML, Hansen M, Holm L, Doessing S, Kongsgaard M, Krogsgaard MR, Mag-

- nusson SP. From mechanical loading to collagen synthesis, structural changes and function in human tendon. *Scand J Med Sci Sports* 2009; **19**: 500-510 [PMID: 19706001 DOI: 10.1111/j.1600-0838.2009.00986.x]
- 62 **Arnocky SP**, Lavagnino M, Egerbacher M. The Response of Tendon Cells to Changing Loads: Implications in the Etiopathogenesis of Tendinopathy. In: Woo L-Y, Renström AFH, Arnoczky SP. *Tendinopathy in athletes*. Oxford, UK: Wiley online library, 2007: 46-59
  - 63 **Matsen FA**, Fehring EV, Lippitt SB, Wirth MA, Rockwood CA. Rotator Cuff. In: Rockwood CA, Matsen FA, Wirth MA, Lippitt SB. *The Shoulder*. Philadelphia: Elsevier, 2009
  - 64 **Aström M**, Westlin N. Blood flow in the human Achilles tendon assessed by laser Doppler flowmetry. *J Orthop Res* 1994; **12**: 246-252 [PMID: 8164098]
  - 65 **Ohberg L**, Alfredson H. Effects on neovascularisation behind the good results with eccentric training in chronic mid-portion Achilles tendinosis? *Knee Surg Sports Traumatol Arthrosc* 2004; **12**: 465-470 [PMID: 15060761]
  - 66 **Kannus P**, Józsa L. Histopathological changes preceding spontaneous rupture of a tendon. A controlled study of 891 patients. *J Bone Joint Surg Am* 1991; **73**: 1507-1525 [PMID: 1748700]
  - 67 **Riley GP**, Goddard MJ, Hazleman BL. Histopathological assessment and pathological significance of matrix degeneration in supraspinatus tendons. *Rheumatology (Oxford)* 2001; **40**: 229-230 [PMID: 11257166]
  - 68 **Hashimoto T**, Nobuhara K, Hamada T. Pathologic evidence of degeneration as a primary cause of rotator cuff tear. *Clin Orthop Relat Res* 2003; **(415)**: 111-120 [PMID: 14612637]
  - 69 **Woo SL**, Hildebrand K, Watanabe N, Fenwick JA, Papa-georgiou CD, Wang JH. Tissue engineering of ligament and tendon healing. *Clin Orthop Relat Res* 1999; **(367 Suppl)**: S312-S323 [PMID: 10546655]
  - 70 **Maffulli N**, Longo UG. How do eccentric exercises work in tendinopathy? *Rheumatology (Oxford)* 2008; **47**: 1444-1445 [PMID: 18697828 DOI: 10.1093/rheumatology/ken337]
  - 71 **Kader D**, Saxena A, Movin T, Maffulli N. Achilles tendinopathy: some aspects of basic science and clinical management. *Br J Sports Med* 2002; **36**: 239-249 [PMID: 12145112]
  - 72 **Sharma P**, Maffulli N. Tendon injury and tendinopathy: healing and repair. *J Bone Joint Surg Am* 2005; **87**: 187-202 [PMID: 15634833]
  - 73 **Magnusson SP**, Qvortrup K, Larsen JO, Rosager S, Hanson P, Aagaard P, Krogsgaard M, Kjaer M. Collagen fibril size and crimp morphology in ruptured and intact Achilles tendons. *Matrix Biol* 2002; **21**: 369-377 [PMID: 12128074]
  - 74 **Cook JL**, Purdam CR. Is tendon pathology a continuum? A pathology model to explain the clinical presentation of load-induced tendinopathy. *Br J Sports Med* 2009; **43**: 409-416 [PMID: 18812414 DOI: 10.1136/bjsm.2008.051193]
  - 75 **Oakes BW**. Tissue healing and repair: tendons and ligaments. In: Frontera WR. *Rehabilitation of Sports Injuries: Scientific Basis*. Oxford, UK: Wiley on line library, 2008: 56-98
  - 76 **Weeks KD**, Dines JS, Rodeo SA, Bedi A. The basic science behind biologic augmentation of tendon-bone healing: a scientific review. *Instr Course Lect* 2014; **63**: 443-450 [PMID: 24720329]
  - 77 **Hudak PL**, Amadio PC, Bombardier C. Development of an upper extremity outcome measure: the DASH (disabilities of the arm, shoulder and hand) [corrected]. The Upper Extremity Collaborative Group (UECG) *Am J Ind Med* 1996; **29**: 602-608 [PMID: 8773720]
  - 78 **Kirkley A**, Alvarez C, Griffin S. The development and evaluation of a disease-specific quality-of-life questionnaire for disorders of the rotator cuff: The Western Ontario Rotator Cuff Index. *Clin J Sport Med* 2003; **13**: 84-92 [PMID: 12629425]
  - 79 **Roach KE**, Budiman-Mak E, Songsiridej N, Lertratanakul Y. Development of a shoulder pain and disability index. *Arthritis Care Res* 1991; **4**: 143-149 [PMID: 11188601]
  - 80 **Leggin BG**, Michener LA, Shaffer MA, Brenneman SK, Iannotti JP, Williams GR. The Penn shoulder score: reliability and validity. *J Orthop Sports Phys Ther* 2006; **36**: 138-151 [PMID: 16596890]
  - 81 **Michener LA**, Walsworth MK, Doukas WC, Murphy KP. Reliability and diagnostic accuracy of 5 physical examination tests and combination of tests for subacromial impingement. *Arch Phys Med Rehabil* 2009; **90**: 1898-1903 [PMID: 19887215 DOI: 10.1016/j.apmr.2009.05.015]
  - 82 **Travell J**, Simons D. *Myofascial Pain and Dysfunction: The Trigger Point Manual*. 2nd ed. Baltimore: Lippincott Williams & Williams, 1999
  - 83 **Alburquerque-Sendín F**, Camargo PR, Vieira A, Salvini TF. Bilateral myofascial trigger points and pressure pain thresholds in the shoulder muscles in patients with unilateral shoulder impingement syndrome: a blinded, controlled study. *Clin J Pain* 2013; **29**: 478-486 [PMID: 23328323 DOI: 10.1097/AJP.0b013e3182652d65]
  - 84 **Ohberg L**, Lorentzon R, Alfredson H. Eccentric training in patients with chronic Achilles tendinosis: normalised tendon structure and decreased thickness at follow up. *Br J Sports Med* 2004; **38**: 8-11; discussion 11 [PMID: 14751936]
  - 85 **Temes WC**, Temes Clifton A, Hilton V, Girard L, Strait N, Karduna A. Reliability and Validity of Thickness Measurements of the Supraspinatus Muscle of the Shoulder: An Ultrasonography Study. *J Sport Rehabil* 2014 Mar 12; Epub ahead of print [PMID: 24622686]
  - 86 **Kuzel BR**, Grindel S, Papandrea R, Ziegler D. Fatty infiltration and rotator cuff atrophy. *J Am Acad Orthop Surg* 2013; **21**: 613-623 [PMID: 24084435 DOI: 10.5435/JAAOS-21-10-613]
  - 87 **Houghum P**. *Therapeutic exercise for musculoskeletal injuries*. 3rd ed. Champaign, IL: Human Kinetics, 2005
  - 88 **Huijbregts PA**, Bron C. Rotator cuff lesions: shoulder impingement. In: Fernández-de-las-Peñas C, Cleland JA, Huijbregts PA. *Neck and Arm Pain Syndromes*. London: Churchill-Livingstone, 2011: 220-233
  - 89 **Collin P**, Matsumura N, Lädermann A, Denard PJ, Walch G. Relationship between massive chronic rotator cuff tear pattern and loss of active shoulder range of motion. *J Shoulder Elbow Surg* 2014; **23**: 1195-1202 [PMID: 24433628 DOI: 10.1016/j.jse.2013.11.019]
  - 90 **Shindle MK**, Chen CC, Robertson C, DiTullio AE, Paulus MC, Clinton CM, Cordasco FA, Rodeo SA, Warren RF. Full-thickness supraspinatus tears are associated with more synovial inflammation and tissue degeneration than partial-thickness tears. *J Shoulder Elbow Surg* 2011; **20**: 917-927 [PMID: 21612944 DOI: 10.1016/j.jse.2011.02.015]
  - 91 **Magra M**, Maffulli N. Nonsteroidal antiinflammatory drugs in tendinopathy: friend or foe. *Clin J Sport Med* 2006; **16**: 1-3 [PMID: 16377967]
  - 92 **Scutt N**, Rolf CG, Scutt A. Glucocorticoids inhibit tenocyte proliferation and Tendon progenitor cell recruitment. *J Orthop Res* 2006; **24**: 173-182 [PMID: 16435354]
  - 93 **Wong MW**, Tang YY, Lee SK, Fu BS. Glucocorticoids suppress proteoglycan production by human tenocytes. *Acta Orthop* 2005; **76**: 927-931 [PMID: 16470453]
  - 94 **de Boer MD**, Selby A, Atherton P, Smith K, Seynnes OR, Maganaris CN, Maffulli N, Movin T, Narici MV, Rennie MJ. The temporal responses of protein synthesis, gene expression and cell signalling in human quadriceps muscle and patellar tendon to disuse. *J Physiol* 2007; **585**: 241-251 [PMID: 17901116]
  - 95 **Lavagnino M**, Arnoczky SP, Egerbacher M, Gardner KL, Burns ME. Isolated fibrillar damage in tendons stimulates local collagenase mRNA expression and protein synthesis. *J Biomech* 2006; **39**: 2355-2362 [PMID: 16256123]
  - 96 **Lavagnino M**, Arnoczky SP, Tian T, Vaupel Z. Effect of amplitude and frequency of cyclic tensile strain on the inhibition of MMP-1 mRNA expression in tendon cells: an in vitro study. *Connect Tissue Res* 2003; **44**: 181-187 [PMID: 14504039]



- 97 **Screen HR**, Shelton JC, Bader DL, Lee DA. Cyclic tensile strain upregulates collagen synthesis in isolated tendon fascicles. *Biochem Biophys Res Commun* 2005; **336**: 424-429 [PMID: 16137647]
- 98 **Frontera WR**, Slovik DM, Dawson DM. Exercise in rehabilitation medicine. Champaign: Human Kinetics, 2005
- 99 **Garber CE**, Blissmer B, Deschenes MR, Franklin BA, Lamonte MJ, Lee IM, Nieman DC, Swain DP. American College of Sports Medicine position stand. Quantity and quality of exercise for developing and maintaining cardiorespiratory, musculoskeletal, and neuromotor fitness in apparently healthy adults: guidance for prescribing exercise. *Med Sci Sports Exerc* 2011; **43**: 1334-1359 [PMID: 21694556 DOI: 10.1249/MSS.0b013e318213fcbf]
- 100 **LaStayo PC**, Woolf JM, Lewek MD, Snyder-Mackler L, Reich T, Lindstedt SL. Eccentric muscle contractions: their contribution to injury, prevention, rehabilitation, and sport. *J Orthop Sports Phys Ther* 2003; **33**: 557-571 [PMID: 14620785]
- 101 **Croisier JL**, Foidart-Dessalle M, Tinant F, Crielaard JM, Forthomme B. An isokinetic eccentric programme for the management of chronic lateral epicondylar tendinopathy. *Br J Sports Med* 2007; **41**: 269-275 [PMID: 17224433]
- 102 **Rompe JD**, Nafe B, Furia JP, Maffulli N. Eccentric loading, shock-wave treatment, or a wait-and-see policy for tendinopathy of the main body of tendo Achillis: a randomized controlled trial. *Am J Sports Med* 2007; **35**: 374-383 [PMID: 17244902]
- 103 **Woodley BL**, Newsham-West RJ, Baxter GD. Chronic tendinopathy: effectiveness of eccentric exercise. *Br J Sports Med* 2007; **41**: 188-198; discussion 199 [PMID: 17062655]
- 104 **Yelvington CJ**, Pong EJ. Tendinopathies of the wrist and hand. In: Fernández-de-las-Peñas, Cleland JA, Huijbregts PA. Neck and Arm Pain Syndromes. London: Churchill-Livingstone, 2011: 335-350
- 105 **McEvoy J**, O'Sullivan K, Bron C. Therapeutic exercises for the shoulder region. In: Fernández-de-las-Peñas, Cleland JA, Huijbregts PA. Neck and Arm Pain Syndromes. London: Churchill-Livingstone, 2011: 335-350
- 106 **Stanish WD**, Rubinovich RM, Curwin S. Eccentric exercise in chronic tendinitis. *Clin Orthop Relat Res* 1986; **(208)**: 65-68 [PMID: 3720143]
- 107 **Peers KH**, Lysens RJ. Patellar tendinopathy in athletes: current diagnostic and therapeutic recommendations. *Sports Med* 2005; **35**: 71-87 [PMID: 15651914]
- 108 **Jeffery R**, Cronin J, Bressel E. Eccentric strengthening: Clinical applications to Achilles tendinopathy. *New Zealand J Sports Med* 2005; **33**: 22-30
- 109 **Langberg H**, Ellingsgaard H, Madsen T, Jansson J, Magnusson SP, Aagaard P, Kjaer M. Eccentric rehabilitation exercise increases peritendinous type I collagen synthesis in humans with Achilles tendinosis. *Scand J Med Sci Sports* 2007; **17**: 61-66 [PMID: 16787448]
- 110 **Whitehead NP**, Allen TJ, Morgan DL, Proske U. Damage to human muscle from eccentric exercise after training with concentric exercise. *J Physiol* 1998; **512** (Pt 2): 615-620 [PMID: 9763649]
- 111 **Shumway-Cook A**, Woollacott MH. Motor Control. Translating research into clinical practice, 3<sup>rd</sup> ed. Philadelphia Pennsylvania: Lippincott Williams & Wilkins, 2007
- 112 **Sousa D**. How the brain learns, Chapters 2-4. Thousand Oaks, California: Corwin Press, 2006
- 113 **Clarkson PM**, Hubal MJ. Exercise-induced muscle damage in humans. *Am J Phys Med Rehabil* 2002; **81**: S52-S69 [PMID: 12409811]
- 114 **Enoka RM**. Eccentric contractions require unique activation strategies by the nervous system. *J Appl Physiol* (1985) 1996; **81**: 2339-2346
- 115 **Bawa P**, Jones KE. Do lengthening contractions represent a case of reversal in recruitment order? *Prog Brain Res* 1999; **123**: 215-220 [PMID: 10635718]
- 116 **Jones DA**, Round JM. Human muscle damage induced by eccentric exercise or reperfusion injury: A common mechanism? In Salmons (ed): Muscle Damage. NewYork: Oxford Press, 1997: 64-75
- 117 **Kapandji IA**. The physiology of the joints, Volume 1: Upper Limb. 6th ed. Edinburgh: Churchill Livingstone, 2007
- 118 **Ludewig PM**, Borstad JD. Effects of a home exercise programme on shoulder pain and functional status in construction workers. *Occup Environ Med* 2003; **60**: 841-849 [PMID: 14573714]
- 119 **Holmgren T**, Björnsson Hallgren H, Öberg B, Adolfsson L, Johansson K. Effect of specific exercise strategy on need for surgery in patients with subacromial impingement syndrome: randomised controlled study. *BMJ* 2012; **344**: e787 [PMID: 22349588 DOI: 10.1136/bmj.e787]
- 120 **Lewis JS**. A specific exercise program for patients with subacromial impingement syndrome can improve function and reduce the need for surgery. *J Physiother* 2012; **58**: 127 [PMID: 22613243 DOI: 10.1016/S1836-9553(12)70093-0]
- 121 **Struyf F**, Nijs J, Mollekens S, Jeurissen I, Truijten S, Mottram S, Meeusen R. Scapular-focused treatment in patients with shoulder impingement syndrome: a randomized clinical trial. *Clin Rheumatol* 2013; **32**: 73-85 [PMID: 23053685 DOI: 10.1007/s10067-012-2093-2]
- 122 **Timmons MK**, Thigpen CA, Seitz AL, Karduna AR, Arnold BL, Michener LA. Scapular kinematics and subacromial-impingement syndrome: a meta-analysis. *J Sport Rehabil* 2012; **21**: 354-370 [PMID: 22388171]
- 123 **Ludewig PM**, Cook TM. Translations of the humerus in persons with shoulder impingement symptoms. *J Orthop Sports Phys Ther* 2002; **32**: 248-259 [PMID: 12061706]
- 124 **Phadke V**, Camargo P, Ludewig P. Scapular and rotator cuff muscle activity during arm elevation: A review of normal function and alterations with shoulder impingement. *Rev Bras Fisioter* 2009; **13**: 1-9 [PMID: 20411160]
- 125 **McClure PW**, Bialker J, Neff N, Williams G, Karduna A. Shoulder function and 3-dimensional kinematics in people with shoulder impingement syndrome before and after a 6-week exercise program. *Phys Ther* 2004; **84**: 832-848 [PMID: 15330696]
- 126 **Tate AR**, McClure PW, Young IA, Salvatori R, Michener LA. Comprehensive impairment-based exercise and manual therapy intervention for patients with subacromial impingement syndrome: a case series. *J Orthop Sports Phys Ther* 2010; **40**: 474-493 [PMID: 20710088 DOI: 10.2519/jospt.2010.3223]
- 127 **Haik MN**, Albuquerque-Sendin F, Silva CZ, Siqueira-Junior AL, Ribeiro IL, Camargo PR. Scapular kinematics pre- and post-thoracic thrust manipulation in individuals with and without shoulder impingement symptoms: a randomized controlled study. *J Orthop Sports Phys Ther* 2014; **44**: 475-487 [PMID: 24853923]

P- Reviewer: Miyamoto H S- Editor: Wen LL  
L- Editor: A E- Editor: Wu HL





## WJO 5<sup>th</sup> Anniversary Special Issues (10): Rheumatoid arthritis

# Thromboembolic disease in patients with rheumatoid arthritis undergoing joint arthroplasty: Update on prophylaxes

Antonella Mameli, Francesco Marongiu

Antonella Mameli, Internal Medicine and Haemocoagulopathies Division, AOU of Monserrato (Ca), 09042 Monserrato, Italy  
 Francesco Marongiu, Internal Medicine and Haemocoagulopathies Division, University of Cagliari, 09123 Cagliari, Italy  
 Author contributions: Mameli A and Marongiu F contributed equally to this work.

Correspondence to: Antonella Mameli, MD, Internal Medicine and Haemocoagulopathies Division, AOU of Monserrato (Ca), SS 554, 09042 Monserrato, Italy. [amameli@medicina.unica.it](mailto:amameli@medicina.unica.it)  
 Telephone: +39-070-6754188 Fax: +39-070-51096201  
 Received: December 25, 2013 Revised: March 26, 2014  
 Accepted: May 28, 2014  
 Published online: November 18, 2014

## Abstract

The risk of venous thromboembolism (VTE) in rheumatoid arthritis (RA) and the higher incidence of RA patients undergoing major orthopedic surgery is well recognized. The objective of the present study is to describe the incidence of VTE and discuss the correct prophylaxis in RA patients undergoing knee or hip replacement. A systematic review of studies on thromboprophylaxis in RA patients undergoing major orthopedic surgery was performed. Detailed information was extracted to calculate the rate of VTE in RA orthopedic patients and analyze the thromboprophylaxis performed and bleeding complications. Eight articles were eligible for full review. No difference in the overall rate of VTE was observed between RA patients and controls. No significant differences were found in RA patients in terms of bleeding complications. The data on the optimal prophylaxis to be used in RA patients were insufficient to recommend any of the several options available. In the absence of dedicated guidelines for the care of RA patients undergoing orthopedic surgery, management must be individualized to obtain favorable

patient outcome, weighing up all the factors that might put the patient at risk for higher bleeding and thrombotic events.

© 2014 Baishideng Publishing Group Inc. All rights reserved.

**Key words:** Thromboprophylaxis; Rheumatoid arthritis; Orthopaedic surgery; Total hip arthroplasty; Total knee arthroplasty

**Core tip:** The purpose of this review is to quantify the incidence of venous thromboembolism (VTE) in patients with rheumatoid arthritis (RA) undergoing major orthopedic surgery and to discuss the current management of VTE prophylaxis in RA patients undergoing major joint arthroplasty and establish whether these patients are at higher risk for VTE than the general population.

Mameli A, Marongiu F. Thromboembolic disease in patients with rheumatoid arthritis undergoing joint arthroplasty: Update on prophylaxes. *World J Orthop* 2014; 5(5): 645-652 Available from: URL: <http://www.wjgnet.com/2218-5836/full/v5/i5/645.htm> DOI: <http://dx.doi.org/10.5312/wjo.v5.i5.645>

## INTRODUCTION

Rheumatoid arthritis (RA) is a chronic systemic inflammatory disorder that can affect many tissues and organs. It principally attacks synovial joints, resulting in a painful condition and even in disability if inadequately treated. At present, surgical correction in patients with RA is a highly successful solution for those suffering from advanced joint destruction. However, it should be taken into account that venous thromboembolism may be a possible complication after total hip arthroplasty (THA) and total

knee arthroplasty (TKA) since orthopedic surgery carries *per se* a high risk for this thrombotic condition<sup>[1]</sup>. The link between chronic systemic inflammatory disease, such as RA and thrombotic disease has been documented: it may be the final effect of a hypercoagulability state concomitantly to a reduced fibrinolysis<sup>[2]</sup>. It is thought that hypercoagulability is induced by active systemic inflammation and production of cytokines such as TNF- $\alpha$  and interleukin-1, that can lead to endothelial dysfunction, down regulation of Protein C, a natural anticoagulant, and then to an inhibition of fibrinolysis<sup>[2,3]</sup>. Acute hospitalizations, drugs, surgical procedures, physical inactivity and other co-morbidities may represent further risk factors for VTE in RA patients<sup>[4]</sup>.

On the basis of the nine American College of Chest Physicians (ACCP) guidelines on VTE prevention, prophylaxis may be extended to more than 30 d, particularly after THA. The recommended thrombo-prophylactic regimens include low-molecular-weight heparin, fondaparinux, dabigatran, apixaban, rivaroxaban (total hip arthroplasty or total knee arthroplasty but not hip fracture surgery), low-dose unfractionated heparin, adjusted-dose vitamin K antagonist, aspirin (all Grade 1B), or an intermittent pneumatic compression device (IPCD) (Grade 1C) for a minimum of 10 to 14 d<sup>[1]</sup>.

These guidelines are based on investigations in which predominantly osteoarthritis (OA) patients were studied. Paradoxically, although the thromboembolic risk in RA patients is recognized to be high, contradictory results emerge from the few studies performed on RA patients undergoing orthopedic surgery.

The aim of this review is to understand better the incidence of thromboembolic diseases in RA patients undergoing major orthopedic surgery. Furthermore, the authors' aim is to discuss the current management of VTE prophylaxis in RA patients undergoing major joint arthroplasty and establish whether RA patients undergoing orthopedic surgery are at higher risk than the general population for VTE.

## RESEARCH

A systematic PubMed search was conducted to identify all articles between January 1970 and 15 November 2013 that analyzed the thromboprophylaxis in RA patients undergoing major orthopedic surgery. The Key words used in the search were: "Arthroplasty" OR "knee surgery," OR "Hip surgery" OR "Venous thromboembolism" OR "Prophylaxis of venous thromboembolism". The search results were combined with "Rheumatoid arthritis" using the Boolean search operator AND.

The authors carried out an initial screening of all titles and abstracts retrieved from the search. Articles were eligible for full text assessment if they reported original data on RA patients that had undergone THA and TKA, and reported information on the thromboprophylaxis performed, the rate of VTE and bleeding complications.

Studies pertaining anticoagulation, DVT, pulmonary embolism (PE) or thromboembolic diseases in RA pa-

tients having major orthopedic surgery were included. Articles were excluded if they were not in English. Case reports were also excluded. To ensure that the research was thorough, the reference lists of each article were also reviewed for other potentially eligible studies. Data were extracted from each article using a self-composed form to extract the following: (1) number of RA patients; (2) type of surgical procedure; (3) method of prophylaxis; (4) method of surveillance used; (5) the incidence of DVT; (6) the incidence of PE; and (7) incidence of bleeding complications. A meta-analysis was carried out entering only those studies that provided the event rate both in patients with RA and controls. For this purpose MEDCALC software (version 10.0.1.0) was used computing both fixed and random model. Pooled results are reported as odds ratio (OR) and 95%CI. A probability value of 0.05 or less was considered statistically significant. Statistical heterogeneity was evaluated using the  $I^2$  statistic which assess the appropriateness of pooling the individual study results. The  $I^2$  value provides the estimate of the amount of variance across studies due to heterogeneity rather than chance.

## STUDY IDENTIFICATION AND SELECTION

A total of 1178 titles were found through the electronic search on PubMed. After deleting duplicates and screening titles and abstracts, 1120 articles were excluded leaving 58 articles for full-paper review. Review of references revealed 2 further articles. After a detailed full-paper review, another 52 were excluded. A total of 8 articles<sup>[5-12]</sup> satisfied most of the inclusion criteria for data extraction after full review (Figure 1): Seven observational cohort studies, and 1 randomized clinical trial. Of the 8 studies, 7 were retrospective, 1 was prospective.

## STUDY CHARACTERISTICS

Characteristics and extracted data of the studies are summarized in Table 1. A total of 8886 RA patients were included in our review. The agents for prophylaxis were: Nadroparine<sup>[5]</sup>, low doses of unfractionated heparin<sup>[6]</sup>, Aspirin<sup>[7]</sup>, Acenocumarol<sup>[8]</sup> and mechanical prophylaxes<sup>[10]</sup>.

As can be observed in table 1, only 3 studies satisfied all the inclusion criteria<sup>[5,6,8]</sup>. In the other studies there were several bias: the prophylaxis utilized was not reported in 3 studies, the duration of prophylaxis was not indicated in 3, the method of surveillance for the diagnosis of VTE was not reported in 3, and the incidence of bleeding complications was not reported in 4 studies.

### Rate of VTE

A total of 4 studies which reported the incidence of VTE in RA patients and controls (mainly patients with Osteoarthritis) undergoing orthopedic surgery were identified<sup>[6,7,9,10]</sup> and included in the meta-analysis. Three studies were excluded from the meta-analysis since the

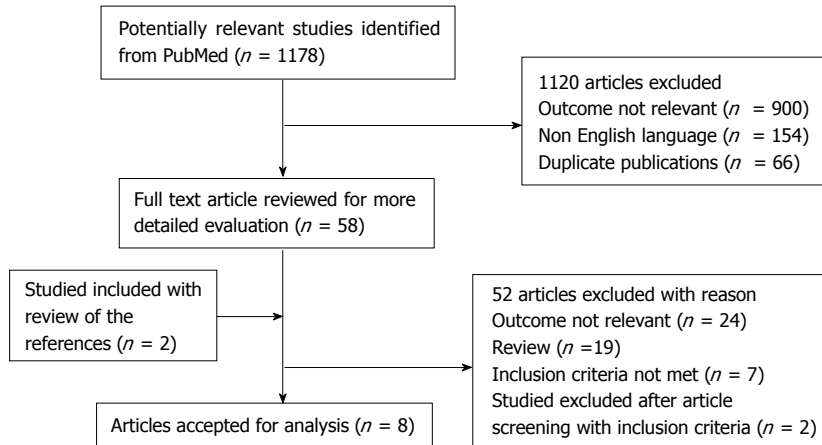


Figure 1 Flow diagram of study selection and information through different phases of the systematic review.

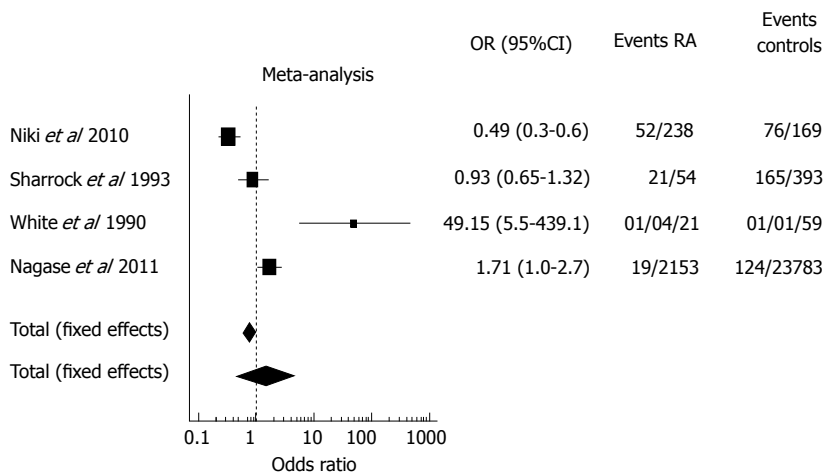


Figure 2 Forrest plots of the rate of venous thromboembolism in rheumatoid arthritis patients and controls underwent major orthopaedics surgery, according to a random and fixed-effects model.

rate of VTE in RA patients was not reported. Another study was excluded because the incidence of VTE in both the RA group and controls was expressed only as Odds Ratio. The final results of the meta-analysis are shown in Figure 2: the OR calculated with both the fixed and the random effect models shows no difference between AR patients and controls in terms of VTE rates. The random effect analysis shows a wider variance between the studies as expected. This data is confirmed by the great heterogeneity found among the studies ( $I^2 = 92.1$ ). Consequent forest plot is also shown to depict the overall rate of the frequency of VTE in RA and controls undergoing orthopedic surgery.

### Bleeding complications

Since bleeding events that occurred both in the AR group and controls were reported in only two studies it was decided not to perform meta-analysis. Niki *et al*<sup>[6]</sup> reported similar figures of bleeding in both groups: 1/238 (0.42 %) in AR patients and 2/169 (1.1 %) ( $P = 0.57$ ) in the controls while in the study of White *et al*<sup>[9]</sup> bleeding events were 30/721 (4.2 %) in RA patients and 345/8859 (3.9 %) ( $P = 0.68$ ) in controls (OA patients). van Heer-evelde *et al*<sup>[5]</sup> reported a bleeding event in 20/151 (13.2 %) AR patients, Swierstra *et al*<sup>[8]</sup> reported 2 bleeding episodes in 14 patients with AR but secondary to anti-vitamin K overdose. In the other studies no data on bleeding were

reported.

## DISCUSSION

On the basis of the results obtained from this review we tried to answer some questions with the aim to confer a practical approach to this topic.

### Do patients with RA that undergo major orthopedic surgery encounter a higher incidence of DVT than other patient groups?

Historically the rate of DVT or PE after major orthopedic surgery was estimated to be 40% to 84% in patients undergoing total knee arthroplasty (TKA)<sup>[13,14]</sup> and in 45% to 57% of those undergoing total hip arthroplasty (THA) in the absence of thromboprophylaxis. Proximal DVT in the absence of thromboprophylaxis has been reported to occur in 9% to 20% of TKA patients and in 23% to 36% of THA patients<sup>[12,15,16]</sup>. Currently with modern techniques and post-operative care, the estimated risk of developing a symptomatic VTE without prophylaxis is approximately 4.3%<sup>[1]</sup>. As for RA patients who underwent major orthopedic surgery, Abernethy and Kelly report a rate of DVT and PE of 70% and 50% respectively in the absence of prophylaxis<sup>[17,18]</sup>. The meta-analysis we have carried out involved only 4 studies for which the rate of VTE both in RA patients and controls were avail-

**Table 1 Summary of the 8 articles selected for inclusion in systematic review**

Ref.	Study design	Operation	RA patients	Methods of prophylaxis	Duration of prophylaxis	Methods of surveillance	VTE	EP	Bleeding complications
van Heereveld <i>et al</i> <sup>[5]</sup>	Retrospective open study of all medical record of patients with RA who underwent a Hip or Knee replacement from Jan 1987 to April 1995	THA and TKA	103 patients with RA who underwent 151 surgical procedure 55 (TKRH) 96 (THR)	Subcutaneous SH 5000 UI twice a day, starting two-six ours before surgery and was given twice a day, or nadroparin 7500 IC-U (10.000-20.00 IC U for obese patients) once a day. NSAIDs in 85% daily and continued after hospital discharge	For a minimum of 7 d and discontinued as soon as patient was adequately mobilized	Sonography, phlebography and V/Q scanning only in patients with clinical suspicion of VTE or PE The patients were seen every three months. the total of follow up was one year	1	0	20/151 (13%) Fifteen haematoma necessitating blood transfusion in six cases In one instance a surgical decompression was made. In none of bleeding episodes were signs of haemodynamic instability
Niki <i>et al</i> <sup>[6]</sup>	Prospective study of 333 patients who underwent primary TKA between October 2003 and June 2007 with diagnosis of RA and OA	TKA	199 (238 KNEES)	LOW dose unfractionated heparin (5000 U) for when patients had history of DVT or D-Dimer levels > 10 g/mL)	From second to eight day post-discharge	Sonography (pre-operatively and on POD 7), d-dimer on POD 0, 1 and 7	51	1	1
Sharrock <i>et al</i> <sup>[7]</sup>	Retrospective review of 571 primary TKA in epidural anesthesia between July 1986 to June 1990	TKA	54 RA	Aspirin (650 mg) and elastic streaking	5 d	Venography at forty and fifty post operative day	21 (39%)	Not reported	Not reported
Swiestra <i>et al</i> <sup>[8]</sup>	Retrospective randomized study of 101 consecutive patients admitted for primary THA	THA	14 RA	Acenocumarol started four or one day preoperatively aiming a thrombotest of 25% during the operation (1.5-1.6 INR)	Discontinuation of anticoagulation after negative venogram	Venography with 99mtc labeled macroaggregates of albumin, performed about 10 d after the operation for identifying proximal DVT	23/101	1 patient post-discharge	2 bleeding complication associated to excessively prolonged protrombine time
White <i>et al</i> <sup>[9]</sup>	Retrospective analysis of in hospitality mortality and morbidity of 721 RA vs 8859 OA patients who underwent a non emergent THR from 1984 to 1985	THA	721 RA	Not reported	Not reported	Not reported	0.3 % of VTE vs 1.2% in OA patients		4.20%
Nagase <i>et al</i> <sup>[10]</sup>	Retrospective analysis of 27542 patients who underwent THA or TKA in 723 japan hospital between 2007 and 2008	THA/TKA	2153 RA	Mechanical prophylaxis or mechanical prophylaxis and fondaparinux	Not reported	Not reported	19 (0.89%)		Not reported



Soohoo <i>et al</i> <sup>[11]</sup>	reviewed discharge data from 138399 patients undergoing primary THA in California from 1995 to 2005	THA	5565 RA	Not reported	Not reported	Not reported	OR = 1.46 (95%CI: 0.82-1.61; <i>P</i> = 0.2)	Not reported
Hull <i>et al</i> <sup>[12]</sup>	A randomized trial was performed in 310 consecutive patients undergoing total hip replacement between 1978 and 1986	THA	77 RA	Sequential calf and thigh intermittent compression was begun postoperatively in the recovery room compared with none prophylaxis	Intermittent compression was continued until the patient was discharged from the hospital or for 14 d, at which time most patients were fully ambulant	Leg scanning was performed on the first day after surgery and then daily for 14 d	None prophylaxis: 77/158 Intermittent leg pneumatic compression: 36/152	Not reported

VTE: Venous thromboembolism; RA: Rheumatoid arthritis; THA: Total hip arthroplasty; TKA: Total knee arthroplasty; POD: Postoperative days; OA: Osteoarthritis.

able. Results show no differences between these group of patients. However, a limitation of these results is the important heterogeneity among the studies documented by the very high value of  $I^2$ . On the basis of these results it is difficult to conclude that RA patients are different from other groups of patients in terms of thromboembolic risk. We therefore believe that RA patients should be given the same prophylactic approach recommended for orthopedic surgery. Another limitation of the meta-analysis we performed is the extremely different anti-thrombotic prophylaxis used in the 4 considered studies.

If other studies not included in the meta-analysis are considered, an indirect confirmation comes from Soohoo *et al*<sup>[11]</sup> who reviewed discharge data from 138399 patients undergoing primary THA in California from 1995 to 2005. Diagnosis of Rheumatoid arthritis was associated to an increase of complications at 90-d after surgery considered as a whole (mortality, infection, dislocation, revision, perioperative fracture, neurologic injury, and thromboembolic disease) compared with patients without RA (OR = 1.53, 95%CI: 1.23-1.91, *P* < 0.001). In particular, the risk is particularly increased for mortality at 90 d (OR = 1.88, 95%CI: 1.17-3.03, *P* = 0.01) but not for thromboembolism [OR = 1.46 (0.82-2.61, *P* = 0.20)]<sup>[11]</sup>.

Another study, not included in the meta-analysis because it dealt retrospectively only with RA patients, was that of van Heereveld *et al*<sup>[5]</sup> who found only one patient, in 151 surgical procedures, who developed symptoms of post-discharge VTE, despite the short duration of heparin administration (7 d). Interestingly, 85% of the RA patients used NSAIDs daily and thus they may have been protected, at least partially, from venous thromboembolism because of the anti-platelet activity of these drugs. However, this possible favorable effect was offset by a relatively high rate of bleeding complications (13%). In summary, the data show that in the presence of a prophylaxis the incidence of VTE in patients with RA is not only greater than other groups of comparison, but even

lower in some studies.

### **Is there a most effective method of VTE prophylaxis after major orthopedic surgery in RA patients?**

To our knowledge the data about the best prophylaxis to be used in RA patients are insufficient to conclude in favor of any of the several options available. Significantly, different rates of DVT following TKA were observed in different preoperative strategies. Maneuvers to reduce accumulation of blood in the deep vein of the limb during surgery or to dislodge adherent clot may be useful strategies to minimize deep vein thrombosis following TKA. Elevation of the leg after surgery and early ambulation may also contribute to lower deep vein thrombosis rates<sup>[5]</sup>. In 2012, the ACCP recommends the use of several drugs for antithrombotic prophylaxis in patients who undergo THA or TKA. These drugs range from heparins (unfractionated, LMWH and fondaparinux) to aspirin. VKA and the new oral anticoagulants (dabigatran, rivaroxaban and apixaban) are also considered. However this recommendation is referred to any anti-thrombotic drug in comparison to no anti-thrombotic prophylaxis. In a further recommendation, the ACCP suggests the use of LMWH, irrespective of the concomitant use of any pneumatic compression device (IPCD), in preference to the other drugs listed above. This choice could be explained by several factors (1) the favorable effect of aspirin is mild and is counterbalanced by the hemorrhagic risk conferred by this drug. Surprisingly we have read the recommendations of ACCP also on the use of aspirin in the thromboembolism prophylaxis after THA and TKA. It worth noting, however, that it was intended that the use of aspirin is to be considered better than nothing so that it is not certainly the drug of choice in that orthopedic setting<sup>[11]</sup>; (2) the difficulty in the peri-operative management of AVK; and (3) the similar efficacy of the new oral anticoagulants (NOAC) in comparison to LMWH, their longer half-life and the lack of post-marketing stud-

ies. In particular, NOAC (dabigatran, rivaroxaban and apixaban) show an increased risk for major bleeding<sup>[19]</sup> and a poor adherence<sup>[20]</sup>. Moreover, there is no data about both the safety and the efficacy of these drugs in patients with RA since the inclusion criteria of the clinical trials comparing NOAC with LMWH did not reflect the typical patient with RA who undergone major orthopedic surgery, that is a subject with several co-morbidities and that frequently use NSAID. Another point of concern may be the number of possible drug-interactions due to the metabolism of NOAC by the cytochrome P450 CYP 3A4 (rivaroxaban and apixaban) and the p-glycoprotein system (dabigatran, rivaroxaban and apixaban)<sup>[21]</sup>. These aspects may be not negligible when considering the Disease Modifying Antirheumatic Drugs (DMARDs) commonly utilized in the management of RA.

### **When should prophylaxis in RA patients be started?**

The historical data suggest that both pre and post-operative initiation of thromboprophylaxis are similar in terms of safety and efficacy. Meta-analysis or systematic review comparing pre- and post-operative initiation of therapy have found no consistent difference in efficacy and safety (bleeding rates) between the two strategies<sup>[22,23,24]</sup>. In many European countries LMWH is considered the standard therapy for prophylaxis following THA or TKA and is initiated pre-operatively to maximize its efficacy<sup>[24]</sup>. Preoperative thrombo-prophylaxis is initiated on the assumption that the surgery *per se* and the accompanying immobility are the main causes of thrombosis<sup>[22,25]</sup>. However, as most thrombi develop post-operatively, starting anticoagulant therapy following surgery could also prevent VTE<sup>[26]</sup>.

Since RA is a medical condition with increased risk of venous thrombotic events, the use of prophylaxis with heparin to prevent venous thrombosis should be administered even several days before surgery if the patient is bed ridden. In other words, if a patient with RA is immobilized and has been scheduled for surgery anti-thrombotic, prophylaxis should be started regardless of the waiting time for surgery. Immobilization *per se* may be related *per se* to disease activity and inflammation which in turn may induce a hypercoagulable state<sup>[27]</sup>.

### **DURATION OF PROPHYLAXIS**

Most VTE events occur after hospital discharge. Consequently, extended thromboprophylaxis after discharge should be considered and is particularly important after major surgery. The peak of DVT incidence is observed around the fifth postoperative day<sup>[28]</sup>. After the first post-operative week a second coagulation process occurs, as demonstrated by an increase of thrombin-antithrombin III complexes and D-dimer, markers of coagulation activation, which may persist for up to six weeks or longer<sup>[29]</sup>. This might be attributable to a relative immobilization of the patient after discharge.

In summary, RA patients should undergo physical therapy since physical activity is necessary to prevent dis-

abilities and restore functions, decrease pain and joint inflammation and increase ROM and strength. The early mobilization is the primary objective for the physician in order to assess the duration of prophylaxis. Anti-thrombotic prophylaxis should be last at least 5 wk as recommended by the ACCP but in RA patients a longer period of anti-thrombotic prophylaxis should be considered depending on recovery of mobility.

### **RISK OF BLEEDING DURING POST-DISCHARGE PROPHYLAXIS IN RA PATIENTS**

A delicate balance exists between VTE prophylaxis and systemic and surgical site of bleeding, which can lead to surgical wound complications including infection, haematoma and gastrointestinal bleeding. Many orthopedic surgeons fear the risk of bleeding associated with the introduction of anticoagulant prophylaxis for VTE prevention. Bleeding may occur earlier than VTE, and seriously compromise the result of surgery, or later as a complication of prophylaxis. A meta-analysis of 9 trials of extended duration (up 42 d) of VTE prophylaxes with LMWH after TKA or THA showed that there was no significant increase in major bleeding episodes despite the marked reductions in symptomatic VTE<sup>[30]</sup>. Only a small (1.2%) increase in minor bleeding was observed compared with patients receiving post-discharge placebo. In summary, in the single RA patient it is important to balance the bleeding risk against that of thromboembolism whilst keeping in mind that the latter represents a priority to be managed.

### **CONCLUSION**

RA patients who undergo major orthopedic surgery for joint destruction typically have severe disease. In these patients medical therapy has generally failed. In the absence of dedicated guidelines for the care of patients with RA undergoing orthopedic surgery, management must be individualized to obtain favorable patient outcome, weighing up all the factors that place the patient at the same time at a higher bleeding and thrombotic risk.

Ideally, preoperative evaluation by an orthopedic surgeon should start several weeks before elective surgery for an optimal management of thrombotic and bleeding risk of RA patients.

RA patients may be at increased risk of VTE due to active inflammatory disease, specific joint problems and the surgical procedures themselves. The presence of co-morbidities, as impaired renal function, cardiovascular and liver diseases and some drugs, especially NSAIDs should be carefully examined prior to starting thromboprophylaxis. Finally, RA patients should be treated as the other candidates for orthopedic surgery but special care should be paid to their comorbidities before and after surgery. Dedicated clinical trials should be planned to respond to the several still unanswered questions we have

tried to discuss here.

## ACKNOWLEDGMENTS

We thank Mr. Barry Mark Wheaton for his editing assistance.

## REFERENCES

- 1 **Falck-Ytter Y**, Francis CV, Johanson N, Curley C, Dahl O, Schulman S, Ortel T, Pauker S, Colwell Jr CW. Prevention of VTE in Orthopedic surgery patients. The Ninth ACCP Conference on Antithrombotic and Thrombolytic Therapy. *Chest* 2012; **141**: 278S–325S [DOI: 10.1378/chest.11-2404]
- 2 **Mameli A**, Barcellona D, Marongiu F. Rheumatoid arthritis and thrombosis. *Clin Exp Rheumatol* 2009; **27**: 846–855 [PMID: 19917173]
- 3 **Fox EA**, Kahn SR. The relationship between inflammation and venous thrombosis. A systematic review of clinical studies. *Thromb Haemost* 2005; **94**: 362–365 [PMID: 16113826]
- 4 **Chung WS**, Peng CL, Lin CL, Chang YJ, Chen YF, Chiang JY, Sung FC, Kao CH. Rheumatoid arthritis increases the risk of deep vein thrombosis and pulmonary thromboembolism: a nationwide cohort study. *Ann Rheum Dis* 2013 Aug 13; Epub ahead of print [PMID: 23926057 DOI: 10.1136/annrheumdis-2013-203380]
- 5 **van Heereveld HA**, Laan RF, van den Hoogen FH, Malefijt MC, Novakova IR, van de Putte LB. Prevention of symptomatic thrombosis with short term (low molecular weight) heparin in patients with rheumatoid arthritis after hip or knee replacement. *Ann Rheum Dis* 2001; **60**: 974–976 [PMID: 11557656 DOI: 10.1136/ard.60.10.974]
- 6 **Niki Y**, Matsumoto H, Hakozaiki A, Mochizuki T, Momohara S. Rheumatoid arthritis: a risk factor for deep venous thrombosis after total knee arthroplasty? Comparative study with osteoarthritis. *J Orthop Sci* 2010; **15**: 57–63 [PMID: 20151252 DOI: 10.1007/s00776-009-1410-3]
- 7 **Sharrock NE**, Hargett MJ, Urquhart B, Peterson MG, Ranawat C, Insall J, Windsor R. Factors affecting deep vein thrombosis rate following total knee arthroplasty under epidural anesthesia. *J Arthroplasty* 1993; **8**: 133–139 [PMID: 8478630 DOI: 10.1016/S0883-5403(06)80052-5]
- 8 **Swierstra BA**, Stibbe J, Schouten HJ. Prevention of thrombosis after hip arthroplasty. A prospective study of preoperative oral anticoagulants. *Acta Orthop Scand* 1988; **59**: 139–143 [PMID: 3364181]
- 9 **White RH**, McCurdy SA, Marder RA. Early morbidity after total hip replacement: rheumatoid arthritis versus osteoarthritis. *J Gen Intern Med* 1990; **5**: 304–309 [PMID: 2374042 DOI: 10.1007/BF02600396]
- 10 **Nagase Y**, Yasunaga H, Horiguchi H, Hashimoto H, Shoda N, Kadono Y, Matsuda S, Nakamura K, Tanaka S. Risk factors for pulmonary embolism and the effects of fondaparinux after total hip and knee arthroplasty: a retrospective observational study with use of a national database in Japan. *J Bone Joint Surg Am* 2011; **93**: e146 [PMID: 22258781 DOI: 10.2106/JBJS.J.01365]
- 11 **Soohoo NE**, Farnig E, Lieberman JR, Chambers L, Zingmond DS. Factors that predict short-term complication rates after total hip arthroplasty. *Clin Orthop Relat Res* 2010; **468**: 2363–2371 [PMID: 20428982 DOI: 10.1007/s11999-010-1354-0]
- 12 **Hull RD**, Raskob GE, Gent M, McLoughlin D, Julian D, Smith FC, Dale NI, Reed-Davis R, Lofthouse RN, Anderson C. Effectiveness of intermittent pneumatic leg compression for preventing deep vein thrombosis after total hip replacement. *JAMA* 1990; **263**: 2313–2317 [PMID: 2182917 DOI: 10.1001/jama.1990.03440170035032]
- 13 **Stulberg BN**, Insall JN, Williams GW, Ghelman B. Deep vein thrombosis following total knee replacement. An analysis of six hundred and thirty-eight arthroplasties. *J Bone Joint Surg Am* 1984; **66**: 194–201 [PMID: 6693445]
- 14 **Stringer MD**, Steadman CA, Hedges AR, Thomas EM, Morley TR, Kakkar VV. Deep vein thrombosis after elective knee surgery. An incidence study in 312 patients. *J Bone Joint Surg Br* 1989; **71**: 492–497 [PMID: 2785998]
- 15 **Lassen MR**, Borris LC, Christiansen HM, Boll KL, Eiskjaer SP, Nielsen BW, Schøtt P, Olsen AD, Rodenberg JC, Lucht U. Prevention of thromboembolism in 190 hip arthroplasties. Comparison of LMW heparin and placebo. *Acta Orthop Scand* 1991; **62**: 33–38 [PMID: 1848385 DOI: 10.3109/17453679108993088]
- 16 **Hoek JA**, Nurmohamed MT, Hamelynck KJ, Marti RK, Knipscheer HC, ten Cate H, Büller HR, Magnani HN, ten Cate JW. Prevention of deep vein thrombosis following total hip replacement by low molecular weight heparinoid. *Thromb Haemost* 1992; **67**: 28–32 [PMID: 1615479]
- 17 **Abernethy PJ**. Surgery of the rheumatoid knee. *Ann Rheum Dis* 1990; **49** Suppl 2: 830–836 [PMID: 2241298 DOI: 10.1136/ard.49.Suppl\_2.830]
- 18 **Kelly IG**. Surgical treatment of the rheumatoid hip. *Ann Rheum Dis* 1990; **49** Suppl 2: 858–862 [PMID: 2241302 DOI: 10.1136/ard.49.Suppl\_2.858]
- 19 **Adam SS**, McDuffie JR, Lachiewicz PF, Ortel TL, Williams JW. Comparative effectiveness of new oral anticoagulants and standard thromboprophylaxis in patients having total hip or knee replacement: a systematic review. *Ann Intern Med* 2013; **159**: 275–284 [PMID: 24026260 DOI: 10.7326/0003-4819-159-4-201308200-00008]
- 20 **Pengo V**, Crippa L, Falanga A, Finazzi G, Marongiu F, Palareti G, Poli D, Testa S, Tiraferri E, Tosetto A, Tripodi A, Manotti C. Questions and answers on the use of dabigatran and perspectives on the use of other new oral anticoagulants in patients with atrial fibrillation. A consensus document of the Italian Federation of Thrombosis Centers (FCSA). *Thromb Haemost* 2011; **106**: 868–876 [PMID: 21946939 DOI: 10.1160/TH11-05-0358]
- 21 **Scaglione F**. New oral anticoagulants: comparative pharmacology with vitamin K antagonists. *Clin Pharmacokinet* 2013; **52**: 69–82 [PMID: 23292752 DOI: 10.1007/s40262-012-0030-9]
- 22 **Strebel N**, Prins M, Agnelli G, Büller HR. Preoperative or postoperative start of prophylaxis for venous thromboembolism with low-molecular-weight heparin in elective hip surgery? *Arch Intern Med* 2002; **162**: 1451–1456 [PMID: 12090880 DOI: 10.1001/archinte.162.13.1451]
- 23 **Hull RD**, Pineo GF, MacIsaac S. Low-molecular-weight heparin prophylaxis: preoperative versus postoperative initiation in patients undergoing elective hip surgery. *Thromb Res* 2001; **101**: V155–V162 [PMID: 11342095 DOI: 10.1016/S0049-3848(00)00387-X]
- 24 **Hull RD**, Raskob GE. Venous thromboembolic disease. *Curr Opin Cardiol* 1991; **6**: 750–756 [PMID: 10150065 DOI: 10.1097/00001573-199110000-00014]
- 25 **Perka C**. Preoperative versus postoperative initiation of thromboprophylaxis following major orthopedic surgery: safety and efficacy of postoperative administration supported by recent trials of new oral anticoagulants. *Thromb J* 2011; **9**: 17 [PMID: 22087515 DOI: 10.1186/1477-9560-9-17]
- 26 **Bjørnara BT**, Gudmundsen TE, Dahl OE. Frequency and timing of clinical venous thromboembolism after major joint surgery. *J Bone Joint Surg Br* 2006; **88**: 386–391 [PMID: 16498018 DOI: 10.1302/0301-620X.88B3.17207]
- 27 **Pottier P**, Fouassier M, Hardouin JB, Volteau C, Planchon B. D-dimers, thrombin-antithrombin complexes, and risk factors for thromboembolism in hospitalized patient. *Clin Appl Thromb Hemost* 2009; **15**: 666–675 [PMID: 18796458 DOI: 10.1177/1076029608321436]
- 28 **Kakkar VV**. Low molecular weight heparins: prophylaxis of venous thromboembolism in surgical patients. *Semin Hema-*

- tol 1997; **34**: 9-19 [PMID: 9399405]
- 29 **Dahl OE**, Aspelin T, Arnesen H, Seljeflot I, Kierulf P, Ruyter R, Lyberg T. Increased activation of coagulation and formation of late deep venous thrombosis following discontinuation of thromboprophylaxis after hip replacement surgery. *Thromb Res* 1995; **80**: 299-306 [PMID: 8585042 DOI: 10.1016/0049-3848(95)00180-Y]
- 30 **Eikelboom JW**, Quinlan DJ, Douketis JD. Extended-duration prophylaxis against venous thromboembolism after total hip or knee replacement: a meta-analysis of the randomised trials. *Lancet* 2001; **358**: 9-15 [PMID: 11454370 DOI: 10.1016/S0140-6736(00)05249-1]

**P- Reviewer:** Undas A **S- Editor:** Song XX **L- Editor:** A  
**E- Editor:** Wu HL





## WJO 5<sup>th</sup> Anniversary Special Issues (10): Rheumatoid arthritis

# Inhibition of rheumatoid arthritis by blocking connective tissue growth factor

Kazuhisa Nozawa, Maki Fujishiro, Yoshinari Takasaki, Iwao Sekigawa

Kazuhisa Nozawa, Yoshinari Takasaki, Department of Rheumatology, School of Medicine, Juntendo University, Tokyo 113-8421, Japan

Maki Fujishiro, Iwao Sekigawa, Institute for Environment and Gender Specific Medicine, Juntendo University Graduate School of Medicine, Chiba 261-7114, Japan

Iwao Sekigawa, Department of Internal Medicine and Rheumatology, Juntendo University Urayasu Hospital, Chiba 261-7114, Japan

**Author contributions:** All authors contributed to this paper.  
**Supported by** Grant-in-Aid for Scientific Research (C), The Ministry of Education, Culture, Sports, Science and Technology and The Institute for Environment and Gender-specific Medicine, Juntendo University Graduate School of Medicine  
**Correspondence to:** Kazuhisa Nozawa, MD, PhD, Department of Rheumatology, School of Medicine, Juntendo University 2-1-1 Hongo, Bunkyo-ku, Tokyo 113-8421, Japan. [k-nozawa@juntendo.ac.jp](mailto:k-nozawa@juntendo.ac.jp)  
**Telephone:** +81-3-58021067 **Fax:** +81-3-58004893  
**Received:** December 26, 2013 **Revised:** April 14, 2014  
**Accepted:** July 17, 2014  
**Published online:** November 18, 2014

## Abstract

The pathogenesis of rheumatoid arthritis (RA) remains to be completely elucidated so far; however, it is known that proinflammatory cytokines play a pivotal role in the induction of RA. Tumor necrosis factor (TNF- $\alpha$ ), in particular, is considered to play a central role in bone destruction by mediating the abnormal activation of osteoclasts or the production of proteolytic enzymes through direct or indirect mechanisms. The use of TNF- $\alpha$  blocking agents has a significant impact on RA therapy. Anti-TNF- $\alpha$  blocking agents such as infliximab are very effective for treatment of RA, especially for the prevention of articular destruction. We have previously shown that several proteins exhibited extensive changes in their expression after amelioration of RA with infliximab treatment. Among the proteins, connective tissue growth factor (CTGF) has a significant

role for the development of RA. Herein, we review the function of CTGF in the pathogenesis of RA and discuss the possibility of a novel treatment for RA. We propose that CTGF is a potentially novel effector molecule in the pathogenesis of RA. Blocking the CTGF pathways by biological agents may have great beneficial effect in patients with RA.

© 2014 Baishideng Publishing Group Inc. All rights reserved.

**Key words:** Connective tissue growth factor; Rheumatoid arthritis; Osteoclasts; Chondrocytes; Tumor necrosis factor- $\alpha$

**Core tip:** Connective tissue growth factor (CTGF) plays an important role in the pathogenesis of rheumatoid arthritis (RA). We propose that CTGF is a potentially novel effector molecule in the pathogenesis of RA. Blocking the CTGF pathways by biological agents may have great beneficial effect in patients with RA.

Nozawa K, Fujishiro M, Takasaki Y, Sekigawa I. Inhibition of rheumatoid arthritis by blocking connective tissue growth factor. *World J Orthop* 2014; 5(5): 653-659 Available from: URL: <http://www.wjgnet.com/2218-5836/full/v5/i5/653.htm> DOI: <http://dx.doi.org/10.5312/wjo.v5.i5.653>

## INTRODUCTION

Rheumatoid arthritis (RA) causes chronic inflammation and consequently destruction of the articular tissue. Although the pathogenesis of RA are not fully understood, proinflammatory cytokines such as tumor necrosis factor (TNF)- $\alpha$  have been proposed as important factors in the pathogenesis of RA<sup>[1-4]</sup>. TNF- $\alpha$  is multiple functional cytokine. In addition to inflammatory process, TNF- $\alpha$  concerns various physiological phenomena in RA<sup>[5,6]</sup>. Moreover, accumulating reports suggest that TNF- $\alpha$

**Table 1** Proteins with greater changes after infliximab treatment<sup>[1]</sup>

	Molecular weight	pI	Accession#
Peptidylprolyl isomerase B precursor	23728	9.42	NP_000933
Caldesmon 1 isoform 1	93175	5.62	NP_149129
Family with sequence similarity 62 (C2 domain containing), member A	122780	5.57	NP_056107
Amylase, alpha 2A; pancreatic precursor	57670	6.60	NP_000690
Filamin 1 (actin-binding protein-280)	280586	5.73	NP_001447
Vasodilator-stimulated phosphoprotein isoform 1	39805	9.05	NP_003361
Cysteine and glycine-rich protein 1	20554	8.90	NP_004069
Myoglobin	17173	7.14	NP_005359
Transgelin 2	22377	8.41	NP_003555
Microtubule-associated protein, RP/EB family, member 1	29980	5.02	NP_036457
NCK adaptor protein isoform A	42889	6.49	NP_003572
Tropomodulin 3 (ubiquitous)	39570	5.08	NP_055362
Connective tissue growth factor	38043	8.36	NP_001892
Latent transforming growth factor beta binding protein 1 isoform	186716	5.63	NP_996826
Regenerating islet-derived 1 alpha precursor	18719	5.65	NP_002900
Peptidylprolyl isomerase A isoform 1	18001	7.68	NP_066953
Coronin, actin binding protein, 1C	53215	6.65	NP_055140
Triggering receptor expressed on myeloid cells-like 1	32658	5.70	NP_835468
Heparin sulfate proteoglycan 2	468528	6.06	NP_005520
Peptidoglycan recognition protein 1	21717	8.92	NP_005082
Superoxidase dismutase 1, soluble	15926	5.70	NP_000445

promotes bone destruction in RA, as excess TNF- $\alpha$  cause the abnormal osteoclast activation by direct or indirect interaction<sup>[2,3]</sup>. Our previous study used a novel approach of proteomic research and showed a significant profile change of serum protein biomarkers (approximately 20 proteins) in patients with RA treated using infliximab<sup>[1]</sup>. Among the proteins listed in our previous study, we found that connective tissue growth factor (CTGF) played an important role for the amelioration of RA<sup>[7-9]</sup> patients in infliximab treatment (Table 1). Based on this finding, we undertook subsequent studies to analyze the contribution of CTGF in the pathogenesis of RA and found that it plays an important role<sup>[8-10]</sup>. Herein, we review the function of CTGF in the pathogenesis of RA based on these findings. In RA, aberrant CTGF regulation may induce aberrant osteoclastogenesis and cause disturbance in cartilage homeostasis, subsequently resulting in articular tissue destruction. Blocking the CTGF pathways may be a novel effective strategy in the treatment of RA.

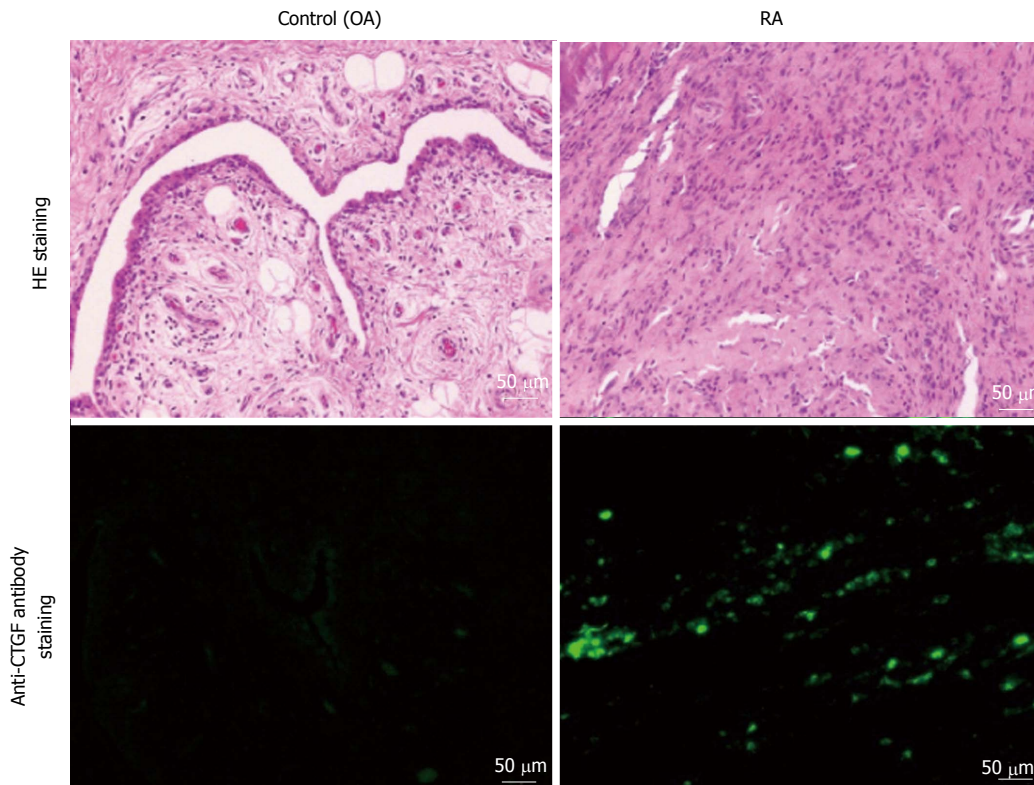
## CONNECTIVE TISSUE GROWTH FACTOR

CTGF was originally identified in human umbilical endothelial cell supernatants that exhibit platelet-derived growth factor (PDGF)-like chemotactic and mitogenic activities toward mesenchymal cells; the cDNA was isolated from a human vein endothelial cells (HU-VECs) cDNA expression library using anti-PDGF and it encoded a 349-amino acid protein<sup>[11]</sup>. CTGF belongs to the CCN protein family and is believed to be a downstream molecule of transforming growth factor (TGF)- $\beta$  pathway<sup>[12]</sup>. Although several candidate specific CTGF receptors have been currently proposed, they have not yet been completely identified to date. CTGF is associated with several biological functions such as fibrosis, tumori-

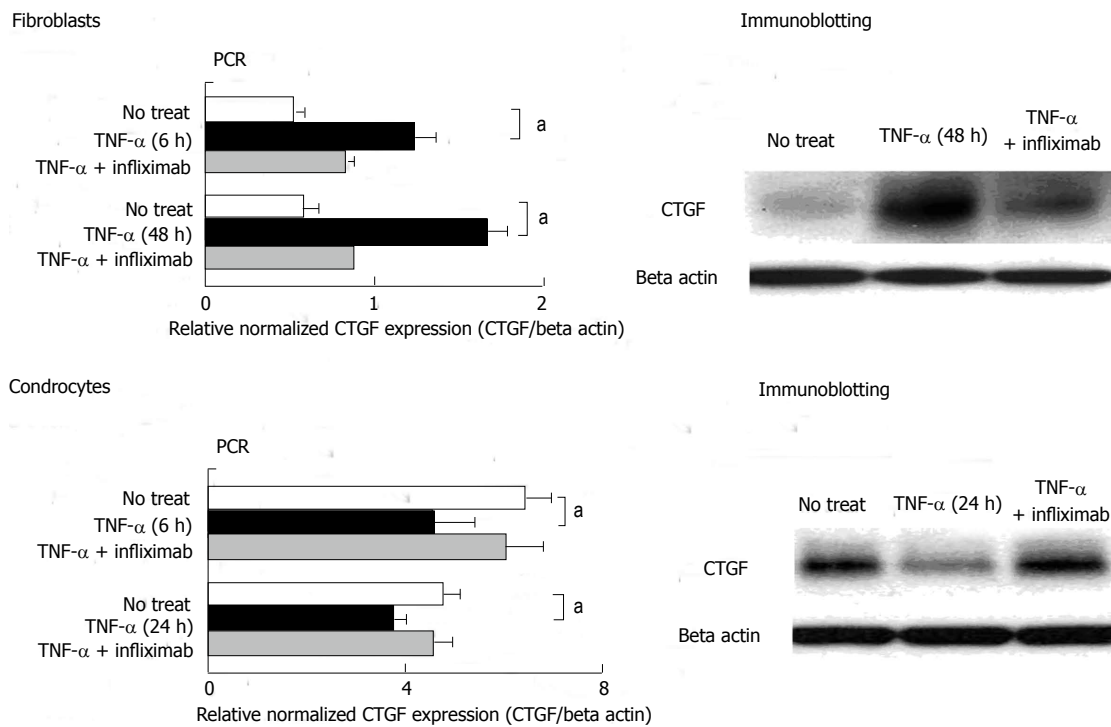
genesis, angiogenesis, and endochondral ossification<sup>[13]</sup>. CTGF in articular tissue, consisting different types of cells, is produced by chondrocytes and maintains cartilage tissue homeostasis *via* the autocrine process. Furthermore, incomplete knock-down of the CTGF gene dramatically inhibits osteoclast-like cell formation in mice, even though the complete knock-down mice exhibit embryonic lethality<sup>[14]</sup>.

## CONTRIBUTION OF CTGF TO THE PROGRESSION OF RA

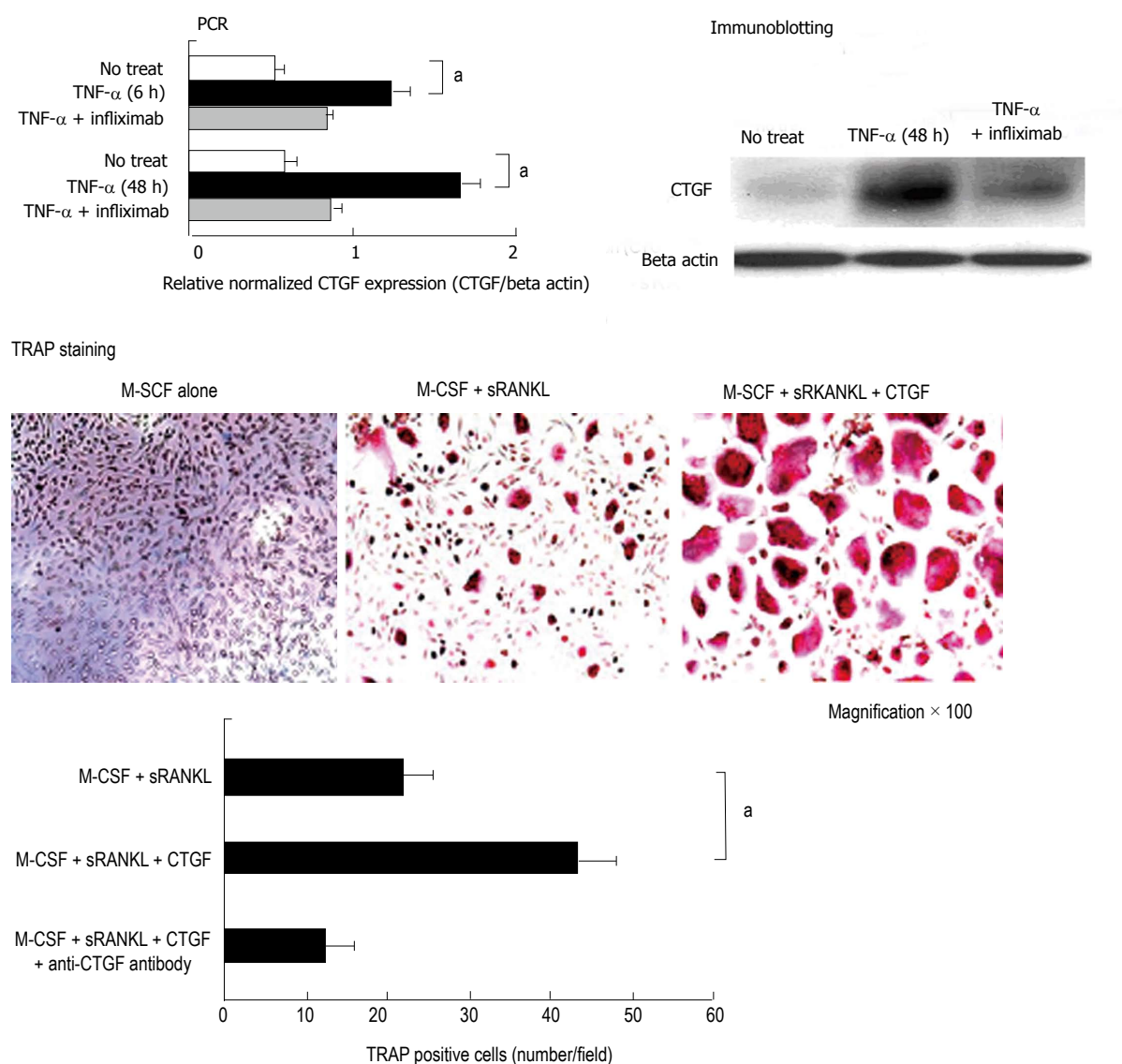
*In vivo* transfection with an adenovirus expression vector that encodes CTGF into mouse knee joints has been shown to cause cartilage damage due to an increase in mRNA coding for proteolytic enzymes such as matrix metalloproteinase (MMP)-3<sup>[15]</sup>. Manns *et al*<sup>[16]</sup> reported the up-regulation of CTGF in an experimental animal model of RA; treatment with a thrombospondin-1-derived peptide ameliorate the development of arthritis concomitant with the down-regulation of CTGF. These reports have indicated that CTGF has a significant role in the pathogenesis of RA. In addition, we observed the following interesting findings in our previous studies: (1) CTGF was overproduced by synovial fibroblasts in patients with RA (Figure 1); (2) the production of CTGF was regulated by TNF- $\alpha$ . CTGF production was up-regulated in synovial fibroblasts and down-regulated in chondrocytes (Figure 2); and (3) CTGF in combination with MCSF/RANKL promoted osteoclastogenesis (Figure 3)<sup>[8]</sup>. In the results of our study, we observed that TNF- $\alpha$  induced CTGF production by synovial cells. In contrast, TNF- $\alpha$  inhibited CTGF production by chondrocytes. TNF receptors have shown to transduce and amplify receptor activation resulting different cellular fates such as NF- $\kappa$ B activation or apoptosis. Although precise intracellular mechanisms



**Figure 1** Connective tissue growth factor expression was increased at synovial tissue in rheumatoid arthritis. Representative results of hematoxylin and eosin (HE) staining, immunofluorescence anti-connective tissue growth factor (CTGF) antibody staining, and anti-F4/80 antibody staining are shown using surgical samples from patients with rheumatoid arthritis (RA) and osteoarthritis (OA). The observed CTGF expression was stronger in the samples of patients with RA than in the samples of patients with OA.



**Figure 2** Tumor necrosis factor- $\alpha$  positively regulated connective tissue growth factor production in synovial fibroblasts and negatively regulated connective tissue growth factor production in chondrocytes. Connective tissue growth factor (CTGF) production from the human synovial fibroblasts cell line (MH7A) and the human chondrocytes cell line (OUMS-27) stimulated with/without tumor necrosis factor (TNF)- $\alpha$  were evaluated by immunoblotting and quantitative real time polymerase chain reaction (PCR). TNF- $\alpha$  promoted CTGF production by synovial fibroblasts and inhibited the production by chondrocytes. Statistical analysis (paired *t* test) was performed, and  $^aP < 0.05$  were considered to be statistically significant.  $^aP < 0.05$ , TNF- $\alpha$  vs no treat.



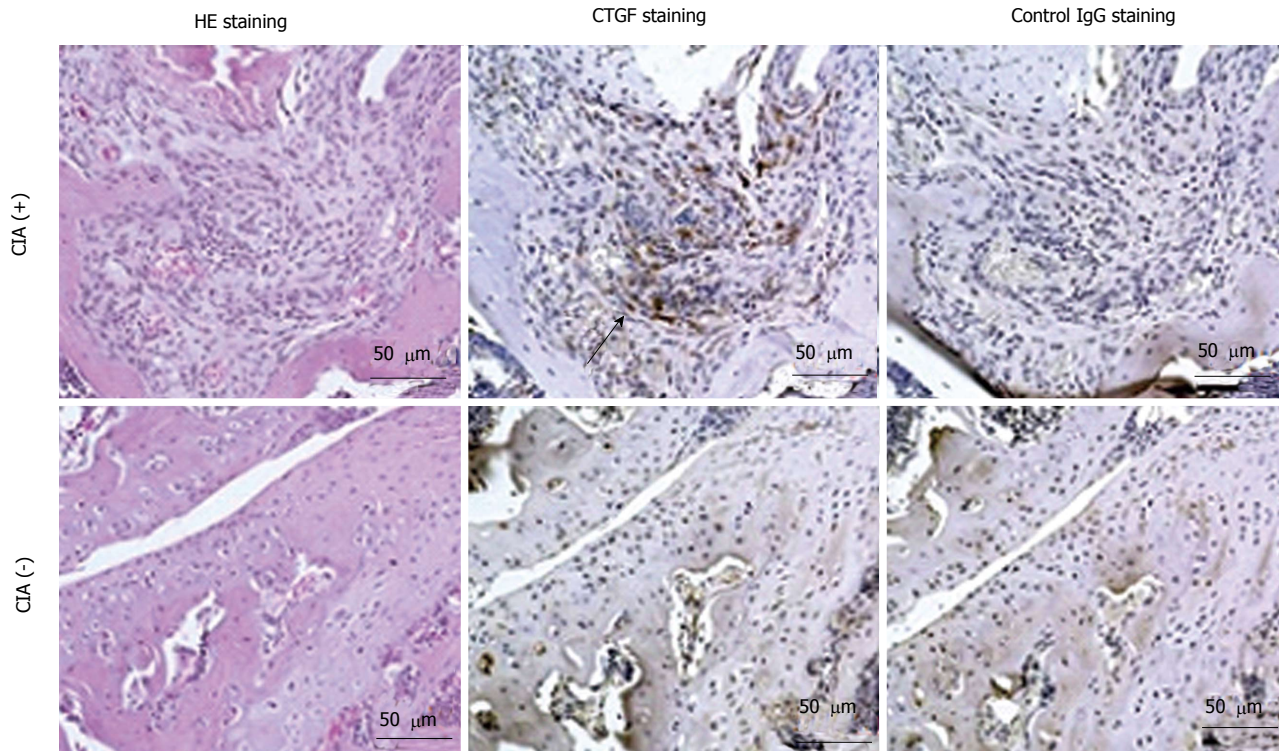
**Figure 3 Connective tissue growth factor enhanced macrophage-colony stimulating factor/receptor activator of nuclear factor kappa-B ligand mediated osteoclastogenesis.** Figure 3 Shows images of tartrate-resistant acidic phosphatase (TRAP) staining and the number of TRAP positive cells. For the evaluation of osteoclastogenesis, CD14<sup>+</sup> were purified from peripheral blood mononuclear cells of healthy volunteers to obtain osteoclastic progenitor cells. Osteoclasts were induced with macrophage-colony stimulating factor (M-CSF) and soluble receptor activator of nuclear factor kappa-B ligand (sRANKL) and the osteoclastogenesis was evaluated by TRAP staining. The TRAP positive cells were defined as osteoclasts. Connective tissue growth factor (CTGF) alone could not help in the differentiation of osteoclasts (data not shown). M-CSF/RANKL-mediated osteoclastogenesis was enhanced, which was detected by the production of CTGF by larger and higher number of osteoclasts; this enhancing effect was abolished by anti-CTGF antibody. The bars in Figure 2 indicate the standard deviation. Statistical analysis (paired *t* test) was performed, and *P* values  $< 0.05$  were considered to be statistically significant. <sup>a</sup>*P*  $< 0.05$ , M-CSF + sRANKL + CTGF vs M-CSF + sRANKL.

has not elucidated, previous studies have indicated that TNF- $\alpha$  increased or inhibited CTGF production depend on cell types. For example, TNF- $\alpha$  positively regulated CTGF production in mesangial cells<sup>[17]</sup>. On the other hand, TNF- $\alpha$  negatively regulated CTGF production in human lung endothelial cells<sup>[18]</sup>.

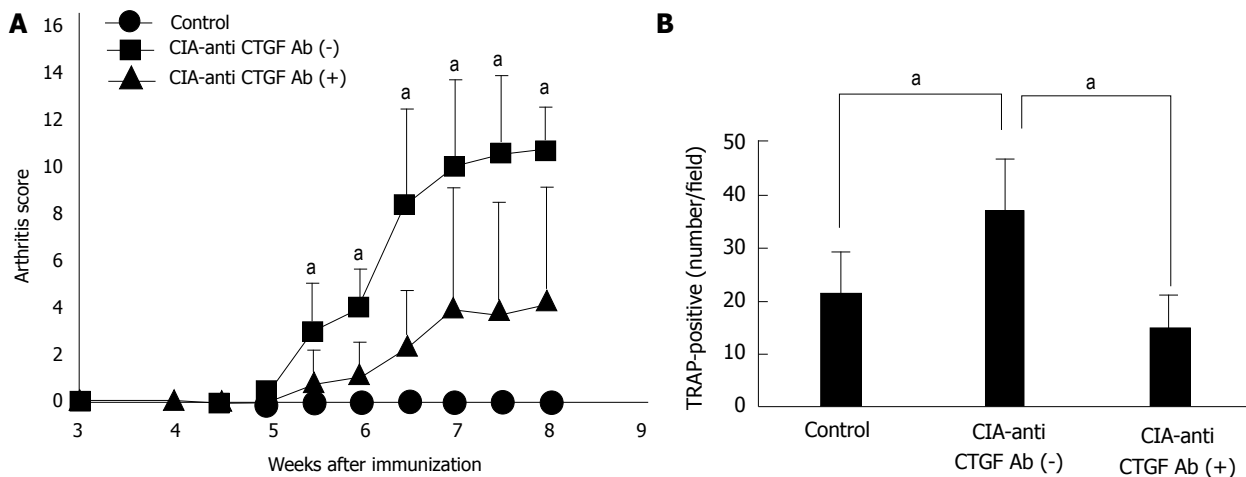
CTGF has been suggested to contribute to the homeostasis of cartilaginous tissue by autocrine process<sup>[14]</sup>. CTGF also may positively regulate proliferation of osteoblasts<sup>[14]</sup>. Therefore, CTGF may function as positive regulator functions for proliferation of chondrocytes and osteoblasts, consequently remaining the physiological articular tissue homeostasis. The disturbance of homeostasis due to impairment of CTGF production from chondrocytes possibly result in cartilage tissue damage in

RA. However, our data indicated that TNF- $\alpha$  was able to stimulate CTGF production in synovial fibroblasts. The excessive CTGF produced by synovial fibroblasts logically may function as protective factor for cartilage destruction in RA, because CTGF plays an important role for chondrogenesis. On the other hand, TNF- $\alpha$  has shown to induce catalytic enzymes production such as MMPs which cause cartilage destruction in synovial fibroblasts. Moreover, our data also indicated that TNF- $\alpha$  oppositely inhibited CTGF production in chondrocytes. In RA, TNF- $\alpha$  possibly functions as positive regulator for cartilage destruction through catalytic enzymes production or the inhibition of CTGF production in chondrocytes more efficiently rather than functions as negative regulator for cartilage destruction through increased CTGF produc-





**Figure 4** Increased *in vivo* expression of connective tissue growth factor at the articular tissue in collagen-induced arthritis mice. The collagen-induced arthritis (CIA) mice were sacrificed at 8 wk after immunization for immunohistochemical analysis. The immunohistochemical staining showed massive connective tissue growth factor (CTGF) expression in the articular tissue samples from CIA mice (indicated by arrow) using anti-CTGF antibody or control goat immunoglobulin G antibody. Serial sections of the articular tissue samples were also counterstained with hematoxylin/eosin (HE) for detection of the arthritis.

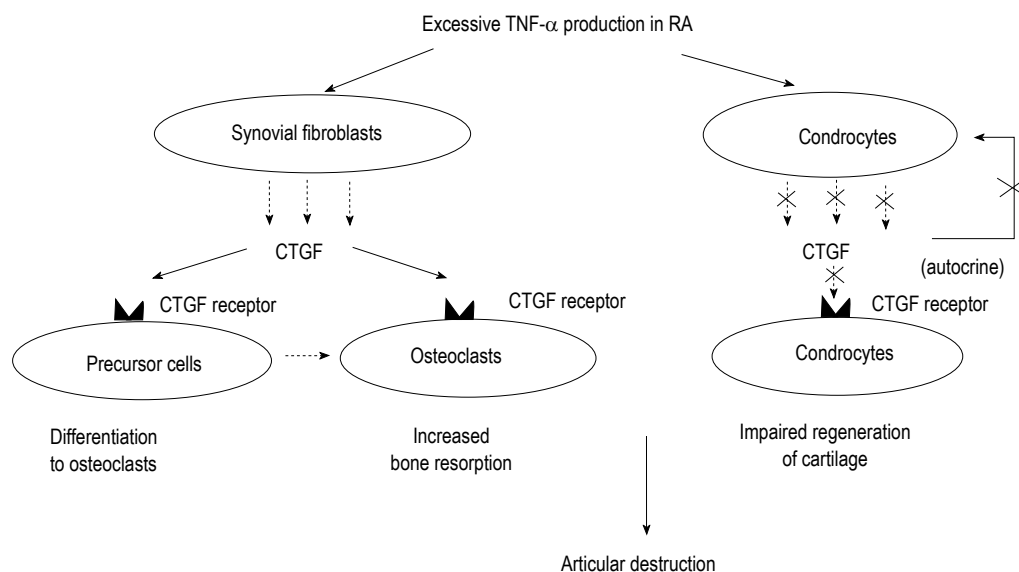


**Figure 5** Blocking connective tissue growth factor prevented the development of arthritis in collagen-induced arthritis mice. Mice with collagen-induced arthritis (CIA) were randomly selected and were intraperitoneally administered every week with anti-connective tissue growth factor (CTGF) monoclonal antibodies (mAbs) (white triangle; CIA-anti-CTGF Ab+) or control purified immunoglobulin (white square; CIA-anti-CTGF Ab-) from 1 wk before immunization to 6 weeks after immunization. Each group comprised 12 mice. The mice were monitored for arthritis every week and scored in a blinded manner (A). Blocking CTGF could efficiently prevent the development of CIA in mice. Bars in Figure 3 indicate the standard deviation. Statistical analysis (anti-CTGF Ab<sup>+</sup> vs anti-CTGF Ab<sup>-</sup>) was performed, and *P* values < 0.05 were considered to be statistically significant. <sup>a</sup>*P* < 0.05, CIA anti-CTGF Ab vs Control. For evaluation of osteoclastogenesis, CD14<sup>+</sup> osteoclastic progenitor cells were purified from splenocytes at 8 wk after immunization and osteoclasts were then induced with macrophage-colony stimulating factor (M-CSF) and soluble receptor activator of nuclear factor kappa-B ligand (sRANKL). Osteoclastogenesis was suppressed in mice with CIA treated using anti-CTGF mAb (B) compared to the non-treated mice. The bars in Figure 3 indicate the standard deviation. Statistical analysis was performed, and *P* values < 0.05 were considered to be statistically significant. <sup>a</sup>*P* < 0.05, CIA anti-CTGF Ab (-) vs Control; CIA anti-CTGF Ab (-) vs CIA anti-CTGF Ab (+).

tion in synovial fibroblasts. Taken together, excessive CTGF production by synovial fibroblasts regulated by TNF- $\alpha$  promotes aberrant activation of osteoclasts and

disturbs the homeostasis of cartilage tissue, ultimately resulting in articular distraction.

Next, we performed an *in vivo* study to clarify the



**Figure 6 Hypothesis of the role of connective tissue growth factor in the pathogenesis of rheumatoid arthritis.** Hypothesis of the possible role of connective tissue growth factor (CTGF) in the pathogenesis of rheumatoid arthritis (RA). TNF: Tumor necrosis factor.

pathological roles of CTGF in the arthritis development using a murine collagen-induced arthritis (CIA) model. A DBA/1J mice were immunized with a combination of type II collagen and complete Freund adjuvant (CFA) for induction of CIA. We confirmed *in vivo* CTGF expression was increased at the articular tissue in CIA mice as well as human patients with RA (Figure 4). Moreover, we evaluated the efficacy of the neutralizing anti-CTGF monoclonal antibody (mAb) in the prevention of CIA development in mice. We found that the neutralizing anti-CTGF mAb significantly ameliorated CIA in the treated mice (Figure 5A). In addition, aberrant osteoclastogenesis observed in the mice with CIA was reduced by anti-CTGF mAb treatment (Figure 5B). Our consecutive studies showed that blocking the production of CTGF prevented the progression of RA. Therefore, CTGF may be a new therapeutic target for the treatment of RA.

## CONCLUSION

We confirmed that CTGF is a novel effector molecule in the pathogenesis of RA. A schematic hypothesis of its role is presented in Figure 6. CTGF is a multiple functional cytokines and possess a several biological functions depend on the target cells. Although many candidate molecules on the cell surface have been suggested as specific CTGF receptors such as integrins, they have not been completely identified to date. Biological functions of CTGF may differ depend on its receptor as well as cell types. Although the mechanism of action and the importance of CTGF in contribution to the RA development are unclear, we showed that blocking the CTGF pathway could ameliorate CIA especially through the reduction of aberrant osteoclastogenesis. These data imply the possible mechanism underlying the efficacy of anti-CTGF antibody in the treatment with RA. Our study indicated

that CTGF is important factor in the development of RA. These results may shed light on the new therapeutic strategies for RA. Further precise studies that will provide clues to assist in the development of new treatment for RA as well as a deeper understanding of its etiology are required.

## REFERENCES

- 1 **Feldmann M**, Brennan FM, Maini RN. Role of cytokines in rheumatoid arthritis. *Annu Rev Immunol* 1996; **14**: 397-440 [PMID: 8717520 DOI: 10.1146/annurev.immunol.14.1.397]
- 2 **Fassbender HG**, Seibel M, Hebert T. Pathways of destruction in metacarpal and metatarsal joints of patients with rheumatoid arthritis. *Scand J Rheumatol* 1992; **21**: 10-16 [PMID: 1570480 DOI: 10.3109/03009749209095055]
- 3 **Raisz LG**. Pathogenesis of osteoporosis: concepts, conflicts, and prospects. *J Clin Invest* 2005; **115**: 3318-3325 [PMID: 16322775 DOI: 10.1172/JCI27071]
- 4 **Teitelbaum SL**. Osteoclasts: what do they do and how do they do it? *Am J Pathol* 2007; **170**: 427-435 [PMID: 17255310 DOI: 10.2353/ajpath.2007.060834]
- 5 **Maini RN**, Elliott MJ, Brennan FM, Williams RO, Chu CQ, Paleolog E, Charles PJ, Taylor PC, Feldmann M. Monoclonal anti-TNF alpha antibody as a probe of pathogenesis and therapy of rheumatoid disease. *Immunol Rev* 1995; **144**: 195-223 [PMID: 7590814 DOI: 10.1111/j.1600-065X.1995.tb00070.x]
- 6 **Redlich K**, Hayer S, Ricci R, David JP, Tohidast-Akrad M, Kollias G, Steiner G, Smolen JS, Wagner EF, Schett G. Osteoclasts are essential for TNF-alpha-mediated joint destruction. *J Clin Invest* 2002; **110**: 1419-1427 [PMID: 12438440 DOI: 10.1172/JCI0215582]
- 7 **Sekigawa I**, Yanagida M, Iwabuchi K, Kaneda K, Kaneko H, Takasaki Y, Jung G, Sone S, Tanaka Y, Ogawa H, Takamori K. Protein biomarker analysis by mass spectrometry in patients with rheumatoid arthritis receiving anti-tumor necrosis factor-alpha antibody therapy. *Clin Exp Rheumatol* 2008; **26**: 261-267 [PMID: 18565247]
- 8 **Nozawa K**, Fujishiro M, Kawasaki M, Kaneko H, Iwabuchi K, Yanagida M, Suzuki F, Miyazawa K, Takasaki Y, Ogawa H, Takamori K, Sekigawa I. Connective tissue growth factor promotes articular damage by increased osteoclastogenesis

- in patients with rheumatoid arthritis. *Arthritis Res Ther* 2009; **11**: R174 [PMID: 19922639 DOI: 10.1186/ar2863]
- 9 **Nozawa K**, Fujishiro M, Kawasaki M, Yamaguchi A, Ikeda K, Morimoto S, Iwabuchi K, Yanagida M, Ichinose S, Morioka M, Ogawa H, Takamori K, Takasaki Y, Sekigawa I. Inhibition of connective tissue growth factor ameliorates disease in a murine model of rheumatoid arthritis. *Arthritis Rheum* 2013; **65**: 1477-1486 [PMID: 23436223]
  - 10 **Fujishiro M**, Yamaguchi A, Kawasaki M, Nozawa K, Takasaki Y, Takamori K, Ogawa H, Endo K, Ng PS, Takehara K, Sekigawa I. The detection of plasma levels of connective tissue growth factor in rheumatoid arthritis patients. *Clin Exp Rheumatol* 2012; **30**: 145-146 [PMID: 22244584]
  - 11 **Bradham DM**, Igarashi A, Potter RL, Grotendorst GR. Connective tissue growth factor: a cysteine-rich mitogen secreted by human vascular endothelial cells is related to the SRC-induced immediate early gene product CEF-10. *J Cell Biol* 1991; **114**: 1285-1294 [PMID: 1654338 DOI: 10.1083/jcb.114.6.1285]
  - 12 **Grotendorst GR**. Connective tissue growth factor: a mediator of TGF-beta action on fibroblasts. *Cytokine Growth Factor Rev* 1997; **8**: 171-179 [PMID: 94622483 DOI: 10.1016/S1359-6101(97)00010-5]
  - 13 **Perbal B**. CCN proteins: multifunctional signalling regulators. *Lancet* 2004; **363**: 62-64 [PMID: 14723997 DOI: 10.1016/S0140-6736(03)15172-0]
  - 14 **Takigawa M**, Nakanishi T, Kubota S, Nishida T. Role of CTGF/HCS24/ecogenin in skeletal growth control. *J Cell Physiol* 2003; **194**: 256-266 [PMID: 12548546 DOI: 10.1002/jcp.10206]
  - 15 **Blaney Davidson EN**, Vitters EL, Mooren FM, Oliver N, Berg WB, van der Kraan PM. Connective tissue growth factor/CCN2 overexpression in mouse synovial lining results in transient fibrosis and cartilage damage. *Arthritis Rheum* 2006; **54**: 1653-1661 [PMID: 16646035 DOI: 10.1002/art.21795]
  - 16 **Manns JM**, Uknis AB, Rico MC, Agelan A, Castaneda J, Arango I, Barbe MF, Safadi FF, Popoff SN, DeLa Cadena RA. A peptide from thrombospondin 1 modulates experimental erosive arthritis by regulating connective tissue growth factor. *Arthritis Rheum* 2006; **54**: 2415-2422 [PMID: 16869004 DOI: 10.1002/art.22021]
  - 17 **Cooker LA**, Peterson D, Rambow J, Riser ML, Riser RE, Najmabadi F, Brigstock D, Riser BL. TNF-alpha, but not IFN-gamma, regulates CCN2 (CTGF), collagen type I, and proliferation in mesangial cells: possible roles in the progression of renal fibrosis. *Am J Physiol Renal Physiol* 2007; **293**: F157-F165 [PMID: 17376761 DOI: 10.1152/ajprenal.00508.2006]
  - 18 **Laug R**, Fehrholz M, Schütze N, Kramer BW, Krump-Konvalinkova V, Speer CP, Kunzmann S. IFN-γ and TNF-α synergize to inhibit CTGF expression in human lung endothelial cells. *PLoS One* 2012; **7**: e45430 [PMID: 23029004 DOI: 10.1371/journal.pone.0045430]

**P- Reviewer:** Andonopoulos AP, Saviola G **S- Editor:** Ji FF

**L- Editor:** A **E- Editor:** Wu HL



## Metallic debris from metal-on-metal total hip arthroplasty regulates periprosthetic tissues

Christoph H Lohmann, Gurpal Singh, Hans-Georg Willert, Gottfried H Buchhorn

Christoph H Lohmann, Gurpal Singh, Department of Orthopaedic Surgery, Otto-von-Guericke University, 39120 Magdeburg, Germany

Gurpal Singh, University Orthopaedics, Hand and Reconstructive Microsurgery Cluster, National University Health System, Singapore 119228, Singapore

Hans-Georg Willert, Gottfried H Buchhorn, Department of Orthopaedics, University Hospital Goettingen, 37075 Göttingen, Germany

Author contributions: Lohmann CH, Singh G, Willert HG and Buchhorn GH contributed to the study design, literature review, preparation and editing of this manuscript.

Correspondence to: Christoph H Lohmann, MD, Department of Orthopaedic Surgery, Otto-von-Guericke University, Leipziger Strasse 44, 39120 Magdeburg,

Germany. [christoph.lohmann@med.ovgu.de](mailto:christoph.lohmann@med.ovgu.de)

Telephone: +49-391-6714000 Fax: +49-391-6713840

Received: December 28, 2013 Revised: June 20, 2014

Accepted: July 12, 2014

Published online: November 18, 2014

### Abstract

The era of metal-on-metal (MoM) total hip arthroplasty has left the orthopaedic community with valuable insights and lessons on periprosthetic tissue reactions to metallic debris. Various terms have been used to describe the tissue reactions. Sometimes the nomenclature can be confusing. We present a review of the concepts introduced by Willert and Semlitsch in 1977, along with further developments made in the understanding of periprosthetic tissue reactions to metallic debris. We propose that periprosthetic tissue reactions be thought of as (1) gross (metallosis, necrosis, cyst formation and pseudotumour); (2) histological (macrophage-dominated, lymphocyte-dominated or mixed); and (3) molecular (expression of inflammatory mediators and cytokines such as interleukin-6 and tumor necrosis factor- $\alpha$ ). Taper corrosion and modularity are discussed, along with future research directions to elucidate the antigen-presenting pathways and materi-

al-specific biomarkers which may allow early detection and intervention in a patient with adverse periprosthetic tissue reactions to metal wear debris.

© 2014 Baishideng Publishing Group Inc. All rights reserved.

**Key words:** Periprosthetic tissue response; Metal-on-Metal; Total hip arthroplasty; Metal debris; Lymphocyte-dominated; Macrophage-dominated; Taper corrosion; Modularity

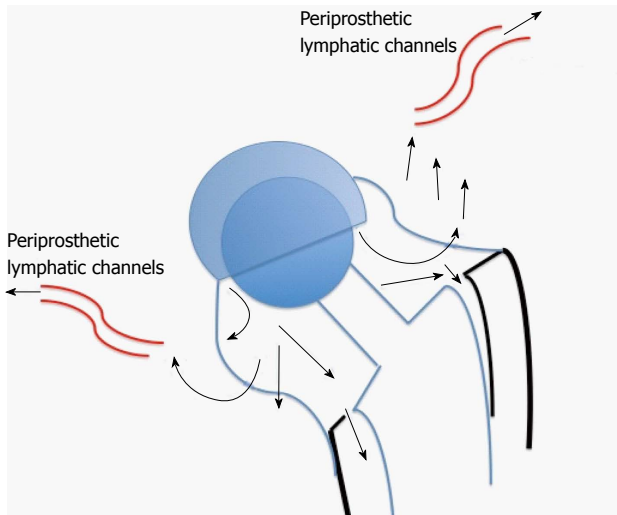
**Core tip:** Valuable lessons have been learnt from the era of metal-on-metal total hip arthroplasty. We present a review of the concepts introduced by Willert and Semlitsch in 1977, along with further developments made in the understanding of periprosthetic tissue reactions to metallic debris. We propose that periprosthetic tissue reactions be thought of as (1) gross (metallosis, necrosis, cyst formation and pseudotumour); (2) histological (macrophage-dominated, lymphocyte-dominated or mixed); and (3) molecular (expression of inflammatory mediators and cytokines such as interleukin-6 and tumor necrosis factor- $\alpha$ ). Taper corrosion and modularity is discussed, along with future research directions in this area.

Lohmann CH, Singh G, Willert HG, Buchhorn GH. Metallic debris from metal-on-metal total hip arthroplasty regulates periprosthetic tissues. *World J Orthop* 2014; 5(5): 660-666 Available from: URL: <http://www.wjgnet.com/2218-5836/full/v5/i5/660.htm> DOI: <http://dx.doi.org/10.5312/wjo.v5.i5.660>

### INTRODUCTION

Retrieval studies on failed metal-on-metal (MoM) total hip arthroplasties (THAs) have contributed significantly to the understanding of adverse local tissue reactions to metallic debris. The McKee Farrar and Ring implants



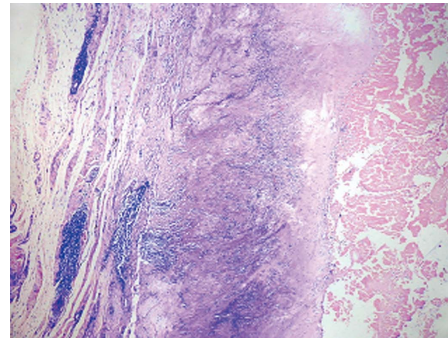


**Figure 1** The Willert-Semlitsch concept of clearance of wear debris by periprosthetic lymph channels. If production of wear debris exceeds the ability of the lymph channels to clear it, the debris then “spills” over into the effective joint space and initiates osteolytic pathways.

used in the 1960s had MoM bearing surfaces<sup>[1-3]</sup>. Weber introduced the first second-generation MoM THA (cobalt-chrome alloy with a high carbon content) in 1988<sup>[4]</sup>. The success of large-diameter hip surface replacement further popularized MoM hip replacements<sup>[5-8]</sup>. Large-diameter MoM heads (36 mm diameter or larger), started being used in revision hip surgery and were later used in primary THAs. Registry data suggest that MoM devices have been implanted into over 60000 patients in England and Wales since 2003 and the figure is closer to a million in the United States<sup>[9,10]</sup>.

Metal wear products in periprosthetic tissue may exist as particulate wear debris, metal ions in solution, metallo-protein complexes and byproducts of synergistic corrosion and wear processes (especially when modular interfaces are involved)<sup>[11,12]</sup>. Proteins present in body fluids and tissue can associate with metal particulate debris especially those in the nanoscale range. These complexes can form haptens and there may exist interindividual variability in immunological threshold and response to these antigens<sup>[13,14]</sup>. Corrosion and wear at modular interfaces *i.e.*, head-neck and neck-stem junction can contribute to the overall particle load<sup>[15-21]</sup>.

Taper corrosion has also been recognized in metal-on-polyethylene THAs<sup>[19,21,22]</sup>. Kurtz and colleagues has studied a hundred femoral head-stem pairs. They have reported that by using a ceramic femoral head, cobalt and chrome fretting and corrosion from the modular head-neck taper can be decreased partially but it is difficult to eliminate it completely<sup>[23]</sup>. Metal particulate debris tends to be in the nanometre size range and MOM articulations generate approximately  $10^{12}$ - $10^{14}$  particles per year<sup>[24]</sup>. Difficulties associated in isolating and characterizing these small nanometric particles suggest that the actual number of particles produced *in vivo* may be higher, taking into account also that intracellular corrosion of phagocytosed

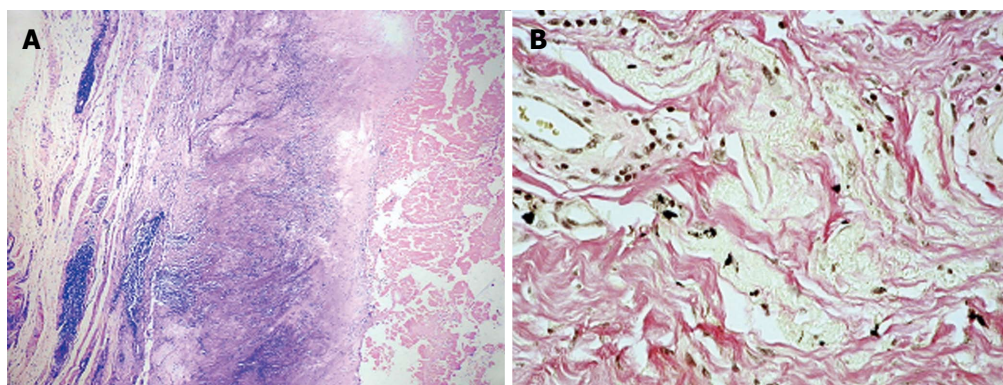


**Figure 2** Plain radiograph showing early, progressive osteolysis in response to metallic wear debris.

nanometric metal particles may occur<sup>[25,26]</sup>.

## TISSUE REACTIONS TO WEAR PRODUCTS

Willert *et al.*<sup>[27]</sup> in 1977, described the tissue reactions of the articular capsule to wear products of artificial joint prostheses. In their landmark article, they reported the development of a foreign-body reaction (consisting of macrophages and foreign-body giant cells) to wear debris. This foreign-body reaction takes place in the neocapsule and, depending on its magnitude, may lead to the formation of granulation tissue, which may subsequently cause scarring and decrease joint mobility. They went on to discuss the concept of an “equilibrium state”, which is achieved when the periprosthetic lymph vessels are effectively clearing the wear debris at the rate of debris production (Figure 1). If the periprosthetic lymph channels are overwhelmed, excess wear debris then spills over via the surrounding tissue into the implant-bone interface, mainly trabecular bone and marrow. Additionally, effusions into the joint space become enriched with wear products. The increase of intracapsular pressure due to muscular activity and compression not only increases local bone resorption<sup>[28]</sup> but also introduces dissociation of the interface membranes and implant surfaces. We now know this as the “effective joint space” as described by Schmalzried and colleagues in 1992<sup>[29]</sup>. Joint fluid helps to transport wear particles to new sites, resulting in activation of osteoclasts and inhibition of osteoblasts *via* molecular signaling pathways involving a host of inflammatory mediators. This phenomenon has also been called “particle disease”<sup>[30,31]</sup>. The “threshold” of the periprosthetic lymphatics to effectively clear wear debris is subject to interindividual variability as well as on the volume of wear (*e.g.*, high rates of UHMWPE wear). This phenomenon may partially explain why some people develop adverse tissue reactions and early osteolysis (Figure 2) in response to metal debris whilst others seem to have a mild or no reaction, assuming all other factors being equal. Since then, research efforts have focused on the types of tissue reactions, immunological and molecular pathways



**Figure 3 Pathologic figure.** A: Diffuse and perivascular lymphocytic infiltration (lymphocyte-dominated tissue response) seen in retrieved periprosthetic tissues from small-diameter metal-on-metal (MoM) total hip arthroplasties (THAs). Haematoxylin-eosin, magnification,  $\times 10$ ; B: Intracellular metal particles seen in retrieval tissues from large-diameter MoM THA. These particles may undergo intracellular corrosion. Haematoxylin-eosin, magnification,  $\times 40$ .

involved. These pathways are still not well-understood, though some light has been shed on the types of tissue reactions to particulate wear debris.

## ADVERSE TISSUE REACTIONS IN MOM THAS

Adverse tissue reactions may be systemic or local. Higher serum and solid organ metal ion levels may theoretically have carcinogenic and teratogenic potential. Various terms have been coined to describe the adverse local tissue reactions seen in MoM THA and the nomenclature is debatable. Essentially, adverse local tissue reaction (ALTR) encompasses all types of adverse local tissue reactions to debris, whereas adverse reaction to metallic debris (ARMD) and aseptic lymphocyte-dominated vasculitis-associated lesion (ALVAL) represent more specific descriptions. For clarity of thought, it may be useful to think about local periprosthetic tissue reactions at the gross, histological and molecular levels.

## GROSS TISSUE REACTIONS

Gross intraoperative findings in revision operations for failed aseptic metal-metal hip replacements range from metallosis, large joint effusions, necrosis and pseudotumours<sup>[32-46]</sup>. “Metallosis” comprises local damage and changes in tissue characteristics provoked by a metallic foreign body in the host with (1) direct (by pressure, destruction or displacement of tissues); (2) collateral (by chemical reactions with body fluids, electrolytic processes with direct galvanic impairment of cellular activity and impregnation of host tissue with ionizing metallic particulate matter; and (3) the resulting biologic reactions of the adjacent tissues<sup>[47]</sup>. A pseudotumour is defined as a granulomatous lesion or a destructive cystic lesion, neither infective nor neoplastic, that is at least 5 cm in size, has developed in the vicinity of the total joint replacement (with or without communication with the joint), and resembles a tumour<sup>[48]</sup>.

## HISTOLOGY: MACROPHAGE-DOMINATED AND LYMPHOCYTE-DOMINATED REACTIONS

Histologically, to avoid confusion associated with the nomenclature, we differentiate the predominant cellular responses into a macrophage-dominated type and a lymphocyte-dominated type. Other features which may be seen are fibrin exudation and necrosis. The lymphocyte based tissue response differs from macrophage dominated tissue response as the former is adaptive and displays “memory”. The lymphocyte dominated tissue response may resemble a type IV delayed hypersensitivity reaction. This type of tissue reaction can lead to development of early aseptic loosening and progressive osteolysis in patients with MoM total hip arthroplasty. This phenomenon may also be seen in the context of corrosion and wear at modular interfaces in non-MoM THA<sup>[49-54]</sup>. The two responses may co-exist and research efforts are being channeled into identifying the factors which are responsible for the predominant type of tissue response.

We analyzed tissue response, serum and periprosthetic tissue metal content among a cohort of 28 small-diameter MoM THAs and found that the overall metal content in the periprosthetic tissues correlated with type of tissue response. Serum metal content did not predict type of tissue response (Table 1)<sup>[54]</sup>.

Twenty-seven patients (28 hips) who were revised from second-generation small-diameter MoM bearing couples (Sikomet®, 0.08% carbon content) to ceramic-on-ultra high molecular weight polyethylene (UHMWPE) (8 hips), metal-on-UHMWPE- (19 hips), or ceramic-on-ceramic (1 hip). The duration of implantation was 54 to 86 mo with a mean of 66 mo. The Cobalt, Chromium, and Nickel content of the periprosthetic tissue was in the range of 1.4 to 4604.0  $\mu\text{g/g}$ . The tissues with a dominant lymphocytic response had a higher mean metal content as compared to macrophage dominant response *i.e.*,  $222.2 \pm 52.9 \mu\text{g/g}$  and  $3.0 \pm 0.9 \mu\text{g/g}$  respectively ( $P = 0.001$ ). The content of nickel in the tissue was similar in both groups but the

**Table 1** Tissue metal content, but not serum metal content has a positive correlation with type of periprosthetic tissue response in a series of 28 small diameter metal-on-metal total hip arthroplasties

	Cobalt, mg/L	Chrome, mg/L	Nickel, mg/L
Tissue metal content			
Macrophage-dominated	17.25	21	22.5
Lymphocyte-dominated	13.41	21.92	8.41
Serum metal content			
Macrophage-dominated	0.3	2	0.6
Lymphocyte-dominated	45.2	163.6	1.6

amount of cobalt was approximately hundred and fifty times higher in the lymphocyte-dominant group. Figure 3 illustrates the typical lymphocyte-dominated tissue response seen in a small-diameter MoM THA and phagocytosed intracellular metal particles from retrieved tissues in large diameter MoM THA.

Head size may be another factor which drives the predominant type of tissue response in one direction or another. Bosker *et al*<sup>[55]</sup> has described that the MoM hip replacements with large heads had higher rates of pseudotumour development. The incidence of pseudotumour formation was 38.5% in this study at a mean follow-up of 3.6 years. In their cohort, patients with higher serum metal levels quadrupled their risk of forming pseudotumors. Langton *et al*<sup>[56]</sup> described an ALVAL type of tissue reaction in failed ASR hips. Kawakita *et al*<sup>[57]</sup> has described a case of histologically proven pseudotumour following a large diameter MoM hip arthroplasty. The patient developed unilateral leg edema secondary to a pelvic mass (pseudotumour) 14 mo after hip replacement surgery. Corrosion at the head-neck interface in large diameter MoM THA<sup>[17,18]</sup> may be contributory to their failure and possibly lead to different profile of wear debris in the periprosthetic tissues. This is presented in more detail in the subsequent section on modularity and taper corrosion.

## MOLECULAR PATHWAYS

Molecular pathways leading to early aseptic loosening among MoM implants are not well understood either. A variety of inflammatory mediators such as interleukin-6 (IL-6), prostaglandin E2 (PGE2) and tumor necrosis factor- $\alpha$  (TNF- $\alpha$ ) have been shown to be expressed by monocytic cells in periprosthetic tissue of failed joint arthroplasties<sup>[58,59]</sup>. Caicedo and colleagues suggested that soluble ions more than particulate cobalt-alloy implant debris induce monocyte co-stimulatory molecule expression and release of proinflammatory cytokines which contribute to metal-induced lymphocyte reactivity<sup>[60]</sup>. Tuan *et al*<sup>[61]</sup> observed that many pro-osteoclastic inflammatory cytokines not only promote osteoclastogenesis but also interfere with osteogenesis led by osteoprogenitor cells. Lin *et al*<sup>[62]</sup> investigated the suppression of chronic inflammation by inhibiting NF- $\kappa$ B activity as a strategy to combat wear particle induced periprosthetic

osteolysis. Ren and colleagues from the University of Kansas group previously reported that VEGF inhibitor treatment prevented UHMWPE particle-induced inflammatory osteolysis<sup>[63]</sup>. Most of these inflammatory chemokines are upregulated in MoM implant failures, periprosthetic tissue affected by osteolysis due to polyethylene wear debris as well as other disease states involving chronic inflammation and even malignancy (*e.g.*, multiple myeloma) and are not specific to the inciting agent or material<sup>[64]</sup>. The common end-point for each of these pathways is osteoclast activation and bone resorption<sup>[65,66]</sup>, leading to implant loosening and revision surgery. Future research efforts should be channeled towards identifying a molecular marker which is material-specific *i.e.*, is up-regulated by the presence of metallic wear debris but not affected by polymeric wear debris and infection.

## TAPER CORROSION AND MODULARITY

Modular interfaces in joint replacement surgery perhaps represent a double-edged sword. Modularity has, beyond doubt, made the technical complexity of surgical operations (particularly revisions) much easier but has also introduced a new set of problems for the revision surgeon - problems associated with the release of corrosion and wear debris from these interfaces. The cone-taper (head-neck) interface and neck-stem interface (when modular necks are used) in THA surgery represent two potential interfaces for a crevice environment and mechanically assisted corrosion leading to instability.

Collier *et al*<sup>[67,68]</sup> were one of the pioneer groups who studied the head-neck or cone-taper interface. They reported corrosion at the head-neck junction in a cohort of THAs which had dissimilar metal alloys in the head and neck but not in endoprosthetic components made from similar metals. This has since been shown to not be the case, with many cases of marked corrosion reported at the head-neck of same alloy systems. Willert *et al*<sup>[53]</sup> observed that a protective passivation layer of an alloy may prevent corrosion until micromotion sets in and abrades this layer. The current understanding of this process is termed mechanically-assisted crevice corrosion.

Gill *et al*<sup>[19]</sup> reported corrosion at the neck-stem junction as an important source of debris leading to pseudotumour formation. Higgs *et al*<sup>[16]</sup> studied 134 heads and 60 stems (41 modular necks) of 8 different bearing designs (5 manufacturers) and concluded that dissimilar alloy pairing, larger head sizes, increased medio-lateral offsets and longer neck moment arms were all associated with increased taper damage at the modular interfaces. Cook *et al*<sup>[22]</sup> have reported pseudotumour formation due to tribocorrosion at the taper interface of large diameter metal-on-polyethylene modular total hip replacements. Cooper's group reported the occurrence of adverse local tissue reactions (ALTR) similar to those seen in MoM THAs and corrosion at the head-neck junction in ten patients with a metal-on-polyethylene total hip prostheses, from three different manufacturers<sup>[21]</sup>.

We have reported the occurrence of corrosion and



instability at the cone-taper interface, tissue metal content and element analysis of periprosthetic wear debris and type of tissue response (macrophage-dominated *vs* lymphocyte dominated) among 2 cohorts of failed MoM total hip arthroplasties (THAs)<sup>[17,18,54]</sup>. The first cohort consisted of 27 patients (28 hips) with small-diameter MoM bearing couples (Sikomet®, 0.08% carbon content) as described above. The second cohort consisted of 110 patients who had 114 revisions of large-diameter head MoM THAs (LDH® head (Zimmer Inc, Warsaw, IN, United States) and a DUROM® hip cup (Zimmer Inc, Warsaw, IN, United States). The head size ranged from 46-58 mm. The duration of implantation was 26 to 68 mo with a mean of 46 mo. All implants were revised to ceramic-on-polyethylene articulating couples. Among the first cohort of small diameter MoM THAs, there was no evidence of corrosion or instability at the cone-taper interface of the retrieved implants intraoperatively. In contrast, we have reported corrosion at the cone-taper interface as being a significant mode of failure in large-diameter MoM hip arthroplasties<sup>[18]</sup>. Out of 114 revisions of large-diameter MoM THAs, 107 (94%) had evidence of corrosion and instability at the head-neck interface. One hundred six (93%) of the 114 hips had joint effusions and tissues with a grayish necrotic appearance were found around the implants, respectively. Intraoperatively, in 94% (*n* = 107), the cones and the tapers were unstable and showed a black color suggestive of corrosion. Interestingly, only 9 cases in this series had a lymphocyte-dominated tissue response and all other cases had a foreign-body type, macrophage-dominated tissue response. Element analysis with Inductive-Coupled Plasma Mass Spectrometry (ICPMS) showed a very different profile of wear debris with titanium or iron predominating, suggestive of abrasive wear from the neck taper.

Goldberg *et al.*<sup>[69]</sup> reported that the combination of dissimilar alloys, metallurgical condition of the alloys, implantation time, and flexural rigidity of the femoral neck were predictors of corrosion of the neck and head. Implantation time, lateral offset, femoral stem modularity, and dissimilar alloys have been implicated as predictors of taper corrosion in a recent multicenter retrieval study<sup>[16]</sup>. The emergence of this phenomenon in non-MoM THAs certainly brings to light the reality of the problem and we recommend that modularity should be used with a hint of caution.

## CONCLUSION

MoM total hip arthroplasties and their failures have given the orthopedic community valuable insights into periprosthetic adverse tissue reactions. Further research needs to be directed towards the immunological mechanisms, antigen-presenting and molecular pathways responsible for these adverse tissue reactions. Identification of material-specific biomarkers will potentially allow early diagnosis of adverse tissue reactions and facilitate early intervention in these patients.

## ACKNOWLEDGMENTS

Dr med. Hans-Georg Willert, Professor, to whom this work is dedicated, passed away on September 25<sup>th</sup>, 2006.

## REFERENCES

- 1 **Brown SR**, Davies WA, DeHeer DH, Swanson AB. Long-term survival of McKee-Farrar total hip prostheses. *Clin Orthop Relat Res* 2002; **(402)**: 157-163 [PMID: 12218479 DOI: 10.1097/00003086-200209000-00013]
- 2 **Howie DW**, McCalden RW, Nawana NS, Costi K, Pearcy MJ, Subramanian C. The long-term wear of retrieved McKee-Farrar metal-on-metal total hip prostheses. *J Arthroplasty* 2005; **20**: 350-357 [PMID: 15809954 DOI: 10.1016/j.arth.2004.09.028]
- 3 **Bryant MJ**, Mollan RA, Nixon JR. Survivorship analysis of the Ring hip arthroplasty. *J Arthroplasty* 1991; **6** Suppl: S5-10 [PMID: 1774571 DOI: 10.1016/S0883-5403(08)80049-6]
- 4 **Weber BG**. [Metal-metal total prosthesis of the hip joint: back to the future]. *Z Orthop Ihre Grenzgeb* 1992; **130**: 306-309 [PMID: 1413976 DOI: 10.1055/s-2008-1039623]
- 5 **Hing C**, Back D, Shimmin A. Hip resurfacing: indications, results, and conclusions. *Instr Course Lect* 2007; **56**: 171-178 [PMID: 17472305]
- 6 **Su EP**, Su SL. Metal-on-metal surface replacement: a triumph of hope over reason: opposes. *Orthopedics* 2011; **34**: e442-e444 [PMID: 21902125]
- 7 **Grecula MJ**. Resurfacing arthroplasty in osteonecrosis of the hip. *Orthop Clin North Am* 2005; **36**: 231-242, x [PMID: 15833461 DOI: 10.1016/j.jocl.2005.02.005]
- 8 **Amstutz HC**, Le Duff MJ. Background of metal-on-metal resurfacing. *Proc Inst Mech Eng H* 2006; **220**: 85-94 [PMID: 16669378 DOI: 10.1243/095441105X69088]
- 9 **Smith AJ**, Dieppe P, Vernon K, Porter M, Blom AW. Failure rates of stemmed metal-on-metal hip replacements: analysis of data from the National Joint Registry of England and Wales. *Lancet* 2012; **379**: 1199-1204 [PMID: 22417410 DOI: 10.1016/S0140-6736(12)60353-5]
- 10 **Cohen D**. How safe are metal-on-metal hip implants? *BMJ* 2012; **344**: e1410 [PMID: 22374741 DOI: 10.1136/bmj.e1410]
- 11 **Catelas I**, Wimmer MA. New insights into wear and biological effects of metal-on-metal bearings. *J Bone Joint Surg Am* 2011; **93** Suppl 2: 76-83 [PMID: 21543694 DOI: 10.2106/JBJS.J.01877]
- 12 **Jacobs JJ**, Hallab NJ, Skipor AK, Urban RM. Metal degradation products: a cause for concern in metal-metal bearings? *Clin Orthop Relat Res* 2003; **(417)**: 139-147 [PMID: 14646711]
- 13 **Hallab NJ**, Mikecz K, Vermes C, Skipor A, Jacobs JJ. Orthopaedic implant related metal toxicity in terms of human lymphocyte reactivity to metal-protein complexes produced from cobalt-base and titanium-base implant alloy degradation. *Mol Cell Biochem* 2001; **222**: 127-136 [PMID: 11678594]
- 14 **Tkaczyk C**, Huk OL, Mwale F, Antoniou J, Zukor DJ, Petit A, Tabrizian M. Investigation of the binding of Cr(III) complexes to bovine and human serum proteins: a proteomic approach. *J Biomed Mater Res A* 2010; **94**: 214-222 [PMID: 20166223 DOI: 10.1002/jbm.a.32700]
- 15 **Matthies AK**, Racasan R, Bills P, Blunt L, Cro S, Panagiotidou A, Blunn G, Skinner J, Hart AJ. Material loss at the taper junction of retrieved large head metal-on-metal total hip replacements. *J Orthop Res* 2013; **31**: 1677-1685 [PMID: 23918742]
- 16 **Higgs GB**, Hanzlik JA, MacDonald DW, Gilbert JL, Rimnac CM, Kurtz SM. Is increased modularity associated with increased fretting and corrosion damage in metal-on-metal total hip arthroplasty devices?: a retrieval study. *J Arthroplasty* 2013; **28**: 2-6 [PMID: 23910820 DOI: 10.1016/j.arth.2013.05.040]



- 17 **Singh G**, Meyer H, Ruetschi M, Chamaon K, Feuerstein B, Lohmann CH. Large-diameter metal-on-metal total hip arthroplasties: a page in orthopedic history? *J Biomed Mater Res A* 2013; **101**: 3320-3326 [PMID: 23529961]
- 18 **Meyer H**, Mueller T, Goldau G, Chamaon K, Ruetschi M, Lohmann CH. Corrosion at the cone/taper interface leads to failure of large-diameter metal-on-metal total hip arthroplasties. *Clin Orthop Relat Res* 2012; **470**: 3101-3108 [PMID: 22864616 DOI: 10.1007/s11999-012-2502-5]
- 19 **Gill IP**, Webb J, Sloan K, Beaver RJ. Corrosion at the neck-stem junction as a cause of metal ion release and pseudotumour formation. *J Bone Joint Surg Br* 2012; **94**: 895-900 [PMID: 22733942 DOI: 10.1302/0301-620X.94B7.29122]
- 20 **Bishop N**, Witt F, Pourzal R, Fischer A, Rüttschi M, Michel M, Morlock M. Wear patterns of taper connections in retrieved large diameter metal-on-metal bearings. *J Orthop Res* 2013; **31**: 1116-1122 [PMID: 23440943 DOI: 10.1002/jor.22326]
- 21 **Cooper HJ**, Della Valle CJ, Berger RA, Tetreault M, Paprosky WG, Sporer SM, Jacobs JJ. Corrosion at the head-neck taper as a cause for adverse local tissue reactions after total hip arthroplasty. *J Bone Joint Surg Am* 2012; **94**: 1655-1661 [PMID: 23289127]
- 22 **Cook RB**, Bolland BJ, Wharton JA, Tilley S, Latham JM, Wood RJ. Pseudotumour formation due to tribocorrosion at the taper interface of large diameter metal on polymer modular total hip replacements. *J Arthroplasty* 2013; **28**: 1430-1436 [PMID: 23528556 DOI: 10.1016/j.arth.2013.02.009]
- 23 **Kurtz SM**, Kocagöz SB, Hanzlik JA, Underwood RJ, Gilbert JL, MacDonald DW, Lee GC, Mont MA, Kraay MJ, Klein GR, Parvizi J, Rinnac CM. Do ceramic femoral heads reduce taper fretting corrosion in hip arthroplasty? A retrieval study. *Clin Orthop Relat Res* 2013; **471**: 3270-3282 [PMID: 23761174 DOI: 10.1007/s11999-013-3096-2]
- 24 **Cobb AG**, Schmalzried TP. The clinical significance of metal ion release from cobalt-chromium metal-on-metal hip joint arthroplasty. *Proc Inst Mech Eng H* 2006; **220**: 385-398 [PMID: 16669404 DOI: 10.1243/09544119JEM78]
- 25 **Billi F**, Campbell P. Nanotoxicology of metal wear particles in total joint arthroplasty: a review of current concepts. *J Appl Biomater Biomech* 2010; **8**: 1-6 [PMID: 20740415]
- 26 **Bowsher JG**, Hussain A, Williams PA, Shelton JC. Metal-on-metal hip simulator study of increased wear particle surface area due to 'severe' patient activity. *Proc Inst Mech Eng H* 2006; **220**: 279-287 [PMID: 16669394 DOI: 10.1243/09544119JEM93]
- 27 **Willert HG**, Semlitsch M. Reactions of the articular capsule to wear products of artificial joint prostheses. *J Biomed Mater Res* 1977; **11**: 157-164 [PMID: 140168 DOI: 10.1002/jbm.820110202]
- 28 **Aspenberg P**, Van der Vis H. Migration, particles, and fluid pressure. A discussion of causes of prosthetic loosening. *Clin Orthop Relat Res* 1998; **(352)**: 75-80 [PMID: 9678035]
- 29 **Schmalzried TP**, Jasty M, Harris WH. Periprosthetic bone loss in total hip arthroplasty. Polyethylene wear debris and the concept of the effective joint space. *J Bone Joint Surg Am* 1992; **74**: 849-863 [PMID: 1634575]
- 30 **Harris WH**. Osteolysis and particle disease in hip replacement. A review. *Acta Orthop Scand* 1994; **65**: 113-123 [PMID: 8154274 DOI: 10.3109/17453679408993734]
- 31 **Gallo J**, Goodman SB, Kontinen YT, Raska M. Particle disease: biologic mechanisms of periprosthetic osteolysis in total hip arthroplasty. *Innate Immun* 2013; **19**: 213-224 [PMID: 22751380 DOI: 10.1177/1753425912451779]
- 32 **Bozic KJ**, Browne J, Dangles CJ, Manner PA, Yates AJ, Weber KL, Boyer KM, Zemaitis P, Woznica A, Turkelson CM, Wies JL. Modern metal-on-metal hip implants. *J Am Acad Orthop Surg* 2012; **20**: 402-406 [PMID: 22661570 DOI: 10.5435/JAAOS-20-06-402]
- 33 **Morrey BF**, Berry DJ, An K, Kitaoka HB, Pagnano MW. Joint Replacement Arthroplasty: Basic Science, Hip, Knee and Ankle. Fourth Centennial Edition, Volume II. Amsterdam: Wolters Kluwer Health/Lipincott Williams & Wilkins, 2011: 510-514
- 34 **Delaunay C**, Petit I, Learmonth ID, Oger P, Vendittoli PA. Metal-on-metal bearings total hip arthroplasty: the cobalt and chromium ions release concern. *Orthop Traumatol Surg Res* 2010; **96**: 894-904 [PMID: 20832379]
- 35 **Browne JA**, Bechtold CD, Berry DJ, Hanssen AD, Lewallen DG. Failed metal-on-metal hip arthroplasties: a spectrum of clinical presentations and operative findings. *Clin Orthop Relat Res* 2010; **468**: 2313-2320 [PMID: 20559767 DOI: 10.1007/s11999-010-1419-0]
- 36 **Mann BS**, Whittingham-Jones PM, Shaerf DA, Nawaz ZS, Harvie P, Hart AJ, Skinner JA. Metal-on-metal bearings, inflammatory pseudotumours and their neurological manifestations. *Hip Int* 2012; **22**: 129-136 [PMID: 22476931 DOI: 10.5301/HIP.2012.9185]
- 37 **Haddad FS**, Thakrar RR, Hart AJ, Skinner JA, Nargol AV, Nolan JF, Gill HS, Murray DW, Blom AW, Case CP. Metal-on-metal bearings: the evidence so far. *J Bone Joint Surg Br* 2011; **93**: 572-579 [PMID: 21511920 DOI: 10.1302/0301-620X.93B4.26429]
- 38 **Shetty VD**, Villar RN. Development and problems of metal-on-metal hip arthroplasty. *Proc Inst Mech Eng H* 2006; **220**: 371-377 [PMID: 16669402 DOI: 10.1243/095441105X63264]
- 39 **MacDonald SJ**. Metal-on-metal total hip arthroplasty: the concerns. *Clin Orthop Relat Res* 2004; **8**: 86-93 [PMID: 15577471 DOI: 10.1097/01.blo.0000150309.48474.8b]
- 40 **Amstutz HC**, Grigoris P. Metal on metal bearings in hip arthroplasty. *Clin Orthop Relat Res* 1996; **(429)**: S11-S34 [PMID: 8769320 DOI: 10.1097/00003086-199608001-00003]
- 41 **Fabi D**, Levine B, Paprosky W, Della Valle C, Sporer S, Klein G, Levine H, Hartzband M. Metal-on-metal total hip arthroplasty: causes and high incidence of early failure. *Orthopedics* 2012; **35**: e1009-e1016 [PMID: 22784892 DOI: 10.3928/01477447-20120621-12]
- 42 **Gonzalez MH**, Carr R, Walton S, Mihalko WM. The evolution and modern use of metal-on-metal bearings in total hip arthroplasty. *Instr Course Lect* 2011; **60**: 247-255 [PMID: 21553777]
- 43 **Bolland BJ**, Culliford DJ, Langton DJ, Millington JP, Arden NK, Latham JM. High failure rates with a large-diameter hybrid metal-on-metal total hip replacement: clinical, radiological and retrieval analysis. *J Bone Joint Surg Br* 2011; **93**: 608-615 [PMID: 21511925 DOI: 10.1302/0301-620X.93B5.26309]
- 44 **Langton DJ**, Jameson SS, Joyce TJ, Hallab NJ, Natsu S, Nargol AV. Early failure of metal-on-metal bearings in hip resurfacing and large-diameter total hip replacement: A consequence of excess wear. *J Bone Joint Surg Br* 2010; **92**: 38-46 [PMID: 20044676 DOI: 10.1302/0301-620X.92B1.22770]
- 45 **Barrett WP**, Kindsfater KA, Lesko JP. Large-diameter modular metal-on-metal total hip arthroplasty: incidence of revision for adverse reaction to metallic debris. *J Arthroplasty* 2012; **27**: 976-83.e1 [PMID: 22425300]
- 46 **Hasegawa M**, Yoshida K, Wakabayashi H, Sudo A. Cobalt and chromium ion release after large-diameter metal-on-metal total hip arthroplasty. *J Arthroplasty* 2012; **27**: 990-996 [PMID: 22325959 DOI: 10.1016/j.arth.2011.12.016]
- 47 **Contzen H**, Straumann F, Paschke E, Geissendörfer R. Grundlagen der Alloplastikmetallen und Kunststoffen. Thieme Verlag, Stuttgart, 1967, p50
- 48 **Daniel J**, Holland J, Quigley L, Sprague S, Bhandari M. Pseudotumors associated with total hip arthroplasty. *J Bone Joint Surg Am* 2012; **94**: 86-93 [PMID: 22218386 DOI: 10.2106/JBJS.J.01612]
- 49 **Goodman SB**. Wear particles, periprosthetic osteolysis and the immune system. *Biomaterials* 2007; **28**: 5044-5048 [PMID: 17645943 DOI: 10.1016/j.biomaterials.2007.06.035]
- 50 **Hallab NJ**, Anderson S, Stafford T, Glant T, Jacobs JJ. Lymphocyte responses in patients with total hip arthroplasty. *J*

- Orthop Res* 2005; **23**: 384-391 [PMID: 15734252 DOI: 10.1016/j.orthres.2004.09.001]
- 51 **Aroukatos P**, Repanti M, Repantis T, Bravou V, Korovessis P. Immunologic adverse reaction associated with low-carbide metal-on-metal bearings in total hip arthroplasty. *Clin Orthop Relat Res* 2010; **468**: 2135-2142 [PMID: 20020335 DOI: 10.1007/s11999-009-1187-x]
- 52 **Lohmann CH**, Nuechtern JV, Willert HG, Junk-Jantsch S, Ruether W, Pflueger G. Hypersensitivity reactions in total hip arthroplasty. *Orthopedics* 2007; **30**: 760-761 [PMID: 17899927]
- 53 **Willert HG**, Buchhorn GH, Fayyazi A, Flury R, Windler M, Köster G, Lohmann CH. Metal-on-metal bearings and hypersensitivity in patients with artificial hip joints. A clinical and histomorphological study. *J Bone Joint Surg Am* 2005; **87**: 28-36 [PMID: 15637030 DOI: 10.2106/JBJS.A.02039pp]
- 54 **Lohmann CH**, Meyer H, Nuechtern JV, Singh G, Junk-Jantsch S, Schmotzer H, Morlock MM, Pflüger G. Periprosthetic tissue metal content but not serum metal content predicts the type of tissue response in failed small-diameter metal-on-metal total hip arthroplasties. *J Bone Joint Surg Am* 2013; **95**: 1561-1568 [PMID: 24005196 DOI: 10.2106/JBJS.L.01273]
- 55 **Bosker BH**, Ettema HB, Boomsma MF, Kollen BJ, Maas M, Verheyen CC. High incidence of pseudotumour formation after large-diameter metal-on-metal total hip replacement: a prospective cohort study. *J Bone Joint Surg Br* 2012; **94**: 755-761 [PMID: 22628588 DOI: 10.1302/0301-620X.94B6.28373]
- 56 **Langton DJ**, Jameson SS, Joyce TJ, Gandhi JN, Sidaginamale R, Mereddy P, Lord J, Nargol AV. Accelerating failure rate of the ASR total hip replacement. *J Bone Joint Surg Br* 2011; **93**: 1011-1016 [PMID: 21768621 DOI: 10.1302/0301-620X.93B8.26040]
- 57 **Kawakita K**, Shibnuma N, Tei K, Nishiyama T, Kuroda R, Kurosaka M. Leg edema due to a mass in the pelvis after a large-diameter metal-on-metal total hip arthroplasty. *J Arthroplasty* 2013; **28**: 197.e1-197.e4 [PMID: 22704029]
- 58 **Burton L**, Paget D, Binder NB, Bohnert K, Nestor BJ, Sculco TP, Santambrogio L, Ross FP, Goldring SR, Purdue PE. Orthopedic wear debris mediated inflammatory osteolysis is mediated in part by NALP3 inflammasome activation. *J Orthop Res* 2013; **31**: 73-80 [PMID: 22933241 DOI: 10.1002/jor.22190]
- 59 **Wang CT**, Lin YT, Chiang BL, Lee SS, Hou SM. Overexpression of receptor activator of nuclear factor- $\kappa$ B ligand (RANKL), inflammatory cytokines, and chemokines in periprosthetic osteolysis of loosened total hip arthroplasty. *Biomaterials* 2010; **31**: 77-82 [PMID: 19781765 DOI: 10.1016/j.biomaterials.2009.09.017]
- 60 **Caicedo MS**, Pennenkamp PH, McAllister K, Jacobs JJ, Hallab NJ. Soluble ions more than particulate cobalt-alloy implant debris induce monocyte costimulatory molecule expression and release of proinflammatory cytokines critical to metal-induced lymphocyte reactivity. *J Biomed Mater Res A* 2010; **93**: 1312-1321 [PMID: 19844976]
- 61 **Tuan RS**, Lee FY, T Kontinen Y, Wilkinson JM, Smith RL. What are the local and systemic biologic reactions and mediators to wear debris, and what host factors determine or modulate the biologic response to wear particles? *J Am Acad Orthop Surg* 2008; **16** Suppl 1: S42-S48 [PMID: 18612013]
- 62 **Lin TH**, Tamaki Y, Pajarinen J, Waters HA, Woo DK, Yao Z, Goodman SB. Chronic inflammation in biomaterial-induced periprosthetic osteolysis: NF- $\kappa$ B as a therapeutic target. *Acta Biomater* 2014; **10**: 1-10 [PMID: 24090989]
- 63 **Ren W**, Zhang R, Markel DC, Wu B, Peng X, Hawkins M, Wooley PH. Blockade of vascular endothelial growth factor activity suppresses wear debris-induced inflammatory osteolysis. *J Rheumatol* 2007; **34**: 27-35 [PMID: 17216676]
- 64 **Romas E**, Gillespie MT, Martin TJ. Involvement of receptor activator of NF $\kappa$ B ligand and tumor necrosis factor- $\alpha$  in bone destruction in rheumatoid arthritis. *Bone* 2002; **30**: 340-346 [PMID: 11856640 DOI: 10.1016/S8756-3282(01)00682-2]
- 65 **Lau YS**, Danks L, Sun SG, Fox S, Sabokbar A, Harris A, Athanasou NA. RANKL-dependent and RANKL-independent mechanisms of macrophage-osteoclast differentiation in breast cancer. *Breast Cancer Res Treat* 2007; **105**: 7-16 [PMID: 17151927 DOI: 10.1007/s10549-006-9438-y]
- 66 **Shen Z**, Crotti TN, McHugh KP, Matsuzaki K, Gravalles EM, Bierbaum BE, Goldring SR. The role played by cell-substrate interactions in the pathogenesis of osteoclast-mediated peri-implant osteolysis. *Arthritis Res Ther* 2006; **8**: R70 [PMID: 16613614 DOI: 10.1186/ar1938]
- 67 **Collier JP**, Suprenant VA, Jensen RE, Mayor MB, Suprenant HP. Corrosion between the components of modular femoral hip prostheses. *J Bone Joint Surg Br* 1992; **74-B**: 511-517
- 68 **Collier JP**, Surprenant VA, Jensen RE, Mayor MB. Corrosion at the interface of cobalt-alloy heads on titanium-alloy stems. *Clin Orthop Relat Res* 1991; **(271)**: 305-312 [PMID: 1688333]
- 69 **Goldberg JR**, Gilbert JL, Jacobs JJ, Bauer TW, Paprosky W, Leurgans S. A multicenter retrieval study of the taper interfaces of modular hip prostheses. *Clin Orthop Relat Res* 2002; **(401)**: 149-161 [PMID: 12151892 DOI: 10.1097/00003086-200208000-00018]

P- Reviewer: Cooper HJ S- Editor: Wen LL L- Editor: A  
E- Editor: Wu HL



## Treatment of acute periprosthetic infections with prosthesis retention: Review of current concepts

Jesse WP Kuiper, Robin Tjeenk Willink, Dirk Jan F Moojen, Michel PJ van den Bekerom, Sascha Colen

Jesse WP Kuiper, Center for Orthopaedic Research Alkmaar, Medical Center Alkmaar, 1815 JD, Alkmaar, The Netherlands

Jesse WP Kuiper, Department of Surgery, Spaarne Hospital, 2134 TM, Hoofddorp, The Netherlands

Robin Tjeenk Willink, Sascha Colen, Department of Orthopaedic Surgery, University Hospitals Leuven, 3212 Leuven, Belgium

Dirk Jan F Moojen, Michel PJ van den Bekerom, Department of Orthopaedic Surgery and Traumatology, Onze Lieve Vrouwe Gasthuis, 1091 AC, Amsterdam, The Netherlands

Sascha Colen, Department of Orthopedic Surgery and Traumatology, Sint Bonifatius Hospital, 49808 Lingel, Germany

Author contributions: Kuiper JWP, van den Bekerom MPJ and Colen S designed the study; all authors performed research, wrote the manuscript and revised the manuscript

Correspondence to: Jesse WP Kuiper, MD, Center for Orthopaedic Research Alkmaar, Medical Center Alkmaar, Wilhelminalaan 12, 1815 JD, Alkmaar, The Netherlands. [jwp.kuiper@gmail.com](mailto:jwp.kuiper@gmail.com)  
Telephone: +31-72-5482503 Fax: +31-72-5482168

Received: January 6, 2014 Revised: April 28, 2014

Accepted: May 31, 2014

Published online: November 18, 2014

### Abstract

Periprosthetic joint infection (PJI) is a devastating complication after total joint arthroplasty, occurring in approximately 1%-2% of all cases. With growing populations and increasing age, PJI will have a growing effect on health care costs. Many risk factors have been identified that increase the risk of developing PJI, including obesity, immune system deficiencies, malignancy, previous surgery of the same joint and longer operating time. Acute PJI occurs either postoperatively (4 wk to 3 mo after initial arthroplasty, depending on the classification system), or *via* hematogenous spreading after a period in which the prosthesis had functioned properly. Diagnosis and the choice of treatment are the cornerstones to success. Although different definitions for PJI have been used in the past, most are more or less similar and include the presence of a sinus tract, blood infection values, synovial white blood cell count, signs of infection on histopathological analysis and one or

more positive culture results. Debridement, antibiotics and implant retention (DAIR) is the primary treatment for acute PJI, and should be performed as soon as possible after the development of symptoms. Success rates differ, but most studies report success rates of around 60%-80%. Whether single or multiple debridement procedures are more successful remains unclear. The use of local antibiotics in addition to the administration of systemic antibiotic agents is also subject to debate, and its pro's and con's should be carefully considered. Systemic treatment, based on culture results, is of importance for all PJI treatments. Additionally, rifampin should be given in Staphylococcal PJIs, unless all foreign material is removed. The most important factors contributing to treatment failure are longer duration of symptoms, a longer time after initial arthroplasty, the need for more debridement procedures, the retention of exchangeable components, and PJI caused by *Staphylococcus (aureus or coagulase negative)*. If DAIR treatment is unsuccessful, the following treatment option should be based on the patient health status and his or her expectations. For the best functional outcome, one- or two-stage revision should be performed after DAIR failure. In conclusion, DAIR is the obvious choice for treatment of acute PJI, with good success rates in selected patients.

© 2014 Baishideng Publishing Group Inc. All rights reserved.

**Key words:** Arthroplasty; Prosthesis; Infection; Periprosthetic joint infection; Retention; Debridement antibiotics and implant retention; Debridement; Acute

**Core tip:** Acute periprosthetic joint infection (PJI) is a major complication after total joint arthroplasty, and occurs either postoperatively or via hematogenous spreading. Debridement, antibiotics and implant retention (DAIR), the primary treatment for acute PJI, should be performed as soon as possible after the development of symptoms, and has success rates around 60%-80%. Whether single or multiple debridement procedures are more successful remains unclear. Sys-



temic treatment, based on culture results, is important for all PJI treatments. Various factors for treatment failure can be identified. For acute PJI, DAIR has good success rates, especially in selected patients.

Kuiper JWP, Tjeenk Willink R, Moojen DJF, van den Bekerom MPJ, Colen S. Treatment of acute periprosthetic infections with prosthesis retention: Review of current concepts. *World J Orthop* 2014; 5(5): 667-676 Available from: URL: <http://www.wjgnet.com/2218-5836/full/v5/i5/667.htm> DOI: <http://dx.doi.org/10.5312/wjo.v5.i5.667>

## INTRODUCTION

With an average infection rate of approximately 1%-2%, periprosthetic joint infection (PJI) is a relatively frequent and devastating complication after performing joint arthroplasty<sup>[1,2]</sup>. It is especially debilitating for patients, as it requires prolonged hospitalization and often multiple surgical procedures. Besides the clinical impact of PJI, there is a high economic impact with tremendously increased health care costs<sup>[3]</sup>. With a rising population and overall increasing age, the number of total hip arthroplasties performed are expected to increase significantly thereby having a growing effect on the number of PJIs and, subsequently, on overall health care costs<sup>[4]</sup>.

Most PJIs are caused by intra-operative contamination and cause either early or delayed infection<sup>[1]</sup>. Hematogenous seeding is less common, and is most often seen years after the initial arthroplasty<sup>[2,5]</sup>. Although these types of infection have a different pathogenesis, both early postoperative and hematogenous infection usually have an acute onset and, therefore, both attribute to "acute infection", based on similar symptoms and treatment options<sup>[6]</sup>. Chronic late infections are usually caused by less virulent microorganisms, and although these are also thought to occur from intraoperative contamination, symptoms develop very slowly. Therefore, patient complaints are often similar to those seen in aseptic arthroplasty loosening<sup>[2,7]</sup>.

Although recent guidelines published by Osmon *et al*<sup>[2]</sup> have provided some directive, classification of acute PJI remains difficult in borderline cases. For early postoperative PJI, the period after initial arthroplasty is reported, in literature, as being between 0-4 wk<sup>[5]</sup> and 0-3 mo<sup>[1]</sup>. For acute hematogenous infections, the (vague) definition encompasses acute symptoms in "a previously well-functioning prosthesis", which can occur at any time postoperatively<sup>[2,5,8]</sup>.

Micro-organisms causing PJI are mainly *Staphylococcus aureus* and coagulase negative *Staphylococcus*, accounting for up to half or even three quarters of the infections<sup>[9,10]</sup>. Other micro-organisms responsible include *Streptococcus* species, *Enterococcus* species, and gram negative bacteria<sup>[9,10]</sup>. The microbiological profile for acute *vs* chronic PJI is reported by only a limited number of authors, and shows that acute PJI is more often caused by *S. aureus*

and *Streptococcus* species<sup>[5,11-13]</sup>. In comparison, chronic infections are more often caused by coagulase negative *Staphylococcus* and *Propionibacterium acnes*<sup>[5,11-13]</sup>.

In this review we will focus on acute PJI, both early postoperative as well as acute hematogenous PJI, after an initial symptom free period in which the arthroplasty functioned properly. First we will clarify the definition of these infections. Which diagnostic tools can be used? Which risk factors are associated with developing PJI? Which micro-organisms are a predominant cause of acute PJI? What kind of treatment options exist and what is the outcome of each of these treatment options? Finally we will discuss the risk factors associated with failure of these treatments.

## DEFINITION OF A PROSTHETIC JOINT INFECTION

Several definitions of PJI have been used in the past decades. The Workgroup of the Musculoskeletal Infection Society published a well restricted definition<sup>[14]</sup>. In their definition the diagnosis of PJI can be made if: (1) there is a sinus tract communicating with the prosthesis; or (2) a pathogen is isolated by culture from at least two separate tissue or fluid samples obtained from the affected prosthetic joint.

In patients presenting without such clear indications four of the following six criteria have to be present to prove the presence of PJI: (1) elevated serum erythrocyte sedimentation rate (ESR) and serum C-reactive protein (CRP) concentration; (2) elevated synovial leukocyte count; (3) elevated synovial polymorphonuclear neutrophil percentage (PMN%); (4) presence of purulence in the affected joint; (5) isolation of a microorganism in one culture of periprosthetic tissue or fluid; and (6) more than five neutrophils per high-power field in five high-power fields observed from histological analysis of periprosthetic tissue at × 400 magnification.

Other authors have described similar definitions, of which some are used more frequently, either directly or slightly adapted<sup>[5,15,16]</sup>. There are yet other studies which use a less well-contained definition, for example only mentioning the diagnosis ("staged revision for septic loosening")<sup>[3]</sup>, or mentioning only that the diagnosis was made based on several laboratory values and culture results<sup>[17]</sup>.

## DEFINITION OF ACUTE, LATE CHRONIC AND ACUTE LATE PJI

Two classification systems are most often used to determine whether or not there is an acute, late chronic or acute late PJI. Tsukayama *et al*<sup>[5]</sup> suggested a system which divides the occurrence of infection into four groups: positive intra-operative cultures (at time of implantation of the prosthesis), early postoperative infection (< 4 wk), late chronic (> 4 wk, indolent onset), and acute hematogenous (acute onset). This system was adapted by Toms *et al*<sup>[18]</sup> to early postoperative (type I, acute, < 6 wk), chronic (type



II, chronic, indolent onset) and acute hematogenous (type III, acute onset in a well-functioning prosthesis, secondary to hematogenous spread). The other commonly used classification, proposed by Zimmerli *et al.*<sup>[1]</sup>, defines the PJIs as early (occurring within 3 mo postoperatively), delayed (3-24 mo) and late (> 24 mo).

Parvizi *et al.*<sup>[19]</sup> also mentioned a period of 3 mo after performing arthroplasty as the cutoff to determine whether the infection can be regarded as being acute or not, however, they referred to an article only including patients undergoing aspiration within 6 wk postoperatively<sup>[20]</sup>.

## DIAGNOSIS

Classical cornerstones of PJI diagnosis are, as for any disease, a thorough patient interview and physical examination. This includes evaluation of the patient's history and comorbidities, medication use, postoperative wound problems and duration of infectious symptoms<sup>[2]</sup>.

In addition to this, different diagnostics, such as infection parameters in the patient's blood (ESR and CRP), pre-operative joint aspiration results (cell count, cell differentiation and culture) and intra-operative tissue and fluid culture results are equally important in order to determine the diagnosis of PJI<sup>[2,14]</sup>.

### Blood analysis

Blood leukocyte count is unable to differentiate between the absence or presence of PJI<sup>[1]</sup>. ESR and CRP have a more discriminating ability, and ESR higher than 30 mm/h, and CRP higher than 10 mg/L are suggestive for the presence of PJI<sup>[14]</sup>. However, shortly after surgery (such as in early infections), these parameters generally remain elevated for a prolonged period (30-60 d)<sup>[14]</sup>. Thus, a single high value is difficult to interpret, and serial measurements are recommended to aid in diagnosing PJI<sup>[1]</sup>.

Several other serum markers have been studied for this purpose, such as interleukin-6. Studies have shown promising results, with high sensitivity and very high specificity, but it has not yet been included in recently published guidelines<sup>[2,21,22]</sup>.

### Pre-operative joint aspiration

When PJI is suspected, preoperative aspiration is recommended in almost all cases, the exceptions being when it will not change further choice of treatment (*e.g.*, presence of a sinus tract), and when the diagnosis (including the causative microorganism) has already been established<sup>[2]</sup>. The synovial fluid should be sent for culture, cell count and differentiation, for the determination of the percentage polymorphonuclear leukocytes.

Gram staining has a limited role in PJI diagnosis according to most authors<sup>[23-26]</sup>. Despite the fact that its specificity and positive predictive value are high, false positive results have also been mentioned. Furthermore, with a sensitivity of 20%, many PJIs are missed<sup>[23-26]</sup>.

Recent studies have focused on two new synovial

fluid diagnostics including synovial CRP levels<sup>[27,28]</sup> and the use of leukocyte esterase strips (also used to diagnose urinary tract infections)<sup>[27-29]</sup>. These diagnostics appear to be promising in the diagnosis of PJI, but are not yet widespread.

### Intra-operative samples

For the definitive diagnosis of PJI, multiple intra-operative samples should be obtained. It is recommended that between 4 to 6 samples should be sent for bacterial culturing<sup>[2]</sup>. The incubation period should be at least 7 d, but preferably 14 d<sup>[30]</sup>. The samples should be tissue samples or samples obtained from dislodging the bacterial biofilm from the prosthetic parts<sup>[2]</sup>. For dislodging, sonication is the preferred method<sup>[31]</sup>. Scraping the biofilm from the foreign material has a lower yield of micro-organisms<sup>[32]</sup>. A relatively new but promising method is the use of dithiothreitol (DTT), an agent that has the ability to dislodge bacteria while also keeping them alive<sup>[33]</sup>. In addition to the culture samples, it is recommended that at least one sample is sent for histopathological determination of acute inflammation<sup>[2]</sup>. For a positive result, the average presence of 1 or more neutrophil polymorphs per high power field in at least 10 high power fields is required<sup>[34]</sup>.

## RISK FACTORS FOR (ACUTE) PJI

Considering the substantial incidence of PJI it is important to recognize certain risk factors associated with the development of such an infection (risk factors associated with debridement, antibiotics and implant retention (DAIR) treatment failure will be discussed further on in this review).

Chen *et al.*<sup>[35]</sup> performed a meta-analysis regarding risk factors for total knee arthroplasties. Patient related factors that increase PJI risk include high body mass index (> 30), diabetes mellitus, hypertension, steroid use and rheumatoid arthritis. Everhart *et al.*<sup>[36]</sup> support these risk factors and found that revision surgery, tobacco abuse, MRSA colonization and infection and (a history of) bone cancer also play an essential role in PJI development. They claim, however, that super obesity (*i.e.*, A BMI > 50) is a critical risk factor. Choong *et al.*<sup>[15]</sup> found that there is a direct correlation between a BMI  $\geq$  30 and an increased risk of infection. This correlation also exists if there are more than 2 co-morbidities present.

According to Liabaud *et al.*<sup>[37]</sup> there is a significant, linear correlation between BMI and operating time which is in line with Willis-Owens's results claiming that "prolonged operating time and male gender are associated with an increased incidence of infection"<sup>[38]</sup>. Luessenhop *et al.*<sup>[39]</sup> also found that a patient diagnosed with rheumatoid arthritis (and subsequent use of steroids) has a greater risk for developing PJI.

Berbari *et al.*<sup>[40]</sup> showed that a patient with a system surgical patient risk index score of 1 or 2, the presence of a malignancy, and a history of joint arthroplasty are

also risk factors.

## TREATMENT

For acute infections with a stable implant and adequate soft tissue mass, the latest guidelines recommend implant retention treatment (also referred to as DAIR: debridement, antibiotics and implant retention) for PJI occurring within 30 d after arthroplasty, or with less than 3 wk of symptoms<sup>[2]</sup>. Osmon *et al*<sup>[2]</sup> noticed that DAIR may be used in patients who do not meet these criteria, but state that worse results can then be expected.

When patients do not meet the criteria to undergo DAIR treatment, revision surgery is the preferred treatment, either in one stage (when tissue quality and micro-organism susceptibility allow for direct exchange) or in multiple stages. Mere medical treatment should be reserved for patients in whom surgery is not the most preferred option or when it is medically irresponsible. Resection arthroplasty (without reimplantation), arthrodesis and amputation are options for difficult to treat and chronic PJI, and these treatment options only very rarely have a role in acute PJI cases<sup>[1,2]</sup>.

### DAIR

DAIR treatment is probably the most widely performed initial treatment option for acute PJI, although the exact data on the number of such procedures performed is yet unknown. When acute PJI is suspected (or confirmed by the previously mentioned criteria) a debridement procedure should be performed as soon as possible, meanwhile keeping in mind that patient health optimization should also be maintained. For example, it has been seen that factors such as hyperglycemia and malnutrition adversely affect outcome after total joint surgery<sup>[41,42]</sup>.

The procedure includes acquiring multiple tissue samples, excessive debridement and removal of all infected (and necrotic) tissue, exchange of modular components and extensive irrigation<sup>[2,6]</sup>. Compared to arthroscopic washout, DAIR is associated with higher success rates: Byren *et al*<sup>[43]</sup> reported a success rate of 47% for arthroscopic washout, *vs* 88% for open washout, with a hazard ratio of 5.4. Retention of modular components is also associated with a higher failure risk. A recent study including hip and knee arthroplasties showed higher success rates for exchange of modular components: 59% for exchange *vs* 44% for retention (HR = 1.54)<sup>[44]</sup>. Another study showed 53% success for exchange *vs* 0% success for retention of modular parts for infected knee arthroplasties<sup>[45]</sup>.

Success rates of DAIR treatment in general also show a great variety. Most small studies report success in approximately 60%-80% of the cases, but these are selected groups. When looking at cohorts with more than 100 patients (including both hip and knee PJI), success rates lie between 31% and 78% (Table 1). A recent meta-analysis showed a combined success rate of 46% for DAIR with one debridement procedure ( $n = 710$ ), and 52% for multiple procedures ( $n = 175$ )<sup>[49]</sup>.

### Single vs multiple debridement procedures

Different strategies regarding debridement surgery can be divided into either performing only one debridement, single debridement with repeat surgery on indication, or standard repeated debridement procedures<sup>[49]</sup>. Traditionally, when only local antibiotic cement beads were used, especially popular in Europe, the strategy of multiple debridements was necessary, because these beads always had to be removed again after initial insertion. However, when using resorbable local antibiotic carriers or no local antibiotics, a single debridement might be a sufficient alternative. Although the authors do not specifically mention it in their publication, in the Zimmerli algorithm a single open debridement seems to be favored as well<sup>[1]</sup>.

Two studies on combined groups of total hip and knee patients suggest that a repeat debridement on indication increases the infection eradication rate compared to a single debridement<sup>[6,50]</sup>. There are also two studies that show good results using the strategy of routine multiple debridements<sup>[51,52]</sup>. Unfortunately, to date, no comparative studies between different strategies are available and therefore no hard recommendations regarding which one to use can be made. For every strategy different studies are published with results ranging from poor to excellent (21% to 90% success rate)<sup>[49,52-54]</sup>. All of them are retrospective case-series, which are often quite heterogeneous regarding inclusion, exact treatment and outcomes.

### Local antibiotic treatment

Carriers for local antibiotic release include antibiotic loaded bone cement (polymethylmethacrylate, PMMA), beads and dissolvable sponges<sup>[55]</sup>. The rationale for using local antibiotic treatment is to achieve a high local concentration of antibiotic agents, thereby killing the causative microorganism, without the side-effects of high systemic concentrations.

Beads are usually loaded with gentamicin, but vancomycin and tobramycin are also used. The beads are most often fabricated in chains of 30 beads. Locally, concentrations of around 300 µg/mL are achieved, far above minimum inhibitory concentration (MIC) values for most micro-organisms<sup>[55-57]</sup>. A disadvantage of antibiotic beads is the additional removal surgery that is necessary, and their capability of forming a foreign body on which a biofilm can develop, after the antibiotic release (10-14 d)<sup>[57]</sup>. Their use in DAIR treatment has been reported in a few studies, with relatively high success rates. Tsukayama *et al*<sup>[58]</sup> ( $n = 20$ , success 75%), Tintle *et al*<sup>[58]</sup> ( $n = 9$ , 100% success), Estes *et al*<sup>[51]</sup> ( $n = 20$ , 90% success), and Geurts *et al*<sup>[59]</sup> ( $n = 89$ , 83% success). Kuiper *et al*<sup>[53]</sup> also mentioned a subgroup treated with beads, albeit with lower success rates ( $n = 12$ , 33% success).

Gentamicin loaded collagen sponges, which are dissolvable, do not need removal surgery. Due to the quick expansion of the collagen, when water is added, the release of gentamicin is fast, resulting in a very high local antibiotic concentration in the first hours, up to 3800 µg/mL<sup>[55,60]</sup>. The addition of hydrophobic gentamicin salt (gentamicin crobepat) has shown a longer release pattern,

**Table 1 Characteristics of studies on debridement antibiotics and implant retention treatment with over 100 patients**

Ref.	Type	Selection	n	Hip	Knee	Other	Success	Success rate	Mean fup (m)
Azzam <i>et al</i> <sup>[6]</sup>	Retrospective cohort	-	104	51	53	-	46	44%	68
Odum <i>et al</i> <sup>[17]</sup>	Retrospective cohort	-	150	53	97	-	46	31%	n.m. <sup>1</sup>
Byren <i>et al</i> <sup>[43]</sup>	Retrospective cohort	-	112	52	51	9	92	82%	27
Lora Tamayo <i>et al</i> <sup>[44]</sup>	Retrospective cohort	<i>Staphylococcus aureus</i> PJI	345	146	195	4	199	55%	n.m.
Cobo <i>et al</i> <sup>[46]</sup>	Prospective cohort	Early infections (< 30 d)	117	69	53	17	67	57%	24
Buller <i>et al</i> <sup>[47]</sup>	Retrospective cohort	-	309	62	247	-	160	52%	34
Koyonos <i>et al</i> <sup>[48]</sup>	Retrospective cohort	-	138	60	78	-	48	35%	54
El Helou <i>et al</i> <sup>[73]</sup>	Prospective cohort compared to 2 retrospective cohorts	Staphylococcal PJI	101	40	61	-	69	68%	12
Tornero <i>et al</i> <sup>[81]</sup>	Retrospective cohort	Staphylococcal PJI	106	39	67	-	81	76%	46

<sup>1</sup>Minimum 2 yr, n.m.: Not mentioned; PJI: Periprosthetic joint infection.

resulting in high concentrations (approximately 1000 µg/mL) for the first 40 h. Up to 3-5 sponges can be used in patients, without reaching toxic serum concentrations<sup>[61]</sup>. A disadvantage of gentamicin sponges might be prolonged and increased wound secretion<sup>[59]</sup>. The clinical success rate of antibiotic loaded sponges in DAIR treatment for hip PJI has only been reported in one retrospective study, with a success rate of 70%<sup>[62]</sup>.

Local continuous irrigation with an antibiotic pump or catheter is another option for local delivery. Its main advantage is that the agent can be changed, as well as the fact that it drains the intra-articular fluid. However, the burden for the patient is very high<sup>[63]</sup>. Reported success rates vary from 18%-85%<sup>[63-66]</sup>.

### Systemic antibiotic treatment

In general, to eradicate PJI, both surgical and medical treatments are necessary<sup>[1,2]</sup>. Antibiotic treatment is recommended in all cases, and involves systemic administration of one or more antibiotic agents, based on the microorganism causing the PJI, for a period of at least three months<sup>[2]</sup>. Usually, in the first two to six weeks of treatment, antibiotics are administered intravenously, to achieve a better penetration of periprosthetic tissues, and thus a higher local concentration. Depending on the culture results, the intravenous administration might be switched to oral administration. This is a possibility if the microorganism is susceptible to an agent which reaches high tissue concentrations upon oral intake<sup>[2]</sup>.

Culture results are the leading factor when choosing the appropriate antibiotic agent. Zimmerli *et al*<sup>[1]</sup> already described a medical treatment protocol in 2004, pointing out the best (combination of) antibiotic agents per causative organism. This algorithm was adapted by recent guidelines, with the addition of several newer antibiotics, such as daptomycin for Staphylococcal or Enterococcal PJI<sup>[2]</sup>. None of the two studies make a distinction between joints involved<sup>[1,2]</sup>.

All recommendations are based on the knowledge of the causative microorganism. What to do when PJI is suspected, but culture results are not yet known, is not mentioned in the guidelines. Only one study provides a treatment algorithm for empirical antibiotic therapy<sup>[67]</sup>.

They advise the use of vancomycin for acute PJI caused by an unknown microorganism, and to switch to carbapenem if gram-negative bacteria are found<sup>[67]</sup>. Another study, on culture negative PJI, mentioned the parenteral use of cefazolin in 69%, and vancomycin in 13% of culture negative cases, but this is a selected group, with many patients that were already treated with antibiotics prior to surgical treatment<sup>[68]</sup>.

In almost all cases of DAIR, the addition of rifampin is useful. Rifampin is thought to penetrate the biofilm, and is recommended in all cases of Staphylococcal PJI treated with DAIR<sup>[1,2]</sup>. Several studies describe the success rates of a regimen including rifampin<sup>[15,69-71]</sup>, but only one prospective clinical study has been performed, which also observed higher success rates when rifampin was added to the antibiotic regimen<sup>[72]</sup>. Another, more recent study, compared a prospective rifampin group with a retrospective rifampin and a retrospective non-rifampin group<sup>[73]</sup>. They found higher success rates with the use of rifampin, but the groups were small, and included more knee rather than hip PJI. Despite the limited evidence, the use of additional rifampin is recommended in the most recent guidelines<sup>[2]</sup>.

## RISK FACTORS FOR DAIR TREATMENT FAILURE

Several studies mention risk factors associated with a higher chance of treatment failure. PJI caused by a *Staphylococcus* infection is the most well documented and influential risk factor. Azzam *et al*<sup>[6]</sup> state that any *Staphylococcus* infection, high American Society of Anesthesiologists score and intra-articular purulence, contribute to a substantial increase in failed treatments. They state that when “none or only one of these risk factors was present, a success rate of at least 67% was attainable”. Vilchez, Choi and Deiermengen all specifically mention *S. aureus* as being much more virulent than other micro-organisms (possibly due to their biofilm production) and having a significant, negative influence on treat outcome<sup>[45,74,75]</sup>. Peel *et al*<sup>[76]</sup> specifically state MRSA infections as leading to a significant decrease in treatment success whereas Kuiper *et al*<sup>[53]</sup> report that coagulase negative *Staphylococcus*

PJI has a higher risk of failure. Martínez-Pastor *et al*<sup>[77]</sup> claim that a fluoroquinolone susceptible micro-organism leads to a better chance of treatment success. This is in line with Jaén *et al*<sup>[78]</sup> who claim fluoroquinolone resistant bacteria to being risk factors for failure.

Another important risk factor appears to be the number of debridement procedures necessary, although the exact cut-off number varies. Vilchez *et al*<sup>[74]</sup> and Lora-Tamayo *et al*<sup>[44]</sup> state that the need for  $\geq 2$  debridements leads to an increased likelihood of failure, whereas Peel *et al*<sup>[76]</sup> set this number at  $> 4$ . Specifically in knee PJI, lack of component exchange together with a *S. aureus* infection leads to much lower infection control rates, according to Choi *et al*<sup>[45]</sup>. Lora-Tamayo confirm the importance of component exchange, stating that this “is an independent predictor of (treatment) success”<sup>[44]</sup>.

The duration of the presenting symptoms and the time after initial surgery are also important contributors to treatment success, or failure. Some studies state that treatment outcomes decline when the patients undergo a debridement a mere  $> 2$  d after onset of symptoms<sup>[79]</sup>, whereas other studies claim the cutoff is at 7 d<sup>[53]</sup>, 21 d<sup>[47]</sup> or even 28 d<sup>[62,80]</sup>. The time after index surgery showed an even greater scope, ranging from 15 d<sup>[81]</sup> to two years<sup>[82]</sup>.

A patient's BMI and the presence of co-morbidities was only statistically significant in one study; Choong states that a BMI  $> 30$  and having  $> 2$  co-morbidities are substantial risk factors<sup>[15]</sup>. Buller *et al*<sup>[47]</sup> and Byren *et al*<sup>[43]</sup> both claim having a history of infection of the same joint as being associated with treatment failure. Byren *et al*<sup>[43]</sup> also state arthroscopic washout as a risk factor. A higher ESR is a potential risk factor<sup>[47]</sup>, whereas a lower preoperative CRP, of  $\leq 15$  mg/dL, leads to a better outcome<sup>[77]</sup>. Lora-Tamayo *et al*<sup>[44]</sup> confirm this, stating that the degree of complexity of the infection (polymicrobial, bacteremic, or presenting with high CRP levels) and immunosuppression were independent predictors of failure. Kuiper *et al*<sup>[53]</sup> also state rheumatoid arthritis as a significant risk factor.

## OUTCOME AFTER DAIR FAILURE

As described above, DAIR treatment for PJI has a success rate of approximately 70%, which may even be higher in selected patients, *e.g.*, those with a shorter duration of symptoms and without co-morbidities. The use of multiple debridement procedures remains up for discussion.

The definition of DAIR treatment failure, just like the PJI definition, is not uniformly well described in the literature. Most studies do, however, consider DAIR as having failed when one or more of the following criteria are met after both surgical and medical treatment<sup>[15,62,52,83]</sup>: (1) presence of local or systemic infectious symptoms; (2) laboratory signs suggesting presence of PJI (*e.g.*, CRP higher than normal laboratory values, usually 5 or 10 mg/L); (3) the use of chronic suppressive antibiotics; (4) signs of loosening on radiography; (5) positive intraoperative culture result in a subsequent procedure; (6) if the arthroplasty has been resected or replaced; or (7) death,

resulting from PJI.

In the majority of the studies, after DAIR failure, most patients were treated with two-stage revision, but one-stage revision, resection arthroplasty without reimplantation and chronic suppression with antibiotics were described as well<sup>[15,16,52,62,83-85]</sup>.

One-stage and two-stage revisions are preferred if function and eradication are important, but the patient must then endure one or more additional elaborate surgical procedures. For knee PJI, two studies suggest that two-stage procedures may have worse results if DAIR already has been attempted<sup>[86,87]</sup>, but this has not yet been described for hip PJI. If patient health status is poor, or his or her expectations are not high, an acceptable situation may be achieved with resection arthroplasty (Girdlestone arthroplasty) or the use of chronic suppressive antibiotics<sup>[2]</sup>.

The choice of treatment after DAIR failure in the abovementioned cohorts was based on individual patient characteristics, if mentioned<sup>[15,62]</sup>. The recent IDSA (Infectious Diseases Society of America) guidelines advise individual judgment in all cases, but endorse the use of treatment algorithms when DAIR has failed, since it has been proven that their use increases treatment success<sup>[2]</sup>. Unfortunately, the current algorithms do not offer help after the initial treatment choice<sup>[1,2,88,89]</sup>. If the symptoms remain and the tissue status progressively worsens, it may be possible to move down the algorithm thereby choosing an alternative treatment plan. However, in our opinion, it is much more important to choose a treatment method that fits the patient's and the doctor's expectations in regard to revalidation time, mobility of the patient and the chance of PJI eradication.

## DISCUSSION

This review is intended to provide a concise summary of all the currently available literature regarding acute periprosthetic joint infections. The various classifications, definitions and diagnostic tools used to make the diagnosis of PJI, as well as the use of DAIR were collected and analysed in order to provide a series of solid treatment recommendations.

The initial difficulty researchers and clinicians face is how to properly make the correct diagnosis. Patient interview and physical examination, together with a blood analysis, pre-operative joint aspiration and intra-operative samples are of equal importance and must all be employed. Despite the fact that different authors use different criteria, in general all of these criteria and definitions are useful. The exact definition and cut-off of an acute infection remains unclear, however, due to the fact that some authors claim this be less than 4 wk whereas other implement less than 6 wk or even less than 3 mo. Literature remains unclear whether a period of 3 mo has worse outcome than 4 wk.

Most of the risk factors for developing PJI are the same as the risk factors associated with DAIR treatment failure. A BMI of more than 30 kg/m<sup>2</sup>, MRSA and the



presence of multiple co-morbidities put all patients at an extra risk, for both infection development and subsequent treatment failure. However, there are some specific risk factors for failure of DAIR, like the number of debridements and the time between presenting symptoms and initial surgery. The sooner the DAIR is carried out, the better.

DAIR (with modular component exchange) remains the preferred initial treatment choice, before one- and two stage revisions, mostly due to its less invasive character. Unfortunately DAIR has a lower success rate than one- and two-stage revision, respectively 70% *vs* higher than 90%<sup>[90]</sup>. There is no consensus regarding the optimal number of debridements necessary.

The use of local treatments such as beads, cement and sponges loaded with antibiotics appear to be promising, though only a handful of studies have been published, all of which analysed a relatively small patient population.

Systemic antibiotic treatment is complementary to surgical treatment. The antibiotic used for PJI is based on the acquired culture results, potentially combined with rifampin in the case of a Staphylococcal infection. However, too few studies have been published regarding the choice of antibiotics when the cultures are not yet known. Vancomycin appears to be a possible antibiotic option though a definite recommendation cannot be made. The duration of antibiotic administration is currently reported to be three months<sup>[1,2]</sup>. If the PJI cannot be eradicated using minimally invasive approaches, one- and two stage revisions are eventually the preferred treatment.

Despite many studies providing information about PJI, much evidence is missing. In order to provide stronger scientific evidence additional multicenter prospective and randomized trials must be carried out, using a single, uniformly agreed upon definition of APJI based upon equal criteria and diagnostic tools.

## REFERENCES

- Zimmerli W**, Trampuz A, Ochsner PE. Prosthetic-joint infections. *N Engl J Med* 2004; **351**: 1645-1654 [PMID: 15483283 DOI: 10.1056/NEJMra040181]
- Osmon DR**, Berbari EF, Berendt AR, Lew D, Zimmerli W, Steckelberg JM, Rao N, Hanssen A, Wilson WR. Executive summary: diagnosis and management of prosthetic joint infection: clinical practice guidelines by the Infectious Diseases Society of America. *Clin Infect Dis* 2013; **56**: 1-10 [PMID: 23230301 DOI: 10.1093/cid/cis966]
- Bozic KJ**, Ries MD. The impact of infection after total hip arthroplasty on hospital and surgeon resource utilization. *J Bone Joint Surg Am* 2005; **87**: 1746-1751 [PMID: 16085614 DOI: 10.2106/JBJS.D.02937]
- Kurtz S**, Ong K, Lau E, Mowat F, Halpern M. Projections of primary and revision hip and knee arthroplasty in the United States from 2005 to 2030. *J Bone Joint Surg Am* 2007; **89**: 780-785 [PMID: 17403800 DOI: 10.2106/JBJS.F.00222]
- Tsukayama DT**, Estrada R, Gustilo RB. Infection after total hip arthroplasty. A study of the treatment of one hundred and six infections. *J Bone Joint Surg Am* 1996; **78**: 512-523 [PMID: 8609130]
- Azzam KA**, Seeley M, Ghanem E, Austin MS, Purtill JJ, Parvizi J. Irrigation and debridement in the management of prosthetic joint infection: traditional indications revisited. *J Arthroplasty* 2010; **25**: 1022-1027 [PMID: 20378306 DOI: 10.1016/j.arth.2010.01.104]
- Kuiper JW**, van den Bekerom MP, van der Stappen J, Nolte PA, Colen S. 2-stage revision recommended for treatment of fungal hip and knee prosthetic joint infections. *Acta Orthop* 2013; **84**: 517-523 [PMID: 24171675 DOI: 10.3109/17453674.2013.859422]
- Deacon JM**, Pagliaro AJ, Zelicof SB, Horowitz HW. Prophylactic use of antibiotics for procedures after total joint replacement. *J Bone Joint Surg Am* 1996; **78**: 1755-1770 [PMID: 8934495]
- Sharma D**, Douglas J, Coulter C, Weinrauch P, Crawford R. Microbiology of infected arthroplasty: implications for empiric peri-operative antibiotics. *J Orthop Surg (Hong Kong)* 2008; **16**: 339-342 [PMID: 19126902]
- Peel TN**, Cheng AC, Choong PF, Buisson KL. Early onset prosthetic hip and knee joint infection: treatment and outcomes in Victoria, Australia. *J Hosp Infect* 2012; **82**: 248-253 [PMID: 23084482 DOI: 10.1016/j.jhin.2012.09.005]
- Stefánsdóttir A**, Johansson D, Knutson K, Lidgren L, Robertsson O. Microbiology of the infected knee arthroplasty: report from the Swedish Knee Arthroplasty Register on 426 surgically revised cases. *Scand J Infect Dis* 2009; **41**: 831-840 [PMID: 19922065 DOI: 10.3109/00365540903186207]
- Phillips JE**, Crane TP, Noy M, Elliott TS, Grimer RJ. The incidence of deep prosthetic infections in a specialist orthopaedic hospital: a 15-year prospective survey. *J Bone Joint Surg Br* 2006; **88**: 943-948 [PMID: 16799001 DOI: 10.1302/0301-620X.88B7.17150]
- Fulkerson E**, Valle CJ, Wise B, Walsh M, Preston C, Di Cesare PE. Antibiotic susceptibility of bacteria infecting total joint arthroplasty sites. *J Bone Joint Surg Am* 2006; **88**: 1231-1237 [PMID: 16757755 DOI: 10.2106/JBJS.E.00004]
- Parvizi J**, Zmistowski B, Berbari EF, Bauer TW, Springer BD, Della Valle CJ, Garvin KL, Mont MA, Wongworawat MD, Zalavras CG. New definition for periprosthetic joint infection: from the Workgroup of the Musculoskeletal Infection Society. *Clin Orthop Relat Res* 2011; **469**: 2992-2994 [PMID: 21938532 DOI: 10.1007/s11999-011-2102-9]
- Choong PF**, Dowsey MM, Carr D, Daffy J, Stanley P. Risk factors associated with acute hip prosthetic joint infections and outcome of treatment with a rifampin-based regimen. *Acta Orthop* 2007; **78**: 755-765 [PMID: 18236181 DOI: 10.1080/17453670710014527]
- Crockarell JR**, Hanssen AD, Osmon DR, Morrey BF. Treatment of infection with débridement and retention of the components following hip arthroplasty. *J Bone Joint Surg Am* 1998; **80**: 1306-1313 [PMID: 9759815]
- Odum SM**, Fehring TK, Lombardi AV, Zmistowski BM, Brown NM, Luna JT, Fehring KA, Hansen EN. Irrigation and debridement for periprosthetic infections: does the organism matter? *J Arthroplasty* 2011; **26**: 114-118 [PMID: 21621955 DOI: 10.1016/j.arth.2011.03.031]
- Toms AD**, Davidson D, Masri BA, Duncan CP. The management of peri-prosthetic infection in total joint arthroplasty. *J Bone Joint Surg Br* 2006; **88**: 149-155 [PMID: 16434514 DOI: 10.1302/0301-620X.88B2.17058]
- Parvizi J**, Jacovides C, Antoci V, Ghanem E. Diagnosis of periprosthetic joint infection: the utility of a simple yet unappreciated enzyme. *J Bone Joint Surg Am* 2011; **93**: 2242-2248 [PMID: 22258769 DOI: 10.2106/JBJS.J.01413]
- Bedair H**, Ting N, Jacovides C, Saxena A, Moric M, Parvizi J, Della Valle CJ. The Mark Coventry Award: diagnosis of early postoperative TKA infection using synovial fluid analysis. *Clin Orthop Relat Res* 2011; **469**: 34-40 [PMID: 20585914 DOI: 10.1007/s11999-010-1433-2]

- 21 **Gollwitzer H**, Dombrowski Y, Prodinge PM, Peric M, Summer B, Hapfelmeier A, Saldamli B, Pankow F, von Eisenhart-Rothe R, Imhoff AB, Schaubert J, Thomas P, Burgkart R, Banke IJ. Antimicrobial peptides and proinflammatory cytokines in periprosthetic joint infection. *J Bone Joint Surg Am* 2013; **95**: 644-651 [PMID: 23553300 DOI: 10.2106/JBJS.L.00205]
- 22 **Di Cesare PE**, Chang E, Preston CF, Liu CJ. Serum interleukin-6 as a marker of periprosthetic infection following total hip and knee arthroplasty. *J Bone Joint Surg Am* 2005; **87**: 1921-1927 [PMID: 16140805 DOI: 10.2106/JBJS.D.01803]
- 23 **Ghanem E**, Ketonis C, Restrepo C, Joshi A, Barrack R, Parvizi J. Periprosthetic infection: where do we stand with regard to Gram stain? *Acta Orthop* 2009; **80**: 37-40 [PMID: 19297787 DOI: 10.1080/17453670902804943]
- 24 **Johnson AJ**, Zywiell MG, Stroh DA, Marker DR, Mont MA. Should gram stains have a role in diagnosing hip arthroplasty infections? *Clin Orthop Relat Res* 2010; **468**: 2387-2391 [PMID: 20049566 DOI: 10.1007/s11999-009-1216-9]
- 25 **Zywiell MG**, Stroh DA, Johnson AJ, Marker DR, Mont MA. Gram stains have limited application in the diagnosis of infected total knee arthroplasty. *Int J Infect Dis* 2011; **15**: e702-e705 [PMID: 21764346 DOI: 10.1016/j.ijid.2011.05.015]
- 26 **Oethinger M**, Warner DK, Schindler SA, Kobayashi H, Bauer TW. Diagnosing periprosthetic infection: false-positive intraoperative Gram stains. *Clin Orthop Relat Res* 2011; **469**: 954-960 [PMID: 20882377 DOI: 10.1007/s11999-010-1589-9]
- 27 **Parvizi J**, Jacovides C, Adeli B, Jung KA, Hozack WJ, Mark B. Coventry Award: synovial C-reactive protein: a prospective evaluation of a molecular marker for periprosthetic knee joint infection. *Clin Orthop Relat Res* 2012; **470**: 54-60 [PMID: 21786056 DOI: 10.1007/s11999-011-1991-y]
- 28 **Parvizi J**, McKenzie JC, Cashman JP. Diagnosis of periprosthetic joint infection using synovial C-reactive protein. *J Arthroplasty* 2012; **27**: 12-16 [PMID: 22560655 DOI: 10.1016/j.arth.2012.03.018]
- 29 **Wetters NG**, Berend KR, Lombardi AV, Morris MJ, Tucker TL, Della Valle CJ. Leukocyte esterase reagent strips for the rapid diagnosis of periprosthetic joint infection. *J Arthroplasty* 2012; **27**: 8-11 [PMID: 22608686 DOI: 10.1016/j.arth.2012.03.037]
- 30 **Larsen LH**, Lange J, Xu Y, Schønheyder HC. Optimizing culture methods for diagnosis of prosthetic joint infections: a summary of modifications and improvements reported since 1995. *J Med Microbiol* 2012; **61**: 309-316 [PMID: 22222201 DOI: 10.1099/jmm.0.035303-0]
- 31 **Trampuz A**, Piper KE, Jacobson MJ, Hanssen AD, Unni KK, Osmon DR, Mandrekar JN, Cockerill FR, Steckelberg JM, Greenleaf JF, Patel R. Sonication of removed hip and knee prostheses for diagnosis of infection. *N Engl J Med* 2007; **357**: 654-663 [PMID: 17699815 DOI: 10.1056/NEJMoa061588]
- 32 **Bjerkkan G**, Witsø E, Bergh K. Sonication is superior to scraping for retrieval of bacteria in biofilm on titanium and steel surfaces in vitro. *Acta Orthop* 2009; **80**: 245-250 [PMID: 19404811 DOI: 10.3109/17453670902947457]
- 33 **Drago L**, Signori V, De Vecchi E, Vassena C, Palazzi E, Cappelletti L, Romanò D, Romanò CL. Use of dithiothreitol to improve the diagnosis of prosthetic joint infections. *J Orthop Res* 2013; **31**: 1694-1699 [PMID: 23817975 DOI: 10.1002/jor.22423]
- 34 **Pandey R**, Berendt AR, Athanasou NA. Histological and microbiological findings in non-infected and infected revision arthroplasty tissues. The OSIRIS Collaborative Study Group. Oxford Skeletal Infection Research and Intervention Service. *Arch Orthop Trauma Surg* 2000; **120**: 570-574 [PMID: 11110138 DOI: 10.1007/s004020000174]
- 35 **Chen J**, Cui Y, Li X, Miao X, Wen Z, Xue Y, Tian J. Risk factors for deep infection after total knee arthroplasty: a meta-analysis. *Arch Orthop Trauma Surg* 2013; **133**: 675-687 [PMID: 23558519 DOI: 10.1007/s00402-013-1723-8]
- 36 **Everhart JS**, Altneu E, Calhoun JH. Medical comorbidities are independent preoperative risk factors for surgical infection after total joint arthroplasty. *Clin Orthop Relat Res* 2013; **471**: 3112-3119 [PMID: 23519927 DOI: 10.1007/s11999-013-2923-9]
- 37 **Liabaud B**, Patrick DA, Geller JA. Higher body mass index leads to longer operative time in total knee arthroplasty. *J Arthroplasty* 2013; **28**: 563-565 [PMID: 23141864 DOI: 10.1016/j.arth.2012.07.037]
- 38 **Willis-Owen CA**, Konyves A, Martin DK. Factors affecting the incidence of infection in hip and knee replacement: an analysis of 5277 cases. *J Bone Joint Surg Br* 2010; **92**: 1128-1133 [PMID: 20675759 DOI: 10.1302/0301-620X.92B8.24333]
- 39 **Luessenhop CP**, Higgins LD, Brause BD, Ranawat CS. Multiple prosthetic infections after total joint arthroplasty. Risk factor analysis. *J Arthroplasty* 1996; **11**: 862-868 [PMID: 8934329 DOI: 10.1016/S0883-5403(96)80189-6]
- 40 **Berbari EF**, Hanssen AD, Duffy MC, Steckelberg JM, Ilstrup DM, Harmsen WS, Osmon DR. Risk factors for prosthetic joint infection: case-control study. *Clin Infect Dis* 1998; **27**: 1247-1254 [PMID: 9827278 DOI: 10.1086/514991]
- 41 **Jaberi FM**, Parvizi J, Haytmanek CT, Joshi A, Purtill J. Procrastination of wound drainage and malnutrition affect the outcome of joint arthroplasty. *Clin Orthop Relat Res* 2008; **466**: 1368-1371 [PMID: 18404297 DOI: 10.1007/s11999-008-0214-7]
- 42 **Marchant MH**, Viens NA, Cook C, Vail TP, Bolognesi MP. The impact of glycemic control and diabetes mellitus on perioperative outcomes after total joint arthroplasty. *J Bone Joint Surg Am* 2009; **91**: 1621-1629 [PMID: 19571084 DOI: 10.2106/JBJS.H.00116]
- 43 **Byren I**, Bejon P, Atkins BL, Angus B, Masters S, McLardy-Smith P, Gundle R, Berendt A. One hundred and twelve infected arthroplasties treated with 'DAIR' (debridement, antibiotics and implant retention): antibiotic duration and outcome. *J Antimicrob Chemother* 2009; **63**: 1264-1271 [PMID: 19336454 DOI: 10.1093/jac/dkp107]
- 44 **Lora-Tamayo J**, Murillo O, Iribarren JA, Soriano A, Sánchez-Somolinos M, Baraia-Etxaburu JM, Rico A, Palomino J, Rodríguez-Pardo D, Horcajada JP, Benito N, Bahamonde A, Granados A, del Toro MD, Cobo J, Riera M, Ramos A, Jover-Sáenz A, Ariza J. A large multicenter study of methicillin-susceptible and methicillin-resistant *Staphylococcus aureus* prosthetic joint infections managed with implant retention. *Clin Infect Dis* 2013; **56**: 182-194 [PMID: 22942204 DOI: 10.1093/cid/cis746]
- 45 **Choi HR**, von Knoch F, Zurakowski D, Nelson SB, Malchau H. Can implant retention be recommended for treatment of infected TKA? *Clin Orthop Relat Res* 2011; **469**: 961-969 [PMID: 21080127 DOI: 10.1007/s11999-010-1679-8]
- 46 **Cobo J**, Miguel LG, Euba G, Rodríguez D, García-Lechuz JM, Riera M, Falgueras L, Palomino J, Benito N, del Toro MD, Pigrau C, Ariza J. Early prosthetic joint infection: outcomes with debridement and implant retention followed by antibiotic therapy. *Clin Microbiol Infect* 2011; **17**: 1632-1637 [PMID: 20678178 DOI: 10.1111/j.1469-0691.2010.03333.x]
- 47 **Buller LT**, Sabry FY, Easton RW, Klika AK, Barsom WK. The preoperative prediction of success following irrigation and debridement with polyethylene exchange for hip and knee prosthetic joint infections. *J Arthroplasty* 2012; **27**: 857-864.e1-4 [PMID: 22402229 DOI: 10.1016/j.arth.2012.01.003]
- 48 **Koyonos L**, Zmisteowski B, Della Valle CJ, Parvizi J. Infection control rate of irrigation and débridement for periprosthetic joint infection. *Clin Orthop Relat Res* 2011; **469**: 3043-3048 [PMID: 21553171 DOI: 10.1007/s11999-011-1910-2]
- 49 **Romanò CL**, Manzi G, Logoluso N, Romanò D. Value of debridement and irrigation for the treatment of peri-prosthetic infections. A systematic review. *Hip Int* 2012; **22** Suppl 8: S19-S24 [PMID: 22956381 DOI: 10.5301/HIP.2012.9566]
- 50 **Van Kleunen JP**, Knox D, Garino JP, Lee GC. Irrigation and débridement and prosthesis retention for treating acute periprosthetic infections. *Clin Orthop Relat Res* 2010; **468**:

- 2024-2028 [PMID: 20224960 DOI: 10.1007/s11999-010-1291-y]
- 51 **Estes CS**, Beauchamp CP, Clarke HD, Spangehl MJ. A two-stage retention débridement protocol for acute periprosthetic joint infections. *Clin Orthop Relat Res* 2010; **468**: 2029-2038 [PMID: 20224958 DOI: 10.1007/s11999-010-1293-9]
- 52 **Aboltins C**, Dowsey MM, Peel T, Lim WK, Parikh S, Stanley P, Choong PF. Early prosthetic hip joint infection treated with debridement, prosthesis retention and biofilm-active antibiotics: functional outcomes, quality of life and complications. *Intern Med J* 2013; **43**: 810-815 [PMID: 23656615 DOI: 10.1111/imj.12174]
- 53 **Kuiper JW**, Vos SJ, Saouti R, Vergroesen DA, Graat HC, Debets-Ossenkopp YJ, Peters EJ, Nolte PA. Prosthetic joint-associated infections treated with DAIR (debridement, antibiotics, irrigation, and retention): analysis of risk factors and local antibiotic carriers in 91 patients. *Acta Orthop* 2013; **84**: 380-386 [PMID: 23848215 DOI: 10.3109/17453674.2013.823589]
- 54 **Konigsberg BS**, Della Valle CJ, Ting NT, Qiu F, Sporer SM. Acute hematogenous infection following total hip and knee arthroplasty. *J Arthroplasty* 2014; **29**: 469-472 [PMID: 23998990 DOI: 10.1016/j.arth.2013.07.021]
- 55 **Diefenbeck M**, Mückley T, Hofmann GO. Prophylaxis and treatment of implant-related infections by local application of antibiotics. *Injury* 2006; **37** Suppl 2: S95-104 [PMID: 16651078 DOI: 10.1016/j.injury.2006.04.015]
- 56 **Walenkamp GH**, Vree TB, van Rens TJ. Gentamicin-PMMA beads. Pharmacokinetic and nephrotoxicological study. *Clin Orthop Relat Res* 1986; **(205)**: 171-183 [PMID: 3516500]
- 57 **Barth RE**, Vogely HC, Hoepelman AI, Peters EJ. 'To bead or not to bead?' Treatment of osteomyelitis and prosthetic joint-associated infections with gentamicin bead chains. *Int J Antimicrob Agents* 2011; **38**: 371-375 [PMID: 21549570 DOI: 10.1016/j.ijantimicag.2011.03.008]
- 58 **Tintle SM**, Forsberg JA, Potter BK, Islinger RB, Andersen RC. Prosthesis retention, serial debridement, and antibiotic bead use for the treatment of infection following total joint arthroplasty. *Orthopedics* 2009; **32**: 87 [PMID: 19301804]
- 59 **Geurts JA**, Janssen DM, Kessels AG, Walenkamp GH. Good results in postoperative and hematogenous deep infections of 89 stable total hip and knee replacements with retention of prosthesis and local antibiotics. *Acta Orthop* 2013; **84**: 509-516 [PMID: 24171687 DOI: 10.3109/17453674.2013.858288]
- 60 **Mehta S**, Humphrey JS, Schenkman DI, Seaber AV, Vail TP. Gentamicin distribution from a collagen carrier. *J Orthop Res* 1996; **14**: 749-754 [PMID: 8893768 DOI: 10.1002/jor.1100140511]
- 61 **Swieringa AJ**, Goosen JH, Jansman FG, Tulp NJ. In vivo pharmacokinetics of a gentamicin-loaded collagen sponge in acute periprosthetic infection: serum values in 19 patients. *Acta Orthop* 2008; **79**: 637-642 [PMID: 18839370 DOI: 10.1080/17453670810016650]
- 62 **Kuiper JW**, Brohet RM, Wassink S, van den Bekerom MP, Nolte PA, Vergroesen DA. Implantation of resorbable gentamicin sponges in addition to irrigation and debridement in 34 patients with infection complicating total hip arthroplasty. *Hip Int* 2013; **23**: 173-180 [PMID: 23397196 DOI: 10.5301/HIP.2013.10612]
- 63 **Fukagawa S**, Matsuda S, Miura H, Okazaki K, Tashiro Y, Iwamoto Y. High-dose antibiotic infusion for infected knee prosthesis without implant removal. *J Orthop Sci* 2010; **15**: 470-476 [PMID: 20721714 DOI: 10.1007/s00776-010-1487-8]
- 64 **Perry CR**, Hulsey RE, Mann FA, Miller GA, Pearson RL. Treatment of acutely infected arthroplasties with incision, drainage, and local antibiotics delivered via an implantable pump. *Clin Orthop Relat Res* 1992; **(281)**: 216-223 [PMID: 1499215]
- 65 **Burger RR**, Basch T, Hopson CN. Implant salvage in infected total knee arthroplasty. *Clin Orthop Relat Res* 1991; **(273)**: 105-112 [PMID: 1959256]
- 66 **Davenport K**, Traina S, Perry C. Treatment of acutely infected arthroplasty with local antibiotics. *J Arthroplasty* 1991; **6**: 179-183 [PMID: 1875210 DOI: 10.1016/S0883-5403(11)80014-8]
- 67 **Sousa R**, Pereira A, Massada M, da Silva MV, Lemos R, Costa e Castro J. Empirical antibiotic therapy in prosthetic joint infections. *Acta Orthop Belg* 2010; **76**: 254-259 [PMID: 20503953]
- 68 **Malekzadeh D**, Osmon DR, Lahr BD, Hanssen AD, Berbari EF. Prior use of antimicrobial therapy is a risk factor for culture-negative prosthetic joint infection. *Clin Orthop Relat Res* 2010; **468**: 2039-2045 [PMID: 20401555 DOI: 10.1007/s11999-010-1338-0]
- 69 **Drancourt M**, Stein A, Argenson JN, Roiron R, Groulier P, Raoult D. Oral treatment of Staphylococcus spp. infected orthopaedic implants with fusidic acid or ofloxacin in combination with rifampicin. *J Antimicrob Chemother* 1997; **39**: 235-240 [PMID: 9069545 DOI: 10.1093/jac/39.2.235]
- 70 **Aboltins CA**, Page MA, Buising KL, Jenney AW, Daffy JR, Choong PF, Stanley PA. Treatment of staphylococcal prosthetic joint infections with debridement, prosthesis retention and oral rifampicin and fusidic acid. *Clin Microbiol Infect* 2007; **13**: 586-591 [PMID: 17331125 DOI: 10.1111/j.1469-0691.2007.01691.x]
- 71 **Berdal JE**, Skråmm I, Mowinckel P, Gulbrandsen P, Bjørnholt JV. Use of rifampicin and ciprofloxacin combination therapy after surgical debridement in the treatment of early manifestation prosthetic joint infections. *Clin Microbiol Infect* 2005; **11**: 843-845 [PMID: 16153261 DOI: 10.1111/j.1469-0691.2005.01230.x]
- 72 **Zimmerli W**, Widmer AF, Blatter M, Frei R, Ochsner PE. Role of rifampin for treatment of orthopedic implant-related staphylococcal infections: a randomized controlled trial. Foreign-Body Infection (FBI) Study Group. *JAMA* 1998; **279**: 1537-1541 [PMID: 9605897 DOI: 10.1001/jama.279.19.1537]
- 73 **El Helou OC**, Berbari EF, Lahr BD, Eckel-Passow JE, Razonable RR, Sia IG, Virk A, Walker RC, Steckelberg JM, Wilson WR, Hanssen AD, Osmon DR. Efficacy and safety of rifampin containing regimen for staphylococcal prosthetic joint infections treated with debridement and retention. *Eur J Clin Microbiol Infect Dis* 2010; **29**: 961-967 [PMID: 20505968 DOI: 10.1007/s10096-010-0952-9]
- 74 **Vilchez F**, Martínez-Pastor JC, García-Ramiro S, Bori G, Tornero E, García E, Mensa J, Soriano A. Efficacy of debridement in hematogenous and early post-surgical prosthetic joint infections. *Int J Artif Organs* 2011; **34**: 863-869 [PMID: 22094567 DOI: 10.5301/ijao.5000029]
- 75 **Deirmengian C**, Greenbaum J, Lotke PA, Booth RE, Lonner JH. Limited success with open debridement and retention of components in the treatment of acute Staphylococcus aureus infections after total knee arthroplasty. *J Arthroplasty* 2003; **18**: 22-26 [PMID: 14560406 DOI: 10.1016/S0883-5403(03)00288-2]
- 76 **Peel TN**, Buising KL, Dowsey MM, Aboltins CA, Daffy JR, Stanley PA, Choong PF. Outcome of debridement and retention in prosthetic joint infections by methicillin-resistant staphylococci, with special reference to rifampin and fusidic acid combination therapy. *Antimicrob Agents Chemother* 2013; **57**: 350-355 [PMID: 23114758 DOI: 10.1128/AAC.02061-12]
- 77 **Martínez-Pastor JC**, Muñoz-Mahamud E, Vilchez F, García-Ramiro S, Bori G, Sierra J, Martínez JA, Font L, Mensa J, Soriano A. Outcome of acute prosthetic joint infections due to gram-negative bacilli treated with open debridement and retention of the prosthesis. *Antimicrob Agents Chemother* 2009; **53**: 4772-4777 [PMID: 19687237 DOI: 10.1128/AAC.00188-09]
- 78 **Jaén N**, Martínez-Pastor JC, Muñoz-Mahamud E, García-Ramiro S, Bosch J, Mensa J, Soriano A. Long-term outcome of acute prosthetic joint infections due to gram-negative bacilli treated with retention of prosthesis. *Rev Esp Quimioter* 2012; **25**: 194-198 [PMID: 22987265]
- 79 **Brandt CM**, Sistrunk WW, Duffy MC, Hanssen AD, Steckelberg JM, Ilstrup DM, Osmon DR. Staphylococcus aureus prosthetic joint infection treated with debridement and



- prosthesis retention. *Clin Infect Dis* 1997; **24**: 914-919 [PMID: 9142792 DOI: 10.1093/clinids/24.5.914]
- 80 **Chiu FY**, Chen CM. Surgical débridement and parenteral antibiotics in infected revision total knee arthroplasty. *Clin Orthop Relat Res* 2007; **461**: 130-135 [PMID: 17438469]
  - 81 **Tornero E**, García-Oltra E, García-Ramiro S, Martínez-Pastor JC, Bosch J, Climent C, Morata L, Camacho P, Mensa J, Soriano A. Prosthetic joint infections due to *Staphylococcus aureus* and coagulase-negative staphylococci. *Int J Artif Organs* 2012; **35**: 884-892 [PMID: 23138701 DOI: 10.5301/ijao.5000148]
  - 82 **Waldman BJ**, Hostin E, Mont MA, Hungerford DS. Infected total knee arthroplasty treated by arthroscopic irrigation and débridement. *J Arthroplasty* 2000; **15**: 430-436 [PMID: 10884201 DOI: 10.1054/arth.2000.4637]
  - 83 **Westberg M**, Grøgaard B, Snorrason F. Early prosthetic joint infections treated with debridement and implant retention: 38 primary hip arthroplasties prospectively recorded and followed for median 4 years. *Acta Orthop* 2012; **83**: 227-232 [PMID: 22489892 DOI: 10.3109/17453674.2012.678801]
  - 84 **Waagsbø B**, Sundøy A, Martinsen TM, Nymo LS. Treatment results with debridement and retention of infected hip prostheses. *Scand J Infect Dis* 2009; **41**: 563-568 [PMID: 19452351 DOI: 10.1080/00365540902984719]
  - 85 **Klouche S**, Lhotellier L, Mamoudy P. Infected total hip arthroplasty treated by an irrigation-debridement/component retention protocol. A prospective study in a 12-case series with minimum 2 years' follow-up. *Orthop Traumatol Surg Res* 2011; **97**: 134-138 [PMID: 21388905 DOI: 10.1016/j.otsr.2011.01.002]
  - 86 **Gardner J**, Gioe TJ, Tatman P. Can this prosthesis be saved?: implant salvage attempts in infected primary TKA. *Clin Orthop Relat Res* 2011; **469**: 970-976 [PMID: 20544317 DOI: 10.1007/s11999-010-1417-2]
  - 87 **Sherrell JC**, Fehring TK, Odum S, Hansen E, Zmistowski B, Dennis A, Kalore N. The Chitranjan Ranawat Award: fate of two-stage reimplantation after failed irrigation and débridement for periprosthetic knee infection. *Clin Orthop Relat Res* 2011; **469**: 18-25 [PMID: 20582495 DOI: 10.1007/s11999-010-1434-1]
  - 88 **De Man FH**, Sendi P, Zimmerli W, Maurer TB, Ochsner PE, Ilchmann T. Infectiological, functional, and radiographic outcome after revision for prosthetic hip infection according to a strict algorithm. *Acta Orthop* 2011; **82**: 27-34 [PMID: 21189099 DOI: 10.3109/17453674.2010.548025]
  - 89 **Giulieri SG**, Graber P, Ochsner PE, Zimmerli W. Management of infection associated with total hip arthroplasty according to a treatment algorithm. *Infection* 2004; **32**: 222-228 [PMID: 15293078]
  - 90 **Lange J**, Troelsen A, Thomsen RW, Søballe K. Chronic infections in hip arthroplasties: comparing risk of reinfection following one-stage and two-stage revision: a systematic review and meta-analysis. *Clin Epidemiol* 2012; **4**: 57-73 [PMID: 22500127 DOI: 10.2147/CLEP.S29025]

**P- Reviewer:** Fisher DA, Knutsen G, Yasuda T

**S- Editor:** Ji FF **L- Editor:** A **E- Editor:** Wu HL





## Treatment for cartilage injuries of the knee with a new treatment algorithm

Ahmet Özmeriç, Kadir Bahadır Alemdaroğlu, Nevres Hürriyet Aydoğan

Ahmet Özmeriç, Kadir Bahadır Alemdaroğlu, Nevres Hürriyet Aydoğan, Department of Orthopedics and Traumatology, Ankara Training and Research Hospital, 06340 Ankara, Turkey  
Author contributions: Özmeriç A contributed to data review, drafting of paper; Alemdaroğlu KB contributed to review and approval of paper; Aydoğan NH was the consultant supervisor.  
Correspondence to: Ahmet Özmeriç, MD, Department of Orthopedics and Traumatology, Ankara Training and Research Hospital, Sukriye Mahallesi Ulucanlar Caddesi No:89 Altındag, 06340 Ankara, Turkey. aozmeric77@yahoo.com  
Telephone: +90-532-5052520477 Fax: +90-312-3633396  
Received: February 11, 2014 Revised: April 19, 2014  
Accepted: June 20, 2014  
Published online: November 18, 2014

© 2014 Baishideng Publishing Group Inc. All rights reserved.

**Key words:** Chondral lesion; Microfracture; Osteochondral transplantation; Autologous chondrocyte implantation; Scaffolds

**Core tip:** This paper discusses the current arthroscopic treatment options of cartilage injuries. Over 1 cm<sup>2</sup> full thickness chondral lesions are seen in 4%-5% of patients under 40 years undergone arthroscopy. Conventional arthroscopic treatment may not have successful results although chondral defects are observed with such a high incidence. Addition of novel scaffolds to conventional methods will provide beneficial effects on healing of articular cartilage lesions with hyaline. We now formulate a new treatment algorithm with scaffolds under the light of existing literature. In future, we expect the widespread use of arthroscopic surgery in chondral defects.

### Abstract

Treatment of articular cartilage injuries to the knee remains a considerable challenge today. Current procedures succeed in providing relief of symptoms, however damaged articular tissue is not replaced with new tissue of the same biomechanical properties and long-term durability as normal hyaline cartilage. Despite many arthroscopic procedures that often manage to achieve these goals, results are far from perfect and there is no agreement on which of these procedures are appropriate, particularly when full-thickness chondral defects are considered. Therefore, the search for biological solution in long-term functional healing and increasing the quality of wounded cartilage has been continuing. For achieving this goal and apply in wide defects, scaffolds are developed. The rationale of using a scaffold is to create an environment with biodegradable polymers for the in vitro growth of living cells and their subsequent implantation into the lesion area. Previously a few numbers of surgical treatment algorithm was described in reports, however none of them contained one-step or two -steps scaffolds. The ultimate aim of this article was to review various arthroscopic treatment options for different stage lesions and develop a new treatment algorithm which included the scaffolds.

Özmeriç A, Alemdaroğlu KB, Aydoğan NH. Treatment for cartilage injuries of the knee with a new treatment algorithm. *World J Orthop* 2014; 5(5): 677-684 Available from: URL: <http://www.wjgnet.com/2218-5836/full/v5/i5/677.htm> DOI: <http://dx.doi.org/10.5312/wjo.v5.i5.677>

### INTRODUCTION

Articular injuries that are related to trauma or overuse have plagued those afflicted for more than 200 years and are still problematic to treat. In 1743, Hueter<sup>[1]</sup> stated, "From Hippocrates down to the present age, we shall find, that an ulcerated cartilage is universally allowed to be a very troublesome disease; that it admits of a cure with more difficulty than carious bone; and that, when destroyed, it is not recovered".

Articular cartilage is vulnerable to both irreversible traumatic injury and degenerative disease<sup>[2]</sup>. The ability of

damaged articular cartilage to recover with normal hyaline cartilage is limited because of two main factors: the absence of a vascular response and the relative absence of an undifferentiated cell population to respond to injury<sup>[3]</sup>. If patients with previous cartilage deformation (chondral defects) have not been treated properly, the osteoarthritis symptoms can be seen radiographically after 10 years and primary gonarthrosis related with osteoarthritis develops 10 years early<sup>[4,5]</sup>. Therefore, it can be said that cartilage deformation leads to osteoarthritis and chondral defects in weight-bearing regions that are at risk of developing osteoarthritis<sup>[6]</sup>.

It is questionable whether every chondral defect results in osteoarthritis. A defect size under 10 mm does not increase the pressure in peripheral healthy cartilage. However, 64% more pressure is exerted on cartilage with a defect size greater than 10 mm<sup>[5]</sup>. After a 14-year follow-up of 10 mm sized defects, it has been reported that the joint gap was observed to be 50% narrower<sup>[7]</sup>. In animal studies where the treatment of cartilage defects has been evaluated, some artificial defects regenerated spontaneously. The defect sizes which do not regenerate without treatment are called “critical sized defects”. The sizes determined for every animal model can not be estimated for humans. In a clinical study, critical defect size was suggested to be 2 cm<sup>[2,8]</sup>. Therefore, defect size is not the only factor for defect resolution. Three major factors must be taken into consideration when making the treatment decision. The first factor to be considered involves defect-specific factors such as size, depth, location, and degree of containment. The second includes patient-specific factors such as patient age, current and desired level of activity and patient expectations. The third area is joint-related factors, including alignment, stability and the status of the meniscus.

Some form of cartilage healing has been proven given certain conditions, although the terms “healing and repair” are rather non-specific. Most often, the repaired articular cartilage is unsuccessful in replicating the structure, composition and function of healthy articular cartilage. Today, there are various surgical procedures to treat articular injuries.

## GOALS, INDICATIONS AND CONTRAINDICATIONS FOR SURGICAL TREATMENT

Candidates for surgical treatment are patients who have documented articular damage and those with an associated ligamentous or meniscal injury that requires surgery. Today, the main purpose of surgical treatment of articular cartilage pathology is to lessen the pathology-related symptoms, stop the progression of articular damage, restore the articular surface anatomy and start a healing or repair process in order to transform damaged tissue into healthier new tissue. Currently, most surgical procedures lead to the formation of a fibrocartilage tissue replacement, which has an inferior biomechanical composition

to normal hyaline cartilage. Surgical treatment of these articular lesions ultimately aims to replace the damaged tissue with normal hyaline cartilage that has an equivalent composition to that of the preexisting tissue. For this aim, indications are ranged according to chondral treatment options, however generally, distal femoral condyles lesions, symptomatic cartilage lesions, and asymptomatic lesion in patient who has an additional injury undergoing to surgical treatment. Contraindications of surgical treatment for articular cartilage lesions are wide-spread degenerative arthritis (including 3 compartment), systemic inflammatory or collagen vascular diseases, active infection in the related joint, body mass index > 30, opposed (kissing) full-thickness cartilage injury, untreated malignment and instability<sup>[9]</sup>.

## CLASSIFICATION OF CARTILAGE DEFECTS

It is important and necessary to thoroughly document and grade chondral lesions when treating patients with articular cartilage defects. In 1961, Outerbridge<sup>[10]</sup> described the simplest scale by directly observing damaged patellas during arthrotomy. The Outerbridge grading system is widely accepted, although it has size, depth and lesion locale descriptive limitations. Many other classification systems have been established to indicate the severity and type of articular cartilage. The international cartilage research society (ICRS) grading system observes the importance of subchondral osseous involvement and is used to describe the defect (area, depth, location)<sup>[11]</sup>. Table 1 shows the classification systems (Outerbridge, modified outerbridge grading system and ICRS) of articular lesions by severity<sup>[12,13]</sup>.

## SURGICAL TREATMENT OPTIONS AND RESULTS

During surgery, chondral defects in the knee joint are often observed. Those lesions do not always trigger symptoms. However, full thickness chondral lesions greater than 1 cm<sup>2</sup> have been reported at 4%-5% in arthroscopy performed on patients aged under 40 years<sup>[14,15]</sup>. In chondral defects, while cartilage is treated, the problem causing the chondral defect should also be detected and resolved<sup>[16]</sup>. The detection and treatment of the chondral problem influences the success of the treatment of the lesion<sup>[17]</sup>. During arthroscopic surgery, the defect is generally seen to be greater than as observed on magnetic resonance imaging (MRI)<sup>[18]</sup>.

In a retrospective review of over 31000 knee arthroscopies, in all age groups, chondral lesions were found in 63% of patients, with an average of 2.7 lesions per knee. 19% of those were focal (not widespread) chondral or osteochondral lesion, 5.2% were grade III or grade IV and only focal cartilage lesions required treatment<sup>[14]</sup>. Most chondral defects (58%-80%) are seen in the medial femoral condyle, followed by the patella and tibial pla-

**Table 1** Classification of articular lesions by severity

Grade	Outerbridge	Modified outerbridge	ICRS
0	Normal cartilage	Intact cartilage	Intact cartilage
I	Softening and swelling	Chondral softening or blistering with intact surface	Superficial (soft indentation or superficial fissures and cracks)
II	Fragmentation and fissures in area less than 0.5 inch in diameter	Superficial ulceration, fibrillation, or fissuring less than 50% of depth of cartilage	Lesion less than half the thickness of articular cartilage
III	Fragmentation and fissures in area larger than 0.5 inch in diameter	Deep ulceration, fibrillation, fissuring or chondral flap more than 50% of cartilage without exposed bone	Lesion more than half the thickness of articular cartilage
IV	Exposed subchondral bone	Full-thickness wear with exposed subchondral bone	Lesion extending to subchondral bone

ICRS: International Cartilage Repair Society.

**Table 2** Treatment options for articular cartilage lesions

Procedure	Indications	Outcome
Arthroscopic debridement and lavage	Minimal symptoms	Palliative
Marrow stimulation	Smaller lesions, low-demand patient	Reparative
Osteochondral autograft	Smaller lesions, low-or high-demand patients	Restorative
Osteochondral allograft	Larger lesions with bone loss, low-or high-demand patients	Restorative
Autologous chondrocyte implantation	Small and large lesions with and without bone loss, high-demand patients	Restorative
Genetic engineering	Investigational	Restorative

From Garrick JG, editor: Orthopaedic knowledge update: sports medicine, 3<sup>rd</sup> ed, Rosemont, IL, 2004, American Academy of Orthopaedic Surgeons.

teau. Defects in the lateral condyle, trochlea and medial tibial plateau are observed at lower incidence rates<sup>[15]</sup>.

The main goal of arthroscopic surgical management of symptomatic chondral defects is to lessen symptoms, improve joint congruence and prevent additional cartilage deterioration. Options can be characterized as palliative, reparative or restorative for those lesions. For lesions discovered incidentally or symptomatic lesions in low-demand patients with a preponderance of mechanical symptoms or signs of meniscal pathology, palliative procedures such as debridement and lavage are used. In the area of the defect, reparative procedures promote a fibrocartilage healing response. Restorative techniques replace the damaged cartilage with new articular cartilage; these include autologous chondrocyte implantation, osteochondral autografting and fresh osteochondral allografting (Table 2).

### Debridement and lavage

Over 60 years ago, Magnusson<sup>[19]</sup> described the benefits of knee joint debridement to relieve arthritic symptoms. Jackson *et al*<sup>[20]</sup> became a proponent of arthroscopic palliative procedures such as debridement and lavage for the treatment of a symptomatic arthritic knee with the arrival of arthroscopy. The purpose of this technique is to debride the loose chondral tissues. Removal of loose intra-articular tissue debris and inflammatory mediators generated by the synovial lining leads to acceptable short-term results for both acute and degenerative chondral lesions. Lavage most often provides short-term symptomatic relief. This procedure is appropriate for older sedentary patients, but when an active population is considered, the results are generally insufficient<sup>[21]</sup>.

Evidence based analyses indicate that lavage and

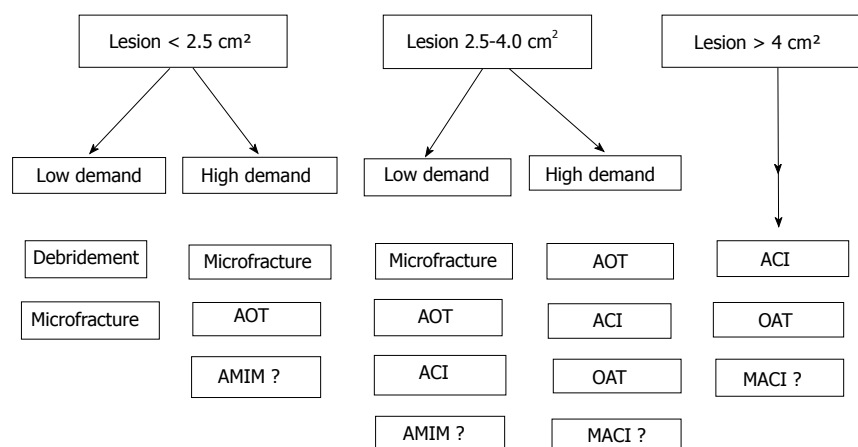
debridement is accepted as an effective technique in the short-term (up to 12 mo) in terms of pain management in patients with early osteoarthritis and those with mechanical symptoms. However, in patients with moderate to advanced osteoarthritis the results are contradictory<sup>[22]</sup>.

### Marrow stimulating techniques

The concept of penetrating the subchondral bone to allow for the release of blood, growth factors and mesenchymal cells into the chondral defect was popularized by the Pirdiean<sup>[23]</sup> open technique in 1959 and was then modified for arthroscopic use by Johnson<sup>[24]</sup>. Marrow-stimulating techniques such as abrasion arthroplasty, subchondral drilling and microfracture are the three described techniques used to penetrate the subchondral bone. All these techniques are used to stimulate fibrocartilage in growth into the chondral defect.

**Abrasion arthroplasty:** This technique involves debridement of the articular defect circumferentially using a motorized burr to remove 1-3 mm of subchondral bone<sup>[23]</sup>. However, excessive trauma to the underlying bone and thermal necrosis can be potentially more destructive than helpful. Therefore this technique is not used in current practice<sup>[11]</sup>.

**Subchondral drilling:** This procedure is an extension of the abrasion arthroplasty technique in which the subchondral bone is drilled with multiple drill holes penetrating into the bone marrow to stimulate a vascular response. Considering the efficacy of this procedure, questions still remain due to poor access, thermal necrosis and long-term results<sup>[25]</sup>. On the other hand, a recent study indicated that drilling does not cause thermal injury



**Figure 1** In small defects in high-demand patients, autologous osteochondral transplantation seems to be a reliable treatment alternative. AOT: Autologous osteochondral transplantation; ACI: Autologous chondrocyte implantation; MACI: Matrix-induced chondrocyte implantation; OAT: Osteochondral allograft transplantation; AMIM: Acellular matrix-induced microfracture.

and the drill holes actually allow more consistent channels for cell migration compared to microfracture holes that may be partially blocked with bony debris. Therefore, although less commonly used than microfracture, drilling is another alternative technique within the scope of marrow stimulating techniques<sup>[26]</sup>.

**Microfracture:** In 1994, Steadman *et al.*<sup>[27]</sup> developed the microfracture technique, which is now the currently preferred marrow-stimulation method. It includes arthroscopic debridement of the cartilage defect down to the subchondral bone but not through it. Damage to the subchondral bone should be avoided in over-aggressive shaving of the soft articular cartilage. When the subchondral bone is identified, an arthroscopic tapered awl is carefully used to make multiple drill holes approximately 3 to 4 mm apart and 4 mm in depth across the exposed surface of the lesion. The use of arthroscopic awls as opposed to subchondral drilling is thought to produce less thermal necrosis in creating the holes.

In spite of progression in chondral defect treatment, the current most widely-used therapy option is the chondral repair technique<sup>[28]</sup>. This technique is performed extensively as the first treatment choice due to its minimally invasive properties, technique simplicity, lower surgical morbidity and cost-effectiveness in focal chondral defects ( $< 2.5 \text{ cm}^2$ ) in patients under 45 years old with a low level of activity<sup>[27,29,30]</sup>. After less than 2 years follow-up of small, full thickness chondral defects treated with the microfracture technique, 75% of patients reported a decrease in pain, increased function and good-excellent clinical results<sup>[27,29]</sup>. Other arthroscopic treatment options of autologous osteochondral transplantation (AOT) and autologous chondrocyte implantation (ACI) have been compared with microfracture and after 5 years follow-up, there were no differences in functional scores and post-operative MRI grades between the groups. Microfracture is the first therapy choice because of the simplicity and cost-effectiveness compared to AOT and ACI<sup>[31]</sup>.

However in a recent review of microfracture techniques, Goyal *et al.*<sup>[32]</sup> emphasised that in young patients and smaller lesions, better results were seen in the first five years, but after 5 years the results worsened and re-

sulted in osteoarthritis regardless of the defect size. Thus, with the aim of improving the quality of repair tissue with the microfracture technique and the management of long-term functional healing, biological solutions are being investigated<sup>[33]</sup>.

Recent meta analyses and systematic review studies have indicated that microfracture technique is effective in smaller lesions (up to  $4 \text{ cm}^2$ ) with short-term follow up. The major short comings have included poor hyaline repair, variable cartilage volume and long-term functional deterioration<sup>[34]</sup> (Figure 1).

**Acellular matrix induced microfracture:** Natural and artificial structure implants such as scaffolds have been developed for the improvement of the quality of repair tissue and treatment of wide defects with the microfracture technique<sup>[35]</sup>. Structure implants are implanted in 3 dimensional or liquid/gel-formed acellular materials to improve marrow inducement with the microfracture technique. The chondroconductive or osteoconductive properties of those implants do not contain vital cells.

In combination with microfracture this can stabilize the fibrin and provide an environment for mesenchymal root cells, keep them in place and support tissue differentiation. This type of microfracture has a scaffold to obtain hyaline chondral repair tissue. The advantages of the method are the placement of implants in single-stage surgery and no need for expensive cell production technology. Scaffolds are cost effective and non time-consuming devices. They are invaded by host tissue cells and resorb over time and are replaced with repair tissue. Chondrotissue®, Hyalofast®, AMIC®, CAIS®, Alginate Beads®, Trufit®, Maioregen® are examples of implanted one-step scaffold implants<sup>[36]</sup>.

Siclari *et al.*<sup>[37]</sup> reported that 52 patients, aged 25-65 years, treated with scaffold implants demonstrated an improvement in functional scores and the histological evaluation of 13 biopsy samples showed homogeneous hyaline-like chondral repair tissue. In a recent study, Gille *et al.*<sup>[38]</sup> implanted scaffold membrane combined with microfracture in 27 patients with a mean defect size of  $3.4 \text{ cm}^2$  (range  $1-12 \text{ cm}^2$ ) and 87% of patients demonstrated significant clinical healing after a 37-mo follow-up period.



Current literature do not contain evidence-based researches or meta-analysis. Thus, to come to a decision with limited evidence, it could be speculated that one-step cell-free approaches have been developed to avoid the problems related to the *ex vivo* chondrocyte culture and expansion in a scaffold. Besides this, they reduce the costs and surgical time. Finally, osteochondral scaffolds have been proposed to treat lesions where the subchondral layer is also involved in the pathologic process and have shown promising preliminary results.

## AOT

AOT is the cartilage restoration procedure which produces true hyaline articular cartilage. Osteochondral autografts can fill the articular defect with human articular cartilage tissue transplanted into damaged areas from areas of less weight-bearing on the femoral condyle as either a single large bone plug or multiple small plugs (mosaicplasty). The term mosaicplasty is reserved to describe the use of multiple, smaller diameter grafts. Autograft harvesting and transplantation techniques have the advantages of using the patient's own tissue and immediate transplantation from the donor site to the recipient site without any additional cost to the patient.

The upper age limit for mosaicplasty is under 50 years and it can be performed on patients with high physical expectations and 1-5 cm<sup>2</sup> focal chondral defects. Hangody *et al*<sup>[39]</sup> stated that 1-4 cm<sup>2</sup> sized defects are ideal for mosaicplasty. According to Ollat *et al*<sup>[40]</sup>, defects of 2 cm<sup>2</sup> or less and to Solheim *et al*<sup>[41]</sup>, 3 cm<sup>2</sup> or less, showed better results. Good prognostic factors are male gender, young age and small defects. Therefore, in small defects in high-demand patients, AOT seems to be a reliable treatment alternative (Figure 1).

Haklar *et al*<sup>[42]</sup> claimed that mosaicplasty is a reliable procedure in the treatment of full-thickness chondral lesions because it is minimally invasive, can be performed at a single session, and has a low complication rate and is cost effective.

Gudas *et al*<sup>[43]</sup> performed microfracture on 22 patients and AOT on 25 patients with a mean age of 24.3 years (range 15-40 years) and a follow-up period of 10 years. Patients treated with microfracture demonstrated good results immediately after surgery, which then worsened over time. The patients with AOT had better results compared with the microfracture group and a high rate of sportsmen in the AOT group were able to resume their previous sporting activities.

Osteochondral grafts in restorative techniques can be complicated by dislodgement of the graft from the transplant site, but this is rare with the press-fit technique. Additionally, graft collapse can occur through biomechanical overload or biological failure of the chondral or subchondral components.

## Osteochondral allograft transplantation

The technique of osteochondral autograft plugs was first introduced by Yamashita<sup>[44]</sup> in 1985 and universalized by Hangody *et al*<sup>[45]</sup>. Fresh osteochondral allograft transplan-

tation includes the implantation of a composite cadaveric graft that involves the subchondral bone and overlying hyaline cartilage in the site of the chondral defect with a single-stage procedure, and is not limited by its size. Osteochondral allograft transplants are used for medium to large articular lesions (up to 3 cm<sup>2</sup>) in relatively high-demand patients. These grafts are generally used on the femoral condyles but can also be used for the patella, trochlea, medial and lateral tibial plateau along with the donor meniscus. There is no donor site morbidity involved in the use of allografts. In addition, allografts may be taken from younger, healthier patients with better quality bone and cartilage. Allografts can also be used in large sized defects. In a study by Giorgini *et al*<sup>[46]</sup> 11 patients were treated and followed up for mean 26.5 mo between 2006-2011. The average defect size was 10.3 cm<sup>2</sup> (range 3-20 cm<sup>2</sup>). The results of this study determined success in 10 patients who showed pain regression and functional recovery. It was emphasized that this technique had better results in lesions smaller than 8 cm<sup>2</sup>, although larger lesions also showed good results.

In another recent study, Chahal *et al*<sup>[47]</sup> conducted a systematic review of clinical outcomes after osteochondral allograft transplantation in the knee. There were 19 eligible studies with 644 knees in total. The mean age was 37 years and the mean follow-up period, 58 mo. The mean defect size across the studies was 6.3 cm<sup>2</sup>. The methods of procurement and storage time included fresh (61%), prolonged fresh (24%) and fresh frozen (15%). It was emphasized that osteochondral allograft transplantation for focal and diffuse (single compartment) chondral defects leads to predictably favorable outcomes and high satisfaction rates at intermediate follow-up. The major drawback of this technique is the use of fresh allogenic tissue, which has the potential for disease transmission. Cost and size mismatch are other issues, which should also be considered.

## Autologous chondrocyte implantation

As an alternative for the treatment of articular cartilage injuries with a hyaline-like cartilage repair, Brittberg *et al*<sup>[48]</sup> were the first to report Autologous chondrocyte implantation (ACI) in 1994. Being a two-stage technique, the first stage in ACI involves an arthroscopic evaluation of the chondral lesion and biopsy by harvesting of chondrocytes. In this stage, cartilage is taken from lesser weight-bearing regions of the knee. The preferred locations are the lateral edge of the intercondylar notch or the superomedial trochlea. The total size of the biopsy should be between 200 and 300 mg. The cartilage specimens are sent to the laboratory for the chondrocytes to be isolated from the harvested cartilage. The cells are cultured for 2 wk to increase the number of cells as the implanted cartilage cells require a stable environment in which to heal. This procedure comes 6 wk after the biopsy. Following this, the second stage involves implantation through a mini-arthrotomy. Coverage is obtained by a periosteal patch sewn according to the defect size with 6-0 Vicryl sutures and sealed with fibrin glue. The aim is to achieve

a more durable “hyaline-like” repair tissue that resembles hyaline articular cartilage.

ACI can be used as the primary treatment choice in over 4 cm<sup>2</sup>, focal, ICRS grade III and IV lesions of the knee joint and in patients with chondral defects who have a high activity demand, excellent compliance and are aged 15-55 years. It can be indicated as a second treatment in patients with 2.5 cm<sup>2</sup> unhealed lesions where microplasty or microfracture has been previously performed.

In a systematic review, Bekkers *et al*<sup>[49]</sup> concluded that for defects over 2.5 cm<sup>2</sup> in young patients, ACI can be performed successfully. In another study by Harris *et al*<sup>[50]</sup> microfracture (*n* = 271), mosaicplasty (*n* = 42) and ACI (*n* = 604) were compared in 917 patients. The clinical results of mosaicplasty were similar to those of ACI in the short term but worsened over a period of two years. In defects over 4 cm<sup>2</sup> in size, ACI was found to be superior to all the other treatments.

The ACI technique has better results in 70%-80% of patients not only in the short term but also in mid and long-term follow-up<sup>[51]</sup>. Moseley *et al*<sup>[52]</sup> showed that 69% of patients maintained the successful treatment results over 6-10 years. In a 5-year follow-up study, ACI was found to be better than microfracture in patients whose complaints had been ongoing for less than 3 years<sup>[53]</sup>. Mosaicplasty and ACI were compared in a 10-year follow-up study and the functional outcome of patients with a surviving graft was significantly better in patients who had undergone ACI compared with the mosaicplasty group<sup>[54]</sup>.

### Matrix induced chondrocyte implantation

In the ACI process, complications, such as graft hypertrophy seen while using periosteal patches, have led to increased interest in utilizing bioabsorbable covers as an alternative. One such technique is matrix-induced chondrocyte implantation (MACI). The MACI membrane involves a porcine-derived collagen bilayer, which is seeded with the patient's harvested chondrocytes. MACI is a two-stage technique, which includes an arthroscopic evaluation of the chondral lesion and biopsied arthroscopically in the first stage and implanted generally through an arthrotomy in the second stage which is also applied by arthroscopic surgery<sup>[55]</sup>. During implantation, the graft is secured to the defect by fibrin glue alone, without sutures. Although there are several implants, Cares®, Hyalograft®, NeoCart®, Novocart®, Bioseed C®, Chondron®, Cartipatch®, Atelocollagen® are examples of implants containing autologous chondrocytes, which have produced satisfactory clinical results<sup>[56]</sup>.

Marlovits *et al*<sup>[56]</sup> reported 2 failures from 21 patients treated with ACI after 5 years and with MRI evaluation it was observed that in 80% of patients, defects had totally healed and integrated with peripheral chondral tissue. Eber *et al*<sup>[57]</sup> reported successful results in 20 patients treated with arthroscopic surgical technique and MACI after 2 years. The follow-up MRI showed 90% defect healing and 70% integration. Vijayan *et al*<sup>[58]</sup> observed good results in deep lesions > 8 mm with MACI, bone

graft and double layer MACI. Several studies have compared MACI with current treatment options<sup>[59,60]</sup>. Basad *et al*<sup>[59]</sup> performed microfracture in 20 patients and MACI in 40 patients with a defect size over 4 cm<sup>2</sup> and reported that MACI was superior to microfracture in the treatment of articular defects over 2 years. The MACI technique represents a significant advance in terms of reproducibility, safety, and reduced invasiveness. Zeifang *et al*<sup>[60]</sup> found no difference in clinical results between ACI and MACI in 21 patients after 2 years. Both treatments had similar results but MACI had significantly better scores in chondral healing when evaluated by MRI.

## CONCLUSION

Appropriate patient selection for articular cartilage lesion treatment is paramount to reduce symptoms and successfully improve function. In smaller lesions of up to 2.5 cm<sup>2</sup> in size, and in larger (up to 4 cm<sup>2</sup>) lesions in low-demand patients, debridement and microfracture are the most commonly used techniques. In lesions up to 4 cm<sup>2</sup>, and in high demand patients, AOT is a reliable method. Although indications of the use of microfracture plus scaffolds are not clear, this technique is commonly used in high demand patients with lesions of up to 4 cm<sup>2</sup>. However, in larger lesions more sophisticated cell based techniques such as ACI or MACI should be use.

In this article a treatment algorithm were formulated to help guide the decision.

Cartilage restoration techniques will most certainly evolve over the next several decades. With the addition of biological scaffolds and gene therapy techniques, the future holds much promise for patients for the natural healing of articular cartilage lesions. Alternative tissue techniques will be available to replace damaged articular cartilage or modifications of existing technology will lead to better results or fewer complications. Moreover, continued advances in arthroscopic techniques will allow procedures, which are commonly performed through an open arthrotomy, to be performed arthroscopically.

## REFERENCES

- 1 Hunter W. Of the structure and disease of articulating cartilages. 1743. *Clin Orthop Relat Res* 1995; **(317)**: 3-6 [PMID: 7671493]
- 2 Magnussen RA, Dunn WR, Carey JL, Spindler KP. Treatment of focal articular cartilage defects in the knee: a systematic review. *Clin Orthop Relat Res* 2008; **466**: 952-962 [PMID: 18196358 DOI: 10.1007/s11999-007-0097-z]
- 3 Frisbie DD, Oxford JT, Southwood L, Trotter GW, Rodkey WG, Steadman JR, Goodnight JL, McIlwraith CW. Early events in cartilage repair after subchondral bone microfracture. *Clin Orthop Relat Res* 2003; **(407)**: 215-227 [PMID: 12567150 DOI: 10.1097/00003086-200302000-00031]
- 4 Prakash D, Learmonth D. Natural progression of osteochondral defect in the femoral condyle. *Knee* 2002; **9**: 7-10 [PMID: 11830374 DOI: 10.1016/S0968-0160(01)00133-8]
- 5 Kock NB, Smolders JM, van Susante JL, Buma P, van Kampen A, Verdonchot N. A cadaveric analysis of contact stress restoration after osteochondral transplantation of a cylindrical cartilage defect. *Knee Surg Sports Traumatol*

- Arthrosc 2008; **16**: 461-468 [PMID: 18292989 DOI: 10.1007/s00167-008-0494-1]
- 6 **Messner K**, Maletius W. The long-term prognosis for severe damage to weight-bearing cartilage in the knee: a 14-year clinical and radiographic follow-up in 28 young athletes. *Acta Orthop Scand* 1996; **67**: 165-168 [PMID: 8623573 DOI: 10.3109/17453679608994664]
- 7 **Coons DA**, Barber FA. Arthroscopic osteochondral autografting. *Orthop Clin North Am* 2005; **36**: 447-458 [PMID: 16164950 DOI: 10.1016/j.ocl.2005.05.007]
- 8 **Nehrer S**, Chiari C, Domayer S, Barkay H, Yayon A. Results of chondrocyte implantation with a fibrin-hyaluronan matrix: a preliminary study. *Clin Orthop Relat Res* 2008; **466**: 1849-1855 [PMID: 18528742 DOI: 10.1007/s11999-008-0322-4]
- 9 **Sgaglione NA**, Miniaci A, Gillogly SD, Carter TR. Update on advanced surgical techniques in the treatment of traumatic focal articular cartilage lesions in the knee. *Arthroscopy* 2002; **18**: 9-32 [PMID: 11828343 DOI: 10.1053/jars.2002.31783]
- 10 **Outerbridge RE**. The etiology of chondromalacia patellae. 1961. *Clin Orthop Relat Res* 2001; **(389)**: 5-8 [PMID: 11501822 DOI: 10.1097/00003086-200108000-00002]
- 11 **Brittberg M**, Winalski CS. Evaluation of cartilage injuries and repair. *J Bone Joint Surg Am* 2003; **85-A Suppl 2**: 58-69 [PMID: 12721346]
- 12 **Mandelbaum BR**, Browne JE, Fu F, Micheli L, Mosely JB, Erggelet C, Minas T, Peterson L. Articular cartilage lesions of the knee. *Am J Sports Med* 1998; **26**: 853-861 [PMID: 9850792]
- 13 **Arøen A**, Løken S, Heir S, Alvik E, Ekeland A, Granlund OG, Engebretsen L. Articular cartilage lesions in 993 consecutive knee arthroscopies. *Am J Sports Med* 2004; **32**: 211-215 [PMID: 14754746 DOI: 10.1177/0363546503259345]
- 14 **Curl WW**, Krome J, Gordon ES, Rushing J, Smith BP, Poehling GG. Cartilage injuries: a review of 31,516 knee arthroscopies. *Arthroscopy* 1997; **13**: 456-460 [PMID: 9276052 DOI: 10.1016/S0749-8063(97)90124-9]
- 15 **Hjelle K**, Solheim E, Strand T, Muri R, Brittberg M. Articular cartilage defects in 1,000 knee arthroscopies. *Arthroscopy* 2002; **18**: 730-734 [PMID: 12209430 DOI: 10.1053/jars.2002.32839]
- 16 **Hangody L**, Sükösd L, Szabó Z. [Repair of cartilage defects. Technical aspects]. *Rev Chir Orthop Reparatrice Appar Mot* 1999; **85**: 846-857 [PMID: 10637886]
- 17 **Hangody L**, Füles P. Autologous osteochondral mosaicplasty for the treatment of full-thickness defects of weight-bearing joints: ten years of experimental and clinical experience. *J Bone Joint Surg Am* 2003; **85-A Suppl 2**: 25-32 [PMID: 12721342]
- 18 **Cole BJ**, Lee SJ. Complex knee reconstruction: articular cartilage treatment options. *Arthroscopy* 2003; **19 Suppl 1**: 1-10 [PMID: 14673413 DOI: 10.1016/j.arthro.2003.09.025]
- 19 **Magnuson PB**. Technic of debridement of the knee joint for arthritis. *Surg Clin North Am* 1946; **249-266** [PMID: 21015514]
- 20 **Jackson RW**. Arthroscopic surgery for osteoarthritis of the knee. *N Engl J Med* 2002; **347**: 1717-179; author reply 1717-1719 [PMID: 12444192 DOI: 10.1056/NEJM200211213472117]
- 21 **Krüger T**, Wohlrab D, Birke A, Hein W. Results of arthroscopic joint debridement in different stages of chondromalacia of the knee joint. *Arch Orthop Trauma Surg* 2000; **120**: 338-342 [PMID: 10853909 DOI: 10.1007/s004020050478]
- 22 **Health Quality Ontario**. Arthroscopic lavage and debridement for osteoarthritis of the knee: an evidence-based analysis. *Ont Health Technol Assess Ser* 2005; **5**: 1-37 [PMID: 23074463]
- 23 **Insall J**. The Pridie debridement operation for osteoarthritis of the knee. *Clin Orthop Relat Res* 1974; **(101)**: 61-67 [PMID: 4837919]
- 24 **Johnson LL**. Arthroscopic abrasion arthroplasty historical and pathologic perspective: present status. *Arthroscopy* 1986; **2**: 54-69 [PMID: 3954840 DOI: 10.1016/S0749-8063(86)80012-3]
- 25 **Shah MR**, Kaplan KM, Meislin RJ, Bosco JA. Articular cartilage restoration of the knee. *Bull NYU Hosp Jt Dis* 2007; **65**: 51-60 [PMID: 17539762]
- 26 **Chen H**, Sun J, Hoemann CD, Lascau-Coman V, Ouyang W, McKee MD, Shive MS, Buschmann MD. Drilling and microfracture lead to different bone structure and necrosis during bone-marrow stimulation for cartilage repair. *J Orthop Res* 2009; **27**: 1432-1438 [PMID: 19402150 DOI: 10.1002/jor.20905]
- 27 **Steadman JR**, Briggs KK, Rodrigo JJ, Kocher MS, Gill TJ, Rodkey WG. Outcomes of microfracture for traumatic chondral defects of the knee: average 11-year follow-up. *Arthroscopy* 2003; **19**: 477-484 [PMID: 12724676 DOI: 10.1053/jars.2003.50112]
- 28 **McNickle AG**, Provencher MT, Cole BJ. Overview of existing cartilage repair technology. *Sports Med Arthrosc* 2008; **16**: 196-201 [PMID: 19011550]
- 29 **Knutsen G**, Drogset JO, Engebretsen L, Grøntvedt T, Isaksen V, Ludvigsen TC, Roberts S, Solheim E, Strand T, Johansen O. A randomized trial comparing autologous chondrocyte implantation with microfracture. Findings at five years. *J Bone Joint Surg Am* 2007; **89**: 2105-2112 [PMID: 17908884 DOI: 10.2106/JBJS.G.00003]
- 30 **Kreuz PC**, Erggelet C, Steinwachs MR, Krause SJ, Lahm A, Niemeyer P, Ghanem N, Uhl M, Südkamp N. Is microfracture of chondral defects in the knee associated with different results in patients aged 40 years or younger? *Arthroscopy* 2006; **22**: 1180-1186 [PMID: 17084294 DOI: 10.1016/j.arthro.2006.06.020]
- 31 **Lim HC**, Bae JH, Song SH, Park YE, Kim SJ. Current treatments of isolated articular cartilage lesions of the knee achieve similar outcomes. *Clin Orthop Relat Res* 2012; **470**: 2261-2267 [PMID: 22422593 DOI: 10.1007/s11999-012-2304-9]
- 32 **Goyal D**, Keyhani S, Lee EH, Hui JH. Evidence-based status of microfracture technique: a systematic review of level I and II studies. *Arthroscopy* 2013; **29**: 1579-1588 [PMID: 23992991 DOI: 10.1016/j.arthro.2013.05.027]
- 33 **Wakitani S**, Kawaguchi A, Tokuhara Y, Takaoka K. Present status of and future direction for articular cartilage repair. *J Bone Miner Metab* 2008; **26**: 115-122 [PMID: 18301966 DOI: 10.1007/s00774-007-0802-8]
- 34 **Negrin L**, Kutscha-Lissberg F, Gartlehner G, Vecsei V. Clinical outcome after microfracture of the knee: a meta-analysis of before/after-data of controlled studies. *Int Orthop* 2012; **36**: 43-50 [PMID: 21968797 DOI: 10.1007/s00264-011-1364-x]
- 35 **Liu Q**, Wang F, Yang L. [Research progress of articular cartilage scaffold for tissue engineering]. *Zhongguo XiuFu ChongJian Waike Zazhi* 2012; **26**: 1247-1250 [PMID: 23167113]
- 36 **Filardo G**, Kon E, Roffi A, Di Martino A, Marcacci M. Scaffold-based repair for cartilage healing: a systematic review and technical note. *Arthroscopy* 2013; **29**: 174-186 [PMID: 23159494 DOI: 10.1016/j.arthro.2012.05.891]
- 37 **Siclari A**, Mascaro G, Gentili C, Cancedda R, Boux E. A cell-free scaffold-based cartilage repair provides improved function hyaline-like repair at one year. *Clin Orthop Relat Res* 2012; **470**: 910-919 [PMID: 21965060 DOI: 10.1007/s11999-011-2107-4]
- 38 **Gille J**, Behrens P, Volpi P, de Girolamo L, Reiss E, Zoch W, Anders S. Outcome of Autologous Matrix Induced Chondrogenesis (AMIC) in cartilage knee surgery: data of the AMIC Registry. *Arch Orthop Trauma Surg* 2013; **133**: 87-93 [PMID: 23070222 DOI: 10.1007/s00402-012-1621-5]
- 39 **Hangody L**, Ráthonyi GK, Duska Z, Vászárhelyi G, Füles P, Módis L. Autologous osteochondral mosaicplasty. Surgical technique. *J Bone Joint Surg Am* 2004; **86-A Suppl 1**: 65-72 [PMID: 14996923]
- 40 **Ollat D**, Lebel B, Thaumat M, Jones D, Mainard L, Dubrana F, Versier G. Mosaic osteochondral transplantations in the knee joint, midterm results of the SFA multicenter study. *Orthop Traumatol Surg Res* 2011; **97**: S160-S166 [PMID: 22036243 DOI: 10.1016/j.otsr.2011.08.005]



- 41 **Solheim E**, Hegna J, Øyen J, Harlem T, Strand T. Results at 10 to 14 years after osteochondral autografting (mosaicplasty) in articular cartilage defects in the knee. *Knee* 2013; **20**: 287-290 [PMID: 23482060 DOI: 10.1016/j.knee.2013.01.001]
- 42 **Haklar U**, Tüzüner T, Kocaoğlu B, Güven O. [Mosaicplasty technique in the treatment of osteochondral lesions of the knee]. *Acta Orthop Traumatol Turc* 2008; **42**: 344-349 [PMID: 19158455 DOI: 10.3944/AOTT.2008.344]
- 43 **Gudas R**, Gudaite A, Pocius A, Gudiene A, Cekanauskas E, Monastyreckiene E, Basevicius A. Ten-year follow-up of a prospective, randomized clinical study of mosaic osteochondral autologous transplantation versus microfracture for the treatment of osteochondral defects in the knee joint of athletes. *Am J Sports Med* 2012; **40**: 2499-2508 [PMID: 23024150 DOI: 10.1177/0363546512458763]
- 44 **Yamashita F**, Sakakida K, Suzu F, Takai S. The transplantation of an autogeneic osteochondral fragment for osteochondritis dissecans of the knee. *Clin Orthop Relat Res* 1985; (**201**): 43-50 [PMID: 3905131]
- 45 **Hangody L**, Kish G, Kárpáti Z, Szerb I, Udvarhelyi I. Arthroscopic autogenous osteochondral mosaicplasty for the treatment of femoral condylar articular defects. A preliminary report. *Knee Surg Sports Traumatol Arthrosc* 1997; **5**: 262-267 [PMID: 9430578 DOI: 10.1007/s001670050061]
- 46 **Giorgini A**, Donati D, Cevolani L, Frisoni T, Zambianchi F, Catani F. Fresh osteochondral allograft is a suitable alternative for wide cartilage defect in the knee. *Injury* 2013; **44** Suppl 1: S16-S20 [PMID: 23351864 DOI: 10.1016/S0020-1383(13)70005-6]
- 47 **Chahal J**, Gross AE, Gross C, Mall N, Dwyer T, Chahal A, Whelan DB, Cole BJ. Outcomes of osteochondral allograft transplantation in the knee. *Arthroscopy* 2013; **29**: 575-588 [PMID: 23544690 DOI: 10.1016/j.arthro.2012.12.002]
- 48 **Brittberg M**, Lindahl A, Nilsson A, Ohlsson C, Isaksson O, Peterson L. Treatment of deep cartilage defects in the knee with autologous chondrocyte transplantation. *N Engl J Med* 1994; **331**: 889-895 [PMID: 8078550 DOI: 10.1056/NEJM199410063311401]
- 49 **Bekkers JE**, Inklaar M, Saris DB. Treatment selection in articular cartilage lesions of the knee: a systematic review. *Am J Sports Med* 2009; **37** Suppl 1: 148S-155S [PMID: 19934442 DOI: 10.1177/0363546509351143]
- 50 **Harris JD**, Siston RA, Pan X, Flanigan DC. Autologous chondrocyte implantation: a systematic review. *J Bone Joint Surg Am* 2010; **92**: 2220-2233 [PMID: 20844166 DOI: 10.2106/JBJS.J.00049]
- 51 **Bhosale AM**, Kuiper JH, Johnson WE, Harrison PE, Richardson JB. Midterm to long-term longitudinal outcome of autologous chondrocyte implantation in the knee joint: a multilevel analysis. *Am J Sports Med* 2009; **37** Suppl 1: 131S-138S [PMID: 19861698 DOI: 10.1177/0363546509350555]
- 52 **Moseley JB**, Anderson AF, Browne JE, Mandelbaum BR, Micheli LJ, Fu F, Erggelet C. Long-term durability of autologous chondrocyte implantation: a multicenter, observational study in US patients. *Am J Sports Med* 2010; **38**: 238-246 [PMID: 20448191 DOI: 10.1177/0363546509348000]
- 53 **Vanlauwe J**, Saris DB, Victor J, Almqvist KF, Bellemans J, Luyten FP. Five-year outcome of characterized chondrocyte implantation versus microfracture for symptomatic cartilage defects of the knee: early treatment matters. *Am J Sports Med* 2011; **39**: 2566-2574 [PMID: 21908720 DOI: 10.1177/0363546511422220]
- 54 **Bentley G**, Biant LC, Vijayan S, Macmull S, Skinner JA, Carrington RW. Minimum ten-year results of a prospective randomised study of autologous chondrocyte implantation versus mosaicplasty for symptomatic articular cartilage lesions of the knee. *J Bone Joint Surg Br* 2012; **94**: 504-509 [PMID: 22434467 DOI: 10.1302/0301-620X.94B4.27495]
- 55 **Abelow SP**, Guillen P, Ramos T. Arthroscopic technique for matrix-induced autologous chondrocyte implantation for the treatment of large chondral defects in the knee and ankle. *Oper Tech Orthop* 2006; **16**: 257-261 [DOI: 10.1053/j.oto.2006.08.006]
- 56 **Marlovits S**, Aldrian S, Wondrasch B, Zak L, Albrecht C, Welsch G, Trattng S. Clinical and radiological outcomes 5 years after matrix-induced autologous chondrocyte implantation in patients with symptomatic, traumatic chondral defects. *Am J Sports Med* 2012; **40**: 2273-2280 [PMID: 22922521 DOI: 10.1177/0363546512457008]
- 57 **Ebert JR**, Fallon M, Ackland TR, Wood DJ, Janes GC. Arthroscopic matrix-induced autologous chondrocyte implantation: 2-year outcomes. *Arthroscopy* 2012; **28**: 952-964.e1-2 [PMID: 22483735 DOI: 10.1016/j.arthro.2011.12.022]
- 58 **Vijayan S**, Bartlett W, Bentley G, Carrington RW, Skinner JA, Pollock RC, Alorjani M, Briggs TW. Autologous chondrocyte implantation for osteochondral lesions in the knee using a bilayer collagen membrane and bone graft: a two- to eight-year follow-up study. *J Bone Joint Surg Br* 2012; **94**: 488-492 [PMID: 22434464 DOI: 10.1302/0301-620X.94B4.27117]
- 59 **Basad E**, Ishaque B, Bachmann G, Stürz H, Steinmeyer J. Matrix-induced autologous chondrocyte implantation versus microfracture in the treatment of cartilage defects of the knee: a 2-year randomised study. *Knee Surg Sports Traumatol Arthrosc* 2010; **18**: 519-527 [PMID: 20062969 DOI: 10.1007/s00167-009-1028-1]
- 60 **Zeifang F**, Oberle D, Nierhoff C, Richter W, Moradi B, Schmitt H. Autologous chondrocyte implantation using the original periosteum-cover technique versus matrix-associated autologous chondrocyte implantation: a randomized clinical trial. *Am J Sports Med* 2010; **38**: 924-933 [PMID: 19966102 DOI: 10.1177/0363546509351499]

P- Reviewer: Zhou S S- Editor: Wen LL L- Editor: A  
E- Editor: Wu HL





## Management of proximal humerus fractures in adults

Leonidas Vachtsevanos, Lydia Hayden, Aravind S Desai, Asterios Dramis

Leonidas Vachtsevanos, Lydia Hayden, Department of Trauma and Orthopaedics, Abertawe Bro Morgannwg University Health Board, Swansea SA6 6NL, United Kingdom

Aravind S Desai, Department of Trauma and Orthopaedics, Newcastle upon Tyne Hospitals NHS Foundation Trust, Newcastle-upon-Tyne, NE7 7DN, United Kingdom

Asterios Dramis, Department of Trauma and Orthopaedics, University Hospital of Wales, Cardiff CF14 4XW, United Kingdom

Author contributions: Vachtsevanos L, Hayden L, Desai AS, Dramis A contributed to conception and design of the study, analysis and interpretation of data; Vachtsevanos L, Hayden L performed the literature review; Vachtsevanos L drafted the article; Dramis A, Desai AS revised the article; all the authors read and approved the final manuscript.

Correspondence to: Asterios Dramis, BM, MSc, MRCS, FEBOT, FRCS (Orth), Senior Trauma Fellow, Department of Trauma and Orthopaedics, University Hospital of Wales, Heath Park, Cardiff CF14 4XW, United Kingdom. [ad199@doctors.org.uk](mailto:ad199@doctors.org.uk)

Telephone: +44-12-14403044 Fax: +44-29-20716310

Received: January 29, 2014 Revised: July 6, 2014

Accepted: July 15, 2014

Published online: November 18, 2014

### Abstract

The majority of proximal humerus fractures are low-energy osteoporotic injuries in the elderly and their incidence is increasing in the light of an ageing population. The diversity of fracture patterns encountered renders objective classification of prognostic value challenging. Non-operative management has been associated with good functional outcomes in stable, minimally displaced and certain types of displaced fractures. Absolute indications for surgery are infrequent and comprise compound, pathological, multi-fragmentary head-splitting fractures and fracture dislocations, as well as those associated with neurovascular injury. A constantly expanding range of reconstructive and replacement options however has been extending the indications for surgical management of complex proximal humerus fractures. As a result, management decisions are becoming increasingly complicated, in an attempt to provide the best possible treatment for each indi-

vidual patient, that will successfully address their specific fracture configuration, comorbidities and functional expectations. Our aim was to review the management options available for the full range of proximal humerus fractures in adults, along with their specific advantages, disadvantages and outcomes.

© 2014 Baishideng Publishing Group Inc. All rights reserved.

**Key words:** Proximal humerus fracture; Reconstruction; Non-operative management; Hemiarthroplasty; Reverse polarity total shoulder arthroplasty

**Core tip:** Non-operative management is associated with good outcomes in the majority of proximal humerus fractures in adults. There is currently insufficient evidence to suggest superiority of one treatment option over the others. Any surgical intervention should have clear aims and indications and the appropriate technique should be selected for each individual patient. Decision-making should involve detailed fracture evaluation, careful patient selection with thorough consideration of individual patient characteristics, comorbidities and functional expectations and profound understanding of the benefits and limitations of each management option.

Vachtsevanos L, Hayden L, Desai AS, Dramis A. Management of proximal humerus fractures in adults. *World J Orthop* 2014; 5(5): 685-693 Available from: URL: <http://www.wjgnet.com/2218-5836/full/v5/i5/685.htm> DOI: <http://dx.doi.org/10.5312/wjo.v5.i5.685>

### INTRODUCTION

#### Epidemiology

Fractures of the proximal humerus are relatively common injuries in adults, representing 4%-5% of all fractures presenting to the accident and emergency department<sup>[1]</sup> and approximately 5% of fractures of the ap-

pendicular skeleton<sup>[2,3]</sup>. The vast majority are low-energy osteoporotic fractures resulting from simple falls from standing height<sup>[4]</sup> with a 2-3 to 1 female to male preponderance<sup>[2,3,5]</sup>.

### Classification

Proximal humerus fractures may either occur in isolation or be associated with concurrent dislocation of the glenohumeral joint. Additional injuries to the shoulder girdle may also be present, such as co-existing scapular fractures giving rise to the “floating shoulder” variety. As such, a wide range of fracture patterns has been described<sup>[6-10]</sup>, rendering accurate and reproducible classification of prognostic value complex and difficult. Neer’s classification<sup>[10]</sup> remains the most commonly used system<sup>[11]</sup>, although additional classification systems have been described more recently<sup>[12-14]</sup>.

Neer’s classification system is based on six groups and four main fracture segments (parts) comprising the head, greater tuberosity, lesser tuberosity and shaft<sup>[10]</sup>. Displacement is defined as more than 1cm of translation or 45 degrees of angulation of the respective fracture part. Group I includes all fracture configurations with *minimum displacement*. Group II includes two-part fractures of the anatomical neck with *articular-segment displacement*. Group III comprises three types of displaced two-part surgical neck fractures (*i.e.*, angulated, separated and comminuted surgical neck fractures) with *shaft displacement*. Group IV consists of two- or three-part fractures with *greater tuberosity displacement*. Group V includes two- or three-part fractures with *lesser tuberosity displacement*. Groups IV and V merge in the four-part fracture where both tuberosities are displaced in addition to the head and shaft. Group VI comprises true *fracture-dislocation* of two-, three- or four-part fractures with ligamentous injury and is subdivided into anterior and posterior dislocations of the glenohumeral joint and partial dislocations of the humeral head with articular surface fractures (*i.e.*, impression fracture and head-splitting fracture).

The AO/OTA classification employs a combination of letters and numbers to describe different levels and patterns of proximal humerus fractures. Proximal humerus fractures are described as 11 fractures with further subdivision into unifocal extra-articular denoted as 11-A, bifocal extra-articular denoted as 11-B and articular fractures denoted as 11-C. Further numbers are assigned according to fracture configuration with 3 representing more complex configurations than 1 and 2, giving rise to a total of twenty-seven subtypes<sup>[14]</sup>.

Nevertheless, both interobserver reliability and intraobserver reproducibility of proximal humerus fracture classification systems have been shown to be poor<sup>[15]</sup>, even when 3-D CT reconstructions are utilised<sup>[16,17]</sup>.

### Radiological assessment

Plain radiographs are the main baseline investigation for the diagnosis, classification and management planning of proximal humerus fractures. The proximal humerus should be imaged in a minimum of two planes. Routine

assessment includes true anteroposterior and either transcapular “Y” or axillary lateral views, if tolerated by the patient. Additional investigations are then performed as necessary, on the basis of clinical and plain radiographic findings.

Doppler ultrasound examination may be used for the evaluation of associated vascular injuries, as well as of concomitant rotator cuff tears.

Computerised tomography (CT) is employed in the evaluation of complex fracture patterns, whilst it also allows quantification of available bone stock and assessment of the extent and position of fracture union.

CT angiography may accurately diagnose and guide interventional management of co-existing arterial injuries.

Magnetic resonance arthrography and angiography are additional high-quality imaging tools for the assessment of periarticular soft tissue and vascular injuries respectively.

### Aim of study

The challenges of proximal humerus fracture classification, alongside individual patient characteristics and functional expectations, surgeon expertise, implant characteristics and availability of rehabilitation services render management decisions complicated and difficult. Our aim was therefore to perform a concise review of the available literature on the current management options of these complex injuries, with a particular focus on their respective advantages, disadvantages and outcomes.

## LITERATURE REVIEW

A thorough literature search of the Embase, Ovid Medline(R), Ovid Medline(R) In-Process and Other Non-Indexed Citations, Ovid Journals and the Cochrane Library databases was conducted by two investigators. The search terms used included the title terms proximal AND humerus AND fractur\* and the limits were set to adult (> 19 years of age) human trials, English language and published in the last 5 years. This search yielded 368 hits.

PubMed was also searched using the following MeSH term search strategy: (“Shoulder Fractures/analysis” [Majr] OR “Shoulder Fractures/anatomy and histology” [Majr] OR “Shoulder Fractures/classification” [Majr] OR “Shoulder Fractures/complications” [Majr] OR “Shoulder Fractures/diagnosis” [Majr] OR “Shoulder Fractures/epidemiology” [Majr] OR “Shoulder Fractures/etiology” [Majr] OR “Shoulder Fractures/history” [Majr] OR “Shoulder Fractures/mortality” [Majr] OR “Shoulder Fractures/physiopathology” [Majr] OR “Shoulder Fractures/prevention and control” [Majr] OR “Shoulder Fractures/radiography” [Majr] OR “Shoulder Fractures/rehabilitation” [Majr] OR “Shoulder Fractures/surgery” [Majr] OR “Shoulder Fractures/therapy” [Majr]), which yielded an additional 1738 hits. Limiting these to Clinical Trials, Controlled Clinical Trials and Reviews in Humans published within the last 5 years resulted in 112 hits.

The 480 studies obtained were searched manually for exclusion of duplicate hits and irrelevant publications. Case reports, studies focusing on pain management and biology of fracture healing were excluded. Additional relevant studies were identified through scrutinising the reference lists of the studies included.

## DISCUSSION

The management of proximal humerus fractures in adults encompasses a constantly expanding range of non-operative, reconstructive and prosthetic replacement options. Good outcomes are highly dependent upon appropriate management decisions, which should be based on a thorough, combined evaluation of fracture-, patient- and treatment centre-related factors.

### Non-operative management

Conservative treatment generally consists of analgesia and a period of immobilisation in a sling, with various rehabilitation and physiotherapy regimes. Early physiotherapy commencing within two weeks from injury has been associated with better functional results than prolonged immobilisation<sup>[18-20]</sup>. Hanging casts are perceived to be less useful than simple collar and cuff slings, as they do not seem to improve reduction and may in fact contribute to fracture distraction and non-union<sup>[21,22]</sup>. Hospital admission may be required in up to 43% of patients, as the majority of these injuries tend to be osteoporotic fractures in elderly patients culminating in loss of independence and inability to cope<sup>[5]</sup>.

Complications encountered with closed treatment include malunion, subacromial impingement, avascular necrosis, shoulder pain and stiffness secondary to osteoarthritis and rotator cuff deficiency<sup>[22]</sup>. Most conservatively treated fractures will progress to full union with an estimated risk of non-union between 1.1% and 10%<sup>[23]</sup>.

A number of studies have revealed very good functional results in conservatively managed minimally displaced, stable fractures of the proximal humerus<sup>[10,18,24]</sup>. Such fractures were classified by Neer as group I fractures, and were estimated to comprise over 85% of all proximal humerus fractures<sup>[10]</sup>. More recent studies have reported lower rates of minimally displaced fractures, ranging between 42% and 49%<sup>[4,5]</sup>. Despite higher rates of displaced fractures however, the majority of patients are still being treated non-operatively, in view of their advanced age at presentation, lower functional demands and significant comorbidities<sup>[5]</sup>.

Non-operative management has also been successful in certain types of displaced fractures. These include translated two-part fractures of the proximal humerus with minimal alteration of the neck-shaft angle<sup>[24]</sup>, valgus and varus impacted fractures of the proximal humerus<sup>[7,8]</sup>. Increasing degrees of displacement and instability, as seen in conservatively managed Neer three- and four-part fracture configurations, are associated with less optimal results than one- or two-part fractures<sup>[21]</sup>. Certain

types of fixation of however, have been shown to confer no benefit to non-operative management in unstable displaced Neer three- and four-part fractures<sup>[25]</sup>.

### Operative management

Operative interventions for the management of proximal humerus fractures are constantly evolving and may be broadly classified into reconstructive and prosthetic replacement options.

### Reconstruction

A wide range of joint preserving reconstructive techniques have been employed in the management of proximal humerus fractures. These aim to reduce complications and optimize function by restoring anatomy and conferring stability for early rehabilitation and promotion of fracture union. Reduction may be achieved closed, through a minimally invasive approach (mini-open) or open, while fixation may be performed percutaneously (pins, wires, screws) or internally (intramedullary nails, trans-osseous sutures, tension-band constructs or plates and screws).

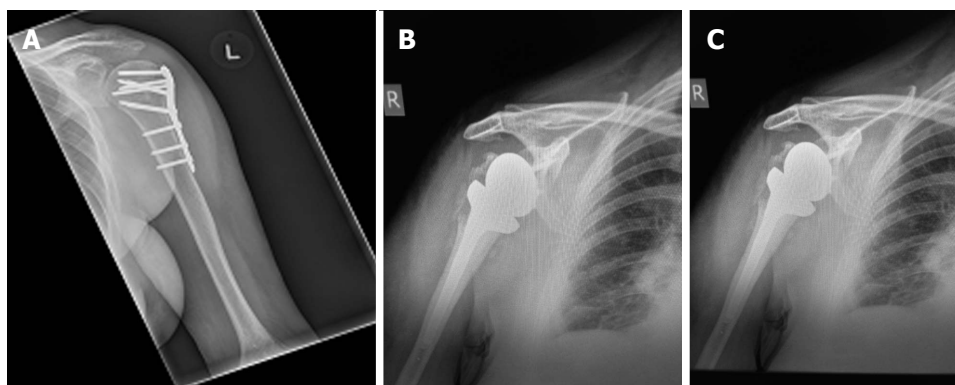
#### Closed or mini-open reduction and percutaneous fixation

This technique utilizes image intensifier-guided closed manipulation or mini-open fracture reduction by means of 'joystick' pins, followed by fixation with a constellation of threaded pins to confer stability<sup>[26]</sup>. Its main advantages include soft-tissue preservation, cosmesis, reduced blood loss and postoperative pain. Disadvantages include possibility of axillary nerve injury during percutaneous pin insertion<sup>[27,28]</sup>, fixation failure<sup>[29]</sup>, intra-articular pin migration during fracture collapse leading to re-operation and need for elective removal of metalwork<sup>[30]</sup>.

Stable fixation to allow early range of motion has been demonstrated in patients with two- and three-part fractures fixed percutaneously with 2.5 mm threaded Schanz or Dynamic Hip Screw guide pins, alongside good functional results and a union rate of 94% at an average of 2.6 mo<sup>[29]</sup>. This type of fixation however is not suitable for patients with four-part fractures, due to a high risk of avascular necrosis and fixation failure. Herscovici *et al*<sup>[29]</sup> have also demonstrated a 100% failure rate with smooth Kirschner wires and recommend the use of threaded pins. Brunner *et al*<sup>[30]</sup> have shown successful maintenance of reduction in 91% of 58 displaced proximal humerus fractures treated with the "humerus block". They have reported no intraoperative complications, but had a 40% unplanned re-operation rate, secondary to wire migration and associated fracture displacement<sup>[30]</sup>.

#### Closed or open reduction and intramedullary nailing

Closed or open reduction and internal fixation by means of a statically locked intramedullary nail is a further joint preserving reconstructive option. Nails are usually inserted anterogradely through a small proximal incision and locked percutaneously. As such, they allow preservation



**Figure 1 Plain radiograph.** A: Showing internal fixation of a left proximal humerus fracture with a locking plate; B: Showing a cemented right shoulder hemiarthroplasty; C: Showing a reverse polarity right total shoulder arthroplasty.

of the periosteal blood supply and surrounding soft tissue envelope, whilst their intramedullary position confers greater stability than other minimally invasive fixation techniques. The benefits of soft tissue preservation and enhanced biomechanical stability render long nails ideal for internal stabilisation of severely osteoporotic and pathological fractures and for prophylactic fixation of impending pathological fractures. In this context, long nails provide protection from additional periprosthetic and skip lesion fractures and allow adjuvant radiotherapy to proceed as necessary with minimal wound healing concerns.

A number of studies using a range of intramedullary nails have produced good results with union rates between 96% and 100%<sup>[31-34]</sup> in patients with two- and three-part fractures. In a prospective randomised trial comparing locking intramedullary nails to locking plates in the treatment of two-part surgical neck fractures, the authors reported less complications in the nail cohort with equivalent functional scores between the two groups at three years<sup>[35]</sup>.

Complications reported include avascular necrosis and pain especially in four-part fractures<sup>[36]</sup>, proximal screw migration<sup>[31,34]</sup>, loss of proximal fixation<sup>[37,38]</sup>, infection, non-union, impingement<sup>[31]</sup> and rotator cuff pain and dysfunction<sup>[39]</sup>. Entry point proximity to the rotator cuff tendons may lead to long-term rotator cuff dysfunction-related morbidity, though new designs of straight instead of curvilinear nails have shown reduced rates of rotator cuff-related symptoms and re-operations<sup>[39]</sup>.

### Open reduction and internal fixation

Open reduction can be achieved through various approaches to the proximal humerus. The extended deltopectoral approach remains the most commonly utilised exposure, despite its limited access to the lateral and posterior aspects of the proximal humerus<sup>[40]</sup>. An alternative extended deltoid-splitting approach has been described, with a view to improve access to the posterior aspect of the shoulder<sup>[41]</sup> through direct lateral<sup>[40]</sup> or anterolateral acromial incisions<sup>[42]</sup>. A recent study by Buecking *et al*<sup>[43]</sup> has demonstrated no difference in complications, re-operations, fluoroscopy use, function and pain scores

between the extended deltoid-splitting and the anterior deltopectoral approach.

Internal fixation has historically been achieved through various implants and techniques ranging from trans-osseous suture fixation<sup>[44]</sup> and tension-band wiring of fracture fragments<sup>[25]</sup> to application of semi-tubular<sup>[45]</sup>, buttress and cloverleaf plates. These have currently been superseded by the use of pre-contoured mono- or polyaxial locking proximal humerus plates<sup>[22,46]</sup>, which have been shown to significantly increase fixation stability in osteoporotic bone<sup>[38,47,48]</sup> (Figure 1A).

Proximal humerus locking plates may provide reliable fixation in two-, three- and four-part fractures, as well as in some pathological fractures of the proximal humerus<sup>[49]</sup>, particularly when used in conjunction with cement augmentation<sup>[50]</sup>. Application of the plate may facilitate indirect reduction of the distal diaphyseal fragment to the proximal parts, upon insertion of the working screw<sup>[49]</sup>. Through a combination of meticulous plate application and appropriately placed rotator cuff tendon fibre-wire suture loops, near anatomical indirect reduction of the tuberosities to the head and shaft fragments becomes possible, without additional soft tissue stripping and compromise to the blood supply<sup>[49]</sup>. Locking plates may also be used in conjunction with bone autograft, allograft<sup>[51-53]</sup>, as well as devices such as the “Da Vinci System”<sup>[54]</sup>, in cases of comminuted fractures with substantial metaphyseal bone voids and loss of the medial column. As such, unstable three- and four-part fractures may be adequately reconstructed.

Anatomical reduction and restoration of the neck-shaft angle are of paramount importance in reducing the risk of locking plate fixation failure<sup>[55,56]</sup>, while several clinical and cadaveric studies have demonstrated the benefit of medial support screws in maintaining reduction of unstable three- and four-part fractures<sup>[57-59]</sup>. Good results with union rates of 97%-98% have been reported<sup>[60,61]</sup> and minimally invasive techniques have been developed to minimise soft tissue dissection<sup>[62]</sup>.

Complications include intra-articular screw penetration, subacromial impingement, varus collapse of fracture and osteonecrosis. These may lead to unplanned re-operations in 13%<sup>[60]</sup> to 19%<sup>[63]</sup> of patients, with a



predilection for those older than 60 years of age with unstable three- and four-part fractures<sup>[56,60]</sup>. In some patient series with high rates of three- and four-part fractures, revision surgery to arthroplasty was required in more than 50% of the patients, whilst screw penetration-mediated glenoid erosion, significantly limited revision options and adversely affected long-term outcomes<sup>[64]</sup>. Displaced four-part fractures and fracture-dislocations with a high risk of osteonecrosis may therefore qualify for primary replacement surgery, particularly in the elderly, low-demand patient.

In high-demand, younger patients however, it is the authors' opinion that reconstruction followed by close monitoring should be attempted first. In the event of failure, early conversion to hemiarthroplasty remains an option, whilst satisfactory tuberosity reduction at reconstruction, may improve function following revision to hemiarthroplasty. Non-reconstructible fractures may still be converted to hemiarthroplasty intraoperatively and adequate preoperative planning should allow for this.

### Replacement

Despite significant advances in surgical technique and a constantly expanding armamentarium of reconstructive options, adequate fixation of metalwork in osteoporotic bone remains a problem<sup>[61,64]</sup>. Joint replacement options for proximal humerus fractures include shoulder hemiarthroplasty, stemmed total shoulder and reverse polarity total shoulder replacements. These may be used either primarily in elderly patients with displaced four-part fractures, fracture dislocations and head-splitting fractures with a high risk of avascular necrosis, or as salvage procedures following failed reconstruction. Primary replacement surgery, however, is less attractive in young active patients, given the expected longevity of the prosthesis and potential need for several revision operations<sup>[65]</sup>.

### Hemiarthroplasty

Hemiarthroplasty is the most commonly used replacement option<sup>[66]</sup> (Figure 1B). It is indicated in non-reconstructible four-part fractures, fracture-dislocations and head-splitting fractures and for the revision of failed reconstructions, provided the tuberosities remain intact. A number of investigators have emphasised the importance of anatomical tuberosity re-attachment and proper implant positioning in terms of component version, height and offset in restoring rotator cuff function and optimising outcome following hemiarthroplasty<sup>[46,67-69]</sup>. The upper border of the pectoralis major tendon insertion provides a reliable landmark for estimation of prosthesis height and version<sup>[70]</sup> and its use has been associated with good clinical and radiological results<sup>[71]</sup>. Modular implant design improvements enable fine adjustments in the height, offset and version of the prosthesis following stem insertion and along with meticulous surgical technique and rehabilitation have been associated with better outcomes<sup>[67,72]</sup>. The overall implant survival for shoulder hemiarthroplasty has been reported to be 96.9% at one year, 95.3%

at five and 93.9% at ten years<sup>[69]</sup>.

In the event of revision surgery, certain modular implants allow conversion of hemiarthroplasty to total shoulder reverse polarity arthroplasty, without the need for stem removal and lead to shorter operative times and good mid-term outcomes<sup>[73]</sup>.

Complications reported with hemiarthroplasty include infection, dislocation, loosening, reflex sympathetic dystrophy, subacromial impingement, intraoperative or periprosthetic fractures, rotator cuff dysfunction secondary to tuberosity displacement and resorption and heterotopic ossification<sup>[22,74]</sup>. Poor results have been associated with advanced patient age, implant malpositioning resulting in head-glenoid mismatch, increasing degree of tuberosity displacement, persistent neurological deficit, postoperative complications requiring early re-operation and use of hemiarthroplasty for salvage of previous failed conservative management or operative reconstruction<sup>[67,69,72]</sup>. In the long-term, hemiarthroplasty has been shown to achieve satisfactory pain relief, but overall functional outcome remains less predictable<sup>[69,74,75]</sup>.

### Reverse polarity total shoulder arthroplasty

Reverse polarity total shoulder arthroplasty was originally designed to treat glenohumeral arthritis with rotator cuff arthropathy<sup>[76,77]</sup>. It is currently also employed in the management of proximal humerus fractures (Figure 1C), in which re-attachment of the tuberosities to a hemiarthroplasty is impossible<sup>[78-80]</sup>. Reverse polarity total shoulder arthroplasty may be inserted primarily or as a salvage of failed hemiarthroplasty secondary to glenoid arthritis or tuberosity resorption-induced shoulder pseudoparesis<sup>[81,82]</sup>.

Cuff *et al*<sup>[81]</sup> have compared primary hemiarthroplasty to primary reverse polarity total shoulder arthroplasty and noted improved forward elevation following reverse polarity total shoulder arthroplasty with similar complication rates between the two groups. In a further comparison by Boyle *et al*<sup>[83]</sup> reverse polarity total shoulder arthroplasty was associated with better 5-year functional outcomes compared to hemiarthroplasty, with similar revision and 1-year mortality rates. Previous studies have failed to demonstrate statistically significant differences between functional outcomes of hemiarthroplasty and reverse polarity total shoulder arthroplasty<sup>[84]</sup>. Forward elevation however, appears to be consistently slightly better in patients treated primarily with reverse polarity total shoulder arthroplasty<sup>[81,83-85]</sup>, albeit at the expense of increased treatment cost in a group of patients with potentially limited life expectancy<sup>[85]</sup>.

A high rate of complications with reverse polarity total shoulder arthroplasty has been reported by Brorson *et al*<sup>[66]</sup> in a recent systematic review of the literature. These included dislocation, infection, haematoma, instability, neurological injury, intraoperative and periprosthetic fracture, baseplate failure, reflex sympathetic dystrophy and scapular notching<sup>[66]</sup>, which in the long-term has been associated with component loosening and glenoid bone

loss<sup>[80]</sup>. Nevertheless, reverse polarity total shoulder arthroplasty remains a good option for independent elderly patients with non-reconstructible fractures and associated cuff deficiency, as well as a valuable salvage solution for failed first-line reconstructive or prosthetic replacement management.

## CONCLUSION

The management of proximal humerus fractures in adults is a challenging and demanding task. Good outcomes depend on detailed fracture evaluation, careful patient selection with thorough consideration of individual patient characteristics, comorbidities and functional expectations and advanced surgical expertise across a wide range of reconstructive and joint replacement options. A multi-disciplinary team approach should be utilised with experienced musculoskeletal radiologists, geriatricians and specialised physiotherapists for optimal rehabilitation.

Treatment of these complex injuries requires careful planning and should therefore be provided in centres, with appropriate resources and expertise in their management and rehabilitation. There is at present not enough evidence to suggest superiority of one treatment option over the others<sup>[11]</sup>. The ProFHER trial is an ongoing UK-based multi-centre randomised controlled trial that aims to compare the effectiveness and cost-effectiveness of surgical versus non-operative management for displaced fractures of the proximal humerus in adults<sup>[86]</sup>. Currently available evidence however suggests that treatment should be individualised and tailored to specific fracture-, patient- and treatment centre-related factors<sup>[46]</sup>.

## REFERENCES

- 1 Horak J, Nilsson BE. Epidemiology of fracture of the upper end of the humerus. *Clin Orthop Relat Res* 1975; **(112)**: 250-253 [PMID: 1192641]
- 2 Court-Brown CM, Caesar B. Epidemiology of adult fractures: A review. *Injury* 2006; **37**: 691-697 [PMID: 16814787 DOI: 10.1016/j.injury.2006.04.130]
- 3 Lind T, Krøner K, Jensen J. The epidemiology of fractures of the proximal humerus. *Arch Orthop Trauma Surg* 1989; **108**: 285-287 [PMID: 2789504]
- 4 Court-Brown CM, Garg A, McQueen MM. The epidemiology of proximal humeral fractures. *Acta Orthop Scand* 2001; **72**: 365-371 [PMID: 11580125 DOI: 10.1080/000164701753542023]
- 5 Roux A, Decroocq L, El Batti S, Bonnevalle N, Moineau G, Trojani C, Boileau P, de Peretti F. Epidemiology of proximal humerus fractures managed in a trauma center. *Orthop Traumatol Surg Res* 2012; **98**: 715-719 [PMID: 23000039 DOI: 10.1016/j.otsr.2012.05.013]
- 6 Robinson CM, Page RS. Severely impacted valgus proximal humeral fractures. Results of operative treatment. *J Bone Joint Surg Am* 2003; **85-A**: 1647-1655 [PMID: 12954821]
- 7 Court-Brown CM, Cattermole H, McQueen MM. Impacted valgus fractures (B1.1) of the proximal humerus. The results of non-operative treatment. *J Bone Joint Surg Br* 2002; **84**: 504-508 [PMID: 12043768]
- 8 Court-Brown CM, McQueen MM. The impacted varus (A2.2) proximal humeral fracture: prediction of outcome and results of nonoperative treatment in 99 patients. *Acta Orthop Scand* 2004; **75**: 736-740 [PMID: 15762264]
- 9 Robinson CM, Wylie JR, Ray AG, Dempster NJ, Olabi B, Seah KT, Akhtar MA. Proximal humeral fractures with a severe varus deformity treated by fixation with a locking plate. *J Bone Joint Surg Br* 2010; **92**: 672-678 [PMID: 20436005 DOI: 10.1302/0301-620x.92b5.22849]
- 10 Neer CS. Displaced proximal humeral fractures. I. Classification and evaluation. *J Bone Joint Surg Am* 1970; **52**: 1077-1089 [PMID: 5455339]
- 11 Handoll HH, Ollivere BJ, Rollins KE. Interventions for treating proximal humeral fractures in adults. *Cochrane Database Syst Rev* 2012; **12**: CD000434 [PMID: 23235575 DOI: 10.1002/14651858.CD000434.pub3]
- 12 Edelson G, Kelly I, Vigder F, Reis ND. A three-dimensional classification for fractures of the proximal humerus. *J Bone Joint Surg Br* 2004; **86**: 413-425 [PMID: 15125131]
- 13 Marsh JL, Slongo TF, Agel J, Broderick JS, Creevey W, DeCoster TA, Prokusi L, Sirkin MS, Ziran B, Henley B, Audigé L. Fracture and dislocation classification compendium - 2007: Orthopaedic Trauma Association classification, database and outcomes committee. *J Orthop Trauma* 2007; **21**: S1-133 [PMID: 18277234]
- 14 Müller ME, Koch P, Nazarian S. The comprehensive classification of fractures of long bones: Springer-Verlag Berlin; 1990
- 15 Sidor ML, Zuckerman JD, Lyon T, Koval K, Cuomo F, Schoenberg N. The Neer classification system for proximal humeral fractures. An assessment of interobserver reliability and intraobserver reproducibility. *J Bone Joint Surg Am* 1993; **75**: 1745-1750 [PMID: 8258543]
- 16 Foroohar A, Tosti R, Richmond JM, Gaughan JP, Ilyas AM. Classification and treatment of proximal humerus fractures: inter-observer reliability and agreement across imaging modalities and experience. *J Orthop Surg Res* 2011; **6**: 38 [PMID: 21801370 DOI: 10.1186/1749-1799X-6-38]
- 17 Bruinsma WE, Guitton TG, Warner JJ, Ring D. Interobserver reliability of classification and characterization of proximal humeral fractures: a comparison of two and three-dimensional CT. *J Bone Joint Surg Am* 2013; **95**: 1600-1604 [PMID: 24005201 DOI: 10.2106/JBJS.L.00586]
- 18 Koval KJ, Gallagher MA, Marsicano JG, Cuomo F, McShinaw A, Zuckerman JD. Functional outcome after minimally displaced fractures of the proximal part of the humerus. *J Bone Joint Surg Am* 1997; **79**: 203-207 [PMID: 9052540]
- 19 Kristiansen B, Angermann P, Larsen TK. Functional results following fractures of the proximal humerus. A controlled clinical study comparing two periods of immobilization. *Arch Orthop Trauma Surg* 1989; **108**: 339-341 [PMID: 2695009 DOI: 10.1007/BF00932441]
- 20 Lefevre-Colau MM, Babinet A, Fayad F, Fermanian J, Anract P, Roren A, Kansao J, Revel M, Poiraudau S. Immediate mobilization compared with conventional immobilization for the impacted nonoperatively treated proximal humeral fracture. A randomized controlled trial. *J Bone Joint Surg Am* 2007; **89**: 2582-2590 [PMID: 18056488 DOI: 10.2106/jbjs.f.01419]
- 21 Rasmussen S, Hvass I, Dalsgaard J, Christensen BS, Holstad E. Displaced proximal humeral fractures: results of conservative treatment. *Injury* 1992; **23**: 41-43 [PMID: 1541498]
- 22 Murray IR, Amin AK, White TO, Robinson CM. Proximal humeral fractures: current concepts in classification, treatment and outcomes. *J Bone Joint Surg Br* 2011; **93**: 1-11 [PMID: 21196536 DOI: 10.1302/0301-620x.93B1.25702]
- 23 Cadet ER, Yin B, Schulz B, Ahmad CS, Rosenwasser MP. Proximal humerus and humeral shaft nonunions. *J Am Acad Orthop Surg* 2013; **21**: 538-547 [PMID: 23996985 DOI: 10.5435/JAAOS-21-09-538]
- 24 Court-Brown CM, Garg A, McQueen MM. The translated two-part fracture of the proximal humerus. Epidemiology and outcome in the older patient. *J Bone Joint Surg Br* 2001;

- 83: 799-804 [PMID: 11521917]
- 25 **Zyto K**, Ahrengart L, Sperber A, Törnkvist H. Treatment of displaced proximal humeral fractures in elderly patients. *J Bone Joint Surg Br* 1997; **79**: 412-417 [PMID: 9180319]
  - 26 **Naidu SH**, Bixler B, Capo JT, Moulton MJ, Radin A. Percutaneous pinning of proximal humerus fractures: a biomechanical study. *Orthopedics* 1997; **20**: 1073-1076 [PMID: 9397435]
  - 27 **Kamineni S**, Ankem H, Sanghavi S. Anatomical considerations for percutaneous proximal humeral fracture fixation. *Injury* 2004; **35**: 1133-1136 [PMID: 15488504 DOI: 10.1016/j.injury.2003.08.008]
  - 28 **Rowles DJ**, McGrory JE. Percutaneous pinning of the proximal part of the humerus. An anatomic study. *J Bone Joint Surg Am* 2001; **83-A**: 1695-1699 [PMID: 11701793]
  - 29 **Herscovici D**, Saunders DT, Johnson MP, Sanders R, DiPasquale T. Percutaneous fixation of proximal humeral fractures. *Clin Orthop Relat Res* 2000; (**375**): 97-104 [PMID: 10853158]
  - 30 **Brunner A**, Weller K, Thormann S, Jöckel JA, Babst R. Closed reduction and minimally invasive percutaneous fixation of proximal humerus fractures using the Humerusblock. *J Orthop Trauma* 2010; **24**: 407-413 [PMID: 20577070 DOI: 10.1097/BOT.0b013e3181c81b1c]
  - 31 **Giannoudis PV**, Xypnitos FN, Dimitriou R, Manidakis N, Hackney R. "Internal fixation of proximal humeral fractures using the Polarus intramedullary nail: our institutional experience and review of the literature". *J Orthop Surg Res* 2012; **7**: 39 [PMID: 23253302 DOI: 10.1186/1749-799x-7-39]
  - 32 **Rajasekhar C**, Ray PS, Bhamra MS. Fixation of proximal humeral fractures with the Polarus nail. *J Shoulder Elbow Surg* 2001; **10**: 7-10 [PMID: 11182729 DOI: 10.1067/mse.2001.109556]
  - 33 **Sforzo CR**, Wright TW. Treatment of acute proximal humerus fractures with a polarus nail. *J Surg Orthop Adv* 2009; **18**: 28-34 [PMID: 19327263]
  - 34 **Popescu D**, Fernandez-Valencia JA, Rios M, Cuñé J, Domingo A, Prat S. Internal fixation of proximal humerus fractures using the T2-proximal humeral nail. *Arch Orthop Trauma Surg* 2009; **129**: 1239-1244 [PMID: 19066921 DOI: 10.1007/s00402-008-0789-1]
  - 35 **Zhu Y**, Lu Y, Shen J, Zhang J, Jiang C. Locking intramedullary nails and locking plates in the treatment of two-part proximal humeral surgical neck fractures: a prospective randomized trial with a minimum of three years of follow-up. *J Bone Joint Surg Am* 2011; **93**: 159-168 [PMID: 21248213 DOI: 10.2106/JBJS.J.00155]
  - 36 **Adedapo AO**, Ikpeke JO. The results of internal fixation of three- and four-part proximal humeral fractures with the Polarus nail. *Injury* 2001; **32**: 115-121 [PMID: 11223042]
  - 37 **Bernard J**, Charalambides C, Aderinto J, Mok D. Early failure of intramedullary nailing for proximal humeral fractures. *Injury* 2000; **31**: 789-792 [PMID: 11154749]
  - 38 **Foruria AM**, Carrascal MT, Revilla C, Munuera L, Sanchez-Sotelo J. Proximal humerus fracture rotational stability after fixation using a locking plate or a fixed-angle locked nail: the role of implant stiffness. *Clin Biomech (Bristol, Avon)* 2010; **25**: 307-311 [PMID: 20153916 DOI: 10.1016/j.clinbiomech.2010.01.009]
  - 39 **Lopez Y**, Garcia-Coiradas J, Garcia-Fernandez C, Marco F. Proximal humerus nailing: a randomized clinical trial between curvilinear and straight nails. *J Shoulder Elbow Surg* 2014; **23**: 369-376 [PMID: 24291047 DOI: 10.1016/j.jse.2013.08.023]
  - 40 **Robinson CM**, Murray IR. The extended deltoid-splitting approach to the proximal humerus: variations and extensions. *J Bone Joint Surg Br* 2011; **93**: 387-392 [PMID: 21357962 DOI: 10.1302/0301-620x.93b3.25818]
  - 41 **Robinson CM**, Khan L, Akhtar A, Whittaker R. The extended deltoid-splitting approach to the proximal humerus. *J Orthop Trauma* 2007; **21**: 657-662 [PMID: 17921842 DOI: 10.1097/BOT.0b013e3180ce833e]
  - 42 **Gardner MJ**, Boraiah S, Helfet DL, Lorich DG. The antero-lateral acromial approach for fractures of the proximal humerus. *J Orthop Trauma* 2008; **22**: 132-137 [PMID: 18349783 DOI: 10.1097/BOT.0b013e3181589f8c]
  - 43 **Buecking B**, Mohr J, Bockmann B, Zettl R, Ruchholtz S. Deltoid-split or deltopectoral approaches for the treatment of displaced proximal humeral fractures? *Clin Orthop Relat Res* 2014; **472**: 1576-1585 [PMID: 24326593 DOI: 10.1007/s11999-013-3415-7]
  - 44 **Dimakopoulos P**, Panagopoulos A, Kasimatis G. Transosseous suture fixation of proximal humeral fractures. Surgical technique. *J Bone Joint Surg Am* 2009; **91** Suppl 2 Pt 1: 8-21 [PMID: 19255196 DOI: 10.2106/JBJS.H.01290]
  - 45 **Sehr JR**, Szabo RM. Semitubular blade plate for fixation in the proximal humerus. *J Orthop Trauma* 1988; **2**: 327-332 [PMID: 3074161]
  - 46 **Maier D**, Jäger M, Strohm PC, Südkamp NP. Treatment of proximal humeral fractures - a review of current concepts enlightened by basic principles. *Acta Chir Orthop Traumatol Cech* 2012; **79**: 307-316 [PMID: 22980928]
  - 47 **Walsh S**, Reindl R, Harvey E, Berry G, Beckman L, Steffen T. Biomechanical comparison of a unique locking plate versus a standard plate for internal fixation of proximal humerus fractures in a cadaveric model. *Clin Biomech (Bristol, Avon)* 2006; **21**: 1027-1031 [PMID: 16919375 DOI: 10.1016/j.clinbiomech.2006.06.005]
  - 48 **Edwards SL**, Wilson NA, Zhang LQ, Flores S, Merk BR. Two-part surgical neck fractures of the proximal part of the humerus. A biomechanical evaluation of two fixation techniques. *J Bone Joint Surg Am* 2006; **88**: 2258-2264 [PMID: 17015605 DOI: 10.2106/jbjs.e.00757]
  - 49 **Plecko M**, Kraus A. Internal fixation of proximal humerus fractures using the locking proximal humerus plate. *Oper Orthop Traumatol* 2005; **17**: 25-50 [PMID: 16007377 DOI: 10.1007/s00064-005-1120-8]
  - 50 **Weiss KR**, Bhumbra R, Biau DJ, Griffin AM, Deheshi B, Wunder JS, Ferguson PC. Fixation of pathological humeral fractures by the cemented plate technique. *J Bone Joint Surg Br* 2011; **93**: 1093-1097 [PMID: 21768635 DOI: 10.1302/0301-620X.93B8.26194]
  - 51 **Russo R**, Visconti V, Lombardi LV, Ciccarelli M, Giudice G. The block-bridge system: a new concept and surgical technique to reconstruct articular surfaces and tuberosities in complex proximal humeral fractures. *J Shoulder Elbow Surg* 2008; **17**: 29-36 [PMID: 18069015 DOI: 10.1016/j.jse.2007.03.027]
  - 52 **Gerber C**, Werner CM, Vienne P. Internal fixation of complex fractures of the proximal humerus. *J Bone Joint Surg Br* 2004; **86**: 848-855 [PMID: 15330026]
  - 53 **Gardner MJ**, Boraiah S, Helfet DL, Lorich DG. Indirect medial reduction and strut support of proximal humerus fractures using an endosteal implant. *J Orthop Trauma* 2008; **22**: 195-200 [PMID: 18317054 DOI: 10.1097/BOT.0b013e31815b3922]
  - 54 **Russo R**, Visconti V, Lombardi LV, Ciccarelli M, Cautiero F. Da Vinci System: clinical experience with complex proximal humerus fractures. *Musculoskelet Surg* 2010; **94** Suppl 1: S57-S64 [PMID: 20383682 DOI: 10.1007/s12306-010-0066-7]
  - 55 **Lee CW**, Shin SJ. Prognostic factors for unstable proximal humeral fractures treated with locking-plate fixation. *J Shoulder Elbow Surg* 2009; **18**: 83-88 [PMID: 19095180 DOI: 10.1016/j.jse.2008.06.014]
  - 56 **Krappinger D**, Bizzotto N, Riedmann S, Kammerlander C, Hengg C, Kralinger FS. Predicting failure after surgical fixation of proximal humerus fractures. *Injury* 2011; **42**: 1283-1288 [PMID: 21310406 DOI: 10.1016/j.injury.2011.01.017]
  - 57 **Zhang L**, Zheng J, Wang W, Lin G, Huang Y, Zheng J, Edem Prince GA, Yang G. The clinical benefit of medial support screws in locking plating of proximal humerus fractures: a prospective randomized study. *Int Orthop* 2011; **35**: 1655-1661



- [PMID: 21387176 DOI: 10.1007/s00264-011-1227-5]
- 58 **Gardner MJ**, Weil Y, Barker JU, Kelly BT, Helfet DL, Lorch DG. The importance of medial support in locked plating of proximal humerus fractures. *J Orthop Trauma* 2007; **21**: 185-191 [PMID: 17473755 DOI: 10.1097/BOT.0b013e3180333094]
- 59 **Ponce BA**, Thompson KJ, Raghava P, Eberhardt AW, Tate JP, Volgas DA, Stannard JP. The role of medial comminution and calcar restoration in varus collapse of proximal humeral fractures treated with locking plates. *J Bone Joint Surg Am* 2013; **95**: e113(1-e1137) [PMID: 23965707 DOI: 10.2106/JBJS.K.00202]
- 60 **Owsley KC**, Gorczyca JT. Fracture displacement and screw cutout after open reduction and locked plate fixation of proximal humeral fractures [corrected]. *J Bone Joint Surg Am* 2008; **90**: 233-240 [PMID: 18245580 DOI: 10.2106/JBJS.F.01351]
- 61 **Moonot P**, Ashwood N, Hamlet M. Early results for treatment of three- and four-part fractures of the proximal humerus using the PHILOS plate system. *J Bone Joint Surg Br* 2007; **89**: 1206-1209 [PMID: 17905959 DOI: 10.1302/0301-620x.89b9.18528]
- 62 **Ruchholtz S**, Hauk C, Lewan U, Franz D, Kühne C, Zettl R. Minimally invasive polyaxial locking plate fixation of proximal humeral fractures: a prospective study. *J Trauma* 2011; **71**: 1737-1744 [PMID: 22182882 DOI: 10.1097/TA.0b013e31823f62e4]
- 63 **Konrad G**, Bayer J, Hepp P, Voigt C, Oestern H, Kääb M, Luo C, Plecko M, Wendt K, Köstler W, Südkamp N. Open reduction and internal fixation of proximal humeral fractures with use of the locking proximal humerus plate. Surgical technique. *J Bone Joint Surg Am* 2010; **92** Suppl 1 Pt 1: 85-95 [PMID: 20194347 DOI: 10.2106/JBJS.L.01462]
- 64 **Jost B**, Spross C, Grehn H, Gerber C. Locking plate fixation of fractures of the proximal humerus: analysis of complications, revision strategies and outcome. *J Shoulder Elbow Surg* 2013; **22**: 542-549 [PMID: 22959524 DOI: 10.1016/j.jse.2012.06.008]
- 65 **Soliman OA**, Koptan WM. Four-part fracture dislocations of the proximal humerus in young adults: results of fixation. *Injury* 2013; **44**: 442-447 [PMID: 23026114 DOI: 10.1016/j.injury.2012.09.005]
- 66 **Brorson S**, Rasmussen JV, Olsen BS, Frich LH, Jensen SL, Hróbjartsson A. Reverse shoulder arthroplasty in acute fractures of the proximal humerus: A systematic review. *Int J Shoulder Surg* 2013; **7**: 70-78 [PMID: 23960366 DOI: 10.4103/0973-6042.114225]
- 67 **Esen E**, Doğramaci Y, Gültekin S, Deveci MA, Suluova F, Kanatli U, Bölükbaşı S. Factors affecting results of patients with humeral proximal end fractures undergoing primary hemiarthroplasty: a retrospective study in 42 patients. *Injury* 2009; **40**: 1336-1341 [PMID: 19595326 DOI: 10.1016/j.injury.2009.06.019]
- 68 **Krause FG**, Huebschle L, Hertel R. Reattachment of the tuberosities with cable wires and bone graft in hemiarthroplasties done for proximal humeral fractures with cable wire and bone graft: 58 patients with a 22-month minimum follow-up. *J Orthop Trauma* 2007; **21**: 682-686 [PMID: 17986884 DOI: 10.1097/BOT.0b013e31815917e0]
- 69 **Robinson CM**, Page RS, Hill RM, Sanders DL, Court-Brown CM, Wakefield AE. Primary hemiarthroplasty for treatment of proximal humeral fractures. *J Bone Joint Surg Am* 2003; **85-A**: 1215-1223 [PMID: 12851345]
- 70 **Torreans C**, Corrales M, Melendo E, Solano A, Rodríguez-Baeza A, Cáceres E. The pectoralis major tendon as a reference for restoring humeral length and retroversion with hemiarthroplasty for fracture. *J Shoulder Elbow Surg* 2008; **17**: 947-950 [PMID: 18774736 DOI: 10.1016/j.jse.2008.05.041]
- 71 **Greiner SH**, Kääb MJ, Kröning I, Scheibel M, Perka C. Reconstruction of humeral length and centering of the prosthetic head in hemiarthroplasty for proximal humeral fractures. *J Shoulder Elbow Surg* 2008; **17**: 709-714 [PMID: 18621554 DOI: 10.1016/j.jse.2008.03.004]
- 72 **Taller S**, Krivohlávek M, Lukás R, Srám J, Král M. Hemiarthroplasty for management of proximal humeral fractures. *Acta Chir Orthop Traumatol Cech* 2007; **74**: 262-267 [PMID: 17877943]
- 73 **Castagna A**, Delcogliano M, de Caro F, Ziveri G, Borroni M, Gumina S, Postacchini F, De Biase CF. Conversion of shoulder arthroplasty to reverse implants: clinical and radiological results using a modular system. *Int Orthop* 2013; **37**: 1297-1305 [PMID: 23685831 DOI: 10.1007/s00264-013-1907-4]
- 74 **Kontakis G**, Koutras C, Tosounidis T, Giannoudis P. Early management of proximal humeral fractures with hemiarthroplasty: a systematic review. *J Bone Joint Surg Br* 2008; **90**: 1407-1413 [PMID: 18978256 DOI: 10.1302/0301-620X.90B11.21070]
- 75 **Antuña SA**, Sperling JW, Cofield RH. Shoulder hemiarthroplasty for acute fractures of the proximal humerus: a minimum five-year follow-up. *J Shoulder Elbow Surg* 2008; **17**: 202-209 [PMID: 18248746 DOI: 10.1016/j.jse.2007.06.025]
- 76 **Baulot E**, Sirveaux F, Boileau P. Grammont's idea: The story of Paul Grammont's functional surgery concept and the development of the reverse principle. *Clin Orthop Relat Res* 2011; **469**: 2425-2431 [PMID: 21210311 DOI: 10.1007/s11999-010-1757-y]
- 77 **Grammont PM**, Baulot E. Delta shoulder prosthesis for rotator cuff rupture. *Orthopedics* 1993; **16**: 65-68 [PMID: 8421661]
- 78 **Lenarz C**, Shishani Y, McCrum C, Nowinski RJ, Edwards TB, Gobeze R. Is reverse shoulder arthroplasty appropriate for the treatment of fractures in the older patient? Early observations. *Clin Orthop Relat Res* 2011; **469**: 3324-3331 [PMID: 21879403 DOI: 10.1007/s11999-011-2055-z]
- 79 **Klein M**, Juschka M, Hinkenjann B, Scherger B, Ostermann PA. Treatment of comminuted fractures of the proximal humerus in elderly patients with the Delta III reverse shoulder prosthesis. *J Orthop Trauma* 2008; **22**: 698-704 [PMID: 18978545 DOI: 10.1097/BOT.0b013e31818afe40]
- 80 **Cazeneuve JF**, Cristofari DJ. [Grammont reversed prosthesis for acute complex fracture of the proximal humerus in an elderly population with 5 to 12 years follow-up]. *Rev Chir Orthop Reparatrice Appar Mot* 2006; **92**: 543-548 [PMID: 17088750]
- 81 **Cuff DJ**, Pupello DR. Comparison of hemiarthroplasty and reverse shoulder arthroplasty for the treatment of proximal humeral fractures in elderly patients. *J Bone Joint Surg Am* 2013; **95**: 2050-2055 [PMID: 24257664 DOI: 10.2106/jbjs.1.01637]
- 82 **Levy J**, Frankle M, Mighell M, Pupello D. The use of the reverse shoulder prosthesis for the treatment of failed hemiarthroplasty for proximal humeral fracture. *J Bone Joint Surg Am* 2007; **89**: 292-300 [PMID: 17272443 DOI: 10.2106/JBJS.E.01310]
- 83 **Boyle MJ**, Youn SM, Frampton CM, Ball CM. Functional outcomes of reverse shoulder arthroplasty compared with hemiarthroplasty for acute proximal humeral fractures. *J Shoulder Elbow Surg* 2013; **22**: 32-37 [PMID: 22652065 DOI: 10.1016/j.jse.2012.03.006]
- 84 **Young SW**, Segal BS, Turner PC, Poon PC. Comparison of functional outcomes of reverse shoulder arthroplasty versus hemiarthroplasty in the primary treatment of acute proximal humerus fracture. *ANZ J Surg* 2010; **80**: 789-793 [PMID: 20969685 DOI: 10.1111/j.1445-2197.2010.05342.x]
- 85 **Garrigues GE**, Johnston PS, Pepe MD, Tucker BS, Ramsey ML, Austin LS. Hemiarthroplasty versus reverse total shoulder arthroplasty for acute proximal humerus fractures in elderly patients. *Orthopedics* 2012; **35**: e703-e708 [PMID: 22588413 DOI: 10.3928/01477447-20120426-25]
- 86 **Handoll H**, Brealey S, Rangan A, Torgerson D, Dennis L, Armstrong A, Chuang LH, Cross B, Dumville J, Gardner S,



Goodchild L, Hamilton S, Hewitt C, Madhok R, Maffulli N, Micklewright L, Wadsworth V, Wallace A, Williams J, Worthy G. Protocol for the ProFHER (PROximal Fracture of the Humerus: Evaluation by Randomisation) trial: a pragmatic

multi-centre randomised controlled trial of surgical versus non-surgical treatment for proximal fracture of the humerus in adults. *BMC Musculoskelet Disord* 2009; **10**: 140 [PMID: 19917097 DOI: 10.1186/1471-2474-10-140]

**P- Reviewer:** Lorbach O, Noh MR   **S- Editor:** Wen LL  
**L- Editor:** A   **E- Editor:** Wu HL



## Vanishing bone disease (Gorham-Stout syndrome): A review of a rare entity

Vasileios S Nikolaou, Dimitrios Chytas, Dimitrios Korres, Nicolas Efstathopoulos

Vasileios S Nikolaou, Dimitrios Chytas, Nicolas Efstathopoulos, 2<sup>nd</sup> Orthopaedic Department, School of Medicine, Athens University, 15124 Athens, Greece

Dimitrios Korres, Orthopaedic Department, Athens University, 15124 Athens, Greece

**Author contributions:** Nikolaou VS and Chytas D contributed equally to this work and performed the literature research and wrote the paper; Korres D provided the pictures and the history of the case example; Efstathopoulos N did the final proof reading of the paper and made final corrections.

**Correspondence to:** Vasileios S Nikolaou, MD, PhD, MSc, Orthopaedic Surgeon, Lecturer in Orthopaedics, 2<sup>nd</sup> Orthopaedic Department, School of Medicine, Athens University, Dimitriou Ralli 21 Street, Maroussi, 15124 Athens, Greece. [vassilios.nikolaou@gmail.com](mailto:vassilios.nikolaou@gmail.com)

Telephone: +30-69-32543400 Fax: +30-21-08022142

Received: February 11, 2014 Revised: March 30, 2014

Accepted: May 31, 2014

Published online: November 18, 2014

**Key words:** Vanishing bone disease; Gorham-Stout syndrome; Histology; Diagnosis; Treatment

**Core tip:** Vanishing bone disease (Gorham-Stout syndrome) is a rare entity of unknown etiology, characterized by destruction of osseous matrix and proliferation of vascular structures, resulting in destruction and absorption of bone. The syndrome can affect one or multiple bones of the patient, including the skull, the upper and lower extremities, the spine and pelvis. Physicians should be aware of the existence of this rare entity and reliably direct affected patients to right diagnosis and therapeutic approach.

Nikolaou VS, Chytas D, Korres D, Efstathopoulos N. Vanishing bone disease (Gorham-Stout syndrome): A review of a rare entity. *World J Orthop* 2014; 5(5): 694-698 Available from: URL: <http://www.wjgnet.com/2218-5836/full/v5/i5/694.htm> DOI: <http://dx.doi.org/10.5312/wjo.v5.i5.694>

### Abstract

Vanishing bone disease (Gorham-Stout syndrome) is a rare entity of unknown etiology, characterized by destruction of osseous matrix and proliferation of vascular structures, resulting in destruction and absorption of bone. Despite the extensive investigation of the pathogenetic mechanisms of the disease, its etiology hasn't been clarified and several theories exist. The syndrome can affect one or multiple bones of the patient, including the skull, the upper and lower extremities, the spine and pelvis. The clinical presentation of a patient suffering from vanishing bone disease includes, pain, functional impairment and swelling of the affected region, although asymptomatic cases have been reported, as well as cases in which the diagnosis was made after a pathologic fracture. In this short review we summarize the theories regarding the etiology as well as the clinical presentation, the diagnostic approach and treatment options of this rare disease.

© 2014 Baishideng Publishing Group Inc. All rights reserved.

### INTRODUCTION

Vanishing bone disease is a rare entity characterized by destruction of osseous matrix and proliferation of vascular structures with benign origin<sup>[1]</sup>. Despite the extensive investigation of the pathogenetic mechanisms of the disease, its etiology hasn't been clarified. The first that described this entity was Jackson in 1838, who reported the case of a young man with a gradually vanishing humerus<sup>[2]</sup>. Moreover, in 1955, Gorham and Stout published a paper, which correlated the massive osteolysis noted in the disease with hemangiomatosis<sup>[3]</sup>, that seems to have played an important role in the fact that vanishing bone disease is also called "Gorham-Stout syndrome".

This syndrome is considered as the type IV of osteolysis, according to Hardegger *et al*<sup>[4]</sup>, among five types: type I is hereditary multicentric osteolysis with dominant transmission, type II is hereditary multicentric osteoly-

sis with recessive transmission, type III is nonhereditary multicentric osteolysis with nephropathy and type V is Winchester syndrome, defined as a monocentric disease of autosomal recessive inheritance<sup>[4]</sup>.

Despite its previously mentioned benign character, its prognosis is unpredictable<sup>[5]</sup> and the presence of several serious complications in some cases cannot be ignored. Therefore, meticulous research has been done concerning the molecular mechanisms of the disease and possible pharmacological targets are systematically investigated.

## ETIOPATHOLOGY

Principally, a reference to the molecular basis of the disease has to be done. Dickson *et al*<sup>[6]</sup> in 1987 were the first that approached Gorham-Stout syndrome from a cytochemical point of view. Investigating the cytochemistry of alkaline and acid phosphatase, they suggested that mononuclear phagocytes, multinuclear osteoclasts and the vascular endothelium participate in bone resorption in this disease<sup>[6]</sup>. Furthermore, in 1996, Devlin *et al*<sup>[7]</sup> attributed this massive osteolysis to the enhanced activity of the osteoclasts, in which Interleukin-6 seems to play a critical role, since its levels in the serum of patients suffering from Gorham-Stout syndrome in early stages, were elevated. Moreover, an interesting observation of Korsić *et al*<sup>[8]</sup>, in 1998, was that the disease appeared in a person with agenesis of C-cells of the thyroid gland and subsequent lack of calcitonin, an hormone with antiosteoclastic activity. On the other hand, Möller *et al*<sup>[9]</sup> in 1999 referred to the increased number of stimulated osteoclasts as a factor that is involved in the pathogenesis of vanishing bone disease, while, in 2001, Hirayama *et al*<sup>[10]</sup> concluded that the increased number of the circulating osteoclasts is the consequence of the increased sensitivity of their precursors to humoral factors that lead to osteoclast formation. Another important point about the histopathology of Gorham-Stout syndrome was noted by Colucci *et al*<sup>[11]</sup> (in 2006), who found that the cells they isolated from a patient's lesion belonged to a monocyte-macrophage lineage and could release high amounts of osteoclastogenic and angiogenic molecules. Additionally, Hagendoorn *et al*<sup>[12]</sup> (in 2006) underlined the critical role that could play the signaling pathway of the PDGFR- $\beta$  (receptor of the lymphangiogenic growth factor Platelet Derived Growth Factor BB) in the pathogenetic mechanism of the disease. Besides, in 2007, Bruch-Gerharz *et al*<sup>[5]</sup> tried to shed more light onto the pathogenesis of the syndrome, writing about lymphatic vascular malformations involving the skin and the soft tissues adjacent to the diseased bone. The character of Gorham-Stout syndrome as a disease of disordered lymphangiogenesis is also highlighted by Radhakrishnan *et al*<sup>[13]</sup> (in 2008), who supported that research should focus on the investigation of lymphangiogenic pathways.

## CLINICAL FEATURES

The syndrome can affect one or multiple bones of the patient, whose age has been reported to be from 1 mo<sup>[14]</sup>

to 75 years old<sup>[15]</sup>. As a general rule, the persons that suffer from the disease are younger than 40-year-old<sup>[16]</sup>, while an epidemiologic correlation with race, gender and geography does not seem to exist<sup>[9,17-19]</sup>. However, some authors noticed a clear "predilection" of the disease in males<sup>[20]</sup>.

Gorham-Stout syndrome is met in a large spectrum of bones, but the majority of case reports refer to the maxillofacial region and the upper extremity<sup>[16]</sup>. Nevertheless, Hu *et al*<sup>[20]</sup> recently reported a case series, in which the femur was the predominant affected bone.

Radiologically, initial x-rays reveal changes resembling patchy osteoporosis. At a later stage bone deformity occurs with bone mass loss and concentric shrinkage in the long bones of upper and lower extremities. Eventually, near complete resorption of the bone occurs, resulting in the appearance of the so-called "vanishing bone" disease<sup>[9,21]</sup>.

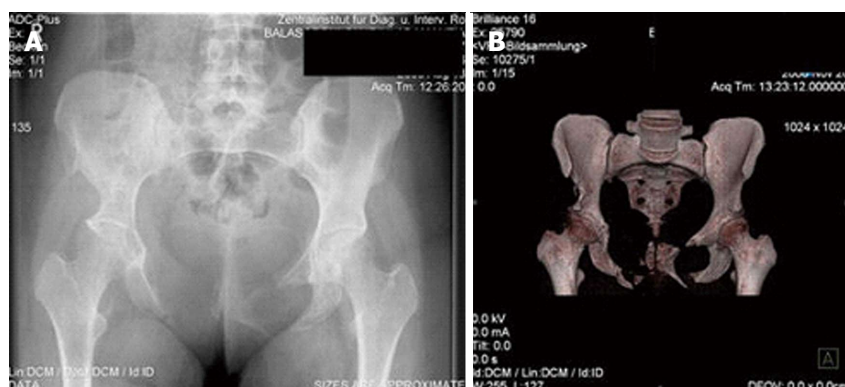
The clinical presentation of a patient suffering from vanishing bone disease includes, most frequently, pain, functional impairment and swelling of the affected region, although asymptomatic cases have been reported, as well as cases in which the diagnosis was made after a pathologic fracture<sup>[20]</sup>. Furthermore, the complications of the syndrome can be potentially fatal. For example, pleural effusion and chylothorax (which has been reported to be a complication of Gorham-Stout syndrome in a percentage up to 17% )<sup>[22]</sup> can dramatically influence the respiratory function. Chylothorax may occur due to the affected thoracic skeleton by the extension of lymphangiectasia into the pleural cavity or by the invasion of the thoracic duct<sup>[23]</sup>. Also, hemangiomatous cutaneous lesions<sup>[5,24]</sup>, bone infection and subsequent septic shock<sup>[24]</sup>, spinal cord involvement and paraplegia due to vertebral lesion<sup>[25]</sup> and cerebrospinal fluid leakage and meningitis due to diseased bones of the skull<sup>[26]</sup> have been rarely reported.

The differential diagnosis of the disease includes hereditary multicentric osteolysis, osteolysis with nephropathy, osteomyelitis, rheumatoid arthritis<sup>[27]</sup>, osteolysis due to intraosseous malignancies, hyperparathyroidism, eosinophilic granuloma and osteolysis due to diseases of central nervous system, like syringomyelia and tabes dorsalis<sup>[28]</sup>.

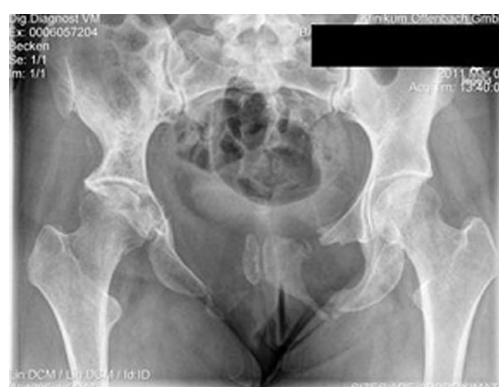Figures 1 and 2 shows a case example of a massive Gorham-Stout syndrome of the Pelvis in a young female, treated in our institution. Only few similar cases of pelvic appearance of the disease have been described in the literature<sup>[17,29-31]</sup>.

## DIAGNOSIS

The diagnosis of the syndrome is challenging, demands a high grade of clinical suspicion and is assisted by several diagnostic examinations. Initially, blood tests are not indicative of the diagnosis, as they are usually normal, with the possible exception of alkaline phosphatase, which may be slightly elevated<sup>[23]</sup>. Additionally, a diagnostic role could be played by plain radiographs<sup>[32,33]</sup>, bone scan<sup>[34]</sup>, Computed tomography<sup>[35]</sup> and magnetic resonance imag-



**Figure 1** Case example: X-ray (A) and computed tomography scan (B), of a 26 years old female, with vanishing bone disease of the pelvis. She presented with mild groin pain without any further symptoms.



**Figure 2** X-ray of the pelvis of the previous patient. Three years later she remained asymptomatic with only mild discomfort to the groin and no further symptoms.

ing (MRI)<sup>[36]</sup>. Plain X-rays, initially, show radiolucent foci in the intramedullary or subcortical regions and, later, slowly progressive atrophy, dissolution, fracture, fragmentation and disappearance of a part of a bone, with tapering or “pointing” of the remaining osseous tissue and atrophy of soft tissues<sup>[37]</sup>. On the other hand, the results from bone scan and MRI are variable<sup>[16,38]</sup>.

Despite the usefulness of the previously reported diagnostic means, the disease is confirmed by the histopathological analysis of the lesions<sup>[39]</sup>; the biopsy shows nonmalignant hyperproliferation of small vessels<sup>[4,5,17]</sup>. So, Heffez *et al.*<sup>[40]</sup> suggested the following 8 diagnostic criteria of Gorham-Stout syndrome: (1) positive biopsy findings in terms of angiomatous tissue presence; (2) absence of cellular atypia; (3) minimal or no osteoclastic response and absence of dystrophic calcifications; (4) evidence of local bone progressive resorption; (5) non-expansive, non-ulcerative lesion; (6) absence of visceral involvement; (7) osteolytic radiographic pattern; and (8) negative hereditary, metabolic, neoplastic, immunologic and infectious etiology<sup>[40]</sup>. Indeed, the diagnosis of vanishing bone disease should be suspected only after other causes of osteolysis, like infection, cancer, inflammatory and endocrine disorders are excluded<sup>[41]</sup>.

## TREATMENT

Vanishing bone disease, despite the fact that is consid-

ered as benign<sup>[42]</sup> and its natural progression is characterized by spontaneous resolution<sup>[4]</sup>, has an unpredictable prognosis<sup>[5]</sup> and possible serious complications. Since its etiology remains unclear, its treatment is still an object of research, although several therapeutic options have been proposed with various results. The treatment of syndrome includes three major categories: medicine therapy, radiation and surgery<sup>[20]</sup>. In the first field, biphosphonates have been successfully used for the treatment of the syndrome, showing an antiosteolytic activity<sup>[43]</sup>. Besides, other pharmacologic agents, like vitamin D, a-2b interferon, calcium, adrenal extracts and androgens have been suggested<sup>[5,13,39,44]</sup>. However, current research about the molecular mechanisms of the disease promises encouraging results, focusing on pathways of receptors of lymphangiogenic growth factors, which may be proved useful therapeutic targets<sup>[4]</sup>.

In patients with large symptomatic lesions with long-standing disabling functional instability, radiation and surgical treatment are preferred<sup>[23]</sup>. The therapeutic results from the use of radiation in moderate doses seem to be satisfactory, with few long-term complications<sup>[42]</sup>. However, radiation could provoke some serious side effects, like secondary malignancy and growth restriction in children and adolescents who receive a high-dose therapy<sup>[23]</sup>. Finally, the surgical management is performed by resection of the lesion and reconstruction by use of bone grafts and/or prostheses<sup>[16]</sup>.

In the case of chylothorax, several therapeutic solutions, like chest drainage<sup>[20]</sup>, thoracic duct ligation, pleurodesis, pleurectomy, radiation therapy, interferon and bleomycin have been suggested<sup>[23]</sup>.

## CONCLUSION

In conclusion, provided that the etiopathology of vanishing bone disease has not been fully clarified, further research is needed for more effective therapeutic interventions. Physicians should be aware of the existence of this rare entity and reliably direct affected patients to correct diagnosis and therapeutic approach.

## REFERENCES

- 1 Deveci M, Inan N, Corapcioglu F, Ekingen G. Gorham-stout



- syndrome with chylothorax in a six-year-old boy. *Indian J Pediatr* 2011; **78**: 737-739 [DOI: 10.1007/s12098-010-0328-2]
- 2 **Jackson J.** A boneless arm. *Boston Med Surg J* 1838; **18**: 398-399
  - 3 **Gorham LW, Stout AP.** Massive osteolysis (acute spontaneous absorption of bone, phantom bone, disappearing bone); its relation to hemangiomatosis. *J Bone Joint Surg Am* 1955; **37-A**: 985-1004 [PMID: 13263344]
  - 4 **Hardegger F, Simpson LA, Segmueller G.** The syndrome of idiopathic osteolysis. Classification, review, and case report. *J Bone Joint Surg Br* 1985; **67**: 88-93 [PMID: 3968152]
  - 5 **Bruch-Gerharz D, Gerharz CD, Stege H, Krutmann J, Pohl M, Koester R, Ruzicka T.** Cutaneous lymphatic malformations in disappearing bone (gorham-stout) disease: A novel clue to the pathogenesis of a rare syndrome. *J AM ACAD DERMATOL* 2007; **56**: S21-25 [DOI: 10.1016/j.jaad.2006.01.063]
  - 6 **Dickson GR, Mollan RA, Carr KE.** Cytochemical localization of alkaline and acid phosphatase in human vanishing bone disease. *Histochemistry* 1987; **87**: 569-572 [PMID: 3692922]
  - 7 **Devlin RD, Bone HG, 3rd, Roodman GD.** Interleukin-6: A potential mediator of the massive osteolysis in patients with gorham-stout disease. *J CLIN ENDOCR METAB* 1996; **81**: 1893-1897 [DOI: 10.1210/jcem.81.5.8626854]
  - 8 **Korsić M, Jelasić D, Potocki K, Giljević Z, Aganović I.** Massive osteolysis in a girl with agenesis of thyroid C cells. *Skeletal Radiol* 1998; **27**: 525-528 [PMID: 9809885]
  - 9 **Möller G, Priemel M, Amling M, Werner M, Kuhlmeier AS, Delling G.** The Gorham-Stout syndrome (Gorham's massive osteolysis). A report of six cases with histopathological findings. *J Bone Joint Surg Br* 1999; **81**: 501-506 [PMID: 10872375]
  - 10 **Hirayama T, Sabokbar A, Itonaga I, Watt-Smith S, Athanasou NA.** Cellular and humoral mechanisms of osteoclast formation and bone resorption in gorham-stout disease. *J PATHOL* 2001; **195**: 624-630 [DOI: 10.1002/path.989]
  - 11 **Colucci S, Taraboletti G, Primo L, Viale A, Roca C, Valdembrì D, Geuna M, Pagano M, Grano M, Pogrel AM, Harris AL, Athanasou NN, Mantovani A, Zallone A, Bussolino F.** Gorham-stout syndrome: A monocyte-mediated cytokine propelled disease. *J BONE MINER RES* 2006; **21**: 207-218 [PMID: DOI: 10.1359/JBMR.051019]
  - 12 **Hagendoorn J, Padera TP, Yock TI, Nielsen GP, di Tomaso E, Duda DG, Delaney TF, Gaisert HA, Pearce J, Rosenberg AE, Jain RK, Ebb DH.** Platelet-derived growth factor receptor-beta in Gorham's disease. *Nat Clin Pract Oncol* 2006; **3**: 693-697 [PMID: 17139320]
  - 13 **Radhakrishnan K, Rockson SG.** Gorham's disease: An osseous disease of lymphangiogenesis? *ANN NY ACAD SCI* 2008; **1131**: 203-205 [DOI: 10.1196/annals.1413.022]
  - 14 **Vinée P, Tanyü MO, Hauenstein KH, Sigmund G, Stöver B, Adler CP.** CT and MRI of Gorham syndrome. *J Comput Assist Tomogr* 1994; **18**: 985-989 [PMID: 7962815]
  - 15 **Szabo C, Habre W.** Gorham syndrome: anaesthetic management. *Anaesthesia* 2000; **55**: 157-159 [PMID: 10651678]
  - 16 **Kiran DN, Anupama A.** Vanishing bone disease: A review. *Journal of oral and maxillofacial surgery: official journal of the American Association of Oral and Maxillofacial Surgeons* 2011; **69**: 199-203 [DOI: 10.1016/j.joms.2010.05.088]
  - 17 **Boyer P, Bourgeois P, Boyer O, Catonné Y, Saillant G.** Massive Gorham-Stout syndrome of the pelvis. *Clin Rheumatol* 2005; **24**: 551-555 [PMID: 15827684 DOI: 10.1007/s10067-005-1088-7]
  - 18 **Lee S, Finn L, Sze RW, Perkins JA, Sie KC.** Gorham Stout syndrome (disappearing bone disease): two additional case reports and a review of the literature. *Arch Otolaryngol Head Neck Surg* 2003; **129**: 1340-1343 [PMID: 14676163 DOI: 10.1001/archotol.129.12.1340]
  - 19 **Mendez AA, Keret D, Robertson W, MacEwen GD.** Massive osteolysis of the femur (Gorham's disease): a case report and review of the literature. *J Pediatr Orthop* 1989; **9**: 604-608 [PMID: 2677046]
  - 20 **Hu P, Yuan XG, Hu XY, Shen FR, Wang JA.** Gorham-Stout syndrome in mainland China: a case series of 67 patients and review of the literature. *J Zhejiang Univ Sci B* 2013; **14**: 729-735 [PMID: 23897792 DOI: 10.1631/jzus.B1200308]
  - 21 **Ross JL, Schinella R, Shenkman L.** Massive osteolysis. An unusual cause of bone destruction. *Am J Med* 1978; **65**: 367-372 [PMID: 686022]
  - 22 **Tie ML, Poland GA, Rosenow EC.** Chylothorax in Gorham's syndrome. A common complication of a rare disease. *Chest* 1994; **105**: 208-213 [PMID: 8275732]
  - 23 **Patel DV.** Gorham's disease or massive osteolysis. *Clin Med Res* 2005; **3**: 65-74 [PMID: 16012123]
  - 24 **Kery L, Wouters HW.** Massive osteolysis. Report of two cases. *J Bone Joint Surg Br* 1970; **52**: 452-459 [PMID: 5455076]
  - 25 **Halliday DR, Dahlin DC, Pugh DG, Young HH.** Massive osteolysis and angiomatosis. *Radiology* 1964; **82**: 637-644 [DOI: 10.1148/82.4.637]
  - 26 **Iyer GV.** Cerebrospinal fluid rhinorrhoea from massive osteolysis of the skull. *J Neurol Neurosurg Psychiatry* 1979; **42**: 767-769 [PMID: 490182]
  - 27 **Ozbayrak M, Yilmaz MH, Kantarci F, Ozer H, Harmanci K, Babacan M, Dervisoglu S.** A case of an idiopathic massive osteolysis with skip lesions. *Korean J Radiol* 2013; **14**: 946-950 [PMID: 24265571 DOI: 10.3348/kjr.2013.14.6.946]
  - 28 **Motamedi MH, Homauni SM, Behnia H.** Massive osteolysis of the mandible: a case report. *J Oral Maxillofac Surg* 2003; **61**: 957-963 [PMID: 12905451]
  - 29 **Leite I, Hernández-Martín A, Colmenero I, López-Gutiérrez JC, Torrelo A.** Invasive lymphatic malformation (gorham-stout) of the pelvis with prominent skin involvement. *Pediatr Dermatol* 2013; **30**: 374-378 [PMID: 22823281 DOI: 10.1111/j.1525-1470.2012.01814.x]
  - 30 **Lehmann G, Pfeil A, Böttcher J, Kaiser WA, Füller J, Hein G, Wolf G.** Benefit of a 17-year long-term bisphosphonate therapy in a patient with Gorham-Stout syndrome. *Arch Orthop Trauma Surg* 2009; **129**: 967-972 [PMID: 18807053 DOI: 10.1007/s00402-008-0742-3]
  - 31 **Stöve J, Reichelt A.** Massive osteolysis of the pelvis, femur and sacral bone with a Gorham-Stout syndrome. *Arch Orthop Trauma Surg* 1995; **114**: 207-210 [PMID: 7662475]
  - 32 **Torg JS, Steel HH.** Sequential roentgenographic changes occurring in massive osteolysis. *J Bone Joint Surg Am* 1969; **51**: 1649-1655 [PMID: 5357185]
  - 33 **Abrahams J, Ganick D, Gilbert E, Wolfson J.** Massive osteolysis in an infant. *AM J ROENTGENOL* 1980; **135**: 1084-1086 [DOI: 10.2214/ajr.135.5.1084]
  - 34 **Marymont JV.** Comparative imaging. Massive osteolysis (Gorham's syndrome, disappearing bone disease). *Clin Nucl Med* 1987; **12**: 153-154 [PMID: 3829539]
  - 35 **Mitchell CS, Parisi MT, Osborn RE.** Gorham's disease involving the thoracic skeleton. Plain films and CT in two cases. *Pediatr Radiol* 1993; **23**: 543-544 [PMID: 8309760]
  - 36 **Assoun J, Richardi G, Railhac JJ, Le Guennec P, Caulier M, Dromer C, Sixou L, Fournie B, Mansat M, Durroux D.** CT and MRI of massive osteolysis of Gorham. *J Comput Assist Tomogr* 1994; **18**: 981-984 [PMID: 7962814]
  - 37 **Resnick D.** Osteolysis and chondrolysis. In: *Resnick D Diagnosis of bone and joint disorders*. Philadelphia, PA: Saunders, 2002: 4920-4944
  - 38 **Spieth ME, Greenspan A, Forrester DM, Ansari AN, Kimura RL, Gleason-Jordan I.** Gorham's disease of the radius: radiographic, scintigraphic, and MRI findings with pathologic correlation. A case report and review of the literature. *Skeletal Radiol* 1997; **26**: 659-663 [PMID: 9428074]
  - 39 **Binder H, Weber PC, Siess W.** Separation of inositol phosphates and glycerophosphoinositol phosphates by high-performance liquid chromatography. *Anal Biochem* 1985; **148**: 220-227 [PMID: 2994520 DOI: 10.4081/rt.2010.e40]
  - 40 **Heffez L, Doku HC, Carter BL, Feeney JE.** Perspectives on massive osteolysis. Report of a case and review of the literature. *Oral Surg Oral Med Oral Pathol* 1983; **55**: 331-343 [PMID:

- 6574409]
- 41 **Raghuveer HP**, Jayalekshmy R. Gorham's massive osteolysis of the mandible - a progressive radiographic presentation. *Dentomaxillofac Radiol* 2009; **38**: 292-295 [PMID: 19474257 DOI: 10.1259/dmfr/73198793]
  - 42 **Dunbar SF**, Rosenberg A, Mankin H, Rosenthal D, Suit HD. Gorham's massive osteolysis: the role of radiation therapy and a review of the literature. *Int J Radiat Oncol Biol Phys* 1993; **26**: 491-497 [PMID: 8514544]
  - 43 **Hammer F**, Kenn W, Wesselmann U, Hofbauer LC, Delling G, Allolio B, Arlt W. Gorham-stout disease--stabilization during bisphosphonate treatment. *J BONE MINER RES* 2005; **20**: 350-353 [DOI: 10.1359/JBMR.041113]
  - 44 **Aizawa T**, Sato T, Kokubun S. Gorham disease of the spine: a case report and treatment strategies for this enigmatic bone disease. *Tohoku J Exp Med* 2005; **205**: 187-196 [PMID: 15673977]

**P- Reviewer:** Espinosa-Gutierrez A, Mazinis E, Xu CY, Zacharia B

**S- Editor:** Ji FF **L- Editor:** A **E- Editor:** Wu HL





## INSTRUCTIONS TO AUTHORS

### GENERAL INFORMATION

*World Journal of Orthopedics* (*World J Orthop*, *WJO*, online ISSN 2218-5836, DOI: 10.5312) is a peer-reviewed open access (OA) academic journal that aims to guide clinical practice and improve diagnostic and therapeutic skills of clinicians.

#### Aim and scope

*WJO* covers topics concerning arrhythmia, heart failure, vascular disease, stroke, hypertension, prevention and epidemiology, dyslipidemia and metabolic disorders, cardiac imaging, pediatrics, nursing, and health promotion. Priority publication will be given to articles concerning diagnosis and treatment of orthopedics diseases. The following aspects are covered: Clinical diagnosis, laboratory diagnosis, differential diagnosis, imaging tests, pathological diagnosis, molecular biological diagnosis, immunological diagnosis, genetic diagnosis, functional diagnostics, and physical diagnosis; and comprehensive therapy, drug therapy, surgical therapy, interventional treatment, minimally invasive therapy, and robot-assisted therapy.

We encourage authors to submit their manuscripts to *WJO*. We will give priority to manuscripts that are supported by major national and international foundations and those that are of great basic and clinical significance.

*WJO* is edited and published by Baishideng Publishing Group (BPG). BPG has a strong professional editorial team composed of science editors, language editors and electronic editors. BPG currently publishes 43 OA clinical medical journals, including 42 in English, has a total of 15471 editorial board members or peer reviewers, and is a world first-class publisher.

#### Columns

The columns in the issues of *WJO* will include: (1) Editorial: The editorial board members are invited to make comments on an important topic in their field in terms of its current research status and future directions to lead the development of this discipline; (2) Frontier: The editorial board members are invited to select a highly cited cutting-edge original paper of his/her own to summarize major findings, the problems that have been resolved and remain to be resolved, and future research directions to help readers understand his/her important academic point of view and future research directions in the field; (3) Diagnostic Advances: The editorial board members are invited to write high-quality diagnostic advances in their field to improve the diagnostic skills of readers. The topic covers general clinical diagnosis, differential diagnosis, pathological diagnosis, laboratory diagnosis, imaging diagnosis, endoscopic diagnosis, biotechnological diagnosis, functional diagnosis, and physical diagnosis; (4) Therapeutics Advances: The editorial board members are invited to write high-quality therapeutic advances in their field to help improve the therapeutic skills of readers. The topic covers medication therapy, psychotherapy, physical therapy, replacement therapy, interventional therapy, minimally invasive therapy, endoscopic therapy, transplantation therapy, and surgical therapy; (5) Field of Vision: The editorial board members are invited to write commentaries on classic articles, hot topic articles, or latest articles to keep readers at the forefront of research and increase their levels of clinical research. Classic articles refer to papers that are included in Web of Knowledge and have received a large number of citations (ranking in the top 1%) after being published for more than years, reflecting the quality and impact of papers. Hot topic articles refer to papers that are included in Web of Knowledge and

have received a large number of citations after being published for no more than 2 years, reflecting cutting-edge trends in scientific research. Latest articles refer to the latest published high-quality papers that are included in PubMed, reflecting the latest research trends. These commentary articles should focus on the status quo of research, the most important research topics, the problems that have now been resolved and remain to be resolved, and future research directions. Basic information about the article to be commented (including authors, article title, journal name, year, volume, and inclusive page numbers); (6) Minireviews: The editorial board members are invited to write short reviews on recent advances and trends in research of molecular biology, genomics, and related cutting-edge technologies to provide readers with the latest knowledge and help improve their diagnostic and therapeutic skills; (7) Review: To make a systematic review to focus on the status quo of research, the most important research topics, the problems that have now been resolved and remain to be resolved, and future research directions; (8) Topic Highlight: The editorial board members are invited to write a series of articles (7-10 articles) to comment and discuss a hot topic to help improve the diagnostic and therapeutic skills of readers; (9) Medical Ethics: The editorial board members are invited to write articles about medical ethics to increase readers' knowledge of medical ethics. The topic covers international ethics guidelines, animal studies, clinical trials, organ transplantation, etc.; (10) Clinical Case Conference or Clinicopathological Conference: The editorial board members are invited to contribute high-quality clinical case conference; (11) Original Articles: To report innovative and original findings in orthopedics; (12) Research Report: To briefly report the novel and innovative findings in orthopedics; (13) Meta-Analysis: To evaluate the clinical effectiveness in orthopedics by using data from two or more randomized control trials; (14) Case Report: To report a rare or typical case; (15) Letters to the Editor: To discuss and make reply to the contributions published in *WJO*, or to introduce and comment on a controversial issue of general interest; (16) Book Reviews: To introduce and comment on quality monographs of orthopedics; and (17) Autobiography: The editorial board members are invited to write their autobiography to provide readers with stories of success or failure in their scientific research career. The topic covers their basic personal information and information about when they started doing research work, where and how they did research work, what they have achieved, and their lessons from success or failure.

#### Name of journal

*World Journal of Orthopedics*

#### ISSN

ISSN 2218-5836 (online)

#### Launch date

November 18, 2010

#### Frequency

Bimonthly

#### Editor-in-Chief

**Bao-Gan Peng, MD, PhD, Professor**, Department of Spinal Surgery, General Hospital of Armed Police Force, 69 Yongding

## Instructions to authors

Road, Beijing 100039, China

### Editorial office

Jin-Lei Wang, Director

Xiu-Xia Song, Vice Director

*World Journal of Orthopedics*

Room 903, Building D, Ocean International Center,

No. 62 Dongsihuan Zhonglu, Chaoyang District,

Beijing 100025, China

Telephone: +86-10-59080039

Fax: +86-10-85381893

E-mail: [editorialoffice@wjnet.com](mailto:editorialoffice@wjnet.com)

Help Desk: <http://www.wjnet.com/esps/helpdesk.aspx>

<http://www.wjnet.com>

### Publisher

Baishideng Publishing Group Inc

8226 Regency Drive,

Pleasanton, CA 94588, USA

Telephone: +1-925-223-8242

Fax: +1-925-223-8243

E-mail: [bpgoffice@wjnet.com](mailto:bpgoffice@wjnet.com)

Help Desk: <http://www.wjnet.com/esps/helpdesk.aspx>

<http://www.wjnet.com>

### Instructions to authors

Full instructions are available online at [http://www.wjnet.com/2218-5836/g\\_info\\_20100316161927.htm](http://www.wjnet.com/2218-5836/g_info_20100316161927.htm).

### Indexed and Abstracted in

PubMed Central, PubMed, Digital Object Identifier, and Directory of Open Access Journals.

## SPECIAL STATEMENT

All articles published in journals owned by the BPG represent the views and opinions of their authors, and not the views, opinions or policies of the BPG, except where otherwise explicitly indicated..

### Biostatistical editing

Statistical review is performed after peer review. We invite an expert in Biomedical Statistics to evaluate the statistical method used in the paper, including *t*-test (group or paired comparisons), chi-squared test, Redit, probit, logit, regression (linear, curvilinear, or stepwise), correlation, analysis of variance, analysis of covariance, *etc.* The reviewing points include: (1) Statistical methods should be described when they are used to verify the results; (2) Whether the statistical techniques are suitable or correct; (3) Only homogeneous data can be averaged. Standard deviations are preferred to standard errors. Give the number of observations and subjects (*n*). Losses in observations, such as drop-outs from the study should be reported; (4) Values such as ED50, LD50, IC50 should have their 95% confidence limits calculated and compared by weighted probit analysis (Bliss and Finney); and (5) The word 'significantly' should be replaced by its synonyms (if it indicates extent) or the *P* value (if it indicates statistical significance).

### Conflict-of-interest statement

In the interests of transparency and to help reviewers assess any potential bias, *WJO* requires authors of all papers to declare any competing commercial, personal, political, intellectual, or religious interests in relation to the submitted work. Referees are also asked to indicate any potential conflict they might have reviewing a particular paper. Before submitting, authors are suggested to read "Uniform Requirements for Manuscripts Submitted to Biomedical Journals: Ethical Considerations in the Conduct and Reporting of Research: Conflicts of Interest" from International Committee of Medical Journal Editors (ICMJE), which is available at: [http://www.icmje.org/ethical\\_4conflicts.html](http://www.icmje.org/ethical_4conflicts.html).

Sample wording: [Name of individual] has received fees for serving as a speaker, a consultant and an advisory board member for [names of organizations], and has received research funding from [names of organization]. [Name of individual] is an employee of [name of organization]. [Name of individual] owns stocks and shares in [name of organization]. [Name of individual] owns patent [patent identification and brief description].

### Statement of informed consent

Manuscripts should contain a statement to the effect that all human studies have been reviewed by the appropriate ethics committee or it should be stated clearly in the text that all persons gave their informed consent prior to their inclusion in the study. Details that might disclose the identity of the subjects under study should be omitted. Authors should also draw attention to the Code of Ethics of the World Medical Association (Declaration of Helsinki, 1964, as revised in 2004).

### Statement of human and animal rights

When reporting the results from experiments, authors should follow the highest standards and the trial should conform to Good Clinical Practice (for example, US Food and Drug Administration Good Clinical Practice in FDA-Regulated Clinical Trials; UK Medicines Research Council Guidelines for Good Clinical Practice in Clinical Trials) and/or the World Medical Association Declaration of Helsinki. Generally, we suggest authors follow the lead investigator's national standard. If doubt exists whether the research was conducted in accordance with the above standards, the authors must explain the rationale for their approach and demonstrate that the institutional review body explicitly approved the doubtful aspects of the study.

Before submitting, authors should make their study approved by the relevant research ethics committee or institutional review board. If human participants were involved, manuscripts must be accompanied by a statement that the experiments were undertaken with the understanding and appropriate informed consent of each. Any personal item or information will not be published without explicit consents from the involved patients. If experimental animals were used, the materials and methods (experimental procedures) section must clearly indicate that appropriate measures were taken to minimize pain or discomfort, and details of animal care should be provided.

## SUBMISSION OF MANUSCRIPTS

Manuscripts should be typed in 1.5 line spacing and 12 pt. Book Antiqua with ample margins. Number all pages consecutively, and start each of the following sections on a new page: Title Page, Abstract, Introduction, Materials and Methods, Results, Discussion, Acknowledgements, References, Tables, Figures, and Figure Legends. Neither the editors nor the publisher are responsible for the opinions expressed by contributors. Manuscripts formally accepted for publication become the permanent property of Baishideng Publishing Group Co., Limited, and may not be reproduced by any means, in whole or in part, without the written permission of both the authors and the publisher. We reserve the right to copy-edit and put onto our website accepted manuscripts. Authors should follow the relevant guidelines for the care and use of laboratory animals of their institution or national animal welfare committee. For the sake of transparency in regard to the performance and reporting of clinical trials, we endorse the policy of the ICMJE to refuse to publish papers on clinical trial results if the trial was not recorded in a publicly-accessible registry at its outset. The only register now available, to our knowledge, is <http://www.clinicaltrials.gov> sponsored by the United States National Library of Medicine and we encourage all potential contributors to register with it. However, in the case that other registers become available you will be duly notified. A letter of recommendation from each author's organization should be provided with the contributed article to ensure the privacy and secrecy of research is protected.

Authors should retain one copy of the text, tables, photographs and illustrations because rejected manuscripts will not be returned to the author(s) and the editors will not be responsible for loss or damage to photographs and illustrations sustained during mailing.



**Online submissions**

Manuscripts should be submitted through the Online Submission System at: <http://www.wjgnet.com/esps/>. Authors are highly recommended to consult the ONLINE INSTRUCTIONS TO AUTHORS ([http://www.wjgnet.com/2218-5836/g\\_info\\_20100316161927.htm](http://www.wjgnet.com/2218-5836/g_info_20100316161927.htm)) before attempting to submit online. For assistance, authors encountering problems with the Online Submission System may send an email describing the problem to [editorialoffice@wjgnet.com](mailto:editorialoffice@wjgnet.com), or by telephone: +86-10-85381892. If you submit your manuscript online, do not make a postal contribution. Repeated online submission for the same manuscript is strictly prohibited.

**MANUSCRIPT PREPARATION**

All contributions should be written in English. All articles must be submitted using word-processing software. All submissions must be typed in 1.5 line spacing and 12 pt. Book Antiqua with ample margins. Style should conform to our house format. Required information for each of the manuscript sections is as follows:

**Title page**

**Title:** Title should be less than 12 words.

**Running title:** A short running title of less than 6 words should be provided.

**Authorship:** Authorship credit should be in accordance with the standard proposed by ICMJE, based on (1) substantial contributions to conception and design, acquisition of data, or analysis and interpretation of data; (2) drafting the article or revising it critically for important intellectual content; and (3) final approval of the version to be published. Authors should meet conditions 1, 2, and 3.

**Institution:** Author names should be given first, then the complete name of institution, city, province and postcode. For example, Xu-Chen Zhang, Li-Xin Mei, Department of Pathology, Chengde Medical College, Chengde 067000, Hebei Province, China. One author may be represented from two institutions, for example, George Sgourakis, Department of General, Visceral, and Transplantation Surgery, Essen 45122, Germany; George Sgourakis, 2nd Surgical Department, Korgialenio-Benakio Red Cross Hospital, Athens 15451, Greece

**Author contributions:** The format of this section should be: Author contributions: Wang CL and Liang L contributed equally to this work; Wang CL, Liang L, Fu JF, Zou CC, Hong F and Wu XM designed the research; Wang CL, Zou CC, Hong F and Wu XM performed the research; Xue JZ and Lu JR contributed new reagents/analytic tools; Wang CL, Liang L and Fu JF analyzed the data; and Wang CL, Liang L and Fu JF wrote the paper.

**Supportive foundations:** The complete name and number of supportive foundations should be provided, e.g. Supported by National Natural Science Foundation of China, No. 30224801

**Correspondence to:** Only one corresponding address should be provided. Author names should be given first, then author title, affiliation, the complete name of institution, city, postcode, province, country, and email. All the letters in the email should be in lower case. A space interval should be inserted between country name and email address. For example, Montgomery Bissell, MD, Professor of Medicine, Chief, Liver Center, Gastroenterology Division, University of California, Box 0538, San Francisco, CA 94143, United States. [montgomery.bissell@ucsf.edu](mailto:montgomery.bissell@ucsf.edu)

**Telephone and fax:** Telephone and fax should consist of +, country number, district number and telephone or fax number, e.g. Telephone: +86-10-85381892 Fax: +86-10-85381893

**Peer reviewers:** All articles received are subject to peer review. Normally, three experts are invited for each article. Decision on

acceptance is made only when at least two experts recommend publication of an article. All peer-reviewers are acknowledged on Express Submission and Peer-review System website.

**Abstract**

There are unstructured abstracts (no less than 200 words) and structured abstracts. The specific requirements for structured abstracts are as follows:

An informative, structured abstract should accompany each manuscript. Abstracts of original contributions should be structured into the following sections: AIM (no more than 20 words; Only the purpose of the study should be included. Please write the Aim in the form of "To investigate/study/..."), METHODS (no less than 140 words for Original Articles; and no less than 80 words for Brief Articles), RESULTS (no less than 150 words for Original Articles and no less than 120 words for Brief Articles; You should present *P* values where appropriate and must provide relevant data to illustrate how they were obtained, e.g.  $6.92 \pm 3.86$  vs  $3.61 \pm 1.67$ ,  $P < 0.001$ ), and CONCLUSION (no more than 26 words).

**Key words**

Please list 5-10 key words, selected mainly from *Index Medicus*, which reflect the content of the study.

**Core tip**

Please write a summary of less than 100 words to outline the most innovative and important arguments and core contents in your paper to attract readers.

**Text**

For articles of these sections, original articles and brief articles, the main text should be structured into the following sections: INTRODUCTION, MATERIALS AND METHODS, RESULTS and DISCUSSION, and should include appropriate Figures and Tables. Data should be presented in the main text or in Figures and Tables, but not in both.

**Illustrations**

Figures should be numbered as 1, 2, 3, *etc.*, and mentioned clearly in the main text. Provide a brief title for each figure on a separate page. Detailed legends should not be provided under the figures. This part should be added into the text where the figures are applicable. Keeping all elements compiled is necessary in line-art image. Scale bars should be used rather than magnification factors, with the length of the bar defined in the legend rather than on the bar itself. File names should identify the figure and panel. Avoid layering type directly over shaded or textured areas. Please use uniform legends for the same subjects. For example: Figure 1 Pathological changes in atrophic gastritis after treatment. A: ...; B: ...; C: ...; D: ...; E: ...; F: ...; G: ... *etc.* It is our principle to publish high resolution-figures for the E-versions.

**Tables**

Three-line tables should be numbered 1, 2, 3, *etc.*, and mentioned clearly in the main text. Provide a brief title for each table. Detailed legends should not be included under tables, but rather added into the text where applicable. The information should complement, but not duplicate the text. Use one horizontal line under the title, a second under column heads, and a third below the Table, above any footnotes. Vertical and italic lines should be omitted.

**Notes in tables and illustrations**

Data that are not statistically significant should not be noted. <sup>a</sup>*P* < 0.05, <sup>b</sup>*P* < 0.01 should be noted (*P* > 0.05 should not be noted). If there are other series of *P* values, <sup>c</sup>*P* < 0.05 and <sup>d</sup>*P* < 0.01 are used. A third series of *P* values can be expressed as <sup>e</sup>*P* < 0.05 and <sup>f</sup>*P* < 0.01. Other notes in tables or under illustrations should be expressed as <sup>1</sup>F, <sup>2</sup>F, <sup>3</sup>F; or sometimes as other symbols with a superscript (Arabic numerals) in the upper left corner. In a multi-curve illustration, each curve should be labeled with ●, ○, ■, ▲, △, *etc.*, in a certain sequence.

## Acknowledgments

Brief acknowledgments of persons who have made genuine contributions to the manuscript and who endorse the data and conclusions should be included. Authors are responsible for obtaining written permission to use any copyrighted text and/or illustrations.

## REFERENCES

### Coding system

The author should number the references in Arabic numerals according to the citation order in the text. Put reference numbers in square brackets in superscript at the end of citation content or after the cited author's name. For citation content which is part of the narration, the coding number and square brackets should be typeset normally. For example, "Crohn's disease (CD) is associated with increased intestinal permeability<sup>[1,2]</sup>". If references are cited directly in the text, they should be put together within the text, for example, "From references<sup>[19,22-24]</sup>, we know that..."

When the authors write the references, please ensure that the order in text is the same as in the references section, and also ensure the spelling accuracy of the first author's name. Do not list the same citation twice.

### PMID and DOI

Please provide PubMed citation numbers to the reference list, e.g. PMID and DOI, which can be found at <http://www.ncbi.nlm.nih.gov/sites/entrez?db=pubmed> and <http://www.crossref.org/SimpleTextQuery/>, respectively. The numbers will be used in E-version of this journal.

### Style for journal references

Authors: the name of the first author should be typed in bold-faced letters. The family name of all authors should be typed with the initial letter capitalized, followed by their abbreviated first and middle initials. (For example, Lian-Sheng Ma is abbreviated as Ma LS, Bo-Rong Pan as Pan BR). The title of the cited article and italicized journal title (journal title should be in its abbreviated form as shown in PubMed), publication date, volume number (in black), start page, and end page [PMID: 11819634 DOI: 10.3748/wjg.13.5396].

### Style for book references

Authors: the name of the first author should be typed in bold-faced letters. The surname of all authors should be typed with the initial letter capitalized, followed by their abbreviated middle and first initials. (For example, Lian-Sheng Ma is abbreviated as Ma LS, Bo-Rong Pan as Pan BR) Book title. Publication number. Publication place: Publication press, Year: start page and end page.

### Format

#### Journals

English journal article (list all authors and include the PMID where applicable)

- 1 **Jung EM**, Clevert DA, Schreyer AG, Schmitt S, Rennert J, Kubale R, Feuerbach S, Jung F. Evaluation of quantitative contrast harmonic imaging to assess malignancy of liver tumors: A prospective controlled two-center study. *World J Gastroenterol* 2007; **13**: 6356-6364 [PMID: 18081224 DOI: 10.3748/wjg.13.6356]

Chinese journal article (list all authors and include the PMID where applicable)

- 2 **Lin GZ**, Wang XZ, Wang P, Lin J, Yang FD. Immunologic effect of Jianpi Yishen decoction in treatment of Pixu-diarhoea. *Shijie Huaren Xiaohua Zazhi* 1999; **7**: 285-287

In press

- 3 **Tian D**, Araki H, Stahl E, Bergelson J, Kreitman M. Signature of balancing selection in Arabidopsis. *Proc Natl Acad Sci USA* 2006; In press

Organization as author

- 4 **Diabetes Prevention Program Research Group**. Hypertension, insulin, and proinsulin in participants with impaired glucose tolerance. *Hypertension* 2002; **40**: 679-686 [PMID: 12411462 PMID:2516377 DOI:10.1161/01.HYP.0000035706.28494.09]

Both personal authors and an organization as author

- 5 **Vallancien G**, Emberton M, Harving N, van Moorselaar RJ; Alf-One Study Group. Sexual dysfunction in 1, 274 European men suffering from lower urinary tract symptoms. *J Urol* 2003; **169**: 2257-2261 [PMID: 12771764 DOI:10.1097/01.ju.0000067940.76090.73]

No author given

- 6 21st century heart solution may have a sting in the tail. *BMJ* 2002; **325**: 184 [PMID: 12142303 DOI:10.1136/bmj.325.7357.184]

Volume with supplement

- 7 **Geraud G**, Spierings EL, Keywood C. Tolerability and safety of frovatriptan with short- and long-term use for treatment of migraine and in comparison with sumatriptan. *Headache* 2002; **42** Suppl 2: S93-99 [PMID: 12028325 DOI:10.1046/j.1526-4610.42.s2.7.x]

Issue with no volume

- 8 **Banit DM**, Kaufer H, Hartford JM. Intraoperative frozen section analysis in revision total joint arthroplasty. *Clin Orthop Relat Res* 2002; (**401**): 230-238 [PMID: 12151900 DOI:10.1097/00003086-200208000-00026]

No volume or issue

- 9 Outreach: Bringing HIV-positive individuals into care. *HRS-A Careaction* 2002; 1-6 [PMID: 12154804]

### Books

Personal author(s)

- 10 **Sherlock S**, Dooley J. Diseases of the liver and biliary system. 9th ed. Oxford: Blackwell Sci Pub, 1993: 258-296

Chapter in a book (list all authors)

- 11 **Lam SK**. Academic investigator's perspectives of medical treatment for peptic ulcer. In: Swabb EA, Azabo S. Ulcer disease: investigation and basis for therapy. New York: Marcel Dekker, 1991: 431-450

Author(s) and editor(s)

- 12 **Breedlove GK**, Schorffheide AM. Adolescent pregnancy. 2nd ed. Wiczorek RR, editor. White Plains (NY): March of Dimes Education Services, 2001: 20-34

Conference proceedings

- 13 **Harnden P**, Joffe JK, Jones WG, editors. Germ cell tumours V. Proceedings of the 5th Germ cell tumours Conference; 2001 Sep 13-15; Leeds, UK. New York: Springer, 2002: 30-56

Conference paper

- 14 **Christensen S**, Oppacher F. An analysis of Koza's computational effort statistic for genetic programming. In: Foster JA, Lutton E, Miller J, Ryan C, Tettamanzi AG, editors. Genetic programming. EuroGP 2002: Proceedings of the 5th European Conference on Genetic Programming; 2002 Apr 3-5; Kinsdale, Ireland. Berlin: Springer, 2002: 182-191

Electronic journal (list all authors)

- 15 Morse SS. Factors in the emergence of infectious diseases. *Emerg Infect Dis* serial online, 1995-01-03, cited 1996-06-05; 1(1): 24 screens. Available from: URL: <http://www.cdc.gov/ncidod/eid/index.htm>

Patent (list all authors)

- 16 **Pagedas AC**, inventor; Ancel Surgical R&D Inc., assignee. Flexible endoscopic grasping and cutting device and positioning tool assembly. United States patent US 20020103498. 2002 Aug 1

### Statistical data

Write as mean  $\pm$  SD or mean  $\pm$  SE.

### Statistical expression

Express *t* test as *t* (in italics), *F* test as *F* (in italics), chi square test as  $\chi^2$  (in Greek), related coefficient as *r* (in italics), degree of freedom as *v* (in Greek), sample number as *n* (in italics), and probability as *P* (in italics).

### Units

Use SI units. For example: body mass, m (B) = 78 kg; blood pres-

sure,  $p$  (B) = 16.2/12.3 kPa; incubation time,  $t$  (incubation) = 96 h, blood glucose concentration,  $c$  (glucose)  $6.4 \pm 2.1$  mmol/L; blood CEA mass concentration,  $p$  (CEA) = 8.6 24.5  $\mu$ g/L; CO<sub>2</sub> volume fraction, 50 mL/L CO<sub>2</sub>, not 5% CO<sub>2</sub>; likewise for 40 g/L formaldehyde, not 10% formalin; and mass fraction, 8 ng/g, *etc.* Arabic numerals such as 23, 243, 641 should be read 23243641.

The format for how to accurately write common units and quantums can be found at: [http://www.wjgnet.com/2218-5836/g\\_info\\_20100724204625.htm](http://www.wjgnet.com/2218-5836/g_info_20100724204625.htm).

### Abbreviations

Standard abbreviations should be defined in the abstract and on first mention in the text. In general, terms should not be abbreviated unless they are used repeatedly and the abbreviation is helpful to the reader. Permissible abbreviations are listed in Units, Symbols and Abbreviations: A Guide for Biological and Medical Editors and Authors (Ed. Baron DN, 1988) published by The Royal Society of Medicine, London. Certain commonly used abbreviations, such as DNA, RNA, HIV, LD50, PCR, HBV, ECG, WBC, RBC, CT, ESR, CSF, IgG, ELISA, PBS, ATP, EDTA, mAb, can be used directly without further explanation.

### Italics

Quantities:  $t$  time or temperature,  $c$  concentration,  $A$  area,  $l$  length,  $m$  mass,  $V$  volume.

Genotypes: *gyrA*, *arg 1*, *c myc*, *c fos*, *etc.*

Restriction enzymes: *EcoRI*, *HindI*, *BamHI*, *Kbo I*, *Kpn I*, *etc.*

Biology: *H. pylori*, *E. coli*, *etc.*

### Examples for paper writing

All types of articles' writing style and requirement will be found in the link: <http://www.wjgnet.com/esps/NavigationInfo.aspx?id=15>

## RESUBMISSION OF THE REVISED MANUSCRIPTS

Authors must revise their manuscript carefully according to the revision policies of BPG. The revised version, along with the signed copyright transfer agreement, responses to the reviewers, and English language Grade A certificate (for non-native speakers of English), should be submitted to the online system via the link contained in the e-mail sent by the editor. If you have any questions about the revision, please send e-mail to [esps@wjgnet.com](mailto:esps@wjgnet.com).

### Language evaluation

The language of a manuscript will be graded before it is sent for revision. (1) Grade A: priority publishing; (2) Grade B: minor language polishing; (3) Grade C: a great deal of language polishing needed; and (4) Grade D: rejected. Revised articles should reach Grade A.

### Copyright assignment form

Please download a Copyright assignment form from [http://www.wjgnet.com/2218-5836/g\\_info\\_20100724204516.htm](http://www.wjgnet.com/2218-5836/g_info_20100724204516.htm).

### Responses to reviewers

Please revise your article according to the comments/suggestions provided by the reviewers. The format for responses to the reviewers' comments can be found at: [http://www.wjgnet.com/2218-5836/g\\_info\\_20100724204306.htm](http://www.wjgnet.com/2218-5836/g_info_20100724204306.htm).

### Proof of financial support

For papers supported by a foundation, authors should provide a copy of the approval document and serial number of the foundation.

## STATEMENT ABOUT ANONYMOUS PUBLICATION OF THE PEER REVIEWERS' COMMENTS

In order to increase the quality of peer review, push authors to carefully revise their manuscripts based on the peer reviewers' comments, and promote academic interactions among peer reviewers, authors and readers, we decide to anonymously publish the reviewers' comments and author's responses at the same time the manuscript is published online.

## PUBLICATION FEE

WJO is an international, peer-reviewed, OA online journal. Articles published by this journal are distributed under the terms of the Creative Commons Attribution Non-commercial License, which permits use, distribution, and reproduction in any medium and format, provided the original work is properly cited. The use is non-commercial and is otherwise in compliance with the license. Authors of accepted articles must pay a publication fee. Publication fee: 698 USD per article. All invited articles are published free of charge.



Published by **Baishideng Publishing Group Inc**

8226 Regency Drive, Pleasanton, CA 94588, USA

Telephone: +1-925-223-8242

Fax: +1-925-223-8243

E-mail: [bpgoffice@wjgnet.com](mailto:bpgoffice@wjgnet.com)

Help Desk: <http://www.wjgnet.com/esps/helpdesk.aspx>

<http://www.wjgnet.com>

