

# World Journal of *Orthopedics*

*World J Orthop* 2014 April 18; 5(2): 69-157





## Editorial Board

2010-2014

The *World Journal of Orthopedics* Editorial Board consists of 433 members, representing a team of worldwide experts in orthopedics. They are from 42 countries, including Argentina (1), Australia (18), Austria (5), Bangladesh (1), Belgium (2), Brazil (4), Canada (11), China (42), Croatia (2), Denmark (2), Egypt (5), Finland (3), France (4), Germany (14), Greece (16), Hungary (1), India (12), Iran (4), Ireland (2), Israel (13), Italy (24), Japan (22), Morocco (1), Netherlands (14), New Zealand (1), Norway (4), Portugal (1), Qatar (1), Saudi Arabia (4), Serbia (3), Singapore (4), Slovenia (1), South Korea (21), Spain (5), Sri Lanka (1), Sweden (4), Switzerland (8), Thailand (3), Tunisia (2), Turkey (7), United Kingdom (17), and United States (123).

### EDITOR-IN-CHIEF

Bao-Gan Peng, *Beijing*

### STRATEGY ASSOCIATE

#### EDITORS-IN-CHIEF

Jenni M Buckley, *San Francisco*

Vijay K Goel, *Toledo*

James F Griffith, *Hong Kong*

Thomas W Kaminski, *Newark*

Enrico Pola, *Rome*

Masato Takao, *Tokyo*

### GUEST EDITORIAL BOARD

#### MEMBERS

Chih-Hwa Chen, *Keelung*

Ruei-Ming Chen, *Taipei*

Yen-Jen Chen, *Taichung*

Pang-Hsin Hsieh, *Taoyuan*

Kuo-Chin Huang, *Chia-Yi*

Tung-Fu Huang, *Taipei*

Shao-Hung Hung, *Tungkang PingTung*

Chian-Her Lee, *Taipei*

Yih-Shiunn Lee, *Taichung*

Po-Chou Liliang, *Kaohsiung*

Feng-Huei Lin, *Taipei*

Jiu-jenq Lin, *Taipei*

Fu-Chan Wei, *Taoyuan*

Ta-Sen Wei, *Changhua*

Chih-Shung Wong, *Taipei*

Jui-Tien Shih, *Taoyuan*

Chen Yuk-Kwan, *Kaohsiung*

### MEMBERS OF THE EDITORIAL

#### BOARD



**Argentina**

Martin Alejandro Buttaró, *Aires*



**Australia**

Gerald James Atkins, *Adelaide*

Gregory Ian Bain, *Adelaide*

Darren John Beales, *Atwell*

Belinda R Beck, *Gold Coast*

Adam Leigh Bryant, *Melbourne*

Changhai Ding, *Hobart*

Ashish Dhar Diwan, *Sydney*

Herwig Drobetz, *Mackay*

Melanie Franklyn, *Melbourne*

Rana Shane Hinman, *Melbourne*

Konstantin I Momot, *Brisbane*

George Samuel Murley, *Melbourne*

Michael E Schneider-Kolsky, *Clayton*

Jerzy M Sikorski, *Perth*

Gordon L Slater, *Albury*

Lucian Bogdan Solomon, *Adelaide*

Mark Watsford, *Sydney*

Cory J Xian, *Adelaide*



**Austria**

Florian Kutscha-Lissberg, *Vienna*

Kevin Laudner, *Innsbruck*

Stefan Toegel, *Vienna*

Klemens Trieb, *Wels*

Heinz KL Winkler, *Wien*



**Bangladesh**

Saidur Rahman Mashreky, *Dhaka*



**Belgium**

Olivier Bruyere, *Liege*

Hendrik Pieter Delpont, *Sint Niklaas*



**Brazil**

Djalma José Fagundes, *São Paulo*

Francisco Bandeira Farias, *Recife*

Eduardo Magalhaes, *São Paulo*

Luci F Teixeira-Salmela, *Minas Gerais*



**Canada**

Richard E Buckley, *Calgary*

Prince Francois, *Quebec*

Reggie Charles Hamdy, *Montreal*

Michael Anthony Hunt, *Columbia*

Richard Kremer, *Montreal*

Jean-Marc Mac-Thiong, *Montreal*

Fackson Mwale, *Montreal*

Vasileios Nikolaou, *Toronto*

Christy C Tomkins-Lane, *Calgary*

Robert E Turcotte, *Quebec*

Stephen D Waldman, *Kingston*



**China**

Yu-Ming Chen, *Guangzhou*

Wing-Hoi Cheung, *Hong Kong*

Hong-Bin Fan, *Xi'an*

Daniel YT Fong, *Hong Kong*

Li-Xin Guo, *Shenyang*

Xia Guo, *Hong Kong*

Xiong Guo, *Xi'an*

Lui-Tun Hing, *Hong Kong*

Jing Hu, *Chengdu*

Yong Hu, *Hong Kong*

Kai-Fu Huo, *Wuhan*

Xiang-Hang Luo, *Changsha*  
 Zhuo-Jing Luo, *Xi'an*  
 Marco YC Pang, *Hong Kong*  
 Ling Qin, *Hong Kong*  
 Jun Tan, *Shanghai*  
 Ricky WK Wong, *Hong Kong*  
 Tak-Chuen Wong, *Hong Kong*  
 Hua-Zi Xu, *Wenzhou*  
 Bin-Sheng Yu, *Guangzhou*  
 Ge Zhang, *Hong Kong*  
 Ming Zhang, *Hong Kong*  
 Jian-Hua Zhao, *Chongqing*



#### Croatia

Robert Kolundzic, *Zgareb*  
 Tomislav Smoljanovic, *Zagreb*



#### Denmark

Stig Brorson, *Copenhagen*  
 Morten Tange Kristensen, *Copenhagen*



#### Egypt

Khaled M Emara, *Cairo*  
 Mohamed Kenawey, *Sohag*  
 Wael MT Koptan, *Cairo*  
 Mahmoud Mahran, *Cairo*  
 Elsayed I Elsayed Massoud, *Elghad*



#### Finland

Timo Järvelä, *Tampere*  
 Yrjö T Konttinen, *Helsinki*  
 Petri Sillanpää, *Tampere*



#### France

Federico Canavese, *Ferrand*  
 Jean-Alain Epinette, *Labuissiere*  
 Yiou Eric, *Paris*  
 Sebastien Zilber, *Paris*



#### Germany

Stefan Grote, *Munich*  
 Carl Haasper, *Hannover*  
 Jorn Kircher, *Düsseldorf*  
 Karsten Knobloch, *Hannover*  
 Philipp Kobbe, *Aachen*  
 Heinz Lohrer, *Main*  
 Olaf Lorbach, *Homburg*  
 Annegret Mündermann, *Radolfzell*  
 Markus Regauer, *München*  
 Volker Schoffl, *Bamberg*  
 Arndt P Schulz, *Lübeck*  
 Sebastian Seitz, *Hamburg*  
 Lars Victor Baron von Engelhardt, *Bochum*  
 Goetz Hannes Welsch, *Erlangen*



#### Greece

Evangelos C Alexopoulos, *Athens*

Stergioulas Thomas Apostolos, *Peloponnese*  
 Constantinos D Apostolou, *Attiki*  
 George C Babis, *Chaidari*  
 Georgios I Drosos, *Alexandroupolis*  
 Christos Garnavos, *Athens*  
 Panagiotis Korovessis, *Patras*  
 Marios Georgios Lykissas, *Ioannina*  
 Dimitrios N Lyras, *Alexandroupolis*  
 Konstantinos N Malizos, *Larissa*  
 Yannis Manios, *Athens*  
 Nikolaos G Papadimitriou, *Thessaloniki*  
 Vassilis Paschalis, *Trikala*  
 Lazaros I Sakkas, *Larissa*  
 Haris S Vasiliadis, *Ioannina*  
 Marianna Vlychou, *Thessaly*



#### Hungary

Andor Sebestyén, *Pécs*



#### India

Vaibhav Bagaria, *Ghaziabad*  
 Kemmannu Vikram Bhat, *Hubli*  
 Antony Gomes, *Calcutta*  
 Shah Alam Khan, *New Delhi*  
 Thomas Joseph Kishen, *Bangalore*  
 Pankaj Kumar, *Andhra Pradesh Pin*  
 Pramod V Lokhande, *Pune*  
 Devdatta Suhas Neogi, *Mumbai*  
 Mohamed Shafi, *Tamil Nadu State*  
 Kunal Sharan, *Lucknow*  
 Vidyadhara Srinivasa, *Karnataka*  
 Divya Vohora, *New Delhi*



#### Iran

Masood Mazaheri, *Isfahan*  
 Sayed Javad Mousavi, *Tehran*  
 Hossein Negahban, *Ahvaz*  
 Ali Razmkon, *Shiraz*



#### Ireland

Joseph S Butler, *Dublin*  
 Eamonn Delahun, *Dublin*



#### Israel

Itai A Bab, *Jerusalem*  
 Itzhak Binderman, *Tel Aviv*  
 Alexander Blankstein, *Ramat Hasharon*  
 Itay Fenichel, *Udim*  
 Aharon Finestone, *Reut*  
 Amir Herman, *Ramat-Gan*  
 Dror Lakstein, *Holon*  
 Yocheved Laufer, *Haifa*  
 Youssef Maher Masharawi, *Tel Aviv*  
 Francis B Mimouni, *Jerusalem*  
 Jacob Kobi Peleg, *Tel Hashomer*  
 Nahum Rosenberg, *Haifa*  
 Yehuda Ullmann, *Haifa*



#### Italy

Saverio Affatato, *Bologna*

Patrizia D Amelio, *Torino*  
 Giuseppe Banfi, *Milano*  
 Angelo Cacchio, *L'Aquila*  
 Giuseppe M Campo, *Messina*  
 Marco Crostelli, *Rome*  
 Pasquale De Negri, *Rionero in Vulture*  
 Alessandro de Stefano, *Bari*  
 Alberto Deganello, *Florence*  
 Costantino Errani, *Bologna*  
 Alessandro Geraci, *Feltre*  
 Andrea Giusti, *Genova*  
 Alberto Gobbi, *Milan*  
 Donatella Lippi, *Florence*  
 Marcello Maggio, *Parma*  
 Gian Luigi Marseglia, *Milano*  
 Monica Mattioli-Belmonte, *Ancona*  
 Claudia Mazzà, *Rome*  
 Marco Monticone, *Lissone*  
 Raoul Saggini, *Chieti*  
 Umberto Tarantino, *Rome*  
 Marco Giuseppe Angelo Teli, *Bergamo*  
 Tomaso Villa, *Milano*



#### Japan

Yoichi Aota, *Yokohama*  
 Jun Iwamoto, *Tokyo*  
 Shuichi Kaneyama, *Kobe*  
 Yuichi Kasai, *Tsu city*  
 Shigeru Kobayashi, *Fukui*  
 Tomihisa Koshino, *Yokohama*  
 Nobuyuki Kumahashi, *Shimane-ken*  
 Makoto Makishima, *Tokyo*  
 Toru Maruyama, *Saitama*  
 Kanji Mori, *Otsu*  
 Satoshi Mori, *Hamamatsu Shizuoka*  
 Ryuichi Morishita, *Suita*  
 Yasuharu Nagano, *Saitama*  
 Hideki Nagashima, *Tottori*  
 Mitsuo Ochi, *Hiroshima*  
 Akio Sakamoto, *Fukuoka*  
 Yasuaki Tokuhashi, *Tokyo*  
 Toshimasa Uemura, *Ibaraki*  
 Hisataka Yasuda, *Nagahama*  
 Takafumi Yoshikawa, *Nara*  
 Tadahiko Yotsumoto, *Higashisaka-city*



#### Morocco

Abdellah EI Maghraoui, *Rabat*



#### Netherlands

Taco Gosens, *Tilburg*  
 PE Huijsmans, *The Hague*  
 Paul C Jutte, *Groningen*  
 Claudine JC Lamoth, *Groningen*  
 Esther Maria Maartje, *Rotterdam*  
 RGH Nelissen, *Leiden*  
 Rob GH Nelissen, *Leiden*  
 Christiaan JA van Bergen, *Amsterdam*  
 Michel van den Bekerom, *Amsterdam*  
 PM van der Kraan, *Nijmegen*  
 BCH van der Wal, *Amersfoort*  
 TM van Raaij, *Groningen*

Barend J Van Royen, *Amsterdam*  
JJ Verlaan, *Utrecht*



#### **New Zealand**

Doug King, *Lower Hutt*



#### **Norway**

Jan Oxholm Gordeladze, *Oslo*  
Anne Keller, *Oslo*  
Gunnar Knutsen, *Tromsø*  
Inigo Martinez, *Tromsø*



#### **Portugal**

João F Mano, *Guimarães*



#### **Qatar**

Cristiano Eirale, *Doha*



#### **Saudi Arabia**

Sultan Abdulaziz Al Mubarak, *Riyadh*  
Einass Al-Eisa, *Riyadh*  
Mir Sadat Ali, *AlKhobar*  
Mohamed Zamzam, *Riyadh*



#### **Serbia**

Radica Dunjic, *Belgrade*  
Miroslav Z Milankov, *Novi Sad*  
Zoran Vukasinovic, *Serbia*



#### **Singapore**

Hwan Tak Hee, *Singapore*  
V Prem Kumar, *Singapore*  
Anselm Mak, *Singapore*  
Dongan Wang, *Singapore*



#### **Slovenia**

Matjaz Sajovic, *Celje*



#### **South Korea**

Seung-Hoon Baek, *Daegu*  
Gun Choi, *Seoul*  
Kook Jin Chung, *Seoul*  
Jae Taek Hong, *Suwon*  
Dae-Geun Jeon, *Seoul*  
Hyun Woo Kim, *Seoul*  
Jae Kwang Kim, *Seoul*  
Seok Woo Kim, *Gyeonggi*  
Shin-Yoon Kim, *Daegu*  
Young Hoon Kim, *Seoul*  
Sang-Hun Ko, *Ulsan City*  
Sung-Uk Kuh, *Seoul*  
Jaebeom Lee, *Miryang*

Sang Ki Lee, *Daejeon*  
Yong Seuk Lee, *Suwon*  
Jin-Young Park, *Seoul*  
Jong-Beom Park, *Kyunggi-do*  
Yang-Sik Shin, *Seoul*  
Eun Kyoo Song, *Jeonnam*  
Paul S Sung, *Seoul*  
Kyu Hyun Yang, *Seoul*



#### **Spain**

Enrique Gomez Barrena, *Madrid*  
Francisco J Blanco Garcia, *Coruna*  
Antonio Herrera, *Zaragoza*  
Daniel Hernandez Vaquero, *Aviles*  
Nuria Vilaboa, *Madrid*



#### **Sri Lanka**

Janaka Lenora, *Galle*



#### **Sweden**

Paul Ackermann, *Stockholm*  
Jan G Jakobsson, *Stockholm*  
Anna Nordström, *Umeå*  
Ola Rolfson, *Mölnådal*



#### **Switzerland**

Achim Elfering, *Bern*  
Peter Fennema, *Baar*  
Bruno Fuchs, *Zürich*  
Benjamin Gantenbein, *Bern*  
Michael Hirschmann, *Basel*  
Beat Knechtle, *St. Gallen*  
Nicola A Maffioletti, *Zurich*  
Elyazid Mouhsine, *Lausanne*



#### **Thailand**

Sittisak Honsawek, *Bangkok*  
Prachya Kongtawelert, *Chiang Mai*  
Boonsin Tangtrakulwanich, *Songkla*



#### **Tunisia**

Abdelkader Krichen, *Sfax*  
Lamia Rezgui-Marhouli, *Tunis*



#### **Turkey**

Bulent Daglar, *Ankara*  
Serkan Erkan, *Manisa*  
Serdar Kahraman, *Istanbul*  
Akmer Mutlu, *Samanpazari Ankara*  
Kemal NAS, *Diyarbakir*  
Salih Ozgocmen, *Kayseri*  
Haluk H Oztekin, *Izmir*



#### **United Kingdom**

Henry DE Atkinson, *London*  
Abhijit Manohar Bhosale, *South York-*

*shire*

Sarah Cartmell, *Manchester*  
David Chesney, *Scotland*  
Yogesh D Kamat, *Surrey*  
Vikas Khanduja, *Cambridge*  
Ranjith Ravindran Kuzhupilly, *Basildon*  
Hammad Malik, *Manchester*  
Jitendra Mangwani, *Wiltshire*  
Ali Mobasheri, *Sutton Bonington*  
Tosan Okoro, *Bangor*  
Hemant G Pandit, *Oxford*  
Mathew Sewell, *Teddington*  
Eleftherios Tsiridis, *London*  
Charles Willis-Owen, *London*  
Vikki Wyld, *Bristol*  
Wei-Ya Zhang, *Nottingham*



#### **United States**

Joseph A Abboud, *Philadelphia*  
Matthew S Abrahams, *Portland*  
David S Bailie, *Scottsdale*  
B Sonny Bal, *Columbia*  
Matthew J Beckman, *Richmond*  
Inna Belfer, *Pittsburgh*  
Angie Botto-van Bemden, *Lauderdale*  
Srino Bharam, *New York*  
Anil Bhave, *Baltimore*  
Craig R Bottoni, *Honolulu*  
Adam Matthew Brufsky, *Pittsburgh*  
Lavjay Butani, *Sacramento*  
Edmund Y S Chao, *Corona*  
Chaoyang Chen, *Detroit*  
R Tong Chuanhe, *Chicago*  
Ock K Chun, *Storrs*  
Christopher J Colloca, *Chandler*  
Quanjun Cui, *Virginia*  
Scott D Daffner, *Morgantown*  
Nabanita S Datta, *Detroit*  
Paul E Di Cesare, *Sacramento*  
Clark Dickin, *Muncie*  
Matthew B Dobbs, *Saint Louis*  
Tammy L Haut Donahue, *Houghton*  
Zhenfeng Duan, *Boston*  
John S Early, *Dallas*  
Jason C Eck, *Worcester*  
Evan F Ekman, *Columbia*  
Steven Howard Elder, *Mississippi*  
John Elias, *Akron*  
David A Fisher, *Indianapolis*  
Michael Fredericson, *Redwood City*  
Joel J Gagnier, *Ann Arbor*  
Glen Michael Ginsburg, *Omaha*  
Federico P Girardi, *New York*  
Beril Gok, *Baltimore*  
Ashraf S Gorgey, *Richmond*  
David J Hak, *Denver*  
Sam Hakki, *Bay Pines*  
Sheri Hale, *Winchester*  
Kyung Mo Han, *Washington*  
James S Harrop, *Philadelphia*  
Erin Hartigan, *Portland*  
Brian Michael Haus, *Boston*  
David L Helfet, *New York*  
John H Hollman, *Rochester*  
Adam H Hsieh, *College Park*  
Johnny Huard, *Pittsburgh*  
G Russell Huffman, *Philadelphia*  
Mozammil Hussain, *Chesterfield*  
Stefan Judex, *Stony Brook*

David Hanwuk Kim, *Boston*  
 Kee D Kim, *Sacramento*  
 Gary Krishnan, *Fishers*  
 Michael A Kuhn, *North Carolina*  
 Shrawan Kumar, *Fort Worth*  
 Monroe Laborde, *New Orleans*  
 Kevin Laudner, *Normal*  
 Bingyun Li, *Morgantown*  
 Xiao-Juan Li, *San Francisco*  
 Ye-Fu Li, *Boston*  
 Zhongyu John Li, *Winston-Salem*  
 Zong-Ming Li, *Cleveland*  
 Chuanju Liu, *New York*  
 Richard M Lovering, *Baltimore*  
 Raman C Mahabir, *Temple*  
 Aditya V Maheshwari, *Brooklyn*  
 Kenneth Allen Mann, *Syracuse*  
 Lyle Joseph Micheli, *Boston*  
 Subburaman Mohan, *Loma Linda*  
 Arash Momeni, *Palo Alto*  
 Nader D Nader, *Buffalo*  
 Rahul Kumar Nath, *Houston*  
 John Nyland, *Louisville*

Brett D Owens, *New York*  
 Dror Paley, *Florida*  
 George Papaioannou, *Milwaukee*  
 Evangelos Pappas, *Brooklyn*  
 Paul Park, *Ann Arbor*  
 Javad Parvizi, *Philadelphia*  
 Ming Pei, *Morgantown*  
 Juan A Pretell, *Philadelphia*  
 Mark D Price, *Worcester*  
 R Lor Randall, *Salt Lake City*  
 Bruce M Rothschild, *Kansas*  
 David P Roye JR, *New York*  
 Thomas A Russell, *Tennessee*  
 G James Sammarco, *Cincinnati*  
 Aaron David Sciascia, *Lexington*  
 Jason Scott Scibek, *Pittsburgh*  
 David M Selkowitz, *Pomona*  
 Hassan Serhan, *Raynham*  
 Chwan-Li Shen, *Lubbock*  
 Francis H Shen, *Charlottesville*  
 Sorin Siegler, *Philadelphia*  
 Karin Gräware Silbernagel, *Newark*  
 David H Song, *Chicago*

Nelson F SooHoo, *Los Angeles*  
 David Andrew Spiegel, *Philadelphia*  
 SPA Stawicki, *Columbus*  
 Marcus B Stone, *Highland*  
 Ann Marie Swank, *Louisville*  
 James S Thomas, *Athens*  
 R Shane Tubbs, *Birmingham*  
 Victoria M Virador, *Bethesda*  
 Bing Wang, *Pittsburgh*  
 Jeffrey C Wang, *Monica*  
 Wenbao Wang, *New York*  
 Terry L Whipple, *Richmond*  
 Savio LY Woo, *Pittsburgh*  
 Dane K Wukich, *Pittsburgh*  
 Masayoshi Yamaguchi, *Atlanta*  
 Feng-Chun Yang, *Indianapolis*  
 Shang-You Yang, *Wichita*  
 Subhashini Yaturu, *Albany*  
 Hiroki Yokota, *Troy*  
 Charalampos Zalavras, *Los Angeles*  
 Li-Qun Zhang, *Chicago*  
 Chunfeng Zhao, *Rochester*  
 Nigel Zheng, *Charlotte*





### TOPIC HIGHLIGHT

- 69 Muscle force and movement variability before and after total knee arthroplasty: A review  
*Smith JW, Christensen JC, Marcus RL, LaStayo PC*
- 80 New perspectives for articular cartilage repair treatment through tissue engineering: A contemporary review  
*Musumeci G, Castrogiovanni P, Leonardi R, Trovato FM, Szychlinska MA, Di Giunta A, Loreto C, Castorina S*
- 89 Research in spinal surgery: Evaluation and practice of evidence-based medicine  
*Oppenlander ME, Maulucci CM, Ghobrial GM, Harrop JS*
- 94 Modern posterior screw techniques in the pediatric cervical spine  
*Hedequist DJ*
- 100 Perioperative visual loss after spine surgery  
*Nickels TJ, Manlapaz MR, Farag E*
- 107 Impact of rheumatoid arthritis on sexual function  
*Tristano AG*

### REVIEW

- 112 Techniques and accuracy of thoracolumbar pedicle screw placement  
*Puvanesarajah V, Liauw JA, Lo SF, Lina IA, Witham TF*
- 124 Surgical advances in the treatment of neuromuscular scoliosis  
*Canavese F, Rousset M, Le Gledic B, Samba A, Dimeglio A*
- 134 Pathophysiology, diagnosis and treatment of intermittent claudication in patients with lumbar canal stenosis  
*Kobayashi S*

### MINIREVIEWS

- 146 Painful sesamoid of the great toe  
*Sims AL, Kurup HV*

**BRIEF ARTICLE****151** Clinical results of linezolid in arthroplasty and trauma related infections*Joel J, Graham SM, Peckham-Cooper A, Korres N, Tsouchnica H, Tsiridis E*

## Contents

*World Journal of Orthopedics*  
Volume 5 Number 2 April 18, 2014

**APPENDIX** I-V Instructions to authors

**ABOUT COVER** Editorial Board Member of *World Journal of Orthopedics*, David A Fisher, MD, Assistant Clinical Professor, Indiana University School of Medicine, OrthoIndy 8450, Northwest Blvd, Indianapolis, IN 46278, United States

**AIM AND SCOPE** *World Journal of Orthopedics* (*World J Orthop*, *WJO*, online ISSN 2218-5836, DOI: 10.5312) is a peer-reviewed open access academic journal that aims to guide clinical practice and improve diagnostic and therapeutic skills of clinicians.

*WJO* covers topics concerning arthroscopy, evidence-based medicine, epidemiology, nursing, sports medicine, therapy of bone and spinal diseases, bone trauma, osteoarthropathy, bone tumors and osteoporosis, minimally invasive therapy, diagnostic imaging. Priority publication will be given to articles concerning diagnosis and treatment of orthopedic diseases. The following aspects are covered: Clinical diagnosis, laboratory diagnosis, differential diagnosis, imaging tests, pathological diagnosis, molecular biological diagnosis, immunological diagnosis, genetic diagnosis, functional diagnostics, and physical diagnosis; and comprehensive therapy, drug therapy, surgical therapy, interventional treatment, minimally invasive therapy, and robot-assisted therapy.

We encourage authors to submit their manuscripts to *WJO*. We will give priority to manuscripts that are supported by major national and international foundations and those that are of great basic and clinical significance.

**INDEXING/ABSTRACTING** *World Journal of Orthopedics* is now indexed in PubMed Central, PubMed, Digital Object Identifier, and Directory of Open Access Journals.

**FLYLEAF** I-IV Editorial Board

## EDITORS FOR THIS ISSUE

Responsible Assistant Editor: *Xiang Li*  
Responsible Electronic Editor: *Ya-Jing Lu*  
Proofing Editor-in-Chief: *Lian-Sheng Ma*

Responsible Science Editor: *Ling-Ling Wen*

NAME OF JOURNAL  
*World Journal of Orthopedics*

ISSN  
ISSN 2218-5836 (online)

LAUNCH DATE  
November 18, 2010

FREQUENCY  
Quarterly

EDITOR-IN-CHIEF  
**Bao-Gan Peng, MD, PhD, Professor**, Department of Spinal Surgery, General Hospital of Armed Police Force, 69 Yongding Road, Beijing 100039, China

EDITORIAL OFFICE  
Jin-Lei Wang, Director  
Xiu-Xia Song, Vice Director

*World Journal of Orthopedics*  
Room 903, Building D, Ocean International Center, No. 62 Dongsihuan Zhonglu, Chaoyang District, Beijing 100025, China  
Telephone: +86-10-85381891  
Fax: +86-10-85381893  
E-mail: [bjgoffice@wjgnet.com](mailto:bjgoffice@wjgnet.com)  
<http://www.wjgnet.com>

PUBLISHER  
Baishideng Publishing Group Co., Limited  
Flat C, 23/F, Lucky Plaza, 315-321 Lockhart Road, Wan Chai, Hong Kong, China  
Fax: +852-65557188  
Telephone: +852-31779906  
E-mail: [bjgoffice@wjgnet.com](mailto:bjgoffice@wjgnet.com)  
<http://www.wjgnet.com>

PUBLICATION DATE  
April 18, 2014

## COPYRIGHT

© 2014 Baishideng. Articles published by this Open-Access journal are distributed under the terms of the Creative Commons Attribution Non-commercial License, which permits use, distribution, and reproduction in any medium, provided the original work is properly cited, the use is non commercial and is otherwise in compliance with the license.

## SPECIAL STATEMENT

All articles published in this journal represent the viewpoints of the authors except where indicated otherwise.


## INSTRUCTIONS TO AUTHORS

Full instructions are available online at [http://www.wjgnet.com/2218-5836/g\\_info\\_20100722172650.htm](http://www.wjgnet.com/2218-5836/g_info_20100722172650.htm)

## ONLINE SUBMISSION

<http://www.wjgnet.com/esps/>





WJO 5<sup>th</sup> Anniversary Special Issues (5): Knee

## Muscle force and movement variability before and after total knee arthroplasty: A review

Jessica W Smith, Jesse C Christensen, Robin L Marcus, Paul C LaStayo

Jessica W Smith, Paul C LaStayo, Department of Bioengineering, University of Utah, Salt Lake City, UT 84108-1290, United States

Jessica W Smith, Jesse C Christensen, Robin L Marcus, Paul C LaStayo, Department of Physical Therapy, University of Utah, Salt Lake City, UT 84108-1290, United States

Paul C LaStayo, Department of Orthopedics, University of Utah, Salt Lake City, UT 84108-1290, United States

Paul C LaStayo, Department of Exercise and Sport Science, University of Utah, Salt Lake City, UT 84108-1290, United States

**Author contributions:** Smith JW contributed significantly to the intellectual content, review of the literature, and overall organization of the manuscript, as well as wrote the majority of the manuscript; Christensen JC contributed significantly to the intellectual content, review of the literature, and overall organization of the manuscript, and assisted in the writing of the manuscript; Marcus RL and LaStayo PC contributed to the intellectual content and interpretation of data.

**Correspondence to:** Jessica W Smith, PhD, Department of Bioengineering, University of Utah, 201 Presidents Cir, Salt Lake City, UT 84108-1290, United States. [j.smith@utah.edu](mailto:j.smith@utah.edu)

Telephone: +1-801-5567360 Fax: +1-801-6067441

Received: December 29, 2013 Revised: February 26, 2014

Accepted: March 11, 2014

Published online: April 18, 2014

### Abstract

Variability in muscle force output and movement variability are important aspects of identifying individuals with mobility deficits, central nervous system impairments, and future risk of falling. This has been investigated in elderly healthy and impaired adults, as well as in adults with osteoarthritis (OA), but the question of whether the same correlations also apply to those who have undergone a surgical intervention such as total knee arthroplasty (TKA) is still being investigated. While there is a growing body of literature identifying potential rehabilitation targets for individuals who have undergone TKA, it is important to first understand the underlying post-operative impairments to more efficiently target functional deficits that may lead to improved

long-term outcomes. The purpose of this article is to review the potential role of muscle force output and movement variability in TKA recipients. The narrative review relies on existing literature in elderly healthy and impaired individuals, as well as in those with OA before and following TKA. The variables that may predict long-term functional abilities and deficits are discussed in the context of existing literature in healthy older adults and older adults with OA and following TKA, as well as the role future research in this field may play in providing evidence-based data for improved rehabilitation targets.

© 2014 Baishideng Publishing Group Co., Limited. All rights reserved.

**Key words:** Osteoarthritis; Elderly; Total knee arthroplasty; Movement variability

**Core tip:** Muscle force output and movement variability are important aspects of identifying individuals with mobility deficits, central nervous system impairments, as well as future risk of falling. These correlations have primarily been investigated in elderly healthy and impaired adults, as well as in adults with osteoarthritis (OA), but the question of whether the same correlations also apply to those who have undergone a surgical intervention such as total knee arthroplasty (TKA) are still being investigated. The variables that may predict long-term functional abilities and deficits are discussed in the context of existing literature in healthy older adults and older adults with OA and following TKA.

Smith JW, Christensen JC, Marcus RL, LaStayo PC. Muscle force and movement variability before and after total knee arthroplasty: A review. *World J Orthop* 2014; 5(2): 69-79 Available from: URL: <http://www.wjgnet.com/2218-5836/full/v5/i2/69.htm> DOI: <http://dx.doi.org/10.5312/wjo.v5.i2.69>

## INTRODUCTION

Knee osteoarthritis (OA) is the most common type of arthritis, affecting over 37% of Americans 60 years and older<sup>[1]</sup>. Of these, approximately 12% have symptoms<sup>[1]</sup> that frequently include pain and loss of motion, resulting in restricted activity, decreased neuromuscular control, impaired proprioceptive acuity, and loss of independence during activities of daily living<sup>[2,3]</sup>. When symptoms become severe as in late stages of OA, many individuals seek additional treatment interventions that often include the total knee arthroplasty (TKA) surgical procedure. Not surprisingly, the increasing prevalence of knee OA coincides with a growing demand for TKA procedures, with an expected 6-fold increase in surgeries by the year 2030<sup>[4]</sup>. In light of this heightened demand, the need for evidence-based rehabilitation protocols that maximize long-term physical and muscle function is critically important.

TKA is often effective for pain relief, but the outcomes of this surgical procedure do not often achieve similar, long-term improvements in both physical and muscle function<sup>[5-7]</sup>. To counteract these deficits, it is important to better understand how TKA may influence various physical and muscle performance parameters that predispose an individual to impaired function post-operatively. Muscle atrophy, muscle weakness, and neuromuscular activation deficits are all factors associated with functional impairments in adults with OA and there is a growing body of evidence suggesting that impairments in these areas lead to variability in muscle force output and movement patterns both pre- and post-operatively. The implications of muscle force output and movement variability in the ability to perform functional tasks is underappreciated in the literature, but could hold value in understanding the ramifications of functional impairments, as well as developing focused rehabilitation protocols that improve long-term functional outcomes in the OA and TKA patient populations.

The purpose of this narrative review is to expose and summarize the current evidence related to variability in muscle force output and movement patterns that occur in older individuals with knee OA before and after TKA. The implications of variable muscle force output and movement during common mobility tasks will be highlighted. Further, the concept that variability may have advantages and disadvantages in individuals with knee OA and following TKA will be explored.

For the purposes of this review, variability is described in two contexts: (1) as the variability an individual displays in muscle force output measured by the amplitude of force fluctuations; and (2) as the intra-subject variability during mobility tasks such as level walking. The former includes tasks involving an isolated muscle group, such as the quadriceps, and the latter includes synergistic activities that involve coordinated involvement of several muscle groups such as required during level walking and stair stepping. More specifically, variability in muscle force output is measured as the force fluctuations relative

to a given submaximal force target while performing a specific task. This concept applies not only to measures of muscle function, such as during isolated tasks that aim to evaluate fluctuations of motor output, but to functional tasks such as gait and stair stepping that aim to evaluate fluctuations of temporal, spatial, and kinematic outcomes. For instance, variability during level walking is a measure of the fluctuation in gait characteristics from one step or stride to the next, while variability in negotiating stairs can be witnessed when stepping from one step to the next. These concepts of variability are applicable to both muscle and physical function, as there are studies that have investigated measures of purely muscle force output variability, and others that have investigated movement variability. The one common theme, however, is that both types of investigations have aimed to identify links between the respective measures of variability and the ability to perform functional tasks efficiently<sup>[8-11]</sup>. Heretofore, the implications of greater or reduced variability relative to healthy controls, in older adults with OA before and after TKA, have not been previously reviewed.

The initial review of the literature for this narrative review involved a general internet search, as well as a search of PubMed (<http://www.ncbi.nlm.nih.gov/pubmed/>) using several search terms. The initial search was performed to identify the breadth of information regarding variability of motor output, as well as during various movement tasks. Following this review, a more focused search strategy was used that included several keywords (*e.g.*, motor output, gait variability, muscle function, muscle force steadiness, arthrogenic muscle inhibition, stair stepping, TKA, and OA), which were applied to the CINAHL and MEDLINE databases. No specific filtering strategy was used for the types of article, although limits were used to include research in humans only, the English language, as well as dates between 1990 and 2013. Of the articles returned, related articles were also reviewed for relevancy, resulting in a review of articles published prior to 1990.

## MUSCLE FORCE OUTPUT VARIABILITY

Diminished quadriceps strength in knee OA and following TKA is coupled to the ability to perform functional tasks that require adequate muscle strength and motor control to perform accurately and within a specified trajectory<sup>[12-14]</sup>. Neuromuscular activation deficits accompanied by declines in proprioception<sup>[15]</sup> and kinesthetic awareness are common manifestations of knee OA, and contribute to these strength deficits, as well as slower movement patterns<sup>[16-18]</sup> and reduced force steadiness<sup>[19-21]</sup> before and after TKA<sup>[7,14,18]</sup>. These adaptations result in diminished ability to exert a steady force output during submaximal efforts, such as those that are required during activities of daily living, as well as greater variability in movement patterns<sup>[14,20,22]</sup>. The importance of understanding how these impairments are altered following TKA is relevant to identifying variables that may be ben-

eficial targets of post-operative rehabilitation.

### Arthrogenic muscle inhibition

A significant component of impaired muscle function is the presence of arthrogenic muscle inhibition (AMI), or the inability to fully activate the quadriceps muscle<sup>[23]</sup>. Quadriceps AMI is associated with changes in the discharge of afferent, articular sensory receptors resulting from swelling, inflammation, joint laxity, and damage to knee joint afferents, all of which are common symptoms of OA<sup>[24]</sup>. Swelling, in particular, has been shown to independently alter joint afferent discharge by increasing the firing frequency and recruitment of group II afferents<sup>[25-27]</sup>. Not surprisingly, in the presence of swelling, the greatest muscle inhibition occurs at the extremes of motion, where intra-articular pressure and afferent discharge are the highest<sup>[28-34]</sup>. In turn, these changes in neuromuscular control are implicated in the ability to control motor output.

Inflammatory responses and joint laxity also contribute to quadriceps AMI by increasing joint afferent discharge; inflammation *via* sensitization of free nerve endings innervated by group III and IV afferents<sup>[35-37]</sup>, and joint laxity *via* increases in the activation of mechanoreceptors and nociceptors<sup>[24,38]</sup>. While nociceptive influences have some correlation to AMI, the relationship between AMI and pain is inconsistent<sup>[24]</sup> in patients with OA<sup>[39]</sup> as well as following TKA<sup>[40,41]</sup>. Indeed, research suggests that while the presence of pain may accompany AMI, inhibition occurs in the absence of pain as well<sup>[24,34]</sup>. Although this research has been useful in clarifying the role of nociceptive influences on AMI, the overall effects on muscle force output variability, as well as movement variability during specific functional tasks have not been identified.

In addition to the increases to joint afferent discharge discussed thus far, as described by Rice *et al*<sup>[24]</sup> these disruptions may be accompanied by simultaneous decreases in afferent output due to damage to articular receptors<sup>[38,42-44]</sup> and subsequent effects on reflex pathways within the spinal cord. The potential contributors to these reflex pathway adaptations include group I non-reciprocal (Ib) inhibitors<sup>[45]</sup>, interneurons associated with the flexion reflex<sup>[46-48]</sup>, and dysfunction of the gamma ( $\gamma$ )-loop<sup>[24]</sup>, with the overall effect being inhibition of the quadriceps  $\alpha$ -motoneuron pool<sup>[38,43,44,49]</sup>. Research suggests that all of these pathways contribute to AMI, with the relative contributions dependent on factors such as the extent and location of joint damage, swelling, inflammation, and laxity<sup>[24,34]</sup>.

In individuals with OA, the different neural mechanisms described above involve a series of complex innervation strategies that contribute to quadriceps AMI, motor output variability, and associated force control. Total knee arthroplasty, by nature, results in disruption of the joint capsule and ligamentous structures [either anterior cruciate ligament (ACL) or ACL and posterior cruciate ligament (PCL)], as well as alterations to joint motion and as a result, would be expected to influence mechanisms

that contribute to AMI that rely specifically on afferent discharge from these structures. Although TKA has been shown to reverse some of the pre-operative impairments by improving proprioception and joint stability, similar improvements in muscle and mobility deficits following TKA persist. The significance of these neuromuscular changes in individuals that undergo TKA is not well understood. That is, the factors that influence the extent to which these changes affect muscle force output variability and movement variability following TKA have not been thoroughly investigated<sup>[34]</sup>.

### Muscle force steadiness

Lower extremity muscle force steadiness (MFS) has been identified as a potential marker of impairment during functional tasks such as walking endurance, chair rising and stair climbing<sup>[13]</sup>. Moreover, correlations between concentric and eccentric quadriceps force steadiness and aging, as well as between eccentric steadiness and falling in elderly adults have been reported<sup>[50]</sup>. Although these studies were not performed in subjects with OA, they provide a basis for understanding the relationship between force steadiness and functional abilities, and subsequently, insight into how they may be altered by deficits common in OA. A summary of research that has focused specifically on lower extremity motor output variability, also reported as force steadiness, in elderly adults, and in OA before and after TKA is included in Table 1.

In elderly adults, the ability to control lower extremity submaximal muscle forces has been shown to be an independent risk factor for increased risk of falling<sup>[13,50]</sup>. Carville *et al*<sup>[50]</sup> compared force steadiness between young and older adults and found that the younger, non-fallers were steadier than older fallers, with eccentric contractions showing the strongest correlation with falling. This finding was consistent with another study that showed that the CV of force steadiness for both isometric and anisometric (*i.e.*, concentric and eccentric) force output was greater in older adults compared to young adults<sup>[58]</sup>. Hortobágyi *et al*<sup>[52]</sup>, however, showed increased muscle force variability in older adults during concentric and eccentric contractions, but not in isometric contractions. Furthermore, Tracy *et al*<sup>[22]</sup> showed a reduction in MFS during isometric, but not concentric and eccentric contractions in healthy older adults compared to young adults. The differences in these findings may be due to inconsistencies in the speed of contraction, as well as in the proportion of the target force relative to the subjects' MVIC. While these discrepancies may appear relatively minor, it is evident that they can have large consequences on the efficiency and control of motor output<sup>[13,53]</sup>. As an example, Seynnes *et al*<sup>[13]</sup> reported isometric steadiness was an independent predictor of chair-rise time and stair-climbing power, while Manini *et al*<sup>[53]</sup> demonstrated no correlation between isometric force steadiness and functional tasks including chair-rise time or time to ascend and descend stairs in older adults. The differences in these studies persist regardless of the fact that both employed an isometric force-matching task at 50% of

Table 1 Summary of the literature addressing muscle force output variability in older adults and those with osteoarthritis before and after total knee arthroplasty

Study	Population	Purpose/hypothesis	Variables assessed	Significant findings
Older adults with native, non-arthritis knees Carville <i>et al</i> <sup>[60]</sup> , 2007	<i>n</i> = 44 (Young adults; Age range = 18-4 yr) <i>n</i> = 78 (Older adults; Age range > 70 yr)	To investigate isometric and anisometric quadriceps contractions in healthy young and older adults	Muscle strength; CV of isometric force steadiness at 10%, 25%, and 50% of MVC; and SD of acceleration of anisometric steadiness during concentric and eccentric contractions against two external loads of 1 and 5 kg	1. Non-significant trend for younger subjects to be most steady and fallers least study 2. Isometric force steadiness was unaffected by the level of force output. 3. Fallers were less steady than both young and non-fallers 4. Older adults were less steady during eccentric contractions than the younger adults and fallers were the least steady 1. CV of force steadiness for all contractions was greater in older subjects than younger subjects 2. Muscle strength was similar for all three types of contractions Young subjects were stronger than older subjects
Christou <i>et al</i> <sup>[51]</sup> , 2002	(Young, active adults; Mean age = 25.3 yr) <i>n</i> = 24 (Older active adults; Mean age = 73.3 yr) <i>n</i> = 27 (Older adults; Mean age = 72 yr) <i>n</i> = 10 (Young adults; Mean age = 21 yr)	To examine the ability to control knee-extension force during discrete isometric, concentric, and eccentric contractions	Muscle strength; Isometric force steadiness at 90 degrees of knee flexion; and Concentric and eccentric force steadiness at 25 deg/s	1. CV of force steadiness for all contractions was greater in older subjects than younger subjects 2. Muscle strength was similar for all three types of contractions Young subjects were stronger than older subjects
Hortobagyi <i>et al</i> <sup>[53]</sup> , 2001	(Older active adults; Mean age = 73.3 yr) <i>n</i> = 27 (Older adults; Mean age = 72 yr) <i>n</i> = 10 (Young adults; Mean age = 21 yr)	To compare the effects of low- and high-intensity strength training on maximal and explosive strength and on the accuracy and steadiness of submaximal quadriceps force in elderly humans	Muscle strength Quadriceps force accuracy and steadiness during isometric, concentric and eccentric contractions performed at 25 N target force	1. Older subjects had significantly more force variability ( <i>i.e.</i> , were less steady) during eccentric and concentric, but not isometric contractions 2. Force variability and accuracy were correlated with each other, but not with maximal strength 3. Training significantly improved force accuracy and variability during eccentric and concentric contractions Isometric quadriceps force steadiness was not a predictor of functional performance in older subjects
Manini <i>et al</i> <sup>[53]</sup> , 2005	<i>n</i> = 50 (Healthy, older adults; Mean age = 76.2 yr)	To determine how knee extensor steadiness during an isometric task is related to performing four everyday tasks that included chair rising, walking at a fast pace, and stair ascending and descending	Isometric knee extensor steadiness at 50% MVC; Chair rise time Time to ascend and descend stairs; and Walking velocity	1. Isokinetic submaximal force control was equally diminished in both young and older adults compared to isometric force control 2. As the force level increased, force variability decreased for both young and older adults
Schiffman <i>et al</i> <sup>[54]</sup> , 2001	<i>n</i> = 19 (Healthy older adults; Mean age = 71.8 yr) <i>n</i> = 20 (Healthy young adults; Mean age = 25.8 yr)	To investigate the effects of motion on submaximal force control abilities in the knee extensors	Isokinetic force variability at two different force levels; 20% of MVC and 60% of MVC	1. Isokinetic submaximal force control was equally diminished in both young and older adults compared to isometric force control 2. As the force level increased, force variability decreased for both young and older adults
Tracy <i>et al</i> <sup>[23]</sup> , 2002	<i>n</i> = 10 (Healthy young adults; Mean age = 22 yr) <i>n</i> = 10 (Healthy older adults; Mean age = 72 yr)	To compare the steadiness and EMG activity of young and old adults while they were performing submaximal isometric and anisometric contractions with the knee extensor muscles	Muscle strength; EMG of quadriceps muscles during experimental tasks; and Isometric, concentric, and eccentric force steadiness for 10-12 s at 2%, 5%, 10%, and 50% of MVC	1. Steadiness of old adults was reduced compared with young adults during isometric, but not during concentric and eccentric contractions 2. Decline in steadiness was not associated with differences in EMG magnitude
Tracy <i>et al</i> <sup>[55]</sup> , 2004	<i>n</i> = 26 (Healthy, older adults; Mean age = 77.7 yr)	To determine the effect of strength and steadiness training with heavy loads by old adults on the fluctuations in force and position during voluntary contractions with the quadriceps femoris muscles	Muscle strength (MVC); Force fluctuations during isometric contractions at 2%, 5%, 10%, and 50% of MVC; Force fluctuations during concentric and eccentric contractions at 5%, 10%, and 50% of MVC; EMG activity of the quadriceps muscles during	1. Force fluctuations during submaximal isometric contractions did not change with training 2. Force fluctuations during submaximal anisometric contractions with a 50% load declined for both heavy and light training groups



Seymes <i>et al.</i> <sup>[13]</sup> , 2005	<i>n</i> = 19 (Healthy older women; Mean age = 77.9 yr)	To assess the relationship between knee-extensor force-control capacity, as MVC measured by isometric force steadiness Rate of torque development; and accuracy, and functional limitations EMG activity; and in healthy older adults	experimental tasks; and Physical function tasks including gait speed, chair rise, and stair ascent and descent	1. Isometric steadiness independently predicts chair-rise time and stair-climbing power 2. None of the accuracy measures were significantly associated with any of the functional performance tests Walking endurance was related to muscle strength, but not steadiness
Older adults with osteoarthritic knees Hortobágyi <i>et al.</i> <sup>[56]</sup> , 2004	<i>n</i> = 20 (Older adults with OA; Mean age = 57.5 yr)	To characterize the distribution of error Quadriceps force accuracy and steadiness during 1. Knee OA subjects needed 67% more time to complete functional tasks, in knee joint proprioception, quadriceps a force target-tracking task during an isometric produced 82 % more proprioception errors, and 89 % more errors in force accuracy and steadiness and muscle contractions.	Isometric quadriceps force steadiness at 50% of MVC	
	<i>n</i> = 20 (Controls; Mean age = 56.8 yr)	Strength in patients with knee OA	Rate of torque development; EMG activity; and Functional performance measures including walking endurance, chair rising, and stair climbing	
Sørensen <i>et al.</i> <sup>[57]</sup> , 2011	<i>n</i> = 41 (Older adults with OA; Mean age = 62 yr)	To investigate the relationship between Submaximal isometric quadriceps force steadiness Quadriceps force steadiness does not predict peak knee adduction moment quadriceps force steadiness and knee during a force target-tracking task.	Isometric, and concentric contractions	1. Pre-operatively, quadriceps force steadiness for both concentric and eccentric contractions was significantly higher in the OA group relative to controls; and 2. Post-operatively quadriceps force steadiness for both concentric and eccentric contractions was significantly lower in the OA group relative to controls Muscle strength was significantly lower in the TKA group both pre- and post-operatively compared to controls
Older adults following total knee arthroplasty Smith <i>et al.</i> <sup>[64]</sup> , 2013	<i>n</i> = 13 (Older adults with TKA; Mean age = 62.7 yr)	To compare muscle force steadiness of Muscle strength; submaximal quadriceps force output in Quadriceps muscle force steadiness (MFS) during eccentric contractions was significantly higher in the OA group relative to individuals with knee OA before and an isometric eccentric and concentric contractions at controls; and		
	<i>n</i> = 11 (Controls; Mean age = 62.2 yr)	after TKA, and to a group of age-matched 50% MVIC controls with native knees		

CV: Coefficient of variation; MVC: Maximal voluntary contraction; OA: Osteoarthritis; TKA: Total knee arthroplasty; EMG: Electromyographic signal.

MVIC. These discrepant findings underscore the need for further research to identify the associations between the ability to control submaximal muscle forces and specific functional tasks in order to identify specific rehabilitation targets.

To shed more light on potential relationships between force steadiness and functional performance, Hortobágyi *et al.*<sup>[56]</sup> investigated lower extremity steadiness during submaximal isometric and anisometric contractions and showed that knee OA was associated with 155% more force variability and 67% more time to complete functional tasks than a group of age- and sex-matched controls without OA. In contrast, Sørensen *et al.*<sup>[57]</sup> identified no relationship between quadriceps force steadiness and peak knee adduction moment during level walking in subjects with knee OA, suggesting that submaximal isometric MFS and knee joint loads during walking represent two distinctive pathways with independent influences on knee OA pathogenesis. These studies lend support for potential relationships between the ability to control submaximal muscle forces and functional tasks in individuals with OA, but the specific correlations remain to be clarified. Consequently, it must also be considered that MFS may represent a distinctive pathway that does not have broader applicability to functional tasks.

Thus far, MFS in both older adults and those with knee OA have been discussed and while the methodologies, level of force exerted, and type of contractions vary between studies, there appears to be an overall trend that some aspect of force steadiness is worse in both elderly individuals and those with OA compared to healthy young and age-matched controls. In this regard, Enoka *et al.*<sup>[12]</sup> described mechanisms that may contribute to the amplitude of force fluctuations between young and old adults as being primar-

ily dependent on the behavior of motor units; namely, the motor unit force and discharge rate variability.

Total knee arthroplasty, by nature, involves the removal of damaged structures and has been reported to positively affect proprioceptive feedback in individuals with OA<sup>[14,59,60]</sup>. Additionally, evidence suggests that following TKA, - which type of prosthesis - PCL retaining or PCL sacrificing? How long after surgery? what was the rehabilitation program after surgery regarding physio? there is a significant improvement in MFS to a level that exceeds a group of healthy, age-matched controls without OA<sup>[14]</sup>. In this study, subjects were examined within one month prior to surgery and at 6-mo post-operatively and were not stratified by ligament retention status or type and extent of post-operative rehabilitation. The authors of this study showed that while quadriceps force steadiness was significantly worse before TKA compared to an age-matched, symptom-free group of controls, following TKA, steadiness improved to a level that exceeded healthy controls<sup>[14]</sup>. These results raise an important question about motor output variability, *i.e.*, is there a level of steadiness that is too low and corresponds to impaired, rather than improved movement ability, and that may have implications for functional tasks? Certainly, a better understanding of how these changes in force control and steadiness following TKA correlate with other functional performance parameters could direct the development of future intervention strategies and improve long-term TKA outcomes.

## MOVEMENT VARIABILITY

Similar to MFS, greater movement variability in elderly individuals as well as in those suffering from OA, is generally considered representative of a pathological or impaired state and has been associated with reduced function and future risk of mobility deficits<sup>[61,62]</sup>. For example, Brach *et al.*<sup>[62]</sup> used stance time variability (STV) during level walking to identify an optimal level of gait variability, above which was an indicator of prevalent mobility disability. And although these findings are well-correlated in the literature, the implications of reduced variability relative to healthy, age-matched controls have received little attention. The next section aims to explore the implications of both increased and decreased movement variability in those with OA before and after TKA. To assist in this review, Table 2 presents an overview of the current literature regarding movement variability during level walking in these patient populations.

### Level walking variability

Gait is a multifaceted and complex task that requires coordinated movement between both central and peripheral neuromuscular control mechanisms. And while variability during gait has been shown to be associated with incident fall risk in elderly adults<sup>[66]</sup>, and predict mobility deficits in different populations<sup>[62,66]</sup>\_ENREF\_62, there are conflicting reports on which variables are associated with

these functional parameters. These inconsistencies only serve to propagate the lack of consistent and effective rehabilitation protocols for both individuals with knee OA as well as following TKA.

Muscle function and proprioceptive deficits associated with knee OA have been suggested to contribute to altered, spatio-temporal, kinematic, and kinetic gait patterns compared to individuals without OA<sup>[61,71-75]</sup>. The resulting gait pattern is characterized by slower gait speed and cadence, reduced stride length, and altered movement patterns that are particularly evident during the loading phase of the gait cycle<sup>[61,73,75]</sup>. However, since OA represents an increased level of pathology with associated neuromuscular changes beyond those that may be associated with aging alone, it is important to first clarify the changes in movement variability that may occur in older adults without OA.

Researchers have investigated several measures of gait variability in older adults to identify meaningful changes that may be associated with disability or impairment, which included the standard deviations (SD) of step width, stance time, swing time, and step length<sup>[61,63]</sup>. The results showed that increased STV is a predictor of central nervous system impairments<sup>[61]</sup> and mobility disability in elderly community-dwelling adults<sup>[62,64]</sup>. In a similar study, variability of gait was assessed in 100 frail community-dwelling adults by using velocity and cadence, as well as the CV of stride time, step width, double support time, and stride length as the predictor variables. The authors found that regulation of gait was impaired in older adults and that frailty was associated with higher variability of all gait parameters<sup>[76]</sup>. Callisaya *et al.*<sup>[66]</sup> also investigated gait variability in older adults, but with the purpose of correlating gait measures with risk of falling. The authors assessed the relationship between the SD of velocity, cadence, step length, step width, step time, and double support phase with incident fall risk and found non-linear associations between velocity, cadence, and step time variability with multiple falls, although, none of the variables predicted risk of single falls<sup>[66]</sup>.

The breadth of literature regarding gait variability in older adults is largely consistent across studies; *i.e.*, greater variability equates to greater impairment, and based on the known deficits that accompany OA, these findings would be expected to be consistent in individuals with OA. In fact, gait variability has been correlated with severity of OA<sup>[9,71]</sup>\_ENREF\_75, as well as risk of future falls and gait instability before and after TKA<sup>[11,69,72,77]</sup>. As an example, Lewek *et al.*<sup>[10]</sup> investigated 15 subjects with unilateral OA and 15 age and gender-matched controls to quantify frontal plane, knee motion variability, which was assessed by the phase angle (knee angle *vs* angular velocity) during early stance phase of level walking. The authors found that despite altered involved side knee kinematics and kinetics, there were no differences between frontal plane variability between the two groups. In fact, the variability in the involved limb was significantly lower than the variability of the uninvolved knee's mo-



Table 2 Summary of the literature addressing gait variability in older adults and those with osteoarthritis before and after total knee arthroplasty

Study	Population	Purpose/hypothesis	Variables assessed	Significant findings
Older adults with native, non-arthritic knees Brach <i>et al</i> <sup>[61]</sup> , 2012	<i>n</i> = 552 (Older adults; Mean age = 79.4 yr)	1. Determine the magnitude of STV that discriminates individuals who currently have mobility disability. Determine the magnitude of STV that predicts a new onset of mobility disability at 1 yr	Gait Variability: Stance time variability Self-reported walking disability	1. Values of STV may be useful in recognizing mobility disability and future disability 2. Recommend using 0.034 s as the cutoff
Brach <i>et al</i> <sup>[61]</sup> , 2010	<i>n</i> = 241 (Older adults; Mean age = 80.3 yr)	1. To estimate clinically meaningful change in gait variability over time. Greater gait variability is a predictor of future falls and mobility disability	Gait Variability: Step width, Stance time, Swing time, Step length	Preliminary criteria for meaningful change are 0.01 s for stance time and swing time variability, and 0.25 cm for step length variability
Brach <i>et al</i> <sup>[61]</sup> , 2008	<i>n</i> = 558 (Older adults; Mean age = 79.4 yr)	1. CNS impairments will affect motor control and be manifested as increased stance time and step length variability. Sensory impairments would affect balance and manifest as increased step width variability To determine if gait variability adds to the prediction of incident mobility disability independent of gait speed	Gait Variability: Step width, Stance time, Step length, Strength Measures: Grip strength, Repeated chair stands Gait speed, Step length, Stance time, STV	CNS impairments affected stance time variability especially in slow walkers, while sensory impairments affected step width variability in fast walkers 1. After adjusting for gait speed and other comorbidities, only stance time variability remained an important indicator of disability 2. STV of 0.01 s was associated with a 13% higher incidence of mobility disability
Brach <i>et al</i> <sup>[61]</sup> , 2007	<i>n</i> = 379 (Older adults; Mean age = 79 yr)	To examine the linear and nonlinear associations between gait variability and fall history in older persons and to examine the influence of gait speed	CV of step width, CV of step length, CV of step time, CV of stance time, Gait speed, Fall history	1. Step width variability had the highest correlation with fall history, which only existed in subjects that walked > 1.0 m/s 2. Step length, stance time, and step time variability were not associated with fall history
Callisaya <i>et al</i> <sup>[61]</sup> , 2011	<i>n</i> = 411 [Older adults; Mean age = 72.6 yr (lost to follow-up); 71.2 yr (no falls); 72.3 yr (single fall); 73.9 yr (multiple falls)]	To investigate the associates of gait and gait variability measures with incident fall risk	Gait Variability: Step length, Step width, DSP, Gait speed, Cadence, Step time	Associations with multiple falls were present for gait speed, cadence and step time variability
Maeki <i>et al</i> <sup>[67]</sup> , 1997	<i>n</i> = 75 (Older adults; Mean age = 82 yr)	To determine whether specific gait measures can predict the likelihood of experiencing future falls or whether they are more likely to be indicative of adaptations associated with pre-existing fear of falling	Gait Variability: Stride length, Stride width, Stride period, Double-support, Stride velocity	1. Stride-to-stride variability in gait is a predictor of falling 2. Wider stride does not increase stability but does predict an increased likelihood of experiencing falls
Older adults with osteoarthritic knees Lewek <i>et al</i> <sup>[10]</sup> , 2006	<i>n</i> = 15 (Older adults with OA; Mean age = 48.7 yr); <i>n</i> = 15 (Controls; Mean age = 48.4 yr)	Quantify the variability of knee motion in patients with medial knee OA	Joint kinematics and kinetics, Knee motion variability, Knee joint laxity, Co-contraction index	Patients with medial knee OA displayed altered kinematics and kinetics
Kiss <i>et al</i> <sup>[68]</sup> , 2011	<i>n</i> = 90 (Older adults with moderate or severe OA; Mean age = 68.9 yr) <i>n</i> = 20 (Controls; Mean age = 70.7 yr)	To clarify how the variability of gait parameters is influenced by the severity of knee OA	Gait variability: Stride length, Stride width, Speed, Cadence, Duration of double-support, Duration of support	1. Variability of gait associated with knee OA is gender-dependent 2. Severity of OA affects step length, duration of support and cadence

Older adults following total knee arthroplasty Kiss <i>et al</i> <sup>[69]</sup> , 2012  n = 45 (Older adults with TKA; Median age = 68.3 yr) n = 21 (Controls; Median age = 76 yr)	To evaluate the influence of different surgical techniques on gait variability and stability	Gait Variability: Stride length, Stride width, Speed, Cadence, Duration of double-support, Duration of support	1. Type of surgical technique influences gait variability and stability 2. Differences in the variability of angular parameters predict gait instability and increased risk of falling after TKA
Fallah-Yakhdani <i>et al</i> <sup>[70]</sup> , 2010  n = 16 (Older adults with TKA; Mean age = 62.3 yr) n = 12 (Healthy, older adults; Mean age = 62.0 yr)	To evaluate treadmill walking at various speeds in OA patients pre- and post-TKA, to assess dynamic stability and variability of sagittal knee movements	Knee motion variability as measured by the angular velocity of sagittal knee movements; Walking speed; and Variability of knee movements	After TKA, knee motion variability decreased and was related to a reduction of fall risk. Stability control was also improved after surgery
Fallah-Yakhdani <i>et al</i> <sup>[70]</sup> , 2012  n = 14 (Older adults with TKA; Mean age = 62.3 yr) n = 12 (Healthy, older adults; Mean age = 62.0 yr) n = 15 (Healthy, young adults; Mean age = 22.9 yr)	To identify the determinant of co-contractions during gait in patients with knee OA before and 1 year after TKA	Gait speed at seven different speeds (0.6-5.4 km/h) EMG activity Variability of angular velocity of sagittal knee movements over the first 30 strides at each speed	1. Variability of sagittal plane knee movements (measured in deg/s) increased with speed; 2. Pre-operatively, the patients' affected and unaffected legs were less variable than those of the young controls and the affected leg was less variable than the healthy peers 3. Post-operatively, variability in the knee OA group was further decreased to a level significantly below both control groups

CV: Coefficient of variation; OA: Osteoarthritis; TKA: Total knee arthroplasty; STV: Stance time variability; CNS: Central nervous system.

tion. Fallah-Yakhdani *et al*<sup>[11]</sup> also showed reduced variability during level walking in a study of individuals with OA before and after TKA. In this study, measurements of the variability in knee angular velocity in the sagittal plane before and at 1 year following TKA were performed. The results showed a positive correlation between reduced stride-to-stride variability and reduced risk of falling, and pre-operatively, OA subjects had reduced variability, which was even more pronounced post-operatively, compared to the healthy controls. The pre-operative findings, which appear contrary to expectations, were hypothesized as being the results of a strategy to avoid falling, as opposed to a sign of pathology. The authors, however, did not have a definitive explanation for the continued decline in variability post-operatively. Even so, these results were supported by findings by Kiss *et al*<sup>[69]</sup>, who found that in individuals with unilateral OA, variability of articular motion decreased post-operatively compared to healthy controls, and similarly, Smith *et al* (unpublished data from the author's lab) showed that gait variability, as assessed by the CV of STV, declined in subjects with OA from the pre- to 6 mo post-operative time points and was significantly lower than a group of healthy controls at the 6 mo post-operatively. Although it is recognized that the specific measures of variability were different between these studies, the relevance of the findings are not diminished in that there appears to be a consistent pattern of decreased movement variability post-TKA relative to pre-operative values and healthy controls.

DISCUSSION

Based on the current evidence, both motor output and movement variability appear to be underappreciated outcome measures that could be linked to physical function both pre- and post-operatively. The evidence in elderly individuals, as well as in those with OA trends toward greater variability equating to greater mobility impairments. However, the alternative question of whether reduced variability, *i.e.*, variability that is less than a healthy, age-matched cohort, also indicates pathology remains unanswered. While data are present that suggest a trend toward reduced motor output and gait variability following TKA, this has not been correlated with functional outcomes, and in fact, some data suggest that reduced variability is associated with a reduced fall risk. Yet, this correlation is only present in older adults with and without OA prior to surgery; the relationship following TKA has not been established.

The question of reduced variability is an interesting one, in that it appears there may be a natural frequency for which individuals move, which serves a specific strategy to optimize balance and proprioception, and reduce the risk of falling. This strategy is likely affected by a variety of factors that may include age, sex, strength, activity level, and degree of pathology.

When considering the ability to respond to sudden balance perturbations, such as those that may occur when walking down stairs, it is theorized that a greater flexibility and available range of motion may be beneficial, thus suggesting that variability that is less than a group of healthy, age-matched controls, may equate to some level of pathology as well. Another potential explanation for the reduced variability following TKA is the influence of co-contraction of antagonist muscles during movement<sup>[10]</sup>. Evidence suggests that in individuals with medial knee OA, co-contraction is used as a stabilization strategy during gait to reduce joint excursions. However, this level of co-contraction does not persist following surgery; Fallah-Yakhdani *et al*<sup>[70]</sup> showed that following TKA, co-contraction is similar to that of healthy controls. Although, additional analysis revealed a negative regression between the affected side variability and unaffected side co-contraction time, leading the authors to surmise that at least some relationship exists between increased co-contraction and decreased variability. Thus, while it makes sense that this strategy may persist post-operatively, the correlation is notably weak and suggests the influence of other potential mechanisms to control motion and improve balance, when the quadriceps have not yet achieved a level of strength that is commensurate with age-matched controls.

When considering knee implant design, the obvious rigidity of the joint compared to a natural joint may impair the ability to respond to rapid perturbations and hence, may reduce movement variability, although, this cannot be elucidated from the available data. Nonetheless, the development of knee implant designs that incorporate greater range of motion in all planes lends support for this theory and may provide a way to test this hypothesis in the future.

## CONCLUSION

Muscle force output and movement variability are important outcome variables that can be used to understand the effects of not only pathological conditions, but surgical interventions such as TKA as well. Movement variability has implications for identifying those at risk of future mobility deficits, fall risk, as well as correlating with severity of OA. In both elderly individuals and those with OA, increased motor output variability tends to implicate greater pathology, which would imply that greater variability, particularly during level walking, has a negative impact on physical function. While the evidence mostly supports this conclusion, it does not answer the question of how reduced variability, below that of an age-matched group of controls, may relate to the same deficits. There are limited data in individuals with knee OA who have undergone TKA, but research that has investigated this population, shows a general trend of reduced post-operative MFS and variability during level walking compared to healthy, age-matched controls. Indeed, if the variability in healthy, age-matched population is considered normal or ideal to optimize mobility function and efficiency, the re-

duced variability in a TKA population may imply impairment, similar to those with greater variability. Additional research investigating this link may provide an important rehabilitation target, or direct development of different implant designs.

## REFERENCES

- 1 **Dillon CF**, Rasch EK, Gu Q, Hirsch R. Prevalence of knee osteoarthritis in the United States: arthritis data from the Third National Health and Nutrition Examination Survey 1991-94. *J Rheumatol* 2006; **33**: 2271-2279 [PMID: 17013996 DOI: jrheum.org/content/33/11/2271]
- 2 **Crepaldi G**, Punzi L. Aging and osteoarthritis. *Aging Clin Exp Res* 2003; **15**: 355-358 [PMID: 14703000 DOI: 10.1007/BF03327355]
- 3 **Punzi L**, Oliviero F, Plebani M. New biochemical insights into the pathogenesis of osteoarthritis and the role of laboratory investigations in clinical assessment. *Crit Rev Clin Lab Sci* 2005; **42**: 279-309 [PMID: 16281737 DOI: 10.1080/10408360591001886]
- 4 **Hootman JM**, Brault MW, Helnick CG, Theis KA, Armour BS. Prevalence and Most Common Causes of Disability Among Adults - United States. *MMWR* 2005; **58**: 421-426
- 5 **Mizner RL**, Snyder-Mackler L. Altered loading during walking and sit-to-stand is affected by quadriceps weakness after total knee arthroplasty. *J Orthop Res* 2005; **23**: 1083-1090 [PMID: 16140191 DOI: 10.1016/j.orthres.2005.01.021]
- 6 **Petterson SC**, Barrance P, Buchanan T, Binder-Macleod S, Snyder-Mackler L. Mechanisms underlying quadriceps weakness in knee osteoarthritis. *Med Sci Sports Exerc* 2008; **40**: 422-427 [PMID: 18379202 DOI: 10.1249/MSS.0b013e31815ef285]
- 7 **Meier W**, Mizner RL, Marcus RL, Dibble LE, Peters C, Lastayo PC. Total knee arthroplasty: muscle impairments, functional limitations, and recommended rehabilitation approaches. *J Orthop Sports Phys Ther* 2008; **38**: 246-256 [PMID: 18448878 DOI: 10.2519/jospt.2008.2715]
- 8 **Brach JS**, Perera S, Studenski S, Newman AB. The reliability and validity of measures of gait variability in community-dwelling older adults. *Arch Phys Med Rehabil* 2008; **89**: 2293-2296 [PMID: 19061741 DOI: 10.1016/j.apmr.2008.06.010]
- 9 **Kiss RM**. Effect of severity of knee osteoarthritis on the variability of gait parameters. *J Electromyogr Kinesiol* 2011; **21**: 695-703 [PMID: 21840223 DOI: 10.1016/j.jelekin.2011.07.011]
- 10 **Lewek MD**, Scholz J, Rudolph KS, Snyder-Mackler L. Stride-to-stride variability of knee motion in patients with knee osteoarthritis. *Gait Posture* 2006; **23**: 505-511 [PMID: 16024250 DOI: 10.1016/j.gaitpost.2005.06.003]
- 11 **Yakhdani HR**, Bafghi HA, Meijer OG, Bruijn SM, van den Dikkenberg N, Stibbe AB, van Royen BJ, van Dieën JH. Stability and variability of knee kinematics during gait in knee osteoarthritis before and after replacement surgery. *Clin Biomech (Bristol, Avon)* 2010; **25**: 230-236 [PMID: 20060628 DOI: 10.1016/j.clinbiomech.2009.12.003]
- 12 **Enoka RM**, Christou EA, Hunter SK, Kornatz KW, Semmler JG, Taylor AM, Tracy BL. Mechanisms that contribute to differences in motor performance between young and old adults. *J Electromyogr Kinesiol* 2003; **13**: 1-12 [PMID: 12488083 DOI: 10.1016/S1050-6411(02)00084-6]
- 13 **Seynnes O**, Hue OA, Garrandes F, Colson SS, Bernard PL, Legros P, Fiatarone Singh MA. Force steadiness in the lower extremities as an independent predictor of functional performance in older women. *J Aging Phys Act* 2005; **13**: 395-408 [PMID: 16301752]
- 14 **Smith JW**, Marcus RL, Peters CL, Pelt CE, Tracy BL, Lastayo PC. Muscle Force Steadiness in Older Adults Before and After Total Knee Arthroplasty. *J Arthroplasty* 2013; Epub ahead of print [PMID: 24405624 DOI: 10.1016/j.arth.2013.11.023]



- 15 **Skinner HB**, Barrack RL, Cook SD, Haddad RJ. Joint position sense in total knee arthroplasty. *J Orthop Res* 1984; **1**: 276-283 [PMID: 6481511 DOI: 10.1002/jor.1100010307]
- 16 **Cole KJ**, Rotella DL, Harper JG. Mechanisms for age-related changes of fingertip forces during precision gripping and lifting in adults. *J Neurosci* 1999; **19**: 3238-3247 [PMID: 10191336]
- 17 **Darling WG**, Cooke JD. Changes in the variability of movement trajectories with practice. *J Mot Behav* 1987; **19**: 291-309 [PMID: 14988049 DOI: 10.1080/00222895.1987.10735414]
- 18 **Yan JH**. Tai chi practice reduces movement force variability for seniors. *J Gerontol A Biol Sci Med Sci* 1999; **54**: M629-M634 [PMID: 10647969 DOI: 10.1093/gerona/54.12.M629]
- 19 **Christou EA**, Shinohara M, Enoka RM. Fluctuations in acceleration during voluntary contractions lead to greater impairment of movement accuracy in old adults. *J Appl Physiol* (1985) 2003; **95**: 373-384 [PMID: 12651861 DOI: 10.1152/jap-physiol.00060.2003]
- 20 **Kinoshita H**, Francis PR. A comparison of prehension force control in young and elderly individuals. *Eur J Appl Physiol Occup Physiol* 1996; **74**: 450-460 [PMID: 8954293 DOI: 10.1007/BF02337726]
- 21 **Walker N**, Philbin DA, Fisk AD. Age-related differences in movement control: adjusting submovement structure to optimize performance. *J Gerontol B Psychol Sci Soc Sci* 1997; **52**: P40-P52 [PMID: 9008674 DOI: 10.1093/geronb/52B.1.P40]
- 22 **Tracy BL**, Enoka RM. Older adults are less steady during submaximal isometric contractions with the knee extensor muscles. *J Appl Physiol* (1985) 2002; **92**: 1004-1012 [PMID: 11842033 DOI: 10.1152/jap-physiol.00954.2001]
- 23 **Palmieri RM**, Weltman A, Edwards JE, Tom JA, Saliba EN, Mistry DJ, Ingersoll CD. Pre-synaptic modulation of quadriceps arthrogenic muscle inhibition. *Knee Surg Sports Traumatol Arthrosc* 2005; **13**: 370-376 [PMID: 15685462 DOI: 10.1007/s00167-004-0547-z]
- 24 **Rice DA**, McNair PJ. Quadriceps arthrogenic muscle inhibition: neural mechanisms and treatment perspectives. *Semin Arthritis Rheum* 2010; **40**: 250-266 [PMID: 19954822 DOI: 10.1016/j.semarthrit.2009.10.001]
- 25 **Ferrell WR**, Nade S, Newbold PJ. The interrelation of neural discharge, intra-articular pressure, and joint angle in the knee of the dog. *J Physiol* 1986; **373**: 353-365 [PMID: 3746677]
- 26 **Ferrell WR**. The effect of acute joint distension on mechanoreceptor discharge in the knee of the cat. *Q J Exp Physiol* 1987; **72**: 493-499 [PMID: 2447602]
- 27 **Wood L**, Ferrell WR. Response of slowly adapting articular mechanoreceptors in the cat knee joint to alterations in intra-articular volume. *Ann Rheum Dis* 1984; **43**: 327-332 [PMID: 6712305]
- 28 **Jensen K**, Graf BK. The effects of knee effusion on quadriceps strength and knee intraarticular pressure. *Arthroscopy* 1993; **9**: 52-56 [PMID: 8442830 DOI: 10.1016/S0749-8063(05)80343-3]
- 29 **Jones DW**, Jones DA, Newham DJ. Chronic knee effusion and aspiration: the effect on quadriceps inhibition. *Br J Rheumatol* 1987; **26**: 370-374 [PMID: 3664162 DOI: 10.1093/rheumatology/26.5.370]
- 30 **Krebs DE**, Staples WH, Cuttita D, Zickel RE. Knee joint angle: its relationship to quadriceps femoris activity in normal and postarthrotomy limbs. *Arch Phys Med Rehabil* 1983; **64**: 441-447 [PMID: 6625877]
- 31 **Reeves ND**, Maffulli N. A case highlighting the influence of knee joint effusion on muscle inhibition and size. *Nat Clin Pract Rheumatol* 2008; **4**: 153-158 [PMID: 18227831 DOI: 10.1038/ncprheum0709]
- 32 **Shakespeare DT**, Rigby HS. The bucket-handle tear of the meniscus. A clinical and arthrographic study. *J Bone Joint Surg Br* 1983; **65**: 383-387 [PMID: 6874707]
- 33 **Stratford P**. Electromyography of the quadriceps femoris muscles in subjects with normal knees and acutely effused knees. *Phys Ther* 1982; **62**: 279-283 [PMID: 7063526]
- 34 **Smith JW**. Inflammatory biomarkers and functional biomechanics of older adults with osteoarthritis before and after total knee arthroplasty [Dissertation]. Bioengineering: University of Utah, 2013
- 35 **Coggeshall RE**, Hong KA, Langford LA, Schaible HG, Schmidt RF. Discharge characteristics of fine medial articular afferents at rest and during passive movements of inflamed knee joints. *Brain Res* 1983; **272**: 185-188 [PMID: 6311338 DOI: 10.1016/0006-8993(83)90379-7]
- 36 **Schaible HG**, Schmidt RF. Time course of mechanosensitivity changes in articular afferents during a developing experimental arthritis. *J Neurophysiol* 1988; **60**: 2180-2195 [PMID: 3236065]
- 37 **Schepelmann K**, Messlinger K, Schaible HG, Schmidt RF. Inflammatory mediators and nociception in the joint: excitation and sensitization of slowly conducting afferent fibers of cat's knee by prostaglandin I<sub>2</sub>. *Neuroscience* 1992; **50**: 237-247 [PMID: 1407558 DOI: 10.1016/0306-4522(92)90395-I]
- 38 **Hurley MV**, Scott DL, Rees J, Newham DJ. Sensorimotor changes and functional performance in patients with knee osteoarthritis. *Ann Rheum Dis* 1997; **56**: 641-648 [PMID: 9462165 DOI: 10.1136/ard.56.11.641]
- 39 **Fitzgerald GK**, Piva SR, Irrgang JJ, Bouzubar F, Starz TW. Quadriceps activation failure as a moderator of the relationship between quadriceps strength and physical function in individuals with knee osteoarthritis. *Arthritis Rheum* 2004; **51**: 40-48 [PMID: 14872454 DOI: 10.1002/art.20084]
- 40 **Stevens JE**, Mizner RL, Snyder-Mackler L. Quadriceps strength and volitional activation before and after total knee arthroplasty for osteoarthritis. *J Orthop Res* 2003; **21**: 775-779 [PMID: 12919862 DOI: 10.1016/S0736-0266(03)00052-4]
- 41 **Mizner RL**, Petterson SC, Stevens JE, Vandendorpe K, Snyder-Mackler L. Early quadriceps strength loss after total knee arthroplasty. The contributions of muscle atrophy and failure of voluntary muscle activation. *J Bone Joint Surg Am* 2005; **87**: 1047-1053 [PMID: 15866968 DOI: 10.2106/JBJS.D.01992]
- 42 **Johansson H**, Sjölander P, Sojka P. Receptors in the knee joint ligaments and their role in the biomechanics of the joint. *Crit Rev Biomed Eng* 1991; **18**: 341-368 [PMID: 2036801]
- 43 **Konishi Y**, Fukubayashi T, Takeshita D. Possible mechanism of quadriceps femoris weakness in patients with ruptured anterior cruciate ligament. *Med Sci Sports Exerc* 2002; **34**: 1414-1418 [PMID: 12218732 DOI: 10.1249/01.mss.0000027628.04801.27]
- 44 **Young A**. Current issues in arthrogenous inhibition. *Ann Rheum Dis* 1993; **52**: 829-834 [PMID: 8250616 DOI: 10.1136/ard.52.11.829]
- 45 **Iles JF**, Stokes M, Young A. Reflex actions of knee joint afferents during contraction of the human quadriceps. *Clin Physiol* 1990; **10**: 489-500 [PMID: 2245598 DOI: 10.1111/j.1475-097X.1990.tb00828.x]
- 46 **Lundberg A**, Malmgren K, Schomburg ED. Reflex pathways from group II muscle afferents. 1. Distribution and linkage of reflex actions to alpha-motoneurons. *Exp Brain Res* 1987; **65**: 271-281 [PMID: 3556457 DOI: 10.1007/BF00236299]
- 47 **McCrea DA**. Supraspinal and segmental interactions. *Can J Physiol Pharmacol* 1996; **74**: 513-517 [PMID: 8828896 DOI: 10.1139/y96-038]
- 48 **Leroux A**, Bélanger M, Boucher JP. Pain effect on mono-synaptic and polysynaptic reflex inhibition. *Arch Phys Med Rehabil* 1995; **76**: 576-582 [PMID: 7763159 DOI: 10.1016/S0003-9993(95)80514-1]
- 49 **Ferrell WR**, Wood L, Baxendale RH. The effect of acute joint inflammation on flexion reflex excitability in the decerebrate, low-spinal cat. *Q J Exp Physiol* 1988; **73**: 95-102 [PMID: 3347700]
- 50 **Carville SF**, Perry MC, Rutherford OM, Smith IC, Newham DJ. Steadiness of quadriceps contractions in young and older adults with and without a history of falling. *Eur J Appl Physiol* 2007; **100**: 527-533 [PMID: 16983499 DOI: 10.1007/

- s00421-006-0245-2]
- 51 **Christou EA**, Carlton LG. Motor output is more variable during eccentric compared with concentric contractions. *Med Sci Sports Exerc* 2002; **34**: 1773-1778 [PMID: 12439082 DOI: 10.1249/01.mss.0000035201.21310.cc]
  - 52 **Hortobágyi T**, Tunnel D, Moody J, Beam S, DeVita P. Low- or high-intensity strength training partially restores impaired quadriceps force accuracy and steadiness in aged adults. *J Gerontol A Biol Sci Med Sci* 2001; **56**: B38-B47 [PMID: 11193224 DOI: 10.1093/gerona/56.1.B38]
  - 53 **Manini TM**, Cook SB, Ordway NR, Ploutz-Snyder RJ, Ploutz-Snyder LL. Knee extensor isometric unsteadiness does not predict functional limitation in older adults. *Am J Phys Med Rehabil* 2005; **84**: 112-121 [PMID: 15668559 DOI: 10.1097/01.PHM.0000151940.47912.DF]
  - 54 **Schiffman JM**, Luchies CW. The effects of motion on force control abilities. *Clin Biomech* (Bristol, Avon) 2001; **16**: 505-513 [PMID: 11427293 DOI: 10.1016/S0268-0033(01)00014-6]
  - 55 **Tracy BL**, Byrnes WC, Enoka RM. Strength training reduces force fluctuations during anisometric contractions of the quadriceps femoris muscles in old adults. *J Appl Physiol* (1985) 2004; **96**: 1530-1540 [PMID: 14565966 DOI: 10.1152/jap-physiol.00861.2003]
  - 56 **Hortobágyi T**, Garry J, Holbert D, Devita P. Aberrations in the control of quadriceps muscle force in patients with knee osteoarthritis. *Arthritis Rheum* 2004; **51**: 562-569 [PMID: 15334428 DOI: 10.1002/art.20545]
  - 57 **Sørensen TJ**, Langberg H, Aaboe J, Bandholm T, Bliddal H, Henriksen M. The association between submaximal quadriceps force steadiness and the knee adduction moment during walking in patients with knee osteoarthritis. *J Orthop Sports Phys Ther* 2011; **41**: 592-599 [PMID: 21765221 DOI: 10.2519/jospt.2011.3481]
  - 58 **Christou EA**, Carlton LG. Age and contraction type influence motor output variability in rapid discrete tasks. *J Appl Physiol* (1985) 2002; **93**: 489-498 [PMID: 12133855 DOI: 10.1152/japplphysiol.00335.2001]
  - 59 **Bade MJ**, Kohrt WM, Stevens-Lapsley JE. Outcomes before and after total knee arthroplasty compared to healthy adults. *J Orthop Sports Phys Ther* 2010; **40**: 559-567 [PMID: 20710093 DOI: 10.2519/jospt.2010.3317]
  - 60 **Barrack RL**, Skinner HB, Cook SD, Haddad RJ. Effect of articular disease and total knee arthroplasty on knee joint-position sense. *J Neurophysiol* 1983; **50**: 684-687 [PMID: 6619913]
  - 61 **Brach JS**, Studenski S, Perera S, VanSwearingen JM, Newman AB. Stance time and step width variability have unique contributing impairments in older persons. *Gait Posture* 2008; **27**: 431-439 [PMID: 17632004 DOI: 10.1016/j.gaitpost.2007.05.016]
  - 62 **Brach JS**, Wert D, VanSwearingen JM, Newman AB, Studenski SA. Use of stance time variability for predicting mobility disability in community-dwelling older persons: a prospective study. *J Geriatr Phys Ther* 2012; **35**: 112-117 [PMID: 22314273 DOI: 10.1519/JPT.0b013e318243e5f9]
  - 63 **Brach JS**, Perera S, Studenski S, Katz M, Hall C, Verghese J. Meaningful change in measures of gait variability in older adults. *Gait Posture* 2010; **31**: 175-179 [PMID: 19889543 DOI: 10.1016/j.gaitpost.2009.10.002]
  - 64 **Brach JS**, Studenski SA, Perera S, VanSwearingen JM, Newman AB. Gait variability and the risk of incident mobility disability in community-dwelling older adults. *J Gerontol A Biol Sci Med Sci* 2007; **62**: 983-988 [PMID: 17895436 DOI: 10.1093/gerona/62.9.983]
  - 65 **Brach JS**, Berlin JE, VanSwearingen JM, Newman AB, Studenski SA. Too much or too little step width variability is associated with a fall history in older persons who walk at or near normal gait speed. *J Neuroeng Rehabil* 2005; **2**: 21 [PMID: 16042812 DOI: 10.1186/1743-0003-2-21]
  - 66 **Callisaya ML**, Blizzard L, Schmidt MD, Martin KL, McGinley JL, Sanders LM, Srikanth VK. Gait, gait variability and the risk of multiple incident falls in older people: a population-based study. *Age Ageing* 2011; **40**: 481-487 [PMID: 21628390 DOI: 10.1093/ageing/afr055]
  - 67 **Maki BE**. Gait changes in older adults: predictors of falls or indicators of fear. *J Am Geriatr Soc* 1997; **45**: 313-320 [PMID: 9063277]
  - 68 **Ko SU**, Ling SM, Schreiber C, Nesbitt M, Ferrucci L. Gait patterns during different walking conditions in older adults with and without knee osteoarthritis--results from the Baltimore Longitudinal Study of Aging. *Gait Posture* 2011; **33**: 205-210 [PMID: 21145241 DOI: 10.1016/j.gaitpost.2010.11.006]
  - 69 **Kiss RM**, Bejek Z, Szendrői M. Variability of gait parameters in patients with total knee arthroplasty. *Knee Surg Sports Traumatol Arthrosc* 2012; **20**: 1252-1260 [PMID: 22453309 DOI: 10.1007/s00167-012-1965-y]
  - 70 **Fallah-Yakhani HR**, Abbasi-Bafghi H, Meijer OG, Bruijn SM, van den Dikkenberg N, Benedetti MG, van Dieën JH. Determinants of co-contraction during walking before and after arthroplasty for knee osteoarthritis. *Clin Biomech* (Bristol, Avon) 2012; **27**: 485-494 [PMID: 22153768 DOI: 10.1016/j.clinbiomech.2011.11.006]
  - 71 **Astephen Wilson JL**, Deluzio KJ, Dunbar MJ, Caldwell GE, Hubley-Kozey CL. The association between knee joint biomechanics and neuromuscular control and moderate knee osteoarthritis radiographic and pain severity. *Osteoarthritis Cartilage* 2011; **19**: 186-193 [PMID: 21074628 DOI: 10.1016/j.joca.2010.10.020]
  - 72 **Collopy MC**, Murray MP, Gardner GM, DiUlio RA, Gore DR. Kinesiologic measurements of functional performance before and after geometric total knee replacement: one-year follow-up of twenty cases. *Clin Orthop Relat Res* 1977; **(126)**: 196-202 [PMID: 598117]
  - 73 **Lafuente R**, Belda JM, Sánchez-Lacuesta J, Soler C, Poveda R, Prat J. Quantitative assessment of gait deviation: contribution to the objective measurement of disability. *Gait Posture* 2000; **11**: 191-198 [PMID: 10802431 DOI: 10.1016/S0966-6362(00)00044-8]
  - 74 **Marks R**, Quinney AH. Reliability and validity of the measurement of position sense in women with osteoarthritis of the knee. *J Rheumatol* 1993; **20**: 1919-1924 [PMID: 8308779]
  - 75 **Suter E**, Herzog W. Does muscle inhibition after knee injury increase the risk of osteoarthritis? *Exerc Sport Sci Rev* 2000; **28**: 15-18 [PMID: 11131682]
  - 76 **Montero-Odasso M**, Muir SW, Hall M, Doherty TJ, Klooseck M, Beauchet O, Speechley M. Gait variability is associated with frailty in community-dwelling older adults. *J Gerontol A Biol Sci Med Sci* 2011; **66**: 568-576 [PMID: 21357190 DOI: 10.1093/gerona/66.4.glr007]
  - 77 **Hatfield GL**, Hubley-Kozey CL, Astephen Wilson JL, Dunbar MJ. The effect of total knee arthroplasty on knee joint kinematics and kinetics during gait. *J Arthroplasty* 2011; **26**: 309-318 [PMID: 20570095 DOI: 10.1016/j.arth.2010.03.021]

**P- Reviewers:** Fisher DA, Fenichel I **S- Editor:** Song XX

**L- Editor:** A **E- Editor:** Lu YJ



## WJO 5<sup>th</sup> Anniversary Special Issues (5): Knee

# New perspectives for articular cartilage repair treatment through tissue engineering: A contemporary review

Giuseppe Musumeci, Paola Castrogiovanni, Rosalia Leonardi, Francesca Maria Trovato, Marta Anna Szychlinska, Angelo Di Giunta, Carla Loreto, Sergio Castorina

Giuseppe Musumeci, Paola Castrogiovanni, Marta Anna Szychlinska, Carla Loreto, Sergio Castorina, Department of Bio-Medical Sciences, Human Anatomy and Histology Section, School of Medicine, University of Catania, 95123 Catania, Italy  
Rosalia Leonardi, Department of Medical and Surgical Sciences, II Dental Unity, University of Catania, 95123 Catania, Italy  
Francesca Maria Trovato, Department of Medical and Pediatric Sciences, Internal Medicine Division, University of Catania, 95123 Catania, Italy

Angelo Di Giunta, Sergio Castorina, Fondazione Mediterranea "G.B. Morgagni", 95125 Catania, Italy

Supported by The Department of Bio-Medical Sciences, University of Catania

**Author contributions:** Musumeci G researched the area and identified papers, wrote and structured the review; Castrogiovanni P, Loreto C, Szychlinska MA and Trovato FM reviewed and edited the paper; Di Giunta A provide the surgical materials; Leonardi R and Castorina S structured the paper.

**Correspondence to:** Giuseppe Musumeci, PhD, Department of Bio-Medical Sciences, Human Anatomy and Histology Section, School of Medicine, University of Catania, 95123 Catania, Italy. [g.musumeci@unict.it](mailto:g.musumeci@unict.it)

Telephone: +39-095-3782043 Fax: +39-095-3782034

Received: October 21, 2013 Revised: January 27, 2014

Accepted: February 20, 2014

Published online: April 18, 2014

## Abstract

In this paper review we describe benefits and disadvantages of the established methods of cartilage regeneration that seem to have a better long-term effectiveness. We illustrated the anatomical aspect of the knee joint cartilage, the current state of cartilage tissue engineering, through mesenchymal stem cells and biomaterials, and in conclusion we provide a short overview on the rehabilitation after articular cartilage repair procedures. Adult articular cartilage has low capacity to repair itself, and thus even minor injuries may lead to progressive damage and osteoarthritic joint degeneration, result-

ing in significant pain and disability. Numerous efforts have been made to develop tissue-engineered grafts or patches to repair focal chondral and osteochondral defects, and to date several researchers aim to implement clinical application of cell-based therapies for cartilage repair. A literature review was conducted on PubMed, Scopus and Google Scholar using appropriate keywords, examining the current literature on the well-known tissue engineering methods for the treatment of knee osteoarthritis.

© 2014 Baishideng Publishing Group Co., Limited. All rights reserved.

**Key words:** Cartilage; Repair; Mesenchymal stem cells; Scaffolds; Tissue engineering; Osteoarthritis

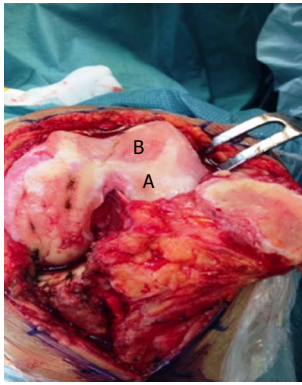
**Core tip:** In this paper review we describe benefits and disadvantages of the established methods of cartilage regeneration that seem to have a better long-term effectiveness. We illustrated the anatomical aspect of the knee joint cartilage, the current state of cartilage tissue engineering through mesenchymal stem cells and biomaterials and in conclusion we provided a short overview on the rehabilitation after articular cartilage repair procedures.

Musumeci G, Castrogiovanni P, Leonardi R, Trovato FM, Szychlinska MA, Di Giunta A, Loreto C, Castorina S. New perspectives for articular cartilage repair treatment through tissue engineering: A contemporary review. *World J Orthop* 2014; 5(2): 80-88 Available from: URL: <http://www.wjgnet.com/2218-5836/full/v5/i2/80.htm> DOI: <http://dx.doi.org/10.5312/wjo.v5.i2.80>

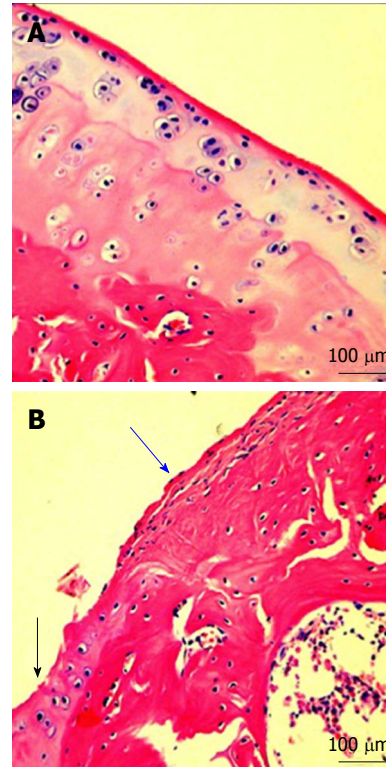
## INTRODUCTION

The knee is one of the largest and most complex joints in





**Figure 1 Macroscopic signs of osteoarthritis knee hyaline cartilage.** A: Healthy cartilage; B: Osteoarthritis cartilage.



**Figure 2 Microscopic signs.** A: Microscopic signs of healthy knee hyaline cartilage. The histological (HE staining) analysis of cartilage from normal donor, showed a preserved morphological structure with no sign of cartilage degradation. Moreover, the surface of healthy hyaline cartilage appears white, shiny, elastic and firm. Magnification x 20; Scale bars: 100 μm; B: Microscopic signs of osteoarthritis (OA) knee hyaline cartilage. The histological (HE staining) analysis of cartilage from OA donor. The donor demonstrated joint swelling and oedema, horizontal cleavage tears or flaps, the surface becomes dull and irregular and had minimal healing capacity. Magnification x 20; Scale bars: 100 μm. Moderate OA cartilage (black arrow), the structural alterations included a reduction of cartilage thickness of the superficial and the middle zones. The structure of the collagen network is damaged, which leads to reduced thickness of the cartilage. The chondrocytes are unable to maintain their repair activity with subsequent loss of the cartilage tissue. Severe OA cartilage (blue arrow), demonstrated deep surface clefts, disappearance of cells from the tangential zone, cloning, and a lack of cells in the intermediate and radial zone, which are not arranged in columns. The tidemark is no longer intact and the subchondral bone shows fibrillation.

our body. It plays an essential role in movement related to carrying the body weight in horizontal (running and walking) and vertical (jumping) directions<sup>[1]</sup>. The knee joint consists of two articulations, one between the femur and tibia, and one between the femur and patella<sup>[1]</sup>. The knee is a mobile angular ginglymus or troclear, which permits flexion and extension as well as a slight medial and lateral rotation<sup>[2]</sup>. The joint is bathed in synovial fluid, which is contained inside the synovial membrane called the joint capsule. Ligaments join the knee bones and tendons connect the knee bones to the leg muscles, providing stability to the knee. Since in humans the knee supports nearly the whole weight of the body, it is vulnerable to both acute injury and chronic development of osteoarthritis. Two C-shaped pieces of cartilage called the medial and lateral menisci lie between the articular surfaces of the femur and tibia<sup>[3-5]</sup>. The menisci are shock absorbers of the load and make concordant the articular surfaces between the femoral condyles and the tibial plateau<sup>[3-5]</sup>. During flexion the menisci slide forward, during extension slide back<sup>[2]</sup>. The menisci are divided into outer rim, inner rim and core<sup>[3-5]</sup>. The inner rim is the most delicate part, because it is not vascularized. The lateral meniscus has the form of an almost complete circle and adheres to the two cruciates<sup>[3-5]</sup>. The medial meniscus has the form of a half moon and is more extensive than lateral, with its extremities adhering to anterior and posterior intercondylar areas. Between the two menisci, the medial meniscus is more subject to trauma, because it is less mobile than the lateral for the presence of the semimembranosus tendon, but also because usually we tend to have a slight valgus during gait<sup>[3-5]</sup>. Numerous bursae, or fluid-filled sacs, are located between the bones and tendons. This anatomical structure helps to reduce the friction between the bones during movement, for helping the knee to move smoothly. The joint capsule of the knee is strengthened by different ligaments, important for the stability of the joint, they are: the patellar ligament or patellar tendon, the lateral and medial retinaculum of the patella, the medial and lateral alar ligaments, the medial and lateral collateral ligaments (preventing the femur from sliding side to side), the popliteal ligaments and the anterior and posterior cruciate ligaments.

Articular cartilage is a form of hyaline cartilage that covers the articulating surfaces of long bones and sesa-

moid bones within synovial joints<sup>[6,7]</sup>, and in the growth plate of the metaphysis, the zone between diaphysis and epiphysis<sup>[8,9]</sup>. Cartilage is a porous, viscoelastic composite that relies on a complex interaction and organization of its constituents to provide the resilient load-bearing, energy-dissipating lubrication and frictional properties<sup>[6,7]</sup>. The impressive load-bearing capacity of this tissue reflects in part the intrinsic matrix toughness and turgidity, as the ability of the tissue to swell is opposed by the internal structure. The degradation, loss, or breakdown of this unique relationship between the collagenous matrix and heavily hydrated charge-carrying proteoglycans caused by trauma or chronic and progressive degenerative joint disease (e.g., osteoarthritis or rheumatoid arthritis) has great functional, biomechanical, clinical, and social implications<sup>[10]</sup>. Knee osteoarthritis (Figures 1, 2) is the most common type of osteoarthritis<sup>[10]</sup>. Early diagnosis and

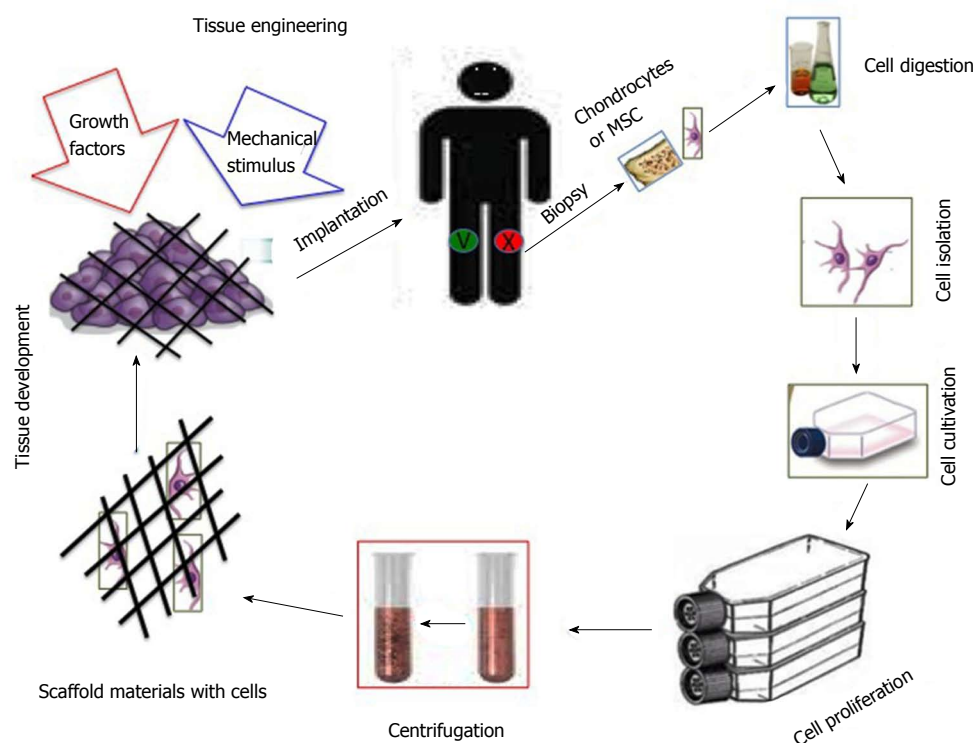
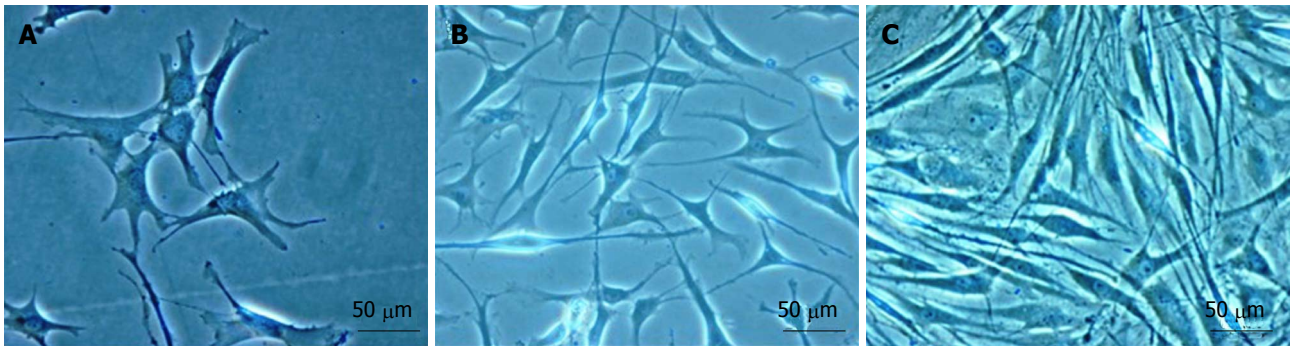


Figure 3 Graphic representation of the cartilage tissue engineering. MSC: Mesenchymal stem cell.

treatment may help to manage its symptoms. Deterioration of articular cartilage is the main problem associated with knee osteoarthritis. The condition can be caused by: previous knee injury like fractures, ligament tears and meniscal injury or repetitive strain on the knee which can affect alignment, obesity, and genetics which make some people more likely to develop knee osteoarthritis<sup>[11]</sup>. Medical history, physical examination, and X-rays are used to diagnose knee osteoarthritis. The evidence of joint space narrowing on X-rays is crucial for the diagnosis and rules out other causes of knee pain<sup>[12]</sup>. If more detailed imaging is needed, an MRI may be ordered<sup>[12]</sup>. Arthroscopic knee surgery is another way to view the condition of the knee<sup>[12]</sup>. Knee osteoarthritis typically develops gradually over a period of years. The primary symptoms include: pain (mild, moderate, or severe), stiffness, limited range of motion in the knee, localized swelling. Knee osteoarthritis pain is usually worse following activity, especially overuse of the affected knee<sup>[10-13]</sup>. Stiffness can worsen after sitting for prolonged periods of time. As knee osteoarthritis progresses, symptoms generally become more severe. Then pain can become continuous rather than only when weight-bearing. The consequence in many cases is an inability to work and often the substitution of the diseased joint with an artificial implant becomes inevitable<sup>[6,7]</sup>. Joint replacement also called knee arthroplasty has had a major impact on the management of OA. After injury, articular cartilage is unable to naturally restore itself back to a functional tissue, and, because of this, a widely studied alternative to avoid the knee replacement surgery for osteoarthritis is tissue engineering<sup>[11-13]</sup>.

## TISSUE ENGINEERING

Tissue engineering (Figure 3), is the use of a combination of cells, biochemical and physio-chemical factors, engineering and biomaterials to improve or replace biological functions<sup>[14-16]</sup>. While it was once categorized as a sub-field of biomaterials, having grown in scope and importance it can be considered as a field in its own right. While most definitions of tissue engineering cover a broad range of applications, in practice the term is closely associated with applications that repair or replace portions of or whole tissues (*i.e.*, bone, cartilage, blood vessels, skin, muscle, nerve *etc.*)<sup>[14-16]</sup>. Often, the tissues involved require certain mechanical and structural properties for proper functioning. The term regenerative medicine is often used synonymously with tissue engineering, although those involved in regenerative medicine place more emphasis on the use of stem cells to produce tissues<sup>[14-16]</sup>. Tissue engineering of natural cartilage tissue has become an attractive new area of research. For this reason, we discuss briefly the most widely used techniques in the treatment of cartilage lesions to solve the problem of the management of cartilage defects. In recent years, surgeons and researchers have been working hard to elaborate surgical cartilage repair interventions for patients who suffer from articular cartilage damage. They provide pain relief, helping patients to return to their original lifestyle (regaining mobility, going back to work and even practicing sports again), while at the same time slowing down the progression of damage or considerably delaying joint replacement. Though these



**Figure 4 Mesenchymal stem cells development.** A: First day of culture; B: Third day of culture; C: One week of culture. Magnification x 40; Scale bars: 50 µm.

solutions do not perfectly restore cartilage, some of the latest technologies start to bring very promising results in repairing cartilage from traumatic injury or chondropathies. Although initially considered a tissue with a simple structure, reproducing the finely balanced structural interactions has proven to be difficult. Tissue engineering is able to create live tissue to replace, repair or strengthen harmed tissue. It is based on cell and genetic therapy and offers some of the most promising strategies of tissue repair, including articular cartilage repair. Although it has concentrated on finding therapies for focal lesions, it has now developed sufficiently to begin considering the challenge of finding novel solutions for the extensive joint damage seen in osteoarthritis.

At the present time, a variety of clinical methods is available for repairing a chondral defect: marrow stimulation, autologous chondrocyte implantation (ACI), and most recently, next-generation ACI involving scaffolds or cell-seeded scaffolds, microfracture, osteoarticular transfer system (OATS) or mosaicplasty, penetration of the subchondral bone, osteochondral plug transplantation and matrix-induced autologous chondrocyte implantation (MACI)<sup>[6,7]</sup>. The cartilage repair procedure seeks to restore the surface of an articular joint's hyaline cartilage and to replace the defect with an optimal repair tissue, mechanically stable, in order to prevent further degeneration. Today almost none of the mentioned procedures prove capable of generating hyaline cartilage and the clinical outcome needs to be further improved. ACI procedures take place in three stages. First, chondrocytes are extracted arthroscopically from the patient's healthy articular cartilage that is located in a nonload-bearing area of either the intercondylar notch or the superior ridge of the femoral condyles. Then these extracted cells are transferred to an "*in vitro*" environment in specialized laboratories where they grow and replicate, for approximately four to six weeks, until their population has increased to a sufficient amount. Finally, the patient undergoes a second surgery where the "*in vitro*" chondrocytes are applied to the damaged area. In this procedure, chondrocytes are injected and applied to the damaged area in combination with either a membrane or a matrix structure. These transplanted cells grow in their new environment, forming new articular cartilage<sup>[6,7]</sup>. Increasing the source of cells for artificial repair of cartilage defects is becoming

a problem<sup>[6,7]</sup>. The limited supply of cartilage, as a source of chondrocytes, requires a phase of expansion in monolayer culture. Chondrocyte differentiation and the maintenance of function require both transient and long-lasting control through humoral factors, particularly under stress, repair and regeneration *in vivo* or *in vitro*. To date, humoral factors from all major classes of molecules are known to contribute: ions (calcium), steroids (estrogens), terpenoids (retinoic acid), peptides (PTHrP, PTH, insulin, FGFs) and complex proteins (IGF-1, BMPs)<sup>[17]</sup>. BMP-4, a stimulator of chondrogenesis, both *in vitro* and *in vivo*, is a potential therapeutic agent for cartilage regeneration. BMP-4 delivery can improve the healing process of an articular cartilage defect by stimulating the synthesis of the cartilage matrix constituents: type II collagen and aggrecan. BMP-4 has also been shown to suppress chondrogenic hypertrophy and maintain regenerated cartilage. Use of an appropriate carrier for BMP-4 is crucial for successful reconstruction of cartilage defects<sup>[18]</sup>.

Chondrocyte expansion is complicated by the fact that monolayer-cultured chondrocytes de-differentiate, lose their characteristic phenotype and synthesize type I (typical of fibrocartilage) rather than type II collagen (typical of hyaline cartilage)<sup>[8]</sup>. Osteochondral plug transplantation, or osteochondral autograft transfer system (OATS), usually applied for mid-sized defects<sup>[19]</sup>, immediately recovers the joint surface. Small sized articular lesions are commonly addressed arthroscopically by penetration of the underlying subchondral bone<sup>[20-22]</sup> to promote a fibrous scar within the defect by invasion of adult mesenchymal stem cells. However, the reparative tissue does not withstand repetitive mechanical forces because of its poor quality, consisting mainly of collagen type I, and clinical outcome deteriorates over time<sup>[23,24]</sup>. This has led to investigation into the use of mesenchymal stem cells (MSCs). MSCs (Figure 4) can be relatively easily harvested and the procedures using them are less invasive or destructive than articular cartilage harvesting procedures.

The inherent ability of MSCs to self-renew opens the possibility that cell expansion may be achievable post-implantation<sup>[25]</sup>. The differentiation of MSCs into different cell types, in this case to produce cartilage tissue, is reliant on the local microenvironment, and growth factors, extracellular matrix and mechanical forces<sup>[25,26]</sup>. MSCs are easily available from bone marrow, synovial membrane,



**Table 1** Natural and synthetic materials

Natural and synthetic materials	Materials	Advantages
Natural	Natural Silk, collagen, gelatin, fibrinogen, hyaluronic acid, alginate	Biodegradable Easily available Bioactive, interact with cells
Synthetic	PEG, PGA, PMMA, PLGA	Facilitate restoration of structure of damaged tissues Inert Long shelf-life Easily tailored for desired porosity and degradation time Predictable and reproducible mechanical and physical properties

PGA: Polyglycolic acid; PLGA: Poly (lactic-co-glycolic acid); PEG: Polyethylene glycol; PMMA: Polymethyl methacrylate.

adipose tissue<sup>[27,28]</sup>, *etc.*, so then, we can get a variable number of cells from a different tissue<sup>[29,30]</sup>. MSCs show a high proliferation and differentiation potential, although coming from different tissue, and have an uneven chondrogenic differentiation capacity probably related to the special cytokines, growth factor and induction molecules composition of the medium<sup>[31,32]</sup>.

Marrow stimulating techniques attempt to solve articular cartilage damage through an arthroscopic procedure. Firstly, damaged cartilage is drilled or punched until the underlying bone is exposed. By doing this, the subchondral bone is perforated to generate a blood clot within the defect. Studies have shown that marrow stimulation techniques often have insufficiently filled the chondral defect and the repair material is often fibrocartilage (which is not as good mechanically as hyaline cartilage)<sup>[6,7,33]</sup>. The blood clot takes about 8 wk to become fibrous tissue and it takes 4 mo to become fibrocartilage. This has implications for the rehabilitation<sup>[2]</sup>. Further on, it is common that only 1 or 2 years after the surgery symptoms start to return as the fibrocartilage wears away, forcing the patient to reengage in articular cartilage repair. This is not always the case and microfracture surgery is therefore considered to be an intermediate step. An evolution of the microfracture technique is the implantation of a collagen membrane onto the site of the microfracture to protect and stabilize the blood clot and to enhance the chondrogenic differentiation of the MSCs<sup>[6,7]</sup>. One of the cons of chondrocyte transplantation is the dedifferentiation process that these cells suffer when they are treated *in vitro* and the limited ability to redifferentiate them<sup>[34]</sup>. On the contrary, MSCs are very stable and they do not suffer this dedifferentiation process and have a high differentiation capacity<sup>[35]</sup>. Beside the characteristics of MSCs expounded above, these cells have self-renewal potential as well as multilineage differentiation potential<sup>[36,37]</sup>, including chondrogenesis<sup>[25]</sup>. A defined medium for *in vitro* chondrogenesis of MSCs was first reported by Johnstone *et al.*<sup>[25]</sup> in 1998, who used micromass culture with TGF- $\beta$  and dexamethasone. To date, the micromass culture is widely used to evaluate chondrogenic potential of MSCs “*in vitro*”. However, this “*in vitro*” chondrogenesis does not imitate cartilage formation during development. During micromass culture, MSCs increase expressions

of both collagen type II (chondrocytes marker) and X (hypertrophic chondrocytes marker)<sup>[25]</sup>. Other cytokines such as insulin like growth factor (IGF), bone morphogenetic protein (BMPs) and parathyroid hormone related peptide (PTHrP) had been tried for better differentiation of the cells, but it is still difficult to obtain “*in vitro*” MSC-based cartilage formation comparative to native cartilage tissue<sup>[25]</sup>. Those molecules may reach chondrocytes *via* free diffusion or may be bound to collagens or proteoglycans on extracellular matrix superstructures, becoming available after metabolic processing of collagens and/or proteoglycans. Depending on their position in the metabolic cascade controlling chondrocyte development and homeostasis, they may be used in tissue engineering and regenerative approaches towards cartilage repair by direct application, carrier-mediated release or genetic delivery<sup>[17]</sup>.

## BIOMATERIALS

Recently a huge expansion in biomaterial technologies, scaffolds, cell sources, and molecular and genetic manipulations took place to create functional tissue replacements to treat cartilage injuries or osteoarthritis<sup>[38-40]</sup>. A new generation of materials is being developed and it is influenced by the knowledge of the anatomical and structural complexity of articular cartilage. The increasing capacity to design and synthesize materials with molecular resolution that ranges across organizational levels is generating great excitement in the biomaterials community<sup>[25]</sup>. The combination of technological advances and an increased knowledge in the fields of molecular and cell biology are generating new biomaterial scaffolds with many desired properties<sup>[25]</sup>. In addition to being biocompatible and accommodating cell adhesion, proliferation, and matrix synthesis, an ideal biomaterial scaffold for cartilage regeneration can now be bioactive, biomimetic, biodegradable and bioresponsive, providing signaling with spatio-temporal control and response that is selective to defined stimuli. Scaffolds analogous to the natural three-dimensional extracellular matrix may provide important micro-environmental clues to cells. A wide array of materials has been used in various “*in vitro*” and “*in vivo*” studies for articular cartilage engineering (Tables 1-3). Scaffolds that are most often studied in cartilage tissue engineering

**Table 2 Overview of advantages and disadvantages of various scaffolds**

Scaffold	Advantages	Disadvantages
Porous scaffolds	High porosity Interconnected structure Simple and easy to manufacture	Use of highly toxic solvent Low pore interconnectivity Difficulty in homogenous cell seeding post scaffold fabrication Highly porous scaffolds can have weak mechanical properties
Fibrous scaffolds	Fiber meshes and fiber bonding are simple techniques Large surface area-volume ratio High inter-fiber distances for nutrition and gas exchange	Lack of control over scaffold thickness Fiber meshes lack mechanical integrity Fiber bonding lacks control over porosity and pore size Small pore sizes produced during fabrication processes such as electrospinning limit cell infiltration and 3-D cellular integration with host tissue after implantation
Hydrogels	Can form stable and highly ordered scaffolds using self assembly Tissue like flexibility Viscoelasticity	Higher cost Non-adherent and usually need to be secured by a secondary dressing, for <i>in-vivo</i> testing
Custom scaffolds (Computer-aided design technique)	Intestinal flow and diffusive transport Controlled matrix architecture: size, shape, interconnectivity, branching, geometry and orientation Can control pore and pore size	Natural polymer hydrogels like collagen gelatin, alginate and agarose may evoke inflammatory responses Low resolution of current systems Selective polymeric materials can only be used
Microspheres	Controlled mechanical properties and degradation kinetics Reproducible architecture and compositional variations Used as cell carriers, when fabricated using biodegradable and non-toxic materials Large surface area for cell attachment and growth	Difficult to remove once injected or implanted Unknown toxicity associated with microsphere/beads
Native/ Extracellular matrix scaffolds	Applicable for 3-D cell culture in a stirred suspension bioreactor Simulates the cell's natural microenvironment in terms of composition, bioactive signal and mechanical properties	Difficult to control degree of decellularization and retain all ECM Non-uniform distribution of cells Immunogenicity upon incomplete decellularization

**Table 3 Overview of advantages and disadvantages of various scaffolds**

Cells	Material	Results
Chondrocytes	Poly(epsilon-caprolactone)-block-poly(L-lactide)	Applicable for cartilage tissue engineering
Rabbit marrow mesenchymal stem cells	Oligo(poly(ethylene glycol) fumarate) with encapsulated cells and gelatin microparticles loaded with TGF-β1	Maintained viability of cells for 14 d Differentiation of cells into chondrocyte-like cells
Chondrocytes	Gelatin microparticle aggregates, +/- TGF-β1	Supported viability and function of chondrocytes Applications in cartilage-engineering
Human adipose derived stem cells	Genipin-crosslinked cartilage derived matrix	Using genipin resulted in contraction free biomaterial. Chondrogenesis
Human mesenchymal stem cells	Poly(epsilon-caprolactone)	Cell colonization, proliferation and osteogenic differentiation were related to the micro-architecture of the pore structure
Human chondrocytes	Blend of poly (lactic-co-glycolic acid) and polyvinyl alcohol	Supported cell adhesion and growth After implantation, there was better bone in-growth and bone formation inside the scaffold.
Bone marrow stem cells	Polyglycolic acid, poly (lactic acid)	Cell infiltrated the scaffold Good cellular compatibility Applicable to repair craniomaxillofacial bone defects

TGF: Transforming growth factor.

include hydrogels made from poly(ethylene glycol) diacrylate (PEGDA)<sup>[7,11-13,41,42]</sup>, collagen<sup>[43]</sup>, fibrin<sup>[44,45]</sup>, agarose, and synthetic peptides<sup>[46,47]</sup>; sponge-like scaffolds manufactured from materials such as collagen, polyglycolic acid, polylactic acid<sup>[48]</sup>, and polyurethane<sup>[49]</sup>; materials with a naturally-occurring porous structure, such as coral, devitalized articular cartilage<sup>[50]</sup>, and hyaluronan based scaffolds<sup>[51]</sup>. The three-dimensional scaffold provides the structural support for cell contact and matrix deposition

prevents dedifferentiation of autologous chondrocytes even after long periods and promotes the expression of chondrocyte-specific markers<sup>[52]</sup>. Advantages of this procedure are a more uniform cell distribution, avoidance of periosteal harvest and implantation, and increased technical ease without the need for suturing to adjacent articular cartilage. These scaffold-less platforms develop a robust ECM framework of their own and permit long-term maintenance of phenotype, at least in long-term *in*

*in vitro* culture, and can improve biophysical properties by mechanical loading. Scaffold-free constructs using alginate as an intermediate step have also been produced<sup>[53]</sup> and subjected to mechanical loading<sup>[54]</sup>. The challenge with such scaffold-free systems is producing them in a cost-effective and timely manner for clinical use, especially with autologous cells. This is also true for scaffold-based systems, but they have biomechanical properties that are immediately functional “*in vivo*”, showing the ability to direct growth; further they can be designed to deliver relevant bioactive factors<sup>[25]</sup>.

## REHABILITATION

Mechanical stimuli are of crucial importance for the development and maintenance of articular cartilage<sup>[55]</sup>. Rehabilitation, following any articular cartilage repair procedure is crucial for the success of any articular cartilage resurfacing technique<sup>[2]</sup>. The rehabilitation is often long as it takes a long time for the cartilage cells to adapt and mature into repair tissue. Cartilage is a slow adapting substance, indeed where a muscle takes approximately 35 wk to fully adapt, cartilage only undergoes 75% adaptation in 2 years. If the rehabilitation period is too short, the cartilage repair might be put under too much stress, causing the repair to fail<sup>[2]</sup>. Over the years a variety of cartilage restorative procedures have been developed for athletes to address focal, full-thickness cartilaginous defects in the knee joint<sup>[56]</sup>. In most rehabilitation protocols, continuous passive motion or range of motion exercises are performed within the first day after injury or surgery. Ice, compression, elevation, weight-bearing activities, and electrical stimulation are also started immediately, and the intensity and repetition of these exercises increases as the rehabilitation program progresses. In addition, exercises to address the complimentary musculoskeletal system are also introduced, especially if distinct asymmetries are noted<sup>[57]</sup>. The type of mobilization exercises used depends on the injury. Experimental and clinical studies demonstrate that early, controlled mobilization is superior to immobilization for primary treatment of acute musculoskeletal soft-tissue injuries and postoperative management<sup>[58]</sup>. Early mobilization helped return the patients more quickly to physical activity, reduce persistent swelling, restore stability, restore range of motion, and improve patient satisfaction with the rehabilitation outcome<sup>[59]</sup>. Postoperative rehabilitation programs following articular cartilage repair procedures will vary greatly among patients and need to be individualized, based on the nature of the lesion, the unique characteristics of the patient, and the type and detail of each surgical procedure<sup>[59]</sup>. These programs are based on knowledge of the basic science, anatomy, and biomechanics of articular cartilage as well as the biological course of healing following surgery<sup>[59]</sup>. The goal is to restore full function in each patient as quickly as possible by facilitating a healing response without overloading the healing articular cartilage<sup>[2]</sup>. A patient, lesion, and sports-specific approach is required on the part of the trainer or

physical therapist to gradually restore knee joint function and strength so that the athlete may be able to return to competitive play<sup>[56]</sup>. In this paper review we also take the opportunity to remind readers of the importance of a healthy lifestyle, including physical activity (mild exercise) and balanced diet such as Mediterranean Diet, in the medical therapy to prevent OA disease, in order to preserve the articular cartilage and then the entire joint<sup>[59]</sup>.

## CONCLUSION

In conclusion, the treatment of articular cartilage defects can be approached by different procedures in relation to cartilage lesions. Further “*in vivo*” and “*in vitro*” studies must be carried out in order to confirm their successful clinical outcomes.

## ACKNOWLEDGMENTS

The authors would like to thank Prof. Iain Halliday for commenting and making corrections to the paper.

## REFERENCES

- 1 **Blackburn TA**, Craig E. Knee anatomy: a brief review. *Phys Ther* 1980; **60**: 1556-1560 [PMID: 7454779]
- 2 **Bennell KL**, Hinman RS. A review of the clinical evidence for exercise in osteoarthritis of the hip and knee. *J Sci Med Sport* 2011; **14**: 4-9 [PMID: 20851051 DOI: 10.1016/j.jsams.2010.08.002]
- 3 **Musumeci G**, Carnazza ML, Leonardi R, Loreto C. Expression of  $\beta$ -defensin-4 in “an *in vivo* and ex vivo model” of human osteoarthritic knee meniscus. *Knee Surg Sports Traumatol Arthrosc* 2012; **20**: 216-222 [PMID: 21879330 DOI: 10.1007/s00167-011-1630-x]
- 4 **Musumeci G**, Loreto C, Carnazza ML, Cardile V, Leonardi R. Acute injury affects lubricin expression in knee menisci: an immunohistochemical study. *Ann Anat* 2013; **195**: 151-158 [PMID: 23083677 DOI: 10.1016/j.aanat.2012.07.010]
- 5 **Musumeci G**, Leonardi R, Carnazza ML, Cardile V, Pichler K, Weinberg AM, Loreto C. Aquaporin 1 (AQP1) expression in experimentally induced osteoarthritic knee menisci: an *in vivo* and *in vitro* study. *Tissue Cell* 2013; **45**: 145-152 [PMID: 23164158 DOI: 10.1016/j.tice.2012.10.004]
- 6 **Musumeci G**, Loreto C, Castorina S, Imbesi R, Leonardi R, Castrogiovanni P. Current Concepts in the Treatment of Cartilage Damage. A Review. *IJAE* 2013; **118**: 189-203
- 7 **Musumeci G**, Loreto C, Castorina S, Imbesi R, Leonardi R, Castrogiovanni P. New perspectives in the treatment of cartilage damage. Poly(ethylene glycol) diacrylate (PEGDA) scaffold. A review. *IJAE* 2013; **118**: 204-210
- 8 **Pichler K**, Musumeci G, Vielgut I, Martinelli E, Sadoghi P, Loreto C, Weinberg AM. Towards a better understanding of bone bridge formation in the growth plate - an immunohistochemical approach. *Connect Tissue Res* 2013; **54**: 408-415 [PMID: 23941205 DOI: 10.3109/03008207.2013.828715]
- 9 **Musumeci G**, Castrogiovanni P, Loreto C, Castorina S, Pichler K, Weinberg AM. Post-traumatic caspase-3 expression in the adjacent areas of growth plate injury site: a morphological study. *Int J Mol Sci* 2013; **14**: 15767-15784 [PMID: 23899790 DOI: 10.3390/ijms140815767]
- 10 **Musumeci G**, Loreto C, Carnazza ML, Martinez G. Characterization of apoptosis in articular cartilage derived from the knee joints of patients with osteoarthritis. *Knee Surg Sports*




- Traumatol Arthrosc* 2011; **19**: 307-313 [PMID: 20644910 DOI: 10.1007/s00167-010-1215-0]
- 11 **Musumeci G**, Carnazza ML, Loreto C, Leonardi R, Loreto C.  $\beta$ -defensin-4 (HBD-4) is expressed in chondrocytes derived from normal and osteoarthritic cartilage encapsulated in PEGDA scaffold. *Acta Histochem* 2012; **114**: 805-812 [PMID: 22564496 DOI: 10.1016/j.acthis.2012.02.001]
  - 12 **Musumeci G**, Loreto C, Carnazza ML, Coppolino F, Cardile V, Leonardi R. Lubricin is expressed in chondrocytes derived from osteoarthritic cartilage encapsulated in poly(ethylene glycol) diacrylate scaffold. *Eur J Histochem* 2011; **55**: e31 [PMID: 22073377 DOI: 10.4081/ejh.2011.e31]
  - 13 **Musumeci G**, Loreto C, Carnazza ML, Strehin I, Elisseeff J. OA cartilage derived chondrocytes encapsulated in poly(ethylene glycol) diacrylate (PEGDA) for the evaluation of cartilage restoration and apoptosis in an *in vitro* model. *Histol Histopathol* 2011; **26**: 1265-1278 [PMID: 21870330]
  - 14 **Langer R**, Vacanti JP. Tissue engineering. *Science* 1993; **260**: 920-926 [PMID: 8493529 DOI: 10.1126/science.8493529]
  - 15 **Langer R**, Vacanti JP. Artificial organs. *Sci Am* 1995; **273**: 130-133 [PMID: 7652530]
  - 16 **Vacanti JP**, Langer R. Tissue engineering: the design and fabrication of living replacement devices for surgical reconstruction and transplantation. *Lancet* 1999; **354** Suppl 1: S132-S134 [PMID: 10437854 DOI: 10.1016/S0140-6736(99)90247-7]
  - 17 **Gaissmaier C**, Koh JL, Weise K. Growth and differentiation factors for cartilage healing and repair. *Injury* 2008; **39** Suppl 1: S88-S96 [PMID: 18313476 DOI: 10.1016/j.injury.2008.01.035]
  - 18 **Miljkovic ND**, Cooper GM, Marra KG. Chondrogenesis, bone morphogenetic protein-4 and mesenchymal stem cells. *Osteoarthritis Cartilage* 2008; **16**: 1121-1130 [PMID: 18406633 DOI: 10.1016/j.joca.2008.03.003]
  - 19 **Benz K**, Breit S, Lukoschek M, Mau H, Richter W. Molecular analysis of expansion, differentiation, and growth factor treatment of human chondrocytes identifies differentiation markers and growth-related genes. *Biochem Biophys Res Commun* 2002; **293**: 284-292 [PMID: 12054597 DOI: 10.1016/S0006-291X(02)00223-1]
  - 20 **Nejadic H**, Hui JH, Feng Choong EP, Tai BC, Lee EH. Autologous bone marrow-derived mesenchymal stem cells versus autologous chondrocyte implantation: an observational cohort study. *Am J Sports Med* 2010; **38**: 1110-1116 [PMID: 20392971 DOI: 10.1177/0363546509359067]
  - 21 **Becerra J**, Andrades JA, Guerado E, Zamora-Navas P, López-Puertas JM, Reddi AH. Articular cartilage: structure and regeneration. *Tissue Eng Part B Rev* 2010; **16**: 617-627 [PMID: 20836752 DOI: 10.1089/ten.teb.2010.0191]
  - 22 **Becerra J**, Santos-Ruiz L, Andrades JA, Mari-Beffa M. The stem cell niche should be a key issue for cell therapy in regenerative medicine. *Stem Cell Rev* 2011; **7**: 248-255 [PMID: 21052872 DOI: 10.1007/s12015-010-9195-5]
  - 23 **Steadman JR**, Briggs KK, Rodrigo JJ, Kocher MS, Gill TJ, Rodkey WG. Outcomes of microfracture for traumatic chondral defects of the knee: average 11-year follow-up. *Arthroscopy* 2003; **19**: 477-484 [PMID: 12724676 DOI: 10.1053/jars.2003.50112]
  - 24 **Basad E**, Ishaque B, Bachmann G, Stürz H, Steinmeyer J. Matrix-induced autologous chondrocyte implantation versus microfracture in the treatment of cartilage defects of the knee: a 2-year randomised study. *Knee Surg Sports Traumatol Arthrosc* 2010; **18**: 519-527 [PMID: 20062969 DOI: 10.1007/s00167-009-1028-1]
  - 25 **Johnstone B**, Alini M, Cucchiari M, Dodge GR, Eglin D, Guilak F, Madry H, Mata A, Mauck RL, Semino CE, Stoddart MJ. Tissue engineering for articular cartilage repair—the state of the art. *Eur Cell Mater* 2013; **25**: 248-267 [PMID: 23636950]
  - 26 **Miyaniishi K**, Trindade MC, Lindsey DP, Beaupré GS, Carter DR, Goodman SB, Schurman DJ, Smith RL. Effects of hydrostatic pressure and transforming growth factor-beta 3 on adult human mesenchymal stem cell chondrogenesis *in vitro*. *Tissue Eng* 2006; **12**: 1419-1428 [PMID: 16846340 DOI: 10.1089/ten.2006.12.1419]
  - 27 **Guilak F**, Estes BT, Diekmann BO, Moutos FT, Gimble JM. 2010 Nicolas Andry Award: Multipotent adult stem cells from adipose tissue for musculoskeletal tissue engineering. *Clin Orthop Relat Res* 2010; **468**: 2530-2540 [PMID: 20625952 DOI: 10.1007/s11999-010-1410-9]
  - 28 **Musumeci G**, Lo Furno D, Loreto C, Giuffrida R, Caggia S, Leonardi R, Cardile V. Mesenchymal stem cells from adipose tissue which have been differentiated into chondrocytes in three-dimensional culture express lubricin. *Exp Biol Med* (Maywood) 2011; **236**: 1333-1341 [PMID: 22036733 DOI: 10.1258/ebm.2011.011183]
  - 29 **Winter A**, Breit S, Parsch D, Benz K, Steck E, Hauner H, Weber RM, Ewerbeck V, Richter W. Cartilage-like gene expression in differentiated human stem cell spheroids: a comparison of bone marrow-derived and adipose tissue-derived stromal cells. *Arthritis Rheum* 2003; **48**: 418-429 [PMID: 12571852 DOI: 10.1002/art.10767]
  - 30 **Hunziker EB**. Articular cartilage repair: basic science and clinical progress. A review of the current status and prospects. *Osteoarthritis Cartilage* 2002; **10**: 432-463 [PMID: 12056848 DOI: 10.1053/joca.2002.0801]
  - 31 **Hennig T**, Lorenz H, Thiel A, Goetzke K, Dickhut A, Geiger F, Richter W. Reduced chondrogenic potential of adipose tissue derived stromal cells correlates with an altered TGFbeta receptor and BMP profile and is overcome by BMP-6. *J Cell Physiol* 2007; **211**: 682-691 [PMID: 17238135 DOI: 10.1002/jcp.20977]
  - 32 **Claros S**, Rodríguez-Losada N, Cruz E, Guerado E, Becerra J, Andrades JA. Characterization of adult stem/progenitor cell populations from bone marrow in a three-dimensional collagen gel culture system. *Cell Transplant* 2012; **21**: 2021-2032 [PMID: 22472743 DOI: 10.3727/096368912X636939]
  - 33 **Kreuz PC**, Steinwachs MR, Erggelet C, Krause SJ, Konrad G, Uhl M, Südkamp N. Results after microfracture of full-thickness chondral defects in different compartments in the knee. *Osteoarthritis Cartilage* 2006; **14**: 1119-1125 [PMID: 16815714 DOI: 10.1016/j.joca.2006.05.003]
  - 34 **Chung C**, Burdick JA. Engineering cartilage tissue. *Adv Drug Deliv Rev* 2008; **60**: 243-262 [PMID: 17976858 DOI: 10.1016/j.addr.2007.08.027]
  - 35 **Chung C**, Mesa J, Randolph MA, Yaremchuk M, Burdick JA. Influence of gel properties on neocartilage formation by auricular chondrocytes photoencapsulated in hyaluronic acid networks. *J Biomed Mater Res A* 2006; **77**: 518-525 [PMID: 16482551 DOI: 10.1002/jbm.a.30660]
  - 36 **Song L**, Baksh D, Tuan RS. Mesenchymal stem cell-based cartilage tissue engineering: cells, scaffold and biology. *Cytotherapy* 2004; **6**: 596-601 [PMID: 15773023 DOI: 10.1080/14653240410005276-1]
  - 37 **Elisseeff J**, Anseth K, Sims D, McIntosh W, Randolph M, Langer R. Transdermal photopolymerization for minimally invasive implantation. *Proc Natl Acad Sci USA* 1999; **96**: 3104-3107 [PMID: 10077644 DOI: 10.1073/pnas.96.6.3104]
  - 38 **Elisseeff J**, McIntosh W, Anseth K, Riley S, Ragan P, Langer R. Photoencapsulation of chondrocytes in poly(ethylene oxide)-based semi-interpenetrating networks. *J Biomed Mater Res* 2000; **51**: 164-171 [PMID: 10825215 DOI: 10.1002/(SICI)1097-4636(200008)51:2<164::AID-JBM4>3.0.CO;2-W]
  - 39 **Dorotka R**, Windberger U, Macfelda K, Bindreiter U, Toma C, Nehrer S. Repair of articular cartilage defects treated by microfracture and a three-dimensional collagen matrix. *Biomaterials* 2005; **26**: 3617-3629 [PMID: 15621252 DOI: 10.1016/j.biomaterials.2004.09.034]
  - 40 **Ameer GA**, Mahmood TA, Langer R. A biodegradable composite scaffold for cell transplantation. *J Orthop Res* 2002; **20**: 16-19 [PMID: 11853084 DOI: 10.1016/S0736-0266(01)00074-2]
  - 41 **Peretti GM**, Randolph MA, Villa MT, Buragas MS, Yarem-

- chuk MJ. Cell-based tissue-engineered allogeneic implant for cartilage repair. *Tissue Eng* 2000; **6**: 567-576 [PMID: 11074942 DOI: 10.1089/107632700750022206]
- 42 **Kisiday J**, Jin M, Kurz B, Hung H, Semino C, Zhang S, Grodzinsky AJ. Self-assembling peptide hydrogel fosters chondrocyte extracellular matrix production and cell division: implications for cartilage tissue repair. *Proc Natl Acad Sci USA* 2002; **99**: 9996-10001 [PMID: 12119393 DOI: 10.1073/pnas.142309999]
  - 43 **Kisiday JD**, Jin M, DiMicco MA, Kurz B, Grodzinsky AJ. Effects of dynamic compressive loading on chondrocyte biosynthesis in self-assembling peptide scaffolds. *J Biomech* 2004; **37**: 595-604 [PMID: 15046988 DOI: 10.1016/j.jbiomech.2003.10.005]
  - 44 **Grande DA**, Halberstadt C, Naughton G, Schwartz R, Manji R. Evaluation of matrix scaffolds for tissue engineering of articular cartilage grafts. *J Biomed Mater Res* 1997; **34**: 211-220 [PMID: 9029301 DOI: 10.1002/(SICI)1097-4636(199702)34:2<211::AID-JBM10>3.0.CO;2-L]
  - 45 **Grad S**, Lee CR, Gorna K, Gogolewski S, Wimmer MA, Alini M. Surface motion upregulates superficial zone protein and hyaluronan production in chondrocyte-seeded three-dimensional scaffolds. *Tissue Eng* 2005; **11**: 249-256 [PMID: 15738679 DOI: 10.1089/ten.2005.11.249]
  - 46 **Hangody L**, Vásárhelyi G, Hangody LR, Sükösd Z, Tibay G, Bartha L, Bodó G. Autologous osteochondral grafting—technique and long-term results. *Injury* 2008; **39** Suppl 1: S32-S39 [PMID: 18313470 DOI: 10.1016/j.injury.2008.01.041]
  - 47 **Kang JY**, Chung CW, Sung JH, Park BS, Choi JY, Lee SJ, Choi BC, Shim CK, Chung SJ, Kim DD. Novel porous matrix of hyaluronic acid for the three-dimensional culture of chondrocytes. *Int J Pharm* 2009; **369**: 114-120 [PMID: 19059468 DOI: 10.1016/j.ijpharm.2008.11.008]
  - 48 **Filová E**, Jelínek F, Handl M, Lytvynets A, Rampichová M, Varga F, Cinátl J, Soukup T, Trc T, Amler E. Novel composite hyaluronan/type I collagen/fibrin scaffold enhances repair of osteochondral defect in rabbit knee. *J Biomed Mater Res B Appl Biomater* 2008; **87**: 415-424 [PMID: 18435405 DOI: 10.1002/jbm.b.31119]
  - 49 **Masuda K**, Sah RL, Hejna MJ, Thonar EJ. A novel two-step method for the formation of tissue-engineered cartilage by mature bovine chondrocytes: the alginate-recovered-chondrocyte (ARC) method. *J Orthop Res* 2003; **21**: 139-148 [PMID: 12507591 DOI: 10.1016/S0736-0266(02)00109-2]
  - 50 **Stoddart MJ**, Ettinger L, Häuselmann HJ. Enhanced matrix synthesis in de novo, scaffold free cartilage-like tissue subjected to compression and shear. *Biotechnol Bioeng* 2006; **95**: 1043-1051 [PMID: 16804949 DOI: 10.1002/bit.21052]
  - 51 **Grad S**, Eglin D, Alini M, Stoddart MJ. Physical stimulation of chondrogenic cells *in vitro*: a review. *Clin Orthop Relat Res* 2011; **469**: 2764-2772 [PMID: 21344272 DOI: 10.1007/s11999-011-1819-9]
  - 52 **Nho SJ**, Pensak MJ, Seigerman DA, Cole BJ. Rehabilitation after autologous chondrocyte implantation in athletes. *Clin Sports Med* 2010; **29**: 267-282, viii [PMID: 20226319 DOI: 10.1016/j.csm.2009.12.004]
  - 53 **Kerkhoffs GM**, Rowe BH, Assendelft WJ, Kelly KD, Struijs PA, van Dijk CN. Immobilisation for acute ankle sprain. A systematic review. *Arch Orthop Trauma Surg* 2001; **121**: 462-471 [PMID: 11550833 DOI: 10.1007/s004020100283]
  - 54 **Andrews JR**, Harrelson GL, Wilk KE. Physical rehabilitation of the injured athlete, 2nd ed. Philadelphia, PA: W.B. Saunders, 1998
  - 55 **Reinold MM**, Wilk KE, Macrina LC, Dugas JR, Cain EL. Current concepts in the rehabilitation following articular cartilage repair procedures in the knee. *J Orthop Sports Phys Ther* 2006; **36**: 774-794 [PMID: 17063839 DOI: 10.2519/jospt.2006.2228]
  - 56 **Musumeci G**, Loreto C, Leonardi R, Castorina S, Giunta S, Carnazza ML, Trovato FM, Pichler K, Weinberg AM. The effects of physical activity on apoptosis and lubricin expression in articular cartilage in rats with glucocorticoid-induced osteoporosis. *J Bone Miner Metab* 2013; **31**: 274-284 [PMID: 23263781 DOI: 10.1007/s00774-012-0414-9]
  - 57 **Pichler K**, Loreto C, Leonardi R, Reuber T, Weinberg AM, Musumeci G. RANKL is downregulated in bone cells by physical activity (treadmill and vibration stimulation training) in rat with glucocorticoid-induced osteoporosis. *Histol Histopathol* 2013; **28**: 1185-1196 [PMID: 23553492]
  - 58 **Musumeci G**, Maria Trovato F, Imbesi R, Castrogiovanni P. Effects of dietary extra-virgin olive oil on oxidative stress resulting from exhaustive exercise in rat skeletal muscle: A morphological study. *Acta Histochem* 2014; **116**: 61-69 [PMID: 23810034]
  - 59 **Musumeci G**, Trovato FM, Pichler K, Weinberg AM, Loreto C, Castrogiovanni P. Extra-virgin olive oil diet and mild physical activity prevent cartilage degeneration in an osteoarthritis model. An “*in vivo*” and “*in vitro*” study on lubricin expression. *J Nutr Biochem* 2013; **24**: 2064-2075 [PMID: 24369033 DOI: 10.1016/j.jnutbio.2013.07.007]

**P- Reviewers:** Fenichel I, Kongtawelert P, Regauer M, van den Bekerom MPJ **S- Editor:** Ma YJ **L- Editor:** A  
**E- Editor:** Lu YJ





## WJO 5<sup>th</sup> Anniversary Special Issues (8): Spine

# Research in spinal surgery: Evaluation and practice of evidence-based medicine

Mark E Oppenlander, Christopher M Maulucci, George M Ghobrial, James S Harrop

Mark E Oppenlander, Christopher M Maulucci, George M Ghobrial, James S Harrop, Department of Neurological Surgery, Thomas Jefferson University Hospital, Philadelphia, PA 19107, United States

Mark E Oppenlander, Division of Neurological Surgery, Barrow Neurological Institute, St. Joseph Hospital and Medical Center, Phoenix, AZ 85003, United States

**Author contributions:** Oppenlander ME designed the research, contributed to data review, drafted the paper; Maulucci CM and Ghobrial GM contributed to data review and drafting of paper; Harrop JS was the consultant supervisor, contributed to review and approval of paper.

**Correspondence to:** James S Harrop, MD, Professor of Neurological Surgery, Department of Neurological Surgery, Thomas Jefferson University, 909 Walnut Street Second Floor, Philadelphia, PA 19107, United States. [james.harrop@jefferson.edu](mailto:james.harrop@jefferson.edu)  
Telephone: +1-215-9557959 Fax: +1-215-5037007

Received: September 29, 2013 Revised: December 19, 2013

Accepted: January 13, 2014

Published online: April 18, 2014

## Abstract

Evidence-based medicine (EBM) is a common concept among medical practitioners, yet unique challenges arise when EBM is applied to spinal surgery. Due to the relative rarity of certain spinal disorders, and a lack of management equipoise, randomized controlled trials may be difficult to execute. Despite this, responsibility rests with spinal surgeons to design high quality studies in order to justify certain treatment modalities. The authors therefore review the tenets of implementing evidence-based research, through the lens of spinal disorders. The process of EBM begins with asking the correct question. An appropriate study is then designed based on the research question. Understanding study designs allows the spinal surgeon to assess the level of evidence provided. Validated outcome measurements allow clinicians to communicate the success of treatment strategies, and will increase the quality of a given study design. Importantly,

one must recognize that the randomized controlled trial is not always the optimal study design for a given research question. Rather, prospective observational cohort studies may be more appropriate in certain circumstances, and would provide superior generalizability. Despite the challenges involved with EBM, it is the future of medicine. These issues surrounding EBM are important for spinal surgeons, as well as health policy makers and editorial boards, to have familiarity.

© 2014 Baishideng Publishing Group Co., Limited. All rights reserved.

**Key words:** Evidence-based medicine; Spinal surgery; Trial design; Research; Methodology

**Core tip:** This paper highlights the intricacies of spinal research. The difficulties of conducting high quality research in spinal surgery are discussed, but the tools for success are outlined. Specifically, the tenets of implementing evidence-based research are provided, along with a discussion of validated outcome measures which will increase the quality of a given study design. Importantly, the randomized controlled trial should not always be considered the best study design for a given research question, and observational cohort studies may be more appropriate in certain circumstances. Ultimately, spinal surgeons are responsible for evidence-based research to justify treatment paradigms.

Oppenlander ME, Maulucci CM, Ghobrial GM, Harrop JS. Research in spinal surgery: Evaluation and practice of evidence-based medicine. *World J Orthop* 2014; 5(2): 89-93 Available from: URL: <http://www.wjgnet.com/2218-5836/full/v5/i2/89.htm>  
DOI: <http://dx.doi.org/10.5312/wjo.v5.i2.89>

## INTRODUCTION

The concept of evidence-based medicine (EBM) assumes

that current medical research, along with individual clinician judgment, can optimally guide clinical decision making to result in the best possible patient outcomes<sup>[1,2]</sup>. While EBM requires the use of best available evidence, multiple challenges may arise in its practical application to spinal surgery. For instance, rare disorders result in small patient numbers and subsequent lower quality data. At the other extreme, randomized controlled trials (RCTs) attempt to generate high quality evidence, yet are hindered by expense and difficulties in study recruitment and conduct.

Despite the challenges involved with EBM, it is the future of medicine<sup>[3,4]</sup>. If spine surgeons do not want poor-quality studies to dictate and limit their clinical decisions, then responsibility rests with this group of practitioners to design high quality studies to justify certain treatment modalities.

This review therefore highlights the tenets of implementing evidence-based research, through the lens of spinal disorders. Techniques of conducting and evaluating EBM are first discussed, followed by a review of pertinent outcome measures in spinal surgery. It is the authors' goal that these basic tools will provide a basis of EBM for the practicing spinal surgeon.

## TECHNIQUES OF EBM

### *Asking the correct question*

Before a study is designed, a research question must be asked. The importance of the research question lies in the fact that it dictates a study's design. Often, the RCT is considered the gold standard of evidence-based medicine, yet the research question may exclude the RCT from feasibility or utility. For example, a question of superiority in treatment protocols, where each treatment has equipoise for the surgeon and patient, is suitable for a RCT. However, a question may best be answered with a prospective cohort design if there are subjective treatment preferences among surgeons, the presence of significant selection biases, or poor generalizability<sup>[3,5]</sup>.

A well-designed and focused research question will not only dictate the study design, but will also aid in literature searches. Instead of turning up hundreds to thousands of citations, a well-defined question will limit the pertinent literature to a manageable number that allows a focused interpretation.

In addition, the research question will permeate through a central theme of the research manuscript. The question should be stated in the introduction of a manuscript, and contain the intervention of study and cohort of interest. Returning to the research question throughout the manuscript will allow reporting of more concise results and a more pertinent discussion.

### *Designing the study*

Once a research question is proposed and a formal review of the literature is performed, the study design is implemented. Table 1 highlights the advantages and disadvantages of various study designs. A case series tracks

patients with a known pathology given similar treatment, and allows assessment of a clinical course based on that treatment. Case series are often retrospective but may be prospective. They are often confounded by selection bias, limiting elucidations of causal relationships. Case series may be improved, however, with well-defined selection criteria and the use of validated outcome measures. For rare spinal disorders, a case series may be the best available evidence.

A case-control study design is a type of observational study, wherein two patient groups with differing outcomes are identified and compared for a supposed causal attribute. They are retrospective in nature and relatively inexpensive. Because of their retrospective nature, however, there is difficulty in obtaining reliable information about a patient's exposure over time. This effectively hinders the ability to make claims of causation.

A cohort study is also observational in nature. It follows a group of patients without a disease in order to determine risks of contracting that condition, or compares two treatment options. A cohort study may be retrospective or prospective in nature. It is beneficial for identifying the natural history of a disease, the risk factors of a disease, or the impact of an intervention. Cohort studies are more expensive and time consuming than a case-control design or a case series, with strict inclusion and exclusion criteria. Prospective cohort studies in particular are considered to yield the most reliable results in observational studies.

A RCT is considered the gold standard for a clinical trial. It is often used to test the effectiveness of a medical or surgical intervention within a well-defined patient population. The intervention is provided to the patient based on a process of randomization, in a blinded or unblinded manner. The RCT offers reliable evidence because it reduces bias and spurious causality. Nonetheless, RCTs are prone to high cost, administrative difficulties, and limited recruitment.

Spine surgeons in particular may struggle with obtaining a high quality RCT because of high crossover rates and low patient recruitment. In addition, it is relatively difficult for surgeons to design a study that randomizes patients to interventions that are typically used in sequence<sup>[3]</sup>. For example, a RCT may be designed to compare operative *vs* non-operative treatment of neck pain. Most surgeons, however, consider failure of non-operative measures as an indication for surgery. Therefore, a patient in this study would need to accept being randomized to a non-operative treatment modality that s/he has already failed. If the concept of equipoise is used in an attempt to circumvent this problem, then surgeons may be relegated to operating on patients without clear operative indications. In this example, a supposed state of equipoise could lead to a surgeon operating on a patient with neck pain who has not failed conservative measures, further confounding results and perhaps leading to poorer surgical outcomes.

Because practical and ethical reasons may prevent the initiation of a RCT, strong observational alternatives are



**Table 1** Types of study design

Design type	Advantages	Disadvantages
Case series	Suitable for rare diseases or new treatments	No comparison group
Case control	Small sample size	Retrospective nature
	Short duration	Presence of confounding
Cohort studies	Evaluates risk factors	Retrospective nature
	Compares two treatments	Presence of confounding
	May be prospective	
Randomized controlled trials	Prospective in nature	Limited generalizability
	Reduce confounding and bias	Potential for low recruitment and high crossover
		High cost and administrative oversight
Systematic review	Provides summation of available literature	Dependent on quality of individual studies

Adapted from Fisher *et al*<sup>[6]</sup>.**Table 2** Levels of evidence

Evidence level	Therapeutic studies: Evaluating results of treatment	Prognostic studies: Evaluating outcome of disease
I	RCT	Prospective study (> 80% follow-up)
	Systematic review of level I RCTs	Systematic review of level I studies
II	Prospective cohort study	Retrospective study
	Poor quality RCT ( <i>e.g.</i> , < 80% follow-up)	Systematic review of level II studies
	Systematic review of level III studies	
III	Case control study	
	Retrospective cohort study	
	Systematic review of level III studies	
IV	Case series	Case series
V	Expert opinion	Expert opinion

Adapted from Wright *et al*<sup>[8]</sup>. RCT: Randomized controlled trial.

needed in spinal research<sup>[2]</sup>. This notion would circumvent the impossibility of randomizing every component of intervention.

Systematic, evidence-based literature reviews provide a summation of the available literature on a topic. This type of study is valuable as a synopsis of previously-reported data, aiding understanding of outcomes, safety, risk factors, and impact of spinal surgery intervention<sup>[6]</sup>. Systemic reviews should be transparent, so that data is presented in an unbiased manner, thus allowing the surgeon to make independent conclusions based on the data. A quantitative synthesis of high quality data is termed a meta-analysis, which may be useful when pooling studies which are individually under-powered to find conclusive results<sup>[7]</sup>.

### Assessing the level of evidence

Based on study design, the level of evidence for an intervention can be assessed (Table 2)<sup>[8]</sup>. RCTs are categorized as level I or II. Cohort studies are level II or III. Case-control studies are level III, and case series are level IV. Expert opinion is considered level V. The level of evidence correlates with certainty of risks and benefits of a given intervention, so that higher levels of evidence (and thus higher quality studies) provide more certainty in their conclusions, and therefore stronger recommendations for treatment.

Although a majority of studies in spinal surgery are of levels III and IV, a select number of studies are of higher level evidence<sup>[9,10]</sup>. Certainly the level of evidence, however, is not the final answer in evaluating the literature. The lack of RCTs in spinal surgery research reflects the complexities and limitations of this study design. In addition, the current system of analyzing levels of evidence ignores whether the study asked the correct question or examined the relevant patient population<sup>[3]</sup>.

## OUTCOME MEASUREMENTS IN SPINE RESEARCH

The use of standardized outcome measurements is important for conducting evidence-based research. The quantification of patient symptoms, ability to perform activities of daily living, and overall health status is necessary to track patient progress as well as to conduct clinical studies. Outcome measurement tools allow clinicians to communicate, in a standardized manner, the success of treatment strategies. However, there is no standardized set of clinical outcome measures for all spine patients<sup>[11]</sup>. Outcome measurements for those with cervical pathology differ from those with lumbar pathology, for example. The questionnaires given to the patient must be carefully selected so as to elicit the most pertinent information in

**Table 3 Outcome tools in spinal surgery**

Topic	Tool	Notes
Pain	VAS	May be used for generalized or localized pain
Disability	ODI, NDI	Evaluates multiple life experiences The NDI is an adaptation of ODI for patients with neck disability
Myelopathy	JOA, mJOA	Evaluates motor function, sensation, and bladder function
Quality of life	SRS-22, EQ-5D-5L, SF-36	SRS-22 developed for patients with spinal deformity

VAS: Visual analog scale; NDI: Neck disability index; ODI: Oswestry disability index; JOA: Japanese Orthopaedic Association; mJOA: Modified JOA; SRS-22: Scoliosis Research Society-22; SF-36: Short Form-36.

the most efficient manner. It is important to recognize that providing an excessive number of questionnaires will decrease patient compliance. The aim of this section is to highlight the outcome measurement tools commonly used in spinal surgery research (Table 3).

The Oswestry disability index (ODI) is the most common questionnaire utilized to evaluate the physical symptoms of patients with low back pain, with an emphasis on quality of life<sup>[12]</sup>. This questionnaire evaluates ten categories: pain, personal care, lifting, walking, sitting, standing, sleeping, sex life, social life, and traveling. There are six answers available per question with point values of zero to five; the maximum score is fifty. A quantification of patient disability may be calculated by dividing the point total by fifty then multiplying by one hundred percent. Those with 0%-20% disability are considered minimally disabled. A score of 21%-40% is moderate disability, 41%-60% is severe, 61%-80% is crippled. Those with scores of 81%-100% are bed bound. A change of 4 points is the minimum difference that can be considered clinically significant. A 15 point change, though, is what is considered significant for patients undergoing spinal fusion.

The neck disability index (NDI) represents a modification of the ODI for patients with cervical spine pain<sup>[13]</sup>. The questions elicit information about activities such as concentration and reading which can be affected by cervical pain. Soft tissue injury can also lead to headache, which is also evaluated by the NDI. The scoring system is the same as that of the ODI.

The visual analog scale is a measurement instrument which quantifies patient subjective pain<sup>[14]</sup>. It consists of a 10 centimeter line with one end representing no pain and the other end the worst pain possible. The patient indicates where on the line his or her pain is in relation to these two extremes. This outcome measure can be used to quantify generalized pain or any specific type of pain (back, leg, *etc.*).

Patients with cervical myelopathy may suffer from a constellation of disabling symptoms, but pain may be a relatively minor issue. The Japanese Orthopaedic Association (JOA) scale is an objective assessment of upper and lower extremity motor function, sensation, and bladder function<sup>[15]</sup>. The highest possible score is 17. The JOA is specific for patients who utilize chopsticks to feed themselves. For those who do not, the modified JOA (mJOA)

has been developed<sup>[16,17]</sup>; the questionnaire has replaced the word “chopsticks” with “knife and fork”. The mJOA is therefore more often used in the United States compared to the JOA. In addition, the mJOA involves a highest score of 18, rather than the JOA’s high score of 17<sup>[15,17]</sup>.

Those with spinal deformities, in particular idiopathic scoliosis, have a slightly different set of concerns and health issues than those with degenerative conditions. These patients are typically adolescents or young adults. The Scoliosis Research Society-22 (SRS-22) questionnaire targets 5 domains: physical function, pain, self image, mental health, and satisfaction with management of scoliosis<sup>[18]</sup>. Each of the 22 questions contains 5 answers with point values from 1 to 5, with 5 being the best. The mean scores from each of the 5 categories are averaged to produce a single value. Studies indicate that significant point differences for the SRS-22 are: pain 0.6, function 0.8, self image 0.5, mental health 0.4, average sum score 0.5, and raw sum score 6.8.

The EQ-5D-5L is a questionnaire that investigates patient quality of life<sup>[19]</sup>. It consists of 2 forms. The first assesses 5 dimensions: mobility, self-care, usual activities, pain/discomfort, and anxiety/depression. Each dimension is associated with 5 statements; the patient selects the statement that most correlates with their condition. No point values are assigned to each statement. The second form consists of a 20 cm vertical line with endpoints labeled “the best health you can imagine” and “the worst health you can imagine.” Patients are asked to indicate where on the line they believe their present state of health to be. Given that no numerical score is calculated from the 5 questions, the data can be presented in a variety of formats.

Similar to the EQ-5D-5L is the Short Form-36 (SF-36)<sup>[20,21]</sup>. This is a health survey analyzing 2 general domains: physical health and mental health. There are 36 questions and 5 possible responses per question. Physical health is divided into physical functioning, physical role functioning, bodily pain, and general health. Mental health is divided into vitality, social functioning, emotional role functioning, and mental condition. The SF-36 consists of eight scaled scores, which are the weighted sums of the questions in each section. Each scale is directly transformed into a 0-100 scale on the assumption that each question carries equal weight.



Ultimately, an outcome assessment tool must be reliable, reproducible, specific to the outcome of interest, yet brief enough to promote compliance. For these purposes, an array of well-validated standardized questionnaires is available.

## CONCLUSION

Evidence-based research in spinal surgery has received a growing amount of attention, not only from surgeons and scientists, but from government regulators and the lay press. With continued pressure to produce high quality evidence for the success of spinal interventions, one must recognize that the RCT is not always the optimal study design for a given research question. Rather, prospective observational cohort studies may be more appropriate in certain circumstances, and would provide superior generalizability. In addition, case series and case-control study designs have their own utility, particularly in studying rare diseases and new treatment options. The use of validated outcome measurements will increase the quality of a given study design. Finally, evaluating spinal research with levels of evidence, I - V, allows for an objective measurement of study quality, yet this system does not account for whether the correct question was asked or if the correct patient population was studied. These issues surrounding EBM are important for spinal surgeons, as well as health policy makers and editorial boards, to have familiarity.

## REFERENCES

- 1 **Fisher CG**, Vaccaro AR. Improving the best available evidence component of evidence-based medicine: it's all in the question! *Spine* (Phila Pa 1976) 2013; **38**: E28-E29 [PMID: 23026868 DOI: 10.1097/BRS.0b013e318275cbd7]
- 2 **Croft P**, Malmivaara A, van Tulder M. The pros and cons of evidence-based medicine. *Spine* (Phila Pa 1976) 2011; **36**: E1121-E1125 [PMID: 21629165 DOI: 10.1097/BRS.0b013e318223ae4c]
- 3 **Glassman SD**, Branch CL. Evidence-based medicine: raising the bar. *Spine J* 2007; **7**: 513-515 [PMID: 17602890 DOI: 10.1016/j.spinee.2007.04.011]
- 4 **Vaccaro AR**, Fisher CG. "Help, I need guidance in how to manage my patients but I am so confused": evidence-based medicine to the rescue? *Spine* (Phila Pa 1976) 2012; **37**: E873-E874 [PMID: 22751142 DOI: 10.1097/BRS.0b013e3182454dd3]
- 5 **Fisher CG**, Wood KB. Introduction to and techniques of evidence-based medicine. *Spine* (Phila Pa 1976) 2007; **32**: S66-S72 [PMID: 17728684 DOI: 10.1097/BRS.0b013e318145308d]
- 6 **Dettori JR**, Norvell DC, Dekutoski M, Fisher C, Chapman JR. Methods for the systematic reviews on patient safety during spine surgery. *Spine* (Phila Pa 1976) 2010; **35**: S22-S27 [PMID: 20407348 DOI: 10.1097/BRS.0b013e3181d70494]
- 7 **Jacobs WC**, Kruijt MC, Verbout AJ, Oner FC. Spine surgery research: on and beyond current strategies. *Spine J* 2012; **12**: 706-713 [PMID: 23021034 DOI: 10.1016/j.spinee.2012.08.424]
- 8 **Wright JG**, Swiontkowski MF, Heckman JD. Introducing levels of evidence to the journal. *J Bone Joint Surg Am* 2003; **85-A**: 1-3 [PMID: 12533564]
- 9 **Weinstein JN**, Tosteson TD, Lurie JD, Tosteson AN, Hanscom B, Skinner JS, Abdu WA, Hilibrand AS, Boden SD, Deyo RA. Surgical vs nonoperative treatment for lumbar disk herniation: the Spine Patient Outcomes Research Trial (SPORT): a randomized trial. *JAMA* 2006; **296**: 2441-2450 [PMID: 17119140 DOI: 10.1001/jama.296.20.2441]
- 10 **Allen RT**, Rihn JA, Glassman SD, Currier B, Albert TJ, Phillips FM. An evidence-based approach to spine surgery. *Am J Med Qual* 2009; **24**: 15S-24S [PMID: 19890181 DOI: 10.1177/1062860609348743]
- 11 **Deyo RA**, Battie M, Beurskens AJ, Bombardier C, Croft P, Koes B, Malmivaara A, Roland M, Von Korf M, Waddell G. Outcome measures for low back pain research. A proposal for standardized use. *Spine* (Phila Pa 1976) 1998; **23**: 2003-2013 [PMID: 9779535 DOI: 10.1097/00007632-199809150-00018]
- 12 **Fairbank JC**, Pynsent PB. The Oswestry Disability Index. *Spine* (Phila Pa 1976) 2000; **25**: 2940-2952; discussion 2952 [PMID: 11074683]
- 13 **Vernon H**, Mior S. The Neck Disability Index: a study of reliability and validity. *J Manipulative Physiol Ther* 1991; **14**: 409-415 [PMID: 1834753]
- 14 **Scott J**, Huskisson EC. Graphic representation of pain. *Pain* 1976; **2**: 175-184 [PMID: 1026900 DOI: 10.1016/0304-3959(76)90113-5]
- 15 **Yonenobu K**, Abumi K, Nagata K, Taketomi E, Ueyama K. Interobserver and intraobserver reliability of the Japanese orthopaedic association scoring system for evaluation of cervical compression myelopathy. *Spine* (Phila Pa 1976) 2001; **26**: 1890-1894; discussion 1895 [PMID: 11568701 DOI: 10.1097/00007632-200109010-00014]
- 16 **Chiles BW**, Leonard MA, Choudhri HF, Cooper PR. Cervical spondylotic myelopathy: patterns of neurological deficit and recovery after anterior cervical decompression. *Neurosurgery* 1999; **44**: 762-769; discussion 762-769 [PMID: 10201301 DOI: 10.1097/00006123-199904000-00041]
- 17 **Benzel EC**, Lancon J, Kesterson L, Hadden T. Cervical laminectomy and dentate ligament section for cervical spondylotic myelopathy. *J Spinal Disord* 1991; **4**: 286-295 [PMID: 1802159 DOI: 10.1097/00002517-199109000-00005]
- 18 **Bagó J**, Pérez-Gruoso FJ, Les E, Hernández P, Pellisé F. Minimal important differences of the SRS-22 Patient Questionnaire following surgical treatment of idiopathic scoliosis. *Eur Spine J* 2009; **18**: 1898-1904 [PMID: 19533179 DOI: 10.1007/s00586-009-1066-x]
- 19 **Brooks R**. EuroQol: the current state of play. *Health Policy* 1996; **37**: 53-72 [PMID: 10158943 DOI: 10.1016/0168-8510(96)00822-6]
- 20 **Brazier J**, Jones N, Kind P. Testing the validity of the Euroqol and comparing it with the SF-36 health survey questionnaire. *Qual Life Res* 1993; **2**: 169-180 [PMID: 8401453 DOI: 10.1007/BF00435221]
- 21 **Haley SM**, McHorney CA, Ware JE. Evaluation of the MOS SF-36 physical functioning scale (PF-10): I. Unidimensionality and reproducibility of the Rasch item scale. *J Clin Epidemiol* 1994; **47**: 671-684 [PMID: 7722580 DOI: 10.1016/0895-4356(94)90215-1]

**P- Reviewers:** Kaneyama S, Kasai Y, Park P, Teli MGA  
**S- Editor:** Zhai HH **L- Editor:** A **E- Editor:** Lu YJ



WJO 5<sup>th</sup> Anniversary Special Issues (8): Spine

## Modern posterior screw techniques in the pediatric cervical spine

Daniel J Hedequist

Daniel J Hedequist, Department of Orthopedic Surgery, Children's Hospital Boston/Harvard Medical School, Boston, MA 02115, United States

Author contributions: Hedequist DJ solely contributed to this paper.

Correspondence to: Daniel J Hedequist, MD, Department of Orthopedic Surgery, Children's Hospital Boston/Harvard Medical School, 300 Longwood Avenue, Boston, MA 02115, United States. [daniel.hedequist@childrens.harvard.edu](mailto:daniel.hedequist@childrens.harvard.edu)  
Telephone: +1-617-3554847 Fax: +1-617-3554847

Received: November 13, 2013 Revised: January 16, 2014

Accepted: March 17, 2014

Published online: April 18, 2014

### Abstract

Treatment of children with cervical spine disorders requiring fusion is a challenging endeavor for a variety of reasons. The size of the patients, the corresponding abnormal bony anatomy, the inherent ligamentous laxity of children, and the relative rarity of the disorders all play a part in difficulty of treatment. The benefits of modern posterior cervical instrumentation in children, defined as rigid screw-rod systems, have been shown to be many including: improved arthrodesis rates, diminished times in halo-vest immobilization, and improved reduction of deformities. The anatomy of children and the corresponding pathology seen frequently is at the upper cervical spine and craniocervical junction given the relatively large head size of children and the horizontal facets at these regions predisposing them to instability or deformity. Posterior screw fixation, while challenging, allows for a rigid base to allow for fusion in these upper cervical areas which are predisposed to pseudarthrosis with non-rigid fixation. A thorough understanding of the anatomy of the cervical spine, the morphology of the cervical spine, and the available screw options is paramount for placing posterior cervical screws in children. The purpose of this review is to discuss both the anatomical and clinical descriptions re-

lated to posterior screw placement in the cervical spine in children.

© 2014 Baishideng Publishing Group Co., Limited. All rights reserved.

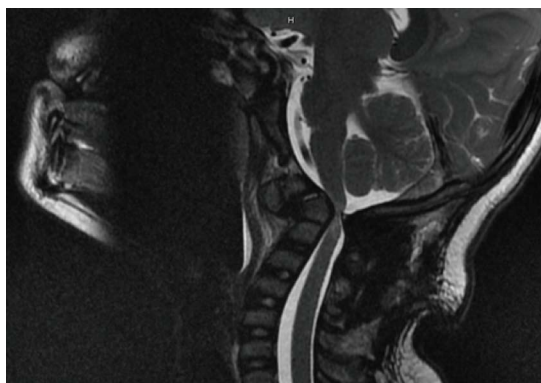
**Key words:** Pediatric cervical spine; Cervical screw fixation; Posterior cervical techniques

**Core tip:** This paper reviews the techniques used for modern posterior screw fixation of the pediatric cervical spine. The preoperative considerations, necessary studies, and surgical techniques are reviewed in order to educate the reader on the use of modern screw fixation in the pediatric cervical spine. Upper cervical fixation techniques as well as lateral mass screw fixation in the subaxial spine are discussed.

Hedequist DJ. Modern posterior screw techniques in the pediatric cervical spine. *World J Orthop* 2014; 5(2): 94-99 Available from: URL: <http://www.wjgnet.com/2218-5836/full/v5/i2/94.htm> DOI: <http://dx.doi.org/10.5312/wjo.v5.i2.94>

### PREOPERATIVE CONSIDERATIONS

The standard preoperative work-up of any child undergoing surgical treatment for a cervical spine problem will include plain radiographs, magnetic resonance imaging, and computed tomography scanning. Plain radiographs include anterior-posterior and lateral views, as well as flexion-extension lateral views of the cervical spine. The use of magnetic resonance imaging (MRI) is important as it gives detail oriented information regarding the spinal cord, neuroforamen, and position of the vertebral artery. Areas of compression are readily visualized as well as cord signal changes which are important to have as a baseline in patients with instability or neurologic findings



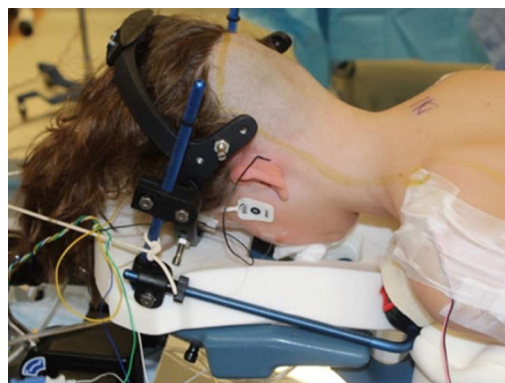
**Figure 1** Magnetic resonance imaging showing severe cord compression at the craniocervical junction in a 6 year-old child with instability and myelopathy due to previous failed fusion for atlanto-axial instability.

(Figure 1).

Computed tomography (CT) scanning with fine cut images is important as it gives concrete information regarding the bony anatomy as well as the course of the vertebral artery. Three-dimensional reconstructions are of paramount importance in cases of upper cervical instrumentation as it gives the surgeon a complete understanding of the course of the vertebral artery which is mandatory with upper cervical screw placement. The standard use of CT angiography or MR angiography is not needed unless either significant congenital bony malformations are present or high grade instability is present with concern regarding the course of the vertebral artery. We have also found in some cases of tumor encasement that angiography is helpful to define the exact location of the vertebral artery as well as the patency of the vertebral artery.

## ANESTHESIA AND POSITIONING CONSIDERATIONS

Depending on the reason that cervical surgery is performed fiberoptic techniques may be required for intubation or nasal intubation may be required. Frequently instability is present requiring immobilization during airway placement and having an anesthesiologist present who is experienced in difficult airways is paramount to patient safety. The use of a halo-vest for positioning or Gardner-wells tongs for positioning is of great importance to secure the cranium and allow for adequate fluoroscopic visualization. In the majority of patients I place the halo crown and attach it to a vest and then turn the patient to prone positioning. The posterior aspect of the vest can then be removed for the operation (Figure 2). This is important for a variety of reasons, the first being complete immobilization of the head and neck during positioning and turning which is the safest way to turn when a patient is completely relaxed under anesthesia. Second, placing the patient in a halo crown and vest also allows me to afford reduction of deformities and to place the skull in the appropriate position in order to avoid craniocervical



**Figure 2** Clinical photo of a 10 year-old child in prone positioning with halo ring and anterior portion of vest attached. Note the alignment of the head and absence of pressure on the eyes or face.

fusions done in misalignment. Finally, if the patient is going to stay in a vest then at the end of the operation the posterior vest can be added and the patient safely turned and then extubated.

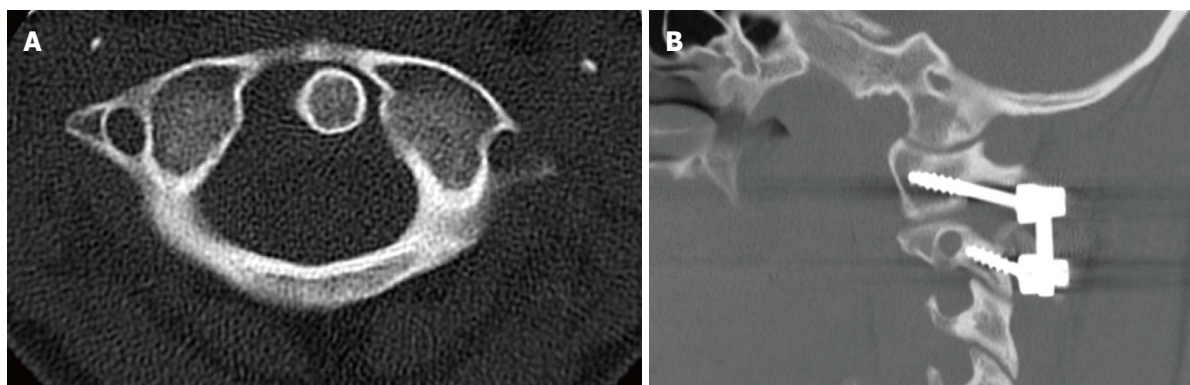
The use of neurologic monitoring is required for all pediatric patients undergoing cervical instrumentation and fusion. The standard for all patients is motor-evoked monitoring, sensory monitoring, as well as EMG monitoring of the upper limb. Anesthetic agents should be used which don't interfere with the ability to obtain stable and reliable monitoring.

## C1 LATERAL MASS FIXATION

Fixation at C1 in the past has traditionally been with sublaminar wiring underneath the arch of the atlas, which is inherently not dangerous or technically difficult given the space available for the cord at this level. However, wiring or cable grafting is problematic both biomechanically and from a pathologic standpoint. C1 wiring is inherently not stable in rotation which is problematic given the articulation of C1 with both the occiput and C2 allows for the majority of cervical rotation. From a clinical standpoint, the posterior ring of C1 frequently requires removal in cases where decompression is required and then wiring is not an option. These factors have led to the anatomical studies of the lateral mass of C1 to determine if screw fixation is feasible, and if so then what are the anatomical constraints<sup>[1-3]</sup>.

The lateral mass of C1 is a quadrilateral structure of bone lying anterolateral to the spinal cord and in close relationship to the vertebral artery, which lies in the anterolateral confines of the lateral mass. The surgical exposure of the lateral mass entry point is challenging for a variety of reasons. The entry point of the lateral mass screws requires following the posterior arch of C1 surgically down to the entry point into the lateral mass (Figure 3A). This can be done by electrocautery dissection staying on the inferior aspect of the posterior arch of C1 as the vertebral artery lies on the superior aspect of the ring of C1 as it exits from the skull base. Classically the teaching had





**Figure 3 C1 lateral mass fixation.** A: Axial computed tomography (CT) cut through the atlas. Note the lateral masses and the relationship of the C1 arch meeting the lateral masses which are landmarks for correct starting points for lateral mass screws; B: Sagittal cut of a CT scan in a 14 year-old patient who has underwent C1-C2 arthrodesis with C1-C2 screw rod construct for an odontoid non-union. Note the starting position of the C1 lateral mass screw inferior to the bony arch of C1. The outline of the vertebral artery can be seen on the superior aspect of the C1 arch.

been the vertebral artery is at risk 1.5 cm from the midline, this has never been validated in children and is not a reliable rule in pathologic cases. Nevertheless, the current recommendation would be to be aware of the position of the vertebral artery laterally on the superior aspect of C1 and if need be a preoperative CT angiography study is helpful, especially with congenital deformities. The ring of C1 gradually turns away and into the lateral mass of C1 and this region needs to be dissected out with meticulous attention to the venous plexus, which is diffuse and engulfs this region. Aggressive bipolar cautery of these venous bleeders prophylactically will make exposure of the entry point easier. The C2 nerve root also is encountered running below the arch of C1 and needs to be identified to find the lateral mass starting point. Variation exists in opinion regarding the need sacrifice the root of C2 for better exposure<sup>[4]</sup>. I have found this not to be required for adequate exposure or for safe screw placement.

The ideal starting point of C1 screws can be found by studying the preoperative CT scan of the patient, however in all cases the screw starting point remains underneath the arch of C1, although occasionally the undersurface of the arch where it meets the bony lateral mass needs to be burred away (Figure 3B). The starting point is usually in line where the arch meets the lateral mass, it is never lateral to the arch and the medial border is easily identified with a freer. The spinal cord is not at risk with this screw given the entry point is anterolateral and usually lies at the anterior-posterior midpoint of the cord.

The C1 lateral mass usually allows for screw placement even in the youngest of pediatric patients. In a recent series of patients as young as two years of age, CT evaluation revealed that the mean length available for the lateral mass screw was greater than 15 mm and the mean medial-lateral dimensions were greater than 7 mm which would allow for safe placement in all patients of a 3.5 mm screw<sup>[2]</sup>. The screw trajectory was evaluated in another series of pediatric patients with CT scans and confirmed from an optimal starting point the ideal screw trajectory would be medially angled 16 degrees and could be placed to a depth of 20 mm<sup>[1]</sup>. In that study, the place-

ment of screws was deemed feasible in 151/152 lateral masses.

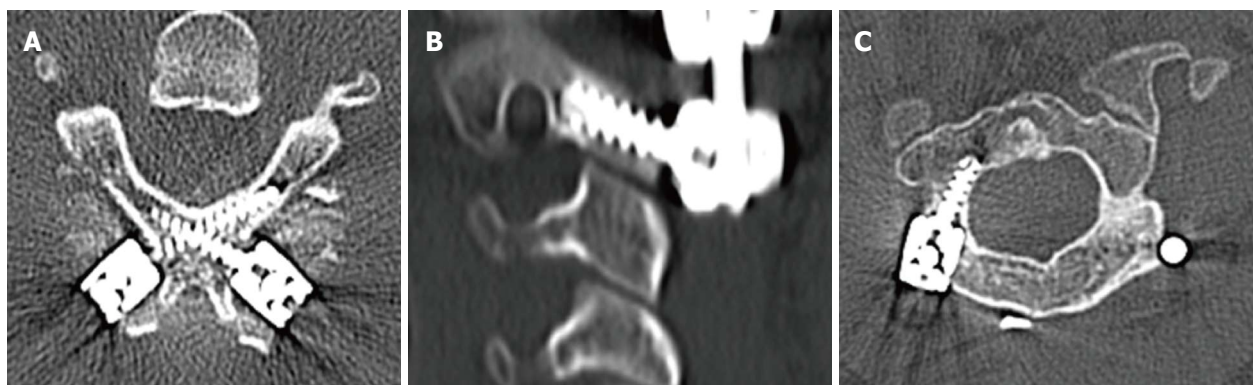Clinically, the anatomic feasibility found in CT studies has been shown to be a reliable indicator of anatomy in children. Two recent series looking specifically at screw placement into C1 in pediatric patients documented successful screw placement with no intraoperative complications and uneventful fusion for a variety of pediatric pathologic conditions<sup>[5,6]</sup>.

## C2 SCREW FIXATION

The axis plays a significant role in the management of cervical spine problems in children requiring instrumentation and fusion. It can be either the base of a cranio-cervical fusion; it may be coupled with the atlas in cases of atlanto-axial instability, or may be the top of a mid-level fusion. Many screw options exist for the axis and are preferable to subaxial cabling as the space available for the cord is much less at the axis rendering sub laminar placement of wires dangerous and the inherent biomechanical weakness of cabling. Screw fixation into the axis may be divided into three separate screw types: pedicle, pars, and intralaminar. The placement of which screw is dependent on a variety of factors which may be seen on the preoperative CT scanning, notably the width of the bony channels and the position of the vertebral artery<sup>[7]</sup>.

The C2 spinous process is used as a landmark in the upper cervical spine and can be used as the entry point for intralaminar screws. Intralaminar screws at C2 have been shown to be effective for rigidity of constructs in biomechanical studies<sup>[8]</sup>. The entry point for C2 laminar screws is on the contralateral side of the spinous process and needs to be placed either caudal or rostral in the spinous process so that crossing screws can be placed (Figure 4A). The dorsal aspect of the lamina is exposed the same for all cervical fusions involving the axis. A starting point on the contralateral side of the spinous process is made using a burr and then the lamina is annulated using an awl. Looking at the dorsal lamina easily sees the rostral-caudal orientation. The avoidance of penetrating the





**Figure 4 C2 screw fixation.** A: Axial cut computed tomography (CT) scan of intralaminar screw placement at C2. The starting point on the spinous process can be seen as well as the space available for screws; B: Sagittal cut CT of a patient who underwent instrumentation with C2 pars screws. Note the relationship of the vertebral artery in this patient and the need for shorter screw placement; C: Axial CT demonstrating the medial orientation of a C2 pedicle screw with the spinal canal medial and the vertebral artery anterior and lateral..

ventral lamina and spinal canal can be done by placing a freer *via* blunt dissection under the ventral lamina as a landmark to avoid misguided trajectory. Screw length can be estimated by the preoperative studies of the presumed screw tract.

CT analysis of the upper cervical vertebra has shown that the lamina is able to accept 3.5 mm screws in most patients. A recent tomographic study of children revealed screw lengths measured on CT to be around a mean of 20 mm with the majority of lamina having a bony channel able to withstand screw placement<sup>[2]</sup>. Clinically, the placement of laminar screws has been shown to be safe and efficacious and the decision regarding intralaminar screw placement can be determined with preoperative CT in all patients<sup>[7,9,10]</sup>. The complication of canal breach has not been reported in multiple clinical studies regarding screw placement in children<sup>[5,7]</sup>.

There is variability in the terminology of C2 screws placed in the pars/isthmus/pedicle. Two separate screw paths exist which have been described, each with different starting points and risks associated with their trajectory. The pars and pedicle are intertwined in a shared mass of bone in the atlas, which needs to be directly visualized during surgical dissection. During dissection as the lamina is followed down laterally the isthmus of C2 can then be followed going superiorly and medially. The dissection of the isthmus is paramount for defining safe screw trajectory as the dorsal and medial part of the isthmus is readily dissected aiding in direct visualization in screw path. The dissection of the isthmus must be done with bipolar cautery to avoid bleeding from the venous plexus, which engulfs the C1-C2 posterior bony complex. The medial aspect of isthmus once dissected can be used to guide screw trajectory and avoid unwanted canal penetration, placing a freer on the medial side will help directly visualize the screw path. Placement of C2 screws can be done with the determination of a pedicle screw or a pars screw. Pars screws are done with a starting point more caudal and just above the C2-C3 facet in the midline. The medial-lateral determination is done by using

the medial dissected out isthmus as the landmark and the lateral trajectory is done under fluoroscopic guidance using the dorsal isthmus as a landmark as well. The length if the pars screw is directly determined by the course of the vertebral artery as well as by the C1-C2 articulation (Figure 4B). C2 pedicle screws share the same isthmus of bone but the starting point is more superior and lateral than the pars screws. The screw trajectory is more medially directed and headed into the C2 body, placing the canal at risk unless dissection has identified the medial pars (Figure 4C).

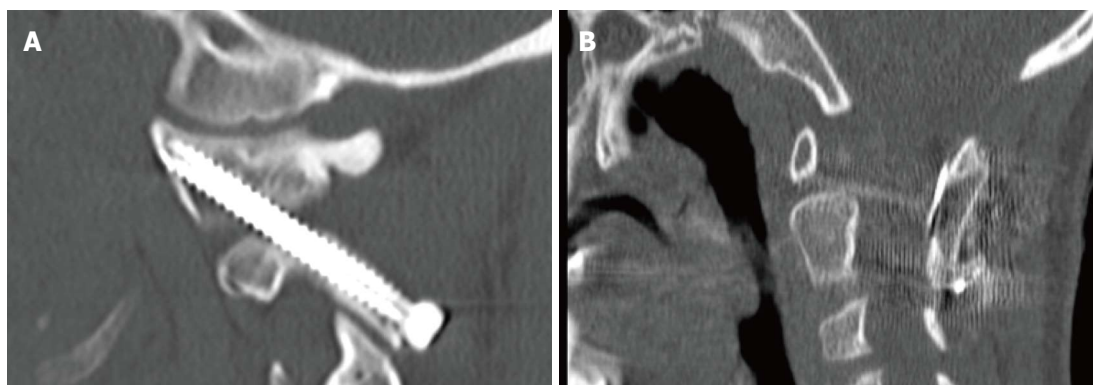
The morphometric studies regarding C2 screws are not entirely clear regarding the variation of pedicle versus pars, but can be interpreted regarding the shared isthmus of bone necessary for screw placement. In a morphometric study of children less than six years of age the mean width of the pedicle measured on CT scan was greater than 3.5 mm and the mean pedicle length was greater than 17 mm<sup>[2]</sup>.

Multiple clinical studies exist regarding the use of pars/pedicle screws in children. While not entirely clear of the separation of pars/pedicle screws it is clear that screws can be placed in the vast majority of patients without injury to the vertebral artery or malposition of screws<sup>[5-7]</sup>. These clinical studies show that rigid screw fixation either through pars/pedicle or intralaminar screws are possible in almost all patients and serves as an excellent and reliable fixation point in pediatric deformity surgery.

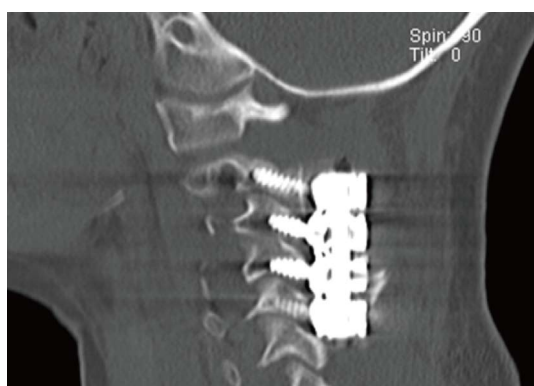
## C1-C2 TRANSARTICULAR SCREWS

Placement of C1-C2 transarticular screws remains a powerful yet challenging technique of fixation. Classically, these screws are placed for C1-C2 instability but may be placed as a base for craniocervical constructs. The challenges of screw placement make dissection of the C2 isthmus as well as C1-C2 joint mandatory for safe screw placement.

The placement of transarticular screws demands a



**Figure 5 C1-C2 transarticular screws.** A: Sagittal computed tomography (CT) of a fully contained and well placed transarticular screw in a 10 year-old male with Down's syndrome and os odontoideum; B: Sagittal CT cut demonstrating the placement of a structural iliac crest graft cable grafted in between C1 and C2 which supplemented transarticular screws in an 8 year-old patient with C1-C2 instability.



**Figure 6 Sagittal computed tomography cut of a 5 year-old patient who underwent lateral mass screw fixation after tumor reconstruction.**

complete understanding of the course of the vertebral artery both in its relationship to the axis and in its relationship to C1. The course of the vertebral artery is anomalous in up to 25% of patients in clinical studies where screw placement would be beneficial<sup>[11]</sup>. The most common problematic course in relationship to C2 is either a medially deviated course where the ideal trajectory of the screw from the isthmus of C2 into the C1 lateral mass does not exist or in a sagittal plane abnormality where the vertebral artery is high riding and lead to a small isthmus negating any potential screw placement<sup>[7]</sup>. The position of the vertebral artery in relationship to the C1 lateral mass is also of paramount importance screw placement must end up in the lateral mass after crossing the joint.

Morphometric studies of upper cervical anatomy suggest that a minority of patients less than six have anatomy suitable for transarticular screws given either the size of the C2 isthmus or the course of the vertebral artery<sup>[2]</sup>. Clinical studies have shown that even in younger patients screws may be safely placed if the preoperative imaging suggests anatomy, which allows for safe screw placement<sup>[12,13]</sup>.

Adequate visualization of the C2 isthmus is paramount to safe screw placement and is done as described

above for pars screws. The C1-C2 joint must also be in a reduced position and accessible by direct fell *via* a freer elevator. We have used a cannulated screw system at our institution and once the guide wire is placed thru C2 into the joint we have made it a step of the procedure then to adequately feel with a freer the guide wire in a good position as well as using confirmatory biplanar fluoroscopy. There is minimal room for error using transarticular screws so guide wire placement in a correct position and must be done by C2 pars visualization, palpation of the guide wire in the C1-C2 joint, and confirmation of correct guide wire placement on AP and lateral fluoroscopy. Once adequate guide wire placement has been done then screws can be placed after measuring, drilling, and tapping (Figure 5A).

Placement of a unilateral C1-C2 transarticular screw is occasionally needed if the anatomy of the vertebral artery on both sides is not symmetrical. Biomechanically this has been shown to be reasonable fixation<sup>[13]</sup>. We have made it a habit to place autogenous structural iliac crest graft between C1 and C2 in cases where the ring of C1 is present in order to augment the posterolateral gutter fusion. Typically we have place a horseshoe shaped graft and secured it *via* cables placed underneath the ring of C1 and through the spinous process of C2 (Figure 5B).

Clinically, transarticular screws have been safely used in children who have safe anatomy on preoperative CT scans. Brockmeyer reviewed his series of patients treated with transarticular screws and found safe screw placement in children younger than age four<sup>[13,14]</sup>.

## SUBAXIAL LATERAL MASS SCREWS

The use of lateral mass screws has been studied in children and shown to be safe and efficacious if the preoperative template on CT scanning is favorable<sup>[15,16]</sup>. The lateral mass is a quadrangular structure of bone, which has a medial border of the spinal canal and an anterior border the vertebral artery. Multiple techniques exist for placement of screws in the lateral mass with variation in the starting point and variation in both the laterally

directed and the cranially directed angle. I have used the modified technique of dividing the lateral mass into a box with the facet above and below being the cranial and caudal borders, the lateral edge of bone being the lateral border and the medial border being where the lamina meets the facet. The starting point for screw placement is 1 mm inferior and 1mm medial to the center of this box. The angulation is approximately 15 degrees laterally and the cranial angulation is dictated by the lateral fluoroscopic views. Fluoroscopy is necessary in children given the small size of the lateral mass does not allow for false drill passage given this will not allow for redirection.

At our institution we have studied the use in lateral mass screws for a variety of pathologic conditions in children. Post-operative computed tomography scanning has shown complete screw containment in all cases and there have been no vertebral artery injuries or post-operative nerve deficits<sup>[15,16]</sup>. Standard screw diameter is 3.5 mm and we have found it useful to have screws as low as 8 mm in length to avoid anterior penetration into the vertebral artery by a long screw. We have placed subaxial screws in children as young as four years of age, although the indications for this age group are rare given most pathologic conditions in younger children involve the craniocervical junction and the upper cervical spine (Figure 6). We have not used cervical pedicle screws in pediatric patients given the cadaveric anatomical studies showing the size of the pedicle is not adequate for screw placement in the majority of patients<sup>[17]</sup>.

## CONCLUSION

Surgeons taking care of children with cervical spine abnormalities will encounter a wide variety of pathologic conditions requiring fusion. Stability of the spine, reduction of deformities, protection of the spinal cord, and enhanced fusion all are aided by stability obtained with modern instrumentation using screw-rod constructs. These constructs have been shown to be both feasible in morphometric studies as well as safe in clinical studies. Placement of screws demands a complete understanding of the preoperative anatomy which can be done by adequate preoperative studies. Finally, given the small nature of the patients meticulous surgical dissection is paramount to safe screw placement. The modern techniques will lead to an improved rate of arthrodesis while minimizing any time needed in external immobilization which ultimately leads to better patient/family satisfaction.

## REFERENCES

- 1 **Chamoun RB**, Whitehead WE, Curry DJ, Luerssen TG, Jea A. Computed tomography morphometric analysis for C-1 lateral mass screw placement in children. Clinical article. *J Neurosurg Pediatr* 2009; **3**: 20-23 [PMID: 19119899 DOI: 10.3171/2008.10.PEDS08224]
- 2 **Geck MJ**, Truumees E, Hawthorne D, Singh D, Stokes JK, Flynn A. Feasibility of Rigid Upper Cervical Instrumentation in Children: Tomographic Analysis of Children Aged 2 to 6. *J Spinal Disord Tech* 2013; Epub ahead of print [PMID: 23563351 DOI: 10.1097/BSD.0b013e318291ce46]
- 3 **Harms J**, Melcher RP. Posterior C1-C2 fusion with polyaxial screw and rod fixation. *Spine (Phila Pa 1976)* 2001; **26**: 2467-2471 [PMID: 11707712]
- 4 **Patel AJ**, Gressot LV, Boatey J, Hwang SW, Brayton A, Jea A. Routine sectioning of the C2 nerve root and ganglion for C1 lateral mass screw placement in children: surgical and functional outcomes. *Childs Nerv Syst* 2013; **29**: 93-97 [PMID: 23014949 DOI: 10.1007/s00381-012-1899-1]
- 5 **Haque A**, Price AV, Sklar FH, Swift DM, Weprin BE, Sacco DJ. Screw fixation of the upper cervical spine in the pediatric population. Clinical article. *J Neurosurg Pediatr* 2009; **3**: 529-533 [PMID: 19485741 DOI: 10.3171/2009.2.PEDS08149]
- 6 **Desai R**, Stevenson CB, Crawford AH, Durrani AA, Mangano FT. C-1 lateral mass screw fixation in children with atlantoaxial instability: case series and technical report. *J Spinal Disord Tech* 2010; **23**: 474-479 [PMID: 20124915 DOI: 10.1097/BSD.0b013e3181bf9f24]
- 7 **Hedequist D**, Proctor M. Screw fixation to C2 in children: a case series and technical report. *J Pediatr Orthop* 2009; **29**: 21-25 [PMID: 19098639 DOI: 10.1097/BPO.0b013e3181924367]
- 8 **Lehman RA**, Dmitriev AE, Helgeson MD, Sasso RC, Kuklo TR, Riew KD. Salvage of C2 pedicle and pars screws using the intralaminar technique: a biomechanical analysis. *Spine (Phila Pa 1976)* 2008; **33**: 960-965 [PMID: 18427316 DOI: 10.1097/BRS.0b013e31816c915b]
- 9 **Lehman RA**, Sasso RC, Helgeson MD, Dmitriev AE, Gill NW, Rosner MR, Riew KD. Accuracy of intraoperative plain radiographs to detect violations of intralaminar screws placed into the C2 vertebrae: a reliability study. *Spine (Phila Pa 1976)* 2007; **32**: 3036-3040 [PMID: 18091498 DOI: 10.1097/BRS.0b013e31815cdab9]
- 10 **Chern JJ**, Chamoun RB, Whitehead WE, Curry DJ, Luerssen TG, Jea A. Computed tomography morphometric analysis for axial and subaxial translaminar screw placement in the pediatric cervical spine. *J Neurosurg Pediatr* 2009; **3**: 121-128 [PMID: 19278311 DOI: 10.3171/2008.11.PEDS08277]
- 11 **Anderson RC**, Ragel BT, Mocco J, Bohman LE, Brockmeyer DL. Selection of a rigid internal fixation construct for stabilization at the craniocervical junction in pediatric patients. *J Neurosurg* 2007; **107**: 36-42 [PMID: 17644919 DOI: 10.3171/PED-07/07/036]
- 12 **Brockmeyer D**, Apfelbaum R, Tippets R, Walker M, Carey L. Pediatric cervical spine instrumentation using screw fixation. *Pediatr Neurosurg* 1995; **22**: 147-157 [PMID: 7786808]
- 13 **Brockmeyer DL**, York JE, Apfelbaum RI. Anatomical suitability of C1-2 transarticular screw placement in pediatric patients. *J Neurosurg* 2000; **92**: 7-11 [PMID: 10616051]
- 14 **Gluf WM**, Brockmeyer DL. Atlantoaxial transarticular screw fixation: a review of surgical indications, fusion rate, complications, and lessons learned in 67 pediatric patients. *J Neurosurg Spine* 2005; **2**: 164-169 [PMID: 15739528 DOI: 10.3171/spi.2005.2.2.0164]
- 15 **Hedequist D**, Proctor M, Hresko T. Lateral mass screw fixation in children. *J Child Orthop* 2010; **4**: 197-201 [PMID: 21629379 DOI: 10.1007/s11832-010-0251-0]
- 16 **Hedequist D**, Hresko T, Proctor M. Modern cervical spine instrumentation in children. *Spine (Phila Pa 1976)* 2008; **33**: 379-383 [PMID: 18277868 DOI: 10.1097/BRS.0b013e318163f9cd]
- 17 **Vara CS**, Thompson GH. A cadaveric examination of pediatric cervical pedicle morphology. *Spine (Phila Pa 1976)* 2006; **31**: 1107-1112 [PMID: 16648744 DOI: 10.1097/01.brs.0000216591.47505.17]

**P- Reviewers:** Canavese F, Hyun SJ, Landi A **S- Editor:** Gou SX  
**L- Editor:** A **E- Editor:** Lu YJ







## WJO 5<sup>th</sup> Anniversary Special Issues (8): Spine

# Perioperative visual loss after spine surgery

Travis J Nickels, Mariel R Manlapaz, Ehab Farag

Travis J Nickels, Mariel R Manlapaz, Ehab Farag, Department of General Anesthesia, Anesthesiology Institute, Cleveland Clinic, Cleveland, OH 44195, United States

Author contributions: Nickels TJ, Manlapaz MR and Farag E performed research, analyzed the data, and wrote the paper.

Correspondence to: Ehab Farag, MD, Department of General Anesthesia, Anesthesiology Institute, Cleveland Clinic, 9500 Euclid Avenue; E-30, Cleveland, OH 44195, United States. farage@ccf.org

Telephone: +1-216-4447550 Fax: +1-216-4449247

Received: December 17, 2013 Revised: February 25, 2014

Accepted: March 13, 2014

Published online: April 18, 2014

## Abstract

Perioperative visual loss (POVL) is an uncommon, but devastating complication that remains primarily associated with spine and cardiac surgery. The incidence and mechanisms of visual loss after surgery remain difficult to determine. According to the American Society of Anesthesiologists Postoperative Visual Loss Registry, the most common causes of POVL in spine procedures are the two different forms of ischemic optic neuropathy: anterior ischemic optic neuropathy and posterior ischemic optic neuropathy, accounting for 89% of the cases. Retinal ischemia, cortical blindness, and posterior reversible encephalopathy are also observed, but in a small minority of cases. A recent multicenter case control study has identified risk factors associated with ischemic optic neuropathy for patients undergoing prone spinal fusion surgery. These include obesity, male sex, Wilson frame use, longer anesthetic duration, greater estimated blood loss, and decreased percent colloid administration. These risk factors are thought to contribute to the elevation of venous pressure and interstitial edema, resulting in damage to the optic nerve by compression of the vessels that feed the optic nerve, venous infarction or direct mechanical compression. This review will expand on these findings as well as the recently updated American Society of Anesthesiologists practice advisory on POVL. There are no effective

treatment options for POVL and the diagnosis is often irreversible, so efforts must focus on prevention and risk factor modification. The role of crystalloids versus colloids and the use of  $\alpha$ -2 agonists to decrease intraocular pressure during prone spine surgery will also be discussed as a potential preventative strategy.

© 2014 Baishideng Publishing Group Co., Limited. All rights reserved.

**Key words:** Perioperative visual loss; Ischemic optic neuropathy; Central retinal artery occlusion; Cortical blindness; Posterior reversible encephalopathy; Spine surgery; Prone positioning

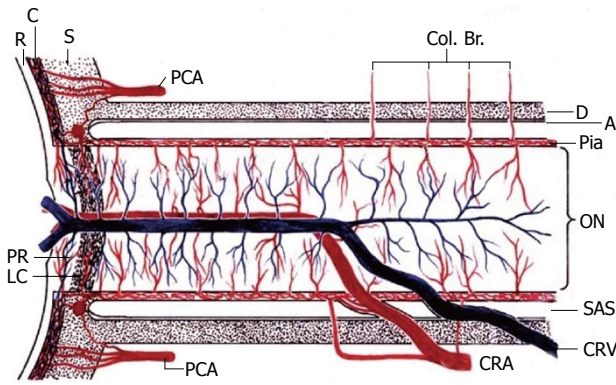
**Core tip:** Perioperative visual loss (POVL) is an uncommon, but devastating complication that remains primarily associated with spine and cardiac surgery. The incidence and mechanisms of visual loss after surgery remain difficult to determine. Ischemic optic neuropathy accounts for the vast majority of these cases, with retinal ischemia, cortical blindness, and posterior reversible encephalopathy observed with low incidence. Recently identified risk factors include obesity, male sex, Wilson frame use, longer anesthetic duration, greater estimated blood loss, and decreased percent colloid administration. POVL is often permanent and untreatable, so prevention is key to limiting its impact.

Nickels TJ, Manlapaz MR, Farag E. Perioperative visual loss after spine surgery. *World J Orthop* 2014; 5(2): 100-106 Available from: URL: <http://www.wjgnet.com/2218-5836/full/v5/i2/100.htm> DOI: <http://dx.doi.org/10.5312/wjo.v5.i2.100>

## INTRODUCTION

Perioperative visual loss (POVL) associated with spine surgery is a rare and disastrous complication that is generally irreversible and without definitive etiology.





**Figure 1** Schematic representation of blood supply of the optic nerve. Reproduced from Hayreh *et al.*<sup>[20]</sup>. A: Arachnoid; C: Choroid; CRA: Central retinal artery; Col. Br.: Collateral branches; CRV: Central retinal vein; D: Dura; LC: Lamina cribrosa; ON: Optic nerve; P: Pia; PCA: Posterior ciliary artery; PR: Prelaminar region; R: Retina; S: Sclera; SAS: Subarachnoid space.

First described by Hollenhorst *et al.*<sup>[11]</sup> in 1954, there have been numerous reports since establishing a clear link between spine surgery in the prone position and vision loss. Unfortunately, however, the research on this topic is limited due to its rare occurrence and consists largely of individual case reports and series<sup>[2-5]</sup>. This article reviews the different types of postoperative visual loss complications after spine surgery. The theoretical pathogenesis, risk factors, and prevention strategies including the use of colloids versus crystalloids and  $\alpha$ -agonists to decrease intraocular pressure (IOP) are also discussed.

## EPIDEMIOLOGY

Vision loss occurring with spine surgery may result from: anterior ischemic optic neuropathy (AION) or posterior ischemic optic neuropathy (PION); central retinal artery occlusion (CRAO); cortical blindness; and posterior reversible encephalopathy (PRES). Two large retrospective studies determined that the incidence of POVL is approximately 1/60000 to 1/125000 of all general anesthetics<sup>[6,7]</sup>. However, the risk of POVL is believed to be significantly greater following cardiac and spine surgeries. A recent review by Shen and colleagues of 5.6 million patients from the National Inpatient Sample (NIS) found that the incidence of POVL to be 3.09/10000 (0.03%) after spinal fusion and 8.64/10000 (0.09%) after cardiac surgery<sup>[5]</sup>. Other large-scale series suggest that the rate of POVL may be even higher after spine surgery, with incidence rates ranging from 0.094%<sup>[4]</sup> to 0.2%<sup>[8]</sup>. Visual loss was more common after spinal fusion for scoliosis and posterior lumbar fusion than anterior lumbar fusion or cervical fusion<sup>[4]</sup>. It was also noted to be significantly increased in hip and femur operations (1.86/10000, or 0.19%)<sup>[5]</sup>. These procedures share several features including large blood loss, hemodynamic perturbations, high embolic loads, and significant inflammation.

According to the American Society of Anesthesiologists (ASA) Postoperative Visual Loss Registry, the most common causes of POVL in spine procedures are the

two different forms of ischemic optic neuropathy (ION): AION and PION, accounting for 89% of the cases<sup>[9]</sup>. PION was diagnosed in 60% of these cases<sup>[9]</sup>. In this database, CRAO only accounted for 11% of the cases.

According to the most recent NIS review, gender plays an important role with men displaying a higher risk of POVL after spinal fusion relative to women (OR = 1.75), which is consistent with the ASA POVL Registry<sup>[9]</sup>, previous case series<sup>[10]</sup>, and a recent multicenter case-control study<sup>[11]</sup>. Age appears to be a factor as well with those aged 50-64 years displaying an increased risk (OR = 1.75). Also notable and unexplained was the finding that children < 18 years old had the highest overall risk for POVL (OR = 6.91), which was primarily attributed to cortical blindness rather than AION/PION and may represent a different etiology<sup>[5]</sup>.

## ANATOMY

### Blood supply to the optic nerve

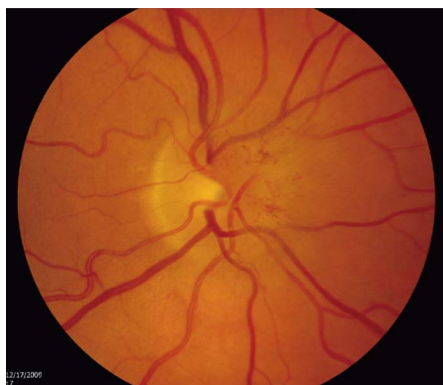In order to understand POVL, especially ION, it is important to have a basic understanding of the blood supply to the optic nerve (Figure 1). For an exhaustive review, please see Hayreh, 2001<sup>[12]</sup>. The ophthalmic artery, originating from the internal carotid artery, and its various branches is the principal blood supply to the retina, globe, and optic nerve. The central retinal artery, a branch of the ophthalmic artery, supplies the inner retina.

The anterior portion of the optic nerve (optic nerve head) has a rich arterial supply principally from the posterior ciliary artery (PCA) circulation, except for the surface nerve fiber layer, which is supplied by the retinal circulation. The blood supply in the optic nerve head has a sectorial distribution, which may explain the segmental vision loss seen in ischemic disorders<sup>[13]</sup>.

The posterior portion of the optic nerve is supplied by the pial vascular plexus, which is supplied by multiple pial branches originating from the peripapillary choroid, circle of Haller and Zinn, central retinal artery, ophthalmic artery, and other orbital arteries<sup>[13]</sup>.

In contrast to the densely supplied anterior and posterior portions of the nerve, the central portion within the optic canal is supplied only by the pial vascular plexus derived from arterial extensions of the anterior and posterior blood supplies and intraneural branches of the central retinal artery. This comparatively sparse vascular supply to the mid portion of the optic nerve renders it more susceptible to ischemia and it is this portion of the nerve that is thought to be related to PION<sup>[14]</sup>. However, it is important to note that there is significant interindividual variability in the complex blood supply to the optic nerve, especially in terms of the location and pattern of watershed zones<sup>[12]</sup>.

Venous drainage occurs mostly via the central retinal vein that is drained by the internal jugular vein. In the pre-laminar region of the eye, there are retinociliary collaterals to the peripapillary choroidal veins and drainage through these collaterals can become significant in case



**Figure 2** Fundoscopic exam of acute anterior ischemic optic neuropathy demonstrating blurring of the optic disk margin from edema.

of central retinal vein thrombosis<sup>[14]</sup>.

## VISION LOSS AFTER SPINE SURGERY

### Ischemic optic neuropathy

Postoperative ION is a devastating complication that can occur after a variety of surgical procedures, most often following cardiothoracic surgery<sup>[15]</sup>, instrumented spinal fusion<sup>[16,17]</sup>, and head and neck surgery<sup>[18]</sup>. ION can be categorized as either anterior or posterior, depending on whether the insult occurs in the anterior or posterior portion of the optic nerve. The type of ION observed varies depending on the type of surgery performed, with AION occurring most frequently after cardiac surgery and PION occurring most frequently after spine surgery in the prone position or radical neck dissection<sup>[9]</sup>.

### Anterior ischemic optic neuropathy

AION is likely caused by occlusion or hypoperfusion of the anterior optic nerve head by the PCAs and typically presents with sudden onset painless vision loss and a visual field defect. It is distinguished on fundoscopy by diffuse or segmental disc edema with ensuing atrophy and sometimes splinter hemorrhages around the optic disc (Figure 2)<sup>[19,20]</sup>. AION can be further classified as either arteritic or nonarteritic. Arteritic AION is rarely found perioperatively. It is caused by temporal arteritis and often presents in the elderly with an elevated erythrocyte sedimentation rate (ESR) and C-reactive protein (CRP), markers that are entirely non-specific in the postoperative period<sup>[21]</sup>.

Nonarteritic AION occurs both spontaneously in the community and in the perioperative setting, often in patients with pre-existing vascular disease<sup>[22]</sup>. Additional risk factors include diabetes mellitus, arterial hypotension, arterial hypertension, blood loss, prone positioning during surgery, prolonged surgery, atherosclerosis, sleep apnea, and migraine<sup>[13]</sup>; however, it can occur in patients that are otherwise healthy. The pathology is likely a combination of these factors, perhaps together with abnormal autoregulation and other patient specific characteristics that predispose to ischemic injury<sup>[23]</sup>. Perioperative nonarteritic AION is most often associated with cardiac surgery,

especially CABG, and generally presents immediately upon awakening from surgery. On rare occasion, AION may occur abruptly after a “delay” or period of normal vision lasting hours to days<sup>[24]</sup>.

### Posterior ischemic optic neuropathy

Posterior ION results from infarction of the optic nerve posterior to the lamina cribrosa and also manifests as sudden onset painless visual loss and visual field deficiencies. In contrast to AION, the fundoscopic examination initially reveals a completely normal appearing fundus, with optic nerve pallor and atrophy occurring only after approximately 4-6 wk<sup>[24]</sup>. It tends to cause significant bilateral visual loss or complete blindness and is usually discovered on waking from the surgical procedure<sup>[13]</sup>. In the ASA Registry of spine-related ION, 46% of the patients reported had no light perception<sup>[9]</sup>, which is usually permanent. Like AION, PION may also be classified as either arteritic or nonarteritic. The arteritic form is attributable to temporal arteritis and the nonarteritic form is seen most commonly following spine surgery.

A host of hemodynamic derangements could contribute to the development of postoperative PION including: hypotension, anemia, increased venous pressure, prone positioning during surgery, increased cerebrospinal fluid, and direct ocular compression<sup>[25]</sup>. Anemia and hypotension are almost always observed in patients that develop postoperative PION<sup>[26]</sup>. The pial vessels that supply the posterior optic nerve lack an autoregulatory mechanism, rendering them susceptible to ischemia during periods of hypotension and when the blood oxygen carrying capacity is decreased<sup>[27]</sup>. However, studies comparing patients with POVl after spine surgery with those of controls demonstrated no difference in perioperative hematocrit and blood pressure, suggesting a multifactorial cause<sup>[10,28]</sup>.

The prone position, a key element to spine surgery, is also the setting in which the majority of postoperative PION is observed. Prone positioning, especially when in the Trendelenburg position, leads to increased orbital venous pressure through an increase in abdominal venous pressure, thus increasing resistance to local blood flow<sup>[29]</sup>. Direct orbital pressure, often seen with face pillows/cushions or other positioning devices, has also been implicated in the pathogenesis of PION. However, with the resultant decreased perfusion pressure to the optic nerve head and central retinal artery, AION or CRAO would be more likely observed<sup>[26]</sup>. Avoidance of the prone position and direct ocular pressure is insufficient, however, to prevent postoperative PION, as cases have been documented following surgery in the supine position and with the use of head pins<sup>[3,9,30]</sup>.

### Risk factors associated with ischemic optic neuropathy and spine surgery

Recently in 2012, the Postoperative Visual Loss Study Group published a multicenter case-control study that explored the risk factors for ION after spinal fusion sur-

gery in the prone position<sup>[11]</sup>. Prior studies of ION after spine surgery were limited by small numbers without appropriately matched controls or by lack of associated intraoperative data (estimated blood loss, fluids administered, type of surgical frame, case duration, *etc.*)<sup>[4,5,10]</sup>. This study comparing 80 cases from the ASA Postoperative Visual Loss Registry to 315 controls from 17 institutions throughout the United States addressed these shortcomings. Obesity, male sex, Wilson frame use, longer anesthetic duration, greater estimated blood loss, and decreased percent colloid administration were significantly and independently associated with ION after spinal fusion surgery<sup>[11]</sup>.

### **Theoretical mechanisms for ischemic optic neuropathy after prone spine surgery**

The most popular pathophysiologic explanations used today for ischemic optic neuropathy during prone position are the elevation of venous pressure and development of interstitial edema<sup>[11]</sup>. Theoretically, these two processes can cause damage to the optic nerve by compression of the vessels that feed the optic nerve, venous infarction or direct mechanical compression. A rise in central venous pressure can occur in obese patients when their abdomen is compressed during prone position. Venous pressure can also elevate when the head position is lower than the heart, a given when patients are placed in the Wilson frame. Lower oncotic pressure leading to a growing interstitial edema can occur when there is significant inflammation and capillary leak such as in situations of major blood loss and/or prolonged cases. The same can occur when less colloid is used overall. Thus far, these explanations are simply theories that require further investigation. Why the male sex appears to be a risk factor for ischemic optic neuropathy during prone position is still a puzzle, but it has been suggested that estrogen may serve a protective role<sup>[31]</sup>.

### **Retinal ischemia: Branch and central retinal artery occlusion**

Central retinal artery occlusion (CRAO) decreases blood supply to the entire retina, whereas occlusion of a retinal branch (BRAO) affects only a portion of the retina. Both are ophthalmic emergencies and analogous to an acute stroke of the eye. Retinal ischemia has been documented in both adults and children following ocular trauma<sup>[32]</sup>, and also embolic<sup>[33]</sup> and vasospastic episodes<sup>[34]</sup>.

With respect to spine surgery, these conditions are mostly commonly seen during the perioperative period from improper patient positioning and external compression on the eye<sup>[35]</sup>. Of the 93 cases submitted to the ASA Visual Loss Registry, there were 10 cases of CRAO<sup>[9]</sup>, representing a much smaller percentage than ION. Perioperative trauma was noted in 70% of the cases, as evidenced by corneal abrasion, ipsilateral decreased supraorbital sensation, ophthalmoplegia, ptosis, or unilateral erythema<sup>[9]</sup>.

Theoretical mechanisms that have been used to explain CRAO include thromboembolism, direct pressure to the globe, and increased intraocular pressure. De-

creased oxygen carrying capacity and blood flow to optic nerve such as from hypovolemia, anemia, large blood loss, and peripheral vascular disease, have also been suggested etiologic factors for CRAO. The use of horseshoe-shaped headrest has been associated with this complication. Hollenhurst *et al.*<sup>[11]</sup> described CRAO in eight patients after prone spine surgery on horseshoe headrest. In fact CRAO in spine surgery was subsequently referred to as “headrest syndrome<sup>[22]</sup>”. Increased risk is also observed in patients with altered facial anatomy, osteogenesis imperfecta, and exophthalmos, all of which can increase effects of external compression<sup>[36]</sup>.

CRAO is often unilateral in presentation with severe visual loss in the affected eye. Patients are found to have a cherry-red spot on the macula, a white ground-glass appearance of the retina, attenuated arterioles, and an afferent pupillary defect<sup>[37]</sup>. Visual loss from CRAO is almost always irreversible and there are no established effective treatment options.

### **Cortical blindness**

Cortical blindness is the result of decreased perfusion to the occipital cortex by the posterior cerebral artery. The cause is either hypoperfusion or embolic phenomenon. Patients with cortical blindness have normal light reflex and fundoscopic examination as the optic tracts and radiations are unaffected. When one side is affected, the patient presents with contralateral homonymous hemianopsia. If both sides suffer ischemic insult, the patient may have peripheral vision loss or complete blindness. Cortical blindness may improve initially after the infarct, but total recovery is rare.

### **PRES**

PRES is a neurologic syndrome that presents as a combination of seizures, visual changes, vomiting, headache, and decreased level of consciousness. It is associated with acute medical illnesses such as hypertensive episodes, autoimmune disease, malignancy, chemotherapy, immunosuppressant therapy, infection, renal disease, vasculitis, eclampsia, and preeclampsia<sup>[38]</sup>. Although more closely identified with obstetric patients, PRES has also been reported after lumbar fusion<sup>[39]</sup>, hysterectomy<sup>[40]</sup> and video-assisted-thoracoscopic wedge resection<sup>[41]</sup>. PRES has characteristic MRI findings. There are two leading theoretical explanation for PRES. One is acute increase in blood pressure above the brain's autoregulatory limit thereby causing brain edema. The other pathophysiologic explanation is cytotoxic drugs or diseases causing endothelial injury and edema formation. Management is appropriate use of anti-seizure and anti-hypertensive agents and treatment of causative factor(s). Unlike ION and CRAO, PRES has a favorable recovery pattern.

## **TREATMENT AND PREVENTION OF POVL**

When a patient reports any visual symptoms following surgery, an urgent ophthalmologic consultation should be obtained to determine its cause. If an apparent ocular



**Table 1 American Society of Anesthesiologists perioperative visual loss practice advisory consensus conclusions**

There is a subset of patients who undergo spine procedures while they are positioned prone and receiving general anesthesia that has an increased risk for the development of POVL. This “high-risk” subset includes patients who are anticipated preoperatively to undergo procedures that are prolonged, have substantial blood loss, or both
Consider continuous blood pressure and central venous pressure monitoring in high-risk patients
Consider informing high-risk patients that there is a small, unpredictable risk of POVL
The use of deliberate hypotensive techniques during spine surgery has not been shown to be associated with the development of POVL
Colloids should be used along with crystalloids to maintain intravascular volume in patients who have substantial blood loss
At this time, there is no apparent transfusion threshold that would eliminate the risk of POVL related to anemia
High-risk patients should be positioned so that their heads are level with or higher than the heart, when possible. In addition, their heads should be maintained in a neutral forward position (without significant neck flexion, extension, lateral flexion, or rotation) when possible
Consideration should be given to the use of staged spine procedures in high-risk patients

POVL: Perioperative visual loss.

injury or central retinal artery occlusion is not obvious, neuroimaging should be obtained, preferably MRI with gadolinium to assess for intracranial pathologies, including occipital stroke or pituitary apoplexy<sup>[42]</sup>. If imaging is negative, the most likely etiology is ION. Treatment has often involved high dose steroids, mannitol or other agents to decrease intraocular pressure, and anti-platelet agents; however, none of these approaches have been shown to be effective<sup>[13,24,43]</sup>.

Our group recently examined the effect of crystalloid versus colloid and the use of the  $\alpha$ -agonist Brimonidine on IOP during prone spine surgery<sup>[44]</sup>. Of note, the mean rate of IOP rise in the prone position and mean IOP at the end of surgery was significantly greater in patients receiving crystalloid than those receiving colloid. Topical Brimonidine also led to a significant reduction in IOP, both intraoperative and postoperative. Ocular perfusion pressure, however, did not vary significantly between the groups as hypotension was aggressively treated, suggesting that maintenance of blood pressure may be a more important factor in determining perfusion pressure. Much larger studies are needed to determine whether maintaining appropriate ocular perfusion pressure reduces the risk of POVL after spine surgery.

Given the poor prognosis and lack of validated treatment options, it is essential to take prophylactic measures during surgery to prevent the development of POVL. The ASA Task Force on Perioperative Blindness, consisting of anesthesiologists, neuro-ophthalmologists, and spine surgeons was formed in 2005 to evaluate the literature and develop a practice advisory to help deal with this issue. In 2006, a “practice advisory” was published and the consensus conclusions are listed in Table 1<sup>[42]</sup>. Other guidelines found in this advisory as well as the update published in 2012<sup>[43]</sup>, suggest periodically checking hemoglobin and hematocrit values, and avoidance of direct pressure on the globe to avoid CRAO injuries. A variety of commercially available devices are available to help limit mechanical ocular compression during prone surgery, but these still require vigilance on the part of the surgeon and anesthesiologist as patient movement and shifting of the device may occur. If POVL is suspected, additional efforts directed towards optimizing hemoglo-

bin/hematocrit values, hemodynamic status, and systemic oxygenation may be appropriate<sup>[43]</sup>.

## PERIOPERATIVE VISUAL LOSS IN OTHER SURGERIES

Perioperative visual loss has also been associated with robotic and laparoscopic surgeries. Cases of visual impairment have been reported to occur in minimally invasive proctocolectomy, laparoscopic nephrectomy and robotic prostatectomy<sup>[45-48]</sup>. During robotic prostatectomy, increased intraocular pressure occurs due to prolonged duration in steep Trendelenburg position combined with CO<sub>2</sub> insufflation of the abdomen. The central venous pressure within the thorax increases with Trendelenburg position, which may reduce drainage of blood flow from the head, thereby leading to elevation in IOP. During CO<sub>2</sub> insufflation, the increase in intra-abdominal pressure will further augment the increase in intrathoracic pressure. Furthermore, insufflation of CO<sub>2</sub> increases the carbon dioxide in the blood, which can lead to cerebral vasodilatation and increased cerebral blood volume. The end result is elevation in venous pressure. It is unknown whether the same risk factors for POVL in spine surgery can be applied to laparoscopic and robotic surgeries, but it appears venous congestion and interstitial edema are commonalities among these surgeries. As robotic surgeries gain popularity, studies to find population at risk are underway. Conservative management, however, with attempts to decrease venous congestion and interstitial edema would seem appropriate.

## CONCLUSION

In summary, POVL in spine surgery is extremely rare, but it remains a dreaded complication despite significant efforts to identify risk factors and a pathophysiological mechanism. Potential causes of POVL after spine surgery include anterior ischemic optic neuropathy, posterior ischemic optic neuropathy, cortical blindness, retinal ischemia, and posterior reversible encephalopathy syndrome. The vast majority of cases are related to ischemic optic



neuropathy. Many reports have attempted to link hypotension, anemia, and blood loss to the development of this disease; however, no single mechanism can entirely explain the varied circumstances in which it occurs. This suggests a multifactorial etiology and perhaps individual susceptibility related to varied optic nerve blood supply and anatomy.

In the largest and most comprehensive study to date, the Postoperative Visual Loss Group, using data from the ASA Post Operative Visual Loss Registry, identified obesity, male sex, Wilson frame use, longer anesthetic duration, greater estimated blood loss, and decreased percent colloid administration as significant independent risk factors for the development of ION. These risk factors, with the possible exception of male sex, are thought to promote a rise in venous pressure and interstitial edema limiting optic nerve perfusion. Further studies will hopefully elucidate whether the use of colloid and/or topical  $\alpha$ -agonists to limit the rise in IOP during complex prone spine surgeries is important in maintaining ocular perfusion and reducing the incidence of POVL.

Given the complete lack of effective treatment modalities, prevention is crucial for limiting the incidence and destruction of POVL. Practitioners are encouraged to follow the ASA guidelines listed in Table 1, especially for patients identified as high risk undergoing procedures that are known to result in visual loss.

## REFERENCES

- Hollenhorst RW, Svien HJ, Benoit CF. Unilateral blindness occurring during anesthesia for neurosurgical operations. *AMA Arch Ophthalmol* 1954; **52**: 819-830 [PMID: 13217529 DOI: 10.1001/archophth.1954.00920050825002]
- Alexandrakis G, Lam BL. Bilateral posterior ischemic optic neuropathy after spinal surgery. *Am J Ophthalmol* 1999; **127**: 354-355 [PMID: 10088754 DOI: 10.1016/S0002-9394(98)00343-2]
- Cheng MA, Todorov A, Tempelhoff R, McHugh T, Crowder CM, Laurysen C. The effect of prone positioning on intraocular pressure in anesthetized patients. *Anesthesiology* 2001; **95**: 1351-1355 [PMID: 11748391]
- Patil CG, Lad EM, Lad SP, Ho C, Boakye M. Visual loss after spine surgery: a population-based study. *Spine (Phila Pa 1976)* 2008; **33**: 1491-1496 [PMID: 18520945 DOI: 10.1097/BRS.0b013e318175d1bf]
- Shen Y, Drum M, Roth S. The prevalence of perioperative visual loss in the United States: a 10-year study from 1996 to 2005 of spinal, orthopedic, cardiac, and general surgery. *Anesth Analg* 2009; **109**: 1534-1545 [PMID: 19713263 DOI: 10.1213/ane.0b013e3181b0500b]
- Warner ME, Warner MA, Garrity JA, MacKenzie RA, Warner DO. The frequency of perioperative vision loss. *Anesth Analg* 2001; **93**: 1417-1421, table of contents [PMID: 11726416 DOI: 10.1097/00005539-200112000-00013]
- Roth S, Thisted RA, Erickson JP, Black S, Schreider BD. Eye injuries after nonocular surgery. A study of 60,965 anesthetics from 1988 to 1992. *Anesthesiology* 1996; **85**: 1020-1027 [PMID: 8916818 DOI: 10.1016/S0001-2092(06)62554-4]
- Stevens WR, Glazer PA, Kelley SD, Lietman TM, Bradford DS. Ophthalmic complications after spinal surgery. *Spine (Phila Pa 1976)* 1997; **22**: 1319-1324 [PMID: 9201834]
- Lee LA, Roth S, Posner KL, Cheney FW, Caplan RA, Newman NJ, Domino KB. The American Society of Anesthesiologists Postoperative Visual Loss Registry: analysis of 93 spine surgery cases with postoperative visual loss. *Anesthesiology* 2006; **105**: 652-659; quiz 652-659 [PMID: 17006060 DOI: 10.1097/00005542-200610000-00007]
- Holy SE, Tsai JH, McAllister RK, Smith KH. Perioperative ischemic optic neuropathy: a case control analysis of 126,666 surgical procedures at a single institution. *Anesthesiology* 2009; **110**: 246-253 [PMID: 19194151 DOI: 10.1097/ALN.0b013e318194b238]
- Postoperative Visual Loss Study Group. Risk factors associated with ischemic optic neuropathy after spinal fusion surgery. *Anesthesiology* 2012; **116**: 15-24 [PMID: 22185873 DOI: 10.1097/ALN.0b013e31823d012a]
- Hayreh SS. The blood supply of the optic nerve head and the evaluation of it - myth and reality. *Prog Retin Eye Res* 2001; **20**: 563-593 [PMID: 11470451 DOI: 10.1016/S1350-9462(01)00004-0]
- Hayreh SS. Ischemic optic neuropathies - where are we now? *Graefes Arch Clin Exp Ophthalmol* 2013; **251**: 1873-1884 [PMID: 23821118 DOI: 10.1007/s00417-013-2399-z]
- Goepfert CE, Ifune C, Tempelhoff R. Ischemic optic neuropathy: are we any further? *Curr Opin Anaesthesiol* 2010; **23**: 582-587 [PMID: 20802327 DOI: 10.1097/ACO.0b013e32833e15d0]
- Tice DA. Ischemic optic neuropathy and cardiac surgery. *Ann Thorac Surg* 1987; **44**: 677 [PMID: 3500683 DOI: 10.1016/S0003-4975(10)62171-6]
- Gill B, Heavner JE. Postoperative visual loss associated with spine surgery. *Eur Spine J* 2006; **15**: 479-484 [PMID: 15926057 DOI: 10.1007/s00586-005-0914-6]
- Stambough JL, Dolan D, Werner R, Godfrey E. Ophthalmologic complications associated with prone positioning in spine surgery. *J Am Acad Orthop Surg* 2007; **15**: 156-165 [PMID: 17341672]
- Schobel GA, Schmidbauer M, Millesi W, Undt G. Posterior ischemic optic neuropathy following bilateral radical neck dissection. *Int J Oral Maxillofac Surg* 1995; **24**: 283-287 [PMID: 7490491 DOI: 10.1016/S0901-5027(95)80030-1]
- Miller NR. Current concepts in the diagnosis, pathogenesis, and management of nonarteritic anterior ischemic optic neuropathy. *J Neuroophthalmol* 2011; **31**: e1-e3 [PMID: 21593625 DOI: 10.1097/WNO.0b013e31821f955c]
- Hayreh SS. Management of ischemic optic neuropathies. *Indian J Ophthalmol* 2011; **59**: 123-136 [PMID: 21350282 DOI: 10.4103/0301-4738.77024]
- Hayreh SS. Anterior ischemic optic neuropathy. VIII. Clinical features and pathogenesis of post-hemorrhagic amaurosis. *Ophthalmology* 1987; **94**: 1488-1502 [PMID: 3500445 DOI: 10.1016/S0161-6420(87)33273-7]
- Lee LA, Newman NJ, Wagner TA, Dettori JR, Dettori NJ. Postoperative ischemic optic neuropathy. *Spine (Phila Pa 1976)* 2010; **35**: S105-S116 [PMID: 20407342 DOI: 10.1097/BRS.0b013e3181d8344d]
- Roth S. Perioperative visual loss: what do we know, what can we do? *Br J Anaesth* 2009; **103** Suppl 1: i31-i40 [PMID: 20007988 DOI: 10.1093/bja/aep295]
- Newman NJ. Perioperative visual loss after nonocular surgeries. *Am J Ophthalmol* 2008; **145**: 604-610 [PMID: 18358851 DOI: 10.1016/j.ajo.2007.09.016]
- Berg KT, Harrison AR, Lee MS. Perioperative visual loss in ocular and nonocular surgery. *Clin Ophthalmol* 2010; **4**: 531-546 [PMID: 20596508]
- Buono LM, Foroozan R. Perioperative posterior ischemic optic neuropathy: review of the literature. *Surv Ophthalmol* 2005; **50**: 15-26 [PMID: 15621075 DOI: 10.1016/j.ajo.2005.03.007]
- Isayama Y, Takahashi T, Inoue M, Jimura T. Posterior ischemic optic neuropathy. III. Clinical diagnosis. *Ophthalmologica* 1983; **187**: 141-147 [PMID: 6634061]
- Myers MA, Hamilton SR, Bogosian AJ, Smith CH, Wagner

- TA. Visual loss as a complication of spine surgery. A review of 37 cases. *Spine* (Phila Pa 1976) 1997; **22**: 1325-1329 [PMID: 9201835 DOI: 10.1097/00007632-199706150-00009]
- 29 **Wollenberg B**, Walz A, Kolbow K, Pauli C, Chaubal S, Andratschke M. Clinical relevance of circulating tumour cells in the bone marrow of patients with SCCHN. *Onkologie* 2004; **27**: 358-362 [PMID: 15347890 DOI: 10.1159/000079088]
- 30 **Cheng MA**, Sigurdson W, Tempelhoff R, Lauryssen C. Visual loss after spine surgery: a survey. *Neurosurgery* 2000; **46**: 625-630; discussion 630-631 [PMID: 10719859 DOI: 10.1097/0006123-200003000-00020]
- 31 **Giordano C**, Montopoli M, Perli E, Orlandi M, Fantin M, Ross-Cisneros FN, Caparrotta L, Martinuzzi A, Ragazzi E, Ghelli A, Sadun AA, d'Amati G, Carelli V. Oestrogens ameliorate mitochondrial dysfunction in Leber's hereditary optic neuropathy. *Brain* 2011; **134**: 220-234 [PMID: 20943885 DOI: 10.1093/brain/awq276]
- 32 **Noble MJ**, Alvarez EV. Combined occlusion of the central retinal artery and central retinal vein following blunt ocular trauma: a case report. *Br J Ophthalmol* 1987; **71**: 834-836 [PMID: 3689734 DOI: 10.1136/bjo.71.11.834]
- 33 **Kollarits CR**, Lubow M, Hissong SL. Retinal strokes. I. Incidence of carotid atheromata. *JAMA* 1972; **222**: 1273-1275 [PMID: 4678141 DOI: 10.1001/jama.222.10.1273]
- 34 **Brown GC**, Magargal LE, Shields JA, Goldberg RE, Walsh PN. Retinal arterial obstruction in children and young adults. *Ophthalmology* 1981; **88**: 18-25 [PMID: 7243224 DOI: 10.1016/S0161-6420(81)35080-5]
- 35 **Katz DA**, Karlin LI. Visual field defect after posterior spine fusion. *Spine* (Phila Pa 1976) 2005; **30**: E83-E85 [PMID: 15682002 DOI: 10.1097/01.brs.0000152169.48117.c7]
- 36 **Bradish CF**, Flowers M. Central retinal artery occlusion in association with osteogenesis imperfecta. *Spine* (Phila Pa 1976) 1987; **12**: 193-194 [PMID: 3589811 DOI: 10.1097/00007632-198703000-00018]
- 37 **Hayreh SS**, Kolder HE, Weingeist TA. Central retinal artery occlusion and retinal tolerance time. *Ophthalmology* 1980; **87**: 75-78 [PMID: 6769079 DOI: 10.1016/S0161-6420(80)35283-4]
- 38 **Lee LA**. Perioperative visual loss and anesthetic management. *Curr Opin Anaesthesiol* 2013; **26**: 375-381 [PMID: 23614957 DOI: 10.1097/ACO.0b013e328360dcd9]
- 39 **Yi JH**, Ha SH, Kim YK, Choi EM. Posterior reversible encephalopathy syndrome in an untreated hypertensive patient after spinal surgery under general anesthesia -A case report-. *Korean J Anesthesiol* 2011; **60**: 369-372 [PMID: 21716568 DOI: 10.4097/kjae.2011.60.5.369]
- 40 **Kim TK**, Yoon JU, Park SC, Lee HJ, Kim WS, Yoon JY. Post-operative blindness associated with posterior reversible encephalopathy syndrome: a case report. *J Anesth* 2010; **24**: 783-785 [PMID: 20694483 DOI: 10.1007/s00540-010-0995-1]
- 41 **Eran A**, Barak M. Posterior reversible encephalopathy syndrome after combined general and spinal anesthesia with intrathecal morphine. *Anesth Analg* 2009; **108**: 609-612 [PMID: 19151296 DOI: 10.1213/ane.0b013e31818f635e]
- 42 **American Society of Anesthesiologists Task Force on Perioperative Blindness**. Practice advisory for perioperative visual loss associated with spine surgery: a report by the American Society of Anesthesiologists Task Force on Perioperative Blindness. *Anesthesiology* 2006; **104**: 1319-1328 [PMID: 16732103 DOI: 10.1097/00000542-200606000-00027]
- 43 **American Society of Anesthesiologists Task Force on Perioperative Visual Loss**. Practice advisory for perioperative visual loss associated with spine surgery: an updated report by the American Society of Anesthesiologists Task Force on Perioperative Visual Loss. *Anesthesiology* 2012; **116**: 274-285 [PMID: 22227790 DOI: 10.1097/ALN.0b013e31823c104d]
- 44 **Farag E**, Sessler DI, Kovaci B, Wang L, Mascha EJ, Bell G, Kalfas I, Rockwood E, Kurz A. Effects of crystalloid versus colloid and the  $\alpha$ -2 agonist brimonidine versus placebo on intraocular pressure during prone spine surgery: a factorial randomized trial. *Anesthesiology* 2012; **116**: 807-815 [PMID: 22322966 DOI: 10.1097/ALN.0b013e3182475c10]
- 45 **Weber ED**, Colyer MH, Lesser RL, Subramanian PS. Posterior ischemic optic neuropathy after minimally invasive prostatectomy. *J Neuroophthalmol* 2007; **27**: 285-287 [PMID: 18090562 DOI: 10.1097/WNO.0b013e31815b9f67]
- 46 **Mizrahi H**, Hugkulstone CE, Vyakarnam P, Parker MC. Bilateral ischaemic optic neuropathy following laparoscopic proctocolectomy: a case report. *Ann R Coll Surg Engl* 2011; **93**: e53-e54 [PMID: 21943450 DOI: 10.1308/147870811X582828]
- 47 **Metwalli AR**, Davis RG, Donovan JF. Visual impairment after laparoscopic donor nephrectomy. *J Endourol* 2004; **18**: 888-890 [PMID: 15659927 DOI: 10.1089/end.2004.18.888]
- 48 **Lee LA**, Posner KL, Bruchas R, Roth S, Domino KB. Visual loss after prostatectomy. Proceedings of the 2010 Annual Meeting of the American Society of Anesthesiologists, 2010: A1132

**P- Reviewers:** Aota Y, Huang J, Kuh SU, Leonardi M, Nagashima H  
**S- Editor:** Zhai HH **L- Editor:** A **E- Editor:** Lu YJ



## WJO 5th Anniversary Special Issues (10): Rheumatoid arthritis

# Impact of rheumatoid arthritis on sexual function

Antonio G Tristano

Antonio G Tristano, Rheumatology Department, Centro Médico Docente La Trinidad, 1080-A Caracas, Venezuela

Antonio G Tristano, Centro Medico Carpetana, 28025 Madrid, Spain

Author contributions: Tristano AG solely contributed to this paper.

Correspondence to: Antonio G Tristano, MD, MSc, FACP, Centro Medico Carpetana, Manuel Alvarez 3-4, 28025 Madrid, Spain. [antoniotristano@yahoo.com](mailto:antoniotristano@yahoo.com)

Telephone: +34-685-475345 Fax: +34-915-256422

Received: November 25, 2013 Revised: March 7, 2014

Accepted: March 13, 2014

Published online: April 18, 2014

## Abstract

Sexuality is a complex aspect of the human being's life and is more than just the sexual act. Normal sexual functioning consists of sexual activity with transition through the phases from arousal to relaxation with no problems, and with a feeling of pleasure, fulfillment and satisfaction. Rheumatic diseases may affect all aspects of life including sexual functioning. The reasons for disturbing sexual functioning are multifactorial and comprise disease-related factors as well as therapy. Rheumatoid arthritis (RA) is a chronic inflammatory autoimmune disease characterized by progressive joint destruction resulting from chronic synovial inflammation. It leads to various degrees of disability, and ultimately has a profound impact on the social, economic, psychological, and sexual aspects of the patient's life. This is a systemic review about the impact of RA on sexual functioning.

© 2014 Baishideng Publishing Group Co., Limited. All rights reserved.

**Key words:** Sexuality; Sexual functioning; Sexual dysfunction; Rheumatoid arthritis

**Core tip:** Sexual functioning is a neglected area of qual-

ity of life in patients with rheumatoid arthritis (RA) that is not routinely addressed by physicians or health professionals. Sexual functioning is also not part of questionnaires frequently used to assess physical function or quality of life. It is therefore important that physicians or any other health professionals in charge of handling these kinds of patients raise the subject of sexuality and discuss it with them. On the other hand, there are not enough studies comparing sexual functioning between RA patients and healthy controls and the impact of the treatments usually used in RA in improving sexual function. Because of the impact of this chronic inflammatory disease on sexual function and because there are not enough overviews about the impact of rheumatoid arthritis on sexual function, this systematic review is intended to cover this important but underestimated problem.

Tristano AG. Impact of rheumatoid arthritis on sexual function. *World J Orthop* 2014; 5(2): 107-111 Available from: URL: <http://www.wjgnet.com/2218-5836/full/v5/i2/107.htm> DOI: <http://dx.doi.org/10.5312/wjo.v5.i2.107>

## INTRODUCTION

RA may affect all aspects of life including sexual functioning. These factors include: pain, fatigue, stiffness, functional impairment, depression, anxiety, negative body image, reduced libido, hormonal imbalance, and drug treatment<sup>[1]</sup>.

The percentage of arthritic patients who experience sexual problems ranged in various studies from 31% to 76%<sup>[2-3]</sup>. The reasons for disturbing sexual functioning are multifactorial and comprise disease-related factors as well as therapy. It can occur before, during and after sexual activities, and can affect sexual health in different perspectives. Normal sexual functioning consists of sexual activity with transition through the phases from arousal to relaxation with no problems, and with a feeling of pleasure,

fulfillment and satisfaction<sup>[6,7]</sup>. Sexuality and its expression are important for healthy and ill individuals and therefore a crucial part of an individual's self-identity<sup>[8]</sup>.

There are not enough studies comparing sexual functioning between rheumatoid arthritis (RA) patients and healthy controls. However, there is a tendency to find more sexual functioning problems in patients with RA. These patients could experience sexual disability and diminish sexual drive, with pain and depression being the most common symptoms.

## SEXUAL FUNCTION IN RA PATIENTS

Sexual functioning is a neglected area of quality of life in patients with RA that is not routinely addressed by physicians or health professionals. Sexual functioning is also not a part of questionnaires frequently used to assess physical function or quality of life. In a recent survey of ten rheumatologists, only 12% of patients seen in their practice were screened for sexual activity. The reasons given by rheumatologists were time constraints, discomfort with the subject, and ambivalence whether such a screening is in their domain or not<sup>[9]</sup>.

The sexual problems in RA could be attributed to physical and psychological variables. Physical variables include difficulties in performing sexual intercourse (sexual disability), while psychological variables include depression, altered body image, worries about partner interest, and diminished sexual drive reflected in both diminished desire and satisfaction<sup>[2,10-14]</sup>. Difficulty in assuming certain positions when hip or knee movements are limited, dyspareunia due to vaginal dryness in secondary Sjogren's syndrome, and joint pain and fatigue during intercourse are the principal manifestations of sexual disability; the latter is experienced by 50%-61% of RA patients<sup>[11,15,16]</sup>.

The majority of patients with RA are female, and there are differences in sexual health between women and men with RA<sup>[17]</sup>. It has been shown that women with RA have fewer sexual fantasies and masturbate less than controls, and during intercourse, pain is the dominant problem, as well as limited joint mobility, but there are no differences in satisfaction<sup>[15,18]</sup>.

On the other hand, in a study of male adolescents and adults with juvenile idiopathic arthritis (JIA) masturbation and intercourse were practiced equally between patients and controls, although joint pain during intercourse was significantly more frequent among patients. Moreover, although some patients experienced joint pain associated with greater functional disability as indicated by higher HAQ scores, overall sexual pleasure and satisfaction were preserved<sup>[19]</sup>. In contrast, van Berlo *et al*<sup>[18]</sup> found that adult males with RA felt less sexual desire than controls (healthy volunteers); however, patients do not differ from controls regarding sexual satisfaction.

Packham *et al*<sup>[20]</sup>, in a study of 246 adult patients with long-standing JIA, found that 50% of them felt a detrimental effect on body image but only 28.2% of the patients experienced problems with their relationships. The percentage of patients who were sexually active or

had had previous sexual experience was 83.3%; 58.3% of these had disease-related sexual problems. Hill *et al*<sup>[3]</sup> studied 58 adults an average of 14.5 years after the diagnosis of juvenile RA. They found that two thirds had mild to moderate disease, good sexual adjustment and "normal" educational achievement, employment history and life-style. One third had severe disease, often with progressive disability; this did not prevent sexual activity but caused some limitations.

A possible explanation of these differences between young and adult patients could be by the fact that JIA manifests in childhood before the establishment of definite links, relationships, and complete growth. Thus, these children are able and have the opportunity and possibility to learn and build up new strategies and developmental mechanisms, such as alternative movements, gestures, and sexual positions, indicating better adaptive skills related to their new reality and life aspects, including sexual functioning<sup>[19]</sup>.

In contrast with this theory, Foster *et al*<sup>[21]</sup> evaluated quality of life (QOL) in adults with JIA, and they found that the SF-36 scores for bodily pain, general health, physical functioning, vitality, emotion, and social isolation were significantly worse in patients compared with controls, and this trend increased with increasing age of the patients and disease duration. Another important question is whether or not there is any difference between patients with early RA compared with RA patients with long-standing disease. Karlsson *et al*<sup>[22]</sup>, found that patients with early RA were less satisfied with life as a whole at disease onset compared to patients with long standing disease. Patients with early RA also reported low levels of satisfaction with self-care activities, work and sexual life. Women reported that they were more satisfied than men. Notably, women report themselves as less satisfied with sexual life after two years of disease duration. Women with long-standing disease report even lower levels of satisfaction. No correlation was found between disease activity variables and satisfaction with life as a whole. There were, however, positive correlations between disease activity and both satisfaction with partnership and with family life after two years. In patients with early RA compared with those who have chronic RA, the early intervention in addition to the modern early pharmacological treatment practiced today will hopefully lead to a higher degree of life satisfaction.

On the other hand, it is recognized that androgenic status could be related to sexual function. However, hypogonadism or testicular dysfunctions do not necessarily reduce sexual activity. In a study by Gordon *et al*<sup>[4]</sup>, it was shown that RA can cause hypogonadism with sexual dysfunction such as impotence and decreased libido.

## IMPACT OF PHYSICAL AND PSYCHOLOGICAL VARIABLES IN SEXUAL FUNCTION IN RA PATIENTS

The two main sexual problems experienced in RA pa-



tients are: difficulties in performing sexual intercourse (sexual disability); and diminished sexual drive, reflected in both diminished desire and satisfaction.

Hill *et al*<sup>[23]</sup> found that 56% of RA patients reported that arthritis placed limitations on sexual intercourse mainly due to fatigue and pain. It has been shown that when the hip joint is severely affected, total hip replacement improves sexual disability to pre-disease levels in 50% of sexually active patients with RA<sup>[24]</sup>. On the other hand, diminished sexual drive is manifested by a decrease in desire in 50%-60% of RA patients, reduced frequency of intercourse in up to 73% of patients, increase in aversion to sexual interactions, and diminished sexual satisfaction over time compared to pre-disease levels<sup>[11,15,16]</sup>.

Elst *et al*<sup>[25]</sup> showed that 50% of patients with RA lost sexual interest during the course of their disease and 60% were dissatisfied with quality of their sex life. However, Ostensen *et al*<sup>[26]</sup>, in a study of patients with history of juvenile chronic arthritis (JCA), showed that in the younger age group and patients with inactive or less active disease, sexual activity and frequency of intercourse was not different from healthy, age-matched controls. Furthermore, female patients who shared characteristics of marital status with their healthy counterparts showed a similar attitude to sexual activity.

Other studies attributed sexual problems in RA to psychological variables such as depression, altered body image, and worries about partner interest<sup>[2,10-14]</sup>.

Moreover, it has been found that in healthy females, anxiety is associated with reduced frequency of intercourse, whereas depression is an important factor in both loss of libido and loss of sexual satisfaction<sup>[13,14]</sup>.

Kraaiaat *et al*<sup>[5]</sup> found that physical disability, pain, and depression all contribute to the intrusiveness of RA on sexuality. Gutweniger *et al*<sup>[27]</sup> found that morning stiffness in female RA patients plays an important role in their feelings of being a handicap. Female RA patients with a high degree of morning stiffness also had significantly more worries about body image and experienced more sexual dissatisfaction than females with lower degrees of morning stiffness.

Recently, Abdel-Nasser *et al*<sup>[28]</sup> studied 52 female patients with RA. They found that 32 patients had difficulties in sexual performance including 9 patients who were totally unable to engage in sexual intercourse because of arthritis. More than 60% of female RA patients experienced variable degrees of sexual disability and diminished sexual desire and satisfaction. Difficulties in sexual performance were related more to disability and hip involvement, while diminished desire and satisfaction were influenced more by perceived pain, age and depression. They also found that 27% of their patients had genital tract abnormalities that could influence sexual performance. However, these abnormalities can be easily controlled by prompt gynecological referral.

In another recent study, van Berlo *et al*<sup>[18]</sup> found that male patients felt less sexual desire, and female patients masturbated and fantasized less than controls. Differ-

ences in satisfaction were not found. Male and female patients did not experience more sexual problems than controls. Up to 41% of the men, and up to 51% of the women have troubles with several joints during sexual activities. Medications influencing ejaculation in men correlated with distress with orgasm.

Finally, El Miedany *et al*<sup>[29]</sup> showed that among 231 rheumatoid arthritis patients included, 49/91 (53.8%) men and 64/140 (45.7%) women reported sexual dysfunction. Erectile dysfunction in men, and problems with orgasm, arousal, and satisfaction in women, were the most prevalent manifestations.

## IMPACT OF RA IN COUPLE'S RELATIONSHIP

Majerovitz *et al*<sup>[30]</sup>, when the relationship between functional disability and sexual satisfaction for both rheumatic disease patients and their spouses was examined and their levels of sexual satisfaction to those of healthy comparison couples were compared, found that rheumatic disease and comparison couples did not differ in sexual dissatisfaction. However, greater functional disability was related to greater sexual dissatisfaction for patients and spouses.

Bermas *et al*<sup>[31]</sup>, in a cross-sectional survey of 79 persons with RA and 78 spouses, correlated their marital satisfaction. They found that patients and spouses were generally satisfied with their marriages. Moreover, it was showed that lower marital satisfaction in patients was associated with higher education level, patient's greater use of escape into fantasy, patient's greater use of finding blame, and spouse's higher use of escape into fantasy. Spouses less satisfied with their marriages were more likely to use passive acceptance and less likely to find blame. Female spouses were less likely to be satisfied in their marriages than male spouses. They concluded that certain passive coping styles, more highly educated patients and female spouses are associated with lower marital satisfaction in persons with RA and their spouses.

Kraaiaat *et al*<sup>[5]</sup> studied whether physical disability, pain, depressive mood, and criticism by the spouse are differentially related to intrusiveness of RA on sexuality in male and female patients. They found that physical disability, pain, and, to a lesser extent, depression were found to contribute to intrusiveness of RA on sexuality. However, female patients, compared with male patients, appeared to have lower levels of mobility and self-care. They suggested that differences in sexual motivation between men and women might have been influential in the absence of gender differences in intrusiveness.

## TREATMENT RECOMMENDATIONS

One of the most important issues about the treatment of sexual dysfunction associated to RA is the fact that neither the sexual functioning is routinely addressed by physicians or health professionals, nor is it part of frequently used

**Table 1** Factors associated to sexual dysfunction in rheumatoid arthritis and recommendations for specific symptoms

Sexual dysfunction	Factors implicated	Recommendations
Sexual disability	Limited mobility	Change position
	Pain, fatigue	Analgesic, heat, and muscle
	Morning stiffness	Relaxation before activity
Dyspareunia	Vaginal dryness	Vaginal lubrication, estrogen cream
Diminished desire	Anxiety, depression	Counseling, antidepressive
Diminished satisfaction	Altered body image	Drugs <sup>1</sup>
Impotence	Hormonal imbalance	Sildenafil, sex therapy

<sup>1</sup>Could decrease libido (Modified from Ref<sup>[33]</sup>).

questionnaires to assess physical function or quality of life. For example, in Europe, United Kingdom health professionals should monitor the sexual activity of RA patients; however, a recent study showed that 66% of RA patients were never asked about the impact of RA on their sexual lives<sup>[23]</sup>. The common problem is communication, so an open communication including inquiry about sexuality in routine care is the first step to improve the situation. To allow the patients to present problems and concerns without embarrassment is also important. After an open communication is achieved, the treatment will depend on the specific patient's symptoms (Table 1). However, there are some general recommendations including: discussion of the problems with the partner, principally about the partner's fear in causing pain or distress during sexual intercourse; exploring different positions; using analgesic drugs, heat, and muscle relaxants before sexual activity in order to decrease pain; exploring alternative methods of sexual expression; and physiotherapy<sup>[32-34]</sup>.

## CONCLUSION

Sexual function in patients with rheumatoid arthritis has not been well studied. There are not enough studies comparing sexual functioning between RA patients and healthy controls and the impact of treatments usually used in RA in improving sexual function.

## REFERENCES

- Ostlere LS, Harris D, Sweny P, Rustin MH. Kaposi's sarcoma following renal transplantation. *Int J Dermatol* 1992; **31**: 439-440 [PMID: 1512104 DOI: 10.1016/j.beth.2004.01.002]
- Blake DJ, Maisiak R, Koplan A, Alarcón GS, Brown S. Sexual dysfunction among patients with arthritis. *Clin Rheumatol* 1988; **7**: 50-60 [PMID: 3409645 DOI: 10.1007/BF02284057]
- Hill RH, Herstein A, Walters K. Juvenile rheumatoid arthritis: follow-up into adulthood - medical, sexual and social status. *Can Med Assoc J* 1976; **114**: 790-796 [PMID: 1268790]
- Gordon D, Beastall GH, Thomson JA, Sturrock RD. Androgenic status and sexual function in males with rheumatoid arthritis and ankylosing spondylitis. *Q J Med* 1986; **60**: 671-679 [PMID: 3094090]
- Kraaijaat FW, Bakker AH, Janssen E, Bijlsma JW. Intrusiveness of rheumatoid arthritis on sexuality in male and female patients living with a spouse. *Arthritis Care Res* 1996; **9**: 120-125 [PMID: 8970270]
- Prady J, Vale A, Hill J. Body image and sexuality. In: Hill J, ed. *Rheumatology nursing: a creative approach*. Churchill Livingstone: Edinburgh, 1998: 109-124
- Wells D. *Caring for sexuality in health and illness*. Churchill Livingstone: Edinburgh, 2000
- Pitts M. *Sexual health: The psychology of preventative health*. London: Routledge, 1996
- Britto MT, Rosenthal SL, Taylor J, Passo MH. Improving rheumatologists' screening for alcohol use and sexual activity. *Arch Pediatr Adolesc Med* 2000; **154**: 478-483 [PMID: 10807299 DOI: 10.1001/archpedi.154.5.478]
- Ehrlich GE. Social, economic, psychologic, and sexual outcomes in rheumatoid arthritis. *Am J Med* 1983; **75**: 27-34 [PMID: 6660238 DOI: 10.1016/0002-9343(83)90472-2]
- Blake DJ, Maisiak R, Alarcón GS, Holley HL, Brown S. Sexual quality-of-life of patients with arthritis compared to arthritis-free controls. *J Rheumatol* 1987; **14**: 570-576 [PMID: 3625637]
- van Lankveld W, Ruiterkamp G, Näring G, de Rooij DJ. Marital and sexual satisfaction in patients with RA and their spouses. *Scand J Rheumatol* 2004; **33**: 405-408 [PMID: 15794200 DOI: 10.1080/03009740410010317]
- Channon LD, Ballinger SE. Some aspects of sexuality and vaginal symptoms during menopause and their relation to anxiety and depression. *Br J Med Psychol* 1986; **59** (Pt 2): 173-180 [PMID: 3730319 DOI: 10.1111/j.2044-8341.1986.tb02682.x]
- Frohlich P, Meston C. Sexual functioning and self-reported depressive symptoms among college women. *J Sex Res* 2002; **39**: 321-325 [PMID: 12545415 DOI: 10.1080/00224490209552156]
- Yoshino S, Uchida S. Sexual problems of women with rheumatoid arthritis. *Arch Phys Med Rehabil* 1981; **62**: 122-123 [PMID: 7235896]
- Bhadoria S, Moser DK, Clements PJ, Singh RR, Lachenbruch PA, Pitkin RM, Weiner SR. Genital tract abnormalities and female sexual function impairment in systemic sclerosis. *Am J Obstet Gynecol* 1995; **172**: 580-587 [PMID: 7856689 DOI: 10.1016/0002-9378(95)90576-6]
- Areskoug-Josefsson K, Öberg U. A literature review of the sexual health of women with rheumatoid arthritis. *Musculoskeletal Care* 2009; **7**: 219-226 [PMID: 19242923 DOI: 10.1002/msc.152]
- van Berlo WT, van de Wiel HB, Taal E, Rasker JJ, Weijmar Schultz WC, van Rijswijk MH. Sexual functioning of people with rheumatoid arthritis: a multicenter study. *Clin Rheumatol* 2007; **26**: 30-38 [PMID: 16508697 DOI: 10.1007/s10067-006-0216-3]
- de Avila Lima Souza L, Gallinaro AL, Abdo CH, Kowalski SC, Suehiro RM, da Silva CA, Goldenstein-Schainberg C. Effect of musculoskeletal pain on sexuality of male adolescents and adults with juvenile idiopathic arthritis. *J Rheumatol* 2009; **36**: 1337-1342 [PMID: 19411396 DOI: 10.3899/jrheum.080867]
- Packham JC, Hall MA, Pimm TJ. Long-term follow-up of 246 adults with juvenile idiopathic arthritis: predictive factors for mood and pain. *Rheumatology (Oxford)* 2002; **41**: 1444-1449 [PMID: 12468828 DOI: 10.1093/rheumatology/41.12.144]
- Foster HE, Marshall N, Myers A, Dunkley P, Griffiths ID. Outcome in adults with juvenile idiopathic arthritis: a quality of life study. *Arthritis Rheum* 2003; **48**: 767-775 [PMID: 12632431 DOI: 10.1002/art.10863]
- Karlsson B, Berglin E, Wållberg-Jonsson S. Life satisfaction in early rheumatoid arthritis: a prospective study. *Scand J Occup Ther* 2006; **13**: 193-199 [PMID: 17042467 DOI: 10.1080/11038120500462337]
- Hill J, Bird H, Thorpe R. Effects of rheumatoid arthritis on sexual activity and relationships. *Rheumatology (Oxford)* 2003;

- 42: 280-286 [PMID: 12595623 DOI: 10.1093/rheumatology/keg079]
- 24 **Yoshino S**, Fujimori J, Morishige T, Uchida S. Bilateral joint replacement of hip and knee joints in patients with rheumatoid arthritis. *Arch Orthop Trauma Surg* 1984; **103**: 1-4 [PMID: 6466058 DOI: 10.1007/BF00451311]
- 25 **Elst P**, Sybesma T, van der Stadt RJ, Prins AP, Muller WH, den Butter A. Sexual problems in rheumatoid arthritis and ankylosing spondylitis. *Arthritis Rheum* 1984; **27**: 217-220 [PMID: 6696775 DOI: 10.1002/art.1780270214]
- 26 **Ostensen M**, Almberg K, Koksvik HS. Sex, reproduction, and gynecological disease in young adults with a history of juvenile chronic arthritis. *J Rheumatol* 2000; **27**: 1783-1787 [PMID: 10914869]
- 27 **Gutweniger S**, Kopp M, Mur E, Günther V. Body image of women with rheumatoid arthritis. *Clin Exp Rheumatol* 1999; **17**: 413-417 [PMID: 10464550]
- 28 **Abdel-Nasser AM**, Ali EI. Determinants of sexual disability and dissatisfaction in female patients with rheumatoid arthritis. *Clin Rheumatol* 2006; **25**: 822-830 [PMID: 16521053 DOI: 10.1007/s10067-005-0175-0]
- 29 **El Miedany Y**, El Gaafary M, El Aroussy N, Youssef S, Ahmed I. Sexual dysfunction in rheumatoid arthritis patients: arthritis and beyond. *Clin Rheumatol* 2012; **31**: 601-606 [DOI: 10.1007/s10067-011-1891-2]
- 30 **Majerovitz SD**, Revenson TA. Sexuality and rheumatic disease: the significance of gender. *Arthritis Care Res* 1994; **7**: 29-34 [PMID: 7918723 DOI: 10.1002/art.1790070107]
- 31 **Bernas BL**, Tucker JS, Winkelman DK, Katz JN. Marital satisfaction in couples with rheumatoid arthritis. *Arthritis Care Res* 2000; **13**: 149-155 [PMID: 14635288]
- 32 **Panush RS**, Mihailescu GD, Gornisiewicz MT, Sutaria SH, Wallace DJ. Sex and arthritis. *Bull Rheum Dis* 2000; **49**: 1-4 [PMID: 11126624]
- 33 **Tristano AG**. The impact of rheumatic diseases on sexual function. *Rheumatol Int* 2009; **29**: 853-860 [PMID: 19152092 DOI: 10.1007/s00296-009-0850-6]
- 34 **Josefsson KA**, Gard G. Women's experiences of sexual health when living with rheumatoid arthritis--an explorative qualitative study. *BMC Musculoskelet Disord* 2010; **11**: 240 [PMID: 20950461 DOI: 10.1186/1471-2474-11-240]

**P- Reviewers:** Garip Y, Ravindran V, Wang F **S- Editor:** Wen LL  
**L- Editor:** O'Neill M **E- Editor:** Lu YJ



## Techniques and accuracy of thoracolumbar pedicle screw placement

Varun Puvanesarajah, Jason A Liauw, Sheng-fu Lo, Ioan A Lina, Timothy F Witham

Varun Puvanesarajah, Jason A Liauw, Sheng-fu Lo, Ioan A Lina, Timothy F Witham, Department of Neurosurgery, Johns Hopkins University School of Medicine, Baltimore, MD 21287, United States

**Author contributions:** Puvanesarajah V, Liauw JA, Lo SF, Lina IA and Witham TF contributed to research and writing of this manuscript.

Supported by Gordon and Marilyn Macklin Foundation

**Correspondence to:** Timothy F Witham, MD, Department of Neurosurgery, Johns Hopkins Hospital, 600 North Wolfe Street, Meyer 7-109, Baltimore, MD 21287, United States. [twitham2@jhmi.edu](mailto:twitham2@jhmi.edu)

Telephone: +1-410-5022383 Fax: +1-410-5023399

Received: November 30, 2013 Revised: February 11, 2014

Accepted: March 13, 2014

Published online: April 18, 2014

### Abstract

Pedicle screw instrumentation has been used to stabilize the thoracolumbar spine for several decades. Although pedicle screws were originally placed *via* a free-hand technique, there has been a movement in favor of pedicle screw placement with the aid of imaging. Such assistive techniques include fluoroscopy guidance and stereotactic navigation. Imaging has the benefit of increased visualization of a pedicle's trajectory, but can result in increased morbidity associated with radiation exposure, increased time expenditure, and possible workflow interruption. Many institutions have reported high accuracies with each of these three core techniques. However, due to differing definitions of accuracy and varying radiographic analyses, it is extremely difficult to compare studies side-by-side to determine which techniques are superior. From the literature, it can be concluded that pedicles of vertebrae within the mid-thoracic spine and vertebrae that have altered morphology due to scoliosis or other deformities are the most difficult to cannulate. Thus, spine surgeons would benefit the most from using assistive technologies in these circumstances. All other pedicles in the

thoracolumbar spine should theoretically be cannulated with ease via a free-hand technique, given appropriate training and experience. Despite these global recommendations, appropriate techniques must be chosen at the surgeon's discretion. Such determinations should be based on the surgeon's experience and the specific pathology that will be treated.

© 2014 Baishideng Publishing Group Co., Limited. All rights reserved.

**Key words:** Thoracic vertebrae; Lumbar vertebrae; Pedicle screw; Fluoroscopy; Computed tomography

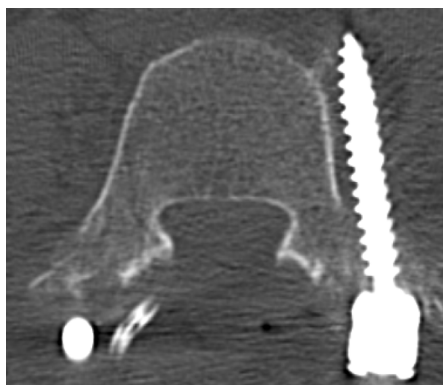
**Core tip:** Pedicle screws are currently placed in the thoracolumbar spine via three main techniques: free-hand, fluoroscopy guidance, and stereotactic navigation. Various studies have reported success with each of these techniques. However, it is clear that there is some difficulty in comparing such studies due to differing definitions of accuracy and methods of evaluation. Regardless, it is evident that image-assisted techniques provide some benefit when cannulating mid-thoracic vertebral levels and vertebrae that have altered morphology due to deformation from complex pathologies. However, a surgeon's ultimate decision must be based on individual experience and comfort with a given technique.

Puvanesarajah V, Liauw JA, Lo SF, Lina IA, Witham TF. Techniques and accuracy of thoracolumbar pedicle screw placement. *World J Orthop* 2014; 5(2): 112-123 Available from: URL: <http://www.wjgnet.com/2218-5836/full/v5/i2/112.htm> DOI: <http://dx.doi.org/10.5312/wjo.v5.i2.112>

### INTRODUCTION

Since it was first described by Boucher<sup>[1]</sup> in the 1950s,





**Figure 1** Axial computed tomography image depicting lateral breach of a pedicle screw intended for the L4 vertebrae.

used more extensively by Roy-Camille *et al*<sup>[2]</sup> later in the 1960s and 1970s, and then downclassified from an FDA Class III to Class II device in 1998, pedicle screw instrumentation has been steadily gaining popularity. This technology is now almost exclusively used when securing fusion constructs in the thoracolumbar spine, due to the purported improved fusion rates and rigidity afforded by these constructs<sup>[3-9]</sup>. Furthermore, studies have found that pedicle screws are biomechanically advantageous when compared to predecessors, including previous rod and hook systems<sup>[10-12]</sup>. Furthermore, pedicle screws are generally considered to be safer than other constructs, including sublaminar wiring, which often necessitate placement of instrumentation within the spinal canal with resultant neurological risk<sup>[13]</sup>.

Initially, pedicle screws were used more frequently in the lumbar spine, where pedicles are thicker and thus easier to cannulate and generally have trajectories that do not skirt important neural or vascular structures. In particular, these lower spinal levels are less susceptible to serious neural damage from medially directed screws, as components of the cauda equina are much less prone to damage<sup>[14]</sup>. However, the inherent biomechanical advantages of pedicle screws led to their adoption in the thoracic spine. In the thoracic spine, there is admittedly a much lower margin of error, as errant screws are capable of injuring the spinal cord and other structures intimately related to the vertebrae, including the thoracic pleura, esophagus and intercostal and segmental vessels. Other structures within the thoracic cavity at risk include the thoracic duct, azygous vein, inferior vena cava, and aorta<sup>[15]</sup>.

Placement of thoracic pedicle screws can be even more challenging as the thoracic vertebrae tend to be more anatomically varied than lumbar vertebrae when considering pedicle angles and attachment to the vertebral body<sup>[16]</sup>. This is particularly observed at the middle thoracic levels (T3-T9), which have the narrowest pedicles and have decreased space between the medial border of the pedicle and spinal cord<sup>[17-19]</sup>. Studies have estimated that screws placed in this region have a 1 mm translational margin of error and a maximal permissible rotational

error of 5° off the pedicular axis, due to anatomically small pedicle diameters<sup>[17]</sup>. Apart from complexity associated with normal anatomy, pedicles can be difficult to instrument due to presenting pathologies. In patients with significant scoliosis, rotation and asymmetric compression of vertebrae can significantly alter pedicle anatomy and complicate pedicle screw placement<sup>[20]</sup>. Surgeons must be cognizant of such asymmetries intraoperatively as there is little margin for error in optimal screw placement in the thoracic spine. In reality, there are three general technique classes currently used by surgeons for placement of pedicle screws. Techniques can be classified as either free-hand (*i.e.*, without the aid of any imaging) or assisted with either fluoroscopy or stereotactic navigation technology. Free-hand technique relies on appreciation of normal and abnormal spinal anatomy, as the surgeon is entirely reliant on pre-operative imaging and intra-operative anatomical landmarks. Assistive fluoroscopy and navigation are helpful in that they guide pedicle screw placement more or less in real time, but are limited by time costs and in the case of fluoroscopy, significant radiation exposure.

Assistive techniques were designed to decrease the breach rate and improve pedicle screw placement accuracy. However, it is unclear whether assistive technologies actually decrease cortical breach and improve outcomes when compared to free-hand techniques. There have been many studies both illustrating institutional practices and pedicle screw placement accuracy, but due to differing definitions of breach and the lack of explicit control groups, many of these studies are difficult to interpret. In this review, we first define different methods of assessing cortical breach of pedicle screws and summarize the literature to date concerning pedicle screw placement accuracy by these various techniques. From this analysis, we hope to make conclusions regarding the necessity of assistive technology when placing pedicle screws in the thoracolumbar spine.

## BREACH CLASSIFICATION

As mentioned previously, incorrect placement of pedicle screws (Figure 1) is a potential source of great patient morbidity. As such, there has been a large volume of data concerning how best to interpret pedicle screw cortical breaches. Several metrics have been applied to characterize cortical breach. These metrics vary slightly when applied in studies from different institutions, which adds an extra level of difficulty when comparing study results. However, they often all require the use of postoperative CT scans, which are generally accepted as being the most beneficial imaging study when judging pedicle screw accuracy<sup>[21-25]</sup>.

In essence, variations of two grading scales are currently used to describe pedicle screw placement. In the first, which is often referred to as the Gertzbein scale, cortical breaches are described by the extent of extra-cortical screw violation. In this system, Grade 0 screws are

**Table 1 Gertzbein classification<sup>[5]</sup>**

Grade	Breach distance
0	0 mm (no breach)
1	< 2 mm
2	2-4 mm
3	> 4 mm

those that are fully contained within a pedicle with no evidence of cortical breach, while higher grades are assigned in breach distances of multiples of 2 mm, where distance is measured from the medial border of the pedicle (Table 1)<sup>[5]</sup>. This scale was first applied when assessing screws placed from T8 to S1. During this initial application, the scale was intended to only assess the degree of spinal canal encroachment, as lateral screws were excluded from graded classification. A later study by Youkilis *et al*<sup>[14]</sup> slightly altered this classification to specify three different grades: Grade 1 screws did not show evidence of pedicle breach, Grade 2 screws breached 2 mm or less, and Grade 3 screws were those that breached more than 2 mm. However, recent studies have expanded on the original Gertzbein scale by applying it in every direction of possible cortical breach. One more recent study pioneered the use of this graded classification in each of six possible directions of cortical breach: anterior, lateral, medial, inferomedial, inferolateral, and superior. As such, each screw was given six different grades ranging from 0-3<sup>[25]</sup>.

In practice, multiple studies have used variations of the Gertzbein classification and initial assertions from his pioneering study have been used to define pedicle screw accuracy. Gertzbein and Robbins noted that at the levels investigated by the authors, cortical breaches of greater than 4 mm were associated with neurologic deficits, leading them to conclude that this 4 mm range may constitute a “safe zone” for screws placed from T10 to L4<sup>[5]</sup>. Other studies have similarly termed breaches ranging from 2 mm medially and 4 mm laterally as a “safe zone”<sup>[26]</sup>. However, these safe zone definitions reflect opinions that have not necessarily been substantiated by specific data or facts.

A study conducted by Heary *et al*<sup>[22]</sup> noted that such grading of inaccurate screw placement may not be representative of clinical repercussions of cortical breaches. In particular, the thoracic spine is characterized by pedicle-rib complexes, where laterally penetrating pedicle screws can often be contained within the posterior rib. In fact, the study’s authors considered lateral breach at mid-thoracic and lower thoracic regions to be sometimes optimal, as additional bony rib purchase could theoretically increase pullout strength. As such, at these levels, they advocated for the use of larger screws at these levels with the intention of lateral pedicle breach. At T1 or T2, where nerve root injury was a greater concern due to their role in upper extremity function, smaller screws were purposefully used to more easily keep screws within the pedicles. The Heary classification is summarized in

**Table 2 Heary classification<sup>[22]</sup>**

Grade	Breach
1	None
2	Lateral, but screw tip is within VB
3	Anterior or lateral breach of screw tip
4	Medial or inferior breach
5	Breach that requires immediate revision (due to proximity to sensitive structures)

Table 2. In essence, this classification scheme serves to stress that some screws require immediate removal due to proximity to critical structures (Grade 5), while other screws that breach laterally but are still contained within the rib may be acceptable (Grade 2). Additionally, this scheme was novel in that it was the first classification that graded anterior breaches, *i.e.*, those through the vertebral body (Grade 3). This scale is limited in that it doesn’t consider the metric extent of breach in any direction, although this is somewhat rectified by the Grade 5 classification, which is ultimately most clinically relevant<sup>[22]</sup>.

Other classification schemes include methods that grade screws as either “in” or “out” by using a cortical breach threshold defined by the amount of the screw’s diameter that exists outside of the pedicle. The most notable example of this technique was illustrated in a study that defined breached screws as those where 25% of the screw diameter was located outside of the pedicle. In this study, it was theorized that CT-related metal artifact, which was estimated to distort perceived screw location by 25% of the diameter of the screw, could skew perception of cortical breach<sup>[27]</sup>. Importantly, this particular breach classification appropriately adjusts for screws that increase in size at lower vertebral levels. However, this classification is not often used due to the frequent usage of the Gertzbein classification scheme.

## PEDICLE SCREW PLACEMENT TECHNIQUES

In the following section, we briefly review each of the three major classes of techniques: free-hand, fluoroscopy-guided, and stereotactic navigation. In these sections, we describe each technique and discuss some of the salient pros and cons associated with each technique. Furthermore, studies reporting isolated use of each technique are provided in a tabular format to demonstrate institutional success with a given technique and associated concerns. Comparison studies are also provided when available. For each study, accuracies and revision rates are listed. Some studies reported multiple accuracy measurements. For these studies, accuracies that were defined by the lowest margin of error were tabulated.

### FREE-HAND TECHNIQUE

Free-hand pedicle screw placement relies on an intricate

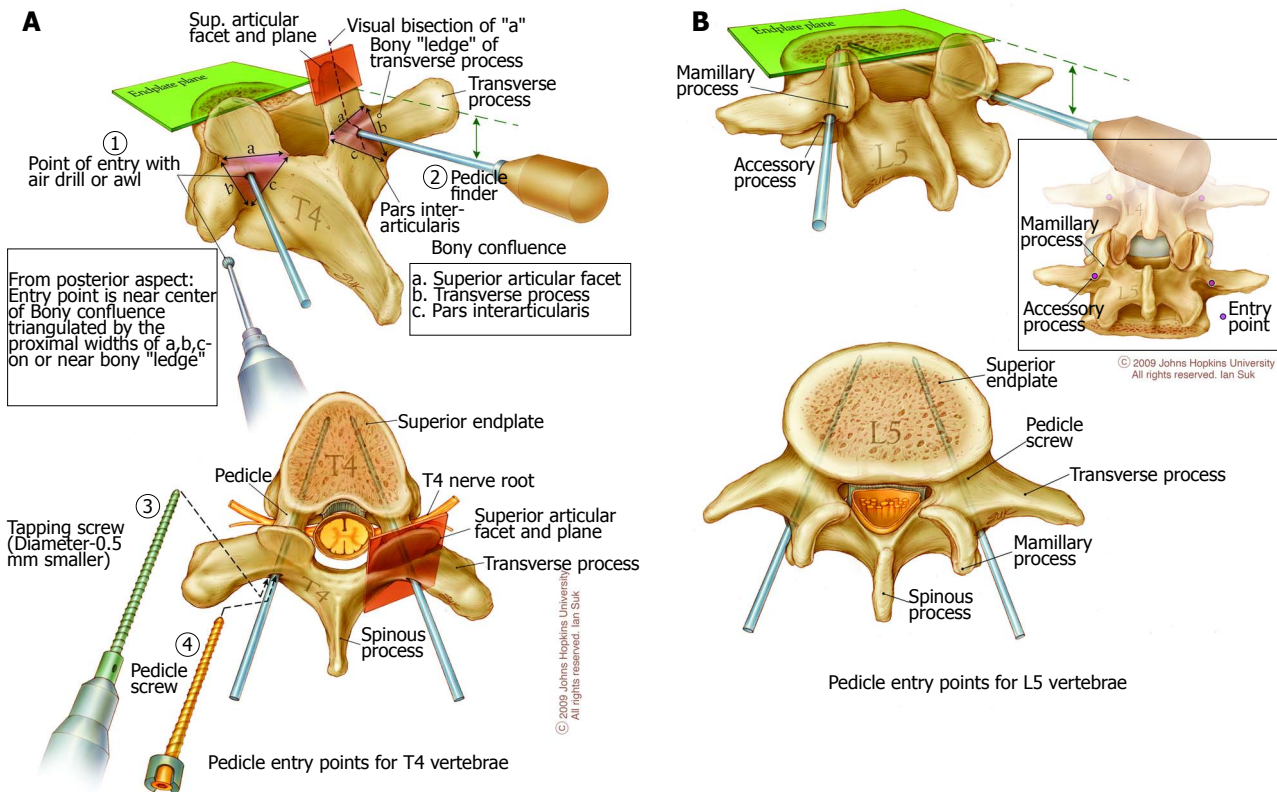


Figure 2 Artist depiction of the entry site used in the T4 (A) and L5 (B) vertebrae. Image has been reproduced from manuscript published by Parker *et al*<sup>[27]</sup>.

appreciation of the relationship of various anatomical landmarks at each level of the thoracolumbar spine. Analogous entry sites guided by differential anatomy are utilized for both the thoracic and lumbar spine. These anatomical sites are specified in such a way that allows direct trajectory along the pedicle axis, providing maximal screw stability. Before targeting an initial entry site, an intraoperative localizing radiograph is often performed to assess spinal alignment.

In the thoracic spine, the lower border of the superior articular facet, the medial border of the transverse process, and the pars interarticularis form a triangle, the center of which should be targeted for initial entry (Figure 2A)<sup>[27]</sup>. This has been variably reported as “the base of the superior articular process at the junction of the lateral one-third and medial two-thirds<sup>[28]</sup>.” Within the thoracic spine, entry sites tend to be more medial and cephalad when progressing from T12 to T7. Above T7, entry sites tend to be more lateral and caudad<sup>[29]</sup>. In the thoracic spine, the “in-out-in” technique, where screws are intentionally placed more laterally to decrease the risk of medial breach and potentially increase bony rib purchase, is often also utilized. The “in-out-in” technique can also be used in situations where patients have congenitally small thoracic pedicles

In the lumbar spine, the entry site is located at the intersection of the bony confluences of the pars interarticularis, the transverse process, and the mammillary process of the vertebrae that will be instrumented (Figure 2B)<sup>[27]</sup>. In patients with degenerative joint disease that precludes

adequate pedicle screw stability at this location, an appropriate entry site would be one that is further medial, at the inferior border of the superior articular process<sup>[27]</sup>.

After using a drill or awl to create a hole at the thoracic pedicle entry site, a trajectory that parallels the superior endplate is often used due to biomechanical superiority over more anatomical trajectories<sup>[30]</sup>. A curved gear shaft pedicle probe should first be directed laterally to avoid medial breach for approximately 15-20 mm. This distance represents a distance just past the widest portion of the spinal canal. At this point, the risk of medial breach is decreased significantly and the probe or drill can be directed more medially to prevent lateral breach. After assessing the integrity of the tract with a feeler, it is optional to first use a “tap” to determine if the screw tract is correct and appropriately directed, before using the final, larger screw.

There have been several studies that have investigated the accuracy of free-hand techniques for pedicle screw placement. Selected studies from the last ten years that reported case series where screw placement was only performed *via* the free-hand method are reported in Table 3. In these studies, accuracy rates ranged from 71.9% to 98.3%<sup>[5,9,23,26,27,31-33]</sup>. Of note, the lowest accuracies were associated with the mid-thoracic spine. In particular, Parker *et al*<sup>[27]</sup> found that screws inserted into T4 and T6 were most likely to breach, while Modi *et al*<sup>[26]</sup> found that screws inserted into the pedicles of T5-T8 had a greater incidence of breaches, particularly those that breached beyond a 6-mm wide safe zone. Furthermore, as expected, free-hand techniques have been noted to have a



**Table 3** Summary of studies that have evaluated free-hand pedicle screw placement

	Most common pathology	Screw location	Number of patients	Number of screws	Accuracy (%)	Revision rate (%)
Gertzbein <i>et al</i> <sup>[5]</sup> , 1990	Trauma	T8-S1	40	167	71.9	N/A
Liljenqvist <i>et al</i> <sup>[9]</sup> , 1997	Scoliosis	T4-T12	32	120	75.0	N/A
Kim <i>et al</i> <sup>[23]</sup> , 2004	Scoliosis	T1-T12	Unclear	577	93.8	0
Karapinar <i>et al</i> <sup>[31]</sup> , 2007	Trauma	T10-L3	98	640	94.2	0
Schizas <i>et al</i> <sup>[32]</sup> , 2007	Trauma	T1-T6	13	60	88.3	0
Kotil <i>et al</i> <sup>[33]</sup> , 200	Trauma	T1-L5	Unclear	368	93.5	1.5
Modi <i>et al</i> <sup>[26]</sup> , 2009	Scoliosis	T1-T12	43	854	93.0	N/A
Parker <i>et al</i> <sup>[27]</sup> , 2011	Degenerative/Deformity	T1-S1	964	6816	98.3	0.8

N/A: Not applicable.

significant learning curve. In one particular study, accuracy rates were observed to increase when comparing the accuracy rate of the entire study (71.9%) to that of only the last 25% of placed screws (84.0%)<sup>[5]</sup>.

The greatest benefit from usage of a free-hand technique lies in decreased radiation exposure and decreased procedure time. Both increased radiation exposure and operative time will be discussed at length in later sections that review both fluoroscopy and navigation techniques.

## FLUOROSCOPY-GUIDED

Free-hand pedicle screw placement is essentially a blind technique that relies on correct identification of anatomical landmarks, surgeon experience, and reproducible technique to ensure adequate screw placement. As such, early on, the learning curve associated with usage of this technique became apparent, leading to increased surgeon-usage of image-assisted techniques. One such assistive technology is intraoperative fluoroscopy. Intraoperative fluoroscopy relies on serial X-rays to allow surgeons to view a screw's trajectory in real time. Fluoroscopy is used so often during pedicle screw placement that it has been referred to as the "conventional" method, perhaps reflecting its almost expected usage when attempting to employ free-hand techniques<sup>[34,35]</sup>.

Fluoroscopy often utilizes a C-arm to take AP and lateral images parallel to the superior endplate. After an entry site hole is created using anatomic landmarks as described above, it is subsequently marked and the C-arm is utilized in either a lateral plane, anterior-posterior plane, or a combination of both at the level to be instrumented. Subsequent serial images guide surgeon screw placement.

Fluoroscopy has a much lower associated learning curve when compared to free-hand pedicle screw placement. In theory, the breach rate should be lower as fluoroscopy can give surgeons a chance to correct errors while the surgical field is still open. However, this added safety mechanism comes at a cost. The use of intraoperative fluoroscopy is associated with increased operating times and increased radiation exposure. Increased operating times are mostly due to the time it takes to request a technician and subsequently set-up a C-arm, including sterile draping and positioning of the device at the correct location. Additionally, each use of the C-arm requires

movement of the equipment into the surgeon's working field, disrupting the workflow and thus increasing operating time. Apart from trivial decreases in efficiency, increased operating times are associated with very real clinical consequences for patients. Increased operating times have been associated with increased incidences of surgical site infection<sup>[36]</sup>.

The radiation risk associated with fluoroscopy during pedicle screw placement has been well-studied in the literature. This risk exists for both the patient and the surgeon, the latter of whom arguably has a greater chance for later development of adverse side effects. Three studies have used anthropomorphic phantoms to approximate radiation exposure in patients treated with pedicle screws guided via intraoperative fluoroscopy<sup>[37-39]</sup>. In the most recent study, the study's authors first acquired radiation exposure data (including total duration of radiation exposure, parameters associated both AP and lateral images, and the cumulative dose-area product) from 20 patients undergoing procedures requiring pedicle screw instrumentation. Using this data, the authors subsequently treated anthropomorphic phantoms with embedded dosimeters with radiation beams to represent clinical operative exposure. From this experimentation, they were able to approximate the radiation dosage experienced by various organ systems. The study found that on average 4.8 pedicle screws were placed, with the average pedicle screw placement requiring 1.2 and 2.1 min of AP and lateral radiation exposure. When the applicable dose was applied to the anthropomorphic phantom, radiation doses were centered over L4, which the study found to be the most common location of screw placement. This resulted in a mean dose of 1.5 mSv<sup>[37]</sup>, which is comparable to radiation doses postulated by other studies that have noted mean effective doses of 6.8 mSv<sup>[38]</sup> and 1.0 mSv<sup>[39]</sup>, which as expected are somewhat dependent on the number of pedicle screws used and the time it takes to seat a pedicle screw, the latter of which can be directly attributable to surgeon experience. Perisinakis *et al*<sup>[37]</sup> estimated that the adjusted risk of fatal cancer in patients receiving an average of 4.8 pedicle screws at the L4 level was about 110 per million, which when compared to a spontaneous cancer risk of 200000 per million is fairly insignificant.

This data suggests that radiation exposure during fluoroscopy is not a relevant consideration when evaluating



**Table 4 Summary of studies evaluating fluoroscopy-aided pedicle screw placement**

	Most common pathology	Screw location	Number of patients	Number of screws	Accuracy (%)	Revision rate (%)
Halm <i>et al</i> <sup>[44]</sup> , 2000	Scoliosis	T10-L4	12	104	81.7	8.3
Belmont <i>et al</i> <sup>[7]</sup> , 2001	Scoliosis	T1-T12	40	279	57.0	5.0
Carbone <i>et al</i> <sup>[45]</sup> , 2003	Trauma	T1-T12	22	126	86.5	N/A
Kuntz <i>et al</i> <sup>[46]</sup> , 2004	Trauma	T1-T12	28	199	27.6	N/A
Vougioukas <i>et al</i> <sup>[47]</sup> , 2005	Degenerative	T1-T12	41	328	78.0	0.0
Amato <i>et al</i> <sup>[48]</sup> , 2010	Degenerative	L1-S1	102	424	92.2	8.8

N/A: Not applicable.

the merits of this assistive modality during pedicle screw placement. However, it must be noted that these cancer risks are heightened in pediatric populations and patients who have much larger numbers of pedicle screws placed. As such, patients with adolescent idiopathic scoliosis and other significant deformities should be considered at increased risk, although likely still significantly less risk than that incurred from daily living<sup>[37]</sup>.

Although patient radiation exposure is a significant consideration, it is arguable that cumulative surgeon radiation exposure from years of instrumentation procedures is a much more pressing concern. In one study that placed a dosimeter both inside and outside of the thyroid shield to approximate whole-body and thyroid radiation doses, respectively, it was determined that within ten years, a thirty-year old surgeon would supersede the maximum allowable whole body radiation dosage<sup>[40]</sup>. However, this study did not take into account the dose reduction that occurs through wearing a lead apron, which is estimated to be around 94%<sup>[41]</sup>. The study further found that thyroid doses were significantly lower than the threshold suggested by the same organization. Hands, on the other hand, are subjected to radiation doses without any real lead protection and undoubtedly receive a significant radiation dose<sup>[42]</sup>.

In recognition of this potential safety issue, studies have postulated that minimizing fluoroscopic time and moving away from beam sources may be indicated to decrease surgeon radiation exposure<sup>[43]</sup>. Hand doses can be reduced with lead impregnated gloves, which reduce radiation exposure by 33%<sup>[42]</sup>. Though most studies have focused on surgeon radiation exposure, it is also important to note that other individuals on a surgical team are at similar risk for heightened radiation doses<sup>[43]</sup>.

Studies have generally shown that accuracy rates of screws placed with this technique have ranged from as low as 27.6% to above 90%. These results are summarized in Table 4, which lists a series of publications that reported institutional experience with only fluoroscopic guided pedicle screw technique<sup>[7,44-48]</sup>. The accuracy range observed here is extended by a study by Kuntz *et al*<sup>[46]</sup>, which reported absence of cortical breach in only 27.6% of studied screws. This rate is substantially lower than that reported in other studies that used intraoperative fluoroscopy to guide thoracic screws, owing to the fact that a majority of the screws included in this study were placed in the mid-thoracic region (T3-T9), a region with

proven screw placement difficulty, and that many of the screws were purposefully chosen such that their diameters were larger than corresponding pedicle widths (for purported increased pullout strength).

Interestingly enough, the combination of narrow pedicles and difficult pedicle trajectories in the mid-thoracic spine again resulted in the greatest number of misplaced pedicle screws. The same Kuntz study noted that “high-risk medial wall perforation” was observed much more frequently when trying to place screws into the pedicles of T3-T9<sup>[46]</sup>.

In addition to its use with open techniques, fluoroscopy is often also used with percutaneous pedicle screw placement. Percutaneous screws placed under fluoroscopic guidance have been shown to be as least as accurate as screws placed with open techniques, if not more accurate<sup>[49-52]</sup>.

## IMAGE-GUIDED OR STEREOTACTIC PEDICLE SCREW PLACEMENT

Stereotactic neurosurgical techniques were first applied during cranial procedures before being applied in the spinal axis, an inherently complex structure due to numerous degrees of freedom. Stereotactic guidance requires initial image registration for eventual computer model generation. This computer-generated structure must then be matched to the actual operating room volume space by way of fiducial markers placed on prominent bony landmarks, a spinal reference marker, and subsequent matching of these points to analogous points on the generated image. This process was originally accomplished with a pre-operative CT and then surgeon matching of points on the computer-generated image to anatomical points on the patient<sup>[53]</sup>. From the reference marker, “virtual” fiducial markers, and strategically placed cameras in the operating room, a surgeon’s instruments can be triangulated and displayed relative to a 3D reconstruction displayed on a screen within the operating room. This allows the surgeon to plan screw entry site and adjust the trajectory of screws in real-time.

However, with increased use of fluoroscopy and more recently intraoperative CT scans, both the reference marker and fiducials are now often placed on bony landmarks prior to image acquisition within the operating room. This prevents any inaccuracy that might result

from re-positioning of the patient that undoubtedly occurs between pre-operative CT scans and transition to the operating table<sup>[54]</sup>. Fluoroscopy, as it was first pioneered, only captures images in the lateral and AP planes. As such, appreciation of pedicular structure is typically limited to only two planes. The development of intraoperative 3D imaging techniques has given surgeons the ability to navigate in a truly three-dimensional fashion, without the inaccuracy of images generated by preoperative scans. Recently, intraoperative CT scanners and O-arms have been used more frequently for pedicle screw navigation purposes.

In its infancy, navigated pedicle screw placement was limited by poor image registration due to re-positioning after pre-operative CTs and computing power. However, currently, these limitations are relatively non-existent with the development of sophisticated intraoperative CT and O-arm technology. Regardless, there are still some clear limitations associated with the technique. For example, image-guided techniques have been associated with decreasing accuracy with increasing distance from the spinal reference marker<sup>[54-55]</sup>. Furthermore, it is reasonable to believe that the process of tapping vertebrae and placing screws can cause motion of vertebral segments relative to one another and can also result in adventant movement of the reference arc. To circumvent any errors caused by such motion, more frequent auto registration verification steps must be taken, which can add time to procedures. Scheufler *et al*<sup>[55]</sup> further noted that certain inaccuracies pertaining to CT image registration exist with respiration, which moves the entire vertebral column. This was most notable at the mid-thoracic levels. Theoretically, ventilation could be halted during image acquisition, although this carries its own risks.

One of the more prominent criticisms of image-guided techniques centers on associated workflow interruption and additional time costs when compared to free-hand techniques. Much time is spent on vertebral registration and assessing image quality, which can vary from patient to patient. However, some studies have noted that surgical navigation systems used by well-trained operating room staff can decrease surgical time when compared to usage of intraoperative fluoroscopy<sup>[56]</sup>. Another possible criticism is the exorbitant cost associated with purchase and installation of an image-guided surgical suite.

As mentioned earlier, fluoroscopy-guided pedicle screw placement has been associated with increased radiation exposure to both the operating room staff and the patient. Since image registration occurs fairly infrequently, as compared to fluoroscopy shots, there is very little radiation exposure to operating room staff and the surgeon. In particular, there is theoretically much less radiation exposure to the surgeon's hands, which are probably the most exposed area during fluoroscopic-guided techniques. During image registration via intraoperative imaging, both the surgeon and operating staff can move safely away from the radiation source. However, these

techniques, which often rely on CT-based image registration, still result in increased radiation exposure to the patient. Recent technological developments, such as helical CT, can potentially limit this radiation risk to the patient<sup>[57]</sup>.

Studies evaluating the individual use of image-guided techniques have reported accuracy rates ranging from 91.5%-97.7% (Table 5)<sup>[14,53-55,58-62]</sup>. These rates are subjectively much higher on average than the rates observed for both free-hand and fluoroscopy-guided screw placement. Again, perforation rates were higher in the mid-thoracic spine<sup>[14]</sup>.

Navigation techniques have also benefited from direct comparisons with other techniques in both retrospective and prospective institutional studies with multiple treatment groups (Table 6)<sup>[34,35,56,63-66]</sup>. These studies have almost unilaterally shown that image-guided techniques have improved accuracy when compared to fluoroscopy-based<sup>[34,35,56,64-66]</sup> and free-hand techniques<sup>[63]</sup>. Of interest, one study by Waschke *et al*<sup>[66]</sup> directly calculated the improvements in accuracy that were observed with CT-navigated pedicle screw placement in both the thoracic and lumbar spine. In the lumbar spine, accuracy improvements were marginal, with a reported accuracy of 96.4% with CT-navigation, as compared to 93.9% with fluoroscopy. However, in the thoracic spine, CT-navigation was associated with a breach rate of 4.5%, while fluoroscopy resulted in breached screws 21.0% of the time, suggesting that image-guided techniques have much higher benefit when applied in the thoracic spine. CT-navigation may similarly be advantageous over fluoroscopy in the context of minimally invasive screws<sup>[67]</sup>.

## DISCUSSION

Regardless of technique, pedicle screw-based instrumentation remains one of the strongest posterior fixation techniques for the thoracolumbar spine. In essence, it is only limited by the risk of patient morbidity due to errant screw placement. As such, techniques such as fluoroscopy and stereotactic screw placement have come in vogue to improve on free-hand technique. In combination, all three techniques have resulted in impressive pedicle screw accuracies. A recent meta-analysis investigating studies published between 1990 and 2009 demonstrated that 89.2% of 7533 pedicle screws were placed accurately<sup>[68]</sup>.

For the most part, pedicle screw placement technique as it is practiced today anecdotally appears to be based more or less on institutional practices and surgeon preference. Understandably, there has been a recent push across the field for usage of more guided techniques, to instill confidence and assure the best patient outcome. In keeping with this message, published data has generally reported improved pedicle screw accuracy with such techniques. However, it must be noted that accuracy data from studies must be interpreted. As mentioned before, studies invariably have different metrics for assessing screw accuracy and thus may present improved institu-

**Table 5 Summary of studies evaluating navigation-aided pedicle screw placement**

	Most common pathology	Screw location	Number of patients	Number of screws	Accuracy (%)	Revision rate (%)
Idler <i>et al</i> <sup>[53]</sup> , 1996	Postlaminectomy instability and spinal stenosis	L1-S1	30	139	95.7	N/A
Youkilis <i>et al</i> <sup>[14]</sup> , 2000	Assorted	T1-T12	52	224	91.5	N/A
Bledsoe <i>et al</i> <sup>[58]</sup> , 2009	Cervical deformity	T1-T3	34	150	93.3	0
Nottmeier <i>et al</i> <sup>[59]</sup> , 2009	Unclear	T1-S1	184	951	92.5	N/A
Oertel <i>et al</i> <sup>[60]</sup> , 2011	Degenerative Disease	T8-S1	50	278	96.8	0
Scheufler <i>et al</i> <sup>[55]</sup> , 2011	Idiopathic and Degenerative Deformity	T2-S1	46	Ta-243 LSb-542	T-96.5 LS-94.4	4.3
Dinesh <i>et al</i> <sup>[54]</sup> , 2012	Metastasis	T1-T12	43	261	97.3	1.5 (intraop) 1.2 (postop)
Lee <i>et al</i> <sup>[61]</sup> , 2013	Degenerative Spondylolisthesis	T1-S1	178	932	96.8	1.4
Ling <i>et al</i> <sup>[62]</sup> , 2013	Degenerative Disease	T5-S1	92	467	95.3	1.3 (intraop)

T: Thoracic spine; LS: Lumbosacral spine; N/A: Not applicable.

**Table 6 Studies comparing navigation methods to either free-hand or fluoroscopic methods**

	Most common pathology	Screw location	Method	Patients (n)	Screws (n)	Revision rate (%)	Accuracy (%)	Method	Patients (n)	Screws (n)	Revision rate (%)	Accuracy (%)	Study design
Amiot <i>et al</i> <sup>[34]</sup> , 2000	Degenerative disease	T2-S1	CT-navigation	50	294	0	95	Fluoroscopy	100	544	2	85.0	R, P
Laine <i>et al</i> <sup>[63]</sup> , 2000	Spinal stenosis	T8-S1	CT-navigation	41	219	4 (intraop)	95.4	Free-hand	50	277	0 (intraop)	86.8	P
Rajasekaran <i>et al</i> <sup>[56]</sup> , 2006	Deformity	T1-T12	Fluoroscopy-navigation	17	242	N/A	98	Fluoroscopy	16	236	N/A	77.0	P
Merloz <i>et al</i> <sup>[35]</sup> , 2007	Trauma and degenerative disease	T8-L5	Fluoroscopy-navigation	26	140	N/A	95	Fluoroscopy	26	138	N/A	87.0	R
Tormenti <i>et al</i> <sup>[64]</sup> , 2010	Deformity	T1-S1	CT-navigation	12	164	0	98.8	Fluoroscopy	14	211	7.1	94.8	R
Shin <i>et al</i> <sup>[65]</sup> , 2013	Degenerative disease	T9-S1	O-arm navigation	20	124	5 (intraop)	91.9	Fluoroscopy	20	138	5 (postop)	87.7	P
Waschke <i>et al</i> <sup>[66]</sup> , 2013	Trauma and degenerative disease	T1-S1	CT-navigation	505	2422	1.2	L-96.4 T-95.5	Fluoroscopy	501	2002	4.4	L-93.9 T-79.0	R

R: Retrospective; P: Prospective; N/A: Not applicable.

tional accuracies with certain techniques solely due to differing interpretations of misplacement or breach. A clear example of this is the usage of accuracy to variably represent everything from placement of the entire screw within the pedicle to placement of the screw within a six millimeter wide “safe zone” (four mm laterally and two mm medially)<sup>[26]</sup>. The concept of a “safe zone” has been based on previous assertions by Gertzbein *et al*<sup>[5]</sup> that there is a total of 4 mm of allowable medial pedicle screw encroachment within the lower thoracic spine and lumbar spine consisting of 2 mm of epidural space and 2 mm of subarachnoid space. In the thoracic spine, this “safe zone” has been generally decreased to 2 mm to reflect both reduced margin of error<sup>[17]</sup> and to adjust for cortical expansion and benign pedicle fracture<sup>[7]</sup>. Regardless of previous literature examinations of this notion of a “safe zone”, it is important to point out that the “safe zone” is fairly arbitrary and warrants discussion of the true necessity of its existence as a conceptual entity. A more realistic measure would be revision rates or patient morbidity, which are direct clinical entities that are not re-

flected in reported accuracy rates. Both morbidity and revision rates are much lower than reported accuracy rates, suggesting that perhaps ever increasing accuracy rates might be associated with diminishing returns in terms of patient outcomes. One last consideration that provides added difficulty in comparing and interpreting reported accuracies is that accuracy rates have a large dependence on the relative proportions of various instrumented levels. A preponderance of lumbar screws, for example, invariably inflates accuracy as these vertebrae tend to have much larger pedicles that are easier to instrument when compared to those in thoracic vertebrae. Due to these reasons, systematic reviews are not completely effective at painting a complete picture when comparing pedicle screw placement, although several have been published<sup>[69,70]</sup>.

As alluded to earlier, the study of pedicle screw placement techniques and their relative accuracies is important in terms of revision of faulty screws. In the literature, screw revision rates are low and generally occur less than once out of every forty pedicle screws placed<sup>[55,64,71-73]</sup>.

However, screw revision can be difficult and time-consuming, as the faulty screw track often hinders effective screw repositioning<sup>[61]</sup>. When considering screw revision time and possible decreases in biomechanical stability, it is reasonable to use image-guided techniques when there is a high chance of failure.

Considering this information, we have fairly specific recommendations concerning pedicle screw placement and choice of technique. It is the authors' opinion that free-hand pedicle screw placement still has a definite role in modern day posterior instrumentation. It is difficult to argue against this technique when used in either the lumbar spine and/or in patients with no significant deformity. Anecdotally, these patients would derive less benefit from image-based techniques that require more radiation exposure and operating room time. Placement of lumbar screws have a much larger margin of error when compared to thoracic screws, due to pedicle size and the transition of the spinal cord into the cauda equina<sup>[17]</sup>. However the free-hand technique has demonstrated reasonable results with regards to accuracy in thoracic pedicle screw placement in the hands of surgeons well versed with the free-hand technique. It is particularly important to mention that accuracy with the free-hand technique increases with experience<sup>[5]</sup>, as noted earlier, although a recent study demonstrated a 15% breach rate of thoracic pedicle screws when placed by neurosurgery residents, a rate that is comparable to reported accuracies and suggests that less experienced surgeons may be able to place pedicle screws with high accuracy<sup>[74]</sup>. Regardless, the free-hand technique may be limited in patients with complicated pathology that can make it difficult to accurately place screws.

In patients with significant deformity or a requirement of mid-thoracic instrumentation, image-guided techniques are recommended. In the literature, high accuracies have in fact been demonstrated in patients with severe scoliosis when using the free-hand technique. However, this can be extremely challenging as even with the aid of pre-operative imaging as curve correction can alter the expected trajectory of non-anatomic pedicles. Thoracic screws similarly pose challenges due to inherent anatomical characteristics. This is particularly evident in the mid-thoracic spine, which is characterized by narrow pedicles<sup>[17-19]</sup>. As expected, this region is characterized by the lowest accuracy rates<sup>[14,26,27,46]</sup>. This has real clinical consequences, as the mid-thoracic region is also associated with a smaller "safe zone" in terms of injury to sensitive structures. Usage of pedicle screws at the T4-T9 vertebral levels has an increased risk of injury to both the cord and the aorta<sup>[75]</sup>.

Regardless of technique, there are a number of methods by which pedicle screw placement accuracy can be improved. Such methods include saline irrigation of drilled pedicles to detect breaches<sup>[76]</sup>, endoscopic visualization<sup>[77]</sup>, and electromyographic monitoring<sup>[78]</sup>. Additionally, with the advent of O-arm and intraoperative CT technology, surgeons can now radiographically

assess pedicle screw placement before full closure of the patient, albeit at increased radiation risk to the patient.

Usage of image-guided techniques has clear benefits due to improved pedicle visualization. However, it may not be needed and might ultimately result in an added hindrance that can be avoided with free-hand pedicle screw placement without endangering the patient. The benefits and disadvantages of each technique must be appropriately weighed on a patient-by-patient basis in order to establish the best possible treatment strategy that both limits morbidity and ensures positive patient outcomes. Ultimately, it is the surgeon's experience with a particular screw technique that determines his or her ability to accurately place pedicle screws.

## CONCLUSION

There are many published studies evaluating the use of free-hand technique, fluoroscopy-guidance, and stereotactic navigation in placing thoracolumbar pedicle screws. Between studies, assessment of screw accuracy varies significantly, which adds difficulty when interpreting and comparing them. When considering time expense and radiation exposure, it is our recommendation to utilize free-hand techniques when instrumenting regions outside of the mid-thoracic spine in pathologies without significant deformity. Screws placed in the mid-thoracic spine and/or in spines with significant deformity should be guided stereotactically to ensure accuracy. However, these are general recommendations and ultimately appropriate screw placement techniques should be determined on a case-by-case basis, taking into account a surgeon's experience.

## REFERENCES

- 1 **Boucher HH.** A method of spinal fusion. *J Bone Joint Surg Br* 1959; **41-B**: 248-259 [PMID: 13641310]
- 2 **Roy-Camille R, Saillant G, Berteaux D, Salgado V.** Osteosynthesis of thoraco-lumbar spine fractures with metal plates screwed through the vertebral pedicles. *Reconstr Surg Traumatol* 1976; **15**: 2-16 [PMID: 968155]
- 3 **Gaines RW.** The use of pedicle-screw internal fixation for the operative treatment of spinal disorders. *J Bone Joint Surg Am* 2000; **82-A**: 1458-1476 [PMID: 11057475]
- 4 **Hartl R, Theodore N, Dickman CA, Sonntag VKH.** Technique of thoracic pedicle screw fixation for trauma. *Operative Techniques Neurosurg* 2004; **7**: 22-30 [DOI: 10.1053/j.otsn.2004.04.005]
- 5 **Gertzbein SD, Robbins SE.** Accuracy of pedicular screw placement in vivo. *Spine (Phila Pa 1976)* 1990; **15**: 11-14 [PMID: 2326693 DOI: 10.1097/00007632-199001000-00004]
- 6 **O'Brien MF, Lenke LG, Mardjetko S, Lowe TG, Kong Y, Eck K, Smith D.** Pedicle morphology in thoracic adolescent idiopathic scoliosis: is pedicle fixation an anatomically viable technique? *Spine (Phila Pa 1976)* 2000; **25**: 2285-2293 [PMID: 10984779 DOI: 10.1097/00007632-200009150-00005]
- 7 **Belmont PJ, Klemme WR, Dhawan A, Polly DW.** In vivo accuracy of thoracic pedicle screws. *Spine (Phila Pa 1976)* 2001; **26**: 2340-2346 [PMID: 11679819 DOI: 10.1097/00007632-20011010-00010]
- 8 **Suk SI, Kim WJ, Lee SM, Kim JH, Chung ER.** Thoracic pedicle screw fixation in spinal deformities: are they really safe?



- Spine* (Phila Pa 1976) 2001; **26**: 2049-2057 [PMID: 11547207 DOI: 10.1097/00007632-200109150-00022]
- 9 **Liljenqvist UR**, Halm HF, Link TM. Pedicle screw instrumentation of the thoracic spine in idiopathic scoliosis. *Spine* (Phila Pa 1976) 1997; **22**: 2239-2245 [PMID: 9346144 DOI: 10.1097/00007632-199710010-00008]
- 10 **Krag MH**, Beynnon BD, Pope MH, DeCoster TA. Depth of insertion of transpedicular vertebral screws into human vertebrae: effect upon screw-vertebra interface strength. *J Spinal Disord* 1988; **1**: 287-294 [PMID: 2980257 DOI: 10.1097/00002517-198800140-00003]
- 11 **Krag MH**, Weaver DL, Beynnon BD, Haugh LD. Morphometry of the thoracic and lumbar spine related to transpedicular screw placement for surgical spinal fixation. *Spine* (Phila Pa 1976) 1988; **13**: 27-32 [PMID: 3381134 DOI: 10.1097/00007632-198801000-00007]
- 12 **Roy-Camille R**, Saillant G, Mazel C. Internal fixation of the lumbar spine with pedicle screw plating. *Clin Orthop Relat Res* 1986; (203): 7-17 [PMID: 3955999]
- 13 **Broom MJ**, Banta JV, Renshaw TS. Spinal fusion augmented by luque-rod segmental instrumentation for neuromuscular scoliosis. *J Bone Joint Surg Am* 1989; **71**: 32-44 [PMID: 2913001]
- 14 **Youkilis AS**, Quint DJ, McGillicuddy JE, Papadopoulos SM. Stereotactic navigation for placement of pedicle screws in the thoracic spine. *Neurosurgery* 2001; **48**: 771-778; discussion 771-778 [PMID: 11322437 DOI: 10.1097/00006123-200104000-00015]
- 15 **Vaccaro AR**, Rizzolo SJ, Balderston RA, Allardice TJ, Garfin SR, Dolinskas C, An HS. Placement of pedicle screws in the thoracic spine. Part II: An anatomical and radiographic assessment. *J Bone Joint Surg Am* 1995; **77**: 1200-1206 [PMID: 7642665]
- 16 **McCormack BM**, Benzel EC, Adams MS, Baldwin NG, Rupp FW, Maher DJ. Anatomy of the thoracic pedicle. *Neurosurgery* 1995; **37**: 303-308 [PMID: 7477783 DOI: 10.1097/00006123-199508000-00016]
- 17 **Rampersaud YR**, Simon DA, Foley KT. Accuracy requirements for image-guided spinal pedicle screw placement. *Spine* (Phila Pa 1976) 2001; **26**: 352-359 [PMID: 11224881 DOI: 10.1097/00007632-200102150-00010]
- 18 **Ebraheim NA**, Jabaly G, Xu R, Yeasting RA. Anatomic relations of the thoracic pedicle to the adjacent neural structures. *Spine* (Phila Pa 1976) 1997; **22**: 1553-1556; discussion 1557 [PMID: 9253087 DOI: 10.1097/00007632-199707150-00002]
- 19 **Liljenqvist UR**, Link TM, Halm HF. Morphometric analysis of thoracic and lumbar vertebrae in idiopathic scoliosis. *Spine* (Phila Pa 1976) 2000; **25**: 1247-1253 [PMID: 10806501 DOI: 10.1097/00007632-200005150-00008]
- 20 **Modi HN**, Suh SW, Hong JY, Yang JH. Accuracy of thoracic pedicle screw using ideal pedicle entry point in severe scoliosis. *Clin Orthop Relat Res* 2010; **468**: 1830-1837 [PMID: 20182830 DOI: 10.1007/s11999-010-1280-1]
- 21 **Fayyazi AH**, Hugate RR, Pennypacker J, Gelb DE, Ludwig SC. Accuracy of computed tomography in assessing thoracic pedicle screw malposition. *J Spinal Disord Tech* 2004; **17**: 367-371 [PMID: 15385875 DOI: 10.1097/01.bsd.0000112049.36255.bc]
- 22 **Heary RF**, Bono CM, Black M. Thoracic pedicle screws: post-operative computerized tomography scanning assessment. *J Neurosurg* 2004; **100**: 325-331 [PMID: 15070139]
- 23 **Kim YJ**, Lenke LG, Bridwell KH, Cho YS, Riew KD. Free hand pedicle screw placement in the thoracic spine: is it safe? *Spine* (Phila Pa 1976) 2004; **29**: 333-342; discussion 342 [PMID: 14752359 DOI: 10.1097/01.BRS.0000109983.12113.9B]
- 24 **Schwarzenbach O**, Berlemann U, Jost B, Visarius H, Arm E, Langlotz F, Nolte LP, Ozdoba C. Accuracy of computer-assisted pedicle screw placement. An in vivo computed tomography analysis. *Spine* (Phila Pa 1976) 1997; **22**: 452-458 [PMID: 9055375 DOI: 10.1097/00007632-199702150-00020]
- 25 **Mirza SK**, Wiggins GC, Kuntz C, York JE, Bellabarba C, Knonodi MA, Chapman JR, Shaffrey CI. Accuracy of thoracic vertebral body screw placement using standard fluoroscopy, fluoroscopic image guidance, and computed tomographic image guidance: a cadaver study. *Spine* (Phila Pa 1976) 2003; **28**: 402-413 [PMID: 12590219 DOI: 10.1097/01.BRS.0000048461.51308.CD]
- 26 **Modi H**, Suh SW, Song HR, Yang JH. Accuracy of thoracic pedicle screw placement in scoliosis using the ideal pedicle entry point during the freehand technique. *Int Orthop* 2009; **33**: 469-475 [PMID: 18357448 DOI: 10.1007/s00264-008-0535-x]
- 27 **Parker SL**, McGirt MJ, Farber SH, Amin AG, Rick AM, Suk I, Bydon A, Sciubba DM, Wolinsky JP, Gokaslan ZL, Witham TF. Accuracy of free-hand pedicle screws in the thoracic and lumbar spine: analysis of 6816 consecutive screws. *Neurosurgery* 2011; **68**: 170-178; discussion 178 [PMID: 21150762 DOI: 10.1227/NEU.0b013e3181fdaf4]
- 28 **Chung KJ**, Suh SW, Desai S, Song HR. Ideal entry point for the thoracic pedicle screw during the free hand technique. *Int Orthop* 2008; **32**: 657-662 [PMID: 17437109 DOI: 10.1007/s00264-007-0363-4]
- 29 **Xu R**, Ebraheim NA, Ou Y, Yeasting RA. Anatomic considerations of pedicle screw placement in the thoracic spine. Roy-Camille technique versus open-lamina technique. *Spine* (Phila Pa 1976) 1998; **23**: 1065-1068 [PMID: 9589548 DOI: 10.1097/00007632-199805010-00021]
- 30 **Lehman RA**, Polly DW, Kuklo TR, Cunningham B, Kirk KL, Belmont PJ. Straight-forward versus anatomic trajectory technique of thoracic pedicle screw fixation: a biomechanical analysis. *Spine* (Phila Pa 1976) 2003; **28**: 2058-2065 [PMID: 14501914 DOI: 10.1097/01.BRS.0000084628.37133.BA]
- 31 **Karapinar L**, Erel N, Ozturk H, Altay T, Kaya A. Pedicle screw placement with a free hand technique in thoracolumbar spine: is it safe? *J Spinal Disord Tech* 2008; **21**: 63-67 [PMID: 18418139 DOI: 10.1097/01.BSD.0b013e3181453dc6]
- 32 **Schizas C**, Theumann N, Kosmopoulos V. Inserting pedicle screws in the upper thoracic spine without the use of fluoroscopy or image guidance. Is it safe? *Eur Spine J* 2007; **16**: 625-629 [PMID: 17106663 DOI: 10.1007/s00586-006-0262-1]
- 33 **Kotil K**, Bilge T. Accuracy of pedicle and mass screw placement in the spine without using fluoroscopy: a prospective clinical study. *Spine J* 2008; **8**: 591-596 [PMID: 17602885 DOI: 10.1016/j.spinee.2007.04.002]
- 34 **Amiot LP**, Lang K, Putzier M, Zippel H, Labelle H. Comparative results between conventional and computer-assisted pedicle screw installation in the thoracic, lumbar, and sacral spine. *Spine* (Phila Pa 1976) 2000; **25**: 606-614 [PMID: 10749638 DOI: 10.1097/00007632-200003010-00012]
- 35 **Merloz P**, Troccaz J, Vouaillat H, Vasile C, Tonetti J, Eid A, Plaweski S. Fluoroscopy-based navigation system in spine surgery. *Proc Inst Mech Eng H* 2007; **221**: 813-820 [PMID: 18019467 DOI: 10.1243/09544119JEIM268]
- 36 **Fang A**, Hu SS, Endres N, Bradford DS. Risk factors for infection after spinal surgery. *Spine* (Phila Pa 1976) 2005; **30**: 1460-1465 [PMID: 15959380 DOI: 10.1097/01.brs.0000166532.58227.4f]
- 37 **Perisinakis K**, Theocharopoulos N, Damilakis J, Katonis P, Papadokostakis G, Hadjipavlou A, Gourtsoyiannis N. Estimation of patient dose and associated radiogenic risks from fluoroscopically guided pedicle screw insertion. *Spine* (Phila Pa 1976) 2004; **29**: 1555-1560 [PMID: 15247578 DOI: 10.1097/01.BRS.0000131214.57597.21]
- 38 **Jones DP**, Robertson PA, Lunt B, Jackson SA. Radiation exposure during fluoroscopically assisted pedicle screw insertion in the lumbar spine. *Spine* (Phila Pa 1976) 2000; **25**: 1538-1541 [PMID: 10851103 DOI: 10.1097/00007632-200006150-00013]
- 39 **Slomczykowski M**, Roberto M, Schneeberger P, Ozdoba C, Vock P. Radiation dose for pedicle screw insertion. Fluoro-

- scopic method versus computer-assisted surgery. *Spine* (Phila Pa 1976) 1999; **24**: 975-982; discussion 983 [PMID: 10332788 DOI: 10.1097/00007632-199905150-00009]
- 40 **Ul Haque M**, Shuffelbarger HL, O'Brien M, Macagno A. Radiation exposure during pedicle screw placement in adolescent idiopathic scoliosis: is fluoroscopy safe? *Spine* (Phila Pa 1976) 2006; **31**: 2516-2520 [PMID: 17023864 DOI: 10.1097/01.brs.0000238675.91612.2f]
- 41 **Ahn Y**, Kim CH, Lee JH, Lee SH, Kim JS. Radiation exposure to the surgeon during percutaneous endoscopic lumbar discectomy: a prospective study. *Spine* (Phila Pa 1976) 2013; **38**: 617-625 [PMID: 23026867 DOI: 10.1097/BRS.0b013e318275ca58]
- 42 **Rampersaud YR**, Foley KT, Shen AC, Williams S, Solomito M. Radiation exposure to the spine surgeon during fluoroscopically assisted pedicle screw insertion. *Spine* (Phila Pa 1976) 2000; **25**: 2637-2645 [PMID: 11034650 DOI: 10.1097/0007632-200010150-00016]
- 43 **Mulconrey DS**. Fluoroscopic Radiation Exposure in Spinal Surgery: In Vivo Evaluation for Operating Room Personnel. *J Spinal Disord Tech* 2013; Epub ahead of print [PMID: 23381176]
- 44 **Halm H**, Niemeyer T, Link T, Liljenqvist U. Segmental pedicle screw instrumentation in idiopathic thoracolumbar and lumbar scoliosis. *Eur Spine J* 2000; **9**: 191-197 [PMID: 10905435 DOI: 10.1007/s005860000139]
- 45 **Carbone JJ**, Tortolani PJ, Quartararo LG. Fluoroscopically assisted pedicle screw fixation for thoracic and thoracolumbar injuries: technique and short-term complications. *Spine* (Phila Pa 1976) 2003; **28**: 91-97 [PMID: 12544964 DOI: 10.1097/00007632-200301010-00021]
- 46 **Kuntz C**, Maher PC, Levine NB, Kurokawa R. Prospective evaluation of thoracic pedicle screw placement using fluoroscopic imaging. *J Spinal Disord Tech* 2004; **17**: 206-214 [PMID: 15167336 DOI: 10.1097/00024720-200406000-00007]
- 47 **Vougioukas VI**, Weber J, Scheufler KM. Clinical and radiological results after parapetacular screw fixation of the thoracic spine. *J Neurosurg Spine* 2005; **3**: 283-287 [PMID: 16266069 DOI: 10.3171/spi.2005.3.4.0283]
- 48 **Amato V**, Giannachi L, Irace C, Corona C. Accuracy of pedicle screw placement in the lumbosacral spine using conventional technique: computed tomography postoperative assessment in 102 consecutive patients. *J Neurosurg Spine* 2010; **12**: 306-313 [PMID: 20192632 DOI: 10.3171/2009.9.SPINE09261]
- 49 **Laine T**, Schlenszka D, Mäkitalo K, Tallroth K, Nolte LP, Visarius H. Improved accuracy of pedicle screw insertion with computer-assisted surgery. A prospective clinical trial of 30 patients. *Spine* (Phila Pa 1976) 1997; **22**: 1254-1258 [PMID: 9201865 DOI: 10.1097/00007632-199706010-00018]
- 50 **Oh HS**, Kim JS, Lee SH, Liu WC, Hong SW. Comparison between the accuracy of percutaneous and open pedicle screw fixations in lumbosacral fusion. *Spine J* 2013; **13**: 1751-1757 [PMID: 23647827]
- 51 **Smith ZA**, Sugimoto K, Lawton CD, Fessler RG. Incidence of Lumbar Spine Pedicle Breach Following Percutaneous Screw Fixation: A Radiographic Evaluation of 601 Screws in 151 Patients. *J Spinal Disord Tech* 2012; Epub ahead of print [PMID: 22688617]
- 52 **Yang BP**, Wahl MM, Idler CS. Percutaneous lumbar pedicle screw placement aided by computer-assisted fluoroscopy-based navigation: perioperative results of a prospective, comparative, multicenter study. *Spine* (Phila Pa 1976) 2012; **37**: 2055-2060 [PMID: 23149423 DOI: 10.1097/BRS.0b013e31825c05cd]
- 53 **Idler C**, Rolfe KW, Gorek JE. Accuracy of percutaneous lumbar pedicle screw placement using the oblique or "owl's-eye" view and novel guidance technology. *J Neurosurg Spine* 2010; **13**: 509-515 [PMID: 20887149 DOI: 10.3171/2010.4.SPINE09580]
- 54 **Dinesh SK**, Tiruchelvarayan R, Ng I. A prospective study on the use of intraoperative computed tomography (iCT) for image-guided placement of thoracic pedicle screws. *Br J Neurosurg* 2012; **26**: 838-844 [PMID: 22698392 DOI: 10.3109/02688697.2012.690917]
- 55 **Scheufler KM**, Franke J, Eckardt A, Dohmen H. Accuracy of image-guided pedicle screw placement using intraoperative computed tomography-based navigation with automated referencing. Part II: thoracolumbar spine. *Neurosurgery* 2011; **69**: 1307-1316 [PMID: 21734616 DOI: 10.1227/NEU.0b013e31822ba190]
- 56 **Rajasekaran S**, Vidyadhara S, Ramesh P, Shetty AP. Randomized clinical study to compare the accuracy of navigated and non-navigated thoracic pedicle screws in deformity correction surgeries. *Spine* (Phila Pa 1976) 2007; **32**: E56-E64 [PMID: 17224800]
- 57 **Abul-Kasim K**, Overgaard A, Maly P, Ohlin A, Gunnarsson M, Sundgren PC. Low-dose helical computed tomography (CT) in the perioperative workup of adolescent idiopathic scoliosis. *Eur Radiol* 2009; **19**: 610-618 [PMID: 18810453]
- 58 **Bledsoe JM**, Fenton D, Fogelson JL, Nottmeier EW. Accuracy of upper thoracic pedicle screw placement using three-dimensional image guidance. *Spine J* 2009; **9**: 817-821 [PMID: 19664966 DOI: 10.1016/j.spinee.2009.06.014]
- 59 **Nottmeier EW**, Seemer W, Young PM. Placement of thoracolumbar pedicle screws using three-dimensional image guidance: experience in a large patient cohort. *J Neurosurg Spine* 2009; **10**: 33-39 [PMID: 19119930 DOI: 10.3171/2008.10.SP108383]
- 60 **Oertel MF**, Hobart J, Stein M, Schreiber V, Scharbrodt W. Clinical and methodological precision of spinal navigation assisted by 3D intraoperative O-arm radiographic imaging. *J Neurosurg Spine* 2011; **14**: 532-536 [PMID: 21275555 DOI: 10.3171/2010.10.SPINE091032]
- 61 **Lee MH**, Lin MH, Weng HH, Cheng WC, Tsai YH, Wang TC, Yang JT. Feasibility of Intra-operative Computed Tomography Navigation System for Pedicle Screw Insertion of the Thoraco-lumbar Spine. *J Spinal Disord Tech* 2012; Epub ahead of print [PMID: 23222100]
- 62 **Ling JM**, Dinesh SK, Pang BC, Chen MW, Lim HL, Louange DT, Yu CS, Wang CM. Routine spinal navigation for thoracolumbar pedicle screw insertion using the O-arm three-dimensional imaging system improves placement accuracy. *J Clin Neurosci* 2014; **21**: 493-498 [PMID: 24090516 DOI: 10.1016/j.jocn.2013.02.034]
- 63 **Laine T**, Lund T, Ylikoski M, Lohikoski J, Schlenszka D. Accuracy of pedicle screw insertion with and without computer assistance: a randomised controlled clinical study in 100 consecutive patients. *Eur Spine J* 2000; **9**: 235-240 [PMID: 10905443]
- 64 **Tormenti MJ**, Kostov DB, Gardner PA, Kanter AS, Spiro RM, Okonkwo DO. Intraoperative computed tomography image-guided navigation for posterior thoracolumbar spinal instrumentation in spinal deformity surgery. *Neurosurg Focus* 2010; **28**: E11 [PMID: 20192656 DOI: 10.3171/2010.1.FOCUS09275]
- 65 **Shin MH**, Hur JW, Ryu KS, Park CK. Prospective Comparison Study Between the Fluoroscopy Guided and Navigation Coupled with O-arm® Guided Pedicle Screw Placement in the Thoracic and Lumbosacral Spines. *J Spinal Disord Tech* 2013; Epub ahead of print [PMID: 23563342]
- 66 **Waschke A**, Walter J, Duenisch P, Reichart R, Kalff R, Ewald C. CT-navigation versus fluoroscopy-guided placement of pedicle screws at the thoracolumbar spine: single center experience of 4500 screws. *Eur Spine J* 2013; **22**: 654-660 [PMID: 23001415 DOI: 10.1007/s00586-012-2509-3]
- 67 **Fraser J**, Gebhard H, Irie D, Parikh K, Härtl R. Iso-C/3-dimensional neuronavigation versus conventional fluoroscopy for minimally invasive pedicle screw placement in lumbar fusion. *Minim Invasive Neurosurg* 2010; **53**: 184-190 [PMID: 21140333 DOI: 10.1055/s-0030-1267926]
- 68 **Tian NF**, Xu HZ. Image-guided pedicle screw insertion accuracy: a meta-analysis. *Int Orthop* 2009; **33**: 895-903 [PMID:

- 19421752 DOI: 10.1007/s00264-009-0792-3]
- 69 **Gelalis ID**, Paschos NK, Pakos EE, Politis AN, Arnaoutoglou CM, Karageorgos AC, Ploumis A, Xenakis TA. Accuracy of pedicle screw placement: a systematic review of prospective in vivo studies comparing free hand, fluoroscopy guidance and navigation techniques. *Eur Spine J* 2012; **21**: 247-255 [PMID: 21901328 DOI: 10.1007/s00586-011-2011-3]
- 70 **Shin BJ**, James AR, Njoku IU, Härtl R. Pedicle screw navigation: a systematic review and meta-analysis of perforation risk for computer-navigated versus freehand insertion. *J Neurosurg Spine* 2012; **17**: 113-122 [PMID: 22724594 DOI: 10.3171/2012.5.S.PINE11399]
- 71 **Costa F**, Cardia A, Ortolina A, Fabio G, Zerbi A, Fornari M. Spinal navigation: standard preoperative versus intraoperative computed tomography data set acquisition for computer-guidance system: radiological and clinical study in 100 consecutive patients. *Spine (Phila Pa 1976)* 2011; **36**: 2094-2098 [PMID: 21304425 DOI: 10.1097/BRS.0b013e318201129d]
- 72 **Cui G**, Wang Y, Kao TH, Zhang Y, Liu Z, Liu B, Li J, Zhang X, Zhu S, Lu N, Mao K, Wang Z, Zhang X, Yuan X, Dong T, Xiao S. Application of intraoperative computed tomography with or without navigation system in surgical correction of spinal deformity: a preliminary result of 59 consecutive human cases. *Spine (Phila Pa 1976)* 2012; **37**: 891-900 [PMID: 22024897 DOI: 10.1097/BRS.0b013e31823aff81]
- 73 **Zausinger S**, Scheder B, Uhl E, Heigl T, Morhard D, Tonn JC. Intraoperative computed tomography with integrated navigation system in spinal stabilizations. *Spine (Phila Pa 1976)* 2009; **34**: 2919-2926 [PMID: 20010400 DOI: 10.1097/BRS.0b013e3181b77b19]
- 74 **Wang VY**, Chin CT, Lu DC, Smith JS, Chou D. Free-hand thoracic pedicle screws placed by neurosurgery residents: a CT analysis. *Eur Spine J* 2010; **19**: 821-827 [PMID: 20135332 DOI: 10.1007/s00586-010-1293-1]
- 75 **Sarlak AY**, Tosun B, Atmaca H, Sarisoy HT, Buluç L. Evaluation of thoracic pedicle screw placement in adolescent idiopathic scoliosis. *Eur Spine J* 2009; **18**: 1892-1897 [PMID: 19526376 DOI: 10.1007/s00586-009-1065-y]
- 76 **An HS**, Benoit PR. Saline injection technique to confirm pedicle screw path: a cadaveric study. *Am J Orthop (Belle Mead NJ)* 1998; **27**: 362-365 [PMID: 9604108]
- 77 **Frank EH**. The use of small malleable endoscopes to assess pedicle screw placement: technical note. *Minim Invasive Neurosurg* 1998; **41**: 10-12 [PMID: 9565958]
- 78 **Reidy DP**, Houlden D, Nolan PC, Kim M, Finkelstein JA. Evaluation of electromyographic monitoring during insertion of thoracic pedicle screws. *J Bone Joint Surg Br* 2001; **83**: 1009-1014 [PMID: 11603513]

**P- Reviewers:** Chen YK, Grote S, Melanie F **S- Editor:** Qi Y  
**L- Editor:** A **E- Editor:** Lu YJ



## Surgical advances in the treatment of neuromuscular scoliosis

Federico Canavese, Marie Rousset, Benoit Le Gledic, Antoine Samba, Alain Dimeglio

Federico Canavese, Marie Rousset, Benoit Le Gledic, Antoine Samba, Pediatric Surgery Department, University Hospital Estaing, 63003 Clermont-Ferrand, France

Alain Dimeglio, Faculté de Médecine, Université de Montpellier, 34000 Montpellier, France

**Author contributions:** Canavese F, Rousset M, Le Gledic B and Dimeglio A contributed equally to this work, designed the aim of the editorial content, generated the figures and wrote the manuscript; Samba A revised the manuscript and granted final approval to the version to be published.

**Correspondence to:** Federico Canavese, MD, PhD, Professor of Pediatric Surgery, Pediatric Surgery Department, University Hospital Estaing, 1 Place Lucie et Raymond Aubrac, 63003 Clermont-Ferrand, France. [canavese\\_federico@yahoo.fr](mailto:canavese_federico@yahoo.fr)

Telephone: +33-4-73750293 Fax: +33-4-73750291

Received: November 29, 2013 Revised: January 8, 2014

Accepted: January 15, 2014

Published online: April 18, 2014

### Abstract

Neuromuscular disorders are a group of diseases affecting the neuro-musculo-skeletal system. Children with neuromuscular disorders frequently develop progressive spinal deformities with cardio-respiratory compromise in the most severe cases. The incidence of neuromuscular scoliosis is variable, inversely correlated with ambulatory abilities and with a reported risk ranging from 80% to 100% in non-ambulatory patients. As surgical and peri-operative techniques have improved, more severely affected children with complex neuromuscular deformities and considerable co-morbidities are now believed to be candidates for extensive surgery for spinal deformity. This article aimed to provide a comprehensive review of how neuromuscular spinal deformities can affect normal spine balance and how these deformities can be treated with segmental instrumentation and sub-laminar devices. Older concepts have been integrated with newer scientific data to provide the reader with a basis for better understanding of how treatment of neuromuscular scoliosis has evolved

over the past few decades. Recent advances, as well as challenges that remain to be overcome, in the surgical treatment of neuromuscular curves with sub-laminar devices and in the management of post-operative infections are outlined.

© 2014 Baishideng Publishing Group Co., Limited. All rights reserved.

**Key words:** Neuromuscular scoliosis; Surgery; Sub-laminar bands; Luque rod; Unit rod

**Core tip:** In patients with neuromuscular disease, the likelihood and severity of the scoliosis increase with the degree of neuromuscular involvement. There is little doubt that segmental instrumentation techniques have revolutionized the care of patients with neuromuscular scoliosis by providing lasting correction and significant relief of pain and by restoring quality of life and sitting position. The state of knowledge regarding neuromuscular scoliosis is a dynamic process, and a current literature review is mandatory. The somewhat large bibliography for this subject reflects the many opinions and findings currently available.

Canavese F, Rousset M, Le Gledic B, Samba A, Dimeglio A. Surgical advances in the treatment of neuromuscular scoliosis. *World J Orthop* 2014; 5(2): 124-133 Available from: URL: <http://www.wjgnet.com/2218-5836/full/v5/i2/124.htm> DOI: <http://dx.doi.org/10.5312/wjo.v5.i2.124>

### INTRODUCTION

Scoliosis is a three-dimensional deformity of the spine with lateral, antero-posterior and rotational components. In most cases, the disease is idiopathic. Non-idiopathic cases are often secondary to neuromuscular diseases affecting the neuro-musculo-skeletal system.



**Table 1 Incidence**

Diagnosis	Incidence of scoliosis
Cerebral palsy	25% (GMFCS I and II) to 100% (GMFCS IV and V)
Charcot-Marie-Tooth disease	30%
Myelodysplasia	60% (lumbar level) to 100% (thoracic level)
Spinal muscular atrophy	70%
Friedreich ataxia	80%
Duchenne muscular dystrophy	90% <sup>1</sup>
Paralysis from spinal cord injury	100%

The incidence of neuromuscular scoliosis is variable. Among patients with neuromuscular disorders, the probability of developing scoliosis is inversely correlated with ambulatory ability, with a reported risk ranging from 80% to 100% in non-ambulatory patients. <sup>1</sup>Corticoids have lowered this percentage<sup>[47]</sup>.

Children with neuromuscular disorders frequently develop progressive spinal deformities, with cardio-respiratory compromise in the most severe cases. Among patients with neuromuscular disorders, the probability of developing scoliosis is inversely correlated with ambulatory ability, with a reported risk ranging from 80% to 100% in non-ambulatory patients (Table 1). Patients with neuromuscular disorders have many similarities in curve patterns, despite different etiologies of the main disease; therefore similar strategies are implemented for treatment.

Neuromuscular scoliosis is characterized by a long collapsing spine, pelvic obliquity and changes in sagittal plane alignment that can affect sitting balance and cardio-respiratory function. Long C-shaped thoraco-lumbar and lumbar curves are very often diagnosed in patients with underlying neuromuscular pathologies. Associated negative predictors include osteopenia and concomitant congenital malformations, which are responsible for rapid progression (collapsing spine)<sup>[1-3]</sup>.

Patients with neuromuscular disorders tend to develop scoliosis at younger ages than patients with idiopathic scoliosis, and a large proportion of neuromuscular curves are progressive and often non-responsive to orthotic management. Unlike idiopathic scoliosis, neuromuscular spine deformities can progress beyond skeletal maturity, particularly in wheelchair-bound patients<sup>[1,3-6]</sup>.

Surgical treatment is more complex in neuromuscular scoliosis than in idiopathic scoliosis. Complex reconstruction can be necessary to obtain satisfactory results. However, a bone stock of poor quality, longer fusions, the frequent need for fusion to the pelvis and increased bleeding can significantly affect operative time and make such surgery difficult.

As surgical and peri-operative techniques have improved, more severely affected children with complex neuromuscular deformities and considerable co-morbidities are now believed to be candidates for extensive surgery for spinal deformity<sup>[1,4-6]</sup>.

Pulmonary, neurologic, genitourinary, nutritional and gastroenterological comorbidities are common in patients

with neuromuscular scoliosis and must be managed (pre- and post-operatively) by a multidisciplinary team of care providers. A multidisciplinary approach is the key to a successful outcome. Comorbidities often make corrective operations high-risk procedures. Orthopedic surgeons experienced in undertaking major spine reconstruction, anesthesiologists, pulmonologists, cardiologists, nutritionists and pediatricians must work together to evaluate and handle these complex surgical patients to obtain the best possible outcomes<sup>[1,3,7-9]</sup>.

Furthermore, the post-operative complication rate is much higher (approximately 30%) in patients with neuromuscular deformities, compared to patients with idiopathic scoliosis. Therefore, the risk-to-benefit ratio is an important parameter that must be considered before surgery as the results can be gratifying if patients are properly selected<sup>[2,6,10]</sup>.

Luque rods, or variations on the Luque technique, often remain the preferred instrumentation for neuromuscular curves. The success of treatment depends on the maintenance of a balanced spine on the coronal and sagittal planes over a level pelvis<sup>[11-13]</sup>.

This article aims to provide a comprehensive review of how neuromuscular spinal deformities can affect normal spine balance and how such deformities can be treated with segmental instrumentation and sub-laminar devices.

Older concepts have been integrated with newer scientific data to provide the reader with a basis for better understanding of how treatment of neuromuscular scoliosis has evolved over the past few decades. Recent advances, as well as challenges that remain to be overcome, are outlined in the surgical treatment of neuromuscular curves with sub-laminar devices and in the management of post-operative infections.

## HISTORY AND PRINCIPLES OF SURGICAL TREATMENT

Surgical management of scoliotic curves in patients with neuromuscular conditions has evolved over the past five decades. Segmental fixation, sub-laminar wires, L-rods, unit-rods and sub-laminar bands have been progressively developed for the treatment of neuromuscular curves and they now form part of the armamentarium of the spinal surgeon in addressing such deformities. The surgical treatment must be adapted to the severity of the deformity and the neuromuscular disease. The treating surgeon should not be a prisoner of a single strategy; rather, the strategy should depend on the health of the patient (Table 2).

### Segmental fixation (early 1960s)

The concept of segmental fixation was pioneered in 1963 by Resina and Alves from Portugal, by fixation with segmental wiring for the treatment of scoliotic curves<sup>[11]</sup>.

Stainless steel wires are passed through a hole at the base of the spinous processes (one wire per vertebra) and are twisted around to two straight rods placed on either

**Table 2** Surgical risk

Surgical risk	Walking abilities	Weight	Cardiac Function	Respiratory function (VC)	Sleep	Comorbidities
Average	Ambulatory	> 40 kg	Normal	Normal	Normal	No
Increased	Ambulates with aid	20-40 kg	Reduced	Reduced, but > 50%	Hypersomnia	
High	Non ambulatory	< 20 kg or obese	Significantly impaired	< 50%	Nocturnal hypercapnic Hypoventilation, Obstructive sleep apnea	Yes

In addition to neuromuscular pathology, factors such as walking abilities, nutritional status, cardiopulmonary function and the presence of other comorbidities, must be considered prior to surgery to minimize surgical risk. Morbidity is higher in non-ambulatory patients, with reduced weight and impaired cardiopulmonary function.

**Table 3** Decade 1980-1989

Decade-Year of publication	Authors	Patients (n)	Neuromuscular condition	Instrumentation	Complications (number of patients)
1980-1989					
1982	Allen <i>et al</i> <sup>[13]</sup>	10	Cerebral palsy	L-rod	
1986	Sponseller <i>et al</i> <sup>[14]</sup>	34	Cerebral palsy	Interspinous process instrumentation	
1988	Gersoff <i>et al</i> <sup>[16]</sup>	33	Cerebral palsy	L-rod	5 deep wound infections Complications rate: 15% 1 death;
1989	Broom <i>et al</i> <sup>[18]</sup>	74	Various	L-rod	3 deep wound infections; 2 pressure sores; 6 sets of broken rods; 1 distal rotation and migration of the rod Complications rate: 18% 3 cases of pseudarthrosis; 3 deaths Complications rate: 13%
1989	Boachie-Adjei <i>et al</i> <sup>[17]</sup>	46	Various	L-rod	

Most significant works published between 1980 and 1989.

side of the spine.

This technique allows for translation of the spine and correction of the deformity (mostly on the frontal plane) using an even distribution of corrective forces.

### **Sub-laminar wires and L-rods (late 1970s)**

Eduardo Luque from Mexico popularized sub-laminar wires to attach to L-shaped rods during the late 1970s (Table 3)<sup>[12]</sup>.

In Luque's system, two L-shaped rods are placed on either side of the spine, and they are wired to each of the vertebrae. The L-rods are contoured or bent to conform to the curve and to provide proper sagittal alignment. The wires are threaded through the spinal canal at each vertebral level and are then twisted around the rods on each side of the spine. The wires are usually doubled (to reduce the risk of fracturing the lamina), with one end joined by a bead and the other by a loop. The beaded end is contoured by creating a small bend at the tip that will emerge on the cephalad side of the lamina. A flatter contour minimizes intrusion into the canal. However, it is important to bear in mind that once metal wires are passed under the lamina, great care must be taken to ensure that none of the operating team inadvertently pushes one of the wires into the canal. To minimize this danger, each

wire should be temporarily bent over the lamina.

Segmental instrumentation with sub-laminar wires results in even distribution of corrective forces with two lateral fixation points on each segment, which provide good rotatory control. The rods apply pressure on the spine to correct the deformity<sup>[12-16]</sup>.

The L-rods and wire constructs aim at translation and coronal and sagittal balancing, rather than derotation, as their principle, so the extent of derotation is not the purpose that is intended to be achieved with this technique. Because there are multiple points of fixation with the Luque technique, the patient does not have to wear a brace after surgery. Therefore, segmental instrumentation with sub-laminar wires has been widely adopted in the treatment of neuromuscular curves because it provides rigid fixation and allows for early mobilization without external support<sup>[12,16-18]</sup>.

Overall, the technique has proved to be safe and relatively easy to perform with a relatively low complications rate, providing rigid fixation and predictable correction with minimal post-operative external support required, and it is applicable for a wide variety of spinal deformities, offers a high rate of fusion with a low incidence of failure of the instrumentation and provides sagittal plane correction comparable to more recent implants.

Table 4 Decade 1990-1999

Decade-Year of publication	Authors	Patients (n)	Neuromuscular condition	Instrumentation	Complications (number of patients)	Outcome/Conclusions
1990-1999						
1991	Gau <i>et al</i> <sup>[34]</sup>	68	Various	Luque-Galveston instrumentation	14 hardware problems; 7 cases of pseudarthrosis; 3 neurologic deficits Complications rate: 35%	
1992	Hopf <i>et al</i> <sup>[35]</sup>	44	Various			
1992	Neustadt <i>et al</i> <sup>[36]</sup>	18	Various	CDI of the pelvis	1 hardware failure; 1 deep wound infection Complications rate: 11%	Posterior spinal fusion with CDI of the pelvis is an effective treatment for patients with neuromuscular scoliosis.
1992	Onimus <i>et al</i> <sup>[37]</sup>	32	Cerebral palsy		3 deaths; 10 other Complications rate: 41%	Pain disappeared in 2/3 of cases; sitting position was acquired in all the cases at follow-up; motor possibilities improved in 25% of cases; associated medical pathologies were reduced in 67% of cases.
1996	Sussman <i>et al</i> <sup>[38]</sup>	25	Cerebral palsy	L-rod		Posterior fusion and instrumentation from the upper thoracic spine to L5 without anterior fusion provides adequate correction and control of spinal deformity for many patients with cerebral palsy
1997	Frischhut <i>et al</i> <sup>[39]</sup>	41	Various	29 L-rod, Luque-Galveston, CDI and ISOLA; 12 Harrington instrumentation	3 deep wound infections Complications rate: 7%	
1997	Marchesi <i>et al</i> <sup>[40]</sup>	25	Duchenne muscular dystrophy	L-rod with sacral screws		In every patient, a good sitting balance could be restored after surgery

Most significant works published between 1990 and 1999. CDI: Cotrel-Dubousset instrumentation.

### Unit-rod for segmental spinal fixation (late 1980s)

The unit-rod (U-rod) technique was developed in the late 1980s by Bell, Moseley and Koreska from Canada<sup>[19]</sup>.

This technique uses a U-shaped, double, prebent rod, and it is a modification of Luque's segmental instrumentation technique, which, in contrast, must link together two single L-shaped rods<sup>[20-22]</sup>.

The distal portion of the U-rod is inserted into both iliac wings, while the middle and proximal portions are wired to sub-laminar wires threaded through the spinal canal at each vertebral level, from the upper thoracic (T1-T2) to the lower lumbar (L4-L5) spine. Sub-laminar wires are progressively twisted around the U-rod from caudal to cephalad to provide gradual deformity correction.

U-rod instrumentation has become a common, standard technique and the primary instrumentation system for the treatment of pediatric patients with neuromuscular spine deformities and pelvic obliquity (Tables 4 and 5). The technique is simple to apply, it is less expensive than most other systems, and it can achieve good deformity correction and a low reoperation rate<sup>[19]</sup>.

### Sub-laminar band technique (late 2000s)

The sub-laminar band devices and technique were first described in 2009 by Mazda *et al*<sup>[23]</sup> from France. The technique is also known as the universal clamp technique (Table 5).

The technique of placing sub-laminar bands is similar to Luque's wire technique. However, while Luque's wires

are made of steel or titanium alloy, the bands with this technique are made of acrylic or polyester material. The bands are supple and, once inserted, cannot be inadvertently pushed into the canal.

The sub-laminar system is composed of a connector, a band-locking set screw, a polyester or acrylic band and, depending on the manufacturer, a rod-locking set screw.

Compared to Luque's metal wires, the technique described by Mazda *et al*<sup>[23]</sup> allows the surgeon to perform progressive tensioning and deformity correction because of the simplicity of the implant and the tensioning of the strips<sup>[24]</sup>.

Sub-laminar bands have the same stress resistance as steel or titanium alloy sub-laminar wires. Moreover, the increased contact area between the bands and bone improves corrective forces and reduces laminar fracture risk<sup>[24]</sup>.

Today, band-only and hybrid constructs, with lumbar transpedicular screws, thoracic sub-laminar bands and pedicle-transverse hooks at the upper end of the curve, have become widely used and have been shown to provide good correction of spinal deformities, as well as reduced operating time, radiation exposure, and blood loss, compared to all-screw constructs.

## SURGICAL TECHNIQUE OF SUB-LAMINAR BANDS PLACEMENT

### Basic principles

Patients can be treated either with band-only or hybrid

Table 5 Decade 2000-2011

Decade-Year of publication	Authors	Patients (n)	Neuromuscular condition	Instrumentation	Complications (number of patients)	Outcome/Complications
2000-2011						
2000	Yazici <i>et al</i> <sup>[25]</sup>	47	Various	ISOLA-Galveston	2 deep wound infections; 2 hardware removals; 4 cases of pseudarthrosis; 1 pseudarthrosis repair Complications rate: 19%	ISOLA-Galveston instrumentation is as safe and effective as other types of instrumentation
2009	Modi <i>et al</i> <sup>[20]</sup>	52	Cerebral palsy	U-rod and pedicle screws	2 deaths; 1 neurologic deficit; 17 respiratory complications (atelectasia, pneumonia, hemothorax) Complications rate: 38%	U-rod with pedicle screws provides good frontal and sagittal plane correction, as well as pelvic obliquity improvement (56% correction)
2010	Nectoux <i>et al</i> <sup>[21]</sup>	28	Cerebral palsy	Luque-Galveston, U-rod	1 case of blindness; 1 death; 16 respiratory complications (atelectasia, pneumonia, pneumothorax) Complications rate: 64%	
2010	Modi <i>et al</i> <sup>[22]</sup>	27	Spinal muscular atrophy and Duchenne muscular dystrophy	U-rod and pedicle screws	1 death; 4 respiratory failure; 2 neurological deficits; 1 ileus; 2 cases of atelectasia; 3 UTIs; 7 cases of coccydynia; 1 rod dislodgement Complications rate: 77%	Although flaccid neuromuscular scoliosis can be corrected well with U-rod and posterior-only pedicle screws, there is a high rate of associated complications
2011	La Rosa <i>et al</i> <sup>[24]</sup>	84	Cerebral palsy	Universal clamps, hooks and L-rod	5 respiratory complications Complications rate: 6%	

Most significant works published between 2000 and 2011.

instrumentation.

Band-only instrumentation (Figure 1) is a construct characterized by two bilateral claws at the upper instrumented vertebra (one per side) and sub-laminar bands as thoracic and lumbar anchorages. Band-only instrumentation should be preferred in non-ambulatory patients.

The hybrid construct (Figure 2) consists of two bilateral claws at the upper instrumented vertebra (one per side), multiple transpedicular screws as distal anchorages and sub-laminar bands between the upper claws and distal screws. Hybrid instrumentation can be used in both ambulatory and non-ambulatory patients.

In cases of severe pelvic obliquity, iliac screws can be added to both constructs. Moreover, Ponte's posterior osteotomies can be performed at and around the apex for rigid curves (less than 30% reduction on bending films).

### Screws and claws

Instrumentation is performed with the PASS® LP side connection segmental system (MEDICREA, Neyron, France), using 5.5 mm titanium (Ti) or cobalt-chrome (Co-Cr) rods, pedicle screws, auto-stable claws, cross-links and various rod-anchorage connectors locked by nuts.

Transpedicular screws can be inserted with the free-hand technique, and they are mostly placed at the lumbar level.

Auto-stable claws consist of a main pedicular hook and a counter-hook, which can be placed under the lamina or above the transverse process of the upper instrumented vertebra (thoracic region). Upper claws and lumbar screws should be placed before band insertion.

### Sub-laminar band insertion

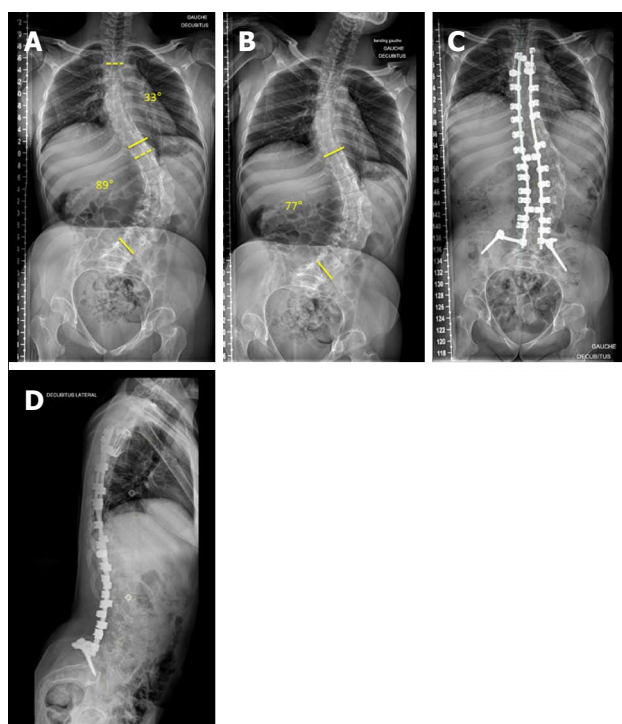
Sub-laminar fixation is performed with the LigaPASS® system (MEDICREA, Neyron, France), which consists of a titanium alloy connector, a rod-locking set screw, a polyester band and a band-locking set screw.

A portion of the ligamentum flavum must be removed from each intervertebral space. Once the canal is opened, the bands can be placed from caudal to cephalad.

Each band ends with malleable Ti leads. The malleable Ti end is contoured by creating a small bend at the tip that will emerge on the cephalad side of the lamina. Contouring the malleable Ti leads helps to slide the band under the lamina from caudal to cephalad, with a very low risk of damaging the thecal sac.

If two bands must be slid under the same lamina, the second band placement can be facilitated using the first band as a guide. The second band should be inserted between the first band and the lamina. By doing so, the thecal sac is protected throughout the whole insertion maneuver of the second band. Moreover, insertion is easier





**Figure 1** A 16-year-old girls with cerebral palsy (GMFCS IV). This non-ambulatory patient was operated on with band-only instrumentation. A: Pre-operative supine anteroposterior X-rays; B: Pre-operative supine left bending X-rays (reducibility of 13%); C: Post-operative supine anteroposterior X-rays; D: Post-operative supine lateral X-rays.

as the first band can be glided from caudal to cephalad, thus bringing the second band into its movement.

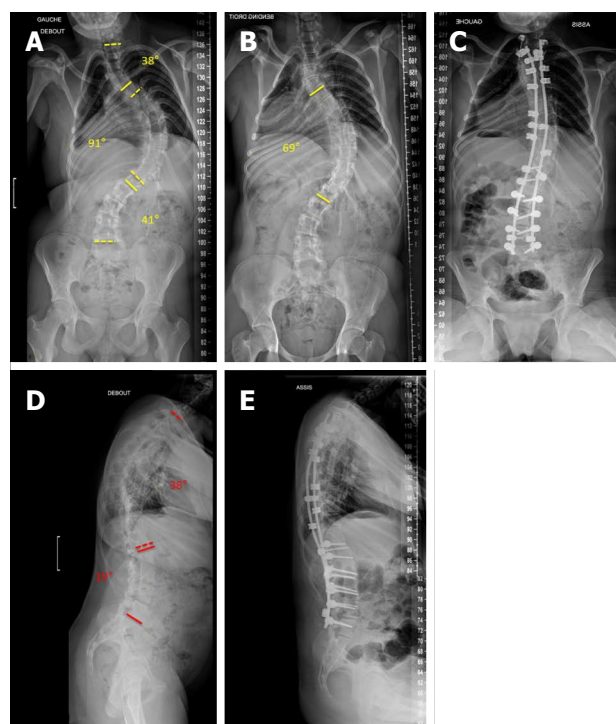
The polyester band can be simply passed under the lamina or inserted in a figure-8 belt (under the lamina and around the transverse process). In any case, attention should be paid to ensuring that the band is not twisted during the passing maneuver.

### Reduction maneuver

Once band placement is completed, all the connectors can be slid on the previously contoured rod. Subsequently, the two extremities of each band are introduced into the opening situated below the band-locking set screw, ensuring that each end of the band is paired correctly and inserted through the corresponding connector.

The rods are then placed and properly oriented on both the sagittal and coronal planes without any attempt to reduce the deformity. In hybrid constructs, rods can be locked to the lowest lumbar transpedicular screws and pelvic screws. If band-only constructs are used, the rods are locked to pelvic screws. Locking of the rods stabilizes the construct and avoids undesired rotation during band tensioning. The rods should not be locked to the upper claws to allow for rod movements during band tensioning and subsequent deformity correction.

The LigaPASS connectors must be locked perpendicularly to the rod on the coronal plane by setting the rod-locking set screw. This procedure prevents the connector from rotating around the rod and creates a platform for



**Figure 2** A 15-year-old boy with a genetic syndrome. This ambulatory patient was operated on with a hybrid construct. A: Pre-operative standing anteroposterior x-rays; B: Pre-operative supine left bending X-rays (reducibility of 24%); C: Post-operative seated anteroposterior X-rays; D: Pre-operative standing lateral X-rays; E: Post-operative seated lateral X-rays.

self-stable band tensioning.

The reduction is performed sequentially by progressively tensioning all the bands with the tension pulleys. This process gradually translates the spine toward the rods and reduces the deformity by sharing forces among all the implants. The tension applied to each band can be assessed by observing the strain gauge on the pulley.

Maximum reduction is achieved when the band connector is seated on the vertebra. Once the desired reduction is achieved, the band is locked within the connector by tightening the band-locking set screw. At this point, the remaining screws and upper claws can also be locked.

## WHEN TO OPERATE ON A PATIENT WITH NEUROMUSCULAR SCOLIOSIS

### Indications for and goals of surgical treatment

In neuromuscular scoliosis, bracing is usually not effective, and surgery becomes the primary treatment option<sup>[8]</sup>.

The type of spinal stabilization is influenced by the age of the patient, the severity of the deformity, the ambulatory status, and the underlying neuromuscular condition.

Posterior instrumentation for neuromuscular deformity treatment should be segmental and low-profile, with sound pelvic purchase if needed<sup>[5,11,18,25]</sup>. In all cases, fitness for surgery and psychological status should be assessed prior to surgery, as the results can be gratifying if

patients are properly selected.

Surgical treatment is indicated in large curves ( $> 50^\circ$ ) and in curves progressing beyond skeletal maturity. However, puberty can begin earlier or, more frequently, later in patients with neuromuscular disease (than the puberty of children with idiopathic curves)<sup>[1]</sup>. Depending on the neuromuscular disease, the rate of progression of the scoliotic deformity during pubertal growth spurt can increase by  $2^\circ$  to  $4^\circ$  per month, especially in patients who are wheelchair-bound. Scoliosis continues to progress beyond skeletal maturity at a rate of approximately  $1^\circ$  to  $4^\circ$  per year if the curvature is greater than  $50^\circ$  at the end of growth, compared to approximately  $0.5^\circ$  to  $1^\circ$  per year for curves of less than  $50^\circ$ <sup>[1,8,26]</sup>.

In addition, neuromuscular curves are responsible overall for a greater decrease in lung volumes compared to idiopathic curves, which, in contrast, are characterized by normal muscle function<sup>[27-29]</sup>.

Sleep-disordered breathing, with or without nocturnal hypercapnic hypoventilation, is a common complication of respiratory muscle weakness in children and adolescents with neuromuscular disorders (Table 2). Nocturnal hypercapnic hypoventilation is a sign of respiratory muscle fatigue and a poor prognosis. It is recommended to perform a polysomnographic evaluation, searching for sleep-disordered breathing in patients with neuromuscular compromise and spinal deformities. Children with neuromuscular scoliosis are at risk for sleep-disordered breathing when the inspiratory vital capacity is less than 60% during daytime hours. Moreover, they are at risk for hypercapnic hypoventilation during the nighttime if their inspiratory vital capacity is less than 40%, and  $\text{PaCO}_2$  is greater than 40 mmHg<sup>[30]</sup>.

Overall, the indications for surgery are: (1) A significant curve resulting in functional disturbance and/or cardio-respiratory compromise; (2) A progressive spinal deformity not controllable with orthosis; (3) A small curve with inevitable progression; and (4) Painful deformities.

The goals of surgical treatment are: (1) To prevent curve progression; (2) To maintain the spine balanced on the coronal and sagittal planes, with a level and upright trunk position; (3) To provide a balanced and comfortable sitting position to reduce repositioning; (4) To reduce pain; (5) To reduce the discomfort caused by the impingement of the ribs against the iliac crest on the concave side of the curve; (6) To maximize patients' health and function; and (7) To maintain walking ability in ambulatory patients.

Although spinal surgery can restore proper spinal alignment, it has some potential disadvantages. In particular, spinal fusion and instrumentation can adversely affect those patients with neuromuscular disorders who have developed functional compensation techniques requiring a short and mobile trunk. Moreover, surgery stops any further growth over the fused segments, and it can accentuate hip deformity<sup>[1,2,6,31]</sup>.

### **Hip dislocation, pelvic obliquity and the extent of instrumented fusion**

A large number of patients with neuromuscular scoliosis have involvement of the sacrum and subsequent pelvic obliquity. However, patients with neuromuscular scoliosis can develop pelvic obliquity from other sources, such as hip joint and other lower extremity contractures, which will eventually affect the lumbar spine. Furthermore, deformity progression can interfere with trunk stability<sup>[32,33]</sup>.

It is important to assess hip motion and contracture carefully in any patient with neuromuscular spinal deformity. Hip contracture and dislocation can secondarily deform the spine dynamically when the patient attempts to accommodate the hip deformity while sitting.

In cases of unilateral dislocation, pelvic obliquity increases spine deformities and can cause ischiatic pressure sores and loss of sitting position. In such situations, hip surgery is recommended. The choice of surgical procedure depends on the morphology of the femoral head and the presence of necrosis and degenerative cartilage changes. The current recommendations are to reconstruct the hip whenever it is possible. Otherwise, a total hip prosthesis or a femoral head resection can be considered. For patients who present with scoliosis and hip dislocation, hip surgery is usually performed before spinal fusion unless pelvic obliquity is caused by the spine deformity. The goal of orthopedic surgery in non-ambulatory patients is to achieve a sitting position with a level pelvis and an upright trunk position<sup>[19,22,24,32]</sup>.

Instrumentation and fusion should be extended to the pelvis in non-ambulatory patients with pelvic obliquity. In contrast, instrumented fusion can stop at L5 or above when the patient is still ambulatory and shows minimal or no signs of pelvic obliquity. Small amounts of pelvic obliquity (less than  $10^\circ$  to  $15^\circ$ ) are compatible with comfortable sitting. In contrast, larger fixed obliquities are not compatible with comfortable sitting and must be corrected surgically or, if not fixed, with wheelchair modifications<sup>[34-36]</sup>.

## **COMPLICATIONS OF SURGERY**

Surgical treatment of neuromuscular spine deformities is more complex than the treatment of idiopathic scoliosis<sup>[37-40]</sup>. Complex reconstruction can be necessary to obtain satisfactory outcomes. However, the post-surgical complication rate is higher in neuromuscular scoliosis patients, compared to patients with idiopathic scoliosis. The Scoliosis Research Society Morbidity and Mortality Committee reported an infection rate of 5.5% for neuromuscular cases compared to 1.4% in idiopathic patients and a new neurological deficit rate of 1.03% *vs* 0.73%, respectively<sup>[41,42]</sup>. These rates are often due to the presence of multiple comorbidities. Chronic cardiovascular disease as a consequence of a severe scoliotic deformity can lead to complications such as hypoxemia, hypercapnia, cor pulmonale, and pulmonary hypertension. A preoperative forced vital capacity less than 30% is strongly predictive

of pulmonary complications, and a significant association between restrictive lung disease and increased pulmonary complications has been reported<sup>[16-18,22,39]</sup>.

The nutritional status of patients with neuromuscular disorders is extremely important, as nutritional depletion has been associated with increased complication rates<sup>[7,34,36,37]</sup>.

Complications can be divided into early and late. Early complications are those diagnosed immediately after or within 4 to 6 wk from the index surgery. In contrast, late complications are diagnosed more than 6 wk after the index surgery.

Early post-operative complications include infections, cardio-respiratory, neurologic and nutritional issues, prolonged ileus, constipation, fluid overload, skin breakdown, bleeding and death. Late post-operative complications include chronic infections, non-union, coccidiodinia, crankshaft phenomena, implant-related issues, loss of correction and inadequate correction<sup>[20,21,25,36,37]</sup>.

## MANAGEMENT OF EARLY SPINE INFECTIONS IN PATIENTS WITH NEUROMUSCULAR SCOLIOSIS

Deep infections after instrumented fusion for the management of scoliosis are uncommon. However, when they do occur, they can result in considerable morbidity, costs and compromise of correction. As surgical and peri-operative techniques have improved, more severely affected children with complex neuromuscular deformities and considerable co-morbidities are now believed to be candidates for extensive surgery for spinal deformity. In the literature, the rate of spinal infections has been reported to increase with the complexity of the procedure, ranging between 1.9% and 20.0%<sup>[5,7,21,33,43]</sup>.

In acute deep spinal infection, the goals are to eradicate the infection by proper debridement of infected and devitalized tissues and to maintain the hardware to avoid losing correction. Most common organisms are *Staphylococcus aureus* and *Enterococcus* spp. However, rises in methicillin-resistant *S. aureus* (MRSA) and *S. aureus* has been observed.

Various treatment protocols for debridement, soft-tissue management and antibiotic therapy have been recommended with mixed results. The use of the wound vacuum-assisted closure (VAC) system (KCI Inc., San Antonio, Texas, USA) has gained increasing popularity in the management of acute, sub-acute and chronic wounds. Vacuum-assisted closure is a relatively new technique for promoting the healing of infected wounds that are resistant to treatment by established methods<sup>[33,43]</sup>.

The controlled application of sub-atmospheric pressure facilitates the formation of granulation tissue, assists debridement of necrotic tissue and acts as a sterile barrier. Increasing use of the VAC system for complex soft-tissue injuries has generally resulted in accelerated wound healing, compared with traditional methods.

## Application of the VAC system

The VAC system consists of a polyurethane ether foam sponge with open pores, 400 µm to 600 µm in size, a connecting tube and a plastic sealant. After thorough lavage and removal of all macroscopic contamination, devitalized tissue and loose bone grafts, the VAC sponge is cut and fitted into the wound. The plastic sealant is used to cover the sponge and is applied several centimeters beyond the margins of the wound to create an airtight seal. A cruciate incision is made in the plastic sealant covering the sponge, through which a suction tube is inserted and fixed. The tubing is connected to a negative pressure device. The sponge is compressed at sub-atmospheric pressure (-125 mmHg), continuously or intermittently. "Controlled negative pressure" is used to evacuate edema from the wound, increase blood flow, decrease bacterial load and increase the formation of granulation tissue. The system also assists the debridement of necrotic tissue and acts as a sterile barrier<sup>[33,43]</sup>.

Intra-operative debridement should involve thorough lavage and removal of all macroscopic contamination, devitalized tissue and loose bone grafts. No attempt should be made to remove grafts that are partially or fully fused. Intra-operative specimens for bacteriological culture must be obtained before application of the VAC system<sup>[33,43]</sup>.

Canavese *et al.*<sup>[43]</sup> treated 14 patients with early post-operative infections in which removal of the implant was undesirable because fusion had not been achieved. These authors had no patients who required removal of hardware and no loss of correction at an average of 44 mo of follow-up.

## DISCUSSION/CONCLUSION

In patients with neuromuscular disease, the likelihood and severity of scoliosis increase with the degree of neuromuscular involvement. There is little doubt that segmental instrumentation techniques have revolutionized the care of patients with neuromuscular scoliosis by providing lasting correction, significant relief of pain, and restoration of quality of life and sitting positions. Moreover, continuous evolution in segmental instrumentation has increased the percentage of successful surgical corrections.

However, it must be stressed that although neuromuscular scoliosis can be well corrected with different constructs (hooks, screws, sub-laminar bands, U-rods, L-rods), there is a high rate of associated complications<sup>[5,33,44,45]</sup>. The complication rates have increased with time, and an increasing number of complications have been reported in the recent literature. This can be explained by the improvement in complication recording but also that more severe patients are now operated. The evidence of such complications should never be underestimated by the treating surgeon, and the rate of such complications is particularly high in patients with flaccid neuromuscular scoliosis, *i.e.*, spinal muscular atrophy and Duchenne muscular dystrophy<sup>[22]</sup>.



The literature regarding the surgical management of spinal deformities in neuromuscular disorders has suggested that bilateral instrumentation and fusion to either L5 or the sacrum are the most effective, and multiple fixation points, such as sub-laminar wires or bands, are preferred<sup>[23,24,36,38,45]</sup>. In our opinion, instrumentation of the pelvis is indicated in non-ambulatory patients with pelvic obliquity. Fixation of the pelvis can be obtained with iliac screws, while hybrid instrumentation (screws, hooks, sub-laminar bands) or band-only instrumentation can be used for deformity correction. Fusion to the sacrum should be avoided in patients with residual walking ability.

In contrast, ambulatory patients should be fused to L5 at most with hybrid constructs (screws as distal anchorages, hooks and sub-laminar bands as proximal anchorages).

Restoring the sagittal balance of the spine is one of the most challenging goals in scoliosis surgery. Sub-laminar bands have been demonstrated to provide good deformity correction on both the coronal and sagittal planes<sup>[46]</sup>. Moreover, the operative time, bleeding and radiation exposure are reduced, with a low rate of early or late surgical complications.

The state of knowledge regarding neuromuscular scoliosis is a dynamic process, so a current literature review was mandatory. The somewhat large bibliography for this subject reflects the many opinions and findings presented here<sup>[1,10,43,46,47]</sup>.

## REFERENCES

- 1 **Madigan RR**, Wallace SL. Scoliosis in the institutionalized cerebral palsy population. *Spine* (Phila Pa 1976) 1981; **6**: 583-590 [PMID: 7336281]
- 2 **Comstock CP**, Leach J, Wenger DR. Scoliosis in total-body-involvement cerebral palsy. Analysis of surgical treatment and patient and caregiver satisfaction. *Spine* (Phila Pa 1976) 1998; **23**: 1412-1424; discussion 1412-1424 [PMID: 9654634]
- 3 **Saito N**, Ebara S, Ohotsuka K, Kumeta H, Takaoka K. Natural history of scoliosis in spastic cerebral palsy. *Lancet* 1998; **351**: 1687-1692 [PMID: 9734885 DOI: 10.1016/s0140-6736(98)01302-6]
- 4 **Bowen RE**, Abel MF, Arlet V, Brown D, Burton DC, D' Ambra P, Gill L, Hoekstra DV, Karlin LI, Raso J, Sanders JO, Schwab FJ. Outcome assessment in neuromuscular spinal deformity. *J Pediatr Orthop* 2012; **32**: 792-798 [PMID: 23147622 DOI: 10.1097/BPO.0b013e318273ab5a]
- 5 **Lonstein JE**, Koop SE, Novachek TF, Perra JH. Results and complications after spinal fusion for neuromuscular scoliosis in cerebral palsy and static encephalopathy using luque galveston instrumentation: experience in 93 patients. *Spine* (Phila Pa 1976) 2012; **37**: 583-591 [PMID: 21673625 DOI: 10.1097/BRS.0b013e318225ebd5]
- 6 **Cady RB**, Bobechko WP. Incidence, natural history, and treatment of scoliosis in Friedreich's ataxia. *J Pediatr Orthop* 1984; **4**: 673-676 [PMID: 6511892 DOI: 10.1097/01241398-198411000-00003]
- 7 **Jevsevar DS**, Karlin LI. The relationship between preoperative nutritional status and complications after an operation for scoliosis in patients who have cerebral palsy. *J Bone Joint Surg Am* 1993; **75**: 880-884 [PMID: 8314827]
- 8 **Miller A**, Temple T, Miller F. Impact of orthoses on the rate of scoliosis progression in children with cerebral palsy. *J Pediatr Orthop* 1996; **16**: 332-335 [PMID: 8728632 DOI: 10.1097/01241398-199605000-00007]
- 9 **Sponseller PD**, LaPorte DM, Hungerford MW, Eck K, Bridwell KH, Lenke LG. Deep wound infections after neuromuscular scoliosis surgery: a multicenter study of risk factors and treatment outcomes. *Spine* (Phila Pa 1976) 2000; **25**: 2461-2466 [PMID: 11013497]
- 10 **Thomson JD**, Banta JV. Scoliosis in cerebral palsy: an overview and recent results. *J Pediatr Orthop B* 2001; **10**: 6-9 [PMID: 11269813]
- 11 **Resina J**, Alves AF. A technique of correction and internal fixation for scoliosis. *J Bone Joint Surg Br* 1977; **59**: 159-165 [PMID: 873976]
- 12 **Luque ER**. Segmental spinal instrumentation for correction of scoliosis. *Clin Orthop Relat Res* 1982; **(163)**: 192-198 [PMID: 7067252]
- 13 **Allen BL**, Ferguson RL. L-rod instrumentation for scoliosis in cerebral palsy. *J Pediatr Orthop* 1982; **2**: 87-96 [PMID: 7076839]
- 14 **Sponseller PD**, Whiffen JR, Drummond DS. Interspinous process segmental spinal instrumentation for scoliosis in cerebral palsy. *J Pediatr Orthop* 2001; **6**: 559-563 [PMID: 3760165 DOI: 10.1097/01241398-198609000-00006]
- 15 **Herring JA**, Wenger DR. Segmental spinal instrumentation: a preliminary report of 40 consecutive cases. *Spine* (Phila Pa 1976) 1982; **7**: 285-298 [PMID: 7112243]
- 16 **Gersoff WK**, Renshaw TS. The treatment of scoliosis in cerebral palsy by posterior spinal fusion with Luque-rod segmental instrumentation. *J Bone Joint Surg Am* 1988; **70**: 41-44 [PMID: 3335572]
- 17 **Boachie-Adjei O**, Lonstein JE, Winter RB, Koop S, vanden Brink K, Denis F. Management of neuromuscular spinal deformities with Luque segmental instrumentation. *J Bone Joint Surg Am* 1989; **71**: 548-562 [PMID: 2703515]
- 18 **Broom MJ**, Banta JV, Renshaw TS. Spinal fusion augmented by luque-rod segmental instrumentation for neuromuscular scoliosis. *J Bone Joint Surg Am* 1989; **71**: 32-44 [PMID: 2913001]
- 19 **Bell DF**, Moseley CF, Koreska J. Unit rod segmental spinal instrumentation in the management of patients with progressive neuromuscular spinal deformity. *Spine* (Phila Pa 1976) 1989; **14**: 1301-1307 [PMID: 2617359]
- 20 **Modi HN**, Hong JY, Mehta SS, Srinivasalu S, Suh SW, Yi JW, Yang JH, Song HR. Surgical correction and fusion using posterior-only pedicle screw construct for neuropathic scoliosis in patients with cerebral palsy: a three-year follow-up study. *Spine* (Phila Pa 1976) 2009; **34**: 1167-1175 [PMID: 19444065 DOI: 10.1097/BRS.0b013e31819c38b7]
- 21 **Nectoux E**, Giacomelli MC, Karger C, Herbaux B, Clavert JM. Complications of the Luque-Galveston scoliosis correction technique in paediatric cerebral palsy. *Orthop Traumatol Surg Res* 2010; **96**: 354-361 [PMID: 20471343 DOI: 10.1016/j.otsr.2010.01.004]
- 22 **Modi HN**, Suh SW, Hong JY, Cho JW, Park JH, Yang JH. Treatment and complications in flaccid neuromuscular scoliosis (Duchenne muscular dystrophy and spinal muscular atrophy) with posterior-only pedicle screw instrumentation. *Eur Spine J* 2010; **19**: 384-393 [PMID: 19885687 DOI: 10.1007/s00586-009-1198-z]
- 23 **Mazda K**, Ilharreborde B, Even J, Lefevre Y, Fitoussi F, Penneçot GF. Efficacy and safety of posteromedial translation for correction of thoracic curves in adolescent idiopathic scoliosis using a new connection to the spine: the Universal Clamp. *Eur Spine J* 2009; **18**: 158-169 [PMID: 19089466 DOI: 10.1007/s00586-008-0839-y]
- 24 **La Rosa G**, Giglio G, Oggiano L. Surgical treatment of neurological scoliosis using hybrid construct (lumbar transpedicular screws plus thoracic sublaminar acrylic loops). *Eur Spine J* 2011; **20** Suppl 1: S90-S94 [PMID: 21404032 DOI: 10.1007/s00586-011-1751-4]
- 25 **Yazici M**, Asher MA, Hardacker JW. The safety and efficacy



- of Isola-Galveston instrumentation and arthrodesis in the treatment of neuromuscular spinal deformities. *J Bone Joint Surg Am* 2000; **82**: 524-543 [PMID: 10761943]
- 26 **Thometz JG**, Simon SR. Progression of scoliosis after skeletal maturity in institutionalized adults who have cerebral palsy. *J Bone Joint Surg Am* 1988; **70**: 1290-1296 [PMID: 3182881]
  - 27 **Bergofsky EH**, Turino GM, Fishman AP. Cardiorespiratory failure in kyphoscoliosis. *Medicine* (Baltimore) 1959; **38**: 263-317 [PMID: 13799416]
  - 28 **Bjure J**, Grimby G, Kasalický J, Lindh M, Nachemson A. Respiratory impairment and airway closure in patients with untreated idiopathic scoliosis. *Thorax* 1970; **25**: 451-456 [PMID: 5485005]
  - 29 **Kafer ER**. Respiratory function in paralytic scoliosis. *Am Rev Respir Dis* 1974; **110**: 450-457 [PMID: 4415584]
  - 30 **Mellies U**, Ragette R, Schwake C, Boehm H, Voit T, Teschler H. Daytime predictors of sleep disordered breathing in children and adolescents with neuromuscular disorders. *Neuromuscul Disord* 2003; **13**: 123-128 [PMID: 12565909 DOI: 10.1016/S0960-8966(02)00219-5]
  - 31 **Cotton LA**. Unit rod segmental spinal instrumentation for the treatment of neuromuscular scoliosis. *Orthop Nurs* 1991; **10**: 17-23 [PMID: 1923573]
  - 32 **Senaran H**, Shah SA, Glutting JJ, Dabney KW, Miller F. The associated effects of untreated unilateral hip dislocation in cerebral palsy scoliosis. *J Pediatr Orthop* 2006; **26**: 769-772 [PMID: 17065943 DOI: 10.1097/01.bpo.0000242426.60995.29]
  - 33 **Canavese F**, Emara K, Sembrano JN, Bialik V, Aiona MD, Sussman MD. Varus derotation osteotomy for the treatment of hip subluxation and dislocation in GMFCS level III to V patients with unilateral hip involvement. Follow-up at skeletal maturity. *J Pediatr Orthop* 2010; **30**: 357-364 [PMID: 20502236 DOI: 10.1097/BPO.0b013e3181d8fbc1]
  - 34 **Gau YL**, Lonstein JE, Winter RB, Koop S, Denis F. Luque-Galveston procedure for correction and stabilization of neuromuscular scoliosis and pelvic obliquity: a review of 68 patients. *J Spinal Disord* 1991; **4**: 399-410 [PMID: 1810562]
  - 35 **Hopf C**, Rompe JD, Heine J. [Indications and results of surgical treatment of neuromuscular scoliosis]. *Z Orthop Ihre Grenzgeb* 1992; **130**: 146-151 [PMID: 1598772 DOI: 10.1055/s-2008-1040129]
  - 36 **Neustadt JB**, Shuffelbarger HL, Cammisa FP. Spinal fusions to the pelvis augmented by Cotrel-Dubousset instrumentation for neuromuscular scoliosis. *J Pediatr Orthop* 1992; **12**: 465-469 [PMID: 1613088 DOI: 10.1097/01241398-199207000-00009]
  - 37 **Onimus M**, Manzone P, Lornet JM, Laurain JM. [Surgical treatment of scoliosis in bed-ridden patients with cerebral palsy]. *Rev Chir Orthop Reparatrice Appar Mot* 1992; **78**: 312-318 [PMID: 1289982]
  - 38 **Sussman MD**, Little D, Alley RM, McCoig JA. Posterior instrumentation and fusion of the thoracolumbar spine for treatment of neuromuscular scoliosis. *J Pediatr Orthop* 1996; **16**: 304-313 [PMID: 8728629 DOI: 10.1097/01241398-199605000-00004]
  - 39 **Frischhut B**, Sterzinger W, Rachbauer F, Klestil T, Krismer M, Bauer R. Surgical treatment of neuropathic scoliosis: morphologic and functional outcome. *Arch Orthop Trauma Surg* 1997; **116**: 367-372 [PMID: 9266043 DOI: 10.1007/BF00433992]
  - 40 **Marchesi D**, Arlet V, Stricker U, Aebi M. Modification of the original Luque technique in the treatment of Duchenne's neuromuscular scoliosis. *J Pediatr Orthop* 1997; **17**: 743-749 [PMID: 9591975 DOI: 10.1097/01241398-199711000-00008]
  - 41 **Smith JS**, Shaffrey CI, Sansur CA, Berven SH, Fu KM, Broadstone PA, Choma TJ, Goytan MJ, Noordeen HH, Knapp DR, Hart RA, Donaldson WF, Polly DW, Perra JH, Boachie-Adjei O. Rates of infection after spine surgery based on 108,419 procedures: a report from the Scoliosis Research Society Morbidity and Mortality Committee. *Spine* (Phila Pa 1976) 2011; **36**: 556-563 [PMID: 21192288 DOI: 10.1097/BRS.0b013e3181eadd41]
  - 42 **Hamilton DK**, Smith JS, Sansur CA, Glassman SD, Ames CP, Berven SH, Polly DW, Perra JH, Knapp DR, Boachie-Adjei O, McCarthy RE, Shaffrey CI. Rates of new neurological deficit associated with spine surgery based on 108,419 procedures: a report of the scoliosis research society morbidity and mortality committee. *Spine* (Phila Pa 1976) 2011; **36**: 1218-1228 [PMID: 21217448 DOI: 10.1097/BRS.0b013e3181ec5fd9]
  - 43 **Canavese F**, Gupta S, Krajchich JI, Emara KM. Vacuum-assisted closure for deep infection after spinal instrumentation for scoliosis. *J Bone Joint Surg Br* 2008; **90**: 377-381 [PMID: 18310764 DOI: 10.1302/0301-620x.90b3.19890]
  - 44 **Sharma S**, Wu C, Andersen T, Wang Y, Hansen ES, Bünger CE. Prevalence of complications in neuromuscular scoliosis surgery: a literature meta-analysis from the past 15 years. *Eur Spine J* 2013; **22**: 1230-1249 [PMID: 23085815 DOI: 10.1007/s00586-012-2542-2]
  - 45 **Mattila M**, Jalanko T, Puisto V, Pajulo O, Helenius IJ. Hybrid versus total pedicle screw instrumentation in patients undergoing surgery for neuromuscular scoliosis: a comparative study with matched cohorts. *J Bone Joint Surg Br* 2012; **94**: 1393-1398 [PMID: 23015567 DOI: 10.1302/0301-620x.94b10.29383]
  - 46 **La Rosa G**, Giglio G, Oggiano L. Sagittal profile control in patients affected by neurological scoliosis using Universal Clamps: a 4-year follow-up study. *Eur Spine J* 2012; **21** Suppl 1: S32-S36 [PMID: 22407266 DOI: 10.1007/s00586-012-2237-8]
  - 47 **Lebel DE**, Corston JA, McAdam LC, Biggar WD, Alman BA. Glucocorticoid treatment for the prevention of scoliosis in children with Duchenne muscular dystrophy: long-term follow-up. *J Bone Joint Surg Am* 2013; **95**: 1057-1061 [PMID: 23783200 DOI: 10.2106/jbjs.1.01577]

**P- Reviewers:** Aota Y, Lykissas MG **S- Editor:** Wen LL  
**L- Editor:** A **E- Editor:** Lu YJ



## Pathophysiology, diagnosis and treatment of intermittent claudication in patients with lumbar canal stenosis

Shigeru Kobayashi

Shigeru Kobayashi, Department of Orthopaedics and Rehabilitation Medicine, Faculty of Medical Sciences, and the Research and Education Program for Life Science, the University of Fukui, Fukui 910-1193, Japan

Author contributions: Kobayashi S solely contributed to this paper.

Supported by Grant-in Aid from the Ministry of Education, Science and Culture of Japan, No. 25460719

Correspondence to: Shigeru Kobayashi, MD, PhD, Department of Orthopaedics and Rehabilitation Medicine, Faculty of Medical Sciences, and the Research and Education Program for Life Science, the University of Fukui, Shimoaizuki 23, Fukui 910-1193, Japan. [kshigeru@u-fukui.ac.jp](mailto:kshigeru@u-fukui.ac.jp)

Telephone: +81-776-618383 Fax: +81-776-618125

Received: October 30, 2013 Revised: December 17, 2013

Accepted: March 03, 2014

Published online: April 18, 2014

### Abstract

Spinal nerve roots have a peculiar structure, different from the arrangements in the peripheral nerve. The nerve roots are devoid of lymphatic vessels but are immersed in the cerebrospinal fluid (CSF) within the subarachnoid space. The blood supply of nerve roots depends on the blood flow from both peripheral direction (ascending) and the spinal cord direction (descending). There is no hypovascular region in the nerve root, although there exists a so-called water-shed of the blood-stream in the radicular artery itself. Increased mechanical compression promotes the disturbance of CSF flow, circulatory disturbance starting from the venous congestion and intradiscal edema formation resulting from the breakdown of the blood-nerve barrier. Although this edema may diffuse into CSF when the subarachnoid space is preserved, the endoneurial fluid pressure may increase when the area is closed by increased compression. On the other hand, the nerve root tissue has already degenerated under the compression and the numerous macrophages releasing various chemical mediators, aggravating radicular symptoms that appear

in the area of Wallerian degeneration. Prostaglandin E<sub>1</sub> (PGE<sub>1</sub>) is a potent vasodilator as well as an inhibitor of platelet aggregation and has therefore attracted interest as a therapeutic drug for lumbar canal stenosis. However, investigations in the clinical setting have shown that PGE<sub>1</sub> is effective in some patients but not in others, although the reason for this is unclear.

© 2014 Baishideng Publishing Group Co., Limited. All rights reserved.

**Key words:** Lumbar canal stenosis; Cauda equine; Nerve root; Prostaglandin E<sub>1</sub>; Blood flow

**Core tip:** The radicular symptoms associated with degenerative disease of the lumbar spine are reported to be attributable to a combination of mechanical nerve root compression and resultant circulatory disturbance. Disturbance of blood flow in the cauda equina and nerve roots is reported to play an important role in the mechanism of intermittent claudication in patients with lumbar canal stenosis. Prostaglandin E<sub>1</sub> (PGE<sub>1</sub>) is a potent vasodilator as well as an inhibitor of platelet aggregation and has therefore attracted interest as a therapeutic drug for lumbar canal stenosis with intermittent claudication. However, investigations in the clinical setting have shown that lipo-PGE<sub>1</sub> is effective in some patients but not in others, although the reason for this is unclear.

Kobayashi S. Pathophysiology, diagnosis and treatment of intermittent claudication in patients with lumbar canal stenosis. *World J Orthop* 2014; 5(2): 134-145 Available from: URL: <http://www.wjgnet.com/2218-5836/full/v5/i2/134.htm> DOI: <http://dx.doi.org/10.5312/wjo.v5.i2.134>

### INTRODUCTION

Lumbar canal stenosis (LCS) is increasingly a common

**Table 1 International classification of lumbar canal stenosis**

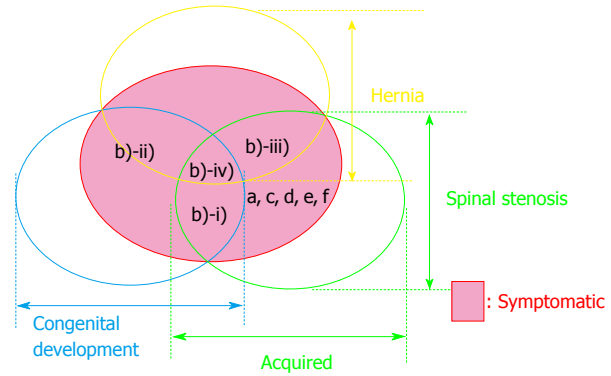
Congenital/developmental
Acquired
Degenerative (spondylosis)
Central
peripheral
Degenerative spondylolisthesis
Combined
Congenital/developmental + Degenerative
Congenital/developmental + Hernia
Degenerative + Hernia
Congenital/developmental + Degenerative + Hernia
Spondylolisthetic/spondylolytic
Iatrogenic
Post-traumatic
Miscellaneous

Reproduced with permission from Arnoldi *et al*<sup>[12]</sup>.

disease in the elderly. The number of patients with LCS complaining of low back pain, lower extremity pain and/or numbness, and neurogenic intermittent claudication (NIC) has increased yearly<sup>[1,2]</sup>. Compression of the cauda equina and nerve roots by LCS is a major clinical problem associated with NIC<sup>[3-5]</sup>. The development of NIC in LCS has been reported to involve circulatory disturbance due to circumferential compression of cauda equina by the surrounding tissues. When lumbar lordosis increases in the standing position, the severity of stenosis increases and the cauda equina are constricted more strongly, while the constriction decreases in the sitting position or when the trunk is flexed. As a result, NIC is often noted as a characteristic feature. The main symptoms of NIC include deep muscular pain, weakness and loss of sensation in the lower limbs. Such symptoms do not develop immediately after the start of walking, but eventually become severe enough to disturb walking. The patient can only walk from 40-50 m to 400-500 m without resting and the symptoms resolve after resting for several to 10 min. Thus, it is generally agreed that the primary cause of NIC is chronic compression of the cauda equina. In this article, we have reviewed the pathophysiology, diagnosis, and treatment of LCS associated with NIC.

## DEFINITION AND CLASSIFICATION OF LCS

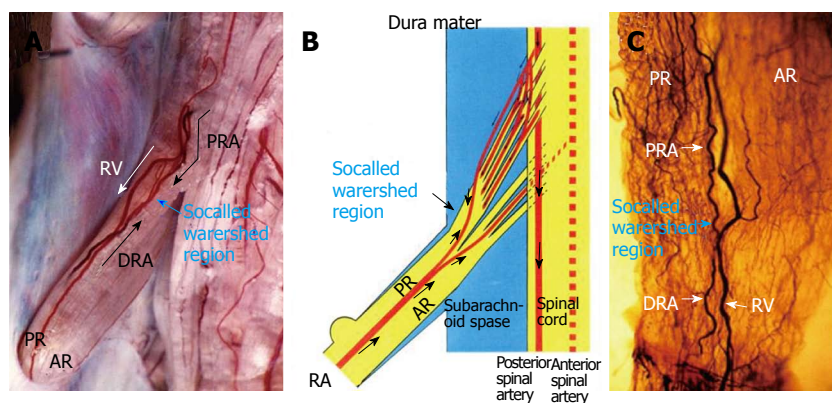
In 1910, Sumida gave the first description of LCS due to fetal chondrodysplasia<sup>[6]</sup>. Sarpyener reported such stenosis due to congenital partial skeletal dysplasia in 1945<sup>[7]</sup>. Thus, both of them reported congenital conditions. The concept of LCS has been known widely since Verbiest reported on idiopathic developmental stenosis in French in 1949<sup>[8]</sup>, in Dutch in 1950<sup>[9]</sup>, and in English in 1954<sup>[10]</sup> and 1955<sup>[11]</sup>. In 1976, Arnoldi *et al*<sup>[12]</sup> proposed the international definition and classification of lumbar spinal canal stenosis that is still used widely. However, confusion has arisen with regard to interpretation, because it covers both central stenosis (spinal canal stenosis) and



**Figure 1 Schematic drawing illustrating the international classification of lumbar canal stenosis.**

lateral stenosis (nerve root canal and intervertebral foramen stenosis), and also covers acquired stenosis due to various degenerative diseases as well as congenital and developmental stenosis. Here, the international classification (Table 1) is interpreted and the problems with it are clarified. The word ‘stenosis’ implies narrowing of a hollow tubular structure. On this basis, LCS may be defined as any type of narrowing of the spinal canal, nerve root canals (or tunnels) or intervertebral foramina. It may be local, segmental or generalized. It may be caused by bone or by soft tissue and the narrowing may involve the bony canal alone or the dural sac or both. Herniations of the nucleus pulposus have in the past been considered as a distinct and separate entity. They are included in this classification when they occur together with other types of stenosis, which is frequently the case. Space occupying lesions due to the products of inflammation or neoplasm are in the strictest sense types of “stenosis” but are excluded. According to this definition, the symptoms caused by LCS are non-specific and very varied.

Figure 1 is designed to make this classification easier to understand. Among the acquired types of stenosis, spondylosis and degenerative spondylolisthesis are classified as degenerative stenosis accompanied with LCS (a, c, d, e, f in Figure 1). The condition is classified as combined stenosis (b-i) if congenital or developmental factors are also present. Disc herniation is not covered by the concept of spinal stenosis when it exists alone. However, it is classified as spinal stenosis (combined stenosis) when congenital or developmental (b-iii, iv) or degenerative (b-iii, iv) factors are also present. The success of surgical treatment for disc herniation is dependent on the presence of factors causing spinal stenosis. However, it is not always easy to determine whether there are such factors in patients with herniation and whether the stenosis is developmental or acquired. As a result, herniation accompanied by spinal canal or nerve root canal stenosis (b-ii, iii, iv) is often treated after misdiagnosis as simple herniation. On the other hand, patients with central or lateral stenosis who are treated under the diagnosis of spinal stenosis due to spondylosis or degenerative spondylolisthesis may also sometimes have combined devel-



**Figure 2** Circulatory dynamics of the radicular artery for the lumbar nerve root in a dog. A: After 3 mL of India ink was injected quickly through a catheter fixed in the aortic arch, serigraphy was performed using a motor-driven camera and repeating flash to observe the flow of India ink into vessels supplying the nerve root. After injection of India ink, at first the proximal radicular arteries (PRA) running along each root filament filled with India ink in a downward direction (↓). Next, the distal radicular arteries (DRA) filled with India ink in an upward direction (↑). A watershed region of blood flow was observed in a radicular vessel (blue arrow). At last, the radicular vein (RV) filled with India ink in the downward direction (white arrows); B: A watershed region was noted in the radicular artery, and in this region the velocity of both blood streams showed a decrease; C: A clear specimen of the nerve root from the same subject as shown in A. An abundant vascular network was noted in the root near the watershed area of the radicular artery observed by serigraphy. AR: Anterior root. Reproduced with permission from Kobayashi *et al*<sup>[28]</sup>.

opmental stenosis (b-i).

## BLOOD SUPPLY OF CAUDA EQUINA NERVE ROOT

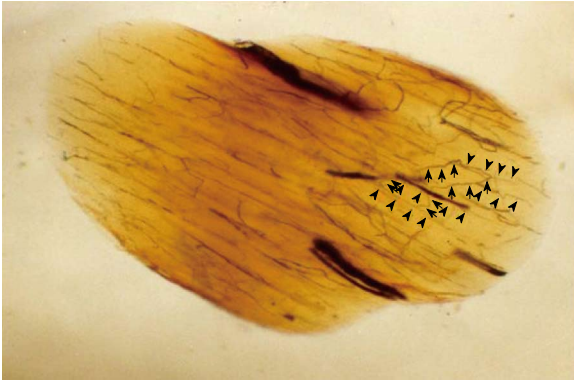
Anatomical studies of the vasculature of the nerve roots have developed in association with studies on the vasculature of the spinal cord. In the 19<sup>th</sup> century, Adamkiewicz<sup>[13,14]</sup> and Kady<sup>[15,16]</sup> clarified the particularly important role of radicular arteries in the blood supply of the spinal cord. After that, much work was devoted to the vasculature of the spinal cord<sup>[17-24]</sup>, but no research placed emphasis on the supply to the nerve roots until the mid-twentieth century. Corbin described anatomic details of radicular arteries and classified them into three groups: artères radiculo-grèzes, artères radiculo-pièmeriennes, and artères radiculo-médullaires<sup>[25]</sup>. The first two arteries were named as distal and proximal radicular arteries by Parke *et al*<sup>[26]</sup> and were thought to be nutrient arteries of the nerve roots. They described that each lumbosacral spinal nerve root receives its intrinsic blood supply from both distal and proximal radicular arteries, through which the blood flows toward a mutual anastomosis in the proximal one third of the root. They postulated that the region of relative hypovascularity formed below the conus by the combined areas of anastomoses in the cauda equina may provide an anatomic rationale for the suspected neuroischemic manifestations concurrent with degenerative changes in the lumbar spine. Crock *et al*<sup>[27]</sup> based on their studies, hold a different view: that there is no area of hypovascularity in the region of the middle third of the cauda equina. Kobayashi *et al*<sup>[28]</sup> also examined the vasculature of the cauda equina nerve root in dogs with the aid of high-speed serial photography after injecting India ink in the Aorta. Consequently, the blood flow direction of the extradural nerve root and descending in the cauda equina nerve root, and there existed a so-called watershed

of the blood-stream in the radicular artery itself near the root of the dural sleeve (Figure 2A, B). When the stream of the ascending radicular artery was intercepted by compression, however, the blood flow direction changed quickly and the blood supply was compensated by the descending radicular artery. Also abundant fine intrinsic arteries form networks in every part of the nerve root, including the area of so-called watershed of the radicular artery (Figure 2B). These observations indicate that there is no relatively hypovascular region in the nerve root, which is vulnerable in the course of degenerative changes of the lumbosacral spine. Although there exists a so-called watershed of the bloodstream in the radicular artery itself, the site of which is, however, changeable due to circumstances. Microangiograms showed an abundant vascular network with repeating T-shaped branching throughout the length of the nerve root (Figure 3). This was also present near the watershed region in the radicular artery, and there was no hypovascular region as suggested by Parke *et al*<sup>[26]</sup>. Thus, the intraradicular vessels controlled segmentally by radicular arteries have no fixed direction of flow and there appears to be no particular clinical significance in the watershed region of arteries maintaining a high intravascular pressure. Regarding the onset of compression-induced disturbance of nerve root circulation as observed in disk herniation and spinal canal stenosis, it is improbable that obstruction of the arterial system, which has thick walls and a high pressure, precedes obstruction of the venous system<sup>[29,30]</sup>.

## EFFECT OF ARTERIAL ISCHEMIA AND VENOUS CONGESTION ON NERVE ROOT FUNCTION

Whether mechanical deformation or a circulatory disturbance plays the more prominent role in the pathogenesis

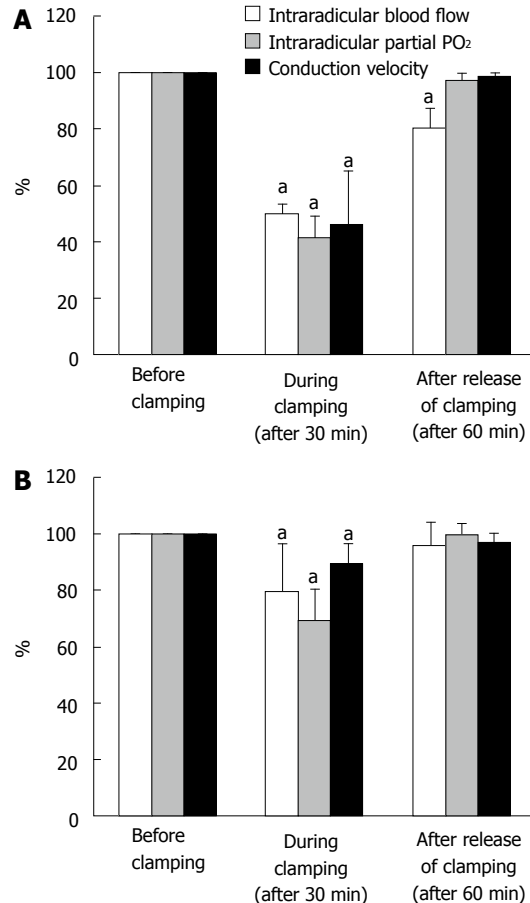




**Figure 3** Oblique cleared section of the lumbar nerve root in a dog. There are many longitudinal (arrow head) and transverse (arrow) microvessels in the nerve root. Intracellular vessels are abundant throughout the nerve root, and their flow is in various directions. Intracellular vessels arising from the radicular artery as T-shaped branches rarely were affected by the direction of blood flow in the nerve root, suggesting the presence of a mechanism that maintains the blood supply to the intrinsic vessels.

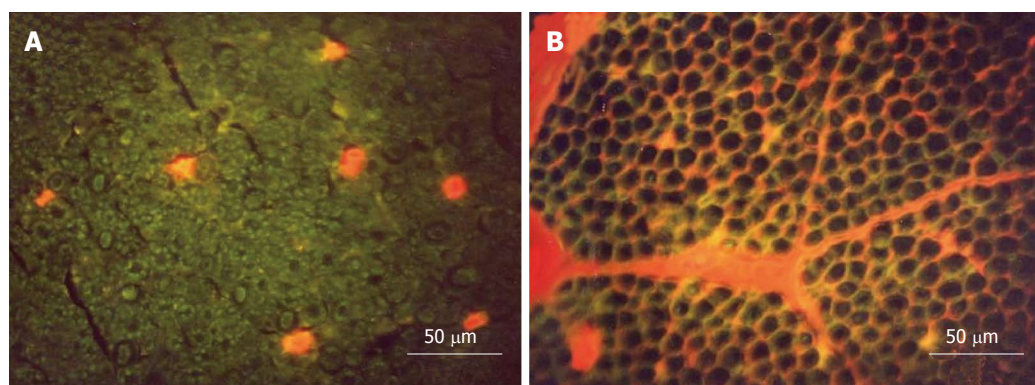
of NIC with LCS has been a subject of speculation for 5 decades. Blau and Logue postulated that NIC might be evoked with ischemic neuritis of the cauda equina<sup>[31]</sup>. Evans advocated exercise-induced ischemia as the cause of NIC, which is the characteristic syndrome of this disease<sup>[32]</sup>. They supposed that reduced blood flow in the spinal nerve roots has been demonstrated during exercise, and this might contribute to the pathogenesis of NIC. Ehni *et al*<sup>[33]</sup> stressed the postural changes in the spinal canal on standing. He demonstrated a myelographic block in the lordotic position, but flexion permitted the contrast medium to pass. Yamada *et al*<sup>[34]</sup> reported the importance of intermittent constriction of the cauda equina associated with postural change. They thought that the ligamentous fulcrum had a significant role in dynamic narrowing of the canal. Kavanaugh *et al*<sup>[35]</sup> reported that the increase of cerebrospinal fluid pressure below the blocked area might obstruct venous return and be the cause of anoxia of the cauda equina. Verbiest thought that this theory deserved further consideration, because he commonly found enlargement of the epidural venous plexus during decompression of spinal canal stenosis<sup>[36]</sup>. Although pathophysiology of the cauda equina induced by arterial ischemia or venous congestion has been an object of study for a long time, there is little agreement over which is more essential for NIC, ischemia or congestion.

Ischemic nerve root injury is a ubiquitous insult that can lead to a wide range of neuropathologic consequences, depending on the severity and duration of the ischemic event. Ischemic injury to nerve roots predominantly causes demyelination, although prolonged ischemia can also interfere with axonal transport, leading to axonal damage and Wallerian degeneration of the nerve fiber<sup>[37-40]</sup>. Vascular damage and fibrosis are common findings within the spinal canal and intervertebral foramina, and such vascular damage is significantly related to the severity of degenerative disc disease. Disc protrusion may lead to compression of epidural veins and dilation of

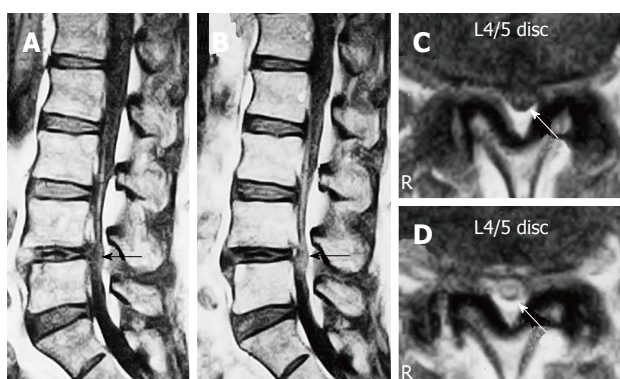


**Figure 4** Changes of intracellular blood flow, partial oxygen pressure and conduction velocity after Aorta (A) or inferior vena cava (B) clamping. Immediately after Aorta clamping, blood pressure in the femoral artery dropped to 26-40 mmHg and meantime, central venous pressure was slightly elevated. When the vena cava was clamped, central venous pressure increased to about 4 times of the pressure before clamping and blood pressure in the femoral artery was reduced by half. The blood flow in the seventh posterior nerve root due to Aorta and vena cava clamping fall to 50% to 60% of the blood flow before clamping in the ischemic model ( $^{\circ}P < 0.05$ ) and to about 20% in the congestion model ( $^{\circ}P < 0.05$ ). The changes of partial oxygen pressure (PO<sub>2</sub>) in the nerve root indicated a similar tendency to blood flow, 50% to 60% drop in the ischemic model ( $^{\circ}P < 0.05$ ) and 20% to 40% drop in the congestion model. Conduction velocity of the nerve root diminished by 40% to 50% in the ischemia model ( $^{\circ}P < 0.05$ ) and 10% to 20% in the congestion model. After release of clamping, both arterial and venous pressures quickly returned to the pressure before clamping. The intracellular blood flow in the congestion model was restored within 1 h. The intracellular blood flow in the ischemic model, however, did not recover and stayed at the reduced level ( $^{\circ}P < 0.05$ ). Intracellular PO<sub>2</sub> recovered completely in both models. The drop of conduction velocity returned almost completely within one hour after release of clamping. Reproduced with permission from Kobayashi *et al*<sup>[42]</sup>.

non-compressed veins. Cooper *et al*<sup>[41]</sup> noted a significant relationship between evidence of venous obstruction, intraneural and perineural fibrosis, and neural atrophy. Fibrosis may further impede nutrient transfer to endoneurial fibers, as well as predisposing to nerve stretch injury. Kobayashi *et al*<sup>[42,43]</sup> assessed the influence of arterial ischemia and venous congestion resulting from obstruction of blood flow without nerve root compression on intracellular blood flow and radicular function (Figure 4). As a result, it was confirmed that nerve root ischemia had a



**Figure 5 Transverse sections of the nerve root seen under a fluorescence microscope.** A: Ischemia model. Evans blue albumin (EBA) emits a bright red fluorescence in clear contrast to the green fluorescence of the nerve tissue. After intravenous injection of EBA, EBA was limited inside the blood vessels, and the blood-nerve barrier was maintained; B: Congestion model. EBA emits a bright red fluorescence, which leaked outside the blood vessels, and intradiscal edema was seen under a fluorescent microscope. Reproduced with permission from Kobayashi *et al*<sup>[42]</sup>.



**Figure 6 Gadolinium-enhanced magnetic resonance imaging of the cauda equina edema in lumbar canal stenosis.** A 73-year-old man complained of weakness and numbness of the lower extremities after walking about 300 m, but no obvious sensory loss and muscle weakness was noted. Precontrast T1-weighted (500/35) sagittal (A) and axial (C) conventional spin echo MR image indicated a diagnosis of LCS at L4/5 disc level (arrows). T1-weighted (500/35) sagittal (B) and axial (D) Magnetic resonance image acquired at L4/5 disc level obtained after 0.1 mmol/kg intravenous Gd-DTPA administration showing the generalized central canal stenosis as well as punctuate areas of intrathecal enhancement (arrows) indicating a breakdown in the blood-nerve barrier. Reproduced with permission from Kobayashi *et al*<sup>[46]</sup>.

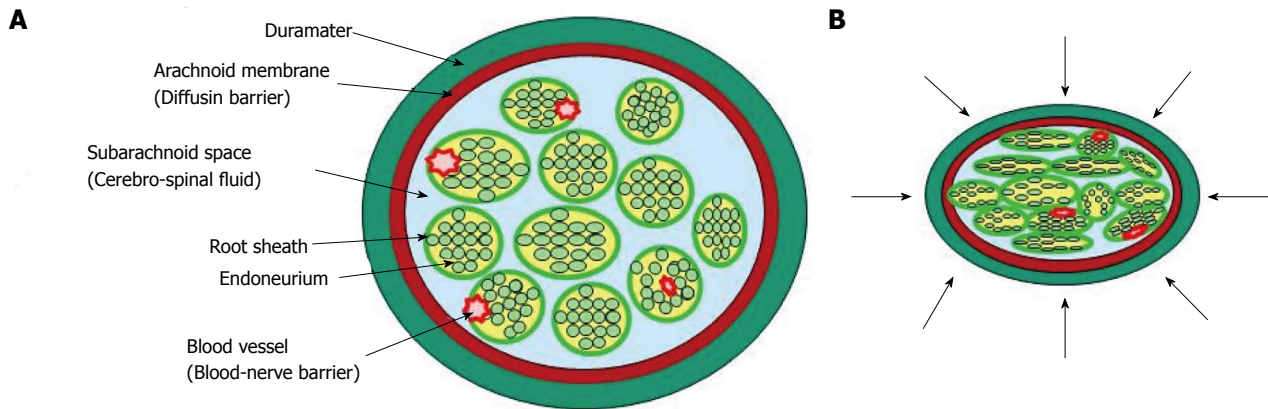
more serious influence on blood flow,  $PO_2$ , and conduction velocity than nerve root congestion. After 30 min of nerve root ischemia, recovery occurred with reperfusion, but longer ischemic periods will cause a permanent effect on radicular function due to oxygen deficiency. When changes of the femoral arterial and central venous pressures were monitored after obstruction of blood flow, both the arterial and venous pressures decreased after aortic blockade and the arterial pressure increased slightly after obstruction of the inferior vena cava. However, the central venous pressure showed an approximately 4-fold increase immediately after obstruction of the inferior vena cava, and this sudden increase in venous pressure could have a marked influence on the capillary pressure in the nerve roots. Usubiaga *et al*<sup>[44]</sup> demonstrated that clamping of the vena cava can be used experimentally to increase

the systemic venous pressure. The same maneuver also produces congestion of the epidural veins and increases the epidural pressure<sup>[45]</sup>. But they did not describe the changes in nerve root circulation.

The arachnoid membrane acts as a diffusion barrier for the nerve root and the blood-nerve barrier is also created by the vascular endothelial cells of the endoneurial microvessels. These nerve root barriers protect and maintain the nerve fibers in a constant environment. The capillary vessels of the nerve roots are lined by endothelial cells that contain only a few pinocytotic vesicles and are bound by tight junctions to form the blood-nerve barrier. Protein tracers that are injected intravenously do not normally leak out of the vessels due to this barrier<sup>[29,46]</sup>. When arterial ischemia was induced, protein tracers remained in the blood vessels, indicating maintenance of the integrity of the blood-nerve barrier (Figure 5A). On the other hand, venous congestion disrupted the blood-nerve barrier and there was extravasation and edema in the nerve roots (Figure 5B). Thus, the blood-nerve barrier that regulates vascular permeability in the nerve root seems to be susceptible to congestion which raises the intra vascular pressure rather than to ischemia which decreases the pressure.

## PATHOMECHANISM OF INTERMITTENT CLAUDICATION

MR imaging is useful because it can noninvasively reveal the severity of LCS. It is known that sites of nerve root compression by spinal canal stenosis frequently show gadolinium enhancement on MR images, suggesting that there is breakdown of the blood-nerve barrier and edema of the nerve root (Figure 6)<sup>[29,47-50]</sup>. In LCS associated with NIC, Kobayashi *et al*<sup>[46]</sup> and Jinkins *et al*<sup>[47-49]</sup> first reported gadolinium enhancement of the cauda equina above the level of stenosis. When the nerve roots in the cauda equina are compressed in association with LCS, the pressure is distributed in a circumferential manner



**Figure 7** Diagram that illustrates possible mechanical effects on cauda equina. A: Normal state; B: Lumbar canal stenosis. The pressure is applied to the cauda equina with many nerve roots in a circumferential manner.

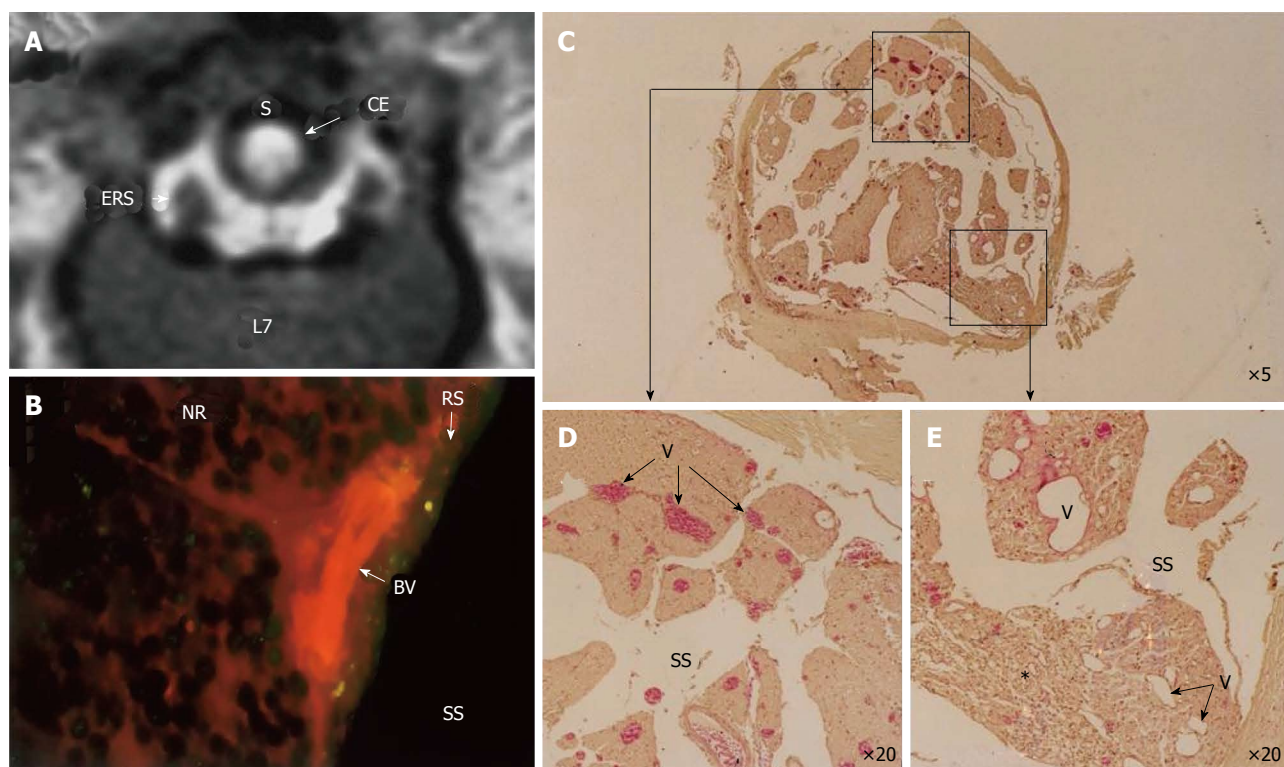
around the nerve root (Figure 7). Kobayashi *et al*<sup>[29]</sup> described that the blood-nerve barrier of the nerve root is disrupted and intradiscal edema is produced by acute compression with a microsurgical clip at more than 15 g of force for one hour or by chronic compression due to wrapping the nerve root for at least one month with a silastic tube slightly larger than the nerve root diameter<sup>[50]</sup>. They also demonstrated that the histological studies in circumferential constriction model of cauda equina revealed congestion and dilation of the intradiscal veins and Wallerian degeneration at site of constriction (Figure 8)<sup>[46]</sup>. These changes were considered to be attributed to intradiscal edema and were thought to explain the enhancement effect at the site of canal stenosis on gadolinium-enhanced MR images in LCS patients. These results suggest that NIC in LCS is caused by the following mechanism. Stenosis of the lumbar canal is aggravated by posterior flexion during walking, and circumferential mechanical compression of the cauda equina occurs repeatedly and increases in severity (Figure 7). As a result, the subarachnoid space is occluded, and congestion as well as degeneration of nerve fibers occurs in the cauda equina. Elevation of the capillary pressure induced by venous stasis is thought to cause intradiscal edema and the inflammatory response produced by compression, as well as mechanical damage to the blood-nerve barrier, because venous blood flow is stopped by compression at a very low pressure. An experiment performed by Olmarker demonstrated that the capillaries and venules of the nerve root could be occluded by mild compression of around 30-40 mmHg<sup>[30]</sup>. Takahashi *et al*<sup>[51]</sup> found that the epidural pressure is only 15 to 18 mmHg during lumbar flexion in LCS patients, but reaches 80 to 100 mmHg during lumbar extension. The epidural pressure increases with walking and the patient then stops walking because of leg pain and/or NIC. The pressure decreases immediately after walking is stopped and leg pain then subsides. There is a repeated pattern of increasing and decreasing pressure during walking. Although, these pressure changes are not great enough to disturb arterial blood flow, the epidural venous system may become congested if the pressure is higher than 10 to 30 mmHg.

Ikawa *et al*<sup>[52]</sup> demonstrated that ectopic firing was elicited by venous stasis in a rat model of lumbar canal stenosis. As a result, the subarachnoid space is occluded, and congestion as well as nerve fiber degeneration occurs in the cauda equina. Efflux of excess fluid into the subarachnoid space becomes impaired by the breakdown of the blood-nerve barrier, leading to an increase in endoneurial pressure<sup>[53,54]</sup>. Although such a pressure rise is reversible, a compartment syndrome may occur in the cauda equina at the site of stenosis, blood flow<sup>[55,56]</sup> and axonal flow disturbance<sup>[38,39]</sup>, provoking ectopic discharge or conduction disturbance<sup>[57,58]</sup> that is essentially responsible for NIC in nerve fibers which have been chronically damaged. Thus, venous congestion may be an essential factor precipitating circulatory disturbance in compressed nerve roots and inducing neurogenic intermittent claudication (Figure 9).

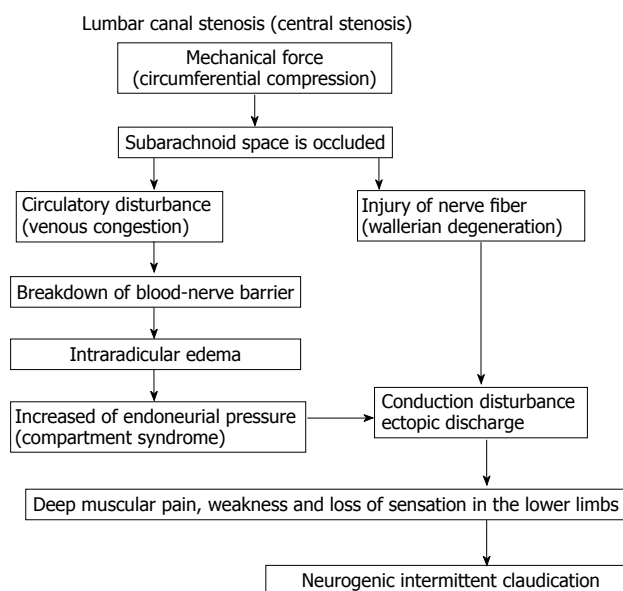
### EFFECT OF PROSTAGLANDIN-E1 TO NORMAL NERVE ROOT AND COMPRESSED NERVE ROOT

Prostaglandin E<sub>1</sub> (PGE<sub>1</sub>), a potent vasodilator and platelet aggregation inhibitor, is well known as a useful drug for peripheral arterial disease, such as Raynaud's and Buerger's diseases<sup>[59]</sup>, and diabetic neuropathy<sup>[60]</sup>. PGE<sub>1</sub> has been reported to relax the contraction of vascular smooth muscle cells<sup>[61]</sup> and increase blood flow in peripheral arteries<sup>[62]</sup>, followed by improvement of endothelial function<sup>[63]</sup>. Since PGE<sub>1</sub> is rapidly inactivated in the lungs, PGE<sub>1</sub> must be administered into the obstructed artery or a large amount of it has to be given intravenously. The distribution of PGE<sub>1</sub> *in-vivo* induces the systemic effects of diarrhea, hypotension, fever and hepatic dysfunction. PGE<sub>1</sub> also causes irritation in blood vessels near the site of injection. To avoid these problems, PGE<sub>1</sub> was mixed with microparticles 0.2 μm in diameter made of soybean oil. Because PGE<sub>1</sub> is incorporated into the lipid particles in this preparation, it is less susceptible to inactivation in the lung<sup>[64]</sup>. In addition, this preparation characteristically becomes concentrated and acts selectively in lesions be-





**Figure 8 Circumferential compression of the dog cauda equine.** The cauda equina was constricted outside the dura mater using a silicone tube (S), which caused 30% constriction of the diameter of the dura mater using a silicone tube at L6/7 disc level. After 3 wk constriction, clear enhancement was seen inside the cauda equina constricted by a silicon tube (S) as seen on gadolinium-enhanced magnetic resonance (MR) image [T1-weighted spin-echo (SE) image, 600/25 (TR/TE)] (A). No enhancement of epidural root sleeves (ERS) was found on this image. In the cauda equina, where enhancement was found on MR imaging, Evans blue albumin emits a bright red fluorescence which leaked outside the blood vessels, and intradiscal edema was seen under a fluorescent microscope (B). Light microscopy revealed congestion and dilation of the radicular veins (C-E) inside the cauda equina, inflammatory cells infiltration, and Wallerian degeneration (E, asterisk) was observed in the entrapped region. This situation was reflected as breakdown of blood-nerve barrier on fluorescent microscopy and high intensity on gadolinium-enhanced MR imaging. BV: Blood vessel; CE: Cauda equina; ENS: Epidural root sleeves; NR: Nerve root; RS: Root sheath; S: Silicon tube; SS: Subarachnoid space.



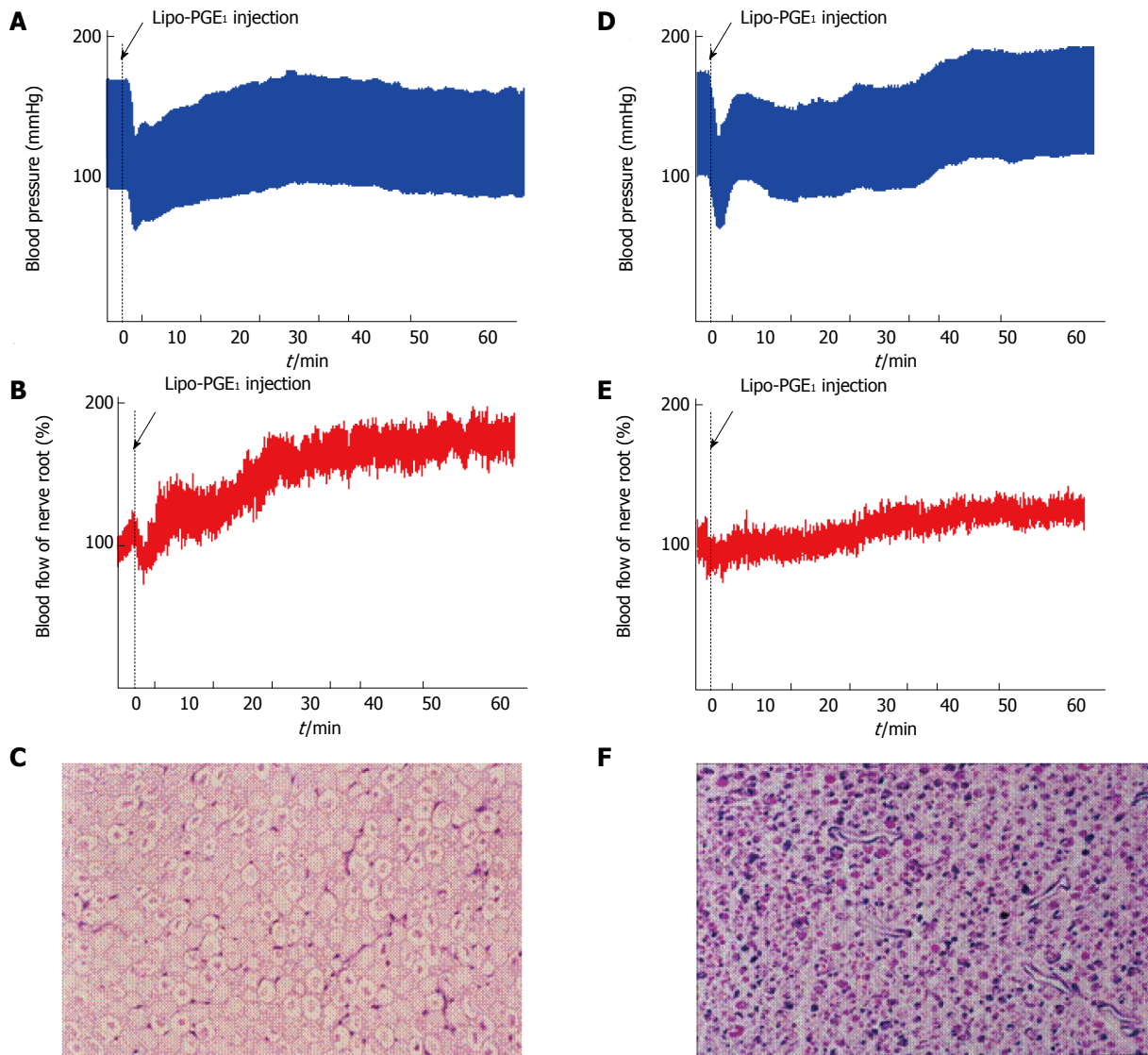
**Figure 9 Pathogenesis of neurogenic intermittent claudication in lumbar canal stenosis.**

cause the lipid particles adhere to the endothelial cells of injured blood vessels<sup>[65]</sup>. Lipid microspheres incorporating prostaglandin E<sub>1</sub> (lipo-PGE<sub>1</sub>) has therefore attracted in-

terest as a therapeutic drug for LCS. However, investigations in the clinical setting have shown that lipo-PGE<sub>1</sub> is effective in some patients but not in others<sup>[66-75]</sup>, although the reason for this is unclear.

So far, some experimental studies of the effect of lipo-PGE<sub>1</sub> on blood flow in normal<sup>[68,70]</sup> and compressed<sup>[76-80]</sup> nerve roots have reported an increase in flow, but none have examined the effect of lipo-PGE<sub>1</sub> on compressed sections with apparently Wallerian degeneration after nerve root compression. After investigating the changes of nerve root blood flow caused by bolus intravenous injection of Lipo-PGE<sub>1</sub>, Toribatake *et al*<sup>[68]</sup> reported a 59% increase of blood flow at a dose of 0.1 µg/kg, while Murakami *et al*<sup>[70]</sup> reported a 37.8% increase at a dose of 0.15 µg/kg. These experimental studies of the effect of lipo-PGE<sub>1</sub> on blood flow in normal nerve roots revealed an increase in flow, but did not examine the effect of lipo-PGE<sub>1</sub> on compressed nerve roots. Subsequently, the effect of PGE<sub>1</sub> on intradiscal blood flow was assessed in a rat cauda equina compression model, and PGE<sub>1</sub> was reported to increase blood flow. However, the extent of compression applied to the nerve root and its duration were both insufficient, and the response was not compared with tissue changes of the nerve root after compression<sup>[76-80]</sup>. Kobayashi *et al*<sup>[81]</sup> firstly demonstrated that intravenous injection of lipo-PGE<sub>1</sub> significantly





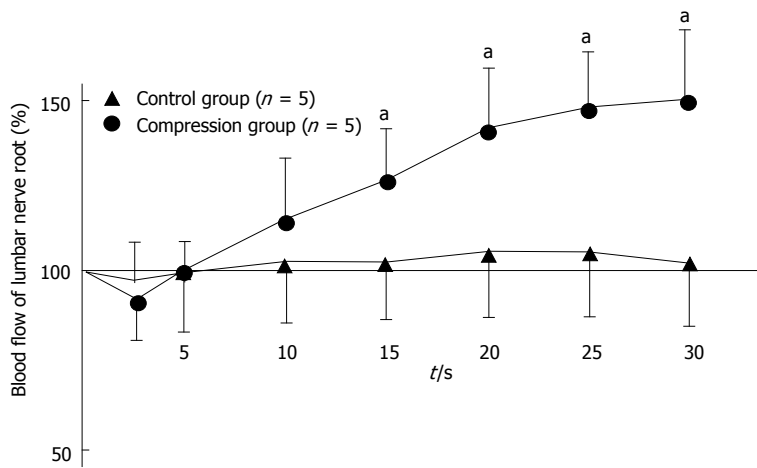
**Figure 10** Effect of prostaglandin E<sub>1</sub> on normal (A-C) and compressed nerve root (D-F). The seventh lumbar nerve root was clamped with a clip for 3 wk using dogs. After release of clipping, the intradiscal blood flow was measured before and after intravenous injection of lipo-prostaglandin E<sub>1</sub> (PGE<sub>1</sub>) (D-F). As the control group, animals were evaluated at 3 wk after laminectomy. The nerve root was only exposed and wasn't clamped with a clip (A-C). In the control (A) group, the mean blood pressure fell immediately after intravenous injection of lipo-PGE<sub>1</sub> due to the peripheral vasodilation, but then gradually increased and recovered after 20 min. The changes of blood pressure in the nerve root compression group were the same as those seen in the control group (D). Intravenous injection of lipo-PGE<sub>1</sub> also resulted in marked increase of blood flow in the normal nerve roots (B), but caused minimal enhancement of blood flow at the sites of nerve root compression exhibiting Wallerian degeneration (E). Histological examination revealed no degeneration of the nerve fibers in the control group (C). However, marked Wallerian degeneration was seen in the nerve root compression group (D). The relative number of small diameter axons increased in the compression group at 3 wk after operation compared with the control group (HE stain, original magnification X 50).

increased intradiscal blood flow in the normal nerve root without compression, but the increase of blood flow observed in the compressed region of the nerve root exhibiting Wallerian degeneration was transient and not sustained (Figures 10 and 11). It is therefore concluded that lipo-PGE<sub>1</sub> has less effect on severely damaged nerve roots than it does on normal nerve roots.

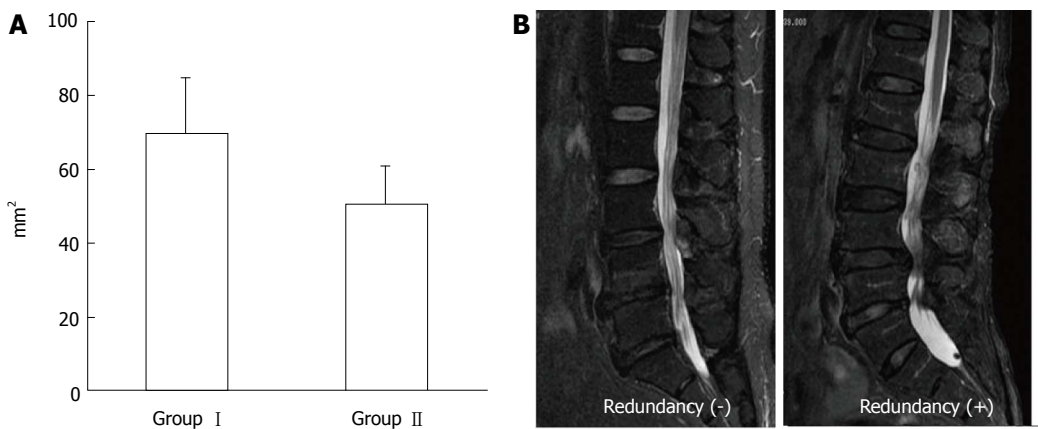
### EFFECT OF PGE<sub>1</sub> ON PATIENTS WITH NIC

PGE<sub>1</sub> has been used in the field of orthopedic surgery for the treatment of cervical and lumbar diseases. The results of numerous studies have also suggested that PGE<sub>1</sub> is likely to be useful for LCS, but its position has not been

firmly established among the treatments available<sup>[66-75]</sup>. It was reported that PGE<sub>1</sub> was effective for 57%-87% of patients with LCS accompanied by NIC (Table 2), but was ineffective in many patients with severe neurological deficits such as muscle weakness. Since it can be assumed that the impaired intradiscal blood flow is improved by the drug in patients whose NIC responds to administration of PGE<sub>1</sub>, this agent can be used for screening and staging of the disease. Yone *et al*<sup>[82]</sup> have reported that when lipo-PGE<sub>1</sub> was injected intravenously in 11 LCS patients during surgery, symptoms were alleviated in 6 patients with dilation of vessels running along the cauda equina, but not in 5 patients with no change of their vessels. Dezawa *et al*<sup>[83]</sup> observed the movement of red blood



**Figure 11** Changes in intradiscal blood flow after intravenous injection of lipo-prostaglandin E<sub>1</sub>. In normal (control) nerve roots (n = 5), intradiscal blood flow fell immediately after intravenous injection of lipo-Prostaglandin E<sub>1</sub> (PGE<sub>1</sub>), but gradually increased (<sup>a</sup>P < 0.05). After 30 min, the mean blood flow was 49% higher than before lipo-PGE<sub>1</sub> injection. However, the changes of intradiscal blood flow in the nerve root compression group (n = 5) were not as marked as in the control group, with the mean value after 30 min being only 5% higher than pretreatment value. Reproduced with permission from Kobayashi *et al*<sup>[81]</sup>.



**Figure 12** Magnetic resonance imaging of lumbar canal stenosis patients with neurogenic intermittent claudication. A: Cross-sectional area of dural sac (T1-w) at the site of maximal canal stenosis; B: Magnetic resonance imaging of redundant nerve root (T2-w).

Table 2 Effect of lipo-prostaglandin E <sub>1</sub> on patients with neurogenic intermittent claudication in lumbar canal stenosis					
Author	Year	Drug	Dose	Period	Effective rate to NIC
Takakura <sup>[66]</sup>	1986	PGE <sub>1</sub>	40-60 µg/d	14-28 consecutive days	79.5% (39/49 cases)
Miura <i>et al</i> <sup>[67]</sup>	1992	Lipo-PGE <sub>1</sub>	10 µg/d	10 d	57.1% (8/14 cases)
Toribatake <i>et al</i> <sup>[68]</sup>	1993	Lipo-PGE <sub>1</sub>	10 µg/d	10 consecutive days	75.0% (12/16 cases)
Kurihara <i>et al</i> <sup>[69]</sup>	1996	Limaprost	3 µg/d	42 consecutive days	27.3% (21/77 cases)
Murakami <i>et al</i> <sup>[70]</sup>	1997	Lipo-PGE <sub>1</sub>	15 µg/d	10 consecutive days	47.8% (33/69 cases)
			10 µg/d		77.5% (31/40 cases)
			5 µg/d		87.0% (40/46 cases)
Ono <i>et al</i> <sup>[71]</sup>	1997	Lipo-PGE <sub>1</sub>	10 µg/d	14 consecutive days	71.1% (27/38 cases)
			20 µg/d		76.5% (26/34 cases)
Miura <i>et al</i> <sup>[72]</sup>	1997	PGE <sub>1</sub>	120 µg/d	14 consecutive days	33.0% (5/12 cases)
Uratuji <i>et al</i> <sup>[73]</sup>	2003	Limaprost	15 µg/d	42 consecutive days	59.3% (54/91 cases)
Harrison <i>et al</i> <sup>[74]</sup>	2007	Limaprost	15 µg/d	42 consecutive days	50.7% (74/146 cases)
Nakanishi <i>et al</i> <sup>[75]</sup>	2008	PGE <sub>1</sub>	60 µg/d	14 consecutive days	71.4% (45/63 cases)

Reproduced with permission from Kobayashi *et al*<sup>[81]</sup>. NIC: Neurogenic intermittent claudication; PGE<sub>1</sub>: Prostaglandin E<sub>1</sub>.

cells in blood vessels running along the cauda equina by myelofiber scope in 8 LCS patients with NIC under local anesthesia, and reported that blood flow increased in 3 patients, stopped in 1, became retrograde in 2, and was unchanged in 2. In LCS patients, myelography and MRI often reveal a redundant nerve root. Suzuki *et al*<sup>[84]</sup> pathologically investigated the cauda equina at autopsy and

reported that the cause of nerve root redundancy was Wallerian degeneration.

We treated LCS patients with PGE<sub>1</sub> and compared their response with the magnetic resonance (MR) imaging. The subjects were 50 LCS patients with NIC (walking distance ≤ 300 m) and MR imaging evidence of central canal stenosis. They comprised 38 men and 12 women

aged 75-95 years (mean: 81 years). Each patient received PGE<sub>1</sub> intravenously at a dose of 10 µg/d for 14 d. After completing treatment, the MRI findings of 25 patients achieving relief from NIC (group I) and 25 patients without relief (group II) were retrospectively compared. In all patients, T<sub>1</sub>- and T<sub>2</sub>-weighted images were obtained. On T<sub>1</sub>-weighted images, the transverse area of the dural tube at the site of maximal canal stenosis was measured using a digitizer. The presence or absence of redundant nerve roots was also identified on T<sub>2</sub>-weighted images.

The transverse area of the dural tube at the site of maximal canal stenosis on MR images was 50.8-88.6 mm<sup>2</sup> (mean: 69.8 ± 15.2 mm<sup>2</sup>) in group I and 35.8-59.8 mm<sup>2</sup> (mean: 50.6 ± 10.3 mm<sup>2</sup>) in group II (Figure 12A). Redundant nerve roots were observed in 14 (56%) of the 25 patients from group II, being located proximal to the site of maximal stenosis, but were not seen in group I (Figure 12B). Intraradicular edema was observed in 21 (84%) of the 25 patients from group II, being located proximal to the site of maximal stenosis, but was only seen in 2 (8%) patients from group I (Figure 6). These results indicate that patients who have a transverse dural area ≤ 60 mm<sup>2</sup> and redundant nerve roots (suggesting Wallerian degeneration) may achieve little relief of NIC with PGE<sub>1</sub> therapy. From the findings of these clinical studies, it has been postulated that the severity of nerve degeneration is an important determinant of the response to PGE<sub>1</sub>. It is considered that LCS patients who are unresponsive to PGE<sub>1</sub> have nerve root degeneration that progresses to the irreversible stage, so that decompression by laminectomy or other methods cannot be expected to provide immediate marked improvement of neurological deficits such as sensory disorders and muscle weakness. In other words, it seems that the outcome of decompression surgery may be predicted from the response to PGE<sub>1</sub>, but further studies are required to confirm this possibility.

## ACKNOWLEDGMENTS

The submitted manuscript does not contain information about medical devices or drugs. No benefits in any form have been received or will be received from a commercial party related directly or indirectly to the subject of this article. I would like to thank Dr. Kenichi Takeno of the Orthopaedic Surgery, Faculty of Medical Sciences, The University of Fukui, Fukui, Japan Dr. Katuhiko Hayakawa and Mr. Takashi Nakane of the Aiko Orthopaedic Clinic, Aichi, Japan, and Dr. Yoshihiko Suzuki of Suzuki Orthopaedic Clinic, Gifu, for their technical assistance.

## REFERENCES

- Martinelli TA, Wiesel SW. Epidemiology of spinal stenosis. *Instr Course Lect* 1992; **41**: 179-181 [PMID: 1588062]
- Johnsson KE. Lumbar spinal stenosis. A retrospective study of 163 cases in southern Sweden. *Acta Orthop Scand* 1995; **66**: 403-405 [PMID: 7484117 DOI: 10.3109/17453679508995574]
- Verbiest H. Pathomorphological aspects of developmental lumbar stenosis. *Orthop Clin North Am* 1975; **6**: 177-196
- Schatzker J, Pennal GF. Spinal stenosis, a cause of cauda equina compression. *J Bone Joint Surg Br* 1968; **50**: 606-618 [PMID: 4235812]
- Kirkaldy-Willis WH, Paine KW, Cauchoux J, McIvor G. Lumbar canal stenosis. *Clin Orthop* 1974; **99**: 30-50 [DOI: 10.1097/00003086-197403000-00004]
- Sumita M. Beiträge zur Lehre von der Chondrodystrophie foetalis (Kaufmann) und osteogenesis imperfecta (Vrolik) mit besonderer Berücksichtigung der anatomischen und klinischen Differential Diagnose. *Dtsch Z Chir* 1910; **107**: 1-110 [DOI: 10.1007/BF02816153]
- Sarpyener MA. Congenital structure of the spinal canal. *J Bone Joint Surg* 1945; **27**: 70-79
- Verbiest H. Sur certaines formes rares de compression de la queue de cheval. In: *Hommage a Clovis Vincent*. Paris: Maloine, 1949: 161-174
- Verbiest H. Primaire stenose van het lumbale wervelkanaal bij volwassenen. *Ned T Geneesk* 1950; **94**: 2415-2433
- Verbiest H. A radicular syndrome from developmental narrowing of the lumbar vertebral canal. *J Bone Joint Surg* 1954; **36B**: 230-237
- Verbiest H. Further experiences on the pathological influence of a developmental narrowness of the bony lumbar vertebral canal. *J Bone Joint Surg* 1955; **37B**: 576-583
- Arnoldi CC, Brodsky AE, Cauchoux J, Crock HV, Dommissie GF, Edgar MA, Gargano FP, Jacobson RE, Kirkaldy-Willis WH, Kurihara A, Langenskiöld A, Macnab I, McIvor GW, Newman PH, Paine KW, Russin LA, Sheldon J, Tile M, Urist MR, Wilson WE, Wiltse LL. Lumbar spinal stenosis and nerve root entrapment syndromes. Definition and classification. *Clin Orthop Relat Res* 1976; **115**: 4-5
- Adamkiewicz A. Die Blutgefäße des menschlichen Rückenmarkes. I. Die Gefäße der Rückenmarkssubstanz. *Sitzungsber. Akad.d.Wiss, In Wien. Math.-Naturwiss Kl* 1881; **84**: 469-502
- Adamkiewicz A. Die Blutgefäße des menschlichen Rückenmarkes. II. Die Gefäße der Rückenmarksoberfläche. *Ibid* 1882; **85**: 101-130
- Kadyi H. Über die Blutgefäße des Menschlichen Rückenmarkes. *Anat Anz* 1886; **1**: 304-314
- Kadyi H. Über die Blutgefäße des Menschlichen Rückenmarkes. Nach einer im XV. Bande der Denkschriften d.math.-naturw.CI.d.Akad.d.Wissensch, in Krakau erschienenen Monographie, aus dem Polischen übersetzt vom Verfasser. Lemberg: Gubrynowicz und Schmidt, 1889
- Bolton B. The blood supply of the human spinal cord. *J Neurol Psychiat* 1939; **2**: 137-148 [DOI: 10.1136/jnnp.2.2.137]
- Suh TH, Alexander L. Vascular system of the human spinal cord. *Arch Neurol. Psychiat* 1939; **41**: 659-677 [DOI: 10.1001/archneurpsyc.1939.02270160009001]
- Woolam DHM, Millen JW. The arterial supply of the spinal cord and its significance. *J Neurol Neurosurg Psychiat* 1955; **18**: 97-102 [DOI: 10.1136/jnnp.18.2.97]
- Hassler O. Blood supply of human spinal cord. A microangiographic study. *Arch Neurol* 1966; **15**: 302-307 [DOI: 10.1001/archneur.1966.00470150080013]
- Gillilan LA. Veins of the spinal cord. Anatomic details; suggested clinical applications. *Neurology* 1970; **20**: 860-868 [PMID: 4989859 DOI: 10.1212/WNL.20.9.860]
- Lazorthes G, Gouaze A, Zadeh JO, Santini JJ, Lazorthes Y, Burdin P. Arterial vascularization of the spinal cord. Recent studies of the anastomotic substitution pathways. *J Neurosurg* 1971; **35**: 253-262 [PMID: 22046635 DOI: 10.3171/jns.1971.35.3.0253]
- Dommissie GF. Arteries and vein of the human spinal cord from birth. New York: Churchill Livingstone: 1975
- Crock HV, Yoshizawa H. The blood supply of the vertebral column and spinal cord in man. New York: Springer-Verlag, 1977 [DOI: 10.1007/978-3-7091-3668-3]
- Corbin JL. Anatomie et pathologie arterielles de la moelle. Paris: Masson et Cie, 1961




- 26 Parke WW, Gammell K, Rothman RH. Arterial vascularization of the cauda equina. *J Bone Joint Surg* 1981; **63A**: 53-62
- 27 Crock HV, Yamagishi M, Crock MC. The conus medullaris and cauda equina in man. New York: Springer-verlag; 1986
- 28 Kobayashi S, Yoshizawa H, Nakai S. Experimental study on the dynamics of lumbosacral nerve root circulation. *Spine* (Phila Pa 1976) 2000; **25**: 298-305 [PMID: 10703100 DOI: 10.1097/00007632-200002010-00007]
- 29 Kobayashi S, Yoshizawa H, Hachiya Y, Ukai T, Morita T. Volvo award winner in basic science. Vasogenic edema induced by compression injury to the spinal nerve root: Distribution of intravenously injected protein tracers and gadolinium-enhanced magnetic resonance imaging. *Spine* 1993; **18**: 1410-1424 [DOI: 10.1097/00007632-199309010-00004]
- 30 Olmarker K, Rydevik B, Holm S. Edema formation in spinal nerve roots induced by experimental, graded compression. An experimental study on the pig cauda equina with special reference to differences in effects between rapid and slow onset of compression. *Spine* (Phila Pa 1976) 1989; **14**: 569-573 [PMID: 2546258 DOI: 10.1097/00007632-198906000-00003]
- 31 Blau JN, Logue V. The natural history of intermittent claudication of the cauda equina: an unusual syndrome resulting from central protrusion of a lumbar intervertebral disc. *Lancet* 1961; **20**: 1081-1086 [DOI: 10.1016/S0140-6736(61)92310-8]
- 32 Evans JG. Neurogenic intermittent claudication. *Br Med J* 1964; **2**: 985-987 [PMID: 14185688 DOI: 10.1136/bmj.2.5415.985]
- 33 Ehni G. Significance of the small lumbar canal: Cauda equina compression syndrome due to spondylosis. *J Neurosurg* 1969; **31**: 490-494 [DOI: 10.3171/jns.1969.31.5.0490]
- 34 Yamada H, Oya M, Okada T, Shiozawa Z. Intermittent cauda equina compression due to narrow spinal canal. *J Neurosurg* 1972; **37**: 83-88 [PMID: 5037049 DOI: 10.3171/jns.1972.37.1.0083]
- 35 Kavanaugh GJ, Svien HJ, Holman CB, Johnson RM. "Pseudoclaudication" syndrome produced by compression of the cauda equina. *JAMA* 1968; **206**: 2477-2481 [PMID: 5754987 DOI: 10.1001/jama.1968.03150110025004]
- 36 Verbiest H. Neurogenic intermittent claudication. Amsterdam: North Holland Publishing Co; New York: American Elsevier, 1976: 749-753
- 37 Kobayashi S, Yoshizawa H, Yamada S. Pathology of lumbar nerve root compression. Part 1: Intradicular inflammatory changes induced by mechanical compression. *J Orthop Res* 2004; **22**: 170-179 [PMID: 14656677 DOI: 10.1016/S0736-0266(03)00131-1]
- 38 Kobayashi S, Kokubo Y, Uchida K, Yayama T, Takeno K, Negoro K, Nakajima H, Baba H, Yoshizawa H. Effect of lumbar nerve root compression on primary sensory neurons and their central branches: changes in the nociceptive neuropeptides substance P and somatostatin. *Spine* (Phila Pa 1976) 2005; **30**: 276-282 [PMID: 15682006 DOI: 10.1097/01.brs.0000152377.72468.f4]
- 39 Kobayashi S, Sasaki S, Shimada S, Kaneyasu M, Mizukami Y, Kitade I, Ogawa M, Kawahara H, Baba H, Yoshizawa H. Changes of calcitonin gene-related peptide in primary sensory neurons and their central branch after nerve root compression of the dog. *Arch Phys Med Rehabil* 2005; **86**: 527-533 [PMID: 15759240 DOI: 10.1016/j.apmr.2004.03.037]
- 40 Kobayashi S, Uchida K, Yayama T, Takeno K, Miyazaki T, Shimada S, Kubota M, Nomura E, Meir A, Baba H. Motor neuron involvement in experimental lumbar nerve root compression: a light and electron microscopic study. *Spine* (Phila Pa 1976) 2007; **32**: 627-634 [PMID: 17413466 DOI: 10.1097/01.brs.0000257559.84494.15]
- 41 Cooper RG, Freemont AJ, Hoyland JA, Jenkins JP, West CG, Illingworth KJ, Jayson MI. Herniated intervertebral disc-associated periradicular fibrosis and vascular abnormalities occur without inflammatory cell infiltration. *Spine* (Phila Pa 1976) 1995; **20**: 591-598 [PMID: 7604329 DOI: 10.1097/00007632-199503010-00016]
- 42 Kobayashi S, Takeno K, Miyazaki T, Kubota M, Shimada S, Yayama T, Uchida K, Normura E, Mwaka E, Baba H. Effects of arterial ischemia and venous congestion on the lumbar nerve root in dogs. *J Orthop Res* 2008; **26**: 1533-1540 [PMID: 18536056 DOI: 10.1002/jor.20696]
- 43 Kobayashi S, Mwaka ES, Meir A, Uchida K, Kokubo Y, Takeno K, Miyazaki T, Nakajima H, Kubota M, Shimada S, Baba H. Changes in blood flow, oxygen tension, action potentials, and vascular permeability induced by arterial ischemia or venous congestion on the lumbar dorsal root ganglia in dogs. *J Neurotrauma* 2009; **26**: 1167-1175 [PMID: 19331518 DOI: 10.1089/neu.2008.0837]
- 44 Usubiaga JE, Moya F, Usubiaga LE. Effect of thoracic and abdominal pressure changes on the epidural space pressure. *Br J Anaesth* 1967; **39**: 612-618 [PMID: 6035128 DOI: 10.1093/bja/39.8.612]
- 45 Heddle RW, Guiler ER. Epidural space manometry and multiple ligation in the investigation of posterior vena cava occlusion in the rat. *J Anat* 1971; **110**: 491 [PMID: 5147309]
- 46 Kobayashi S, Uchida K, Takeno K, Baba H, Suzuki Y, Hayakawa K, Yoshizawa H. Imaging of cauda equina edema in lumbar canal stenosis by using gadolinium-enhanced MR imaging: experimental constriction injury. *AJNR Am J Neuroradiol* 2006; **27**: 346-353 [PMID: 16484408]
- 47 Jinkins JR. Gd-DTPA enhanced MR of the lumbar spinal canal in patients with claudication. *J Comput Assist Tomogr* 1993; **17**: 555-562 [PMID: 8331225 DOI: 10.1097/00004728-199307000-00007]
- 48 Jinkins JR. MR of enhancing nerve roots in the unoperated lumbosacral spine. *AJNR Am J Neuroradiol* 1993; **14**: 193-202 [PMID: 8427089]
- 49 Jinkins R. Magnetic resonance imaging of benign nerve root enhancement in the unoperated and postoperative lumbosacral spine. *Neuroimag Clin N Am* 1993; **3**: 525-541
- 50 Yoshizawa H, Kobayashi S, Morita T. Chronic nerve root compression. Pathophysiologic mechanism of nerve root dysfunction. *Spine* (Phila Pa 1976) 1995; **20**: 397-407 [PMID: 7747222 DOI: 10.1097/00007632-199502001-00001]
- 51 Takahashi K, Kagechika K, Takino T, Matsui T, Miyazaki T, Shima I. Changes in epidural pressure during walking in patients with lumbar spinal stenosis. *Spine* (Phila Pa 1976) 1995; **20**: 2746-2749 [PMID: 8747254 DOI: 10.1097/00007632-199512150-00017]
- 52 Ikawa M, Atsuta Y, Tsunekawa H. Ectopic firing due to artificial venous stasis in rat lumbar spinal canal stenosis model: a possible pathogenesis of neurogenic intermittent claudication. *Spine* (Phila Pa 1976) 2005; **30**: 2393-2397 [PMID: 16261115 DOI: 10.1097/01.brs.0000184718.56122.90]
- 53 Rydevik BL, Myers RR, Powell HC. Pressure increase in the dorsal root ganglion following mechanical compression. Closed compartment syndrome in nerve roots. *Spine* (Phila Pa 1976) 1989; **14**: 574-576 [PMID: 2749371 DOI: 10.1097/00007632-198906000-00004]
- 54 Myers RR. The neuropathology of nerve injury and pain. In: Weinstein J, editor. Low back pain. A scientific and clinical overview. Rosemont, IL: American Academy of Orthopaedic Surgeons, 1997: 247-264
- 55 Kobayashi S, Shizu N, Suzuki Y, Asai T, Yoshizawa H. Changes in nerve root motion and intradicular blood flow during an intraoperative straight-leg-raising test. *Spine* (Phila Pa 1976) 2003; **28**: 1427-1434 [PMID: 12838102 DOI: 10.1097/01.BRS.0000067087.94398.35]
- 56 Kobayashi S, Suzuki Y, Asai T, Yoshizawa H. Changes in nerve root motion and intradicular blood flow during intraoperative femoral nerve stretch test. Report of four cases. *J Neurosurg* 2003; **99**: 298-305 [PMID: 14563148]
- 57 Howe JF, Loeser JD, Calvin WH. Mechanosensitivity of dorsal root ganglia and chronically injured axons: a physiological basis for the radicular pain of nerve root compression. *Pain* 1977; **3**: 25-41 [PMID: 195255 DOI: 10.1016/0304-3959(77)90033-1]



- 58 **Calvin WH.** Some design features of axons and how neuralgias may defeat them; advances in pain research and therapy. *Pain* 1979; **3**: 297-309
- 59 **Clifford PC, Martin MF, Shedd EJ, Kirby JD, Baird RN, Dieppe PA.** Treatment of vasospastic disease with prostaglandin E<sub>1</sub>. *Br Med J* 1980; **281**: 1031-1034 [PMID: 7427564 DOI: 10.1136/bmj.281.6247.1031]
- 60 **Itoh Y, Yasui T, Kakizawa H, Makino M, Fujiwara K, Kato T, Imamura S, Yamamoto K, Hishida H, Nakai A, Itoh M, Nagasaka A.** The therapeutic effect of lipo PGE<sub>1</sub> on diabetic neuropathy-changes in endothelin and various angiopathic factors. *Prostaglandins Other Lipid Mediat* 2001; **66**: 221-234 [PMID: 11577785 DOI: 10.1016/S0090-6980(01)00165-4]
- 61 **Strong CG, Bohr DF.** Effects of prostaglandins E<sub>1</sub>, E<sub>2</sub>, A<sub>1</sub>, and F<sub>1</sub>-alpha on isolated vascular smooth muscle. *Am J Physiol* 1967; **213**: 725-733 [PMID: 6036791]
- 62 **Greenberg RA, Sparks HV.** Prostaglandins and consecutive vascular segments of the canine hindlimb. *Am J Physiol* 1969; **216**: 567-571 [PMID: 5765607]
- 63 **Makita S, Nakamura M, Ohhira A, Itoh S, Hiramori K.** Effects of prostaglandin E<sub>1</sub> infusion on limb hemodynamics and vasodilatory response in patients with arteriosclerosis obliterans. *Cardiovasc Drugs Ther* 1997; **11**: 441-448 [PMID: 9310272 DOI: 10.1023/A: 1007793321780]
- 64 **Stewart MA, Sherman WR, Kurien MM, Moonsammy GI, Wisgerhof M.** Polylol accumulations in nervous tissue of rats with experimental diabetes and galactosaemia. *J Neurochem* 1967; **14**: 1057-1066 [PMID: 6058523 DOI: 10.1111/j.1471-4159.1967.tb09516.x]
- 65 **Gabbay KH, O'Sullivan JB.** The sorbitol pathway. Enzyme localization and content in normal and diabetic nerve and cord. *Diabetes* 1968; **17**: 239-243 [PMID: 4384869]
- 66 **Takakura Y.** Clinical effect of prostaglandin on spinal canal stenosis. *Gendai iryo* 1986; **18**: 673-679
- 67 **Miura Y, Yamaura I.** The clinical response of Lipo-PGE<sub>1</sub> to compressive cervical myelopathy and compressive lesion of cauda equina and nerve root. *Igaku yakugaku* 1992; **28**: 925-935
- 68 **Toribatake Y, Takahashi K, Kawahara N, Tomita K.** Effect of Lipo PGE<sub>1</sub> on neurogenic intermittent claudication. *Sinyaku Rinsho* 1993; **42**: 158-166
- 69 **Kurihara A, Kataoka O, Sugawara S, Sano S, Shirai Y.** Clinical benefit of OP-1206-CD on lumbar spinal canal stenosis. Multi-center comparative double-blind clinical study. *Rinsho Iyaku* 1996; **12**: 511-529
- 70 **Murakami M, Takahashi K, Sekikawa T, Yasuhara K, Yamagata M, Moriya H.** Effects of intravenous lipoprostaglandin E<sub>1</sub> on neurogenic intermittent claudication. *J Spinal Disord* 1997; **10**: 499-504 [PMID: 9438815 DOI: 10.1097/00002517-199712000-00007]
- 71 **Ono K, Miura Y, Tsuji H, Kataoka O.** Clinical assessment of PGE<sub>1</sub> formulation for lumbar spinal canal stenosis. *Sekitui Sekizui* 1997; **10**: 517-524
- 72 **Miura J, Kurihara A, Sya T, Uratsuj M, Sakamoto T.** Drip infusion therapy with prostaglandin E<sub>1</sub> for lumbar canal stenosis. *J Lumbar Spine Disord* 1997; **3**: 55-59
- 73 **Uratsuj M, Kurihara A, Ooi T.** Conservative treatment of lumbar spinal stenosis with prostaglandin E<sub>1</sub> derivative results of a double-blind, multi-center trial. International Society for the Study of the Lumbar Spine (ISSLS), 23rd Annual Meeting. Burlington, 1996: Abstract 84
- 74 **Harrison TS, Plosker GL.** Limaprost. *Drugs* 2007; **67**: 109-118 [DOI: 10.2165/00003495-200767010-00010]
- 75 **Nakanishi K, Tanaka M, Misawa H, Takigawa T, Ozaki T.** Midterm results of prostaglandin E<sub>1</sub> treatment in patients with lumbar spinal canal stenosis accompanied by intermittent claudication. *Spine (Phila Pa 1976)* 2008; **33**: 1465-1469 [PMID: 18520942 DOI: 10.1097/BRS.0b013e3181753c1e]
- 76 **Konno S, Kayama S, Olmarker K, Kikuchi S.** Effects of OP-1206 (prostaglandin E<sub>1</sub>) on nerve-conduction velocity in the dog cauda equina subjected to acute experimental compression. *J Spinal Disord* 1996; **9**: 103-106 [PMID: 8793775 DOI: 10.1097/00002517-199604000-00003]
- 77 **Nakai K, Takenobu Y, Eguchi K, Takimizu H, Honjo K, Akimaru S, Maegawa H, Marsala M, Katsube N.** The effects of OP-1206 alpha-CD on walking dysfunction in the rat neuropathic intermittent claudication model. *Anesth Analg* 2002; **94**: 1537-141, table of contents [PMID: 12032022]
- 78 **Nakai K, Takenobu Y, Takimizu H, Akimaru S, Ito H, Maegawa H, Marsala M, Katsube N.** Effects of orally administered OP-1206 alpha-CD with loxoprofen-Na on walking dysfunction in the rat neuropathic intermittent claudication model. *Prostaglandins Leukot Essent Fatty Acids* 2003; **69**: 269-273 [PMID: 12907137 DOI: 10.1016/S0952-3278(03)00109-1]
- 79 **Sekiguchi M, Konno S, Kikuchi S.** Effects on improvement of blood flow in the chronically compressed cauda equina: comparison between a selective prostaglandin E receptor (EP<sub>4</sub>) agonist and a prostaglandin E<sub>1</sub> derivative. *Spine (Phila Pa 1976)* 2006; **31**: 869-872 [PMID: 16622373 DOI: 10.1097/01.brs.0000209256.96186.a7]
- 80 **Shirasaka M, Takayama B, Sekiguchi M, Konno S, Kikuchi S.** Vasodilative effects of prostaglandin E<sub>1</sub> derivate on arteries of nerve roots in a canine model of a chronically compressed cauda equina. *BMC Musculoskelet Disord* 2008; **9**: 41 [PMID: 18394203 DOI: 10.1186/1471-2474-9-41]
- 81 **Kobayashi S, Baba H, Takeno K, Shimada S, Kubota M, Yayama T, Miyazaki T, Uchida K, Suzuki Y.** Blood flow analysis of compressed nerve root after intravenous injection of lipo-prostaglandin E<sub>1</sub>. *J Orthop Res* 2009; **27**: 1252-1257 [PMID: 19322792 DOI: 10.1002/jor.20881]
- 82 **Yone K, Sakou T, Kawauchi Y.** The effect of Lipo prostaglandin E<sub>1</sub> on cauda equina blood flow in patients with lumbar spinal canal stenosis: myeloscopic observation. *Spinal Cord* 1999; **37**: 269-274 [PMID: 10338347 DOI: 10.1038/sj.sc.3100780]
- 83 **Dezawa A, Kitahara H.** The orthopaedic study with the ultrathin fiberoptic spinal endoscope. *Byoutaiseiri* 1992; **11**: 703-708
- 84 **Suzuki K, Ishida Y, Ohmori K, Sakai H, Hashizume Y.** Redundant nerve roots of the cauda equina: clinical aspects and consideration of pathogenesis. *Neurosurgery* 1989; **24**: 521-528 [PMID: 2540446 DOI: 10.1227/00006123-198904000-00006]

**P- Reviewers:** Alimehmeti R, Bludovsky D, Serhan H, Vugt A  
**S- Editor:** Song XX **L- Editor:** O'Neill M **E- Editor:** Lu YJ





## Painful sesamoid of the great toe

Alex L Sims, Harish V Kurup

Alex L Sims, Department of Orthopaedics, University Hospital of North Tees, Cleveland TS19 8PE, United Kingdom  
Harish V Kurup, Department of Orthopaedics, Pilgrim Hospital Sibsey Rd, Lincolnshire PE21 9QS, United Kingdom

Author contributions: Sims AL wrote the paper; Kurup HV wrote and edited the paper.

Correspondence to: Alex L Sims, MBBS, MSc, MRCS, Department of Orthopaedics, University Hospital of North Tees, Hardwick Rd, Stockton-on-Tees, Cleveland TS19 8PE, United Kingdom. [asims@nhs.net](mailto:asims@nhs.net)

Telephone: +44-1642-617617 Fax: +44-1642-624814

Received: September 25, 2013 Revised: December 29, 2013

Accepted: January 15, 2014

Published online: April 18, 2014

### Abstract

The painful sesamoid can be a chronic and disabling problem and isolating the cause can be far from straightforward. There are a number of forefoot pathologies that can present similarly to sesmoid pathologies and likewise identifying the particular cause of sesamoid pain can be challenging. Modern imaging techniques can be helpful. This article reviews the anatomy, development and morphological variability present in the sesamoids of the great toe. We review evidence on approach to history, diagnosis and investigation of sesamoid pain. Differential diagnoses and management strategies, including conservative and operative are outlined. Our recommendations are that early consideration of magnetic resonance imaging and discussion with a specialist musculoskeletal radiologist may help to identify a cause of pain accurately and quickly. Conservative measures should be first line in most cases. Where fracture and avascular necrosis can be ruled out, injection under fluoroscopic guidance may help to avoid operative intervention.

© 2014 Baishideng Publishing Group Co., Limited. All rights reserved.

**Key words:** Sesamoid; Pain; Great toe; Management; Forefoot

**Core tip:** This paper is a review article examining available evidence on the anatomy, function and common variation in the sesmoids of the great toe. There is discussion of the presentation, history, examination, investigations and subsequent management of the patient with a painful sesamoid. We discuss the role of operative intervention. We recommend early use of magnetic resonance imaging and discussion with a musculoskeletal radiologist to assist in diagnosis. Conservative management should be the first line in most cases.

Sims AL, Kurup HV. Painful sesamoid of the great toe. *World J Orthop* 2014; 5(2): 146-150 Available from: URL: <http://www.wjgnet.com/2218-5836/full/v5/i2/146.htm> DOI: <http://dx.doi.org/10.5312/wjo.v5.i2.146>

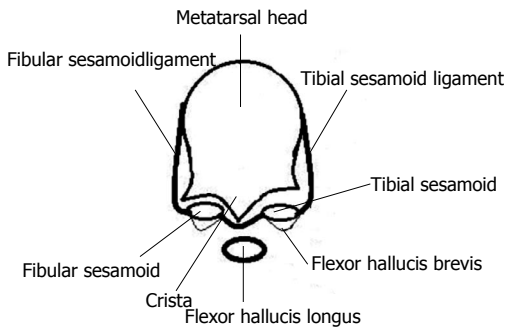
### INTRODUCTION

#### Origins

The term sesamoid comes from the Arabic word, *sem-sem*, meaning sesame seed. Galen named these small rounded bones in reference to their similarity to sesame seeds<sup>[1]</sup>. The anatomic locations of some sesamoid bones are constant but others are variable.

#### Anatomy

The two sesamoid bones of the big toe metatarsophalangeal joint are contained within the tendons of Flexor Hallucis Brevis and forms portion of the plantar plate. There are two sesamoids, tibial (medial) and fibular (lateral) sesamoids. The sesamoids articulate on their dorsal surface with the plantar facets of metatarsal head<sup>[2]</sup>. A crista or intersesamoid ridge separates the medial and lateral metatarsal facets. The crista provides intrinsic stability to the complex. In severe cases of hallux valgus the intersesamoid ridge atrophies and can be obliterated. The sesamoids are connected to the plantar aspect of proximal phalanx through plantar plate<sup>[3]</sup> which is continuation of the flexor hallucis brevis tendon<sup>[4]</sup>. The inferior sur-



**Figure 1** Diagrammatic representation of a cross section through the distal metatarsal and sesamoids.

face of the sesamoid is covered by a thin layer of flexor hallucis brevis tendon and superior surface is articular. The sesamoids are suspended by a sling like mechanism; sesamoid ligaments to the corresponding aspect of metatarsal head (Figure 1). There is no direct connection between sesamoids and flexor hallucis longus tendon that runs between them. The abductor hallucis and adductor hallucis tendons have fibrous insertions into the tibial and fibular sesamoids respectively. The deep transverse metatarsal ligament attaches to the fibular sesamoid<sup>[5]</sup>.

### Function

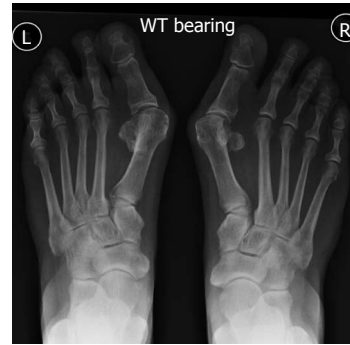The function of sesamoids is to distribute weight bearing of first ray, increase mechanical advantage of the pull of short flexor tendon and stabilize the first ray. The tibial sesamoid normally assumes most of the weight bearing forces transmitted to the head of the first metatarsal<sup>[6]</sup>. When a person is in standing position sesamoids are proximal to the metatarsal heads. With dorsiflexion of first ray they however move distally thereby protecting the exposed plantar aspect of metatarsal head. When a person rises on to the toes, sesamoids (especially tibial) act as the main weight bearing focus for medial forefoot. Tibial sesamoid is more prone for pathology due to increased loading on this by the first metatarsal head<sup>[7]</sup>.

### Perfusion

Sesamoids have a tenuous blood supply and this is often variable as well. Blood supply to sesamoids enters mostly from proximal part and distal part has more tenuous blood supply. This can lead to delayed or unsuccessful healing following injury<sup>[8]</sup>.

### The bipartite sesamoid

Sesamoids ossify between the ages of 6 and 7. Ossification of sesamoids often occurs from multiple centres and this is the reason for bipartite sesamoids. Bipartite sesamoids are a normal anatomical variant. Studies quote the incidence of bipartite sesamoids to be between 7 and 30<sup>[9-11]</sup>. Ninety percent involve tibial sesamoid and 80%-90% are bilateral<sup>[10]</sup>. Bipartite sesamoid has narrow and distinct regular edges and also are usually larger than single sesamoid. Some of these divided sesamoids do undergo osseous union with time. The synchondrosis



**Figure 2** X-ray to demonstrate a case of sesamoid coalition.

between the sesamoid fragments can also disrupt with injury leading to symptoms and makes it difficult to distinguish whether some of these partite sesamoids are actually ununited fractures<sup>[12]</sup>. A Bone scan or magnetic resonance imaging (MRI) scan may help in differentiating between the two<sup>[13]</sup>. Bipartite sesamoids can predispose to hallux valgus deformity as twice higher incidence is noted in patients with Hallux Valgus<sup>[14]</sup>.

### Abnormalities of the sesamoids

Other variations with sesamoids include congenital absence (reported widely in literature)<sup>[15-17]</sup> and also changes in shape. Hypertrophy can cause a projection on the plantar surface leading to hyperkeratotic lesion. Exostoses of sesamoids have been reported and these can cause keratosis or ulcerations. Hypertrophied fibular sesamoid can cause pain in the first intermetatarsal space due to local irritation or nerve compression. Coalition of sesamoids can also occur and give rise to symptoms (Figure 2)<sup>[18]</sup>.

## HISTORY AND EXAMINATION

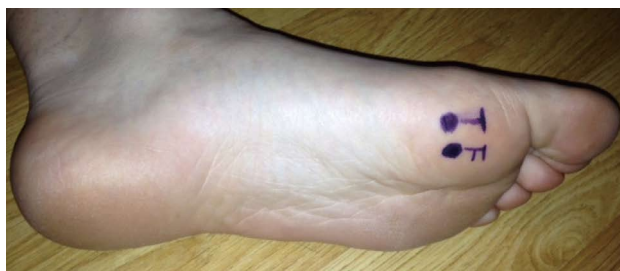Pain is typically during toe off phase of gait. Careful history taking should include examination of footwear used in past and present, leisure activities to identify causation, occupation and treatment taken so far. Occupational factors include running, ballet dancing and jumping from a height<sup>[19-21]</sup>. The wearing of high heels and a high arched foot type also has an aetiological association. Previous injections to the area and smoking status should be asked for. Patients tend to avoid weight bearing on the involved sesamoid and load the lateral aspect of foot.

Findings include restricted and painful range of metatarsophalangeal joint motion, tenderness (Figure 3), and diminished plantar flexion strength. With long standing overloading, an intractable plantar keratotic lesion may develop beneath the affected sesamoid. Any tendency for hallux valgus, varus or clawing should be looked for. Examination of sensory nerves is important to rule out digital nerve compression<sup>[11]</sup>.

## INVESTIGATIONS

### Radiographs

Routine AP and lateral radiographs provide limited infor-



**Figure 3** Photograph to show surface markings of the tibial (T) and fibular (F) sesamoids.

mation. The tibial sesamoid can be better imaged with a medial oblique view and the fibular sesamoid can be visualised better with a lateral oblique view. An axial sesamoid view will provide a better profile of both sesamoids with their metatarsal articulations (Figure 4)<sup>[22]</sup>.

### Isotope bone scan

Isotope bone scanning can demonstrate altered uptake before radiographs show changes. It shows increased uptake prior to development of radiological changes such as sclerosis, fragmentation. Bone scanning may be of use in differentiation of the fractured sesamoid from the congenital bipartite sesamoid<sup>[23]</sup>.

### MRI

Pathologies affecting the hallux sesamoids may have overlap of both history and examination. For this reason, imaging is a useful tool that can differentiate causes of sesamoid pain where a diagnosis may not otherwise be easily made<sup>[20]</sup>. It can also distinguish between bipartite sesamoids and fracture non-unions. This is currently the investigation of choice for most sesamoid pathology<sup>[20,24]</sup>.

## DIFFERENTIAL DIAGNOSIS

### Intractable plantar keratosis

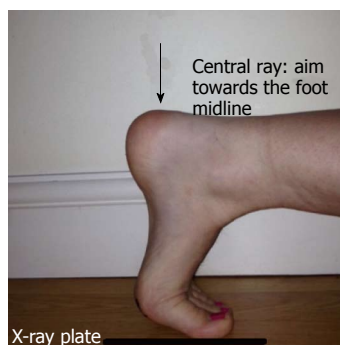
Intractable plantar keratosis may form under the heads of the metatarsals. This can often be as a result of repeated abrasion or increased activity. It is important to differentiate IPK from verruca. Radiographs may help to identify causative osseous abnormality. This may include deformity of an underlying sesamoid. Management may involve activity modification, padding of pressure areas, use of orthosis or shaving of the keratosis. For persistent cases, condylectomy or osteotomy may be required<sup>[25]</sup>.

### Bursitis

Bursitis may affect the intermetatarsal bursae or the adventitious bursae. magnetic resonance imaging may help to diagnose the location of the affected bursa. Should conservative measures fail, bursectomy alone or in combination with sesamoidectomy or metatarsal osteotomy may provide relief<sup>[26]</sup>.

### Nerve compression

Plantar medial and plantar lateral digital nerves travel near



**Figure 4** Photograph to show patient positioning to obtain a sesamoid axial view.

to the corresponding sesamoids and can be a source of pain. Nerve compression at these sites can cause altered sensation, pain and a positive Tinel's sign. Surgical decompression may be indicated in the resistant case<sup>[5]</sup>.

### Osteoarthritis

This may be associated with Hallux rigidus or localized to the sesamoid metatarsal articulation. This can develop secondary to trauma, chondromalacia or sesamoiditis. If conservative treatment fails where disease is restricted to one sesamoid resection of the involved sesamoid may help. When both sesamoids are involved excision can lead to clawing, hence MTP fusion is more appropriate<sup>[18]</sup>.

### Infection

Infection of sesamoids is uncommon. Direct trauma with puncture wound or breakdown of skin in those with peripheral neuropathy are the common mechanisms. Should antibiotic therapy prove ineffective, excision of the sesamoid can be considered. Care should be taken when excising the sesamoids to preserve the surrounding structures to prevent development of intrinsic minus deformity<sup>[11]</sup>.

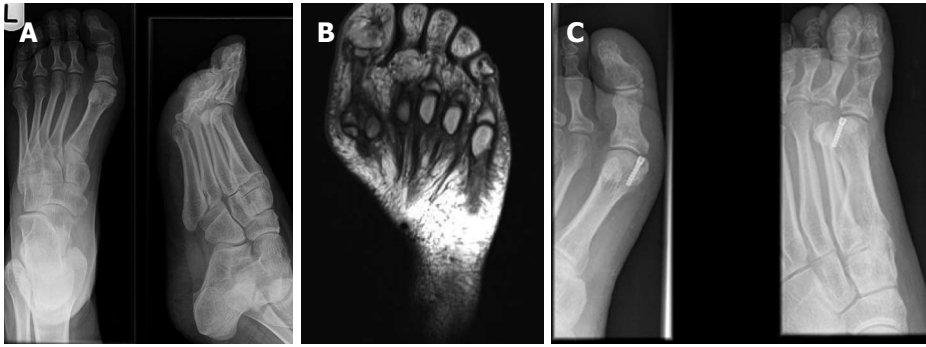
### Fracture of sesamoid

An acute fracture of unipartite sesamoid can be differentiated from a congenital bipartite sesamoid using bone scan or MRI. Bipartite sesamoids can also fracture following trauma when the synchondrosis between the two sesamoid fragments prevents healing. Rest in a non-weight bearing cast for 6 to 8 wk is the first line of treatment. Symptomatic non-union may be treated with percutaneous screw fixation, open fixation or open bone grafting (Figure 5)<sup>[27]</sup>. Surgical excision may be reserved for revision surgery.

### Subluxation/dislocation of sesamoids

As hallux valgus develops, first metatarsal drifts medially. The sesamoids maintain their relationship to the second metatarsal due to tethering by transverse metatarsal ligament and adductor hallucis tendon. There is often erosion of the crista and increased weight bearing by the tibial sesamoid. Fibular sesamoid is spared as it is dis-





**Figure 5** Symptomatic non-union may be treated with percutaneous screw fixation, open fixation or open bone grafting. A: X-ray to show a symptomatic non-union of a sesamoid fracture; B: Magnetic resonance imaging scan demonstrating fracture of the sesamoid; C: Post-operative X-ray following fixation of a non-union sesamoid fracture.

placed into the first intermetatarsal space<sup>[28]</sup>.

### **Osteochondritis/avascular necrosis**

Sesamoids have a tenuous circulation making them vulnerable to avascular necrosis. In cases of avascular necrosis trauma may be an aetiological factor. Radiographs may show fragmentation with areas of increased bone density. MRI is also helpful in diagnosis. Excision of the sesamoid is reserved for cases where conservative management is ineffective<sup>[11]</sup>.

### **Sesamoiditis**

Sesamoiditis is a diagnosis of exclusion once other causes of sesamoid pain have been excluded. Sesamoiditis is a painful condition affecting the sesamoids and can occur with or without trauma. This may be due to cartilage abnormalities similar to chondromalacia of patellofemoral joint<sup>[29]</sup> or inflammation of peritendinous structures. This condition is typically seen in younger women. The tibial sesamoid is more often involved. Radiographs are usually normal and bone scan and MRI may help in diagnosis. Conservative treatment involves decrease in activity. Low heels reduce pressure on sesamoids. Offloading custom made insoles are often helpful. Injections can be helpful and when everything fails excision is treatment of choice.

## **MANAGEMENT**

### **Conservative management**

Initial attempts at management include a period of non- or reduced weight bearing, providing wide shoes with a reduced heel height, orthotics or padding<sup>[30]</sup>. The toes may be taped in plantar flexion or neutral to avoid excessive dorsi-flexion. Clinical evidence confirming resolution of symptoms with simple, conservative measures is often possible<sup>[31]</sup>. Non-steroidal anti-inflammatory drugs may also help to provide relief.

### **Injection**

Steroid and local anaesthetic injections can be both diagnostic and therapeutic. Injections are usually done under radiological guidance to improve accuracy of needle placement. Steroid injections should not be used in presence of a sesamoid fracture or avascular necrosis<sup>[3]</sup>.

## **SURGERY**

### **Sesamoid shaving**

In the presence of an intractable plantar keratosis due to prominence of a tibial sesamoid, shaving of the plantar half of the sesamoid may provide relief without excision of the complete sesamoid. This should only be attempted in the presence of normal mobility at the first metatarsal<sup>[32]</sup>.

### **Sesamoidectomy**

Surgical excision of a sesamoid should be considered only when other treatment modalities have failed. Only one sesamoid may be excised, excision of both is likely to lead to a cock-up deformity or a claw toes deformity<sup>[30]</sup>. The sesamoid to be excised will dictate the surgical approach. For tibial sesamoidectomy a medial approach is preferred to avoid injury to plantar medial nerves. In one study, ninety-percent of patients were able to return to normal pre-morbid levels of activity following tibial sesamoidectomy<sup>[33]</sup>. A dorsolateral approach is preferred for fibular sesamoidectomy as a plantar approach is likely to encounter the neurovascular bundle and flexor hallucis longus tendon, making access difficult<sup>[11]</sup>. Painful plantar scar is a difficult problem to resolve and should be avoided.

### **Percutaneous screw fixation**

In cases of fracture of the sesamoid unresponsive to conservative management, percutaneous fixation of the sesamoid may provide improvement of symptoms. In one study of nine patients managed this way, all patients had dramatic relief from pain at three months post-operatively<sup>[27]</sup>.

## **CONCLUSION**

A range of conditions can lead to sesamoid pain. Careful history examining occupation and hobbies alongside a thorough examination and use of appropriate imaging modalities are likely to identify aetiology. Our recommendations are that early consideration of MRI and discussion with a specialist musculoskeletal radiologist may help to identify a cause of pain accurately and quickly. Conservative measures should in most cases be first line. Where fracture and avascular necrosis can be ruled out, injection under fluoroscopic guidance may help to avoid operative

intervention. Operative intervention used only in resistant cases operative morbidity should be considered and explained to patients.

## REFERENCES

- 1 **van Dam Scott BE**, Dye F, Wilbur Westin G. Etymology and the Orthopaedic Surgeon: Onomasticon (Vocabulary). *Iowa Orthop J* 1991; **11**: 84-90
- 2 **Aseyo D**, Nathan H. Hallux sesamoid bones. Anatomical observations with special reference to osteoarthritis and hallux valgus. *Int Orthop* 1984; **8**: 67-73 [PMID: 6480190 DOI: 10.1007/BF00267743]
- 3 **Deland JT**, Lee KT, Sobel M, DiCarlo EF. Anatomy of the plantar plate and its attachments in the lesser metatarsal phalangeal joint. *Foot Ankle Int* 1995; **16**: 480-486 [PMID: 8520660 DOI: 10.1177/107110079501600804]
- 4 **Brenner E**. The intersesamoidal ridge of the first metatarsal bone: anatomical basics and clinical considerations. *Surg Radiol Anat* 2003; **25**: 127-131 [PMID: 12734678 DOI: 10.1007/s00276-003-0107-0]
- 5 **Anwar R**, Anjum SN, Nicholl JE. Sesamoids of the Foot. *Curr Orthopaed* 2005; **19**: 40-48 [DOI: 10.1016/j.cuor.2005.01.001]
- 6 **Dedmond BT**, Cory JW, McBryde A. The hallucal sesamoid complex. *J Am Acad Orthop Surg* 2006; **14**: 745-753 [PMID: 17148622]
- 7 **Shereff MJ**, Bejjani FJ, Kummer FJ. Kinematics of the first metatarsophalangeal joint. *J Bone Joint Surg Am* 1986; **68**: 392-398 [PMID: 3949833]
- 8 **Rath B**, Notermans HP, Frank D, Walpert J, Deschner J, Luering CM, Koeck FX, Koeck J. Arterial anatomy of the hallucal sesamoids. *Clin Anat* 2009; **22**: 755-760 [PMID: 19644971 DOI: 10.1002/ca.20843]
- 9 **Frankel JP**, Harrington J. Symptomatic bipartite sesamoids. *J Foot Surg* 1990; **29**: 318-323 [PMID: 2229903]
- 10 **Munuera PV**, Domínguez G, Reina M, Trujillo P. Bipartite hallucal sesamoid bones: relationship with hallux valgus and metatarsal index. *Skeletal Radiol* 2007; **36**: 1043-1050 [PMID: 17768619 DOI: 10.1007/s00256-007-0359-6]
- 11 **Richardson EG**. Hallucal sesamoid pain: causes and surgical treatment. *J Am Acad Orthop Surg* 1999; **7**: 270-278 [PMID: 10434081]
- 12 **Van Hal ME**, Keene JS, Lange TA, Clancy WG. Stress fractures of the great toe sesamoids. *Am J Sports Med* 1982; **10**: 122-128 [PMID: 7081526 DOI: 10.1177/036354658201000212]
- 13 **Cohen BE**. Hallux sesamoid disorders. *Foot Ankle Clin* 2009; **14**: 91-104 [PMID: 19232995 DOI: 10.1016/j.fcl.2008.11.003]
- 14 **Weil LS**, Hill M. Bipartite tibial sesamoid and hallux abducto valgus deformity: a previously unreported correlation. *J Foot Surg* 1992; **31**: 104-111 [PMID: 1644993]
- 15 **Day F**, Jones PC, Gilbert CL. Congenital absence of the tibial sesamoid. *J Am Podiatr Med Assoc* 2002; **92**: 153-154 [PMID: 11904328]
- 16 **Jeng CL**, Maurer A, Mizel MS. Congenital absence of the hallux fibular sesamoid: a case report and review of the literature. *Foot Ankle Int* 1998; **19**: 329-331 [PMID: 9622426 DOI: 10.1177/107110079801900512]
- 17 **Le Minor JM**. Congenital absence of the lateral metatarsophalangeal sesamoid bone of the human hallux: a case report. *Surg Radiol Anat* 1999; **21**: 225-227 [PMID: 10431339 DOI: 10.1007/s00276-999-0225-4]
- 18 **Coughlin MJ**, Mann RA, Saltzman CL, Anderson RB. Surgery of the Foot and Ankle. St. Louis: Mosby, 2007
- 19 **Hillier JC**, Peace K, Hulme A, Healy JC. Pictorial review: MRI features of foot and ankle injuries in ballet dancers. *Br J Radiol* 2004; **77**: 532-537 [PMID: 15151980 DOI: 10.1259/bjr/60447506]
- 20 **Karasick D**, Schweitzer ME. Disorders of the hallux sesamoid complex: MR features. *Skeletal Radiol* 1998; **27**: 411-418 [PMID: 9765133 DOI: 10.1007/s002560050410]
- 21 **McBryde AM**, Anderson RB. Sesamoid foot problems in the athlete. *Clin Sports Med* 1988; **7**: 51-60 [PMID: 3044622]
- 22 **Richardson EG**. Injuries to the hallucal sesamoids in the athlete. *Foot Ankle* 1987; **7**: 229-244 [PMID: 3817668 DOI: 10.1177/107110078700700405]
- 23 **Maurice HD**, Newman JH, Watt I. Bone scanning of the foot for unexplained pain. *J Bone Joint Surg Br* 1987; **69**: 448-452 [PMID: 3108262]
- 24 **Sanders TG**, Rathur SK. Imaging of painful conditions of the hallucal sesamoid complex and plantar capsular structures of the first metatarsophalangeal joint. *Radiol Clin North Am* 2008; **46**: 1079-1092, vii [PMID: 19038614 DOI: 10.1016/j.rcl.2008.09.001]
- 25 **Coughlin MJ**. Common causes of pain in the forefoot in adults. *J Bone Joint Surg Br* 2000; **82**: 781-790 [PMID: 10990297 DOI: 10.1302/0301-620X.82B6.11422]
- 26 **Ashman CJ**, Klecker RJ, Yu JS. Forefoot pain involving the metatarsal region: differential diagnosis with MR imaging. *Radiographics* 2001; **21**: 1425-1440 [PMID: 11706214]
- 27 **Blundell CM**, Nicholson P, Blackney MW. Percutaneous screw fixation for fractures of the sesamoid bones of the hallux. *J Bone Joint Surg Br* 2002; **84**: 1138-1141 [PMID: 12463658 DOI: 10.1302/0301-620X.84B8.13064]
- 28 **Bulstrode C**, Wilson-Macdonald J, Fairbank J, Eastwood D. Oxford Textbook of Trauma and Orthopaedics. Oxford: Oxford University Press, 2011
- 29 **Apley AG**. Open sesamoid. A re-appraisal of the medial sesamoid of the hallux. *Proc R Soc Med* 1966; **59**: 120-121 [PMID: 5906752]
- 30 **Leventen EO**. Sesamoid disorders and treatment. An update. *Clin Orthop Relat Res* 1991; (269): 236-240 [PMID: 1864044]
- 31 **Heim M**, Siev-Ner Y, Nadvorna H, Marcovich C, Engelberg S, Azaria M. Metatarsal-Phalangeal Sesamoid Bones. *Curr Orthopaed* 1997; **11**: 267-270 [DOI: 10.1016/S0268-0890(97)90005-0]
- 32 **Mann RA**, Wapner KL. Tibial sesamoid shaving for treatment of intractable plantar keratosis. *Foot Ankle* 1992; **13**: 196-198 [PMID: 1634151 DOI: 10.1177/107110079201300405]
- 33 **Lee S**, James WC, Cohen BE, Davis WH, Anderson RB. Evaluation of hallux alignment and functional outcome after isolated tibial sesamoidectomy. *Foot Ankle Int* 2005; **26**: 803-809 [PMID: 16221451 DOI: 10.1177/107110070502601003]

**P- Reviewers:** Chen YK, Peng BG **S- Editor:** Gou SX

**L- Editor:** A **E- Editor:** Lu YJ



## Clinical results of linezolid in arthroplasty and trauma related infections

James Joel, Simon Matthew Graham, Adam Peckham-Cooper, Nectarios Korres, Helen Tsouchnica, Eleftherios Tsiridis

James Joel, Adam Peckham-Cooper, Academic Orthopaedic and Trauma Unit, Leeds Teaching Hospitals, Leeds School of Medicine, Leeds LS1 3EX, United Kingdom

Simon Matthew Graham, Royal Liverpool University Hospital, Liverpool L7 8XP, United Kingdom

Nectarios Korres, Helen Tsouchnica, Eleftherios Tsiridis, Academic Orthopaedics and Trauma Unit, Division of Surgery, Aristotle University Medical School, University Campus, 54 124 Thessaloniki, Greece

Author contributions: Joel J, Graham SM and Peckham-Cooper A contributed equally to this work in designing, writing and editing the paper; Korres N and Tsouchnica H assisted with the data collection; Tsiridis E designed the study and oversaw all areas of data collection and writing up of the paper.

Correspondence to: Eleftherios Tsiridis, MD, MSc, DMed, PhD, FRCS, Associate Professor of Orthopaedics and Trauma, Academic Orthopaedic and Trauma Unit, Division of Surgery, Aristotle University Medical School, University Campus, Kiriakidi 1, 54 124 Thessaloniki, Greece. [etsiridis@doctors.org.uk](mailto:etsiridis@doctors.org.uk)

Telephone: +30-210-3620666 Fax: +30-210-3620666

Received: October 17, 2013 Revised: February 10, 2014

Accepted: March 3, 2014

Published online: April 18, 2014

### Abstract

**AIM:** To analyse the management of patients treated with linezolid for orthopaedic infections.

**METHODS:** Twenty-two patients with orthopaedic related infections receiving a course of linezolid were reviewed retrospectively. Patients were classified into either post trauma, post arthroplasty and non trauma related infections. A diagnosis of infection was based on clinical findings, positive microbiological specimens, and positive signs of infection on radiological imaging and raised inflammatory markers. Pathogens isolated, inflammatory markers both at presentation and at final follow up, length of linezolid treatment, adverse drug reactions, concomitant anti-microbial therapy, length of hospital stay and any surgical interventions were recorded.

**RESULTS:** Infections were classified as post arthroplasty ( $n = 10$ ), post trauma surgery ( $n = 8$ ) or non-trauma related infections ( $n = 4$ ). Twenty patients (91%) underwent surgical intervention as part of their treatment. The number of required surgical procedures ranged from 1 to 6 (mean = 2.56). Mean total length of stay per admission was 28.5 d (range 1-160 d). Furthermore, the mean duration of treatment with linezolid of patients who had resolution of symptoms was 31 d (range 10-84 d). All patients within this group were discharged on oral linezolid. Pathogens isolated included methicillin resistant *Staphylococcus aureus*, coagulase negative staphylococci, coliforms, enterococcus, *Staphylococcus epidermidis*, *Streptococcus viridans*, *Escherichia coli*, group B streptococcus and pseudomonas. An overall 77% of patients demonstrated resolution of infections at follow-up, with mean C-reactive protein reducing from 123 mg/L to 13.2 mg/L.

**CONCLUSION:** This study demonstrates that the use of linezolid offers excellent efficacy in orthopaedic related infections when used alongside appropriate surgical management.

© 2014 Baishideng Publishing Group Co., Limited. All rights reserved.

**Key words:** Antibiotic resistance; Linezolid; Orthopaedic infections; Osteomyelitis; Periprosthetic joint infection

**Core tip:** Our study demonstrates that linezolid delivers excellent oral bioavailability, with good penetration into bone, joints and soft tissue. It exhibits action against gram-positive organisms, including methicillin resistant *Staphylococcus aureus* and vancomycin resistant enterococci, and it is ideally suited for the variety of infections encountered in orthopaedic practice. Used in conjunction with surgical management, excellent results can be achieved in resolving infection.

Joel J, Graham SM, Peckham-Cooper A, Korres N, Tsouchnica H, Tsiridis E. Clinical results of linezolid in arthroplasty and trauma related infections. *World J Orthop* 2014; 5(2): 151-157 Available from: URL: <http://www.wjgnet.com/2218-5836/full/v5/i2/151.htm> DOI: <http://dx.doi.org/10.5312/wjo.v5.i2.151>

## INTRODUCTION

Infections encountered in trauma surgery and implant related infection in arthroplasty, present a complex therapeutic challenge. Gram-positive organisms, particularly staphylococci and streptococci, are responsible for the majority of these infections encountered in orthopaedic practice in the United Kingdom and United States<sup>[1,2]</sup>. These infections can be notoriously difficult to treat, often requiring lengthy courses of anti-microbial therapy coupled with extensive surgical intervention.

The emergence of antibiotic resistant strains has led to increasing challenges for current management of these infections. In the United States, methicillin resistant *Staphylococcus aureus* (MRSA) now represents 60% of *Staphylococcus aureus* (*S. aureus*) nosocomial infections (CDC 2004)<sup>[3]</sup>. The incidence of MRSA bacteraemia increased from 2% in 1989 to 34% in 1998 in the United Kingdom, but since 2006 there has been a general decline in the incidence of MRSA in the United Kingdom<sup>[4,5]</sup>. Glycopeptide antibiotics, which include vancomycin and teicoplanin, are generally used for treatment in these cases. Use of these agents involves intravenous administration for protracted periods of time usually via a central or a peripherally inserted central catheter (PICC). This factor and the lack of suitable oral alternatives can equate to lengthy inpatient admissions for the treatment of orthopaedic related infections. Additionally, there are increasing concerns over the emergence of glycopeptide resistance in the Gram-positive organisms responsible.

Linezolid is a synthetic antibiotic possessing a novel mode of action, inhibiting bacterial protein synthesis via inhibition of the 50S ribosomal subunit. This blocks the formation of the initiation complex with mRNA and tRNA thus inhibiting bacterial replication<sup>[6]</sup>. Oral administration results in 100% bioavailability and thus, oral and parental administration of the drug are bioequivalent. The drug has a favourable pharmacokinetic profile and has been demonstrated to penetrate in high concentrations in osteo-articular tissues<sup>[7]</sup>. It also has excellent activity against Gram positive bacteria with resistance to beta lactams and glycopeptides<sup>[8]</sup>.

The characteristics of linezolid make it potentially an extremely appealing agent for the treatment of infections encountered in orthopaedic practise. The possibility of an effective oral treatment carries favourable cost saving implications for health care systems. It is estimated that use of outpatient linezolid for prolonged treatment in orthopaedic infection could be considerably less expensive than inpatient glycopeptide therapy<sup>[9]</sup>. Studies support reduction in patient stays of up to 8 d less when treated

with linezolid in comparison to vancomycin. This potentially equates to a cost saving of up to £4800 per patient requiring treatment for orthopaedic related infection.

There are, however, concerns surrounding the tolerability of the drug and particularly in regard to bone marrow suppression. This has been observed with prolonged administration, and requires patients to be carefully monitored whilst undergoing treatment<sup>[10]</sup>.

Although the efficacy of linezolid has been well demonstrated in nosocomial pneumonia, bacteraemia, skin and soft tissue infections there is limited data supporting its use in complex orthopaedic infections. The aims of this study were to identify patients treated with linezolid for orthopaedic infection and evaluate its efficacy and tolerability.

## MATERIALS AND METHODS

This was a retrospective, non-randomised observational study of patients with orthopaedic related infection treated with oral linezolid from April 2005 to June 2007 in a University Hospital covering a population of 1.5 million.

Patients were selected from the hospital data base using clinical coding related to orthopaedic infections, which included infected joint arthroplasty, infection related to fracture fixation, septic arthritis soft tissue or spinal infection. ICD 10 codes used to identify relevant patients included: infection or inflammatory reaction due to other internal prosthetic orthopaedic device/implant graft (T847); infection and or inflammatory reaction due to internal joint prosthesis (T845); infection and or inflammatory reaction due to internal fixation of any device (T846); and the ICD 10 code specific for MRSA infection (B956). In all patients treated with oral linezolid therapy, treatment was initiated following a multi-disciplinary decision and prescribed and monitored with the involvement of medical microbiologist advice. Fifteen patients were initially started with parenteral vancomycin therapy prior to commencement of linezolid when patients were discharged from hospital. The other cases were treated initially with a variety of intravenous antibiotics (rifampicin, cefuroxime and flucloxacillin) based on initial microbiology advice prior to oral linezolid commencement on discharge.

Data regarding patients' concurrent medical history were collected. These included diabetes, nicotine use, alcoholism, vascular disease, systemic inflammatory disease, immunosuppressive drugs and pulmonary disease. Diagnosis of infection was based on a combination of clinical findings, including positive microbiology cultures, and radiographic, biochemical, and haematological signs of infection. Clinical symptoms considered were pain, local warmth, erythema, discharge and tenderness. Objective radiological signs included evidence of osteomyelitis or loosening of the prosthesis on plain X-ray. Laboratory indicators included elevated C-reactive protein (CRP) > 10 mg/L, erythrocyte sedimentation rate (ESR) > 30 mm per hour<sup>[11]</sup>, leucocytosis/leucopenia, and neutrophilia/neutropenia<sup>[11]</sup>. All patients were categorised as having infection following arthroplasty surgery, post trauma



surgery of non trauma bone and/or soft tissue infection. Outcome data collected for review include pathogens isolated, the index procedure, number and nature of surgical interventions required, length of linezolid treatment, use of concomitant antibiotics and duration of treatment, length of hospital stay, adverse reactions to linezolid use, serial biochemical data when available and outcome at follow-up.

Outcome of treatment was classified as successful if no subjective and objective signs of infection were documented at follow up. Cases were considered as unsuccessful if there was evidence of clinical, biochemical or radiological recurrence of infection.

## RESULTS

A total of 22 patients were identified (14 males, 8 females), with an age range of 20 to 86 years (mean age 60.4 years). Infections were classified as post arthroplasty ( $n = 10$ ), post trauma surgery ( $n = 8$ ) or non-trauma related infections ( $n = 4$ ). Non-trauma related infections included infected pre-patella bursitis, 2 cases of L4-5 discitis, L4-5 osteomyelitis, and septic mono-arthritis. 50% of patients were found to have risk factors for infection.

Pathogens identified included MRSA ( $n = 9$ ), coagulase negative staphylococci ( $n = 8$ ), coliforms ( $n = 3$ ) and enterococcus ( $n = 2$ ). Six of the patients had multi-organism infection. In one case no organism was identified despite prolonged culturing of tissue samples and treatment was thus started empirically after discussion with microbiology.

Twenty patients (91%) underwent surgical intervention as part of their treatment. The number of required surgical procedures ranged from 1 to 6 (mean = 2.56) (Table 1). These procedures varied from washout and debridement, removal of metal work and revision surgery.

The mean number of hospital admissions within this group was 1.5 (range 1-6). Mean total length of stay per admission was 28.5 d (range 1-160 d). Mean duration of treatment with linezolid of patients who had resolution of symptoms was 31 d (range 10-84). All patients within this group were discharged on oral linezolid. All previous and concurrent antimicrobial treatment is described in Table 1. Length of follow up for this group ranged from 3 to 57 mo (mean = 28).

Three patients suffered an adverse reaction to linezolid. One patient complained of nausea and vomiting (patient 15), another of visual disturbances (patient 20) and in one instance linezolid treatment was stopped due to thrombocytopenia (patient 16). Two patients died (patient 14, 16) as a sequela of sepsis. Infection resolved in patient 20, but in patients 15, 19 and 21 treatment failed to clear the infection and patients were re-admitted. Their infection subsequently resolved but this was after discontinuing linezolid. The reasons behind these failures are not clear. This resulted in a readmission rate of 13% (3/22).

Resolution of infection was diagnosed clinically by

absence of local and systemic signs and symptoms of infection, alongside radiological and biochemical assessment. Resolution of infection occurred in 17 (77.27%) of all patients at 3-57 mo, with a significant reduction in CRP in all cases. Mean initial CRP was 123 mg/L (range 21-301), with a mean of 13.2 mg/L at resolution of treatment (range < 5-54) (Table 1). The patients were followed up for a mean of 5 years after infection occurred.

## DISCUSSION

Linezolid acts by binding to the 50s ribosomal subunit inhibiting bacterial protein synthesis. It belongs to the oxazolidinone family and demonstrates excellent action against gram-positive bacteria<sup>[6]</sup>. Furthermore, linezolid exhibits excellent penetration into bone and periarticular structures making it suitable for use in orthopaedic related infection<sup>[12]</sup>. Our study clearly demonstrates good results with the use of linezolid to treat orthopaedic related infections, with a resolution of infection in 77% of all patients at 3-57 mo. Additional studies in the literature support our finding, with resolution of infection in up to 90% of patients<sup>[10,13]</sup>.

Infection following joint arthroplasty is a disastrous complication with treatment notoriously difficult. The development of a glycocalyx biofilm layer on implants confers protection to pathogens and thus requires a two-pronged treatment strategy of chemotherapy and surgery. Studies have demonstrated 80%-100% resolution rates in patients treated for infected hip and knee joint arthroplasty with linezolid<sup>[14,15]</sup>. Ten patients in this series who had infections post arthroplasty insertion, 8 (80%) had resolution of infection. Of the two treatment failures, one individual (patient 21) did not tolerate the drug developing nausea and vomiting. This patient received long-term suppressive flucloxacillin as an alternative. The second treatment failure has ongoing symptoms (patient 16). This patient underwent single stage revision for infection. A two-stage procedure allows for the delivery of local therapeutic levels of antibiotics to the surrounding bone and soft tissues whilst systemic treatment is delivered. This method is thought to represent the most efficacious treatment for clearing infection and allowing for revision of the implant, especially in the presence of resistant organisms<sup>[16,17]</sup>.

Risk factors for infection in post trauma patients are secondary to an inadequate initial debridement, presence of prosthetic material in the wound, degree of devitalisation and contamination of soft tissues, and in chronic situations the length of time infection is present. Furthermore patient risk factors resulting in immunosuppression are significant. Ideally all diseased bone should be removed at the earliest opportunity and a radical debridement should be conducted. Following debridement revascularisation of adult bone takes 3-4 wk and this period of time will adversely affect antibiotic activity<sup>[1]</sup>. 87.5% (7 out of 8) of patients in the post trauma infection group had resolution of infection following treatment with

Table 1 Summary of patient management

Patient number	Age, yr	Sex	Organism	Category	CRP (Initial/final)	Surgical intervention	Number of surgical procedures	Linezolid duration (d)	Concurrent antibiotics	Previous antibiotics prior to linezolid	Follow-up (mo)	Resolution
1	43	M	MRSA	Post Trauma	301/< 5	Yes	2	14	Rifampicin	Vancomycin	57	Yes
2	47	F	MRSA	Non Trauma	148/9.8	Yes	2	28	No	Vancomycin Clarithromycin	3	Yes
3	43	M	MRSA	Non Trauma	235/9.8	No	0	84	No	N	14	Yes
4	80	F	Coag neg staph	Arthroplasty	30/< 5	Yes	2	28	No	Vancomycin	33	Yes
5	81	F	Coag Neg staph	Arthroplasty	134/39	Yes	1	42	Rifampicin	Vancomycin	25	Yes
6	20	M	MRSA	Post Trauma	146/< 5	Yes	5	28	No	Flucloxacillin Vancomycin Rifampicin	23	Yes
7	52	F	Staph aureus Pseudomonas	Arthroplasty	133/54	Yes	3	28	No	Vancomycin Clindamycin	41	Yes
8	79	M	Staph epidermidis Coag Neg staph Coliforms	Arthroplasty	153/15.5	Yes	2	28	Rifampicin	Vancomycin	20	Yes
9	73	F	Coag Neg staph	Arthroplasty	106/46	Yes	2	28	No	Vancomycin Rifampicin	24	Yes
10	45	M	None identified	Post Trauma	129/< 5	Yes	2	28	No	Vancomycin	36	Yes
11	48	M	Coag Neg staph Strep viridians Coliforms Acro Xylo	Arthroplasty	79/15	Yes	6	28	No	Vancomycin	41	Yes
12	43	M	MRSA	Post Trauma	72/< 5	Yes	1	28	No	None	24	Yes
13	63	F	Staph aureus	Post Trauma	Sep-63	Yes	1	70	No	Vancomycin	6	Yes
14	47	M	MRSA	Post Trauma	124/12	Yes	4	42	No	Vancomycin	19	No
15	64	F	Staph aureus <i>E. coli</i> Enterococcus	Non Trauma	155/5.5	No	0	8	No	Vancomycin	RIP	No
16	83	F	Enterococcus	Arthroplasty	21/18.6	Yes	1	21	No	Vancomycin	39	No
17	73	M	Coag neg staph	Arthroplasty	68/< 5	Yes	1	28	No	Vancomycin	50	Yes
18	68	M	MRSA Group B strep	Post Trauma	91/< 5	Yes	1	28	No	Vancomycin	18	Yes
19	77	M	MRSA Coliforms Gram negative bacillus	Arthroplasty	65/62	Yes	4	28	No	Vancomycin	47	No
20	86	M	MRSA	Non Trauma	155/26	Yes	2	10	No	Vancomycin Rifampicin	6	Yes
21	79	M	Coag Neg staph	Arthroplasty	29/5	Yes	3	42	No	Vancomycin Rifampicin	22	No
22	35	M	Coag Neg staph	Post Trauma	64/< 5	Yes	3	42	No	Vancomycin	45	Yes

F: Female; M: male; MRSA: Methicillin resistant *Staphylococcus aureus*; CRP: C-reactive protein.

linezolid. All patients within this group underwent surgical intervention as part of their management. The single patient within this group (patient 14), who failed treatment, had initial resolution of symptoms but returned 9 months later with recurrence and thus was regarded as a treatment failure. Surgical debridement in prosthetic related orthopaedic infection is of paramount importance in trying to eradicate infection. The production of the glycocalyx biofilm can act as a protective colony for MRSA thus increasing difficulty in eradication where orthopaedic implants may be *in-situ*<sup>[18]</sup>. This therefore ne-

cessitates the use of debridement and implant removal<sup>[18]</sup>. Studies have demonstrated that debridement alone with retention of prosthetic material in MRSA infection following total knee arthroplasty has a high failure rate<sup>[19]</sup>. Ninety one percent of patients in our cohort underwent at least one surgical procedure alongside combined chemotherapy in an attempt to eradicate the infection. All of these patients using the outlined strategy were successful. The use of combined surgical and chemotherapeutic regimens as demonstrated in this study should be used in combination for the highest chance of success.

The final group reviewed were the patients with non-trauma related infection. The use of linezolid in spinal surgery is less well documented. A study evaluating antibiotic penetration in a rabbit spine model suggests that linezolid is inadequate for the treatment of spinal infection limited to the intervertebral disc, but may be effective for the treatment of infection extending into the muscle and bone marrow, such as in vertebral osteomyelitis, iliopsoas abscess, and postsurgical infection. Three cases (75%) in this series were successfully treated with linezolid<sup>[20]</sup>. The patient with treatment failure in this group (patient 15) developed an L4/5 osteomyelitis with associated psoas abscess and died related to a sequelea of sepsis.

Linezolid has 100% oral bioavailability<sup>[21]</sup>. Oral administration avoids the morbidity associated with intravenous access and line sepsis and the cost of insertion and monitoring of these devices. This may aid in shortening patient stay, as traditionally these patients have required lengthy admissions for parenteral antibiotics. This potentially has major cost implications for health care systems. However, this must be offset by the need to undertake more outpatient follow-up appointments and the fact regular blood tests need to be undertaken to monitor for myelosuppression. Welshman *et al*<sup>[22]</sup> demonstrated statistically significant reduction in length of in-patient stay with MRSA soft tissue infection in patients treated with linezolid as opposed to vancomycin. Further studies have also demonstrated reduction of length of hospital stay in patients with MRSA treated with linezolid<sup>[9,23]</sup>.

*Staphylococcus aureus* is the single most common organism causing osteomyelitis secondary to trauma, surgery or insertion of a joint<sup>[24]</sup>. Chronic infection is notoriously difficult to treat. The relatively high failure rate of antibiotic treatment alone in bone infection is well documented<sup>[25]</sup>. Use of linezolid, along with appropriate surgical management, has been shown to be efficacious. Vercillo *et al*<sup>[26]</sup> demonstrated no recurrence of infection at a minimum of 6 mo follow up in a group of 14 patients with implant related chronic osteomyelitis. Similarly, Rao *et al*<sup>[27]</sup> prospectively monitored 11 patients who received linezolid for osteomyelitis for a mean 27 mo. The entire group had remission demonstrated by clinical, biochemical and radiographic markers<sup>[27]</sup>. The most common causative organisms encountered in this study were predominantly gram-positive organisms, the most common being MRSA.

Only 3 of the patients in our study group were treated with an additional antibiotic as well as linezolid. In all cases this was oral rifampicin. Resistance rates to linezolid have been reported to be low<sup>[28]</sup>. Linezolid resistance occurred in < 1% of *Staphylococcus aureus*, coagulase-negative staphylococci, and enterococci isolates from the US between 2002 and 2009<sup>[29]</sup>. Resistance usually develops after prolonged therapy with linezolid for serious infection although nosocomial acquisition of both resistant enterococci has been reported, including cases in patients with no prior treatment with linezolid<sup>[30-32]</sup>. It has been proposed that a combination with a second antibacterial

agent, particularly rifampicin or fusidic acid, may delay the emergence of linezolid resistance in *Staphylococcus aureus*<sup>[33]</sup>.

Adverse reactions to linezolid treatment are documented. Treatment has been associated with myelosuppression, with reports of anaemia, leucopenia and thrombocytopenia<sup>[15,34,35]</sup>. The side effects of treatment can be detected by close monitoring of blood with myelosuppression being reversible on stopping treatment<sup>[34]</sup>. In this series myelosuppression was observed in one case. The patient developed multi-organ dysfunction syndrome related to sepsis.

Other notable side effects include peripheral neuropathy<sup>[36]</sup>. A single patient within this study group developed a visual disturbance. Optic neuropathy secondary to linezolid has been described<sup>[14]</sup> and there are concerns that linezolid induced peripheral neuropathy may be an irreversible event<sup>[34,36]</sup>. Furthermore, there are several documented case reports of serotonin toxicity when linezolid is used with selective serotonin reuptake inhibitors<sup>[37]</sup>. The symptoms of serotonin syndrome are alteration of mental state, autonomic dysfunction, and neuromuscular disorders. None of our patients developed such symptoms; however it is important that surgeons and physicians are aware of the nonspecific presentation of serotonin symptoms and the treatment when using linezolid. Additionally, contraindications to commencing linezolid include patients taking any medicine which inhibits monoamine oxidases A or B (*e.g.*, phenelzine, isocarboxazid) or within two weeks of taking any such medicinal product. Unless patients are monitored for potential increases in blood pressure, linezolid should not be administered to patients with uncontrolled hypertension, pheochromocytoma, thyrotoxicosis and/or patients taking any of the following types of medications: directly and indirectly acting sympathomimetic agents (*e.g.*, pseudoephedrine), vasopressive agents (*e.g.*, epinephrine, norepinephrine), dopaminergic agents (*e.g.*, dopamine, dobutamine).

Our study has a number of limitations. The patient group was highly heterogeneous and the numbers, as with many other studies, were relatively small. The lack of randomisation and a control further limits definitive conclusions. However, it does lend weight to the growing evidence of linezolid use in this group of patients with joint, bone and implant related infection.

In conclusion, linezolid delivers excellent oral bioavailability, with good penetration into bone, joints and soft tissue. It exhibits action against gram-positive organisms, including MRSA and vancomycin resistant enterococci, and it is ideally suited for the variety of infections encountered in orthopaedic practice. Used in conjunction with surgical management, excellent results can be achieved in resolving infection. It is generally well tolerated but regular monitoring of blood parameters is advisable. While haematological disturbance have been documented, these are generally shown to be transient and reversible in nature on cessation of treatment. Oral administration facilitates earlier hospital discharge, with

associated cost savings to health care systems. Prospective randomised controlled trials are required to further ascertain the role of linezolid in the treatment of orthopaedic related infection.

## COMMENTS

### Background

Infections encountered in trauma surgery and implant related infection in arthroplasty present a complex therapeutic challenge, often requiring lengthy courses of anti-microbial therapy coupled with extensive surgical intervention. Furthermore, the emergence of antibiotic resistant strains has led to increasing challenges for current management of these infections.

### Research frontiers

Linezolid is a synthetic antibiotic that when orally administered results in 100% bioavailability. The drug has a favourable pharmacokinetic profile and been demonstrated to penetrate in high concentrations in osteo-articular tissues. The characteristics of linezolid make it potentially an extremely appealing agent for the treatment of infections encountered in orthopaedic practice.

### Innovations and breakthroughs

Although the efficacy of linezolid has been well demonstrated in nosocomial pneumonia, bacteraemia, skin and soft tissue infections there is limited data supporting its use in complex orthopaedic infections.

### Applications

This study demonstrates that linezolid delivers excellent oral bioavailability, with good penetration into bone, joints and soft tissue. It exhibits action against gram-positive organisms, including methicillin resistant *Staphylococcus aureus* and vancomycin resistant enterococci, and it is ideally suited for the variety of infections encountered in orthopaedic practice. Used in conjunction with surgical management, excellent results can be achieved in resolving orthopaedic infections.

### Terminology

Arthroplasty is the insertion of a prosthetic joint into a patient. Following arthroplasty surgery and bone related injuries, people can potentially develop infections which are very difficult to treat. This study demonstrates that by using the antibiotic linezolid, these infections can be treated effectively. Since linezolid can be given as an oral tablet this results in a patient potentially spending less time in hospital being treated for these types of infections, which results in health care savings and is more convenient for patients

### Peer review

According to the authors "the aim of the present investigation was to identify patients treated with linezolid for orthopaedic infection and evaluate efficacy and tolerability". The authors state that "the results of this study support the use of linezolid, with a 77% resolution at 3-57 mo across all patient groups". It was concluded that the study demonstrates that use of linezolid offers excellent efficacy in orthopaedic related infections when used alongside appropriate surgical management. This is an interesting and important case series.

## REFERENCES


- 1 Darley ES, MacGowan AP. Antibiotic treatment of gram-positive bone and joint infections. *J Antimicrob Chemother* 2004; **53**: 928-935 [PMID: 15117932 DOI: 10.1093/jac/dkh191]
- 2 Metzger R, Bonatti H, Sawyer R. Future trends in the treatment of serious Gram-positive infections. *Drugs Today (Barc)* 2009; **45**: 33-45 [PMID: 19271030 DOI: 10.1358/dot.2009.45.1.1315922]
- 3 Centers for Disease Control and Prevention. (2004). Available from: URL: <http://www.cdc.gov/ncidod/hip/MRSA.htm>
- 4 Reacher MH, Shah A, Livermore DM, Wale MC, Graham C, Johnson AP, Heine H, Monnickendam MA, Barker KF, James D, George RC. Bacteraemia and antibiotic resistance of its pathogens reported in England and Wales between 1990 and 1998: trend analysis. *BMJ* 2000; **320**: 213-216 [PMID: 10642227 DOI: 10.1136/bmj.320.7229.213]
- 5 Wilson J, Guy R, Elgohari S, Sheridan E, Davies J, Lamagni T, Pearson A. Trends in sources of methicillin-resistant *Staphylococcus aureus* (MRSA) bacteraemia: data from the national mandatory surveillance of MRSA bacteraemia in England, 2006-2009. *J Hosp Infect* 2011; **79**: 211-217 [PMID: 21764174 DOI: 10.1016/j.jhin.2011.05.013]
- 6 Bozdogan B, Appelbaum PC. Oxazolidinones: activity, mode of action, and mechanism of resistance. *Int J Antimicrob Agents* 2004; **23**: 113-119 [PMID: 15013035 DOI: 10.1016/j.ijantimicag.2003.11.003]
- 7 Rana B, Butcher I, Grigoris P, Murnaghan C, Seaton RA, Tobin CM. Linezolid penetration into osteo-articular tissues. *J Antimicrob Chemother* 2002; **50**: 747-750 [PMID: 12407135 DOI: 10.1093/jac/dkf207]
- 8 Rybak MJ, Hershberger E, Moldovan T, Grucz RG. In vitro activities of daptomycin, vancomycin, linezolid, and quinupristin-dalfopristin against *Staphylococci* and *Enterococci*, including vancomycin-intermediate and -resistant strains. *Antimicrob Agents Chemother* 2000; **44**: 1062-1066 [PMID: 10722513 DOI: 10.1128/AAC.44.4.1062-1066.2000]
- 9 Nathwani D. Impact of methicillin-resistant *Staphylococcus aureus* infections on key health economic outcomes: does reducing the length of hospital stay matter? *J Antimicrob Chemother* 2003; **51** Suppl 2: ii37-ii44 [PMID: 12730141 DOI: 10.1093/jac/dkg250]
- 10 Harwood PJ, Giannoudis PV. The safety and efficacy of linezolid in orthopaedic practice for the treatment of infection due to antibiotic-resistant organisms. *Expert Opin Drug Saf* 2004; **3**: 405-414 [PMID: 15335296 DOI: 10.1517/14740338.3.5.405]
- 11 Spangehl MJ, Masri BA, O'Connell JX, Duncan CP. Prospective analysis of preoperative and intraoperative investigations for the diagnosis of infection at the sites of two hundred and two revision total hip arthroplasties. *J Bone Joint Surg Am* 1999; **81**: 672-683 [PMID: 10360695]
- 12 Lovering AM, Zhang J, Bannister GC, Lankester BJ, Brown JH, Narendra G, MacGowan AP. Penetration of linezolid into bone, fat, muscle and haematoma of patients undergoing routine hip replacement. *J Antimicrob Chemother* 2002; **50**: 73-77 [PMID: 12096009 DOI: 10.1093/jac/dkf066]
- 13 Harwood PJ, Talbot C, Dimoutsos M, Sunderland G, Shaw D, Wilcox MH, Giannoudis PV. Early experience with linezolid for infections in orthopaedics. *Injury* 2006; **37**: 818-826 [PMID: 16620816 DOI: 10.1016/j.injury.2006.02.007]
- 14 Bassetti M, Vitale F, Melica G, Righi E, Di Biagio A, Molfetta L, Pipino F, Cruciani M, Bassetti D. Linezolid in the treatment of Gram-positive prosthetic joint infections. *J Antimicrob Chemother* 2005; **55**: 387-390 [PMID: 15705640 DOI: 10.1093/jac/dki016]
- 15 Oussedik SI, Haddad FS. The use of linezolid in the treatment of infected total joint arthroplasty. *J Arthroplasty* 2008; **23**: 273-278 [PMID: 18280424 DOI: 10.1016/j.arth.2007.03.022]
- 16 Kordelle J, Frommelt L, Klüber D, Seemann K. [Results of one-stage endoprosthesis revision in periprosthetic infection cause by methicillin-resistant *Staphylococcus aureus*]. *Z Orthop Ihre Grenzgeb* 2000; **138**: 240-244 [PMID: 10929616 DOI: 10.1055/s-2000-10143]
- 17 Jackson WO, Schmalzried TP. Limited role of direct exchange arthroplasty in the treatment of infected total hip replacements. *Clin Orthop Relat Res* 2000; **381**: 101-105 [PMID: 11127645 DOI: 10.1097/00003086-200012000-00012]
- 18 Jabra-Rizk MA, Meiller TF, James CE, Shirliff ME. Effect of farnesol on *Staphylococcus aureus* biofilm formation and antimicrobial susceptibility. *Antimicrob Agents Chemother* 2006; **50**: 1463-1469 [PMID: 16569866 DOI: 10.1128/AAC.50.4.1463-1469.2006]
- 19 Patel A, Calfee RP, Plante M, Fischer SA, Arcand N, Born C. Methicillin-resistant *Staphylococcus aureus* in orthopaedic surgery. *J Bone Joint Surg Br* 2008; **90**: 1401-1406 [PMID: 18978255 DOI: 10.1302/0301-620X.90B11.20771]
- 20 Bradbury T, Fehring TK, Taunton M, Hanssen A, Azzam K, Parvizi J, Odum SM. The fate of acute methicillin-resistant *Staphylococcus aureus* periprosthetic knee infections treated



- by open debridement and retention of components. *J Arthroplasty* 2009; **24**: 101-104 [PMID: 19553077 DOI: 10.1016/j.arth.2009.04.028]
- 21 **Komatsu M**, Takahata M, Sugawara M, Takekuma Y, Kato T, Ito M, Abe Y, Irie T, Iwasaki N, Minami A. Penetration of linezolid into rabbit intervertebral discs and surrounding tissues. *Eur Spine J* 2010; **19**: 2149-2155 [PMID: 20694846 DOI: 10.1007/s00586-010-1548-x]
  - 22 **Welshman IR**, Sisson TA, Jungbluth GL, Stalker DJ, Hopkins NK. Linezolid absolute bioavailability and the effect of food on oral bioavailability. *Biopharm Drug Dispos* 2001; **22**: 91-97 [PMID: 11745911]
  - 23 **Itani KM**, Weigelt J, Li JZ, Duttgupta S. Linezolid reduces length of stay and duration of intravenous treatment compared with vancomycin for complicated skin and soft tissue infections due to suspected or proven methicillin-resistant *Staphylococcus aureus* (MRSA). *Int J Antimicrob Agents* 2005; **26**: 442-448 [PMID: 16289514 DOI: 10.1016/j.ijantimicag.2005.09.003]
  - 24 **Willke RJ**, Glick HA, Li JZ, Rittenhouse BE. Effects of linezolid on hospital length of stay compared with vancomycin in treatment of methicillin-resistant *Staphylococcus* infections. An application of multivariate survival analysis. *Int J Technol Assess Health Care* 2002; **18**: 540-554 [PMID: 12391947]
  - 25 **Lew DP**, Waldvogel FA. Osteomyelitis. *Lancet* 2004; **364**: 369-379 [PMID: 15276398 DOI: 10.1016/S0140-6736(04)16727-5]
  - 26 **Vercillo M**, Patzakis MJ, Holtom P, Zalavras CG. Linezolid in the treatment of implant-related chronic osteomyelitis. *Clin Orthop Relat Res* 2007; **461**: 40-43 [PMID: 17514011]
  - 27 **Rao N**, Ziran BH, Hall RA, Santa ER. Successful treatment of chronic bone and joint infections with oral linezolid. *Clin Orthop Relat Res* 2004; **427**: 67-71 [PMID: 15552139 DOI: 10.1097/01.blo.0000144860.11193.5e]
  - 28 **Jones RN**, Kohno S, Ono Y, Ross JE, Yanagihara K. ZAAPS International Surveillance Program (2007) for linezolid resistance: results from 5591 Gram-positive clinical isolates in 23 countries. *Diagn Microbiol Infect Dis* 2009; **64**: 191-201 [PMID: 19500528 DOI: 10.1016/j.diagmicrobio.2009.03.001]
  - 29 **Ross JE**, Farrell DJ, Mendes RE, Sader HS, Jones RN. Eight-year (2002-2009) summary of the linezolid (Zyvox® Annual Appraisal of Potency and Spectrum; ZAAPS) program in European countries. *J Chemother* 2011; **23**: 71-76 [PMID: 21571621 DOI: 10.1179/joc.2011.23.2.71]
  - 30 **Kola A**, Kirschner P, Gohrbandt B, Chaberny IF, Mattner F, Strüder M, Gastmeier P, Suerbaum S. An infection with linezolid-resistant *S. aureus* in a patient with left ventricular assist system. *Scand J Infect Dis* 2007; **39**: 463-465 [PMID: 17464873 DOI: 10.1080/00365540601071875]
  - 31 **Kelly S**, Collins J, Maguire M, Gowing C, Flanagan M, Donnelly M, Murphy PG. An outbreak of colonization with linezolid-resistant *Staphylococcus epidermidis* in an intensive therapy unit. *J Antimicrob Chemother* 2008; **61**: 901-907 [PMID: 18272512 DOI: 10.1093/jac/dkn043]
  - 32 **Dobbs TE**, Patel M, Waites KB, Moser SA, Stamm AM, Hoesley CJ. Nosocomial spread of *Enterococcus faecium* resistant to vancomycin and linezolid in a tertiary care medical center. *J Clin Microbiol* 2006; **44**: 3368-3370 [PMID: 16954275 DOI: 10.1128/JCM.00850-06]
  - 33 **Miller K**, O'Neill AJ, Wilcox MH, Ingham E, Chopra I. Delayed development of linezolid resistance in *Staphylococcus aureus* following exposure to low levels of antimicrobial agents. *Antimicrob Agents Chemother* 2008; **52**: 1940-1944 [PMID: 18378719 DOI: 10.1128/AAC.01302-07]
  - 34 **Razonable RR**, Osmon DR, Steckelberg JM. Linezolid therapy for orthopedic infections. *Mayo Clin Proc* 2004; **79**: 1137-1144 [PMID: 15357035]
  - 35 **Shaw KJ**, Barbachyn MR. The oxazolidinones: past, present, and future. *Ann N Y Acad Sci* 2011; **1241**: 48-70 [PMID: 22191526 DOI: 10.1111/j.1749-6632.2011.06330.x]
  - 36 **Falagas ME**, Siempos II, Papagelopoulos PJ, Vardakas KZ. Linezolid for the treatment of adults with bone and joint infections. *Int J Antimicrob Agents* 2007; **29**: 233-239 [PMID: 17204407 DOI: 10.1016/j.ijantimicag.2006.08.030]
  - 37 **Mason LW**, Randhawa KS, Carpenter EC. Serotonin toxicity as a consequence of linezolid use in revision hip arthroplasty. *Orthopedics* 2008; **31**: 1140 [PMID: 19226083 DOI: 10.3928/01477447-20081101-17]

**P- Reviewers:** Peng BG, Paschalis V, Willis-Owen CA  
**S- Editor:** Song XX **L- Editor:** O'Neill M **E- Editor:** Lu YJ





## INSTRUCTIONS TO AUTHORS

### GENERAL INFORMATION

*World Journal of Orthopedics* (World J Orthop, WJO, online ISSN 2218-5836, DOI: 10.5312) is a peer-reviewed open access (OA) academic journal that aims to guide clinical practice and improve diagnostic and therapeutic skills of clinicians.

#### Aim and scope

WJO covers topics concerning arrhythmia, heart failure, vascular disease, stroke, hypertension, prevention and epidemiology, dyslipidemia and metabolic disorders, cardiac imaging, pediatrics, nursing, and health promotion. Priority publication will be given to articles concerning diagnosis and treatment of orthopedics diseases. The following aspects are covered: Clinical diagnosis, laboratory diagnosis, differential diagnosis, imaging tests, pathological diagnosis, molecular biological diagnosis, immunological diagnosis, genetic diagnosis, functional diagnostics, and physical diagnosis; and comprehensive therapy, drug therapy, surgical therapy, interventional treatment, minimally invasive therapy, and robot-assisted therapy.

We encourage authors to submit their manuscripts to WJO. We will give priority to manuscripts that are supported by major national and international foundations and those that are of great basic and clinical significance.

WJO is edited and published by Baishideng Publishing Group (BPG). BPG has a strong professional editorial team composed of science editors, language editors and electronic editors. BPG currently publishes 42 OA clinical medical journals, including 41 in English, has a total of 15471 editorial board members or peer reviewers, and is a world first-class publisher.

#### Columns

The columns in the issues of WJO will include: (1) Editorial: The editorial board members are invited to make comments on an important topic in their field in terms of its current research status and future directions to lead the development of this discipline; (2) Frontier: The editorial board members are invited to select a highly cited cutting-edge original paper of his/her own to summarize major findings, the problems that have been resolved and remain to be resolved, and future research directions to help readers understand his/her important academic point of view and future research directions in the field; (3) Diagnostic Advances: The editorial board members are invited to write high-quality diagnostic advances in their field to improve the diagnostic skills of readers. The topic covers general clinical diagnosis, differential diagnosis, pathological diagnosis, laboratory diagnosis, imaging diagnosis, endoscopic diagnosis, biotechnological diagnosis, functional diagnosis, and physical diagnosis; (4) Therapeutics Advances: The editorial board members are invited to write high-quality therapeutic advances in their field to help improve the therapeutic skills of readers. The topic covers medication therapy, psychotherapy, physical therapy, replacement therapy, interventional therapy, minimally invasive therapy, endoscopic therapy, transplantation therapy, and surgical therapy; (5) Field of Vision: The editorial board members are invited to write commentaries on classic articles, hot topic articles, or latest articles to keep readers at the forefront of research and increase their levels of clinical research. Classic articles refer to papers that are included in Web of Knowledge and have received a large number of citations (ranking in the top 1%) after being published for more than years, reflecting the quality and impact of papers. Hot topic articles refer to papers that are included in

Web of Knowledge and have received a large number of citations after being published for no more than 2 years, reflecting cutting-edge trends in scientific research. Latest articles refer to the latest published high-quality papers that are included in PubMed, reflecting the latest research trends. These commentary articles should focus on the status quo of research, the most important research topics, the problems that have now been resolved and remain to be resolved, and future research directions. Basic information about the article to be commented (including authors, article title, journal name, year, volume, and inclusive page numbers; (6) Minireviews: The editorial board members are invited to write short reviews on recent advances and trends in research of molecular biology, genomics, and related cutting-edge technologies to provide readers with the latest knowledge and help improve their diagnostic and therapeutic skills; (7) Review: To make a systematic review to focus on the status quo of research, the most important research topics, the problems that have now been resolved and remain to be resolved, and future research directions; (8) Topic Highlight: The editorial board members are invited to write a series of articles (7-10 articles) to comment and discuss a hot topic to help improve the diagnostic and therapeutic skills of readers; (9) Medical Ethics: The editorial board members are invited to write articles about medical ethics to increase readers' knowledge of medical ethics. The topic covers international ethics guidelines, animal studies, clinical trials, organ transplantation, etc.; (10) Clinical Case Conference or Clinicopathological Conference: The editorial board members are invited to contribute high-quality clinical case conference; (11) Original Articles: To report innovative and original findings in orthopedics; (12) Brief Articles: To briefly report the novel and innovative findings in orthopedics; (13) Meta-Analysis: To evaluate the clinical effectiveness in orthopedics by using data from two or more randomised control trials; (14) Case Report: To report a rare or typical case; (15) Letters to the Editor: To discuss and make reply to the contributions published in WJO, or to introduce and comment on a controversial issue of general interest; (16) Book Reviews: To introduce and comment on quality monographs of orthopedics; and (17) Autobiography: The editorial board members are invited to write their autobiography to provide readers with stories of success or failure in their scientific research career. The topic covers their basic personal information and information about when they started doing research work, where and how they did research work, what they have achieved, and their lessons from success or failure.

#### Name of journal

*World Journal of Orthopedics*

#### ISSN

ISSN 2218-5836 (online)

#### Launch date

November 18, 2010

#### Frequency

Quarterly

#### Editor-in-Chief

Bao-Gan Peng, MD, PhD, Professor, Department of Spinal Surgery, General Hospital of Armed Police Force, 69 Yongding

## Instructions to authors

Road, Beijing 100039, China

### Editorial office

Jin-Lei Wang, Director

Xiu-Xia Song, Vice Director

*World Journal of Orthopedics*

Room 903, Building D, Ocean International Center,

No. 62 Dongsihuan Zhonglu, Chaoyang District,

Beijing 100025, China

Telephone: +86-10-85381891

Fax: +86-10-85381893

E-mail: [bpgoffice@wjgnet.com](mailto:bpgoffice@wjgnet.com)

<http://www.wjgnet.com>

### Publisher

Baishideng Publishing Group Co., Limited

Flat C, 23/F, Lucky Plaza, 315-321 Lockhart Road,

Wan Chai, Hong Kong, China

Fax: +852-65557188

Telephone: +852-31779906

E-mail: [bpgoffice@wjgnet.com](mailto:bpgoffice@wjgnet.com)

<http://www.wjgnet.com>

### Production center

Beijing Baishideng BioMed Scientific Co., Limited

Room 903, Building D, Ocean International Center,

No. 62 Dongsihuan Zhonglu, Chaoyang District,

Beijing 100025, China

Telephone: +86-10-85381892

Fax: +86-10-85381893

### Representative office

USA Office

8226 Regency Drive,

Pleasanton, CA 94588-3144, United States

### Instructions to authors

Full instructions are available online at [http://www.wjgnet.com/2218-5836/g\\_info\\_20100316161927.htm](http://www.wjgnet.com/2218-5836/g_info_20100316161927.htm).

### Indexed and Abstracted in

PubMed Central, PubMed, Digital Object Identifier, and Directory of Open Access Journals.

## SPECIAL STATEMENT

All articles published in this journal represent the viewpoints of the authors except where indicated otherwise.

### Biostatistical editing

Statistical review is performed after peer review. We invite an expert in Biomedical Statistics to evaluate the statistical method used in the paper, including *t*-test (group or paired comparisons), chi-squared test, Redit, probit, logit, regression (linear, curvilinear, or stepwise), correlation, analysis of variance, analysis of covariance, *etc.* The reviewing points include: (1) Statistical methods should be described when they are used to verify the results; (2) Whether the statistical techniques are suitable or correct; (3) Only homogeneous data can be averaged. Standard deviations are preferred to standard errors. Give the number of observations and subjects (*n*). Losses in observations, such as drop-outs from the study should be reported; (4) Values such as ED50, LD50, IC50 should have their 95% confidence limits calculated and compared by weighted probit analysis (Bliss and Finney); and (5) The word 'significantly' should be replaced by its synonyms (if it indicates extent) or the *P* value (if it indicates statistical significance).

### Conflict-of-interest statement

In the interests of transparency and to help reviewers assess any potential bias, *WJO* requires authors of all papers to declare any competing commercial, personal, political, intellectual, or religious interests

in relation to the submitted work. Referees are also asked to indicate any potential conflict they might have reviewing a particular paper. Before submitting, authors are suggested to read "Uniform Requirements for Manuscripts Submitted to Biomedical Journals: Ethical Considerations in the Conduct and Reporting of Research: Conflicts of Interest" from International Committee of Medical Journal Editors (ICMJE), which is available at: [http://www.icmje.org/ethical\\_4conflicts.html](http://www.icmje.org/ethical_4conflicts.html).

Sample wording: [Name of individual] has received fees for serving as a speaker, a consultant and an advisory board member for [names of organizations], and has received research funding from [names of organization]. [Name of individual] is an employee of [name of organization]. [Name of individual] owns stocks and shares in [name of organization]. [Name of individual] owns patent [patent identification and brief description].

### Statement of informed consent

Manuscripts should contain a statement to the effect that all human studies have been reviewed by the appropriate ethics committee or it should be stated clearly in the text that all persons gave their informed consent prior to their inclusion in the study. Details that might disclose the identity of the subjects under study should be omitted. Authors should also draw attention to the Code of Ethics of the World Medical Association (Declaration of Helsinki, 1964, as revised in 2004).

### Statement of human and animal rights

When reporting the results from experiments, authors should follow the highest standards and the trial should conform to Good Clinical Practice (for example, US Food and Drug Administration Good Clinical Practice in FDA-Regulated Clinical Trials; UK Medicines Research Council Guidelines for Good Clinical Practice in Clinical Trials) and/or the World Medical Association Declaration of Helsinki. Generally, we suggest authors follow the lead investigator's national standard. If doubt exists whether the research was conducted in accordance with the above standards, the authors must explain the rationale for their approach and demonstrate that the institutional review body explicitly approved the doubtful aspects of the study.

Before submitting, authors should make their study approved by the relevant research ethics committee or institutional review board. If human participants were involved, manuscripts must be accompanied by a statement that the experiments were undertaken with the understanding and appropriate informed consent of each. Any personal item or information will not be published without explicit consents from the involved patients. If experimental animals were used, the materials and methods (experimental procedures) section must clearly indicate that appropriate measures were taken to minimize pain or discomfort, and details of animal care should be provided.

## SUBMISSION OF MANUSCRIPTS

Manuscripts should be typed in 1.5 line spacing and 12 pt. Book Antiqua with ample margins. Number all pages consecutively, and start each of the following sections on a new page: Title Page, Abstract, Introduction, Materials and Methods, Results, Discussion, Acknowledgements, References, Tables, Figures, and Figure Legends. Neither the editors nor the publisher are responsible for the opinions expressed by contributors. Manuscripts formally accepted for publication become the permanent property of Baishideng Publishing Group Co., Limited, and may not be reproduced by any means, in whole or in part, without the written permission of both the authors and the publisher. We reserve the right to copy-edit and put onto our website accepted manuscripts. Authors should follow the relevant guidelines for the care and use of laboratory animals of their institution or national animal welfare committee. For the sake of transparency in regard to the performance and reporting of clinical trials, we endorse the policy of the ICMJE to refuse to publish papers on clinical trial results if the trial was not recorded in a publicly-accessible registry at its outset. The only register now available, to our knowledge, is <http://www.clinicaltrials.gov> sponsored by the United States National Library of Medicine and we encourage all potential contributors to register with it. However, in the case that other registers become available you will be duly notified.

A letter of recommendation from each author's organization should be provided with the contributed article to ensure the privacy and secrecy of research is protected.

Authors should retain one copy of the text, tables, photographs and illustrations because rejected manuscripts will not be returned to the author(s) and the editors will not be responsible for loss or damage to photographs and illustrations sustained during mailing.

### Online submissions

Manuscripts should be submitted through the Online Submission System at: <http://www.wjgnet.com/esp/>. Authors are highly recommended to consult the ONLINE INSTRUCTIONS TO AUTHORS ([http://www.wjgnet.com/2218-5836/g\\_info\\_20100316161927.htm](http://www.wjgnet.com/2218-5836/g_info_20100316161927.htm)) before attempting to submit online. For assistance, authors encountering problems with the Online Submission System may send an email describing the problem to [wjo@wjgnet.com](mailto:wjo@wjgnet.com), or by telephone: +86-10-85381892. If you submit your manuscript online, do not make a postal contribution. Repeated online submission for the same manuscript is strictly prohibited.

## MANUSCRIPT PREPARATION

All contributions should be written in English. All articles must be submitted using word-processing software. All submissions must be typed in 1.5 line spacing and 12 pt. Book Antiqua with ample margins. Style should conform to our house format. Required information for each of the manuscript sections is as follows:

### Title page

**Title:** Title should be less than 12 words.

**Running title:** A short running title of less than 6 words should be provided.

**Authorship:** Authorship credit should be in accordance with the standard proposed by ICMJE, based on (1) substantial contributions to conception and design, acquisition of data, or analysis and interpretation of data; (2) drafting the article or revising it critically for important intellectual content; and (3) final approval of the version to be published. Authors should meet conditions 1, 2, and 3.

**Institution:** Author names should be given first, then the complete name of institution, city, province and postcode. For example, Xu-Chen Zhang, Li-Xin Mei, Department of Pathology, Chengde Medical College, Chengde 067000, Hebei Province, China. One author may be represented from two institutions, for example, George Sgourakis, Department of General, Visceral, and Transplantation Surgery, Essen 45122, Germany; George Sgourakis, 2nd Surgical Department, Korgialenio-Benakio Red Cross Hospital, Athens 15451, Greece

**Author contributions:** The format of this section should be: Author contributions: Wang CL and Liang L contributed equally to this work; Wang CL, Liang L, Fu JF, Zou CC, Hong F and Wu XM designed the research; Wang CL, Zou CC, Hong F and Wu XM performed the research; Xue JZ and Lu JR contributed new reagents/analytic tools; Wang CL, Liang L and Fu JF analyzed the data; and Wang CL, Liang L and Fu JF wrote the paper.

**Supportive foundations:** The complete name and number of supportive foundations should be provided, e.g. Supported by National Natural Science Foundation of China, No. 30224801

**Correspondence to:** Only one corresponding address should be provided. Author names should be given first, then author title, affiliation, the complete name of institution, city, postcode, province, country, and email. All the letters in the email should be in lower case. A space interval should be inserted between country name and email address. For example, Montgomery Bissell, MD, Professor of Medicine, Chief, Liver Center, Gastroenterology Division, Uni-

versity of California, Box 0538, San Francisco, CA 94143, United States. [montgomery.bissell@ucsf.edu](mailto:montgomery.bissell@ucsf.edu)

**Telephone and fax:** Telephone and fax should consist of +, country number, district number and telephone or fax number, e.g. Telephone: +86-10-85381892 Fax: +86-10-85381893

**Peer reviewers:** All articles received are subject to peer review. Normally, three experts are invited for each article. Decision on acceptance is made only when at least two experts recommend publication of an article. All peer-reviewers are acknowledged on Express Submission and Peer-review System website.

### Abstract

There are unstructured abstracts (no less than 200 words) and structured abstracts. The specific requirements for structured abstracts are as follows:

An informative, structured abstract should accompany each manuscript. Abstracts of original contributions should be structured into the following sections: AIM (no more than 20 words; Only the purpose of the study should be included. Please write the Aim in the form of "To investigate/study/..."), METHODS (no less than 140 words for Original Articles; and no less than 80 words for Brief Articles), RESULTS (no less than 150 words for Original Articles and no less than 120 words for Brief Articles; You should present *P* values where appropriate and must provide relevant data to illustrate how they were obtained, e.g.  $6.92 \pm 3.86$  vs  $3.61 \pm 1.67$ ,  $P < 0.001$ ), and CONCLUSION (no more than 26 words).

### Key words

Please list 5-10 key words, selected mainly from *Index Medicus*, which reflect the content of the study.

### Core tip

Please write a summary of less than 100 words to outline the most innovative and important arguments and core contents in your paper to attract readers.

### Text

For articles of these sections, original articles and brief articles, the main text should be structured into the following sections: INTRODUCTION, MATERIALS AND METHODS, RESULTS and DISCUSSION, and should include appropriate Figures and Tables. Data should be presented in the main text or in Figures and Tables, but not in both.

### Illustrations

Figures should be numbered as 1, 2, 3, *etc.*, and mentioned clearly in the main text. Provide a brief title for each figure on a separate page. Detailed legends should not be provided under the figures. This part should be added into the text where the figures are applicable. Keeping all elements compiled is necessary in line-art image. Scale bars should be used rather than magnification factors, with the length of the bar defined in the legend rather than on the bar itself. File names should identify the figure and panel. Avoid layering type directly over shaded or textured areas. Please use uniform legends for the same subjects. For example: Figure 1 Pathological changes in atrophic gastritis after treatment. A: ...; B: ...; C: ...; D: ...; E: ...; F: ...; G: ... *etc.* It is our principle to publish high resolution-figures for the E-versions.

### Tables

Three-line tables should be numbered 1, 2, 3, *etc.*, and mentioned clearly in the main text. Provide a brief title for each table. Detailed legends should not be included under tables, but rather added into the text where applicable. The information should complement, but not duplicate the text. Use one horizontal line under the title, a second under column heads, and a third below the Table, above any footnotes. Vertical and italic lines should be omitted.

### Notes in tables and illustrations

Data that are not statistically significant should not be noted. \* $P <$



## Instructions to authors

0.05, <sup>b</sup> $P < 0.01$  should be noted ( $P > 0.05$  should not be noted). If there are other series of  $P$  values, <sup>c</sup> $P < 0.05$  and <sup>d</sup> $P < 0.01$  are used. A third series of  $P$  values can be expressed as <sup>e</sup> $P < 0.05$  and <sup>f</sup> $P < 0.01$ . Other notes in tables or under illustrations should be expressed as <sup>1</sup>F, <sup>2</sup>F, <sup>3</sup>F; or sometimes as other symbols with a superscript (Arabic numerals) in the upper left corner. In a multi-curve illustration, each curve should be labeled with ●, ○, ■, □, ▲, △, etc., in a certain sequence.

### Acknowledgments

Brief acknowledgments of persons who have made genuine contributions to the manuscript and who endorse the data and conclusions should be included. Authors are responsible for obtaining written permission to use any copyrighted text and/or illustrations.

## REFERENCES

### Coding system

The author should number the references in Arabic numerals according to the citation order in the text. Put reference numbers in square brackets in superscript at the end of citation content or after the cited author's name. For citation content which is part of the narration, the coding number and square brackets should be typeset normally. For example, "Crohn's disease (CD) is associated with increased intestinal permeability<sup>[1,2]</sup>". If references are cited directly in the text, they should be put together within the text, for example, "From references<sup>[19,22-24]</sup>, we know that..."

When the authors write the references, please ensure that the order in text is the same as in the references section, and also ensure the spelling accuracy of the first author's name. Do not list the same citation twice.

### PMID and DOI

Please provide PubMed citation numbers to the reference list, e.g. PMID and DOI, which can be found at <http://www.ncbi.nlm.nih.gov/sites/entrez?db=pubmed> and <http://www.crossref.org/SimpleTextQuery/>, respectively. The numbers will be used in E-version of this journal.

### Style for journal references

Authors: the name of the first author should be typed in bold-faced letters. The family name of all authors should be typed with the initial letter capitalized, followed by their abbreviated first and middle initials. (For example, Lian-Sheng Ma is abbreviated as Ma LS, Bo-Rong Pan as Pan BR). The title of the cited article and italicized journal title (journal title should be in its abbreviated form as shown in PubMed), publication date, volume number (in black), start page, and end page [PMID: 11819634 DOI: 10.3748/wjg.13.5396].

### Style for book references

Authors: the name of the first author should be typed in bold-faced letters. The surname of all authors should be typed with the initial letter capitalized, followed by their abbreviated middle and first initials. (For example, Lian-Sheng Ma is abbreviated as Ma LS, Bo-Rong Pan as Pan BR) Book title. Publication number. Publication place: Publication press, Year: start page and end page.

### Format

#### Journals

English journal article (list all authors and include the PMID where applicable)

- 1 **Jung EM**, Clevert DA, Schreyer AG, Schmitt S, Rennert J, Kubale R, Feuerbach S, Jung F. Evaluation of quantitative contrast harmonic imaging to assess malignancy of liver tumors: A prospective controlled two-center study. *World J Gastroenterol* 2007; **13**: 6356-6364 [PMID: 18081224 DOI: 10.3748/wjg.13.6356]

Chinese journal article (list all authors and include the PMID where applicable)

- 2 **Lin GZ**, Wang XZ, Wang P, Lin J, Yang FD. Immunologic effect of Jianpi Yishen decoction in treatment of Pixu-diarhoea. *Shijie Huaren Xiaohua Zazhi* 1999; **7**: 285-287

In press

- 3 **Tian D**, Araki H, Stahl E, Bergelson J, Kreitman M. Signature

of balancing selection in Arabidopsis. *Proc Natl Acad Sci USA* 2006; In press

Organization as author

- 4 **Diabetes Prevention Program Research Group**. Hypertension, insulin, and proinsulin in participants with impaired glucose tolerance. *Hypertension* 2002; **40**: 679-686 [PMID: 12411462 PMID:2516377 DOI:10.1161/01.HYP.0000035706.28494.09]

Both personal authors and an organization as author

- 5 **Vallancien G**, Emberton M, Harving N, van Moorselaar RJ; Alf-One Study Group. Sexual dysfunction in 1, 274 European men suffering from lower urinary tract symptoms. *J Urol* 2003; **169**: 2257-2261 [PMID: 12771764 DOI:10.1097/01.ju.0000067940.76090.73]

No author given

- 6 21st century heart solution may have a sting in the tail. *BMJ* 2002; **325**: 184 [PMID: 12142303 DOI:10.1136/bmj.325.7357.184]

Volume with supplement

- 7 **Geraud G**, Spierings EL, Keywood C. Tolerability and safety of frovatriptan with short- and long-term use for treatment of migraine and in comparison with sumatriptan. *Headache* 2002; **42** Suppl 2: S93-99 [PMID: 12028325 DOI:10.1046/j.1526-4610.42.s2.7.x]

Issue with no volume

- 8 **Banit DM**, Kaufer H, Hartford JM. Intraoperative frozen section analysis in revision total joint arthroplasty. *Clin Orthop Relat Res* 2002; (**401**): 230-238 [PMID: 12151900 DOI:10.1097/00003086-200208000-00026]

No volume or issue

- 9 Outreach: Bringing HIV-positive individuals into care. *HRS-A Careaction* 2002; 1-6 [PMID: 12154804]

### Books

Personal author(s)

- 10 **Sherlock S**, Dooley J. Diseases of the liver and biliary system. 9th ed. Oxford: Blackwell Sci Pub, 1993: 258-296

Chapter in a book (list all authors)

- 11 **Lam SK**. Academic investigator's perspectives of medical treatment for peptic ulcer. In: Swabb EA, Azabo S. Ulcer disease: investigation and basis for therapy. New York: Marcel Dekker, 1991: 431-450

Author(s) and editor(s)

- 12 **Breedlove GK**, Schorfheide AM. Adolescent pregnancy. 2nd ed. Wiczorek RR, editor. White Plains (NY): March of Dimes Education Services, 2001: 20-34

Conference proceedings

- 13 **Harnden P**, Joffe JK, Jones WG, editors. Germ cell tumours V. Proceedings of the 5th Germ cell tumours Conference; 2001 Sep 13-15; Leeds, UK. New York: Springer, 2002: 30-56

Conference paper

- 14 **Christensen S**, Oppacher F. An analysis of Koza's computational effort statistic for genetic programming. In: Foster JA, Lutton E, Miller J, Ryan C, Tettamanzi AG, editors. Genetic programming. EuroGP 2002: Proceedings of the 5th European Conference on Genetic Programming; 2002 Apr 3-5; Kinsdale, Ireland. Berlin: Springer, 2002: 182-191

Electronic journal (list all authors)

- 15 Morse SS. Factors in the emergence of infectious diseases. *Emerg Infect Dis* serial online, 1995-01-03, cited 1996-06-05; 1(1): 24 screens. Available from: URL: <http://www.cdc.gov/ncidod/eid/index.htm>

Patent (list all authors)

- 16 **Pagedas AC**, inventor; Ancel Surgical R&D Inc., assignee. Flexible endoscopic grasping and cutting device and positioning tool assembly. United States patent US 20020103498. 2002 Aug 1

### Statistical data

Write as mean  $\pm$  SD or mean  $\pm$  SE.

**Statistical expression**

Express *t* test as *t* (in italics), *F* test as *F* (in italics), chi square test as  $\chi^2$  (in Greek), related coefficient as *r* (in italics), degree of freedom as *ν* (in Greek), sample number as *n* (in italics), and probability as *P* (in italics).

**Units**

Use SI units. For example: body mass, *m* (B) = 78 kg; blood pressure, *p* (B) = 16.2/12.3 kPa; incubation time, *t* (incubation) = 96 h; blood glucose concentration, *c* (glucose)  $6.4 \pm 2.1$  mmol/L; blood CEA mass concentration, *p* (CEA) = 8.6 24.5 μg/L; CO<sub>2</sub> volume fraction, 50 mL/L CO<sub>2</sub>, not 5% CO<sub>2</sub>; likewise for 40 g/L formaldehyde, not 10% formalin; and mass fraction, 8 ng/g, *etc.* Arabic numerals such as 23, 243, 641 should be read 23243641.

The format for how to accurately write common units and quantums can be found at: [http://www.wjgnet.com/2218-5836/g\\_info\\_20100724204625.htm](http://www.wjgnet.com/2218-5836/g_info_20100724204625.htm).

**Abbreviations**

Standard abbreviations should be defined in the abstract and on first mention in the text. In general, terms should not be abbreviated unless they are used repeatedly and the abbreviation is helpful to the reader. Permissible abbreviations are listed in Units, Symbols and Abbreviations: A Guide for Biological and Medical Editors and Authors (Ed. Baron DN, 1988) published by The Royal Society of Medicine, London. Certain commonly used abbreviations, such as DNA, RNA, HIV, LD50, PCR, HBV, ECG, WBC, RBC, CT, ESR, CSF, IgG, ELISA, PBS, ATP, EDTA, mAb, can be used directly without further explanation.

**Italics**

Quantities: *t* time or temperature, *c* concentration, *A* area, *l* length, *m* mass, *V* volume.

Genotypes: *gyrA*, *arg 1*, *c myc*, *c fos*, *etc.*

Restriction enzymes: *EcoRI*, *HindI*, *BamHI*, *Kho I*, *Kpn I*, *etc.*

Biology: *H. pylori*, *E. coli*, *etc.*

**Examples for paper writing**

All types of articles' writing style and requirement will be found in the link: <http://www.wjgnet.com/esps/NavigationInfo.aspx?id=15>

**RESUBMISSION OF THE REVISED MANUSCRIPTS**

Authors must revise their manuscript carefully according to the revision policies of Baishideng Publishing Group Co., Limited. The revised version, along with the signed copyright transfer agreement,

responses to the reviewers, and English language Grade A certificate (for non-native speakers of English), should be submitted to the online system via the link contained in the e-mail sent by the editor. If you have any questions about the revision, please send e-mail to [esps@wjgnet.com](mailto:esps@wjgnet.com).

**Language evaluation**

The language of a manuscript will be graded before it is sent for revision. (1) Grade A: priority publishing; (2) Grade B: minor language polishing; (3) Grade C: a great deal of language polishing needed; and (4) Grade D: rejected. Revised articles should reach Grade A.

**Copyright assignment form**

Please download a Copyright assignment form from [http://www.wjgnet.com/2218-5836/g\\_info\\_20100724204516.htm](http://www.wjgnet.com/2218-5836/g_info_20100724204516.htm).

**Responses to reviewers**

Please revise your article according to the comments/suggestions provided by the reviewers. The format for responses to the reviewers' comments can be found at: [http://www.wjgnet.com/2218-5836/g\\_info\\_20100724204306.htm](http://www.wjgnet.com/2218-5836/g_info_20100724204306.htm).

**Proof of financial support**

For papers supported by a foundation, authors should provide a copy of the approval document and serial number of the foundation.

**STATEMENT ABOUT ANONYMOUS PUBLICATION OF THE PEER REVIEWERS' COMMENTS**

In order to increase the quality of peer review, push authors to carefully revise their manuscripts based on the peer reviewers' comments, and promote academic interactions among peer reviewers, authors and readers, we decide to anonymously publish the reviewers' comments and author's responses at the same time the manuscript is published online.

**PUBLICATION FEE**

WJO is an international, peer-reviewed, OA online journal. Articles published by this journal are distributed under the terms of the Creative Commons Attribution Non-commercial License, which permits use, distribution, and reproduction in any medium and format, provided the original work is properly cited. The use is non-commercial and is otherwise in compliance with the license. Authors of accepted articles must pay a publication fee. Publication fee: 698 USD per article. All invited articles are published free of charge.



百世登  
**Baishideng**®

Published by **Baishideng Publishing Group Co., Limited**

Flat C, 23/F., Lucky Plaza, 315-321 Lockhart Road,

Wan Chai, Hong Kong, China

Fax: +852-65557188

Telephone: +852-31779906

E-mail: [bpgoffice@wjgnet.com](mailto:bpgoffice@wjgnet.com)

<http://www.wjgnet.com>

