

World Journal of *Cardiology*

World J Cardiol 2018 July 26; 10(7): 49-61



**EDITORIAL**

- 49 Preventing pediatric cardiothoracic trauma: Role of policy and legislation
Mylonas KS, Hemmati P, Tsilimigras DI, Texakalidis P, Economopoulos KP

REVIEW

- 52 Novel approaches for the treatment of ventricular tachycardia
Spartalis M, Spartalis E, Tzatzaki E, Tsilimigras DI, Moris D, Kontogiannis C, Livanis E, Iliopoulos DC, Voudris V, Theodorakis GN

CORRECTION

- 60 Correction to "Clinical outcomes of combined flow-pressure drop measurements using newly developed diagnostic endpoint: Pressure drop coefficient in patients with coronary artery dysfunction"
Effat MA, Peelukhana SV, Banerjee RK

ABOUT COVER

Editorial Board Member of *World Journal of Cardiology*, Ibrahim Akin, FACC, MD, Professor, First Department of Medicine, University Medical Center Mannheim, University of Heidelberg, Heidelberg 69115, Germany

AIM AND SCOPE

World Journal of Cardiology (*World J Cardiol*, *WJC*, online ISSN 1949-8462, DOI: 10.4330) is a peer-reviewed open access journal that aims to guide clinical practice and improve diagnostic and therapeutic skills of clinicians.

WJC covers topics concerning arrhythmia, heart failure, vascular disease, stroke, hypertension, prevention and epidemiology, dyslipidemia and metabolic disorders, cardiac imaging, pediatrics, nursing, and health promotion. Priority publication will be given to articles concerning diagnosis and treatment of cardiology diseases. The following aspects are covered: Clinical diagnosis, laboratory diagnosis, differential diagnosis, imaging tests, pathological diagnosis, molecular biological diagnosis, immunological diagnosis, genetic diagnosis, functional diagnostics, and physical diagnosis; and comprehensive therapy, drug therapy, surgical therapy, interventional treatment, minimally invasive therapy, and robot-assisted therapy.

We encourage authors to submit their manuscripts to *WJC*. We will give priority to manuscripts that are supported by major national and international foundations and those that are of great basic and clinical significance.

INDEXING/ABSTRACTING

World Journal of Cardiology is now indexed in Emerging Sources Citation Index (Web of Science), PubMed, and PubMed Central.

EDITORS FOR THIS ISSUE

Responsible Assistant Editor: *Xiang Li*
Responsible Electronic Editor: *Wen-Wen Tan*
Proofing Editor-in-Chief: *Lian-Sheng Ma*

Responsible Science Editor: *Fang-Fang Ji*
Proofing Editorial Office Director: *Jin-Lei Wang*

NAME OF JOURNAL

World Journal of Cardiology

ISSN

ISSN 1949-8462 (online)

LAUNCH DATE

December 31, 2009

FREQUENCY

Monthly

EDITORIAL BOARD MEMBERS

All editorial board members resources online at <http://www.wjgnet.com/1949-8462/editorialboard.htm>

EDITORIAL OFFICE

Jin-Lei Wang, Director
World Journal of Cardiology
Baishideng Publishing Group Inc

7901 Stoneridge Drive, Suite 501, Pleasanton, CA 94588, USA

USA

Telephone: +1-925-2238242

Fax: +1-925-2238243

E-mail: editorialoffice@wjgnet.com

Help Desk: <http://www.f6publishing.com/helpdesk>

<http://www.wjgnet.com>

PUBLISHER

Baishideng Publishing Group Inc

7901 Stoneridge Drive, Suite 501,

Pleasanton, CA 94588, USA

Telephone: +1-925-2238242

Fax: +1-925-2238243

E-mail: bpgooffice@wjgnet.com

Help Desk: <http://www.f6publishing.com/helpdesk>

<http://www.wjgnet.com>

PUBLICATION DATE

July 26, 2018

COPYRIGHT

© 2018 Baishideng Publishing Group Inc. Articles published by this Open-Access journal are distributed under the terms of the Creative Commons Attribution Non-commercial License, which permits use, distribution, and reproduction in any medium, provided the original work is properly cited, the use is non commercial and is otherwise in compliance with the license.

SPECIAL STATEMENT

All articles published in journals owned by the Baishideng Publishing Group (BPG) represent the views and opinions of their authors, and not the views, opinions or policies of the BPG, except where otherwise explicitly indicated.

INSTRUCTIONS TO AUTHORS

<http://www.wjgnet.com/bpg/gerinfo/204>

ONLINE SUBMISSION

<http://www.f6publishing.com>

Preventing pediatric cardiothoracic trauma: Role of policy and legislation

Konstantinos S Mylonas, Pouya Hemmati, Diamantis I Tsilimigras, Pavlos Texakalidis,
Konstantinos P Economopoulos

Konstantinos S Mylonas, Pediatric Cardiology Working Group, Society of Junior Doctors, Athens 15123, Greece

Pouya Hemmati, Department of Surgery, Mayo Clinic, Rochester, MN 55902, United States

Diamantis I Tsilimigras, School of Medicine, National and Kapodistrian University of Athens, Athens 11527, Greece

Diamantis I Tsilimigras, Pavlos Texakalidis, Konstantinos P Economopoulos, Surgery Working Group, Society of Junior Doctors, Athens 15123, Greece

Pavlos Texakalidis, School of Medicine, Faculty of Health Sciences, Aristotle University of Thessaloniki, Thessaloniki 54621, Greece

Konstantinos P Economopoulos, Department of Surgery, Duke University Medical Center, Durham, NC 27710, United States

ORCID number: Konstantinos S Mylonas (0000-0002-2356-6694); Pouya Hemmati (0000-0002-6248-3744); Diamantis I Tsilimigras (0000-0002-3676-9263); Pavlos Texakalidis (0000-0002-8715-6651); Konstantinos P Economopoulos (0000-0003-4856-0405).

Author contributions: Mylonas KS, Hemmati P, Tsilimigras DI, Texakalidis P and Economopoulos KP designed the study; Mylonas KS, Tsilimigras DI and Texakalidis P collected the data; Mylonas KS drafted the manuscript; Mylonas KS, Hemmati P, Tsilimigras DI, Texakalidis P and Economopoulos KP critically revised the manuscript; Economopoulos KP supervised this study.

Conflict-of-interest statement: The authors declare no potential conflicts of interest with respect to the research, authorship, and/or publication of this article.

Open-Access: This article is an open-access article which was selected by an in-house editor and fully peer-reviewed by external reviewers. It is distributed in accordance with the Creative Commons Attribution Non Commercial (CC BY-NC 4.0) license, which permits others to distribute, remix, adapt, build upon this work non-commercially, and license their derivative works on

different terms, provided the original work is properly cited and the use is non-commercial. See: <http://creativecommons.org/licenses/by-nc/4.0/>

Manuscript source: Invited Manuscript

Correspondence to: Konstantinos S Mylonas, MD, Post-doctoral Fellow, Pediatric Cardiology Working Group, Society of Junior Doctors, Menalou 5, Athens 15123, Greece. ksmylonas@gmail.com
Telephone: +30-69-76948121

Received: May 12, 2018

Peer-review started: May 12, 2018

First decision: June 6, 2018

Revised: June 11, 2018

Accepted: June 27, 2018

Article in press: June 27, 2018

Published online: July 26, 2018

Abstract

Data from the last 50 years suggest that pediatric patients typically suffer cardiothoracic injuries following blunt traumatic force (70%) in the setting of either motor vehicle crashes (53.5%) or vehicle-pedestrian accidents (18.2%). Penetrating trauma accounts for 30% of pediatric cardiothoracic injuries, half of which are gunshot wounds. Graduated driver licensing programs, gun-control legislation, off-road vehicle regulation, initiatives such as "Prevent the Bleed", as well as professional society recommendations are key in preventing pediatric cardiothoracic injuries.

Key words: Pediatric trauma; Blunt cardiac trauma; Penetrating cardiac trauma; Injury; Children; Policy; Legislation

© The Author(s) 2018. Published by Baishideng Publishing

Group Inc. All rights reserved.

Core tip: Graduated driver licensing programs, gun-control legislation, off-road vehicle regulation, initiatives such as “Prevent the Bleed”, as well as professional society recommendations are key in preventing pediatric cardiothoracic injuries.

Mylonas KS, Hemmati P, Tsilimigras DI, Texakalidis P, Economopoulos KP. Preventing pediatric cardiothoracic trauma: Role of policy and legislation. *World J Cardiol* 2018; 10(7): 49-51 Available from: URL: <http://www.wjgnet.com/1949-8462/full/v10/i7/49.htm> DOI: <http://dx.doi.org/10.4330/wjc.v10.i7.49>

INTRODUCTION

Trauma is a leading cause of pediatric mortality in the developed world and can have substantial physical and psychological sequelae in surviving victims^[1]. Cardiothoracic injury is the second most commonly reported trauma-associated cause of fatality after head trauma^[2,3]. Although isolated cardiothoracic injury is typically non-lethal, mortality rates can be as high as 20%-40% in multi-system trauma patients^[4]. Our group recently analyzed epidemiological and outcomes data on a total of 1062 pediatric cardiac trauma patients that were treated at United States centers in the last 50 years^[5]. In this editorial, we explore various policy interventions directed at reducing the incidence, morbidity, and mortality of cardiothoracic trauma in children.

Pediatric patients typically suffer cardiothoracic injuries following blunt traumatic force (70%) in the setting of either motor vehicle crashes (MVCs) (53.5%) or vehicle-pedestrian accidents (18.2%)^[5,6]. A National Trauma Data Bank analysis revealed that teenagers are at a higher risk of suffering blunt cardiothoracic injury^[7], at least partly due to sociobehavioral factors. In several states, teenagers can get a learner's permit before age 16 and a driver's license by age 16. Also, a number of risk factors predisposing to MVCs, such as reckless driving, cell phone use while driving, and driving while intoxicated (DWI) are frequently seen amongst adolescents^[8-10].

Therefore, preventing MVCs is essential in diminishing pediatric cardiothoracic trauma rates. Graduated driver licensing (GDL) has been legislated in an effort to reduce MVC rates and is predicated on the concept of slowly and safely exposing young drivers to higher-risk driving conditions^[11,12]. Traditionally GDL programs begin with restricted to supervised driving, followed by unsupervised driving under settings that involve intermediate risk, and ultimately lead to full licensure^[12]. According to data from the Fatality Analysis Reporting System, National Automotive Sampling System General Estimates System, Census Bureau, and National Household Travel Surveys, per capita fatal and police-

reported MVC rates in 2012 were higher for middle-aged drivers than for adolescent over 16 years old. Fatal DWIs also decreased for teenagers after introducing GDL programs^[13]. In addition, implementing school-based pedestrian safety intervention programs has been shown to reduce the incidence of pediatric pedestrian collisions^[14,15].

Off-road vehicles (ORVs) have also been associated with pediatric cardiothoracic trauma among various other types of injury^[16-18]. The Eastern Association for the Surgery of Trauma supports the enactment and implementation of legislature as a way of reducing ORV-related injuries^[17]. A landmark act regulating the use of ORVs was “Sean's Law” which amended Massachusetts General Laws Chapter 90b (Sections 21-35). After the enforcement of “Sean's Law”, the rate of emergency department discharges in Massachusetts declined by over 30% in children under the age of 10, 50% in 10- to 13-year-old, and nearly 40% in 14- to 17-year-old^[16].

Our recent analysis also suggests that penetrating trauma accounts for 30% of pediatric cardiothoracic injuries, half of which are gunshot wounds (GSWs)^[5]. Of note, in recent years, GSW-related mortality rates in United States adolescents exceeded deaths from MVCs^[19]. In an attempt to reduce firearm injuries in children, both the American Academy of Pediatrics (AAP) and the American Pediatric Surgical Association support firearm-control legislation^[20,21]. The AAP also endorses all efforts to identify adolescents at high risk for becoming GSW victims, including those with a history of family or peer violence, substance abuse, depression, previous suicide attempts, or carrying of weapons^[20]. Child health care professionals are encouraged to engage in discussions with parents regarding making a gun-safe environment at home by either implementing safe storage techniques (ammunition and firearm stored separately and locked) or by removing firearms from the family's house altogether^[20,22]. Similarly, the American College of Surgeons (ACS) Committee on Trauma advocates towards firearm safety features such as proof locks and “smart gun” technology^[23].

CONCLUSION

Data from the last 50 years suggest that, in the United States, the vast majority of pediatric cardiothoracic injuries occur due to MVCs and GSWs^[5]. Although public education programs such as the ACS's “Stop the Bleed” (teaching bystanders how to respond to life-threatening arterial hemorrhage) will save lives after traumatic wounds, we feel that advocating for methods that would prevent these injuries in the first place is equally, if not more, important^[24]. Gun-control and ORV legislation, GDL programs, initiatives such as “Prevent the Bleed”, as well as professional society recommendations are applicable in pediatric cardiothoracic trauma and can prevent these injuries^[25].

REFERENCES

- 1 **Guice KS**, Cassidy LD, Oldham KT. Traumatic injury and children: a national assessment. *J Trauma* 2007; **63**: S68-S80; discussion S81-86 [PMID: 18091214 DOI: 10.1097/TA.0b013e31815aebb6]
- 2 **Gross BW**, Edavettal MM, Cook AD, Rinehart CD, Lynch CA, Bradburn EH, Wu D, Rogers FB. Big children or little adults? A statewide analysis of adolescent isolated severe traumatic brain injury outcomes at pediatric versus adult trauma centers. *J Trauma Acute Care Surg* 2017; **82**: 368-373 [PMID: 27805998 DOI: 10.1097/TA.0000000000001291]
- 3 **Cooper A**, Barlow B, DiScala C, String D. Mortality and truncl injury: the pediatric perspective. *J Pediatr Surg* 1994; **29**: 33-38 [PMID: 8120758 DOI: 10.1016/0022-3468(94)90518-5]
- 4 **Hannan EL**, Farrell LS, Meaker PS, Cooper A. Predicting inpatient mortality for pediatric trauma patients with blunt injuries: a better alternative. *J Pediatr Surg* 2000; **35**: 155-159 [PMID: 10693657 DOI: 10.1016/S0022-3468(00)90001-0]
- 5 **Mylonas KS**, Tsilimigras DI, Texakalidis P, Hemmati P, Schizas D, Economopoulos KP. Pediatric Cardiac Trauma in the United States: A Systematic Review. *World J Pediatr Congenit Heart Surg* 2018; **9**: 214-223 [PMID: 29544413 DOI: 10.1177/2150135117747488]
- 6 **Pearson EG**, Fitzgerald CA, Santore MT. Pediatric thoracic trauma: Current trends. *Semin Pediatr Surg* 2017; **26**: 36-42 [PMID: 28302283 DOI: 10.1053/j.sempedsurg.2017.01.007]
- 7 **Kaptein YE**, Talving P, Konstantinidis A, Lam L, Inaba K, Plurad D, Demetriades D. Epidemiology of pediatric cardiac injuries: a National Trauma Data Bank analysis. *J Pediatr Surg* 2011; **46**: 1564-1571 [PMID: 21843725 DOI: 10.1016/j.jpedsurg.2011.02.041]
- 8 **Scott-Parker B**, Oviedo-Trespalacios O. Young driver risky behaviour and predictors of crash risk in Australia, New Zealand and Colombia: Same but different? *Accid Anal Prev* 2017; **99**: 30-38 [PMID: 27865138 DOI: 10.1016/j.aap.2016.11.001]
- 9 **Scott-Parker B**, Watson B, King MJ, Hyde MK. "I drove after drinking alcohol" and other risky driving behaviours reported by young novice drivers. *Accid Anal Prev* 2014; **70**: 65-73 [PMID: 24698806 DOI: 10.1016/j.aap.2014.03.002]
- 10 **Atchley P**, Strayer DL. Small Screen Use and Driving Safety. *Pediatrics* 2017; **140**: S107-S111 [PMID: 29093043 DOI: 10.1542/peds.2016-1758M]
- 11 **DePesa C**, Raybould T, Hurwitz S, Lee J, Gervasini A, Velmahos GC, Masiakos PT, Kaafarani HMA. The impact of the 2007 graduated driver licensing law in Massachusetts on the rate of citations and licensing in teenage drivers. *J Safety Res* 2017; **61**: 199-204 [PMID: 28454865 DOI: 10.1016/j.jsr.2017.02.012]
- 12 **Russell KF**, Vandermeer B, Hartling L. Graduated driver licensing for reducing motor vehicle crashes among young drivers. *Cochrane Database Syst Rev* 2011; CD003300 [PMID: 21975738 DOI: 10.1002/14651858.CD003300.pub3]
- 13 **McCartt AT**, Teoh ER. Tracking progress in teenage driver crash risk in the United States since the advent of graduated driver licensing programs. *J Safety Res* 2015; **53**: 1-9 [PMID: 25933991 DOI: 10.1016/j.jsr.2015.01.001]
- 14 **Nauta J**, van Mechelen W, Otten RH, Verhagen EA. A systematic review on the effectiveness of school and community-based injury prevention programmes on risk behaviour and injury risk in 8-12 year old children. *J Sci Med Sport* 2014; **17**: 165-172 [PMID: 23962868 DOI: 10.1016/j.jsams.2013.07.011]
- 15 **Hotz G**, de Marcilla AG, Lutfi K, Kennedy A, Castellon P, Duncan R. The WalkSafe Program: developing and evaluating the educational component. *J Trauma* 2009; **66**: S3-S9 [PMID: 19276724 DOI: 10.1097/TA.0b013e3181937f62]
- 16 **Flaherty MR**, Raybould T, Kelleher CM, Seethala R, Lee J, Kaafarani HMA, Masiakos PT. Age Legislation and Off-Road Vehicle Injuries in Children. *Pediatrics* 2017; **140**: pii: e20171164 [PMID: 28893850 DOI: 10.1542/peds.2017-1164]
- 17 **Rattan R**, Joseph DK, Dente CJ, Klein EN, Kimbrough MK, Nguyen J, Simmons JD, O'Keeffe T, Crandall M. Prevention of all-terrain vehicle injuries: A systematic review from The Eastern Association for the Surgery of Trauma. *J Trauma Acute Care Surg* 2018; **84**: 1017-1026 [PMID: 29389840 DOI: 10.1097/TA.0000000000001828]
- 18 **Akinpelu BJ**, Zuckerman SL, Gannon SR, Westrick A, Shannon C, Naftel RP. Pediatric isolated thoracic and/or lumbar transverse and spinous process fractures. *J Neurosurg Pediatr* 2016; **17**: 639-644 [PMID: 26894517 DOI: 10.3171/2015.10.PEDS15377]
- 19 **Fowler KA**, Dahlberg LL, Haileyesus T, Annett JL. Firearm injuries in the United States. *Prev Med* 2015; **79**: 5-14 [PMID: 26116133 DOI: 10.1016/j.ypmed.2015.06.002]
- 20 **Olson LM**, Christoffel KK, O'Connor KG. Pediatricians' involvement in gun injury prevention. *Inj Prev* 2007; **13**: 99-104 [PMID: 17446249 DOI: 10.1136/ip.2006.012401]
- 21 **Nance ML**, Krummel TM, Oldham KT; Trauma Committee of American Pediatric Surgical Association. Firearm injuries and children: a policy statement of the American Pediatric Surgical Association. *J Am Coll Surg* 2013; **217**: 940-946 [PMID: 24045138 DOI: 10.1016/j.jamcollsurg.2013.07.381]
- 22 **Firearm-related injuries affecting the pediatric population.** Committee on Injury and Poison Prevention. American Academy of Pediatrics. *Pediatrics* 2000; **105**: 888-895 [PMID: 10742344 DOI: 10.1542/peds.105.4.888]
- 23 **Kuhls DA**, Campbell BT, Burke PA, Allee L, Hink A, Letton RW, Masiakos PT, Coburn M, Alvi M, Lerer TJ, Gaines BA, Nance ML, Schuerer DJE, Palmieri TL, Davis JW, Geehan DM, Elsey JK, Sutton BH, McAndrew MP, Gross RI, Reed DN Jr, Van Boerum DH, Esposito TJ, Albrecht RM, Sarani B, Shapiro DS, Wiggins-Dohlvik K, Stewart RM; American College of Surgeons Committee on Trauma. Survey of American College of Surgeons Committee on trauma members on firearm injury: Consensus and opportunities. *J Trauma Acute Care Surg* 2017; **82**: 877-886 [PMID: 28240673 DOI: 10.1097/TA.0000000000001405]
- 24 **Masiakos PT**, Warshaw AL. Stopping the Bleeding Is Not Enough. *Ann Surg* 2017; **265**: 37-38 [PMID: 27611613 DOI: 10.1097/SLA.0000000000001969]
- 25 **Maa J**, Masiakos PT, Elsey JK, Warshaw AL. Prevent the Bleed: How Surgeons Can Lead the National Conversation About Firearm Safety Forward. *Ann Surg* 2018; **267**: 428-429 [PMID: 29252222 DOI: 10.1097/sla.0000000000002638]

P- Reviewer: Lin JA, Rigatelli G, Xavier-Elsas P **S- Editor:** Cui LJ

L- Editor: A **E- Editor:** Tan WW



Novel approaches for the treatment of ventricular tachycardia

Michael Spartalis, Eleftherios Spartalis, Eleni Tzatzaki, Diamantis I Tsilimigras, Demetrios Moris, Christos Kontogiannis, Efthimios Livanis, Dimitrios C Iliopoulos, Vassilis Voudris, George N Theodorakis

Michael Spartalis, ESC Working Group on Cardiac Cellular Electrophysiology, Sophia Antipolis Cedex 06903, France

Michael Spartalis, Eleni Tzatzaki, Efthimios Livanis, Vassilis Voudris, George N Theodorakis, Division of Cardiology, Onassis Cardiac Surgery Center, Athens 17674, Greece

Eleftherios Spartalis, Diamantis I Tsilimigras, Dimitrios C Iliopoulos, Laboratory of Experimental Surgery and Surgical Research, University of Athens Medical School, Athens 11527, Greece

Demetrios Moris, Department of Surgery, Duke University, Durham, NC 27710, United States

Christos Kontogiannis, Department of Clinical Therapeutics, "Alexandra" Hospital, University of Athens, Athens 11528, Greece

ORCID number: Michael Spartalis (0000-0002-7442-838X); Eleftherios Spartalis (0000-0003-4451-8074); Eleni Tzatzaki (0000-0002-6370-4713); Diamantis I Tsilimigras (0000-0002-3676-9263); Demetrios Moris (0000-0002-5276-0699); Christos Kontogiannis (0000-0002-1967-2654); Efthimios Livanis (0000-0001-7971-1339); Dimitrios C Iliopoulos (0000-0003-2780-2372); Vassilis Voudris (0000-0002-3296-3640); George N Theodorakis (0000-0002-7923-0540).

Author contributions: All authors equally contributed to this paper with conception and design of the study, literature review and analysis, drafting and critical revision and editing, and final approval of the final version.

Conflict-of-interest statement: No potential conflicts of interest. No financial support.

Open-Access: This article is an open-access article which was selected by an in-house editor and fully peer-reviewed by external reviewers. It is distributed in accordance with the Creative Commons Attribution Non Commercial (CC BY-NC 4.0) license, which permits others to distribute, remix, adapt, build upon this work non-commercially, and license their derivative works on different terms, provided the original work is properly cited and the use is non-commercial. See: <http://creativecommons.org/licenses/by-nc/4.0/>

licenses/by-nc/4.0/

Manuscript source: Invited manuscript

Correspondence to: Michael Spartalis, MD, MSc, PhD, Academic Research, Doctor, Research Fellow, Division of Cardiology, Onassis Cardiac Surgery Center, 356 Syggrou Ave, Athens 17674, Greece. msparta@med.uoa.gr
Telephone: +30-210-9493000
Fax: +30-210-9493000

Received: February 18, 2018

Peer-review started: February 19, 2018

First decision: March 9, 2018

Revised: March 24, 2018

Accepted: June 25, 2018

Article in press: June 27, 2018

Published online: July 26, 2017

Abstract

Ventricular tachycardia (VT) is a crucial cause of sudden cardiac death (SCD) and a primary cause of mortality and morbidity in patients with structural cardiac disease. VT includes clinical disorders varying from benign to life-threatening. Most life-threatening episodes are correlated with coronary artery disease, but the risk of SCD varies in certain populations, with various underlying heart conditions, specific family history, and genetic variants. The targets of VT management are symptom alleviation, improved quality of life, reduced implantable cardioverter defibrillator shocks, prevention of reduction of left ventricular function, reduced risk of SCD, and improved overall survival. Antiarrhythmic drug therapy and endocardial catheter ablation remains the cornerstone of guideline-endorsed VT treatment strategies in patients with structural cardiac abnormalities. Novel strategies such as epicardial ablation, surgical cryoablation, transcatheter alcohol ablation, pre-procedural imaging, and stereotactic ablative radiotherapy are an appealing area of res-

earch. In this review, we gathered all recent advances in innovative therapies as well as experimental evidence focusing on different aspects of VT treatment that could be significant for future favorable clinical applications.

Key words: Ventricular tachycardia; Catheter ablation; Epicardial; Sudden cardiac death; Novel techniques; Substrate

© **The Author(s) 2018.** Published by Baishideng Publishing Group Inc. All rights reserved.

Core tip: Antiarrhythmic drug therapy and endocardial catheter ablation remains the cornerstone of ventricular tachycardia (VT) treatment management, but both treatments have limited efficacy and important adverse effects. Catheter ablation for cardiomyopathic (scar-related) VT is associated with recurrence rates as high as 50% at 6 mo. Implantable cardioverter defibrillator provides a safety net; however, there is an increased need for more effective and safer methods to decrease VT recurrence episodes. We sought to review current literature in order to summarize data on innovative techniques for VT treatment.

Spartalis M, Spartalis E, Tzatzaki E, Tsilimigras DI, Moris D, Kontogiannis C, Livanis E, Iliopoulos DC, Voudris V, Theodorakis GN. Novel approaches for the treatment of ventricular tachycardia. *World J Cardiol* 2018; 10(7): 52-59 Available from: URL: <http://www.wjgnet.com/1949-8462/full/v10/i7/52.htm> DOI: <http://dx.doi.org/10.4330/wjc.v10.i7.52>

INTRODUCTION

Sudden cardiac death (SCD) is a vital public health issue, accountable for almost 50% of all cardiovascular deaths^[1]. In the last three decades, SCD was the leading cause for almost 230000 to 350000 deaths per annum in the United States^[1]. Ventricular arrhythmias account for 25% to 36% of witnessed sudden cardiac arrests (SCA) at home and 38% to 79% of witnessed SCA in public^[2].

Ischemic heart disease, structural disorders, various forms of cardiomyopathy associated with myocardial fibrosis, cardiac channelopathies, myocarditis, congenital heart diseases, and other genetic rare disorders are associated with ventricular arrhythmias^[1].

Even though treatment for heart failure lowers mortality and SCD, it was unsuccessful in lessening ventricular tachycardia (VT) recurrences^[3]. Implantable cardioverter defibrillators (ICD) are very effective in eliminating VT episodes and in lowering the possibility of SCD, but they are not useful for arrhythmia prevention^[4]. When the VT substrate manifests, anti-arrhythmic drug treatment or catheter ablation are the current choices to reduce VT episodes^[5]. Catheter ablation and antiarrhythmic drug therapy though, are also limited

by incomplete efficacy, unfavorable side effects, and procedural risk^[5]. In this review, we outline the current advances in VT treatment options and describe the imaging modalities, progress, and novel strategies.

LITERATURE SEARCH

We have collected all experimental and clinical investigations focused on new aspects that could be essential for tailoring VT therapy according to underlying etiology, in order to achieve higher efficacy. The MEDLINE database was screened for studies with the medical term "ventricular tachycardia" and keywords "treatment", or "ablation", or "management". We restricted our search to English literature.

NOVEL VT THERAPIES

Epicardial catheter ablation

Endocardial catheter ablation and antiarrhythmic drug treatment are currently the mainstays of VT treatment^[1,3]. However, the procedural success rates of VT are quite variable due to the heterogeneous substrates that reflect the variety of pathophysiological processes^[6,7]. The success rate of endocardial ablation in patients with outflow tract VT is 84%, in patients with papillary muscle VT is 60%, and in patients with idiopathic left ventricular VT is 70%^[6]. Moreover, the VT recurrence rates of endocardial ablation in ischemic cardiomyopathy patients are between 23% and 49% and in dilated cardiomyopathy patients between 46% and 61%^[7]. Non-ischemic cardiomyopathy patients have worse outcomes than ischemic cardiomyopathy patients due to scar patterns with epicardial and intramural sites^[7].

Epicardial ablation has emerged as a potential alternative ablation strategy in order to increase the success rate in complex substrates and to eliminate VT in patients with different cardiomyopathies and more recently in patients with Brugada syndrome^[8-11]. Percutaneous approach to the pericardial area facilitates epicardial ablation when the VT substrate is situated in the subepicardium^[8] (Figure 1). Adjacency to coronary circulation and the phrenic nerve may hinder the procedure in certain situations^[9]. In patients with previous heart surgery or previous epicardial ablation attempts, percutaneous access may not be possible and as such, video-assisted thoracoscopy may be a good and minimally invasive alternative to open surgery^[12].

Epicardial ablation is a safe procedure with low complication rates^[13]. Pericardial effusion is the most common complication^[13]. Damage to subdiaphragmatic organs and hemorrhage from diaphragmatic vessels have also been reported^[13].

Della Bella *et al*^[14] evaluated the possible benefit of endo-epicardial catheter ablation for the management of VT in 528 patients with any form of structural cardiac disorder (Figure 2). Endo-epicardial catheter ablation resulted in a VT recurrence rate of 34.1%, in comparison

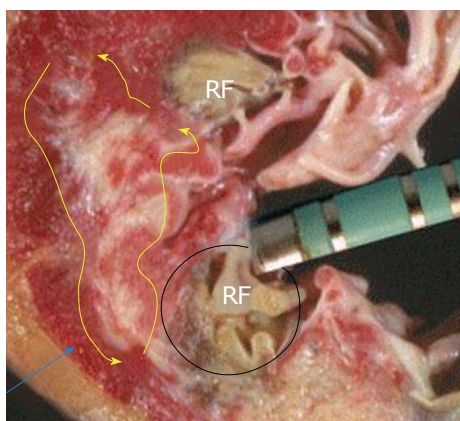


Figure 1 Arrhythmia substrate is deep (blue arrow), but the radiofrequency ablation lesions are not that deep. RF: Radiofrequency.

to a rate of up to 50% with the standard endocardial approach^[14].

Intramyocardial infusion-needle catheter ablation

Transcoronary alcohol ablation has emerged to approach deep intramyocardial substrate in patients not amenable to endo-epicardial catheter ablation (mechanical valve, thrombus, significant comorbidities)^[15,16]. Transcoronary alcohol ablation requires the injected dose of sterile pure ethanol with proximal balloon expansion to a culprit vessel with a target of abolishing perfusion^[15,16] (Figure 3). This method can prevent recurrent VT, VT storm and can control incessant VT^[15,16]. The exact recognition of the target vessel and the existence of collaterals may hinder the adoption of the method^[15-17].

Kim *et al.*^[15] introduced the novel use of cardioplegia as a mapping technique in order to identify the critical VT isthmus to facilitate effective transcoronary ethanol ablation and avoid irreversible myocardial injury. Furthermore, Sapp *et al.*^[17] showed that intramyocardial needle mapping and ablation with saline infusion could create deep injuries and is a practical and efficient method. Intracoronary wire mapping and coil embolization have also been utilized just as alcohol ablation to target VT arising from intraventricular septum^[18]. After intracoronary wire mapping and recognition of a culprit vessel, coils are directed to embolize the branch, eliminating the desired target perfusion^[18].

Bipolar ablation

Bipolar ablation between two ablation catheters located on either position of the septum from both ventricles improves lesion transmurally because it depends less on catheter contact and alignment^[19,20] (Figure 4). Bipolar ablation has the theoretical benefit of producing more powerful energy and providing deeper lesions, in comparison to two separate unipolar catheters^[19,20]. Sakamoto *et al.*^[20] recently successfully eliminated the critical VT circuit in a patient with an arrhythmogenic substrate (cardiac sarcoidosis), utilizing bipolar ablation.

Cardiac sympathetic denervation

Accumulated evidence strongly suggests a role of sympathetic neuromodulation in controlling refractory VT^[19-24]. Cardiac sympathetic denervation surgery has been proven to be useful for the management of congenital long QT syndrome and catecholaminergic polymorphic VT^[21]. The procedure requires extraction of the lower fraction of the stellate ganglion and T2-T4 sympathetic thoracic ganglia^[21]. Complications regarding the procedure were infrequent, with 4% developing acute ptosis or Horner syndrome^[21]. Vaseghi *et al.*^[21] showed that cardiac sympathetic denervation has greater shock free survival as well as a considerable decline in shock burden in patients with recurrent VT or VT storm, regardless of antiarrhythmic drug therapy and catheter ablation. In addition, bilateral cardiac sympathetic denervation appeared to be more efficacious than left-sided denervation^[21,22].

Augmented sympathetic activity leads to early and delayed afterdepolarization, enhances diffuse repolarization, leading to ventricular electrical susceptibility and increases the possibility of malignant VT^[23]. Stellate ganglionectomy lengthens the ventricular refractory period and raises the VF threshold, decreasing VT or VF inducibility in the context of myocardial infarction^[23,24]. Locally invasive sympathetic ganglion block could select individuals with greater possibilities of long-term clinical benefits prior to sympathetic denervation^[23,24].

Renal sympathetic denervation

Enhanced sympathetic tone shortens the ventricular effective refractory period, enhances automaticity, and lowers the threshold for ventricular arrhythmias^[25-27]. Feyz *et al.*^[25] performed bilateral renal denervation in a patient with polymorphic VT with excellent results. Aksu *et al.*^[27] also showed that catheter-based renal denervation was successful in a patient with an electrical storm due to catecholaminergic polymorphic VT. However, the microanatomy of human renal vessels has great variability. Accessory renal vessels that bifurcated early can also influence the result negatively, and there is still the absence of procedural endpoint during the technique^[26].

As a result, renal sympathetic denervation is not currently recognized as an ideal or approved VT treatment method^[25-27]. However, certain ventricular arrhythmias do not terminate after catheter ablation, thus making renal sympathetic denervation a possible option for patients in whom other ablative approaches were ineffective^[25,27].

Stereotactic radioablative therapies

Despite catheter-oriented ablation, which applies radiofrequency or freezing to damage tissues, radiotherapy is based on photons from X-rays or gamma rays to injure the desired target, mainly cancer. Through novel distribution methods such as intensity-modulated radiotherapy, a dosage of radiotherapy can be precisely and accurately directed to the desired site, while diminishing

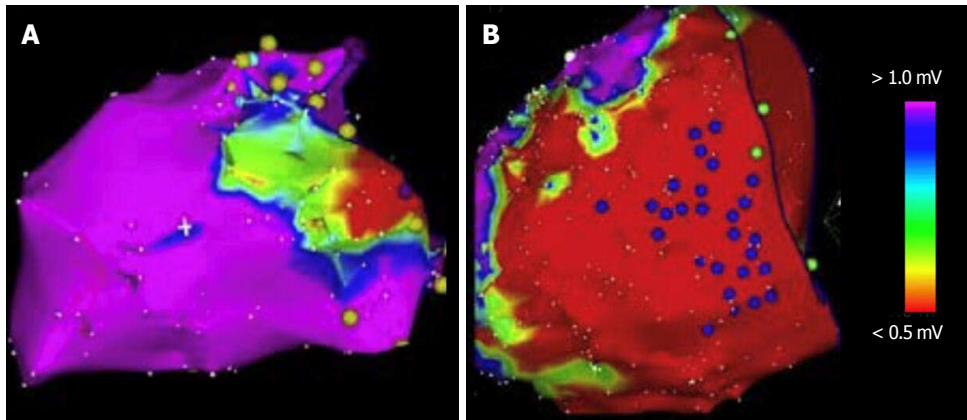


Figure 2 Endocardial and epicardial voltage mapping. A: The voltage map of the endocardium shows an area of scar. The map is color-coded to represent bipolar electro-gram voltage (red: Dense scar, 0.5 mV; purple: Normal tissue, 1.5 mV, intervening colors represent voltage values in between); B: The voltage map of the epicardium shows a larger area of scar.

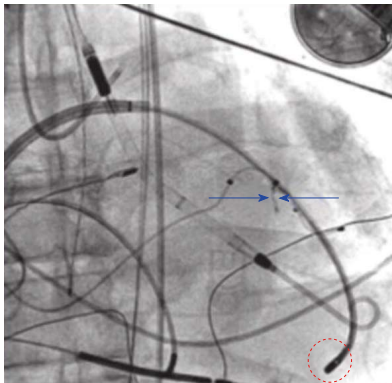


Figure 3 Transcoronary alcohol ablation. Coronary angiography of the left anterior descending artery shows a septal perforator with a course to the site of earliest activity. A balloon catheter occludes this branch and ethanol is infused (blue arrows). The ablation catheter is placed at the region of earliest activity (red circle).

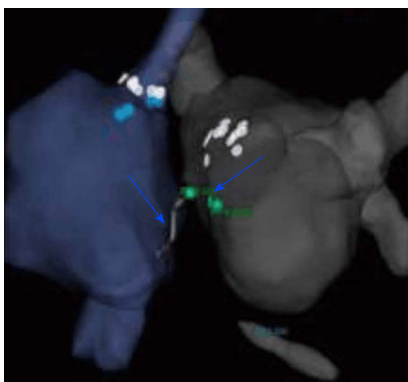


Figure 4 Bipolar ablation. Bipolar radiofrequency ablation between the right and left ventricular septum using two catheters.

dosage to adjoining healthy tissues^[28,29].

Ablative radiotherapy is generally a noninvasive, outpatient method, which does not involve anesthesia^[28,29]. Potential risks consist of damage to tissue next to the ablated site, such as brain edema for intracranial les-

ions, pneumonitis for chest therapies, myelopathy for spinal carcinomas, or bowel perforation for abdominal locations^[28,29]. In comparison to radiofrequency or cryoenergy, the damage from ablative radiotherapy progresses over days to months, needing time for the total tissue damage to be shown^[28,29].

The first patient was treated on a robotic radiosurgery system (CyberKnife®, Accuray, Sunnyvale, CA, United States) in 2012^[28]. The follow-up revealed no definite acute or late adverse effects, and a seven-month reduction burden in VT on standard antiarrhythmic drug therapy, suggesting a potential transient benefit of this method^[28].

Cuculich *et al.*^[29] investigated five patients with increased-risk, refractory VT. The authors focused on arrhythmogenic scar sites by merging anatomical imaging with noninvasive electrocardiographic imaging during VT that was produced using an ICD^[29]. Patients were treated with a single dose of 25 Gy while awake, using a noninvasive distribution of accurate ablative radiation with stereotactic body radiation treatment^[29]. Cuculich *et al.*^[29] reported a reduction in events of VT in all five patients.

Cryoablation

Catheter radiofrequency ablation of VT originating from the left ventricle's papillary muscles has been linked to conflicting outcomes^[30,31]. Rivera *et al.*^[31] investigated twenty-one patients with drug-refractory VT, who underwent catheter cryoablation or radiofrequency ablation. Cryoablation was correlated with greater success rates and smaller recurrence rates than radiofrequency procedures, superior catheter support, and smaller frequency of polymorphic arrhythmias^[31]. Marai *et al.*^[30] recently used cryoablation guided by intracardiac echocardiography, 3-dimensional mapping system, and image integration to treat a patient with refractory VT originating from papillary muscle with excellent results.

Surgical therapy for VT

Catheter ablation provides efficient outcomes for su-

stained monomorphic VT, but certain situations, such as the existence of mural thrombus and heavy calcification, can lead to adverse results^[32,33]. Higuchi *et al.*^[33] successfully treated a 67-year-old patient with sustained monomorphic VT due to ventricular scar and resistant to endocardial radiofrequency ablation, by left ventricular reconstruction with cryoablation. Li *et al.*^[34] conducted a retrospective investigation of 38 consecutive surgical epicardial VT ablation procedures and compared the results with those of a propensity-matched percutaneous epicardial access control group. Surgical epicardial access after heart surgery for VT ablation showed no statistical difference in long-term results in comparison to the percutaneous epicardial group^[34].

Recently, Berte *et al.*^[35] presented the first animal survey utilizing a more potent cryoablation system that can generate larger, transmural ventricular lesions from both the endocardium and the epicardium. Surgical cryoablation in sheep had no acute macroscopic vascular or extracardiac damage and resulted in 100% successful lesions at necropsy^[35].

In some patients with non-ischemic cardiomyopathy and VT refractory to standard therapy or undergoing cardiac surgery, surgical ablation may be an alternative option for potentially reducing the burden of ICD shocks during long-term follow-up^[36]. Liang *et al.*^[36] showed that detailed arrhythmogenic substrate in the electrophysiology lab before surgery, in conjunction with a direct scar and radiofrequency ablation lesions visualization in the operating room, is crucial for guiding surgical ablation.

Extracorporeal life support for refractory VT

Extracorporeal life support is a highly efficient bridging treatment in patients with refractory VT associated with cardiogenic shock^[37]. Extracorporeal life support allows the usage of negative inotropic antiarrhythmic drug therapy, leads to the weaning of catecholamine delivery, thus resolving the dangerous period of the catecholamine driven electrical storm^[37]. The utilization of extracorporeal life support maintains hemodynamic support during an ablation procedure, while mapping and induction of VT are commenced and provides sufficient vital organ perfusion in patients with refractory VT^[37]. Current literature suggests the usage of extracorporeal life support, as it has proven to be a safe, practical and efficient therapeutic solution when traditional treatments have failed^[37].

Steroid pulse therapy

Okabe *et al.*^[38] successfully treated a patient with cardiac sarcoidosis associated with VT using steroid pulse therapy.

Gene therapy

Catecholaminergic polymorphic VT (CPVT) is a rare cardiac ion channelopathy induced by anomalies in proteins that regulate Ca²⁺ transport in heart cells that can lead

to SCD^[39,40]. CPVT is associated with mutations in the gene encoding the cardiac RyR2, a cardiac ryanodine receptor protein which is involved in calcium homeostasis and mutations in the gene that encodes calsequestrin (CASQ2), a protein that interacts with RyR2^[39-41].

Denegri *et al.*^[42] showed that viral gene transfer of wild-type CASQ2 into the heart of mice prevented and reverted severe manifestations of CPVT. Furthermore, Lodola *et al.*^[43] infected induced pluripotent stem cells with an adeno-associated viral vector serotype 9 (AAV9) encoding the human CASQ2 gene and noticed a significant decline in the percentage of delayed afterdepolarizations. Li *et al.*^[44] used tetracaine, a local anesthetic drug with known RyR2 inhibiting action, in mice and showed that the drug efficiently halted the induction of VT in a mouse model of CPVT.

INNOVATIVE MODALITIES FOR VT AND FUTURE CLINICAL APPLICATIONS

Endo-epicardial ablation reduces VT recurrences, but not all patients have a VT substrate^[45]. Contrast-enhanced magnetic resonance imaging (ceMRI) is utilized to identify VT substrate after myocardial infarction^[45]. Arana *et al.*^[45] showed that ceMRI-based endo-epicardial signal intensity mapping in a porcine model allowed characterization of the epicardial VT substrate.

Klein *et al.*^[46] used 3D meta-iodobenzylguanidine (MIBG) imaging to guide VT ablation. MIBG innervation defects are greater than scars produced from bipolar voltage maps, and the investigation showed that 36% of successful ablative locations were situated in sections of irregular innervation and normal voltage, suggesting that innervation maps may identify additional VT ablation sites^[46].

Zhang *et al.*^[47] investigated non-invasive high-resolution mapping and electrocardiographic imaging to provide epicardial substrate information. Electrocardiographic imaging identified scar electrophysiologic substrates in ischemic cardiomyopathy patients^[47].

Cardiac ripple mapping for slow conducting channels is an innovative technique to integrate voltage and activation mapping^[48,49]. Cardiac ripple mapping allows the concurrent vision of voltage and activation data and facilitates recognition of slow conduction channels within scar areas in the myocardium that could be probable VT ablation sites^[48,49]. Table 1 summarizes the studies investigating novel approaches for the treatment of VT.

CONCLUSION

The management of patients with VT can be demanding. ICD implant led to a considerable difference in the survival of subjects with VT, but the estimate of subjects with recurrent ICD shocks is still a growing issue. Antiarrhythmic drug treatment has reduced effectiveness and is correlated with serious adverse effects. Catheter ablation remains the cornerstone in

Table 1 Summary of studies investigating novel approaches for the treatment of ventricular tachycardia

| Ref. | Type of study | No. of subjects | Focus of study | Complications |
|---|---------------|-----------------|---|--|
| Della Bella <i>et al</i> ^[14] | Clinical | 528 | Endo-epicardial Ablation | Pericardial effusion, tamponade |
| Kim <i>et al</i> ^[15] | Clinical | 1 | Cardioplegia/Transcoronary alcohol ablation | Atrioventricular block, extensive myocardial damage, perforation |
| Sapp <i>et al</i> ^[17] | Clinical | 8 | Intramyocardial infusion-needle catheter ablation | Atrioventricular block, perforation, tamponade |
| Tholakanahalli <i>et al</i> ^[18] | Clinical | 2 | Intracoronary wire mapping and coil embolization | Atrioventricular block, coronary injury, embolization of unintended branches |
| Vaseghi <i>et al</i> ^[21] | Clinical | 121 | Cardiac sympathetic denervation | Hemothorax, pneumothorax, ptosis or Horner syndrome |
| Cuculich <i>et al</i> ^[29] | Clinical | 5 | Stereotactic radioablation therapy | Fatigue |
| Rivera <i>et al</i> ^[31] | Clinical | 21 | Cryoablation | - |
| Li <i>et al</i> ^[34] | Clinical | 38 | Surgical epicardial ablation | Ventricle laceration |
| Berte <i>et al</i> ^[35] | Experimental | 5 (sheep) | Surgical cryoablation | - |
| Liang <i>et al</i> ^[36] | Clinical | 20 | Surgical cryoablation | - |
| Denegri <i>et al</i> ^[42] | Experimental | 25 (mice) | Viral gene transfer of wild-type CASQ2 | - |
| Li <i>et al</i> ^[44] | Experimental | 9 (mice) | Tetracaine derivatives (RyR2 inhibitors) | - |
| Arenal <i>et al</i> ^[45] | Experimental | 31 (pigs) | MRI-based signal intensity mapping for epicardial substrate | Coronary occlusion |
| Klein <i>et al</i> ^[46] | Clinical | 15 | 3D meta-iodobenzyl-guanidine innervation maps to assess substrate and successful ablation sites | - |
| Zhang <i>et al</i> ^[47] | Clinical | 32 | Non-invasive high-resolution endocardial and epicardial mapping and electro-cardiographic imaging | - |
| Luther <i>et al</i> ^[48] | Clinical | 15 | Cardiac ripple mapping for slow conducting channels | - |
| Jamil-Copley <i>et al</i> ^[49] | Clinical | 21 | Cardiac ripple mapping for slow conducting channels | - |

the treatment of VT and efficiently lowers recurrent VT episodes but carries upfront procedural danger. Novel methods could enhance its future effectiveness. The final management strategy should be individualized utilizing clinical and imaging assessment, patient views and intentions, futility concerns, and operator's catheter ablation experience.

REFERENCES

- Al-Khatib SM, Stevenson WG, Ackerman MJ, Bryant WJ, Callans DJ, Curtis AB, Deal BJ, Dickfeld T, Field ME, Fonarow GC, Gillis AM, Hlatky MA, Granger CB, Hammill SC, Joglar JA, Kay GN, Matlock DD, Myerburg RJ, Page RL. 2017 AHA/ACC/HRS Guideline for Management of Patients With Ventricular Arrhythmias and the Prevention of Sudden Cardiac Death: Executive Summary: A Report of the American College of Cardiology/American Heart Association Task Force on Clinical Practice Guidelines and the Heart Rhythm Society. *Circulation* 2017; pii: CIR.0000000000000548 [PMID: 29084733 DOI: 10.1161/CIR.0000000000000548]
- Weisfeldt ML, Everson-Stewart S, Sitlani C, Rea T, Aufderheide TP, Atkins DL, Bigham B, Brooks SC, Foerster C, Gray R, Ornato JP, Powell J, Kudenchuk PJ, Morrison LJ; Resuscitation Outcomes Consortium Investigators. Ventricular tachyarrhythmias after cardiac arrest in public versus at home. *N Engl J Med* 2011; **364**: 313-321 [PMID: 21268723 DOI: 10.1056/NEJMoa1010663]
- Priori SG, Blomström-Lundqvist C, Mazzanti A, Blom N, Borggrefe M, Camm J, Elliott PM, Fitzsimons D, Hatala R, Hindricks G, Kirchhof P, Kjeldsen K, Kuck KH, Hernandez-Madrid A, Nikolaou N, Norekvål TM, Spaulding C, Van Veldhuisen DJ; ESC Scientific Document Group. 2015 ESC Guidelines for the management of patients with ventricular arrhythmias and the prevention of sudden cardiac death: The Task Force for the Management of Patients with Ventricular Arrhythmias and the Prevention of Sudden Cardiac Death of the European Society of Cardiology (ESC). Endorsed by: Association for European Paediatric and Congenital Cardiology (AEPC). *Eur Heart J* 2015; **36**: 2793-2867 [PMID: 26320108 DOI: 10.1093/eurheartj/ehv316]
- Hohnloser SH, Israel CW. Current evidence base for use of the implantable cardioverter-defibrillator. *Circulation* 2013; **128**: 172-183 [PMID: 23836830 DOI: 10.1161/CIRCULATIONAHA.112.000547]
- Santangeli P, Muser D, Maeda S, Filtz A, Zado ES, Frankel DS, Dixit S, Epstein AE, Callans DJ, Marchlinski FE. Comparative effectiveness of antiarrhythmic drugs and catheter ablation for the prevention of recurrent ventricular tachycardia in patients with implantable cardioverter-defibrillators: A systematic review and meta-analysis of randomized controlled trials. *Heart Rhythm* 2016; **13**: 1552-1559 [PMID: 26961297 DOI: 10.1016/j.hrthm.2016.03.004]
- Dukkipati SR, Choudry S, Koruth JS, Miller MA, Whang W, Reddy VY. Catheter Ablation of Ventricular Tachycardia in Structurally Normal Hearts: Indications, Strategies, and Outcomes-Part I. *J Am Coll Cardiol* 2017; **70**: 2909-2923 [PMID: 29216987 DOI: 10.1016/j.jacc.2017.10.031]
- Dukkipati SR, Koruth JS, Choudry S, Miller MA, Whang W, Reddy VY. Catheter Ablation of Ventricular Tachycardia in Structural Heart Disease: Indications, Strategies, and Outcomes-Part II. *J Am Coll Cardiol* 2017; **70**: 2924-2941 [PMID: 29216988 DOI: 10.1016/j.jacc.2017.10.030]
- MacIntyre CJ, Sapp JL. Treatment of persistent ventricular tachycardia: Drugs or ablation? *Trends Cardiovasc Med* 2017; **27**: 506-513 [PMID: 28625728 DOI: 10.1016/j.tcm.2017.05.004]

- 9 **Baldinger SH**, Stevenson WG, John RM. Ablation of ischemic ventricular tachycardia: evidence, techniques, results, and future directions. *Curr Opin Cardiol* 2016; **31**: 29-36 [PMID: 26569083 DOI: 10.1097/HCO.0000000000000237]
- 10 **Aryana A**, d'Avila A. Epicardial Catheter Ablation of Ventricular Tachycardia. *Card Electrophysiol Clin* 2017; **9**: 119-131 [PMID: 28167080 DOI: 10.1016/j.ccep.2016.10.009]
- 11 **Nademanee K**, Hocini M, Haïssaguerre M. Epicardial substrate ablation for Brugada syndrome. *Heart Rhythm* 2017; **14**: 457-461 [PMID: 27979714 DOI: 10.1016/j.hrthm.2016.12.001]
- 12 **Aksu T**, Erdem Guler T, Yalin K. Successful ablation of an epicardial ventricular tachycardia by video-assisted thoracoscopy. *Europace* 2015; **17**: 1116 [PMID: 25736561 DOI: 10.1093/europace/euv012]
- 13 **Graham AJ**, Orini M, Lambiase PD. Limitations and Challenges in Mapping Ventricular Tachycardia: New Technologies and Future Directions. *Arrhythm Electrophysiol Rev* 2017; **6**: 118-124 [PMID: 29018519 DOI: 10.15420/aer.2017.20.1]
- 14 **Della Bella P**, Baratto F, Tsiachris D, Trevisi N, Vergara P, Bisceglia C, Petracca F, Carbucicchio C, Benussi S, Maisano F, Alfieri O, Pappalardo F, Zangrillo A, Maccabelli G. Management of ventricular tachycardia in the setting of a dedicated unit for the treatment of complex ventricular arrhythmias: long-term outcome after ablation. *Circulation* 2013; **127**: 1359-1368 [PMID: 23439513 DOI: 10.1161/CIRCULATIONAHA.112.000872]
- 15 **Kim SM**, Virgadamo S, Gurley J, Elayi CS. Use of Cardioplegia to Guide Alcohol Ablation for Incessant Ventricular Tachycardia. *Pacing Clin Electrophysiol* 2017; **40**: 213-216 [PMID: 27565122 DOI: 10.1111/pace.12945]
- 16 **Markowitz SM**, Minutello RM, Kim LK, Ip JE, Thomas G, Lerman BB. Treatment of intramural ventricular tachycardia in cardiac sarcoidosis with transcatheter ethanol ablation. *Europace* 2017; **19**: 1921 [PMID: 29126258 DOI: 10.1093/europace/eux277]
- 17 **Sapp JL**, Beeckler C, Pike R, Parkash R, Gray CJ, Zeppenfeld K, Kuriachan V, Stevenson WG. Initial human feasibility of infusion needle catheter ablation for refractory ventricular tachycardia. *Circulation* 2013; **128**: 2289-2295 [PMID: 24036605 DOI: 10.1161/CIRCULATIONAHA.113.003423]
- 18 **Tholakanahalli VN**, Bertog S, Roukoz H, Shivkumar K. Catheter ablation of ventricular tachycardia using intracoronary wire mapping and coil embolization: description of a new technique. *Heart Rhythm* 2013; **10**: 292-296 [PMID: 23089899 DOI: 10.1016/j.hrthm.2012.10.031]
- 19 **Gianni C**, Mohanty S, Trivedi C, Di Biase L, Al-Ahmad A, Natale A, David Burkhardt J. Alternative Approaches for Ablation of Resistant Ventricular Tachycardia. *Card Electrophysiol Clin* 2017; **9**: 93-98 [PMID: 28167089 DOI: 10.1016/j.ccep.2016.10.006]
- 20 **Sakamoto K**, Nozoe M, Tsutsui Y, Suematsu N, Kubota T, Okabe M, Yamamoto Y. Successful bipolar ablation for ventricular tachycardia with potential substrate identification by pre-procedural cardiac magnetic resonance imaging. *Int Med Case Rep J* 2017; **10**: 167-171 [PMID: 28546773 DOI: 10.2147/IMCRJ.S135952]
- 21 **Vaseghi M**, Barwad P, Malavassi Corrales FJ, Tandri H, Mathuria N, Shah R, Sorg JM, Gima J, Mandal K, Sáenz Morales LC, Lokhandwala Y, Shivkumar K. Cardiac Sympathetic Denervation for Refractory Ventricular Arrhythmias. *J Am Coll Cardiol* 2017; **69**: 3070-3080 [PMID: 28641796 DOI: 10.1016/j.jacc.2017.04.035]
- 22 **Kopecky K**, Afzal A, Felius J, Hall SA, Mendez JC, Assar M, Mason DP, Bindra AS. Bilateral sympathectomy for treatment of refractory ventricular tachycardia. *Pacing Clin Electrophysiol* 2018; **41**: 93-95 [PMID: 28851062 DOI: 10.1111/pace.13164]
- 23 **Amer M**, Burrows WM, Dickfeld TM. Unilateral sympathetic ganglion denervation in the management of sustained ventricular tachycardia. *HeartRhythm Case Rep* 2017; **3**: 467-469 [PMID: 29062699 DOI: 10.1016/j.hrcr.2017.07.002]
- 24 **Rajesh MC**, Deepa KV, Ramdas EK. Stellate Ganglion Block as Rescue Therapy in Refractory Ventricular Tachycardia. *Anesth Essays Res* 2017; **11**: 266-267 [PMID: 28298801 DOI: 10.4103/0259-1162.194566]
- 25 **Feyz L**, Wijchers S, Daemen J. Renal denervation as a treatment strategy for vasospastic angina induced ventricular tachycardia. *Neth Heart J* 2017; **25**: 596-597 [PMID: 28608267 DOI: 10.1007/s12471-017-1012-1]
- 26 **Aksu T**, Güler TE, Özcan KS, Bozyel S, Yalin K. Renal sympathetic denervation assisted treatment of electrical storm due to polymorphic ventricular tachycardia in a patient with catecholaminergic polymorphic ventricular tachycardia. *Türk Kardiyol Dern Ars* 2017; **45**: 441-449 [PMID: 28694398 DOI: 10.5543/tkda.2017.72773]
- 27 **Aksu T**, Güler E. Percutaneous renal sympathetic denervation in catecholaminergic polymorphic ventricular tachycardia. *J Arrhythm* 2017; **33**: 245 [PMID: 28607624 DOI: 10.1016/j.joa.2016.12.004]
- 28 **Wang L**, Fahimian B, Soltys SG, Zei P, Lo A, Gardner EA, Maguire PJ, Loo BW Jr. Stereotactic Arrhythmia Radioablation (STAR) of Ventricular Tachycardia: A Treatment Planning Study. *Cureus* 2016; **8**: e694 [PMID: 27570715 DOI: 10.7759/cureus.694]
- 29 **Cuculich PS**, Schill MR, Kashani R, Mutic S, Lang A, Cooper D, Faddis M, Gleva M, Noheria A, Smith TW, Hallahan D, Rudy Y, Robinson CG. Noninvasive Cardiac Radiation for Ablation of Ventricular Tachycardia. *N Engl J Med* 2017; **377**: 2325-2336 [PMID: 29236642 DOI: 10.1056/NEJMoa1613773]
- 30 **Marai I**, Andria N, Gurevitz O. Cryoablation for Ventricular Tachycardia Originating from Anterior Papillary Muscle of Left Ventricle Guided by Intracardiac Echocardiography. *Case Rep Cardiol* 2017; **2017**: 9734795 [PMID: 28512586 DOI: 10.1155/2017/9734795]
- 31 **Rivera S**, Ricapito Mde L, Tomas L, Parodi J, Bardera Molina G, Banega R, Bueti P, Orosco A, Reinoso M, Caro M, Belardi D, Albina G, Giniger A, Scazzuso F. Results of Cryoenergy and Radiofrequency-Based Catheter Ablation for Treating Ventricular Arrhythmias Arising From the Papillary Muscles of the Left Ventricle, Guided by Intracardiac Echocardiography and Image Integration. *Circ Arrhythm Electrophysiol* 2016; **9**: e003874 [PMID: 27069089 DOI: 10.1161/CIRCEP.115.003874]
- 32 **Shenasa M**, Miller JM, Callans DJ, Almendral JM, Marchlinski FE, Buxton AE. Conquest of Ventricular Tachycardia: Insights Into Mechanisms, Innovations in Management: Contribution of Mark E. Josephson, MD, to Clinical Electrophysiology. *Circ Arrhythm Electrophysiol* 2017; **10**: pii: e005150 [PMID: 28487348 DOI: 10.1161/CIRCEP.117.005150]
- 33 **Higuchi T**, Tsutsumi Y, Monta O, Asada S, Matsumoto R, Yamada S, Ohashi H. Surgical treatment for endocardial radiofrequency ablation-resistant sustained monomorphic ventricular tachycardia with mural thrombus including dense calcification in the left ventricle. *Gen Thorac Cardiovasc Surg* 2017; Epub ahead of print [PMID: 29188428 DOI: 10.1007/s11748-017-0853-2]
- 34 **Li A**, Hayase J, Do D, Buch E, Vaseghi M, Ajjola OA, Macias C, Krokhalava Y, Khakpour H, Boyle NG, Benharash P, Biniwale R, Shivkumar K, Bradfield JS. Hybrid surgical vs percutaneous access epicardial ventricular tachycardia ablation. *Heart Rhythm* 2018; **15**: 512-519 [PMID: 29132931 DOI: 10.1016/j.hrthm.2017.11.009]
- 35 **Berte B**, Sacher F, Wielandts JY, Mahida S, Pillois X, Weerasooriya R, Bernus O, Jais P. A new cryoenergy for ventricular tachycardia ablation: a proof-of-concept study. *Europace* 2017; **19**: 1401-1407 [PMID: 27907904 DOI: 10.1093/europace/euw217]
- 36 **Liang JJ**, Betensky BP, Muser D, Zado ES, Anter E, Desai ND, Callans DJ, Deo R, Frankel DS, Hutchinson MD, Lin D, Riley MP, Schaller RD, Supple GE, Santangeli P, Ackerman MA, Bavaria JE, Szeto WY, Vallabhajosyula P, Marchlinski FE, Dixit S. Long-term outcome of surgical cryoablation for refractory ventricular tachycardia in patients with non-ischemic cardiomyopathy. *Europace* 2018; **20**: e30-e41 [PMID: 28402404 DOI: 10.1093/europace/eux029]
- 37 **Bhandary SP**, Joseph N, Hofmann JP, Saranteas T, Papadimos TJ. Extracorporeal life support for refractory ventricular tachycardia. *Ann Transl Med* 2017; **5**: 73 [PMID: 28275618 DOI: 10.21037/atm.2017.01.39]
- 38 **Okabe T**, Yakushiji T, Hiroe M, Oyama Y, Igawa W, Ono M, Kido T, Ebara S, Yamashita K, Yamamoto MH, Saito S, Hoshimoto K, Kizaki A, Isomura N, Araki H, Ochiai M. Steroid pulse therapy was effective for cardiac sarcoidosis with ventricular tachycardia and systolic dysfunction. *ESC Heart Fail* 2016; **3**: 288-292 [PMID: 27867531 DOI: 10.1002/ehf2.12095]

- 39 **Roston TM**, Cunningham TC, Sanatani S. Advances in the diagnosis and treatment of catecholaminergic polymorphic ventricular tachycardia. *Cardiol Young* 2017; **27**: S49-S56 [PMID: 28084961 DOI: 10.1017/S1047951116002237]
- 40 **Arakawa J**, Hamabe A, Aiba T, Nagai T, Yoshida M, Touya T, Ishigami N, Hisadome H, Katsushika S, Tabata H, Miyamoto Y, Shimizu W. A novel cardiac ryanodine receptor gene (RyR2) mutation in an athlete with aborted sudden cardiac death: a case of adult-onset catecholaminergic polymorphic ventricular tachycardia. *Heart Vessels* 2015; **30**: 835-840 [PMID: 25092222 DOI: 10.1007/s00380-014-0555-y]
- 41 **Kawata H**, Ohno S, Aiba T, Sakaguchi H, Miyazaki A, Sumitomo N, Kamakura T, Nakajima I, Inoue YY, Miyamoto K, Okamura H, Noda T, Kusano K, Kamakura S, Miyamoto Y, Shiraishi I, Horie M, Shimizu W. Catecholaminergic Polymorphic Ventricular Tachycardia (CPVT) Associated With Ryanodine Receptor (RyR2) Gene Mutations- Long-Term Prognosis After Initiation of Medical Treatment. *Circ J* 2016; **80**: 1907-1915 [PMID: 27452199 DOI: 10.1253/circj.CJ-16-0250]
- 42 **Denegri M**, Bongianino R, Lodola F, Boncompagni S, De Giusti VC, Avelino-Cruz JE, Liu N, Persampieri S, Curcio A, Esposito F, Pietrangelo L, Marty I, Villani L, Moyaho A, Baiardi P, Auricchio A, Protasi F, Napolitano C, Priori SG. Single delivery of an adeno-associated viral construct to transfer the CASQ2 gene to knock-in mice affected by catecholaminergic polymorphic ventricular tachycardia is able to cure the disease from birth to advanced age. *Circulation* 2014; **129**: 2673-2681 [PMID: 24888331 DOI: 10.1161/CIRCULATIONAHA.113.006901]
- 43 **Lodola F**, Morone D, Denegri M, Bongianino R, Nakahama H, Rutigliano L, Gosetti R, Rizzo G, Vollero A, Buonocore M, Napolitano C, Condorelli G, Priori SG, Di Pasquale E. Adeno-associated virus-mediated CASQ2 delivery rescues phenotypic alterations in a patient-specific model of recessive catecholaminergic polymorphic ventricular tachycardia. *Cell Death Dis* 2016; **7**: e2393 [PMID: 27711080 DOI: 10.1038/cddis.2016.304]
- 44 **Li N**, Wang Q, Sibrian-Vazquez M, Klipp RC, Reynolds JO, Word TA, Scott L Jr, Salama G, Strongin RM, Abramson JJ, Wehrens XHT. Treatment of catecholaminergic polymorphic ventricular tachycardia in mice using novel RyR2-modifying drugs. *Int J Cardiol* 2017; **227**: 668-673 [PMID: 27838126 DOI: 10.1016/j.ijcard.2016.10.078]
- 45 **Arenal A**, Pérez-David E, Avila P, Fernández-Portales J, Crisóstomo V, Báez C, Jiménez-Candil J, Rubio-Guivernau JL, Ledesma-Carbayo MJ, Loughlin G, Bermejo J, Sánchez-Margallo FM, Fernández-Avilés F. Noninvasive identification of epicardial ventricular tachycardia substrate by magnetic resonance-based signal intensity mapping. *Heart Rhythm* 2014; **11**: 1456-1464 [PMID: 24747421 DOI: 10.1016/j.hrthm.2014.04.022]
- 46 **Klein T**, Abdulghani M, Smith M, Huang R, Asoglu R, Remo BF, Turgeman A, Mesubi O, Sidhu S, Synowski S, Saliaris A, See V, Shorofsky S, Chen W, Dilsizian V, Dickfeld T. Three-dimensional 123I-meta-iodobenzylguanidine cardiac innervation maps to assess substrate and successful ablation sites for ventricular tachycardia: feasibility study for a novel paradigm of innervation imaging. *Circ Arrhythm Electrophysiol* 2015; **8**: 583-591 [PMID: 25713216 DOI: 10.1161/CIRCEP.114.002105]
- 47 **Zhang J**, Cooper DH, Desouza KA, Cuculich PS, Woodard PK, Smith TW, Rudy Y. Electrophysiologic Scar Substrate in Relation to VT: Noninvasive High-Resolution Mapping and Risk Assessment with ECGI. *Pacing Clin Electrophysiol* 2016; **39**: 781-791 [PMID: 27197804 DOI: 10.1111/pace.12882]
- 48 **Luther V**, Linton NW, Jamil-Copley S, Koa-Wing M, Lim PB, Qureshi N, Ng FS, Hayat S, Whinnett Z, Davies DW, Peters NS, Kanagaratnam P. A Prospective Study of Ripple Mapping the Post-Infarct Ventricular Scar to Guide Substrate Ablation for Ventricular Tachycardia. *Circ Arrhythm Electrophysiol* 2016; **9**: pii: e004072 [PMID: 27307519 DOI: 10.1161/CIRCEP.116.004072]
- 49 **Jamil-Copley S**, Vergara P, Carbucicchio C, Linton N, Koa-Wing M, Luther V, Francis DP, Peters NS, Davies DW, Tondo C, Della Bella P, Kanagaratnam P. Application of ripple mapping to visualize slow conduction channels within the infarct-related left ventricular scar. *Circ Arrhythm Electrophysiol* 2015; **8**: 76-86 [PMID: 25527678 DOI: 10.1161/CIRCEP.114.001827]

P- Reviewer: Aksu T **S- Editor:** Ji FF **L- Editor:** Filipodia
E- Editor: Tan WW



Correction to “Clinical outcomes of combined flow-pressure drop measurements using newly developed diagnostic endpoint: Pressure drop coefficient in patients with coronary artery dysfunction”

Mohamed A Effat, Srikara Viswanath Peelukhana, Rupak K Banerjee

Mohamed A Effat, Division of Cardiovascular Health and Diseases, University of Cincinnati Medical Center, Veteran Affairs Medical Center, Cincinnati, OH 45221, United States

Srikara Viswanath Peelukhana, Rupak K Banerjee, Research Services, Veteran Affairs Medical Center, Cincinnati, OH 45220, United States

Srikara Viswanath Peelukhana, Rupak K Banerjee, Department of Mechanical and Materials Engineering, University of Cincinnati, Cincinnati, OH 45221, United States

ORCID number: Mohamed A Effat (0000-0002-3646-4873); Srikara Viswanath Peelukhana (0000-0003-1290-7526); Rupak K Banerjee (0000-0002-7235-9560).

Author contributions: Effat MA, Peelukhana SV and Banerjee RK contributed to this correction.

Conflict-of-interest statement: No potential conflicts of interest relevant to this article were reported.

Open-Access: This article is an open-access article, which was selected by an in-house editor and fully peer-reviewed by external reviewers. It is distributed in accordance with the Creative Commons Attribution Non Commercial (CC BY-NC 4.0) license, which permits others to distribute, remix, adapt, build upon this work non-commercially, and license their derivative works on different terms, provided the original work is properly cited and the use is non-commercial. See: <http://creativecommons.org/licenses/by-nc/4.0/>

Manuscript source: Unsolicited manuscript

Correspondence to: Rupak K Banerjee, PhD, Professor, Department of Mechanical and Materials Engineering, University of Cincinnati, 598 Rhodes Hall, PO Box 0072, Cincinnati, OH 45221, United States. rupak.banerjee@uc.edu
Telephone: +1-513-5562124
Fax: +1-513-5563390

Received: March 1, 2018

First decision: March 8, 2018

Revised: March 19, 2018

Accepted: April 1, 2018

Article in press: April 1, 2018

Published online: July 26, 2018

© The Author(s) 2018. Published by Baishideng Publishing Group Inc. All rights reserved.

Effat MA, Peelukhana SV, Banerjee RK. Correction to “Clinical outcomes of combined flow-pressure drop measurements using newly developed diagnostic endpoint: Pressure drop coefficient in patients with coronary artery dysfunction”. *World J Cardiol* 2018; 10(7): 60-61 Available from: URL: <http://www.wjgnet.com/1949-8462/full/v10/i7/60.htm> DOI: <http://dx.doi.org/10.4330/wjc.v10.i7.60>

CORRECTION

Correction to “Clinical outcomes of combined flow-pressure drop measurements using newly developed diagnostic endpoint: Pressure drop coefficient in patients with coronary artery dysfunction”. *World J Cardiol* 2016; 8(3): 283-292 PMID: 27022460 DOI: 10.4330/wjc.v8.i3.283.

Correction 1

The percentage value of 8.57%, in page 284, line 10 and in page 287, lines 4 and 8, is a typo^[1]. It should read as 5.7%, which corresponds to 2/35, as correctly reported within the parentheses.

Correction 2

Figure 1A in page 287 reflects the correct percentage, which is 5.7%.

REFERENCES

- 1 **Effat MA**, Peelukhana SV, Banerjee RK. Clinical outcomes of combined flow-pressure drop measurements using newly developed

diagnostic endpoint: Pressure drop coefficient in patients with coronary artery dysfunction. *World J Cardiol* 2016; **8**: 283-292 [PMID: 27022460 DOI: 10.4330/wjc.v8.i3.283]

S- Editor: Cui LJ **L- Editor:** A **E- Editor:** Tan WW





Published by **Baishideng Publishing Group Inc**
7901 Stoneridge Drive, Suite 501, Pleasanton, CA 94588, USA
Telephone: +1-925-223-8242
Fax: +1-925-223-8243
E-mail: bpgoffice@wjgnet.com
Help Desk: <http://www.f6publishing.com/helpdesk>
<http://www.wjgnet.com>

