ISSN 1948-9366 (online)

World Journal of *Gastrointestinal Surgery*

World J Gastrointest Surg 2011 May 27; 3(5): 59-72

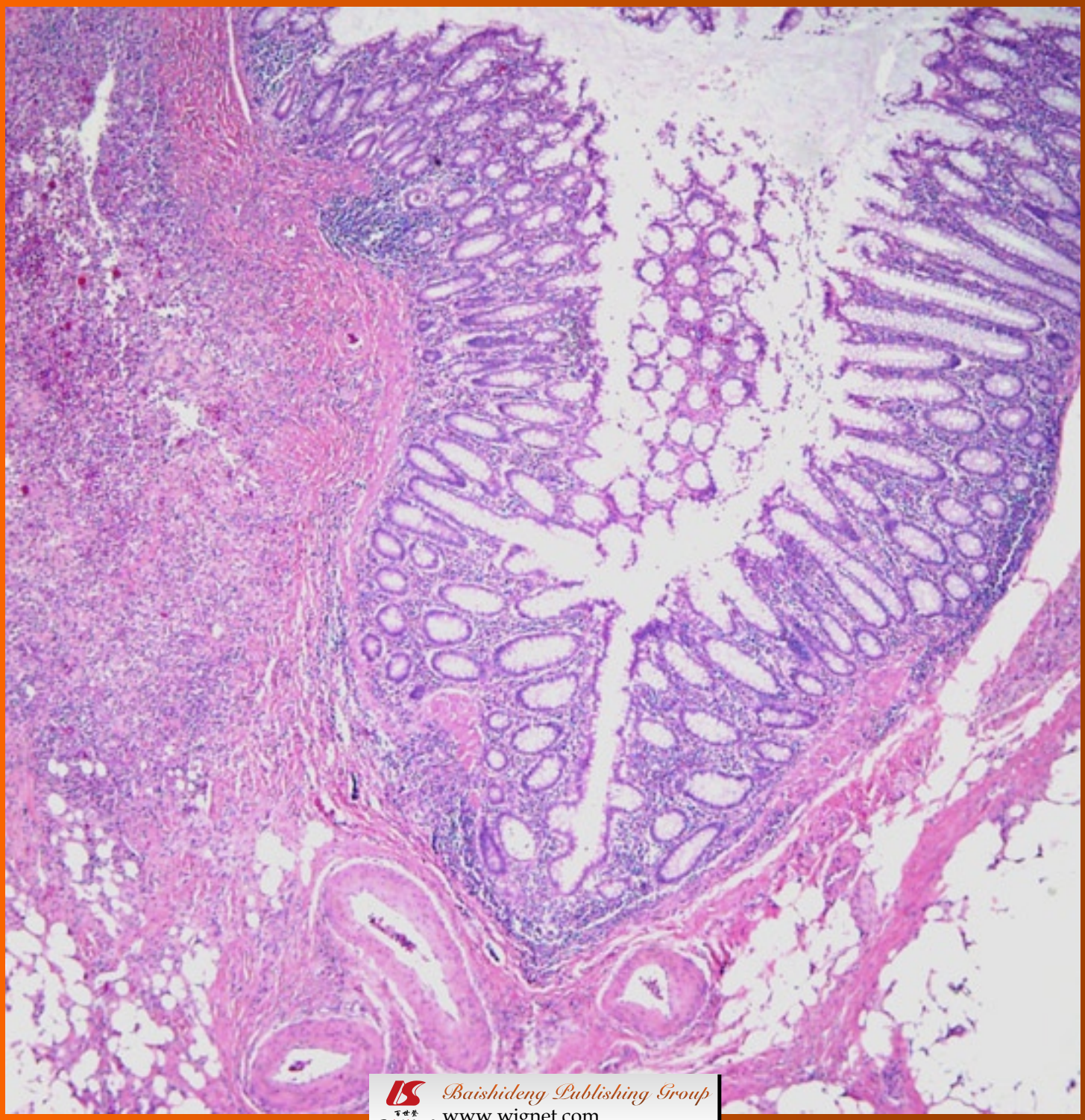

Baishideng Publishing Group
www.wjgnet.com

WJGS

World Journal of Gastrointestinal Surgery

A peer-reviewed, online, open-access journal of gastrointestinal surgery

Editorial Board

2009-2013

The *World Journal of Gastrointestinal Surgery* Editorial Board consists of 336 members, representing a team of worldwide experts in gastrointestinal surgery research. They are from 35 countries, including Australia (6), Austria (2), Belgium (6), Brazil (9), Bulgaria (2), Canada (8), China (30), Denmark (1), Finland (1), France (10), Germany (22), Greece (6), India (10), Ireland (3), Israel (3), Italy (48), Jamaica (1), Japan (47), Malaysia (1), Netherlands (9), Pakistan (1), Poland (1), Portugal (1), Russia (1), Singapore (6), Serbia (1), South Korea (9), Spain (5), Sweden (2), Switzerland (4), Thailand (2), Tunisia (1), Turkey (8), United Kingdom (7), and United State (62).

WJGS

World Journal of
Gastrointestinal Surgery

Contents

Monthly Volume 3 Number 5 May 27, 2011

Contents

World Journal of Gastrointestinal Surgery
Volume 3 Number 5 May 27, 2011

ABOUT COVER

Metz Y, Nagler J. Diverticulitis presenting as a tubo-ovarian abscess with subsequent colon perforation.
World J Gastrointest Surg 2011; 3(5): 70-72
http://www.wjgnet.com/1948-9366/full/v3/i5/70.htm

AIM AND SCOPE

World Journal of Gastrointestinal Surgery (*World J Gastrointest Surg*, *WJGS*, online ISSN 1948-9366, DOI: 10.4240), is a monthly, open-access, peer-reviewed journal supported by an editorial board of 336 experts in gastrointestinal surgery from 35 countries.

The major task of *WJGS* is to rapidly report the most recent results in basic and clinical research on gastrointestinal surgery, specifically including micro-invasive surgery, laparoscopy, hepatic surgery, biliary surgery, pancreatic surgery, splenic surgery, surgical nutrition, portal hypertension, as well as the associated subjects such as epidemiology, cancer research, biomarkers, prevention, pathology, radiology, genetics, genomics, proteomics, pharmacology, pharmacokinetics, pharmacogenetics, molecular biology, clinical trials, diagnosis and therapeutics and multimodality treatment. Emphasis is placed on original research articles and clinical case reports. This journal will also provide balanced, extensive and timely review articles on selected topics.

NAME OF JOURNAL
World Journal of Gastrointestinal Surgery

LAUNCH DATE
November 30, 2009

SPONSOR
Beijing Baishideng BioMed Scientific Co., Ltd.,
Room 903, Building D, Ocean International Center,
No. 62 Dongsihuan Zhonglu, Chaoyang District,
Beijing 100025, China
Telephone: +86-10-8538-1892
Fax: +86-10-8538-1893
E-mail: baishideng@wjgnet.com
http://www.wjgnet.com

EDITING
Editorial Board of *World Journal of Gastrointestinal Surgery*,
Room 903, Building D, Ocean International Center,
No. 62 Dongsihuan Zhonglu, Chaoyang District,
Beijing 100025, China
Telephone: +86-10-8538-1891
Fax: +86-10-8538-1893
E-mail: wjgs@wjgnet.com
http://www.wjgnet.com

PUBLISHING
Baishideng Publishing Group Co., Limited,
Room 1701, 17/F, Henan Building,
No.90 Jaffe Road, Wanchai,
Hong Kong, China
Fax: +852-3115-8812
Telephone: +852-5804-2046
E-mail: baishideng@wjgnet.com
http://www.wjgnet.com

SUBSCRIPTION
Beijing Baishideng BioMed Scientific Co., Ltd.,
Room 903, Building D, Ocean International Center,
No. 62 Dongsihuan Zhonglu, Chaoyang District,
Beijing 100025, China
Telephone: +86-10-8538-1892
Fax: +86-10-8538-1893
E-mail: baishideng@wjgnet.com
http://www.wjgnet.com

PUBLICATION DATE
May 27, 2011

ISSN
ISSN 1948-9366 (online)

PRESIDENT AND EDITOR-IN-CHIEF
Lian-Sheng Ma, *Beijing*

STRATEGY ASSOCIATE EDITORS-IN-CHIEF
Elijah Dixon, *Calgary*
Antonello Forgione, *Milan*
Tobias Keck, *Freiburg*
Tsuyoshi Konishi, *Tokyo*
Natale Di Martino, *Naples*

EDITORIAL OFFICE
Jin-Lei Wang, Director
World Journal of Gastrointestinal Surgery
Room 903, Building D, Ocean International Center,
No. 62 Dongsihuan Zhonglu, Chaoyang District,
Beijing 100025, China
Telephone: +86-10-8538-1891
Fax: +86-10-8538-1893
E-mail: wjgs@wjgnet.com
http://www.wjgnet.com

SPECIAL STATEMENT
All articles published in this journal represent the viewpoints of the authors except where indicated otherwise.

INSTRUCTIONS TO AUTHORS
Full instructions are available online at http://www.wjgnet.com/1948-9366/g_info_20100305152206.htm.

ONLINE SUBMISSION
http://www.wjgnet.com/1948-9366office

World Journal of Gastrointestinal Surgery

Online Submissions: http://www.wjgnet.com/1948-9366office
wjgs@wjgnet.com
doi:10.4240/wjgs.v3.i5.59

World J Gastrointest Surg 2011 May 27; 3(5): 59-69
ISSN 1948-9366 (online)

EDITORIAL

How to assess intestinal viability during surgery: A review of techniques

Linas Urbanavičius, Piet Pattyn, Dirk Van de Putte, Donatas Venskutonis

Linas Urbanavičius, Donatas Venskutonis, Lithuanian University of Health Sciences, Department of General Surgery, Josvainiu str. 2; Kaunas, LT-47144, Lithuania
Piet Pattyn, Dirk Van de Putte, Department of Gastrointestinal Surgery, Ghent University Hospital, De Pintelaan 185, Ghent, B-9000, Belgium
Author contributions: All authors contributed to the conception and design of the manuscript; Urbanavičius L and Van de Putte D drafted the manuscript; Pattyn P and Venskutonis D edited and critically revised the manuscript.
Supported by Research Council of Lithuania
Correspondence to: Linas Urbanavičius, MD, Department of General Surgery, Lithuanian University of Health Sciences. Address: Josvainiu str. 2; Kaunas, LT-47144, Lithuania. ulinas@gmail.com
Telephone: +370 685 75938 Fax: +370 37 306066
Received: November 6, 2010 Revised: March 18, 2011
Accepted: March 25, 2011
Published online: May 27, 2011

Abstract

Objective and quantitative intraoperative methods of bowel viability assessment are essential in gastrointestinal surgery. Exact determination of the borderline of the viable bowel with the help of an objective test could result in a decrease of postoperative ischemic complications. An accurate, reproducible and cost effective method is desirable in every operating theater dealing with abdominal operations. Numerous techniques assessing various parameters of intestinal viability are described by the studies. However, there is no consensus about their clinical use. To evaluate the available methods, a systematic search of the English literature was performed. Virtues and drawbacks of the techniques and possibilities of clinical application are reviewed. Valuable parameters related to postoperative intestinal anastomotic or stoma complications are analyzed. Important issues in the measurement and interpretation of bowel viability are discussed. To date, only a few methods are applicable in surgical practice. Further studies are needed to determine the limiting values of intestinal tissue oxygenation and flow indicative of ischemic complications and to standardize the methods.

Key words: Microperfusion; Tissue ischemia; Colon perfusion; Anastomotic leakage; Stoma

Peer reviewer: Giulio A Santoro, Professor, Pelvic Floor Unit and Colorectal Unit, Department of Surgery, Regional Hospital, Treviso 31000, Italy

Urbanavičius L, Pattyn P, Van de Putte D, Venskutonis D. How to assess intestinal viability during surgery: A review of techniques. *World J Gastrointest Surg* 2011; 3(5): 59-69 Available from: URL: http://www.wjgnet.com/1948-9366/full/v3/i5/59.htm DOI: http://dx.doi.org/10.4240/wjgs.v3.i5.59

INTRODUCTION

Viability of the bowel must be evaluated frequently during abdominal surgery. Sufficient blood supply is very important for successful healing of the anastomosis and avoidance of intestinal ischemia and necrosis. Insufficient microcirculation of the anastomotic region leads to anastomotic leakage or stricture, especially in elderly patients. This is associated with an increased length of hospital stay, significant postoperative morbidity and mortality and recurrence after colorectal resections for malignant bowel tumors. The reported incidence of anastomotic leakage ranges between 1.2% and 19.2%. Up to 32% of patients with an anastomotic leak die from this postoperative complication[1,2].

Intestinal microcirculation and viability is usually estimated from the color of the serosal surface, presence of bowel peristalsis, pulsation and bleeding from the marginal arteries. This is subjective and based on the experience of the surgeon. Clinical assessment may be deceptive. A dark hue may be due to transient venous insufficiency and

the bowel may in fact be viable, whereas in early arterial occlusion it may appear normal. Absence of mesenteric pulsation may be due to hypotension or spasm. Peristalsis may persist even in a grossly ischemic bowel[3]. Karliczek *et al*[4] evaluated the surgeons' predictive accuracy for anastomotic leakage in a prospective clinical study. Clinical risk assessment by the surgeons appeared to have a low predictive value for anastomotic leakage in gastrointestinal surgery. It has been shown that improvement in inadequate intraoperative colonic perfusion from increased collateral circulation is unlikely to develop during the first five postoperative days and therefore anastomotic perfusion is probably determined at the time of surgery and should be assessed intraoperatively[5,6]. Thus, objective and quantitative intraoperative methods of bowel microcirculation assessment are of paramount importance. The aim of this review is to survey and evaluate the valuable methods of intestinal viability assessment and the possibilities of their clinical application.

A systematic English literature review was performed. The electronic databases of ISI Web of Science, PubMed Medline and SpringerLink were searched. Studies investigating intraoperative quantitative methods of microcirculation assessment predicting the healing of anastomosis or intestinal stoma were searched for in the databases. The search was performed using both MeSH (Medical Subject Heading) terms and free text terms. The following MeSH terms were used: "Intestines" [MeSH] AND "Ischemia " [MeSH] AND "Monitoring" [MeSH]. Free text terms: bowel, intestine, anastomosis, stoma, perfusion, microcirculation, viability, oxygenation, ischemia, evaluation, assessment, measurement and intraoperative. The type of surgery included in the search: operations for intestinal tumors, incarcerated hernias, intestinal ischemia, bowel perforations, ileus, restoration of bowel continuity, transplantation of bowel segment, abdominal aorta disorders etc., where to avoid bowel necrosis, anastomotic or stoma complications, assessment of bowel microcirculation and viability is essential. Both urgent and elective surgical procedures were included as well as open and laparoscopic. Decision to resect the intestine and perform the anastomosis could be made either deliberately before the operation or during the operation due to intraoperative findings. All quantitative parameters which reflect intestinal microcirculation and viability intraoperatively were involved. The relationship of those parameters to postoperative anastomotic or stoma complications was analyzed.

Pulse oximetry

The principle of pulse oximetry is based on two light sources with different wavelengths (660 nm and 940 nm) emitted through the cutaneous vascular bed of a finger or earlobe. The Hb absorbs more light at 660 nm and HbO2 absorbs more light at 940 nm. A detector at the far side measures the intensity of the transmitted light at each wavelength and the arterial oxygen saturation (SpO_2) is derived by the ratio between the red light (660 nm) and the infrared light (940 nm) absorbed[7]. Erikoglu *et al* and DeNobile *et al* measured oxygen saturation of the bowel by pulse oximetry and investigated the relationship between these measures and concomitant pathological grading. They found that intraoperative evaluation of intestinal viability by pulse oximetry may give an idea about the degree of pathological changes[8,9]. MacDonald and coworkers supported the notion that a pulse oximeter has the potential to be of value in the intraoperative assessment of intestinal blood flow[10]. A reflectance pulse oximetry of the colon mucosa was applied in an animal model during aortic reconstruction. It was shown to be useful in monitoring the blood flow of the distal colon[11]. Pulse oximetry has been shown to be applicable as an adjunct technique in the assessment of small bowel ischemia in a patient with a strangulated ileus[3]. In a recent study, a novel reflectance pulse oximetry technique was introduced for intraoperative measurements of SpO_2 in the esophagus and large bowel. The method has been proven to be able to measure SpO_2 continuously in patients with a compromised peripheral perfusion[12]. However, according to Hadley and Mars, pulse oximeters do not measure blood flow or tissue viability; they only measure hemoglobin saturation. A low oximeter reading in the limbs would usually be interpreted as a reflection of inadequate central oxygenation and the authors doubt that the pulse oximetry readings taken from the bowel are different from that taken from the limbs. They agree that pulse oximetry could be, at best, an adjunct to established techniques[13]. Dyess *et al*[14] argued against the clinical value of pulse oximetry given it was found to result in a high rate of false-negative and false-positive evaluations.

Polarographic measurement of oxygen tension

The principle of tissue oxygen tension (PtO_2) measurements relies on the reduction of molecular oxygen at a noble metal cathode affecting the current set-up in a polarized circuit. The current that is set up by the probe is linearly dependent on the partial pressure of oxygen in the tissue being measured. The PtO_2 is an extravascular parameter as oxygen in the tissue is measured after capillary gas exchange. It correlated well with StO_2 and IVM findings under stable respiratory conditions[15]. Sheridan *et al* measured PtO_2 on the colon of 50 patients undergoing colonic resection and anastomosis and found the decreasing PtO_2 levels at the colonic serosa to be predictive of anastomotic leakage[16]. Conversely, in a study by Jacobi *et al,* no decrease of the submucosal PtO_2 was seen in patients with anastomotic insufficiency after esophageal resections. Even increased PtO_2 values were observed in the anastomotic leakage group[17]. These controversial findings have led to doubts about the role of impaired tissue oxygenation in anastomotic healing.

Near-infrared and visible light spectrophotometry

Spectrophotometry (spectroscopy) uses the principles of light transmission and absorption to measure the concentrations of Hb oxygen saturation in tissues (StO_2). The amount of light passing through the substance is dependent upon the wavelength; thus, near-infrared and visible light have different characteristics for spectrophotometry.

Visible light spectrophotometry (VLS) relies on locally absorbed, shallow-penetrating visible light at 475-625 nm wavelengths and the near-infrared is the part of the spectrum with wavelengths just above the visible, typically beginning at 700-730 nm wavelengths. Visual light penetrates approximately 2 mm into the tissue, whereas near-infrared light has a deeper penetration. As a result, near-infrared spectrophotometry (NIRS) provides a global assessment of oxygenation in all vascular compartments (arterial, venous and capillary) and VLS is designed for monitoring of StO_2 in the capillaries[7,18]. In combination with an intravenous dye injection, NIRS can be used to directly measure perfusion [19]. Visible light spectroscopy is similar to NIRS in that the mean VLS StO_2 is in accordance with NIRS StO_2 (bias VLS–NIRS -1 ± 5%; P = NS)[20].

The spectroscope or oximeter emits low-powered white or near-infrared light from a handheld or endoscopic probe placed near or on the bowel wall. The light penetrates and diffuses and reemerges colored according to the oxygenation level (StO_2). Tissue Hb is estimated as [deoxyhemoglobin + oxyhemoglobin], and the tissue Hb oxygen saturation (StO_2) is determined as [oxyhemoglobin]/[deoxyhemoglobin + oxyhemoglobin][20]. VLS and NIRS have been applied in recent studies.

Hirano and colleagues measured bowel StO_2 at the serosa using NIRS in a pilot study[21]. StO_2 was measured at the anastomotic site of the bowel in 20 patients during colorectal resections for colorectal cancer. It was shown that StO_2 of the anastomotic site can be safely and reliably measured by NIRS during colorectal surgery. Low StO_2 on both sides of the anastomosis may indicate an increased risk of anastomotic complications, although further study is needed to determine the cutoff value for StO_2 to prevent serious complications.

Lee and colleagues assessed colon mucosal oxygen saturation during aortic reconstruction surgery in a prospective observational study of 25 patients using a VLS oximeter with an endorectal spectrophotometer probe. In their opinion, intraoperative VLS is a sensitive measure and persistently low colon mucosal oxygen saturation suggests colon ischemia and a threat of colon infarction[22].

Karliczek *et al* evaluated the predictive value of VLS for anastomotic leakage of the colon and the rectum in 77 patients undergoing colorectal resections in a prospective observational study[1]. StO_2 levels in colonic tissue were shown to be stable and reproducible. Rising values of colon serosal StO_2 were observed at the anastomotic site of the bowel after the construction of anastomosis. The mean StO_2 value at the proximal anastomotic end in the group of patients who healed uneventfully was 72.1 ± 9.0% and it increased to 76.7 ± 8.0% after construction of the anastomosis. The authors speculate that the underlying mechanism of increasing tissue oxygenation is a response to ischemic preconditioning caused by manipulating the bowel. There was no rising StO_2 in anastomoses that ultimately leaked. In anastomoses showing leakage, a significantly lower StO_2 was recorded in the cecum (73.6 ± 5.7 in non-leakage *vs* 69.6 ± 5.6 in leakage group).

Compared to VLS, the minimal sampled volume of the tissue by NIRS is relatively large, whereas in VLS the point measurements of small tissue samples are possible[1,18]. Advocates of VLS claim that a shallow penetrating visible light is more appropriate for the measurements of bowel wall oxygenation[1]. Another advantage of VLS is that, compared with NIRS, the normal range is significantly narrower: ± 3% *vs* ± 9% respectively[20,23]. A tissue contact is not required in VLS measurements as the instrument corrects for an uneven baseline and the full light spectrum is analyzed[1]. This is a great advantage compared to other techniques such as polarographic or tonometry measurements, NIRS or laser Doppler flowmetry (LDF) where the probe opposition to the tissue leads to decreased perfusion and StO_2[20]. Although there are no comparison studies, VLS is a newer technique for bowel oxygenation measurement, applied in the majority of studies and seems to be more promising.

Oximetry has a number of drawbacks. Firstly, a specific level of StO_2 that leads to intestinal tissue ischemia has not been defined to date. In studies where VLS of the skin was applied, the critical StO_2 level of microsurgical flap perfusion was between 10% and 15% and a level of 15% saturation has been shown to be clinically sensitive and specific in determining amputation level[24,25]. Secondly, there is no uniformity in StO_2 measurements as different algorithms are used by different oximetry systems for estimating StO_2. A variety of VLS and NIRS equipment is available where the measurements are performed with different amount of wavelengths and also at different wavelengths of light[7,26,27]. Thirdly, the reproducibility of the results can be affected by the presence of bile, stool or food within the intestine which can interfere with the passage of light when measurements are taken at the mucosa. Also, the optimal angle of the probe relative to the tissue is 90° and a different angle can lead to inaccurate measurements[28]. Measurements are not always feasible for colorectal anastomoses within 5 cm from the anal verge or when the site of measurement is situated behind sponges and retractors[1]. Finally, prices of the oximetry systems are currently high.

Intravital microscopy

Intravital microscopy (IVM) has been considered a gold standard for microcirculatory research because it can directly visualize and quantify changes at the capillary level using fluorescent-labeled plasma or blood cells[15]. Yasumura *et al* performed microscopy of the serosal bowel layer and calculated the ratio of blood cell transition and the effective area of the vascular bed. These parameters were found to be useful indices for prediction of bowel survival[29]. This technique has not yet been introduced into human studies, probably because it is time consuming.

Doppler ultrasound

In earlier studies, intraoperative Doppler ultrasound of the marginal arteries was believed to be a more reliable

intraoperative predictor of intestinal viability than clinical assessment alone[30]. The authors favored the low costs and simplicity of the technique and suggested its adjunctive use[31]. In a study of 117 patients undergoing intestinal anastomosis or enterostomy, a Doppler ultrasound was applied to determine the adequacy of blood supply at the margins of resection. No postoperative complications were experienced when relying on a Doppler signal[32]. In a more recent series of colorectal resections in 200 patients, only 1% incidence of anastomotic insufficiency was observed when the bowel ends to be resected were assessed with a Doppler ultrasound[33]. Conversely, other authors observed that this adds little if anything to clinical judgment[34]. Sensitivity of Doppler ultrasound of 86% was shown in an experimental study which was significantly lower than that of laser Doppler and perfusion fluorometry[31]. Doppler ultrasonography resulted in a high rate of false-negative and false-positive results in an experimental study by Dyess *et al*[14]. The superiority of laser Doppler flowmetry compared with ultrasound studies was shown[35]. Widely discussed limitations of this technique are that it is considered to be vulnerable to the signals from the neighboring large vessels, it requires an artery exposure and a pulsatile blood flow and a tissue contact is required which can impair local blood flow[1,29].

Hydrogen gas clearance

Hydrogen gas clearance was attempted for intestinal microcirculation assessment in earlier experimental studies[36,37,38]. The basic paradigm of hydrogen clearance consists of inserting a positively polarized electrode into tissue, administering H2 either by respiration or intra-arterially, allowing the H2 to be cleared from arterial blood, and then monitoring the exponential clearance rate of H2 from the tissue [39]. This technique has been validated for measuring blood flow in different organs; however, it is not used routinely for evaluation of intestinal ischemia due to its invasiveness, inconvenience and insufficient accurateness[21, 29].

Radioisotope studies

Radioisotopes were used in earlier studies to quantify the perfusion at the anastomotic or ischemic site of the bowel. In animal and human studies, intraperitoneal[40], intravenous[41,42], intra arterial[43] or local submucosal[44] injections of radioisotopes were applied to monitor ischemic sites and blood flow in the intestine or anastomosis. Disadvantages of radioactive isotopes are exposure to radiation for both the patient and personnel, the technique is expensive in terms of storage and disposal and it is rather cumbersome[45]. These are the possible causes why this technique is not employed at present.

Fluorescence studies

Two techniques, the perfusion fluorometry and laser fluorescence angiography (LFA), have been applied for evaluation of intestinal viability. Perfusion fluorometry was tried in animal and human studies and gained wide acceptance in the diagnosis of acute bowel ischemia in earlier studies. Here, the sodium fluorescein is administered intravenously and the bowel is illuminated with an ultraviolet light investigating the perfusion. It can be used both for a laparotomy when the source of UV light is a Wood's lamp as well for laparoscopy when the optical filters are placed to the light source of the laparoscopic set to produce UV light[46-50]. The earlier studies applied qualitative fluorometry and in the more recent studies, a fiberoptic fluorometry technique was introduced to measure the blood flow in dye fluorescence units. Its superiority over the qualitative technique was shown[50,51]. Previous studies reported adverse reactions of intravenous fluorescent dye injections, even anaphylactic reactions with fatal outcomes[52,53]. However, a recent international multicenter study has shown intravenous administration of fluorescein to be safe for a confocal laser endomicroscopy of the gastrointestinal tract[54]. The major drawback of fluorometry is the inability to perform repeated measurements since the fluorescein sticks around once it gets into the tissue[50]. Very large standard deviations of quantitative fluorometry measurements were observed, showing insufficient accuracy of the technique[51]. Some authors argued that the viability is not measured directly by fluorometry; it can also be overpredictive of nonviability and lead to unnecessary resections, particularly in patients with the isolated venous occlusion[34,50].

Recently a more sophisticated method, LFA, has been validated for intestinal microcirculation assessment. The method is based on intravenous injection of fluorescent dye (indocyanine green) and illumination of the bowel at the site of interest with a laser light. Digital videos of the fluorescence are recorded as a function of tissue perfusion[55]. The system is reliable and the measurements can be repeated after the rapid clearance of the fluorescent dye by hepatic uptake and biliary excretion. This is an advantage compared to the conventional perfusion fluorometry. In a study by Kudzsus *et al*[2], the predictive value of LFA was analyzed in a retrospective matched-pairs analysis. Measurements by LFA led to extended resections of malperfused intestine in 14.2% of patients, avoiding leaving nonviable bowel *in situ*. In 2% of the cases, resection of the viable bowel could be avoided. The use of intraoperative LFA reduced the risk of revision due to anastomotic leakage by 60% in patients undergoing elective colorectal surgery irrespective of their age and by 64% in patients above the age of 70. Hand-sewn anastomosis controlled by LFA reduced the risk of revision by 84% compared to the same anastomotic technique without LFA. The authors recommend the technique for routine use in clinical practice. However, the technique has limitations too: the contents of the intestine can interfere with fluorescence and the limiting values of LFA representing irreversible necrosis are not yet defined. The low LFA values were not consistent with pathological grade of ischemia in an animal model [50]. Moreover, the measurements are position dependent and not applicable for the assessment of colorectal anastomosis situated in the minor pelvis[1,3,56].

Infrared imaging

Thermal or infrared imaging is a scanning technique for recording small temperature differences between adjacent structures on a photographic display. The current medical application of thermal imaging is mainly limited to the detection of peripheral circulatory disturbances or breast cancer and to assess graft patency in plastic or cardiac surgery. Low surface temperature can be interpreted to be the poor vascularization that may cause an anastomotic impairment[57].

Thermal imaging was applied for assessment of the intestinal blood supply in several studies. The first study investigating a reactive bowel hyperemia after an ischemia and reperfusion was published in 1978[58]. Brooks *et al*[59] compared thermal imaging to visual inspection, Doppler ultrasound and fluorescence with Wood's lamp. All methods had a high positive predictive value in detecting bowel ischemia, except the visual inspection which was the only method unable to detect a difference between vascularized and devascularized bowel. Doppler ultrasound and thermal imaging were 100% sensitive for a necrotic bowel[59]. Roberts *et al* showed that infrared imaging is a potential tool for localizing anatomic structures and assessing tissue viability during laparoscopic surgical procedures in a porcine model[60]. Nishikawa *et al* examined the use of intraoperative thermal imaging to assess gastric vascularization and gastric tube viability in patients during esophagectomy. They found intraoperative thermal imaging to be a noninvasive and reliable technique[57]. However, this is an indirect indicator of perfusion and oxygenation and the measurements are dependent on ambient temperature.

Laser Doppler flowmetry

The principle of Laser Doppler flowmetry (LDF) is to measure the Doppler shift — the frequency change that light undergoes when reflected by moving objects such as red blood cells. LDF works by illuminating the tissue under observation with a monochromatic laser from a probe. When the tissue is illuminated, only 3%–7% of the light is reflected. The remaining 93%–97% is either absorbed by various structures or undergoes scattering. Another optical fiber collects the backscattered light from the tissue and returns it to the monitor. As a result, LDF produces an output signal that is proportional to the number of blood cells moving in the measured volume X mean velocity of the cells[61]. The measurements are expressed as mL/min per l00 g of tissue.

Vignali *et al* tested the reliability of intraoperative LDF measurements in predicting the occurrence of anastomotic leak in patients with colorectal cancer[62]. In a prospective study of 55 patients, the transmural colonic blood flow was measured during different stages of large bowel resection. Mean rectal stump flow reduction of 6.2% and proximal stump flow reduction of 5.1% was detected. The cut-off values of flow reduction, indicative of anastomotic insufficiency, were 16% and 12.9% respectively.

LDF measurements were also applied by Seike *et al*[5]. Colonic blood flow at the proximal site of the anastomosis was measured by LDF in 96 patients with cancer of the rectum and sigmoid colon while clamping inferior mesenteric artery (IMA) or left colic artery (LCA). Blood flow measured by LDF was significantly decreased by clamping the arteries. The flow reduction rate by IMA clamping was completely dependent on the individual patient and varied from zero to more than 80%. The study suggests that patients demonstrating significant decrease in blood flow by IMA clamping (more than 50%) may be at risk for the anastomotic ischemia. In such cases, the authors recommend preservation of LCA.

Nakatsuka measured gastric mucosal pH by a gastric tonometry and colonic tissue blood flow at the serosal layer by LDF during infrarenal abdominal aortic surgery in a prospective comparison study of eight patients[63]. In this study, the borderline value 41.7 ± 7.4 mL/min per l00 g of the sigmoid colonic tissue blood flow determined by LDF was detected which is sufficient to prevent postoperative ischemic colitis. Decrease of gastric mucosal pH measured by a gastric tonometry was not clinically significant and it did not reflect changes in intestinal microcirculation following aortic cross-clamping.

Singh and coworkers investigated VLS and LDF for assessing bowel serosal and mucosal oxygenation and blood flow in a pilot study of seven patients during different stages of colon surgery[64]. The authors found that the mean sigmoid mucosal StO_2 decreased after ligation of inferior mesenteric artery from the baseline of 73% to 55%. After complete devascularization, the mean sigmoid mucosal StO_2 was reduced to 39%. The mean sigmoid mucosal flux decreased after ligation of inferior mesenteric artery and it further decreased after complete devascularization. A similar trend was seen on the serosal flux measurements. In contrast, sigmoid serosal StO_2 measured by VLS did not decrease after ligation of inferior mesenteric artery and it decreased only slightly after complete devascularization from a baseline of 86% to 79%. The authors believe that mucosal StO_2 measurements by VLS can accurately diagnose bowel ischemia but serosal StO_2 measurements do not reflect a mucosal ischemia. Doppler flux measurements could be useful in detecting ischemia from the serosal surface of the bowel.

A major limitation of LDF is that it does not take into account the heterogeneity of blood flow as the velocity measurements represent the average of velocities in all vessels of the window studied.

LDF data are affected by motion artifacts in recording sites. In measurements of the oral mucosa, mucosa and serosa of the colon, large standard deviations of the flow parameters were observed[64,65]. Continuous measurement holding the probe securely may be necessary to overcome this limitation[5]. Pulsatile blood flow is required as the blood flow is measured in the deeper layers of the bowel containing arterioles. Changes in the patient's cardiovascular status caused by intraoperative blood loss or drug administration through epidural anesthesia can also influence the measurements by LDF and might be time consuming since repeated measurements are necessary[5,21]. LDF re-

quires tissue contact and may disturb local blood flow[1]. Scanning LDF was proposed for intraoperative use to overcome the limitations of single-point LDF[66,67]. In an animal study, this technique has been shown to have a significant relationship with histological grade of ischemia[68]. However, it is time consuming since the time needed to produce a perfusion image may be several minutes. The probability that movement artifacts will degrade the image quality increases with acquisition time[69]. The cut-off level of flow indicative of intestinal ischemia varies in different studies. In an animal study, a value of 30% of flow in the intact colon measured by LDF was considered to be safe for anastomotic healing[70]. In human studies, much lower decreases in LDF values showed risk of ischemia. The perfusion units are arbitrary and rather qualitative. Further studies are needed to create references in order to have quantitative values, the tools for distinction between capillary and global tissue perfusion and the tools providing measurements avoiding motion artifacts[69].

Bowel wall contractility measurements

In 1986, the electronic contractility meter (ECM) was introduced as a quantitative method of measuring contractile activity of ischemic bowel. The ECM consists of two major components, a specially designed probe and an electronic control unit. The probe is clipped onto the serosal surface of the bowel and the electromyogram reflecting peristalsis of the small intestine is recorded at each 2 cm interval and quantified in millivolts by a computer algorithm[71]. Low electromyography (EMG) values referred to ischemic damage of the submucosal neuromuscular plexus[72].

Brolin *et al* have applied EMG, Doppler ultrasound and perfusion fluorometry. They showed that EMG might be a more sensitive indicator of ischemic damage than either ultrasonography or perfusion fluorometry in a model of acute intestinal ischemia[72,73]. However, after reperfusion, a slow increase of EMG values was observed and after 15 min normal values were reached. This shows the technique to be time consuming when no definitive necrosis of the intestine is present and the site of bowel resection must be determined. Also, the limit values of bowel wall contractility are not precise. Brolin *et al*[72] considered 50% of the contractility of a normal bowel to be sufficient for the anastomotic healing in a dog model. However, extrapolation to human conditions might be difficult considering that the bowels of different species are not equally resistant to ischemia. Electromyography has been used clinically in a study by Dutkiewicz *et al*[74]. Myoelectrical small bowel activity was measured intraoperatively in patients with and without small bowel ischemia. The diminished myoelectrical activity of the ischemic bowel wall was observed, which well correlated with histological changes[74]. It has not found a wider clinical acceptance, probably due to many unanswered questions and the complexity of the technique.

pH measurement

Tonometry is a noninvasive method to determine the intramucosal pH (pHi) in hollow organs which correlates with the oxygen supply to the mucosa. During mucosal hypoperfusion, acidosis develops, thereby resulting in a decrease of pHi. The tonometer is a silicone balloon catheter which is introduced into the lumen of the gut, then filled with isotonic sodium chloride solution and allows the free diffusion of carbon dioxide (CO_2). After an equilibration period, pCO_2 of the saline filling the balloon is proportionate to the intestinal mucosal pCO_2. This value and that of the arterial bicarbonate are then used in the Henderson-Hasselbach equation to calculate the intramucosal pH: $pHi = 6.1 + \log10 [(HCO_3)/(0.03 \times pCO_2 \times F)]$, in which F is a time-dependent correction factor and $[HCO_3]$ is the actual bicarbonate concentration (mmol/L) of the arterial blood sample[75,76].

Kamiya and coworkers monitored pHi levels in the intestinal lumen using a tonometer intraoperatively and after the operation[75]. 35 patients who underwent free jejunal transfer following pharyngolaryngoesophagectomy for laryngeal, hypopharyngeal and cervical esophageal cancer were enrolled in the prospective observational study. The critical value of pHi < 7.10 was detected which leads to jejunal graft microcirculation disturbance and graft necrosis. It was shown that pHi measurement using a tonometer is useful for finding vascular problems in free jejunal grafts.

Millan, in a prospective study of 90 patients with colorectal resections, determined pHi levels at 24 and 48 h postoperatively and found that pHi<7.28 in the first 24 h postoperatively is associated with 22 times higher risk of anastomotic leak [76].

Despite being an accurate technique, tonometry is rather used for postoperative monitoring of bowel ischemia[76-78]. The necessity of leaving the catheters in situ may be considered a shortcoming of the technique.

Microdialysis

Deeba *et al*[77] employed a momental intramural microdialysis to measure glucose and lactate levels in the bowel wall of specimens being resected intraoperatively and to monitor bowel ischemia in seven patients. After mobilization and before transecting any feeding vessel, a microdialysis probe was tunneled in the seromuscular layer of the left colon and fixed in place. Glucose and lactate concentrations were monitored until the bowel specimen was removed. After the transection of the feeding arteries, the glucose concentrations decreased whereas lactate concentrations increased leading to increase of lactate/glucose ratio. The study demonstrated the feasibility of using the microdialysis system in clinical practice. The authors suggest implanting the catheter near a bowel segment that is of questionable viability and to tunnel it outside the abdomen for postoperative bedside monitoring to alert the physician before ischemia manifests clinically.

Assessment of electrical properties

Matsuo *et al*[79] evaluated the viability of a strangulated intestine by measuring its electrical properties in an experimental study. Correlation of changes in dielectric

Table 1 Intraoperative quantitative assessment of intestinal viability, overview of studies from 2000 to 2010

Author, year of publication	Type of study and number of patients	Type of surgery	Technique for assessment	Site of measurement	Measured units
Vignali *et al*, 2000[62]	Prospective observational study of 55 patients	Rectosigmoid resection for cancer	LDF	Serosa of rectal and sigmoid colon stump	Blood flow (perfusion units [1])
Seike *et al*, 2007[5]	Prospective observational study of 96 patients	Rectosigmoid resection for cancer	LDF	Serosa of sigmoid colon stump	Blood flow (ml/min/100g)
Nakatsuka, 2002[63]	Prospective observational study of 8 patients	Abdominal aorta operations	LDF	Serosa of the sigmoid colon	Blood flow (ml/min/100g)
Singh *et al*, 2009[64]	Pilot study of 7 patients	Left side colon resections for cancer and benign conditions	LDF and VLS	Serosa and mucosa at the anastomotic site	Flux units and StO2(%)
Lee *et al*, 2006[22]	Prospective observational study of 25 patients	Abdominal aorta operations	VLS	Rectal mucosa	StO2 (%)
Karliczek *et al*, 2009[1]	Prospective observational study of 77 patients	Rectosigmoid resection for cancer	VLS	Rectosigmoid serosa at the anastomotic site within 25 cm from the anal verge	StO2 (%)
Hirano *et al*, 2006[21]	Pilot study of 20 patients	Ileocecal, colon and rectal resections for cancer	NIRS	Serosa at the anastomotic site	StO2 (%)
Kudszus *et al*, 2010[2]	Retrospective matched-pairs analysis of 638 patients	Colon resections for colon cancer and benign conditions	LFA	Serosa at the anastomotic site	Perfusion index based on fluorescence
Kamiya *et al*, 2007[75]	Prospective observational study of 35 patients	Jejunal transfer for esophageal resections	Tonometry	Jejunal graft mucosa	Mucosal pH
Deeba *et al*,2008[77]	Prospective observational study of 7 patients	Left colectomy	Rapid sampling microdialysis	Colon serosa	Glucose and lactate concentration, lactate/ glucose ratio

parameters with intestinal ischemia was found. Values suggesting the need for resection of the nonviable bowel were found; however, no intermediate value showing the possible recovery could be determined.

CLINICAL APPLICATION OF THE METHODS

Horgan and Gorey defined the requirements of an ideal bowel viability test: 1) The technique must have ready availability, preferably in every operating theater dealing with abdominal emergencies; 2) The necessary equipment must not be cumbersome or require specialized personnel; 3) The method must be accurate with a minimum of false-negative results and, more importantly, few false positives; 4) The technique must be objective and reproducible; and 5) The method must be cost effective[80].

Despite numerous techniques are available as aforementioned, only several have been used in human studies over the last ten years (Table 1). There is no agreement as to which method is the most accurate and best applicable. Some of the techniques are applicable for postoperative follow-up of intestinal microcirculation (tonometry and rapid sampling microdialysis). Various parameters are measured by different methods and the most widely used are those reflecting oxygenation and perfusion, measured by VLS and LDF respectively. Considering that oxygenation and perfusion would probably have to be both evaluated intraoperatively, these two techniques seem to be the most promising. However, only one study has made comparison between the LDF and VLS and the oximetry has not been compared to other techniques of intestinal viability assessment[64]. No cut-off values of parameters indicative of intestinal ischemia have been determined yet. Several authors obtained different results applying the same technique. So far, there is no method that would fulfill all requirements stated by Horgan and Gorey.

Site of measurements

It has been estimated that blood flow in the mucosal and submucosal layers accounts for 70% of total blood flow in intestinal tissues; therefore, microcirculation should be

evaluated in mucosal and submucosal layer[81]. In other experimental studies using LDF and hydrogen gas clearance, a strong correlation between submucosal and subserosal blood flow was shown[38,82]. It was also confirmed in human studies[1,20,21,63,64,77]. Brolin *et al*[72] observed that in an ischemia model, extensive mucosal damage does not consistently result in bowel infarction and suggested that the measurements should be obtained from the serosal surface. This led to less invasive microcirculation assessment at the serosa of the intestine[39]. However, measurements performed by different authors and different systems yield unequal results. Karliczek *et al* have shown the reproducible measurements at the serosa of the resected bowel end whereas Singh *et al* have showed that the serosal StO_2 measurements are not sensitive to ischemia and are only possible at the mucosa. Moreover, different baseline values of serosal StO_2 were detected by the studies, 72.1 ± 9.0% and 86 ± 7.3% respectively[1,64]. The authors used different oximeter systems and the inter-device variability could possibly be the reason for the different results.

Evaluation of intestinal stoma viability

There are multiple risk factors predisposing stoma complications, including smoking, diabetes, grade of operating surgeon and emergency procedure. Necrosis is very important among other stoma complications. An insufficient perfusion and ischemia of the resected bowel end is one of the predisposing risk factors. In a prospective observational study of 97 patients with a newly created intestinal stoma, three patients developed necrosis and two experienced ischemia of their stoma[83]. In a nationwide prospective audit in the UK, the observed frequency of stoma necrosis was 8.7%[84]. The incidence of stoma ischemia and necrosis could be potentially diminished by objective intraoperative evaluation of stoma viability and timely surgical correction. However, it relies mainly on subjective intraoperative findings. Adequacy of blood supply at the enterostomy resection margin was assessed by Doppler ultrasound in a previous study[32]. In two studies, stoma microcirculation was assessed postoperatively. Boerma and coworkers compared sublingual and stoma microcirculation using orthogonal polarization spectral imaging technique in patients with abdominal sepsis[85]. The method has been validated previously for microcirculatory research in sepsis patients[86]. There was neither correlation between intestinal and sublingual blood flow, nor between intestinal and systemic hemodynamic parameters in abdominal sepsis patients on day one of sepsis and on day three this correlation appeared to be restored. These findings suggest that intestinal microcirculation cannot always be judged from the parameters of other microcirculatory beds or systemic hemodynamic parameters. Singh and Harrison investigated tissue oxygen saturation in end colostomy stomas with a minimum age of three months using a visible light spectroscopy. The normal oxygenation value of 77.6 ± 6.8 was detected. There were no significant diurnal variations in the stomal oxygenation values[87].

Importance of systemic hemodynamics

Düchs and Foitzik analyzed the influence of systemic hemodynamics on microcirculatory parameters. The authors used three techniques in parallel: an intravital bowel mucosal microscopy for the measurement of capillary blood flow, a spectroscopy for the measurement of Hb oxygen saturation in the tissue and a polarographic measurement of mucosal pO_2. Capillary blood flow of the bowel mucosa measured by intravital microscopy did not demonstrate insufficient oxygen supply of the tissue under systemic hypoxia. This was demonstrated by another two techniques. Comparing microcirculation measurements by the three methods, the authors observed that the extent to which hypovolemia and hypoxia influence these parameters is different. Moreover, a poor correlation between measurements by the different methods was found. In conclusion, the mean arterial pressure, blood gases and hematocrit must be analyzed to correctly interpret microcirculatory parameters [15].

CONCLUSION

Although numerous objective quantitative techniques of intraoperative bowel viability assessment are available, only a few are applicable in gastrointestinal surgery. VLS and LDF have been the most frequently used in humans over the last decade. The majority of methods are still far from ideal. Further studies are needed to determine the limiting values of tissue oxygenation and flow indicative of ischemic complications and to standardize the methods. Rapid progression in development of new instruments and techniques will hopefully help to solve these problems.

REFERENCES

1 **Karliczek A**, Benaron DA, Baas PC, Zeebregts CJ, Wiggers T, van Dam GM. Intraoperative assessment of microperfusion with visible light spectroscopy for prediction of anastomotic leakage in colorectal anastomoses. *Colorectal Dis* 2010; **12**: 1018-1025

2 **Kudszus S**, Roesel C, Schachtrupp A, Höer JJ. Intraoperative laser fluorescence angiography in colorectal surgery: a noninvasive analysis to reduce the rate of anastomotic leakage. *Langenbecks Arch Surg* 2010 ;**395**:1025-1030

3 **La Hei ER**, Shun A. Intra-operative pulse oximetry can help determine intestinal viability. *Pediatr Surg Int* 2001; **17**: 120-121

4 **Karliczek A**, Harlaar NJ, Zeebregts CJ, Wiggers T, Baas PC, van Dam GM. Surgeons lack predictive accuracy for anastomotic leakage in gastrointestinal surgery. *Int J Colorectal Dis* 2009; **24**: 569-576

5 **Seike K**, Koda K, Saito N, Oda K, Kosugi C, Shimizu K, Miyazaki M. Laser Doppler assessment of the influence of division at the root of the inferior mesenteric artery on anastomotic blood flow in rectosigmoid cancer surgery. *Int J Colorectal Dis* 2007; **22**: 689-697

6 **Dworkin MJ**, Allen-Mersh TG. Effect of inferior mesenteric artery ligation on blood flow in the marginal artery-dependent sigmoid colon. *J Am Coll Surg* 1996; **183**: 357-360

7 **Lima A**, Bakker J. Noninvasive monitoring of peripheral perfusion. *Intensive Care Med* 2005; **31**: 1316-1326

8 **Erikoglu M**, Kaynak A, Beyatli EA, Toy H. Intraoperative determination of intestinal viability: a comparison with transserosal pulse oximetry and histopathological examination. *J Surg Res* 2005; **128**: 66-69

9 **DeNobile J**, Guzzetta P, Patterson K. Pulse oximetry as a means of assessing bowel viability. *J Surg Res* 1990; **48** : 21-23

10 **MacDonald PH**, Dinda PK, Beck IT, Mercer CD. The use of oximetry in determining intestinal blood flow. *Surg Gynecol Obstet* 1993; **176**: 451-458

11 **Gardner GP**, LaMorte WW, Obi-Tabot ET, Menzoian JO. Transanal intracolonic pulse oximetry as a means of monitoring the adequacy of colonic perfusion. *J Surg Res* 1994; **57**: 537-540

12 **Phillips JP**, Kyriacou PA, Jones DP, Shelley KH, Langford RM. Pulse oximetry and photoplethysmographic waveform analysis of the esophagus and bowel. *Curr Opin Anaesthesiol* 2008; **21**: 779-783

13 **Hadley GP**, Mars M. Limitations of oximeters. *Pediatr Surg Int* 2003; **19**: 130

14 **Dyess DL**, Bruner BW, Donnell CA, Ferrara JJ, Powell RW. Intraoperative evaluation of intestinal ischemia: a comparison of methods. *South Med J* 1991; **84**: 966-99, 974

15 **Düchs R**, Foitzik T. Possible Pitfalls in the Interpretation of Microcirculatory Measurements. *Eur Surg Res* 2008; **40**: 47–54

16 **Sheridan WG**, Lowndes RH, Young HL. Tissue oxygen tension as a predictor of colonic anastomotic healing. *Dis Colon Rectum* 1987; **30**: 867-871

17 **Jacobi CA**, Zieren HU, Zieren J, Müller JM. Is tissue oxygen tension during esophagectomy a predictor of esophagogastric anastomotic healing? *J Surg Res* 1998; **74**: 161-164

18 **Benaron DA**, Parachikov IH, Cheong WF, Friedland S, Rubinsky BE, Otten DM, Liu FW, Levinson CJ, Murphy AL, Price JW, Talmi Y, Weersing JP, Duckworth JL, Hörchner UB, Kermit EL. Design of a visible-light spectroscopy clinical tissue oximeter. *J Biomed Opt* ; **10**: 44005

19 **Posma LA**, Hendriks T, Verhofstad AA, de Man BM, Lomme RM, Bleichrodt RP. Reduction of oxygenation and blood flow in pedicled bowel segments in the rat and its consequences for anastomotic healing. *Dis Colon Rectum* 2010; **53**: 93-100

20 **Benaron DA**, Parachikov IH, Friedland S, Soetikno R, Brock-Utne J, van der Starre PJ, Nezhat C, Terris MK, Maxim PG, Carson JJ, Razavi MK, Gladstone HB, Fincher EF, Hsu CP, Clark FL, Cheong WF, Duckworth JL, Stevenson DK. Continuous, noninvasive, and localized microvascular tissue oximetry using visible light spectroscopy. *Anesthesiology* 2004; **100**: 1469-1475

21 **Hirano Y**, Omura K, Tatsuzawa Y, Shimizu J, Kawaura Y, Watanabe G. Tissue oxygen saturation during colorectal surgery measured by near-infrared spectroscopy: pilot study to predict anastomotic complications. *World J Surg* 2006; **30**: 457-461

22 **Lee ES**, Bass A, Arko FR, Heikkinen M, Harris EJ, Zarins CK, van der Starre P, Olcott C. Intraoperative colon mucosal oxygen saturation during aortic surgery. *J Surg Res* 2006; **136**: 19-24

23 http: //www.spectros.com/index.php?id=53

24 **Schultze-Mosgau S**, Wiltfang J, Birklein F, Neukam FW. Micro-lightguide spectrophotometry as an intraoral monitoring method in free vascular soft tissue flaps. *J Oral Maxillofac Surg* 2003; **61**: 292-27; discussion 297

25 **Harrison DK**, Hawthorn IE. Amputation level viability in critical limb ischaemia: setting new standards. *Adv Exp Med Biol* 2005; **566**: 325-331

26 **Myers DE**, Anderson LD, Seifert RP, Ortner JP, Cooper CE, Beilman GJ, Mowlem JD. Noninvasive method for measuring local hemoglobin oxygen saturation in tissue using wide gap second derivative near-infrared spectroscopy. *J Biomed Opt* 2005; **10**: 034017

27 **Hirano Y**, Omura K, Yoshiba H, Ohta N, Hiranuma C, Nitta K, Nishida Y, Watanabe G. Near-infrared spectroscopy for assessment of tissue oxygen saturation of transplanted jejunal autografts in cervical esophageal reconstruction. *Surg Today* 2005; **35**: 67-72

28 **Myers C**, Mutafyan G, Petersen R, Pryor A, Reynolds J, Demaria E. Real-time probe measurement of tissue oxygenation during gastrointestinal stapling: mucosal ischemia occurs and is not influenced by staple height. *Surg Endosc* 2009; **23**: 2345-2350

29 **Yasumura M**, Mori Y, Takagi H, Yamada T, Sakamoto K, Iwata H, Hirose H. Experimental model to estimate intestinal viability using charge-coupled device microscopy. *Br J Surg* 2003; **90**: 460-465

30 **Cooperman M**, Martin EW Jr, Carey LC. Evaluation of ischemic intestine by Doppler ultrasound. *Am J Surg* 1980; **139**: 73-77

31 **Lynch TG**, Hobson RW, Kerr JC, Brousseau DA, Silverman DG, Reilly CA, Tseng H. Doppler ultrasound, laser Doppler, and perfusion fluorometry in bowel ischemia. *Arch Surg* 1988; **123**: 483-486

32 **Cooperman M**, Martin EW Jr, Keith LM, Carey LC. Use of Doppler ultrasound in intestinal surgery. *Am J Surg* 1979; **138**: 856-859

33 **Ambrosetti P**, Robert J, Mathey P, Rohner A. Left-sided colon and colorectal anastomoses: Doppler ultrasound as an aid to assess bowel vascularization. A prospective evaluation of 200 consecutive elective cases. *Int J Colorectal Dis* 1994; **9**: 211-214

34 **Bulkley GB**, Zuidema GD, Hamilton SR, O'Mara CS, Klacsmann PG, Horn SD. Intraoperative determination of small intestinal viability following ischemic injury: a prospective, controlled trial of two adjuvant methods (Doppler and fluorescein) compared with standard clinical judgment. *Ann Surg* 1981; **193**: 628-637

35 **Rotering RH**, Dixon JA, Holloway GA, McCloskey DW. A comparison of the He Ne laser and ultrasound Doppler systems in the determination of viability of ischemic canine intestine. *Ann Surg* 1982; **196**: 705-708

36 **Aukland K**, Bower BF, Berliner RW. Measurement of local blood flow with hydrogen gas. *Circ Res* 1964; **16**: 164–187

37 **Oohata Y**, Mibu R, Hotokezawa M, Ikeda S, Nakahara S, Itoh H. Comparison of blood flow assessment between laser Doppler velocimetry and the hydrogen gas clearance method in ischemic intestine in dogs. *Am J Surg* 1990; **160**: 511–514

38 **Mishima Y**, Shigematsu H, Horie Y, Satoh M. Measurement of local blood flow of the intestine by hydrogen clearance method; experimental study. *Jpn J Surg* 1979; **9**: 63-70

39 **Young W**. H2 clearance measurement of blood flow: a review of technique and polarographic principles. *Stroke* ; **11**: 552-564

40 **Bulkley GB**, Gharagozloo F, Alderson PO, Horn SD, Zuidema GD. Use of intraperitoneal xenon- 133 for imaging of intestinal strangulation in small bowel obstruction. *Am J Surg* 1981; **141**: 128-135

41 **Hummel SJ**, Delgado G, Butterfield A, Dritschilo A, Harbert J. Measurement of blood flow through surgical anastomosis using the radioactive microsphere technique. *Obstet Gynecol* 1985; **66**: 579-581

42 **Wheeless CR**, Smith JJ. A comparison of the flow of iodine 125 through three different intestinal anastomoses: standard, Gambee, and stapler. *Obstet Gynecol* 1983; **62**: 513-518

43 **Hulten L**, Jodal M, Lindhagen J, Lundgren O. Colonic blood flow in cat and man as analyzed by an inert gas washout technique. *Gastroenterology* 1976; **70**: 36-44

44 **Forrester DW**, Spence VA, Walker WF. Colonic mucosal-submucosal blood flow and the incidence of faecal fistula

formation following colostomy closure. *Br J Surg* 1981; **68**: 541-544
45 **Frits W**. Prinzen, James B. Bassingthwaighte. Blood flow distributions by microsphere deposition methods. *Cardiovascular Research* 2000; **45**: 13–21
46 **Bergman RT**, Gloviczki P, Welch TJ, Naessens JM, Bower TC, Hallett JW, Pairolero PC, Cherry KJ. The role of intravenous fluorescein in the detection of colon ischemia during aortic reconstruction. *Ann Vasc Surg* 1992; **6**: 74-79
47 **McGinty JJ**, Hogle N, Fowler DL. Laparoscopic evaluation of intestinal ischemia using fluorescein and ultraviolet light in a porcine model. *Surg Endosc* 2003; **17**: 1140-1143
48 **Silverman DG**, Hurford WE, Cooper HS, Robinson M, Brousseau DA. Quantification of fluorescein distribution to strangulated rat ileum. *J Surg Res* 1983; **34**: 179-186
49 **Pával J**, Subrt Z, Lochman P, Ferko A, Dusek T, Slaninka I, Cecka F, Louda M, Romzová M, Jon B, Kaska M. [Peroperative diagnostics of acute bowel ischemia using ultraviolet light and fluorescein dye]. *Rozhl Chir* 2009; **88**: 590-595
50 **Holmes NJ**, Cazi G, Reddell MT, Gorman JH, Fedorciw B, Semmlow JL, Brolin RE. Intraoperative assessment of bowel viability. *J Invest Surg* ; **6**: 211-221
51 **Carter MS**, Fantini GA, Sammartano RJ, Mitsudo S, Silverman DG, Boley SJ. Qualitative and quantitative fluorescein fluorescence in determining intestinal viability. *Am J Surg* 1984; **147**: 117-123
52 **LaPiana FG**, Penner R. Anaphylactoid reaction to intravenously administered fluorescein. *Arch Ophthalmol* 1968; **79**: 161-162
53 **Cunningham EE**, Balu V. Cardiac arrest following fluorescein angiography. *JAMA* 1979; **242**: 2431–2431
54 **Wallace MB**, Meining A, Canto MI, Fockens P, Miehlke S, Roesch T, Lightdale CJ, Pohl H, Carr-Locke D, Löhr M, Coron E, Filoche B, Giovannini M, Moreau J, Schmidt C, Kiesslich R. The safety of intravenous fluorescein for confocal laser endomicroscopy in the gastrointestinal tract. *Aliment Pharmacol Ther* 2010; **31**: 548-552
55 **Toens C**, Krones CJ, Blum U, Fernandez V, Grommes J, Hoelzl F, Stumpf M, Klinge U, Schumpelick V. Validation of the ICview fluorescence videography in a rabbit model of mesenteric ischemia and reperfusion. *Int J Colorectal Dis* 2005; **19**: 1–7
56 **Willis S**, Hölzl F, Krones CJ, Tittel A, Schumpelick V. Evaluation of anastomotic microcirculation after low anterior rectal resection: an experimental study with different reconstruction forms in dogs. *Tech Coloproctol* 2006; **10**: 222-226
57 **Nishikawa K**, Matsudaira H, Suzuki H, Mizuno R, Hanyuu N, Iwabuchi S, Yanaga K. Intraoperative thermal imaging in esophageal replacement: its use in the assessment of gastric tube viability. *Surg Today* 2006; **36**: 802-806
58 **Moss AA**, Kressel HY, Brito AC. Thermographic assessment of intestinal viability following ischemic damage. *Invest Radiol* ; **13**: 16-20
59 **Brooks JP**, Perry WB, Putnam AT, Karulf RE. Thermal imaging in the detection of bowel ischemia. *Dis Colon Rectum* 2000; **43**: 1319-1321
60 **Roberts WW**, Dinkel TA, Schulam PG, Bonnell L, Kavoussi LR. Laparoscopic infrared imaging. *Surg Endosc* 1997; **11**: 1221-1223
61 **Redaelli CA**, Schilling MK, Carrel TP. Intraoperative assessment of intestinal viability by laser Doppler flowmetry for surgery of ruptured abdominal aortic aneurysms. *World J Surg* 1998; **22**: 283-289
62 **Vignali A**, Gianotti L, Braga M, Radaelli G, Malvezzi L, Di Carlo V. Altered microperfusion at the rectal stump is predictive for rectal anastomotic leak. *Dis Colon Rectum* 2000; **43**: 76-82
63 **Nakatsuka M**. Assessment of gut mucosal perfusion and colonic tissue blood flow during abdominal aortic surgery with gastric tonometry and laser Doppler flowmetry. *Vasc Endovascular Surg* ; **36**: 193-198
64 **Singh DB**, Stansby G, Bain I, Harrison DK. Intraoperative measurement of colonic oxygenation during bowel resection. *Adv Exp Med Biol* 2009; **645**: 261-266
65 **Singh DB**, Stansby G, Harrison DK. Assessment of oxygenation and perfusion in the tongue and oral mucosa by visible spectrophotometry and laser Doppler flowmetry in healthy subjects. *Adv Exp Med Biol* 2008; **614**: 227-233
66 **Boyle NH,** Manifold D, Jordan MH, Mason RC. Intraoperative assessment of colonic perfusion using scanning laser Doppler flowmetry during colonic resection. J Am Coll Surg 2000; 191: 504-510
67 **Hajivassiliou CA**, Greer K, Fisher A, Finlay IG. Non-invasive measurement of colonic blood flow distribution using laser Doppler imaging. *Br J Surg* 1998; **85**: 52-55
68 **Ando M**, Ito M, Nihei Z, Sugihara K. Assessment of intestinal viablity using a non-contact laser tissue blood flowmeter. *Am J Surg* 2000; **180**: 176-180
69 **Humeau A**, Steenbergen W, Nilsson H, Strömberg T. Laser Doppler perfusion monitoring and imaging: novel approaches. *Med Biol Eng Comput* 2007; **45**: 421-435
70 **Kashiwagi H**. The lower limit of tissue blood flow for safe colonic anastomosis: an experimental study using laser Doppler velocimetry. *Surg Today* 1993; **23**: 430-438
71 **Orland PJ**, Cazi GA, Semmlow JL, Reddell MT, Brolin RE. Determination of small bowel viability using quantitative myoelectric and color analysis. *J Surg Res* 1993; **55**: 581-587
72 **Brolin RE**, Bibbo C, Petschenik A, Reddell MT, Semmlow JL. Comparison of Ischemic and Reperfusion Injury in Canine Bowel Viability Assessment. *Gastrointest surg* 1997; **1**: 511-516
73 **Brolin RE**, Semmlow JL, Sehonanda A, Koch RA, Reddell MT, Mast BA, Mackenzie JW. Comparison of five methods of assessment of intestinal viability. *Surg Gynecol Obstet* 1989; **168**: 6-12
74 **Dutkiewicz W**, Thor P, Pawlicki R, Bobrzyński A, Budzyński A. Electromyographic and histologic evaluation of intestinal viability. *Wiad Lek* 1997; **50**: 50-53
75 **Kamiya K**, Suzuki S, Mineta H, Konno H. Tonometer pHi monitoring of free jejunal grafts following pharyngolaryngoesophagectomy for hypopharyngeal or cervical esophageal cancer. *Dig Surg* 2007; **24**: 214-220
76 **Millan M**, García-Granero E, Flor B, García-Botello S, Lledo S. Early prediction of anastomotic leak in colorectal cancer surgery by intramucosal pH. *Dis Colon Rectum* 2006; **49**: 595-601
77 **Deeba S**, Corcoles EP, Hanna BG, Pareskevas P, Aziz O, Boutelle MG, Darzi A. Use of Rapid Sampling Microdialysis for Intraoperative Monitoring of Bowel Ischemia. *Dis Colon Rectum* 2008; **51**: 1408-1413
78 **Sorensen HB**. Free jejunal flaps can be monitored by use of microdialysis. *J Reconstr Microsurg* 2008; **24**: 443-448
79 **Matsuo H**, Hirose H, Mori Y, Takagi H, Iwata H, Yamada T, Sakamoto K, Yasumura M. Experimental studies to estimate the intestinal viability in a rat strangulated ileus model using a dielectric parameter. *Dig Dis Sci* 2004; **49**: 633-638
80 **Horgan PG**, Gorey TF. Operative assessment of intestinal viability. *Surg Clin North Am* 1992; **72**: 143-155
81 **Gore RW**, Bohlen HG. Microvascular pressures in rat intestinal muscle and mucosal villi. *Am J Physiol* 1977; **80**: H685–H693
82 **Ahn H**, Lindhagen J, Nilsson GE, Salerud EG, Jodal M, Lundgren O. Evaluation of laser Doppler flowmetry in the assessment of intestinal blood flow in cat. *Gastroenterology* 1985; **88**: 951-957
83 **Arumugam PJ**, Bevan L, Macdonald L, Watkins AJ, Morgan AR, Beynon J, Carr ND. A prospective audit of stomas--analysis of risk factors and complications and their management. *Colorectal Dis* 2003; **5**: 49-52

84 **Cottam J**, Richards K, Hasted A, Blackman A. Results of a nationwide prospective audit of stoma complications within 3 wk of surgery. *Colorectal Dis* 2007; **9**: 834-838
85 **Boerma EC**, van der Voort PH, Spronk PE, Ince C. Relationship between sublingual and intestinal microcirculatory perfusion in patients with abdominal sepsis. *Crit Care Med* 2007; **35**: 1055-1060
86 **Boerma EC**, Mathura KR, van der Voort PH, Spronk PE, Ince C. Quantifying bedside-derived imaging of microcirculatory abnormalities in septic patients: a prospective validation study. *Crit Care* 2005; **9**: R601-R606
87 **Singh DB**, Bain I, Harrison DK. Use of visible spectrophotometry to assess tissue oxygenation in the colostomy stoma. *Adv Exp Med Biol* 2010; **662**: 273-278

S- Editor Wang JL **L- Editor** Roemmele A **E- Editor** Zhang L

World Journal of Gastrointestinal Surgery

Online Submissions: http://www.wjgnet.com/1948-9366office
wjgs@wjgnet.com
doi:10.4240/wjgs.v3.i5.70

World J Gastrointest Surg 2011 May 27; 3(5):70-72
ISSN 1948-9366 (online)

CASE REPORT

Diverticulitis presenting as a tubo-ovarian abscess with subsequent colon perforation

Yasmin Metz, Jerry Nagler

Yasmin Metz, Jerry Nagler, Division of Gastroenterology and Hepatology, New York-Presbyterian Hospital, Weill Cornell Medical Center, New York, NY 10021, United States
Author contributions: Metz Y and Nagler J contributed equally to this work and wrote the paper.
Correspondence to: Jerry Nagler, MD, Division of Gastroenterology and Hepatology, New York-Presbyterian, Weill Cornell Medical Center, 407 East 70th Street, New York, NY 10021, United States. jen2001@med.cornell.edu
Telephone: +001-212-628-7777 Fax: +001-212-517-6625
Received: September 10, 2010 Revised: March 15, 2011
Accepted: March 22, 2011
Published online: May 27, 2011

Abstract

Described here is an unusual complication of a common condition; diverticulitis resulting in a tubo-ovarian abscess. The etiology of this abscess was clinically unapparent due to atypical presenting symptoms and signs. Furthermore, radiological diagnosis was misleading because of an inflammatory reaction of the colon which prevented visualization of diverticula. Failure to correctly identify the underlying pathology early in the patient's course of treatment led to a perforation of the colon.

Key words: Diverticulitis; Tubo-ovarian abscess; Colon perforation

Peer reviewers: Yoshihiro Moriwaki, MD, PhD, Department of Critical Care and Emergency Center, Yokohama City University Medical Center, 4-57, Urafune-cho, Minami-ku, Yokohama 232-0024, Japan; Theodoros E Pavlidis, MD, PhD, Professor, Department of Surgery, University of Thessaloniki, Hippocration Hospital, A Samothraki 23, Thessaloniki 54248, Greece

Metz Y, Nagler J. Diverticulitis presenting as a tubo-ovarian abscess with subsequent colon perforation. *World J Gastrointest Surg* 2011; 3(5): 70-72 Available from: URL: http://www.wjgnet.com/1948-9366/full/v3/i5/70.htm DOI: http://dx.doi.org/10.4240/wjgs.v3.i5.70

INTRODUCTION

Diverticulosis is a common condition in Western countries, affecting approximately 30%-50% of adults over the age of 60 and 67% over 80 years[1,2]. It is defined as a pocket of mucosa bounded by muscularis mucosa which herniates through areas of weakness in the muscularis propria, usually at vascular entry sites[3]. Complications of diverticulosis include diverticulitis, bleeding, abscess formation, fistula, stricture formation and free perforation. Approximately 10% of patients with diverticulosis will eventually develop acute diverticulitis and other complications[4]. Occasionally acute diverticulitis will involve the female organs, especially the left ovary which lies in close proximity to the sigmoid colon where diverticula are most commonly located[8]. In such cases, the usual predominantly bowel symptoms of diverticulitis, such as localized lower abdominal pain, constipation or diarrhea and increased flatulence, may be minimal or absent[10]. We present a case of diverticulitis causing a tubo-ovarian abscess which was unrecognized due to atypical symptoms. Additionally, two abdominal-pelvic computerized tomography scans failed to demonstrate diverticula, eventually resulting in a free peritoneal perforation of the colon.

CASE REPORT

A 63-year old woman presented to her gastroenterologist with vague persistent abdominal cramps. A subsequent work-up consisting of an abdominal ultrasound dem-

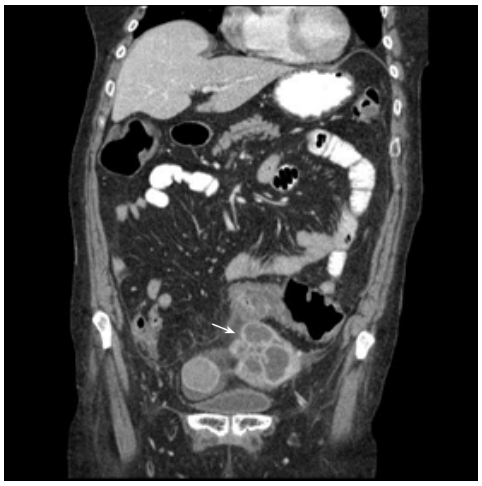

Figure 1 Tubo-ovarian abscess with adjacent sigmoid colon.

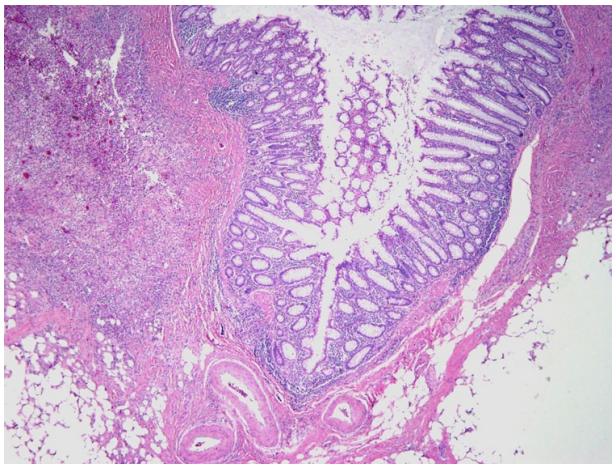

Figure 2 Perforated diverticulum with adjacent peri-colonic abscess. (HE stain, x 40)

onstrated a complex left ovarian cystic mass and elective surgery was recommended by gynecology due to the suspicion of ovarian cancer. The patient, however, deferred surgery. She presented to the New York Presbyterian Hospital Emergency Department one month later because of increased abdominal discomfort and the new onset of diarrhea. On physical examination, she appeared to be well nourished, well developed and in no acute distress. Vital signs were all normal, including a temperature of 36.7 degrees centigrade. Her examination was only remarkable for mild distention with left upper quadrant, right lower quadrant and suprapubic tenderness, without rebound tenderness. Laboratory data was significant for hypokalemia (2.9 mmol/L), leukocytosis (18 500 uL) and hypoalbuminemia (2.3 g/dL). An abdominal-pelvic CT scan confirmed the presence of a complex cystic left adnexal mass with surrounding inflammatory changes and mild ascites. The sigmoid colon adjacent to the pelvic mass contained a long segment of wall thickening, without diverticula seen (Figure 1). The patient was treated with levaquin and metronidazole antibiotics for a presumed tubo-ovarian abscess. Evaluation of the patient's diarrhea with stool examination revealed evidence of fecal leukocytes but no pathogenic bacteria, parasites or *Clostridium difficile* toxin. A subsequent flexible sigmoidoscopy was limited to only 30 cm from the anal verge due to severe narrowing. Biopsies of the sigmoid colon demonstrated non-specific inflamed colonic mucosa. On the ninth hospital day, the patient's abdomen became more distended and a repeat abdominal-pelvic CT scan showed free intraperitoneal air but with a stable enhancing left pelvic mass inseparable from the adjacent sigmoid colon. The patient was taken to the operating room on the same day. The pelvic mass together with adherent sigmoid colon was removed. A subsequent pathological examination of the resected specimen revealed a 7-cm mass encompassing the left fallopian tube and ovary adherent to a perforated diverticulum of the sigmoid colon which contained features of organization and a striking fibroinflammatory response (Figure 2).

DISCUSSION

Postmenopausal tubo-ovarian abscesses may occur due to pelvic inflammatory disease but this is uncommon and most often the abscess is associated with a gynecological malignancy[6,7]. Often the possibility of acute diverticulitis is not considered pre-operatively. A series of seventeen patients with diagnoses of ovarian cancer or twisted ovarian cysts were proven at surgery to have acute diverticulitis as the cause of their symptoms and pre-operative findings[15]. In another series, five patients with the preoperative diagnoses of either twisted ovarian cyst, ovarian abscess or ectopic pregnancy were discovered post-operatively to be misdiagnosed and actually had acute diverticulitis[16]. In a larger series of 69 women who underwent surgery for what was believed to be gynecological disease, 38% were found to have acute diverticulitis[13]. Another case has been reported in the literature of a 31-year old woman who underwent the surgical resection of a tubo-ovarian abscess but required another operation shortly afterwards because of a recurrent pelvic abscess due to diverticulitis that was unrecognized at the time of the first operation[14]. This illustrates the importance of recognizing acute diverticulitis which may present as a gynecological problem, even at a young age. Diverticulitis with abscess formation can be very insidious and reports of presentation as only chronic diarrhea[11] or even an isolated brain abscess[12] have been described.

Early recognition of tubo-ovarian abscess resulting from diverticulitis and prompt treatment is crucial for prevention of further complications[9]. Appropriate surgical treatment with possible pre-operative percutaneous abscess drainage can avoid further complications such as stricture or fistula formation and free perforation[5]. The discovery of a pelvic mass together with any bowel symptoms should arouse suspicion of possible diverticulitis with abscess. Diverticula may be absent on x-ray examination as a consequence of intense peri-colonic inflammation secondary to the diverticulitis. The finding of a

thickened loop of sigmoid colon adherent to the pelvic mass, even without diverticulosis, visualized on x-ray, is suggestive of possible diverticulitis as the underlying pathology. Prompt recognition of this condition early in the patient's course will greatly improve the chances of a full and uncomplicated recovery.

ACKNOWLEDGMENTS

We thank Dr. Maria La Gratta for providing the radiological image and Drs. Jeffrey Henderson and Rhonda Yantiss for their pathology review and image.

REFERENCES

1 **West AB**, Losada M. The pathology of diverticulosis coli. *J Clin Gastroenterol* ; **38**: S11-S16
2 **Pfeifer J**. Diverticulitis. *Acta Chir Iugosl* 2008; **55**: 97-102
3 **West AB**. The pathology of diverticulitis. *J Clin Gastroenterol* ; **42**: 1137-1138
4 **Freeman SR**, McNally PR. Diverticulitis. *Med Clin North Am* 1993; **77**: 1149-1167
5 **Mesia AF**, Lam H, Wallach RC. Xanthogranulomatous tuboovarian abscess resulting from chronic diverticulitis. *Gynecol Obstet Invest* 2000; **49**: 70-72
6 **Roth JL**. Diagnosis and differential diagnosis of colonic diverticulitis. *Postgrad Med* 1976; **60**: 85-90
7 **Protopapas AG**, Diakomanolis ES, Milingos SD, Rodolakis AJ, Markaki SN, Vlachos GD, Papadopoulos DE, Michalas SP. Tubo-ovarian abscesses in postmenopausal women: gynecological malignancy until proven otherwise? *Eur J Obstet Gynecol Reprod Biol* 2004; **114**: 203-209
8 **Jackson SL**, Soper DE. Pelvic inflammatory disease in the postmenopausal woman. *Infect Dis Obstet Gynecol* 1999; **7**: 248-252
9 **Gray LA**. Diverticulitis presenting as a gynecologic problem. *Am Surg* 1980; **46**: 88-94
10 **HURWITZ A**, SOLOMONS E. Diverticulitis, a diagnostic dilemma; report of five cases. *Obstet Gynecol* 1957; **10**: 128-132
11 **Walker JD**, Gray LA, Polk HC. Diverticulitis in women: an unappreciated clinical presentation. *Ann Surg* 1977; **185**: 402-405
12 **Naliboff JA**, Longmire-Cook SJ. Diverticulitis mimicking a tuboovarian abscess. Report of a case in a young woman. *J Reprod Med* 1996; **41**: 921-923
13 **Daryani NE**, Keramati MR, Habibollahi P, Pashaei MR, Ansarinejad N, Ajdarkosh H. Colonic diverticular abscess presenting as chronic diarrhea: a case report. *Cases J* 2009; **2**: 9389
14 **Pompeo L**, Heller DS, Hameed MR, Sama J, Cracchiolo BM. Unilateral chronic tuboovarian abscess secondary to ruptured colonic diverticulum presenting as a brain abscess. A case report. *J Reprod Med* 2000; **45**: 145-148
15 **Chao AS**, Chang SY, Soong YK. Postmenopausal tuboovarian abscess. *Changgeng Yi Xue Za Zhi* 1992; **15**: 128-133
16 **Eggenberger JC**. Diverticular Disease. *Curr Treat Options Gastroenterol* 1999; **2**: 507-516

S- Editor Wang JL **L- Editor** Roemmele A **E- Editor** Zheng L

World Journal of Gastrointestinal Surgery

Online Submissions: http://www.wjgnet.com/1948-9366office
wjgs@wjgnet.com
www.wjgnet.com

World J Gastrointest Surg 2011 May 27; 3(5): I
ISSN 1948-9366 (online)

Acknowledgments to reviewers of *World Journal of Gastrointestinal Surgery*

Many reviewers have contributed their expertise and time to the peer review, a critical process to ensure the quality of *World Journal of Gastrointestinal Surgery*. The editors and authors of the articles submitted to the journal are grateful to the following reviewers for evaluating the articles (including those published in this issue and those rejected for this issue) during the last editing time period.

Ned Abraham, MBBS, FRACS, FRCS, PhD, Coffs Colorectal and Capsule Endoscopy Centre, University of New South Wales, 187 Rose Avenue, PO Box 2244, Coffs Harbour, NSW 2450, Australia

Chapel Alain, PhD, Department of Men Radioprotection, Laboratory of Radio Pathology and Innovative Therapy, Institute of nuclear Safety and radioprotection, PO Box 17, Far 92262, France

Vollmar Brigitte, MD, Professor, Institute of Experimental Surgery, University of Rostock, Schillingallee 69a, Rostock 18057, Germany

Chien-Hung Chen, MD, PhD, Department of Internal Medicine, National Taiwan University Hospital and National Taiwan University College of Medicine, No. 7, Chung-Shan South Road, Taipei 100, Taiwan, China

Stavros J Gourgiotis, MD, PhD, Department of Second Surgical, 401 General Army Hospital of Athens, 41 Zakinthinou Street, Papagou, Athens 15669, Greece

Helena M Isoniemi, MD, PhD, Professor, Transplantation and Liver Surgery Clinic, Helsinki University Hospital, box 263, Helsinki 00029-HUCH, Finland

Chen-Guo Ker, MD, PhD, Professor, Department of Surgery, Kaohsiung Medical University, No. 100, Tz-You 1st Rd, Kaohsiung, Taiwan, China

Adnan Narci, Professor, Department of Pediatric Surgery, Afyon Kocatepe University School of Medicine, Izmir Street, 7km, Afyonkarahisar 03200, Turkey

Marcelo AF Ribeiro, MD, PhD, TCBC, TCBCD, FACS, Department of Surgery, Santo Amaro University, Alameda Gregorio Bogossian Sobrinho, 80/155, Santana de Parnaiba, SP 06543-385, Brazil

Sukamal Saha, MD, FACS, FRCS, FICS, Department of Orthopedics, 3500 Calkins Rd, Suite A, Flint, MI 48532, United States

Manuela Santos, PhD, Associate Professor, Department of Medicine, University of Montreal, Montreal Cancer Institute, CRCHUM/Notre-Dame Hospital, Pavillon De Seve Y5625, 1560 Sherbrooke Est, Montreal, QC, H2L 4M1, Canada

Christian Max Schmidt, MD, PhD, MBA, FACS, Departments of Surgery and Biochemistry/Molecular Biology, Indiana University School of Medicine, 980 W Walnut St C522, Indianapolis, IN 46202, United States

Gregory Peter Sergeant, MD, Department of General Surgery, University Hospital Leuven, Herestraat 49, Leuven B-3000, Belgium

Douglas S Tyler, MD, Department of Surgery, Duke University Medical Center, Box 3118, Durham, NC 27710, United States

Marcus VM Valadao, MD, Instituto Nacional de Cancer, Hospital do Cancer Unidade I, Hc2., Rua do Equador 831, Santo Cristo, Rio de Janeiro 20220-410, RJ, Brazil

Caroline S Verbeke, MD, PhD, Department of Histopathology, Bexley Wing Level 5 St James's University, Hospital Beckett Street, Leeds LS9 7TF, United Kingdom

World Journal of Gastrointestinal Surgery

Online Submissions: http://www.wjgnet.com/1948-9366office
wjgs@wjgnet.com
www.wjgnet.com

World J Gastrointest Surg 2011 May 27; 3(5): I
ISSN 1948-9366 (online)

Events Calendar 2011

January 15-19, 2011
EAES Advanced Laparoscopic GI Surgery Course, Cairo, Egypt

January 20-22, 2011
Gastrointestinal Cancers Symposium (ASCO GI), San Francisco, CA, United States

January 26-30, 2011
5th UK Alpine Liver and Pancreatic Surgery Meeting, Carlo Magno Zeledria Hotel, Madonna di Campiglio, Italy

February 01-03, 2011
6th Annual Academic Surgical Congress, Huntington Beach, CA, United States

February 21-26, 2011
Minimally Invasive Surgery Symposium 2011, The Grand America Hotel, Salt Lake City, Utah, United States

March 03-06, 2011
The Society of Surgical Oncology 63rd Annual Meeting, San Antonio, TX, United States

March 10-13, 2011
The American Hepato-Pancreato-Biliary Association Annual Meeting, Miami Beach, FL, United States

March 14-17, 2011
British Society for Gastroenterology Annual Meeting, International Convention Centre, Birmingham, United Kingdom

March 25-27, 2011
NZAGS Conference 2011 GI Surgery, New Plymouth, New Zealand

March 30-April 02, 2011
The Society of American Gastrointestinal and Endoscopic Surgeons 2011 Annual Meeting, San Antonio Convention Center, San Antonio, TX, United States

April 02-06, 2011
The American Association for Cancer Research 102nd Annual Meeting, Orlando, FL, United States

April 10-12, 2011
The American Association of Endocrine Surgeons 32nd Annual Meeting, Houston, TX, United States

April 14-16, 2011
The American Surgical Association 131st Annual Meeting, Boca Raton, FL, United States

May 07-10, 2011
Digestive Disease Week, Chicago, IL, United States

May 07-10, 2011
45th Annual Meeting of the Pancreas Club, Chicago, IL, United States

June 15-18, 2011
19th International Congress of the European Association for Endoscopic Surgery, in collaboration with and incorporating the 15th National Congress of the Italian Society of Endoscopic Surgery, Torino, Italy

September 10-14, 2011
International Congress of Endoscopy, Los Angeles, CA, United States

September 22-24, 2011
5th joint EAES and ESGE, European Workshop on NOTES, Frankfurt, Germany

September 23-25, 2011
The New England Surgical Society 92nd Annual Meeting, Breton Woods, NH, United States

September 23-27, 2011
ECCO-European Society for Medical Oncology Congress, Stockholm, Sweden

October 23-27, 2011
The American College of Surgeons 97th Annual Clinical Congress, San Francisco, CA, United States

November 02-05, 2011
American Pancreatic Association 42nd Annual Meeting, Chicago, IL, United States

November 13-16, 2011
The Western Surgical Association 119th Scientific Session, Tucson, AZ, United States

WJGS World Journal of Gastrointestinal Surgery

Online Submissions: http://www.wjgnet.com/1948-9366office
wjgs@wjgnet.com
www.wjgnet.com

World J Gastrointest Surg 2011 May 27; 3(5): I-V
ISSN 1948-9366 (online)

INSTRUCTIONS TO AUTHORS

GENERAL INFORMATION

World Journal of Gastrointestinal Surgery (*World J Gastrointest Surg*, *WJGS*, online ISSN 1948-9366, DOI: 10.4240), is a monthly, open-access (OA), peer-reviewed journal supported by an editorial board of 336 experts in gastrointestinal surgery from 35 countries.

The biggest advantage of the OA model is that it provides free, full-text articles in PDF and other formats for experts and the public without registration, which eliminates the obstacle that traditional journals possess and usually delays the speed of the propagation and communication of scientific research results. The open access model has been proven to be a true approach that may achieve the ultimate goal of the journals, i.e. the maximization of the value to the readers, authors and society.

Maximization of personal benefits

The role of academic journals is to exhibit the scientific levels of a country, a university, a center, a department, and even a scientist, and build an important bridge for communication between scientists and the public. As we all know, the significance of the publication of scientific articles lies not only in disseminating and communicating innovative scientific achievements and academic views, as well as promoting the application of scientific achievements, but also in formally recognizing the "priority" and "copyright" of innovative achievements published, as well as evaluating research performance and academic levels. So, to realize these desired attributes of *WJGS* and create a well-recognized journal, the following four types of personal benefits should be maximized. The maximization of personal benefits refers to the pursuit of the maximum personal benefits in a well-considered optimal manner without violation of the laws, ethical rules and the benefits of others. (1) Maximization of the benefits of editorial board members: The primary task of editorial board members is to give a peer review of an unpublished scientific article *via* online office system to evaluate its innovativeness, scientific and practical values and determine whether it should be published or not. During peer review, editorial board members can also obtain cutting-edge information in that field at first hand. As leaders in their field, they have priority to be invited to write articles and publish commentary articles. We will put peer reviewers' names and affiliations along with the article they reviewed in the journal to acknowledge their contribution; (2) Maximization of the benefits of authors: Since *WJGS* is an open-access journal, readers around the world can immediately download and read, free of charge, high-quality, peer-reviewed articles from *WJGS* official website, thereby realizing the goals and significance of the communication between authors and peers as well as public reading; (3) Maximization of the benefits of readers: Readers can read or use, free of charge, high-quality peer-reviewed articles without any limits, and cite the arguments, viewpoints, concepts, theories, methods, results, conclusion or facts and data of pertinent literature so as to validate the innovativeness, scientific and practical values of their own research achievements, thus ensuring that their articles have novel arguments or viewpoints, solid evidence and correct conclusion; and (4) Maximization of the benefits of employees: It is an iron law that a first-class journal is unable to exist without first-class editors, and only first-class editors can create a first-class academic journal. We insist on strengthening our team cultivation and construction so that every employee, in an open, fair and transparent environment, could contribute their wisdom to edit and publish high-quality articles, thereby realizing the maximization of the personal benefits of editorial board members, authors and readers, and yielding the greatest social and economic benefits.

Aims and scope

The major task of *WJGS* is to rapidly report the most recent results in basic and clinical research on gastrointestinal surgery, specifically including micro-invasive surgery, laparoscopy, hepatic surgery, biliary surgery, pancreatic surgery, splenic surgery, surgical nutrition, portal hypertension, as well as the associated subjects such as epidemiology, cancer research, biomarkers, prevention, pathology, radiology, genetics, genomics, proteomics, pharmacology, pharmacokinetics, pharmacogenetics, molecular biology, clinical trials, diagnosis and therapeutics and multimodality treatment. Emphasis is placed on original research articles and clinical case reports. This journal will also provide balanced, extensive and timely review articles on selected topics.

Columns

The columns in the issues of *WJGS* will include: (1) Editorial: To introduce and comment on major advances and developments in the field; (2) Frontier: To review representative achievements, comment on the state of current research, and propose directions for future research; (3) Topic Highlight: This column consists of three formats, including (A) 10 invited review articles on a hot topic, (B) a commentary on common issues of this hot topic, and (C) a commentary on the 10 individual articles; (4) Observation: To update the development of old and new questions, highlight unsolved problems, and provide strategies on how to solve the questions; (5) Guidelines for Basic Research: To provide guidelines for basic research; (6) Guidelines for Clinical Practice: To provide guidelines for clinical diagnosis and treatment; (7) Review: To review systemically progress and unresolved problems in the field, comment on the state of current research, and make suggestions for future work; (8) Original Article: To report innovative and original findings in gastrointestinal surgery; (9) Brief Article: To briefly report the novel and innovative findings in gastrointestinal surgery; (10) Case Report: To report a rare or typical case; (11) Letters to the Editor: To discuss and make reply to the contributions published in *WJGS*, or to introduce and comment on a controversial issue of general interest; (12) Book Reviews: To introduce and comment on quality monographs of gastrointestinal surgery; and (13) Guidelines: To introduce consensuses and guidelines reached by international and national academic authorities worldwide on basic research and clinical practice in gastrointestinal surgery.

Name of journal

World Journal of Gastrointestinal Surgery

ISSN

ISSN 1948-9366 (online)

Indexing/abstracting

PubMed Central, PubMed, Digital Object Identifer, and Directory of Open Access Journals.

Published by

Baishideng Publishing Group Co., Limited

SPECIAL STATEMENT

All articles published in this journal represent the viewpoints of the authors except where indicated otherwise.

Biostatistical editing

Statistical review is performed after peer review. We invite an expert in Biomedical Statistics from to evaluate the statistical method used in the paper, including *t*-test (group or paired comparisons), chi-squared test, Ridit, probit, logit, regression (linear, curvilinear, or stepwise), correlation, analysis of variance, analysis of covariance, *etc*. The reviewing points include: (1) Statistical methods should be described when they are used to verify the results; (2) Whether the statistical techniques are suitable or correct; (3) Only homogeneous data can be averaged. Standard deviations are preferred to standard errors. Give the number of observations and subjects (*n*). Losses in observations, such as drop-outs from the study should be reported; (4) Values such as ED50, LD50, IC50 should have their 95% confidence limits calculated and compared by weighted probit analysis (Bliss and Finney); and (5) The word 'significantly' should be replaced by its synonyms (if it indicates extent) or the *P* value (if it indicates statistical significance).

Conflict-of-interest statement

In the interests of transparency and to help reviewers assess any potential bias, *WJGS* requires authors of all papers to declare any competing commercial, personal, political, intellectual, or religious interests in relation to the submitted work. Referees are also asked to indicate any potential conflict they might have reviewing a particular paper. Before submitting, authors are suggested to read "Uniform Requirements for Manuscripts Submitted to Biomedical Journals: Ethical Considerations in the Conduct and Reporting of Research: Conflicts of Interest" from International Committee of Medical Journal Editors (ICMJE), which is available at: http://www.icmje.org/ethical_4conflicts.html.

Sample wording: [Name of individual] has received fees for serving as a speaker, a consultant and an advisory board member for [names of organizations], and has received research funding from [names of organization]. [Name of individual] is an employee of [name of organization]. [Name of individual] owns stocks and shares in [name of organization]. [Name of individual] owns patent [patent identification and brief description].

Statement of informed consent

Manuscripts should contain a statement to the effect that all human studies have been reviewed by the appropriate ethics committee or it should be stated clearly in the text that all persons gave their informed consent prior to their inclusion in the study. Details that might disclose the identity of the subjects under study should be omitted. Authors should also draw attention to the Code of Ethics of the World Medical Association (Declaration of Helsinki, 1964, as revised in 2004).

Statement of human and animal rights

When reporting the results from experiments, authors should follow the highest standards and the trial should conform to Good Clinical Practice (for example, US Food and Drug Administration Good Clinical Practice in FDA-Regulated Clinical Trials; UK Medicines Research Council Guidelines for Good Clinical Practice in Clinical Trials) and/or the World Medical Association Declaration of Helsinki. Generally, we suggest authors follow the lead investigator's national standard. If doubt exists whether the research was conducted in accordance with the above standards, the authors must explain the rationale for their approach and demonstrate that the institutional review body explicitly approved the doubtful aspects of the study.

Before submitting, authors should make their study approved by the relevant research ethics committee or institutional review board. If human participants were involved, manuscripts must be accompanied by a statement that the experiments were undertaken with the understanding and appropriate informed consent of each. Any personal item or information will not be published without explicit consents from the involved patients. If experimental animals were used, the materials and methods (experimental procedures) section must clearly indicate that appropriate measures were taken to minimize pain or discomfort, and details of animal care should be provided.

SUBMISSION OF MANUSCRIPTS

Manuscripts should be typed in 1.5 line spacing and 12 pt. Book Antiqua with ample margins. Number all pages consecutively, and start each of the following sections on a new page: Title Page, Abstract, Introduction, Materials and Methods, Results, Discussion, Acknowledgements, References, Tables, Figures, and Figure Legends. Neither the editors nor the publisher are responsible for the opinions expressed by contributors. Manuscripts formally accepted for publication become the permanent property of Baishideng Publishing Group Co., Limited, and may not be reproduced by any means, in whole or in part, without the written permission of both the authors and the publisher. We reserve the right to copy-edit and put onto our website accepted manuscripts. Authors should follow the relevant guidelines for the care and use of laboratory animals of their institution or national animal welfare committee. For the sake of transparency in regard to the performance and reporting of clinical trials, we endorse the policy of the ICMJE to refuse to publish papers on clinical trial results if the trial was not recorded in a publicly-accessible registry at its outset. The only register now available, to our knowledge, is http://www.clinicaltrials.gov sponsored by the United States National Library of Medicine and we encourage all potential contributors to register with it. However, in the case that other registers become available you will be duly notified. A letter of recommendation from each author's organization should be provided with the contributed article to ensure the privacy and secrecy of research is protected.

Authors should retain one copy of the text, tables, photographs and illustrations because rejected manuscripts will not be returned to the author(s) and the editors will not be responsible for loss or damage to photographs and illustrations sustained during mailing.

Online submissions

Manuscripts should be submitted through the Online Submission System at: http://www.wjgnet.com/1948-9366office. Authors are highly recommended to consult the ONLINE INSTRUCTIONS TO AUTHORS (http://www.wjgnet.com/1948-9366/g_info_20100305152206.htm) before attempting to submit online. For assistance, authors encountering problems with the Online Submission System may send an email describing the problem to wjgs@wjgnet.com, or by telephone: +86-10-85381891. If you submit your manuscript online, do not make a postal contribution. Repeated online submission for the same manuscript is strictly prohibited.

MANUSCRIPT PREPARATION

All contributions should be written in English. All articles must be submitted using word-processing software. All submissions must be typed in 1.5 line spacing and 12 pt. Book Antiqua with ample margins. Style should conform to our house format. Required information for each of the manuscript sections is as follows:

Title page

Title: Title should be less than 12 words.

Running title: A short running title of less than 6 words should be provided.

Authorship: Authorship credit should be in accordance with the standard proposed by International Committee of Medical Journal Editors, based on (1) substantial contributions to conception and design, acquisition of data, or analysis and interpretation of data; (2) drafting the article or revising it critically for important intellectual content; and (3) final approval of the version to be published. Authors should meet conditions 1, 2, and 3.

Institution: Author names should be given first, then the complete name of institution, city, province and postcode. For example, Xu-Chen Zhang, Li-Xin Mei, Department of Pathology, Chengde Medical College, Chengde 067000, Hebei Province, China. One author may be represented from two institutions, for example, George Sgourakis, Department of General, Visceral, and Transplantation Surgery, Essen 45122, Germany; George Sgourakis, 2nd Surgical Department, Korgialenio-Benakio Red Cross Hospital, Athens 15451, Greece

Author contributions: The format of this section should be: Author contributions: Wang CL and Liang L contributed equally to this work; Wang CL, Liang L, Fu JF, Zou CC, Hong F and Wu XM designed the research; Wang CL, Zou CC, Hong F and Wu XM performed the research; Xue JZ and Lu JR contributed new reagents/analytic tools; Wang CL, Liang L and Fu JF analyzed the data; and Wang CL, Liang L and Fu JF wrote the paper.

Supportive foundations: The complete name and number of supportive foundations should be provided, e.g. Supported by National Natural Science Foundation of China, No. 30224801

Correspondence to: Only one corresponding address should be provided. Author names should be given first, then author title, affiliation, the complete name of institution, city, postcode, province, country, and email. All the letters in the email should be in lower case. A space interval should be inserted between country name and email address. For example, Montgomery Bissell, MD, Professor of Medicine, Chief, Liver Center, Gastroenterology Division, University of California, Box 0538, San Francisco, CA 94143, United States. montgomery.bissell@ucsf.edu

Telephone and fax: Telephone and fax should consist of +, country number, district number and telephone or fax number, e.g. Telephone: +86-10-85381891 Fax: +86-10-85381893

Peer reviewers: All articles received are subject to peer review. Normally, three experts are invited for each article. Decision for acceptance is made only when at least two experts recommend an article for publication. Reviewers for accepted manuscripts are acknowledged in each manuscript, and reviewers of articles which were not accepted will be acknowledged at the end of each issue. To ensure the quality of the articles published in *WJGS*, reviewers of accepted manuscripts will be announced by publishing the name, title/position and institution of the reviewer in the footnote accompanying the printed article. For example, reviewers: Professor Jing-Yuan Fang, Shanghai Institute of Digestive Disease, Shanghai, Affiliated Renji Hospital, Medical Faculty, Shanghai Jiaotong University, Shanghai, China; Professor Xin-Wei Han, Department of Radiology, The First Affiliated Hospital, Zhengzhou University, Zhengzhou, Henan Province, China; and Professor Anren Kuang, Department of Nuclear Medicine, Huaxi Hospital, Sichuan University, Chengdu, Sichuan Province, China.

Abstract

There are unstructured abstracts (no more than 256 words) and structured abstracts (no more than 480). The specific requirements for structured abstracts are as follows:

An informative, structured abstracts of no more than 480 words should accompany each manuscript. Abstracts for original contributions should be structured into the following sections. AIM (no more than 20 words): Only the purpose should be included. Please write the aim as the form of "To investigate/study/…"; MATERIALS AND METHODS (no more than 140 words); RESULTS (no more than 294 words): You should present *P* values where appropriate and must provide relevant data to illustrate how they were obtained, e.g. 6.92 ± 3.86 *vs* 3.61 ± 1.67, $P < 0.001$; CONCLUSION (no more than 26 words).

Key words

Please list 5-10 key words, selected mainly from *Index Medicus*, which reflect the content of the study.

Text

For articles of these sections, original articles and brief articles, the main text should be structured into the following sections: INTRODUCTION, MATERIALS AND METHODS, RESULTS and DISCUSSION, and should include appropriate Figures and Tables. Data should be presented in the main text or in Figures and Tables, but not in both. The main text format of these sections, editorial, topic highlight, case report, letters to the editors, can be found at: http://www.wjgnet.com/1948-9366/g_info_list.htm.

Illustrations

Figures should be numbered as 1, 2, 3, *etc.*, and mentioned clearly in the main text. Provide a brief title for each figure on a separate page. Detailed legends should not be provided under the figures. This part should be added into the text where the figures are applicable. Figures should be either Photoshop or Illustrator files (in tiff, eps, jpeg formats) at high-resolution. Examples can be found at: http://www.wjgnet.com/1007-9327/13/4520.pdf; http://www.wjgnet.com/1007-9327/13/4554.pdf; http://www.wjgnet.com/1007-9327/13/4891.pdf; http://www.wjgnet.com/1007-9327/13/4986.pdf; http://www.wjgnet.com/1007-9327/13/4498.pdf. Keeping all elements compiled is necessary in line-art image. Scale bars should be used rather than magnification factors, with the length of the bar defined in the legend rather than on the bar itself. File names should identify the figure and panel. Avoid layering type directly over shaded or textured areas. Please use uniform legends for the same subjects. For example: Figure 1 Pathological changes in atrophic gastritis after treatment. A: ...; B: ...; C: ...; D: ...; E: ...; F: ...; G: …*etc.* It is our principle to publish high resolution-figures for the printed and E-versions.

Tables

Three-line tables should be numbered 1, 2, 3, *etc.*, and mentioned clearly in the main text. Provide a brief title for each table. Detailed legends should not be included under tables, but rather added into the text where applicable. The information should complement, but not duplicate the text. Use one horizontal line under the title, a second under column heads, and a third below the Table, above any footnotes. Vertical and italic lines should be omitted.

Notes in tables and illustrations

Data that are not statistically significant should not be noted. $^{a}P < 0.05$, $^{b}P < 0.01$ should be noted ($P > 0.05$ should not be noted). If there are other series of *P* values, $^{c}P < 0.05$ and $^{d}P < 0.01$ are used. A third series of *P* values can be expressed as $^{e}P < 0.05$ and $^{f}P < 0.01$. Other notes in tables or under illustrations should be expressed as ^{1}F, ^{2}F, ^{3}F; or sometimes as other symbols with a superscript (Arabic numerals) in the upper left corner. In a multi-curve illustration, each curve should be labeled with ●, ○, ■, □, ▲, △, *etc.*, in a certain sequence.

Acknowledgments

Brief acknowledgments of persons who have made genuine contributions to the manuscript and who endorse the data and conclusions should be included. Authors are responsible for obtaining written permission to use any copyrighted text and/or illustrations.

REFERENCES

Coding system

The author should number the references in Arabic numerals according to the citation order in the text. Put reference numbers in square brackets in superscript at the end of citation content or after the cited author's name. For citation content which is part of the narration, the coding number and square brackets should be typeset normally. For example, "Crohn's disease (CD) is associated with increased intestinal permeability[1,2]". If references are cited directly in the text, they should be put together within the text, for

example, "From references[19,22-24], we know that...".

When the authors write the references, please ensure that the order in text is the same as in the references section, and also ensure the spelling accuracy of the first author's name. Do not list the same citation twice.

PMID and DOI

Pleased provide PubMed citation numbers to the reference list, e.g. PMID and DOI, which can be found at http://www.ncbi.nlm.nih.gov/sites/entrez?db=pubmed and http://www.crossref.org/SimpleTextQuery/, respectively. The numbers will be used in E-version of this journal.

Style for journal references

Authors: the name of the first author should be typed in bold-faced letters. The family name of all authors should be typed with the initial letter capitalized, followed by their abbreviated first and middle initials. (For example, Lian-Sheng Ma is abbreviated as Ma LS, Bo-Rong Pan as Pan BR). The title of the cited article and italicized journal title (journal title should be in its abbreviated form as shown in PubMed), publication date, volume number (in black), start page, and end page [PMID: 11819634 DOI: 10.3748/wjg.13.5396].

Style for book references

Authors: the name of the first author should be typed in bold-faced letters. The surname of all authors should be typed with the initial letter capitalized, followed by their abbreviated middle and first initials. (For example, Lian-Sheng Ma is abbreviated as Ma LS, Bo-Rong Pan as Pan BR) Book title. Publication number. Publication place: Publication press, Year: start page and end page.

Format

Journals

English journal article (list all authors and include the PMID where applicable)

1 **Jung EM**, Clevert DA, Schreyer AG, Schmitt S, Rennert J, Kubale R, Feuerbach S, Jung F. Evaluation of quantitative contrast harmonic imaging to assess malignancy of liver tumors: A prospective controlled two-center study. *World J Gastroenterol* 2007; **13**: 6356-6364 [PMID: 18081224 DOI: 10.3748/wjg.13.6356]

Chinese journal article (list all authors and include the PMID where applicable)

2 **Lin GZ**, Wang XZ, Wang P, Lin J, Yang FD. Immunologic effect of Jianpi Yishen decoction in treatment of Pixu-diarrhoea. *Shijie Huaren Xiaohua Zazhi* 1999; **7**: 285-287

In press

3 **Tian D**, Araki H, Stahl E, Bergelson J, Kreitman M. Signature of balancing selection in Arabidopsis. *Proc Natl Acad Sci USA* 2006; In press

Organization as author

4 **Diabetes Prevention Program Research Group**. Hypertension, insulin, and proinsulin in participants with impaired glucose tolerance. *Hypertension* 2002; **40**: 679-686 [PMID: 12411462 PMCID:2516377 DOI:10.1161/01.HYP.0000035706.28494.09]

Both personal authors and an organization as author

5 **Vallancien G**, Emberton M, Harving N, van Moorselaar RJ; Alf-One Study Group. Sexual dysfunction in 1, 274 European men suffering from lower urinary tract symptoms. *J Urol* 2003; **169**: 2257-2261 [PMID: 12771764 DOI:10.1097/01.ju.0000067940.76090.73]

No author given

6 21st century heart solution may have a sting in the tail. *BMJ* 2002; **325**: 184 [PMID: 12142303 DOI:10.1136/bmj.325.7357.184]

Volume with supplement

7 **Geraud G**, Spierings EL, Keywood C. Tolerability and safety of frovatriptan with short- and long-term use for treatment of migraine and in comparison with sumatriptan. *Headache* 2002; **42** Suppl 2: S93-99 [PMID: 12028325 DOI:10.1046/j.1526-4610.42.s2.7.x]

Issue with no volume

8 **Banit DM**, Kaufer H, Hartford JM. Intraoperative frozen section analysis in revision total joint arthroplasty. *Clin Orthop Relat Res* 2002; (**401**): 230-238 [PMID: 12151900 DOI:10.1097/00003086-200208000-00026]

No volume or issue

9 Outreach: Bringing HIV-positive individuals into care. *HRSA Careaction* 2002; 1-6 [PMID: 12154804]

Books

Personal author(s)

10 **Sherlock S**, Dooley J. Diseases of the liver and billiary system. 9th ed. Oxford: Blackwell Sci Pub, 1993: 258-296

Chapter in a book (list all authors)

11 **Lam SK**. Academic investigator's perspectives of medical treatment for peptic ulcer. In: Swabb EA, Azabo S. Ulcer disease: investigation and basis for therapy. New York: Marcel Dekker, 1991: 431-450

Author(s) and editor(s)

12 **Breedlove GK**, Schorfheide AM. Adolescent pregnancy. 2nd ed. Wieczorek RR, editor. White Plains (NY): March of Dimes Education Services, 2001: 20-34

Conference proceedings

13 **Harnden P**, Joffe JK, Jones WG, editors. Germ cell tumours V. Proceedings of the 5th Germ cell tumours Conference; 2001 Sep 13-15; Leeds, UK. New York: Springer, 2002: 30-56

Conference paper

14 **Christensen S**, Oppacher F. An analysis of Koza's computational effort statistic for genetic programming. In: Foster JA, Lutton E, Miller J, Ryan C, Tettamanzi AG, editors. Genetic programming. EuroGP 2002: Proceedings of the 5th European Conference on Genetic Programming; 2002 Apr 3-5; Kinsdale, Ireland. Berlin: Springer, 2002: 182-191

Electronic journal (list all authors)

15 Morse SS. Factors in the emergence of infectious diseases. Emerg Infect Dis serial online, 1995-01-03, cited 1996-06-05; 1(1): 24 screens. Available from: URL: http://www.cdc.gov/ncidod/eid/index.htm

Patent (list all authors)

16 **Pagedas AC**, inventor; Ancel Surgical R&D Inc., assignee. Flexible endoscopic grasping and cutting device and positioning tool assembly. United States patent US 20020103498. 2002 Aug 1

Statistical data

Write as mean ± SD or mean ± SE.

Statistical expression

Express *t* test as *t* (in italics), *F* test as *F* (in italics), chi square test as χ^2 (in Greek), related coefficient as *r* (in italics), degree of freedom as υ (in Greek), sample number as *n* (in italics), and probability as *P* (in italics).

Units

Use SI units. For example: body mass, m (B) = 78 kg; blood pressure, p (B) = 16.2/12.3 kPa; incubation time, t (incubation) = 96 h, blood glucose concentration, c (glucose) 6.4 ± 2.1 mmol/L; blood CEA mass concentration, p (CEA) = 8.6 24.5 μg/L; CO_2 volume fraction, 50 mL/L CO_2, not 5% CO_2; likewise for 40 g/L formaldehyde, not 10% formalin; and mass fraction, 8 ng/g, *etc.* Arabic numerals such as 23, 243, 641 should be read 23 243 641.

The format for how to accurately write common units and quantums can be found at: http://www.wjgnet.com/1948-9366/g_info_20100312191949.htm.

Abbreviations

Standard abbreviations should be defined in the abstract and on first mention in the text. In general, terms should not be abbreviated unless they are used repeatedly and the abbreviation is helpful to the reader. Permissible abbreviations are listed in Units, Symbols

and Abbreviations: A Guide for Biological and Medical Editors and Authors (Ed. Baron DN, 1988) published by The Royal Society of Medicine, London. Certain commonly used abbreviations, such as DNA, RNA, HIV, LD50, PCR, HBV, ECG, WBC, RBC, CT, ESR, CSF, IgG, ELISA, PBS, ATP, EDTA, mAb, can be used directly without further explanation.

Italics

Quantities: *t* time or temperature, *c* concentration, *A* area, *l* length, *m* mass, *V* volume.
Genotypes: *gyrA*, *arg* 1, *c myc*, *c fos*, *etc.*
Restriction enzymes: *Eco*RI, *Hin*dI, *Bam*HI, *Kbo* I, *Kpn* I, *etc.*
Biology: *H. pylori*, *E coli*, *etc.*

Examples for paper writing

Editorial: http://www.wjgnet.com/1948-9366/g_info_20100312190249.htm

Frontier: http://www.wjgnet.com/1948-9366/g_info_20100312190321.htm

Topic highlight: http://www.wjgnet.com/1948-9366/g_info_20100312190447.htm

Observation: http://www.wjgnet.com/1948-9366/g_info_20100312190550.htm

Guidelines for basic research: http://www.wjgnet.com/1948-9366/g_info_20100312190653.htm

Guidelines for clinical practice: http://www.wjgnet.com/1948-9366/g_info_20100312190758.htm

Review: http://www.wjgnet.com/1948-9366/g_info_20100312190907.htm

Original articles: http://www.wjgnet.com/1948-9366/g_info_20100312191047.htm

Brief articles: http://www.wjgnet.com/1948-9366/g_info_20100312191203.htm

Case report: http://www.wjgnet.com/1948-9366/g_info_20100312191328.htm

Letters to the editor: http://www.wjgnet.com/1948-9366/g_info_20100312191431.htm

Book reviews: http://www.wjgnet.com/1948-9366/g_info_20100312191548.htm

Guidelines: http://www.wjgnet.com/1948-9366/g_info_20100312191635.htm

SUBMISSION OF THE REVISED MANUSCRIPTS AFTER ACCEPTED

Please revise your article according to the revision policies of *WJGS*. The revised version including manuscript and high-resolution image figures (if any) should be copied on a floppy or compact disk. The author should send the revised manuscript, along with printed high-resolution color or black and white photos, copyright transfer letter, and responses to the reviewers by courier (such as EMS/DHL).

Editorial Office

World Journal of Gastrointestinal Surgery
Editorial Department: Room 903, Building D,
Ocean International Center,
No. 62 Dongsihuan Zhonglu,
Chaoyang District, Beijing 100025, China
E-mail: wjgs@wjgnet.com
http://www.wjgnet.com
Telephone: +86-10-8538-1891
Fax: +86-10-8538-1893

Language evaluation

The language of a manuscript will be graded before it is sent for revision. (1) Grade A: priority publishing; (2) Grade B: minor language polishing; (3) Grade C: a great deal of language polishing needed; and (4) Grade D: rejected. Revised articles should reach Grade A or B.

Copyright assignment form

Please download a Copyright assignment form from http://www.wjgnet.com/1948-9366/g_info_20100312191901.htm.

Responses to reviewers

Please revise your article according to the comments/suggestions provided by the reviewers. The format for responses to the reviewers' comments can be found at: http://www.wjgnet.com/1948-9366/g_info_20100312191818.htm.

Proof of financial support

For paper supported by a foundation, authors should provide a copy of the document and serial number of the foundation.

Links to documents related to the manuscript

WJGS will be initiating a platform to promote dynamic interactions between the editors, peer reviewers, readers and authors. After a manuscript is published online, links to the PDF version of the submitted manuscript, the peer-reviewers' report and the revised manuscript will be put on-line. Readers can make comments on the peer reviewer's report, authors' responses to peer reviewers, and the revised manuscript. We hope that authors will benefit from this feedback and be able to revise the manuscript accordingly in a timely manner.

Science news releases

Authors of accepted manuscripts are suggested to write a science news item to promote their articles. The news will be released rapidly at EurekAlert/AAAS (http://www.eurekalert.org). The title for news items should be less than 90 characters; the summary should be less than 75 words; and main body less than 500 words. Science news items should be lawful, ethical, and strictly based on your original content with an attractive title and interesting pictures.

Publication fee

WJGS is an international, peer-reviewed, Open-Access, online journal. Articles published by this journal are distributed under the terms of the Creative Commons Attribution Non-commercial License, which permits use, distribution, and reproduction in any medium, provided the original work is properly cited, the use is non commercial and is otherwise in compliance with the license. Authors of accepted articles must pay a publication fee. The related standards are as follows. Publication fee: 1300 USD per article. Editorial, topic highlights, book reviews and letters to the editor are published free of charge..