ISSN 1948-5204 (online)

World Journal of *Gastrointestinal Oncology*

World J Gastrointest Oncol 2018 June 15; 10(6): 124-144



Published by Baishideng Publishing Group Inc

W J G O

World Journal of
Gastrointestinal Oncology

Contents

Monthly Volume 10 Number 6 June 15, 2018

REVIEW

124 Emerging evidence of the molecular landscape specific for hematogenous metastasis from gastric cancer
Shimizu D, Kanda M, Kodera Y

ORIGINAL ARTICLE

Retrospective Cohort Study

137 Trans-anal minimally invasive surgery for rectal neoplasia: Experience from single tertiary institution in China
Chen N, Peng YF, Yao YF, Gu J

Contents

World Journal of Gastrointestinal Oncology
Volume 10 Number 6 June 15, 2018

ABOUT COVER

Editorial Board Member of *World Journal of Gastrointestinal Oncology*, Deliang Cao, MD, PhD, Associate Professor, Department of Medical Microbiology, Immunology, and Cell Biology, Simmons Cooper Cancer Institute, Springfield, IL 62794, United States

AIM AND SCOPE

World Journal of Gastrointestinal Oncology (*World J Gastrointest Oncol*, *WJGO*, online ISSN 1948-5204, DOI: 10.4251) is a peer-reviewed open access academic journal that aims to guide clinical practice and improve diagnostic and therapeutic skills of clinicians.

WJGO covers topics concerning carcinogenesis, tumorigenesis, metastasis, diagnosis, prevention, prognosis, clinical manifestations, nutritional support, molecular mechanisms, and therapy of benign and malignant tumors of the digestive tract. The current columns of *WJGO* include editorial, frontier, diagnostic advances, therapeutics advances, field of vision, mini-reviews, review, topic highlight, medical ethics, original articles, case report, clinical case conference (Clinicopathological conference), and autobiography. Priority publication will be given to articles concerning diagnosis and treatment of gastrointestinal oncology diseases. The following aspects are covered: Clinical diagnosis, laboratory diagnosis, differential diagnosis, imaging tests, pathological diagnosis, molecular biological diagnosis, immunological diagnosis, genetic diagnosis, functional diagnostics, and physical diagnosis; and comprehensive therapy, drug therapy, surgical therapy, interventional treatment, minimally invasive therapy, and robot-assisted therapy.

We encourage authors to submit their manuscripts to *WJGO*. We will give priority to manuscripts that are supported by major national and international foundations and those that are of great clinical significance.

INDEXING/ABSTRACTING

World Journal of Gastrointestinal Oncology is now indexed in Science Citation Index Expanded (also known as SciSearch®), PubMed, and PubMed Central.

EDITORS FOR THIS ISSUE

Responsible Assistant Editor: *Xiang Li*
Responsible Electronic Editor: *Wen-Wen Tan*
Proofing Editor-in-Chief: *Lian-Sheng Ma*
Responsible Science Editor: *Fang-Fang Ji*
Proofing Editorial Office Director: *Jin-Lei Wang*

NAME OF JOURNAL
World Journal of Gastrointestinal Oncology

ISSN
ISSN 1948-5204 (online)

LAUNCH DATE
February 15, 2009

FREQUENCY
Monthly

EDITORIAL BOARD MEMBERS
All editorial board members resources online at http://www.wjgnet.com/1948-5204/editorialboard.htm

EDITORIAL OFFICE
Jin-Lei Wang, Director
World Journal of Gastrointestinal Oncology
Baishideng Publishing Group Inc
7901 Stoneridge Drive, Suite 501, Pleasanton, CA 94588, USA
Telephone: +1-925-2238242
Fax: +1-925-2238243
E-mail: editorialoffice@wjgnet.com
Help Desk: http://www.f6publishing.com/helpdesk
http://www.wjgnet.com

PUBLISHER
Baishideng Publishing Group Inc
7901 Stoneridge Drive,
Suite 501, Pleasanton, CA 94588, USA
Telephone: +1-925-2238242
Fax: +1-925-2238243
E-mail: bpgoffice@wjgnet.com
Help Desk: http://www.f6publishing.com/helpdesk
http://www.wjgnet.com

PUBLICATION DATE
June 15, 2018

COPYRIGHT
© 2018 Baishideng Publishing Group Inc. Articles published by this Open-Access journal are distributed under the terms of the Creative Commons Attribution Non-commercial License, which permits use, distribution, and reproduction in any medium, provided the original work is properly cited, the use is non commercial and is otherwise in compliance with the license.

SPECIAL STATEMENT
All articles published in journals owned by the Baishideng Publishing Group (BPG) represent the views and opinions of their authors, and not the views, opinions or policies of the BPG, except where otherwise explicitly indicated.

INSTRUCTIONS TO AUTHORS
http://www.wjgnet.com/bpg/gerinfo/204

ONLINE SUBMISSION
http://www.f6publishing.com

WJGO World Journal of Gastrointestinal Oncology

Submit a Manuscript: http://www.f6publishing.com

DOI: 10.4251/wjgo.v10.i6.124

World J Gastrointest Oncol 2018 June 15; 10(6): 124-136

ISSN 1948-5204 (online)

REVIEW

Emerging evidence of the molecular landscape specific for hematogenous metastasis from gastric cancer

Dai Shimizu, Mitsuro Kanda, Yasuhiro Kodera

Dai Shimizu, Mitsuro Kanda, Yasuhiro Kodera, Department of Gastroenterological Surgery (Surgery II), Nagoya University Graduate School of Medicine, Nagoya 466-8550, Japan

ORCID number: Dai Shimizu (0000-0001-7982-1079); Mitsuro Kanda (0000-0001-5464-3819); Yasuhiro Kodera (0000-0002-6173-7474).

Author contributions: Shimizu D wrote the manuscript; Kanda M and Kodera Y revised the manuscript.

Conflict-of-interest statement: The authors have no conflicts of interest or financial support to disclose.

Open-Access: This article is an open-access article which was selected by an in-house editor and fully peer-reviewed by external reviewers. It is distributed in accordance with the Creative Commons Attribution Non Commercial (CC BY-NC 4.0) license, which permits others to distribute, remix, adapt, build upon this work non-commercially, and license their derivative works on different terms, provided the original work is properly cited and the use is non-commercial. See: http://creativecommons.org/licenses/by-nc/4.0/

Manuscript source: Invited manuscript

Correspondence to: Mitsuro Kanda, MD, PhD, Research Fellow, Department of Gastroenterological Surgery (Surgery II), Nagoya University Graduate School of Medicine, 65 Tsurumai-cho, Showa-ku, Nagoya 466-8550,
Japan. m-kanda@med.nagoya-u.ac.jp
Telephone: +81-52-7442249
Fax: +81-52-7442255

Received: February 23, 2018
Peer-review started: February 23, 2018
First decision: March 23, 2018
Revised: March 23, 2018
Accepted: April 19, 2018
Article in press: April 19, 2018
Published online: June 15, 2018

Abstract

Gastric cancer (GC) is one of the most frequently diagnosed cancers in the world. Most GC patients are diagnosed when the cancer is in an advanced stage, and consequently, some develop metastatic lesions that generally cause cancer-related death. Metastasis establishment is affected by various conditions, such as tumor location, hemodynamics and organotropism. While digestive cancers may share a primary site, certain cases develop hematogenous metastasis with the absence of peritoneal metastasis, and vice versa. Numerous studies have revealed the clinicopathological risk factors for hematogenous metastasis from GC, such as vascular invasion, advanced age, differentiation, Borrmann type 1 or 2 and expansive growth. Recently, molecular mechanisms that contribute to metastatic site determination have been elucidated by advanced molecular biological techniques. Investigating the molecules that specifically participate in metastasis establishment in distinct secondary organs will lead to the development of novel biomarkers for patient stratification according to their metastatic risk and strategies for preventing and treating distinct metastases. We reviewed articles related to the molecular landscape of hematogenous metastasis from GC.

Key words: Gastric cancer; Hematogenous metastasis; Hepatic metastasis; Molecular mechanism; Biomarker; Premetastatic niche

© The Author(s) 2018. Published by Baishideng Publishing Group Inc. All rights reserved.

Core tip: Gastric cancer (GC) has high cancer-related mortality, which is mainly caused by distant metastasis including hematogenous metastasis. Numerous steps are required to establish a metastatic focus, and understanding the molecular mechanisms of each step is necessary to conquer metastasis. Development and dissemination of sequencing technology have elucidated some of the molecular biological mechanisms associated with cancer metastasis. This review aims to summarize the molecules reportedly contributing to hematogenous metastasis from GC and to become

the groundwork for the further development of novel biomarkers and molecular targets.

Shimizu D, Kanda M, Kodera Y. Emerging evidence of the molecular landscape specific for hematogenous metastasis from gastric cancer. *World J Gastrointest Oncol* 2018; 10(6): 124-136 Available from: URL: http://www.wjgnet.com/1948-5204/full/v10/i6/124.htm DOI: http://dx.doi.org/10.4251/wjgo.v10.i6.124

INTRODUCTION

Malignant tumor cells have characteristics unlike noncancerous cells, such as autonomous growth, immortalization, invasion and metastasis. Among these characteristics, metastasis greatly affects the quality of life of patients and is the main cause of cancer-related mortality. Understanding the mechanism and management of metastasis is urgently required to improve the prognosis of cancer patients.

The establishment of metastasis is affected by various conditions. Metastatic sites depend on anatomical and hemodynamic structures of the vascular system[1]. Digestive cancers have a higher incidence of hepatic metastasis than other malignancies, and colon cancer tends to metastasize to the liver more frequently than rectal cancer because of the portal vein reflux. Alternatively, the frequency of hepatic metastasis is lower in gastric cancer (GC) than that in colon cancer despite the similar portal vein reflux in both cancers[2]. Cancers have respective organotropism that cannot be illustrated by only the anatomical viewpoint. A compatibility between circulating tumor cells and a premetastatic niche is required, which is referred to as the seed and soil hypothesis[3]. This hypothesis has pioneered the molecular biological understanding of the mechanism of tumor metastasis. Recently, improved sequencing technology has provided new insight into the steps required for tumor metastasis, such as vascular invasion, detachment, survival in hypoxic or non-anchored environments, immune evasion, tissue engraftment, and colonization[4,5]. In addition to metastatic organotropism due to the primary organ, intratumor and intertumor heterogeneity contributes to metastatic target organ determination[6,7]. Only an appropriate subclone with suitable attributes for a certain microenvironment can form a metastatic focus in a corresponding organ. In this article, we review the molecules associated with hematogenous metastasis from GC and microenvironment establishment for hepatic metastasis that is representative of hematogenous metastasis and list the molecules in Table 1 and Figure 1.

GC is the third leading cause of cancer-related death in both sexes worldwide[8]. The prognosis of patients with GC is dismal: The 5-year survival for all patients is approximately 50% and is only 25%-30% for patients with advanced GC due to a lack of curative therapeutic agents and sensitive biomarkers predicting recurrence[9]. Concerning peritoneal dissemination that is the most frequent metastasis from GC, development of recent therapeutic strategies might improve the prognosis of GC patients[10,11]. Surgical resection of hepatic metastasis can improve the outcome of GC patients, though the adaptation of surgical treatment for hematogenous metastasis is limited[12]. The development of remedies against hematogenous metastasis has stalled. Elucidating the molecular biological mechanisms specific for hematogenous metastasis from GC will be a significant and effectual step for the development of novel biomarkers and therapeutic target molecules, which will lead to the improvement of patients' prognoses.

EPITHELIAL MESENCHYMAL TRANSITION AND INVASION INTO THE CIRCULATION

Epithelial mesenchymal transition and invasion into the circulation are the first steps for distant metastasis from the primary lesion. To spread to other organs through the blood stream, tumor cells must invade the basal lamina, reach and invade vessels, and detach from the primary tumor nodule. Then, single tumor cells or tumorspheres must acquire a mesenchymal phenotype and resist anoikis to arrive at a target organ. We have listed the genes that reportedly contribute to these steps and summarized the studies below.

Vimentin

Vimentin (VIM) is a type Ⅲ intermediate filament protein that is mainly expressed in mesenchymal cells and an important marker of epithelial mesenchymal transition (EMT)[13]. Epithelial cancer cells acquire motility and metastatic potential by cellular re-programming to a mesenchymal phenotype. Increased vimentin expression has been reported in various cancers including gastrointestinal cancers[14,15]. Zhao *et al*[16] explored the clinical significance of VIM expression and human epidermal growth factor receptor 2 (HER2) status in GC tissues by immunohistochemistry (IHC). They found that VIM expression was significantly correlated with older age, advanced stage, poorly differentiated type, venous invasion, hepatic metastasis and recurrence and that HER2 status was correlated with advanced cancer, poor differentiation, venous invasion, hepatic metastasis and recurrence. There was a significant correlation between VIM expression and HER2-positivity. VIM expression was detected in 9.8% in GC patients and was not detected in early GC patients. The 3-year survival of the patients with vimentin-positive GC was significantly poorer than that of patients with vimentin-negative GC. VIM positivity was an independent prognostic factor in multivariate analysis with respect to overall survival. VIM plays an important role in metastasis and may have a more requisite role in the establishment of hematogenous metastasis in GC. EMT inhibitors in-

Table 1 Molecules reported to be associated with hematogenous metastasis from gastric cancer

Molecule	Full name	Biological function	Specimens	Detection methods	*In vivo*	Associating molecules and cells	Ref.
EMT and invasion into the circulation							
VIM	Vimentin	Type Ⅲ intermediate filament	GC tissue	IHC	-	*HER2*	[16]
GPR155	G protein-coupled receptor 155	Seven-pass transmembrane receptor	GC tissue, GC cell line	qPCR, IHC	-	*TWIST1, WNT5B, p-ERK1/2, p-STAT1*	[19]
Survival in the circulation							
HIF-1α	Hypoxia inducible factor-1 alpha	Transcription factor in response to hypoxia	GC tissue	IHC	-	-	[25]
EGFL7	Epidermal growth factor-like domain-containing protein 7	Epidermal growth factor for vasculogenesis	GC tissue, GC cell line	qPCR, WB, IHC	Yes	*AKT, SNAI1*	[30]
Premetastatic niche							
CXCL1	C-X-C motif chemokine ligand 1	Inflammatory chemokine binding CXCR2	CRC cell line, liver (M)^1, lung (M)^1, cecum (M)^1	ELISA, FCM	Yes	*CXCR2, VEGF-A, MDSCs*	[36]
TIMP1	Tissue inhibitor of metallopeptidase 1	Inhibitor of MMPs	Plasma, CRC tissue, CRC cell line, liver (M)^1	qPCR, ELISA	Yes	*SDF-1*, Neutrophil	[43]
			Plasma, PDAC tissue, PDAC cell line (M), liver (M)	qPCR, ELISA, IHC	Yes	*PI3K, CD63, SDF-1, HSC*, Neutrophil	[44]
Exosome	-	Cell-derived membrane vesicle	CRC tissue, serum, CRC cell line	qPCR, WB	Yes	miR-203	[51]
			PDAC cell line, liver (M)^1, lung (M)^1, spleen (M)^1, kidney (M)^1, brain (M)^1, bone marrow (M)^1	WB, IHC, IF, FCM, Proteomics	Yes	Proteins^2	[52]
Migration, invasion and proliferation at the target organs							
NFKB1/p105	Nuclear factor kappa B subunit 1	Transcription factor	GC tissue	FCM	-	-	[55]
			GC tissue	FCM	-	*Ki-67*	[57]
MAP1LC3	Microtubule associated protein 1 light chain 3	Subunit of MAP1 and associated with autophagy	GC tissue	IHC	-	-	[63]
BECN1	Beclin1	Autophagy regulator and component of PI3K complex	GC tissue	IHC	-	-	[63]
SQSTM1/p62	sequestosome 1	Activator of NF-kB signaling	GC tissue	IHC	-	-	[63]
MFSD4	Major facilitator superfamily domain containing 4	Multi-pass transmembrane protein	GC tissue, GC cell line	qPCR	-	*BMP2, NUDT13,* OCLN	[64]
PAK1	p21 (RAC1) activated kinase 1	serine/threonine p21-activating kinase	GC tissue, GC cell line	qPCR, WB, IHC, IF	Yes	*ATF2*, miR-132, *CD44, FN1*	[66]
Angiogenesis							
VEGF-D	Vascular endothelial growth factor-D	Growth factor for angiogenesis	GC tissue	IHC	-	-	[70]
TYMP	Thymidine phosphorylase	Angiogenic factor	GC tissue	IHC	-	-	[72]
			GC tissue	IHC	-	-	[73]
Biomarkers predicting hematogenous metastasis from GC							
IL-6	Interleukin-6	Inflammatory cytokines	Serum	ELISA, CLEIA	-	HGF	[78]
Glut1	Glucose transporter-1	Glucose transporter	GC tissue	IHC	-	-	[79]
HER2	Human epidermal growth factor receptor 2	Epidermal growth factor receptor	GC tissue	IHC, FISH	-	-	[80]
			GC tissue	IHC, FISH	-	-	[81]
NCPAP3	NTase domain containing non-canonical poly(A) polymerase 3	mRNA stabilizing factor	GC tissue, GC cell line	qPCR	-	-	[82]
NPM1	Nucleophosmin 1	Nucleolar protein	GC tissue	IHC	-	-	[83]
CXCR4	C-X-C motif chemokine receptor 4	Inflammatory chemokine receptor binding CXCL12	GC tissue	IHC	-	*CXCL12*	[84]
CXCL12	C-X-C motif chemokine ligand 12	Inflammatory chemokine binding CXCR4	GC tissue	IHC	-	*CXCR4*	[84]

D-Dimer	-	Fibrin degradation product	Plasma	LEIA	-	-	[85]
Fibrinogen	-	Coagulation factor	Plasma	Clauss clotting method	-	-	[86]
CD44v6	CD44 variant 6	Adhesion molecule	GC tissue	qPCR, IHC	-	-	[87]

[1](M): Specimen obtained from mouse; [2]70 proteins were listed in the original article. IHC: Immunohistochemistry; qPCR: Quantitative reverse transcription polymerase chain reaction; *TWIST1*: Twist family bHLH transcription factor 1; WNT5B: Wingless-type MMTV integration site family, member 5B; p-: Phosphorylated; ERK1/2: Extracellular signal-regulated kinase 1 and 2; *STAT1*: Signal transducer and activator of transcription 1; WB: Western blotting; AKT: AKT serine/threonine kinase; *SNAI1*: Snail family transcriptional repressor 1; CRC: Colorectal cancer; ELISA: Enzyme-linked immunosorbent assay; FCM: Flow cytometry; MDSCs: Myeloid-derived suppressor cells; MMPs: Matrix metalloproteinases; *SDF-1*: Stromal cell-derived factor 1; PDAC: Pancreatic ductal adenocarcinoma; PI3K: Phosphatidylinositol-4,5-bisphosphate 3-kinase; HSC: Hepatic stellate cell; miR: MicroRNA; IF: Immunofluorescence; Ki-67: Marker of proliferation Ki-67; MAP1: Microtubule-associated proteins 1; BMP2: Bone morphogenetic protein 2; *NUDT13*: Nudix hydrolase 13; *OCLN*: Occluding; *ATF-2*: Activating transcription factor 2; FN1: Fibronectin 1; CLEIA: Chemiluminescent enzyme immuno assay; HGF: Hepatocyte growth factor; FISH: Fluorescence *in situ* hybridization; GC: Gastric cancer.

cluding TGF-β signaling pathway inhibitor might be a therapeutic agent for hematogenous metastasis from GC[17].

G protein-coupled receptor 155

G protein-coupled receptors (*GPCRs*) are seven-pass transmembrane receptors that participate in diverse physiological processes including visual sensing, immune responce, cell viability, and tumor metastasis[18]. Ligand binding to *GPCRs* activates the G protein and intracellular signaling. Because there are numerous *GPCRs* and they are the origin of many intracellular signals, *GPCRs* represent 30%-50% of the targets of currently marketed therapeutic drugs[19]. *GPR155* is a member of the *GPCR* family and little is known about its function. Our recent global expression analysis of primary GC tissues obtained from patients with synchronous hepatic metastasis and without metastasis to the peritoneal cavity or distant lymph nodes uncovered that *GPR155* was a molecule specific for hematogenous metastasis[20]. *GPR155* was the most downregulated gene in GC tissues with synchronous hepatic metastasis compared with GC tissues without hepatic metastasis. In stage Ⅳ GC, the expression level of *GPR155* was significantly lower in patients with synchronous hematogenous metastasis compared with patients without hematogenous metastasis. In stage Ⅱ/Ⅲ GC, the patients in the *GPR155* low expression group had significantly higher cumulative incidence of hematogenous recurrence. Multivariate analysis showed that downregulated expression of *GPR155* mRNA was an independent predictor of hematogenous metastasis. Furthermore, we revealed that the expression level of *GPR155* was inversely correlated with the expression of *TWIST1* and *WNT5B*, which have been well known to play pivotal roles in *EMT*. Inhibition of *GPR155* expression using siRNA specific for *GPR155* increased the level of p-ERK1/2 and p-STAT1 and cell proliferation and invasion capacity *in vitro*. We found that *GPR155* may represent a molecule specific for hematogenous metastasis from GC *via* EMT and cell viability promotion and may be a putative biomarker for diagnosing and predicting hematogenous metastasis from GC. *GPR155* is a transmembrane receptor, is expected to be a druggable target.

SURVIVING IN THE CIRCULATION

When tumor cells detach from the primary nodule and enter the circulation, they are exposed to stress from hypoxia in the portal vein and a non-adherent state. Activation of an alternative metabolic pathway under hypoxia and acquisition of anoikis resistance are necessary to endure these environmental selective pressures[21,22]. A subclone that evolves to adapt itself to this severe environment for epithelial cells can reach the new soil alive. Here, we review the molecules that contribute to environmental adaptation that are reportedly related to hematogenous metastasis from GC.

Hypoxia inducible factor-1 alpha

The hypoxic environment is known to be related to angiogenesis, a malignant tumor phenotype and resistance to therapies[23]. The adaptation to a hypoxic environment is an important advantage for the development of distant metastases[24]. Hypoxia inducible factor-1 alpha (*HIF-1α*) expression is suppressed under normal oxygen partial pressure by the ubiquitin-proteasome pathway. When oxygen supply becomes deficient, the concentration of *HIF-1α* is elevated, promoting transcription of vascular endothelial growth factor (*VEGF*), glucose transporter 1, platelet derived growth factor subunit B, carbonic anhydrase 9, *etc*., by forming a heterodimer with *HIF-1β*[25]. Some studies have suggested the utility of HIF-1α inhibitor to suppress cancer cell activity[26,27]. GC cells that have detached from a primary lesion can survive and engraft in the portal vein, which is hypoxic, to form metastatic loci. Chen *et al*[28] showed that HIF-1α overexpression in GC tissue was more frequent in patients with hepatic metastases than without hepatic metastasis. They also reported that HIF-1α was higher in patients with peritoneal metastasis than in patients without peritoneal metastasis, but the population of high HIF-1α still tended to be large in patients with hepatic metastasis. HIF-1α must play an important role in distant metastases including hematogenous metastasis from GC.

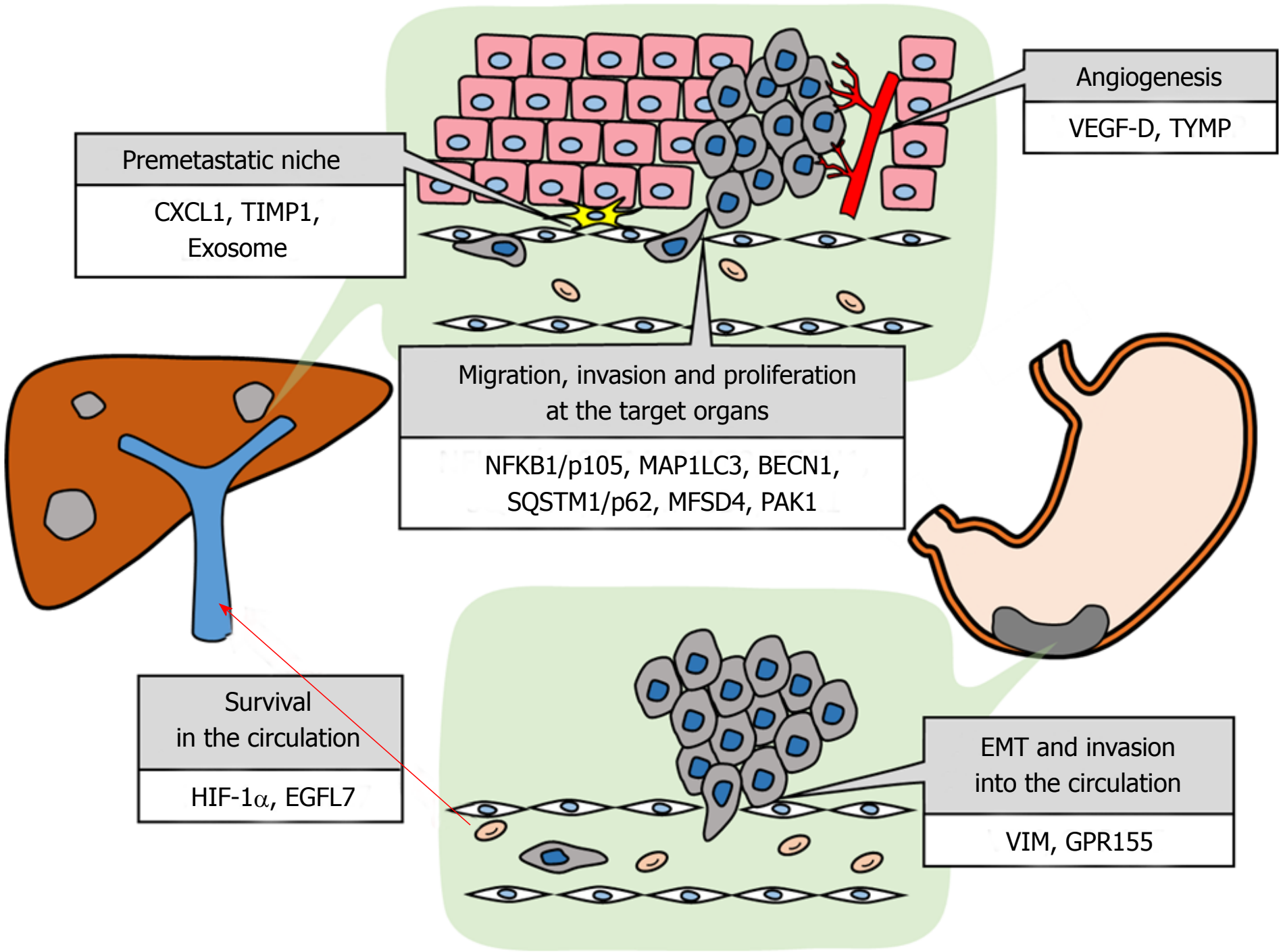
Premetastatic niche
CXCL1, TIMP1, Exosome
Angiogenesis
VEGF-D, TYMP
Migration, invasion and proliferation at the target organs
NFKB1/p105, MAP1LC3, BECN1, SQSTM1/p62, MFSD4, PAK1
Survival in the circulation
HIF-1α, EGFL7
EMT and invasion into the circulation
VIM, GPR155

Figure 1 Schema of molecules associated with each step of the establishment of hepatic metastasis from gastric cancer. VIM: Vimentin; GPR155: G protein-coupled receptor 155; HIF-1α: Hypoxia inducible factor-1 alpha; EGFL7: Epidermal growth factor-like domain-containing protein 7; CXCL1: C-X-C motif chemokine ligand 1; TIMP1: Tissue inhibitor of metallopeptidase 1; NFKB1/p105: Nuclear factor kappa B subunit 1; MAP1LC3: Microtubule associated protein 1 light chain 3; BECN1: Beclin1; SQSTM1/p62: Sequestosome 1; MFSD4: Major facilitator superfamily domain containing 4; PAK1: P21 (RAC1) activated kinase 1; VEGF-D: Vascular endothelial growth factor-D; TYMP: Thymidine phosphorylase.

Epidermal growth factor-like domain-containing protein 7

In a physiological state, epithelial cells, including neoplastic cells, suppress anoikis by adhering to the extracellular matrix (ECM) and adjacent cells *via* integrin or cadherin, and a loss of adhesion induces apoptosis[29]. Anoikis resistance is an important factor for metastasizing to distant organs in various cancers[30]. In GC, anoikis resistance has been relatively well investigated in peritoneal metastasis, which is the most frequent metastasis from GC[31,32]. Luo *et al*[33] demonstrated that epidermal growth factor-like domain-containing protein 7 (EGFL7) promoted metastasis by activating EMT through an EGFR-AKT-Snail signaling pathway and by protecting GC cells from anoikis. Overexpression of EGFL7 significantly decreased apoptotic GC cells in suspension culture, and GC cells treated with *EGFL7*-specific shRNA had a significantly higher percentage of apoptotic cells. Moreover, they showed that EGFL7-overexpressing cells grew into larger tumors and were more likely to metastasize to the liver compared to *EGFL7*-underexpressing CG cells *in vivo*. Although the mouse xenografts in their study were ectopic subcutaneous tumors, the results suggested that EGFL7 should play a pivotal role in the establishment of hematogenous metastasis *via* anoikis resistance.

PREMETASTATIC NICHE

In 1978, Schofield[34] postulated that the microenvironment could maintain hematopoietic stem cells and advocated the concept of the niche for stemness in the spleen. Recently, the concept has been extended to a metastatic niche as the microenvironment that is conducive to the survival and proliferation of metastatic cancer cells[35]. A premetastatic niche is the soil in secondary organs that is formed before the arrival of circulating tumor cells by factors from primary tumor cells that adjust the premetastatic niche. Studies on blocking premetastatic niche formation may provide novel treatment strategies to prevent distant metastasis and cure cancers, as cancers cannot be cured when they metastasize to distant organ. To the best of our knowledge, there have been no reports regarding a hematogenous premetastatic niche. Hence, elements reported to be involved in premetastatic niche formation in gastrointestinal cancers are introduced below.

C-X-C motif chemokine ligand 1

C-X-C motif chemokine ligand 1 *(CXCL1)* encodes an 11 kDa chemokine and is a member of the *CXC* family. *CXCL1* is secreted by macrophages and epithelial cells and acts as a chemoattractant for neutrophils[36]. *CXCL1* participates in angiogenesis, inflammation, wound healing and development of the spinal cord, and its aberrant expression facilitates tumorigenesis, cell proliferation and metastasis in certain cancers[37,38]. In colorectal cancer (CRC), *CXCL1* contributes to premetastatic niche formation by recruiting *C-X-C* motif chemokine receptor (*CXCR2*)-positive myeloid-derived suppressor cells (MDSCs)[39]. *VEGF-A* secreted by primary CRC cells stimulates tumor associated macrophages (TAMs) in the primary focus to produce *CXCL1*. The secreted *CXCL1* drives circulating MDSCs to the premetastatic liver. MDSCs isolated from premetastatic livers of xenograft mice bearing human CRC cells in the cecal wall promote CRC cell survival. The cancer cells in the primary focus drive MDSCs to the liver *via* CXCL1 from TAMs and might form a premetastatic niche to evade innate and adaptive immune responses.

Tissue inhibitor of metallopeptidase 1

The balance of proteases and their inhibitors is essential to maintain homeostasis in the ECM. Matrix metalloproteinases (MMPs) are proteinases that decompose the ECM, and their overexpression is reportedly associated with tumor spread and metastasis[40]. Several studies have reported the correlation between MMP overexpression and poor prognosis in several malignant tumors[41]. Thus, it was hypothesized that inhibition of MMPs would result in a therapeutic anticancer effect[42]. Tissue inhibitor of metallopeptidase (TIMP) inhibits MMP activity and prevents tissue destruction by forming a complex with MMPs[43]. However, increased expression of TIMP1 is negatively correlated with survival in patients with several cancer types[44,45]. Additionally, in GC patients, the association between TIMP1 overexpression and poor outcome has been reported[46]. Seubert *et al*[47] described that TIPM1 created a premetastatic niche for hepatic metastasis from CRC, which explains the paradoxical phenomenon where TIMP expression correlated with poor prognosis in cancer patients even though TIMP inhibits MMPs. In their study, high TIMP1 levels in plasma and CRC tissue were associated with hepatic metastasis in CRC patients, and TIMP1-overexpressing tumors transplanted subcutaneously diverted intravenously injected cancer cells to the liver in a mouse model. Additionally, they demonstrated that TIMP1 established a premetastatic niche by recruiting stromal cell-derived factor 1 (SDF-1)-dependent neutrophils to the liver. Grünwald *et al*[48] demonstrated that TIMP1 secreted by pancreatic cancer activated hepatic stellate cells (HSCs) *via* CD63 and phosphatidylinositol 3-kinase signaling and increased susceptibility of the liver to pancreatic cancer cells. Activated HSCs expressed SDF-1, attracting neutrophils to the liver, which formed a premetastatic niche. *In vivo*, systemic increases in TIMP1 lead to more hepatic metastases after injections of pancreatic cancer cells, which did not occur in TIMP1 or CD63 knockout mice. HSCs were reported to participate in the formation of a premetastatic niche in other studies[49]. TIMP1 overexpression was observed in GC tissue, and therefore TIMP1 might contribute to the formation a hepatic premetastatic niche in GC[46].

Exosomes

Exosomes are small membrane vesicles derived from most eukaryotic cells *in vivo* and *in vitro*[50]. Derived exosomes exist not only in the ECM but also in bodily fluids, including blood, urine and cerebrospinal fluid, circulating in the body. Past studies have indicated that exosomes are associated with various biological processes, participating in apoptosis, angiogenesis, inflammation, coagulation and antigen presentation[51]. Moreover, exosomes function as a cargo transporting proteins and nucleic acids to target cells and act as a communication tool between distant cells[52]. Recently, exosomes from cancer cells were reported to facilitate cancer progression and metastasis and to suppress anti-tumor immunity[53,54]. Takano *et al*[55] described that circulating exosomal microRNA (miR)-203 was associated with distant metastasis in CRC patients. Exosomal miR-203 that originated from primary CRC was reportedly incorporated into monocytes and promoted the differentiation of monocytes to M2-tumor-associated macrophages (TAMs). In a xenograft mouse model, miR-203-transfected CRC cells developed more liver metastases than control CRC cells. Their result suggested that exosomes bearing miR-203 contribute to the establishment of a premetastatic niche *via* TAM promotion in the liver of CRC patients. Yu *et al*[56] demonstrated that exosomes derived from pancreatic cancer induced a liver premetastatic niche. They performed proteomic analysis on exosomal proteins and revealed that these proteins were involved in pancreatic cancer growth, invasion and metastasis. Interestingly, another study showed that exosomes had respective organotropism, which was prescribed by integrin on their membranes[57]. The organotropism of exosomes depended on the combination of the alpha chain and β chain of integrin and distinct cells in the target organ took up the circulating exosomes. Exosomes from cancer cells were delivered by integrin to a particular organ and formed a premetastatic niche *via* contained proteins or nucleic acids, leading to metastatic organotropism. Further exploration of exosomes should uncover more insights on organotropism and the mechanisms of metastasis.

MIGRATION, INVASION AND PROLIFERATION AT THE TARGET ORGANS

Cancer cells that arrive at a metastatic organ are trapped in a capillary plexus. Subsequently, the adhesion of cancer cells to epithelial cells is driven by selectin and integrin families[58]. Then, cancer cells migrate to the interval of epithelial cells and invade target organ tissue *via* adhesion to and decomposition of the basal lamina. Among the cancer cells that arrive at a metastatic target organ, only the cells that have acquired the capacities of adhesion, migration, invasion and proliferation can form a new tumor focus. We summarized the reported molecules associated with these steps.

Nuclear factor kappa B subunit 1

Ohyama *et al*[59] examined nuclear factor kappa B subunit 1 (NFKB1/p105) immunofluorescence intensity in GC cells isolated from 43 clinical specimens using flow cytometry. The intensity was higher in patients with hepatic metastasis than in patients without hepatic metastasis and was positively correlated with venous invasion. In contrast, the intensity was lower in patients with peritoneal metastasis than in patients without peritoneal metastasis. NFKB1/p105 intensity was not associated with nodal metastasis, lymphatic invasion, serosal invasion or histological type. Kimura *et al*[60] also reported a correlation between the p105-labeling rate detected by flow cytometry and hepatic metastasis from GC. In addition, they reported that NFKB1/p105 positivity by flow cytometry correlated positively with Ki-67 positivity, an index widely used for cell proliferation[61]. NFKB1/p105 in GC cells is a putative biomarker specific for hematogenous metastasis. It was also reported that 5-FU resistance might be overcome *via* suppression of phosphorylated NFKB in Epstein-Barr virus-positive gastric cancer[62]. The development of therapeutic agent targeting NFKB might lead to improvement of GC patients' prognosis.

Autophagy-related proteins

Autophagy is an intracellular degradation system that delivers cytoplasmic proteins and organelles to the lysosome, and it is an important system for maintaining intracellular homeostasis against pathogens and nutrient stress[63]. Additionally, there are contradictory aspects in autophagy regarding neoplasia. In non-cancerous cells, autophagy protects cells from adverse effects leading to malignant transformation, such as reactive oxygen species, aberration of organelles and DNA damage[64]. In contrast, autophagy acts as an important anti-apoptotic mechanism in established cancer cells resisting hypoxia, malnutrition and therapeutic agents[65]. Therefore, inhibiting autophagy should be a viable therapeutic strategy for cancers, and effective treatments with an anti-autophagy agent have been reported[66]. Sharifi *et al*[67] showed that autophagy was necessary for metastatic cells to migrate and invade by focal adhesion disassembly *via* proteolysis of paxillin. Their work marked the first anti-metastatic effect *via* autophagy inhibition and was a notable achievement. Masuda *et al*[68] indicated the correlation between autophagy-related proteins, microtubule associated protein 1 light chain 3, beclin1 and sequestosome 1/p62, and clinicopathological features. They investigated the expression of these proteins by IHC in 510 GC tissues. Autophagy, as determined by the expression of these proteins, was significantly correlated with poor survival rates and incidence of hepatic metastasis, but not with incidence of peritoneal metastasis. Understanding the role of autophagy in tumor survival and metastasis would help develop specific autophagy inhibitors and might improve the outcome of patients with GC.

Major facilitator superfamily domain containing 4

Major facilitator superfamily domain containing 4 (MFSD4) is located on chromosome 1q32.1 and encodes a multi-pass transmembrane protein, and its biological function has not yet been determined. We recently detected MFSD4 as a biomarker specific for hepatic metastasis of GC by sequencing RNA from the GC tissue of patients with or without hepatic metastasis[69]. Patients with low MFSD4 expression in primary GC tissues had significantly higher cumulative incidence of hepatic recurrence, and reduced MFSD4 expression was an independent risk factor of metachronous and synchronous hepatic metastasis. We indicated that DNA methylation in CpG islands of MFSD4 was one of the suppressive mechanisms of transcription. Furthermore, GC cell migration and invasion abilities were significantly increased by inhibition of MFSD4 expression using siRNA. MFSD4 should be a promising biomarker predicting hepatic metastasis in GC patients.

p21 (RAC1) activated kinase 1

p21 (RAC1) activated kinase 1 (PAK1) is a serine/threonine-protein kinase that plays a critical role in cytoskeleton dynamics, cell adhesion, migration, proliferation, apoptosis and mitosis[70]. Liu *et al*[71] delineated the downstream pathway of PAK1 in which PAK1 acted as an oncogenic factor. PAK1 suppressed the expression of miR-132 *via* phosphorylating activating transcription factor 2 (ATF2), which bound to the promoter of miR-132. Phosphorylation of ATF2 inhibited its nuclear translocation and resulted in the diminution of miR-132. Additionally, their bioinformatics analysis revealed direct targets of miR-132, including CD44 and fibronectin 1, whose inhibition induced tumor apoptosis. Furthermore, miR-132 overexpression inhibited cell adhesion and migration *in vitro* and hematogenous metastasis *in vivo*. The patients with lower miR-132 expression in GC tissue had significantly poorer prognoses, and hepatic metastatic tissues expressed significantly lower miR-132 compared with primary GC tissues while there were no differences between primary GC tissues and lymph node metastases or peritoneal metastases. PAK1 and its downstream pathway should be a useful biomarker and therapeutic target for hematogenous metastasis from GC.

ANGIOGENESIS

As in the primary lesion, growth factors and angiogenic factors are required for metastatic focus growth. Tumor angiogenesis is necessary to supply nutrients and oxygen, and to carry out metabolites for tumor growth[72]. Additionally, an increase in blood vessels leads to further metastatic opportunities. In this section, we introduce studies that investigated the relationship between angiogenic factors and hematogenous metastasis.

Vascular endothelial growth factor-D

Effectiveness of anti-VEGF and anti-VEGFR monoclonal antibodies were proved in clinical management[73-75]. Several studies have shown the association between vascular endothelial growth factor-D (VEGF-D) and lymph node metastasis in GC[76,77]. Deng *et al*[78] indicated that VEGF-D is associated with hepatic metastasis from GC. They investigated the correlation between hepatic metastasis and the expression levels of VEGF-A, VEGF-C, VEGF-D, VEGFR-3, and CD34 by IHC. VEGF-D, VEGFR-3, CD34, Lauren classification and lymph node metastasis were associated with hepatic metastasis after radical surgery in univariate analysis, and VEGF-D was the only independent indicator of hepatic metastasis in multivariate analysis. They concluded that VEGF-D is an important factor for predicting hepatic metastasis of GC. The VEGF family plays a key role in angiogenesis and lymphangiogenesis. Their study lacks evidence of the molecular mechanism of hepatic metastasis establishment, though VEGF-D might contribute to hepatic metastasis *via* angiogenesis, which increases intratumor blood flow and nourishes the metastatic tumor.

Thymidine phosphorylase

Thymidine phosphorylase (TYMP) is an enzyme involved in pyrimidine nucleotide metabolism and was recently reported to be identical to platelet-derived endothelial cell growth factor (PD-ECGF). PD-ECGF has angiogenic activity *in vitro* and *in vivo*[79]. Kimura *et al*[80] investigated the association of clinicopathological features with the expression of VEGF and TYMP in IHC analysis. In their study, there was a significant correlation between the positive expression of VEGF and lymphatic invasion. Additionally, the positive expression of TYMP and VEGF was significantly correlated with the frequency of hepatic recurrence. Moreover, patients with positivity of both TYMP and VEGF had significantly unfavorable prognoses. Their results indicated that combination analyses of TYMP and VEGF expression in GC appear to be well-characterized indicators of prognosis and suggested that co-expression of TYMP and VEGF, molecules contributing to angiogenesis, supported hepatic metastasis formation. Maeda *et al*[81] also reported that TYMP was associated with angiogenesis and hepatic metastasis from GC. They showed a correlation between TYMP expression and microvessel density in GC tissue by IHC. TYMP-positive patients had higher microvessel density and a significantly higher frequency of hepatic metastasis. Their result suggested that microangiogenesis promotes the establishment of hepatic metastasis.

BIOMARKERS PREDICTING HEMATOGENOUS METASTASIS FROM GC

Many cancer-related genes that should be putative biomarkers and therapeutic targets have been reported in the past[82,83]. In recent decades, the progress and generalization of sequencing technologies have enriched our molecular knowledge regarding cancers and revealed the molecular mechanisms specific for distinct metastatic organs and hematogenous metastasis[84,85]. While some studies have described mechanisms contributing to the establishment of hematogenous metastasis or downstream pathways, other studies have described biomarkers for predicting hematogenous metastasis. These biomarkers are useful for patient stratification, selection of therapeutic strategy and postoperative surveillance according to individual risk of metastasis and recurrence. Additionally, further investigation of molecular mechanisms might lead to the development of novel therapeutic target molecules. We listed the molecules reported as biomarkers of hematogenous metastasis in Table 1 and outlined some of them below[86-95].

Interleukin-6

Interleukin-6 (IL-6) is a representative inflammatory cytokine that participates in B cell maturation, T cell differentiation, activation of natural killer cells, suppression of regulatory T cells and cancer cachexia[96]. Additionally, IL-6 involvement in the biological activity of cancer cells has been previously reported[97,98]. High IL-6 expressing tumor cells formed more distant metastases in breast cancer, lung cancer and hepatocellular carcinoma[99,100]. Furthermore, adhesion of tumor cells to targeted organs, which leads to metastatic focus formation, is facilitated in high IL-6 expressing organs such as brain, lung, liver and bone marrow[101]. In GC, the association between IL-6 and clinicopathological factors has been reported[102,103]. Ashizawa *et al*[86] assessed the correlation of preoperative serum levels of IL-6 with GC patients' characteristics. They found that serum IL-6 level was significantly related to advanced stage, tumor depth, lymphatic invasion, venous invasion and hepatic metastasis. IL-6 expression in GC tissue or serum might be related to distant metastasis, and in particular, hepatic metastasis.

Glucose transporter-1

Glucose intake is increased in malignant tumor cells, which is facilitated by glucose transporters. Glucose transporter-1 (Glut1), a member of the glucose transporter family, is overexpressed in several cancers and is correlated with malignant phenotypes[104]. The association between Glut1 and GC was first reported in 2000. Kim *et al*[105] showed that high Glut1 protein expression was associated with an intestinal type of GC. In 2001, Kawamura *et al*[87] demonstrated that Glut1-positive GC by IHC had a significantly higher incidence of hepatic metastasis whereas there was no statistical significance regarding the correlation between Glut1 and peritoneal metastasis. Additionally, they showed that Glut1-positive GC cells were localized mainly in the central part of the tumor. The result was consistent with an adaptation to a hypoxic environment at the center of the tumor. It is expected that the transcription of Glut1 is activated *via* increased HIF1-α. Glut1 could be a putative biomarker for hepatic metastasis from GC.

Human epidermal growth factor receptor 2

HER is a member of the epidermal growth factor receptor family. HER2 is involved in the pathogenesis and poor prognosis of breast cancer and GC, and monoclonal antibodies to HER2, trastuzumab and pertuzumab have been applied clinically worldwide[106,107]. The major role of HER2 is to promote cell proliferation, suppress apoptosis, and facilitate tumorigenesis[108]. A few studies have reported the association between HER2 expression and GC patients' prognoses[109,110]. Lee *et al*[88] analyzed the relationship between HER2 expression and computed tomography (CT) imaging in GC patients. In their cohort of 276 patients, hepatic metastases were more frequently found in HER2-positive GC while peritoneal metastasis was more often found in HER2-negative GC. Hepatic metastases were significant independent factors that predict HER2-positive cancers. Similarly, Matsusaka *et al*[89] reported the correlation between HER2 positivity and hepatic metastasis in 1466 GC patients. In their data, the incidence of hepatic metastasis was significantly higher in HER2-positive patients, and moreover, HER2-positive patients had a significantly lower incidence of peritoneal metastasis. These two studies suggested that HER2 positivity was associated with hepatic metastasis from GC specifically and was negatively associated with peritoneal metastasis. As supportive data, a meta-analysis also demonstrated that HER2 positivity was associated with differentiated type and intestinal type, and differentiated type and Borrmann type1/2 are reportedly risk factors for hepatic metastasis from GC[111]. The mechanism is unknown; however, HER2 positivity may be a predictive biomarker for hepatic metastasis from GC.

NTase domain containing non-canonical poly(A) polymerase 3

We recently focused on genes reflecting the metastatic potential of GC cells and identified a NTase domain containing non-canonical poly(A) polymerase 3 (NCPAP3) as a predictor for hepatic metastasis[90]. NCPAP3 has been shown to regulate translation by acting as an mRNA stability factor and the gene has a mutation predicting worse prognosis in multiple myeloma[112]. NCPAP3 expression was decreased in GC tissue compared with adjacent noncancerous mucosae in most patients. Patients with lower NCPAP3 expression have a shorter overall survival and disease-free survival. Furthermore, lower NCPAP3 expression was significantly correlated with the cumulative incidence of hepatic metastasis while there was no significant difference in the cumulative incidence of peritoneal metastasis by NCPAP3 expression. Additionally, we revealed the mechanisms for suppression of NCPAP3 expression. Copy number alterations at the NCPAP3 locus were observed in the GC tissues of 35% of patients and in 50% of GC cell lines. Additionally, 42% of GC cell lines harbored single nucleotide variants, and all of these cell lines expressed lower NCPAP3 mRNA. Aberrant DNA methylation was not observed in GC cell lines. NCPAP3 not only associates with the malignant phenotype of GC but may also be a predictive biomarker specific for hepatic metastasis.

Nucleophosmin 1

Nucleophosmin 1 (NPM1) is a nucleolar phosphoprotein involved in numerous cellular processes, including centrosome duplication, histone assembly, protein chaperoning and cell proliferation[113,114]. NPM1 downregulates the tumor suppressor cyclin dependent kinase inhibitor 2A in the nucleolus and has inhibitory effects by activating transcription factor 5 (ATF5) and abrogating ATF5-induced G(2)/M cell cycle blockade[115,116]. Some studies revealed that positive expression of NPM1 in GC tissue was associated with poor prognosis in postoperative GC patients. Zhou *et al*[117] and Li *et al*[118] found that NPM1 level was linked to more advanced tumor stages and was an independent indicator for prognosis and recurrence. Ding *et al*[91] indicated a correlation between NPM1 expression and clinicopathological features including metastatic site. Patients with NPM1-positive GC had significantly higher rates of hepatic metastasis and recurrence. While the molecular basis remains to be elucidated, NPM1 expression might predict hepatic metastasis from GC.

CONCLUSION

The development of molecular techniques and bioinformatics has led to accumulated knowledge and an understanding of the mechanisms of distant metastasis from cancer. Cancers generate manifold subclones as seeds based on their genomic instability and heterogeneity. Subsequently, subclones that pass through the selection of each step for metastasis and adapt to the secondary organ, the so-called soil, have the opportunity to metastasize. Moreover, cancer cells create a pre-metastatic niche *via* secretion of exosomes. However, knowledge of the mechanism specific for hematogenous metastasis is scarce, and the full picture of organotropism has not yet been elucidated. Hematogenous metastasis is a factor that strongly contributes to poor prognosis in GC. Therefore, understanding and controlling its mechanism are significant issues. Further studies on this theme should improve GC patients' prognoses.

REFERENCES

1 **Ewing J.** Neoplastic diseases; a treatise on tumors. 2ed. Philadelphia London: W.B. Saunders company, 1922

2 **Weiss L.** Metastasis of cancer: a conceptual history from antiquity to the 1990s. *Cancer Metastasis Rev* 2000; **19**: I-XI, 193-383 [PMID: 11394186]

3 **Paget S.** The distribution of secondary growths in cancer of the

breast. 1889. *Cancer Metastasis Rev* 1989; **8**: 98-101 [PMID: 2673568]

4 **De Mattos-Arruda L**, Bidard FC, Won HH, Cortes J, Ng CK, Peg V, Nuciforo P, Jungbluth AA, Weigelt B, Berger MF, Seoane J, Reis-Filho JS. Establishing the origin of metastatic deposits in the setting of multiple primary malignancies: the role of massively parallel sequencing. *Mol Oncol* 2014; **8**: 150-158 [PMID: 24220311 DOI: 10.1016/j.molonc.2013.10.006]

5 **Shimizu D**, Kanda M, Kodera Y. Review of recent molecular landscape knowledge of gastric cancer. *Histol Histopathol* 2018; **33**: 11-26 [PMID: 28447336 DOI: 10.14670/hh-11-898]

6 **Naxerova K**, Reiter JG, Brachtel E, Lennerz JK, van de Wetering M, Rowan A, Cai T, Clevers H, Swanton C, Nowak MA, Elledge SJ, Jain RK. Origins of lymphatic and distant metastases in human colorectal cancer. *Science* 2017; **357**: 55-60 [PMID: 28684519 DOI: 10.1126/science.aai8515]

7 **Makohon-Moore AP**, Zhang M, Reiter JG, Bozic I, Allen B, Kundu D, Chatterjee K, Wong F, Jiao Y, Kohutek ZA, Hong J, Attiyeh M, Javier B, Wood LD, Hruban RH, Nowak MA, Papadopoulos N, Kinzler KW, Vogelstein B, Iacobuzio-Donahue CA. Limited heterogeneity of known driver gene mutations among the metastases of individual patients with pancreatic cancer. *Nat Genet* 2017; **49**: 358-366 [PMID: 28092682 DOI: 10.1038/ng.3764]

8 **Ferlay J**, Soerjomataram I, Dikshit R, Eser S, Mathers C, Rebelo M, Parkin DM, Forman D, Bray F. Cancer incidence and mortality worldwide: sources, methods and major patterns in GLOBOCAN 2012. *Int J Cancer* 2015; **136**: E359-E386 [PMID: 25220842 DOI: 10.1002/ijc.29210]

9 **Allemani C**, Weir HK, Carreira H, Harewood R, Spika D, Wang XS, Bannon F, Ahn JV, Johnson CJ, Bonaventure A, Marcos-Gragera R, Stiller C, Azevedo e Silva G, Chen WQ, Ogunbiyi OJ, Rachet B, Soeberg MJ, You H, Matsuda T, Bielska-Lasota M, Storm H, Tucker TC, Coleman MP; CONCORD Working Group. Global surveillance of cancer survival 1995-2009: analysis of individual data for 25,676,887 patients from 279 population-based registries in 67 countries (CONCORD-2). *Lancet* 2015; **385**: 977-1010 [PMID: 25467588 DOI: 10.1016/s0140-6736(14)62038-9]

10 **Kanda M**, Kodera Y, Sakamoto J. Updated evidence on adjuvant treatments for gastric cancer. *Expert Rev Gastroenterol Hepatol* 2015; **9**: 1549-1560 [PMID: 26414453 DOI: 10.1586/17474124.2015.1094373]

11 **Ishigami H**, Kitayama J, Kaisaki S, Hidemura A, Kato M, Otani K, Kamei T, Soma D, Miyato H, Yamashita H, Nagawa H. Phase II study of weekly intravenous and intraperitoneal paclitaxel combined with S-1 for advanced gastric cancer with peritoneal metastasis. *Ann Oncol* 2010; **21**: 67-70 [PMID: 19605503 DOI: 10.1093/annonc/mdp260]

12 **Kodera Y,** Fujitani K, Fukushima N, Ito S, Muro K, Ohashi N, Yoshikawa T, Kobayashi D, Tanaka C, Fujiwara M. Surgical resection of hepatic metastasis from gastric cancer: a review and new recommendation in the Japanese gastric cancer treatment guidelines. *Gastric Cancer* 2013; **17**: 206-212 [DOI: 10.1007/s10120-013-0299-x]

13 **Thiery JP**. Epithelial-mesenchymal transitions in tumour progression. *Nat Rev Cancer* 2002; **2**: 442-454 [PMID: 12189386 DOI: 10.1038/nrc822]

14 **Singh S**, Sadacharan S, Su S, Belldegrun A, Persad S, Singh G. Overexpression of vimentin: role in the invasive phenotype in an androgen-independent model of prostate cancer. *Cancer Res* 2003; **63**: 2306-2311 [PMID: 12727854]

15 **Shirahata A**, Sakata M, Sakuraba K, Goto T, Mizukami H, Saito M, Ishibashi K, Kigawa G, Nemoto H, Sanada Y, Hibi K. Vimentin methylation as a marker for advanced colorectal carcinoma. *Anticancer Res* 2009; **29**: 279-281 [PMID: 19331162]

16 **Zhao W**, Yue L, Zhou F, Xu C, Liang W, Sui A, Ding A, Qiu W. Clinical significance of vimentin expression and Her-2 status in patients with gastric carcinoma. *Clin Transl Sci* 2013; **6**: 184-190 [PMID: 23751022 DOI: 10.1111/cts.12043]

17 **Bartscht T**, Rosien B, Rades D, Kaufmann R, Biersack H, Lehnerta H, Ungefroren H. Inhibition of TGF-β Signaling in Tumor Cells by Small Molecule Src Family Kinase Inhibitors. *Anticancer Agents Med Chem* 2017; **17**: 1351-1356 [PMID: 28044939 DOI: 10.2174/1871520617666170103094946]

18 **Dorsam RT**, Gutkind JS. G-protein-coupled receptors and cancer. *Nat Rev Cancer* 2007; **7**: 79-94 [PMID: 17251915 DOI: 10.1038/nrc2069]

19 **Jo M**, Jung ST. Engineering therapeutic antibodies targeting G-protein-coupled receptors. *Exp Mol Med* 2016; **48**: e207 [PMID: 26846450 DOI: 10.1038/emm.2015.105]

20 **Shimizu D**, Kanda M, Tanaka H, Kobayashi D, Tanaka C, Hayashi M, Iwata N, Niwa Y, Takami H, Yamada S, Fujii T, Nakayama G, Fujiwara M, Kodera Y. GPR155 Serves as a Predictive Biomarker for Hematogenous Metastasis in Patients with Gastric Cancer. *Sci Rep* 2017; **7**: 42089 [PMID: 28165032 DOI: 10.1038/srep42089]

21 **Gilkes DM**, Semenza GL, Wirtz D. Hypoxia and the extracellular matrix: drivers of tumour metastasis. *Nat Rev Cancer* 2014; **14**: 430-439 [PMID: 24827502 DOI: 10.1038/nrc3726]

22 **Douma S**, Van Laar T, Zevenhoven J, Meuwissen R, Van Garderen E, Peeper DS. Suppression of anoikis and induction of metastasis by the neurotrophic receptor TrkB. *Nature* 2004; **430**: 1034-1039 [PMID: 15329723 DOI: 10.1038/nature02765]

23 **Muz B**, de la Puente P, Azab F, Azab AK. The role of hypoxia in cancer progression, angiogenesis, metastasis, and resistance to therapy. *Hypoxia* (Auckl) 2015; **3**: 83-92 [PMID: 27774485 DOI: 10.2147/hp.s93413]

24 **Lu X**, Kang Y. Hypoxia and hypoxia-inducible factors: master regulators of metastasis. *Clin Cancer Res* 2010; **16**: 5928-5935 [PMID: 20962028 DOI: 10.1158/1078-0432.ccr-10-1360]

25 **Wan J**, Chai H, Yu Z, Ge W, Kang N, Xia W, Che Y. HIF-1α effects on angiogenic potential in human small cell lung carcinoma. *J Exp Clin Cancer Res* 2011; **30**: 77 [PMID: 21843314 DOI: 10.1186/1756-9966-30-77]

26 **Riby JE**, Firestone GL, Bjeldanes LF. 3,3’-diindolylmethane reduces levels of HIF-1alpha and HIF-1 activity in hypoxic cultured human cancer cells. *Biochem Pharmacol* 2008; **75**: 1858-1867 [PMID: 18329003 DOI: 10.1016/j.bcp.2008.01.017]

27 **Sutendra G**, Dromparis P, Kinnaird A, Stenson TH, Haromy A, Parker JM, McMurtry MS, Michelakis ED. Mitochondrial activation by inhibition of PDKII suppresses HIF1a signaling and angiogenesis in cancer. *Oncogene* 2013; **32**: 1638-1650 [PMID: 22614004 DOI: 10.1038/onc.2012.198]

28 **Chen L**, Shi Y, Yuan J, Han Y, Qin R, Wu Q, Jia B, Wei B, Wei L, Dai G, Jiao S. HIF-1 alpha overexpression correlates with poor overall survival and disease-free survival in gastric cancer patients post-gastrectomy. *PLoS One* 2014; **9**: e90678 [PMID: 24614305 DOI: 10.1371/journal.pone.0090678]

29 **Buchheit CL**, Weigel KJ, Schafer ZT. Cancer cell survival during detachment from the ECM: multiple barriers to tumour progression. *Nat Rev Cancer* 2014; **14**: 632-641 [PMID: 25098270 DOI: 10.1038/nrc3789]

30 **Duxbury MS**, Ito H, Zinner MJ, Ashley SW, Whang EE. Focal adhesion kinase gene silencing promotes anoikis and suppresses metastasis of human pancreatic adenocarcinoma cells. *Surgery* 2004; **135**: 555-562 [PMID: 15118593 DOI: 10.1016/j.surg.2003.10.017]

31 **Nishimura S**, Adachi M, Ishida T, Matsunaga T, Uchida H, Hamada H, Imai K. Adenovirus-mediated transfection of caspase-8 augments anoikis and inhibits peritoneal dissemination of human gastric carcinoma cells. *Cancer Res* 2001; **61**: 7009-7014 [PMID: 11585725]

32 **Sakai H**, Ohuchida K, Mizumoto K, Cui L, Nakata K, Toma H, Nagai E, Tanaka M. Inhibition of p600 expression suppresses both invasiveness and anoikis resistance of gastric cancer. *Ann Surg Oncol* 2011; **18**: 2057-2065 [PMID: 21347795 DOI: 10.1245/s10434-010-1523-0]

33 **Luo BH**, Xiong F, Wang JP, Li JH, Zhong M, Liu QL, Luo GQ, Yang XJ, Xiao N, Xie B, Xiao H, Liu RJ, Dong CS, Wang KS, Wen JF. Epidermal growth factor-like domain-containing protein 7 (EGFL7) enhances EGF receptor-AKT signaling, epithelial-mesenchymal transition, and metastasis of gastric cancer cells. *PLoS One* 2014; **9**: e99922 [PMID: 24945379 DOI: 10.1371/journal.

pone.0099922]
34 **Schofield R**. The relationship between the spleen colony-forming cell and the haemopoietic stem cell. *Blood Cells* 1978; **4**: 7-25 [PMID: 747780]
35 **Peinado H**, Zhang H, Matei IR, Costa-Silva B, Hoshino A, Rodrigues G, Psaila B, Kaplan RN, Bromberg JF, Kang Y, Bissell MJ, Cox TR, Giaccia AJ, Erler JT, Hiratsuka S, Ghajar CM, Lyden D. Pre-metastatic niches: organ-specific homes for metastases. *Nat Rev Cancer* 2017; **17**: 302-317 [PMID: 28303905 DOI: 10.1038/nrc.2017.6]
36 **Amiri KI**, Richmond A. Fine tuning the transcriptional regulation of the CXCL1 chemokine. *Prog Nucleic Acid Res Mol Biol* 2003; **74**: 1-36 [PMID: 14510072]
37 **Dhawan P**, Richmond A. Role of CXCL1 in tumorigenesis of melanoma. *J Leukoc Biol* 2002; **72**: 9-18 [PMID: 12101257]
38 **Verbeke H**, Geboes K, Van Damme J, Struyf S. The role of CXC chemokines in the transition of chronic inflammation to esophageal and gastric cancer. *Biochim Biophys Acta* 2012; **1825**: 117-129 [PMID: 22079531 DOI: 10.1016/j.bbcan.2011.10.008]
39 **Wang D**, Sun H, Wei J, Cen B, DuBois RN. CXCL1 Is Critical for Premetastatic Niche Formation and Metastasis in Colorectal Cancer. *Cancer Res* 2017; **77**: 3655-3665 [PMID: 28455419 DOI: 10.1158/0008-5472.can-16-3199]
40 **Deryugina EI**, Quigley JP. Matrix metalloproteinases and tumor metastasis. *Cancer Metastasis Rev* 2006; **25**: 9-34 [PMID: 16680569 DOI: 10.1007/s10555-006-7886-9]
41 **Egeblad M**, Werb Z. New functions for the matrix metalloproteinases in cancer progression. *Nat Rev Cancer* 2002; **2**: 161-174 [PMID: 11990853 DOI: 10.1038/nrc745]
42 **Brown PD**. Ongoing trials with matrix metalloproteinase inhibitors. *Expert Opin Investig Drugs* 2000; **9**: 2167-2177 [PMID: 11060801 DOI: 10.1517/13543784.9.9.2167]
43 **Brew K**, Dinakarpandian D, Nagase H. Tissue inhibitors of metalloproteinases: evolution, structure and function. *Biochim Biophys Acta* 2000; **1477**: 267-283 [PMID: 10708863]
44 **Krüger A**, Fata JE, Khokha R. Altered tumor growth and metastasis of a T-cell lymphoma in Timp-1 transgenic mice. *Blood* 1997; **90**: 1993-2000 [PMID: 9292534]
45 **Holten-Andersen MN**, Stephens RW, Nielsen HJ, Murphy G, Christensen IJ, Stetler-Stevenson W, Brünner N. High preoperative plasma tissue inhibitor of metalloproteinase-1 levels are associated with short survival of patients with colorectal cancer. *Clin Cancer Res* 2000; **6**: 4292-4299 [PMID: 11106246]
46 **Grunnet M**, Mau-Sørensen M, Brünner N. Tissue inhibitor of metalloproteinase 1 (TIMP-1) as a biomarker in gastric cancer: a review. *Scand J Gastroenterol* 2013; **48**: 899-905 [PMID: 23834019 DOI: 10.3109/00365521.2013.812235]
47 **Seubert B**, Grünwald B, Kobuch J, Cui H, Schelter F, Schaten S, Siveke JT, Lim NH, Nagase H, Simonavicius N, Heikenwalder M, Reinheckel T, Sleeman JP, Janssen KP, Knolle PA, Krüger A. Tissue inhibitor of metalloproteinases (TIMP)-1 creates a premetastatic niche in the liver through SDF-1/CXCR4-dependent neutrophil recruitment in mice. *Hepatology* 2015; **61**: 238-248 [PMID: 25131778 DOI: 10.1002/hep.27378]
48 **Grünwald B**, Harant V, Schaten S, Frühschütz M, Spallek R, Höchst B, Stutzer K, Berchtold S, Erkan M, Prokopchuk O, Martignoni M, Esposito I, Heikenwalder M, Gupta A, Siveke J, Saftig P, Knolle P, Wohlleber D, Krüger A. Pancreatic Premalignant Lesions Secrete Tissue Inhibitor of Metalloproteinases-1, Which Activates Hepatic Stellate Cells Via CD63 Signaling to Create a Premetastatic Niche in the Liver. *Gastroenterology* 2016; **151**: 1011-1024.e7 [PMID: 27506299 DOI: 10.1053/j.gastro.2016.07.043]
49 **Eveno C**, Hainaud P, Rampanou A, Bonnin P, Bakhouche S, Dupuy E, Contreres JO, Pocard M. Proof of prometastatic niche induction by hepatic stellate cells. *J Surg Res* 2015; **194**: 496-504 [PMID: 25528682 DOI: 10.1016/j.jss.2014.11.005]
50 **van der Pol E**, Böing AN, Harrison P, Sturk A, Nieuwland R. Classification, functions, and clinical relevance of extracellular vesicles. *Pharmacol Rev* 2012; **64**: 676-705 [PMID: 22722893 DOI: 10.1124/pr.112.005983]
51 **Théry C**, Zitvogel L, Amigorena S. Exosomes: composition, biogenesis and function. *Nat Rev Immunol* 2002; **2**: 569-579 [PMID: 12154376 DOI: 10.1038/nri855]
52 **Belting M**, Wittrup A. Nanotubes, exosomes, and nucleic acid-binding peptides provide novel mechanisms of intercellular communication in eukaryotic cells: implications in health and disease. *J Cell Biol* 2008; **183**: 1187-1191 [PMID: 19103810 DOI: 10.1083/jcb.200810038]
53 **Ruivo CF**, Adem B, Silva M, Melo SA. The Biology of Cancer Exosomes: Insights and New Perspectives. *Cancer Res* 2017; **77**: 6480-6488 [PMID: 29162616 DOI: 10.1158/0008-5472.can-17-0994]
54 **Nakajima K**, Nangia-Makker P, Hogan V, Raz A. Cancer Self-Defense: An Immune Stealth. *Cancer Res* 2017; **77**: 5441-5444 [PMID: 28838888 DOI: 10.1158/0008-5472.can-17-1324]
55 **Takano Y**, Masuda T, Iinuma H, Yamaguchi R, Sato K, Tobo T, Hirata H, Kuroda Y, Nambara S, Hayashi N, Iguchi T, Ito S, Eguchi H, Ochiya T, Yanaga K, Miyano S, Mimori K. Circulating exosomal microRNA-203 is associated with metastasis possibly via inducing tumor-associated macrophages in colorectal cancer. *Oncotarget* 2017; **8**: 78598-78613 [PMID: 29108252 DOI: 10.18632/oncotarget.20009]
56 **Yu Z**, Zhao S, Ren L, Wang L, Chen Z, Hoffman RM, Zhou J. Pancreatic cancer-derived exosomes promote tumor metastasis and liver pre-metastatic niche formation. *Oncotarget* 2017; **8**: 63461-63483 [PMID: 28969005 DOI: 10.18632/oncotarget.18831]
57 **Hoshino A**, Costa-Silva B, Shen TL, Rodrigues G, Hashimoto A, Tesic Mark M, Molina H, Kohsaka S, Di Giannatale A, Ceder S, Singh S, Williams C, Soplop N, Uryu K, Pharmer L, King T, Bojmar L, Davies AE, Ararso Y, Zhang T, Zhang H, Hernandez J, Weiss JM, Dumont-Cole VD, Kramer K, Wexler LH, Narendran A, Schwartz GK, Healey JH, Sandstrom P, Labori KJ, Kure EH, Grandgenett PM, Hollingsworth MA, de Sousa M, Kaur S, Jain M, Mallya K, Batra SK, Jarnagin WR, Brady MS, Fodstad O, Muller V, Pantel K, Minn AJ, Bissell MJ, Garcia BA, Kang Y, Rajasekhar VK, Ghajar CM, Matei I, Peinado H, Bromberg J, Lyden D. Tumour exosome integrins determine organotropic metastasis. *Nature* 2015; **527**: 329-335 [PMID: 26524530 DOI: 10.1038/nature15756]
58 **Kannagi R**. Carbohydrate-mediated cell adhesion involved in hematogenous metastasis of cancer. *Glycoconj J* 1997; **14**: 577-584 [PMID: 9298690]
59 **Ohyama S**, Yonemura Y, Kimura H, Kosaka T, Miyazaki I, Sasaki T. Proliferation-associated nuclear antigen p105 as a marker for metastasis of human gastric cancer. *J Cancer Res Clin Oncol* 1991; **117**: 583-586 [PMID: 1683872]
60 **Kimura H**, Yonemura Y, Epstein AL. Flow cytometric quantitation of the proliferation-associated nuclear antigen p105 and DNA content in advanced gastric cancers. *Cancer* 1991; **68**: 2175-2180 [PMID: 1913456]
61 **Kimura H**, Yonemura Y, Miyazaki I. Proliferative activity in gastric cancer determined with cell cycle-related monoclonal antibodies Ki-67 and p105: analysis by flow cytometry. *J Surg Oncol* 1992; **51**: 174-178 [PMID: 1359195]
62 **Shin JY**, Kim JO, Lee SK, Chae HS, Kang JH. LY294002 may overcome 5-FU resistance via down-regulation of activated p-AKT in Epstein-Barr virus-positive gastric cancer cells. *BMC Cancer* 2010; **10**: 425 [PMID: 20704765 DOI: 10.1186/1471-2407-10-425]
63 **Choi AM**, Ryter SW, Levine B. Autophagy in human health and disease. *N Engl J Med* 2013; **368**: 1845-1846 [PMID: 23656658 DOI: 10.1056/NEJMc1303158]
64 **Cuervo AM**. Autophagy: in sickness and in health. *Trends Cell Biol* 2004; **14**: 70-77 [PMID: 15102438 DOI: 10.1016/j.tcb.2003.12.002]
65 **Kimmelman AC**. The dynamic nature of autophagy in cancer. *Genes Dev* 2011; **25**: 1999-2010 [PMID: 21979913 DOI: 10.1101/gad.17558811]
66 **Shao Y**, Gao Z, Marks PA, Jiang X. Apoptotic and autophagic cell death induced by histone deacetylase inhibitors. *Proc Natl Acad Sci USA* 2004; **101**: 18030-18035 [PMID: 15596714 DOI: 10.1073/pnas.0408345102]
67 **Sharifi MN**, Mowers EE, Drake LE, Collier C, Chen H, Zamora

M, Mui S, Macleod KF. Autophagy Promotes Focal Adhesion Disassembly and Cell Motility of Metastatic Tumor Cells through the Direct Interaction of Paxillin with LC3. *Cell Rep* 2016; **15**: 1660-1672 [PMID: 27184837 DOI: 10.1016/j.celrep.2016.04.065]

68 **Masuda GO**, Yashiro M, Kitayama K, Miki Y, Kasashima H, Kinoshita H, Morisaki T, Fukuoka T, Hasegawa T, Sakurai K, Toyokawa T, Kubo N, Tanaka H, Muguruma K, Masaichi O, Hirakawa K. Clinicopathological Correlations of Autophagy-related Proteins LC3, Beclin 1 and p62 in Gastric Cancer. *Anticancer Res* 2016; **36**: 129-136 [PMID: 26722036]

69 **Kanda M**, Shimizu D, Tanaka H, Shibata M, Iwata N, Hayashi M, Kobayashi D, Tanaka C, Yamada S, Fujii T, Nakayama G, Sugimoto H, Koike M, Fujiwara M, Kodera Y. Metastatic pathway-specific transcriptome analysis identifies MFSD4 as a putative tumor suppressor and biomarker for hepatic metastasis in patients with gastric cancer. *Oncotarget* 2016; **7**: 13667-13679 [PMID: 26872374 DOI: 10.18632/oncotarget.7269]

70 **Kelly ML**, Chernoff J. Getting smart about p21-activated kinases. *Mol Cell Biol* 2011; **31**: 386-387 [PMID: 21115726 DOI: 10.1128/mcb.01267-10]

71 **Liu F**, Cheng Z, Li X, Li Y, Zhang H, Li J, Liu F, Xu H, Li F. A novel Pak1/ATF2/miR-132 Signaling Axis is involved in the hematogenous metastasis of gastric cancer cells. *Mol Ther Nucleic Acids* 2017; **8**: 370-382 [PMID: 28918037 DOI: 10.1016/j.omtn.2017.07.005]

72 **Deryugina EI**, Quigley JP. Tumor angiogenesis: MMP-mediated induction of intravasation- and metastasis-sustaining neovasculature. *Matrix Biol* 2015; **44-46**: 94-112 [PMID: 25912949 DOI: 10.1016/j.matbio.2015.04.004]

73 **Ohtsu A**, Shah MA, Van Cutsem E, Rha SY, Sawaki A, Park SR, Lim HY, Yamada Y, Wu J, Langer B, Starnawski M, Kang YK. Bevacizumab in combination with chemotherapy as first-line therapy in advanced gastric cancer: a randomized, double-blind, placebo-controlled phase III study. *J Clin Oncol* 2011; **29**: 3968-3976 [PMID: 21844504 DOI: 10.1200/jco.2011.36.2236]

74 **Wilke H**, Muro K, Van Cutsem E, Oh SC, Bodoky G, Shimada Y, Hironaka S, Sugimoto N, Lipatov O, Kim TY, Cunningham D, Rougier P, Komatsu Y, Ajani J, Emig M, Carlesi R, Ferry D, Chandrawansa K, Schwartz JD, Ohtsu A; RAINBOW Study Group. Ramucirumab plus paclitaxel versus placebo plus paclitaxel in patients with previously treated advanced gastric or gastro-oesophageal junction adenocarcinoma (RAINBOW): a double-blind, randomised phase 3 trial. *Lancet Oncol* 2014; **15**: 1224-1235 [PMID: 25240821 DOI: 10.1016/s1470-2045(14)70420-6]

75 **Fuchs CS**, Tomasek J, Yong CJ, Dumitru F, Passalacqua R, Goswami C, Safran H, Dos Santos LV, Aprile G, Ferry DR, Melichar B, Tehfe M, Topuzov E, Zalcberg JR, Chau I, Campbell W, Sivanandan C, Pikiel J, Koshiji M, Hsu Y, Liepa AM, Gao L, Schwartz JD, Tabernero J; REGARD Trial Investigators. Ramucirumab monotherapy for previously treated advanced gastric or gastro-oesophageal junction adenocarcinoma (REGARD): an international, randomised, multicentre, placebo-controlled, phase 3 trial. *Lancet* 2014; **383**: 31-39 [PMID: 24094768 DOI: 10.1016/s0140-6736(13)61719-5]

76 **Shida A**, Fujioka S, Kobayashi K, Ishibashi Y, Nimura H, Mitsumori N, Yanaga K. Expression of vascular endothelial growth factor (VEGF)-C and -D in gastric carcinoma. *Int J Clin Oncol* 2006; **11**: 38-43 [PMID: 16508727 DOI: 10.1007/s10147-005-0528-3]

77 **Shida A**, Fujioka S, Ishibashi Y, Kobayashi K, Nimura H, Mitsumori N, Suzuki Y, Kawakami M, Urashima M, Yanaga K. Prognostic significance of vascular endothelial growth factor D in gastric carcinoma. *World J Surg* 2005; **29**: 1600-1607 [PMID: 16311850 DOI: 10.1007/s00268-005-0076-z]

78 **Deng J**, Liang H, Sun D, Pan Y, Wang B, Guo Y. Vascular endothelial growth factor-D is correlated with hepatic metastasis from gastric cancer after radical gastrectomy. *Surgery* 2009; **146**: 896-905 [PMID: 19744460 DOI: 10.1016/j.surg.2009.04.025]

79 **Ishikawa F**, Miyazono K, Hellman U, Drexler H, Wernstedt C, Hagiwara K, Usuki K, Takaku F, Risau W, Heldin CH. Identification of angiogenic activity and the cloning and expression of platelet-derived endothelial cell growth factor. *Nature* 1989; **338**: 557-562 [PMID: 2467210 DOI: 10.1038/338557a0]

80 **Kimura H**, Konishi K, Nukui T, Kaji M, Maeda K, Yabushita K, Tsuji M, Miwa A. Prognostic significance of expression of thymidine phosphorylase and vascular endothelial growth factor in human gastric carcinoma. *J Surg Oncol* 2001; **76**: 31-36 [PMID: 11223822]

81 **Maeda K**, Chung YS, Ogawa Y, Takatsuka S, Kang SM, Ogawa M, Sawada T, Onoda N, Kato Y, Sowa M. Thymidine phosphorylase/platelet-derived endothelial cell growth factor expression associated with hepatic metastasis in gastric carcinoma. *Br J Cancer* 1996; **73**: 884-888 [PMID: 8611421]

82 **Shimizu D**, Kanda M, Nomoto S, Oya H, Takami H, Hibino S, Suenaga M, Inokawa Y, Hishida M, Takano N, Nishikawa Y, Yamada S, Fujii T, Nakayama G, Sugimoto H, Koike M, Fujiwara M, Kodera Y. Identification of intragenic methylation in the TUSC1 gene as a novel prognostic marker of hepatocellular carcinoma. *Oncol Rep* 2014; **31**: 1305-1313 [PMID: 24366000 DOI: 10.3892/or.2013.2939]

83 **Tanaka H**, Kanda M, Koike M, Iwata N, Shimizu D, Ezaka K, Sueoka S, Tanaka Y, Takami H, Hashimoto R, Tanaka C, Yamada S, Fujii T, Nakayama G, Sugimoto H, Fujiwara M, Kodera Y. Adherens junctions associated protein 1 serves as a predictor of recurrence of squamous cell carcinoma of the esophagus. *Int J Oncol* 2015; **47**: 1811-1818 [PMID: 26397940 DOI: 10.3892/ijo.2015.3167]

84 **Kanda M**, Shimizu D, Tanaka H, Tanaka C, Kobayashi D, Hayashi M, Iwata N, Niwa Y, Yamada S, Fujii T, Sugimoto H, Murotani K, Fujiwara M, Kodera Y. Significance of SYT8 For the Detection, Prediction, and Treatment of Peritoneal Metastasis From Gastric Cancer. *Ann Surg* 2018; **267**: 495-503 [PMID: 28026832 DOI: 10.1097/SLA.0000000000002096]

85 **Kanda M**, Kodera Y. Molecular mechanisms of peritoneal dissemination in gastric cancer. *World J Gastroenterol* 2016; **22**: 6829-6840 [PMID: 27570420 DOI: 10.3748/wjg.v22.i30.6829]

86 **Ashizawa T**, Okada R, Suzuki Y, Takagi M, Yamazaki T, Sumi T, Aoki T, Ohnuma S, Aoki T. Clinical significance of interleukin-6 (IL-6) in the spread of gastric cancer: role of IL-6 as a prognostic factor. *Gastric Cancer* 2005; **8**: 124-131 [PMID: 15864720 DOI: 10.1007/s10120-005-0315-x]

87 **Kawamura T**, Kusakabe T, Sugino T, Watanabe K, Fukuda T, Nashimoto A, Honma K, Suzuki T. Expression of glucose transporter-1 in human gastric carcinoma: association with tumor aggressiveness, metastasis, and patient survival. *Cancer* 2001; **92**: 634-641 [PMID: 11505409]

88 **Lee JS**, Kim SH, Im SA, Kim MA, Han JK. Human Epidermal Growth Factor Receptor 2 Expression in Unresectable Gastric Cancers: Relationship with CT Characteristics. *Korean J Radiol* 2017; **18**: 809-820 [PMID: 28860898 DOI: 10.3348/kjr.2017.18.5.809]

89 **Matsusaka S**, Nashimoto A, Nishikawa K, Miki A, Miwa H, Yamaguchi K, Yoshikawa T, Ochiai A, Morita S, Sano T, Kodera Y, Kakeji Y, Sakamoto J, Saji S, Yoshida K. Clinicopathological factors associated with HER2 status in gastric cancer: results from a prospective multicenter observational cohort study in a Japanese population (JFMC44-1101). *Gastric Cancer* 2016; **19**: 839-851 [PMID: 26265390 DOI: 10.1007/s10120-015-0518-8]

90 **Tanaka H**, Kanda M, Shimizu D, Tanaka C, Kobayashi D, Hayashi M, Iwata N, Yamada S, Fujii T, Nakayama G, Sugimoto H, Fujiwara M, Niwa Y, Kodera Y. FAM46C Serves as a Predictor of Hepatic Recurrence in Patients with Resectable Gastric Cancer. *Ann Surg Oncol* 2017; **24**: 3438-3445 [PMID: 27770343 DOI: 10.1245/s10434-016-5636-y]

91 **Ding A**, Zhao W, Shi X, Yao R, Zhou F, Yue L, Liu S, Qiu W. Impact of NPM, TFF3 and TACC1 on the prognosis of patients with primary gastric cancer. *PLoS One* 2013; **8**: e82136 [PMID: 24358147 DOI: 10.1371/journal.pone.0082136]

92 **Iwasa S**, Yanagawa T, Fan J, Katoh R. Expression of CXCR4 and its ligand SDF-1 in intestinal-type gastric cancer is associated with lymph node and liver metastasis. *Anticancer Res* 2009; **29**: 4751-4758 [PMID: 20032431]

93 **Diao D**, Wang Z, Cheng Y, Zhang H, Guo Q, Song Y, Zhu K, Li K,

Liu D, Dang C. D-dimer: not just an indicator of venous thrombosis but a predictor of asymptomatic hematogenous metastasis in gastric cancer patients. *PLoS One* 2014; **9**: e101125 [PMID: 24983619 DOI: 10.1371/journal.pone.0101125]

94 **Yamashita H**, Kitayama J, Kanno N, Yatomi Y, Nagawa H. Hyperfibrinogenemia is associated with lymphatic as well as hematogenous metastasis and worse clinical outcome in T2 gastric cancer. *BMC Cancer* 2006; **6**: 147 [PMID: 16740157 DOI: 10.1186/1471-2407-6-147]

95 **Yamaguchi A**, Goi T, Yu J, Hirono Y, Ishida M, Iida A, Kimura T, Takeuchi K, Katayama K, Hirose K. Expression of CD44v6 in advanced gastric cancer and its relationship to hematogenous metastasis and long-term prognosis. *J Surg Oncol* 2002; **79**: 230-235 [PMID: 11920780 DOI: 10.1002/jso.10082]

96 **Dong C**. TH17 cells in development: an updated view of their molecular identity and genetic programming. *Nat Rev Immunol* 2008; **8**: 337-348 [PMID: 18408735 DOI: 10.1038/nri2295]

97 **Oka M**, Yamamoto K, Takahashi M, Hakozaki M, Abe T, Iizuka N, Hazama S, Hirazawa K, Hayashi H, Tangoku A, Hirose K, Ishihara T, Suzuki T. Relationship between serum levels of interleukin 6, various disease parameters and malnutrition in patients with esophageal squamous cell carcinoma. *Cancer Res* 1996; **56**: 2776-2780 [PMID: 8665513]

98 **Yoshida N**, Ikemoto S, Narita K, Sugimura K, Wada S, Yasumoto R, Kishimoto T, Nakatani T. Interleukin-6, tumour necrosis factor alpha and interleukin-1beta in patients with renal cell carcinoma. *Br J Cancer* 2002; **86**: 1396-1400 [PMID: 11986770 DOI: 10.1038/sj.bjc.6600257]

99 **Takeda K**, Fujii N, Nitta Y, Sakihara H, Nakayama K, Rikiishi H, Kumagai K. Murine tumor cells metastasizing selectively in the liver: ability to produce hepatocyte-activating cytokines interleukin-1 and/or -6. *Jpn J Cancer Res* 1991; **82**: 1299-1308 [PMID: 1752786]

100 **Reichner JS**, Mulligan JA, Palla ME, Hixson DC, Albina JE, Bland KI. Interleukin-6 production by rat hepatocellular carcinoma cells is associated with metastatic potential but not with tumorigenicity. *Arch Surg* 1996; **131**: 360-365 [PMID: 8615719]

101 **Ara T**, Declerck YA. Interleukin-6 in bone metastasis and cancer progression. *Eur J Cancer* 2010; **46**: 1223-1231 [PMID: 20335016 DOI: 10.1016/j.ejca.2010.02.026]

102 **Fu XL**, Duan W, Su CY, Mao FY, Lv YP, Teng YS, Yu PW, Zhuang Y, Zhao YL. Interleukin 6 induces M2 macrophage differentiation by STAT3 activation that correlates with gastric cancer progression. *Cancer Immunol Immunother* 2017; **66**: 1597-1608 [PMID: 28828629 DOI: 10.1007/s00262-017-2052-5]

103 **Wu X**, Tao P, Zhou Q, Li J, Yu Z, Wang X, Li J, Li C, Yan M, Zhu Z, Liu B, Su L. IL-6 secreted by cancer-associated fibroblasts promotes epithelial-mesenchymal transition and metastasis of gastric cancer via JAK2/STAT3 signaling pathway. *Oncotarget* 2017; **8**: 20741-20750 [PMID: 28186964 DOI: 10.18632/oncotarget.15119]

104 **Yamamoto T**, Seino Y, Fukumoto H, Koh G, Yano H, Inagaki N, Yamada Y, Inoue K, Manabe T, Imura H. Over-expression of facilitative glucose transporter genes in human cancer. *Biochem Biophys Res Commun* 1990; **170**: 223-230 [PMID: 2372287]

105 **Kim WS**, Kim YY, Jang SJ, Kimm K, Jung MH. Glucose transporter 1 (GLUT1) expression is associated with intestinal type of gastric carcinoma. *J Korean Med Sci* 2000; **15**: 420-424 [PMID: 10983690 DOI: 10.3346/jkms.2000.15.4.420]

106 **Slamon DJ**, Leyland-Jones B, Shak S, Fuchs H, Paton V, Bajamonde A, Fleming T, Eiermann W, Wolter J, Pegram M, Baselga J, Norton L. Use of chemotherapy plus a monoclonal antibody against HER2 for metastatic breast cancer that overexpresses HER2. *N Engl J Med* 2001; **344**: 783-792 [PMID: 11248153 DOI: 10.1056/nejm200103153441101]

107 **Bang YJ**, Van Cutsem E, Feyereislova A, Chung HC, Shen L, Sawaki A, Lordick F, Ohtsu A, Omuro Y, Satoh T, Aprile G, Kulikov E, Hill J, Lehle M, Rüschoff J, Kang YK; ToGA Trial Investigators. Trastuzumab in combination with chemotherapy versus chemotherapy alone for treatment of HER2-positive advanced gastric or gastro-oesophageal junction cancer (ToGA): a phase 3, open-label, randomised controlled trial. *Lancet* 2010; **376**: 687-697 [PMID: 20728210 DOI: 10.1016/s0140-6736(10)61121-x]

108 **Ménard S**, Pupa SM, Campiglio M, Tagliabue E. Biologic and therapeutic role of HER2 in cancer. *Oncogene* 2003; **22**: 6570-6578 [PMID: 14528282 DOI: 10.1038/sj.onc.1206779]

109 **Dang HZ**, Yu Y, Jiao SC. Prognosis of HER2 over-expressing gastric cancer patients with liver metastasis. *World J Gastroenterol* 2012; **18**: 2402-2407 [PMID: 22654433 DOI: 10.3748/wjg.v18.i19.2402]

110 **Terashima M**, Kitada K, Ochiai A, Ichikawa W, Kurahashi I, Sakuramoto S, Katai H, Sano T, Imamura H, Sasako M; ACTS-GC Group. Impact of expression of human epidermal growth factor receptors EGFR and ERBB2 on survival in stage II/III gastric cancer. *Clin Cancer Res* 2012; **18**: 5992-6000 [PMID: 22977193 DOI: 10.1158/1078-0432.ccr-12-1318]

111 **Wang HB**, Liao XF, Zhang J. Clinicopathological factors associated with HER2-positive gastric cancer: A meta-analysis. *Medicine* (Baltimore) 2017; **96**: e8437 [PMID: 29095284 DOI: 10.1097/md.0000000000008437]

112 **Chapman MA**, Lawrence MS, Keats JJ, Cibulskis K, Sougnez C, Schinzel AC, Harview CL, Brunet JP, Ahmann GJ, Adli M, Anderson KC, Ardlie KG, Auclair D, Baker A, Bergsagel PL, Bernstein BE, Drier Y, Fonseca R, Gabriel SB, Hofmeister CC, Jagannath S, Jakubowiak AJ, Krishnan A, Levy J, Liefeld T, Lonial S, Mahan S, Mfuko B, Monti S, Perkins LM, Onofrio R, Pugh TJ, Rajkumar SV, Ramos AH, Siegel DS, Sivachenko A, Stewart AK, Trudel S, Vij R, Voet D, Winckler W, Zimmerman T, Carpten J, Trent J, Hahn WC, Garraway LA, Meyerson M, Lander ES, Getz G, Golub TR. Initial genome sequencing and analysis of multiple myeloma. *Nature* 2011; **471**: 467-472 [PMID: 21430775 DOI: 10.1038/nature09837]

113 **Grisendi S**, Mecucci C, Falini B, Pandolfi PP. Nucleophosmin and cancer. *Nat Rev Cancer* 2006; **6**: 493-505 [PMID: 16794633 DOI: 10.1038/nrc1885]

114 **Lin CY**, Liang YC, Yung BY. Nucleophosmin/B23 regulates transcriptional activation of E2F1 via modulating the promoter binding of NF-kappaB, E2F1 and pRB. *Cell Signal* 2006; **18**: 2041-2048 [PMID: 16725311 DOI: 10.1016/j.cellsig.2006.04.001]

115 **Luchinat E**, Chiarella S, Franceschini M, Di Matteo A, Brunori M, Banci L, Federici L. Identification of a novel nucleophosmin-interaction motif in the tumor suppressor p14arf. *FEBS J* 2018; **285**: 832-847 [PMID: 29283500 DOI: 10.1111/febs.14373]

116 **Liu X**, Liu D, Qian D, Dai J, An Y, Jiang S, Stanley B, Yang J, Wang B, Liu X, Liu DX. Nucleophosmin (NPM1/B23) interacts with activating transcription factor 5 (ATF5) protein and promotes proteasome- and caspase-dependent ATF5 degradation in hepatocellular carcinoma cells. *J Biol Chem* 2012; **287**: 19599-19609 [PMID: 22528486 DOI: 10.1074/jbc.M112.363622]

117 **Zhou F**, Qiu W, Sun L, Xiang J, Sun X, Sui A, Ding A, Yue L. Clinical significance of nucleophosmin/B23 and human epidermal growth factor receptor 2/neu expressions in gastric cancers. *APMIS* 2013; **121**: 582-591 [PMID: 23489260 DOI: 10.1111/apm.12043]

118 **Li Y**, Sun Z, Liu K, Qiu W, Yao R, Feng T, Xin C, Yue L. Prognostic significance of the co-expression of nucleophosmin and trefoil factor 3 in postoperative gastric cancer patients. *Mol Clin Oncol* 2014; **2**: 1055-1061 [PMID: 25279197 DOI: 10.3892/mco.2014.351]

P- Reviewer: Ding SZ, Liu SH, Yip D **S- Editor**: Cui LJ
L- Editor: A **E- Editor**: Huang Y

WJGO World Journal of Gastrointestinal Oncology

Submit a Manuscript: http://www.f6publishing.com

World J Gastrointest Oncol 2018 June 15; 10(6): 137-144

DOI: 10.4251/wjgo.v10.i6.137

ISSN 1948-5204 (online)

ORIGINAL ARTICLE

Retrospective Cohort Study

Trans-anal minimally invasive surgery for rectal neoplasia: Experience from single tertiary institution in China

Nan Chen, Yi-Fan Peng, Yun-Feng Yao, Jin Gu

Nan Chen, Yi-Fan Peng, Yun-Feng Yao, Jin Gu, Department of Gastrointestinal Center Unit III, Peking University Hospital and Institute, Beijing 100142, China

ORCID number: Nan Chen (0000-0002-0085-7472); Yi-Fan Peng (0000-0002-6159-6088); Yun-Feng Yao (0000-0001-8433-0688); Jin Gu (0000-0002-9650-1963).

Author contributions: Chen N and Yunfeng Yao designed the study; Chen N and Yao YF performed the TAMIS surgeries; Chen N and Peng YF drafted the manuscript; Chen N, Peng YF and Yao YF contributed equally to this paper.

Supported by Science Foundation of Peking University Cancer Hospital, No. 2017-13.

Institutional review board statement: The study was reviewed and approved for publication by our institutional reviewer.

Informed consent statement: All study participants provided informed written consent about personal and medical data collection prior to study enrolment.

Conflict-of-interest statement: All the authors have no conflict of interest related to the manuscript.

Open-Access: This article is an open-access article which was selected by an in-house editor and fully peer-reviewed by external reviewers. It is distributed in accordance with the Creative Commons Attribution Non Commercial (CC BY-NC 4.0) license, which permits others to distribute, remix, adapt, build upon this work non-commercially, and license their derivative works on different terms, provided the original work is properly cited and the use is non-commercial. See: http://creativecommons.org/licenses/by-nc/4.0/

Manuscript source: Unsolicited manuscript

Correspondence to: Nan Chen, MD, PhD, Attending Doctor, Lecturer, Department of Gastrointestinal Center Unit III, Peking University Hospital and Institute, No. 52 Fucheng Road, Haidian District, Beijing 100142, China. chennanpku@126.com
Telephone: +86-10-88196086
Fax: +86-10-88196086

Received: March 11, 2018
Peer-review started: March 12, 2018
First decision: April 10, 2018
Revised: April 26, 2018
Accepted: May 30, 2018
Article in press: May 30, 2018
Published online: June 15, 2018

Abstract

AIM
To evaluate the feasibility and safety of trans-anal minimally invasive surgery (TAMIS) from single institute in China.

METHODS
A retrospective review was conducted for patients with rectal neoplasia, who underwent TAMIS using single incision laparoscopic surgery-Port from January 2013 till January 2016 by a group of colorectal surgeons from Gastrointestinal Center Unit Ⅲ, Peking University Cancer Hospital. Patients' demographic data, surgical related information, post-operational pathology, as well as peri-operative follow-up were all collected.

RESULTS
Twenty-five patients with rectal neoplasia were identified consequently. Complete full-thickness excision was achieved in all cases without conversion. 22 (88%) cases had rectal malignancies [6 were adenocarcinomas and 16 were neuroendocrine tumors (NET)], while 3 patients had adenomas. Mean surgical duration was 61.3 min, and mean post-operative stay were 2.7 d. Post-operational examination demonstrated 5 cases had positive resection margin: 2 adenocarcinoma cases and 1 NET case with positive lateral margin, and the other 2 NET cases with positive basal margin. The curve of operation time for TAMIS cases suggested a minimum of 10 cases for a laparoscopic surgeon proficient with

this technique.

CONCLUSION

TAMIS was demonstrated to be reproducible and safe, with a relatively short learning process for laparoscopic surgeons in selected cases for rectal neoplasia. Long-term oncological outcome needs to be determined by further investigation.

Key words: Rectal neoplasia; Resection margin; Trans-anal minimally invasive surgery

© The Author(s) 2018. Published by Baishideng Publishing Group Inc. All rights reserved.

Core tip: Local excision was regarded as the conversional treatment for early stage rectal neoplasia. Recent evidence, however, revealed certain disadvantages. Minimally invasive surgery has been adopted in treating rectal cancer. This study was the first well-documented retrospective trail demonstrating the safety and feasibility of trans-anal minimally invasive surgery. Short-term follow-up showed no serious post-operative complications (over grade Ⅲa by CD classification), meanwhile, lateral resection margin should be evaluated pathologically and surgeons proficient for laparoscopic surgery would be confident over the learning curve regarding 10 cases.

Chen N, Peng YF, Yao YF, Gu J. Trans-anal minimally invasive surgery for rectal neoplasia: Experience from single tertiary institution in China. *World J Gastrointest Oncol* 2018; 10(6): 137-144 Available from: URL: http://www.wjgnet.com/1948-5204/full/v10/i6/137.htm DOI: http://dx.doi.org/10.4251/wjgo.v10.i6.137

INTRODUCTION

As a challenging area, low rectum has drawn significant attention and caution due to anatomic features. The rates of sphincter-preserving surgery have largely increased, due to the application of neoadjuvant chemoradiation as well as the laparoscopic approach, or both. It, however, is still the fact that colostomy or temporary ileostomy might be necessary in around 10%-30% of the patients with neoplasia in the mid-low third of the rectum[1]. For benign neoplasia or early-stage malignancy located in mid-low rectum, a variety of treatments might be available. Tran-anal local excision is commonly recommended. This approach, however, should be limited to well-selected patients since high-quality oncological excision could not be guaranteed due to exposure and visibility[2,3]. Another meaningful technique might be trans-anal endoscopic microsurgery (TEM), first introduced by Buess *et al*[4] and considered as an alternative approach, providing acceptable oncological outcome with less postoperative complications and better function, compared with radical excision. Nevertheless, TEM is embedded with certain disadvantages, such as high cost, complexity of the instruments, rather steep learning curve and limited indications, resulting in failure of widespread adoption[5]. Marked advances in instrumental innovation (single port) and technical expertise (laparoscopy) led to the creation of trans-anal minimally invasive surgery (TAMIS). At present, two well-designed platforms for TAMIS, the GelPOINT Path and the single incision laparoscopic surgery (SILS) Port have gained the approval of Food and Drug Administration for use[6,7]. Previous literature has demonstrated that TAMIS might be an alternative choice for rectal lesions, offering several technical advantages compare with TEM: Firstly, with the widespread of laparoscopic surgery, laparoscopic instruments which has been already available could easily be applied in the TAMIS setting, meanwhile the unique apparatus employed by TEM could not be compatible with laparoscopic platform; secondly, the soft platform-SILS Port could provide safer trans-anal access as well as less sphincter traction, compared with rigid channel employed by TEM.

In the present study, SILS Port platform was applied using a standard laparoscopic setting, and the characteristics of patients underwent TAMIS were collected as well as the short-term outcome, aiming to demonstrating the utility of this TAMIS technique with both favorable and unfavorable factors.

MATERIALS AND METHODS

This study population consisted of consecutive patients identified from a single institution retrospectively from January 2013 till January 2016. Data from individual patients were reviewed and analyzed. The indications for TAMIS were as follows: benign neoplasia (adenomas over 2.5 cm in diameter); low grade (G1) neuroendocrine tumors with diameter less than 2 cm, and for curative intent stage Ⅰ rectal cancer with favorable histological features (mri-lymph node negative cT1, with diameter less than 3 cm, moderate to well differentiation, and no mri-lympho-vascular invasion).

Exclusion criteria were patients with certain conditions: invasive rectal tumor (over mri T2 or lymph node positivity), history of inflammatory bowel disease, severe hemorrhoids or anal stricture, fecal incontinence, or with contraindications to general anesthesia. Patients with diagnosis of malignancy underwent preoperative staging with 3-Tesla pelvic MRI or endorectal ultrasound to determine depth of invasion and status of lymph nodes. Standard preoperative imaging, such as computed tomography of the chest, abdomen, and baseline blood test for carcinoembryonic antigen (CEA) were completed before surgical intervention. All TAMIS surgeries were performed in single high-volume tertiary hospital by trained laparoscopic colorectal surgeons under general anesthesia. Technically, TAMIS was a platform whereby standard laparoscopic instruments and cameras were used combined with disposable multi-channel port positioned trans-anally with gas insufflation of the rectum.

Table 1 Patients' clinical and pathological characteristics

	Benign (n = 3)	Malignant[1] (n = 22)	All (n = 25)
Mean age, yr (SD)	55.3 (7.5)	51.3 (13.8)	51.8 (13.2)
Gender			
Male	1	8	10 (40%)
Female	2	14	15 (60%)
Mean body mass index, kg/m^2 (SD)	23.9 (1.3)	23.9 (3.0)	23.9 (2.9)
Pre-TAMIS excision	0	5	5 (20%)
Mean lesion size, cm (SD)	1.1 (0.7)	1.1 (0.5)	1.1 (0.5)
Mean distance from anal verge, cm (SD)	9.3 (0.6)	8.3 (1.6)	8.4 (1.6)
Final pathology			
Benign	3		3 (12%)
Malignant			22 (88%)
Adenocarcinoma		6	6 (24%)
Mid-high differentiation		6	6 (24%)
Low differentiation		0	0
T0 (no residual tumor)		0	0
T1		5	5 (20%)
T2-3		1	1 (4%)
NET		16	16 (64%)
Lymph-vascular invasion	0	1	1 (4%)
Positive margin	0	5	5 (20%)
Position			
Lloyd-Davies	3	15	18 (72%)
Jackknife	0	7	7 (28%)
Mean duration of surgery, min (SD)	58.0 (37.0)	61.8 (24.7)	61.3 (25.5)
Mean blood loss, mL (SD)	5 (0)	8.6 (4.4)	8.2 (4.3)
Mean length of post-operative stay	2.3 (1.5)	2.8 (1.4)	2.7 (1.4)

[1] Includes *in situ* and invasive adenocarcinoma and neuroendocrine tumors. NET: Neuroendocrine tumors.

Full mechanical bowel preparation (polyethylene glycol) was performed, and all patients received preoperative antibiotics which were continued for 1 d in all patients postoperatively.

Surgical procedure

Trans-anal minimally invasive surgeries were performed using the SILS Port (Covidien-Medtronic, Minneapolis, MN). Pnuemo-rectum was maintained with CO_2 insufflation with flow set to 40 L/min and pressure set to 15 mmHg (range, 10-18 mmHg). A high-definition 30º 5 mm or 10 mm camera lens was used in combination with standard laparoscopic graspers and electrocautery or Ethicon Endo-Surgery HARMONIC ACE (Figure 1). After marking the area of resection (Figure 2A), the dissection was started around 5 mm from the lesion margins to obtain a full thickness excision (Figure 2B). The defect was closed in all patients using a running suture of Vicryl 3-0 or V-lock 3-0 (Covidien) (Figure 2C). The surgical specimen were pinned on a cork board and sent fresh for histopathological examination (Figure 2D). Liquid diet was prescribed during post-operational day 1-3. Patients were discharged routinely on the following day of surgery with prolonged stay for special patients, depending on case complexity and occurrence of complications. Data was collected retrospectively in a common database. Complications were graded according to the Clavien-Dindo classification. The size of specimen, surgery duration, final pathological diagnosis and other peri-operative factors were recorded. Follow up consisted of postoperative visits at 2- and 8-wk after TAMIS, with digital rectal examination.

Statistical analysis

Summary data were presented as mean ± SD for continuous variables and percentages for discrete variables. All statistical tests were two-sided and a P value less than 0.05 was considered significant. The analysis was performed using SPSS 19.0 (IBM Switzerland Ltd., Zurich, Switzerland).

RESULTS

Demographics

A total of 25 patients were enrolled in this study, baseline patient demographics and tumor characteristics were summarized in Table 1. The mean age of the patients was 51.8, 10 (40%) patients were male, with the mean body mass index 23.9 kg/m^2. Five (20%) out of 25 patients had pre-TAMIS local excision before admission. Mean size of the lesions was 1.1 cm (range from 0.5 to 2 cm) in diameter, meanwhile, the mean distance from lesions to anal verge was 8.4 cm (range from 5 to 10 cm). The pathological examination revealed that 3 (12%) patients was diagnosed benign lesions (adenomas), on the other hand, 22 (88%) were malignant, among which 16 with neuroendocrine tumors (NETs) and 6 patients with adenocarcinoma (5 patients pT1, and 1 pT3). Positive lymph-vascular invasion was seen in 1 patient, and resection margin

Table 2 Characteristics of patients with positive resection margin

Patients' No	Age	Gender	BMI (kg/m^2)	Distance from anal verge (cm)	Diameter (cm)	Surgery duration (min)	Position	Post-op stay	Type of positive margin	Pathology	Post-op treatment
1	58	2	19.9	7	2	50	Lloyd-Davies	1	Lateral	Adenocarcinoma	Curative surgery
2	75	2	23.2	10	2	60	Lloyd-Davies	1	Basal	NET-G1	Imatinib
3	64	2	26.1	6	1.5	45	Lloyd-Davies	4	Basal	NET-G1	Imatinib
4	63	2	20.0	10	0.5	60	Lloyd-Davies	2	Lateral	NET-G1	Imatinib
5	59	1	24.8	8	1.5	30	Lloyd-Davies	3	Lateral	Adenocarcinoma	Chemo-radiation

NET: Neuroendocrine tumors.

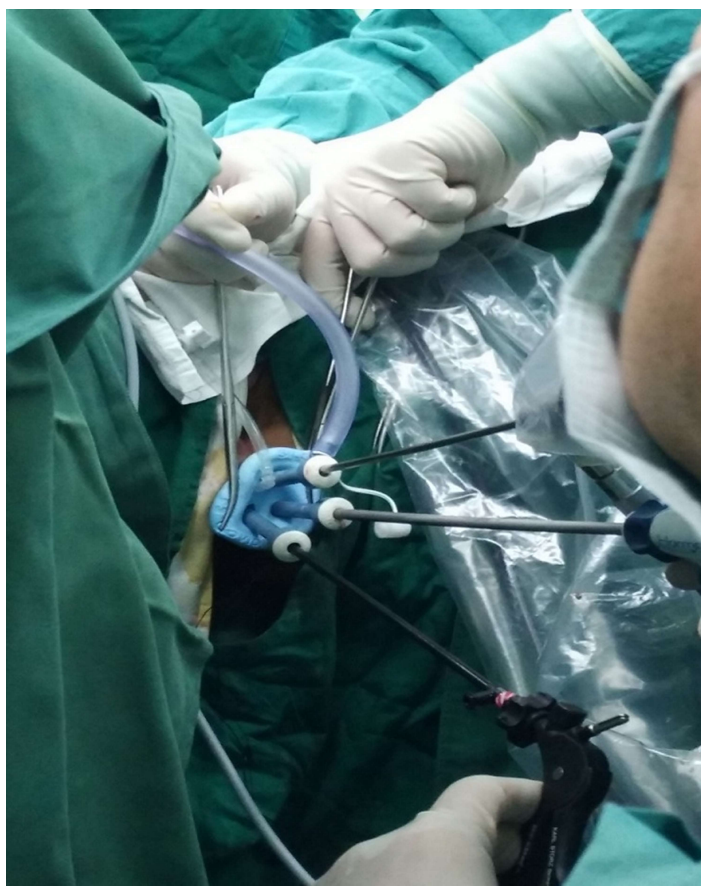

Figure 1 Settings for trans-anal minimally invasive surgery. The SILS-Port® was inserted through the anus. Assisting trocars and routine laparoscopic instruments were placed. A high-definition 30° 5 mm or 10 mm laparoscopic camera lens was chosen. SILS: Single incision laparoscopic surgery.

was interpreted positive (less than 1 mm) in 5 patients. 18 (72%) patients had their surgeries performed in the Lloyd-Davies position, meanwhile, 7 patients in jackknife position in terms of anterior lesions. There was no intraoperative conversion from TAMIS to laparoscopic radical resection, and the mean duration of TAMIS surgeries was 61.3 min (ranger from 25 to 105 min), with mean blood loss 8.2 mL (range from 5 to 20 mL). There was no operative mortality or serious complication (over grade 3 by Clavien-Dindo grading system), and the mean length of hospital stay was 2.7 d post-operatively. Patients were follow-up more than 3 mo.

Learning curve for TAMIS

TAMIS surgeries were performed by a group of surgeons proficient with laparoscopic skills. Figure 3 demonstrated the correlation between cases and duration of TAMIS surgeries, indicating the learning curve of this technique. A trend line showed a steep decline in the surgery duration from 1 to 10 cases, and after 10 cases, this line stayed relatively steady.

Positive resection margin

In this study, we noted that 5 (20%) patients had positive resection margin (defined as less than 1 mm from the cutting edge) by post-operative pathological examination: 2 patients were diagnosed with adenocarcinoma, meanwhile the other 3 were low grade NETs (G1), as shown in Table 2. Interestingly, for cases of adenocarcinoma, positivity occurred at the lateral resection margin, while for cases of NETs, results showed 1 case had positive lateral margin and 2 cases had positive basal margin. All 5 patients with positive margin underwent MDT discussion for further treatment strategies. Finally, for the 2 patients with adenocarcinoma, 1 had curative surgery (low anterior resection), and 1 underwent post-operative chemoradiation; for the 3 NETs patients, adjuvant imatinib were recommended by oncologists.

DISCUSSION

Local excision (LE), as an alternative approach, has been employed under certain circumstances (benign adenomas, early stage adenocarcinomas, and low grade neuroendocrine tumors) for curative intent in rectal neoplasia. However, due to the difficulties in exposure and dissection, LE has been applied only in selected cases[8,9]. Since introduced by Buess *et al*[4], TEM has progressively become another recommended surgical procedure in clinical practice. The application of TEM, nevertheless, has been notably slow, due to the instrumental obstacles: Surgeons were compelled to operate through a rigid rectoscope, limiting triangulation and the subsequent instrumental manipulation, compared with the standard experience laparoscopically. With the widespread of laparoscopic approach, abdominal and pelvic operations have undergone magnificent changes. Using single-port system with common laparoscopic instruments, trans-anal laparoscopic resection has recently become more accessible. TAMIS, first reported by Atallah *et al*[10], was a novel trans-anal platform for full-thickness local excision of rectal benign and malignant tumors. TAMIS was more than a local excision technique, based on the laparoscopic platform with curative intent, by adopting the full-thickness resection and wound-sewing under camera and grasper. Several studies with limited cases have been published, demonstrating the better exposure

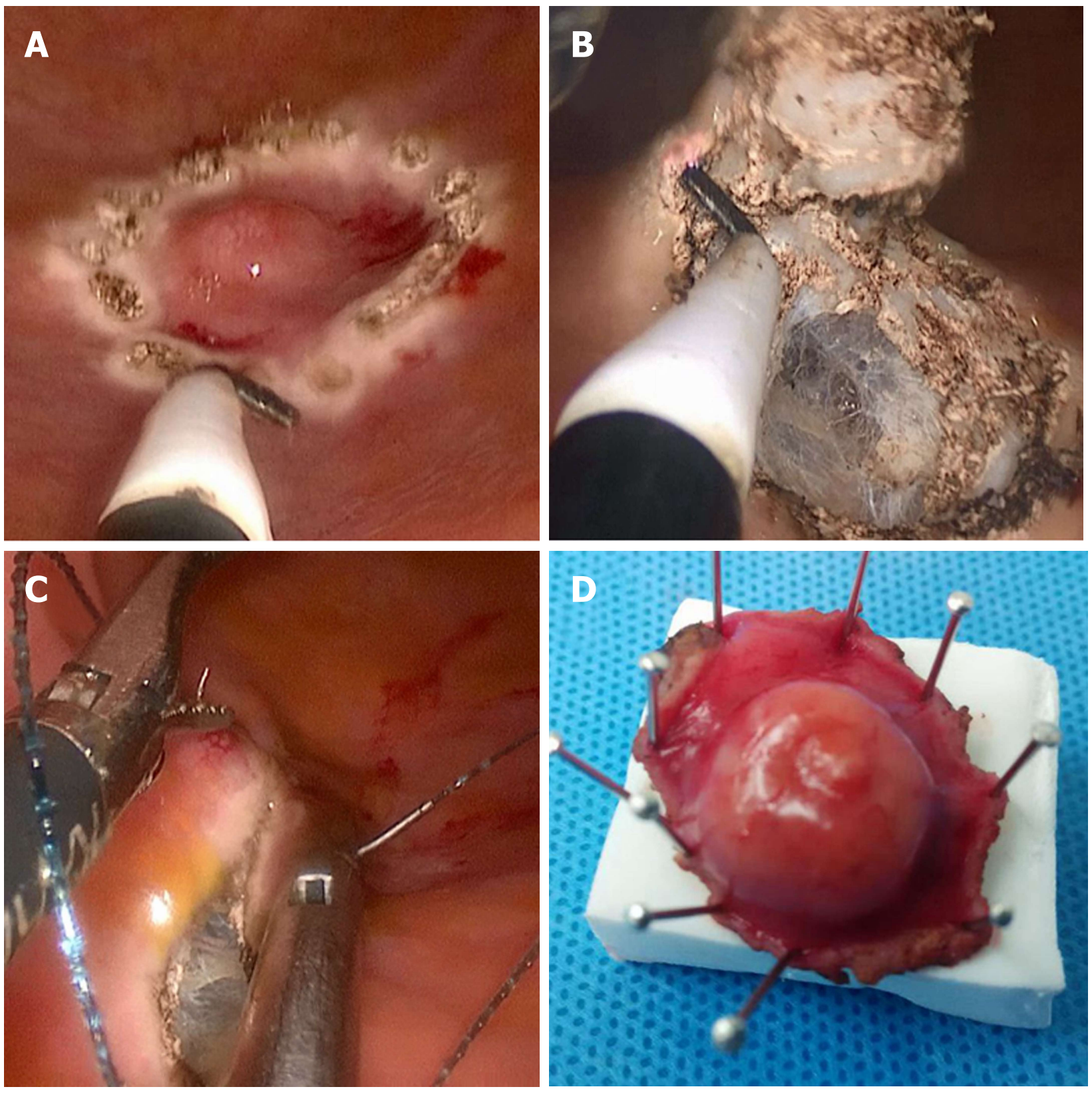

Figure 2 Procedures of trans-anal minimally invasive surgery. A: Intra-operative view of TAMIS showed resection margin was marked by electrocautery; B: An endoscopic grasper and electrocautery were used to facilitate a full-thickness excision; C: The defect of rectal wall was closed using STRATAFIXTM; D: The surgical specimen was pinned on plastic board with indicative orientation. TAMIS: Trans-anal minimally invasive surgery.

of operative field and easier instrumental manipulation, with the help of high-definition flexible camera and constant gas insufflation[5,7,11,12]. TAMIS settings provided a more precise resection margin and dissection plane, following the full-thickness excision principle.

This paper presented preliminary data from a single-center series of 25 consecutive patients affected by rectal neoplasia, including 22 cases malignancies (6 cases with adenocarcinomas, 16 cases with G1 neuroendocrine tumors) and 3 cases with adenomas, treated by TAMIS. All surgeries were successfully achieved without intra-operative conversion. In the first few cases, TAMIS surgeries were started with considerably better condition, like middle aged, female patients, then all patients meeting the inclusive criteria were suggested afterwards. Therefore, the mean age of enrolled patients was 51.8, and 60% were female due to the safety concerns. Five patients underwent local excision pre-operatively, with positive or unknown margins. In terms of precise orientation of the neoplastic residue or scar, all 5 patients underwent pre-TAMIS endoscopic examination with lesion clipped. Excision was done following the clips. Cases were selected based on the principle of trans-anal local excision by the National Comprehensive Cancer Network (NCCN) guideline version 2017. 1[13]. Post-operational pathology revealed that 3 cases with benign adenomas, while the other 22 were malignant. Among those, 16 (64%) were G1 NETs, and 6 were adenocarcinoma, with 5 T1 tumor and 1 case T3 tumor. No lymph-vascular invasion was seen. Interestingly, for the case with pT3 tumor, pre-operative mri demonstrated T1 (mucosa invasion) while trans-anal ultrasonography showed T1-T2 (putative muscularis invasion), fortunately negative resection margin was achieved by full-thickness resection. Higher risk of recurrence and curative surgery was informed, however, this patient refused surgical intervention due to concerns of anal function, with close follow-up.

The mean diameter of rectal lesions was 1.1 cm, and mean distance from the anal verge was 8.4 cm, indicating the location of mid to high third of the rectum. For cases within 4 cm from the anal verge, retrospective studies noted trans-anal local excision might be more applicable due to several considerations: Firstly, for low rectal lesion, it seems easier for exposure with tractors instead of SILS channel; secondly, the installation of SILS required at least 2 cm normal anal mucosa, resulting in the awkward location-too close from the lesion to the port without guaranteed resection margin. Another concern for the TAMIS technique was the surgical duration, and the majority cases in our studies were finished approximately 60 min with a maximum blood loss of 20 mL, demonstrating the reproducibility of this technique. No severe post-operative complications (Clavien-Dindo 3A or over), such as bleeding or stenosis were observed during the hospital stay and short term

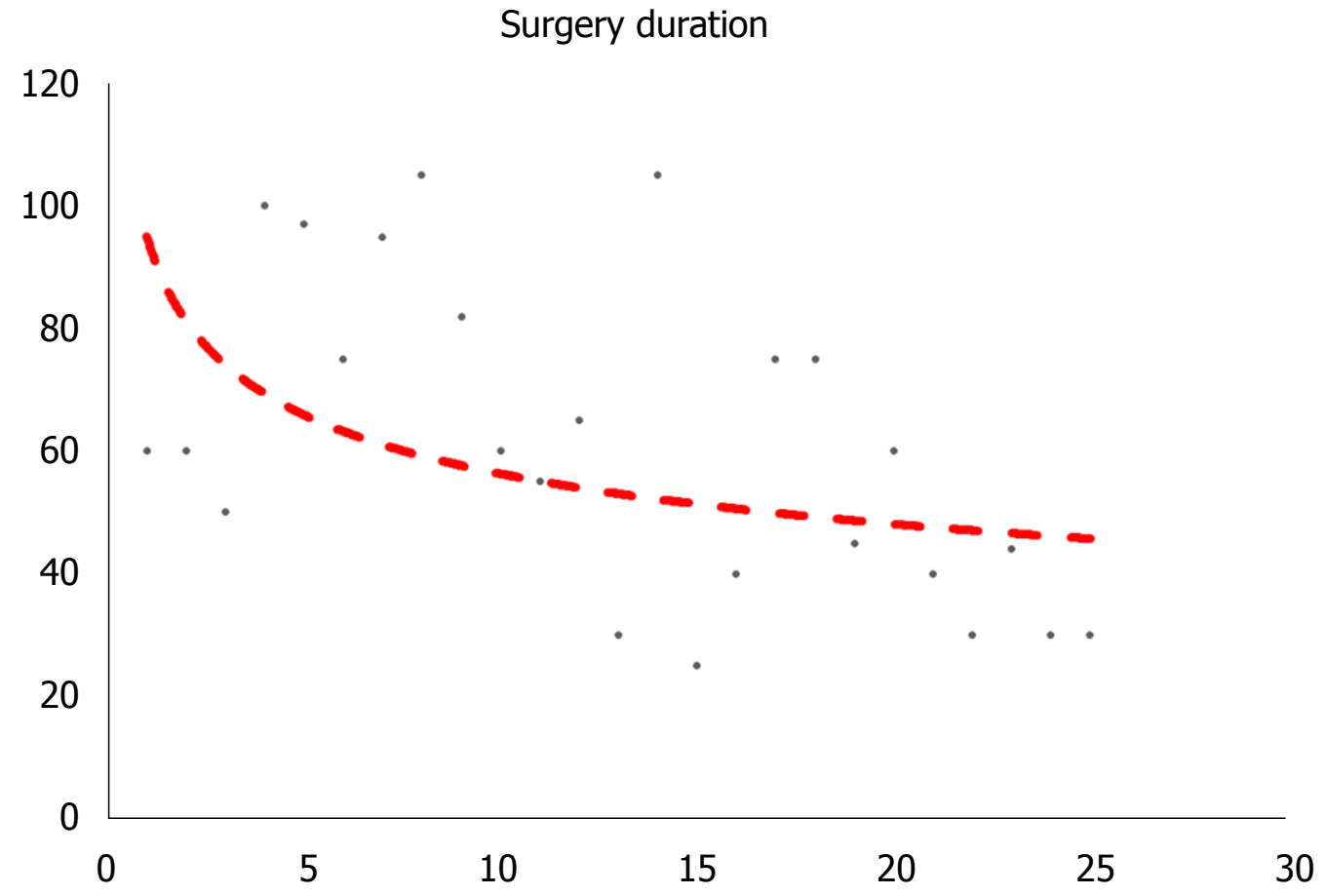

Figure 3 Correlation between cases and duration of trans-anal minimally invasive surgery surgeries. The X-axis represented individual case consequently, while the Y-axis was the duration of each surgery (min), indicating the learning curve of this technique.

(2 and 8 wk) follow-up. Previous literature mentioned the 3.3%-16.8% postoperative complication rate[4,14,15], such as peritoneum perforation, urinary tract infection, subcutaneous emphysema, hemorrhoid thrombosis, *etc*.

Surgical duration and learning curve

Previous studies of TAMIS were majorly institutional experience with a small amount of cases by retrospective nature. Maya *et al*[16] demonstrated that 4 cases might be necessary before the skillfulness obtaining by employing the CUSUM curve to assess competence in the surgical techniques of TAMIS. In this study, the routine protocol for TAMIS surgery were established following the literature. From the learning curve as shown above, we noted that surgery duration markedly varied within the first 10 cases and then stayed relatively stable (approximately 60 min), indicating that the proficient skills for TAMIS surgery required a minimal number of 10 cases. For surgeons with proficient laparoscopic technique, TAMIS would be easier since the share of similar instruments.

Positive resection margin

Previous studies reported that margin positivity was round 4% to 10%[12], according to the so-far largest review on TAMIS. In our study, the rate of positive margin was 20%, which seemed higher than expected. Further reviewing of the data revealed that 2 of 5 cases with positive margin occurred in the first 10 cases, indicating so-called "trial and error" period in TAMIS surgery. Among the following cases, the rates of positive margin greatly lessened. It is important to notice that full thickness resection would merely be guaranteed by dissection of fat tissue in the mesorectum or even penetration into pelvic cavity. Interestingly, it was noted that all these cases were performed with patients in the Lloyd-Davies position, with tumors located either lateral (4/5) or anterior (1/5) wall. It was plausible that patients' position might had a significant effect on the exposure and dissection of the lesion and the Lloyd-Davies position might not be appropriate for anterior lesions due to the rotated viewing angle[17]. Additionally, correlation between types of positivity with final pathology demonstrated that for adenocarcinoma, 2 of 2 cases had lateral positive margin, while for NETs, 2 of 3 cases had basal positive margin as well as the other 1 with lateral positivity. It is believed that adenocarcinoma, originated from mucosa, would have intraluminal mucosa infiltration[13]; conversely, NET has more mysterious features with various types of infiltration[18]. The 3mm resection margin was recommended by "National Comprehensive Cancer Network" (NCCN) for the principle of local excision in terms of curative intent[19], as implemented in our study. However, trans-anal local excision was performed using a variety of other standards of resection margin, from 5 mm to 10 mm[20,21]. It is speculated that positivity of resection margin might be decreased if the 5 mm (or 10 mm) margin applied, indicating for rectal malignancy treated by the TAMIS surgery, an enlarged resection margin might be safer. On the other hand, the defect resulted from enlarged resection, might raise higher requirement for laparoscopic sewing, regarding longer incision, higher suture tension, increased probability of post-operative stricture or scarring[22]. Whether enlarged margin would result in survival benefit might still be controversial and need more high quality of evidence.

Penetration into pelvic cavity

For neoplasia located on the anterior wall of upper third of rectum (above the peritoneal reflection), full-thickness resection inevitably results in the penetration into peritoneal cavity. In our study, there were 4 (16%) patients had the entering into peritoneal cavity intra-operatively with neoplasia located in the anterior wall. It is believed that full-thickness excision is mandatory when local excision performed for malignancy due to the probability containing an invasive component[23]. However, not all published literature reported[24]. It has been demonstrated that a partial thickness excision would result in a dramatic increase in the rates of positive margin[25], leading to enhanced risk of loco-regional recurrence.

Though with the well-established settings, TAMIS has its technical shortcomings. Firstly, it seems easier for instrumental manipulation compared with TEM, however, difficulties occurred with rectal masses which located over 10 cm from the anal verge, due to the existence of these transverse rectal folds as well as the physiological curvature of the pelvis. Secondly, the firm fixation of SILS Port platform to the anus required a minimal of 3-4 cm anal canal, therefore it would be difficult to get TAMIS done within 3-4 cm from the anal verge[15]. Thirdly, through the single port apparatus, laparoscopic instruments roughly oriented in parallel, resulting in the failure of triangulation, making free bending and rotating more difficult. Fourthly, general anesthesia, as applied in our TAMIS surgeries, yet had the problem of peristalsis under autonomic innervation intraoperatively, which was a disturbing factor for steady surgical fields. For better relaxation effect, additional methods, such as low sacral anesthesia might worth a try.

This study has its own limitations by its retrospective nature, relatively small cohort size and selected cases. The short-term outcome demonstrated that TAMIS might be a feasible technique in terms of full-thickness resection and minimal sphincter injury. Recent studies demonstrated that total mesorectal excision (TME) by using the platform of TAMIS was increasingly performed, leading the advance in the management of distal rectal cancer[26]. Long-term oncological safety needs to be investigated with further follow-up.

In summary, TAMIS is a feasible method of performing full thickness resection for rectal lesions with acceptable short-term outcome. Surgeon proficient with laparoscopic surgery would able to manage this technique after a training period of approximately 10 cases. TAMIS might be suggested as one of the alternative choices for the treatment of lesions located in the mid rectum of selected patients.

ARTICLE HIGHLIGHTS

Research background

Local excision is regarded as the standard treatment for mid-low rectal neoplasia, including benign tumors and early-stage malignancy. Due to the disadvantages in exposure, high quality of local excision could not be well guaranteed, though trans-anal endoscopic microsurgery (TEM) could merely provide solutions in certain conditions. Therefore, it is essential to call for another technique to fill the gap in-between. Recently, trans-anal minimally invasive surgery (TAMIS) has been introduced as an alternative choice for rectal lesions.

Research motivation

TAMIS surgery was reported by literature with relatively small amount of cases, however, there has been no published data on TAMIS surgery on the Chinese population. The safety and feasibility of TAMIS is still lack of evidence.

Research objectives

This study was designed to investigate the utility of TAMIS technique with both favorable and unfavorable factors.

Research methods

TAMIS surgery was done by a standard laparoscopic platform (SILS Port). Patients' characteristics, surgery duration, pathological diagnosis and post-operative complications (Clavien-Dindo classification) were collected.

Research results

The research findings, their contributions to the research in this field, and the problems that remain to be solved should be described in detail. Among 25 patients enrolled, 10 (40%) patients were male, with the mean age of the patients 51.8 and the mean body mass index 23.9 kg/m^2. Mean diameter of the lesions was 1.1 cm (range from 0.5 to 2 cm) and the mean distance to anal verge was 8.4 cm (range from 5 to 10 cm). 3 (12%) patients was diagnosed benign lesions (adenomas), 22 (88%) were malignancies (16 with neuroendocrine tumors (NETs) and 6 with adenocarcinoma (5 patients pT1, and 1 pT3). Positive resection margin (less than 1 mm) was revealed in 5 patients and lymph-vascular invasion was seen in 1 patient. Eighteen (72%) TAMIS surgeries were performed in the Lloyd-Davies position, with the rest in jackknife position. The mean duration of was 61.3 min (ranger from 25 to 105 min), with mean blood loss 8.2 mL (range from 5 to 20 mL) and no conversion to laparoscopic surgery. No operative mortality or serious complication (over grade 3 by Clavien-Dindo grading system), and the mean length of hospital stay was 2.7 d post-operatively. A laparoscopic surgeon would be proficient to perform TAMIS surgery with around 10 cases.

Research conclusions

TAMIS could be safe and feasible technique to early stage rectal neoplasia. Laparoscopic surgeons would be proficient for TAMIS with approximately 10 cases. TAMIS might provide an alternative method with conventional laparoscopic apparatus, compared with TEM. This study demonstrated the first piece of evidence of peri-operative data and short-term outcome in patients treated with TAMIS in Chinese tertiary hospital. TAMIS is a safe method treating early stage rectal neoplasia. Surgical position might have a significant effect on the positivity of resection margin, and Lloyds-Davies position might not be appropriate for anterior lesions. TAMIS could offer full-thickness resection and minimal sphincter injury. TAMIS might be an alternative choice for patients with early stage rectal neoplasia.

Research perspectives

TAMIS could be feasible by utilizing laparoscopic apparatus. For lesion located anteriorly, it might be better with jackknife position. It might be essential to know the rate of positivity concerning resection margin with larger number of cases prospectively; and it worth a try to use TAMIS in down-stage rectal cancer patients underwent neoadjuvant chemoradiation for re-staging and curative intent. A prospective clinical trial might be a good choice.

ACKNOWLEDGEMENTS

We greatly appreciate the following staff members who contributed to this work: Professor Ai-Wen Wu, Professor Jun Zhao, Professor Ming Li, Professor Zhong-Wu Li in Peking University Cancer Hospital.

REFERENCES

1 **Siegel R**, Naishadham D, Jemal A. Cancer statistics, 2012. *CA Cancer J Clin* 2012; **62**: 10-29 [PMID: 22237781 DOI: 10.3322/caac.20138]

2 **Garcia-Aguilar J**, Renfro LA, Chow OS, Shi Q, Carrero XW, Lynn PB, Thomas CR Jr, Chan E, Cataldo PA, Marcet JE, Medich DS, Johnson CS, Oommen SC, Wolff BG, Pigazzi A, McNevin SM, Pons RK, Bleday R. Organ preservation for clinical T2N0 distal rectal cancer using neoadjuvant chemoradiotherapy and local excision (ACOSOG Z6041): results of an open-label, single-arm, multi-institutional, phase 2 trial. *Lancet Oncol* 2015; **16**: 1537-1546

[PMID: 26474521 DOI: 10.1016/S1470-2045(15)00215-6]

3 **Hallam S**, Messenger DE, Thomas MG. A Systematic Review of Local Excision After Neoadjuvant Therapy for Rectal Cancer: Are ypT0 Tumors the Limit? *Dis Colon Rectum* 2016; **59**: 984-997 [PMID: 27602930 DOI: 10.1097/DCR.0000000000000613]

4 **Buess G**, Theiss R, Hutterer F, Pichlmaier H, Pelz C, Holfeld T, Said S, Isselhard W. [Transanal endoscopic surgery of the rectum - testing a new method in animal experiments]. *Leber Magen Darm* 1983; **13**: 73-77 [PMID: 6621245]

5 **Clancy C**, Burke JP, Albert MR, O'Connell PR, Winter DC. Transanal endoscopic microsurgery versus standard transanal excision for the removal of rectal neoplasms: a systematic review and meta-analysis. *Dis Colon Rectum* 2015; **58**: 254-261 [PMID: 25585086 DOI: 10.1097/DCR.0000000000000309]

6 **Noura S**, Ohue M, Miyoshi N, Yasui M. Transanal minimally invasive surgery (TAMIS) with a GelPOINT® Path for lower rectal cancer as an alternative to transanal endoscopic microsurgery (TEM). *Mol Clin Oncol* 2016; **5**: 148-152 [PMID: 27330788 DOI: 10.3892/mco.2016.893]

7 **McLemore EC**, Weston LA, Coker AM, Jacobsen GR, Talamini MA, Horgan S, Ramamoorthy SL. Transanal minimally invasive surgery for benign and malignant rectal neoplasia. *Am J Surg* 2014; **208**: 372-381 [PMID: 24832238 DOI: 10.1016/j.amjsurg.2014.01.006]

8 **Marijnen CA**. Organ preservation in rectal cancer: have all questions been answered? *Lancet Oncol* 2015; **16**: e13-e22 [PMID: 25638548 DOI: 10.1016/S1470-2045(14)70398-5]

9 **Sugarbaker PH**, Corlew S. Influence of surgical techniques on survival in patients with colorectal cancer. *Dis Colon Rectum* 1982; **25**: 545-557 [PMID: 6749455]

10 **Atallah S**, Albert M, Larach S. Transanal minimally invasive surgery: a giant leap forward. *Surg Endosc* 2010; **24**: 2200-2205 [PMID: 20174935 DOI: 10.1007/s00464-010-0927-z]

11 **Albert MR**, Atallah SB, deBeche-Adams TC, Izfar S, Larach SW. Transanal minimally invasive surgery (TAMIS) for local excision of benign neoplasms and early-stage rectal cancer: efficacy and outcomes in the first 50 patients. *Dis Colon Rectum* 2013; **56**: 301-307 [PMID: 23392143 DOI: 10.1097/DCR.0b013e31827ca313]

12 **Lee L**, Burke JP, deBeche-Adams T, Nassif G, Martin-Perez B, Monson JRT, Albert MR, Atallah SB. Transanal Minimally Invasive Surgery for Local Excision of Benign and Malignant Rectal Neoplasia: Outcomes From 200 Consecutive Cases With Midterm Follow Up. *Ann Surg* 2018; **267**: 910-916 [PMID: 28252517 DOI: 10.1097/SLA.0000000000002190]

13 **Graham RA**, Hackford AW, Wazer DE. Local excision of rectal carcinoma: a safe alternative for more advanced tumors? *J Surg Oncol* 1999; **70**: 235-238 [PMID: 10219019]

14 **Atallah SB**, Albert MR. Transanal minimally invasive surgery (TAMIS) versus transanal endoscopic microsurgery (TEM): is one better than the other? *Surg Endosc* 2013; **27**: 4750-4751 [PMID: 23892763 DOI: 10.1007/s00464-013-3111-4]

15 **Lee TG**, Lee SJ. Transanal single-port microsurgery for rectal tumors: minimal invasive surgery under spinal anesthesia. *Surg Endosc* 2014; **28**: 271-280 [PMID: 24061623 DOI: 10.1007/s00464-013-3184-0]

16 **Maya A**, Vorenberg A, Oviedo M, da Silva G, Wexner SD, Sands D. Learning curve for transanal endoscopic microsurgery: a single-center experience. *Surg Endosc* 2014; **28**: 1407-1412 [PMID: 24366188 DOI: 10.1007/s00464-013-3341-5]

17 **Buchs NC**, Pugin F, Volonte F, Hagen ME, Morel P, Ris F. Robotic transanal endoscopic microsurgery: technical details for the lateral approach. *Dis Colon Rectum* 2013; **56**: 1194-1198 [PMID: 24022537 DOI: 10.1097/DCR.0b013e3182a2ac84]

18 **Soga J**. Early-stage carcinoids of the gastrointestinal tract: an analysis of 1914 reported cases. *Cancer* 2005; **103**: 1587-1595 [PMID: 15742328 DOI: 10.1002/cncr.20939]

19 **You YN**, Baxter NN, Stewart A, Nelson H. Is the increasing rate of local excision for stage I rectal cancer in the United States justified?: a nationwide cohort study from the National Cancer Database. *Ann Surg* 2007; **245**: 726-733 [PMID: 17457165 DOI: 10.1097/01.sla.0000252590.95116.4f]

20 **Dias AR**, Nahas CS, Marques CF, Nahas SC, Cecconello I. Transanal endoscopic microsurgery: indications, results and controversies. *Tech Coloproctol* 2009; **13**: 105-111 [PMID: 19484350 DOI: 10.1007/s10151-009-0466-6]

21 **Hakiman H**, Pendola M, Fleshman JW. Replacing Transanal Excision with Transanal Endoscopic Microsurgery and/or Transanal Minimally Invasive Surgery for Early Rectal Cancer. *Clin Colon Rectal Surg* 2015; **28**: 38-42 [PMID: 25733972 DOI: 10.1055/s-0035-1545068]

22 **Cataldo PA**, O'Brien S, Osler T. Transanal endoscopic microsurgery: a prospective evaluation of functional results. *Dis Colon Rectum* 2005; **48**: 1366-1371 [PMID: 15933798 DOI: 10.1007/s10350-005-0031-y]

23 **Ramirez JM**, Aguilella V, Gracia JA, Ortego J, Escudero P, Valencia J, Esco R, Martinez M. Local full-thickness excision as first line treatment for sessile rectal adenomas: long-term results. *Ann Surg* 2009; **249**: 225-228 [PMID: 19212174 DOI: 10.1097/SLA.0b013e318190496f]

24 **Martin-Perez B**, Andrade-Ribeiro GD, Hunter L, Atallah S. A systematic review of transanal minimally invasive surgery (TAMIS) from 2010 to 2013. *Tech Coloproctol* 2014; **18**: 775-788 [PMID: 24848524 DOI: 10.1007/s10151-014-1148-6]

25 **Bach SP**, Hill J, Monson JR, Simson JN, Lane L, Merrie A, Warren B, Mortensen NJ; Association of Coloproctology of Great Britain and Ireland Transanal Endoscopic Microsurgery (TEM) Collaboration. A predictive model for local recurrence after transanal endoscopic microsurgery for rectal cancer. *Br J Surg* 2009; **96**: 280-290 [PMID: 19224520 DOI: 10.1002/bjs.6456]

26 **Atallah S**, Albert M, DeBeche-Adams T, Nassif G, Polavarapu H, Larach S. Transanal minimally invasive surgery for total mesorectal excision (TAMIS-TME): a stepwise description of the surgical technique with video demonstration. *Tech Coloproctol* 2013; **17**: 321-325 [PMID: 23377536 DOI: 10.1007/s10151-012-0971-x]

P- Reviewer: Amin S, Facciorusso A, Musquer N **S- Editor**: Ji FF
L- Editor: A **E- Editor**: Tan WW

Published by **Baishideng Publishing Group Inc**
7901 Stoneridge Drive, Suite 501, Pleasanton, CA 94588, USA
Telephone: +1-925-223-8242
Fax: +1-925-223-8243
E-mail: bpgoffice@wjgnet.com
Help Desk: http://www.f6publishing.com/helpdesk
http://www.wjgnet.com

© 2018 Baishideng Publishing Group Inc. All rights reserved.