ISSN 1948-5190 (online)

World Journal of Gastrointestinal Endoscopy

World J Gastrointest Endosc 2010 August 16; 2(8): 271-300

A peer-reviewed, online, open-access journal of gastrointestinal endoscopy

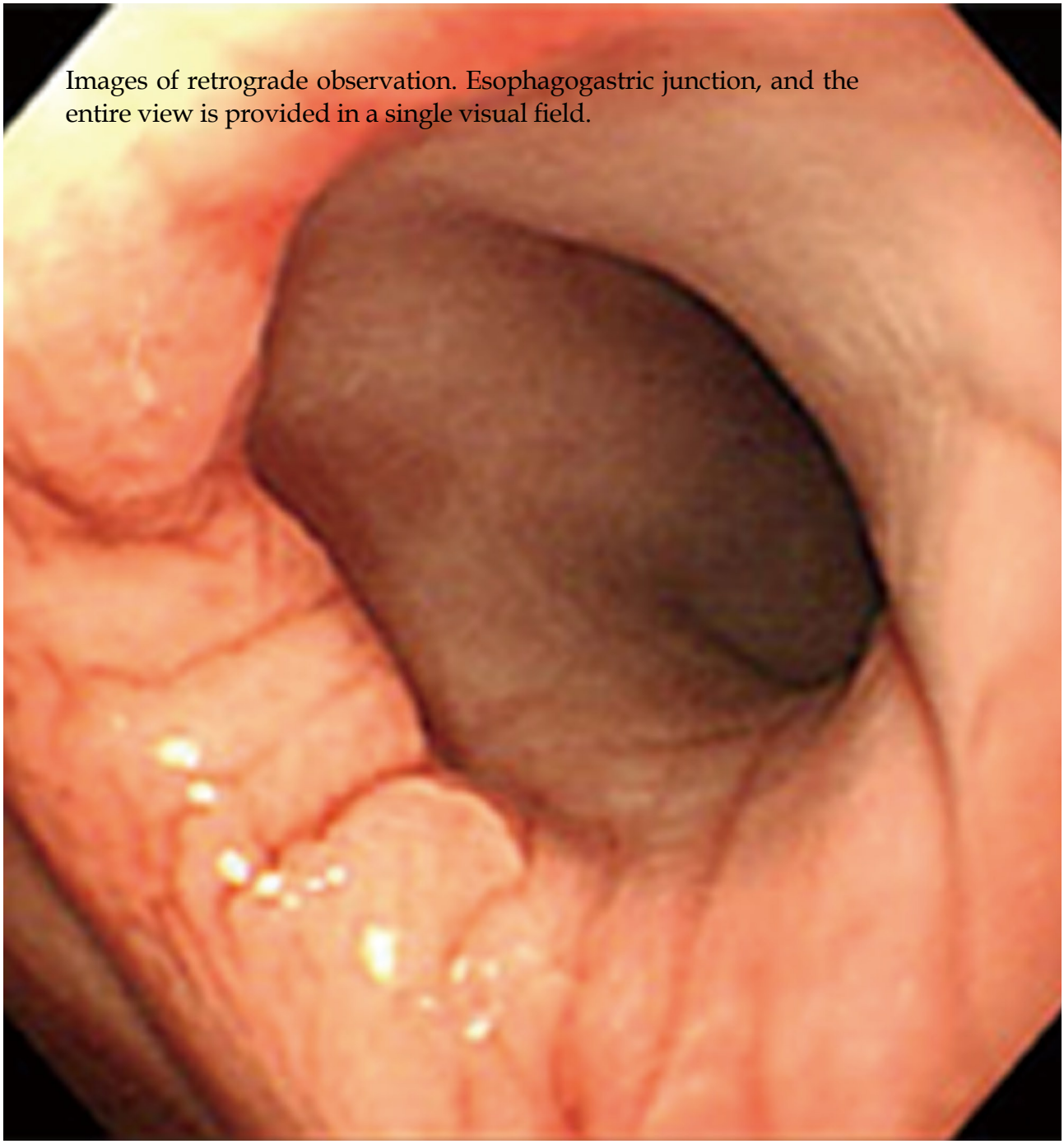

Images of retrograde observation. Esophagogastric junction, and the entire view is provided in a single visual field.

WJGE World Journal of Gastrointestinal Endoscopy

A peer-reviewed, online, open-access journal of gastrointestinal endoscopy

Editorial Board

2009-2013

The *World Journal of Gastrointestinal Endoscopy* Editorial Board consists of 400 members, representing a team of worldwide experts in gastrointestinal endoscopy. They are from 45 countries, including Australia (7), Austria (1), Belgium (6), Brazil (7), Canada (5), Chile (2), China (26), Croatia (2), Cuba (1), Czech Republic (3), Denmark (1), Ecuador (1), Egypt (1), Finland (2), France (10), Germany (27), Greece (11), Hungary (4), India (15), Iran (2), Ireland (3), Israel (6), Italy (37), Japan (62), Lebanon (1), Lithuania (1), Malaysia (2), Mexico (1), Netherlands (6), New Zealand (1), Norway (2), Pakistan (2), Poland (2), Portugal (5), Romania (2), Singapore (2), South Africa (1), South Korea (13), Spain (17), Sweden (3), Thailand (5), Turkey (8), United Arab Emirates (1), United Kingdom (14), and United States (69).

WJGE World Journal of Gastrointestinal Endoscopy

Contents

Monthly Volume 2 Number 8 August 16, 2010

Contents

World Journal of Gastrointestinal Endoscopy
Volume 2 Number 8 August 16, 2010

World Journal of Gastrointestinal Endoscopy (*World J Gastrointest Endosc*, *WJGE*, online ISSN 1948-5190, DOI: 10.4253), is a monthly, open-access, peer-reviewed journal supported by an editorial board of 400 experts in gastrointestinal endoscopy from 45 countries.

The major task of *WJGE* is to report rapidly the most recent results in basic and clinical research on gastrointestinal endoscopy including: gastroscopy, intestinal endoscopy, colonoscopy, capsule endoscopy, laparoscopy, interventional diagnosis and therapy, as well as advances in technology. Emphasis is placed on the clinical practice of treating gastrointestinal diseases with or under endoscopy. Papers on advances and application of endoscopy-associated techniques, such as endoscopic ultrasonography, endoscopic retrograde cholangiopancreatography, endoscopic submucosal dissection and endoscopic balloon dilation are also welcome.

NAME OF JOURNAL
World Journal of Gastrointestinal Endoscopy

LAUNCH DATE
October 15, 2009

SPONSOR
Beijing Baishideng BioMed Scientific Co., Ltd.,
Room 903, Building D, Ocean International Center,
No. 62 Dongsihuan Zhonglu, Chaoyang District,
Beijing 100025, China
Telephone: +86-10-8538-1892
Fax: +86-10-8538-1893
E-mail: baishideng@wjgnet.com
http://www.wjgnet.com

EDITING
Editorial Board of *World Journal of Gastrointestinal Endoscopy*,
Room 903, Building D, Ocean International Center,
No. 62 Dongsihuan Zhonglu, Chaoyang District,
Beijing 100025, China
Telephone: +86-10-5908-0038
Fax: +86-10-8538-1893
E-mail: wjge@wjgnet.com
http://www.wjgnet.com

PUBLISHING
Baishideng Publishing Group Co., Limited,
Room 1701, 17/F, Henan Bulding,
No.90 Jaffe Road, Wanchai,
Hong Kong, China
Fax: 00852-3115-8812
Telephone: 00852-5804-2046
E-mail: baishideng@wjgnet.com
http://www.wjgnet.com

SUBSCRIPTION
Beijing Baishideng BioMed Scientific Co., Ltd.,
Room 903, Building D, Ocean International Center,
No. 62 Dongsihuan Zhonglu, Chaoyang District,
Beijing 100025, China
Telephone: +86-10-8538-1892
Fax: +86-10-8538-1893
E-mail: baishideng@wjgnet.com
http://www.wjgnet.com

ONLINE SUBSCRIPTION
One-Year Price: 216.00 USD

PUBLICATION DATE
August 16, 2010

CSSN
ISSN 1948-5190 (online)

EDITORIAL OFFICE
Hai-Ning Zhang, Director
World Journal of Gastrointestinal Endoscopy
Room 903, Building D, Ocean International Center,
No. 62 Dongsihuan Zhonglu, Chaoyang District,
Beijing 100025, China
Telephone: +86-10-5908-0038
Fax: +86-10-8538-1893
E-mail: wjge@wjgnet.com
http://www.wjgnet.com

INSTRUCTIONS TO AUTHORS
Full instructions are available online at http://www.wjgnet.com/1948-5190/g_info_20100316080002.htm. If you do not have web access please contact the editorial office.

ONLINE SUBMISSION
http://www.wjgnet.com/1948-5190office/

World Journal of Gastrointestinal Endoscopy

Online Submissions: http://www.wjgnet.com/1948-5190office
wjge@wjgnet.com
doi:10.4253/wjge.v2.i8.271

World J Gastrointest Endosc 2010 August 16; 2(8): 271-277
ISSN 1948-5190 (online)

EDITORIAL

Gastrointestinal stromal tumor of the stomach: How to manage?

Kazuya Akahoshi, Masafumi Oya

Kazuya Akahoshi, Department of Gastroenterology, Aso Iizuka Hospital, Iizuka 820-8505, Japan
Masafumi Oya, Department of Pathology, Aso Iizuka Hospital, Iizuka 820-8505, Japan
Author contributions: Akahoshi K performed endoscopic ultrasound-guided fine needle aspiration (EUS-FNA) and wrote the paper; and Oya M performed immunohistological analysis of EUS-FNA specimens.
Correspondence to: Kazuya Akahoshi, MD, PhD, Department of Gastroenterology, Aso Iizuka Hospital, 3-83 Yoshio Town, Iizuka 820-8505, Japan. kakahoshi2@aol.com
Telephone: +81-948-223800 Fax: +81-948-298747
Received: February 27, 2010 Revised: June 27, 2010
Accepted: July 4, 2010
Published online: August 16, 2010

Abstract

Gastrointestinal stromal tumor (GIST) is one of the most common malignant mesenchymal tumors of the stomach. Prognosis of this disease is related to tumor size and mitotic activity and early diagnosis is the only way to improve it. Diagnosis of GIST always requires histological and immunohistochemical confirmation as no imaging modalities can diagnose it conclusively. Endoscopic forceps biopsy results are frequently negative. Endoscopic ultrasound-guided fine needle aspiration (EUS-FNA) is a technique which allows tissue samples to be obtained with minimal risks and is accurate in the diagnosis of GIST. From the point of view of the endoscopist, aggressive use of EUS-FNA is the only promising way to allow early diagnosis and early treatment of this disease.

Key words: Gastrointestinal stromal tumor; Endoscopic ultrasound; Fine needle aspiration; Gastrointestinal endoscopy; Algorithm

Peer reviewer: Sherman M Chamberlain, MD, FACP, FACG, AGAF, Associate Professor of Medicine, Section of Gastroenterology, BBR-2538, Medical College of Georgia, Augusta, GA 30912, United States

Akahoshi K, Oya M. Gastrointestinal stromal tumor of the stomach: How to manage? *World J Gastrointest Endosc* 2010; 2(8): 271-277 Available from: URL: http://www.wjgnet.com/1948-5190/full/v2/i8/271.htm DOI: http://dx.doi.org/10.4253/wjge.v2.i8.271

INTRODUCTION

Gastrointestinal stromal tumor (GIST) is one of the most common malignant mesenchymal tumors of the gastrointestinal tract, and is pathologically defined by positive immunostaining for c-kit or CD34[1-6]. Every GIST is now considered to be potentially malignant and all GISTs without metastasis need to be resected[7]. Miettinen reported that small gastric GISTs less than 2 cm have a 100% cure rate after complete surgical resection[6]. So, early diagnosis and early surgical resection while the tumor is still small are important to improve the prognosis of this disease. However, since not all intramural lesions of the stomach are GIST, a preoperative pathological diagnosis should be obtained. The mucosal surface of a GIST is usually normal, and endoscopic forceps biopsy results are frequently negative. Therefore, most cases are preoperatively diagnosed as suspected GIST using imaging modalities only [esophagogastroduodenoscopy (EGD), endoscopic ultrasound (EUS), and computed tomography (CT), *etc*], and definitive diagnosis is then made by immunohistochemical analysis after surgery[1,3,4]. These clinical conditions make it difficult to diagnose GIST at an early stage. Endoscopic ultrasound-guided fine needle aspiration (EUS-FNA) is recognized as the only accurate diagnostic modality for the diagnosis of GIST[8-12]. At present, management algorithms for GIST remain controversial from the point of view of the endoscopist,

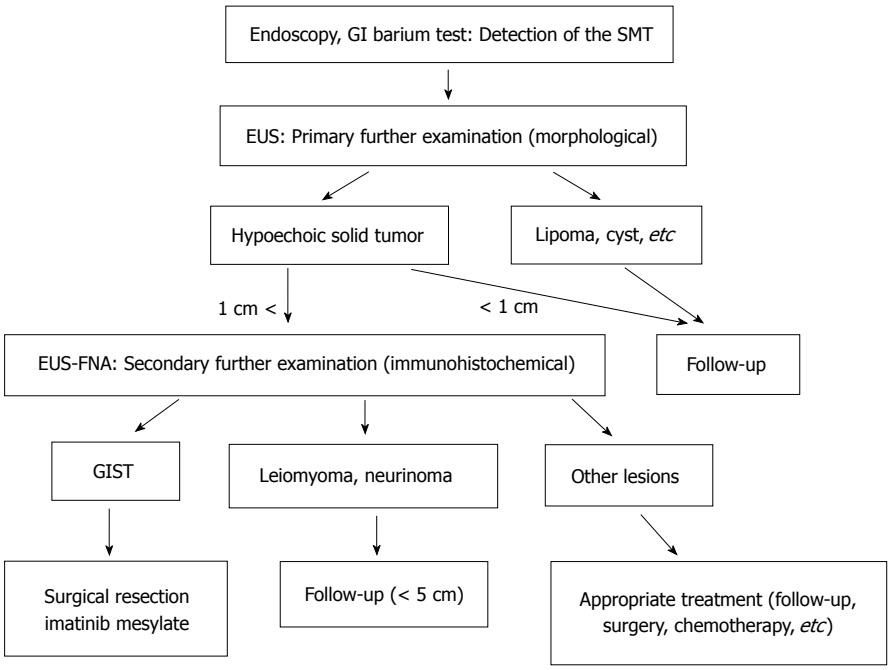

Figure 1 Diagnostic and therapeutic algorithm of gastrointestinal stromal tumor using endoscopic ultrasound-guided fine needle aspiration. Quoted and modified from reference [8,14]. GIST: gastrointestinal stromal tumor; GI: gastrointestinal; SMT: submucosal tumor; EUS: endoscopic ultrasound; EUS-FNA: endoscopic ultrasound-guided fine needle aspiration.

especially for small lesions[8,13-15]. Furthermore, diagnosis of GIST using EUS-FNA has not spread globally[8-13]. This editorial outlines the clinical usefulness of our institutional management algorithm for GIST using EUS-FNA for early diagnosis and early treatment of GIST (Figure 1)[8,14,15].

CLINICAL CHARACTERISTICS OF THE GASTRIC GIST

GIST is the most common mesenchymal tumor of the digestive tract[1]. It originate from the interstitial cell of Cajal located in the proper muscle layer and is characterized by over-expression of the tyrosine kinase receptor KIT[1,2]. Pathologically, the diagnosis of GIST relies on morphology and immunohistochemistry (c-kit is generally positive) (Figure 2)[16]. Incidence of GIST is estimated at 1.5/100 000/year[7]. GIST predominantly occurs in middle-aged and older persons (5th to 7th decade), with no significant difference in distribution between males and females[17,18]. Most GISTs arise in the stomach (approximately 60%) and small intestine (approximately 30%) and infrequently in other organs[19,20]. The symptoms, which depend on tumor size and location, are usually nonspecific[21]. Small GISTs are usually asymptomatic and are detected either during investigations or surgical procedures for unrelated disease. The commonest presentation of GIST is bleeding related mucosal erosion (delle)[21]. There are no recognized specific imaging examinations for GIST diagnosis. Barium contrast studies and endoscopy may provide useful data on the localization of GIST. CT scan is usually performed for staging of GIST. Endoscopic biopsy for the tumor is difficult without ulceration. Reported diagnostic accuracy for submucosal tumor (SMT) is about

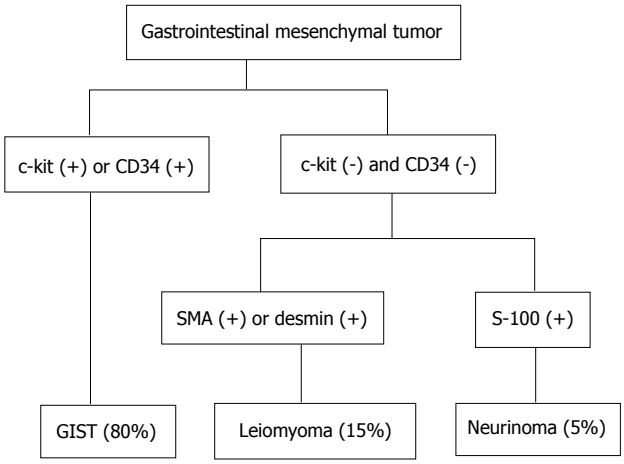

Figure 2 Flow chart of diagnosis for gastrointestinal mesenchymal tumors using immunohistochemical analysis. Quoted and modified from reference [16]. GIST: gastrointestinal stromal tumor; SMT: submucosal tumor.

40%[22]. GIST usually, and primarily, metastasizes to the liver and peritoneal cavity, while pleural, lung, or lymph node metastases are rare[19]. For localized tumors, wedge resection of the stomach is considered to be adequate treatment since GISTs tend to be exophytic and do not involve regional lymph nodes[3,4,7]. For unresectable and/or metastatic disease, treatment with imatinib is the first choice. The overall 5-year survival rate for patients with primary gastric GISTs who underwent complete resection, ranges from 20% to 63%, with a recurrence rate of 17% to 76%[19,23]. Predicting the postoperative metastatic risk (malignant potential) of GIST is often difficult, and various histopathological criteria have been proposed based on tumor size and tumor cell proliferating activity[3,4]. However, it has been recognized that a subset of small GISTs with low mitotic activity occasionally

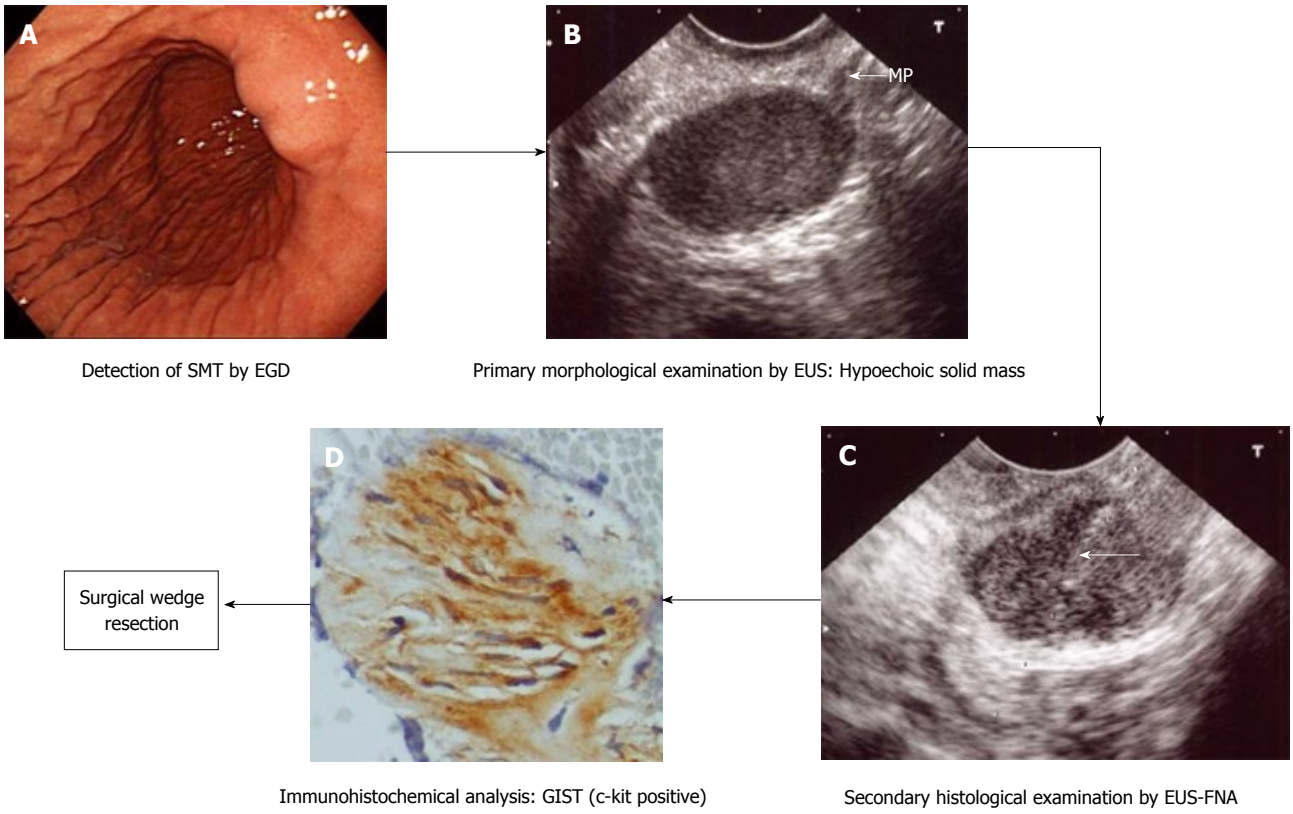

Figure 3 Management process of gastric submucosal tumor (in a case of gastrointestinal stromal tumor) according to our institutional algorithm (Figure 1). Quoted and modified from reference [15]. A: Esophagogastroduodenoscopy (EGD) shows submucosal tumor (SMT) in the lower body of the stomach; B: Endoscopic ultrasound (EUS) reveals 2.5 cm subepithelial hypoechoic solid tumor with continuity to proper muscle layer (arrow-mp); C: Puncture of the small gastrointestinal stromal tumor (GIST) under EUS guidance. Arrow: tip of needle; D: The immunohistochemical fnding of endoscopic ultrasound-guided fne needle aspiration (EUS-FNA) specimen of GIST. The tumor is diffusely positive for c-kit.

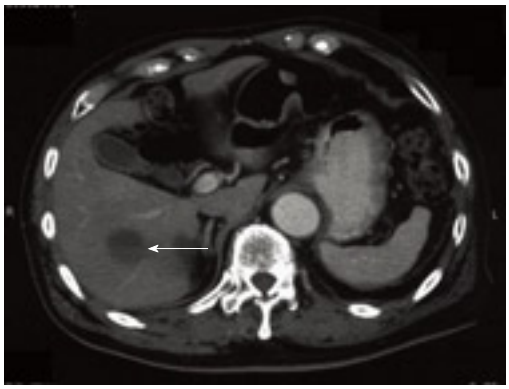

Figure 4 Computed tomography at 2 years after surgery showing hepatic metastasis (arrow). Quoted from reference [15].

metastasize; thus, no GIST can be definitely labeled as benign. Since every GIST is now considered as potentially malignant, all GISTs may need to be resected, even small intramural lesions of the gastrointestinal tract[3-6]. Clinical imaging modalities (endoscopy, EUS, *etc*) can provide only tumor size as a predictor of metastatic potential. Miettinen reported that with small gastric GIST (< 2 cm) there occurred no metastasis in 1765 cases (Table 1)[6]. In our previous study and experience, postoperative hepatic metastasis occurred in one case of 2.5 cm gastric GIST (Figures 3 and 4)[15], and in all GISTs less than 2 cm there was no postoperative relapse[8]. In other words, complete surgical resection of gastric GIST smaller than 2 cm has a 100% cure rate. So, early diagnosis and early surgical resection while the tumor is still small is a promising way for improving the prognosis of this disease.

Table 1 Reported risk of progressive disease (%)[1] of primary gastric gastrointestinal stromal tumor by mitotic index and size

	Tumor size			
Mitotic index	0-2 cm	2-5 cm	5-10 cm	> 10 cm
< 5 per 50 hpf	0%	1.9%	3.6%	10%
> 5 per 50 hpf	0%	16%	55%	86%

Adapted from reference [6], 2005. Data are based on long-term follow-up of 1765 gastric gastrointestinal stromal tumors. [1]Defined as metastasis or tumor-related death.

EUS AND EUS-FNA DIAGNOSIS

EUS allows clear imaging of the gastrointestinal wall layers and precise evaluation of the submucosal tumor (Figure 5)[15] whether from extrinsic compression or from the layer in which the intramural lesion originates[8,11,14,15]. Usually, GIST is imaged by EUS as a hypoechoic solid

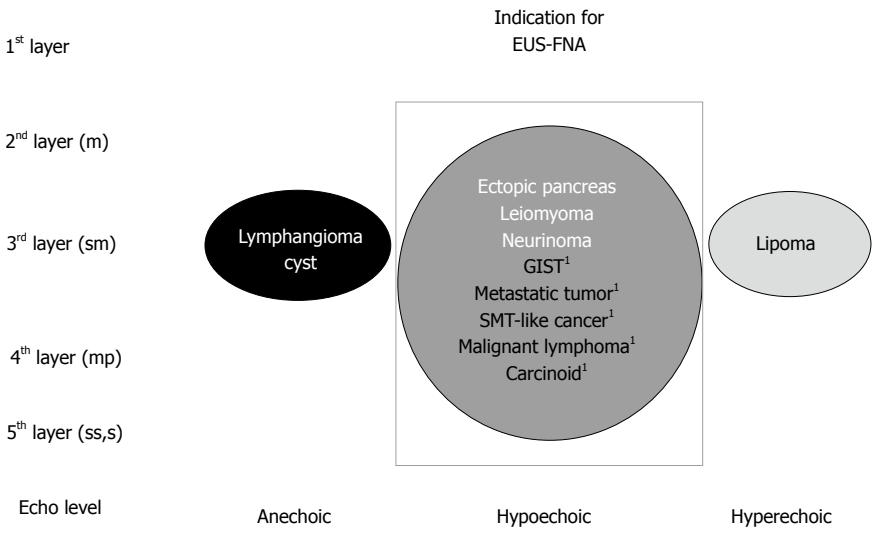

Figure 5 Differential diagnosis of gastric submucosal tumor by endoscopic ultrasound. Quoted and modified from reference [15]. GIST: gastrointestinal stromal tumor; SMT: submucosal tumor; EUS-FNA: endoscopic ultrasound-guided fine needle aspiration. [1]Malignant tumor.

tumor continuous with the proper muscle[8,11,14,15]. A large group of submucosal lesions such as lipomas, cysts, and submucosal varices have typical features that allow accurate diagnosis based solely on the data gathered from endoscopy and EUS imaging[8,11,14,15]. However, an important subset of submucosal lesions such as GISTs, leiomyoma, neurinoma, carcinoid tumors, ectopic pancreas, lymphoid mass tissues, SMT-like cancers, and metastases may have overlapping echo (hypoechoic solid mass) and endoscopic features and cannot be accurately determined without a biopsy sample. In the diagnostic process of GIST, immunohistochemical analysis of tissue sample such as c-kit is vital for confirmation of this disease[1-4]. Therefore, EUS-FNA should be performed for all hypoechoic solid tumors imaged by EUS (Figure 1).

Observations to date indicate that EUS-FNA is a safe and accurate procedure[8-12,14,15]. The reported accuracy of preoperative diagnosis of EUS-FNA using immunohistochemical analysis for surgically resected GIST cases ranges from 91% to 100%[8,10-12]. The diagnostic accuracy of EUS-FNA using immunohistochemical analysis is excellent. The reported diagnostic rate for tumors less than 2 cm, 2 cm to 4cm, and 4cm or more was 71%, 86%, and 100%, respectively[8]. This accurate preoperative histological proof of GIST using EUS-FNA facilitates the surgeon's and oncologist's decision, making for early local resection and early start of imatinib treatment [8,10-12].

MANAGEMENT ALGORITHMS FOR GIST FROM THE POINT OF VIEW OF THE ENDOSCOPIST

Some management algorithms for GIST are available[1,8,13-15,24]. However, few algorithms exist for using EUS-FNA in early diagnosis and early treatment of GIST[8,13-15]. In our hospital, we designed an algorithm for early diagnosis of GIST using EUS-FNA, and have performed decision-making for GIST according to this algorithm in the daily clinical setting (Figure 1)[14,15]. In the authors' experience and in discussions with surgeons at our institution, crucial preoperative planning and management are facilitated by the histological diagnoses provided with EUS-FNA. Operative planning, including decisions on the type of surgery to be conducted, varies dramatically in relation to the histological diagnosis[8,11,13-15]. For example, a patient with localized GIST can be cured with a wedge resection, or if the GIST is extensive, the patient can receive imatinib. However, a patient with SMT-like advanced gastric cancer would undergo gastrectomy with lymph-node dissection and might need postoperative chemotherapy. A patient with benign SMT, such as ectopic pancreas, could avoid surgery completely following EUS-FNA confirmation of histologic benignancy. In addition, a definitive histological diagnosis by EUS-FNA is routinely requested by oncologists before initiating any chemotherapy, radiotherapy, or palliative treatment[25]. Thus, EUS-FNA evidently has a significant positive impact on clinical management of patients by providing a definitive histological diagnosis[8]. We believe that aggressive use of EUS-FNA in the management algorithm for GISTs is a key factor for improving the prognosis of this disease. However, it is difficult to obtain histological samples from a small tumor (especially less than 1 cm) using current EUS-FNA. Furthermore, EUS-FNA for small GIST theoretically has a risk of seeding due to penetration of the tumor by the needle. Having regards to the technical problems of EUS-FNA and the extremely rare metastatic risk in small GIST less than 1 cm, we recommend aggressive use of EUS-FNA for all GI tract submucosal hypoechoic tumors larger than 1 cm.

PATIENT MANAGEMENT ACCORDING TO THE ALGORITHM: REPRESENTATIVE CASES

A case of GIST

Representative EGD, EUS and EUS-FNA findings in

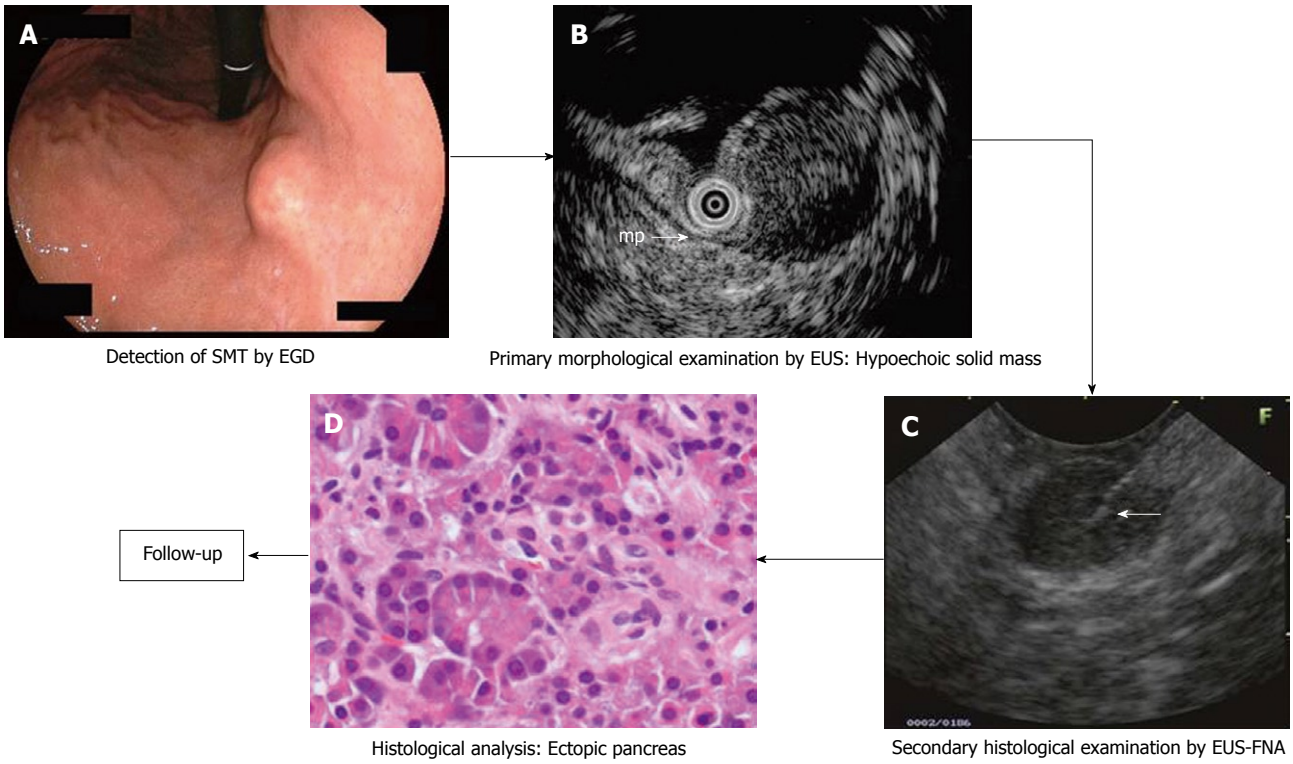

Figure 6 Management process of gastric submucosal tumor (in a case of ectopic pancreas) according to our institutional algorithm (Figure 2). Quoted and modified from reference [15]. A: Esophagogastroduodenoscopy (EGD) showing submucosal tumor (SMT) in the middle body of the stomach; B: Endoscopic ultrasound (EUS) revealing 1.5 cm subepithelial hypoechoic solid tumor with continuity to proper muscle layer (arrow-mp); C: Puncture of the small submucosal nodule under EUS guidance. Arrow: tip of needle; D: Histology of endoscopic ultrasound-guided fine needle aspiration (EUS-FNA) specimen reveals pancreatic acinar cells.

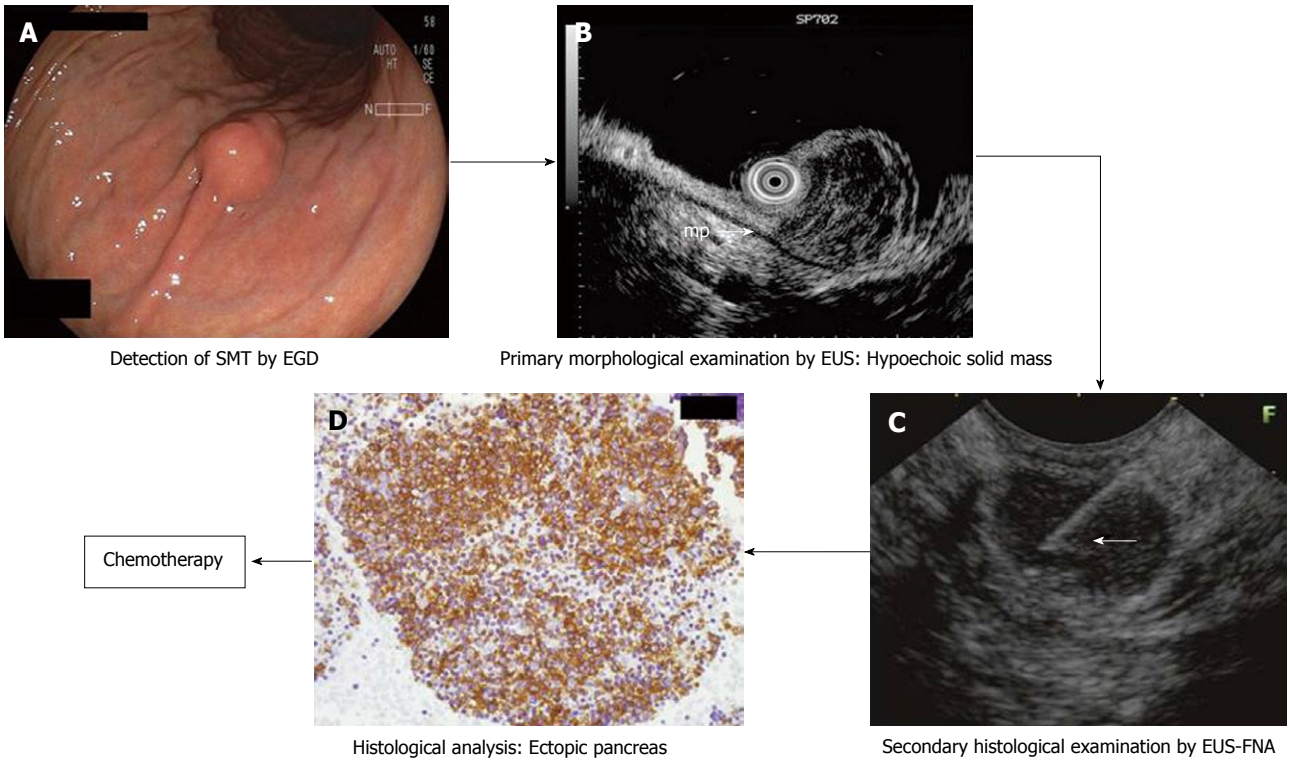

Figure 7 Management process of gastric submucosal tumor (in a case of B-cell lymphoma) according to our institutional algorithm (Figure 2). Quoted and modified from reference [15]. A: Esophagogastroduodenoscopy (EGD) showing submucosal tumor (SMT) in the middle body of the stomach; B; Endoscopic ultrasound (EUS) reveals 1.5 cm subepithelial hypoechoic solid tumor within submucosal layer. Proper muscle layer (arrow-mp) is intact; C: Puncture of the small gastric malignant lymphoma under EUS guidance. Arrow: tip of needle; D: The immunohistochemical findings of endoscopic ultrasound-guided fine needle aspiration (EUS-FNA) specimen reveals CD-20 positive diffuse large B cell lymphoma.

a patient with a small gastric GIST (2.5 cm) are shown in Figure 3[15]. The results of immunohistochemical analysis of the tumor showed positive reaction for c-kit and CD34, and negative reaction for muscle actin and S-100. The tumor was diagnosed as GIST, and the patient underwent local resection. The immunohistochemical staining pattern in the surgically resected lesion had similar results (diagnosed as GIST). However, this tumor had high mitotic activity (> 5/50 HPF), and was classified as of intermediate risk of aggressive behavior of GIST. CT at 2 years after surgery revealed hepatic metastasis (Figure 4). The patient was then treated with imatinib mesylate.

A case of ectopic pancreas

Figure 6[15] shows EGD, EUS and EUS-FNA findings in a patient with a small non-GIST (1.5 cm). EUS revealed a small hypoechoic tumor, suspected as GIST, with continuity to the proper muscle layer. The tumor thereafter was diagnosed as an ectopic pancreas by EUS-FNA, and follow-up was then performed on the patient.

A case of B-cell lymphoma

Figure 7[15] shows EGD, EUS and EUS-FNA findings in a patient with small non-GIST (2 cm). EUS revealed small hypoechoic tumor within the submucosal layer suspected as carcinoid tumor, lymphoma, or metastatic tumor, *etc*. The tumor was diagnosed as B-cell lymphoma (positive reaction to CD20.) by the following EUS-FNA, and then chemotherapy was performed on the patient.

CONCLUSION

EUS-FNA is a safe and accurate test in the diagnosis of GIST. At present, aggressive use of EUS-FNA is the only viable way of allowing early diagnosis and early treatment of this disease from the point of view of the endoscopist.

REFERENCES

1 **Bucher P**, Villiger P, Egger JF, Buhler LH, Morel P. Management of gastrointestinal stromal tumors: from diagnosis to treatment. *Swiss Med Wkly* 2004; **134**: 145-153

2 **Hirota S**, Isozaki K, Moriyama Y, Hashimoto K, Nishida T, Ishiguro S, Kawano K, Hanada M, Kurata A, Takeda M, Muhammad Tunio G, Matsuzawa Y, Kanakura Y, Shinomura Y, Kitamura Y. Gain-of-function mutations of c-kit in human gastrointestinal stromal tumors. *Science* 1998; **279**: 577-580

3 **Demetri GD**, Benjamin RS, Blanke CD, Blay JY, Casali P, Choi H, Corless CL, Debiec-Rychter M, DeMatteo RP, Ettinger DS, Fisher GA, Fletcher CD, Gronchi A, Hohenberger P, Hughes M, Joensuu H, Judson I, Le Cesne A, Maki RG, Morse M, Pappo AS, Pisters PW, Raut CP, Reichardt P, Tyler DS, Van den Abbeele AD, von Mehren M, Wayne JD, Zalcberg J. NCCN Task Force report: management of patients with gastrointestinal stromal tumor (GIST)--update of the NCCN clinical practice guidelines. *J Natl Compr Canc Netw* 2007; **5** Suppl 2: S1-S29; quiz S30

4 **Blay JY**, Bonvalot S, Casali P, Choi H, Debiec-Richter M, Dei Tos AP, Emile JF, Gronchi A, Hogendoorn PC, Joensuu H, Le Cesne A, McClure J, Maurel J, Nupponen N, Ray-Coquard I, Reichardt P, Sciot R, Stroobants S, van Glabbeke M, van Oosterom A, Demetri GD. Consensus meeting for the management of gastrointestinal stromal tumors. Report of the GIST Consensus Conference of 20-21 March 2004, under the auspices of ESMO. *Ann Oncol* 2005; **16**: 566-578

5 **Fletcher CD**, Berman JJ, Corless C, Gorstein F, Lasota J, Longley BJ, Miettinen M, O'Leary TJ, Remotti H, Rubin BP, Shmookler B, Sobin LH, Weiss SW. Diagnosis of gastrointestinal stromal tumors: A consensus approach. *Hum Pathol* 2002; **33**: 459-465

6 **Miettinen M**, Sobin LH, Lasota J. Gastrointestinal stromal tumors of the stomach: a clinicopathologic, immunohistochemical, and molecular genetic study of 1765 cases with long-term follow-up. *Am J Surg Pathol* 2005; **29**: 52-68

7 **Casali PG**, Jost L, Reichardt P, Schlemmer M, Blay JY. Gastrointestinal stromal tumours: ESMO clinical recommendations for diagnosis, treatment and follow-up. *Ann Oncol* 2009; **20** Suppl 4: 64-67

8 **Akahoshi K**, Sumida Y, Matsui N, Oya M, Akinaga R, Kubokawa M, Motomura Y, Honda K, Watanabe M, Nagaie T. Preoperative diagnosis of gastrointestinal stromal tumor by endoscopic ultrasound-guided fine needle aspiration. *World J Gastroenterol* 2007; **13**: 2077-2082

9 **Sawaki A**, Mizuno N, Takahashi K, Nakamura T, Tajika M, Kawai H, Isaka T, Imaoka H, Okamoto Y, Aoki M, Inoue H, Salem AA, Yatabe Y, Yamao K. Long-term follow up of patients with small gastrointestinal stromal tumors in the stomach using endoscopic ultrasonography-guided fine-needle aspiration biopsy. *Dig Endosc* 2006; **18**: 40-44

10 **Ando N**, Goto H, Niwa Y, Hirooka Y, Ohmiya N, Nagasaka T, Hayakawa T. The diagnosis of GI stromal tumors with EUS-guided fine needle aspiration with immunohistochemical analysis. *Gastrointest Endosc* 2002; **55**: 37-43

11 **Okubo K**, Yamao K, Nakamura T, Tajika M, Sawaki A, Hara K, Kawai H, Yamamura Y, Mochizuki Y, Koshikawa T, Inada K. Endoscopic ultrasound-guided fine-needle aspiration biopsy for the diagnosis of gastrointestinal stromal tumors in the stomach. *J Gastroenterol* 2004; **39**: 747-753

12 **Chatzipantelis P**, Salla C, Karoumpalis I, Apessou D, Sakellariou S, Doumani I, Papaliodi E, Konstantinou P. Endoscopic ultrasound-guided fine needle aspiration biopsy in the diagnosis of gastrointestinal stromal tumors of the stomach. A study of 17 cases. *J Gastrointestin Liver Dis* 2008; **17**: 15-20

13 **Kubota T**. Gastrointestinal stromal tumor (GIST) and imatinib. *Int J Clin Oncol* 2006; **11**: 184-189

14 **Akahoshi K**, Endoscopic ultrasonography in the stomach. In: Tajiri H, Oyama T, editors, Knack and pitfall of gastrointestinal endoscopy in diagnosis of esophageal, gastric and duodenal diseases. Tokyo: Yodosya, 2009: 149-156

15 **Akahoshi K**, Matsui N, Sumida Y, Kubokawa M, Motomura Y, Oya M, Matono H, Sakamoto M, Miyazaki M, Maekawa R, Kozaki S, Uozumi H. Diagnosis of the gastric Submucosal tumors by endoscopic ultrasonography-guided fine needle aspiration. *Endoscopia Digestiva* 2009; **21**: 1709-1717

16 **Ohashi T**, Hirota S. Immunohistochemical diagnosis of GIST (gastrointestinal stromal tumor). *Rhinshogeka* 2004; **59**: 129-135

17 **Miettinen M**, Majidi M, Lasota J. Pathology and diagnostic criteria of gastrointestinal stromal tumors (GISTs): a review. *Eur J Cancer* 2002; **38** Suppl 5: S39-S51

18 **Rossi CR**, Mocellin S, Mencarelli R, Foletto M, Pilati P, Nitti D, Lise M. Gastrointestinal stromal tumors: from a surgical to a molecular approach. *Int J Cancer* 2003; **107**: 171-176

19 **DeMatteo RP**, Lewis JJ, Leung D, Mudan SS, Woodruff JM, Brennan MF. Two hundred gastrointestinal stromal tumors: recurrence patterns and prognostic factors for survival. *Ann Surg* 2000; **231**: 51-58

20 **Miettinen M**, Sarlomo-Rikala M, Lasota J. Gastrointestinal stromal tumours. *Ann Chir Gynaecol* 1998; **87**: 278-281

21 **Ludwig DJ**, Traverso LW. Gut stromal tumors and their clinical behavior. *Am J Surg* 1997; **173**: 390-394

22 **Rösch T**, Kapfer B, Will U, Baronius W, Strobel M, Lorenz R, Ulm K. Accuracy of endoscopic ultrasonography in upper gastrointestinal submucosal lesions: a prospective multicenter study. *Scand J Gastroenterol* 2002; **37**: 856-862
23 **Lehnert T**. Gastrointestinal sarcoma (GIST)--a review of surgical management. *Ann Chir Gynaecol* 1998; **87**: 297-305
24 **Pisters PW**, Patel SR. Gastrointestinal stromal tumors: Current management. *J Surg Oncol* 2010; Epub ahead of print
25 **Wu PC**, Langerman A, Ryan CW, Hart J, Swiger S, Posner MC. Surgical treatment of gastrointestinal stromal tumors in the imatinib (STI-571) era. *Surgery* 2003; **134**: 656-665; discussion 665-666

S- Editor Zhang HN **L- Editor** Hughes D **E- Editor** Liu N

World Journal of Gastrointestinal Endoscopy

Online Submissions: http://www.wjgnet.com/1948-5190office
wjge@wjgnet.com
doi:10.4253/wjge.v2.i8.278

World J Gastrointest Endosc 2010 August 16; 2(8): 278-287
ISSN 1948-5190 (online)

TOPIC HIGHLIGHT

Carlos Robles-Medranda, MD, *Series Editor*

Endoscopic ultrasound in the papilla and the periampullary region

Cecilia Castillo

Cecilia Castillo, Endoscopy Service, Latin American Endoscopy Training Center, Clínica Alemana de Santiago, Universidad del Desarrollo, Vitacura 5951, Santiago, Chile
Author contributions: Castillo C wrote the paper.
Correspondence to: Cecilia Castillo, MD, Endoscopy Service, Latin American Endoscopy Training Center, Clínica Alemana de Santiago, Universidad del Desarrollo, Vitacura 5951, Santiago, Chile. ccastillo@alemana.cl
Telephone: +56-2-5866032 Fax: +56-2-5866032
Received: March 1, 2010 Revised: June 22, 2010
Accepted: June 29, 2010
Published online: August 16, 2010

Key words: Endoscopic ultrasound; Periampullary region; Ampulla of Vater; Ampuloma; Pancreatic cancer

Peer reviewer: Viktor E Eysselein, MD, Professor of Medicine, Division of Gastroenterology, Harbor-UCLA Medical Center, 1000 W. Carson Street, Box 483, Torrance, CA 90509, United States

Castillo C. Endoscopic ultrasound in the papilla and the periampullary region. *World J Gastrointest Endosc* 2010; 2(8): 278-287 Available from: URL: http://www.wjgnet.com/1948-5190/full/v2/i8/278.htm DOI: http://dx.doi.org/10.4253/wjge.v2.i8.278

Abstract

Endoscopic ultrasound (EUS) provides relevant information when an ampullary or periampullary tumor is suspected. Early detection, T and N staging and Fine Needle Aspiration plus cithologic confirmation, are some of the expected benefits. Exclusion of benign findings like choledocholithiasis or chronic pancreatitis is also important. A correct understanding of the complex ampullary and periampullary anatomy is needed. Knowledge of the individual clinical history and other previous diagnostic images all contribute to a successful EUS examination. Radial and lineal EUS images are uniquely detailed and, at the moment, it seems to be the best way to exclude or confirm malignant or benign findings. We propose a procedural algorithm, including EUS, for suspected ampullary or periampullary tumors. This review summarizes the vast amount of information to be found spread in the literature, and recognizes this small anatomic area as the origin for a clinical entity with proper clinical presentation, proper imaging and proper therapeutic resolutions. The benefits of performing EUS for its study are highlighted.

INTRODUCTION

Tumors of the papilla and the periampullary region are rare and often malignant. Their prognosis is generally better than for other digestive malignancies, due to their different histology and because the clinical manifestations tend to manifest themselves earlier. Detection of small tumors and proper staging are therefore important.

Two particular features make EUS useful in the investigation of ampullary and periampullary pathologies: the first is its capacity to identify small lesions more effectively than other imaging technologies, and the second, the possibility of puncturing these lesions as well as neighboring lymph nodes for cytohistologic confirmation[1]. EUS is considered one of the optimal indications for evaluating the papilla and the periampullary region, although there is no final consensus on this[2,3].

DEFINITIONS AND EPIDEMIOLOGY

Tumors in the periampullary region arise in the papilla of Vater and the two centimeters surrounding it. Histologically, they could originate in the duodenal wall, pancreatic tissue, the wall of the distal bile duct or the structures of the ampullary complex. The papilla of Vater

is formed by the confluence of the pancreatic duct and the bile duct and by the sphincter of Oddi that surrounds it. The sphincter of Oddi also has components for the bile duct and pancreatic duct which are outside the papilla. The primary ampullary tumors originate in the epithelium of the bile duct, the pancreatic duct or the duodenal mucosa[4].

Ampullary and periampullary tumors are infrequent, but have a malignancy rate of more than 90%[4]. Periampullary tumors comprise 5% of malignant gastrointestinal tumors, while ampullary tumors comprise less than 1%[5].

The overall prevalence of resected periampullary cancers show in 50%-70%, cancer of the head of the pancreas, ampullary cancer in 15%-25%, biliary cancer in 10% and duodenal cancer in 10%. The prognosis and survival of patients depends on the tissue of origin and the tumor stage. Survival of these patients is greatest for ampullary and duodenal tumors (4 to 5 years), intermediate for bile duct tumors (3 years) and lowest for pancreatic tumors (less than 1 year)[5-7].

Accurate histological classification is not always possible, even after careful histopathological sample review[5]. All periampullary cancers arise from their respective epithelia and almost all are adenocarcinomas.

Other tumors in the ampullary and periampullary region are basically ampullary villous adenomas or tubulovillous adenomas, hemangiomas, leiomyomas, leiomyofibromas, lipomas, lymphangiomas and neuroendocrine tumors[4,5].

The benign pathology we must rule out upon examining the ampullary and periampullary region is also diverse: choledocholithiasis or microlithiasis, chronic pancreatitis, dysfunction of the sphincter of Oddi and the presence of alterations in biliopancreatic drainage as a periampullary diverticulum, choledochocele or pancreas divisum.

CLINICAL MANIFESTATIONS

The clinical manifestations of tumors in this region can appear early on, due to small neoplasias that obstruct either the bile duct or the pancreatic duct or both, and which may be discovered incidentally or as a result of symptoms.

Symptoms may be similar in patients with ampullary or periampullary pathology and these symptoms can be diverse. They may be insidious, as in silent obstructive jaundice or ferropenic anemia. They may manifest as acute pancreatitis, upper digestive hemorrhage or a duodenal obstruction[8].

The most frequent isolated symptoms of ampullary and periampullary neoplasias are obstructive jaundice and clinical or laboratory cholestasis (50% to 80%)[4,8]. Usually there is no pain; rather, certain unspecific symptoms occur, such as nausea, dyspepsia or vague discomfort in the upper hemiabdomen. Obstruction of the bile duct can manifest as pruritus or appear as cholangitis. In ampullary tumors, the jaundice is usually fluctuant, due to the erosion and intermittent permeability of the bile duct. Upon ulceration, upper digestive hemorrhage may present, causing anemia. Tumor markers may be helpful in some cases (CA19-9).

Benign diseases may present a very characteristic symptomatology, such as a choledocholithiasis. However, it is precisely the complex cases, with superimposed clinical symptoms, with unclear or non-conclusive findings in the laboratory or conventional images, which require the contribution of the endosonography.

The clinical manifestations and their diagnosis may be troublesome: an impacted stone may present clinical symptoms of silent obstruction; an ampullary or periampullary tumor can be the cause of acute pancreatitis. In addition, in some patients, lithiasis coexists in an obstructed bile duct, with symptoms in addition to the symptoms of the obstruction.

The principal incidental finding in abdominal ultrasound (US), computerized tomography (CT) or magnetic resonance imaging (MRI) is bile-duct or pancreatic dilatation or dilatation of both ducts, as indirect signs of obstruction. The cause of the obstruction is not always identifiable in these images.

Another frequent incidental finding is that of ampullary growth during an upper digestive tract endoscopy or during evaluation procedures for at-risk patients. The prevalence of ampullary lesions increases 200 to 300 times in patients with familial adenomatous polyposis and also in patients with hereditary nonpolyposis colorectal cancer. These two genetic conditions require follow-up screening, even among young patients.

There are some endoscopic characteristics that could help in the diagnosis of malignant transformation of an ampullary adenoma: induration or rigidity, the presence of ulcerations, lack of elevation after submucosal injection or the presence of a submucosal mass. Some ampullary tumors could grow without invading the mucosa, thus simulating a submucosal tumor with large and convex papillae.

It is important to know the history and clinical evolution of the patient's symptoms, their laboratory and image data, as well as their personal and family background and associated risk factors, prior to performing EUS. The objective is to understand what is being studied, and the possible procedures derived from the findings. By bearing this background information in mind, we will know what it is we are looking for, and the possibility of finding lesions, especially small ones, will increase. If we are not aware of this information, our findings will be incidental, mistaken or we will only find obvious lesions[9].

ENDOSONOGRAPHY TECHNIQUE

The equipment we use to evaluate the ampullary and periampullary region will depend on what we are looking for and the operator's expertise in radial and/or linear techniques. With both we can obtain images which are

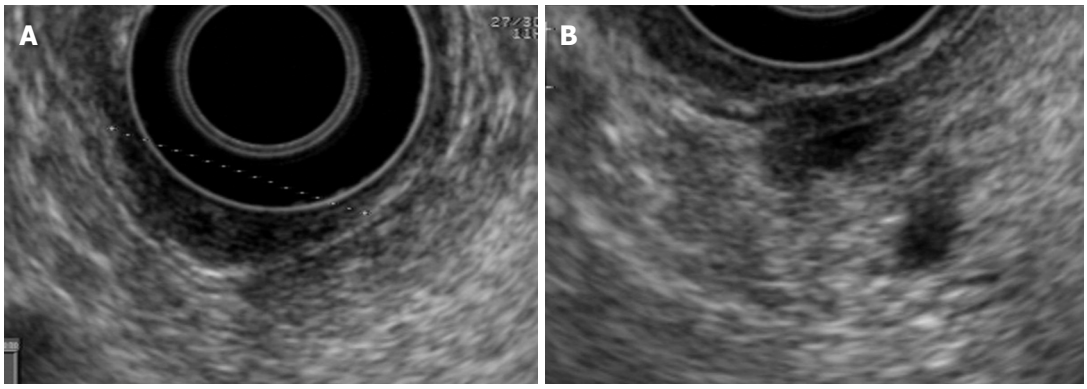

Figure 1 Normal radial view. A: Ampulla; B: Periampullary region.

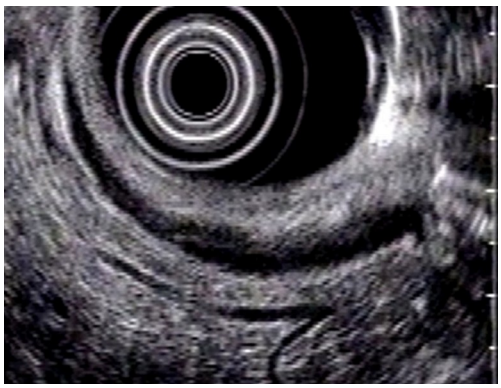

Figure 2 Radial view of normal distal choledochus and wirsung duct.

uniquely precise and detailed, both of the papilla and of the periampullary region and the opening of the bile duct and pancreatic duct.

The recognized advantages of using radial equipment include the possibility of visualizing the extrahepatic biliary tract in one section, and for the linear equipment, the feasibility of complementing the exam with fine needle aspiration (FNA) for cytohistology.

Probes for performing intraductal sonography (IDUS) are not widely used. In expert hands, IDUS is the most precise method for in-depth evaluation of the severity or "T", of the ampullary tumors[10-12]. Because of its lack of ultrasound penetration, it is not used to establish the presence of lymph nodes.

The endosonography exam begins with a conventional evaluation of the patient's pancreas, gallbladder and bile duct. It is useful to know the structure of the pancreatic parenchyma in the body and tail prior to evaluating the head, in order to have a comparison pattern for its echogenicity and thus to identify any focal lesion with greater certainty.

The endoscopic image of the papilla and the periampullary region provides us with a very valuable semiology which could include duodenal compressions or stenosis, the quality of the mucosa, the size and form of the papilla, pore aspect, leakage (or not) of bile, mucous or blood, and the presence or lack of diverticula. Staining and magnification can also help with the diagnosis.

The papilla and the periampullary region are examined from the second portion of the duodenum. Better images are obtained by using duodenal paralysis with Buscopan or Glucagon and by adding water to the duodenum so that the papilla is submerged and free of bubbles. The techniques for radial and linear transducers are similar. Once the papilla is identified by means of endoscopy, we set the small wheel, and free up the large wheel. Our position should be such that as we bring the large wheel toward us, the transducer moves closer to the papilla. We then begin the endoscope withdrawal, maintaining a distance from the papilla so as not to compress it and to be able to identify its various characteristics. Once we are able to see the papilla through endoscopy, we should withdraw the endoscope 1 to 2 cm in order to position the papilla in front of the ultrasound transducer. We can then obtain the best image by making small up-and-down movements with the large wheel and small lateral movements with the shoulders.

The papilla may easily be compressed by the transducer, so it is important to carefully maintain the proper distance in order not to deform it. The lesion may be delicate and could bleed during the exploration.

The vascular and lymph node exam is described further on.

ENDOSONOGRAPHY FINDINGS

The normal papilla is visualized with radial equipment as a hypoechoic, homogeneous thickening, with a crescent moon shape, well demarcated by the duodenal wall. With the linear equipment, the boundaries of the papilla are less clear. However, the opening and the tract of the bile and pancreatic ducts through the papilla can be better observed than with the radial equipment (Figures 1-3).

TNM classification is used for ampullary tumors. For periampullary tumors, the pancreas TNM classification, which is the most frequent etiology, is used. Strictly speaking, the classification that should be used is the one that corresponds to the organ of origin, that is, the extrahepatic bile duct, the pancreas or the duodenum.

The presence of a stent in the bile duct produces acoustic interference that makes it difficult to interpret the images and diminishes the accuracy of the diagnosis both of T and N by approximately 10%[13-15]. Whenever possible, it is preferable to perform EUS prior to the endoscopic bile duct exploration. Occasionally it is reco-

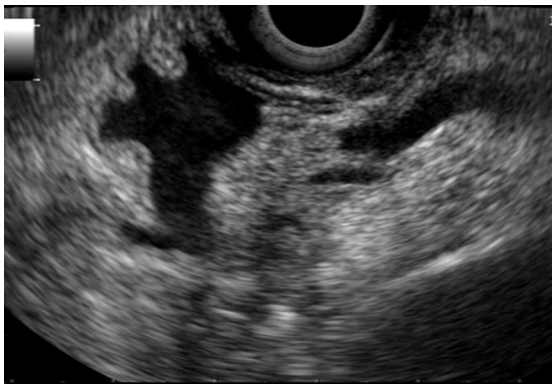

Figure 3 Linear view of normal papilla and periampullary region. The opening of the choledochal and Wirsung ducts is seen through the papilla.

mmended that the endoprosthesis be withdrawn and reimplanted once the EUS exam has been done (Figure 4).

The EUS image in the ampullary tumor varies, depending on whether it is an adenoma or an adenocarcinoma.

The adenoma is a benign tumor that is visualized as a hypoechoic and homogenous thickening of the papilla, without invasion of the duodenal wall. If the view is optimal, we can recognize harmless submucosal and duodenal muscularis propria layers. The adenoma can grow toward the lumen of the bile duct and/or the pancreatic duct. This information is very valuable for planning therapy, as progress greater than 1 cm toward the ducts excludes the possibility of complete endoscopic resection therapy (Figure 5).

It is difficult for the EUS to identify a focal malignancy within an ampullary adenoma, however, invasive carcinoma can be ruled out, and thus an unnecessary endoscopic procedure can be avoided[4].

In an ampullary adenocarcinoma, the echogenicity is generally more hypoechoic and heterogeneous. One must define the relationship of this image to the duodenal wall. This relationship is quite subtle, and it is not always possible to distinguish it precisely with conventional endosonography equipment. If there is effacement of the interface between the ampullary tumor and the duodenal wall, this is a T2 in the TNM classification. Invasion of an ampullary carcinoma in the periampullary pancreatic tissue is generally easier to see. If this invasion is less than 2 cm, it is a T3, and if it is greater than 2 cm or invades other structures, it is a T4[16] (Figures 6A and B).

The staging of ampullary and periampullary tumors includes examination of the portal vein and mesenteric vessels. In order to obtain an adequate vascular evaluation, this must be complemented with images from the stomach, bulb, and 2nd, 3rd and 4th duodenal portions[17,18].

The vascular invasion is defined using the following criteria[19]: (1) Presence of venous collaterals around a pancreatic mass that obliterates the usual anatomic location of a portal vessel; (2) Presence of tumor in the vascular lumen; and (3) Abnormal vascular outline due

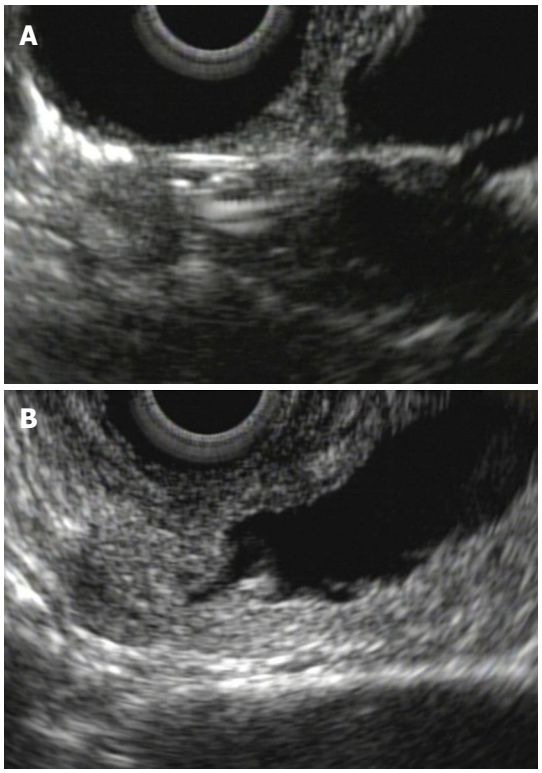

Figure 4 Biliary stent in the papilla, linear view. A: Acoustic interference in periampullary region due to biliary stent; B: The same patient after stent removal.

to compression of a vessel by the mass as well as loss of the hyperechoic interface between the vessel and the parenchyma.

These criteria have been standardized for the venous infiltration and not for the arterial infiltration. Whichever one is present, it has a precision rate of 87.5% to predict vascular invasion[20-22]. This is very well evaluated for the portal vein, superior mesenteric vein and splenic vein. The loss of the interface between the vessel and the tumor does not in itself confirm the invasion if it is not accompanied by an anomaly in the vessel outline. Compromise of the superior mesenteric artery and the celiac trunk can usually be better visualized in multislice CT and MRI angiography[19].

Finally, regional and remote lymph nodes are examined, in order to complete the staging. The courses of lymphatic drainage of the papilla and the periampullary region move toward the chains of the posterior and anterior pancreatoduodenal arteries, the hepatic artery and the superior mesenteric artery. The lymph nodes which are furthest away, the splenic ones or those of the celiac trunk, are considered distant metastases[23].

The malignancy "N" criteria for the finding of lymph nodes are common to other neoplastic processes: (1) size greater than 10 mm; (2) round shape; (3) distinct margins; and (4) hypoechoic echogenicity.

If these 4 criteria are present in a lymph node, there is a positive predictive value of 100% for malignancy. However, only 25% of the infiltrated lymph nodes have

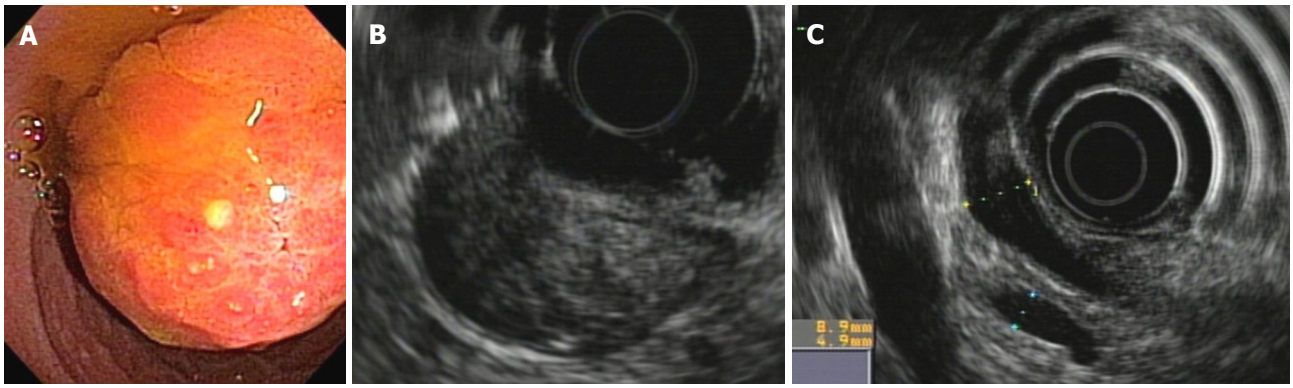

Figure 5 Ampullary tubulo-villous adenoma. A: Endoscopic view; B: Tumor restricted to the duodenal wall as shown in radial endoscopic ultrasound; C: No ductal ingrowth. Endoscopic ampullectomy was indicated.

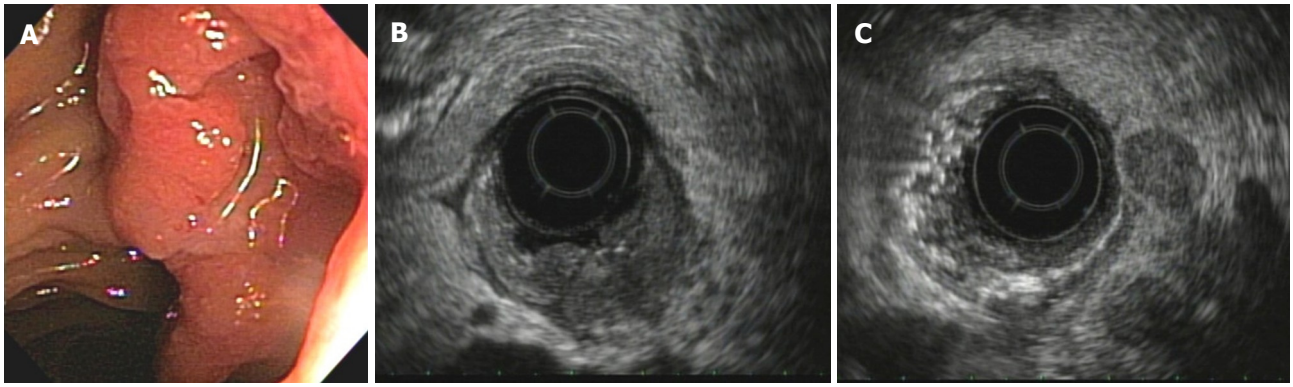

Figure 6 Ampullary carcinoma. A: Ulcerated ampullary tumor revealed by endoscopy; B: Duodenal wall disruption and pancreatic invasion in radial endoscopic ultrasound of the same tumor; C: Tumoral lymph nodes (same patient). Palliative therapy was indicated.

these 4 characteristics. The presence of only one of these findings can predict neoplastic infiltration. Up to two of these criteria may be found in normal lymph nodes. The FNA enables this to be confirmed[24] (Figure 6C).

STUDY THROUGH IMAGES AND PROCEDURAL ALGORITHM

We have a variety of images and procedures that can be used in evaluating an ampullary or periampullary tumor: US, CT, Magnetic Resonance Cholangiopancreatography (MRCP), Positron Emission Tomography (PET), EUS, IDUS, Endoscopic Retrograde Cholangiopancreatography (ERCP), Percutaneous Transhepatic Cholangiography (THC), laparoscopy or exploratory laparoscopy. Each method has an advantage over the others and all of them are constantly undergoing development. Each one requires special skills in order to acquire and interpret the images, or to carry out the procedures[25]. The results of each exam in detection, and accurate TNM staging of ampullary and periampullary lesions depends on the technology and the operator's skills, which makes it difficult to compare studies[26,27]. Staging accuracy is highest for IDUS, followed by EUS, MRI, CT and finally abdominal US[10]. Each institution should adapt the study algorithm, depending on the availability, access, reliability, cost-benefit analysis and patient invasion[28].

Abdominal US is widely used and can evaluate the intra- and extrahepatic bile duct and the presence of lithiasis and vesicular pathology. It is useful for initiating the evaluation of patients with obstructive jaundice. It is not adequate for examining the distal bile duct, the papilla or the head of the pancreas, due to frequent interposition of intestinal air.

CT is an exam that is widely available and which provides a very complete representation of the pathology of the pancreas. It is valuable in detecting neoplasias and also distant metastasis, above all in relation to CT/PET. Vascular compromise, especially arterial, is well defined by the multisection spiral CT[29,30]. MRI enables the ruling out of the presence of choledocholithiasis. It provides guidance toward the etiology of periampullary tumors, with detection of lesions or with indirect signs in the MRCP. The compromise of the venous system is also adequately defined by MRI[31,32].

ERCP is not used for diagnosis, but to decompress the bile duct through an endoprosthesis in the event of cholangitis or in palliative therapy. It is also indicated for taking a biopsy directly from the papilla or the ducts[33]. THC is indicated for complementing therapeutic procedures, often in combination with endoscopic drainage

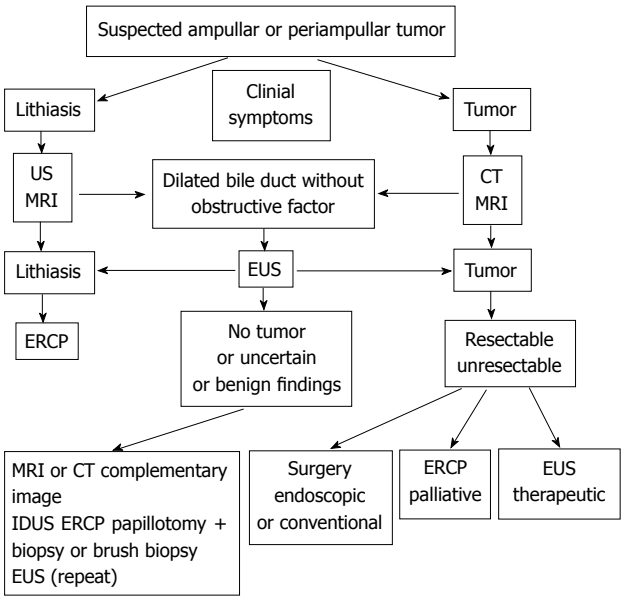

Figure 7 Procedural algorithm for suspected ampullary or periampullary tumor. EUS: endoscopic ultrasound; MRI: magnetic resonance imaging; ERCP: endoscopic retrograde cholangiopancreatography; CT: computerized tomography; US: ultrasound; IDUS: intraductal sonography.

techniques, ERCP or therapeutic enteroscopy. Bile duct drainage guided by EUS from the duodenum or the stomach is an endoscopic procedure that is increasingly used as an alternative to percutaneous procedures[34,35].

It would seem reasonable to combine the technologies to arrive at a better diagnosis.

In Figure 7, an algorithm for a suspected ampullary or periampullary tumor is proposed. This procedural algorithm summarizes the most common clinical situations.

The most frequent cause of suspicion is obstructive jaundice, as a clinical or laboratory finding. The other causes correspond to the discovery of bile duct dilatation in some images, with or without dilatation of the pancreatic duct, and also the endoscopic discovery of an ampullary growth.

Patients with suspected lithiasic etiology are usually studied first with an abdominal US and/or an MRI. In those where there is a suspected tumor etiology, often the study will begin with a CT and/or an MRI.

EUS plays an important role (Figure 8) in those situations in which the findings from conventional images, US, CT or MRI (and even ERCP) are not concordant with the clinical symptoms, or are not sufficient to confirm or rule out the presence of a tumor[36].

EUS in tumoral pathology: The principal role of EUS in a suspected periampullary tumor is detection, and if there is indeed a tumor, in the staging. In the ampullary tumor, the diagnosis is done through endoscopy, and EUS is indicated for staging and to evaluate its endoscopic or surgical resectability[4,37]. The depth of the tumor "T" compromise, the presence of lymph nodes "N" and vascular compromise is evaluated. The FNA of

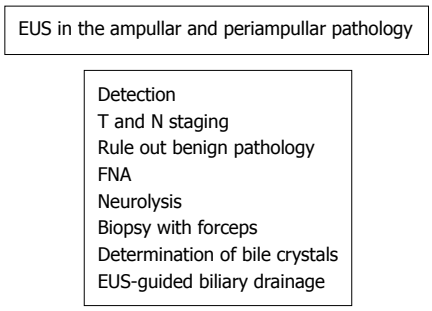

Figure 8 Role of the Endosonography in the ampullary and periampullary pathology. EUS: endoscopic ultrasoun; FNA: fine needle aspiration.

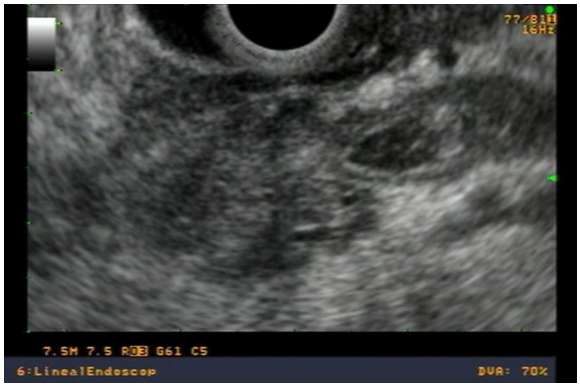

Figure 9 Linear view of periampullary carcinoma obstructing biliary duct.

the papilla, the periampullary region, or regional lymph nodes for cytology, is occasionally required to confirm the findings or to plan a neoadjuvant or palliative therapy (Figures 9 and 10).

The indication for endoscopic ampullectomy with curative option requires that the EUS exclude invasion of the duodenal muscularis propria layer and that there is also no tumor growth beyond 1 cm inside the bile duct or pancreatic duct. The outcome of the final procedure depends on the histological evaluation of the tissue sample: free lateral and in-depth margins and the absence of lymphovascular compromise are required. The histology should correspond to benign adenomas, in situ tumors (Tis) or early well or moderately differentiated type cancer T1N0M0.

If one of these requisites is not fulfilled, it is considered an inadequate endoscopic resection and surgery should then be considered, with or without adjuvant therapy[38,39].

Surgical resectability of an ampullary or periampullary tumor is a topic of debate on which there is no consensus. The most important prognosis factors are the tissue of origin and the presence of compromised lymph nodes. Vascular invasion is not an unresectability factor for all surgical teams; however, it has been demonstrated that survival does not improve with more radical surgery[40].

Correct staging will permit comparative studies that help to ensure rational procedures. The combination of

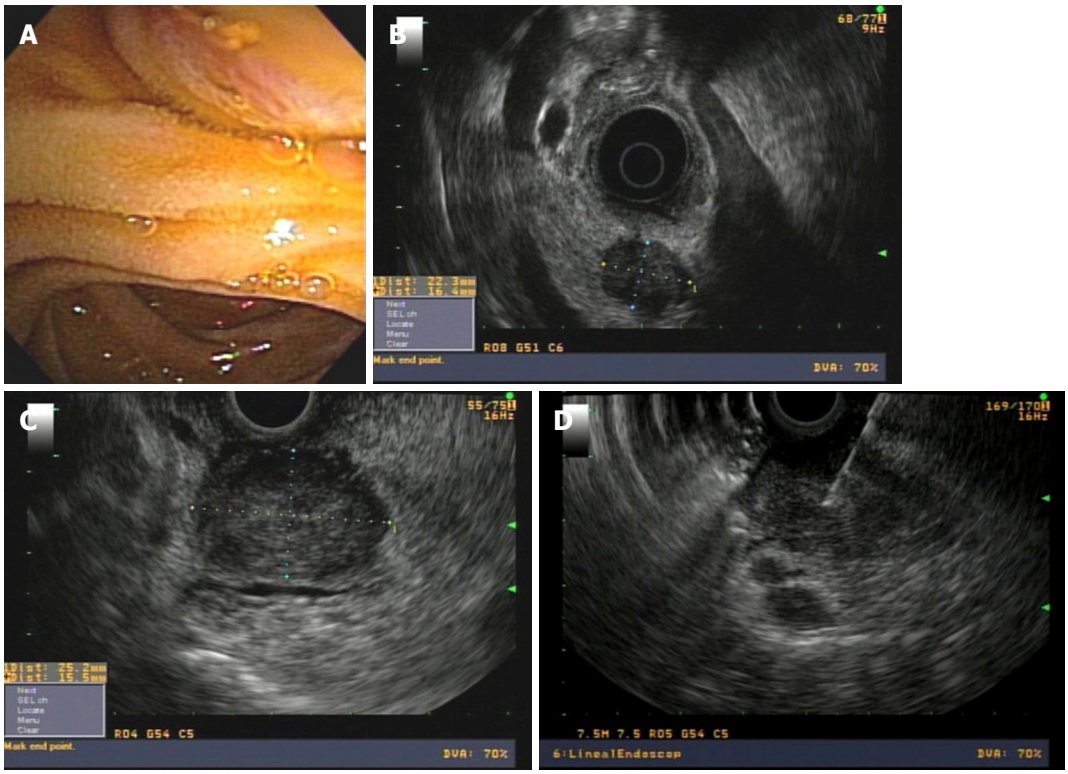

Figure 10 Periampullary tumor. A: Normal papilla in endoscopic view; B: Radial endoscopic ultrasound (EUS) finding of periampullary tumor; C: Linear EUS view; D: Fine needle aspiration puncture.

EUS and CT currently allow for improved evaluation of local and distant staging[19].

In cases of advanced tumor pathology with a palliative therapy indication, the EUS can be used as a guide to obtain access to the bile duct from the duodenum, or to the intrahepatic bile duct from the stomach. In expert hands, it is not very invasive and yields good results. However, there are only case series reports, and the most frequent complication is bile leakage and migration of the prosthesis. It should be reserved for highly specialized centers that manage biliopancreatic patients, with the requirement that access failed or was not possible through ERCP[34,35].

Another objective for the EUS is monitoring the response to neoadjuvant radiochemotherapy, where it can have a positive influence through improved outcomes for patients with locally invasive pancreatic adenocarcinoma[19].

In the case of pain management, neurolysis of the celiac plexus can be performed through EUS[41]. The efficacy and risk of hypotension, increased pain and diarrhea are all transient and similar to those of other access routes. The risk of neurological damage diminishes in procedures that address the celiac plexus through the anterior route and severe complications have not been reported for EUS[42].

EUS in benign pathology: EUS provides endoscopic information, with the visualization of the papilla and its surroundings, and the eventual performance of a biopsy with forceps. A half-open pore can be indicative of the migration of a stone. The intradiverticular location of a papilla can be the only cause that explains a bile duct dilatation.

The presence of lithiasis will guide the procedure toward a therapeutic ERCP. It is a simple diagnosis for EUS with a better outcome than MRI when the bile duct is not dilated, when the stones are smaller than 3 mm, or when the stones are impacted[43] (Figures 11 and 12). We should bear in mind the association of lithiasis in obstructed bile ducts, which can be as high as 25%.

EUS is of great value in differential diagnosis with other benign pathologies in addition to lithiasis, such as chronic pancreatitis, the presence of a periampullary diverticulum, choledochocele or pancreas divisum.

In the diagnosis of chronic pancreatitis, EUS together with MRI achieves an accuracy close to 100%. FNA is useful, in these cases, for differentiating neoplasias from inflammatory pseudotumors[44,45].

Perhaps the most challenging aspect of evaluation by endosonography is confirming that there is no obstructive tumor lesion or that there are only benign findings (Figure 13). In these cases it is essential to look for agreement between the clinical symptoms, the radiological images, the laboratory and endoscopic findings and the EUS[46].

We already emphasized the importance of having access to a complete clinical history to guide our search. The value we give to our findings is related to our own clinical assessment.

In the event that suspicion of the presence of a neoplasia persists, there are different actions we can take, which will depend on the clinical suspicion: repeat the EUS with another, more experienced operator[47], repeat or perform another complementary image: MRI or CT, perform an ERCP with a papillotomy and biopsy or brush biopsy for cytology, depending on the morphology of the papilla. Another option in cases where there is doubt is to repeat the EUS in 2 mo.

We should keep in mind the multicenter study by

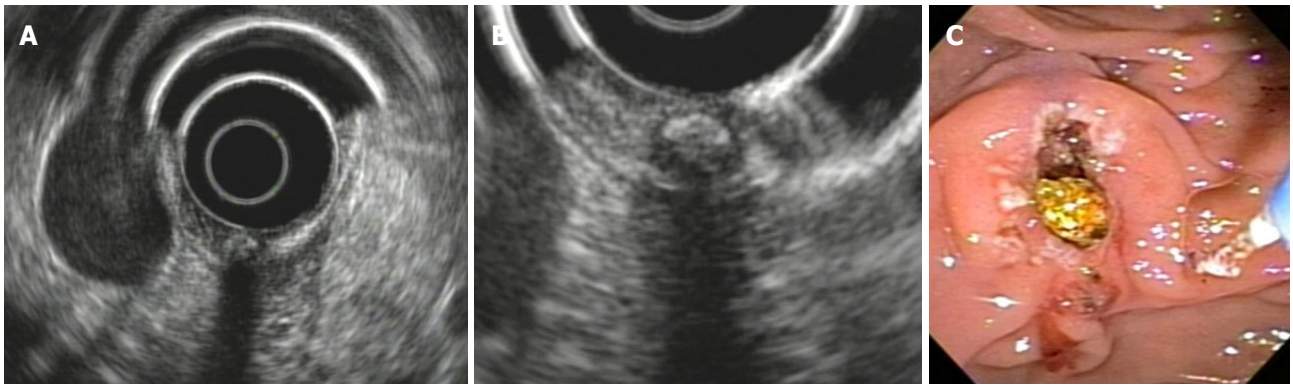

Figure 11 Endoscopic ultrasound finding in acute pancreatitis in a patient with normal magnetic resonance imaging. A: Impacted 4 mm stone in the ampulla with radial endoscopic ultrasound; B: Close-up; C: Precut during Endoscopic retrograde cholangiopancreatography in the same patient.

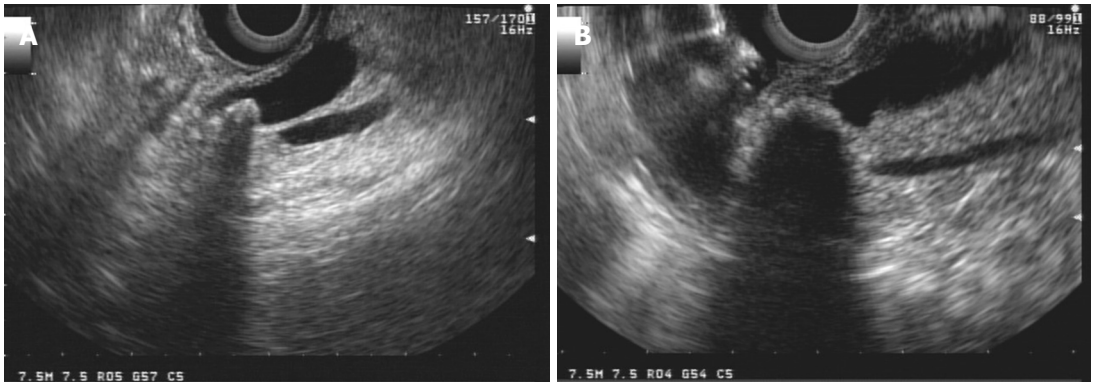

Figure 12 Lineal imaging of distal choledochal lithiasis. A: Stone and acoustic shadow is clearly seen; B: Bulging of the papilla due to impacted stone.

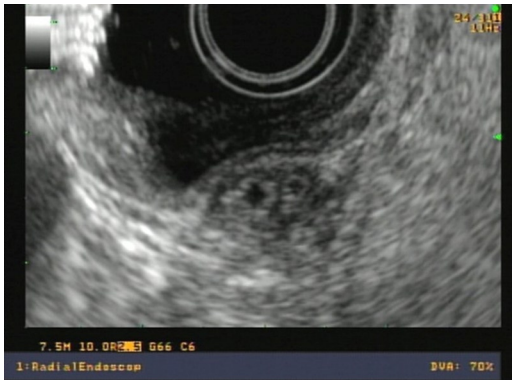

Figure 13 Transverse view of the ampulla with radial transducer in a patient with suspected sphincter of oddi dysfunction. Oddi muscle can be seen.

Bhutani *et al*[48], which sets forth that a recent acute pancreatitis (prior to 4 wk), changes in a chronic pancreatitis, a prominent ventral/dorsal fissure, and the diffuse infiltrative carcinoma of the pancreas are all conditions that can lead endosonography experts to err in their interpretation and fail to detect a neoplasia through EUS. Repetition of the EUS within two months enabled them to identify the lesions that had not previously been seen[48].

Recourse to surgical exploration is always present and is indicated in selected circumstances.

CONCLUSION

Ampullary and periampullary pathology is rich and diverse, more frequently tumoral and among these, malignant. Although there is not a higher prevalence, its clinical presentation tends to be early, enabling the initiation of curative therapies. This requires a previous study that addresses questions of resectability and the best way to achieve it.

Clinical presentation and radiological images are shared for ampullary and periampullary pathology, as are also surgical treatment and palliative treatment. The greatest differences are in the endoscopic therapy which is possible in some ampullary tumors, and in the long-term prognosis. The prognosis is better for duodenal or ampullary tumors than for those of bile duct or pancreatic origin.

Several images contribute to diagnosis and evaluation, in order to determine the most appropriate therapeutic procedure.

We present a study algorithm that includes EUS as an important diagnostic imaging tool, supported by FNA and also as a less invasive therapeutic alternative for pain management and bile duct drainage.

The best available study and treatment options should be offered to patients with pathology of the papilla or periampullary region, taking into consideration each individual situation and also that of each institution.

REFERENCES

1 **Gan SI**, Rajan E, Adler DG, Baron TH, Anderson MA, Cash BD, Davila RE, Dominitz JA, Harrison ME 3rd, Ikenberry SO, Lichtenstein D, Qureshi W, Shen B, Zuckerman M, Fanelli RD, Lee KK, Van Guilder T. Role of EUS. *Gastrointest Endosc* 2007; **66**: 425-434

2 **Adler DG**, Qureshi W, Davila R, Gan SI, Lichtenstein D, Rajan E, Shen B, Zuckerman MJ, Fanelli RD, Van Guilder T, Baron TH. The role of endoscopy in ampullary and duodenal adenomas. *Gastrointest Endosc* 2006; **64**: 849-854

3 **Trede M**, Richter A, Wendl K. Personal observations, opinions, and approaches to cancer of the pancreas and the periampullary area. *Surg Clin North Am* 2001; **81**: 595-610

4 **Albores-Saavedra J**, Schwartz AM, Batich K, Henson DE. Cancers of the ampulla of vater: demographics, morphology, and survival based on 5,625 cases from the SEER program. *J Surg Oncol* 2009; **100**: 598

5 **Sarmiento JM**, Nagomey DM, Sarr MG, Farnell MB. Periampullary cancers: are there differences? *Surg Clin North Am* 2001; **81**: 543-555

6 **O'Connell JB**, Maggard MA, Manunga J Jr, Tomlinson JS, Reber HA, Ko CY, Hines OJ. Survival after resection of ampullary carcinoma: a national population-based study. *Ann Surg Oncol* 2008; **15**: 1820-1817

7 **Burgos L**. Cholangiocarcinoma. *Rev Med Chil* 2008; **136**: 240-248

8 **Binmoeller**, KF, Boaventura, S, Ramsperger, K, Soehendra, N. Endoscopic snare excision of benign adenomas of the papilla of Vater. *Gastrointest Endosc* 1993; **39**: 127

9 **Rösch T**, Dittler H, Strobel K. Endoscopic Ultrasound Criteria for Vascular Invasion in the Staging of Cancer of the Head of the Pancreas: a Blind Reevaluation of Videotapes. *Gastrointest Endosc* 2000; **52**: 469-477

10 **DeWitt J**. EUS in Pancreatic Neoplasms. In Hawes R, Fockens P, Editors. Endosonography. Philadelphia: Saunders Elsevier; 2006

11 **Vazquez-Sequeiros E**, Baron TH, Clain JE, Gostout CJ, Norton ID, Petersen BT, Levy MJ, Jondal ML, Wiersema MJ. Evaluation of indeterminate bile duct strictures by intraductal US. *Gastrointest Endosc* 2002; **56**: 372

12 **Ito K**, Fujita N, Noda Y, Kobayashi G, Horaguchi J, Takasawa O, Obana T. Preoperative evaluation of ampullary neoplasm with EUS and transpapillary intraductal US: a prospective and histopathologically controlled study. *Gastrointest Endosc* 2007; **66**: 740-747

13 **Fusaroli P**, Manta R, Fedeli P, Maltoni S, Grillo A, Giovannini E, Bucchi L, Caletti G. The influence of endoscopic biliary stents on the accuracy of endoscopic ultrasound for pancreatic head cancer staging. *Endoscopy* 2007; **39**: 813-817

14 **Chen CH**, Tseng LJ, Yang CC, Yeh YH. Preoperative evaluation of periampullary tumors by endoscopic sonography, transabdominal sonography, and computed tomography. *J Clin Ultrasound* 2001; **29**: 313-321

15 **Cannon ME**, Carpenter SL, Elta GH, Nostrant TT, Kochman ML, Ginsberg GG, Stotland B, Rosato EF, Morris JB, Eckhauser F, Scheiman JM. EUS compared with CT, magnetic resonance imaging, and angiography and the influence of biliary stenting on staging accuracy of ampullary neoplasms. *Gastrointest Endosc* 1999; **50**: 27-33

16 International Union Against Cancer's TNM. In Classification of Malignant Tumours. Sixth edition. Wiley-Liss, 2002, American Joint Committee on Cancer. AJCC Cancer Staging Manual. Sixth edition. Springer; 2002

17 **Brugge WR**. Pancreatic cancer staging. Endoscopic ultrasonography criteria for vascular invasion. *Gastrointest Endosc Clin N Am* 1995; **5**: 741-753

18 **Fritscher-Ravens A**, Knoefel WT, Krause C, Swain CP, Brandt L, Patel K. Three-dimensional linear endoscopic ultrasound-feasibility of a novel technique applied for the detection of vessel involvement of pancreatic masses. *Am J Gastroenterol* 2005; **100**: 1296-1302

19 **Snady H**. EUS criteria for vascular invasion: analyzing the meta-analysis. *Gastrointest Endosc* 2007; **65**: 798-807

20 **Buscail L**, Pagès P, Berthélemy P, Fourtanier G, Frexinos J, Escourrou J. Role of EUS in the management of pancreatic and ampullary carcinoma: a prospective study assessing resectability and prognosis. *Gastrointest Endosc* 1999; **50**: 34-40

21 **Puli SR**, Singh S, Hagedorn CH, Reddy J, Olyaee M. Diagnostic accuracy of EUS for vascular invasion in pancreatic and periampullary cancers: a meta-analysis and systematic review. *Gastrointest Endosc* 2007; **65**: 788-797

22 **Brugge WR**, Lee MJ, Kelsey PB, Schapiro RH, Warshaw AL. The use of EUS to diagnose malignant portal venous system invasion by pancreatic cancer. *Gastrointest Endosc* 1996; **43**: 561-567

23 **Hurtuk MG**, Hughes C, Shoup M, Aranha GV. Does lymph node ratio impact survival in resected periampullary malignancies? *Am J Surg* 2009; **197**: 348-352

24 **Catalano MF**, Sivak MV Jr, Rice T, Gragg LA, Van Dam J. Endosonographic features predictive of lymph node metastasis. *Gastrointest Endosc* 1994; **40**: 442-446

25 **Maluf-Filho F**, Sakai P, Cunha JE, Garrido T, Rocha M, Machado MC, Ishioka S. Radial endoscopic ultrasound and spiral computed tomography in the diagnosis and staging of periampullary tumors. *Pancreatology* 2004; **4**: 122-128

26 **Ho JM**, Eysselein VE, Stabile BE. The value of endoscopic ultrasonography in predicting resectability and margins of resection for periampullary tumors. *Am Surg* 2008; **74**: 1026-1029

27 **Chen CH**, Yang CC, Yeh YH, Chou DA, Nien CK. Reappraisal of endosonography of ampullary tumors: correlation with transabdominal sonography, CT, and MRI. *J Clin Ultrasound* 2009; **37**: 18-25

28 **Schwarz M**, Pauls S, Sokiranski R, Brambs HJ, Glasbrenner B, Adler G, Diederichs CG, Reske SN, Möller P, Beger HG. Is a preoperative multidiagnostic approach to predict surgical resectability of periampullary tumors still effective? *Am J Surg* 2001; **182**: 243-249

29 **Dewitt J**, Devereaux BM, Lehman GA, Sherman S, Imperiale TF. Comparison of endoscopic ultrasound and computed tomography for the preoperative evaluation of pancreatic cancer: a systematic review. *Clin Gastroenterol Hepatol* 2006; **4**: 717-725; quiz 664

30 **Mansfield SD**, Scott J, Oppong K, Richardson DL, Sen G, Jaques BC, Manas DM, Charnley RM. Comparison of multislice computed tomography and endoscopic ultrasonography with operative and histological findings in suspected pancreatic and periampullary malignancy. *Br J Surg* 2008; **95**: 1512-1520

31 **Kan SJ**, Suyama M, Kubokawa Y. Early Detection of Extrahepatic Bile-Duct Carcinomas in the Non Icteric Stage by Using MRCP Followed by EUS. *Gastrointest Endosc* 2009; **70**: 29-36

32 **Kim JH**, Kim MJ, Chung JJ, Lee WJ, Yoo HS, Lee JT. Differential diagnosis of periampullary carcinomas at MR imaging. *Radiographics* 2002; **22**: 1335-1352

33 **Escalante-Glorsky S**, Raijman I, Angulo P. Endoscopic Methods for the Diagnosis of Pancreaticobiliary Neoplasms. 2008, in press

34 **Savides TJ**, Varadarajulu S, Palazzo L. EUS 2008 Working Group document: evaluation of EUS-guided hepaticogastrostomy. *Gastrointest Endosc* 2009; **69**: S3-S7

35 **Itoi T**, Yamao K. EUS 2008 Working Group document: evaluation of EUS-guided choledochoduodenostomy (with video). *Gastrointest Endosc* 2009; **69**: S8-S12

36 **Will U**, Bosseckert H, Meyer F. Correlation of endoscopic ultrasonography (EUS) for differential diagnostics between inflammatory and neoplastic lesions of the papilla of Vater and the peripapillary region with results of histologic investigation. *Ultraschall Med* 2008; **29**: 275-280

37 **Gress FG**, Hawes RH, Savides TJ, Ikenberry SO, Cummings O, Kopecky K, Sherman S, Wiersema M, Lehman GA. Role of EUS in the preoperative staging of pancreatic cancer: a large single-center experience. *Gastrointest Endosc* 1999; **50**: 786

38 **Seewald S**, Omar S, Soehendra N. Endoscopic resection of tumors of the ampulla of Vater: how far up and how deep down can we go? *Gastrointest Endosc* 2006; **63**: 789-791

39 **Baillie J**. Endoscopic ampullectomy. *Am J Gastroenterol* 2005; **100**: 2379-2381

40 **Yeo CJ**, Cameron JL, Lillemoe KD, Sohn TA, Campbell KA, Sauter PK, Coleman J, Abrams RA, Hruban RH. Pancreaticoduodenectomy with or without distal gastrectomy and extended retroperitoneal lymphadenectomy for periampullary adenocarcinoma, part 2: randomized controlled trial evaluating survival, morbidity, and mortality. *Ann Surg* 2002; **236**: 355-366;. discussion 366-368

41 **Brugge WR**, Van Dam J. Pancreatic and biliary endoscopy. *N Engl J Med* 1999; **341**: 1808-1816

42 **Levy MJ**, Wiersema MJ. EUS-guided celiac plexus neurolysis and celiac plexus block. *Gastrointest Endosc* 2003; **57**: 923-930

43 **Kondo S**, Isayama H, Akahane M, Toda N, Sasahira N, Nakai Y, Yamamoto N, Hirano K, Komatsu Y, Tada M, Yoshida H, Kawabe T, Ohtomo K, Omata M. Detection of common bile duct stones: comparison between endoscopic ultrasonography, magnetic resonance cholangiography, and helical-computed-tomographic cholangiography. *Eur J Radiol* 2005; **54**: 271-275

44 **Pungpapong S**, Wallace MB, Woodward TA, Noh KW, Raimondo M. Accuracy of endoscopic ultrasonography and magnetic resonance cholangiopancreatography for the diagnosis of chronic pancreatitis: a prospective comparison study. *J Clin Gastroenterol* 2007; **41**: 88-93

45 **Pungpapong S**, Noh KW, Woodward TA, Wallace MB, Al-Haddad M, Raimondo M. Endoscopic ultrasound and IL-8 in pancreatic juice to diagnose chronic pancreatitis. *Pancreatology* 2007; **7**: 491-496

46 **Malik S**, Kaushik N, Khalid A, Bauer K, Brody D, Slivka A, McGrath K. EUS yield in evaluating biliary dilatation in patients with normal serum liver enzymes. *Dig Dis Sci* 2007; **52**: 508-512

47 **DeWitt J**, McGreevy K, Sherman S, LeBlanc J. Utility of a repeated EUS at a tertiary-referral center. *Gastrointest Endosc* 2008; **67**: 610-619

48 **Bhutani MS**, Gress FG, Giovannini M, Erickson RA, Catalano MF, Chak A, Deprez PH, Faigel DO, Nguyen CC. The No Endosonographic Detection of Tumor (NEST) Study: a case series of pancreatic cancers missed on endoscopic ultrasonography. *Endoscopy* 2004; **36**: 385-389

S- Editor Zhang HN **L- Editor** Herholdt A **E- Editor** Liu N

World Journal of Gastrointestinal Endoscopy

Online Submissions: http://www.wjgnet.com/1948-5190office
wjge@wjgnet.com
doi:10.4253/wjge.v2.i8.288

World J Gastrointest Endosc 2010 August 16; 2(8): 288-292
ISSN 1948-5190 (online)

BRIEF ARTICLES

Observation of the esophagus, pharynx and lingual root by gastrointestinal endoscopy with a percutaneous retrograde approach

Michitaka Honda, Yoshio Hori, Yoshiki Shionoya, Akira Nakada, Toshihiko Sato, Takeshi Kobayashi, Hidenori Shimada, Naoki Kida, Tatsuo Nakamura

Michitaka Honda, Yoshio Hori, Yoshiki Shionoya, Akira Nakada, Toshihiko Sato, Takeshi Kobayashi, Hidenori Shimada, Naoki Kida, Tatsuo Nakamura, Department of Bioartifical Organs, Institute for Frontier Medical Science, Kyoto University, 53 Kawahara Cho, Sakyo-ku, Kyoto 606-8507, Japan
Author contributions: Honda M conceived the experiments; Honda M, Nakamura T and Shionoya Y performed the experiments and together analyzed the data with Hori Y, Sato T and Kobayashi T; Kida N and Shimada H and Nakada A provide technical support and valuable help; and all the authors discussed the results and commented on the manuscript.
Correspondence to: Tatsuo Nakamura, MD, Department of Bioartifical Organs, Institute for Frontier Medical Science, Kyoto University, 53 Kawahara Cho, Sakyo-ku, Kyoto 606-8507, Japan. nakamura@frontier.kyoto-u.ac.jp
Telephone: +81-75-7514149 Fax: +81-75-7514844
Received: April 6, 2010 Revised: June 24, 2010
Accepted: July 1, 2010
Published online: August 16, 2010

Abstract

AIM: To evaluate the efficacy of retrograde observation of the esophagus, pharynx, larynx and lingual root.

METHODS: With the beagle dog under anesthesia, the anterior wall of the stomach was fixed on the abdominal wall in a similar way to percutaneous endoscopic gastrostomy. The gastrointestinal scope was inserted *via* a 12 mm laparoscopic port for subsequent retrograde observation from stomach to the oral cavity.

RESULTS: With this technique, direct observation of gastric cardia was possible without restriction. The cervical esophagus was dilated well, also allowing clear observation of the hypopharyngo-esophageal junction. If the tongue was manually pulled out forward, observation of the lingual root was possible.

CONCLUSION: This procedure is easy and effective for pre-treatment evaluation of the feasibility of endoscopic resection in cases of superficial carcinoma of head and neck.

Key words: Mesopharynx; Lingual root; Percutaneous endoscopic gastrostomy; Gastrointestinal endoscopy; Retrograde observation

Peer reviewers: Shinji Tanaka, MD, PhD, Professor, Department of Endoscopy, Hiroshima University Hospital, 1-2-3 Kasumi, Minami-ku, Hiroshima 734-8551, Japan; Alfredo José Lucendo, MD, PhD, Department of Gastroenterology, Hospital General de Tomelloso, Vereda de Socuéllamos, s/n, Tomelloso 13700, Spain

Honda M, Hori Y, Shionoya Y, Nakada A, Sato T, Kobayashi T, Shimada H, Kida N, Nakamura T. Observation of the esophagus, pharynx and lingual root by gastrointestinal endoscopy with a percutaneous retrograde approach. *World J Gastrointest Endosc* 2010; 2(8): 288-292 Available from: URL: http://www.wjgnet.com/1948-5190/full/v2/i8/288.htm DOI: http://dx.doi.org/10.4253/wjge.v2.i8.288

INTRODUCTION

Recent advances in the devices for gastrointestinal endoscopy have enabled detailed observation of the oral cavity, pharynx and larynx[1,2]. Screening by means of narrow band imaging especially can detect minute changes in the vascular structure on the mucosal surface, making it easier to diagnose superficial tumors of the pharynx and larynx difficult to find in the past[3-5]. Since detection of early lesions has become possible, attempts have been made to apply endoscopic mucosal resection, previously

used for treatment of gastric early stage carcinomas or polyps, to the pharynx and larynx. This technique is promising as a means of function-preserving treatment of pharynx and larynx lesions[6]. However, the orally inserted gastrointestinal endoscope has a limitation in the scope of visual field and observation of the anterior wall of mesopharynx and the lingual root is particularly difficult with this technique[6,7].

We recently conducted an experiment using dogs in which a gastrointestinal endoscope was inserted percutaneously into the stomach followed by retrograde observation of the stomach, esophagus, pharynx, larynx, lingual root and tongue. This paper will discuss and report on the procedure for simple insertion of a gastrointestinal endoscope and retrograde observation with the thus inserted endoscope.

MATERIALS AND METHOD

Device used

The upper gastrointestinal endoscope used was the Olympus Endoscopic System (GIF-XQ240; Olympus Optical Co, Ltd., Tokyo Japan). It was used in combination with a gastric wall lifting and fixing tool (Ideal Lifting, Olympus Optical Co, Ltd., Tokyo Japan) for percutaneous endoscopic gastrostomy (PEG) and with a laparoscopic camera port 12 mm (Ethicon Endo-surgery, Inc., Cincinnati, OH, USA).

Operative procedure

One beagle dog (male, 15 mo old, weighing 9.5 kg) was used for this experiment. The dog was preoperatively anesthetized with an intramuscular injection of atropine sulfate 0.05 mg/kg, ketamine hydrochloride 15 mg/kg and xylazine hydrochloride 3 mg/kg. First, the gastrointestinal endoscope was orally inserted followed by sufficient aeration within the stomach. In the similar way to PEG, the anterior wall of the gastric body was fixed on the abdominal wall at 2 points. A 1.5 cm skin incision was made between the two fixed points followed by incision of subcutaneous tissue and the gastric wall immediately below it to reach into the stomach. A 12 mm laparoscopic port was inserted and the endoscope was inserted *via* this port for subsequent retrograde observation of the stomach, esophagus, pharynx, larynx and tongue (Figure 1). The usefulness and safety of endoscopic observation with this approach were evaluated.

The protocol for this study was prepared in accordance with the "Guide for the Care and Use of Laboratory Animals" published by the National Institute of Health (NIH Publication No. 85-23, revised 1985) and was approved by the Kyoto University Animal Experiment Committee.

RESULTS

The steps of observation with this technique and image findings are presented. With conventional endoscopic techniques, the endoscope is usually inverted at the gastric cardia. With our technique, direct observation of this area was possible without restriction (Figure 2A). The endoscope was then advanced in a retrograde fashion beyond the esophagogastric junction into the esophagus and reached the cervical esophagus. The cervical esophagus could be dilated well, also allowing clear observation of the hypopharyngoesophageal junction (Figure 2B). The endoscope then entered the pharynx, enabling observation of the hypopharynx and the laryngeal surface of the epiglottis (Figure 2C). If the endoscope was further advanced, it reached epipharynx and nasal cavity (Figure 2D). If the endoscope was advanced towards the oral cavity, observation of the soft palate was possible. If the tongue was manually pulled out forward, observation of the lingual root was possible (Figure 2E and F). However, observation of the epiglottic vallecula was difficult because the epiglottis served as an obstacle. For comparison, the images of the lingual root observed by the per-oral approach are shown in Figure 3. As it was a dead angle of the endoscope, the lingual root is an unclear image.

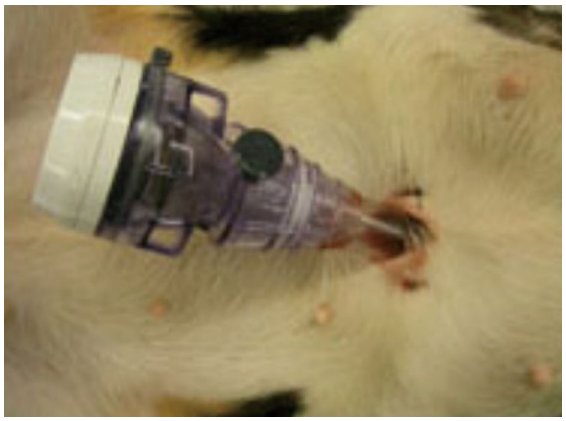

Figure 1 Insertion of laparoscopic port 12 mm (Ethicon Endo-surgery, Inc., Cincinnati, OH, USA). The sutures on both sides serve as a support for lifting of the gastric wall with Ideal Lifting (Olympus Optical Co, Ltd., Tokyo Japan).

The time taken from completion of anesthesia to the start of observation was about 30 min. At the end of observation, the camera port was removed and the wounds in the gastric and abdominal wall were closed by suturing. Blood loss was small, requiring no infusion or additional anesthetic. On the day following surgery, oral ingestion of diet was resumed. The dog is currently in good condition, 2 mo after surgery.

DISCUSSION

As described above, we devised a technique of percutaneous insertion of an endoscope into the stomach for subsequent retrograde observation. This technique allowed easy observation of the lingual root and epipharynx which are the dead angle during ordinary anterograde observation via the oral route. Furthermore, the gastric cardia, esophagogastric junction and the

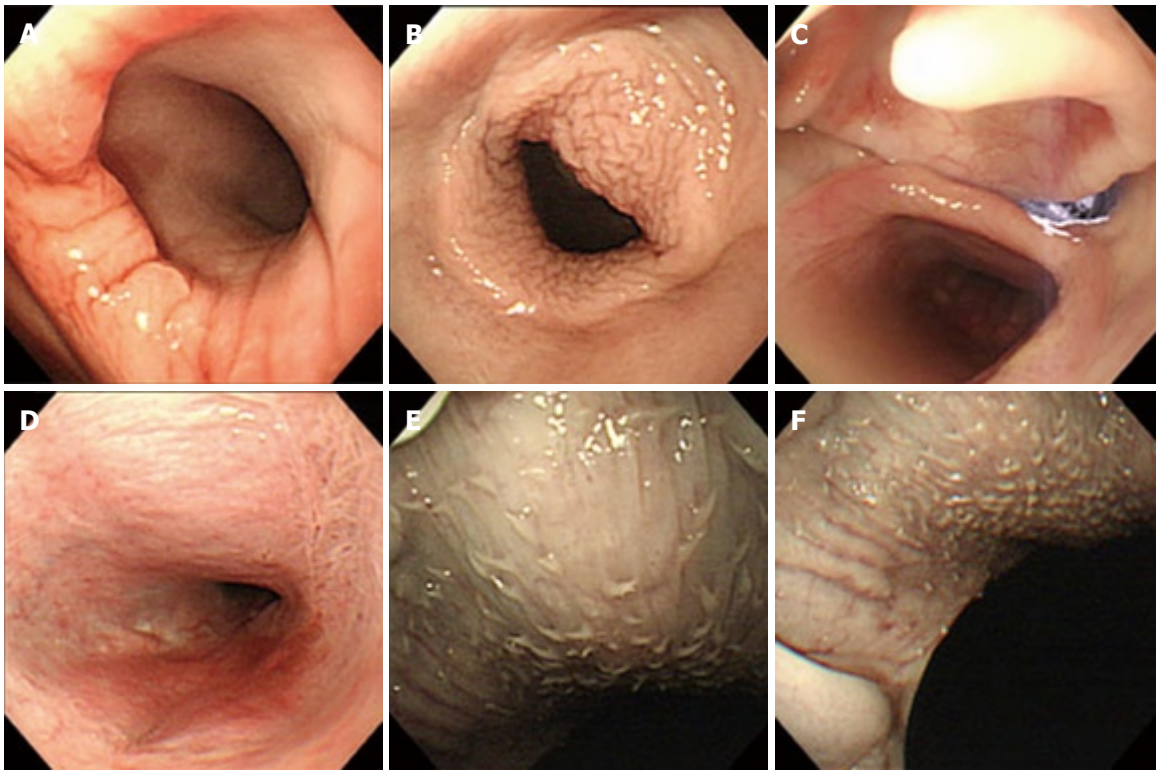

Figure 2 Images of retrograde observation. A: Esophagogastric junction, and the entire view is provided in a single visual field; B: Observation of the hypopharyngoesophageal junction from the cervical esophagus. The cervical esophagus is dilated well, providing a good visual field; C: Laryngeal surface of the epiglottis viewed up from the hypopharynx. Epipharynx and nasal cavity are present in the arrow direction; D: Observation of the epipharynx is possible; E, F: Observation of the lingual root is possible.

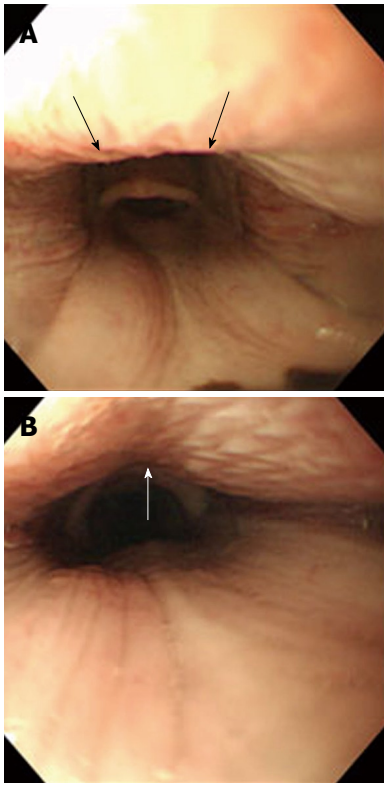

Figure 3 The lingual root of the oral approach. A, B: The arrow showed the lingual root. The observation of this part was limited.

cervical esophagus could also be observed well without restriction of the visual field.

Recently, the accuracy of diagnosis using gastroenterological endoscopy devices in combination with narrow band imaging has improved, making it possible to detect carcinomas of the pharynx and larynx at early stages[1-4]. Following such improvement, endoscopic mucosal resection as a less invasive means of treatment while preserving the head/neck function has begun to be introduced clinically, attracting large expectations[5-7]. As treatment of pharyngeal/laryngeal carcinomas tends to be accompanied by significant loss of pharyngeal/laryngeal functions due to adverse events arising from chemoradiotherapy or surgery[8-10], evaluation of the efficacy of endoscopic mucosal resection and arguments about cases indicated for this procedure will increase in importance. Endoscopic treatment requires precise determination of the scope of the tumor-affected area. Needless to say, endoscopic resection is not possible in cases where the lesion has spread beyond the endoscopically visible range. With anterograde endoscopic observation via the oral route, observation is quite difficult at the anterior wall of mesopharynx, particularly the lingual root. In cases where the tumor has undergone intraepithelial spread in this area, endoscopic evaluation is difficult. In the present study, we evaluate the extent to which observation of lingual root would be possible with retrograde endoscopic observation. When the tongue was manually pulled forward, a good visual field was obtained, allowing sufficient observation of the lingual root. So far

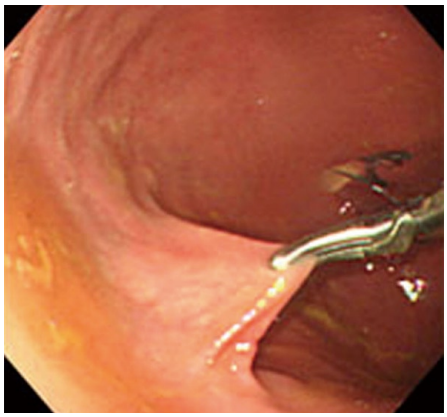

Figure 4 With forceps for laparoscopic surgery inserted through the port hole, intragastric surgery is possible.

as observation of the epiglottic vallecula is concerned, anterograde observation seems more useful. So, it seems advisable to determine the scope of a lesion using a combination of endoscopic observation in two directions (anterograde and retrograde). This approach also seems to be useful for pre-treatment evaluation of the feasibility of endoscopic resection in cases of superficial carcinoma of the nasopharyngeal anterior wall and as a means of resecting such lesions[6].

This procedure involves incision of the abdominal and gastric wall and is therefore more invasive than conventional endoscopy. However, it can be performed safely and in a short time by fixing the gastric wall with the use of Ideal Lifting, a device for PEG. The safety of PEG has already been established and it is now used widely at many medical facilities[11,12]. The procedure we have devised is also advantageous in that the use of this procedure is not limited to particular facilities or surgeons.

Although further evaluation of usefulness and safety in animal studies is needed, the use of this procedure for creation of multiple port holes will also enable per cutaneous intragastric surgery with forceps for laparoscopic surgery (Figure 4). Another possibility with this procedure is that it may be used for treatment of superficial tumors of the cardia and esophagogastric junction where endoscopic mucosal resection has conventionally been difficult.

COMMENTS

Background

Recently, the accuracy of diagnosis using gastrointestinal endoscope in combination with narrow band imaging has been improved, making it possible to detect carcinomas of the pharynx and larynx at early stages. Clinicians have been tried to apply endoscopic mucosal resection, previously used for treatment of gastric early stage carcinomas or polyps, to lesions of the pharynx and larynx. This technique is promising as a less invasive and function-preserving treatment of pharynx and larynx lesions. However, the orally inserted an endoscope has a limitation, dead angle, in the scope of visual field: the anterior wall of mesopharynx and the lingual root.

Research frontiers

This article described by first time an endoscopic procedure to correctly and completely evaluate those more difficult to explore areas in pharynx.

Innovations and breakthroughs

Innovation of our technique is the percutaneous insertion of an endoscope into the stomach for subsequent retrograde observation. This technique allowed easy observation of the lingual root and epipharynx which are the dead angle during ordinary anterograde observation via the oral route. No articles explained this method, previously.

Applications

This procedure will develop and become to enable percutaneous intragastric surgery with laparoscopic devices in future.

Terminology

The retrograde observation: a gastrointestinal endoscope is inserted percutaneously into the stomach, and mesopharynx and the lingual root are observed passing esophagus from stomach. This route is the opposite direction to conservative method.

Peer review

Reviewer's comments: This manuscript described by first time an endoscopic procedure to correctly and completely evaluate those more difficult to explore areas in pharynx. Authors develop the technique via retrograde access by means of endoscopic gastrostomy insertion and successfully achieved to evaluated the target structures. This pre-clinical evaluation of the technique could have a promising future since the instruments used by authors are widely available in almost every hospital. This study is very interesting and feasible to new thrapeutic world.

REFERENCES

1 **Katsinelos P**, Kountouras J, Chatzimavroudis G, Zavos C, Beltsis A, Paroutoglou G, Kamarianis N, Pournaras A, Pilpilidis I. Should inspection of the laryngopharyngeal area be part of routine upper gastrointestinal endoscopy? A prospective study. *Dig Liver Dis* 2009; **41**: 283-288

2 **Muto M**, Nakane M, Katada C, Sano Y, Ohtsu A, Esumi H, Ebihara S, Yoshida S. Squamous cell carcinoma in situ at oropharyngeal and hypopharyngeal mucosal sites. *Cancer* 2004; **101**: 1375-1381

3 **Ugumori T**, Muto M, Hayashi R, Hayashi T, Kishimoto S. Prospective study of early detection of pharyngeal superficial carcinoma with the narrowband imaging laryngoscope. *Head Neck* 2009; **31**: 189-194

4 **Orita Y**, Kawabata K, Mitani H, Fukushima H, Tanaka S, Yoshimoto S, Yamamoto N. Can narrow-band imaging be used to determine the surgical margin of superficial hypopharyngeal cancer? *Acta Med Okayama* 2008; **62**: 205-208

5 **Piazza C**, Dessouky O, Peretti G, Cocco D, De Benedetto L, Nicolai P. Narrow-band imaging: a new tool for evaluation of head and neck squamous cell carcinomas. Review of the literature. *Acta Otorhinolaryngol Ital* 2008; **28**: 49-54

6 **Iizuka T**, Kikuchi D, Hoteya S, Yahagi N, Takeda H. Endoscopic submucosal dissection for treatment of mesopharyngeal and hypopharyngeal carcinomas. *Endoscopy* 2009; **41**: 113-117

7 **Muto M**, Morita S, Chiba T. [Diagnosis and treatment for superficial cancer in the oropharynx and hypopharynx: new strategy of early detection and minimally invasive treatment]. *Nippon Shokakibyo Gakkai Zasshi* 2009; **106**: 1291-1298

8 **Abouzeid WM**, Mokhtar SA, Mahdy NH, El Kwsky FS. Quality of life of patients with oral and pharyngeal malignancies. *J Egypt Public Health Assoc* 2009; **84**: 299-329

9 **Licitra L**, Bernier J, Grandi C, Merlano M, Bruzzi P, Lefebvre JL. Cancer of the oropharynx. *Crit Rev Oncol Hematol* 2002; **41**: 107-122

10 **Parsons JT**, Mendenhall WM, Stringer SP, Amdur RJ, Hinerman RW, Villaret DB, Moore-Higgs GJ, Greene BD, Speer TW, Cassisi NJ, Million RR. Squamous cell carcinoma of the oropharynx: surgery, radiation therapy, or both. *Cancer* 2002; **94**: 2967-2980

11 **Campoli PM**, Cardoso DM, Turchi MD, Ejima FH, Mota OM. Assessment of safety and feasibility of a new technical variant

of gastropexy for percutaneous endoscopic gastrostomy: an experience with 435 cases. *BMC Gastroenterol* 2009; **9**: 48
12 **Cruz I**, Mamel JJ, Brady PG, Cass-Garcia M. Incidence of abdominal wall metastasis complicating PEG tube placement in untreated head and neck cancer. *Gastrointest Endosc* 2005; **62**: 708-711; quiz 752, 753

S- Editor Zhang HN **L- Editor** Roemmele A **E- Editor** Liu N

World Journal of Gastrointestinal Endoscopy

Online Submissions: http://www.wjgnet.com/1948-5190office
wjge@wjgnet.com
doi:10.4253/wjge.v2.i8.293

World J Gastrointest Endosc 2010 August 16; 2(8): 293-297
ISSN 1948-5190 (online)

CASE REPORT

Toxic megacolon associated *Clostridium difficile* colitis

Leena Sayedy, Darshan Kothari, Robert J Richards

Leena Sayedy, Darshan Kothari, Robert J Richards, Division of Gastroenterology, Department of Medicine, Stony Brook University School of Medicine, Stony Brook, NY 11794-8160, United States
Author contributions: Sayedy L, Kothari D, and Richards RJ were responsible for the content, accuracy and writing of this article.
Correspondence to: Robert J Richards, Associate Professor of Clinical Medicine, Division of Gastroenterology, Department of Medicine, Stony Brook University School of Medicine, HSC, Level 17, Room 063, Stony Brook, NY 11794, United States. rrichards@notes.cc.sunysb.edu
Telephone: +1-631-4442119 Fax: +1-631-4448886
Received: May 4, 2010 Revised: June 23, 2010
Accepted: June 30, 2010
Published online: August 16, 2010

Peer reviewers: Kaushal K Prasad, Associate Professor, Chief, Division of GE Histopathology, Department of Superspeciality of Gastroenterology, Post Graduate Institute of Medical Education and Research, Chandigarh, UT 160012, India; Jose LS Souza, MD, Department of Gastroenterology, University of São Paulo, São Paulo 05403-000, Brizal; Vasileios Panteris, MD, FEBG, Gastroenterologist, Consultant, Deptartment of Gastroenterology, "St. Panteleimon" General Hospital of Nikaia, Athens 13231, Greece

Sayedy L, Kothari D, Richards RJ. Toxic megacolon associated *Clostridium difficile* colitis. *World J Gastrointest Endosc* 2010; 2(8): 293-297 Available from: URL: http://www.wjgnet.com/1948-5190/full/v2/i8/293.htm DOI: http://dx.doi.org/10.4253/wjge.v2.i8.293

Abstract

Toxic megacolon is a severe complication of *Clostridium difficile* (*C. difficile*) colitis. As the prevalence of *C. difficile* colitis increases and treatments become more refractory, clinicians will encounter more patients with *C. difficile* associated toxic megacolon in the future. Here, we review a case of toxic megacolon secondary to *C. difficile* colitis and review the current literature on diagnosis and management. We identify both clinical and radiologic criteria for diagnosis and discuss both medical and surgical options for management. Ultimately, we recommend using the Jalen criteria in conjunction with daily abdominal radiographs to help establish the diagnosis of toxic megacolon and to make appropriate treatment recommendations. Aggressive medical management using supportive measures and antibiotics should remain the mainstay of treatment. Surgical intervention should be considered if the patient does not clinically improve within 2-3 d of initial treatment.

Key words: Toxic megacolon; *Clostridium difficile*; Colitis; Diarrhea; Surgery; Colon; Antibiotics; Metronidazole; Vancomycin

INTRODUCTION

Clostridium difficile (*C. difficile*) is a gram positive, anaerobic, spore forming bacterium spread by the fecal oral route[1-4]. It produces toxins A and B, causing severe mucosal destruction and pseudomembrane formation[1-5]. Clindamycin, cephalosporins and fluoroquinolones are the most common antibiotics associated with *C. difficile* infection[3,6,7]. The prevalence of *C. difficile* colitis has been increasing[8]. The percentage of complicated cases of *C. difficile* rose from 7.1% in 1991 to 18.2% in 2003, and the proportion of patients who died within 30 d after a severe *C. difficile* associated diarrheal episode rose from 4.7% in 1991 to 13.8% in 2003[9]. Between 2003 and 2006, *C. difficile* infection became more severe and refractory to standard therapy. It also became more likely to relapse than in previous years[4,6,10].

Toxic megacolon, first described by Marshak *et al*[11] in 1950 is a known complication of *C. difficile* colitis. The incidence of toxic megacolon associated *C. difficile* colitis varies from 0.4%-3% of cases[12,13]. Toxic megacolon is thought to develop from inflammatory changes that penetrate into the muscularis propria resulting in neural injury, altered motility and dilation[13]. Risk factors for toxic megacolon include any severe inflammatory condition

such as inflammatory bowel disease, ischemic colitis and infectious colitis. Risk factors for development of toxic megacolon include concurrent malignancy, severe chronic obstructive pulmonary disease, organ transplantation, cardiothoracic procedures, diabetes mellitus, immunosuppression and renal failure[13-16]. Patients with toxic megacolon will often present with peritoneal signs, abdominal distension, diarrhea, oliguria, tachypnea, fever, hy potension, and marked leukocytosis. In atypical cases, diarrhea maybe absent[13,15,17-19].

The mortality rate of toxic megacolon secondary to *C. difficile* colitis is substantial and varies from 38% to 80%[5,13]. Early recognition and aggressive treatment of toxic megacolon associated with *C. difficile* may lead to improved outcomes. Yet, standards for diagnosis and management of this potentially lethal condition are not clearly defined.

CASE REPORT

A 64-year-old woman presented to the hospital with 3 days of abdominal pain, nausea, vomiting and profuse watery diarrhea. She was recently discharged from the hospital for a urinary tract infection and acute renal failure. She had just completed a 14 d course of ciprofloxacin.

The past medical history was significant for hyperlipidemia, hypertension, and gouty arthritis. There were no prior surgeries except for a remote history of tonsillectomy. She used tobacco and on average she drank four cans of beer daily. She denied using intravenous drugs.

On admission to the hospital the blood pressure was 65/41 mmHg. Hypothermia was present. The temperature was 35.8℃. She was obese and appeared in mild distress. Her abdomen was mildly distended, with hypoactive bowel sounds. There was tenderness in the lower quadrants without rebound.

The WBC was 53.9 K/mcl with 84% neutrophils. The Hct was 36.1%. There was severe metabolic acidosis with an anion gap of 19, bicarbonate level of 12 mmol/L, lactic acid level of 3.6 mmol/L. The arterial blood gas demonstrated a pH of 7.11, CO_2 of 16, and O_2 of 150 on 2 liters of oxygen via nasal canula. The serum creatinine was 11.5 mg/dL. The K+ was 2.5 mmol/L, and Mg++ of 0.6 mg/dL. The INR was 2.1.

The patient was resuscitated with Ⅳ fluids, and placed on dopamine and later norepinephrine. She was also given intravenous ciprofloxacin 500 mg every 12 h, oral vancomycin 250 mg every 6 h and Ⅳ metronidazole 500 mg every 6 h.

A CT of the abdomen and pelvis demonstrated circumferential wall thickening of the colon consistent with a pancolitis (Figure 1). The transverse colon was dilated to 5.8 cm.

The patient did not improve despite treatment over the next 36 h. The WBC rose to 62.4 K/mcl. There was no other source of infection. Blood, urine and stool cultures were negative. The cytotoxicity assay for *C. difficile* on stool samples was also negative.

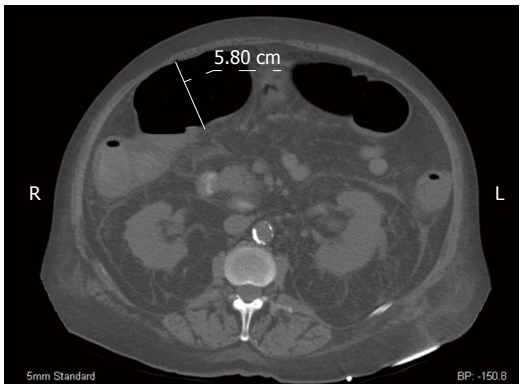

Figure 1 Computerized tomography axial image of our patient. We measured the patient's transverse colon at 5.80 cm. Additionally, perinephric fluid is markedly evident bilaterally.

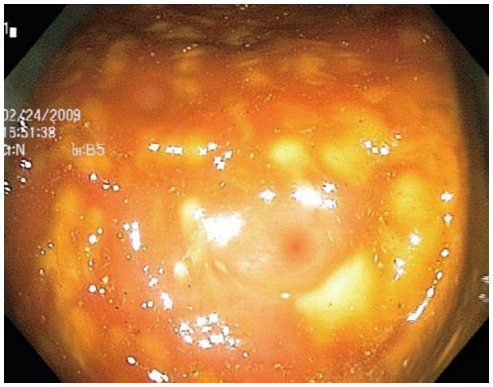

Figure 2 Colonoscopic image taken of the descending colon consistent with pseudomembranous colitis.

The surgery service was consulted for presumed toxic megacolon. A rigid sigmoidoscope was advanced to 25 cm from the anal verge. The mucosa appeared pink without pseudomembranes. The gastroenterology service next performed a colonoscopy, which demonstrated edematous mucosa with raised yellowish plaques consistent with pseudomembranous colitis in the sigmoid and descending colon. No biopsies were taken (Figure 2).

Medical treatment was continued and surgery was not offered at this time. Vancomycin 500 mg enemas every 12 h were added to the regimen. On subsequent stool samples the cytotoxicity assay for *C. difficile* was positive.

The patient's blood pressure began to improve on the third day and Ⅳ pressors were discontinued. The patient was discharged after 23 d.

DISCUSSION

Concerning this case, we were presented with three questions: (1) What are the criteria for the diagnosis of toxic megacolon? (2) Is endoscopy necessary to confirm the diagnosis of *C. difficile* related toxic megacolon? and (3) When should surgery be performed for *C. difficile* related toxic megacolon? In order to answer these questions, we performed a systematic literature review. We searched the

Web of Science, PubMed, MEDLINE, the Cochrane Library and Google Scholar for articles written between January 1990 and June 2009 using a combination of keywords and MeSH terminology "*Clostridium difficile*" and "toxic megacolon." We limited our search to English language articles. We initially identified 55 articles. All articles were reviewed for content to determine relevance to the discussion. 17 articles were excluded because of lack of relevance to the topic. The citations of identified articles were also examined for additional publications. The total number of articles that were selected for our review was 37.

The diagnosis of toxic megacolon requires radiological evidence of colonic dilatation primarily involving the ascending or transverse colon. The degree of dilation is somewhat controversial - some using > 5 cm as a cut-off, while others require colonic dilation of > 6 cm to make the diagnosis[6,13,20-23].

CT is helpful in confirming the diagnosis of a toxic megacolon. CT findings commonly seen in patients with toxic megacolon are: pericolonic fat stranding, colonic wall thickening, absence or distortion of haustral folds, and ascites[13,15,24]. Other CT findings include the 'target' sign, which indicates mucosal hyperemia and submucosal edema and the 'accordion' sign, which is due to marked thickening of the haustral folds[24]. In a study by Hall *et al*[5], which reviewed 36 patients who had documented toxic megacolon at surgery, CT was accurate in 94% of cases.

In addition to colonic dilation, several clinical criteria must be fulfilled. The most accepted clinical criteria for toxic megacolon are derived from Jalan *et al*[19]. To establish the diagnosis of toxic megacolon three of the following four criteria should be present: fever > 101.5 F: HR > 120 beats/min: WBC > 10 500/mm^3: and anemia with hemoglobin or hematocrit level less than 60% of normal. In addition, the patient must have any one of the following four clinical findings: dehydration, electrolyte disturbance, hypotension or changes in mental status.

Endoscopy is seldom used to confirm the diagnosis of *C. difficile* related toxic megacolon since the diagnosis can be made by a combination of immunotoxin assay, clinical findings and imaging. An endoscopy may be dangerous, especially in a setting of fulminant colitis due to the increased risk of perforation[6,25]. A study by Johal *et al*[26], however encouraged the use of flexible sigmoidoscopy as a tool for the diagnosis of *C. difficile* toxic colitis when stool assays are negative. In their study 52% of patients who tested negative for *C. difficile* toxin assay had pseudomembranous colitis on flexible sigmoidoscopy.

Endoscopy is recommended for the diagnosis of *C. difficile* toxic colitis under the following conditions: (1) when there is a high level of clinical suspicion for *C. difficile* despite repeated negative laboratory assays; (2) when a prompt diagnosis is needed before laboratory results can be obtained; (3) when *C. difficile* infection fails to respond to antibiotic therapy or (4) for atypical presentations of *C. difficile* colitis such as in patients who present with ileus, acute abdomen, or leukocytosis without diarrhea[3,15,21].

In the treatment of *C. difficile* related toxic megacolon, aggressive medical therapy may help prevent surgical intervention in up to 50% of cases[13]. In a retrospective review by Imbriaco *et al*[27] 12 of the 18 patients (67%) with toxic megacolon due to *C. difficile* improved with medical therapy without the need for surgery.

The medical management of toxic megacolon includes oral vancomycin, IV metronidazole, bowel rest, bow el decompression, and replacement of fluids and electrolytes[13,18,21]. Some authors note that adequate intracolonic concentrations of vancomycin may not be achieved with oral vancomycin because of poor intestinal motility. Therefore, vancomycin enemas have been recommended; however enemas may fail to treat right-sided disease of the colon. Other alternatives include direct instillation of vancomycin by colonoscopy, colostomy or ileostomy[28].

The dilated colon may be decompressed with nasogastric suction and frequent repositioning of the patient[13]. Some authors recommend prone positioning for 10 to 15 min every 2 to 3 h allowing the passage of flatus. Panos *et al*[22] presented two cases where bowel decompression was successfully achieved with the knee-chest position.

Colonic decompression can also be achieved with a colonoscopy. Shetler *et al*[29] reviewed seven patients with toxic megacolon due to *C. difficile* who underwent decompressive colonoscopy and intracolonic perfusion of vancomycin. The authors found that 57% of the patients had complete resolution of toxic megacolon. Their reported data suggested that decompressive colonoscopy may be safe and effective in the medical treatment of toxic megacolon although the number of patients in this study was small. Other authors suggest that endoscopic decompression may worsen disease[21]. Colonoscopy may cause further dilation of the colon leading to impaired blood supply to the colon wall, increasing the risk of perforation and translocation of bacteria[13,21].

Management of toxic megacolon also includes with holding medications that slow intestinal motility. These medications include anticholinergics, antidepressants, antidiarrheals, and narcotics[6,13,30].

Surgical intervention may be necessary in up to 80% of patients with toxic megacolon due to *C. difficile* colitis[22]. Indications for surgery include: perforation, progressive dilation of the colon, lack of clinical improvement over the first 48-72 h and uncontrolled bleeding[9,13,21,26,31,32]. Ausch *et al*[31] evaluated 70 patients who had surgery for toxic megacolon due to *C. difficile* colitis and found that the most common indication for surgery was progressive colonic dilation. Clinical deterioration (36%) and uncontrolled bleeding (4%) were other reasons the authors noted.

The mortality rate for a colectomy has varies widely across studies. Byrne *et al*[14] retrospectively reviewed 73 patients who underwent colectomy for toxic megacolon due to *C. difficile* colitis between 1994 and 2005. The hospital mortality rate was 34% with a single intraoperative death. This study along with others have found that preoperative vasopressor requirement, endotracheal

intubation, and altered mental status were significant predictors of mortality after colectomy[5,9]. Miller *et al*[33] retrospectively reviewed 49 patients who underwent colectomy for fulminant *C. difficile* colitis. The study found that the 30 d mortality rate was 57%, with an in-hospital morality rate of 49%. The 5 year survival rate for those who lived past 30 d from a colectomy was 38%.

The surgical procedure of choice for toxic megacolon is total colectomy with preservation of rectum and diverting ileostomy[6,7,13,31]. Outcomes are worse if a partial colectomy is performed, perhaps owing to residual diseased bowel left in place[3,4,29,34]. Grundfest-Broniatowski *et al*[35] reviewed 21 studies between 1976 and 1994. They reported a 24% mortality rate for subtotal colectomy compared to 40% for sigmoid resection alone. In a study by Koss *et al*[25], total colectomy resulted in a lower mortality rate (11%) compared to those with a left hemicolectomy (100%).

It must be emphasized that clear standardized indications for surgery in patients with toxic megacolon due to *C. difficile* colitis do not currently exist. In several articles reviewed, surgery was performed only in patients who had signs of systemic toxicity such as shock requiring vasopressors, multisystem organ failure or perito nitis[4,14,16,31,36]. It is interesting to speculate that mortality rates might be improved if patients were operated on earlier in the course of their illness, before signs of organ failure set in. Lamontagne[37] advised surgery for patients with WBC > 50 K/mcl and lactate levels > 5 mmol/L as these patients were likely to die within 30 d of ICU admission without surgery.

In conclusion, toxic megacolon is a complication of *C. difficile* colitis. The diagnosis is made when colonic dilation is at least > 5 cm. CT is helpful in establishing the presence of toxic megacolon by demonstrating wall thickening and distortion of haustra. The criteria described by Jalan *et al*[38] should be used in making the diagnosis. Patients should have aggressive medical management and daily abdominal X-rays. Patients with an ileus should be given rectal vancomycin as well - even though there is a lack of evidence-based studies to confirm its efficacy. Surgery should be considered if there is progressive colonic dilation or if clinical improvement is not noted within 2 to 3 d.

REFERENCES

1 **Aslam S**, Hamill RJ, Musher DM. Treatment of Clostridium difficile-associated disease: old therapies and new strategies. *Lancet Infect Dis* 2005; **5**: 549-557

2 **Barbut F**, Gariazzo B, Bonné L, Lalande V, Burghoffer B, Luiuz R, Petit JC. Clinical features of Clostridium difficile-associated infections and molecular characterization of strains: results of a retrospective study, 2000-2004. *Infect Control Hosp Epidemiol* 2007; **28**: 131-139

3 **Cleary RK**. Clostridium difficile-associated diarrhea and colitis - Clinical manifestations, diagnosis, and treatment. *Dis Colon Rectum* 1998; **41**: 1435-1449

4 **Wilmanns C**, Schoffel U, Farthmann EH. Surgery as the Final Option for Treatment of Clostridium-difficile-Associated pseudomembranous Colitis. *Dig Surg* 1997; **14**: 222-228

5 **Hall JF**, Berger D. Outcome of colectomy for Clostridium difficile colitis: a plea for early surgical management. *Am J Surg* 2008; **196**: 384-388

6 **Hookman P**, Barkin JS. Clostridium difficile associated infection, diarrhea and colitis. *World J Gastroenterol* 2009; **15**: 1554-1580

7 **Klipfel AA**, Schein M, Fahoum B, Wise L. Acute abdomen and Clostridium difficile colitis: still a lethal combination. *Dig Surg* 2000; **17**: 160-163

8 **Ricciardi R**, Rothenberger DA, Madoff RD, Baxter NN. Increasing prevalence and severity of Clostridium difficile colitis in hospitalized patients in the United States. *Arch Surg* 2007; **142**: 624-631; discussion 631

9 **Bouza E**, Muñoz P, Alonso R. Clinical manifestations, treatment and control of infections caused by Clostridium difficile. *Clin Microbiol Infect* 2005; **11** Suppl 4: 57-64

10 **Indra A**, Schmid D, Huhulescu S, Hell M, Gattringer R, Hasenberger P, Fiedler A, Wewalka G, Allerberger F. Characterization of clinical Clostridium difficile isolates by PCR ribotyping and detection of toxin genes in Austria, 2006-2007. *J Med Microbiol* 2008; **57**: 702-708

11 **Marshak RH**, Lester LJ. Megacolon a complication of ulcerative colitis. *Gastroenterology* 1950; **16**: 768-772

12 **Berman L**, Carling T, Fitzgerald TN, Bell RL, Duffy AJ, Longo WE, Roberts KE. Defining surgical therapy for pseudomembranous colitis with toxic megacolon. *J Clin Gastroenterol* 2008; **42**: 476-480

13 **Earhart MM**. The identification and treatment of toxic megacolon secondary to pseudomembranous colitis. *Dimens Crit Care Nurs* 2008; **27**: 249-254

14 **Byrn JC**, Maun DC, Gingold DS, Baril DT, Ozao JJ, Divino CM. Predictors of mortality after colectomy for fulminant Clostridium difficile colitis. *Arch Surg* 2008; **143**: 150-154; discussion 155

15 **Hinkson PL**, Dinardo C, DeCiero D, Klinger JD, Barker RH Jr. Tolevamer, an anionic polymer, neutralizes toxins produced by the BI/027 strains of Clostridium difficile. *Antimicrob Agents Chemother* 2008; **52**: 2190-2195

16 **Velanovich V**, LaPorta AJ, Garrett WL, Richards TB, Cornett PA. Pseudomembranous colitis leading to toxic megacolon associated with antineoplastic chemotherapy. Report of a case and review of the literature. *Dis Colon Rectum* 1992; **35**: 369-372

17 **Dallal RM**, Harbrecht BG, Boujoukas AJ, Sirio CA, Farkas LM, Lee KK, Simmons RL. Fulminant Clostridium difficile: an underappreciated and increasing cause of death and complications. *Ann Surg* 2002; **235**: 363-372

18 **Gerding DN**, Muto CA, Owens RC Jr. Treatment of Clostridium difficile infection. *Clin Infect Dis* 2008; **46** Suppl 1: S32-S42

19 **Longo WE**, Mazuski JE, Virgo KS, Lee P, Bahadursingh AN, Johnson FE. Outcome after colectomy for Clostridium difficile colitis. *Dis Colon Rectum* 2004; **47**: 1620-1626

20 **Dobson G**, Hickey C, Trinder J. Clostridium difficile colitis causing toxic megacolon, severe sepsis and multiple organ dysfunction syndrome. *Intensive Care Med* 2003; **29**: 1030

21 **Gan SI**, Beck PL. A new look at toxic megacolon: an update and review of incidence, etiology, pathogenesis, and management. *Am J Gastroenterol* 2003; **98**: 2363-2371

22 **Panos MZ**, Wood MJ, Asquith P. Toxic megacolon: the knee-elbow position relieves bowel distension. *Gut* 1993; **34**: 1726-1727

23 **Trudel JL**, Deschenes M, Mayrand S, Barkun, AN. Toxic megacolon complicating psuedomembranous enterocolitis. *Dis Colon Rectum* 1995; **38**: 1033-1038

24 **Kawamoto S**, Horton KM, Fishman EK. Pseudomembranous colitis: can CT predict which patients will need surgical intervention? *J Comput Assist Tomogr* 1999; **23**: 79-85

25 **Kawamoto S**, Horton KM, Fishman EK. Pseudomembranous colitis: spectrum of imaging findings with clinical and pathologic correlation. *Radiographics* 1999; **19**: 887-897

26 **Johal SS**, Hammond J, Solomon K, James PD, Mahida YR. Clostridium difficile associated diarrhoea in hospitalised patients: onset in the community and hospital and role of flexible sigmoidoscopy. *Gut* 2004; **53**: 673-677

27 **Imbriaco M**, Balthazar, EJ. Toxic megacolon: role of CT in evaluation and detection of complications. *Clin Imaging* 2001; **25**: 349-354

28 **Shetler K**, Nieuwenhuis R, Wren SM, Triadafilopoulos G. Decompressive colonoscopy with intracolonic vancomycin administration for the treatment of severe pseudomembranous colitis. *Surg Endosc* 2001; **15**: 653-659

29 **Kuijper EJ**, van Dissel JT, Wilcox MH. Clostridium difficile: changing epidemiology and new treatment options. *Curr Opin Infect Dis* 2007; **20**: 376-383

30 **Koo HL**, Koo DC, Musher DM, DuPont HL. Antimotility agents for the treatment of Clostridium difficile diarrhea and colitis. *Clin Infect Dis* 2009; **48**: 598-605

31 **Ausch C**, Madoff RD, Gnant M, Rosen HR, Garcia-Aguilar J, Hölbling N, Herbst F, Buxhofer V, Holzer B, Rothenberger DA, Schiessel R. Aetiology and surgical management of toxic megacolon. *Colorectal Dis* 2006; **8**: 195-201

32 **Reihnér E**, Hellers G, Lindqvist L, Veress B. Pseudmembranous colitis presenting as an acute abdomen. *Eur J Surg* 1996; **162**: 579-581

33 **Miller AT**, Tabrizian P, Greenstein AJ, Dikman A, Byrn J, Divino C. Long-term follow-up of patients with fulminant Clostridium difficile colitis. *J Gastrointest Surg* 2009; **13**: 956-959

34 **Koss K**, Clark MA, Sanders DS, Morton D, Keighley MR, Goh J. The outcome of surgery in fulminant Clostridium difficile colitis. *Colorectal Dis* 2006; **8**: 149-154

35 **Grundfest-Broniatowski S**, Quader M, Alexander F, Walsh RM, Lavery I, Milsom J. Clostridium difficile colitis in the critically ill. *Dis Colon Rectum* 1996; **39**: 619-623

36 **Synnott K**, Mealy K, Merry C, Kyne L, Keane C, Quill R. Timing of surgery for fulminating pseudomembranous colitis. *Br J Surg* 1998; **85**: 229-231

37 **Lamontagne F**, Labbé AC, Haeck O, Lesur O, Lalancette M, Patino C, Leblanc M, Laverdière M, Pépin J. Impact of emergency colectomy on survival of patients with fulminant Clostridium difficile colitis during an epidemic caused by a hypervirulent strain. *Ann Surg* 2007; **245**: 267-272

38 **Jalan KN**, Sircus W, Card WI, Bruce J, Falconer CW, Small WP, Smith AN, McManus JPA. Toxic dilatation of the colon - An experience of 55 cases. *Gut* 1967; **8**: 633-638

S- Editor Zhang HN **L- Editor** Hughes D **E- Editor** Liu N

World Journal of Gastrointestinal Endoscopy

Online Submissions: http://www.wjgnet.com/1948-5190office
wjge@wjgnet.com
doi:10.4253/wjge.v2.i8.298

World J Gastrointest Endosc 2010 August 16; 2(8): 298-300
ISSN 1948-5190 (online)

CASE REPORT

A novel endoscopic ablation of gastric antral vascular ectasia

Masae Komiyama, Kuangi Fu, Takashi Morimoto, Hironori Konuma, Toshifumi Yamagata, Yuko Izumi, Akihisa Miyazaki, Sumio Watanabe

Masae Komiyama, Kuangi Fu, Takashi Morimoto, Hironori Konuma, Toshifumi Yamagata, Yuko Izumi, Akihisa Miyazaki, Department of Gastroenterology, Juntendo Univerity Nerima Hospital, Tokyo 177-0033, Japan
Sumio Watanabe, Department of Gastroenterology, Juntendo University School of Medicine, Tokyo 113-8431, Japan
Author contributions: Komiyama M and Fu KI supplemented the data for this case report; Morimoto T, Konuma H, Yamagata T, Izumi Y, Miyazaki A, Watanabe S analysed the data of the patient; and Komiyama M and Fu KI wrote the paper.
Correspondence to: Kuangi Fu, MD, PhD, Department of Gastroenterology, Juntendo University Nerima Hospital, 3-1-10 Nerimatakanodai, Nerima, Tokyo 177-0033, Japan. fukuangi@hotmail.com
Telephone: +81-3-59233111 Fax: +81-3-59233111
Received: March 26, 2010 Revised: June 22, 2010
Accepted: June 29, 2010
Published online: August 16, 2010

Abstract

An 80-year-old woman was admitted to our hospital because of tarry stool with iron deficiency anemia. Her past history included autoimmune hepatitis. Esophagogastroduodenal endoscopy was performed to investigate the bleeding source and revealed multiple linear gastric vascular malformations in the antrum and cardia, compatible with Gastric antral vascular ectasia (GAVE). Endoscopic ablation was carried out with the tip of the hot biopsy forceps without opening at soft coagulation mode of 80W. The patient tolerated the procedure well and there were no complications associated with endoscopic therapies. After two sessions of endoscopic ablation her anemia improved to around 10 g/dL, an increase of 3.6 g/dL. Various endoscopic treatments have been described to manage GAVE. The most popular is argon plasma coagulation (APC), although APC is associated with over-distension induced by the argon plasma gas. To avoid over-distension and to reduce the abdominal discomfort/pain of this patient, we have used hot biopsy forceps instead of APC. Our case suggests that this procedure is effective, easy and convenient, as no special equipment or skill is necessary.

Key words: Hot biopsy forceps; Endoscopic ablation; Gastric antral vascular ectasia

Peer reviewer: Kazuki Sumiyama, MD, PhD, Department of Endoscopy, The Jikei University School of Medicine, 3-25-8 Nishi Shinbashi, Minato-ku, Tokyo 105-8461, Japan

Komiyama M, Fu KI, Morimoto T, Konuma H, Yamagata T, Izumi Y, Miyazaki A, Watanabe S. A novel endoscopic ablation of gastric antral vascular ectasia. *World J Gastrointest Endosc* 2010; 2(8): 298-300 Available from: URL: http://www.wjgnet.com/1948-5190/full/v2/i8/298.htm DOI: http://dx.doi.org/10.4253/wjge.v2.i8.298

INTRODUCTION

Gastric antral vascular ectasia (GAVE), also named watermelon stomach, is a source of recurrent gastrointestinal hemorrhage and anemia, accounting for about 4% of all non-variceal upper gastrointestinal bleeding. Endoscopically, all patients present with a characteristic antral appearance of either ecstatic vascular stripes radiating out from the pylorus, or multiple cherry-red spots. Marked improvement of both endoscopic and histological features can be achieved with endoscopic treatment using heater probe, Gold probe, Argon plasma coagulation (APC) or laser therapy, which obliterates the vascular ectasia and decreases the degree of bleeding[1-3]. Endoscopic band ligation has also been reported[4]. Surgical intervention includes antrectomy which prevents recurrent bleeding but is usually reserved for patients who

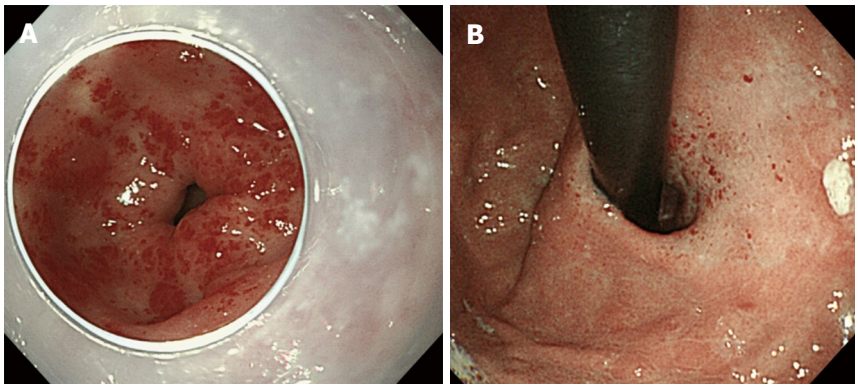

Figure 1 Multiple linear gastric vascular malformations found endoscopically, which is compatible with gastric antral vascular ectasia. A: In the antrum; B: In the cardia.

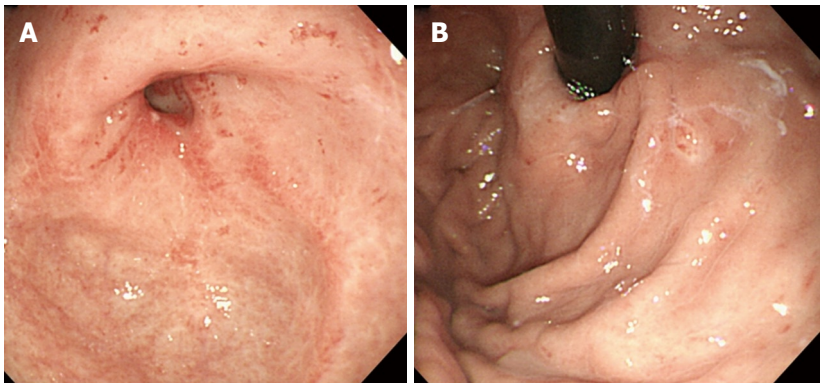

Figure 2 Gastric vascular malformations were markedly diminished after 2 sessions of endoscopic ablation with hot biopsy forceps. A: In the antrum; B: In the cardia.

fail endoscopic therapies, as it is associated with a high mortality[5]. We herein report a case of GAVE associated with autoimmune hepatitis which was successfully treated with a simple and effective endoscopic ablation with hot biopsy forceps in common use.

CASE REPORT

An 80-year-old woman admitted to our hospital because of tarry stool with iron deficiency anemia. Her past history included 13 years of liver dysfunction. She had been referred to our hospital for investigation and treatment of liver cirrhosis three years before this admission. The laboratory data showed that her liver cirrhosis was related to autoimmune hepatitis. Esophagogastroduodenal endoscopy was performed for investigation of the bleeding source and revealed multiple linear gastric vascular malformations in the antrum, compatible with GAVE or watermelon stomach (Figure 1A). Moreover, multiple gastric vascular malformations mimicking GAVE were also detected in the cardia (Figure 1B). A slim, single-channel and high-resolution endoscope with a water-jet system (GIFQ260J; Olympus, Tokyo, Japan) was used for endoscopic treatment. A transparent attachment (D-201-11804; Olympus) was fitted onto the tip of the endoscope mainly to obtain a constant endoscopic view. Endoscopic ablation was carried out with hot biopsy forceps (RADIAL JAW® 3 HOT BIOPSY FORCEPS; BOSTON SCIENTIFIC CORP. MA, USA) and a high-frequency generator (ICC 200; ERBE Elektromedizin, Tübingen, Germany). Contact thermal therapies were conducted with the tip of the hot biopsy forceps without opening at a special coagulation setting (soft coagulation mode 80W). Separate sessions of endoscopic ablation were performed for vascular malformations located in the antrum and cardia, respectively. After endoscopic treatment, a proton pump inhibitor was given orally and iron supplementation intravenously, with food intake started 36 h thereafter. The patient tolerated the procedure well and there were no complications associated with endoscopic therapies. After two sessions of endoscopic ablation, GAVE was markedly diminished (Figure 2A and B). The patient required no further blood transfusions. Her anemia responded well to oral iron supplementation, and her hemoglobin concentration after endoscopic ablation was maintained at around 10 g/dL, an increase of 3.6 g/dL.

DISCUSSION

GAVE was first described by Rider *et al*[6] in a patient with severe chronic iron-deficiency anemia in 1953. The ectactic vessels are typically limited to the antrum. Similar to our case, Stoltzer *et al*[7], however, postulated a high incidence of vascular ectasias located in the cardia as well. Most patients with GAVE suffer from liver cirrhosis, autoimmune disease, chronic renal failure and bone marrow transplantation. The typical initial presentations range from occult bleeding causing transfusion-dependent chronic iron-deficiency anemia to severe acute gastrointestinal bleeding.

Various endoscopic treatments have been described to manage GAVE. Recently, several reports presented the efficacy of endoscopic therapies, such as heater probe

coagulation, laser coagulation, and APC in the control of bleeding[1-3]. In particular, APC is the most frequently used endoscopic treatment for GAVE, as it has been reported to be easier to use and to be safer and more effective in comparison to other non-contact treatments[3]. Furthermore, APC has a theoretical safety advantage over other modalities due to its decreased depth of penetration and the tendency for the ionized arc of electrical current to deflect away from coagulated tissue to surrounding areas. However, on the basis of two randomized controlled trials, there is still no evidence to support the suggestion that APC is superior to other endoscopic therapies for acute non-variceal upper gastrointestinal bleeding[8]. Moreover, side-effects of APC may include bleeding, antral scarring, hyperplastic polyps, and gastric outlet obstruction[9]. Symptomatic pneumoperitoneum induced transient abdominal pain, and subcutaneous bubbling of gas have also been observed[10]. It is likely that these problems are caused by over-distension induced by argon plasma gas. To avoid over-distension and to reduce the abdominal discomfort/pain of this patient, we used hot biopsy forceps instead of APC for treatment. Our case suggested that hot biopsy forceps also can be used to ablate GAVE effectively and safely. This technique is similar to that of the heater probe, which is not only more expensive but also less commonly used recently.

Hot biopsy forceps technique involves the use of insulated monopolar electrocoagulating forceps to simultaneously biopsy and electrocoagulate tissue. It is popular for biopsy resection of diminutive polyps during colonoscopy. Furthermore, hot biopsy forceps recently have been used for hemostasis during a newly developed therapeutic endoscopy, named endoscopic submucosal dissection (ESD), for early gastric cancers[11]. Acute bleeding during ESD can be easily stopped by grasping and coagulation of the bleeding vessels using hot biopsy forceps. In personal experience, the tip of the hot biopsy forceps without grasping the mucosa for contact thermal therapies can also be used for hemostasis, especially for bleeding in deep ulcers, during ESD. To avoid deep burn, in our case we used this non-opening hot biopsy forceps contact technique, and furthermore a setting of soft coagulation mode instead of forced coagulation mode was used. Each session of endoscopic therapies was easily finished within 20 min without any complication or discomfort. This procedure is easy, convenient and cost-effective, as the device is available everywhere and no special equipment or skill is needed.

In summary, we have used hot biopsy forceps for complete and successful ablation of GAVE associated with autoimmune hepatitis. This procedure is easy, convenient and cost-effective, as no special equipment or skill is necessary. Further accumulation of cases and follow-up are needed to prove its long term efficacy.

REFERENCES

1 **Watson M**, Hally RJ, McCue PA, Varga J, Jiménez SA. Gastric antral vascular ectasia (watermelon stomach) in patients with systemic sclerosis. *Arthritis Rheum* 1996; **39**: 341-346

2 **Stefanidis I**, Liakopoulos V, Kapsoritakis AN, Ioannidis I, Eleftheriadis T, Mertens PR, Winograd R, Vamvaka E, Psychos AK, Potamianos SP. Gastric antral vascular ectasia (watermelon stomach) in patients with ESRD. *Am J Kidney Dis* 2006; **47**: e77-e82

3 **Yusoff I**, Brennan F, Ormonde D, Laurence B. Argon plasma coagulation for treatment of watermelon stomach. *Endoscopy* 2002; **34**: 407-410

4 **Sinha SK**, Udawat HP, Varma S, Lal A, Rana SS, Bhasin DK. Watermelon stomach treated with endoscopic band ligation. *Gastrointest Endosc* 2006; **64**: 1028-1031

5 **Mann NS**, Rachut E. Gastric antral vascular ectasia causing severe hypoalbuminemia and anemia cured by antrectomy. *J Clin Gastroenterol* 2002; **34**: 284-286

6 **Rider JA**, Klotz AP, Kirsner JB. Gastritis with veno-capillary ectasia as a source of massive gastric hemorrhage. *Gastroenterology* 1953; **24**: 118-123

7 **Stotzer PO**, Willén R, Kilander AF. Watermelon stomach: not only an antral disease. *Gastrointest Endosc* 2002; **55**: 897-900

8 **Havanond C**, Havanond P. Argon plasma coagulation therapy for acute non-variceal upper gastrointestinal bleeding. *Cochrane Database Syst Rev* 2005; CD003791

9 **Schmeck-Lindenau HJ**, Kurtz W, Heine M. Inflammatory polyps: an unreported side effect of argon plasma coagulation. *Endoscopy* 1998; **30**: S93-S94

10 **Hoyer N**, Thouet R, Zellweger U. Massive pneumoperitoneum after endoscopic argon plasma coagulation. *Endoscopy* 1998; **30**: S44-S45

11 **Takizawa K**, Oda I, Gotoda T, Yokoi C, Matsuda T, Saito Y, Saito D, Ono H. Routine coagulation of visible vessels may prevent delayed bleeding after endoscopic submucosal dissection--an analysis of risk factors. *Endoscopy* 2008; **40**: 179-183

S- Editor Zhang HN **L- Editor** Hughes D **E- Editor** Liu N

World Journal of Gastrointestinal Endoscopy

Online Submissions: http://www.wjgnet.com/1948-5190office
wjge@wjgnet.com
www.wjgnet.com

World J Gastrointest Endosc 2010 August 16; 2(8): I
ISSN 1948-5190 (online)

Acknowledgments to reviewers of *World Journal of Gastrointestinal Endoscopy*

Many reviewers have contributed their expertise and time to the peer review, a critical process to ensure the quality of *World Journal of Gastrointestinal Endoscopy*. The editors and authors of the articles submitted to the journal are grateful to the following reviewers for evaluating the articles (including those published in this issue and those rejected for this issue) during the last editing time period.

Sherman M Chamberlain, MD, FACP, FACG, AGAF, Associate Professor of Medicine, Section of Gastroenterology, BBR-2538, Medical College of Georgia, Augusta, GA 30912, United States

Viktor E Eysselein, MD, Professor of Medicine, Division of Gastroenterology, Harbor-UCLA Medical Center, 1000 W. Carson Street, Box 483, Torrance, CA 90509, United States

Carlo M Girelli, MD, 1st Department of Internal Medicine, Service of Gastroenterology and Digestive Endoscopy, Hospital of Busto Arsizio, Via Arnaldo da Brescia, Busto Arsizio, VA 121052, Italy

Lesur Gilles, MD, Hopital Ambroise Paré, 9 avenue Charles de Gaulle, Boulogne 92100, France

Dimitrios Kapetanos, MD, Gastroenterology Department, George Papanikolaou Hospital, Exohi, Thessaloniki 57010, Greece

Alfredo José Lucendo, MD, PhD, Department of Gastroenterology, Hospital General de Tomelloso, Vereda de Socuéllamos, s/n, Tomelloso 13700, Spain

Vasileios Panteris, MD, FEBG, Gastroenterologist, Consultant, Deptartment of Gastroenterology, "St. Panteleimon" General Hospital of Nikaia, Athens 13231, Greece

Kaushal K Prasad, Associate Professor, Chief, Division of GE Histopathology, Department of Superspeciality of Gastroenterology, Post Graduate Institute of Medical Education and Research, Chandigarh, UT 160012, India

Jose LS Souza, MD, Department of Gastroenterology, University of São Paulo, São Paulo 05403-000, Brizal

Kazuki Sumiyama, MD, PhD, Department of Endoscopy, The Jikei University School of Medicine, 3-25-8 Nishi Shinbashi, Minato-ku, Tokyo 105-8461, Japan

Shinji Tanaka, MD, PhD, Professor, Department of Endoscopy, Hiroshima University Hospital, 1-2-3 Kasumi, Minami-ku, Hiroshima 734-8551, Japan

World Journal of Gastrointestinal Endoscopy

Online Submissions: http://www.wjgnet.com/1948-5190office
wjge@wjgnet.com
www.wjgnet.com

World J Gastrointest Endosc 2010 August 16; 2(8): I
ISSN 1948-5190 (online)

Meetings

Events Calendar 2010

January 25-26
Tamilnadu, India
International Conference on Medical Negligence and Litigation in Medical Practice

January 25-29
Waikoloa, HI, United States
Selected Topics in Internal Medicine

January 26-27
Dubai, United Arab Emirates
2nd Middle East Gastroenterology Conference

February 11-13
Fort Lauderdale, FL, United States
21th Annual International Colorectal Disease Symposium

February 26-28
Carolina, United States
First Symposium of GI Oncology at The Caribbean

March 05-07
Peshawar, Pakistan
26th Pakistan Society of Gastroenterology & Endoscopy Meeting

March 12-14
Bhubaneswar, India
18th Annual Meeting of Indian National Association for Study of the Liver

March 25-28
Beijing, China
The 20th Conference of the Asian Pacific Association for the Study of the Liver

March 27-28
San Diego, California, United States
25th Annual New Treatments in Chronic Liver Disease

April 07-09
Dubai, United Arab Emirates
The 6th Emirates Gastroenterology and Hepatology Conference, EGHC 2010

April 14-17
Landover, Maryland, United States
12th World Congress of Endoscopic Surgery

April 14-18
Vienna, Austria
The International Liver Congress™ 2010

April 28-May 01
Dubrovnik, Croatia
3rd Central European Congress of surgery and the 5th Croatian Congress of Surgery

May 01-05
New Orleans, LA, United States
Digestive Disease Week Annual Meeting

May 15-19
Minneapolis, MN, United States
American Society of Colon and Rectal Surgeons Annual Meeting

June 04-06
Chicago, IL, United States
American Society of Clinical Oncologists Annual Meeting

June 16-19
Hong Kong, China
ILTS: International Liver Transplantation Society ILTS Annual International Congress

June 20-23
Mannheim, Germany
16th World Congress for Bronchoesophagology-WCBE

August 28-31
Boston, Massachusetts, United States
10th OESO World Congress on Diseases of the Oesophagus 2010

September 10-12
Montreal, Canada
International Liver Association's Fourth Annual Conference

September 11-12
La Jolla, CA, United States
New Advances in Inflammatory Bowel Disease

September 16-18
Prague, Czech Republic
Prague Hepatology Meeting 2010

September 23-26
Prague, Czech Republic
The 1st World Congress on Controversies in Gastroenterology & Liver Diseases

October 07-09
Belgrade, Serbia
The 7th Biannual International Symposium of Society of Coloproctology

October 15-20
San Antonio, TX, United States
ACG 2010: American College of Gastroenterology Annual Scienitfic Meeting

October 23-27
Barcelona, Spain
18th United European Gastroenterology Week

October 29-November 02
Boston, Massachusetts, United States
The Liver Meeting® 2010--AASLD's 61st Annual Meeting

November 13-14
San Francisco, CA, United States
Case-Based Approach to the Management of Inflammatory Bowel Disease

World Journal of Gastrointestinal Endoscopy

Online Submissions: http://www.wjgnet.com/1948-5190office
wjge@wjgnet.com
www.wjgnet.com

World J Gastrointest Endosc 2010 August 16; 2(8): I-V
ISSN 1948-5190 (online)

Instructions to authors

GENERAL INFORMATION

World Journal of Gastrointestinal Endoscopy (*World J Gastrointest Endosc*, *WJGE*, online ISSN 1948-5190, DOI: 10.4253), is a monthly, open-access (OA), peer-reviewed online journal supported by an editorial board of 400 experts in gastrointestinal endoscopy from 45 countries.

The biggest advantage of the OA model is that it provides free, full-text articles in PDF and other formats for experts and the public without registration, which eliminates the obstacle that traditional journals possess and usually delays the speed of the propagation and communication of scientific research results.

The role of academic journals is to exhibit the scientific levels of a country, a university, a center, a department, and even a scientist, and build an important bridge for communication between scientists and the public. As we all know, the significance of the publication of scientific articles lies not only in disseminating and communicating innovative scientific achievements and academic views, as well as promoting the application of scientific achievements, but also in formally recognizing the "priority" and "copyright" of innovative achievements published, as well as evaluating research performance and academic levels. So, to realize these desired attributes of *WJGE* and create a well-recognized journal, the following four types of personal benefits should be maximized. The maximization of personal benefits refers to the pursuit of the maximum personal benefits in a well-considered optimal manner without violation of the laws, ethical rules and the benefits of others. (1) Maximization of the benefits of editorial board members: The primary task of editorial board members is to give a peer review of an unpublished scientific article via online office system to evaluate its innovativeness, scientific and practical values and determine whether it should be published or not. During peer review, editorial board members can also obtain cutting-edge information in that field at first hand. As leaders in their field, they have priority to be invited to write articles and publish commentary articles. We will put peer reviewers' names and affiliations along with the article they reviewed in the journal to acknowledge their contribution; (2) Maximization of the benefits of authors: Since *WJGE* is an open-access journal, readers around the world can immediately download and read, free of charge, high-quality, peer-reviewed articles from *WJGE* official website, thereby realizing the goals and significance of the communication between authors and peers as well as public reading; (3) Maximization of the benefits of readers: Readers can read or use, free of charge, high-quality peer-reviewed articles without any limits, and cite the arguments, viewpoints, concepts, theories, methods, results, conclusion or facts and data of pertinent literature so as to validate the innovativeness, scientific and practical values of their own research achievements, thus ensuring that their articles have novel arguments or viewpoints, solid evidence and correct conclusion; and (4) Maximization of the benefits of employees: It is an iron law that a first-class journal is unable to exist without first-class editors, and only first-class editors can create a first-class academic journal. We insist on strengthening our team cultivation and construction so that every employee, in an open, fair and transparent environment, could contribute their wisdom to edit and publish high-quality articles, thereby realizing the maximization of the personal benefits of editorial board members, authors and readers, and yielding the greatest social and economic benefits.

The major task of *WJGE* is to report rapidly the most recent results in basic and clinical research on gastrointestinal endoscopy including: gastroscopy, intestinal endoscopy, colonoscopy, capsule endoscopy, laparoscopy, interventional diagnosis and therapy, as well as advances in technology. Emphasis is placed on the clinical practice of treating gastrointestinal diseases with or under endoscopy. Papers on advances and application of endoscopy-associated techniques, such as endoscopic ultrasonography, endoscopic retrograde cholangiopancreatography, endoscopic submucosal dissection and endoscopic balloon dilation are also welcome.

The columns in the issues of *WJGE* will include: (1) Editorial: To introduce and comment on major advances and developments in the field; (2) Frontier: To review representative achievements, comment on the state of current research, and propose directions for future research; (3) Topic Highlight: This column consists of three formats, including (A) 10 invited review articles on a hot topic, (B) a commentary on common issues of this hot topic, and (C) a commentary on the 10 individual articles; (4) Observation: To update the development of old and new questions, highlight unsolved problems, and provide strategies on how to solve the questions; (5) Guidelines for Basic Research: To provide guidelines for basic research; (6) Guidelines for Clinical Practice: To provide guidelines for clinical diagnosis and treatment; (7) Review: To review systemically progress and unresolved problems in the field, comment on the state of current research, and make suggestions for future work; (8) Original Article: To report innovative and original findings in gastrointestinal endoscopy; (9) Brief Article: To briefly report the novel and innovative findings in gastrointestinal endoscopy; (10) Case Report: To report a rare or typical case; (11) Letters to the Editor: To discuss and make reply to the contributions published in *WJGE*, or to introduce and comment on a controversial issue of general interest; (12) Book Reviews: To introduce and comment on quality monographs of gastrointestinal endoscopy; and (13) Guidelines: To introduce consensuses and guidelines reached by international and national academic authorities worldwide on basic research and clinical practice in gastrointestinal endoscopy.

CSSN
ISSN 1948-5190 (online)

Published by
Baishideng Publishing Group Co., Limited.

SUBMISSION OF MANUSCRIPTS

Manuscripts should be typed in 1.5 line spacing and 12 pt. Book Antiqua with ample margins. Number all pages consecutively, and start each of the following sections on a new page: Title

Page, Abstract, Introduction, Materials and Methods, Results, Discussion, Acknowledgements, References, Tables, Figures, and Figure Legends. Neither the editors nor the publisher are responsible for the opinions expressed by contributors. Manuscripts formally accepted for publication become the permanent property of Baishideng Publishing Group Co., Limited, and may not be reproduced by any means, in whole or in part, without the written permission of both the authors and the publisher. We reserve the right to copy-edit and put onto our website accepted manuscripts. Authors should follow the relevant guidelines for the care and use of laboratory animals of their institution or national animal welfare committee. For the sake of transparency in regard to the performance and reporting of clinical trials, we endorse the policy of the International Committee of Medical Journal Editors to refuse to publish papers on clinical trial results if the trial was not recorded in a publicly-accessible registry at its outset. The only register now available, to our knowledge, is http://www. clinicaltrials.gov sponsored by the United States National Library of Medicine and we encourage all potential contributors to register with it. However, in the case that other registers become available you will be duly notified. A letter of recommendation from each author's organization should be provided with the contributed article to ensure the privacy and secrecy of research is protected.

Authors should retain one copy of the text, tables, photographs and illustrations because rejected manuscripts will not be returned to the author(s) and the editors will not be responsible for loss or damage to photographs and illustrations sustained during mailing.

Online submissions

Manuscripts should be submitted through the Online Submission System at: wjge@wjgnet.com. Authors are highly recommended to consult the ONLINE INSTRUCTIONS TO AUTHORS (http://www.wjgnet.com/1948-5190/g_info_20100316080002.htm) before attempting to submit online. For assistance, authors encountering problems with the Online Submission System may send an email describing the problem to http://www.wjgnet.com/1948-5190office/, or by telephone: +86-10-59080038. If you submit your manuscript online, do not make a postal contribution. Repeated online submission for the same manuscript is strictly prohibited.

MANUSCRIPT PREPARATION

All contributions should be written in English. All articles must be submitted using word-processing software. All submissions must be typed in 1.5 line spacing and 12 pt. Book Antiqua with ample margins. Style should conform to our house format. Required information for each of the manuscript sections is as follows:

Title page

Title: Title should be less than 12 words.

Running title: A short running title of less than 6 words should be provided.

Authorship: Authorship credit should be in accordance with the standard proposed by International Committee of Medical Journal Editors, based on (1) substantial contributions to conception and design, acquisition of data, or analysis and interpretation of data; (2) drafting the article or revising it critically for important intellectual content; and (3) final approval of the version to be published. Authors should meet conditions 1, 2, and 3.

Institution: Author names should be given first, then the complete name of institution, city, province and postcode. For example, Xu-Chen Zhang, Li-Xin Mei, Department of Pathology, Chengde Medical College, Chengde 067000, Hebei Province, China. One author may be represented from two institutions, for example, George Sgourakis, Department of General, Visceral, and Transplantation Surgery, Essen 45122, Germany; George Sgourakis, 2nd Surgical Department, Korgialenio-Benakio Red Cross Hospital, Athens 15451, Greece

Author contributions: The format of this section should be: Author contributions: Wang CL and Liang L contributed equally to this work; Wang CL, Liang L, Fu JF, Zou CC, Hong F and Wu XM designed the research; Wang CL, Zou CC, Hong F and Wu XM performed the research; Xue JZ and Lu JR contributed new reagents/analytic tools; Wang CL, Liang L and Fu JF analyzed the data; and Wang CL, Liang L and Fu JF wrote the paper.

Supportive foundations: The complete name and number of supportive foundations should be provided, e.g., Supported by National Natural Science Foundation of China, No. 30224801

Correspondence to: Only one corresponding address should be provided. Author names should be given first, then author title, affiliation, the complete name of institution, city, postcode, province, country, and email. All the letters in the email should be in lower case. A space interval should be inserted between country name and email address. For example, Montgomery Bissell, MD, Professor of Medicine, Chief, Liver Center, Gastroenterology Division, University of California, Box 0538, San Francisco, CA 94143, United States. montgomery.bissell@ucsf.edu

Telephone and fax: Telephone and fax should consist of +, country number, district number and telephone or fax number, e.g., Telephone: +86-10-59080039 Fax: +86-10-85381893

Peer reviewers: All articles received are subject to peer review. Normally, three experts are invited for each article. Decision for acceptance is made only when at least two experts recommend an article for publication. Reviewers for accepted manuscripts are acknowledged in each manuscript, and reviewers of articles which were not accepted will be acknowledged at the end of each issue. To ensure the quality of the articles published in *WJGE*, reviewers of accepted manuscripts will be announced by publishing the name, title/position and institution of the reviewer in the footnote accompanying the printed article. For example, reviewers: Professor Jing-Yuan Fang, Shanghai Institute of Digestive Disease, Shanghai, Affiliated Renji Hospital, Medical Faculty, Shanghai Jiaotong University, Shanghai, China; Professor Xin-Wei Han, Department of Radiology, The First Affiliated Hospital, Zhengzhou University, Zhengzhou, Henan Province, China; and Professor Anren Kuang, Department of Nuclear Medicine, Huaxi Hospital, Sichuan University, Chengdu, Sichuan Province, China.

Abstract

There are unstructured abstracts (no more than 256 words) and structured abstracts (no more than 480). The specific requirements for structured abstracts are as follows:

An informative, structured abstracts of no more than 480 words should accompany each manuscript. Abstracts for original contributions should be structured into the following sections. AIM (no more than 20 words): Only the purpose should be included. Please write the aim as the form of "To investigate/study/…; MATERIALS AND METHODS (no more than 140 words); RESULTS (no more than 294 words): You should present *P* values where appropriate and must provide relevant data to illustrate how they were obtained, e.g. 6.92 ± 3.86 *vs* 3.61 ± 1.67, $P < 0.001$; CONCLUSION (no more than 26 words).

Key words

Please list 5-10 key words, selected mainly from *Index Medicus*, which reflect the content of the study.

Text

For articles of these sections, original articles, rapid communication and case reports, the main text should be structured into the following sections: INTRODUCTION, MATERIALS AND METHODS, RESULTS and DISCUSSION, and should include appropriate Figures and Tables. Data should be presented in the main text or in Figures and Tables, but not in both. The main text format of these sections, editorial, topic highlight, case report, letters to the editors, can be found at: http://www.wjgnet.com/1948-5190/g_info_20100316080002.htm.

Illustrations

Figures should be numbered as 1, 2, 3, *etc.*, and mentioned clearly in the main text. Provide a brief title for each figure on a separate page. Detailed legends should not be provided under the figures. This part should be added into the text where the figures are applicable. Figures should be either Photoshop or Illustrator files (in tiff, eps, jpeg formats) at high-resolution. Examples can be found at: http://www.wjgnet.com/1007-9327/13/4520.pdf; http://www.wjgnet.com/1007-9327/13/4554.pdf; http://www.wjgnet.com/1007-9327/13/4891.pdf; http://www.wjgnet.com/1007-9327/13/4986.pdf; http://www.wjgnet.com/1007-9327/13/4498.pdf. Keeping all elements compiled is necessary in line-art image. Scale bars should be used rather than magnification factors, with the length of the bar defined in the legend rather than on the bar itself. File names should identify the figure and panel. Avoid layering type directly over shaded or textured areas. Please use uniform legends for the same subjects. For example: Figure 1 Pathological changes in atrophic gastritis after treatment. A: ...; B: ...; C: ...; D: ...; E: ...; F: ...; G: …*etc.* It is our principle to publish high resolution-figures for the printed and E-versions.

Tables

Three-line tables should be numbered 1, 2, 3, *etc.*, and mentioned clearly in the main text. Provide a brief title for each table. Detailed legends should not be included under tables, but rather added into the text where applicable. The information should complement, but not duplicate the text. Use one horizontal line under the title, a second under column heads, and a third below the Table, above any footnotes. Vertical and italic lines should be omitted.

Notes in tables and illustrations

Data that are not statistically significant should not be noted. $^{a}P < 0.05$, $^{b}P < 0.01$ should be noted ($P > 0.05$ should not be noted). If there are other series of *P* values, $^{c}P < 0.05$ and $^{d}P < 0.01$ are used. A third series of *P* values can be expressed as $^{e}P < 0.05$ and $^{f}P < 0.01$. Other notes in tables or under illustrations should be expressed as ^{1}F, ^{2}F, ^{3}F; or sometimes as other symbols with a superscript (Arabic numerals) in the upper left corner. In a multi-curve illustration, each curve should be labeled with ●, ○, ■, □, ▲, △, *etc.*, in a certain sequence.

Acknowledgments

Brief acknowledgments of persons who have made genuine contributions to the manuscript and who endorse the data and conclusions should be included. Authors are responsible for obtaining written permission to use any copyrighted text and/or illustrations.

REFERENCES

Coding system

The author should number the references in Arabic numerals according to the citation order in the text. Put reference numbers in square brackets in superscript at the end of citation content or after the cited author's name. For citation content which is part of the narration, the coding number and square brackets should be typeset normally. For example, "Crohn's disease (CD) is associated with increased intestinal permeability[1,2]". If references are cited directly in the text, they should be put together within the text, for example, "From references[19,22-24], we know that..."

When the authors write the references, please ensure that the order in text is the same as in the references section, and also ensure the spelling accuracy of the first author's name. Do not list the same citation twice.

PMID and DOI

Pleased provide PubMed citation numbers to the reference list, e.g. PMID and DOI, which can be found at http://www.ncbi.nlm.nih.gov/sites/entrez?db=pubmed and http://www.crossref.org/SimpleTextQuery/, respectively. The numbers will be used in E-version of this journal.

Style for journal references

Authors: the name of the first author should be typed in bold-faced letters. The family name of all authors should be typed with the initial letter capitalized, followed by their abbreviated first and middle initials. (For example, Lian-Sheng Ma is abbreviated as Ma LS, Bo-Rong Pan as Pan BR). The title of the cited article and italicized journal title (journal title should be in its abbreviated form as shown in PubMed), publication date, volume number (in black), start page, and end page [PMID: 11819634 DOI: 10.3748/wjg.13.5396].

Style for book references

Authors: the name of the first author should be typed in bold-faced letters. The surname of all authors should be typed with the initial letter capitalized, followed by their abbreviated middle and first initials. (For example, Lian-Sheng Ma is abbreviated as Ma LS, Bo-Rong Pan as Pan BR) Book title. Publication number. Publication place: Publication press, Year: start page and end page.

Format

Journals

English journal article (list all authors and include the PMID where applicable)

1 **Jung EM**, Clevert DA, Schreyer AG, Schmitt S, Rennert J, Kubale R, Feuerbach S, Jung F. Evaluation of quantitative contrast harmonic imaging to assess malignancy of liver

tumors: A prospective controlled two-center study. *World J Gastroenterol* 2007; **13**: 6356-6364 [PMID: 18081224 DOI: 10.3748/wjg.13.6356]

Chinese journal article (list all authors and include the PMID where applicable)

2 **Lin GZ**, Wang XZ, Wang P, Lin J, Yang FD. Immunologic effect of Jianpi Yishen decoction in treatment of Pixu-diarrhoea. *Shijie Huaren Xiaohua Zazhi* 1999; **7**: 285-287

In press

3 **Tian D**, Araki H, Stahl E, Bergelson J, Kreitman M. Signature of balancing selection in Arabidopsis. *Proc Natl Acad Sci USA* 2006; In press

Organization as author

4 **Diabetes Prevention Program Research Group**. Hypertension, insulin, and proinsulin in participants with impaired glucose tolerance. *Hypertension* 2002; **40**: 679-686 [PMID: 12411462 PMCID:2516377 DOI:10.1161/01.HYP.0000035706.28494.09]

Both personal authors and an organization as author

5 **Vallancien G**, Emberton M, Harving N, van Moorselaar RJ; Alf-One Study Group. Sexual dysfunction in 1, 274 European men suffering from lower urinary tract symptoms. *J Urol* 2003; **169**: 2257-2261 [PMID: 12771764 DOI:10.1097/01.ju.0000067940.76090.73]

No author given

6 21st century heart solution may have a sting in the tail. *BMJ* 2002; **325**: 184 [PMID: 12142303 DOI:10.1136/bmj.325.7357.184]

Volume with supplement

7 **Geraud G**, Spierings EL, Keywood C. Tolerability and safety of frovatriptan with short- and long-term use for treatment of migraine and in comparison with sumatriptan. *Headache* 2002; **42** Suppl 2: S93-99 [PMID: 12028325 DOI:10.1046/j.1526-4610.42.s2.7.x]

Issue with no volume

8 **Banit DM**, Kaufer H, Hartford JM. Intraoperative frozen section analysis in revision total joint arthroplasty. *Clin Orthop Relat Res* 2002; (**401**): 230-238 [PMID: 12151900 DOI:10.1097/00003086-200208000-00026]

No volume or issue

9 Outreach: Bringing HIV-positive individuals into care. *HRSA Careaction* 2002; 1-6 [PMID: 12154804]

Books

Personal author(s)

10 **Sherlock S**, Dooley J. Diseases of the liver and billiary system. 9th ed. Oxford: Blackwell Sci Pub, 1993: 258-296

Chapter in a book (list all authors)

11 **Lam SK**. Academic investigator's perspectives of medical treatment for peptic ulcer. In: Swabb EA, Azabo S. Ulcer disease: investigation and basis for therapy. New York: Marcel Dekker, 1991: 431-450

Author(s) and editor(s)

12 **Breedlove GK**, Schorfheide AM. Adolescent pregnancy. 2nd ed. Wieczorek RR, editor. White Plains (NY): March of Dimes Education Services, 2001: 20-34

Conference proceedings

13 **Harnden P**, Joffe JK, Jones WG, editors. Germ cell tumours V. Proceedings of the 5th Germ cell tumours Conference; 2001 Sep 13-15; Leeds, UK. New York: Springer, 2002: 30-56

Conference paper

14 **Christensen S**, Oppacher F. An analysis of Koza's computational effort statistic for genetic programming. In: Foster JA, Lutton E, Miller J, Ryan C, Tettamanzi AG, editors. Genetic programming. EuroGP 2002: Proceedings of the 5th European Conference on Genetic Programming; 2002 Apr 3-5; Kinsdale, Ireland. Berlin: Springer, 2002: 182-191

Electronic journal (list all authors)

15 Morse SS. Factors in the emergence of infectious diseases. Emerg Infect Dis serial online, 1995-01-03, cited 1996-06-05; 1(1): 24 screens. Available from: URL: http://www.cdc.gov/ncidod/eid/index.htm

Patent (list all authors)

16 **Pagedas AC**, inventor; Ancel Surgical R&D Inc., assignee. Flexible endoscopic grasping and cutting device and positioning tool assembly. United States patent US 20020103498. 2002 Aug 1

Statistical data

Write as mean ± SD or mean ± SE.

Statistical expression

Express *t* test as *t* (in italics), *F* test as *F* (in italics), chi square test as χ^2 (in Greek), related coefficient as *r* (in italics), degree of freedom as υ (in Greek), sample number as *n* (in italics), and probability as *P* (in italics).

Units

Use SI units. For example: body mass, m (B) = 78 kg; blood pressure, p (B) = 16.2/12.3 kPa; incubation time, t (incubation) = 96 h, blood glucose concentration, c (glucose) 6.4 ± 2.1 mmol/L; blood CEA mass concentration, p (CEA) = 8.6 24.5 μg/L; CO_2 volume fraction, 50 mL/L CO_2, not 5% CO_2; likewise for 40 g/L formaldehyde, not 10% formalin; and mass fraction, 8 ng/g, *etc*. Arabic numerals such as 23, 243, 641 should be read 23 243 641.

The format for how to accurately write common units and quantums can be found at: http://www.wjgnet.com/wjg/help/15.doc.

Abbreviations

Standard abbreviations should be defined in the abstract and on first mention in the text. In general, terms should not be abbreviated unless they are used repeatedly and the abbreviation is helpful to the reader. Permissible abbreviations are listed in Units, Symbols and Abbreviations: A Guide for Biological and Medical Editors and Authors (Ed. Baron DN, 1988) published by The Royal Society of Medicine, London. Certain commonly used abbreviations, such as DNA, RNA, HIV, LD50, PCR, HBV, ECG, WBC, RBC, CT, ESR, CSF, IgG, ELISA, PBS, ATP, EDTA, mAb, can be used directly without further explanation.

Italics

Quantities: *t* time or temperature, *c* concentration, *A* area, *l* length, *m* mass, *V* volume.

Genotypes: *gyrA*, *arg* 1, *c myc*, *c fos*, *etc*.

Restriction enzymes: *Eco*RI, *Hin*dI, *Bam*HI, *Kbo* I, *Kpn* I, *etc*.

Biology: *H. pylori*, *E coli*, *etc*.

SUBMISSION OF THE REVISED MANUSCRIPTS AFTER ACCEPTED

Please revise your article according to the revision policies of *WJGE*. The revised version including manuscript and high-resolution image figures (if any) should be copied on a floppy or compact disk. The author should send the revised manuscript, along with printed high-resolution color or black

and white photos, copyright transfer letter, and responses to the reviewers by courier (such as EMS/DHL).

Editorial Office

World Journal of Gastrointestinal Endoscopy
Editorial Department: Room 903, Building D,
Ocean International Center,
No. 62 Dongsihuan Zhonglu,
Chaoyang District, Beijing 100025, China
E-mail: wjge@wjgnet.com
http://www.wjgnet.com
Telephone: +86-10-59080038
Fax: +86-10-85381893

Language evaluation

The language of a manuscript will be graded before it is sent for revision. (1) Grade A: priority publishing; (2) Grade B: minor language polishing; (3) Grade C: a great deal of language polishing needed; and (4) Grade D: rejected. Revised articles should reach Grade A or B.

Copyright assignment form

Please download a Copyright assignment form from http://www.wjgnet.com/1948-5190/g_info_20100107134847.htm.

Responses to reviewers

Please revise your article according to the comments/suggestions provided by the reviewers. The format for responses to the reviewers' comments can be found at: http://www.wjgnet.com/1948-5190/g_info_20100107134601.htm.

Proof of financial support

For paper supported by a foundation, authors should provide a copy of the document and serial number of the foundation.

Links to documents related to the manuscript

WJGE will be initiating a platform to promote dynamic interactions between the editors, peer reviewers, readers and authors. After a manuscript is published online, links to the PDF version of the submitted manuscript, the peer-reviewers' report and the revised manuscript will be put on-line. Readers can make comments on the peer reviewer's report, authors' responses to peer reviewers, and the revised manuscript. We hope that authors will benefit from this feedback and be able to revise the manuscript accordingly in a timely manner.

Science news releases

Authors of accepted manuscripts are suggested to write a science news item to promote their articles. The news will be released rapidly at EurekAlert/AAAS (http://www.eurekalert.org). The title for news items should be less than 90 characters; the summary should be less than 75 words; and main body less than 500 words. Science news items should be lawful, ethical, and strictly based on your original content with an attractive title and interesting pictures.

Publication fee

Authors of accepted articles must pay a publication fee.
EDITORIAL, TOPIC HIGHLIGHTS, BOOK REVIEWS and LETTERS TO THE EDITOR are published free of charge.