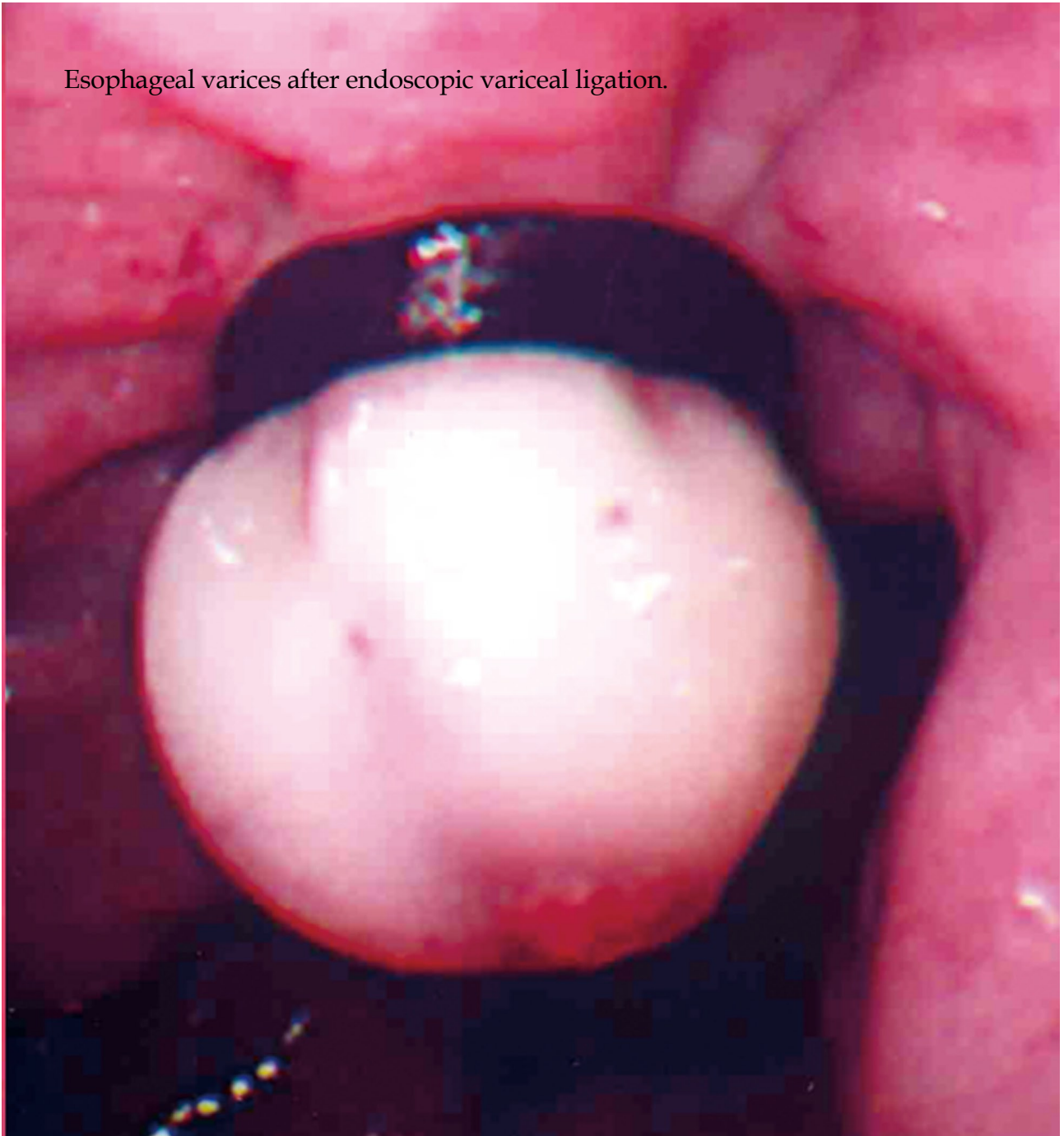



Esophageal varices after endoscopic variceal ligation.





World Journal of Gastrointestinal Endoscopy

A peer-reviewed, online, open-access journal of gastrointestinal endoscopy

Editorial Board

2009-2013

The World Journal of Gastrointestinal Endoscopy Editorial Board consists of 143 members, representing a team of worldwide experts in gastrointestinal endoscopy. They are from 28 countries, including Australia (3), Belgium (2), Brazil (1), Canada (2), China (7), Ecuador (1), Finland (1), France (4), Germany (11), Greece (6), Hungary (2), India (4), Ireland (1), Israel (3), Italy (12), Japan (27), Lithuania (1), Mexico (1), Poland (1), Romania (1), South Korea (4), Spain (8), Sweden (1), Thailand (2), Netherlands (1), Turkey (2), United Kingdom (4), and United States (30).

PRESIDENT AND EDITOR-IN-CHIEF

Lian-Sheng Ma, *Beijing*

STRATEGY ASSOCIATE

EDITORS-IN-CHIEF

Kazuya Akahoshi, *Iizuka*

William Robert Brugge, *Massachusetts*

Qiang Cai, *Georgia*

Juan J Vila Costas, *Pamplona*

Atsushi Irisawa, *Fukushima*

Andreas Sieg, *Heidelberg*

Gaetana Ilaria Tarantino, *Palermo*

Tony CK Tham, *Northern Ireland*

Konstantinos Triantafyllou, *Haidari*

GUEST EDITORIAL BOARD

MEMBERS

Bor-Shyang Sheu, *Tainan*

Sheng-Lei Yan, *Tainan*

MEMBERS OF THE EDITORIAL BOARD



Australia

Michael J Bourke, *Sydney*

Rupert W Leong, *Concord*

Rajvinder Singh, *South Australia*



Belgium

Christophe Moreno, *Brussel*

Tom G Moreels, *Antwerp*



Brazil

Everson LA Artifon, *Sao Paulo*



Canada

André Roy, *Québec*

Brian Michael Yan, *Alberta*



China

Ka Ho Lok, *Hong Kong*

Fu-Yu Li, *Chengdu*

Tian-Le Ma, *Shanghai*

Philip Wai Yan Chiu, *Hong Kong*



Ecuador

Carlos Robles-Medranda, *Portoviejo*



Finland

Paulina Salminen, *Turku*



France

Lesur Gilles, *Boulogne*

Sylvain Manfredi, *Rennes*

JF Rey, *Saint Laurent Du Var Cedex*

José Sahel, *Marseille*



Germany

P Born, *Munich*

Dirk Domagk, *Muenster*

Günter Kampf, *Hamburg*

Georg FBA Kähler, *Mannheim*

Ralf Kiesslich, *Mainz*

Oliver Pech, *Wiesbaden*

Claus Schäfer, *Munich*

Hubert J Scheidbach, *Magdeburg*

Thomas W Spahn, *Schwerte*

Uwe Will, *Gera*



Greece

Georgios K Anagnostopoulos, *Athens*

Dimitrios Kapetanios, *Thessaloniki*

John A Karagiannis, *Athens*

Spiros D Ladas, *Athens*

Konstantinos A Papadakis, *Heraklion*



Hungary

Lujber László, *Pecs*

István Rác, *Gyor*



India

Sri Prakash Misra, *Allahabad*

Sandeep Nijhawan, *Rajasthan*

D Nageshwar Reddy, *Hyderabad*

Omar Javed Shah, *Kashmir*

**Ireland**

Eamonn Martin Quigley, *Cork*

**Israel**

Simon Bar-Meir, *Ramat Gan*
Rami Eliakim, *Haifa*
Zvi Fireman, *Hadera*

**Italy**

Giampaolo Bresci, *Pisa*
Salvatore MA Campo, *Rome*
Carlo M Girelli, *Busto Arsizio*
Andrea Moglia, *Pisa*
Gabriele Masselli, *Rome*
Mauro Manno, *Baggiogara di Modena*
Raffaele Pezzilli, *Bologna*
Emanuele Rondonotti, *Milano*
Franco Radaelli, *Como*
Marmo Riccardo, *Via Luigi Curto Polla*
Antonio Tucci, *Bologna*

**Japan**

Shotaro Enomoto, *Wakayama*
Akira Hokama, *Okinawa*
Akira Horiuchi, *Komagane*
Makoto Hashizume, *Fukuoka*
Atsushi Imagawa, *Kagawa*
Haruhiro Inoue, *Yokohama*
Hiroo Imazu, *Tokyo*
Ryu Ishihara, *Osaka*
Takao Itoi, *Tokyo*
Keiichiro Kume, *Kitakyusyu*
Satoru Kakizaki, *Gunma*
Terumi Kamisawa, *Tokyo*
Takashi Kawai, *Tokyo*
Akihiro Mori, *Inuyama Aichi*
Iruru Maetani, *Tokyo*
Naoki Muguruma, *Tokushima*
Kazuichi Okazaki, *Osaka*
Yutaka Saito, *Tokyo*
Takashi Shida, *Chiba*
Kazuki Sumiyama, *Tokyo*
Gen Tohda, *Fukui*
Kyosuke Tanaka, *Mie*
Shinji Tanaka, *Hiroshima*

Tomoyuki Tsujikawa, *Shiga*
Noriya Uedo, *Osaka*

**Lithuania**

Laimas Virginijus Jonaitis, *Kaunas*

**Mexico**

OT Teramoto-Matsubara, *México*

**Poland**

Arthur Hoffman, *Mainz*

**Romania**

Mihai Ciocirlan, *Bucharest*

**South Korea**

Young-Tae Bak, *Seoul*
Seong Woo Jeon, *Daegu*
Dong Kyun Park, *Incheon*
Si-Young Song, *Seoul*

**Spain**

Adolfo P Blanco, *Asturias*
Jesús García-Cano, *Cuenca*
Alfredo José Lucendo, *Tomelloso*
G Payeras Llodrá, *Madrid*
Eduardo Redondo-Cerezo, *Cuenca*
Luis Rodrigo, *Oviedo*
Santiago Vivas, *León*

**Sweden**

Carlos A Rubio, *Stockholm*

**Thailand**

Somchai Amornytin, *Bangkok*
Rungsun Rerknimitr, *Bangkok*

**The Netherlands**

Chris JJ Mulder, *Amsterdam*

**Turkey**

Selcuk Disibeyaz, *Nkara*
Mehmet Eken, *Istanbul*

**United Kingdom**

Annette Fritscher-Ravens, *London*
Krish Ragunath, *Nottingham*
Jayesh Sagar, *Wishaw*

**United States**

Douglas G Adler, *Utah*
Jamie S Barkin, *Florida*
James Stephen Barthel, *Florida*
Sherman M Chamberlain, *Georgia*
Lawrence B Cohen, *New York*
Viktor Ernst Eysselein, *Torrance*
Ronnie Fass, *Southern Arizona*
Georg Feldmann, *Maryland*
David Friedel, *New York*
Denise W Gee, *Massachusetts*
Samuel A Giday, *Maryland*
Sammy Ho, *New York*
Michel Kahaleh, *Virginia*
Simon K Lo, *California*
Christopher Lawrence, *Charleston*
Hiroshi Mashimo, *Massachusetts*
Massimo Raimondo, *Jacksonville*
Robert J Richards, *New York*
Praveen Roy, *New Mexico*
Prateek Sharma, *Kansas*
Bo Shen, *Ohio*
Bennie Ray Upchurch, *Ohio*
Shyam Varadarajulu, *Alabama*
Marcelo F Vela, *South Carolina*
Irving Waxman, *Illinois*
C Mel Wilcox, *Alabama*
Field Farrar Willingham, *Massachusetts*
Shuhehi Yoshida, *Massachusetts*

Contents

Monthly Volume 2 Number 2 February 16, 2010

- | | | |
|---|----|--|
| EDITORIAL | 47 | Pulmonary or otolaryngologic extraesophageal manifestations in patients with gastroesophageal reflux disease
<i>Bresci G, Sacco R</i> |
| GUIDELINES FOR CLINICAL PRACTICE | 50 | Transnasal endoscopic biliary drainage as a rescue management for the treatment of acute cholangitis
<i>Itoi T, Sofuni A, Itokawa F, Tsuchiya T, Kurihara T, Ishii K, Tsuji S, Ikeuchi N, Moriyasu F</i> |
| | 54 | Endoscopic hemostasis techniques for upper gastrointestinal hemorrhage: A review
<i>Anjiki H, Kamisawa T, Sanaka M, Ishii T, Kuyama Y</i> |
| REVIEW | 61 | Intralesional steroid injection therapy in the management of resistant gastrointestinal strictures
<i>Kochhar R, Poornachandra KS</i> |
| BRIEF ARTICLE | 69 | Short term results of endoscopic submucosal dissection in superficial esophageal squamous cell neoplasms
<i>Nonaka K, Arai S, Ishikawa K, Nakao M, Nakai Y, Togawa O, Nagata K, Shimizu M, Sasaki Y, Kita H</i> |
| CASE REPORT | 75 | Trimming of a migrated metal stent for malignant colonic stricture using argon plasma coagulation
<i>Rao KV, Beri GD, Wang WW</i> |

Contents

World Journal of Gastrointestinal Endoscopy
Volume 2 Number 2 February 16, 2010

ACKNOWLEDGMENTS I Acknowledgments to reviewers of *World Journal of Gastrointestinal Endoscopy*

APPENDIX I Meetings
I-V Instructions to authors

ABOUT COVER Anjiki H, Kamisawa T, Sanaka M, Ishii T, Kuyama Y. Endoscopic hemostasis for upper gastrointestinal hemorrhage: A review
World J Gastrointest Endosc 2010; 2(2): 54-60
<http://www.wjgnet.com/1948-5190/full/v2/i2/54.htm>

AIM AND SCOPE *World Journal of Gastrointestinal Endoscopy* (*World J Gastrointest Endosc*, *WJGE*, online ISSN 1948-5190, DOI: 10.4253), is a monthly, open-access, peer-reviewed journal supported by an editorial board of 143 experts in gastrointestinal endoscopy from 28 countries.
The major task of *WJGE* is to report rapidly the most recent results in basic and clinical research on gastrointestinal endoscopy including: gastroscopy, intestinal endoscopy, colonoscopy, capsule endoscopy, laparoscopy, interventional diagnosis and therapy, as well as advances in technology. Emphasis is placed on the clinical practice of treating gastrointestinal diseases with or under endoscopy. Papers on advances and application of endoscopy-associated techniques, such as endoscopic ultrasonography, endoscopic retrograde cholangiopancreatography, endoscopic submucosal dissection and endoscopic balloon dilation are also welcome.

FLYLEAF I-II Editorial Board

EDITORS FOR THIS ISSUE

Responsible Assistant Editor: Na Liu
Responsible Electronic Editor: Na Lin
Proofing Editor-in-Chief: Lian-Sheng Ma

Responsible Science Editor: Hai-Ning Zhang
Proofing Editorial Office Director: Hai-Ning Zhang

NAME OF JOURNAL
World Journal of Gastrointestinal Endoscopy

LAUNCH DATE
October 15, 2009

SPONSOR
Beijing Baishideng BioMed Scientific Co., Ltd.,
Room 903, Building D, Ocean International Center,
No. 62 Dongsihuan Zhonglu, Chaoyang District,
Beijing 100025, China
Telephone: +86-10-8538-1892
Fax: +86-10-8538-1893
E-mail: baishideng@wjgnet.com
<http://www.wjgnet.com>

EDITING
Editorial Board of *World Journal of Gastrointestinal Endoscopy*,
Room 903, Building D, Ocean International Center,
No. 62 Dongsihuan Zhonglu, Chaoyang District,
Beijing 100025, China
Telephone: +86-10-5908-0038
Fax: +86-10-8538-1893
E-mail: wjge@wjgnet.com
<http://www.wjgnet.com>

PUBLISHING
Beijing Baishideng BioMed Scientific Co., Ltd.,
Room 903, Building D, Ocean International Center,
No. 62 Dongsihuan Zhonglu, Chaoyang District,
Beijing 100025, China
Telephone: +86-10-8538-1892
Fax: +86-10-8538-1893
E-mail: baishideng@wjgnet.com
<http://www.wjgnet.com>

SUBSCRIPTION
Beijing Baishideng BioMed Scientific Co., Ltd.,
Room 903, Building D, Ocean International Center,
No. 62 Dongsihuan Zhonglu, Chaoyang District,
Beijing 100025, China
Telephone: +86-10-8538-1892
Fax: +86-10-8538-1893
E-mail: baishideng@wjgnet.com
<http://www.wjgnet.com>

ONLINE SUBSCRIPTION
One-Year Price: 216.00 USD

PUBLICATION DATE
February 16, 2010

CSSN
ISSN 1948-5190 (online)

PRESIDENT AND EDITOR-IN-CHIEF
Lian-Sheng Ma, Beijing

STRATEGY ASSOCIATE EDITORS-IN-CHIEF
Kazuya Akahoshi, *Iizuka*
William Robert Brugge, *Massachusetts*
Qiang Cai, *Georgia*
Juan J Vila Costas, *Pamplona*
Atsushi Irisawa, *Fukushima*
Andreas Sieg, *Heidelberg*
Gaetana Ilaria Tarantino, *Palermo*
Tony CK Tham, *Northern Ireland*
Konstantinos Triantafyllou, *Haidari*

EDITORIAL OFFICE
Hai-Ning Zhang, Director
World Journal of Gastrointestinal Endoscopy
Room 903, Building D, Ocean International Center,
No. 62 Dongsihuan Zhonglu, Chaoyang District,
Beijing 100025, China
Telephone: +86-10-5908-0038
Fax: +86-10-8538-1893
E-mail: wjge@wjgnet.com
<http://www.wjgnet.com>

COPYRIGHT
© 2010 Baishideng. All rights reserved; no part of this publication may be reproduced, stored in a retrieval system, or transmitted in any form or by any means, electronic, mechanical, photocopying, recording, or otherwise without the prior permission of Baishideng. Authors are required to grant *World Journal of Gastrointestinal Endoscopy* an exclusive license to publish.

SPECIAL STATEMENT
All articles published in this journal represent the viewpoints of the authors except where indicated otherwise.

INSTRUCTIONS TO AUTHORS
Full instructions are available online at http://www.wjgnet.com/1948-5190/g_info_14.htm. If you do not have web access please contact the editorial office.

ONLINE SUBMISSION
<http://www.wjgnet.com/1948-5190office/>

Pulmonary or otolaryngologic extraesophageal manifestations in patients with gastroesophageal reflux disease

Giampaolo Bresci, Rodolfo Sacco

Giampaolo Bresci, Rodolfo Sacco, Gastroenterology Department, Cisanello Pisa University Hospital, Pisa 56124, Italy
Rodolfo Sacco, Institute of Internal Medicine, University of Foggia, Viale Pinto, Foggia 71100, Italy

Author contributions: Bresci G designed and wrote the paper; Sacco R critically revised and edited the paper.

Correspondence to: Giampaolo Bresci, MD, Gastroenterology Department, Cisanello Pisa University Hospital, Via Paradisa 2, Pisa 56124, Italy. gbresci@libero.it

Telephone: +39-50-45227 Fax: +39-50-45227

Received: February 3, 2009 Revised: December 6, 2009

Accepted: December 13, 2009

Published online: February 16, 2010

Abstract

The extraesophageal manifestations of gastroesophageal reflux disease that are similar to a heart attack or gastric diseases are well known, while those categorized as pulmonary or otolaryngological are less known and less studied. In this article, we introduce this less known aspect of gastroesophageal reflux.

© 2010 Baishideng. All rights reserved.

Key words: Gastroesophageal reflux; Extraesophageal symptoms; Gastroesophageal reflux disease

Peer reviewer: Bor-Shyang Sheu, MD, Professor, Department of Internal Medicine, Institute of Clinical Medicine, National Cheng Kung University, 138 Sheng Li Road, Tainan 70428, Taiwan, China

Bresci G, Sacco R. Pulmonary or otolaryngologic extraesophageal manifestations in patients with gastroesophageal reflux disease. *World J Gastrointest Endosc* 2010; 2(2): 47-49 Available from: URL: <http://www.wjgnet.com/1948-5190/full/v2/i2/47.htm> DOI: <http://dx.doi.org/10.4253/wjge.v2.i2.47>

INTRODUCTION

The crossing of acid, pepsin and other noxious sub-

stances from the stomach into the esophagus causes of gastroesophageal reflux (GER). This reflux is a normal event in healthy people. It is defined as gastroesophageal reflux disease (GERD) when it causes symptoms related to excessive exposure of the esophageal mucosa to refluxed gastric contents^[1,2]. Prolonged exposure to gastric contents can lead to esophagitis and ulceration; however, GER can occur without esophagitis. GER often presents with typical symptoms, such as heartburn or acid regurgitation. However, nearly 40% of patients might present with a combination of symptoms and signs not directly related to esophageal damage. Such conditions are known as the extraesophageal manifestations of GERD^[3-5]. The extraesophageal manifestations of GER that are similar to heart attack or gastric disorder are well known, while those categorized as pulmonary and/or otolaryngological are less known and less studied. This article analyzes this less well-known aspect of GER.

FEASIBILITY

In contrast to common GERD, with predominant symptoms such as pyrosis (heartburn sensation) and/or acid regurgitation, the symptoms in patients with extraesophageal manifestations depend upon the anatomical structures involved in the acid reflux. The major pulmonary manifestations of GER include asthma, wheezing, cough, and shortness of breath. Moreover, those otolaryngologic manifestations of GER can present as laryngeal disorders, dysphagia, dysphonia, altered salivation, hoarseness, sore throat, and globus sensation. There are various otorhinolaryngological disorders related to GER, and it has been recognized that GER is a possible cause of manifestations localized in the rhino-sinus and auricular district. Furthermore, gingivitis and pitting of dental enamel have been reported in patients with GER.

CLINICAL APPLICATIONS

These pulmonary or otolaryngologic extraesophageal

manifestations of GER have a common pathophysiology, involving microaspiration of acid into the pulmonary tree, the larynx, and pharynx. Moreover these manifestations are mediated by cholinergic vagal pathways and might cause bronchospasm and laryngospasm. Increased GER has been described in up to 80% of asthmatics, but this high prevalence of abnormal acid exposure in asthmatics might be misleading, because wheezing and coughing could result in reflux episodes^[6]. Microaspiration of the stomach contents might bring about changes in the immune system that drive the development of asthma^[7]. GER has been confirmed to be one of the most common causes of chronic coughing^[8,9]. The relationship between coughing and GER is not completely clear, even though GER has been documented to be a cause of chronic coughing in 13%-38% of patients with GER. Chronic coughing in GER has been attributed to irritation of the esophagus and/or upper airways by reflux of gastric contents. There is also evidence to support that coughing might promote GER, probably by increasing the pressure gradient between the thorax and the abdomen or by causing transient lower esophageal sphincter relaxation. The role of extraesophageal reflux in such disorders is underestimated, due to silent symptoms and difficult confirmation of diagnosis. Care must be taken to determine if the patient has these pulmonary or otolaryngologic extraesophageal manifestations of GER, in addition to the typical symptoms of GER. Thus, we must deepen the investigation to rule out the cause of symptoms resulting from other factors. There has been no definite demographic or clinical profile available that permits us to distinguish between patients with and without GERD among those with ear, nose, and throat and pulmonary symptoms or chest pain. Moreover, the symptoms cannot predict the degree of esophagitis or future complications of GERD such as Barrett's esophagus. The diagnosis of reflux disease in these individuals can be challenging, because they might have an absence of heartburn and a negative esophageal mucosa injury during endoscopy. Patients with these symptoms should be a heterogeneous subgroup of GERD, either combined with and without typical esophagitis^[10,11]. The commonly used tests, such as laryngoscopy, upper gastrointestinal endoscopy or pH monitoring, are rather unreliable, with low specificity to define the exact diagnosis for the patients suspected of having extraesophageal symptoms of GERD. The treatment of these individuals is thus based on decrease in volume and potency of GER and protection of the mucosa from acid-induced injury^[12,13]. If the patient's history is typical for pulmonary or otolaryngological extraesophageal manifestations of GERD, an initial trial of empirical therapy (including lifestyle modification, acid suppression, promotility therapy, maintenance therapy, antireflux surgery, and endoscopic therapy) is appropriate. Lifestyle modification may benefit many patients, although these changes alone are unlikely to control extraesophageal symptoms in the majority of such patients. Education of the patient about factors that may precipitate reflux remains reasonable. Numerous studies have indicated the

efficacy of elevation of the head of the bed, decreased fat intake, cessation of smoking, and avoiding recumbency within three hours after meals.

The more the stomach is stretched by food, the higher the tendency to reflux. The tendency is also increased by eating fatty meals, because fat delays gastric emptying. Avoiding large rich meals, particularly in the evening, will reduce the tendency to reflux. Chocolate, peppermint, coffee, fruit juices and alcohol prevent the esophageal sphincter from working properly. Weight loss also reduces stomach acid reflux. When symptoms persist, continuous therapy is required using antacids, antirefluxants (such as alginic acid) and promotility agents. The most effective therapy should be H₂ receptor antagonists or Proton Pump Inhibitors (PPIs), which are highly recommended by consensus as an optimal empirical treatment. Upper gastrointestinal endoscopy is in usual negative. Moreover, even if endoscopy and/or pH monitoring are positive, they will offer a low predictive value to determine the usefulness of therapy.

Patients with GERD-related extraesophageal manifestations have the same requirement for PPI as patients with typical symptoms of GERD. However, the optimal dose and length of PPI therapy remains unclear, due to the paucity and heterogeneity of trials that are often uncontrolled. In a minority of such cases where medical therapy has failed, the problem might be solved by a laparoscopic surgical procedure in which the oesophageal sphincter is strengthened (fundoplication).

EXPERT COMMENTARY

Since GERD is a prevalent condition characterised by frequent relapses, long-term costs of management for this disease are high. Thus, strategies to decrease resource expenditures without impairing the patient's quality of life are desirable. On-demand therapy (one-dose when symptoms occur) and intermittent therapy (short course of medication when symptoms occur) are attractive, as pharmaceutical expenditures might be decreased, and many patients self-medicate *via* this strategy^[14]. An alternative to traditional therapy in order to reduce costs is the step-down therapy^[15], i.e. switching from more potent to less expensive medication once symptoms are alleviated. This approach is successful in the majority of patients and can decrease costs without adversely affecting quality of life.

FIVE-YEAR VIEW

Pulmonary or otolaryngologic extraesophageal manifestations in patients with GER are emerging disorders with specific symptoms in need of clinical alerts. Further work to define quality of life and patient preferences associated with GERD may allow for a proper allocation of resources to manage this specific condition.

REFERENCES

- 1 Kahrilas PJ. Clinical practice. Gastroesophageal reflux disease. *N Engl J Med* 2008; **359**: 1700-1707

- 2 **Kahrilas PJ**, Shaheen NJ, Vaezi MF, Hiltz SW, Black E, Modlin IM, Johnson SP, Allen J, Brill JV. American Gastroenterological Association Medical Position Statement on the management of gastroesophageal reflux disease. *Gastroenterology* 2008; **135**: 1383-1391, 1391.e1-e5
- 3 **DeVault KR**. Gastroesophageal reflux disease: extraesophageal manifestations and therapy. *Semin Gastrointest Dis* 2001; **12**: 46-51
- 4 **Katz PO**. Gastroesophageal reflux disease and extraesophageal disease. *Rev Gastroenterol Disord* 2005; **5** Suppl 2: S31-S38
- 5 **Gurski RR**, da Rosa AR, do Valle E, de Borba MA, Valiati AA. Extraesophageal manifestations of gastroesophageal reflux disease. *J Bras Pneumol* 2006; **32**: 150-160
- 6 **Mujica VR**, Rao SS. Recognizing atypical manifestations of GERD. Asthma, chest pain, and otolaryngologic disorders may be due to reflux. *Postgrad Med* 1999; **105**: 53-55, 60, 63-66
- 7 **Barbas AS**, Downing TE, Balsara KR, Tan HE, Rubinstein GJ, Holzknecht ZE, Collins BH, Parker W, Davis RD, Lin SS. Chronic aspiration shifts the immune response from Th1 to Th2 in a murine model of asthma. *Eur J Clin Invest* 2008; **38**: 596-602
- 8 **Tatar M**, Plevkova J, Brozmanova M, Pecova R, Kollarik M. Mechanisms of the cough associated with rhinosinusitis. *Pulm Pharmacol Ther* 2009; **22**: 121-126
- 9 **Lalloo UG**, Barnes PJ, Chung KF. Pathophysiology and clinical presentations of cough. *J Allergy Clin Immunol* 1996; **98**: S91-S96; discussion S96-S97
- 10 **Heidelbaugh JJ**, Gill AS, Van Harrison R, Nostrant TT. Atypical presentations of gastroesophageal reflux disease. *Am Fam Physician* 2008; **78**: 483-488
- 11 **Kim GH**. [Extraesophageal manifestations of gastroesophageal reflux disease] *Korean J Gastroenterol* 2008; **52**: 69-79
- 12 **Halstead LA**. Extraesophageal manifestations of GERD: diagnosis and therapy. *Drugs Today (Barc)* 2005; **41** Suppl B: 19-26
- 13 **Penagini R**. Extra-oesophageal manifestations of gastro-oesophageal reflux disease: good news... in the long term! *Dig Liver Dis* 2006; **38**: 238-239
- 14 **Inadomi JM**. On-demand and intermittent therapy for gastro-oesophageal reflux disease: economic considerations. *Pharmacoeconomics* 2002; **20**: 565-576
- 15 **Inadomi JM**, Jamal R, Murata GH, Hoffman RM, Lavezo LA, Vigil JM, Swanson KM, Sonnenberg A. Step-down management of gastroesophageal reflux disease. *Gastroenterology* 2001; **121**: 1095-1100

S- Editor Li JL L- Editor Stewart GJ E- Editor Ma WH

Transnasal endoscopic biliary drainage as a rescue management for the treatment of acute cholangitis

Takao Itoi, Atushi Sofuni, Fumihide Itokawa, Takayoshi Tsuchiya, Toshio Kurihara, Kentaro Ishii, Shujiro Tsuji, Nobuhito Ikeuchi, Fuminori Moriyasu

Takao Itoi, Atushi Sofuni, Fumihide Itokawa, Takayoshi Tsuchiya, Toshio Kurihara, Kentaro Ishii, Shujiro Tsuji, Nobuhito Ikeuchi, Fuminori Moriyasu, Department of Gastroenterology and Hepatology, Tokyo Medical University, Tokyo 160-0023, Japan

Author contributions: Itoi T performed this procedure; Itoi T, Sofuni A, and Itokawa F contributed equally to this work; Kurihara T, Tsuchiya T, Ishii K, Tsuji S, Ikeuchi N, performed collected the data; Itoi T and Moriyasu F reviewed this paper.

Correspondence to: Takao Itoi, MD, PhD, Department of Gastroenterology and Hepatology, Tokyo Medical University, Shinjuku-ku, Nishishinjuku 6-7-1, Tokyo 160-0023, Japan. ittoi@tokyo-med.ac.jp

Telephone: +81-3-33426111 Fax: +81-3-53816654

Received: March 18, 2009 Revised: September 2, 2009

Accepted: September 9, 2009

Published online: February 16, 2010

Key words: Transnasal endoscope; Ultrathin endoscope; Biliary drainage

Peer reviewer: Eduardo Redondo-Cerezo, MD, PhD, Sección de Aparato Digestivo, Hospital General Virgen de la Luz, Avenida Hermandad de Donantes de Sangre 1, Cuenca 16002, Spain

Itoi T, Sofuni A, Itokawa F, Tsuchiya T, Kurihara T, Ishii K, Tsuji S, Ikeuchi N, Moriyasu F. Transnasal endoscopic biliary drainage as a rescue management for the treatment of acute cholangitis. *World J Gastrointest Endosc* 2010; 2(2): 50-53 Available from: URL: <http://www.wjgnet.com/1948-5190/full/v2/i2/50.htm> DOI: <http://dx.doi.org/10.4253/wjge.v2.i2.50>

Abstract

Endoscopic biliary drainage has been established to provide effective treatment for acute obstructive jaundice and cholangitis. A recently developed ultrathin transnasal videoendoscope (TNE) is minimally invasive even for critically ill patients and can be performed without conscious sedation. Transnasal endoscopic biliary drainage (TNE-BD) is performed using a front-viewing TNE with approximately 5 mm outer diameter and 2 mm working channel diameter. Finally, 5F naso-biliary tube or plastic stent are placed. Technical success rates are approximately 100% and 70% for post-endoscopic sphincterotomy or placement of self-expandable metallic stent, and intact papilla, respectively. There are no serious complications. In conclusion, although further cases should be accumulated, TNE-BD and in particular, one-step naso-biliary drainage using TNE may be a useful and novel technique for the treatment of acute cholangitis.

© 2010 Baishideng. All rights reserved.

INTRODUCTION

To date, ultrathin endoscopes including transnasal endoscopes have been used for various gastrointestinal conditions^[1,2]. In particular, transnasal endoscopies can be performed without conscious sedation because they are not only less stressful to patients, but also have fewer deleterious hemodynamic effects than the conventional transoral videoendoscope^[3].

Endoscopic biliary drainage has been established for the treatment of acute cholangitis^[4-8]. Recently, a novel approach using less invasive ultrathin forward-viewing endoscopes has been reported for the treatment of acute cholangitis^[9-11]. In this study, we introduce transnasal endoscopic biliary drainage (TNE-BD) using an ultrathin endoscope.

TNE-BD PROCEDURES

Endoscopic retrograde cholangiopancreatography (ERCP) is performed with commercially available transnasal endoscopes or ultrathin pediatric endoscopes. Each specification is shown in Table 1. Prior to the procedure,

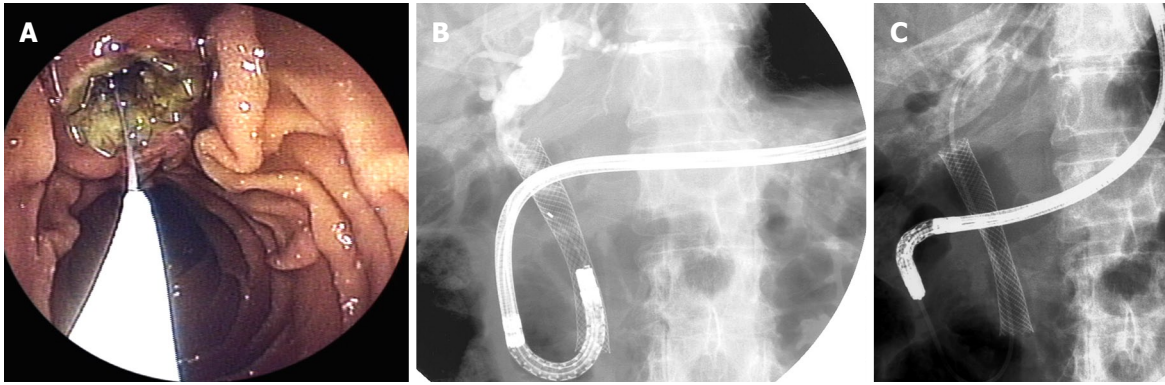


Figure 1 Transnasal endoscopic biliary drainage. A: Endoscopic image shows biliary cannulation by transnasal endoscopy in patients with placement of self-expandable metallic stent; B: Endoscopic cholangiography showed obstruction of stent; C: Transnasal endoscopic naso-biliary drainage could be performed.

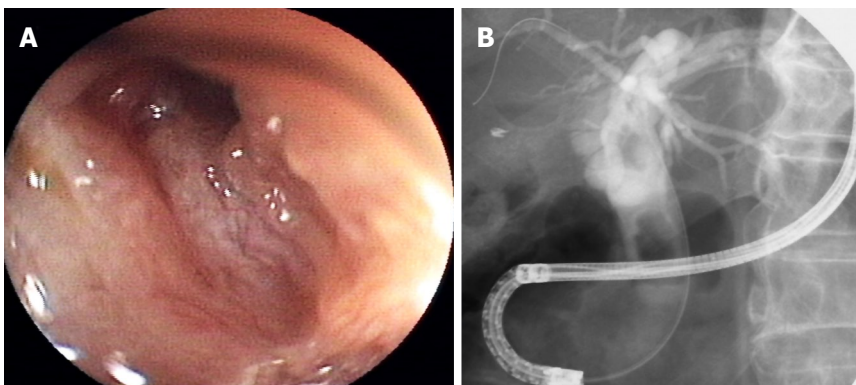


Figure 2 Transnasal endoscopic cholangiography (long scope position). A: Endoscopic image shows orifice of bile duct in patients with post-sphincterotomy; B: Cholangiography showed bile duct stones.

Table 1 Specification of transnasal endoscopes

	GIF-N260	EG-530N2	EG-1580K
Direction of view	Forward-viewing	Forward-viewing	Forward-viewing
Angle of view	120°	120°	140°
Outer diameter (mm)			
Distal end	5	5.9	5.5
Insertion end	5.5	5.9	5.1
Bending section			
Up/Down	210°/90°	210°/90°	210°/120°
Right/Left	100°/100°	100°/100°	NA
Working length (mm)	1100	1100	1050
Total length (mm)	1420	1400	1360
Working channel diameter (mm)	2	2	2

NA: No available.

each nasal cavity is sprayed with 0.05% naphazoline nitrate (Novartis Pharma K.K., Tokyo, Japan) for vasoconstriction. The nasal cavities are then sprayed with 4% lidocaine solution, and the oropharynx with 8% lidocaine solution (both Astra Zeneca Japan Ltd, Osaka, Japan) as topical anesthesia. Endoscopic procedures are performed without conscious sedation. Patients are put in a prone position. The transnasal endoscope is inserted through the nose under direct vision, through the most patent nostril to the pharynx. If insertion is not possible, the other nostril is tried.

The transnasal endoscope is advanced into the first

and second portions of the duodenum (long scope position) (Figures 1 and 2). After confirming the major duodenal papilla, the tip of the thin catheter (5 Fr, PR-110Q, Olympus Medical Systems, Tokyo, Japan) is inserted into the bile duct. However, since the axes of the catheter do not usually match those of the bile duct at long scope position, the sharp angle of the scope is needed to insert a catheter in order to perform cholangiography. In patients post sphincterotomy or with a self-expandable metallic stent (SEMS) in position, selective cannulations can be safely performed without difficulty (Figure 1A-C). Prior to cannulation, endoscopists should understand the orientation at which the catheter is expected to appear on the video display for each endoscope. After deep cannulation of the catheter into the common duct, a 0.018-inch or 0.025-inch stiff-type guidewire (Pathfinder® or Jagwaire®, Boston Scientific Japan, Tokyo, Japan) is advanced into the right or left intrahepatic bile duct. When deep cannulation is difficult, a 0.025-inch Radifocus® guidewire (Terumo Co., Ltd., Tokyo, Japan) is advanced into the intrahepatic bile duct and then replaced by a stiff-type guidewire. When the orifice of the bile duct can not be confirmed by the standard method, the scope is advanced to the 3rd portion of the duodenum, the tip of the scope is then rotated, and the papilla is confirmed while pulling back the tip. Then the catheter is inserted (short scope position) (Figure 3). If bile is sufficiently aspirated, injection of contrast medium is avoided in order to prevent further contamination of the biliary tree.

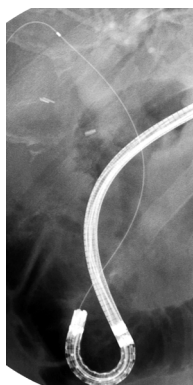


Figure 3 Transnasal endoscopic cholangiography (short scope position). Bile duct cannulation by transnasal endoscopy at the short scope position.

Finally, one or two 5-Fr diameter double pig-tail or straight indwelling biliary stents (ZEBD-5-7, Cook Endoscopy Inc., Winston-Salem, NC, USA), or a 5-Fr straight-tip NBD catheter (ENBD-5-NAG, Cook Endoscopy Inc., Winston-Salem, USA) are placed, following the guidewire.

DISCUSSION

Recently, some endoscopists have revealed that TNE-BD is feasible and safe^[9-12]. Despite established biliary drainage using a conventional duodenoscope, one of greatest motivations to perform the TNE-BD may be that it is minimally invasive even for critically ill patients (Table 2)^[3]. Our important data could reveal that transnasal endoscopy has less hemodynamic effects than the transoral videoendoscope. In particular, endoscopic nasobiliary drainage using a conventional duodenoscope may be cumbersome to convert from an orobiliary to a nasobiliary tube after the endoscope is withdrawn. The endoscopist may be at risk of infectious diseases due to penetration of the skin from biting, while the patients may suffer complications resulting from the blind passage of a finger or forceps into the posterior pharynx^[13]. To avoid these unnecessary risks, a one-step method using transnasal endoscopic nasobiliary drainage has advantages^[10]. Furthermore, there may be the possibility of performing this procedure by the bedside rather than in the endoscopic room although comparatively skillful technique is needed without X-ray.

Although TNE-BD is a novel and unique drainage technique, there is no argument whether this can be an alternative technique to conventional ERCP. Firstly, TNE has some disadvantages. Side effects of TNE are rare, but the incidence ranges between 1.5%-22.6%^[2]. The most common is transnasal insertion. Dumortier reported that failures in TNE were more likely to occur in young female patients undergoing TNE with instruments larger than 5.9 mm^[2]. In reports of TNE-BD^[9-12] there was no failure of insertion, probably because of the small sample size. Further investigation with a large number of patients is necessary, and the development of more flexible and thinner scopes may overcome the side effects of transnasal insertion in the near future.

One of most serious drawbacks of TNE-BD is success rate of selective cannulation, in particular of the

Table 2 Advantage and drawbacks of transnasal endoscopic biliary drainage

Advantages	Drawbacks
Fewer deleterious hemodynamic effects	Low success rate of selective cannulation
Possible procedure without conscious sedation	Limited devices
Possible one-step placement of nasobiliary tube	Limited procedures
Possible procedure in the bedside	Impossible transnasal insertion

bile duct. In our previous study, TNE-BD was performed in limited patients post sphincterotomy or placement of self-expandable metallic stent because of patient benefit, resulting in successful procedures in all but one. However, in patients with intact papilla, the success rate of bile duct cannulation in TNE-BD was comparatively low (72%) compared to conventional ERCP (96%, $P = 0.053$). Theoretically, using forward-viewing endoscopes the axes of the catheter cannot be matched to those of the bile duct at the long scope position except for particular patients, for instance, with periampullary diverticula. Therefore, performing TNE-BD at the long scope position, may be a good indication for patients with post-endoscopic sphincterotomy or placement of SEMS. In contrast, in patients with intact papilla, a short scope position may be necessary to perform bile duct cannulation unless using sphincterotomy.

Another drawback of TNE-BD is the limited number of devices because of a small working channel. At the present time, there are 3 commercially available TNEs (GIF-XP260N: Olympus medical systems, Tokyo, Japan, EG-530N2, Fujinon Toshiba ES Systems Co., Ltd., Tokyo, Japan, EG-1580K: Pentax Co Ltd, Tokyo, Japan) (Table 1). The specifications of these 3 TNEs are similar. In particular, the working channel diameter is only 2 mm, leading to limitations of device usage. Furthermore, the lack of elevator system may cause the failure of stent insertion when the stricture is very tough.

Serious procedure-related complications have not been reported. Nevertheless, ERCP procedures using TNE or ultrathin endoscope have some possibilities for direct endoscopic diagnosis or therapy into the bile duct for instance, electrohydraulic lithotripsy and tumor ablation^[14-19]. In the future, improvement of ultrathin endoscopes may lead to minimally invasive diagnosis and therapy in patients with biliary tract diseases.

In conclusion, although further cases should be accumulated, TNE-BD, in particular, one-step nasobiliary drainage using TNE may be a useful and novel technique for the treatment of acute cholangitis.

REFERENCES

- 1 Abraham N, Barkun A, Larocque M, Fallone C, Mayrand S, Baffis V, Cohen A, Daly D, Daoud H, Joseph L. Predicting which patients can undergo upper endoscopy comfortably

- without conscious sedation. *Gastrointest Endosc* 2002; **56**: 180-189
- 2 **Dumortier J**, Napoleon B, Hedelius F, Pellissier PE, Leprince E, Pujol B, Ponchon T. Unsedated transnasal EGD in daily practice: results with 1100 consecutive patients. *Gastrointest Endosc* 2003; **57**: 198-204
 - 3 **Kawai T**, Miyazaki I, Yagi K, Kataoka M, Kawakami K, Yamagishi T, Sofuni A, Itoi T, Moriyasu F, Osaka Y, Takagi Y, Aoki T. Comparison of the effects on cardiopulmonary function of ultrathin transnasal versus normal diameter transoral esophagogastroduodenoscopy in Japan. *Hepatogastroenterology* 2007; **54**: 770-774
 - 4 **Leung JW**, Chung SC, Sung JJ, Banez VP, Li AK. Urgent endoscopic drainage for acute suppurative cholangitis. *Lancet* 1989; **1**: 1307-1309
 - 5 **Cotton PB**. Endoscopic drainage for suppurative cholangitis. *Lancet* 1989; **2**: 213
 - 6 **Ikeda S**, Tanaka M, Yoshimoto H, Maeshiro K, Matsumoto S. Endoscopic biliary drainage for acute obstructive cholangitis: Analysis of 100 consecutive patients. *Dig Endosc* 1990; **2**: 214-217
 - 7 **Lai EC**, Paterson IA, Tam PC, Choi TK, Fan ST, Wong J. Severe acute cholangitis: the role of emergency nasobiliary drainage. *Surgery* 1990; **107**: 268-272
 - 8 **Lai EC**, Mok FP, Tan ES, Lo CM, Fan ST, You KT, Wong J. Endoscopic biliary drainage for severe acute cholangitis. *N Engl J Med* 1992; **326**: 1582-1586
 - 9 **Itoi T**, Kawai T, Itokawa F, Sofuni A, Kurihara T, Tsuchiya T, Ishii K, Tsuji S, Ikeuchi N, Takeuchi M, Sakai Y, Moriyasu F. Initial experience of transnasal endoscopic biliary drainage without conscious sedation for the treatment of acute cholangitis (with video). *Gastrointest Endosc* 2008; **67**: 328-332
 - 10 **Itoi T**, Kawai T, Sofuni A, Itokawa F, Tsuchiya T, Kurihara T, Kusano C, Saito Y, Gotoda T. Efficacy and safety of 1-step transnasal endoscopic nasobiliary drainage for the treatment of acute cholangitis in patients with previous endoscopic sphincterotomy (with videos). *Gastrointest Endosc* 2008; **68**: 84-90
 - 11 **Mori A**, Asano T, Maruyama T, Ohashi N, Inoue H, Takekoshi S, Okuno M. Transnasal ERCP/ENBD using an ultrathin esophagogastroduodenoscope. *J Gastroenterol* 2006; **41**: 1237-1238
 - 12 **Mori A**, Ohashi N, Maruyama T, Tatebe H, Sakai K, Shibuya T, Inoue H, Takegoshi S, Okuno M. Transnasal endoscopic retrograde cholangiopancreatography using an ultrathin endoscope: a prospective comparison with a routine oral procedure. *World J Gastroenterol* 2008; **14**: 1514-1520
 - 13 **Shah SM**, Barkin JS. Conversion from an orobiliary to a nasobiliary tube: a hands-off method. *Gastrointest Endosc* 2007; **65**: 355-356
 - 14 **Larghi A**, Waxman I. Endoscopic direct cholangioscopy by using an ultra-slim upper endoscope: a feasibility study. *Gastrointest Endosc* 2006; **63**: 853-857
 - 15 **Mori A**, Sakai K, Ohashi N, Maruyama T, Tatebe H, Shibuya T, Inoue H, Okuno M. Electrohydraulic lithotripsy of the common bile duct stone under transnasal direct cholangioscopy. *Endoscopy* 2008; **40** Suppl 2: E63
 - 16 **Brauer BC**, Fukami N, Chen YK. Direct cholangioscopy with narrow-band imaging, chromoendoscopy, and argon plasma coagulation of intraductal papillary mucinous neoplasm of the bile duct (with videos). *Gastrointest Endosc* 2008; **67**: 574-576
 - 17 **Park do H**, Park BW, Lee HS, Park SH, Park JH, Lee SH, Kim HS, Kim SJ. Peroral direct cholangioscopic argon plasma coagulation by using an ultraslim upper endoscope for recurrent hepatoma with intraductal nodular tumor growth (with videos). *Gastrointest Endosc* 2007; **66**: 201-203
 - 18 **Moon JH**, Ko BM, Choi HJ, Hong SJ, Cheon YK, Cho YD, Lee JS, Lee MS, Shim CS. Intraductal balloon-guided direct peroral cholangioscopy with an ultraslim upper endoscope (with videos). *Gastrointest Endosc* 2009; **70**: 297-302
 - 19 **Choi HJ**, Moon JH, Ko BM, Hong SJ, Koo HC, Cheon YK, Cho YD, Lee JS, Lee MS, Shim CS. Overtube-balloon-assisted direct peroral cholangioscopy by using an ultraslim upper endoscope (with videos). *Gastrointest Endosc* 2009; **69**: 935-940

S- Editor Zhang HN L- Editor Lalor PF E- Editor Ma WH

Endoscopic hemostasis techniques for upper gastrointestinal hemorrhage: A review

Hajime Anjiki, Terumi Kamisawa, Masaki Sanaka, Taro Ishii, Yasushi Kuyama

Hajime Anjiki, Terumi Kamisawa, Masaki Sanaka, Department of Internal Medicine, Tokyo Metropolitan Komagome Hospital, Tokyo 113-8677, Japan

Taro Ishii, Yasushi Kuyama, Department of Internal Medicine, Teikyo University School of Medicine, Tokyo 173, Japan

Author contributions: Anjiki H wrote the paper and carried out the endoscopy; Kamisawa T and Sanaka M guided the thesis; Ishii T and Kuyama Y carried out the endoscopy.

Correspondence to: Hajime Anjiki, MD, PhD, Department of Internal Medicine, Tokyo Metropolitan Komagome Hospital, 3-18-22 Honkomagome, Bunkyo-ku, Tokyo 113-8677, Japan. anjiki@cick.jp

Telephone: +81-3-38232101 Fax: +81-3-38241552

Received: August 19, 2009 Revised: September 12, 2009

Accepted: September 19, 2009

Published online: February 16, 2010

of Internal Medicine, University of the Ryukyus, 207 Uehara, Nishihara, Okinawa 903-0215, Japan; Sherman M Chamberlain, Associate Professor of Medicine, Section of Gastroenterology, BBR-2538, Medical College of Georgia, Augusta, GA 30912, United States

Anjiki H, Kamisawa T, Sanaka M, Ishii T, Kuyama Y. Endoscopic hemostasis for upper gastrointestinal hemorrhage: A review. *World J Gastrointest Endosc* 2010; 2(2): 54-60 Available from: URL: <http://www.wjgnet.com/1948-5190/full/v2/i2/54.htm> DOI: <http://dx.doi.org/10.4253/wjge.v2.i2.54>

Abstract

Upper gastrointestinal hemorrhage (UGIH) is an urgent disease that is often encountered in daily medical practice. Endoscopic hemostasis is currently indispensable for the treatment of UGIH. Initially, when UGIH is suspected, a cause of UGIH is presumed from the medical interview and physical findings. After ample primary treatment, urgent endoscopy is performed. Many methods of endoscopic hemostasis are in wide use, including hemoclip, injection and thermo-coagulation methods. Although UGIH develops from a wide variety of diseases, such as esophageal varices and gastric and duodenal ulcer, hemostasis is almost always possible. Identification of the causative diseases, primary treatment and characteristic features of endoscopic hemostasis are needed to allow appropriate treatment.

© 2010 Baishideng. All rights reserved.

Key words: Upper gastrointestinal hemorrhage; Primary treatment; Endoscopic hemostasis techniques

Peer reviewers: Akira Hokama, MD, PhD, First Department

INTRODUCTION

Upper gastrointestinal hemorrhage (UGIH) is an urgent disease often encountered in daily medical practice. Massive hemorrhage influences the circulatory dynamic state, causes various problems with internal organs, and can of course prove fatal. Quickly grasping patient status, starting primary treatment, and stopping bleeding is thus important. Endoscopic hemostasis is widely known to be useful in treating UGIH^[1-5]. However, difficult cases in endoscopic hemostasis still exist, and emergency operation or angiographic embolization is required on occasion^[6-9]. To achieve quick hemostasis in UGIH, mastering the methods and limitations of endoscopic hemostasis is imperative. Here we review clinical methods of endoscopic hemostasis for UGIH, based on our experience.

DIFFERENTIAL DIAGNOSIS OF UGIH

Patients with UGIH present with various symptoms, such as hematemesis, melena and progressive anemia. Sources of bleeding other than the digestive tract must first be excluded, including hemoptysis, epistaxis, and discrimination of lower digestive hemorrhage^[10]. Table 1 shows causative diseases for UGIH. Peptic ulcer is the most common causative disease^[1,6,11,12]. When UGIH is

Table 1 Causative diseases for upper GI-hemorrhage

Esophagus	Esophageal varices Esophagitis Mallory-weiss syndrome Esophageal cancer Others (aortointestinal fistula, foreign body, <i>etc.</i>)
Stomach	Ulcer (peptic ulcer, NSAID-associated ulcer, dieulafoy's lesion, <i>etc.</i>) AGML Gastric varices Gastric cancer Other tumor (GIST, malignant lymphoma, <i>etc.</i>) Vascular ectasia, GAVE, PHG Hyperplastic polyp Others (foreign body, <i>etc.</i>)
Duodenum	Ulcer (peptic ulcer, NSAID-associated ulcer, dieulafoy's lesion, <i>etc.</i>) Duodenitis Duodenal varices Diverticulum Tumor (cancer, malignant lymphoma, GIST, <i>etc.</i>) Invasion of malignant tumor (pancreas, bile duct, <i>etc.</i>) Others (hemobilia, aortointestinal fistula, <i>etc.</i>)

NSAIDs: Nonsteroidal anti-inflammatory drugs; AGML: Acute gastric mucosal lesion; GIST: Gastrointestinal stromal tumor; GAVE: Gastroantral vascular ectasia; PHG: Portal hypertensive gastropathy.

suspected, causes of UGIH may be presumed from the medical interview and physical findings. The strategy for hemostasis of UGIH with primary treatment is then considered.

PRIMARY TREATMENT

A firm grasp of the systemic status is important. Signs of shock, pallor, prostration, perspiration, pulselessness and pulmonary insufficiency suggest massive digestive hemorrhage. Above all, stabilization of the circulatory dynamic state by intravenous injection of extracellular fluid is crucial^[10]. In addition, an inhibitor of gastric acid-secretion should be given as quickly as practically possible, as gastric acid inhibits blood coagulation^[13]. If massive hemorrhage is suspected from gastroesophageal varices in patients with liver disease, vasoactive drugs (such as terlipressin, somatostatin and octreotide) should be started for initial management before therapeutic endoscopy^[14,15]. Temporary balloon tamponade, such as Sengstaken-Blakemore tubes, must be used with care to prevent further complications^[16,17]. If coagulopathy is present, transfusion is necessary. When the circulatory dynamic state is stable and UGIH has been judged as a cause of shock, urgent endoscopy is performed.

METHODS OF ENDOSCOPIC HEMOSTASIS

The methods of endoscopic hemostasis are shown in Table 2. Hemostasis can be performed using independent or combined methods. The hemoclip grips the exposed blood vessel directly and stops bleeding. Destruc-

Table 2 Method of endoscopic hemostasis

Mechanical method	Hemoclip Balloon tamponade Ligation (EVL, detachable snare)
Injection method	Ethanol Epinephrine Monoethanolamine oleate Polidocanol N-butyl-2-cyanoacrylate APC
Thermo-coagulation	Heater probe Hemostatic forceps Microwaves Laser (Nd-YAG, diode, <i>etc.</i>)
Hemostyptic sprays	Thrombin Sodium alginate Fibrin glue

EVL: Endoscopic variceal ligation; APC: Argon plasma coagulation.

tion of organization is minimal, and hemostatic ability is high^[18]. However, this method requires technical skill to maintain a front view of the exposed blood vessel. When difficulty is encountered, a transparent cap can prove useful^[19].

Injection methods are effective over a wider range than the hemoclip method, and can be used even if a front view of the bleeding point cannot be maintained. A combination of injection method and other methods is even more effective^[20]. However, careful attention is required, due to the risk of delayed perforation.

Thermo-coagulation methods are also effective if a front view of the bleeding point cannot be maintained. These techniques are useful in many cases^[21,22], but again carry the possibility of delayed perforation.

As the last method, hemostyptic sprays are used as supplementary treatments^[20]. Various methods of hemostasis are selected by adjusting to the individual's condition.

HEMOSTASIS FOR VARIOUS CAUSATIVE DISEASES

Esophageal varices

Esophageal varices are frequent in patients with liver cirrhosis. If bleeding from the esophageal varices continues, endoscopic balloon tamponade can be effective for stopping bleeding. Next, endoscopic variceal ligation (EVL) is generally used at the bleeding point (Figure 1A and B). After temporary hemostasis, aiming toward permanent hemostasis is desirable.

In the EVL method, application of the bands is started at the gastroesophageal junction and progresses cephalad in a helical fashion. EVL sessions are repeated at approximately 2-wk intervals until varices are obliterated, usually requiring 2 to 4 ligation sessions. EVL is a safer method than endoscopic injection sclerotherapy (EIS)^[23]. When technical factors, such as ulcer scars, do not allow ligation band placement, EIS is selected.

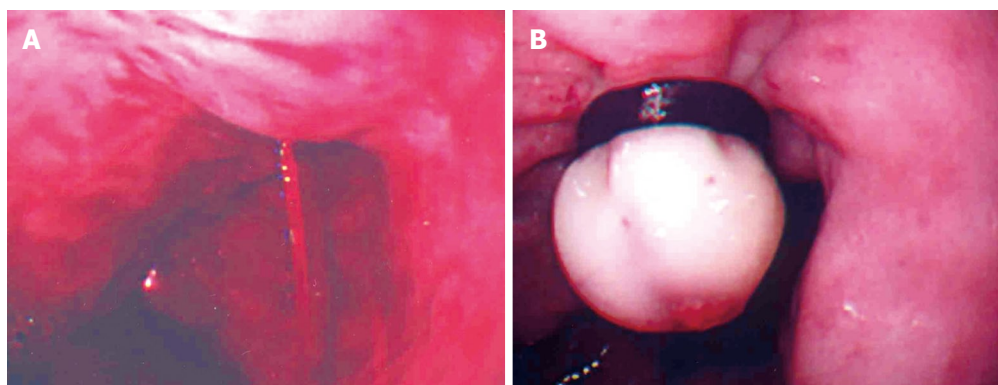


Figure 1 Use of EVL at the bleeding point. A: A spurting bleeding from esophageal varices; B: Esophageal varices after EVL.

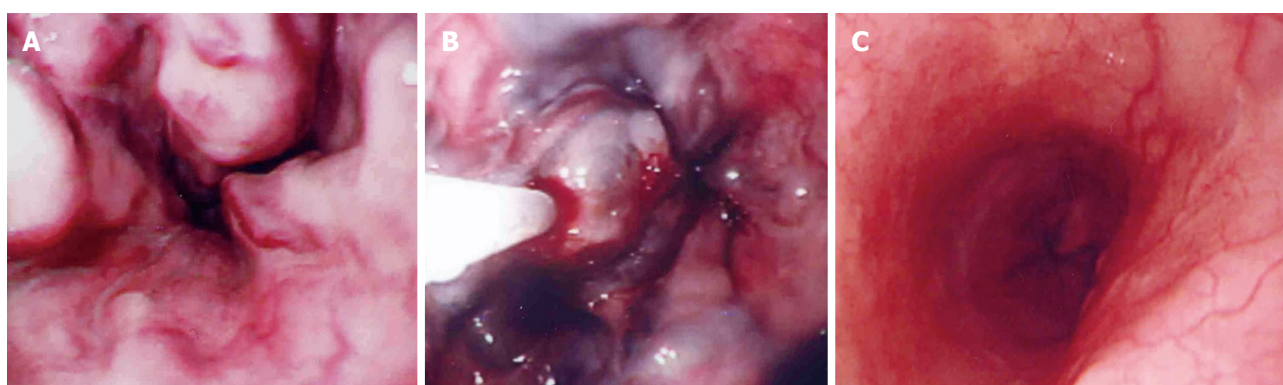


Figure 2 Changes of Esophageal varices after Endoscopic injection sclerotherapy. A: Esophageal varices before an endoscopic therapy; B: Endoscopic injection sclerotherapy (EIS); C: Esophagus after EIS 2 years later.

In EIS, to prevent variceal recurrence, complete obliteration of feeder vessels should be verified under fluoroscopy (Figure 2A-C)^[24]. Also, combined EVL and EIS treatment is reportedly superior to a single method^[25,26].

Recently, bacterial infections and/or endotoxaemia have been associated with failure to control variceal bleeding, earlier variceal rebleeding, abnormalities in coagulation, vasodilatation of the systemic vasculature, and worsening liver function^[27]. Prophylactic antibiotics are recommended for patients with bleeding varices^[28].

There are no clear hemostasis options as salvage for failure of endoscopic therapy. A transjugular intrahepatic portosystemic shunt (TIPS) procedure is effective to prevent variceal rebleeding, but it may cause complications such as portosystemic encephalopathy^[29,30]. Despite being an invasive procedure, a portocaval shunt operation is one of the effective choices in patients with Child's A or B. Patients with Child's B or C cirrhosis should be evaluated for transplantation^[23,31].

Gastric varices

Gastric varices cause massive hemorrhage and can be fatal. Identifying the tributaries of the gastric varices is most important, and contrast-enhanced CT is useful for appraisal. Depending on their location and relation to esophageal varices, gastric varices can be classified as gastroesophageal varices (GOV) and isolated gastric varices (IGV). Each of these can be further subdivided as follows: GOV1 (extension of oesophageal varices along

lesser curve) and GOV2 (extension of oesophageal varices towards fundus); and IGV1 (varices in the fundus) and IGV2 (isolated varices anywhere in the stomach)^[32]. If traffic with esophageal varices is seen, EIS from the esophageal varices is effective. In cases of IGV1, endoscopic injection of N-butyl-2-cyanoacrylate^[33,34] and combined EVL methods^[35] are reportedly safe and effective. If a gastro-renal shunt exists, balloon-occluded retrograde obliteration (B-RTO) under angiography is possible^[36,37].

When endoscopic therapy fails, TIPS and surgical operation are mentioned as salvage in the same way as esophageal varices. Splenectomy is quite effective in treating gastric varices due to segmental portal hypertension. For gastric varices bleeding due to generalized portal hypertension, a shunt operation is often effective^[23,38].

Gastric and duodenal ulcer and acute gastric mucosal lesions

Gastric and duodenal ulcers include various ulcers such as peptic ulcer, ulcers associated with use of non-steroidal anti-inflammatory drugs (NSAIDs) and Dieulafoy's lesion. All of these ulcers can cause UGIH, which then needs treatment.

Previous studies have clarified adaptations of hemostasis for hemorrhagic ulcer. Table 3 shows the modified Forrest classification for hemorrhagic gastric ulcer^[1,39]. Adaptation is decided according to the state of the exposed blood vessel at the base of the ulcer^[40-42]. Specifically, spurting bleeding (Figure 3A), oozing bleeding

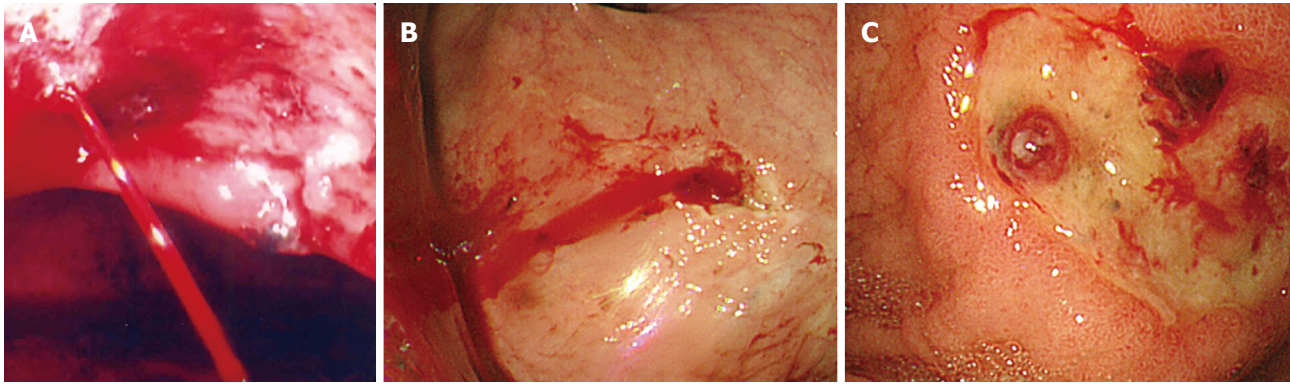


Figure 3 Different patterns of bleeding of the gastric ulcer. A: A spurting bleeding of the gastric ulcer (Forrest I a); B oozing bleeding of the gastric ulcer (Forrest I b); C: Non-bleeding visible vessel of the gastric ulcer (Forrest II a).

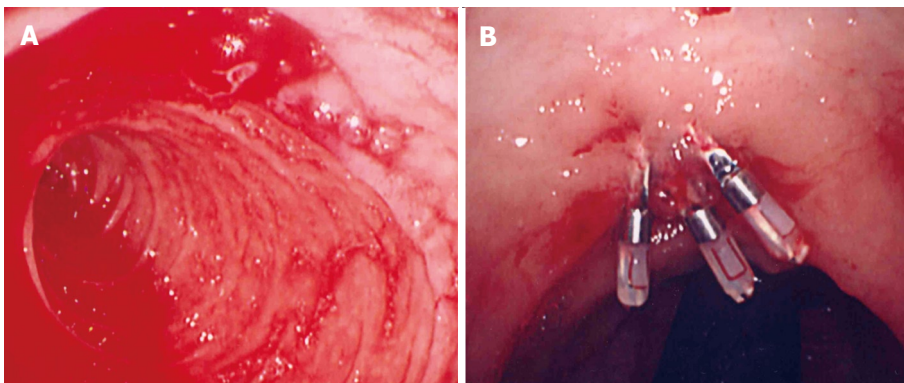


Figure 4 Duodenal diverticulum. A: Hemorrhage; B: After endoscopic hemostasis.

Table 3 Modified Forrest classification of hemorrhagic gastric ulcer

Active bleeding	Type I a: spurting bleeding Type I b: oozing bleeding
Recent bleeding	Type II a: non-bleeding visible vessel Type II b: adherent blood clot Type II c: black base
No bleeding	Type III: no stigma

(Figure 3B) and non-bleeding visible vessels (Figure 3C) need to be treated. Clot clinging to the ulcer base should be carefully removed by washing, suction and forceps until the ulcer base is visible. Ulcers can be treated with independent or combined methods. As each method offers certain characteristic features, discussing the advantages and disadvantages of these methods is difficult^[43,44]. In previous reports, a combination of injection methods with other methods has appeared superior to injection methods alone^[44-49]. Dieulafoy's lesion can be treated with these endoscopic hemostasis methods^[50,51]. Acute gastric mucosal lesions apply to gastric ulcers.

After temporary hemostasis, systemic second-look endoscopy with retreatment the next day significantly reduces the risk of recurrent bleeding^[52]. Administration of a proton pump inhibitor (PPI) after hemostasis is also important^[53] and *Helicobacter pylori* should be eradicated in peptic ulcers showing positive results for this bacteria^[54].

Tumor

Endoscopic hemostasis for severe upper gastrointestinal bleeding due to tumor, such as cancer, gastrointestinal stromal tumor, and malignant lymphoma, is effective as temporary hemostasis^[55]. Argon plasma coagulation is useful, in particular, for different cases of identification of the vessel responsible for the bleeding^[56,57]. However, permanent hemostasis is difficult in many cases due to diffuse bleeding. Early consultation with a surgeon is warranted in cases where hemostasis is difficult to achieve.

Mallory-weiss syndrome

Mallory-Weiss syndrome heals spontaneously in many cases, but endoscopic therapy is occasionally necessary to stop bleeding. Various methods have been reported, such as Hemoclip placement, epinephrine injection and band ligation^[58,59].

Reflux esophagitis

The few cases of reflux esophagitis requiring endoscopic hemostasis are treated with a PPI, and most cases heal with conservative therapy. However, when an anticoagulant drug is being administered or bleeding tendencies exist, chronic bleeding can continue. These cases must be treated by addressing the bleeding tendency^[60].

Vascular ectasia

UGIH is sometimes induced by vascular ectasia, such as

gastric antral vascular ectasia, diffuse antral vascular ectasia or portal hypertensive gastropathy. In many cases, the cause of vascular ectasia is unclear. Chronic bleeding from vascular ectasia is typically noticed by progressive anemia. Argon plasma coagulation^[61,62] and endoscopic band ligation^[63] are useful for hemostasis.

Hyperplastic polyps

Hyperplastic polyps of the stomach are usually asymptomatic, but can cause UGIH leading to anemia. The majority of such lesions are benign, but when a polyp exceeds 2 cm in maximum diameter, the frequency of focal cancer increases. Pathological diagnosis of large polyps is thus desirable^[64].

Duodenal diverticulum

Duodenal diverticulum is a rare cause of UGIH, and endoscopy is reportedly useful for diagnosis and treatment of this condition^[65]. Patients receive various endoscopic therapies, such as thermo-coagulation, injection, and hemoclip. The point of the hemoclip method is to grasp a vessel, diverticulum and other tissue (Figure 4A and B).

CONCLUSION

We have provided an outline of endoscopic hemostasis for UGIH. For the digestive endoscopist, endoscopic hemostasis is a field that cannot be avoided. Being prepared to take proper measures is important. As the causes of UGIH differ in various patients, knowledge of UGIH including causes and preferred treatments requires constant attention.

REFERENCES

- Kohler B, Riemann JF. Upper GI-bleeding--value and consequences of emergency endoscopy and endoscopic treatment. *Hepatogastroenterology* 1991; **38**: 198-200
- Sacks HS, Chalmers TC, Blum AL, Berrier J, Pagano D. Endoscopic hemostasis. An effective therapy for bleeding peptic ulcers. *JAMA* 1990; **264**: 494-499
- Jensen DM, Kovacs TO, Jutabha R, Machicado GA, Gralnek IM, Savides TJ, Smith J, Jensen ME, Alofaituli G, Gornbein J. Randomized trial of medical or endoscopic therapy to prevent recurrent ulcer hemorrhage in patients with adherent clots. *Gastroenterology* 2002; **123**: 407-413
- Sung JJ, Chan FK, Lau JY, Yung MY, Leung WK, Wu JC, Ng EK, Chung SC. The effect of endoscopic therapy in patients receiving omeprazole for bleeding ulcers with nonbleeding visible vessels or adherent clots: a randomized comparison. *Ann Intern Med* 2003; **139**: 237-243
- Kahi CJ, Jensen DM, Sung JJ, Bleau BL, Jung HK, Eckert G, Imperiale TF. Endoscopic therapy versus medical therapy for bleeding peptic ulcer with adherent clot: a meta-analysis. *Gastroenterology* 2005; **129**: 855-862
- Starlinger M, Becker HD. Upper gastrointestinal bleeding--indications and results in surgery. *Hepatogastroenterology* 1991; **38**: 216-219
- Rockall TA. Management and outcome of patients undergoing surgery after acute upper gastrointestinal haemorrhage. Steering Group for the National Audit of Acute Upper Gastrointestinal Haemorrhage. *J R Soc Med* 1998; **91**: 518-523
- Keller FS, Routh WD. Angiographic diagnosis and management. *Hepatogastroenterology* 1991; **38**: 207-215
- Loffroy R, Guieu B, Cercueil JP, Lepage C, Latournerie M, Hillon P, Rat P, Ricolfi F, Krausé D. Refractory bleeding from gastroduodenal ulcers: arterial embolization in high-operative-risk patients. *J Clin Gastroenterol* 2008; **42**: 361-367
- Cappell MS, Friedel D. Initial management of acute upper gastrointestinal bleeding: from initial evaluation up to gastrointestinal endoscopy. *Med Clin North Am* 2008; **92**: 491-509, xi
- Henrion J, Schapira M, Ghilain JM, Maisin JM, De Maeght S, Deltenre P, Moulart M, Delaunoit T. Upper gastrointestinal bleeding: What has changed during the last 20 years? *Gastroenterol Clin Biol* 2008; Epub ahead of print
- van Leerdam ME. Epidemiology of acute upper gastrointestinal bleeding. *Best Pract Res Clin Gastroenterol* 2008; **22**: 209-224
- Lau JY, Leung WK, Wu JC, Chan FK, Wong VW, Chiu PW, Lee VW, Lee KK, Cheung FK, Siu P, Ng EK, Sung JJ. Omeprazole before endoscopy in patients with gastrointestinal bleeding. *N Engl J Med* 2007; **356**: 1631-1640
- Dell'Era A, de Franchis R, Iannuzzi F. Acute variceal bleeding: pharmacological treatment and primary/secondary prophylaxis. *Best Pract Res Clin Gastroenterol* 2008; **22**: 279-294
- Villanueva C, Balanzó J. Variceal bleeding : pharmacological treatment and prophylactic strategies. *Drugs* 2008; **68**: 2303-2324
- Cook D, Laine L. Indications, technique, and complications of balloon tamponade for variceal gastrointestinal bleeding. *J Intensive Care Med* 1992; **7**: 212-218
- Chong CF. Esophageal rupture due to Sengstaken-Blakemore tube misplacement. *World J Gastroenterol* 2005; **11**: 6563-6565
- Lai YC, Yang SS, Wu CH, Chen TK. Endoscopic hemoclip treatment for bleeding peptic ulcer. *World J Gastroenterol* 2000; **6**: 53-56
- Kim JI, Kim SS, Park S, Han J, Kim JK, Han SW, Choi KY, Chung IS, Chung KW, Sun HS. Endoscopic hemoclip using a transparent cap in technically difficult cases. *Endoscopy* 2003; **35**: 659-662
- Park WG, Yeh RW, Triadafilopoulos G. Injection therapies for nonvariceal bleeding disorders of the GI tract. *Gastrointest Endosc* 2007; **66**: 343-354
- Chung SC, Lau JY, Rutgeerts P, Fennerty MB. Thermal coagulation for nonvariceal bleeding. *Endoscopy* 2002; **34**: 89-92
- Kanai M, Hamada A, Endo Y, Takeda Y, Yamakawa M, Nishikawa H, Torii A. Efficacy of argon plasma coagulation in nonvariceal upper gastrointestinal bleeding. *Endoscopy* 2004; **36**: 1085-1088
- Sass DA, Chopra KB. Portal hypertension and variceal hemorrhage. *Med Clin North Am* 2009; **93**: 837-853, vii-viii
- Naritaka Y, Shimakawa T, Isohata N, Asaka S, Konno S, Murayama M, Yoshimatsu K, Shiozawa S, Katsube T, Ogawa K. Long-term results of endoscopic injection sclerotherapy in 602 patients with esophageal varices. *Hepatogastroenterology* 2008; **55**: 2096-2102
- Bhargava DK, Pokharna R. Endoscopic variceal ligation versus endoscopic variceal ligation and endoscopic sclerotherapy: a prospective randomized study. *Am J Gastroenterol* 1997; **92**: 950-953
- Yoshida H, Mamada Y, Taniai N, Tajiri T. New methods for the management of esophageal varices. *World J Gastroenterol* 2007; **13**: 1641-1645
- Thalheimer U, Triantos CK, Samonakis DN, Patch D, Burroughs AK. Infection, coagulation, and variceal bleeding in cirrhosis. *Gut* 2005; **54**: 556-563
- Rerknimitr R, Chanyaswad J, Kongkam P, Kullavanijaya P. Risk of bacteremia in bleeding and nonbleeding gastric varices after endoscopic injection of cyanoacrylate. *Endoscopy* 2008; **40**: 644-649
- Colombato L. The role of transjugular intrahepatic portosystemic shunt (TIPS) in the management of portal hypertension. *J Clin Gastroenterol* 2007; **41** Suppl 3: S344-S351

- 30 **Zheng M**, Chen Y, Bai J, Zeng Q, You J, Jin R, Zhou X, Shen H, Zheng Y, Du Z. Transjugular intrahepatic portosystemic shunt versus endoscopic therapy in the secondary prophylaxis of variceal rebleeding in cirrhotic patients: meta-analysis update. *J Clin Gastroenterol* 2008; **42**: 507-516
- 31 **Orloff MJ**, Isenberg JI, Wheeler HO, Haynes KS, Jinich-Brook H, Rapier R, Vaida F, Hye RJ. Randomized trial of emergency endoscopic sclerotherapy versus emergency portacaval shunt for acutely bleeding esophageal varices in cirrhosis. *J Am Coll Surg* 2009; **209**: 25-40
- 32 **Sarin SK**, Lahoti D. Management of gastric varices. *Baillieres Clin Gastroenterol* 1992; **6**: 527-548
- 33 **Seewald S**, Ang TL, Imazu H, Naga M, Omar S, Groth S, Seitz U, Zhong Y, Thonke F, Soehendra N. A standardized injection technique and regimen ensures success and safety of N-butyl-2-cyanoacrylate injection for the treatment of gastric fundal varices (with videos). *Gastrointest Endosc* 2008; **68**: 447-454
- 34 **Belletrutti PJ**, Romagnuolo J, Hilsden RJ, Chen F, Kaplan B, Love J, Beck PL. Endoscopic management of gastric varices: efficacy and outcomes of gluing with N-butyl-2-cyanoacrylate in a North American patient population. *Can J Gastroenterol* 2008; **22**: 931-936
- 35 **Sugimoto N**, Watanabe K, Watanabe K, Ogata S, Shimoda R, Sakata H, Eguchi Y, Mizuta T, Tsunada S, Iwakiri R, Nojiri J, Mizuguchi M, Kudo S, Miyazaki K, Fujimoto K. Endoscopic hemostasis for bleeding gastric varices treated by combination of variceal ligation and sclerotherapy with N-butyl-2-cyanoacrylate. *J Gastroenterol* 2007; **42**: 528-532
- 36 **Ninomi T**, Nishida N, Kaminou T, Sakai Y, Kitayama T, Hamuro M, Yamada R, Nakamura K, Arakawa T, Inoue Y. Balloon-occluded retrograde transvenous obliteration of gastric varices with gastroduodenal shunt: long-term follow-up in 78 patients. *AJR Am J Roentgenol* 2005; **184**: 1340-1346
- 37 **Hiraga N**, Aikata H, Takaki S, Kodama H, Shirakawa H, Imamura M, Kawakami Y, Takahashi S, Toyota N, Ito K, Tanaka S, Kitamoto M, Chayama K. The long-term outcome of patients with bleeding gastric varices after balloon-occluded retrograde transvenous obliteration. *J Gastroenterol* 2007; **42**: 663-672
- 38 **Lee JH**, Han HS, Kim HA, Koo MY. Long-term results of fundectomy and periesophagogastric devascularization in patients with gastric fundal variceal bleeding. *World J Surg* 2009; **33**: 2144-2149
- 39 **Heldwein W**, Schreiner J, Pedrazzoli J, Lehnert P. Is the Forrest classification a useful tool for planning endoscopic therapy of bleeding peptic ulcers? *Endoscopy* 1989; **21**: 258-262
- 40 **Bleau BL**, Gostout CJ, Sherman KE, Shaw MJ, Harford WV, Keate RF, Bracy WP, Fleischer DE. Recurrent bleeding from peptic ulcer associated with adherent clot: a randomized study comparing endoscopic treatment with medical therapy. *Gastrointest Endosc* 2002; **56**: 1-6
- 41 **Jensen DM**, Kovacs TO, Jutabha R, Machicado GA, Gralnek IM, Savides TJ, Smith J, Jensen ME, Alofaituli G, Gornbein J. Randomized trial of medical or endoscopic therapy to prevent recurrent ulcer hemorrhage in patients with adherent clots. *Gastroenterology* 2002; **123**: 407-413
- 42 **Sung JJ**, Chan FK, Lau JY, Yung MY, Leung WK, Wu JC, Ng EK, Chung SC. The effect of endoscopic therapy in patients receiving omeprazole for bleeding ulcers with nonbleeding visible vessels or adherent clots: a randomized comparison. *Ann Intern Med* 2003; **139**: 237-243
- 43 **Bianco MA**, Rotondano G, Marmo R, Piscopo R, Orsini L, Cipolletta L. Combined epinephrine and bipolar probe coagulation vs. bipolar probe coagulation alone for bleeding peptic ulcer: a randomized, controlled trial. *Gastrointest Endosc* 2004; **60**: 910-915
- 44 **Yuan Y**, Wang C, Hunt RH. Endoscopic clipping for acute nonvariceal upper-GI bleeding: a meta-analysis and critical appraisal of randomized controlled trials. *Gastrointest Endosc* 2008; **68**: 339-351
- 45 **Park CH**, Joo YE, Kim HS, Choi SK, Rew JS, Kim SJ. A prospective, randomized trial comparing mechanical methods of hemostasis plus epinephrine injection to epinephrine injection alone for bleeding peptic ulcer. *Gastrointest Endosc* 2004; **60**: 173-179
- 46 **Calvet X**, Vergara M, Brullet E, Gisbert JP, Campo R. Addition of a second endoscopic treatment following epinephrine injection improves outcome in high-risk bleeding ulcers. *Gastroenterology* 2004; **126**: 441-450
- 47 **Sung JJ**, Tsoi KK, Lai LH, Wu JC, Lau JY. Endoscopic clipping versus injection and thermo-coagulation in the treatment of non-variceal upper gastrointestinal bleeding: a meta-analysis. *Gut* 2007; **56**: 1364-1373
- 48 **Marmo R**, Rotondano G, Piscopo R, Bianco MA, D'Angella R, Cipolletta L. Dual therapy versus monotherapy in the endoscopic treatment of high-risk bleeding ulcers: a meta-analysis of controlled trials. *Am J Gastroenterol* 2007; **102**: 279-289; quiz 469
- 49 **Laine L**, McQuaid KR. Endoscopic therapy for bleeding ulcers: an evidence-based approach based on meta-analyses of randomized controlled trials. *Clin Gastroenterol Hepatol* 2009; **7**: 33-47; quiz 1-2
- 50 **Yamaguchi Y**, Yamato T, Katsumi N, Imao Y, Aoki K, Morita Y, Miura M, Morozumi K, Ishida H, Takahashi S. Short-term and long-term benefits of endoscopic hemoclip application for Dieulafoy's lesion in the upper GI tract. *Gastrointest Endosc* 2003; **57**: 653-656
- 51 **Iacopini F**, Petruzzello L, Marchese M, Larghi A, Spada C, Familiari P, Tringali A, Riccioni ME, Gabbriellini A, Costamagna G. Hemostasis of Dieulafoy's lesions by argon plasma coagulation (with video). *Gastrointest Endosc* 2007; **66**: 20-26
- 52 **Marmo R**, Rotondano G, Bianco MA, Piscopo R, Prisco A, Cipolletta L. Outcome of endoscopic treatment for peptic ulcer bleeding: Is a second look necessary? A meta-analysis. *Gastrointest Endosc* 2003; **57**: 62-67
- 53 **Massó González EL**, García Rodríguez LA. Proton pump inhibitors reduce the long-term risk of recurrent upper gastrointestinal bleeding: an observational study. *Aliment Pharmacol Ther* 2008; **28**: 629-637
- 54 **Ford AC**, Delaney BC, Forman D, Moayyedi P. Eradication therapy in *Helicobacter pylori* positive peptic ulcer disease: systematic review and economic analysis. *Am J Gastroenterol* 2004; **99**: 1833-1855
- 55 **Savides TJ**, Jensen DM, Cohen J, Randall GM, Kovacs TO, Pelayo E, Cheng S, Jensen ME, Hsieh HY. Severe upper gastrointestinal tumor bleeding: endoscopic findings, treatment, and outcome. *Endoscopy* 1996; **28**: 244-248
- 56 **Johanns W**, Luis W, Janssen J, Kahl S, Greiner L. Argon plasma coagulation (APC) in gastroenterology: experimental and clinical experiences. *Eur J Gastroenterol Hepatol* 1997; **9**: 581-587
- 57 **Kawamura H**, Inamori M, Akiyama T, Akimoto K, Fujita K, Takahashi H, Yoneda M, Abe Y, Kubota K, Ueno N, Inayama Y, Harada H, Rino Y, Nakajima A. Argon plasma coagulation for a bleeding gastrointestinal stromal tumor. *Digestion* 2007; **75**: 164
- 58 **Huang SP**, Wang HP, Lee YC, Lin CC, Yang CS, Wu MS, Lin JT. Endoscopic hemoclip placement and epinephrine injection for Mallory-Weiss syndrome with active bleeding. *Gastrointest Endosc* 2002; **55**: 842-846
- 59 **Cho YS**, Chae HS, Kim HK, Kim JS, Kim BW, Kim SS, Han SW, Choi KY. Endoscopic band ligation and endoscopic hemoclip placement for patients with Mallory-Weiss syndrome and active bleeding. *World J Gastroenterol* 2008; **14**: 2080-2084
- 60 **Costa ND**, Cadiot G, Merle C, Jolly D, Bouche O, Thiéfin G, Zeitoun P. Bleeding reflux esophagitis: a prospective 1-year study in a university hospital. *Am J Gastroenterol* 2001; **96**: 47-51
- 61 **Kwan V**, Bourke MJ, Williams SJ, Gillespie PE, Murray MA,

- Kaffes AJ, Henriquez MS, Chan RO. Argon plasma coagulation in the management of symptomatic gastrointestinal vascular lesions: experience in 100 consecutive patients with long-term follow-up. *Am J Gastroenterol* 2006; **101**: 58-63
- 62 **Herrera S**, Bordas JM, Llach J, Ginès A, Pellisé M, Fernández-Esparrach G, Mondelo F, Mata A, Cárdenas A, Castells A. The beneficial effects of argon plasma coagulation in the management of different types of gastric vascular ectasia lesions in patients admitted for GI hemorrhage. *Gastrointest Endosc* 2008; **68**: 440-446
- 63 **Wells CD**, Harrison ME, Gurudu SR, Crowell MD, Byrne TJ, Depetris G, Sharma VK. Treatment of gastric antral vascular ectasia (watermelon stomach) with endoscopic band ligation. *Gastrointest Endosc* 2008; **68**: 231-236
- 64 **Jain R**, Chetty R. Gastric hyperplastic polyps: a review. *Dig Dis Sci* 2009; **54**: 1839-1846
- 65 **Chen YY**, Yen HH, Soon MS. Impact of endoscopy in the management of duodenal diverticular bleeding: experience of a single medical center and a review of recent literature. *Gastrointest Endosc* 2007; **66**: 831-835

S- Editor Zhang HN **L- Editor** Lutze M **E- Editor** Ma WH

Intralesional steroid injection therapy in the management of resistant gastrointestinal strictures

Rakesh Kochhar, Kuchhangi Suresh Poornachandra

Rakesh Kochhar, Kuchhangi Suresh Poornachandra, Department of Gastroenterology, Postgraduate Institute of Medical Education and Research, Chandigarh 160012, India
Author contributions: Kochhar R conceived and designed the review, reviewed the literature and prepared the manuscript; Poornachandra KS reviewed the literature and prepared the manuscript.

Correspondence to: Rakesh Kochhar, Professor, Department of Gastroenterology, Postgraduate Institute of Medical Education and Research, Chandigarh 160012,

India. dr_kochhar@hotmail.com

Telephone: +91-172-2715016 Fax: +91-172-2744401

Received: April 11, 2009 Revised: September 7, 2009

Accepted: September 15, 2009

Published online: February 16, 2010

Abstract

Esophageal strictures are a problem frequently encountered by gastroenterologists. Dilation has been the customary treatment for benign esophageal strictures, and dilation techniques have advanced over the years. Depending on their characteristics and the response to treatment, esophageal strictures can be classified into two types: 1, simple (Schatzki rings, webs, peptic injury, and following sclerotherapy) - these are easily amenable to dilation, with a low recurrence rate after initial treatment; and 2, complex (caused by caustic ingestion, radiation injury, anastomotic strictures, and photodynamic therapy) - these are difficult to dilate and are associated with higher recurrence rates. Refractory strictures are those in which it is not possible to relieve the anatomic restriction successfully up to a diameter of 14 mm over five sessions at 2-weekly intervals, due to cicatricial luminal compromise or fibrosis; and recurrent strictures are those in which it is not possible to maintain a satisfactory luminal diameter for 4 wk once the target diameter of 14 mm has been achieved. There are no standard recommendations for the management of refractory strictures. The various techniques used include intralesional steroid injection

combined with dilation; endoscopic incisional therapy, with or without dilation; placement of self-expanding metal stents, Polyflex stents, or biodegradable stents; self-bougienage; and endoscopic surgery. This review discusses the indications, technique, results, and complications of the use of intralesional steroid injections combined with dilation and endoscopic incisional therapy with dilation in refractory strictures.

© 2010 Baishideng. All rights reserved.

Key words: Gastrointestinal strictures; Intralesional injection; Triamcinolone; Steroids; Dilation; Endoscopy

Peer reviewer: Naoki Muguruma, MD, PhD, Department of Gastroenterology and Oncology, The University of Tokushima Graduate School, 3-18-15, Kuramoto-cho, Tokushima 770-8503, Japan

Kochhar R, Poornachandra KS. Intralesional steroid injection therapy in the management of resistant gastrointestinal strictures. *World J Gastrointest Endosc* 2010; 2(2): 61-68 Available from: URL: <http://www.wjgnet.com/1948-5190/full/v2/i2/61.htm> DOI: <http://dx.doi.org/10.4253/wjge.v2.i2.61>

INTRODUCTION

Esophageal strictures are a problem frequently encountered by gastroenterologists. Strictures can be subdivided into those with malignant causes and those that are benign. Malignant esophageal strictures are usually due to carcinoma, and in these cases dilation is used only as a supplementary procedure in addition to stent placement, or in order to complete another procedure. Common benign causes include peptic injury, Schatzki rings, esophageal webs, radiation injury, caustic ingestion, and anastomotic strictures^[1-3]. Dilation has been the customary treatment for benign esophageal strictures, and dilation techniques have developed from the use of whale-

bones (reported in the treatment of achalasia) and rigid bougienage in the seventeenth and eighteenth centuries to the present-day use of wire-guided, flexible, polyvinyl bougies (Savary-Gilliard; Wilson-Cook Medical Inc., Winston-Salem, North Carolina, USA) and through-the-scope balloon dilators.

Depending on their characteristics and on the response to treatment, esophageal strictures can be differentiated into two structural types - simple or complex^[1]. Simple esophageal strictures are focal, straight, symmetrical, or concentric, with a diameter of > 12 mm (allowing easy passage of a diagnostic upper endoscope), and they are often amenable to treatment with standard techniques such as bougienage or balloon dilation. Common etiologies for simple strictures include Schatzki rings, webs, and peptic injury; they may also develop following sclerotherapy. In these strictures, only one to three dilation sessions are usually required in order to achieve symptomatic relief^[1,2], but after initial treatment they may recur in up to 30%-40% of patients during the long-term follow-up^[4].

Complex strictures are long (> 2 cm), tortuous, and asymmetrical and are associated with a severely compromised luminal diameter (< 12 mm)^[1]. Common causes of benign complex strictures include caustic ingestion, radiation injury, anastomotic strictures, and photodynamic therapy. Some peptic strictures may also be complex in nature. Complex strictures are usually more difficult to treat, requiring some three to eight dilation sessions when conventional bougienage or balloon dilation techniques are used^[1,2], and they are associated with higher recurrence rates^[3]. In tortuous strictures, fluoroscopic guidance may be needed during dilation therapy^[1]. Some complex strictures (e.g. after radiotherapy) may appear completely closed, without an identifiable lumen being visible on endoscopy or contrast esophagography.

REFRACTORY STRICTURES

There is no universally accepted definition for a refractory esophageal stricture, and the numbers of additional dilation sessions required before strictures are categorized as refractory vary in different series^[5,6]. A refractory or recurrent stricture is defined as an anatomic restriction resulting from cicatricial luminal compromise or due to fibrosis leading to clinical symptoms of dysphagia in the absence of any endoscopic evidence of inflammation. This may occur either as a result of an inability to successfully resolve the anatomic problem up to a diameter of 14 mm over five sessions at 2-wk intervals (refractory stricture) or due to an inability to maintain a satisfactory luminal diameter for 4 wk once the target diameter of 14 mm has been achieved (recurrent stricture)^[7]. There are no standard recommendations for the management of refractory strictures. Intraleisional steroid injection combined with dilation^[8-13], endoscopic incisional therapy with or without dilation^[14-16], and placement of self-expanding metallic stents (SEMS)^[17,18],

Polyflex stents^[19], or biodegradable stents^[20], self-bougie-nage^[21], and endoscopic surgery^[22,23] have been used in the management of refractory strictures.

INTRALESIONAL STEROID THERAPY

Historical aspects

On the basis of successful injection treatment for dermatologic scars such as keloids and burn scars^[24,25], intralesional injection of corticosteroids has been practiced in refractory esophageal strictures of various etiologies for the last 40 years. Although evidence of the effectiveness of corticosteroid injection in benign esophageal strictures was first reported by Ashcraft and Holder^[26] in 1969 in an animal model, the technique was used only occasionally during the 1970s and 1980s, primarily with rigid endoscopes in patients under general anesthesia^[10,27]. However, during the last decade there has been growing interest in the use of this form of therapy for refractory benign esophageal strictures^[8,9,11-13,28,29].

Preparation

Preparation is as for esophageal dilation. Esophageal dilation is routinely performed in an outpatient setting. Patients should fast for 4-6 h before the procedure. Anti-coagulant medication should be discontinued^[30]. Routine antibiotic coverage is not recommended, and the guidelines for endocarditis prophylaxis should be followed^[31]. During the informed consent process, patients should be informed about the risk of perforation and the possible need for surgery should it occur. Although some patients may tolerate dilation with topical anesthesia alone, conscious sedation is generally used^[32].

Type and dose of steroids

Most investigators^[8-13] have used triamcinolone acetate or acetone 10 mg/mL, although some have used a concentration of 40 mg/mL^[27,28]. The volume of corticosteroid used per injection has varied from 0.5 mL^[28] to 2.8 mL^[9]. We initially used 10 mg/mL triamcinolone acetate^[12], but in a subsequent study we administered 40 mg/mL triamcinolone acetate to a total of 40-100 mg in each session^[13]. Ramage *et al.*^[28], in a randomized study, standardized the dosage to 0.5 mL aliquots of 20 mg each of 40 mg/mL triamcinolone acetone.

Ramboer *et al.*^[33] used a betamethasone preparation: one 1-mL vial containing 5 mg of betamethasone as a dipropionate suspension diluted into usually 5 mL and sometimes 10 mL of normal saline solution and injected as 0.5-1.0-mL aliquots. Miyashita *et al.*^[34] used a total of 8 mg dexamethasone (2 mL) injected endoscopically into four sites (2 mg/0.5 mL per site) at the anastomotic site immediately after dilation. Mendelson and Maloney^[10] used hydrocortisone acetate in two of their patients.

There were no differences among the reported studies with regard to the response outcome after using different steroid formulations.

The number of injection sessions in the reported

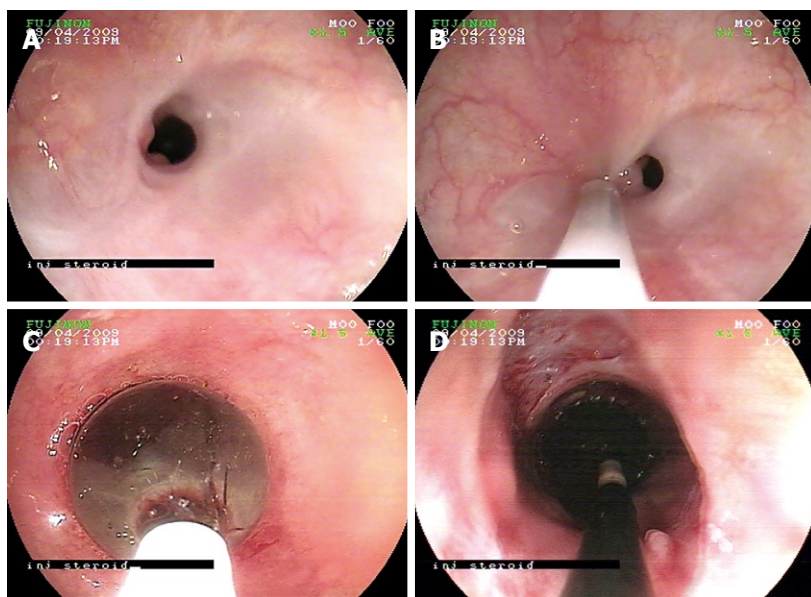


Figure 1 Endoscopic image of an esophageal stricture and its management. A: A refractory stricture; B: Steroid injection at the proximal edge of the stricture; C: Through-the-scope (TTS) balloon dilation of the stricture; D: The opened stricture after deflation of the TTS balloon.

series varies from only one to as many sessions as the number of dilations. Kochhar *et al.*^[12,13] used a maximum of four sessions, whereas Rupp *et al.*^[35] carried out a maximum of five sessions and Gandhi *et al.*^[27] conducted as many as 13 sessions. The number of sessions is an issue that has not yet been settled and requires standardization.

The role of systemic steroids has been a matter of debate, especially in patients with caustic ingestion. In an interesting study, Morikawa *et al.*^[36] reported that two children, one with a caustic-induced stricture and the other with an anastomotic stricture, responded to high-dose intravenous methylprednisolone after they had failed to respond to intralesional steroids. However, the follow-up periods for these two patients were only 7 and 8 mo. The authors postulated that high-dose intravenous steroids might deliver the steroid to the stricture segment better than direct injection, as the wall of the stricture appeared to be too thick. They also expected that high-dose steroids given immediately after dilation would suppress the initial inflammation.

However, a meta-analysis of 10 studies^[37] concluded that administration of systemic steroids in the management of corrosive ingestion does not prevent the development of strictures and may actually lead to the development of serious adverse effects. In 305 patients treated with corticosteroids, 35.1% developed strictures, whereas 33.3% of the 267 patients who were not treated with corticosteroids developed strictures.

Procedure (Figure 1A-D)

Triamcinolone is injected intralesionally using a 23-gauge, 5-mm long sclerotherapy injection needle (3MK; Olympus Optical Co., Tokyo, Japan) in aliquots of 0.2-0.8 mL at 10-40 mg/mL, after premedication with intravenous hyoscine N-butylbromide. Injections are commonly given into four quadrants; a total of four to six injections are made at the proximal edge of the stricture and another four to six injections into the strictured segment proper whenever possible. Injections should be given just before

dilation whenever possible. In long strictures, injections are first made at the entrance to the stricture, and as the stricture opens they are placed in more distal locations^[14]. Kochhar *et al.*^[12] suggest that patients with proximal strictures and long strictures should undergo dilation first, followed 2 h later by injections so that the whole length of the stricture can be injected.

Although injections can be made satisfactorily under endoscopic guidance, failures have been noted. Improper localization of the injection has been cited as a probable cause^[13]. Bhutani *et al.*^[29] have therefore suggested that an endoscopic ultrasound miniprobe should be used to guide the injection into the thickest portion of the esophageal stricture for better results. In their study, one patient with a stricture 4 cm long responded well to steroid injection under ultrasound miniprobe guidance (for 6 mo) after only partially responding (for 12 wk) to steroid injection without ultrasound guidance.

The injection can be repeated if there is no subjective improvement in the dysphagia score or a rapid recurrence of dysphagia is seen. There is no consensus regarding the number of injections to be administered. After each dilation, patients should remain under observation for at least 4 h. After a luminal diameter of 15 mm has been reached, a contrast study may be repeated for documentation (Figure 2).

Mechanism of action

The exact mechanism by which intralesional steroids enhance the efficacy of dilation is not clear. Intralesional steroid injections have been shown to inhibit stricture formation by interfering with collagen synthesis, fibrosis, and chronic scarring processes^[38]. Triamcinolone inhibits the transcription of matrix protein genes, including fibronectin and procollagen. It also reduces the synthesis of α_2 -macroglobulin, an inhibitor of collagenase activity^[24]. It has also been suggested that triamcinolone prevents the cross-linking of collagen that results in scar contraction, so that if the scar is stretched and corticosteroid is

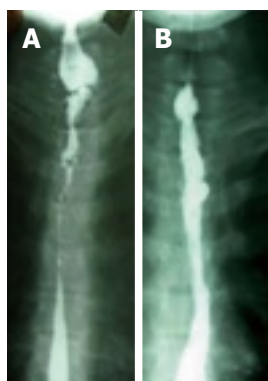

Figure 2 Barium swallow image of a stricture. A: A complex resistant esophageal stricture; B: The opened stricture after intralesional steroid injection and balloon dilation.

injected into it, contracture will presumably not occur^[10]. Corticosteroids also decrease the fibrotic healing that appears to occur after dilation^[38]. Gandhi *et al*^[27] observed that with corticosteroid injections and dilations, longer corrosive strictures became shorter with time and thus more amenable to nonsurgical treatment.

Assessment of efficacy

In one of the earliest studies, the efficacy of intralesional steroids was tested in an animal model. In canine models of lye-induced esophageal strictures, Ashcraft and Holder^[38] and our own group^[12,13] confirmed the efficacy of this form of therapy in conjunction with dilation treatment.

The efficacy of steroid injections in humans has traditionally been assessed by studying the need for dilations, the time to dilations, and the number of additional dilations. A periodic dilation index (PDI), calculated as the number of dilations required/duration of time in months, has frequently been used to demonstrate efficacy^[12,13].

ESOPHAGEAL STRICTURES

Peptic strictures

As many as 60%-70% of benign esophageal strictures are peptic in origin and result from acid-induced mucosal damage^[39]. These patients routinely undergo stricture dilation. However, nearly half of them require subsequent dilation within 1 year, and two-thirds of those requiring repeat dilation within the first year require additional subsequent dilations^[40]. Although proton-pump inhibitors may reduce the rate of recurrent stricture formation, a significant proportion of patients require repeated periodic dilation^[28]. It is in this group of patients that intralesional steroids have been shown to be useful in reducing the need for repeated dilations. Most of the literature reports on the use of intralesional steroids refer to patients with peptic strictures. Kirsch *et al*^[11] were among the first to demonstrate the usefulness of this form of treatment using fiberoptic endoscopes. They showed a dramatic improvement in two patients with resistant peptic strictures. Lee *et al*^[9] used this therapy in a total of 31 patients, 12 of whom had peptic strictures. All of them showed a reduced need for dilation and an increase in the interval between dilations. Kochhar *et al*^[12]

devised an objective parameter for evaluating the response to intralesional steroids, terming the number of dilations required per month the PDI. They studied 14 patients with peptic strictures who required repeated dilation and were given intralesional triamcinolone acetate (40 mg/mL, dilute 1:1) in aliquots of 0.5 mL in four quadrants around the stricture. The periodic dilation index (number of dilations per month) fell significantly from 0.92 ± 0.44 to 0.42 ± 0.2 over a postdilatation period of 3-12 mo. This was also associated with a significant ($P < 0.001$) improvement in the dysphagia score (0.28 ± 0.46 vs 1.85 ± 0.36).

Two randomized trials have confirmed the utility of this form of therapy. Altintas *et al*^[41] randomly assigned 21 patients with esophageal strictures who were undergoing bougie dilation either to an intralesional steroid injection group or to a control group. There were six patients with peptic strictures in the study group and four in the control group. The authors injected triamcinolone acetate (40 mg/mL) diluted with 4 mL of saline in four aliquots into the proximal segment of the stricture. The periodic dilation index declined from 0.71 to 0.28 in the study group, which also had a longer symptom-free interval than the control group. Ramage *et al*^[28], in a study including 30 patients with peptic strictures who required repeated dilations, randomly assigned the patients to an intralesional triamcinolone group (40 mg/mL; 0.5 mL in each quadrant) and a sham injection group. During a follow-up period of 1 year, two patients (13%) in the study group and nine patients (60%) in the control group required repeat dilation. Two patients in each group required fundoplication. In another randomized study, published only as an abstract, Rupp *et al*^[35] randomly assigned 43 patients with peptic strictures to an intralesional steroid group and a control group. The PDI was 0.07 in the steroid group in comparison with 0.253 in the control group over 10-13 mo after steroid therapy. Kochhar and Makharia^[13] repeated intralesional steroid injections in each session of dilation, with a limit of four injections. Ramage *et al*^[28] and Altintas *et al*^[41] gave steroid injections only once. In all of the studies, steroid injections were combined with bougienage or balloon dilation and all of the patients received proton-pump inhibitors.

Caustic strictures

Caustic-induced strictures are often multiple, tortuous, and more difficult to treat^[16]. They are reported to require larger numbers of dilations in comparison with peptic strictures^[42]. Most of the early reports on intralesional steroid treatment concerned difficult strictures following caustic ingestion. Mendelson and Maloney^[10], using rigid endoscopes, administered two different steroid injections (hydrocortisone and triamcinolone) in five patients with caustic-induced esophageal strictures, with good results in four of the patients. In one patient, they used a hyaluronidase injection along with hydrocortisone acetate. In another study, Gandhi *et al*^[27] carried out 2-13 sessions of intralesional steroid treatment in six

infants and children (aged 4 mo-5 years) with caustic-induced strictures and reported a good response in all cases, with 4-11 years of follow-up. Kochhar *et al*^[12] used triamcinolone acetonide (10 mg/mL) in 17 patients with caustic-induced esophageal strictures, 14 of whom had already had repeated dilations, while the other three had not yet undergone dilation. Eleven of the strictures were 3-6 cm long. The periodic dilation index in 14 patients who had previously been receiving dilation treatment declined from 1.67 to 0.32. The mean number of dilations in these patients was 27.9 over a 22-mo period before steroid injections and 3.57 over a period of 10.5 mo after steroid injections. Significantly, three patients did not require any further dilation after the steroid injections. In another study, Kochhar and Makharia^[13] reported the use of steroids in 29 patients with caustic-induced esophageal strictures. The periodic dilation index declined from 1.37 (0.5-3.16) before injections to 0.53 (0.1-1.33) after injections. These data confirm the benefit of steroid injections in patients with caustic-induced esophageal strictures, which was also associated with a significant ($P < 0.001$) improvement in the dysphagia score. There has been one randomized trial comparing triamcinolone injection with saline injection in 14 patients. A larger luminal diameter was achieved in the patients in the steroid group in comparison with those in the control group^[43].

Anastomotic strictures

In a study by Catalano *et al*^[44], seven of 15 patients with anastomotic strictures following resection of esophageal carcinoma received triamcinolone injections at the anastomotic site (four quadrants); these patients were classified as having refractory cases following the initial dilation. The symptoms resolved in all of the patients following complete serial dilation. They were all placed on high-dose proton-pump inhibitor treatment following the initial endoscopic dilation. Three stricture recurrences occurred at 2, 4, and 9 mo and were treated successfully by repeat dilation with the use of intralesional steroids. No complications were encountered during therapy. In another study on anastomotic esophageal strictures, Catalano *et al*^[45] found that patients who received steroid injections (triamcinolone 40 mg) along with balloon dilation required fewer dilation sessions (mean 2.7 *vs* 4.4) and had fewer recurrences (0 *vs* 2) in comparison with those who received balloon dilation alone. Miyashita *et al*^[34] used injections of dexamethasone (8 mg) around the anastomotic site immediately after balloon dilation in 11 patients with anastomotic strictures following esophagogastrostomy. Endoscopic steroid injection immediately after balloon dilation enhanced the effect of the procedure and significantly reduced the number of treatments needed. Kochhar and Makharia^[13] used steroid injections in 19 anastomotic strictures following transhiatal esophagectomy and observed a decline in the periodic dilation index from 1.24 (0.13-2.0) before steroid injections to 0.51 (0-2) after injection therapy. There was a significant increase in the maximum dilation diameter achieved after injection therapy. This was also

associated with a significant ($P < 0.001$) improvement in the dysphagia score (0.63 ± 0.59 *vs* 2.42 ± 0.5).

Radiation strictures

Radiation-induced strictures are often difficult to treat, due to intense fibrosis. In a study including six patients with radiation stricture, Lee *et al*^[9] injected 28 mg of triamcinolone in each session. The study by Kochhar and Makharia^[13] included nine patients with radiation-induced esophageal strictures. The periodic dilation index decreased significantly from 1.32 (0-2) to 0.6 (0-1) ($P < 0.02$) following use of intralesional triamcinolone injections. This was also associated with a significant ($P < 0.001$) improvement in the dysphagia score (1.22 ± 0.44 *vs* 2.44 ± 0.52). Other researchers have also used steroid injections in the treatment of small numbers of patients with radiation-induced strictures^[8,41].

Other etiologies

Various reports have included a few patients with strictures of other etiologies who have undergone intralesional steroid treatment. Lee *et al*^[9] described one patient with a sclerotherapy-induced stricture and one with pill-induced esophagitis in their series. Gandhi *et al*^[27] used steroid injections to treat five patients with esophageal atresia, with a good response.

PYLORIC STENOSIS

There have only been a few reports on the use of intralesional steroids in the treatment of pyloric stenosis. Lee *et al*^[9] treated two such patients with injections of 10 mg/mL triamcinolone in two patients, in one case with a peptic etiology and in the other following pyloroplasty. Subsequently, Kochhar *et al*^[46] treated three patients with caustic-induced pyloric stenosis, in two of whom balloon dilation had previously failed. They administered one session of steroid injection each in two patients, while two sessions were given in one patient. All three patients remained well during a follow-up period of up to 3 years and 3 mo.

BILIARY STRICTURES

In a pilot study of eight benign biliary strictures (post-operative, $n = 6$; primary sclerosing cholangitis, $n = 2$), Wehrmann *et al*^[47] injected 2×10 mg of triamcinolone into the wall of the common bile duct (CBD) at the stricture site using a sclerotherapy needle, along with dilation and placement of a 10-Fr stent. The initial mean diameter of the CBD stenoses was 1.81 mm. The mean serum levels of alkaline phosphatase and bilirubin were 455 U/L and 4.9 mg/dL, respectively. No significant improvement was observed after the initial balloon dilation and stent insertion. However, after local triamcinolone injection and a second dilation and stent insertion, the diameter of the CBD stenosis increased significantly to 3.68 mm ($P < 0.01$). No adverse effects were noted. Three patients had complete recovery from the CBD stenosis after a third dilation; the remaining five patients

were cured after two or three additional balloon dilations with intermittent stent exchanges. Thereafter, no recurrent CBD stenoses were observed during a median follow-up of 12 mo. At the conclusion of the study, the mean serum alkaline phosphatase and bilirubin levels were 195 U/L and 1.2 mg/dL, respectively.

STRICTURES IN CROHN'S DISEASE

Although resection of stenotic or perforated intestinal segments in Crohn's disease is often unavoidable, surgical remission is only temporary. New lesions are found on endoscopy in more than 70% of patients within a year and 40% become symptomatic within 4 years^[48]. Uncontrolled transformation of resident mesenchymal cells into matrix-depositing myofibroblasts is the most likely cause of fibrosis in Crohn's disease^[49], but the underlying molecular mechanisms have not yet been fully explained. As repeated bowel resections may lead to short bowel syndrome, the quest for bowel-conserving strategies during the last 25 years led to the development of both endoscopic and surgical strictureplasty in clinical practice.

Successful endoscopic dilation of anastomotic or intrinsic strictures in patients with Crohn's disease, using through-the-scope rigid balloons, was first reported in 1981. This procedure is indicated for relatively short (maximum 5 cm), symptomatic, and isolated strictures within the reach of the endoscope in the upper and lower gastrointestinal tract. The immediate success rates vary between 71% and 100%, with symptom recurrence in 13%-100% of patients^[33,50-54]. Because of suboptimal long-term outcomes with endoscopic balloon dilation, adjuvant techniques such as intralesional steroid injection have been studied.

In a pilot study of intrastricture steroid injection versus placebo injection after balloon dilation of Crohn's strictures, East *et al*^[55] noted that a single treatment with intrastricture triamcinolone injection did not reduce the time to redilation after balloon dilation of Crohn's ileocolonic anastomotic strictures, and there was a trend toward a poorer outcome.

However, Ramboer *et al*^[33] reported a 100% immediate success rate in 13 patients with endoscopic dilation and intramural injection of corticosteroids after the procedure. During a follow-up of 9-73 mo, three patients remained asymptomatic, three required one additional session, and the rest required four or more sessions of dilation with steroid injection. Two operations were carried out during this period, but they were not related to the treated segment itself.

More recently, Singh *et al*^[56] have reported 29 stricture dilations in 17 patients with Crohn's disease (10 female, seven male) with 20 strictures. Five of the strictures were located in the rectum, two in the sigmoid colon, three at colo-colonic anastomoses, four at ileocolonic anastomoses, one in the ileum, one in the descending colon, one in the cecum, and three in the distal duodenal bulb. The mean follow-up period was 18.8 mo (range 5-50 mo).

Technical success was achieved in 28 of the 29 stricture dilations (96.5%). Four-quadrant steroid injections were carried out in 11 strictures. The recurrence rate in this group was 10% and that in the nonsteroid group was 31.3%. Three perforations occurred (all colonic) during the 29 stricture dilations - a complication rate of 10%, with no mortalities.

Lavy^[57] described the treatment of 10 patients with colonic strictures attributable to Crohn's disease who were treated with dilation and injection of triamcinolone. Five of the patients had postoperative strictures. Two patients required additional dilation and injection of steroids after 1 year, while eight patients remained well over a follow up period of 1.5-3 years.

In a retrospective study by Brooker *et al*^[58], 14 patients with Crohn-related strictures underwent a total of 26 dilations, with triamcinolone being injected (median dose 20 mg, range 10-40 mg) in 20 of the procedures. Seven patients (50%) had sustained remission after a single dilation and steroid injection, with a median follow-up period of 16.4 mo (range 13.2-22.0 mo). Four patients (28.5%) required more than one dilation (median three dilations, range two to four) to control their symptoms, with a median follow-up period of 27.8 mo (range 14-32.8 mo). Endoscopic management failed in three patients (21.4%), who were referred for surgery. There were no complications due to dilation or triamcinolone injection.

Recently, Swaminath and Lichtiger^[59] have described dilation of a colonic stricture along with injection of infliximab into the distal and medial portions of the strictures in three patients refractory to all medical therapy, including systemic infliximab. Infliximab was effective in treating the strictures in all three patients.

USE IN PEDIATRIC PATIENTS

The safety of intralesional steroids has been documented in a number of studies in pediatric patients, including infants. Zein *et al*^[8] described intralesional steroid injection treatment in seven boys ranging in age from 1-14 years. Three patients had strictures secondary to gastroesophageal reflux; one had a stricture as a complication of radiation therapy to the mediastinum for treatment of lymphoma; one had a stricture at the site of a surgical anastomosis after repair of an esophageal fistula; one had a stricture that developed after lye ingestion; and one was later found at surgery to have a tracheobronchial remnant. Each patient underwent two sessions of intralesional steroid injections, 3-20 d apart, with a 10-mg/mL solution of triamcinolone acetate. An average of four injections per session were given circumferentially, using 0.2 mL of triamcinolone at each site, before balloon dilation. Only two of the seven patients did not show improvement with the steroid injections; one later had a tracheobronchial remnant diagnosed after a limited esophageal resection, and the other, in whom the stricture was related to lye ingestion, required partial esophagectomy to relieve the symptoms. Similar beneficial effects in pediatric esophageal strictures have been observed by Mendelson and Maloney^[10] and Gandhi *et al*^[27].

COMPLICATIONS

There is a theoretical risk that intramural infection might be induced with this form of therapy. Some esophageal strictures are known to be associated with intramural pseudodiverticula, which has been causally linked to *Candida albicans*^[26]. Zein *et al*^[8] observed *Candida albicans* esophagitis at the site of injection in one patient, and a suspected yeast esophagitis in another. Both were easily treated with an oral antifungal medication. Theoretically, there is a potential for esophageal perforation and mediastinitis or pleural effusion. The only reported esophageal perforation occurred in a series of patients in whom a rigid endoscope was used^[10]. Lilly and Bensard^[60] reported a significant delay in linear growth in a young boy who had been intermittently treated with intralesional steroids for esophageal stricture between the ages of 5 mo and 2 years. Growth returned to normal after steroid injections were stopped.

CONCLUSION

It has been demonstrated that intralesional steroid injections augment the effect of endoscopic dilation in strictures of varied etiologies and at various sites. As has been recommended in an editorial, intralesional steroid injection therapy should be considered in patients with refractory strictures, especially complex strictures^[61]. Triamcinolone acetate/acetone is the most widely used steroid. The dosage that has been shown to be most effective is 20 mg in each quadrant, to a total of 80 mg. The triamcinolone suspension may need to be diluted for easier injection. The number of sessions of steroid injections that can be carried out has still not yet been determined. Endoscopic ultrasonography may be helpful to improve the targeting of injections.

REFERENCES

- 1 **Lew RJ**, Kochman ML. A review of endoscopic methods of esophageal dilation. *J Clin Gastroenterol* 2002; **35**: 117-126
- 2 **Pereira-Lima JC**, Ramires RP, Zamin I Jr, Cassal AP, Marroni CA, Mattos AA. Endoscopic dilation of benign esophageal strictures: report on 1043 procedures. *Am J Gastroenterol* 1999; **94**: 1497-1501
- 3 **Said A**, Brust DJ, Gaumnitz EA, Reichelderfer M. Predictors of early recurrence of benign esophageal strictures. *Am J Gastroenterol* 2003; **98**: 1252-1256
- 4 **Spechler SJ**. American gastroenterological association medical position statement on treatment of patients with dysphagia caused by benign disorders of the distal esophagus. *Gastroenterology* 1999; **117**: 229-233
- 5 **Hordijk ML**, Siersema PD, Tilanus HW, Kuipers EJ. Electrocautery therapy for refractory anastomotic strictures of the esophagus. *Gastrointest Endosc* 2006; **63**: 157-163
- 6 **Repici A**, Conio M, De Angelis C, Battaglia E, Musso A, Pellicano R, Goss M, Venezia G, Rizzetto M, Saracco G. Temporary placement of an expandable polyester silicone-covered stent for treatment of refractory benign esophageal strictures. *Gastrointest Endosc* 2004; **60**: 513-519
- 7 **Kochman ML**, McClave SA, Boyce HW. The refractory and the recurrent esophageal stricture: a definition. *Gastrointest Endosc* 2005; **62**: 474-475
- 8 **Zein NN**, Greseth JM, Perrault J. Endoscopic intralesional steroid injections in the management of refractory esophageal strictures. *Gastrointest Endosc* 1995; **41**: 596-598
- 9 **Lee M**, Kubik CM, Polhamus CD, Brady CE 3rd, Kadakia SC. Preliminary experience with endoscopic intralesional steroid injection therapy for refractory upper gastrointestinal strictures. *Gastrointest Endosc* 1995; **41**: 598-601
- 10 **Mendelsohn HJ**, Maloney WH. The treatment of benign strictures of the esophagus with cortisone injection. *Ann Otol Rhinol Laryngol* 1970; **79**: 900-904
- 11 **Kirsch M**, Blue M, Desai RK, Sivak MV Jr. Intralesional steroid injections for peptic esophageal strictures. *Gastrointest Endosc* 1991; **37**: 180-182
- 12 **Kochhar R**, Ray JD, Sriram PV, Kumar S, Singh K. Intralesional steroids augment the effects of endoscopic dilation in corrosive esophageal strictures. *Gastrointest Endosc* 1999; **49**: 509-513
- 13 **Kochhar R**, Makharia GK. Usefulness of intralesional triamcinolone in treatment of benign esophageal strictures. *Gastrointest Endosc* 2002; **56**: 829-834
- 14 **DiSario JA**, Pedersen PJ, Bichis-Canoutas C, Alder SC, Fang JC. Incision of recurrent distal esophageal (Schatzki) ring after dilation. *Gastrointest Endosc* 2002; **56**: 244-248
- 15 **Brandimarte G**, Tursi A. Endoscopic treatment of benign anastomotic esophageal stenosis with electrocautery. *Endoscopy* 2002; **34**: 399-401
- 16 **Hagiwara A**, Togawa T, Yamasaki J, Shirasu M, Sakakura C, Yamagishi H. Endoscopic incision and balloon dilatation for cicatricial anastomotic strictures. *Hepatogastroenterology* 1999; **46**: 997-999
- 17 **Fiorini A**, Fleischer D, Valero J, Israeli E, Wengrower D, Goldin E. Self-expandable metal coil stents in the treatment of benign esophageal strictures refractory to conventional therapy: a case series. *Gastrointest Endosc* 2000; **52**: 259-262
- 18 **Song HY**, Jung HY, Park SI, Kim SB, Lee DH, Kang SG, Il Min Y. Covered retrievable expandable nitinol stents in patients with benign esophageal strictures: initial experience. *Radiology* 2000; **217**: 551-7
- 19 **Radecke K**, Gerken G, Treichel U. Impact of a self-expanding, plastic esophageal stent on various esophageal stenoses, fistulas, and leakages: a single-center experience in 39 patients. *Gastrointest Endosc* 2005; **61**: 812-818
- 20 **Fry SW**, Fleischer DE. Management of a refractory benign esophageal stricture with a new biodegradable stent. *Gastrointest Endosc* 1997; **45**: 179-182
- 21 **Kim CH**, Groskreutz JL, Gehrking SJ. Recurrent benign esophageal strictures treated with self-bougienage: report of seven cases. *Mayo Clin Proc* 1990; **65**: 799-803
- 22 **Lucktong TA**, Morton JM, Shaheen NJ, Farrell TM. Resection of benign esophageal stricture through a minimally invasive endoscopic and transgastric approach. *Am Surg* 2002; **68**: 720-723
- 23 **Beilstein MC**, Kochman ML. Endoscopic incision of a refractory esophageal stricture: novel management with an endoscopic scissors. *Gastrointest Endosc* 2005; **61**: 623-625
- 24 **Ketchum LD**, Smith J, Robinson DW, Masters FW. The treatment of hypertrophic scar, keloid and scar contracture by triamcinolone acetone. *Plast Reconstr Surg* 1966; **38**: 209-218
- 25 **Kiil J**. Keloids treated with topical injections of triamcinolone acetone (kenalog). Immediate and long-term results. *Scand J Plast Reconstr Surg* 1977; **11**: 169-172
- 26 **Sabanathan S**, Salama FD, Morgan WE. Oesophageal intramural pseudodiverticulosis. *Thorax* 1985; **40**: 849-857
- 27 **Gandhi RP**, Cooper A, Barlow BA. Successful management of esophageal strictures without resection or replacement. *J Pediatr Surg* 1989; **24**: 745-749; discussion 749-750
- 28 **Ramage JI Jr**, Rumalla A, Baron TH, Pochron NL, Zinsmeister AR, Murray JA, Norton ID, Diehl N, Romero Y. A prospective, randomized, double-blind, placebo-controlled trial of endoscopic steroid injection therapy for

- recalcitrant esophageal peptic strictures. *Am J Gastroenterol* 2005; **100**: 2419-2425
- 29 **Bhutani MS**, Usman N, Shenoy V, Qarqash A, Singh A, Barde CJ, Gopalswamy N. Endoscopic ultrasound miniprobe-guided steroid injection for treatment of refractory esophageal strictures. *Endoscopy* 1997; **29**: 757-759
- 30 **Eisen GM**, Baron TH, Dominitz JA, Faigel DO, Goldstein JL, Johanson JF, Mallory JS, Raddawi HM, Vargo JJ 2nd, Waring JP, Fanelli RD, Wheeler-Harbough J. Guideline on the management of anticoagulation and antiplatelet therapy for endoscopic procedures. *Gastrointest Endosc* 2002; **55**: 775-779
- 31 **Hirota WK**, Petersen K, Baron TH, Goldstein JL, Jacobson BC, Leighton JA, Mallory JS, Waring JP, Fanelli RD, Wheeler-Harbough J, Faigel DO. Guidelines for antibiotic prophylaxis for GI endoscopy. *Gastrointest Endosc* 2003; **58**: 475-482
- 32 **Petrini J**, Egan JV. Risk management regarding sedation/analgesia. *Gastrointest Endosc Clin N Am* 2004; **14**: 401-414
- 33 **Ramboer C**, Verhamme M, Dhondt E, Huys S, Van Eygen K, Vermeire L. Endoscopic treatment of stenosis in recurrent Crohn's disease with balloon dilation combined with local corticosteroid injection. *Gastrointest Endosc* 1995; **42**: 252-255
- 34 **Miyashita M**, Onda M, Okawa K, Matsutani T, Yoshiyuki T, Sasajima K, Kyono S, Yamashita K. Endoscopic dexamethasone injection following balloon dilatation of anastomotic stricture after esophagogastrotomy. *Am J Surg* 1997; **174**: 442-444
- 35 Rupp T, Earle D, Ikenberry S, Lumeng L, Lehman G. Randomized trial of Savary dilation with/without intralesional steroids for benign gastroesophageal reflux strictures [abstract]. *Gastrointest Endosc* 1995; **41**: 357
- 36 **Morikawa N**, Honna T, Kuroda T, Watanabe K, Tanaka H, Takayasu H, Fujino A, Tanemura H, Matsukubo M. High dose intravenous methylprednisolone resolves esophageal stricture resistant to balloon dilatation with intralesional injection of dexamethasone. *Pediatr Surg Int* 2008; **24**: 1161-1164
- 37 **Pelclová D**, Navrátil T. Do corticosteroids prevent oesophageal stricture after corrosive ingestion? *Toxicol Rev* 2005; **24**: 125-129
- 38 **Ashcraft KW**, Holder TM. The experimental treatment of esophageal strictures by intralesional steroid injections. *J Thorac Cardiovasc Surg* 1969; **58**: 685-691 passim
- 39 **Spechler SJ**. AGA technical review on treatment of patients with dysphagia caused by benign disorders of the distal esophagus. *Gastroenterology* 1999; **117**: 233-254
- 40 **Patterson DJ**, Graham DY, Smith JL, Schwartz JT, Alpert E, Lanza FL, Cain GD. Natural history of benign esophageal stricture treated by dilatation. *Gastroenterology* 1983; **85**: 346-350
- 41 **Altintas E**, Kacar S, Tunc B, Sezgin O, Parlak E, Altiparmak E, Saritas U, Sahin B. Intralesional steroid injection in benign esophageal strictures resistant to bougie dilation. *J Gastroenterol Hepatol* 2004; **19**: 1388-1391
- 42 **Broor SL**, Kumar A, Chari ST, Singal A, Misra SP, Kumar N, Sarin SK, Vij JC. Corrosive oesophageal strictures following acid ingestion: clinical profile and results of endoscopic dilatation. *J Gastroenterol Hepatol* 1989; **4**: 55-61
- 43 **Camargo MA**, Lopes LR, Grangeia Tde A, Andreollo NA, Brandalise NA. [Use of corticosteroids after esophageal dilations on patients with corrosive stenosis: prospective, randomized and double-blind study] *Rev Assoc Med Bras* 2003; **49**: 286-292
- 44 **Catalano MF**, George S, Thomas M, Geenen JE. Endoscopic treatment of anastomotic strictures following resection of esophageal carcinoma: Increased success using submucosal corticosteroid injection (Abstract W1501). *Gastrointest Endosc* 2004; **59**: P241
- 45 **Catalano MF**, Kaul V, Pezanoski J, Guda N, Geenen JE. Endoscopic treatment of anastomotic strictures following resection of esophageal carcinoma (Abstract S1305). *Gastrointest Endosc* 2007; **65**: AB139
- 46 **Kochhar R**, Dutta U, Sethy PK, Singh G, Sinha SK, Nagi B, Wig JD, Singh K. Endoscopic balloon dilation in caustic-induced chronic gastric outlet obstruction. *Gastrointest Endosc* 2009; **69**: 800-805
- 47 **Wehrmann T**, Schmitt T, Caspary WF, Seifert H. [Local injection of depot corticosteroids in endoscopic therapy of benign bile duct strictures] *Z Gastroenterol* 2000; **38**: 235-241
- 48 **Rutgeerts P**, Geboes K, Vantrappen G, Beyls J, Kerremans R, Hiele M. Predictability of the postoperative course of Crohn's disease. *Gastroenterology* 1990; **99**: 956-963
- 49 **Pucilowska JB**, Williams KL, Lund PK. Fibrogenesis. IV. Fibrosis and inflammatory bowel disease: cellular mediators and animal models. *Am J Physiol Gastrointest Liver Physiol* 2000; **279**: G653-G659
- 50 **Blomberg B**, Rolny P, Järnerot G. Endoscopic treatment of anastomotic strictures in Crohn's disease. *Endoscopy* 1991; **23**: 195-198
- 51 **Couckuyt H**, Gevers AM, Coremans G, Hiele M, Rutgeerts P. Efficacy and safety of hydrostatic balloon dilatation of ileocolonic Crohn's strictures: a prospective longterm analysis. *Gut* 1995; **36**: 577-580
- 52 **Dear KL**, Hunter JO. Colonoscopic hydrostatic balloon dilatation of Crohn's strictures. *J Clin Gastroenterol* 2001; **33**: 315-318
- 53 **Junge U**, Züchner H. [Endoscopic balloon dilatation of symptomatic strictures in Crohn's disease] *Dtsch Med Wochenschr* 1994; **119**: 1377-1382
- 54 **Thomas-Gibson S**, Brooker JC, Hayward CM, Shah SG, Williams CB, Saunders BP. Colonoscopic balloon dilation of Crohn's strictures: a review of long-term outcomes. *Eur J Gastroenterol Hepatol* 2003; **15**: 485-488
- 55 **East JE**, Brooker JC, Rutter MD, Saunders BP. A pilot study of intrastricture steroid versus placebo injection after balloon dilatation of Crohn's strictures. *Clin Gastroenterol Hepatol* 2007; **5**: 1065-1069
- 56 **Singh VV**, Draganov P, Valentine J. Efficacy and safety of endoscopic balloon dilation of symptomatic upper and lower gastrointestinal Crohn's disease strictures. *J Clin Gastroenterol* 2005; **39**: 284-290
- 57 **Lavy A**. Triamcinolone improves outcome in Crohn's disease strictures. *Dis Colon Rectum* 1997; **40**: 184-186
- 58 **Brooker JC**, Beckett CG, Saunders BP, Benson MJ. Long-acting steroid injection after endoscopic dilation of anastomotic Crohn's strictures may improve the outcome: a retrospective case series. *Endoscopy* 2003; **35**: 333-337
- 59 **Swaminath A**, Lichtiger S. Dilation of colonic strictures by intralesional injection of infliximab in patients with Crohn's colitis. *Inflamm Bowel Dis* 2008; **14**: 213-216
- 60 **Lilly JR**, Bensard D. Intralesional steroid injection in the management of esophageal stricture. *J Pediatr Surg* 1989; **24**: 1312
- 61 **Shah JN**. Benign refractory esophageal strictures: widening the endoscopist's role. *Gastrointest Endosc* 2006; **63**: 164-167

S- Editor Zhang HN L- Editor Robertson M E- Editor Ma WH

Short term results of endoscopic submucosal dissection in superficial esophageal squamous cell neoplasms

Kouichi Nonaka, Shin Arai, Keiko Ishikawa, Masamitsu Nakao, Yousuke Nakai, Osamu Togawa, Koji Nagata, Michio Shimizu, Yutaka Sasaki, Hiroto Kita

Kouichi Nonaka, Shin Arai, Keiko Ishikawa, Masamitsu Nakao, Yousuke Nakai, Osamu Togawa, Hiroto Kita, Department of Gastroenterology, Saitama Medical University International Medical Center, Saitama 350-1298, Japan
Koji Nagata, Michio Shimizu, Department of Pathology, Saitama Medical University International Medical Center, Saitama 350-1298, Japan

Yutaka Sasaki, Department of Gastroenterology, Faculty of Medicine, Kumamoto University, Kumamoto 860-0856, Japan

Author contributions: Nonaka K: study design, analysis and interpretation of data, drafting of the article; Arai S, Ishikawa K: critical revision of the article for important intellectual content; Nakao M, Nakai Y, Togawa O, Sasaki Y: analysis and interpretation of the data; Nagata K, Shimizu M: pathological analysis; Hiroto K: final approval of the article.

Correspondence to: Hiroto Kita, MD, Department of Gastroenterology, Saitama Medical University International Medical Center, 1397-1 Yamane, Hidaka, Saitama 350-1298, Japan. hkita@saitama-med.ac.jp

Telephone: +81-4-29844111 Fax: +81-4-29844741

Received: June 12, 2009 Revised: January 12, 2010

Accepted: January 19, 2010

Published online: February 16, 2010

Abstract

AIM: To evaluate the efficacy of endoscopic submucosal dissection for superficial esophageal squamous cell neoplasms.

METHODS: Between July 2007 and March 2009, 27 consecutive superficial esophageal squamous cell neoplasms in 25 enrolled patients were treated by endoscopic submucosal dissection. The therapeutic efficacy, complications, and follow-up results were assessed.

RESULTS: The mean size of the lesions was 21 ± 13 mm (range 2-55 mm); the mean size of the resection specimens was 32 ± 12 mm (range 10-70 mm). The en

block resection rate was 100% (27/27), and en block resection with tumor-free lateral/basal margins was 88.9% (24/27). Perforation occurred in 1 patient who was managed by conservative medical treatments. None of the patients developed local recurrence or distant metastasis in the follow-up period.

CONCLUSION: Endoscopic submucosal dissection is applicable to superficial esophageal squamous cell neoplasms with promising results.

© 2010 Baishideng. All rights reserved.

Key words: Endoscopic submucosal dissection; Esophageal cancer; Squamous cell; Neoplasm; Endoscopy

Peer reviewer: Seong Woo Jeon, Assistant Professor, Internal Medicine, Kyungpook National University Hospital, 50 Samduk-2Ga, Chung-gu, Daegu 700-721, South Korea

Nonaka K, Arai S, Ishikawa K, Nakao M, Nakai Y, Togawa O, Nagata K, Shimizu M, Sasaki Y, Kita H. Short term results of endoscopic submucosal dissection in superficial esophageal squamous cell neoplasms. *World J Gastrointest Endosc* 2010; 2(2): 69-74 Available from: URL: <http://www.wjgnet.com/1948-5190/full/v2/i2/69.htm> DOI: <http://dx.doi.org/10.4253/wjge.v2.i2.69>

INTRODUCTION

There is a considerable increase in the number of esophageal squamous cell neoplasms (SCNs) indicated for local treatment thanks to the recent development in endoscopy, including magnifying endoscopy by using narrow-band imaging (NBI) and iodine staining^[1,2]. Noninvasive carcinoma (carcinoma in situ, m1) and intramucosal invasive carcinoma limited to the lamina propria mucosae (m2) without vessels infiltration, have

proved to have no lymph node or distant metastases. This has been shown by a large number of retrospective histopathological analyses of surgically resected esophageal SCNs, and, as a result, endoscopic therapy may be considered as treatment option for these lesions.

Endoscopic mucosal resection (EMR) has been accepted widely for localized SCNs as an alternative to surgical therapy, especially in Japan, because of the considerable rates of surgical mortality and postsurgical complications related to esophagectomy (range 2.1% to 13.7%), that result in poor patient quality-of-life^[3-5]. The long-term outcomes after EMR of esophagus squamous cell carcinomas show similar effectiveness compared with surgical therapy for early-stage neoplasms^[6,7]. However, conventional EMR techniques are limited in resection size, and therefore large lesions need to be resected in multiple fragments.

In recent years, endoscopic submucosal dissection (ESD) has been developed as a method to resect larger lesions, as it enables precise resection irrespective of the size and shape of the lesions^[8-12]. On the other hand, ESD may be associated with technical difficulty and a higher incidence of complications. Although ESD is widely accepted as a more reliable therapeutic procedure for large superficial gastric cancer in Japan^[13-16], few studies have elucidated the technical feasibility of this procedure in the esophagus^[16]. This study set out to evaluate the efficacy, safety and short-term follow-up outcomes of ESD for esophageal SCNs.

PATIENTS AND METHODS

From July 2007 through March 2009, twenty-seven consecutive superficial esophageal SCNs, occurring in 25 patients, underwent ESD at the Saitama Medical University International Medical Center, Saitama, Japan. Diagnosis was made by using chromoendoscopy with iodine staining, NBI, and endoscopic biopsy. Endoscopic ultrasonography was also indicated for lesions suspected of submucosal invasion. All 25 patients were confirmed to have no lymph-node metastasis by CT before the treatment. Written informed consent was obtained from all the patients. 22 SCNs, preoperatively diagnosed as high-grade intraepithelial neoplasm (high-grade dysplasia and noninvasive carcinoma; m1) or intramucosal invasive carcinoma (m2), were primary indicated for ESD. Although the majority of the lesions were m2 or superficial infiltrations, in 4 SCNs, a small portion of m3 (invasive to the muscularis mucosae) to sm1 (less than 200 μ m below the muscularis mucosae) infiltration was suspected. ESD was also chosen in these 4 patients after informed consent was obtained. This was based on the patients' strong wish and to avoid risks associated with esophagectomy/chemoradiotherapy (CRT), because of the presence of accompanying diseases. In the remaining 1 patient, EUS and NBI-magnified observation suggested sm2 infiltration (more than 200 μ m below the muscularis mucosae). This patient had already undergone EMR and

radiotherapy several times for this lesion, and difficult endoscopic resection was expected for the local recurrent lesion due to fibrosis. However, ESD was chosen in this case, in accordance with the patient's strong wish.

Endoscopic operating system

ESD procedures were performed by using video endoscopes (GIF-Q260J; Olympus Optical Co, Ltd, Tokyo, Japan).

Procedure of ESD

Detail of the procedure has been described elsewhere^[17-19]. In brief, normal saline was pre-injected into the submucosal layer of the esophagus to avoid subsequent injections of sodium hyaluronate solution into an inappropriate layer. Sodium hyaluronate (0.5%) was then injected to make a good protrusion of the targeted mucosa. By mixing a small amount of dye, the sodium hyaluronate can be distinguished easily from the non-injected area even after the pre-injection of normal saline. A small amount of epinephrine was also mixed with sodium hyaluronate to diminish bleeding during the procedures. A mucosal incision around the tumor was then made with either a flash knife (KD-2618 JN-15; Fujinon) or flex knife (KD-630L; Olympus). The knife was gently pressed onto the mucosa. The distal half of the mucosal incision was completed first, followed by the proximal half. A hood, 4 mm in length attached at the endoscope tip, was also helpful for the safety of mucosal incision by blocking unintentional movements of the esophageal wall toward the knife.

Before incising the entire circumference of the lesion, dissection of the submucosa was started from the area in which the mucosal incision was completed, prior to the flattening of the lifted area as the procedure progressed. The principal knife used for the submucosal dissection was the same one as that used for the mucosal incision. A hook knife (KD-620LR; Olympus) was also used in combination with the principal knife in difficult dissections. The operation time was recorded for all the procedures. A typical example is shown in Figure 1.

In our department, a flex knife (KD-630L; Olympus) was used in 15 patients who were treated before June 2008. We then switched to a flash knife, of 1.5 mm in tip length, in all the patients since July 2008. A water-pumping function at the knife tip is employed in the flash knife, facilitating the removal of tissues such as lesions adhered to the tip during treatment without requiring knife extraction/insertion from/into a scope. In addition, saline employed for water pumping at the tip facilitates additional topical injection into the submucosal layer. This reduces time loss related to the frequent extraction/insertion of an injection needle for the additional topical injection of sodium hyaluronate. ESD of esophageal lesions was performed under general anesthesia managed by anesthesiologists in the operating room in 15 patients. In 10 patients, in who the resection was not expected to be difficult, the lesions

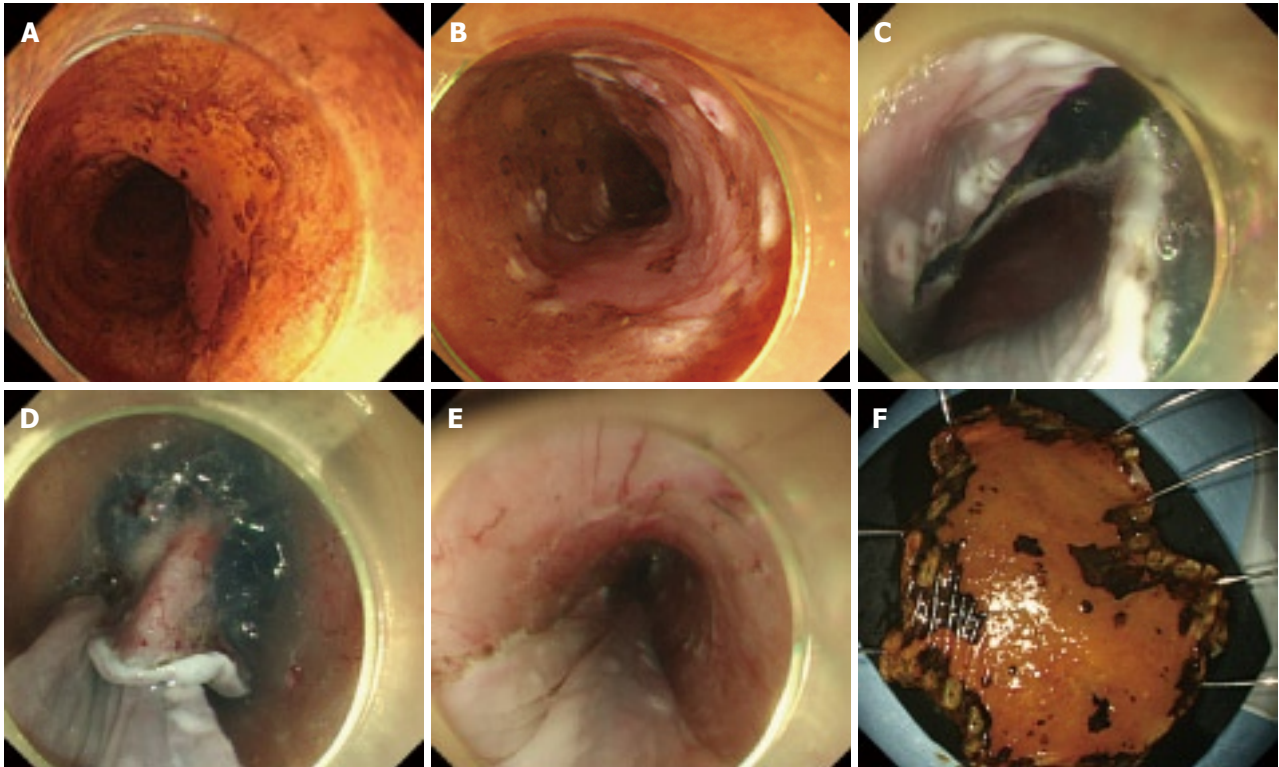


Figure 1 Typical example case of ESD for esophageal neoplasm. A: Chromoendoscopy with iodine staining to demarcate the lesion from the non-neoplastic area; B: Marking placement around the lesion; C: Initial mucosal incision after submucosal injection at the distal margin of the lesions; D: Mucosal incision after submucosal injection at the proximal margin of the lesion and subsequent submucosal dissection from the proximal end; E: Mucosal defect after ESD; F: Resected specimen.

were treated under conscious sedation with midazolam in the endoscopy room.

Histological assessment and follow up care

Histological evaluation of the resected specimen was performed according to the Paris classification and revised Vienna classification^[20-22]. The specimens, fixed by formalin, were cut into 2-mm slices. They were examined microscopically for histological type, depth on invasion (m1, m2, m3, sm1, sm2, sm3), lateral resection margin, and vertical resection margin.

Additional treatment was recommended for patients who had a histopathological diagnosis of invasive carcinoma deeper than the lamina propria mucosae (m3), or sm and/or vessel infiltration or incomplete resection on the basal margins, resection with non-evaluable tumor-free basal margins, or resection with tumor-exposed basal margins. Recommended treatments included CRT or radiation therapy alone for possible lymph node metastases or esophagectomy with lymph node dissection. In some cases the histopathological evaluation suggested that the lesions fulfilled the criteria of node-negative tumors but were resected incompletely on the lateral margins, resection with nonevaluable tumor-free lateral margins, or resection with tumor-exposed lateral margins. However, these patients were followed without additional treatments because the burn effects on the resected tissue sometimes made a precise histopathologic evaluation of the lateral margins difficult.

All patients who underwent ESD were regularly observed with half-yearly endoscopic examinations to check for local recurrence and/or a 2nd primary lesion as well as CTs to evaluate the existence of distant or lymph node metastases.

Statistical analysis

Some variables in this study were described as mean (SD). All statistical analyses were performed by using SAS version 8.0 (SAS Institute Inc, Cary, NC). The *P* value was 2 sided, and *P* < 0.05 was used to determine statistical validity.

RESULTS

The clinicopathologic characteristics of the included patients are shown in Table 1. The mean (SD) size of the lesions was 21 ± 13 mm (range 2-55 mm); the mean (SD) size of the resection specimens was 32 ± 12 mm (range 10-70 mm). All the lesions were resected in an en bloc fashion. En bloc resection with tumor-free lateral/basal margins was accomplished in 24 of the 27 dissected lesions (88.9%). 24 lesions (88.9%) were located in the thoracic esophagus. Twenty-one lesions (77.8%) (1 dysplasia, 6 mL, and 12 m2) in 19 patients were considered node-negative tumors by histopathological evaluations of the resected specimens. The mean procedure time of ESD was 88 ± 65 min (range 20-300 min). Minor bleeding was encountered in

Table 1 Clinicopathologic characteristic of esophageal SCNs

	Number of lesions	
Location	Ce/Ut/Mt/Lt/Ae	3/12/9/3/0
En bloc resection rate	100% (27/27)	
Tumor-free lateral margin rate	88.9% (24/27)	
Tumor-free basal margin rate	92.6% (25/27)	
Tumor-free lateral/basal rate	96.3% (26/27)	
Mean tumor size [mean (SD)], mm (range)	21 ± 13 mm (2-55)	
Mean specimen size [mean (SD)], mm (range)	32 ± 12 mm (10-70)	
Macroscopic type	II a/ II b/ II c/ II c + II b	2/5/19/3
Preoperative determining depth of invasion of SCNs	m1/m2/m3/sm1/sm2	7/15/2/2/1
Histologic depth	Dysplasia/m1/m2/m3/sm1/sm2	1/6/14/4/0/2
Vessel infiltration (+)		2
Procedure time [mean (SD)], min	88 ± 65 min	
Local recurrence		0
Complication (perforation)		1
The mean hospital length of stay	9 d	
Balloon dilation (+)		3

Ce: Cervical esophagus; Ut: Upper thoracic esophagus; Mt: Middle thoracic esophagus; Lt: Lower thoracic esophagus; Ae: Abdominal esophagus; II a: Superficial elevated type; II b: Flat type; II c: Superficial shallow depressed type; m1: Intraepithelial carcinoma; m2: Microinvasive carcinoma (invasion through the basement membrane); m3: Intramucosal carcinoma (invasion to the muscularis mucosae); sm1: Superficial invasion (less than 200 µm below the muscularis mucosae) in the submucosa; sm2: Middle invasion (more than 200 µm below the muscularis mucosae) in the submucosa; SCNs: esophageal squamous cell neoplasms.

all the dissections when incising the mucosa or dissecting the submucosal layer and hemostasis was achieved with thermocoagulation without the use of clips. No patient experienced massive hemorrhage requiring a blood transfusion or a postprocedure emergency endoscopy. Perforation, diagnosed by endoscopic findings of tearing of the proper muscle layer, occurred in 1 lesion. In this case, ESD was completed after closing the perforation site *via* endoscopic clipping. Fever and thoracic pain was noted after the surgery and this patient was cured conservatively. Three lesions in 3 patients required several sessions of periodic balloon dilation for esophageal stricture after ESD. The postprocedure stricture was successfully managed endoscopically in all cases. None of the patients developed local recurrence or distant metastasis in the follow-up period. By preoperative examination, 7 lesions were diagnosed as m1, 15 lesions as m2, 2 lesions as m3, 2 lesions as sm1, and 1 lesion as sm2. Histopathological diagnosis of esophageal SCNs after ESD were m1 in 6 lesions, m2 in 14 lesions, m3 in 4 lesions, sm2 in 2 lesions, and dysplasia in 1 lesion. The overall accuracy rate for depth of invasion was 62.9%.

Of the 8 lesions in 8 patients with concomitant risks of nodal metastases, 5 lesions in 5 patients were closely followed up without additional treatment, at the patient's decision. These included 3 with cancer

Table 2 Comparison of ESD under general anesthesia with that under intravenous anesthesia

	General anesthesia	Intravenous anesthesia	P value
Mean tumor size (mm)	26.9	15.1	$P < 0.05$
Procedure time (min)	98	75	NS
Complication (perforation)	0	1	NS
The mean hospital length of stay (day)	9.6	8.4	NS

NS: Not significant; ESD: endoscopic submucosal dissection.

infiltration in the muscularis mucosae (m3), one with m1 carcinoma in whom the horizontal stump was positive for tumor cells, and one with m2 carcinoma and lymphatic vessel infiltration, which increased the possibility of nodal metastasis. In one case with m3 infiltration, hypopharyngeal cancer was detected, and CRT was performed. In one case with sm infiltration in whom the horizontal stump was positive for tumor cells, additional surgery was conducted. In another case with sm infiltration in whom the vertical stump was positive for tumor cells, RT was performed. In 25 patients who underwent ESD (27 lesions), the mean admission period required for ESD was 9 d.

In our study, 3 cases developed stenosis and required dilatation after ESD. The lesions in these three cases were large, covering more than 3/4 of the circumference of the middle thoracic esophagus. Although ESD facilitates en bloc resection regardless of the size, wide lesions covering more than 3/4 of the circumference require frequent dilatation. This may reduce the patient's quality of life and, therefore, for larger lesions in the esophagus caution is required before carrying out endoscopic therapy.

As shown in Table 2, we compared 15 lesions in which ESD was performed under general anesthesia managed by anesthesiologists, with 12 lesions treated under conscious sedation. The mean lesion size was 26.9 mm in patients who underwent ESD under general anesthesia and 15.1 mm under conscious sedation. This significant difference was not unexpected because the choice of anaesthesia was based on the expected level of difficulty, including tumor size. There was no significant difference in the duration of surgery, incidences of complications, and mean admission period between the two groups.

Finally, we compared 15 lesions in which ESD was performed by using a flex knife, with 12 lesions treated by using a flash knife. As shown in Table 3, there is no significant difference between the two groups in the mean lesion size, duration of surgery, incidences of complications, and the rate of en-block resection.

DISCUSSION

In the field of gastric cancer treatment, ESD is incre-

Table 3 Comparison of ESD with flex knife and flush knife

	Flex knife	Flush knife	P
Mean tumor size (mm)	20	23	NS
Procedure time (min)	78	100	NS
Complication (perforation)	0	1	NS
En block resection rate (%)	100	100	NS

asingly employed following rapid technical advances. By contrast, in the field of esophageal cancer treatment, the development of ESD has been hampered because the esophageal wall is thin and perforation is a frequent complication of ESD. This can result in worsening of the patient's condition should mediastinitis develop. In addition, favorable mucosal mobility facilitates the resection of lesions measuring 2 cm or less using conventional EMR^[23-25]. However, the risk of residual tumor/relapse is increased after EMR in lesions measuring 2 cm or more. In these lesions, residual tumor/relapse is associated with the number of the resected sections, and not with the size or circumference. In our data, the rate of en-block resection was 100%. This suggests that ESD could overcome the risk of residual tumor/relapse associated with EMR.

Although the duration of follow-up is short, the present study also shows that no patient with esophageal SCNs, that met the criteria of node-negative tumors after the treatment with ESD, experienced recurrence extraluminally. Our data suggest that ESD can be a successful treatment for esophageal SCNs fulfilling the criteria of node-negative tumors. Furthermore, given the lack of complications, ESD can be considered to be a relatively safe procedure. The operative mortality rate was zero, and the only postoperative complication was benign stricture of the esophagus that could successfully be treated with balloon dilatation. Although 1 patient had small perforations, this was managed successfully without surgical rescue.

As esophageal surgery is invasive, postoperative management in the intensive care unit is required for a few days. A study reported that the mean admission period in patients undergoing esophagogastrectomy for ECJ lesions was 13.5 d^[5]. Other studies indicated that the mean admission period in patients undergoing minimally invasive esophagectomy for esophageal neoplasms was 7 to 8 d^[26,27]. ESD has considerable advantages over surgery, considering the high esophagectomy-related mortality rate and patient's reduced quality of life after surgery^[4,5,26,27]. In our study, the mean admission period was 9 d ESD was performed on more than half of the patients under general anesthesia, in whom the resection was expected to be difficult. However, they returned to a standard ward after the treatment, and were discharged after ESD, in a similar way to those conducted under conscious sedation. From a medico-economic viewpoint, the mean admission period in patients undergoing ESD for esophageal SCNs can be further shortened and this can also contribute to the advantage of ESD over surgery. In this study, there

were no significant differences between the flex knife and flush knife used for ESD in relation to duration of surgery, the incidence of complications, and the rate of en-block resection, although different knives may potentially have different characteristics.

The local recurrence rate after esophageal EMR was reported to be as high as 20% because en bloc resection by EMR was difficult and required multiple resection for large lesion^[24]. Moreover, a high incidence (21%) of complications in esophageal EMR (perforation and hemorrhage) has been reported^[28]. In our ESD cases, the outcomes were markedly favorable as complication occurred in only one patient and the en bloc resection rate was 100%. These findings suggest that ESD is safer and more useful than EMR.

In conclusion, our study shows that ESD is a feasible technique for the resection of esophageal SCNs. Accumulation of the further cases is necessary before ESD can be widely accepted as a standard treatment for esophageal SCNs.

COMMENTS

Background

Endoscopic en bloc resection of superficial esophageal squamous cell neoplasms is difficult.

Research frontiers

Endoscopic submucosal dissection (ESD) is applicable to esophagus superficial tumors.

Innovations and breakthroughs

The results of ESD in 25 esophageal cancer patients (27 lesions) were analyzed. A very high en bloc resection rate and high-level safety of the procedure were demonstrated.

Applications

ESD facilitated the safe en bloc resection of superficial esophageal squamous cell neoplasms regardless of the size.

Peer review

Although small sample size might hamper the merits of this study, there are few studies indicating the results of ESD in esophageal squamous cell carcinoma.

REFERENCES

- 1 **Mandard AM**, Tourneux J, Gignoux M, Blanc L, Segol P, Mandard JC. In situ carcinoma of the esophagus. Macroscopic study with particular reference to the Lugol test. *Endoscopy* 1980; **12**: 51-57
- 2 **Endo M**, Takeshita K, Yoshida M. How can we diagnose the early stage of esophageal cancer? *Endoscopic diagnosis Endoscopy* 1986; **18** Suppl 3: 11-18
- 3 **Makuuchi H**. Endoscopic mucosal resection for mucosal cancer in the esophagus. *Gastrointest Endosc Clin N Am* 2001; **11**: 445-458
- 4 **McCulloch P**, Ward J, Tekkis PP. Mortality and morbidity in gastro-oesophageal cancer surgery: initial results of ASCOT multicentre prospective cohort study. *BMJ* 2003; **327**: 1192-1197
- 5 **Karl RC**, Schreiber R, Boulware D, Baker S, Coppola D. Factors affecting morbidity, mortality, and survival in patients undergoing Ivor Lewis esophagogastrectomy. *Ann Surg* 2000; **231**: 635-643
- 6 **Shimizu Y**, Tsukagoshi H, Fujita M, Hosokawa M, Kato M, Asaka M. Long-term outcome after endoscopic mucosal resection in patients with esophageal squamous cell carcinoma invading the muscularis mucosae or deeper. *Gastrointest Endosc* 2002; **56**: 387-390

- 7 **Fujita H**, Sueyoshi S, Yamana H, Shinozaki K, Toh U, Tanaka Y, Mine T, Kubota M, Shirouzu K, Toyonaga A, Harada H, Ban S, Watanabe M, Toda Y, Tabuchi E, Hayabuchi N, Inutsuka H. Optimum treatment strategy for superficial esophageal cancer: endoscopic mucosal resection versus radical esophagectomy. *World J Surg* 2001; **25**: 424-431
- 8 **Yamamoto H**, Yube T, Isoda N, Sato Y, Sekine Y, Higashizawa T, Ido K, Kimura K, Kanai N. A novel method of endoscopic mucosal resection using sodium hyaluronate. *Gastrointest Endosc* 1999; **50**: 251-256
- 9 **Gotoda T**, Kondo H, Ono H, Saito Y, Yamaguchi H, Saito D, Yokota T. A new endoscopic mucosal resection procedure using an insulation-tipped electrosurgical knife for rectal flat lesions: report of two cases. *Gastrointest Endosc* 1999; **50**: 560-563
- 10 **Ono H**, Kondo H, Gotoda T, Shirao K, Yamaguchi H, Saito D, Hosokawa K, Shimoda T, Yoshida S. Endoscopic mucosal resection for treatment of early gastric cancer. *Gut* 2001; **48**: 225-229
- 11 **Oyama T**, Kikuchi Y. Aggressive endoscopic mucosal resection in the upper GI tract—Hook knife EMR method. *Min Invas Ther & Allied Technol* 2002; **11**: 291-295
- 12 **Yahagi N**, Fujishiro M, Kakushima N, Kobayashi K, Hashimoto T, Oka M, Iguchi M, Enomoto S, Ichinose M, Niwa H, Omata M. Endoscopic submucosal dissection for early gastric cancer using the tip of an electro-surgical snare (thin type). *Dig Endosc* 2004; **16**: 34-38
- 13 **Ono H**, Kondo H, Gotoda T, Shirao K, Yamaguchi H, Saito D, Hosokawa K, Shimoda T, Yoshida S. Endoscopic mucosal resection for treatment of early gastric cancer. *Gut* 2001; **48**: 225-229
- 14 **Ohkuwa M**, Hosokawa K, Boku N, Ohtu A, Tajiri H, Yoshida S. New endoscopic treatment for intramucosal gastric tumors using an insulated-tip diathermic knife. *Endoscopy* 2001; **33**: 221-226
- 15 **Yamamoto H**, Kawata H, Sunada K, Satoh K, Kaneko Y, Ido K, Sugano K. Success rate of curative endoscopic mucosal resection with circumferential mucosal incision assisted by submucosal injection of sodium hyaluronate. *Gastrointest Endosc* 2002; **56**: 507-512
- 16 **Fujishiro M**, Yahagi N, Kakushima N, Kodashima S, Muraki Y, Ono S, Yamamichi N, Tateishi A, Shimizu Y, Oka M, Ogura K, Kawabe T, Ichinose M, Omata M. Endoscopic submucosal dissection of esophageal squamous cell neoplasms. *Clin Gastroenterol Hepatol* 2006; **4**: 688-694
- 17 **Yamamoto H**, Kawata H, Sunada K, Satoh K, Kaneko Y, Ido K, Sugano K. Success rate of curative endoscopic mucosal resection with circumferential mucosal incision assisted by submucosal injection of sodium hyaluronate. *Gastrointest Endosc* 2002; **56**: 507-512
- 18 **Yamamoto H**, Kita H. Endoscopic therapy of early gastric cancer. *Best Pract Res Clin Gastroenterol* 2005; **19**: 909-926
- 19 **Kita H**, Yamamoto H, Miyata T, Sunada K, Iwamoto M, Yano T, Yoshizawa M, Hanatsuka K, Arashiro M, Omata T, Sugano K. Endoscopic submucosal dissection using sodium hyaluronate, a new technique for en bloc resection of a large superficial tumor in the colon. *Inflammopharmacology* 2007; **15**: 129-131
- 20 **The Paris endoscopic classification of superficial neoplastic lesions: esophagus, stomach, and colon: November 30 to December 1, 2002.** *Gastrointest Endosc* 2003; **58**: S3-S43
- 21 **Schlemper RJ**, Riddell RH, Kato Y, Borchard F, Cooper HS, Dawsey SM, Dixon MF, Fenoglio-Preiser CM, Flejou JF, Geboes K, Hattori T, Hirota T, Itabashi M, Iwafuchi M, Iwashita A, Kim YI, Kirchner T, Klimpfinger M, Koike M, Lauwers GY, Lewin KJ, Oberhuber G, Offner F, Price AB, Rubio CA, Shimizu M, Shimoda T, Sipponen P, Solcia E, Stolte M, Watanabe H, Yamabe H. The Vienna classification of gastrointestinal epithelial neoplasia. *Gut* 2000; **47**: 251-255
- 22 **Dixon MF**. Gastrointestinal epithelial neoplasia: Vienna revisited. *Gut* 2002; **51**: 130-131
- 23 **Ishihara R**, Iishi H, Takeuchi Y, Kato M, Yamamoto S, Yamamoto S, Masuda E, Tatsumi K, Higashino K, Uedo N, Tatsuta M. Local recurrence of large squamous-cell carcinoma of the esophagus after endoscopic resection. *Gastrointest Endosc* 2008; **67**: 799-804
- 24 **Katada C**, Muto M, Manabe T, Ohtsu A, Yoshida S. Local recurrence of squamous-cell carcinoma of the esophagus after EMR. *Gastrointest Endosc* 2005; **61**: 219-225
- 25 **Esaki M**, Matsumoto T, Hirakawa K, Nakamura S, Umeno J, Koga H, Yao T, Iida M. Risk factors for local recurrence of superficial esophageal cancer after treatment by endoscopic mucosal resection. *Endoscopy* 2007; **39**: 41-45
- 26 **Nguyen NT**, Hinojosa MW, Smith BR, Chang KJ, Gray J, Hoyt D. Minimally invasive esophagectomy: lessons learned from 104 operations. *Ann Surg* 2008; **248**: 1081-1091
- 27 **Kilic A**, Schuchert MJ, Pennathur A, Yaeger K, Prasanna V, Luketich JD, Gilbert S. Impact of obesity on perioperative outcomes of minimally invasive esophagectomy. *Ann Thorac Surg* 2009; **87**: 412-415
- 28 **Noguchi H**, Naomoto Y, Kondo H, Haisa M, Yamatsuji T, Shigemitsu K, Aoki H, Isozaki H, Tanaka N. Evaluation of endoscopic mucosal resection for superficial esophageal carcinoma. *Surg Laparosc Endosc Percutan Tech* 2000; **10**: 343-350

S- Editor Zhang HN L- Editor Hughes D E- Editor Liu N

Trimming of a migrated metal stent for malignant colonic stricture using argon plasma coagulation

Kiran Venkat Rao, Gagan Deep Beri, Weizheng William Wang

Kiran Venkat Rao, Gagan Deep Beri, Weizheng William Wang, Division of Gastroenterology, Department of Medicine, New Jersey Medical School, University of Medicine and Dentistry, Newark, NJ 07103, United States

Author contributions: Wang WW performed and supervised the procedure with Beri GD as an assisting fellow; Rao KV played a key role in manuscript preparation.

Correspondence to: Weizheng William Wang, MD, Division of Gastroenterology, Department of Medicine, New Jersey Medical School, University of Medicine and Dentistry, Newark, NJ 07103, United States. wangww@umdnj.edu

Telephone: +1-973-9724268 Fax: +1-973-9723144

Received: March 18, 2009 Revised: August 1, 2009

Accepted: August 8, 2009

Published online: February 16, 2010

© 2010 Baishideng. All rights reserved.

Key words: Argon plasma coagulation; Metal stent; Rectal pain; Colonic stricture

Peer reviewer: Rungsun Rerknimitr, MD, Associate Professor, Division of Gastroenterology, Department of Medicine, Chulalongkorn University, Rama IV Rd., Bangkok 10330, Thailand

Rao KV, Beri GD, Wang WW. Trimming of a migrated metal stent for malignant colonic stricture using argon plasma coagulation. *World J Gastrointest Endosc* 2010; 2(2): 75-76
Available from: URL: <http://www.wjgnet.com/1948-5190/full/v2/i2/75.htm> DOI: <http://dx.doi.org/10.4253/wjge.v2.i2.75>

Abstract

We report the first case of trimming of a migrated metal colonic stent for stent induced severe anorectal pain. We present a case of a 54-year-old female with history of metastatic colorectal carcinoma who had stent placement secondary to obstruction. Subsequent distal migration of the stent caused ulcerations into the rectal mucosa and excruciating anorectal pain. We used argon plasma coagulation (APC) to successfully trim the exposed distal portion of the metal stent and rat tooth forceps to retrieve the stent fragments. The use of APC for trimming metallic stents is an effective procedure that can be used to trim migrated rectal stents that result in significant rectal pain. To date, few studies have been published that use APC to trim metallic stents placed in the gastrointestinal tract. To the best of our knowledge, ours is the only known case in which the indication for stent trimming was severe stent induced rectal pain. The procedure resulted in complete relief of patient symptoms. Therefore, APC is a safe and effective way to trim colo-rectal stents to definitively relieve the symptom of stent induced rectal pain in patients who have experienced distal stent migration and mucosal ulceration.

INTRODUCTION

Malignant obstruction of the colon occurs in 7%-25% of patients with colorectal carcinoma^[1]. Over the last decade, colorectal stenting has been reported as an alternative to emergency laparotomy to relieve acute colonic obstruction^[1]. Complications of colorectal stenting include tenesmus, transient anorectal pain, rectal bleeding, colonic perforation and even stent migration^[2]. We present a case of a 54-year-old female with history of metastatic colorectal carcinoma who had stent placement secondary to obstruction. Subsequent distal migration of the stent caused erosions into the rectal mucosa and excruciating anorectal pain. We used argon plasma coagulation (APC) to successfully trim the exposed distal portion of the metal stent. We report the first case of trimming of a migrated metal colonic stent for stent induced severe anorectal pain.

CASE REPORT

A 54-year-old female initially presented with a 6 mo history of blood per rectum with alternating constipation

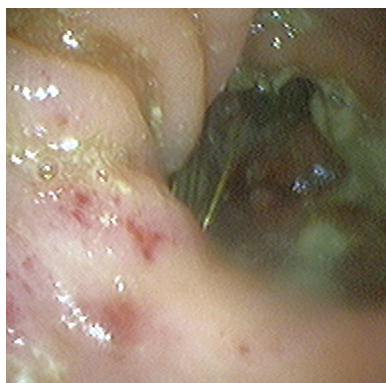

Figure 1 Rectal erosions secondary to stent irritation.

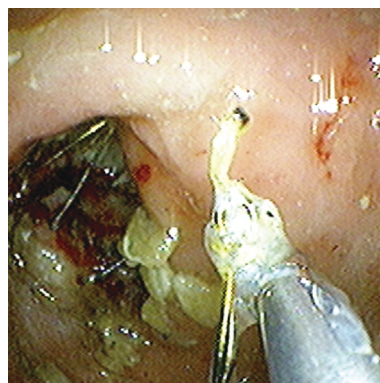


Figure 2 Removal of stent fragments with rat tooth forceps.

and diarrhea, and a 20 pound unintentional weight loss. On colonoscopy, the patient was found to have an adenocarcinoma of the transverse colon for which a hemicolectomy with diverting colostomy was performed. The patient was also noted to have a fixed adenocarcinoma of the rectum. Subsequently, chemo-radiotherapy was started but discontinued due to patient intolerance. She presented 5 mo later with persistent abdominal pain, nausea, and vomiting.

A colonoscopy was performed which revealed a tumor mass obstructing her rectum and a mesh rectal metallic stent (Z stent) was placed to palliate the obstruction. A few months later the patient presented to the GI clinic complaining of severe rectal pain. Flexible sigmoidoscopy revealed multiple areas of rectal ulceration secondary to erosion of the distal stent mesh into the rectal mucosa (Figure 1). APC was used (35 watts and 2 Liters flow rate) to successfully trim the distal 1 cm of the Z stent. The trimmings were retrieved using rat tooth forceps (Figure 2).

DISCUSSION

The use of APC for trimming metallic stents is an efficient procedure that can be used to trim migrated rectal stents that result in significant rectal pain. To date, few studies have been published that use APC to trim metallic stents placed in the gastrointestinal tract. Most cases of stent trimming with APC have been reported in metallic biliary stents that have migrated distally^[3,4]. Two cases have

been reported where a colonic stent was trimmed using APC for the treatment of tenesmus^[5]. To the best of our knowledge, ours is the only known case in which the indication for stent trimming was severe rectal pain and upon subsequent follow up a few days later, the patient was entirely pain free. Therefore, APC is a safe and effective way to trim colo-rectal stents to definitely relieve the symptom of pain in patients who have experienced distal stent migration and mucosal ulceration.

REFERENCES

- 1 **Repici A**, Pagano N, Hervoso CM, Danese S, Nicita R, Preatoni P, Malesci A. Metal stents for malignant colorectal obstruction. *Minim Invasive Ther Allied Technol* 2006; **15**: 331-338
- 2 **Pericoli Ridolfini M**, Sofo L, Di Giorgio A, Gourgiotis S, Di Miceli D, Alfieri S, Doglietto GB. [Late complication after colon self-expandable metal stent placement: a case report] *Minerva Chir* 2007; **62**: 69-72
- 3 **Vanbiervliet G**, Piche T, Caroli-Bosc FX, Dumas R, Peten EP, Huet PM, Tran A, Demarquay JF. Endoscopic argon plasma trimming of biliary and gastrointestinal metallic stents. *Endoscopy* 2005; **37**: 434-438
- 4 **Chen YK**, Jakribettuu V, Springer EW, Shah RJ, Penberthy J, Nash SR. Safety and efficacy of argon plasma coagulation trimming of malpositioned and migrated biliary metal stents: a controlled study in the porcine model. *Am J Gastroenterol* 2006; **101**: 2025-2030
- 5 **Witte TN**, Danovitch SH, Borum ML, Irani SK. Endoscopic trimming of a rectal self-expanding metallic stent by use of argon plasma coagulation. *Gastrointest Endosc* 2007; **66**: 210-211

S- Editor Zhang HN L- Editor Lalor P E- Editor Ma WH

Acknowledgments to reviewers of *World Journal of Gastrointestinal Endoscopy*

Many reviewers have contributed their expertise and time to the peer review, a critical process to ensure the quality of *World Journal of Gastrointestinal Endoscopy*. The editors and authors of the articles submitted to the journal are grateful to the following reviewers for evaluating the articles (including those published in this issue and those rejected for this issue) during the last editing time period.

Sherman M Chamberlain, Associate Professor of Medicine, Section of Gastroenterology, BBR-2538, Medical College of Georgia, Augusta, GA 30912, United States

Carlo M Girelli, MD, 1st Department of Internal Medicine, Service of Gastroenterology and Digestive Endoscopy, Hospital of Busto Arsizio, Via Arnaldo da Brescia, Busto Arsizio (VA)121052, Italy

Lesur Gilles, MD, Hopital Ambroise Paré, 9 avenue Charles de Gaulle, Boulogne 92100, France

Akira Hokama, MD, PhD, First Department of Internal Me-

dicine, University of the Ryukyus, 207 Uehara, Nishihara, Okinawa 903-0215, Japan

Seong Woo Jeon, Assistant Professor, Internal Medicine, Kyungpook National University Hospital, 50 Samduk-2Ga, Chung-gu, Daegu 700-721, South Korea

Dimitrios Kapetanios, MD, Gastroenterology Department, George Papanikolaou Hospital, Exohi, Thessaloniki 57010, Greece

Naoki Muguruma, MD, PhD, Department of Gastroenterology and Oncology, The University of Tokushima Graduate School, 3-18-15, Kuramoto-cho, Tokushima 770-8503, Japan

Eduardo Redondo-Cerezo, MD, PhD, Sección de Aparato Digestivo, Hospital General Virgen de la Luz, Avenida Hermandad de Donantes de Sangre 1, Cuenca 16002, Spain

Rungsun Rerknimitr, MD, Associate Professor, Division of Gastroenterology, Department of Medicine, Chulalongkorn University, Rama IV Rd., Bangkok 10330, Thailand

Bor-Shyang Sheu, MD, Professor, Department of Internal Medicine, Institute of Clinical Medicine, National Cheng Kung University, 138 Sheng Li Road, Tainan 70428, Taiwan, China



Meetings

Events Calendar 2010

January 25-26
Tamilnadu, India
International Conference on Medical
Negligence and Litigation in Medical
Practice

January 25-29
Waikoloa, HI, United States
Selected Topics in Internal Medicine

January 26-27
Dubai, United Arab Emirates
2nd Middle East Gastroenterology
Conference

February 11-13
Fort Lauderdale, FL, United States
21th Annual International Colorectal
Disease Symposium

February 26-28
Carolina, United States
First Symposium of GI Oncology at
The Caribbean

March 05-07
Peshawar, Pakistan
26th Pakistan Society of
Gastroenterology & Endoscopy
Meeting

March 12-14
Bhubaneswar, India
18th Annual Meeting of Indian
National Association for Study of
the Liver

March 25-28
Beijing, China
The 20th Conference of the Asian
Pacific Association for the Study of
the Liver

March 27-28
San Diego, California, United States
25th Annual New Treatments in
Chronic Liver Disease

April 07-09
Dubai, United Arab Emirates
The 6th Emirates Gastroenterology
and Hepatology Conference, EGHC
2010

April 14-17
Landover, Maryland, United States
12th World Congress of Endoscopic
Surgery

April 14-18
Vienna, Austria
The International Liver Congress™
2010

April 28-May 01
Dubrovnik, Croatia
3rd Central European Congress
of surgery and the 5th Croatian
Congress of Surgery

May 01-05
New Orleans, LA, United States
Digestive Disease Week Annual
Meeting

May 15-19
Minneapolis, MN, United States
American Society of Colon and
Rectal Surgeons Annual Meeting

June 04-06
Chicago, IL, United States
American Society of Clinical
Oncologists Annual Meeting

June 16-19
Hong Kong, China
ILTS: International Liver
Transplantation Society ILTS Annual
International Congress

June 20-23
Mannheim, Germany
16th World Congress for
Bronchoesophagology-WCBE

August 28-31
Boston, Massachusetts, United States
10th OESO World Congress on
Diseases of the Oesophagus 2010

September 10-12
Montreal, Canada
International Liver Association's
Fourth Annual Conference

September 11-12
La Jolla, CA, United States
New Advances in Inflammatory
Bowel Disease

September 16-18
Prague, Czech Republic
Prague Hepatology Meeting 2010

September 23-26
Prague, Czech Republic
The 1st World Congress on
Controversies in Gastroenterology &
Liver Diseases

October 07-09
Belgrade, Serbia
The 7th Biannual International

Symposium of Society of
Coloproctology

October 15-20
San Antonio, TX, United States
ACG 2010: American College of
Gastroenterology Annual Scientific
Meeting

October 23-27
Barcelona, Spain
18th United European
Gastroenterology Week

October 29-November 02
Boston, Massachusetts, United States
The Liver Meeting® 2010--AASLD's
61st Annual Meeting

November 13-14
San Francisco, CA, United States
Case-Based Approach to the
Management of Inflammatory Bowel
Disease



Instructions to authors

GENERAL INFORMATION

World Journal of Gastrointestinal Endoscopy (World J Gastrointest Endosc, WJGE, ISSN 1948-5190, DOI: 10.4253), is a monthly, open-access (OA), peer-reviewed online journal supported by an editorial board of 143 experts in gastrointestinal endoscopy from 28 countries.

The biggest advantage of the OA model is that it provides free, full-text articles in PDF and other formats for experts and the public without registration, which eliminates the obstacle that traditional journals possess and usually delays the speed of the propagation and communication of scientific research results.

The role of academic journals is to exhibit the scientific levels of a country, a university, a center, a department, and even a scientist, and build an important bridge for communication between scientists and the public. As we all know, the significance of the publication of scientific articles lies not only in disseminating and communicating innovative scientific achievements and academic views, as well as promoting the application of scientific achievements, but also in formally recognizing the "priority" and "copyright" of innovative achievements published, as well as evaluating research performance and academic levels. So, to realize these desired attributes of WJGE and create a well-recognized journal, the following four types of personal benefits should be maximized. The maximization of personal benefits refers to the pursuit of the maximum personal benefits in a well-considered optimal manner without violation of the laws, ethical rules and the benefits of others. (1) Maximization of the benefits of editorial board members: The primary task of editorial board members is to give a peer review of an unpublished scientific article via online office system to evaluate its innovativeness, scientific and practical values and determine whether it should be published or not. During peer review, editorial board members can also obtain cutting-edge information in that field at first hand. As leaders in their field, they have priority to be invited to write articles and publish commentary articles. We will put peer reviewers' names and affiliations along with the article they reviewed in the journal to acknowledge their contribution; (2) Maximization of the benefits of authors: Since WJGE is an open-access journal, readers around the world can immediately download and read, free of charge, high-quality, peer-reviewed articles from WJGE official website, thereby realizing the goals and significance of the communication between authors and peers as well as public reading; (3) Maximization of the benefits of readers: Readers can read or use, free of charge, high-quality peer-reviewed articles without any limits, and cite the arguments, viewpoints, concepts, theories, methods, results, conclusion or facts and data of pertinent literature so as to validate the innovativeness, scientific and practical values of their own research achievements, thus ensuring that their articles have novel arguments or viewpoints, solid evidence and correct conclusion; and (4) Maximization of the benefits of employees: It is an iron law that a first-class journal is unable to exist without first-class editors, and only first-class editors can create a first-class academic journal. We insist on

strengthening our team cultivation and construction so that every employee, in an open, fair and transparent environment, could contribute their wisdom to edit and publish high-quality articles, thereby realizing the maximization of the personal benefits of editorial board members, authors and readers, and yielding the greatest social and economic benefits.

The major task of WJGE is to report rapidly the most recent results in basic and clinical research on gastrointestinal endoscopy including: gastroscopy, intestinal endoscopy, colonoscopy, capsule endoscopy, laparoscopy, interventional diagnosis and therapy, as well as advances in technology. Emphasis is placed on the clinical practice of treating gastrointestinal diseases with or under endoscopy. Papers on advances and application of endoscopy-associated techniques, such as endoscopic ultrasonography, endoscopic retrograde cholangiopancreatography, endoscopic submucosal dissection and endoscopic balloon dilation are also welcome.

The columns in the issues of WJGE will include: (1) Editorial: To introduce and comment on the substantial advance and its importance in the fast-developing areas; (2) Frontier: To review the most representative achievements and comment on the current research status in the important fields, and propose directions for the future research; (3) Topic Highlight: This column consists of three formats, including (A) 10 invited review articles on a hot topic, (B) a commentary on common issues of this hot topic, and (C) a commentary on the 10 individual articles; (4) Observation: To update the development of old and new questions, highlight unsolved problems, and provide strategies on how to solve the questions; (5) Guidelines for Basic Research: To provide Guidelines for basic research; (6) Guidelines for Clinical Practice: To provide guidelines for clinical diagnosis and treatment; (7) Review: To systemically review the most representative progress and unsolved problems in the major scientific disciplines, comment on the current research status, and make suggestions on the future work; (8) Original Articles: To originally report the innovative and valuable findings in gastrointestinal endoscopy; (9) Brief Articles: To briefly report the novel and innovative findings in gastrointestinal endoscopy; (10) Case Report: To report a rare or typical case; (11) Letters to the Editor: To discuss and make reply to the contributions published in WJGE, or to introduce and comment on a controversial issue of general interest; (12) Book Reviews: To introduce and comment on quality monographs of gastrointestinal endoscopy; and (13) Guidelines: To introduce Consensus and Guidelines reached by international and national academic authorities worldwide on basic research and clinical practice in gastrointestinal endoscopy.

CSSN

ISSN 1948-5190 (online)

Published by

Beijing Baishideng BioMed Scientific Co., Ltd.

SUBMISSION OF MANUSCRIPTS

Manuscripts should be typed in 1.5 line spacing and 12 pt. Book

Instructions to authors

Antiqua with ample margins. Number all pages consecutively, and start each of the following sections on a new page: Title Page, Abstract, Introduction, Materials and Methods, Results, Discussion, Acknowledgements, References, Tables, Figures, and Figure Legends. Neither the editors nor the publisher are responsible for the opinions expressed by contributors. Manuscripts formally accepted for publication become the permanent property of Beijing Baishideng BioMed Scientific Co., Ltd, and may not be reproduced by any means, in whole or in part, without the written permission of both the authors and the publisher. We reserve the right to copy-edit and put onto our website accepted manuscripts. Authors should follow the relevant guidelines for the care and use of laboratory animals of their institution or national animal welfare committee. For the sake of transparency in regard to the performance and reporting of clinical trials, we endorse the policy of the International Committee of Medical Journal Editors to refuse to publish papers on clinical trial results if the trial was not recorded in a publicly-accessible registry at its outset. The only register now available, to our knowledge, is <http://www.clinicaltrials.gov> sponsored by the United States National Library of Medicine and we encourage all potential contributors to register with it. However, in the case that other registers become available you will be duly notified. A letter of recommendation from each author's organization should be provided with the contributed article to ensure the privacy and secrecy of research is protected.

Authors should retain one copy of the text, tables, photographs and illustrations because rejected manuscripts will not be returned to the author(s) and the editors will not be responsible for loss or damage to photographs and illustrations sustained during mailing.

Online submissions

Manuscripts should be submitted through the Online Submission System at: wjge@wjgnet.com. Authors are highly recommended to consult the ONLINE INSTRUCTIONS TO AUTHORS (http://www.wjgnet.com/1948-5190/g_info_14.htm) before attempting to submit online. For assistance, authors encountering problems with the Online Submission System may send an email describing the problem to <http://www.wjgnet.com/1948-5190office/>, or by telephone: +86-10-59080038. If you submit your manuscript online, do not make a postal contribution. Repeated online submission for the same manuscript is strictly prohibited.

MANUSCRIPT PREPARATION

All contributions should be written in English. All articles must be submitted using word-processing software. All submissions must be typed in 1.5 line spacing and 12 pt. Book Antiqua with ample margins. Style should conform to our house format. Required information for each of the manuscript sections is as follows:

Title page

Title: Title should be less than 12 words.

Running title: A short running title of less than 6 words should be provided.

Authorship: Authorship credit should be in accordance with the standard proposed by International Committee of Medical Journal Editors, based on (1) substantial contributions to conception and design, acquisition of data, or analysis and interpretation of data; (2) drafting the article or revising

it critically for important intellectual content; and (3) final approval of the version to be published. Authors should meet conditions 1, 2, and 3.

Institution: Author names should be given first, then the complete name of institution, city, province and postcode. For example, Xu-Chen Zhang, Li-Xin Mei, Department of Pathology, Chengde Medical College, Chengde 067000, Hebei Province, China. One author may be represented from two institutions, for example, George Sgourakis, Department of General, Visceral, and Transplantation Surgery, Essen 45122, Germany; George Sgourakis, 2nd Surgical Department, Korgialenio-Benakio Red Cross Hospital, Athens 15451, Greece

Author contributions: The format of this section should be: Author contributions: Wang CL and Liang L contributed equally to this work; Wang CL, Liang L, Fu JF, Zou CC, Hong F and Wu XM designed the research; Wang CL, Zou CC, Hong F and Wu XM performed the research; Xue JZ and Lu JR contributed new reagents/analytic tools; Wang CL, Liang L and Fu JF analyzed the data; and Wang CL, Liang L and Fu JF wrote the paper.

Supportive foundations: The complete name and number of supportive foundations should be provided, e.g., Supported by National Natural Science Foundation of China, No. 30224801

Correspondence to: Only one corresponding address should be provided. Author names should be given first, then author title, affiliation, the complete name of institution, city, postcode, province, country, and email. All the letters in the email should be in lower case. A space interval should be inserted between country name and email address. For example, Montgomery Bissell, MD, Professor of Medicine, Chief, Liver Center, Gastroenterology Division, University of California, Box 0538, San Francisco, CA 94143, United States. montgomery.bissell@ucsf.edu

Telephone and fax: Telephone and fax should consist of +, country number, district number and telephone or fax number, e.g., Telephone: +86-10-59080039 Fax: +86-10-85381893

Peer reviewers: All articles received are subject to peer review. Normally, three experts are invited for each article. Decision for acceptance is made only when at least two experts recommend an article for publication. Reviewers for accepted manuscripts are acknowledged in each manuscript, and reviewers of articles which were not accepted will be acknowledged at the end of each issue. To ensure the quality of the articles published in *WJGE*, reviewers of accepted manuscripts will be announced by publishing the name, title/position and institution of the reviewer in the footnote accompanying the printed article. For example, reviewers: Professor Jing-Yuan Fang, Shanghai Institute of Digestive Disease, Shanghai, Affiliated Renji Hospital, Medical Faculty, Shanghai Jiaotong University, Shanghai, China; Professor Xin-Wei Han, Department of Radiology, The First Affiliated Hospital, Zhengzhou University, Zhengzhou, Henan Province, China; and Professor Anren Kuang, Department of Nuclear Medicine, Huaxi Hospital, Sichuan University, Chengdu, Sichuan Province, China.

Abstract

There are unstructured abstracts (no more than 256 words) and structured abstracts (no more than 480). The specific requirements for structured abstracts are as follows:

An informative, structured abstracts of no more than 480 words should accompany each manuscript. Abstracts for original contributions should be structured into the following sections. AIM (no more than 20 words): Only the purpose should be included. Please write the aim as the form of "To investigate/study/...; MATERIALS AND METHODS (no more than 140 words); RESULTS (no more than 294 words): You should present *P* values where appropriate and must provide relevant data to illustrate how they were obtained, e.g. 6.92 ± 3.86 vs 3.61 ± 1.67 , $P < 0.001$; CONCLUSION (no more than 26 words). Available from: http://www.wjgnet.com/1948-5190/g_info_20100107134231.htm.

Key words

Please list 5-10 key words, selected mainly from *Index Medicus*, which reflect the content of the study.

Text

For articles of these sections, original articles, rapid communication and case reports, the main text should be structured into the following sections: INTRODUCTION, MATERIALS AND METHODS, RESULTS and DISCUSSION, and should include appropriate Figures and Tables. Data should be presented in the main text or in Figures and Tables, but not in both. The main text format of these sections, editorial, topic highlight, case report, letters to the editors, can be found at: http://www.wjgnet.com/1948-5190/g_info_list.htm.

Illustrations

Figures should be numbered as 1, 2, 3, *etc.*, and mentioned clearly in the main text. Provide a brief title for each figure on a separate page. Detailed legends should not be provided under the figures. This part should be added into the text where the figures are applicable. Figures should be either Photoshop or Illustrator files (in tiff, eps, jpeg formats) at high-resolution. Examples can be found at: <http://www.wjgnet.com/1007-9327/13/4520.pdf>; <http://www.wjgnet.com/1007-9327/13/4554.pdf>; <http://www.wjgnet.com/1007-9327/13/4891.pdf>; <http://www.wjgnet.com/1007-9327/13/4986.pdf>; <http://www.wjgnet.com/1007-9327/13/4498.pdf>. Keeping all elements compiled is necessary in line-art image. Scale bars should be used rather than magnification factors, with the length of the bar defined in the legend rather than on the bar itself. File names should identify the figure and panel. Avoid layering type directly over shaded or textured areas. Please use uniform legends for the same subjects. For example: Figure 1 Pathological changes in atrophic gastritis after treatment. A: ...; B: ...; C: ...; D: ...; E: ...; F: ...; G: ...*etc.* It is our principle to publish high resolution-figures for the printed and E-versions.

Tables

Three-line tables should be numbered 1, 2, 3, *etc.*, and mentioned clearly in the main text. Provide a brief title for each table. Detailed legends should not be included under tables, but rather added into the text where applicable. The information should complement, but not duplicate the text. Use one horizontal line under the title, a second under column heads, and a third below the Table, above any footnotes. Vertical and italic lines should be omitted.

Notes in tables and illustrations

Data that are not statistically significant should not be noted. ^a $P < 0.05$, ^b $P < 0.01$ should be noted ($P > 0.05$ should not be noted). If there are other series of *P* values, ^c $P < 0.05$ and ^d $P < 0.01$ are used. A third series of *P* values can be expressed as ^e P

< 0.05 and ^f $P < 0.01$. Other notes in tables or under illustrations should be expressed as ¹F, ²F, ³F; or sometimes as other symbols with a superscript (Arabic numerals) in the upper left corner. In a multi-curve illustration, each curve should be labeled with ●, ○, ■, □, ▲, △, *etc.*, in a certain sequence.

Acknowledgments

Brief acknowledgments of persons who have made genuine contributions to the manuscript and who endorse the data and conclusions should be included. Authors are responsible for obtaining written permission to use any copyrighted text and/or illustrations.

REFERENCES

Coding system

The author should number the references in Arabic numerals according to the citation order in the text. Put reference numbers in square brackets in superscript at the end of citation content or after the cited author's name. For citation content which is part of the narration, the coding number and square brackets should be typeset normally. For example, "Crohn's disease (CD) is associated with increased intestinal permeability^[1,2]". If references are cited directly in the text, they should be put together within the text, for example, "From references^[19,22-24], we know that..."

When the authors write the references, please ensure that the order in text is the same as in the references section, and also ensure the spelling accuracy of the first author's name. Do not list the same citation twice.

PMID and DOI

Please provide PubMed citation numbers to the reference list, e.g. PMID and DOI, which can be found at <http://www.ncbi.nlm.nih.gov/sites/entrez?db=pubmed> and <http://www.crossref.org/SimpleTextQuery/>, respectively. The numbers will be used in E-version of this journal.

Style for journal references

Authors: the name of the first author should be typed in bold-faced letters. The family name of all authors should be typed with the initial letter capitalized, followed by their abbreviated first and middle initials. (For example, Lian-Sheng Ma is abbreviated as Ma LS, Bo-Rong Pan as Pan BR). The title of the cited article and italicized journal title (journal title should be in its abbreviated form as shown in PubMed), publication date, volume number (in black), start page, and end page [PMID: 11819634 DOI: 10.3748/wjg.13.5396].

Style for book references

Authors: the name of the first author should be typed in bold-faced letters. The surname of all authors should be typed with the initial letter capitalized, followed by their abbreviated middle and first initials. (For example, Lian-Sheng Ma is abbreviated as Ma LS, Bo-Rong Pan as Pan BR) Book title. Publication number. Publication place: Publication press, Year: start page and end page.

Format

Journals

English journal article (list all authors and include the PMID where applicable)

- 1 Jung EM, Clevert DA, Schreyer AG, Schmitt S, Rennert J, Kubale R, Feuerbach S, Jung F. Evaluation of quantitative contrast harmonic imaging to assess malignancy of liver

Instructions to authors

tumors: A prospective controlled two-center study. *World J Gastroenterol* 2007; **13**: 6356-6364 [PMID: 18081224 DOI: 10.3748/wjg.13.6356]

Chinese journal article (list all authors and include the PMID where applicable)

- 2 **Lin GZ**, Wang XZ, Wang P, Lin J, Yang FD. Immunologic effect of Jianpi Yishen decoction in treatment of Pixu-diarrhoea. *Shijie Huaren Xiaobua Zazhi* 1999; **7**: 285-287

In press

- 3 **Tian D**, Araki H, Stahl E, Bergelson J, Kreitman M. Signature of balancing selection in Arabidopsis. *Proc Natl Acad Sci USA* 2006; In press

Organization as author

- 4 **Diabetes Prevention Program Research Group**. Hypertension, insulin, and proinsulin in participants with impaired glucose tolerance. *Hypertension* 2002; **40**: 679-686 [PMID: 12411462 PMCID:2516377 DOI:10.1161/01.HYP.0000035706.28494.09]

Both personal authors and an organization as author

- 5 **Vallancien G**, Emberton M, Harving N, van Moorselaar RJ; Alf-One Study Group. Sexual dysfunction in 1, 274 European men suffering from lower urinary tract symptoms. *J Urol* 2003; **169**: 2257-2261 [PMID: 12771764 DOI:10.1097/01.ju.0000067940.76090.73]

No author given

- 6 21st century heart solution may have a sting in the tail. *BMJ* 2002; **325**: 184 [PMID: 12142303 DOI:10.1136/bmj.325.7357.184]

Volume with supplement

- 7 **Geraud G**, Spierings EL, Keywood C. Tolerability and safety of frovatriptan with short- and long-term use for treatment of migraine and in comparison with sumatriptan. *Headache* 2002; **42** Suppl 2: S93-99 [PMID: 12028325 DOI:10.1046/j.1526-4610.42.s2.7.x]

Issue with no volume

- 8 **Banit DM**, Kaufer H, Hartford JM. Intraoperative frozen section analysis in revision total joint arthroplasty. *Clin Orthop Relat Res* 2002; **(401)**: 230-238 [PMID: 12151900 DOI:10.1097/00003086-200208000-00026]

No volume or issue

- 9 Outreach: Bringing HIV-positive individuals into care. *HRSA Careaction* 2002; 1-6 [PMID: 12154804]

Books

Personal author(s)

- 10 **Sherlock S**, Dooley J. Diseases of the liver and biliary system. 9th ed. Oxford: Blackwell Sci Pub, 1993: 258-296

Chapter in a book (list all authors)

- 11 **Lam SK**. Academic investigator's perspectives of medical treatment for peptic ulcer. In: Swabb EA, Azabo S. Ulcer disease: investigation and basis for therapy. New York: Marcel Dekker, 1991: 431-450

Author(s) and editor(s)

- 12 **Breedlove GK**, Schorheide AM. Adolescent pregnancy. 2nd ed. Wiecezorek RR, editor. White Plains (NY): March of Dimes Education Services, 2001: 20-34

Conference proceedings

- 13 **Harnden P**, Joffe JK, Jones WG, editors. Germ cell tumours V. Proceedings of the 5th Germ cell tumours Conference; 2001 Sep 13-15; Leeds, UK. New York: Springer, 2002: 30-56

Conference paper

- 14 **Christensen S**, Oppacher F. An analysis of Koza's computational effort statistic for genetic programming. In: Foster JA, Lutton E, Miller J, Ryan C, Tettamanzi AG,

editors. Genetic programming. EuroGP 2002: Proceedings of the 5th European Conference on Genetic Programming; 2002 Apr 3-5; Kinsdale, Ireland. Berlin: Springer, 2002: 182-191

Electronic journal (list all authors)

- 15 Morse SS. Factors in the emergence of infectious diseases. *Emerg Infect Dis* serial online, 1995-01-03, cited 1996-06-05; 1(1): 24 screens. Available from: URL: <http://www.cdc.gov/ncidod/EID/eid.htm>

Patent (list all authors)

- 16 **Pagedas AC**, inventor; Ancel Surgical R&D Inc., assignee. Flexible endoscopic grasping and cutting device and positioning tool assembly. United States patent US 20020103498. 2002 Aug 1

Statistical data

Write as mean \pm SD or mean \pm SE.

Statistical expression

Express *t* test as *t* (in italics), *F* test as *F* (in italics), chi square test as χ^2 (in Greek), related coefficient as *r* (in italics), degree of freedom as *v* (in Greek), sample number as *n* (in italics), and probability as *P* (in italics).

Units

Use SI units. For example: body mass, *m* (B) = 78 kg; blood pressure, *p* (B) = 16.2/12.3 kPa; incubation time, *t* (incubation) = 96 h, blood glucose concentration, *c* (glucose) 6.4 \pm 2.1 mmol/L; blood CEA mass concentration, *p* (CEA) = 8.6 24.5 μ g/L; CO₂ volume fraction, 50 mL/L CO₂, not 5% CO₂; likewise for 40 g/L formaldehyde, not 10% formalin; and mass fraction, 8 ng/g, etc. Arabic numerals such as 23, 243, 641 should be read 23 243 641.

The format for how to accurately write common units and quantums can be found at: <http://www.wjgnet.com/wjg/help/15.doc>.

Abbreviations

Standard abbreviations should be defined in the abstract and on first mention in the text. In general, terms should not be abbreviated unless they are used repeatedly and the abbreviation is helpful to the reader. Permissible abbreviations are listed in Units, Symbols and Abbreviations: A Guide for Biological and Medical Editors and Authors (Ed. Baron DN, 1988) published by The Royal Society of Medicine, London. Certain commonly used abbreviations, such as DNA, RNA, HIV, LD50, PCR, HBV, ECG, WBC, RBC, CT, ESR, CSF, IgG, ELISA, PBS, ATP, EDTA, mAb, can be used directly without further explanation.

Italics

Quantities: *t* time or temperature, *c* concentration, *A* area, *l* length, *m* mass, *V* volume.

Genotypes: *gyrA*, *arg 1*, *c myc*, *c fos*, etc.

Restriction enzymes: *EcoRI*, *HindI*, *BamHI*, *Kho I*, *Kpn I*, etc.

Biology: *H. pylori*, *E. coli*, etc.

SUBMISSION OF THE REVISED MANUSCRIPTS AFTER ACCEPTED

Please revise your article according to the revision policies of *WJGE*. The revised version including manuscript and high-resolution image figures (if any) should be copied on a floppy or compact disk. The author should send the revised manuscript, along with printed high-resolution color or black

and white photos, copyright transfer letter, and responses to the reviewers by courier (such as EMS/DHL).

Editorial Office

World Journal of Gastrointestinal Endoscopy

Editorial Department: Room 903, Building D,
Ocean International Center,
No. 62 Dongsihuan Zhonglu,
Chaoyang District, Beijing 100025, China
E-mail: wjge@wjgnet.com
<http://www.wjgnet.com>
Telephone: +86-10-59080038
Fax: +86-10-85381893

Language evaluation

The language of a manuscript will be graded before it is sent for revision. (1) Grade A: priority publishing; (2) Grade B: minor language polishing; (3) Grade C: a great deal of language polishing needed; and (4) Grade D: rejected. Revised articles should reach Grade A or B.

Copyright assignment form

Please download a Copyright assignment form from http://www.wjgnet.com/1948-5190/g_info_20100107134847.htm.

Responses to reviewers

Please revise your article according to the comments/suggestions provided by the reviewers. The format for responses to the reviewers' comments can be found at: http://www.wjgnet.com/1948-5190/g_info_20100107134601.htm.

Proof of financial support

For paper supported by a foundation, authors should provide a copy of the document and serial number of the foundation.

Links to documents related to the manuscript

WJGE will be initiating a platform to promote dynamic interactions between the editors, peer reviewers, readers and authors. After a manuscript is published online, links to the PDF version of the submitted manuscript, the peer-reviewers' report and the revised manuscript will be put on-line. Readers can make comments on the peer reviewer's report, authors' responses to peer reviewers, and the revised manuscript. We hope that authors will benefit from this feedback and be able to revise the manuscript accordingly in a timely manner.

Science news releases

Authors of accepted manuscripts are suggested to write a science news item to promote their articles. The news will be released rapidly at EurekAlert/AAAS (<http://www.eurekalert.org>). The title for news items should be less than 90 characters; the summary should be less than 75 words; and main body less than 500 words. Science news items should be lawful, ethical, and strictly based on your original content with an attractive title and interesting pictures.

Publication fee

Authors of accepted articles must pay a publication fee. EDITORIAL, TOPIC HIGHLIGHTS, BOOK REVIEWS and LETTERS TO THE EDITOR are published free of charge.