ISSN 1948-5190 (online)

World Journal of *Gastrointestinal Endoscopy*

World J Gastrointest Endosc 2020 January 16; 12(1): 1-52

Published by Baishideng Publishing Group Inc

WJGE

World Journal of Gastrointestinal Endoscopy

Contents

Monthly Volume 12 Number 1 January 16, 2020

World Journal of Gastrointestinal Endoscopy
Volume 12 Number 1 January 16, 2020

Contents

ABOUT COVER

Editorial Board Member of *World Journal of Gastrointestinal Endoscopy*, Dimitrios Kapetanos, FEBG, PhD, Doctor, Department of Gastroenterology, George Papanikolaou Hospital, Thessaloniki 55236, Greece.

AIMS AND SCOPE

The primary aim of *World Journal of Gastrointestinal Endoscopy* (*WJGE*, *World J Gastrointest Endosc*) is to provide scholars and readers from various fields of gastrointestinal endoscopy with a platform to publish high-quality basic and clinical research articles and communicate their research findings online.

WJGE mainly publishes articles reporting research results and findings obtained in the field of gastrointestinal endoscopy and covering a wide range of topics including capsule endoscopy, colonoscopy, double-balloon enteroscopy, duodenoscopy, endoscopic retrograde cholangiopancreatography, endosonography, esophagoscopy, gastrointestinal endoscopy, gastroscopy, laparoscopy, natural orifice endoscopic surgery, proctoscopy, and sigmoidoscopy.

INDEXING/ABSTRACTING

The *WJGE* is now abstracted and indexed in Emerging Sources Citation Index (Web of Science), PubMed, PubMed Central, China National Knowledge Infrastructure (CNKI), and Superstar Journals Database.

RESPONSIBLE EDITORS FOR THIS ISSUE

Responsible Electronic Editor: *Yu-Jie Ma*

Proofing Production Department Director: *Xiang Li*

NAME OF JOURNAL
World Journal of Gastrointestinal Endoscopy

ISSN
ISSN 1948-5190 (online)

LAUNCH DATE
October 15, 2009

FREQUENCY
Monthly

EDITORIAL OFFICE
Ruo-Yu Ma, Director

PUBLICATION DATE
January 16, 2020

INSTRUCTIONS TO AUTHORS
https://www.wjgnet.com/bpg/gerinfo/204

GUIDELINES FOR ETHICS DOCUMENTS
https://www.wjgnet.com/bpg/GerInfo/287

GUIDELINES FOR NON-NATIVE SPEAKERS OF ENGLISH
https://www.wjgnet.com/bpg/gerinfo/240

PUBLICATION MISCONDUCT
https://www.wjgnet.com/bpg/gerinfo/208

ARTICLE PROCESSING CHARGE
https://www.wjgnet.com/bpg/gerinfo/242

STEPS FOR SUBMITTING MANUSCRIPTS
https://www.wjgnet.com/bpg/GerInfo/239

ONLINE SUBMISSION
https://www.f6publishing.com

World Journal of Gastrointestinal Endoscopy

Submit a Manuscript: https://www.f6publishing.com

World J Gastrointest Endosc 2020 January 16; 12(1): 1-16

DOI: 10.4253/wjge.v12.i1.1

ISSN 1948-5190 (online)

MINIREVIEWS

Endoscopic advances in the management of non-variceal upper gastrointestinal bleeding: A review

Maliha Naseer, Karissa Lambert, Ahmed Hamed, Eslam Ali

ORCID number: Maliha Naseer (0000-0001-6891-1378); Karissa Lambert (0000-0002-0663-2549); Ahmed Hamed (0000-0001-7448-5715); Eslam Ali (0000-0002-3379-8683).

Author contributions: All authors equally contributed to this paper with conception and design of the study, literature review and analysis, drafting and critical revision and editing, and final approval of the final version.

Conflict-of-interest statement: No potential conflicts of interest. No financial support.

Manuscript source: Invited manuscript

Received: March 30, 2019
Peer-review started: April 4, 2019
First decision: August 2, 2019
Revised: August 28, 2019
Accepted: October 19, 2019
Article in press: October 19, 2019

Maliha Naseer, Eslam Ali, Division of Gastroenterology and Hepatology, Department of Internal Medicine, East Carolina University, Greenville, NC 27834, United States

Karissa Lambert, Ahmed Hamed, Department of Internal Medicine, East Carolina University, Greenville, NC 27834, United States

Corresponding author: Maliha Naseer, MD, Gastroenterology Fellow, Division of Gastroenterology and Hepatology, Department of Internal Medicine, East Carolina University, 521 Moye Blvd, Greenville, NC 27834, United States. naseerm18@ecu.edu

Abstract

Upper gastrointestinal bleeding is defined as the bleeding originating from the esophagus to the ligament of Treitz and further classified into variceal and non-variceal gastrointestinal bleeding. Non-variceal upper gastrointestinal bleeding remains a common clinical problem globally. It is associated with high mortality, morbidity, and cost of the health care system. Despite the continuous improvement of therapeutic endoscopy, the 30-d readmission rate secondary to rebleeding and associated mortality is an ongoing issue. Available Food and Drug Administration approved traditional or conventional therapeutic endoscopic modalities includes epinephrine injection, argon plasma coagulation, heater probe, and placement of through the scope clip, which can be used alone or in combination to decrease the risk of rebleeding. Recently, more attention has been paid to the novel advanced endoscopic devices for primary treatment of the bleeding lesion and as a secondary measure when conventional therapies fail to achieve hemostasis. This review highlights emerging endoscopic modalities used in the management of non-variceal upper gastrointestinal related bleeding such as over-the-scope clip, Coagrasper, hemostatic sprays, radiofrequency ablation, cryotherapy, endoscopic suturing devices, and endoscopic ultrasound-guided angiotherapy. In this review article, we will also discuss the technical aspects of the common procedures, outcomes in terms of safety and efficacy, and their advantages and limitations in the setting of non-variceal upper gastrointestinal bleeding.

Key words: Non-variceal upper gastrointestinal bleeding; Over the scope clip; Hemospray; Radiofrequency ablation; Endoscopic suturing device

Published online: January 16, 2020

P-Reviewer: Madalinski M, Quach DT
S-Editor: Yan JP
L-Editor: A
E-Editor: Ma YJ

Core tip: In the last two decades, there has been drastic decline in the mortality and morbidity caused non-variceal upper gastrointestinal bleeding due to significant progress in the therapeutic endoscopy. The use of devices such as over the scope clips system, Coagrasper, hemospray and endoscopic suturing has tremendously evolved and expanded to achieve hemostasis as a primary method or when conventional therapeutic devices such as heater probe, hemoclips or epinephrine injection fails to control bleeding.

Citation: Naseer M, Lambert K, Hamed A, Ali E. Endoscopic advances in the management of non-variceal upper gastrointestinal bleeding: A review. *World J Gastrointest Endosc* 2020; 12(1): 1-16
URL: https://www.wjgnet.com/1948-5190/full/v12/i1/1.htm
DOI: https://dx.doi.org/10.4253/wjge.v12.i1.1

INTRODUCTION

Gastrointestinal bleeding is a medical emergency that results in substantial morbidity, mortality, and health care cost[1,2]. It can present as a massive life-threatening hemorrhage, or a slow chronic bleed. Upper gastrointestinal bleeding (UGIB) is defined as any gastrointestinal bleeding that originates above the ligament of Treitz[3,4]. UGIB can be further classified as non-variceal UGIB (NVUGIB) and variceal UGIB (VUGIB). The common causes of NVUGIB are listed in Table 1. The incidence and mortality associated with NVUGIB have been decreasing due to the advancements in the prevention and management of NVUGIB[5-7]. Yet, it remains a common clinical problem with an annual incidence of about 90-108 per 100000 and mortality of 3% to 14%[8,9].

The initial approach to the patient presenting with acute NVUGIB is highlighted in Figure 1. Early endoscopic intervention within 24 h of presentation dramatically improves patient outcomes, and there was no difference observed compared to those who underwent endoscopic intervention < 12 h after presentation[10,11]. When an endoscopic approach is performed, it is crucial to have a standardized method of diagnosing the cause of bleeding, evaluating the stigmata of recent hemorrhage (*i.e.*, active bleeding, a visible blood vessel, presence of clots, or red or black spots covering the ulcer lesion), and classifying gastric ulcers according to the Forrest classification[12,13]. Endoscopy is important in revealing the etiology of NVUGIB.

The development and widespread use of endoscopy has been a major contributor to the reduced need for surgery and morbidity associated with NVUGIB[14]. Endoscopic management is classified as injection, thermal, and mechanical methods. Amongst the traditional methods, injection of epinephrine is the most common and widely used modality because of its feasibility to perform and requires less coordination between endoscopist and assistant. However, epinephrine alone is less effective than combination with thermal or mechanical and other monotherapies such as clips, probes and electrocoagulation[15,16]. According to the Cochrane review, combination treatment has been associated with significant reduced risk of rebleeding, surgery and mortality in peptic ulcers with active bleeding or high-risk stigmata such as adherent clot[17]. Through the scope endoclips or hemoclips are found to be effective and safe hemostatic mechanical devices when applied precisely as mono or combine therapy. Clip grasp the vessel in the submucosa, seal the defect in the target blood vessel with or without approximation of the sides of the lesion. Furthermore, the tissue damage is minimal with clips and ulcer healing process is not hampered[18,19]. Introduced in clinical practice in 1990s, over the years, clips are evolved in terms of functionality (such as precision, tensile strength, rotatability, overshoot and strength of closure), physical characteristics and cost[20,21]. Recently published study by Wang *et al*[22] compared the functionality of the five different types of hemostatic clips. According to the study findings, Resolution 360 (Boston Scientific, Marlborough, Mass) was the fastest rotating clip when operated by the physicians. Instinct (Cook Medical, Bloomington, Ind) was found more mechanically stronger and performed better for compression of thick, fibrous tissue and crated ulcers. Overshoot and whipping (defined as > 30° and > 1 half revolution respectively) tends to happen when clips are rotated multiply in same direction. For both overshoot and whip, the SureClip 16 mm performed well when compared with other types of through the scope clips[22].

Table 1 Etiologies of non-variceal upper gastrointestinal bleeding

Etiologies of non-variceal upper gastrointestinal bleeding	
Ulcer/ inflammation	Peptic ulcer disease
	Erosive esophagitis, gastritis or duodenitis
	Anastomotic ulcers (post gastric bypass)
Vascular lesions	Gastric antral vascular ectasia
	Dieulafoy's lesion
	Angiodysplasia/ Arteriovenous malformation
	Aorto-enteric fistula
Congestive gastropathy	Portal hypertensive gastropathy
Malignant lesions	Gastrointestinal stromal tumors (GIST)
	Non-GIST (*e.g.*, Lipoma, schwannoma)
	Gastric and esophageal cancer
	Metastatic lesions in the upper GI tract
Post procedural	Endoscopic mucosal and submucosal dissection
	Post sphincterotomy
Others	Mallory Weis tear
	Cameron ulcers

GI: Gastrointestinal; GIST: Gastrointestinal stromal tumors.

Despite the continued improvements, traditional therapies sometimes lack effectiveness at primary control or prevention of rebleeding, which are reported to be as high as 10%-24%[23-25]. Posterior duodenal wall ulcers or ulcers higher up the lesser curvature, actively bleeding lesions during endoscopy, ulcers larger than 2 cm in diameter, or with bleeding vessel > 2 mm are some of the major predictors of rebleeding[26]. For the past decade, there is much interest in developing and studying endoscopic methods to effectively achieve hemostasis and overcome the limitation of the traditional endoscopic methods. Tables 2 and 3 summarize emerging endoscopic modalities for the management of NVUGIB and their pros and cons. In this article, we will review the advanced endoscopic modalities currently available for the management of NVUGIB.

EMERGING MECHANICAL TREATMENT OPTIONS FOR NVUGIB

Over the scope clips

It has been proved that mechanical hemostatic methods are more effective in achieving hemostasis than injections or thermal modalities alone. The Over-The-Scope Clip (OTSC, Ovesco Endoscopy GmbH, TÜbingen, Germany) is a Food and Drug Administration approved novel endoscopic clipping device[27]. The use of OTSC system was first reported in 2007 by Kirschniak *et al*[28] for gastrointestinal tissue approximation. Since then, the device has been widely used to control gastrointestinal bleeding, particularly caused by large and fibrotic ulcers at anatomic locations that are difficult to treat with through-the-scope (TTS) clips or at risk of perforation[29]. Other uses include the closure of perforation and fistula[30].

The OTSC® System Set consists of an applicator cap with a mounted over the scope clip, thread, thread retriever, and a hand wheel for clip release. The clip is made up of a super elastic nitinol alloy, which is delivered by means of an applicator cap and released by tightening the thread with the hand wheel. OTSC caps are available in 3 diameters (11, 12, and 14 mm) and 2 working depths (3 and 6 mm). There are three versions of OTSC versions available currently (atraumatic, traumatic and more gastric wall closure clip)[31]. Due to its unique design and elastic properties, the nitinol clip closes itself and secures the therapeutic effect by exerting constant circumferential compression force enough to stop bleeding from large size tissue defects and blood vessels[32].

Over the scope clip system has been established to be safe and effective as a first line and in the rescue management of non-variceal gastrointestinal bleeding. The first case series comprises a total of 9 patients (7 patients with GI bleeding) and was first

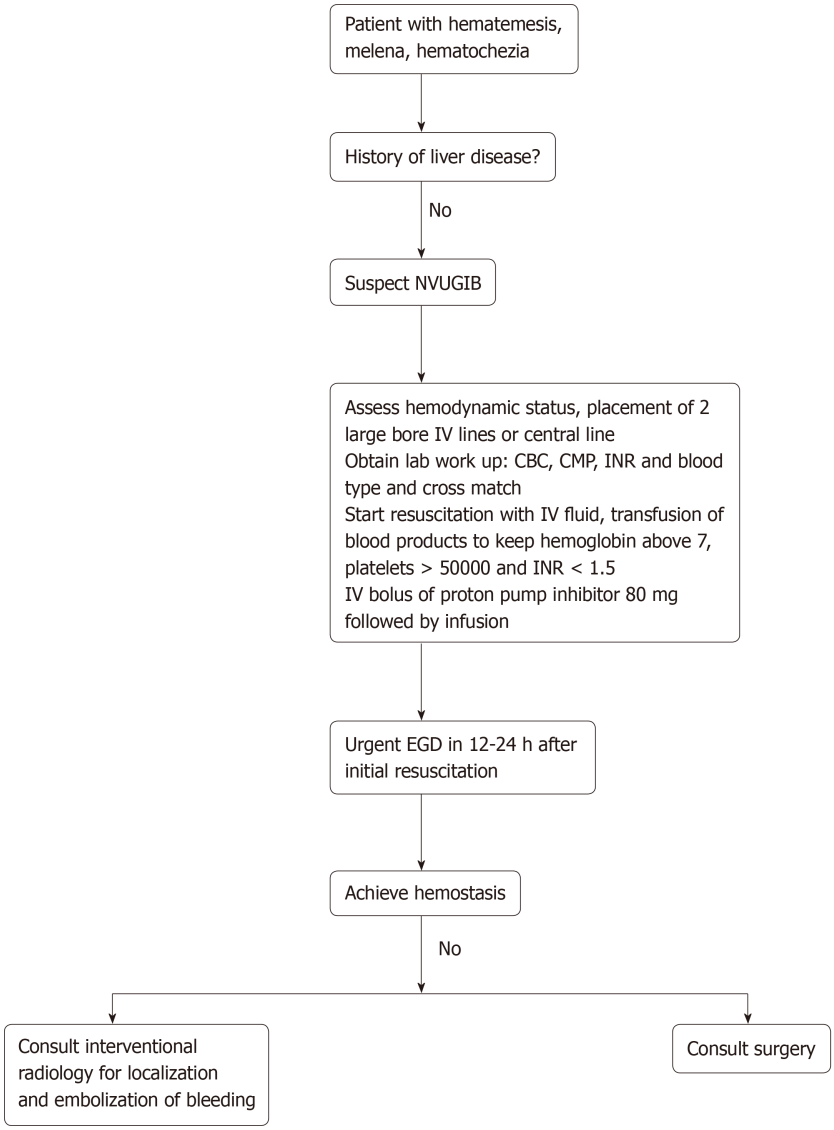

Figure 1 Initial evaluation and management of patient presented with suspected upper gastrointestinal bleeding. EGD: Esophagogastroduodenoscopy; CBC: Complete blood count; CMP: Comprehensive metabolic panel; INR: International normalized ratio; NVUGIB: Non-variceal upper gastrointestinal bleeding.

published in 2009 by Repici *et al*[33] from Italy. It was followed by several other retrospective analyses of single and multi-center experience with OTSC to achieve hemostasis (Table 4)[33-43]. Four retrospective studies with large sample sizes (n = 67-93) were published between 2016-2018. The primary outcomes of these studies were the technical success to control bleeding and rebleeding rates. Most of the studies reported success rates between 78% to 100% with the rebleeding risk of < 1%. However, rebleeding was seen approximately 26% patients in a retrospective analysis conducted by Brandler *et al*[43]. In this study, the authors attributed high rebleeding rates and failure of OTSC to the history of coronary artery disease. Lamberts *et al*[42] reported rebleeding rates of 26%. Their data suggest that first line endoscopic treatment of the ulcer with OTSC has higher success and low rebleeding rates as compared to its use as second-line treatment. Also, they found OTSC as the less preferable treatment for diffusely bleeding polypoid lesions and vascular malformations.

Only one prospective randomized control multicenter trial compared OTSC with standard treatment (TTS clips or thermal therapy plus injection with diluted adrenaline) of severe recurrent UGIB was published by Schmidt *et al*[44]. According to the study, results demonstrated significant differences noted in the persistent bleeding rates between treatment (6.0%) and control group (42.4%) and rebleeding at 30 d. However, the rebleeding rates at day 7 were not significantly different between groups. A recently published study analyzed 1517 cases treated with OTSC in 30 published studies over a 9-year period. The overall success rate of OTSC to control

Table 2 Summary of emerging endoscopic modalities for the management of non-variceal upper gastrointestinal bleeding

Emerging endoscopic modalities	
Injection	Endoscopic ultrasound guided angiotherapy
Thermal therapies	Coagulation grasper, radiofrequency ablation, cryotherapy
Mechanical	Over the scope clip system, endoscopic suturing, flexible linear stapler (experimental)
Topical	Hemospray, endoclot, pure-Stat, ankaferd blood stopper, oxidized cellulose

hemorrhage was found to be 85% with the complication risk of about 1.7%. Procedural accidents for e.g. deviation of the over the scope clip system itself or deviation of the clip from fibrotic tissue, intraluminal stenosis, and perforation of the thin duodenal wall with the bear claw were a few of the reported complication in these studies[45].

One of the major advantages of the OTSC system is it's simple to use and does not require special endoscopic skills to implant the clip[46]. However, it is difficult to close hard, chronic, and severely fibrotic lesions with OTSC. Another limitation is the application of the clip in the emergency situations because after identifying the bleeding source, the scope must be removed to mount OTSC system on the scope (just like variceal band ligator) and reintroduced to deploy clips[47].

Endoscopic suturing

An endoscopic suturing device to perform minimally invasive endoscopic interventions was first proposed by Kalloo *et al*[48] more than a decade ago. Since its development, the endoscopic suturing device (Overstitch TM, Apollo Endosurgery, Austin, TX, United States) has continuously evolved and been established to be successfully used in a variety of endoscopic procedures including gastrointestinal fistula closure, perforations, leaks, endoscopic revision of gastro-jejunal bypass after bariatric surgery, and endoscopic submucosal dissection (ESD)[49-51].

The endoscopic suturing device is introduced into the stomach through an over tube. The Overstitch system attaches proximally and distally to the double-channel endoscope, which is comprised of a cap-based suturing curved arm (to operate the tissue helix for atraumatic tissue manipulation), anchor exchange catheter (pass suture), and handle (to be mounted on the shaft of the endoscope to control suturing process). The suturing process begins at one of the edges of the ulcer using a curved needle. The curved needle then closes and grabbed by the anchor exchange and detached from the driver. The endoscope, with Overstitch, then moves proximally towards the other edge of the ulcer. This process repeats until the two edges of the ulcer are pulled together. Once the edges of the ulcer approximate each other, the 2 'O' polypropylene suture, placed by the cinching device, is tightened and secured[52].

Endoscopic suturing is found to be a promising modality in the management of NVUGIB in several case reports and case series due to its excellent ability to close large mucosal defects after conventional methods fail to achieve hemostasis. Recently, Agarwal *et al*[53], published a case series of 10 patients and demonstrated the endoscopic suturing device was used successfully to control bleeding related to large recurrent peptic ulcers. Mean suturing time was reported to be 13.4 ± 5.6 (range 3.5-20) min. No early or delayed procedural related complications were reported[53].

The endoscopic suturing device has several advantages over OTSC and hemospray (HS). Although these devices have high success rates in controlling NVUGIB, the endoscopic suturing device is technically more feasible and efficacious for larger, deep, and fibrotic ulcers. However, bleeding from small, shallow, and non-fibrotic ulcers can be more efficiently controlled with OTSC placement[54]. HS, on the other hand, can be utilized as the temporizing measure to control bleeding, as published data suggested that its rebleeding rate is up to 29% to 38%[55]. Limitations of the endoscopic suturing device include the need for a double channel endoscope and expert endoscopic skills. The use of endoscopic suturing should be avoided if there is a suspicion of malignant ulcer[56].

Endoscopic band ligation

Endoscopic band ligation (EBL) was initially developed for esophageal and hemorrhoidal ligation; however, it can be also used in the management of upper gastrointestinal vascular lesions, such as nodular gastric antral vascular ectasia (GAVE)[57]. Studies have demonstrated that EBL may be superior to argon plasma coagulation and endoscopic thermal therapy regarding the reduction of treatment sessions, control of bleeding and need for transfusion, proving to be a promising

Table 3 Summary of the pros and cons of new emerging endoscopic treatment modalities for non-variceal gastrointestinal bleeding

Emerging endoscopic treatment	Pros	Cons
Over the scope clips	1 Simple to use	1 Difficult to close hard, chronic, and severely fibrotic lesions with OTSC
	2 Special endoscopic skills are not required to implant the clip	2 Time consuming especially in the emergency situations (after identifying the bleeding source, the scope must be removed to mount OTSC system on the scope and reintroduce to deploy clips
	3 Effective for the ulcers larger than 2 cm in diameter, or with bleeding vessel > 2 mm	
Endoscopic suturing	1 Technically more feasible and efficacious for larger, deep, and fibrotic ulcers	1 Double channel endoscope and expert endoscopic skills are required to operate endoscopic suturing device
Endoscopic band ligation (EVL)	1 Associated with the reduction of treatment sessions, control of bleeding and need for transfusion	Few cases of Hyperplastic gastric polyps
	2 EVL is safe, technically straightforward, and highly effective in this patient with complete eradication of GAVE	
Coagrasper	1 One of the safest and most efficacious hemostasis modalities due to large surface area of the forceps and anti-slip jaw design provides mechanical tamponade effect to the surrounding tissue	1 Coagulation may be incomplete because of electrical leakage if the lesion submerged in water or lesion with large tissue volume or surface area
	2 The risk of perforation is extremely low because coagrasper works at a lower voltage as compared to other thermal treatments coagulates tissues without any carbonization and does not extend to deeper tissue	2 Because the devices used for soft coagulation, including disposable hemostatic forceps, are relatively expensive, the method may be appropriate only for centers that perform ESD frequently
	3 The forceps can be used to treat multiple bleeding sites proving to be cost-effective	3 Few cases of aspiration pneumonia reported
Radiofrequency ablation	1 Feasible and safe in ablating GAVE lesions	1 Endoscopic skills are required to perform RFA
	2 Able to deliver high energy captive coagulation of superficial mucosa including blood vessels	2 Exact apposition of the gastric antral mucosa with electrode is required to allow effective delivery of the electric energy which means the endoscope may have to be removed, the electrode rotated, and reintroduced multiple times The newer through-the-scope internally rotatable ablating catheter may sidestep this disadvantage but has smaller surface area
	3 Wider surface area coverage of mucosa owing to the various electrode sizes	
	4 Contact technique with uniform zone of energy distribution and penetration such that deeper ectatic submucosal vascular channels are coagulated	
Endoscopic ultrasound guided angiotherapy	1 EUS-guided therapy of nonvariceal bleeding has been shown to be feasible and safe for peptic ulcer disease, Dieulafoy's lesions, bleeding tumors, and pseudoaneurysms due to the ability to directly visualize and target the bleeding vessel with a specific therapy and subsequently confirm hemostasis with real-time Doppler ultrasound are significant advantages of EUS-guided therapy	1 Endoscopic skills are required to perform endoscopic ultrasound
		2 EUS guided angiotherapy more resource intensive than other routine hemostasis endoscopic procedures
Topical therapies, *i.e.*, Hemospray and Endoclot	Easy to use, safe and effective Cost effective. Can be used for malignant GI hemorrhage	1 Theoretically possible side effects of Hemospray include embolization, intestinal obstruction, and allergic reaction to the powder
		2 If hemostasis fails, there is the disadvantage that the powder attached to the mucous membrane may limit the use of other hemostatic modalities
		3 Hemospray works only on active bleeding

EVL: Endoscopic band ligation; GAVE: Gastric antral vascular ectasia; EUS: Endoscopic ultrasound; GI: Gastrointestinal; RFA: Radiofrequency ablation; ESD: Endoscopic submucosal dissection; OTSC: Over-The-Scope Clip.

efficacious alternative modality[58,59]. However, further prospective studies are warranted with larger sample sizes, longer follow-up interval, and examination of cost-effectiveness and procedural time.

EMERGING THERMAL TREATMENT OPTIONS FOR NVUGIB

Coagrasper

Coagrasper (Olympus Corp., Tokyo, Japan) or hemostatic forceps is a combination of

Table 4 Efficacy and safety of over the scope clips in the management of non-variceal upper gastrointestinal bleeding (2009-2018)

Authors and year of publication	Study design	Study participants	Sample size	Duration	Outcomes of the study	Success rate
Repici *et al*[33], 2009	Retrospective	Mean age, 70 yr, gender (M/F): 5/2	7	Unknown	Success rates with the first endoscopic therapy	Success rates with the first endoscopic therapy
Kirschniak *et al*[34], 2011	Retrospective	Mean age, 68 yr, gender (M/F): 18/9	27	2006-2010	1 Success rates with the first endoscopic therapy 2 Rebleeding episodes	Primary hemostasis was achieved in all cases (100%) Rebleeding was observed in 2 cases
Albert *et al*[35], 2011	Retrospective	Mean age, 62 yr, gender (M/F): 5/2	7	Unknown	1 Success rates with the first endoscopic therapy 2 Rebleeding episodes	Primary success rate was observed in 100%
Skinner *et al*[36], 2014	Retrospective	Mean age, 59 yr, gender (M/F): 8/5	12	2012-2013	1 Success rates with the first endoscopic therapy 2 Rebleeding episodes	Hemostasis was achieved in all patients. Rebleeding occurred in two patients 1 d and 7 d after OTSC placement
Nishiyama *et al*[37], 2013	Retrospective	Mean age, 77 yr, gender (M/F): 5/4	9	2011-2012	Success rates with the first endoscopic therapy	Primary success rate was observed in 77.8%
Manta *et al*[39], 2013	Retrospective	Mean age, 64 yr, gender (M/F): 14/16	30	2011-2012	1 Success rates with the first endoscopic therapy 2 Rebleeding episodes	Primary hemostasis was achieved in 29 of 30 cases (97%) Rebleeding was observed in two cases (one duodenal bulb and one gastric ulcer)
Manno *et al*[38], 2016	Retrospective	Mean age, 69 yr, gender (M/F): 33/7	40	2013-2014	1 Success rates with the first endoscopic therapy 2 Rebleeding episodes	Technical success and primary haemostasis were achieved in all patients (100%). No re-bleeding need for surgical or radiological embolization treatment or other complications were observed during the follow-up period of 30 d
Richter-Schrag *et al*[40], 2016	Retrospective	Mean age, 72 yr, gender (M/F): 58/35	93	2012-2016	1 Success rates with the first endoscopic therapy 2 Rebleeding episodes	Primary hemostasis and clinical success of bleeding lesions (without rebleeding) was achieved in 88/100 (88%) and 78/100 (78%), respectively
Wedi *et al*[41], 2016	Retrospective	Mean age, 71 yr, gender (M/F): 50/34	84	2009-2012	Success rates with the first endoscopic therapy	Success rate 35/41 (85.36%)

Lamberts *et al*[42], 2017	Retrospective	Mean age, 71.7 yr, gender (M/F): 55/20	75	February 2011 and June 2014	1 Success rates with the first endoscopic therapy 2 Rebleeding episodes	Application of the OTSC resulted in immediate hemostasis (primary success rate) in all 75 patients. However, in 34.7% a rebleeding episode was noted that could be treated by further endoscopic interventions. Only 3 patients had to be sent to the operating room because of failure of endoscopic therapy. In the rebleeding group the use of antiplatelet therapies was higher (73.1% *vs* 48.9%)
Brandler *et al*[43], 2018	Retrospective	Mean age, 71 yr, gender (M/F): 38/29	67	2011-2015	OTSC safety and efficacy in GI bleeding	OTSC success rate of 81.3%
Schmidt *et al*[44], 2018	Prospective, randomized, controlled multicenter trial	Mean age: 77 yr, gender (M/F): 37/29	67	March 2013 to September 2016	1 Persistent bleeding despite endoscopic therapy according to the protocol or 2 Recurrent bleeding within 7 d after initial successful endoscopic therapy	Persistent bleeding after per-protocol hemostasis was observed in 14 patients (42.4%) in the standard therapy group and 2 patients (6.0%) in the OTSC group ($P < 0.001$) Recurrent bleeding within 7 d occurred in 5 patients (16.1%) in the standard therapy group *vs* 3 patients (9.1%) in the OTSC group ($P = 0.468$)

GI: Gastrointestinal; OTSC: Over-The-Scope Clip.

a thermal and mechanical hemostasis device that delivers targeted monopolar coagulation at the precise site of bleeding[60]. It was initially developed to prevent and treat gastrointestinal bleeding associated with minimally invasive endoscopic procedures, such as EMRs, ESD, and resection of small gastric tumors[61]. Three sizes of the coagrasper are available with different jaw widths to allow effective hemostasis.

Coagrasper has several advantages over conventional heater probe thermal coagulation and hemoclips. Due to these unique properties, it is one of the safest and most efficacious hemostasis modalities[62]. The large surface area of the forceps and anti-slip jaw design provides mechanical tamponade effect to the surrounding tissue making it a highly efficacious hemostasis method. In addition, the risk of perforation is extremely low because coagrasper works at a lower voltage as compared to other thermal treatments coagulates tissues without any carbonization and does not extend to deeper tissue. The forceps can be used to treat multiple bleeding sites proving to be cost-effective[63].

A recent randomized prospective trial by Toka B and co-authors compared the efficacy of hemostatic forceps ($n = 56$) with hemoclip ($n = 56$) for NVUGIB[64]. The study reported an initial success rate in more than 98% of patients treated with coagrasper as compared to 80% in the hemoclip group. Rebleeding rates were lower in coagrasper group without adverse events. The shorter length of hospitalization and duration of endoscopic procedure in patients treated with coagrasper were reported. Another randomized controlled trial comparing efficacy of soft mode coagulation and heater probe thermocoagulation for peptic ulcer bleeding was published in 2015[65]. Significant differences were observed in achieving primary hemostasis in treatments groups with coagrasper (96%) and heater probe (67%). No reports of rebleeding and adverse events were observed in the coagrasper group. In contrast, perforation occurred in 2 patients treated with a heater probe, which were managed conservatively.

Radiofrequency ablation

Radiofrequency ablation (RFA) was primarily used for the treatment of Barrett's esophagus; however, it is an emerging endoscopic treatment for GAVE[66]. RFA can be performed by either using focal catheter (Barrx™ HALO^{90} and HALO^{ULTRA}) or Barrx TTS RFA catheter.

In a prospective open-label single center study, Raza and colleagues demonstrated 100% technical success with the HALO system and 67% clinical success in 9 patients after an 11-mo follow-up interval[67]. Further studies confirmed similar results of technical and clinical success with improved post-procedural hemoglobin without major adverse events observed[67,68]. Despite the promising results, the studies do not present a randomized design and have a short follow-up interval. A multicenter open-label retrospective case series demonstrated a significant increase in hemoglobin post-procedural with the HALO system, as well as a reduction of blood transfusions needed in 24 patients[68]. There are limited studies examining the use of RFA in other gastrointestinal related bleeds.

Cryotherapy

Cryotherapy has been proposed as a useful hemostasis modality by inducing cell necrosis through localized freezing of the large surface area of tissue[69]. Cho and colleagues demonstrated 50% of patients achieving complete response, while the other half achieved a partial response of GAVE related bleeding[70]. There was a reduction of blood transfusions required post-procedural, and an increase in hemoglobin was observed. There were no immediate complications observed. However, this was a small single-study pilot study with a short follow-up period. The number of treatment sessions and the type of cryogen need to be determined.

Endoscopic laser coagulation

Endoscopic laser coagulation is another non-contact modality thermal method of hemostasis. An Nd: YAG laser is applied through the channel of an endoscope with the tip positioned 5 to 10 mm from the ulcer and the beam directed at the site of bleeding. Although ND: YAG laser therapy has been shown to be effective, it is not routinely used in the management of NVUGIB[55]. This is due to the technical constraints of the technique, the large size of laser delivery unit, requirement of special electrical and water supplies, and least cost-effective as compared to other modalities[71].

EMERGING TOPICAL TREATMENT OPTIONS FOR NVUGIB

Hemospray

Hemostatic spray (Cook Medical, Winston-Salem, NC, United States), also known as HS or TC-325, is an absorptive inorganic powder that coalesces and adheres to the bleeding site forming a mechanical barrier[72]. It is not absorbed or metabolized by the gastrointestinal tract, limiting systemic toxicity, and sloughs off once hemostasis is achieved allowing for re-application if necessary[72]. HS does not require direct contact with the bleeding vessel and can, therefore, cover a larger surface area. In addition, it may promote platelet aggregation, activate the clotting cascade, as well as promote tissue formation[72]. HS has been evaluated as a monotherapy modality, such as in the management of a bulbar ulcer related bleed, as well as with other conventional therapy and as a rescue therapy[73]. In addition, it has been studied in malignancy related bleeding and use after therapeutic endoscopic interventions (Table 5).

Several case series described the effect of HS on malignancy related bleeding. Chen *et al*[55] described 100% (5/5) of patients attaining immediate hemostasis with one recurrence of bleeding in a patient with severe metastatic disease complicated by disseminated intravascular coagulation[55,73]. As studied by Leblanc *et al*[72], 100% (5/5) of patients achieved immediate hemostasis (absent bleeding > 5 min after application) with one of two patients (esophageal tumor and stent placement) considered a treatment failure (not achieving immediate hemostasis or with recurrent bleeding despite 2 separate applications)[72]. Furthermore, Arena *et al*[74] demonstrated 93% achieving immediate hemostasis with a rebleeding rate (drop in hemoglobin > 2 g/dL) of 20%. Lastly, in a retrospective study, immediate hemostasis was achieved in 97.7% patients with recurrent bleeding of 15% (classified as early, < 3 d) and 17% (classified as delayed, > 3 d)[75]. No adverse events or procedural complications were observed in either study. Although bleeding may recur, HS appears to be effective for NVUGIB related to malignancies. The rate of recurrent bleeding and mortality have also been studied.

HS use in post-procedural related bleeds has also been studied. Leblanc and

Table 5 Efficacy and safety of hemospray in the management of non-variceal upper gastrointestinal bleeding (2013-2018)

Study	Type of study	Sample size	Bleeding source	Modality	Outcomes	Results
Leblanc *et al*[72], 2013	Case series, single arm (July 2011-March 2012)	17 patients	Procedural (12/17) and malignancy related bleeding (5/17)	Monotherapy or rescue therapy	Immediate hemostasis, recurrent bleeding and mortality at 7 and 30 d, and related adverse events	Immediate hemostasis achieved in 100% patient in both groups; 2 patients with recurrent bleeding with 1 of 2 with treatment failure. No adverse events. No related complications
Sakai *et al*[73], 2016	Case report	1 patient	Ulcer related bleeding	Monotherapy	Immediate hemostasis	Immediate hemostasis achieved. No recurrent bleeding. No adverse events
Chen *et al*[55], 2015	Retrospectiv single center study; (July 2011-July 2013)	60 patients	21 for nonmalignant nonvariceal upper gastrointestinal bleeding, 19 for malignant upper gastrointestinal bleeding, 11 for lower gastrointestinal bleeding, and 16 for intra-procedural bleeding	Monotherapy	Immediate hemostasis and early rebleeding (≤ 72 h)	Immediate hemostasis achieved in 66 cases including upper and lower (98.5%), with 6 cases (9.5%) of early rebleeding
Arena *et al*[74], 2017	Retrospective cohort study; (January 2014-December 2015)	A total of 15 patients, 8 males, mean age 74 yr ± 7.7	Malignancy related bleeding	Monotherapy	Immediate hemostasis, bleeding recurrence, adverse events, clinical outcome at 1 and 6 mo	Immediate hemostasis achieved in 93% (14/15). 3 (21%) patients with recurrent bleeding. 12/14 (80%) with good clinical outcome at 30 d and 50% (6/12) at 6 mo. No related adverse events
Pittayanon *et al*[75], 2018	Retrospective study; (2011-2016)	99 patients (70.5% were male, age 65 ± 14 yr	Malignancy related bleeding	Monotherapy and adjuvant therapy	Immediate hemostasis, early (≤ 3 d) and late (> 3 d) recurrent bleeding	Immediate hemostasis was 97.7%, with recurrent bleeding in 15% (early) and 17% (delayed). Six-month survival was 53.4%
Baracat *et al*[76], 2017	Case report	1 patient	Post-sphincterotomy bleeding	Rescue therapy	Hemostasis	Immediate hemostasis achieved
González *et al*[77], 2016	Case report	1 patient	Post-sclerotherapy bleeding	Monotherapy	Hemostasis	Immediate hemostasis achieved
Sung *et al*[78], 2011	Prospective single-arm	20 patients (18 men, 2 women; mean age 60.2 yr)	Peptic ulcer bleeding (Forrest score Ia or Ib)	Monotherapy	Immediate hemostasis (max of 2 applications allowed), bleeding recurrence post-operatively, after 72 h endoscopically, and after 30 d *via* phone; mortality, need for surgery, and complications	Immediate hemostasis in 95% (19/20) of patients; (1/20) with a pseudoaneurysm requiring arterial embolization. Bleeding recurred in 2 patients ≤ 72 h (hemoglobin drop); neither had active bleeding at the 72-h endoscopy. No mortality, adverse events, or procedural-related complications at 30-d

Sinha *et al*[79], 2016	Retrospective single center	20 patients (median age of 75 yr; 50% men)	Peptic ulcer related bleeding (forrest 1a and 1b)	Adjuvant therapy to adrenaline, or to adrenaline with clips or a thermal device	Immediate hemostasis, 7 and 30-d rebleeding; all-cause and GI-related 30-d mortality	Initial hemostasis was attained in 95% with an overall rebleeding rate (RBR) at 7 d of 16%. No difference between the 7 and 30-d RBR. Hemospray + adrenaline = 100% initial hemostasis and 25% 7-d RBR. Hemospray as third agent = 92% initial hemostasis and 9% RBR. All-cause mortality was 15% with 1 GI-related death (3%)
Haddara *et al*[80], 2016	Prospective registry; (published 2016)	202 patients	Ulcer related bleeding in 75 patients, malignancy related bleed in 61 patients, procedural related bleed in 35 patients, and other in 31 patients	Monotherapy or rescue therapy	Feasibility, efficacy, re-bleeding rate at day 8 and 30	Application of hemospray was found to be very easy or easy in 31.7% and 55.4%, respectively. Immediate hemostasis achieved in 96.5%. Re-bleeding rate at day 8 and 30 were 26.7% and 33.5%, respectively
Yau *et al*[81], 2014	Retrospective (February 2012-July 2013)	19 patients (mean age 67.6 yr)	Peptic ulcers in 12 (63.2%) patients, Dieulafoy lesions in 2 (10.5%), mucosal erosion in 1 (5.3%), angiodysplastic lesion in 1 (5.3%), ampullectomy site in 1 (5.3%), polypectomy site in 1 (5.3%), and an unidentified lesion in 1 (5.3%)	Monotherapy, adjuvant therapy, and rescue therapy	Immediate hemostasis, recurrent bleeding at 7- and 30 d, mortality at 7 and 30 d (related to GIB), and adverse events (related to Hemospray)	Hemostasis in 14 of 15 (93.3%) patients; Rebleeding within 7 d in 7/18 (38.9%) patients. Potential adverse events in 2 (10.5%) patients (visceral perforation and splenic infarct). Mortality in 5 (26.3%) patients with 1 with hemoperitoneum
Smith *et al*[82], 2014	Multicenter registry (June 2011-September 2011)	63 patients (44 men; median age 65)	30 patients with ulcer related bleeding	Monotherapy or rescue therapy	Immediate hemostasis	47/55 (85%) patients in monotherapy group achieved immediate hemostasis
Sulz *et al*[83], 2014	Case series; (published in 2014)	16 patients	NVUGIB, unidentified	Monotherapy or rescue therapy	Immediate hemostasis	Immediate hemostasis of 93.75% (15/16)

NVUGIB: Non-variceal upper gastrointestinal bleeding; GI: Gastrointestinal; GIB: Gastrointestinal bleeding; RBR: Rebleeding rate.

colleagues studied its efficacy after endoscopic intervention (5 patients after esophageal endoscopic mucosal resection, 4 after duodenal endoscopic mucosal resection, 2 after ampullary resection, and 1 after biliary sphincterotomy)[72]. Immediate hemostasis was achieved in 100% of patients whether used initially alone or as rescue therapy (after epinephrine injection and hemostatic clip placement)[72]. Further proving that HS is an appropriate and efficacious post-procedural hemostatic modality, two case reports highlighted immediate hemostasis achieved in post-sphincterotomy and post-sclerotherapy related bleeding[76,77].

HS can be used as adjunct and rescue therapy[78-81]. Per Sinha, it was used as an adjunct therapy to adrenaline in 40% of patients. Hemostasis was achieved in 95% of patients with an overall rebleeding rate of 16% at 7 d suggesting it should be considered as an adjunct therapy. Per Yau, HS was used as rescue therapy in 84.2% of patients with an overall hemostasis rate of 93.3%, however with a rebleeding rate of 38.9%[81]. Anticoagulant and antiplatelet use, coagulopathy, and thrombocytopenia likely contributed to the significant rebleeding rate[81].

To provide additional data on the efficacy of HS, there is a multicenter registry, by Smith and colleagues, which includes 63 patients[82]. Immediate hemostasis is defined

as the absence of bleeding at the completion of the procedure, while rebleeding was defined as clinical manifestations of gastrointestinal bleeding and a reduction in hemoglobin by 2 g/dL. 10 of the 63 patients were treated for post-procedural bleeding. As a monotherapy use, 85% (47/55) achieved immediate hemostasis, while 100% achieved immediate hemostasis with HS used as adjunct therapy[82]. The efficacy of HS, whether as monotherapy, adjunct therapy, or rescue therapy, appears promising in the management of NVUGIB[83]. However, further, larger prospective studies are warranted to confirm.

Endoclot

Endoclot is an absorbable polysaccharide powder that has been proposed as a useful hemostatic agent. It has been shown to have similar rates of immediate hemostasis achieved and rebleeding compared to standard conventional therapy[84]. Examining endoclot as a primary monotherapy, Kim *et al*[85] studied its use in 12 patients with malignancy-related bleeding. 11 of the 12 patients had advanced gastric cancer. Immediate hemostasis was achieved, regardless of the tumor location and size, or previous use of antiplatelet medications, in all patients with a rebleeding rate in 2 patients (16%) at three and five days after treatment. There were no procedural related adverse events, nor all-cause mortality at 30 d after the procedure[85]. Although the sample size was small and limited to forrest 1b classification of bleeding, as well as the type of malignancy-related bleed, it appeared to be an efficacious modality.

To further evaluate its efficacy as a rescue therapy, Beg *et al*[86] studied the use of endoclot in 21 patients with various gastrointestinal bleeding lesions. Immediate hemostasis was achieved in all patients. The 30-d rebleeding rate was 4.8% and the mortality rate was 19.0%, however, without a statistically significant difference compared to the dual or triple endoscopic therapy group (P = 0.51 and P = 0.31, respectively). Only one death was attributed to the UGI bleed in a patient with a malignant related bleed and significant comorbidities[86].

EMERGING INJECTION TREATMENT OPTION FOR NVUGIB

Endoscopic ultrasound guided angiotherapy

Endoscopic ultrasound (EUS)–guided angiotherapy with doppler monitoring of the vascular response is a promising modality for the management of bleeding lesions that are inaccessible or refractory to standard endoscopic and interventional radiologic techniques[87]. EUS can detect vascular lesions in the gastrointestinal tract that are not visually apparent at endoscopy and target lesions for fine-needle injection of therapeutic agents[88]. Despite most reports on EUS-guided angiotherapy pertain to varices, the technique has also been described for the management of NVUGIB lesions. Although the feasibility and apparent safety of EUS-guided angiotherapy has been demonstrated, the use of EUS as an interventional tool in the managing NVUGIH has remained limited to a few centers worldwide. This is because of the lack of endosonographer training expertise and limited availability of EUS in the acute care setting.

CONCLUSION

In conclusion, NVUGIB continues to be a persistent challenge despite advancements in the both pharmacologic and endoscopic techniques. Several new modalities, as well as, modifications to traditional therapeutic modalities have clearly shown promise in improving outcomes whether used as monotherapy, adjuvant therapy, or rescue therapy for the management of NVUGIB. Due to the numerous NVUGIB etiologies, the indications, efficacy, and safety of the emerging endoscopic techniques continue to be defined. Additional studies are warranted to further define the role of these modalities into the treatment algorithm of NVUGIB and to determine the optimal treatment modality for specific NVUGIB pathology.

REFERENCES

1 **Alzoubaidi D**, Lovat LB, Haidry R. Management of non-variceal upper gastrointestinal bleeding: where are we in 2018? *Frontline Gastroenterol* 2019; **10**: 35-42 [PMID: 30651955 DOI: 10.1136/flgastro-2017-100901]

2 **Luo PJ**, Lin XH, Lin CC, Luo JC, Hu HY, Ting PH, Hou MC. Risk factors for upper gastrointestinal bleeding among aspirin users: An old issue with new findings from a population-based cohort study. *J*

Formos Med Assoc 2019; **118**: 939-944 [PMID: 30366771 DOI: 10.1016/j.jfma.2018.10.007]
3 **Gralnek IM**, Neeman Z, Strate LL. Acute Lower Gastrointestinal Bleeding. *N Engl J Med* 2017; **376**: e50 [PMID: 28591535 DOI: 10.1056/NEJMc1705188]
4 **Khamaysi I**, Gralnek IM. Acute upper gastrointestinal bleeding (UGIB) - initial evaluation and management. *Best Pract Res Clin Gastroenterol* 2013; **27**: 633-638 [PMID: 24160923 DOI: 10.1016/j.bpg.2013.09.002]
5 **Marmo R**, Koch M, Cipolletta L, Capurso L, Pera A, Bianco MA, Rocca R, Dezi A, Fasoli R, Brunati S, Lorenzini I, Germani U, Di Matteo G, Giorgio P, Imperiali G, Minoli G, Barberani F, Boschetto S, Martorano M, Gatto G, Amuso M, Pastorelli A, Torre ES, Triossi O, Buzzi A, Cestari R, Della Casa D, Proietti M, Tanzilli A, Aragona G, Giangregorio F, Allegretta L, Tronci S, Michetti P, Romagnoli P, Nucci A, Rogai F, Piubello W, Tebaldi M, Bonfante F, Casadei A, Cortini C, Chiozzini G, Girardi L, Leoci C, Bagnalasta G, Segato S, Chianese G, Salvagnini M, Rotondano G. Predictive factors of mortality from nonvariceal upper gastrointestinal hemorrhage: a multicenter study. *Am J Gastroenterol* 2008; **103**: 1639-47; quiz 1648 [PMID: 18564127 DOI: 10.1111/j.1572-0241.2008.01865.x]
6 **van Leerdam ME**. Epidemiology of acute upper gastrointestinal bleeding. *Best Pract Res Clin Gastroenterol* 2008; **22**: 209-224 [PMID: 18346679 DOI: 10.1016/j.bpg.2007.10.011]
7 **Laine L**, Yang H, Chang SC, Datto C. Trends for incidence of hospitalization and death due to GI complications in the United States from 2001 to 2009. *Am J Gastroenterol* 2012; **107**: 1190-5; quiz 1196 [PMID: 22688850 DOI: 10.1038/ajg.2012.168]
8 **Wuerth BA**, Rockey DC. Changing Epidemiology of Upper Gastrointestinal Hemorrhage in the Last Decade: A Nationwide Analysis. *Dig Dis Sci* 2018; **63**: 1286-1293 [PMID: 29282637 DOI: 10.1007/s10620-017-4882-6]
9 **Jairath V**, Martel M, Logan RF, Barkun AN. Why do mortality rates for nonvariceal upper gastrointestinal bleeding differ around the world? A systematic review of cohort studies. *Can J Gastroenterol* 2012; **26**: 537-543 [PMID: 22891179 DOI: 10.1155/2012/862905]
10 **Vergara M**, Bennett C, Calvet X, Gisbert JP. Epinephrine injection versus epinephrine injection and a second endoscopic method in high-risk bleeding ulcers. *Cochrane Database Syst Rev* 2014; CD005584 [PMID: 25308912 DOI: 10.1002/14651858.CD005584.pub3]
11 **Fujishiro M**, Iguchi M, Kakushima N, Kato M, Sakata Y, Hoteya S, Kataoka M, Shimaoka S, Yahagi N, Fujimoto K. Guidelines for endoscopic management of non-variceal upper gastrointestinal bleeding. *Dig Endosc* 2016; **28**: 363-378 [PMID: 26900095 DOI: 10.1111/den.12639]
12 **Samuel R**, Bilal M, Tayyem O, Guturu P. Evaluation and management of Non-variceal upper gastrointestinal bleeding. *Dis Mon* 2018; **64**: 333-343 [PMID: 29525375 DOI: 10.1016/j.disamonth.2018.02.003]
13 **Troland D**, Stanley A. Endotherapy of Peptic Ulcer Bleeding. *Gastrointest Endosc Clin N Am* 2018; **28**: 277-289 [PMID: 29933775 DOI: 10.1016/j.giec.2018.02.002]
14 **Laine L**, Jensen DM. Management of patients with ulcer bleeding. *Am J Gastroenterol* 2012; **107**: 345-60; quiz 361 [PMID: 22310222 DOI: 10.1038/ajg.2011.480]
15 **Tsoi KK**, Chiu PW, Chan FK, Ching JY, Lau JY, Sung JJ. The risk of peptic ulcer bleeding mortality in relation to hospital admission on holidays: a cohort study on 8,222 cases of peptic ulcer bleeding. *Am J Gastroenterol* 2012; **107**: 405-410 [PMID: 22108453 DOI: 10.1038/ajg.2011.409]
16 **Camus M**, Jensen DM, Kovacs TO, Jensen ME, Markovic D, Gornbein J. Independent risk factors of 30-day outcomes in 1264 patients with peptic ulcer bleeding in the USA: large ulcers do worse. *Aliment Pharmacol Ther* 2016; **43**: 1080-1089 [PMID: 27000531 DOI: 10.1111/apt.13591]
17 **Gralnek IM**, Dumonceau JM, Kuipers EJ, Lanas A, Sanders DS, Kurien M, Rotondano G, Hucl T, Dinis-Ribeiro M, Marmo R, Racz I, Arezzo A, Hoffmann RT, Lesur G, de Franchis R, Aabakken L, Veitch A, Radaelli F, Salgueiro P, Cardoso R, Maia L, Zullo A, Cipolletta L, Hassan C. Diagnosis and management of nonvariceal upper gastrointestinal hemorrhage: European Society of Gastrointestinal Endoscopy (ESGE) Guideline. *Endoscopy* 2015; **47**: a1-46 [PMID: 26417980 DOI: 10.1055/s-0034-1393172]
18 **Barkun AN**, Bardou M, Kuipers EJ, Sung J, Hunt RH, Martel M, Sinclair P; International Consensus Upper Gastrointestinal Bleeding Conference Group. International consensus recommendations on the management of patients with nonvariceal upper gastrointestinal bleeding. *Ann Intern Med* 2010; **152**: 101-113 [PMID: 20083829 DOI: 10.7326/0003-4819-152-2-201001190-00009]
19 **Lai YC**, Yang SS, Wu CH, Chen TK. Endoscopic hemoclip treatment for bleeding peptic ulcer. *World J Gastroenterol* 2000; **6**: 53-56 [PMID: 11819522 DOI: 10.3748/wjg.v6.i1.53]
20 **Kovacs TO**, Jensen DM. Endoscopic therapy for severe ulcer bleeding. *Gastrointest Endosc Clin N Am* 2011; **21**: 681-696 [PMID: 21944418 DOI: 10.1016/j.giec.2011.07.012]
21 **Gevers AM**, De Goede E, Simoens M, Hiele M, Rutgeerts P. A randomized trial comparing injection therapy with hemoclip and with injection combined with hemoclip for bleeding ulcers. *Gastrointest Endosc* 2002; **55**: 466-469 [PMID: 11923755 DOI: 10.1067/mge.2002.112613]
22 **Wang TJ**, Aihara H, Thompson AC, Schulman AR, Thompson CC, Ryou M. Choosing the right through-the-scope clip: a rigorous comparison of rotatability, whip, open/close precision, and closure strength (with videos). *Gastrointest Endosc* 2019; **89**: 77-86.e1 [PMID: 30056253 DOI: 10.1016/j.gie.2018.07.025]
23 **Sarin N**, Monga N, Adams PC. Time to endoscopy and outcomes in upper gastrointestinal bleeding. *Can J Gastroenterol* 2009; **23**: 489-493 [PMID: 19623332 DOI: 10.1155/2009/604639]
24 **Laursen SB**. Treatment and prognosis in peptic ulcer bleeding. *Dan Med J* 2014; **61**: B4797 [PMID: 24547604]
25 **Maggio D**, Barkun AN, Martel M, Elouali S, Gralnek IM; Reason Investigators. Predictors of early rebleeding after endoscopic therapy in patients with nonvariceal upper gastrointestinal bleeding secondary to high-risk lesions. *Can J Gastroenterol* 2013; **27**: 454-458 [PMID: 23936874 DOI: 10.1155/2013/128760]
26 **García-Iglesias P**, Villoria A, Suarez D, Brullet E, Gallach M, Feu F, Gisbert JP, Barkun A, Calvet X. Meta-analysis: predictors of rebleeding after endoscopic treatment for bleeding peptic ulcer. *Aliment Pharmacol Ther* 2011; **34**: 888-900 [PMID: 21899582 DOI: 10.1111/j.1365-2036.2011.04830.x]
27 **Angsuwatcharakon P**, Prueksapanich P, Kongkam P, Rattanachu-Ek T, Sottisuporn J, Rerknimitr R. Efficacy of the Ovesco Clip for Closure of Endoscope Related Perforations. *Diagn Ther Endosc* 2016; **2016**: 9371878 [PMID: 27293368 DOI: 10.1155/2016/9371878]
28 **Kirschniak A**, Traub F, Kueper MA, Stüker D, Königsrainer A, Kratt T. Endoscopic treatment of gastric perforation caused by acute necrotizing pancreatitis using over-the-scope clips: a case report. *Endoscopy* 2007; **39**: 1100-1102 [PMID: 18072063 DOI: 10.1055/s-2007-966848]
29 **Kirschniak A**, Kratt T, Stüker D, Braun A, Schurr MO, Königsrainer A. A new endoscopic over-the-

scope clip system for treatment of lesions and bleeding in the GI tract: first clinical experiences. *Gastrointest Endosc* 2007; **66**: 162-167 [PMID: 17591492 DOI: 10.1016/j.gie.2007.01.034]

30 **Cahyadi O**, Caca K, Schmidt A. Over-the-scope clip is an effective therapy for postbanding ulcer bleeding after initially successful transjugular intrahepatic portosystemic shunt therapy. *Endoscopy* 2017; **49**: E258-E259 [PMID: 28759921 DOI: 10.1055/s-0043-115890]

31 **Samarasena J**, Chen CL, Chin M, Chang K, Lee J. Successful closure of a cryotherapy-induced bleeding jejunal perforation with the over-the-scope clip system. *Gastrointest Endosc* 2017; **85**: 451 [PMID: 27866906 DOI: 10.1016/j.gie.2016.10.038]

32 **Haito-Chavez Y**, Law JK, Kratt T, Arezzo A, Verra M, Morino M, Sharaiha RZ, Poley JW, Kahaleh M, Thompson CC, Ryan MB, Choksi N, Elmunzer BJ, Gosain S, Goldberg EM, Modayil RJ, Stavropoulos SN, Schembre DB, DiMaio CJ, Chandrasekhara V, Hasan MK, Varadarajulu S, Hawes R, Gomez V, Woodward TA, Rubel-Cohen S, Fluxa F, Vleggaar FP, Akshintala VS, Raju GS, Khashab MA. International multicenter experience with an over-the-scope clipping device for endoscopic management of GI defects (with video). *Gastrointest Endosc* 2014; **80**: 610-622 [PMID: 24908191 DOI: 10.1016/j.gie.2014.03.049]

33 **Repici A**, Arezzo A, De Caro G, Morino M, Pagano N, Rando G, Romeo F, Del Conte G, Danese S, Malesci A. Clinical experience with a new endoscopic over-the-scope clip system for use in the GI tract. *Dig Liver Dis* 2009; **41**: 406-410 [PMID: 18930700 DOI: 10.1016/j.dld.2008.09.002]

34 **Kirschniak A**, Subotova N, Zieker D, Königsrainer A, Kratt T. The Over-The-Scope Clip (OTSC) for the treatment of gastrointestinal bleeding, perforations, and fistulas. *Surg Endosc* 2011; **25**: 2901-2905 [PMID: 21424197 DOI: 10.1007/s00464-011-1640-2]

35 **Albert JG**, Friedrich-Rust M, Woeste G, Strey C, Bechstein WO, Zeuzem S, Sarrazin C. Benefit of a clipping device in use in intestinal bleeding and intestinal leakage. *Gastrointest Endosc* 2011; **74**: 389-397 [PMID: 21612776 DOI: 10.1016/j.gie.2011.03.1128]

36 **Skinner M**, Gutierrez JP, Neumann H, Wilcox CM, Burski C, Mönkemüller K. Over-the-scope clip placement is effective rescue therapy for severe acute upper gastrointestinal bleeding. *Endosc Int Open* 2014; **2**: E37-E40 [PMID: 26134611 DOI: 10.1055/s-0034-1365282]

37 **Nishiyama N**, Mori H, Kobara H, Rafiq K, Fujihara S, Kobayashi M, Oryu M, Masaki T. Efficacy and safety of over-the-scope clip: including complications after endoscopic submucosal dissection. *World J Gastroenterol* 2013; **19**: 2752-2760 [PMID: 23687412 DOI: 10.3748/wjg.v19.i18.2752]

38 **Manno M**, Mangiafico S, Caruso A, Barbera C, Bertani H, Mirante VG, Pigò F, Amardeep K, Conigliaro R. First-line endoscopic treatment with OTSC in patients with high-risk non-variceal upper gastrointestinal bleeding: preliminary experience in 40 cases. *Surg Endosc* 2016; **30**: 2026-2029 [PMID: 26201415 DOI: 10.1007/s00464-015-4436-y]

39 **Manta R**, Galloro G, Mangiavillano B, Conigliaro R, Pasquale L, Arezzo A, Masci E, Bassotti G, Frazzoni M. Over-the-scope clip (OTSC) represents an effective endoscopic treatment for acute GI bleeding after failure of conventional techniques. *Surg Endosc* 2013; **27**: 3162-3164 [PMID: 23436101 DOI: 10.1007/s00464-013-2871-1]

40 **Richter-Schrag HJ**, Glatz T, Walker C, Fischer A, Thimme R. First-line endoscopic treatment with over-the-scope clips significantly improves the primary failure and rebleeding rates in high-risk gastrointestinal bleeding: A single-center experience with 100 cases. *World J Gastroenterol* 2016; **22**: 9162-9171 [PMID: 27895403 DOI: 10.3748/wjg.v22.i41.9162]

41 **Wedi E**, Gonzalez S, Menke D, Kruse E, Matthes K, Hochberger J. One hundred and one over-the-scope-clip applications for severe gastrointestinal bleeding, leaks and fistulas. *World J Gastroenterol* 2016; **22**: 1844-1853 [PMID: 26855543 DOI: 10.3748/wjg.v22.i5.1844]

42 **Lamberts R**, Koch A, Binner C, Zachäus M, Knigge I, Bernhardt M, Halm U. Use of over-the-scope clips (OTSC) for hemostasis in gastrointestinal bleeding in patients under antithrombotic therapy. *Endosc Int Open* 2017; **5**: E324-E330 [PMID: 28484732 DOI: 10.1055/s-0043-104860]

43 **Brandler J**, Baruah A, Zeb M, Mehfooz A, Pophali P, Wong Kee Song L, AbuDayyeh B, Gostout C, Mara K, Dierkhising R, Buttar N. Efficacy of Over-the-Scope Clips in Management of High-Risk Gastrointestinal Bleeding. *Clin Gastroenterol Hepatol* 2018; **16**: 690-696.e1 [PMID: 28756055 DOI: 10.1016/j.cgh.2017.07.020]

44 **Schmidt A**, Gölder S, Goetz M, Meining A, Lau J, von Delius S, Escher M, Hoffmann A, Wiest R, Messmann H, Kratt T, Walter B, Bettinger D, Caca K. Over-the-Scope Clips Are More Effective Than Standard Endoscopic Therapy for Patients With Recurrent Bleeding of Peptic Ulcers. *Gastroenterology* 2018; **155**: 674-686.e6 [PMID: 29803838 DOI: 10.1053/j.gastro.2018.05.037]

45 **Mercky P**, Gonzalez JM, Aimore Bonin E, Emungania O, Brunet J, Grimaud JC, Barthet M. Usefulness of over-the-scope clipping system for closing digestive fistulas. *Dig Endosc* 2015; **27**: 18-24 [PMID: 24720574 DOI: 10.1111/den.12295]

46 **Kobara H**, Mori H, Nishiyama N, Fujihara S, Okano K, Suzuki Y, Masaki T. Over-the-scope clip system: A review of 1517 cases over 9 years. *J Gastroenterol Hepatol* 2019; **34**: 22-30 [PMID: 30069935 DOI: 10.1111/jgh.14402]

47 **Baron TH**, Song LM, Ross A, Tokar JL, Irani S, Kozarek RA. Use of an over-the-scope clipping device: multicenter retrospective results of the first U.S. experience (with videos). *Gastrointest Endosc* 2012; **76**: 202-208 [PMID: 22726484 DOI: 10.1016/j.gie.2012.03.250]

48 **Kalloo AN**, Singh VK, Jagannath SB, Niiyama H, Hill SL, Vaughn CA, Magee CA, Kantsevoy SV. Flexible transgastric peritoneoscopy: a novel approach to diagnostic and therapeutic interventions in the peritoneal cavity. *Gastrointest Endosc* 2004; **60**: 114-117 [PMID: 15229442 DOI: 10.1016/S0016-5107(04)01309-4]

49 **Mori H**, Rahman A, Kobara H, Morishita A, Masaki T. The Development of Endoscopic Suturing Devices: Challenges in the Treatment of Iatrogenic Perforation and Bleeding. *Intern Med* 2016; **55**: 3075-3076 [PMID: 27803396 DOI: 10.2169/internalmedicine.55.7508]

50 **Barola S**, Magnuson T, Schweitzer M, Chen YI, Ngamruengphong S, Khashab MA, Kumbhari V. Endoscopic Suturing for Massively Bleeding Marginal Ulcer 10 days Post Roux-en-Y Gastric Bypass. *Obes Surg* 2017; **27**: 1394-1396 [PMID: 28247322 DOI: 10.1007/s11695-017-2621-x]

51 **Fujihara S**, Mori H, Kobara H, Nishiyama N, Kobayashi M, Rafiq K, Masaki T. The efficacy and safety of prophylactic closure for a large mucosal defect after colorectal endoscopic submucosal dissection. *Oncol Rep* 2013; **30**: 85-90 [PMID: 23674165 DOI: 10.3892/or.2013.2466]

52 **Chiu PW**, Chan FK, Lau JY. Endoscopic Suturing for Ulcer Exclusion in Patients With Massively Bleeding Large Gastric Ulcer. *Gastroenterology* 2015; **149**: 29-30 [PMID: 25962937 DOI: 10.1053/j.gastro.2015.04.054]

53 **Agarwal A**, Benias P, Brewer Gutierrez OI, Wong V, Hanada Y, Yang J, Villgran V, Kumbhari V, Kalloo A, Khashab MA, Chiu P, Ngamruengphong S. Endoscopic suturing for management of peptic ulcer-related upper gastrointestinal bleeding: a preliminary experience. *Endosc Int Open* 2018; **6**: E1439-E1444 [PMID: 30539067 DOI: 10.1055/a-0749-0011]

54 **Barola S**, Fayad L, Hill C, Magnuson T, Schweitzer M, Singh V, Chen YI, Ngamruengphong S, Khashab MA, Kalloo AN, Kumbhari V. Endoscopic Management of Recalcitrant Marginal Ulcers by Covering the Ulcer Bed. *Obes Surg* 2018; **28**: 2252-2260 [PMID: 29556889 DOI: 10.1007/s11695-018-3162-7]

55 **Chen YI**, Barkun A, Nolan S. Hemostatic powder TC-325 in the management of upper and lower gastrointestinal bleeding: a two-year experience at a single institution. *Endoscopy* 2015; **47**: 167-171 [PMID: 25264762 DOI: 10.1055/s-0034-1378098]

56 **Mori H**, Kobara H, Kazi R, Fujihara S, Nishiyama N, Masaki T. Balloon-armed mechanical counter traction and double-armed bar suturing systems for pure endoscopic full-thickness resection. *Gastroenterology* 2014; **147**: 278-80.e1 [PMID: 24973723 DOI: 10.1053/j.gastro.2014.06.030]

57 **Wells CD**, Harrison ME, Gurudu SR, Crowell MD, Byrne TJ, Depetris G, Sharma VK. Treatment of gastric antral vascular ectasia (watermelon stomach) with endoscopic band ligation. *Gastrointest Endosc* 2008; **68**: 231-236 [PMID: 18533150 DOI: 10.1016/j.gie.2008.02.021]

58 **Elhendawy M**, Mosaad S, Alkhalawany W, Abo-Ali L, Enaba M, Elsaka A, Elfert AA. Randomized controlled study of endoscopic band ligation and argon plasma coagulation in the treatment of gastric antral and fundal vascular ectasia. *United European Gastroenterol J* 2016; **4**: 423-428 [PMID: 27403309 DOI: 10.1177/2050640615619837]

59 **Takizawa K**, Oda I, Gotoda T, Yokoi C, Matsuda T, Saito Y, Saito D, Ono H. Routine coagulation of visible vessels may prevent delayed bleeding after endoscopic submucosal dissection--an analysis of risk factors. *Endoscopy* 2008; **40**: 179-183 [PMID: 18322872 DOI: 10.1055/s-2007-995530]

60 **Arima S**, Sakata Y, Ogata S, Tominaga N, Tsuruoka N, Mannen K, Shiraishi R, Shimoda R, Tsunada S, Sakata H, Iwakiri R, Fujimoto K. Evaluation of hemostasis with soft coagulation using endoscopic hemostatic forceps in comparison with metallic hemoclips for bleeding gastric ulcers: a prospective, randomized trial. *J Gastroenterol* 2010; **45**: 501-505 [PMID: 20033825 DOI: 10.1007/s00535-009-0186-8]

61 **Fujishiro M**, Abe N, Endo M, Kawahara Y, Shimoda R, Nagata S, Homma K, Morita Y, Uedo N. Retrospective multicenter study concerning electrocautery forceps with soft coagulation for nonmalignant gastroduodenal ulcer bleeding in Japan. *Dig Endosc* 2010; **22** Suppl 1: S15-S18 [PMID: 20590763 DOI: 10.1111/j.1443-1661.2010.00962.x]

62 **Nagata S**, Kimura S, Ogoshi H, Hidaka T. Endoscopic hemostasis of gastric ulcer bleeding by hemostatic forceps coagulation. *Dig Endosc* 2010; **22** Suppl 1: S22-S25 [PMID: 20590766 DOI: 10.1111/j.1443-1661.2010.00973.x]

63 **Tanaka S**, Toyonaga T, Morita Y, Ishida T, Hoshi N, Grimes KL, Ohara Y, Yoshizaki T, Kawara F, Umegaki E, Azuma T. Efficacy of a new hemostatic forceps during gastric endoscopic submucosal dissection: A prospective randomized controlled trial. *J Gastroenterol Hepatol* 2017; **32**: 846-851 [PMID: 27648821 DOI: 10.1111/jgh.13599]

64 **Toka B**, Eminler AT, Karacaer C, Uslan MI, Koksal AS, Parlak E. Comparison of monopolar hemostatic forceps with soft coagulation versus hemoclip for peptic ulcer bleeding: a randomized trial (with video). *Gastrointest Endosc* 2019; **89**: 792-802 [PMID: 30342026 DOI: 10.1016/j.gie.2018.10.011]

65 **Nunoue T**, Takenaka R, Hori K, Okazaki N, Hamada K, Baba Y, Yamasaki Y, Kono Y, Seki H, Inokuchi T, Takemoto K, Taira A, Tsugeno H, Fujiki S, Kawahara Y, Okada H. A Randomized Trial of Monopolar Soft-mode Coagulation Versus Heater Probe Thermocoagulation for Peptic Ulcer Bleeding. *J Clin Gastroenterol* 2015; **49**: 472-476 [PMID: 25083773 DOI: 10.1097/MCG.0000000000000190]

66 **Maida M**, Camilleri S, Manganaro M, Garufi S, Scarpulla G. Radiofrequency Ablation for Treatment of Refractory Gastric Antral Vascular Ectasia: A Systematic Review of the Literature. *Gastroenterol Res Pract* 2017; **2017**: 5609647 [PMID: 28835751 DOI: 10.1155/2017/5609647]

67 **Raza N**, Diehl DL. Radiofrequency ablation of treatment-refractory gastric antral vascular ectasia (GAVE). *Surg Laparosc Endosc Percutan Tech* 2015; **25**: 79-82 [PMID: 24743681 DOI: 10.1097/SLE.0000000000000033]

68 **Dray X**, Repici A, Gonzalez P, Fristrup C, Lecleire S, Kantsevoy S, Wengrower D, Elbe P, Camus M, Carlino A, Pérez-Roldán F, Adar T, Marteau P. Radiofrequency ablation for the treatment of gastric antral vascular ectasia. *Endoscopy* 2014; **46**: 963-969 [PMID: 25111135 DOI: 10.1055/s-0034-1377695]

69 **Patel AA**, Trindade AJ, Diehl DL, Khara HS, Lee TP, Lee C, Sethi A. Nitrous oxide cryotherapy ablation for refractory gastric antral vascular ectasia. *United European Gastroenterol J* 2018; **6**: 1155-1160 [PMID: 30288277 DOI: 10.1177/2050640618783537]

70 **Cho S**, Zanati S, Yong E, Cirocco M, Kandel G, Kortan P, May G, Marcon N. Endoscopic cryotherapy for the management of gastric antral vascular ectasia. *Gastrointest Endosc* 2008; **68**: 895-902 [PMID: 18640673 DOI: 10.1016/j.gie.2008.03.1109]

71 **Macrì A**, Saladino E, Versaci A, Basile A, Lamberto S, De Francesco F, Familiari L, Famulari C. Massive bleeding from a Dieulafoy's lesion of the duodenum successfully treated with "adjuvant" transarterial embolization and endoscopic laser coagulation. *Acta Chir Belg* 2010; **110**: 208-209 [PMID: 20514835 DOI: 10.1080/00015458.2010.11680599]

72 **Leblanc S**, Vienne A, Dhooge M, Coriat R, Chaussade S, Prat F. Early experience with a novel hemostatic powder used to treat upper GI bleeding related to malignancies or after therapeutic interventions (with videos). *Gastrointest Endosc* 2013; **78**: 169-175 [PMID: 23622976 DOI: 10.1016/j.gie.2013.03.006]

73 **Sakai CM**, Duarte RB, Baracat FI, Baracat R, de Moura EGH. Endoscopic treatment of upper-GI ulcer bleeding with hemostatic powder spray. *VideoGIE* 2016; **2**: 12-13 [PMID: 29905242 DOI: 10.1016/j.vgie.2016.11.005]

74 **Arena M**, Masci E, Eusebi LH, Iabichino G, Mangiavillano B, Viaggi P, Morandi E, Fanti L, Granata A, Traina M, Testoni PA, Opocher E, Luigiano C. Hemospray for treatment of acute bleeding due to upper gastrointestinal tumours. *Dig Liver Dis* 2017; **49**: 514-517 [PMID: 28065526 DOI: 10.1016/j.dld.2016.12.012]

75 **Pittayanon R**, Rerknimitr R, Barkun A. Prognostic factors affecting outcomes in patients with malignant GI bleeding treated with a novel endoscopically delivered hemostatic powder. *Gastrointest Endosc* 2018; **87**: 994-1002 [PMID: 29158179 DOI: 10.1016/j.gie.2017.11.013]

76 **Baracat FI**, Tranquillini CV, Brunaldi VO, Baracat R, de Moura EGH. Hemostatic powder: a new ally in the management of postsphincterotomy bleeding. *VideoGIE* 2017; **2**: 303-304 [PMID: 30027130 DOI: 10.1016/j.vgie.2017.07.002]

77 **González Ortiz B**, Tapia Monge DM, Reyes Cerecedo A, Hernández Mondragón O. [Use of Hemospray®

in post-sclerotherapy bleeding]. *Bol Med Hosp Infant Mex* 2016; **73**: 335-337 [PMID: 29384127 DOI: 10.1016/j.bmhimx.2016.06.005]

78 **Sung JJ**, Luo D, Wu JC, Ching JY, Chan FK, Lau JY, Mack S, Ducharme R, Okolo P, Canto M, Kalloo A, Giday SA. Early clinical experience of the safety and effectiveness of Hemospray in achieving hemostasis in patients with acute peptic ulcer bleeding. *Endoscopy* 2011; **43**: 291-295 [PMID: 21455870 DOI: 10.1055/s-0030-1256311]

79 **Sinha R**, Lockman KA, Church NI, Plevris JN, Hayes PC. The use of hemostatic spray as an adjunct to conventional hemostatic measures in high-risk nonvariceal upper GI bleeding (with video). *Gastrointest Endosc* 2016; **84**: 900-906.e3 [PMID: 27108061 DOI: 10.1016/j.gie.2016.04.016]

80 **Haddara S**, Jacques J, Lecleire S, Branche J, Leblanc S, Le Baleur Y, Privat J, Heyries L, Bichard P, Granval P, Chaput U, Koch S, Levy J, Godart B, Charachon A, Bourgaux JF, Metivier-Cesbron E, Chabrun E, Quentin V, Perrot B, Vanbiervliet G, Coron E. A novel hemostatic powder for upper gastrointestinal bleeding: a multicenter study (the "GRAPHE" registry). *Endoscopy* 2016; **48**: 1084-1095 [PMID: 27760437 DOI: 10.1055/s-0042-116148]

81 **Yau AH**, Ou G, Galorport C, Amar J, Bressler B, Donnellan F, Ko HH, Lam E, Enns RA. Safety and efficacy of Hemospray® in upper gastrointestinal bleeding. *Can J Gastroenterol Hepatol* 2014; **28**: 72-76 [PMID: 24501723 DOI: 10.1155/2014/759436]

82 **Smith LA**, Stanley AJ, Bergman JJ, Kiesslich R, Hoffman A, Tjwa ET, Kuipers EJ, von Holstein CS, Oberg S, Brullet E, Schmidt PN, Iqbal T, Mangiavillano B, Masci E, Prat F, Morris AJ. Hemospray application in nonvariceal upper gastrointestinal bleeding: results of the Survey to Evaluate the Application of Hemospray in the Luminal Tract. *J Clin Gastroenterol* 2014; **48**: e89-e92 [PMID: 24326829 DOI: 10.1097/MCG.0000000000000054]

83 **Sulz MC**, Frei R, Meyenberger C, Bauerfeind P, Semadeni GM, Gubler C. Routine use of Hemospray for gastrointestinal bleeding: prospective two-center experience in Switzerland. *Endoscopy* 2014; **46**: 619-624 [PMID: 24770964 DOI: 10.1055/s-0034-1365505]

84 **Park JC**, Kim YJ, Kim EH, Lee J, Yang HS, Kim EH, Hahn KY, Shin SK, Lee SK, Lee YC. Effectiveness of the polysaccharide hemostatic powder in non-variceal upper gastrointestinal bleeding: Using propensity score matching. *J Gastroenterol Hepatol* 2018; **33**: 1500-1506 [PMID: 29415371 DOI: 10.1111/jgh.14118]

85 **Kim YJ**, Park JC, Kim EH, Shin SK, Lee SK, Lee YC. Hemostatic powder application for control of acute upper gastrointestinal bleeding in patients with gastric malignancy. *Endosc Int Open* 2018; **6**: E700-E705 [PMID: 29868635 DOI: 10.1055/a-0593-5884]

86 **Beg S**, Al-Bakir I, Bhuva M, Patel J, Fullard M, Leahy A. Early clinical experience of the safety and efficacy of EndoClot in the management of non-variceal upper gastrointestinal bleeding. *Endosc Int Open* 2015; **3**: E605-E609 [PMID: 26716120 DOI: 10.1055/s-0034-1393087]

87 **Anastasiou J**, Berzin TM. Endoscopic Ultrasound-Guided Vascular Interventions: From Diagnosis to Treatment. *Saudi J Med Med Sci* 2018; **6**: 61-67 [PMID: 30787823 DOI: 10.4103/sjmms.sjmms_131_17]

88 **Satyavada S**, Davitkov P, Akbar Ali M, Cooper G, Wong RCK, Chak A. Endoscopic Doppler Probe in the Diagnosis and Management of Upper Gastrointestinal Hemorrhage. *ACG Case Rep J* 2018; **5**: e68 [PMID: 30280108 DOI: 10.14309/crj.2018.68]

World Journal of Gastrointestinal Endoscopy

Submit a Manuscript: https://www.f6publishing.com

World J Gastrointest Endosc 2020 January 16; 12(1): 17-22

DOI: 10.4253/wjge.v12.i1.17

ISSN 1948-5190 (online)

ORIGINAL ARTICLE

Retrospective Study

Efficacy of mucosa-submucosa clip closure method after gastric endoscopic submucosal dissection

Satoshi Kinoshita, Toshihiro Nishizawa, Ai Fujimoto, Hideki Mori, Yoshihiro Nakazato, Masahiro Kikuchi, Toshio Uraoka

ORCID number: Satoshi Kinoshita (0000-0001-6501-0443); Toshihiro Nishizawa (0000-0003-4876-3384); Ai Fujimoto (0000-0003-3489-3356); Hideki Mori (0000-0001-8830-4671); Yoshihiro Nakazato (0000-0003-0356-4525); Masahiro Kikuchi (0000-0002-7200-1796); Toshio Uraoka (0000-0002-4425-4331).

Author contributions: All authors helped to perform the research; Kinoshita S and Nishizawa T contributed to manuscript writing and data analysis; Kinoshita S, Nishizawa T, Fujimoto A and Mori H performed the procedures; Nakazato Y and Kikuchi M recruited the patients; Uraoka T developed the mucosa-submucosa clip closure method.

Institutional review board statement: This study was reviewed and approved by the Ethics Committee of the Tokyo Medical Center.

Informed consent statement: Informed consent was obtained from all patients.

Conflict-of-interest statement: All authors declare no conflicts-of-interest related to this article.

Data sharing statement: No additional data are available.

Satoshi Kinoshita, Toshihiro Nishizawa, Ai Fujimoto, Hideki Mori, Yoshihiro Nakazato, Masahiro Kikuchi, Department of Gastroenterology, National Hospital Organization Tokyo Medical Center, Tokyo 152-8902, Japan

Satoshi Kinoshita, Toshihiro Nishizawa, Ai Fujimoto, Division of Research and Development for Minimally Invasive Treatment, Cancer Center, Keio University School of Medicine, Tokyo 160-8582, Japan

Toshihiro Nishizawa, Department of Gastroenterology and Hepatology, International University of Health and Welfare Mita Hospital, Tokyo 108-8329, Japan

Toshio Uraoka, Department of Internal Medicine, Division of Gastroenterology and Hepatology, Gunma University, Maebashi 371-8511, Japan

Corresponding author: Toshihiro Nishizawa, MD, PhD, Doctor, Department of Gastroenterology and Hepatology, International University of Health and Welfare Mita Hospital, Mita 1-4-3 Minato-ku, Tokyo 108-8329, Japan. nisizawa@kf7.so-net.jp

Abstract

BACKGROUND

We recently developed a new endoscopic closure technique using only conventional endo-clips for colorectal lesions. Little is known about the feasibility of the endoscopic mucosa-submucosa clip closure method for gastric lesions.

AIM

To elucidate the efficacy of the endoscopic mucosa-submucosa clip closure method after gastric endoscopic submucosal dissection (ESD).

METHODS

Twenty-two patients who underwent gastric ESD and mucosa-submucosa clip closure were included in this study. In this method, endo-clips are placed at the edges of a mucosal defect. Additional endo-clips are then applied in the same way to facilitate reduction of the defect size. Additional endo-clips are applied to both sides of the mucosal defect. Complete closure can be achieved. We have also developed a "location score" and "closure difficulty index" for assessment purposes.

RESULTS

Complete closure was achieved in 68.2% of the patients (15/22). The location

Manuscript source: Unsolicited manuscript

Received: May 15, 2019
Peer-review started: May 20, 2019
First decision: August 2, 2019
Revised: August 30, 2019
Accepted: November 6, 2019
Article in press: November 6, 2019
Published online: January 16, 2020

P-Reviewer: Goral V, Jonaitis LV, Lee CL, Zhu YL
S-Editor: Yan JP
L-Editor: Webster JR
E-Editor: Ma YJ

score in the failure group was significantly larger than that in the complete closure group (P = 0.023). The closure difficulty index in the failure group was significantly higher than that in the complete closure group (P = 0.007). When the cutoff value of the closure difficulty index was set at 99, the high closure difficulty index predicted failure with a sensitivity of 57.1%, specificity of 100%, and accuracy of 86.3%.

CONCLUSION
The endoscopic mucosa-submucosa clip closure method was unreliable after gastric ESD, especially in cases with a high closure difficulty index.

Key words: Endoscopic submucosal dissection; Stomach; Endoscopic mucosa-submucosa clip closure method; Colorectal

Core tip: The endoscopic mucosa-submucosa clip closure method is a simple closure method using only conventional clips. The success rate of the endoscopic mucosa-submucosa clip closure method was 68.2% (15/22) after gastric endoscopic submucosal dissection. The location and size of a mucosal defect were considered to be the main factors underlying difficulty in closure. Defects were relatively easy to close in the greater curvature of the upper or middle third stomach, because the gastric wall was relatively thin and soft and a front view approach could be taken.

Citation: Kinoshita S, Nishizawa T, Fujimoto A, Mori H, Nakazato Y, Kikuchi M, Uraoka T. Efficacy of mucosa-submucosa clip closure method after gastric endoscopic submucosal dissection. *World J Gastrointest Endosc* 2020; 12(1): 17-22
URL: https://www.wjgnet.com/1948-5190/full/v12/i1/17.htm
DOI: https://dx.doi.org/10.4253/wjge.v12.i1.17

INTRODUCTION

The introduction of endoscopic submucosal dissection (ESD) has led to great advances in the endoscopic treatment of gastric cancer. ESD has been adopted as an established standard treatment for early gastric tumors with the proven capacity to remove large lesions exceeding 2 cm in diameter[1,2]. However, this method sometimes causes complications such as bleeding and perforation. Even when ESD is successfully performed, the ESD-induced ulcers are exposed to gastric acid, pepsin, and mechanical stimuli. Exposure of the ulcers to these elements introduces a risk of delayed perforation or bleeding for several days after the ESD procedure. Patients, therefore, generally must remain in hospital for 5-7 d post-operation[3].

The endoscopic purse-string suture[4], "loop clip"[5], slip knot clip suturing method[6], and string clip suturing method[7] have been reported to be useful for closure of large mucosal defect. The success rates of these methods are over 90%. However, these methods require an endo-loop, double-channel endoscope, string, or supplemental devices. Our group previously developed a simple closure method using only conventional clips[8]. The endoscopic mucosa-submucosa clip closure method is effective in completely closing mucosal defects as large as 2-4 cm in diameter after colorectal ESD[9]. Here we report the results of a clinical pilot study to investigate the use of the endoscopic mucosa-submucosa clip closure method after gastric ESD.

MATERIALS AND METHODS

Patients

Patients with early gastric cancers of less than 35 mm in diameter were selected for inclusion in this study. The exclusion criteria were as follows: (1) Specimen diameter of more than 50 mm; (2) Tumor extension to the cardia or pyloric ring; (3) Suspected submucosal invasion; (4) Tumor with indistinct borders; and (5) Judgment by the operator that the mucosal defect cannot be closed. Seventy patients underwent gastric

ESD at Tokyo Medical Center between May 2018 and February 2019. Of these, 22 patients underwent mucosa-submucosa clip closure after gastric ESD. The protocol of this trial was approved by the in-facility review committee of the Tokyo Medical Center (registration number: R17-106). Written informed consent was obtained from all patients.

Mucosa-submucosa clip closure method

Several standard endo-clips [EZ Clip, HX-610-090L (long-type), Olympus, Tokyo, Japan] were placed at the edges of the mucosal defect[8]. In some cases, a Resolution™ Clip Device (Boston Scientific, Boston, MA, United States) was also occasionally used. The two arms of the endo-clips respectively gripped the mucosa and submucosa in the direction parallel to the short axis of the mucosal defect. Additional endo-clips were then applied in the same way to facilitate the gradual reduction in defect size. Additional endo-clips can then be applied to both sides of the mucosal defect. Complete closure is then achieved. Furthermore, endoscopic inspection was performed to visually confirm complete closure (Figure 1). The endoscopic procedure was carried out using a GIF-Q260J, GIF-H260Z, or GIF-2 TMQ260M (Olympus Co., Tokyo, Japan).

Evaluation of the procedure

Outcomes: We evaluated the success rate, size of the resected specimen, location of the lesion, procedure time, number of clips, adverse events, and length of hospital stay. The areas of the resected specimens were measured using Image J software (National Institutes of Health, Unites States).

The success rate was defined as the percentage of successes (complete closure of mucosal defect) in the patients enrolled. "Complete closure of the mucosal defect" was defined as complete closure of the whole resection site with clips. The procedure time was measured from the insertion of the first clip to completion of the procedure.

Closure difficulty index: The difficulty in closing the defects was assessed by assigning a "closure difficulty index" defined as: The "size of the resected specimen (mm)" × "location score." The location score was assigned as follows: The posterior wall of the stomach and anterior wall or lessor curvature of the upper third stomach were scored as 3; the greater curvature of the upper or middle third stomach was scored as 1; other areas were scored as 2. Mucosal defects were difficult to close in the posterior wall of the stomach and anterior wall or lessor curvature of the upper third stomach, because a lateral view approach had to be taken. Defects were relatively easy to close in the greater curvature of the upper or middle third stomach, because the gastric wall was relatively thin and soft and a front view approach could be taken.

Adverse events: Perforation during ESD was diagnosed if mesenteric fat or intra-abdominal space was observed during the ESD procedure or if free air was detected on chest and abdominal radiographs. Delayed perforation was defined when a patient manifested no signs of perforation during ESD and no symptoms immediately after tumor removal but later complained of sudden abdominal pain and manifested free air on X-ray. Delayed bleeding was defined as bleeding symptoms or hemoglobin loss (≥ 2 g/dL).

Statistics

Each continuous variable was expressed as a mean ± standard deviation. Differences between the two groups were detected using the Student's *t*-test or Welch's *t*-test for continuous data. Categorical secondary outcomes were compared using the chi-squared test. A *P* value of less than 0.05 was considered statistically significant. All statistical analyses were performed using Stat Mate IV software (ATOMS, Tokyo, Japan).

RESULTS

The characteristics of the complete closure group and failure group are summarized in Table 1. The success rate of the endoscopic mucosa-submucosa clip closure method was 68.2% (15/22). Of the 7 cases in the failure group, 3 had partial closure of more than 80% but failed to achieve complete closure. The specimens resected from the failure group were larger than those resected from the complete closure group, but not significantly ($P = 0.087$). The failure group had a significantly higher location score ($P = 0.023$) and closure difficulty index ($P = 0.007$) than the complete closure group.

There were no significant differences between the complete closure group and failure group in delayed perforation, delayed bleeding, and the length of hospital stay

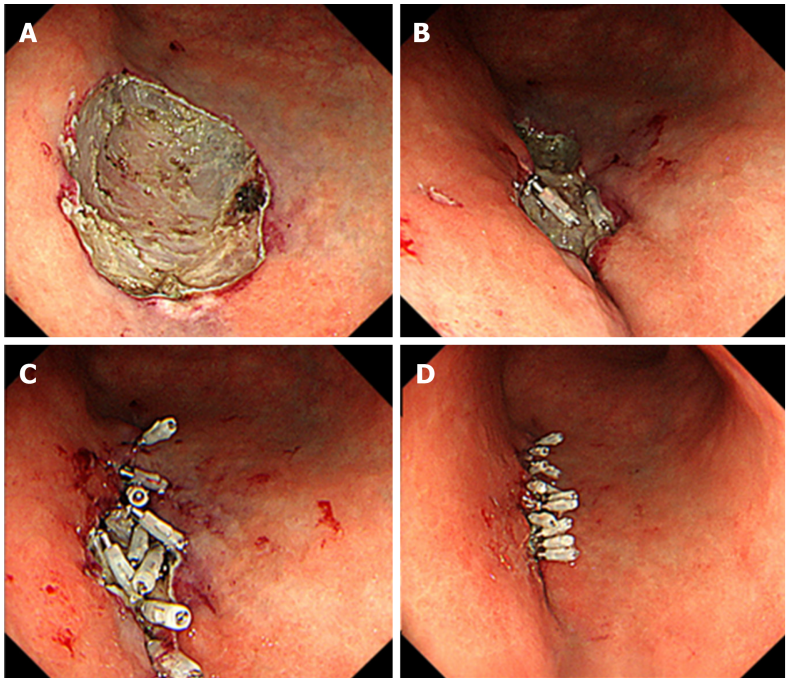

Figure 1 Endoscopic mucosa-submucosa clip closure method for gastric mucosal defect. A: A mucosal defect after gastric endoscopic submucosal dissection at the greater curvature of the middle third stomach; the first and second endo-clips were placed at the edge of the mucosal defect; B: Each arm of the endo-clip hooked mucosa and submucosa, respectively; additional endo-clips were placed; C: This stage shows partial closure of more than 80%; D: Additional endo-clips were placed to achieve complete closure.

(Table 1). When the cutoff value of the closure difficulty index was set at 99, the high index (≥ 99) predicted failure with a sensitivity of 57.1%, specificity of 100%, positive predictive value of 100%, negative predictive value of 83.3%, and accuracy of 86.3% (Table 2). In cases with a high closure difficulty index (≥ 99), the success rate of the endoscopic mucosa-submucosa clip closure method was 0% (0/4).

DISCUSSION

We hypothesized that the endoscopic mucosa-submucosa clip closure method would close gastric mucosal defects of around 2-4 cm in diameter. This study failed to confirm that this method could perform reliably after gastric ESD.

Endoscopic mucosa-submucosa clip closure was often unachieved, especially in cases with a high closure difficulty index (≥ 99). We developed the "closure difficulty index" in the belief that the location and size of a mucosal defect were the main factors underlying difficulty in closure. To the best of our knowledge, the present study is the first to report a useful predictor of failure of gastric mucosal defect closure. Endoscopists should consider other closure methods or forgo closing altogether in cases with a high closure difficulty index.

Few reports have described the closure of post-gastric ESD compared with post-colorectal ESD[4,10-14]. The lesser degree of closure of post-gastric ESD likely stems from the difficulty in closing a large mucosal defect, because the gastric wall is thick and hard. Li *et al*[10] reported that mucosal closure with a detachable snare and clips has a success rate of 61% (16/26). Maekawa *et al*[15] reported that a combined method using over-the-scope clips and through-the-scope clips had a success rate of 91.7% (11/12), but the patients selected for their study had gastric tumors of 3 cm in diameter or less. More effective methods are expected to be developed in the future for larger lesions.

The limitations of this study include its retrospective design. The study was also single-armed and did not compare the superiority of the mucosa-submucosa clip closure method with other methods. Furthermore, the small number of patients was also a limiting factor. These issues should be re-evaluated in larger prospective studies in the future. In conclusion, the endoscopic mucosa-submucosa clip closure method was unreliable after gastric ESD, especially in cases with a high closure difficulty index.

Table 1 The characteristics of the complete closure group and failure group

	Complete closure	Failure	*P* value
Patient			
Number	15	7	
Male sex, *n* (%)	12 (80)	6 (85.7)	0.787
Age (years)	71.5 ± 8.75	75.6 ± 13.1	0.392
Use of antithrombotic agent	3	2	
Resected specimen			
Size	29.3 ± 4.75	34.4 ± 8.68	0.087
Area	6.68 ± 2.39	7.96 ± 4.21	0.37
Location			
L/M/U	6/8/1	2/4/1	0.82
A/P/L/G	5/3/3/4	0/5/1/1	0.09
Location score	1.93 ± 0.704	2.71 ± 0.49	0.016
Closure difficulty index	56.8 ± 21.9	95.4 ± 35	0.005
Closure			
Procedure time (s)	1005.5 ± 723	608.3 ± 358.9	0.22
Number of clips	11.8 ± 2.17	8.57 ± 3.87	0.018
Adverse event			
Perforation during ESD	3	0	0.54
Delayed perforation	0	0	-
Delayed bleeding	0	1	0.69
Length of hospital stay (days)	7.36 ± 0.93	7.86 ± 2.27	0.59

L/M/U: Lower third stomach/middle third stomach/upper third stomach; A/P/L/G: Anterior wall/posterior wall/lessor curvature/greater curvature; ESD: Endoscopic submucosal dissection.

Table 2 High closure difficulty index could predict the failure of complete closure

	Failure	Success
High closure difficulty index (≥ 99)	4	0
Low closure difficulty index (< 99)	3	15

ARTICLE HIGHLIGHTS

Research background

We recently developed the endoscopic mucosa-submucosa clip closure method for mucosal defects after endoscopic submucosal dissection (ESD). The method is a simple closure method using only conventional clips.

Research motivation

The endoscopic mucosa-submucosa clip closure method is feasible for colorectal mucosal defects. However, the feasibility for gastric mucosal defects is still unknown.

Research objectives

The aim of this retrospective study was to elucidate the efficacy of endoscopic mucosa-submucosa clip closure method for gastric mucosal defects.

Research methods

Twenty-two patients who underwent gastric ESD and mucosa-submucosa clip closure were investigated in this study. The difficulty in closing the defects was assessed by the newly developed "location score" and "closure difficulty index". "Closure difficulty index" was defined as: "size of the resected specimen (mm)" × "location score." In the "location score", the area with thick gastric wall and lateral view approach was scored as 3; the area with thin gastric wall and front view approach was scored as 1; other areas were scored as 2.

Research results

The success rate was 68.2% (15/22). The failure group had a significantly higher location score (*P*

= 0.023) and closure difficulty index (P = 0.007) than the complete closure group. When the cutoff value of the closure difficulty index was set at 99, the high closure difficulty index predicted failure with a sensitivity of 57.1%, specificity of 100%, and accuracy of 86.3%.

Research conclusions

The endoscopic mucosa-submucosa clip closure method after gastric ESD would fail in cases with a high closure difficulty index.

Research perspectives

The endoscopic mucosa-submucosa clip closure method is effective in completely closing mucosal defects as large as 2-4 cm in diameter after colorectal ESD.

REFERENCES

1 **Nishizawa T**, Yahagi N. Endoscopic mucosal resection and endoscopic submucosal dissection: technique and new directions. *Curr Opin Gastroenterol* 2017; **33**: 315-319 [PMID: 28704212 DOI: 10.1097/MOG.0000000000000388]

2 **Fujimoto A**, Goto O, Nishizawa T, Ochiai Y, Horii J, Maehata T, Akimoto T, Kinoshita S, Sagara S, Sasaki M, Uraoka T, Yahagi N. Gastric ESD may be useful as accurate staging and decision of future therapeutic strategy. *Endosc Int Open* 2017; **5**: E90-E95 [PMID: 28210705 DOI: 10.1055/s-0042-119392]

3 **Kim YJ**, Park DK. Management of complications following endoscopic submucosal dissection for gastric cancer. *World J Gastrointest Endosc* 2011; **3**: 67-70 [PMID: 21603034 DOI: 10.4253/wjge.v3.i4.67]

4 **Zhang Y**, Wang X, Xiong G, Qian Y, Wang H, Liu L, Miao L, Fan Z. Complete defect closure of gastric submucosal tumors with purse-string sutures. *Surg Endosc* 2014; **28**: 1844-1851 [PMID: 24442680 DOI: 10.1007/s00464-013-3404-7]

5 **Sakamoto N**, Beppu K, Matsumoto K, Shibuya T, Osada T, Mori H, Shimada Y, Konno A, Kurosawa A, Nagahara A, Otaka M, Ohkusa T, Ogihara T, Watanabe S. "Loop Clip", a new closure device for large mucosal defects after EMR and ESD. *Endoscopy* 2008; **40** Suppl 2: E97-E98 [PMID: 19085714 DOI: 10.1055/s-2007-995604]

6 **Nishizawa T**, Ochiai Y, Uraoka T, Akimoto T, Mitsunaga Y, Goto O, Fujimoto A, Maehata T, Kanai T, Yahagi N. Endoscopic slip-knot clip suturing method: prospective pilot study (with video). *Gastrointest Endosc* 2017; **85**: 433-437 [PMID: 27475491 DOI: 10.1016/j.gie.2016.07.047]

7 **Yahagi N**, Nishizawa T, Akimoto T, Ochiai Y, Goto O. New endoscopic suturing method: string clip suturing method. *Gastrointest Endosc* 2016; **84**: 1064-1065 [PMID: 27327846 DOI: 10.1016/j.gie.2016.05.054]

8 **Banno S**, Nishizawa T, Kinoshita S, Mori H, Uraoka T. Endoscopic mucosa-submucosal clip closure method. *Endoscopy* 2017; **49**: E307-E308 [PMID: 28992633 DOI: 10.1055/s-0043-119349]

9 **Nishizawa T**, Banno S, Kinoshita S, Mori H, Nakazato Y, Hirai Y, Kubosawa Y, Sunata Y, Matsushita M, Uraoka T. Feasibility of endoscopic mucosa-submucosa clip closure method (with video). *Endosc Int Open* 2018; **6**: E1070-E1074 [PMID: 30105296 DOI: 10.1055/a-0630-0566]

10 **Lee BI**, Kim BW, Kim HK, Choi H, Ji JS, Hwang SM, Cho YS, Chae HS, Choi KY. Routine mucosal closure with a detachable snare and clips after endoscopic submucosal dissection for gastric epithelial neoplasms: a randomized controlled trial. *Gut Liver* 2011; **5**: 454-459 [PMID: 22195243 DOI: 10.5009/gnl.2011.5.4.454]

11 **Goto O**, Sasaki M, Akimoto T, Ochiai Y, Kiguchi Y, Mitsunaga Y, Fujimoto A, Maehata T, Nishizawa T, Takeuchi H, Kitagawa Y, Yahagi N. Endoscopic hand-suturing for defect closure after gastric endoscopic submucosal dissection: a pilot study in animals and in humans. *Endoscopy* 2017; **49**: 792-797 [PMID: 28561197 DOI: 10.1055/s-0043-110668]

12 **Akimoto T**, Goto O, Sasaki M, Ochiai Y, Maehata T, Fujimoto A, Nishizawa T, Yahagi N. "Hold-and-drag" closure technique using repositionable clips for large mucosal defects after colonic endoscopic submucosal dissection. *Endosc Int Open* 2016; **4**: E1068-E1072 [PMID: 27747279 DOI: 10.1055/s-0042-112126]

13 **Harada H**, Suehiro S, Murakami D, Nakahara R, Ujihara T, Shimizu T, Miyama Y, Katsuyama Y, Hayasaka K, Tounou S. Clinical impact of prophylactic clip closure of mucosal defects after colorectal endoscopic submucosal dissection. *Endosc Int Open* 2017; **5**: E1165-E1171 [PMID: 29201999 DOI: 10.1055/s-0043-118743]

14 **Ogiyama H**, Tsutsui S, Murayama Y, Maeda S, Satake S, Nasu A, Umeda D, Miura Y, Tominaga K, Horiki M, Sanomura T, Imanaka K, Iishi H. Prophylactic clip closure may reduce the risk of delayed bleeding after colorectal endoscopic submucosal dissection. *Endosc Int Open* 2018; **6**: E582-E588 [PMID: 29756016 DOI: 10.1055/a-0581-8886]

15 **Maekawa S**, Nomura R, Murase T, Ann Y, Harada M. Complete closure of artificial gastric ulcer after endoscopic submucosal dissection by combined use of a single over-the-scope clip and through-the-scope clips (with videos). *Surg Endosc* 2015; **29**: 500-504 [PMID: 25052125 DOI: 10.1007/s00464-014-3725-1]

World Journal of Gastrointestinal Endoscopy

Submit a Manuscript: https://www.f6publishing.com

World J Gastrointest Endosc 2020 January 16; 12(1): 23-32

DOI: 10.4253/wjge.v12.i1.23

ISSN 1948-5190 (online)

ORIGINAL ARTICLE

Clinical Trials Study

High-definition optical magnification with digital chromoendoscopy detects gastric mucosal changes in dyspeptic-patients

Carlos Robles-Medranda, Manuel Valero, Miguel Puga-Tejada, Roberto Oleas, Jorge Baquerizo-Burgos, Miguel Soria-Alcívar, Haydee Alvarado-Escobar, Hannah Pitanga-Lukashok

ORCID number: Carlos Robles-Medranda (0000-0003-2434-3369); Manuel Valero (0000-0002-3787-2166); Miguel Puga-Tejada (0000-0001-8853-0847); Roberto Oleas (0000-0001-9810-4745); Jorge Baquerizo-Burgos (0000-0002-6741-4211); Miguel Soria-Alcivar (0000-0003-0038-3155); Haydee Alvarado-Escobar (0000-0003-0383-8370); Hannah Pitanga-Lukashok (0000-0002-4364-1321).

Author contributions: Robles-Medranda C and Pitanga-Lukashok H designed the study; Robles-Medranda C, Valero M, Soria-Alcívar M and Alvarado-Escobar H performed the research; Puga-Tejada M analyzed the data; Valero M, Oleas R and Baquerizo-Burgos J wrote the paper.

Institutional review board statement: This study was reviewed and approved by the Instituto Ecuatoriano de Enfermedades Digestivas Institutional Review Board.

Clinical trial registration statement: This study is registered on clinical trials.gov under the code NCT02597517.

Informed consent statement: Informed written consent was provided from all study participants or their legal guardian prior to study enrollment.

Conflict-of-interest statement: Robles-Medranda C is a key

Carlos Robles-Medranda, Manuel Valero, Miguel Puga-Tejada, Roberto Oleas, Jorge Baquerizo-Burgos, Miguel Soria-Alcívar, Haydee Alvarado-Escobar, Hannah Pitanga-Lukashok, Gastroenterology and Endoscopy Division, Instituto Ecuatoriano de Enfermedades Digestivas (IECED), Guayaquil 090505, Ecuador

Corresponding author: Carlos Robles-Medranda, MD, Professor, Gastroenterology and Endoscopy Division, Instituto Ecuatoriano de Enfermedades Digestivas (IECED), Av. Abel Romeo Castillo y Av. Juan Tanca Marengo, Torre Vitalis, Mezzanine 3, Guayaquil 090505, Ecuador. carlosoakm@yahoo.es

Abstract

BACKGROUND

Accurate detection of gastric infection by *Helicobacter pylori* (*H. pylori*) and premalignant lesions are important for effective provision of treatment, preventing the development of gastric neoplasia. Optical enhancement systems with optical magnification improved the identification of mucosal superficial and vascular patterns in patients with dyspepsia.

AIM

To evaluate an optical enhancement system with high-definition magnification, for diagnosis of normal gastric mucosa, *H. pylori*-associated gastritis, and gastric atrophy.

METHODS

A cross-sectional, nonrandomized study from November 2015 to April 2016 performed in a single-tertiary academic center from Ecuador. Seventy-two consecutive patients with functional dyspepsia according to the Rome III criteria, were tested for *H. pylori* using a stool antigen test and were assigned to an Hp^+ group or an Hp^- control group. Esophagogastroduodenoscopy with high-definition optical magnification and digital chromoendoscopy was performed, and patients were classified into 4 groups, in accordance to the microvascular-architecture pattern of the mucosa. Interobserver and intraobserver agreement among operators were calculated.

RESULTS

Of the 72 participants, 35 were Hp^+ and 37 were Hp^-. Among 10 patients with normal mucosal histology in biopsy samples, 90% had a Type I pattern of microvascular architecture by endoscopy. Among participants with type IIa and

opinion leader for Pentax Medial and Boston Scientific. The other authors declare that they have no conflicts of interest.

Manuscript source: Unsolicited manuscript

Received: June 28, 2019
Peer-review started: June 29, 2019
First decision: August 2, 2019
Revised: August 13, 2019
Accepted: November 18, 2019
Article in press: November 18, 2019
Published online: January 16, 2020

P-Reviewer: Altonbary A
S-Editor: Yan JP
L-Editor: A
E-Editor: Ma YJ

type IIb patterns, significantly more were *Hp*+ than *Hp*− (32 *vs* 8), and most (31 out of 40) had histological diagnoses of chronic active gastritis. Two of the three participants with a histological diagnosis of atrophy had a type III microvascular pattern. The type I pattern predicted normal mucosa, type IIa–IIb predicted *H. pylori* infection, and type III predicted atrophy with sensitivities of 90.0%, 91.4%, and 66.7%, respectively. The intraobserver and interobserver agreements had kappa values of 0.91 and 0.89, respectively.

CONCLUSION

High-definition optical magnification with digital chromoendoscopy is useful for diagnosis of normal gastric mucosa and *H. pylori*-associated gastritis with high accuracy, but further studies are needed to determine whether endoscopic diagnosis of gastric atrophy is feasible.

Key words: Gastritis; *Helicobacter pylori*; Gastric mucosa; Atrophic; Endoscopy; Digestive system

Core tip: The accurate and reliable detection of *Helicobacter pylori*-associated gastritis and gastric atrophy is imperative for appropriate therapy, preventing the development of gastric neoplasia. Digital chromoendoscopy with optical magnification improved the identification of mucosal superficial and vascular patterns in the gastric mucosa of dyspeptic patients. We described a high sensitivity and accuracy for predicting normal gastric mucosa and *Helicobacter pylori*-associated gastritis, with a high interobserver agreement. The accurate detection of gastric infection by *Helicobacter pylori* and the presence of premalignant lesion at an early stage are important for the effective provision of treatment.

Citation: Robles-Medranda C, Valero M, Puga-Tejada M, Oleas R, Baquerizo-Burgos J, Soria-Alcívar M, Alvarado-Escobar H, Pitanga-Lukashok H. High-definition optical magnification with digital chromoendoscopy detects gastric mucosal changes in dyspeptic-patients. *World J Gastrointest Endosc* 2020; 12(1): 23-32
URL: https://www.wjgnet.com/1948-5190/full/v12/i1/23.htm
DOI: https://dx.doi.org/10.4253/wjge.v12.i1.23

INTRODUCTION

Gastric cancer is the second most common cause of cancer-related death worldwide, and upper endoscopy is essential to enable its identification at an early stage[1]. *Helicobacter pylori* (*H. pylori*) is involved in the pathogenesis of gastric diseases, such as peptic ulcers, gastric lymphoma, and gastric cancer[2-6].Thus, it is important to detect *H. pylori* infection and premalignant gastric lesions at an early stage so that the best therapeutic approaches can be offered[7]. Diagnosis of *H. pylori*-associated gastritis and gastric atrophy on the basis of endoscopic findings can be difficult, so histology is considered to be the diagnostic gold standard for these conditions[8,9]. *H. pylori* infection and the resultant gastric atrophy are known premalignant lesions linked to gastric carcinogenesis[10]. However, the reliability of detection of *H. pylori* infection or gastric atrophy by histology depends on the location, number, and size of the endoscopy-guided gastric-biopsy specimens. Alternatively, obtaining samples for histological assessment by endoscopic gastric biopsy can result in significant sampling errors.

Pentax Medical (HOYA, Tokyo, Japan) developed the Optical Enhancement™ (OE) System, which combines bandwidth-limited light with an endoscopy video system. This technology combines digital signal processing (similar to I-SCAN™) with optical filters that limit the spectral characteristics of the illuminating light, enhancing visualization of the mucosal surface and microvessels[11]. In addition, MagniView™ endoscopes have been developed, and can combine high-definition imaging with optical magnification.

The present study was designed to enable evaluation of the OE System with optical magnification for diagnosis of normal gastric mucosa, *H. pylori*-associated gastritis,

and gastric atrophy. Additionally, interobserver and intraobserver reproducibility in the assessment of endoscopic patterns detected was assessed.

MATERIALS AND METHODS

Study design

The investigation involved a cross-sectional, nonrandomized, double-blind study that was performed at the Instituto Ecuatoriano de Enfermedades Digestivas, Academic Tertiary Center, Ecuador, between November 2015 and April 2016. The study protocol and consent form were approved by the Institutional Review Board, registered at ClinicalTrials.gov (ID: NCT02597517), and the study was conducted according to the guidelines of the Declaration of Helsinki. All patients provided written informed consent. All authors had access to the study data and had reviewed and approved the final manuscript.

Population selection

The required sample size was estimated with a 95% confidence interval (CI) and a 7.5% margin of error, on the basis of the results of Tongtawee *et al*[12]. All consecutive participants had functional dyspepsia according to the Rome III criteria, and were ≥ 18 years old. Participants had an epigastric pain syndrome (defined as localized pain or burning pain in the upper abdomen at least once a week, which was intermittent, nongeneralized, not relieved by defecation, and did not meet the criteria for pathology of the gallbladder or sphincter of Oddi) and/or a postprandial distress syndrome (defined as the presence of a nagging feeling of postprandial fullness after normal-volume meals, and/or early satiety that prevented the completion of a regular meal several times a week). The criteria had to be present within the three months prior to enrolment, and to have started ≥ 6 mo prior to diagnosis of dyspepsia[13]. Patients with severe uncontrolled coagulopathy, prior history of gastric surgery, or ongoing pregnancy, as well as patients who had received nonsteroidal anti-inflammatory drugs (NSAIDs), proton-pump inhibitors (PPIs) or antibiotics in the preceding three weeks were excluded.

Participants were tested for *H. pylori* infection with the *H. pylori* stool antigen test (Wondfo®, Wondfo Biotech Co., Guangzhou, China), prior to allocation into two groups: Hp^+ and Hp^- (control group) (Figure 1). Finally, upper endoscopy was performed with the OE System and optical magnification. Endoscopists and participants were blinded to the group allocation.

Endoscopic technique

Complete endoscopic procedures were performed, with evaluation of the entire stomach with conventional white light, to exclude obvious lesions. Participants were also evaluated by upper endoscopy with the OE System (including OPTIVISTA EPK-i7010 HD Video Processor; Pentax Medical, Hoya Corp., Japan) and MagniView™ EG-2990Zi Video Gastroscope (Pentax Medical, Hoya Corp., Japan) under intravenous sedation in a standardized manner. This technique involved the use of a distal black rubber hood (OE-A58; Pentax) at the tip of the endoscope, to fix the distance between the tip of the endoscope and the gastric mucosa at 2 mm. The OE System was initially used in mode 1 and mode 2 without optical magnification, to obtain an overview of the gastric body and identify any gross changes in the mucosa, then optical magnification was implemented. At maximum magnification, the hood was brought into contact with the gastric mucosa, and water was instilled. Any residue in the stomach was removed with a water-ejection pump prior to the procedure. Each endoscopy was performed by one of three endoscopists (Robles-Medranda C, Valero M, and Soria-Alcívar M), who were assigned by randomized allocation, blinded to the group selection, and trained in the use of the OE system with optical magnification.

OE System and MagniView™ endoscope

OE System: The OE System combines digital signal processing with optical filters that limit the spectral characteristics of the illuminating light, connecting the peaks of the hemoglobin absorption spectrum (415 nm, 540 nm, and 570 nm) to create a continuous wavelength spectrum. The OE System has two modes that use different filters to optimize visualization of specific features. Here, only mode 1 was used for the high-magnification studies, because of its ability to enhance microvessel visualization.

MagniView endoscope: The MagniView™ combines a high-definition endoscope with optical magnification, to produce detailed images with magnification of up to 136×. This imaging facilitates the evaluation of the superficial vascular aspects of the mucosa, enabling identification of early signs of inflammation or lesions not

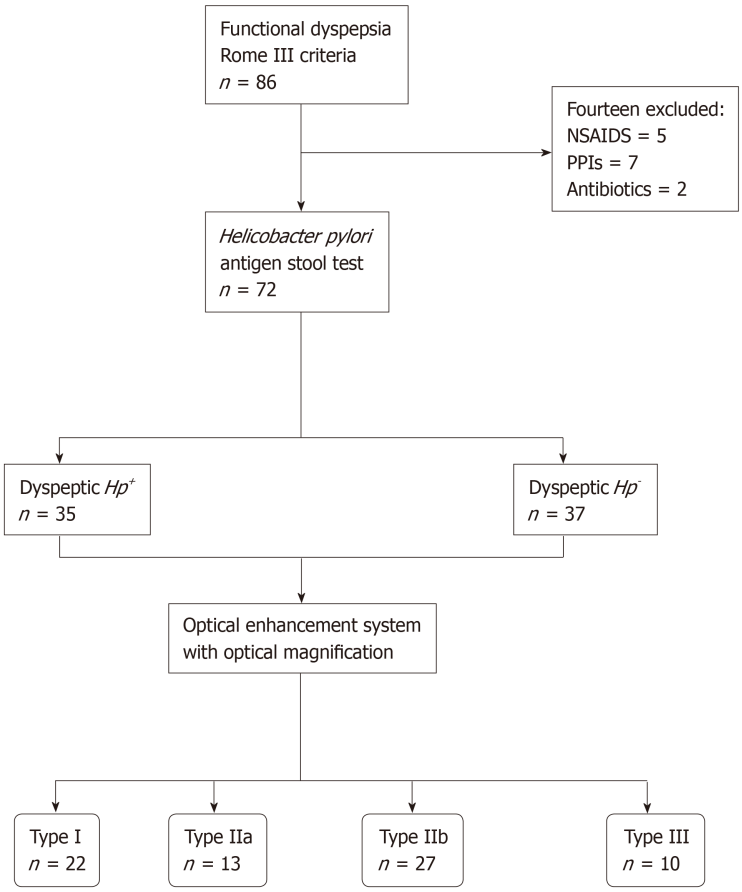

Figure 1 Flowchart showing the process of classification of the study participants. NSAIDs: Nonsteroidal anti-inflammatory drugs; PPIs: Proton-pump inhibitors; *Hp*: *Helicobacter pylori*.

previously seen with conventional endoscopy.

Microvascular-architecture patterns

The gastric body was chosen instead of the antrum for evaluation of the mucosa. The microvascular architecture of the normal stomach shows two distinct patterns depending on the region of the stomach. The gastric body has a honeycomb-like subepithelial capillary network (SECN) pattern with collecting venules, whereas the gastric antrum has a coil-shaped SECN pattern, where collecting venules lie in deeper layers and cannot be seen[14,15].

Endoscopic evaluation enabled classification of participants according to four patterns of microvascular architecture, on the basis of the combination of the SECN, collecting venules, and round pits[16]. The type I pattern consisted of a honeycomb-type SECN with a regular arrangement of collecting venules (RAC) and regular round pits; type IIa involved a honeycomb-type SECN with regular round pits, but with loss of collecting venules; the type IIb pattern consisted of enlarged white pits surrounded by erythema with loss of normal SECN and collecting venules; and the type III pattern involved loss of normal SECN and round pits, with irregular arrangements of collecting venules (Figure 2).

Endoscopic images were recorded, and biopsy samples were obtained to correlate the images with histological assessments. The biopsies were taken with regular biopsy forceps at random locations following the Sydney protocol (two from the gastric body, two from the antrum and one from the incisura angularis) in cases of type I pattern, with additional targeted biopsies from areas with type IIa, IIb, or III patterns[17]. The specimens were fixed immediately in 10% formalin solution, stained with hematoxylin–eosin for histopathological assessment, and stained with the Giemsa stain for *H. pylori* detection. Detection of *H. pylori* infection was performed by histology and by the *H. pylori* stool antigen test. A positive result with either of these tests was considered to indicate *H. pylori* infection. The pathologist was blinded to the endoscopic diagnosis.

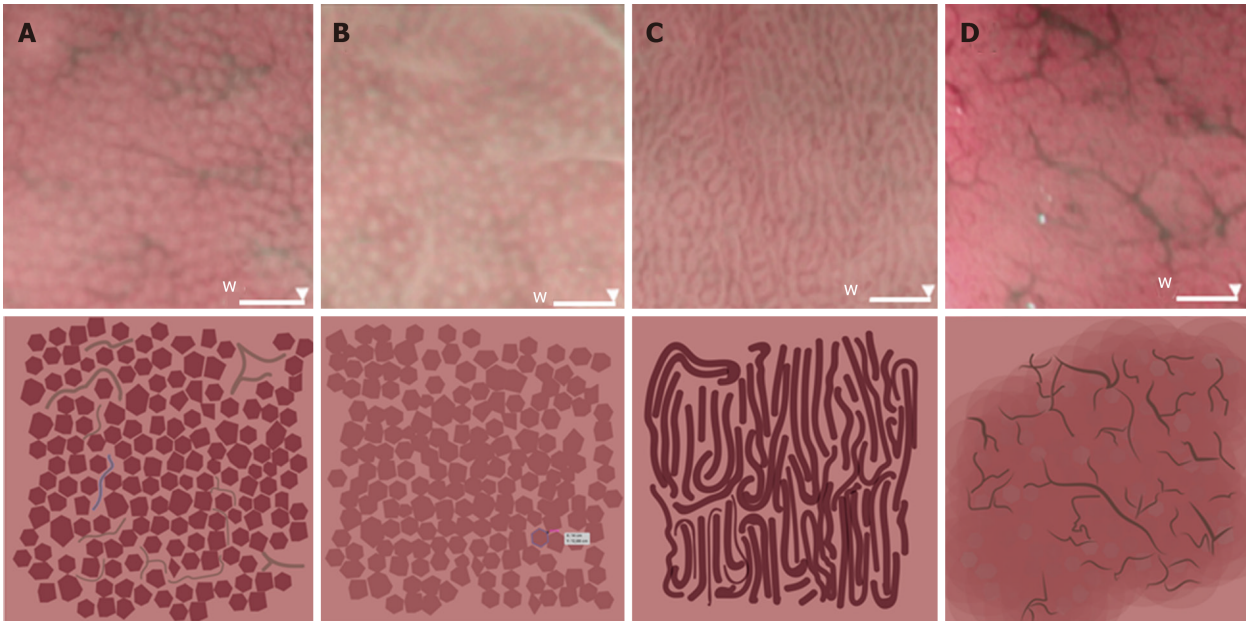

Figure 2 Four microvascular patterns identified by endoscopy of the gastric body mucosa. A: The type I pattern comprises a honeycomb-type subepithelial capillary network (SECN), with a regular arrangement of collecting venules and regular, round pits; B: The type IIa pattern comprises a honeycomb-type SECN with regular, round pits, but with loss of collecting venules; C: In the type IIb pattern, there is loss of the normal SECN and collecting venules, and the presence instead of enlarged white pits surrounded by erythema; D: The type III pattern is characterized by loss of the normal SECN and round pits, with irregular arrangement of the collecting venules.

Interobserver and intraobserver agreement

A dataset containing 60 photographs taking during the study of the gastric body was presented in a blinded manner to four endoscopists who were individually asked to classify the photographs according to the four microvascular patterns at three time points, each 1 wk apart. At each evaluation, the same photographs were shown to the endoscopists in a different order. The four endoscopists were trained to evaluate the four patterns. Interobserver agreement was assessed by comparison of the photographic analyses by each endoscopist (Alvarado-Escobar H, Puga-Tejada M, Oleas R, and Baquerizo-Burgos J), and intraobserver agreement was assessed by comparison of the photographic analysis by each endoscopist at each time point.

Statistical analysis

The statistical review of the study was performed by a biomedical statistician. The baseline characteristics of Hp^+ and Hp^- patients were compared by Pearson's chi-square or Fisher's exact tests for categorical variables and the Mann-Whitney *U*-test for continuous variables. Continuous variables are expressed as the mean (standard deviation) or median (interquartile range), according to their statistical distribution. Categorical variables are presented as percentages. The sensitivity, specificity, predictive values, and accuracy of the endoscopic findings for normal gastric mucosa, *H. pylori* infection, and gastric atrophy were calculated with 95% CIs. For interobserver and intraobserver agreement, kappa values were calculated[18]. Kappa coefficients < 0.4 indicated "poor agreement", values of 0.4-0.8 represented "moderate-to-good agreement", and values > 0.8 indicated "excellent agreement". A P value < 0.05 was considered statistically significant. Data analysis was performed using R v3.4.3 (R Foundation for Statistical Computing, Vienna, Austria).

RESULTS

The sample-size calculation indicated that the study required at least 68 patients. Of the 72 participants who were enrolled, 35 (48.6%) were dyspeptic Hp^+ and 37 (51.4%) were dyspeptic Hp^-. Histopathology and the *H. pylori* stool antigen test showed 100% agreement for diagnosis of *H. pylori* infection. There were no significant differences between Hp^+ and Hp^- groups in terms of age (mean 46.3 ± 13.7 years), sex (69.4% female), or primary symptom (58.3% epigastric pain) (Table 1).

Endoscopic images were analyzed and patients were classified following agreement among endoscopists (Robles-Medranda C, Valero M, and Soria-Alcívar M), into type I (30.6%), type II 55.6%, and type III (13.9%). We compared distribution of

Table 1 Baseline demographic data of study participants, who had functional dyspepsia, according to *Helicobacter pylori* infection status

	Total (*n* = 72)	*Hp*⁺ (*n* = 35)	*Hp*⁻ (*n* = 37)	*P* value
Sex (female), *n* (%)	50 (69.4)	27 (77.1)	23 (62.1)	0.168[1]
Age (yr), mean ± SD	46.3 ± 13.7	43.3 ± 13.5	49.1 ± 13.5	0.075[2]
Symptoms, *n* (%)				0.512[1]
Epigastric pain syndrome	42 (58.3)	21 (60.0)	21 (56.8)	
Postprandial distress syndrome	14 (19.4)	5 (14.3)	9 (24.3)	
Both	16 (22.2)	9 (25.7)	7 (18.9)	
Endoscopic classification, *n* (%)				< 0.001[1]
Type I	22 (30.6)	3 (8.6)	19 (51.4)	
Type IIa and IIb	40 (55.6)	32 (91.4)	8 (21.6)	
Type III	10 (13.9)	0	10 (27.0)	

[1]Pearson's chi-square test;
[2]Student's *t*-test. *Hp*: *Helicobacter pylori*; SD: Standard deviation.

patients according to the microvascular types with distribution according to histopathology and *H. pylori*-infection results. Among the 10 individuals with normal mucosal histology, 90% were type I (Table 2). The type I pattern was also present in three individuals with chronic active gastritis and 10 with chronic inactive gastritis. Most individuals with type IIa and type IIb patterns (10 out of 13 and 21 out of 27, respectively) had chronic active gastritis, and similar numbers were *Hp*+. Notably, 32 of the 35 *Hp*⁺ individuals (91.5%) were Type IIa–IIb. Only three individuals had gastric atrophy identified by histology; one with type IIb microvascular pattern and two (66.7%) with type III pattern. Eight of the 10 individuals with a type III pattern had chronic inactive gastritis, and two exhibited gastric atrophy, but none of them were *Hp*+.

Predictive performance of the microvascular patterns was calculated (Table 3). The type I pattern was predictive of normal mucosa, with sensitivity of 90.0% and accuracy of 80.5%. The presence of a type IIa or type IIb pattern was predictive of *H. pylori* infection, with sensitivity of 91.4% and accuracy of 84.7%. The type III pattern predicted gastric atrophy with a sensitivity 66.7% and accuracy of 87.5%. For assessment of the three endoscopic patterns, interobserver agreement had a kappa value of 0.89 (95%CI: 0.84-0.93) and intraobserver agreement had a kappa value of 0.91 (95%CI: 0.85-0.96).

DISCUSSION

In the present study of individuals with dyspepsia, 90% of those with histologically normal gastric mucosa had the type I microvascular pattern on endoscopy and were *Hp*−, 91.5% of *Hp*+ participants had the type IIa or type IIb pattern, and of the three individuals with gastric atrophy on histology, two had the type III pattern on endoscopy. Identification of these microvascular patterns with the OE System with optical magnification enabled prediction of normal gastric mucosa or *H. pylori*-associated gastritis with high sensitivity and accuracy, with excellent interobserver and intraobserver agreement.

In recent decades, the role of upper endoscopy in the real-time identification of *H. pylori* infection of the stomach and gastric atrophy has been evaluated. Initially, studies that were designed to determine whether there was a relationship between endoscopic features and *H. pylori*-induced gastritis used white-light endoscopy[8,19-21]. The results of these studies showed that some endoscopic features related to *H. pylori* infection were difficult to distinguish from non-*H. pylori* gastritis and were not specific[8,21]. Additionally, prediction of gastric atrophy through endoscopic signs such as the absence of gastric folds and the presence of visible vessels had low sensitivity (67%) and specificity (48%)[22]. These results suggested that *H. pylori* infection and gastric atrophy can be suspected, but not confirmed, by endoscopy alone, and that histology is needed for a definitive diagnosis[8,9].

The reliability of detection of *H. pylori* infection or gastric atrophy by histology depends on the location, number, and size of the gastric biopsies, but considerable sampling errors can occur during endoscopic biopsy sampling. Advances in

Table 2 Distribution of microvascular-pattern types according to histopathology and *Helicobacter pylori* infection

		Classification, *n* (%)			
		Type I (*n* = 22)	Type IIa and IIb (*n* = 40)	Type III (*n* = 10)	*P* value
Histopathology	Normal	9 (40.9)	1 (2.5)	0	< 0.001[1]
	CAG	3 (13.6)	31 (77.5)	0	
	CIG	10 (45.5)	7 (17.5)	8 (80.0)	
	Atrophy	0	1 (2.5)	2 (20.0)	
Helicobacter pylori infection	Positive	3 (13.6)	32 (80.0)	0	< 0.001[1]
	Negative	19 (86.4)	8 (20.0)	10 (100.0)	

[1]Pearson's chi-square test. CAG: Chronic active gastritis; CIG: Chronic inactive gastritis.

magnification technology have made it possible to determine endoscopically whether patients have *H. pylori* infection. The blood-vessel network in the surface layer of the gastric body has been shown endoscopically to be associated with previous histopathology findings[23]. Normal gastric-body mucosal microvascular architecture consists of a honeycomb-type SECN and collecting venules in a regular arrangement[24,25]. The presence and regular distribution of numerous red spots (collecting venules) in the gastric body have been shown to indicate a stomach with no *H. pylori* infection[14,26-29]. The RAC as an endoscopic feature has been shown to have sensitivity, specificity, and accuracy for identification of an *Hp*− stomach of 93.8%, 96.2%, and 95.5%, respectively, with RAC-negative findings having an accuracy of 95% for identification of *H. pylori* infection[30]. In the current study, RAC positivity (a type I microvascular pattern) had a sensitivity, specificity, and accuracy to predict *Hp*− of 90%, 79%, and 80.5%, respectively, and RAC negativity (a type IIa or type IIb pattern) had a sensitivity, specificity, and accuracy to predict *Hp*+ of 91.4%, 78.3%, and 84.7%, respectively.

Nakagawa *et al*[31] evaluated the association of patterns of collecting venules (regular, irregular, or obscured) with *H. pylori* infection and histopathological gastritis. The presence of a regular pattern of collecting venules in the gastric mucosa was shown to indicate an absence of *H. pylori* infection, which suggests that a biopsy is unnecessary. Conversely, observation of an obscure or irregular pattern was shown to indicate *H. pylori* infection, with the irregular pattern suggesting the presence of severe gastric mucosal atrophy[31].

The endoscopic classification that we used was based on a previous evaluation of the gastric body by magnified white-light endoscopy[16]. Here, the use of the OE System with optical magnification improved the identification of mucosal superficial and vascular patterns and made it easier to classify images, thereby improving interobserver agreement (0.89 *vs* 0.73). In the previous study, type I and type II/III sensitivities for prediction of normal mucosa and *H. pylori*-related gastritis (92.7% and 100%) were similar to our findings (90% and 91.4% for type IIa and IIb, respectively). However, the type IV pattern sensitivity for prediction of gastric atrophy was 90% with white-light endoscopy compared with 66% (type III) with the OE System, although this difference could be explained by the greater number of individuals with the type IV pattern in the previous study compared with the current study (21 *vs* 10)[16].

The present investigation had some limitations. First, the use of the magnified OE System with optical magnification for these indications has not been studied systematically, and there is a learning curve in obtaining and interpreting the images. This was a small, single-center study, and further investigations with multiple endoscopists are needed. Neither the severity of gastritis nor the degree of endoscopic gastric mucosal atrophy was evaluated. The sample size of patients with gastric atrophy was small. Finally, intake of NSAIDs and PPIs in the three weeks preceding the study was considered an exclusion criterion in our study, to avoid bias and an incorrect interpretation.

Our results demonstrate the potential of the OE System with optical magnification to enable the identification of histopathological changes in the gastric mucosa. In this study, the reproducibility of the classification was excellent. High-definition optical magnification and digital chromoendoscopy exhibited high accuracy for the diagnosis of normal gastric mucosa and *H. pylori*-associated gastritis, with lower accuracy for the evaluation of gastric atrophy. Clinical practice experience needs to be further tested in order to determine the applicability of these techniques in defining chronic

Table 3 Predictive performance of the endoscopic microvascular patterns

	Sensitivity, % (95%CI)	Specificity, % (95%CI)	PPV, % (95%CI)	NPV, % (95%CI)	Accuracy, %
Type I[1]	90.0 (55.5-99.8)	79.0 (66.8-88.3)	40.9 (20.7-63.7)	90.0 (89.4-99.9)	80.5
Type IIa–IIb[2]	91.4 (76.9-98.2)	78.4 (61.8-90.2)	80.0 (64.4-90.9)	90.6 (74.9-98.0)	84.7
Type III[3]	66.7 (9.4-99.2)	88.4 (78.4-94.9)	20.0 (2.5-55.6)	98.4 (91.3-99.9)	87.5

[1]Ability to predict histologically normal mucosa;
[2]Ability to predict *Helicobacter pylori* infection;
[3]Ability to predict mucosal atrophy. CI: Confidence interval; NPV: Negative predictive value; PPV: Positive predictive value.

active gastritis and *H. pylori* infection. In order to validate our results, the optical enhancement with magnification technologies should be evaluated in randomized, controlled trials. In addition, further studies are needed to determine whether endoscopic diagnosis of gastric atrophy is feasible.

ARTICLE HIGHLIGHTS

Research background

Helicobacter pylori (*H. pylori*) infection and atrophic gastritis are linked to gastric carcinogenesis. The endoscopic diagnosis of *H. pylori* infection and gastric atrophy is challenging, requiring histological confirmation; however, sampling errors might occur.

Research motivation

Digital chromoendoscopy with optical magnification improved the identification of mucosal superficial and vascular patterns in the gastric mucosa and might provide a more accurate endoscopic visual impression of the gastric mucosa.

Research objectives

The main objective of the study was to evaluate digital chromoendoscopy with optical magnification for the diagnosis of normal gastric mucosa, *H. pylori* associated gastritis and atrophic gastritis.

Research methods

This was a cross-sectional, nonrandomized, single-center study in which consecutive patients with functional dyspepsia were evaluated *via* esophagogastroduodenoscopy using a high definition endoscope with digital chromoendoscopy and optical magnification for the endoscopic diagnosis of *H. pylori* associated gastritis and atrophic gastritis. The endoscopic visual impression was compared to *H. pylori* stool antigen test and histological analysis.

Research results

We described a high sensitivity and accuracy for predicting normal gastric mucosa and *H. pylori* associated gastritis, with a high inter and intraobserver agreement. Atrophic gastritis was detected with a low sensitivity, and further studies are required to determine if endoscopic diagnosis of atrophic gastritis is feasible.

Research conclusions

In our study, esophagogastroduodenoscopy with digital chromoendoscopy and optical magnification enable the identification of histological changes in the gastric mucosa of consecutive patients with functional dyspepsia.

Research perspectives

We encourage a randomized multicenter trial evaluating high definition white light endoscopy versus digital chromoendoscopy with optical magnification for the evaluation of the gastric mucosa of dyspeptic patients, in order to determine the clinical practice applicability of these techniques. Further studies are needed to determine if endoscopic diagnosis of atrophic gastritis is feasible.

REFERENCES

1 **Huang JQ**, Sridhar S, Chen Y, Hunt RH. Meta-analysis of the relationship between Helicobacter pylori seropositivity and gastric cancer. *Gastroenterology* 1998; **114**: 1169-1179 [PMID: 9609753 DOI: 10.1016/s0016-5085(98)70422-6]

2 **NIH Consensus Conference**. Helicobacter pylori in peptic ulcer disease. NIH Consensus Development Panel on Helicobacter pylori in Peptic Ulcer Disease. *JAMA* 1994; **272**: 65-69 [PMID: 8007082 DOI: 10.1001/jama.272.1.65]

3 **Parsonnet J**, Friedman GD, Vandersteen DP, Chang Y, Vogelman JH, Orentreich N, Sibley RK.

Helicobacter pylori infection and the risk of gastric carcinoma. *N Engl J Med* 1991; **325**: 1127-1131 [PMID: 1891020 DOI: 10.1056/NEJM199110173251603]
4 **Forman D**, Newell DG, Fullerton F, Yarnell JW, Stacey AR, Wald N, Sitas F. Association between infection with Helicobacter pylori and risk of gastric cancer: evidence from a prospective investigation. *BMJ* 1991; **302**: 1302-1305 [PMID: 2059685 DOI: 10.1136/bmj.302.6788.1302]
5 **Uemura N**, Okamoto S, Yamamoto S, Matsumura N, Yamaguchi S, Yamakido M, Taniyama K, Sasaki N, Schlemper RJ. Helicobacter pylori infection and the development of gastric cancer. *N Engl J Med* 2001; **345**: 784-789 [PMID: 11556297 DOI: 10.1056/NEJMoa001999]
6 **Correa P**. Human gastric carcinogenesis: a multistep and multifactorial process--First American Cancer Society Award Lecture on Cancer Epidemiology and Prevention. *Cancer Res* 1992; **52**: 6735-6740 [PMID: 1458460]
7 **Whiting JL**, Sigurdsson A, Rowlands DC, Hallissey MT, Fielding JW. The long term results of endoscopic surveillance of premalignant gastric lesions. *Gut* 2002; **50**: 378-381 [PMID: 11839718 DOI: 10.1136/gut.50.3.378]
8 **Bah A**, Saraga E, Armstrong D, Vouillamoz D, Dorta G, Duroux P, Weber B, Froehlich F, Blum AL, Schnegg JF. Endoscopic features of Helicobacter pylori-related gastritis. *Endoscopy* 1995; **27**: 593-596 [PMID: 8608753 DOI: 10.1055/s-2007-1005764]
9 **Calabrese C**, Di Febo G, Brandi G, Morselli-Labate AM, Areni A, Scialpi C, Biasco G, Miglioli M. Correlation between endoscopic features of gastric antrum, histology and Helicobacter pylori infection in adults. *Ital J Gastroenterol Hepatol* 1999; **31**: 359-365 [PMID: 10470592 DOI: 10.1016/S1386-6346(99)00015-7]
10 **Spence AD**, Cardwell CR, McMenamin ÚC, Hicks BM, Johnston BT, Murray LJ, Coleman HG. Adenocarcinoma risk in gastric atrophy and intestinal metaplasia: A systematic review. *BMC Gastroenterol* 2017; **17**: 157 [PMID: 29228909 DOI: 10.1186/s12876-017-0708-4]
11 **Neumann H**, Fujishiro M, Wilcox CM, Mönkemüller K. Present and future perspectives of virtual chromoendoscopy with i-scan and optical enhancement technology. *Dig Endosc* 2014; **26** Suppl 1: 43-51 [PMID: 24373000 DOI: 10.1111/den.12190]
12 **Tongtawee T**, Kaewpitoon S, Kaewpitoon N, Dechsukhum C, Loyd RA, Matrakool L. Correlation between Gastric Mucosal Morphologic Patterns and Histopathological Severity of Helicobacter pylori Associated Gastritis Using Conventional Narrow Band Imaging Gastroscopy. *Biomed Res Int* 2015; **2015**: 808505 [PMID: 26120585 DOI: 10.1155/2015/808505]
13 **Drossman DA**. The functional gastrointestinal disorders and the Rome III process. *Gastroenterology* 2006; **130**: 1377-1390 [PMID: 16678553 DOI: 10.1053/j.gastro.2006.03.008]
14 **Yagi K**, Nakamura A, Sekine A, Goto T. Endoscopic features of the normal gastric mucosa without Helicobacter pylori infection. *Gastroenterol Endosc* 2000; **42**: 1977-1987
15 **Yao K**. Gastric microvascular architecture as visualized by magnifying endoscopy: body and antral mucosa without pathologic change demonstrate two different patterns of microvascular architecture. *Gastrointest Endosc* 2004; **59**: 596-7; author reply 597 [PMID: 15044912 DOI: 10.1016/s0016-5107(03)02825-6]
16 **Anagnostopoulos GK**, Yao K, Kaye P, Fogden E, Fortun P, Shonde A, Foley S, Sunil S, Atherton JJ, Hawkey C, Ragunath K. High-resolution magnification endoscopy can reliably identify normal gastric mucosa, Helicobacter pylori-associated gastritis, and gastric atrophy. *Endoscopy* 2007; **39**: 202-207 [PMID: 17273960 DOI: 10.1055/s-2006-945056]
17 **Dixon MF**, Genta RM, Yardley JH, Correa P. Classification and grading of gastritis. The updated Sydney System. International Workshop on the Histopathology of Gastritis, Houston 1994. *Am J Surg Pathol* 1996; **20**: 1161-1181 [PMID: 8827022 DOI: 10.1097/00000478-199610000-00001]
18 **Landis JR**, Koch GG. The measurement of observer agreement for categorical data. *Biometrics* 1977; **33**: 159-174 [PMID: 843571 DOI: 10.2307/2529310]
19 **Laine L**, Cohen H, Sloane R, Marin-Sorensen M, Weinstein WM. Interobserver agreement and predictive value of endoscopic findings for H. pylori and gastritis in normal volunteers. *Gastrointest Endosc* 1995; **42**: 420-423 [PMID: 8566631 DOI: 10.1016/s0016-5107(95)70043-9]
20 **Mond DJ**, Pochaczevsky R, Vernace F, Bank S, Chow KW. Can the radiologist recognize Helicobacter pylori gastritis? *J Clin Gastroenterol* 1995; **20**: 199-202 [PMID: 7797826 DOI: 10.1097/00004836-199504000-00007]
21 **Yela MC**, Manzano ML, Rodríguez-Muñoz S, Sánchez F, Pérez-Carreras M, Sánchez-Pobre P, Garfia P, Castellano G. Assessment of the usefulness of endoscopic signs in Helicobacter pylori associated gastritis. *Rev Esp Enferm Dig* 1997; **89**: 3-12 [PMID: 9055583 DOI: 10.1097/00006676-199701000-00019]
22 **Redéen S**, Petersson F, Jönsson KA, Borch K. Relationship of gastroscopic features to histological findings in gastritis and Helicobacter pylori infection in a general population sample. *Endoscopy* 2003; **35**: 946-950 [PMID: 14606018 DOI: 10.1055/s-2003-43479]
23 **Tsuchihashi Y**, Tani T, Maruyama K, Yorioka S, Okada K, Sudo H, Ashihara T, Fujita S, Kawai K, Manabe H, Zweifach BW, Messmer K. Structural alterations of mucosal microvascular system in human chronic gastritis. Microcirculation in circulatory disorders. Manabe H, Zweifach BW, Messmer K. Tokyo: Springer 1988; 161-169
24 **Yao K**, Oishi T, Matsui T, Yao T, Iwashita A. Novel magnified endoscopic findings of microvascular architecture in intramucosal gastric cancer. *Gastrointest Endosc* 2002; **56**: 279-284 [PMID: 12145613 DOI: 10.1016/s0016-5107(02)70194-6]
25 **Yao K**, Tatsuhiro O. Microgastroscopic findings of mucosal microvascular architecture as visualized by magnifying endoscopy. Novel magnified endoscopic findings of microvascular architecture in intramucosal gastric cancer. *Dig Endosc* 2001; **13**: 27-33 [DOI: 10.1111/j.1443-1661.2001.00114.x]
26 **Yagi K**, Nakamura A, Sekine A. Characteristic endoscopic and magnified endoscopic findings in the normal stomach without Helicobacter pylori infection. *J Gastroenterol Hepatol* 2002; **17**: 39-45 [PMID: 11895551 DOI: 10.1046/j.1440-1746.2002.02665.x]
27 **Yagi K**, Nakamura A, Sekine A. Comparison between magnifying endoscopy and histological, culture and urease test findings from the gastric mucosa of the corpus. *Endoscopy* 2002; **34**: 376-381 [PMID: 11972268 DOI: 10.1055/s-2002-25281]
28 **Yagi K**, Honda H, Yang JM, Nakagawa S. Magnifying endoscopy in gastritis of the corpus. *Endoscopy* 2005; **37**: 660-666 [PMID: 16010611 DOI: 10.1055/s-2005-861423]
29 **Yagi K**, Nakamura A, Sekine A. Magnifying endoscopy of the gastric body: a comparison of the findings before and after Helicobacter pylori eradication. *Dig Endosc* 2002; **14**: 76-82 [DOI: 10.1046/j.1443-1661.14.s1.10.x]

30 **Yagi K**, Aruga Y, Nakamura A, Sekine A. Regular arrangement of collecting venules (RAC): a characteristic endoscopic feature of Helicobacter pylori-negative normal stomach and its relationship with esophago-gastric adenocarcinoma. *J Gastroenterol* 2005; **40**: 443-452 [PMID: 15942708 DOI: 10.1007/s00535-005-1605-0]

31 **Nakagawa S**, Kato M, Shimizu Y, Nakagawa M, Yamamoto J, Luis PA, Kodaira J, Kawarasaki M, Takeda H, Sugiyama T, Asaka M. Relationship between histopathologic gastritis and mucosal microvascularity: observations with magnifying endoscopy. *Gastrointest Endosc* 2003; **58**: 71-75 [PMID: 12838224 DOI: 10.1067/mge.2003.316]

World Journal of Gastrointestinal Endoscopy

Submit a Manuscript: https://www.f6publishing.com

World J Gastrointest Endosc 2020 January 16; 12(1): 33-41

DOI: 10.4253/wjge.v12.i1.33

ISSN 1948-5190 (online)

ORIGINAL ARTICLE

Observational Study

Endoscopic removal of foreign bodies: A retrospective study in Japan

Kenji JL Limpias Kamiya, Naoki Hosoe, Kaoru Takabayashi, Yukie Hayashi, Xi Sun, Ryoichi Miyanaga, Kayoko Fukuhara, Seiichiro Fukuhara, Makoto Naganuma, Atsushi Nakayama, Motohiko Kato, Tadateru Maehata, Rieko Nakamura, Koichi Ueno, Junichi Sasaki, Yuko Kitagawa, Naohisa Yahagi, Haruhiko Ogata, Takanori Kanai

ORCID number: Kenji JL Limpias Kamiya (0000-0001-9449-5910); Naoki Hosoe (0000-0002-4516-5648); Kaoru Takabayashi (0000-0002-4891-8246); Yukie Hayashi (0000-0002-3777-2261); Xi Sun (0000-0002-4271-0102); Ryoichi Miyanaga (0000-0001-9625-2195); Kayoko Fukuhara (0000-0002-0428-8502); Seiichiro Fukuhara (0000-0003-1675-5670); Makoto Naganuma (0000-0002-4244-3243); Atsushi Nakayama (0000-0001-7513-1767); Motohiko Kato (0000-0002-7579-1316); Tadateru Maehata (0000-0003-4279-0138); Rieko Nakamura (0000-0003-0947-6358); Koichi Ueno (0000-0002-4076-2873); Junichi Sasaki (0000-0002-5190-8524); Yuko Kitagawa (0000-0002-0271-5670); Naohisa Yahagi (0000-0002-9597-4750); Haruhiko Ogata (0000-0002-3304-3635); Takanori Kanai (0000-0002-1466-4532).

Author contributions: All authors helped to perform the research; Hosoe N, Takabayashi K, Hayashi Y, Sun X, Miyanaga R, Fukuhara K, Fukuhara S, Naganuma M, Nakayama A, Kato M, Maehata T, Nakamura R, Ueno K, Sasaki J, Kitagawa Y, Yahagi N, Ogata H, and Kanai T contributed to drafting conception; Limpias Kamiya KJL, Hosoe N, Takabayashi K, Hayashi Y, Sun X, Miyanaga R, Fukuhara K, Fukuhara S, Naganuma M,

Kenji JL Limpias Kamiya, Yukie Hayashi, Ryoichi Miyanaga, Makoto Naganuma, Takanori Kanai, Division of Gastroenterology and Hepatology, Department of Internal Medicine, Keio University School of Medicine, Tokyo 160-8582, Japan

Naoki Hosoe, Kaoru Takabayashi, Xi Sun, Kayoko Fukuhara, Seiichiro Fukuhara, Haruhiko Ogata, Center for Diagnostic and Therapeutic Endoscopy, Keio University School of Medicine, Tokyo 160-8582, Japan

Xi Sun, Department of Gastroenterology and Hepatology, Chinese PLA General Hospital, Beijing 100853, China

Atsushi Nakayama, Motohiko Kato, Tadateru Maehata, Naohisa Yahagi, Division of Research and Development for Minimally Invasive Treatment, Cancer Center, Keio University School of Medicine, Tokyo 160-8582, Japan

Rieko Nakamura, Yuko Kitagawa, Department of Surgery, Keio University School of Medicine, Tokyo 160-8582, Japan

Koichi Ueno, Junichi Sasaki, Department of Emergency and Critical Care Medicine, Keio University School of Medicine, Tokyo 160-8582, Japan

Corresponding author: Naoki Hosoe, FACG, MD, PhD, Associate Professor, Center for Diagnostic and Therapeutic Endoscopy, Keio University School of Medicine, 35 Shinanomachi, Shinjuku, Tokyo 160-8582, Japan. nhosoe@z5.keio.jp

Abstract

BACKGROUND

The ingestion of foreign bodies (FBs) and food bolus impaction (FBI) in the digestive tract are commonly encountered clinical problems. Methods to handle such problems continue to evolve offering advantages, such as the avoidance of surgery, reduced cost, improved visualization, reduced morbidity, and high removal success rate. However, to date, no studies have evaluated the endoscopic management of FBs in Japan.

AIM

To elucidate level of safety and efficacy in the endoscopic management of FBs and FBI.

Nakayama A, Kato M, Maehata T, Nakamura R, Ueno K, Sasaki J, Kitagawa Y, Yahagi N, Ogata H, and Kanai T contribution to design; Limpias Kamiya KJL, Hosoe N, Sasaki J, Kitagawa Y, Yahagi N, Ogata H, and Kanai T contribution to writing the manuscript; Limpias Kamiya KJL and Hosoe N performed procedures and analyzed the data; Takabayashi K, Hayashi Y, Sun X, Miyanaga R, Fukuhara K, Fukuhara S, Naganuma M, Nakayama A, Kato M, Maehata T, Nakamura R, and Ueno K contributed to performing the endoscopy.

Institutional review board statement: The present observational study was reviewed and approved by the ethics committee of Keio University Hospital (approval ID 20180281).

Informed consent statement: Patients were not required to give informed consent to the study because the analysis used anonymous clinical data that were obtained after each patient agreed to treatment by written consent.

Conflict-of-interest statement: All authors disclosed no financial conflict of interest relevant to this publication.

STROBE statement: The authors have read the Strobe statement-checklist of items, and the manuscript was prepared according to the Strobe statement.

Manuscript source: Invited manuscript

Received: June 24, 2019
Peer-review started: June 26, 2019
First decision: August 2, 2019
Revised: August 9, 2019
Accepted: November 18, 2019
Article in press: November 18, 2019
Published online: January 16, 2020

P-Reviewer: Doyle JJ, Farhat S, Nijhawan S
S-Editor: Yan JP

METHODS
A total of 215 procedures were performed at Keio University Hospital between November 2007 and August 2018. Data were collected from medical charts, and endoscopic details were collected from an endoscopic reporting system. Procedures performed with a flexible gastrointestinal endoscope were only taken into account. Patients who underwent a technique involving FB or FBI from the digestive tract were only included. Data on patient sex, patient age, outpatient, inpatient, FB type, FB location, procedure time, procedure type, removal device type, success, and technical complications were reviewed and analyzed retrospectively.

RESULTS
Among the 215 procedures, 136 (63.3%) were performed in old adults (≥ 60 years), 180 (83.7%) procedures were performed in outpatients. The most common type of FBs were press-through-pack (PTP) medications [72 (33.5%) cases], FBI [47 (21.9%)], Anisakis parasite (AP) [41 (19.1%) cases]. Most FBs were located in the esophagus [130 (60.5%) cases] followed by the stomach [68 (31.6%) cases]. AP was commonly found in the stomach [39 (57.4%) cases], and it was removed using biopsy forceps in 97.5% of the cases. The most common FBs according to anatomical location were PTP medications (40%) and dental prostheses (DP) (40%) in the laryngopharynx, PTP (48.5%) in the esophagus, AP (57.4%) in the stomach, DP (37.5%) in the small intestine and video capsule endoscopy device (75%) in the colon. A transparent cap with grasping forceps was the most commonly used device [82 (38.1%) cases]. The success rate of the procedure was 100%, and complication were observed in only one case (0.5%).

CONCLUSION
Endoscopic management of FBs and FBI in our Hospital is extremely safe and effective.

Key words: Anisakis parasite; Endoscopic removal; Food bolus impaction; Foreign body; Grasping forceps

Core tip: The present study highlights the level of efficacy and safety in the removal of foreign bodies in Japan, using different devices avoiding any type of lesion of the digestive tract. Extractions of foreign body using flexible endoscopy were enrolled in the analysis. Press-through-pack medications was the most common FB, as it is commonly used in Japan. We used a large caliber soft oblique cap and grasping forceps and there was no complication in any of the cases. The level of safety and efficacy were excellent, therefore we recommend using devices used in this study.

Citation: Limpias Kamiya KJ, Hosoe N, Takabayashi K, Hayashi Y, Sun X, Miyanaga R, Fukuhara K, Fukuhara S, Naganuma M, Nakayama A, Kato M, Maehata T, Nakamura R, Ueno K, Sasaki J, Kitagawa Y, Yahagi N, Ogata H, Kanai T. Endoscopic removal of foreign bodies: A retrospective study in Japan. *World J Gastrointest Endosc* 2020; 12(1): 33-41
URL: https://www.wjgnet.com/1948-5190/full/v12/i1/33.htm
DOI: https://dx.doi.org/10.4253/wjge.v12.i1.33

INTRODUCTION

The ingestion of foreign bodies (FBs) and food bolus impaction (FBI) are common problems in clinical practice globally. Pre-endoscopic series have shown that ≥ 80% of FBs are likely to pass without requiring intervention, 10%-20% will require non-operative intervention, and ≤ 1% will require surgery[1-6]. The ingestion of FBs mainly occurs in the pediatric population, with a peak incidence between 6 mo and 6 years of age[7]. Among adults, it occurs more commonly in those with psychiatric disorders, alcohol intoxication, and mental retardation and in incarcerated individuals looking for another opportunity to be sent to a medical facility[8]. Edentulous adults are also at risk of the ingestion of FBs, including their own dental prostheses (DP), and FBI[1].

L-Editor: A
E-Editor: Ma YJ

Since the first report in 1972 on the removal of a FB using a flexible endoscope by McKechnie *et al*[9], this method has continued to evolve owing to its advantages, such as surgery avoidance, reduced cost, accessible technical facilities, visualization improvement, reduced morbidity, and high removal success rate (> 95%)[1,10] as well as the possibility of diagnosis of other diseases. However, to the best of our knowledge, currently, there are no reports on the endoscopic management of FBs and FBIs in Japan.

MATERIALS AND METHODS

Study design

The present observational study was conducted at the Center for Diagnostic and Therapeutic Endoscopy of Keio University Hospital and was approved by the ethics committee of Keio University Hospital (approval ID 20180281). The study included the data of patients with a history of FB ingestion or FBI who underwent endoscopic therapy at Keio University Hospital between November 2007 and August 2018. Data were collected from medical records, and endoscopic details were collected through an endoscopic reporting system (Solemio ENDO, Olympus, Tokyo, Japan). Only procedures performed with a flexible gastrointestinal endoscope were considered. Additionally, only patients who underwent a technique involving FBs or FBI removal from the digestive tract were included. Patients who underwent a technique involving pushing of the FBI into the stomach without posterior removal were excluded. The following data were extracted: (1) Sex; (2) Age; (3) Outpatient or inpatient; (4) FB type; (5) FB location (laryngopharynx, esophagus, stomach, small intestine, or colon); (6) FB type according to anatomical location; (7) Procedure time; (8) Procedure type [esophagogastroduodenoscopy (EGD), colonoscopy (CS), or single-balloon enteroscopy (SBE)]; (9) Extraction device type; (10) Most used devices according to FB type; and (11) Success and technical complications. According to age, patients were divided into the following four groups: Children (< 15 years old), youth and adults (15-59 years old), old adults (60-79 years old), and very old adults (> 79 years old). FBs that were not very frequent were categorized as "others" (catheters, toothpicks, coins, cotton swabs, packs of illegal drugs, feces, shells, staples, stents, and vinyl). Procedure time was considered as the time required for removal of the FBs or FBI, which was calculated from the insertion of the flexible endoscope to complete extraction of the FB or FBI, including resolution of complications. With regard to the extraction device, we considered all devices used for the removal of the FB or FBI and for the protection of the digestive tract, including devices that were used in combination. Technical complications were considered as complications involving deep laceration, perforation, or bleeding of the mucosa that required additional procedures to achieve hemostasis. In this study, we did not take into account lacerations that showed slight bleeding, in which hemostasis occurred naturally. Procedure success was considered as complete removal of the FB or FBI from the digestive tract, with subsequent confirmation of absence of the FB or FBI on assessment of the digestive tract.

Statistical analysis

Categorical data are expressed as number and percentage (%), and the procedure duration was calculated as mean with standard deviation (SD) expressed in minutes. All statistical analyses were performed using IBM SPSS software, version 24.0 (IBM Corp., Armonk, NY, United States).

RESULTS

Patient background

A total of 215 procedures were performed between November 2007 and August 2018. Patient background data are presented in Table 1. Of the 215 procedures, 106 (49.3%) were performed in male patients and 109 (50.7%) were performed in female patients. With regard to age, 2 (1%) procedures were performed in children, 77 (36%) were performed in youth and adults, 109 (51%) were performed in old adults, and 27 (12%) were performed in very old adults. Additionally, 180 (83.7%) procedures were performed in outpatients and 35 (16.3%) in inpatients.

Foreign body type and location

Data on FB type are presented in Table 2. In this study, the most common FB was press-trough-pack (PTP) medications [72 (33.5%) cases], followed by FBI [47 (21.9%) cases], Anisakis parasite (AP) [41 (19.1%) cases], DP [23 (10.7%) cases], fish bone [9

Table 1 Patient background

	Number of patients (%)
Sex (male/female)	106 (49.3)/109 (50.7)
Age group	
< 15 yr	2 (0.9)
15-59 yr	77 (35.8)
60-79 yr	109 (50.7)
> 79 yr	27(12.6)
Outpatient/inpatient	180 (83.7)/35 (16.3)

(4.2%) cases], endoscopic video capsule device (VCE) [7 (3.3%) cases], spoon [3 (1.4%) cases], and others [13 (6.0%) cases]. On the other hand, the most common location was the esophagus [130 (60.5%) cases], followed by the stomach [68 (31.6%) cases], small intestine [8 (3.7%) cases], laryngopharynx [5 (2.3%) cases], and colon [4 (1.9%) cases].

Anatomical location, most common foreign body type, and procedure time

Data on FB type according to anatomical location are presented in Table 3. The most common FBs according to anatomical location were PTP medications (40%) and DP (40%) in the laryngopharynx, PTP medications (48.5%) and FBI (36.2%) in the esophagus, AP (57.4%) and DP (13.2%) in the stomach, DP (37.5%) and VCE (25%) in the small intestine, and VCE (75%) in the colon.

Procedure type and time

As shown in Table 4, procedure type was dependent on the FB location. The most commonly used procedure was EGD [207 (96.3%) cases], followed by SBE [5 (2.3%) cases] and CS [3 (1.4%) cases]. The procedure times for FB and FBI removal according to location were as follows: Laryngopharynx, 14.2 min (SD 2.7 min); esophagus, 14.5 min (SD 1.1 min); stomach, 14.7 min (SD 1.3 min); small intestine, 31.1 min (SD 1.0 min); and colon, 45.2 min (SD 2.7 min). There was no significant difference in the procedure time across the locations.

Most used devices according to FB type

Data on the most used devices according to FB type are presented in Table 5. Different types of devices were used. Devices were used in combination or were used alone. The most common devices according to FB type were a large caliber soft oblique cap with grasping forceps for PTP medications (83.3%) (Figure 1 and Video, grasping forceps for FBI (76.5%), biopsy forceps for AP (97.5%), a large caliber soft oblique cap with grasping forceps for DP (73.9%), a large caliber soft oblique cap with grasping forceps for fish bone (88.8%), a net retriever for VCE (85.7%), and an over-tube with a snare for spoon (66.6%).

Success and technical complications

FB removal was successful in all 215 cases (100%), and a complication was noted in only 1 case (0.5%). The complication involved a deep laceration of the mucosa that occurred during DP extraction, and the bleeding was immediately stopped with hemostasis endoclips. There was no need for surgery or re-admission after hospital discharge.

DISCUSSION

In the present study, most patients were older adults, and this might be because the index of older adults is the highest in the entire Japanese population at present[11]. PTP medications was the most common FB, as it is commonly used in Japan for packaging of medications and is ingested mostly among older adults owing to the use of medications for their different pathologies[12]. Sugawa *et al*[6] indicated in a review that PTP medications can be removed using a snare net with a protector over-tube or a retractable latex-rubber condom-type hood for mucosal protection. In our study, 83.3% of cases of impaction of PTP medications underwent removal involving a large caliber soft oblique cap and grasping forceps to avoid any damage to the mucosa, and there was no complication in any of the cases. As shown in Figure 1 and Video, a large caliber soft oblique cap can store the PTP medications avoiding mucosal damage, and thus, no complication occurred. A change in the material of PTP medications should

Table 2 Foreign body type and retrieved location

	Number of patients (%)
Foreign body type	
PTP medications	72 (33.5)
Food bolus	47 (21.9)
Anisakis parasite	41 (19.1)
Dental prosthesis	23 (10.7)
Fish bone	9 (4.2)
Video capsule device	7 (3.3)
Spoon	3 (1.4)
Others	13 (6.0)
Location	
Laryngopharynx	5 (2.3)
Esophagus	130 (60.5)
Stomach	68 (31.6)
Small intestine	8 (3.7)
Colon	4 (1.9)

PTP: Press-through-pack.

be considered to avoid impaction and complications associated with PTP medications ingestion, as it was the most common FB in this study.

FBI was the second most common type of FB (21.9% of cases), and it was noted in the esophagus, which was the anatomical location with the highest incidence in this study. The endoscopic treatment options according to the American Society for Gastrointestinal Endoscopy (ASGE) include in block removal using grasping devices, a piecemeal approach, and advancement of the food bolus into the stomach[1]. Some controversy is present regarding the push technique as there is a perforation risk when applying this technique without first examining the distal esophagus[13]. However, two large studies did not report perforation in a total of 375 patients using the push technique[14,15]. Their approach involved the application of gentle pressure to the center of the food bolus or the reduction of the bolus by piecemeal removal followed by the application of gentle pressure when advancement of the bolus was not successful. It is considered safe to perform dilation after bolus extraction when there is an esophageal stricture in order to avoid recurrence[14,15]. According to previous studies, the push technique is considered as the primary method with a success rate of over 90% and with minimal complications[1,4-6,14,16-19]. The most commonly used technique in our endoscopic center was the piecemeal approach with grasping forceps (76.5% of cases), and there was no complication during or after the extraction. In patients with a suspected etiology of eosinophilic esophagitis, biopsy samples were taken after removal of the FBI, and in patients who presented with an esophageal stricture, balloon dilatation was performed in order to avoid recurrences. The third most common FB in this study was AP (19.1%), and it was commonly located in the stomach. This high percentage might be associated with the fact that in Japan, there is a cultural tradition of eating raw fish in popular dishes, such as sushi and sashimi, which are the main sources of nematodes. According to Tokiwa *et al*[20], of the 301 cases of food poisoning in Japan between 2013 and 2015, 294 cases involved Anisakis food poisoning, and the most common source of infection was mackerel fish. Opportunities to eat raw fish in sushi bars and Japanese restaurants outside Japan are increasing; therefore, it is important to know about the existence of this parasite and its endoscopic management, as removal is the only approach for symptom relief[21]. In our study, 97.5% of all cases of AP underwent extraction using biopsy forceps, and this approach was successful in all cases without any complications. The fourth most common FB in this study was DP. This FB was common in our study owing to the fact that people using a DP are often old adults or very old adults. The European Society of Gastrointestinal Endoscopy (ESGE), the ASGE, and Bertoni *et al*[22] recommend the use of an over-tube as it helps to protect the esophageal and laryngeal mucosa from lacerations. If this protective device is not available, the use of a transparent cap or latex rubber hood is recommended to prevent mucosal injury[3]. In a recent study, Zhang *et al*[23] recommended the use of a transparent cap to allow a short procedure time and a clear visual field, in addition to mucosal protection. We used a large

Table 3 Common foreign bodies at each anatomical location

Anatomical location	Most common foreign bodies (number/total number)	%
Laryngopharynx	PTP (2/5)	40.0
	Dental prosthesis (2/5)	40.0
Esophagus	PTP (63/130)	48.5
	Food bolus (47/130)	36.2
Stomach	Anisakis parasite (39/68)	57.4
	Dental prosthesis (9/68)	13.2
	PTP (7/68)	10.3
Small intestine	Dental prosthesis (3/8)	37.5
	Video capsule device (2/8)	25.0
Colon	Video capsule device (3/4)	75.0

PTP: Press-though-pack; SD: Standard deviation.

caliber soft oblique cap in 73.9% of cases. The only complication noted in this study was for DP despite the fact that grip and protection devices for the esophageal mucosa were used. This complication might have been associated with the extended time taken to visit our hospital, which increased the risk of a complication, the fact that the extraction was performed by a beginner endoscopist as our center is a university hospital, the limited working space in the esophagus, or the fact that the rate of complications for sharp-pointed objects is as high as 35%[1]. There were also cases of fish bone impaction and VCE retention, but they were not very frequent. In cases involving fish bone, which is a sharp-pointed object, according to the ASGE and ESGE guidelines and other reports[1-3,22,23], we performed extraction using a large caliber soft oblique cap and grasping forceps in 88.8% of cases, and there were no complications. On the other hand, in the few cases of VCE retention in the small intestine, we successfully used SBE, without any complications. However, double-balloon enteroscopy is also recommended by few reports[1,24,25] There were also some cases of VCE retention in the colon, and the device was removed by conventional CS using a net retriever in almost all cases. This approach was successful in all cases, and there were no complications.

The ASGE and ESGE have stated that only 10%-20% of FB ingestion cases require endoscopic removal[1,3]; however, according to our study, we believe that this percentage might be higher in Japan owing to differences in dietary habits, average population age, and cultural backgrounds between people from Western countries and those from Asian countries, and the most common FBs were sharp-pointed objects that have a higher risk of complications when compared with other types of FBs. Webb *et al*[10] reported a success rate of 98.8% for endoscopic removal, Li *et al*[19] reported a success rate of 94.1% in China, and Zhang *et al*[26] reported a success rate of 96.1% in South China, and most complications involved sharp-pointed objects, similar to our only complication; however, our success rate was 100%.

The present study has some limitations. The study involved a retrospective analysis with a small sample size. There might have been several biases in the current study, such as selection bias associated with the patient enrollment methodology (use of an endoscopic database only). Thus, patients who were expected to have difficulty in endoscopic removal might have directly undergone surgery. Nevertheless, to our knowledge, this is the first study to elucidate the efficacy and safety of endoscopic retrieval of FBs and FBI in Japan.

In conclusion, endoscopic management of FBs is extremely safe and effective. The devices used for FB extraction depend on the location and type of FB. As most FBs in our study were sharp-pointed objects, we suggest always placing a large caliber soft oblique cap on the tip of the endoscope and not a straight transparent cap (Figure 1), this will help avoid mucosal injury from the sharp edges during extraction and will provide a clear visual field.

Table 4 Procedure type and time

	Number of patients (%)
Procedure type	
EGD	207 (96.3)
CS	3 (1.4)
SBE	5 (2.3)
Procedure time (mean ± SD, min)	
Laryngopharynx	14.2 ± 2.7
Esophagus	14.5 ± 1.1
Stomach	14.7 ± 1.3
Small intestine	31.1 ± 1.0
Colon	45.2 ± 2.7

EGD: Esophagogastroduodenoscopy; CS: Colonoscopy; SBE: Single-balloon enteroscopy; SD: Standard deviation.

Table 5 Foreign bodies and devices most used for extraction

Foreign body type	Device (number/total number)	Percentage (%)
PTP	Large caliber transparent cap and grasping forceps (60/72)	83.3
Food bolus	Grasping forceps (36/47)	76.5
Anisakis parasite	Biopsy forceps (40/41)	97.5
Dental prosthesis	Large caliber transparent cap and grasping forceps (17/23)	73.9
Fish bone	Large caliber transparent cap and grasping forceps (8/9)	88.8
Capsule device	Net retriever (6/7)	85.7
Spoon	Over-tube and polypectomy snare (2/3)	66.6

PTP: Press-through-pack.



Figure 1 Difference between a large–caliber, soft oblique cap and straight, conventional-caliber transparent cap. A: A large-caliber, soft oblique cap can store the press-through-pack (PTP), protecting the digestive mucosa when retrieving the PTP; B: A straight, conventional-caliber transparent cap cannot cover the sharp edges, which may result in mucosal injury.

ARTICLE HIGHLIGHTS

Research background

Endoscopic extraction of foreign bodies (FBs) is a method that can present complications depending on the type of management performed.

Research motivation
To date, there are no studies evaluating the endoscopic management of FBs in Japan.

Research objectives
The aim of this study is to elucidate level of safety and efficacy in the endoscopic management of FBs and food boluses in Japan.

Research methods
This study was a retrospective medical record analysis. A total of 215 procedures were performed at Keio University Hospital between November 2007 and August 2018. Data were collected from medical charts, and endoscopic details were collected from an endoscopic reporting system. Procedures performed with a flexible gastrointestinal endoscope were only taken into account. Patients who underwent a technique involving FB or food bolus removal from the digestive tract were only included. Data on patient sex, patient age, outpatient, inpatient, FB type, FB location, procedure time, procedure type, removal device type, success, and technical complications were reviewed and analyzed retrospectively.

Research results
The most common type of FB were press-through-pack (PTP) [72 (33.5%) cases], food bolus [47 (21.9%)], Anisakis parasite (AP) [41 (19.1%) cases]. Most FBs were located in the esophagus [130 (60.5%) cases] followed by the stomach [68 (31.6%) cases]. The most common FBs according to anatomical location were PTP (40%) and dental prostheses (DP) (40%) in the laryngopharynx, PTP (48.5%) in the esophagus, AP (57.4%) in the stomach, DP (37.5%) in the small intestine and video capsule endoscopy device (75%) in the colon. A transparent cap with grasping forceps was the most commonly used device [82 (38.1%) cases]. The success rate of the procedure was 100%, and complication was observed in only one case (0.5%).

Research conclusions
Endoscopic management of FBs is extremely safe and effective. The devices used for FB extraction depend on the location and type of FB.

Research perspectives
We suggest always placing a large caliber soft oblique cap on the tip of the endoscope and not a straight transparent cap, this will help avoid mucosal injury from the sharp edges during extraction and will provide a clear visual field.

REFERENCES

1 **ASGE Standards of Practice Committee**. Ikenberry SO, Jue TL, Anderson MA, Appalaneni V, Banerjee S, Ben-Menachem T, Decker GA, Fanelli RD, Fisher LR, Fukami N, Harrison ME, Jain R, Khan KM, Krinsky ML, Maple JT, Sharaf R, Strohmeyer L, Dominitz JA. Management of ingested foreign bodies and food impactions. *Gastrointest Endosc* 2011; **73**: 1085-1091 [PMID: 21628009 DOI: 10.1016/j.gie.2010.11.010]

2 **Ginsberg GG**. Management of ingested foreign objects and food bolus impactions. *Gastrointest Endosc* 1995; **41**: 33-38 [PMID: 7698622 DOI: 10.1016/S0016-5107(95)70273-3]

3 **Birk M**, Bauerfeind P, Deprez PH, Häfner M, Hartmann D, Hassan C, Hucl T, Lesur G, Aabakken L, Meining A. Removal of foreign bodies in the upper gastrointestinal tract in adults: European Society of Gastrointestinal Endoscopy (ESGE) Clinical Guideline. *Endoscopy* 2016; **48**: 489-496 [PMID: 26862844 DOI: 10.1055/s-0042-100456]

4 **Ambe P**, Weber SA, Schauer M, Knoefel WT. Swallowed foreign bodies in adults. *Dtsch Arztebl Int* 2012; **109**: 869-875 [PMID: 23293675 DOI: 10.3238/arztebl.2012.0869]

5 **Ko HH**, Enns R. Review of food bolus management. *Can J Gastroenterol* 2008; **22**: 805-808 [PMID: 18925301 DOI: 10.1155/2008/682082]

6 **Sugawa C**, Ono H, Taleb M, Lucas CE. Endoscopic management of foreign bodies in the upper gastrointestinal tract: A review. *World J Gastrointest Endosc* 2014; **6**: 475-481 [PMID: 25324918 DOI: 10.4253/wjge.v6.i10.475]

7 **Cheng W**, Tam PK. Foreign-body ingestion in children: experience with 1,265 cases. *J Pediatr Surg* 1999; **34**: 1472-1476 [PMID: 10549750 DOI: 10.1016/S0022-3468(99)90106-9]

8 **Nassar E**, Yacoub R, Raad D, Hallman J, Novak J. Foreign Body Endoscopy Experience of a University Based Hospital. *Gastroenterology Res* 2013; **6**: 4-9 [PMID: 27785219 DOI: 10.4021/gr517w]

9 **McKechnie JC**. Gastroscopic removal of a phytobezoar. *Gastroenterology* 1972; **62**: 1047-1051 [PMID: 5029071 DOI: 10.1016/S0016-5085(72)80123-9]

10 **Webb WA**. Management of foreign bodies of the upper gastrointestinal tract: update. *Gastrointest Endosc* 1995; **41**: 39-51 [PMID: 7698623 DOI: 10.1016/s0016-5107(95)70274-1]

11 **Miyanaga R**, Hosoe N, Naganuma M, Hirata K, Fukuhara S, Nakazato Y, Ojiro K, Iwasaki E, Yahagi N, Ogata H, Kanai T. Complications and outcomes of routine endoscopy in the very elderly. *Endosc Int Open* 2018; **6**: E224-E229 [PMID: 29423432 DOI: 10.1055/s-0043-120569]

12 **Sudo T**, Sueyoshi S, Fujita H, Yamana H, Shirouzu K. Esophageal perforation caused by a press through pack. *Dis Esophagus* 2003; **16**: 169-172 [PMID: 12823223 DOI: 10.1046/j.1442-2050.2003.00320.x]

13 **Vizcarrondo FJ**, Brady PG, Nord HJ. Foreign bodies of the upper gastrointestinal tract. *Gastrointest Endosc* 1983; **29**: 208-210 [PMID: 6618118 DOI: 10.1016/S0016-5107(83)72586-1]

14 **Vicari JJ**, Johanson JF, Frakes JT. Outcomes of acute esophageal food impaction: success of the push technique. *Gastrointest Endosc* 2001; **53**: 178-181 [PMID: 11174288 DOI: 10.1067/mge.2001.111039]

15 **Longstreth GF**, Longstreth KJ, Yao JF. Esophageal food impaction: epidemiology and therapy. A retrospective, observational study. *Gastrointest Endosc* 2001; **53**: 193-198 [PMID: 11174291 DOI:

10.1067/mge.2001.112709]
16 **Dray X**, Cattan P. Foreign bodies and caustic lesions. *Best Pract Res Clin Gastroenterol* 2013; **27**: 679-689 [PMID: 24160927 DOI: 10.1016/j.bpg.2013.08.009]
17 **Ciriza C**, García L, Suárez P, Jiménez C, Romero MJ, Urquiza O, Dajil S. What predictive parameters best indicate the need for emergent gastrointestinal endoscopy after foreign body ingestion? *J Clin Gastroenterol* 2000; **31**: 23-28 [PMID: 10914771 DOI: 10.1097/00004836-200007000-00006]
18 **Wu WT**, Chiu CT, Kuo CJ, Lin CJ, Chu YY, Tsou YK, Su MY. Endoscopic management of suspected esophageal foreign body in adults. *Dis Esophagus* 2011; **24**: 131-137 [PMID: 20946132 DOI: 10.1111/j.1442-2050.2010.01116.x]
19 **Li ZS**, Sun ZX, Zou DW, Xu GM, Wu RP, Liao Z. Endoscopic management of foreign bodies in the upper-GI tract: experience with 1088 cases in China. *Gastrointest Endosc* 2006; **64**: 485-492 [PMID: 16996336 DOI: 10.1016/j.gie.2006.01.059]
20 **Tokiwa T**, Kobayashi Y, Ike K, Morishima Y, Sugiyama H. Detection of Anisakid Larvae in Marinated Mackerel Sushi in Tokyo, Japan. *Jpn J Infect Dis* 2018; **71**: 88-89 [PMID: 29279440 DOI: 10.7883/yoken.JJID.2017.280]
21 **Furuya K**, Nakajima H, Sasaki Y, Urita Y. Anisakiasis: The risks of seafood consumption. *Niger J Clin Pract* 2018; **21**: 1492-1494 [PMID: 30417849]
22 **Bertoni G**, Sassatelli R, Conigliaro R, Bedogni G. A simple latex protector hood for safe endoscopic removal of sharp-pointed gastroesophageal foreign bodies. *Gastrointest Endosc* 1996; **44**: 458-461 [PMID: 8905368 DOI: 10.1016/S0016-5107(96)70099-8]
23 **Zhang S**, Wang J, Wang J, Zhong B, Chen M, Cui Y. Transparent cap-assisted endoscopic management of foreign bodies in the upper esophagus: a randomized, controlled trial. *J Gastroenterol Hepatol* 2013; **28**: 1339-1342 [PMID: 23573993 DOI: 10.1111/jgh.12215]
24 **May A**, Nachbar L, Ell C. Extraction of entrapped capsules from the small bowel by means of push-and-pull enteroscopy with the double-balloon technique. *Endoscopy* 2005; **37**: 591-593 [PMID: 15933937 DOI: 10.1055/s-2005-861320]
25 **Miehlke S**, Tausche AK, Brückner S, Aust D, Morgner A, Madisch A. Retrieval of two retained endoscopy capsules with retrograde double-balloon enteroscopy in a patient with a history of complicated small-bowel disease. *Endoscopy* 2007; **39** Suppl 1: E157 [PMID: 17570097 DOI: 10.1055/s-2006-925375]
26 **Zhang S**, Cui Y, Gong X, Gu F, Chen M, Zhong B. Endoscopic management of foreign bodies in the upper gastrointestinal tract in South China: a retrospective study of 561 cases. *Dig Dis Sci* 2010; **55**: 1305-1312 [PMID: 19655249 DOI: 10.1007/s10620-009-0900-7]

World Journal of Gastrointestinal Endoscopy

Submit a Manuscript: https://www.f6publishing.com

World J Gastrointest Endosc 2020 January 16; 12(1): 42-48

DOI: 10.4253/wjge.v12.i1.42

ISSN 1948-5190 (online)

CASE REPORT

Endoscopic vacuum assisted closure of esophagogastric anastomosis dehiscence: A case report

Jarosław Cwaliński, Jacek Hermann, Mariusz Kasprzyk, Tomasz Banasiewicz

ORCID number: Jarosław Cwaliński (0000-0001-8606-9495); Jacek Hermann (0000-0001-7236-0409); Mariusz Kasprzyk (0000-0001-6553-7675); Tomasz Banasiewicz (0000-0003-2809-6940).

Author contributions: All authors contributed equally to this work; Cwaliński J wrote the initial manuscript and reviewed the images; Hermann J prepared English language editing; Cwaliński J, Hermann J and Kasprzyk M performed procedures; Banasiewicz T drafted the concepts and designed the study.

Informed consent statement: The therapy described was in accordance with the principles of medical ethics and good medical practice. Patients provided informed written consent prior to all medical procedures and for the publication of this report.

Conflict-of-interest statement: Authors declare no conflict of interest regarding this manuscript.

CARE Checklist (2016) statement: The authors have read the CARE Checklist (2016), and the manuscript was prepared and revised according to the CARE Checklist (2016).

Jarosław Cwaliński, Jacek Hermann, Tomasz Banasiewicz, Department of General and Endocrynologic Surgery and Gastroenterologic Oncology, Poznan University of Medical Sciences, Poznan 60-355, Poland

Mariusz Kasprzyk, Department of Thoracic Surgery, Poznan University of Medical Sciences, Poznan 60-355, Poland

Corresponding author: Jarosław Cwaliński, MD, PhD, Academic Research, Doctor, Lecturer, Department of General, and Endocrynologic Surgery, and Gastroenterologic Oncology, Poznan University of Medical Sciences, Przybyszewskiego 49, Poznan 60-355, Poland. cwalinski.jaroslaw@spsk2.pl

Abstract

BACKGROUND

Esophagogastric leakage is one of the most severe postoperative complications. Partial disruption of the anastomosis, can be successfully treated with an endoscopic vacuum assisted closure (E-VAC). The advantage of that method of treatment is the ability to adjust a vacuum dressing individually to the size of the dehiscence and thus to reduce the risk of a secondary fistula or abscess. The authors present two patients with postoperative gastroesophageal leakage treated successfully with E-VAC.

CASE SUMMARY

Two male patients developed a potentially life threatening esophagogastric leakage. Patient A underwent resection of the distal half of the esophagus and upper part of the stomach due to Siewert type II adenocarcinoma of the gastroesophageal junction. Proximal resection of the stomach was performed in the patient B after massive bleeding from Mallory-Weiss tears. Both patients were treated successfully with an individually adapted E-VAC with concomitant correction of fluid and electrolyte disturbances, and treatment of sepsis with appropriate antibiotics.

CONCLUSION

Endoscopic vacuum closure is an effective alternative to endoscopic stenting or relaparotomy. Through individual approach it allows a more accurate assessment of healing.

Key words: Esophagogastric leakage; Endoscopic vacuum assisted closure; Endoscopic negative pressure wound therapy; Anastomotic insufficiency; Case report

Manuscript source: Unsolicited manuscript

Received: May 8, 2019
Peer-review started: May 10, 2019
First decision: May 31, 2019
Revised: September 19, 2019
Accepted: November 6, 2019
Article in press: November 6, 2019
Published online: January 16, 2020

P-Reviewer: Hu B
S-Editor: Dou Y
L-Editor: A
E-Editor: Ma YJ

Core tip: Postoperative esophagogastric leakage might be successfully treated with conservative measures either with well-established endoscopic stenting or endoscopic vacuum assisted closure with respect to the type and localization of leakage. The advantage of vacuum treatment is a continuous evacuation of septic discharge and an individual adjustment of the dressing depending on the size of the dehiscence. The application of an endoscopic vacuum dressing is relatively simple, cost-effective, easily accessible and in many cases, it avoids consecutive laparotomies.

Citation: Cwaliński J, Hermann J, Kasprzyk M, Banasiewicz T. Endoscopic vacuum assisted closure of esophagogastric anastomosis dehiscence: A case report. *World J Gastrointest Endosc* 2020; 12(1): 42-48
URL: https://www.wjgnet.com/1948-5190/full/v12/i1/42.htm
DOI: https://dx.doi.org/10.4253/wjge.v12.i1.42

INTRODUCTION

Esophagogastric leakage remains the most severe and a life threatening complication of gastroesophageal junction (GEJ) resection. The reported leak rate following esophageal resection due to carcinoma varies from 5% to 17%[1,2]. The management depends on the clinical condition of a patient and a type of leakage, that might be secondary to dehiscence of less than 10% of the anastomosis circumference, disruption of 10%-50% of the circuit, or necrosis with anastomotic separation of more than 50% of the circumference[3,4]. The last type of leakage results usually in a catastrophic septic shock and requires urgent redo operation. The other types might be treated conservatively with correction of fluid and electrolyte disturbances, treatment of sepsis with appropriate antibiotics, percutaneous drainage, stent implantation or endoscopic vacuum assisted closure (E-VAC) placement[5,6]. Based on a limited experiences negative pressure drainage appears today a promising alternative to stenting[6,7]. The aim of the study is to show the possibilities of endoscopic vacuum therapy in the treatment of upper gastrointestinal tract leakage adapted individually to the size and location of a leakage.

CASE PRESENTATION

Chief complaints

Two male patients with postoperative esophagogastric leakage treated with individually adapted E-VAC.

History of present illness

Patient A, a 53-year-old male was admitted to the authors' Surgery Clinic due to *Siewert* type II adenocarcinoma of GEJ. He underwent a radical resection of the distal half of the esophagus and upper part of the stomach through thoraco-phreno-laparotomy. Primary anastomosis of the esophageal remnant with gastric conduit was performed within the thoracic cavity to restore continuity of the digestive tract. The postoperative course was complicated with dehiscence of the esophagogastric anastomosis followed by leakage into the mediastinum limited by the gastric conduit, the lung, and the diaphragm but without entering the pleural cavity.

Patient B, a 23 year-old male was admitted to the Clinic from a county hospital with esophagogastric anastomosis dehiscence 4 d after urgent, proximal resection of the stomach due to massive bleeding from Mallory-Weiss tears which failed to respond to endoscopic treatment.

Past medical history

Patient A complained of dysphagia and anorexia and he lost weight in 6 mo, He was addicted to cigarettes and alcohol within 10 years before surgery. Gastroscopy revealed cancer of the gastro-oesophageal junction. The medical history of patient B was unencumbered and the esophageal rupture was a result of massive vomiting in the course of gastroenteritis.

Physical examination

Patient's A general condition deteriorated on the fourth day after surgery. He developed dyspnoea and pain in the upper abdomen. The pulse increased to 110 bpm with permanent hypotension. There was also a purulent discharge through an abdominal drain located close to the hiatus followed by gastric content and saliva on the 6th d after surgery with a total volume up to 300 mL per day. Patient B after admission to the Clinic developed septic shock and underwent redo operation limited to drainage of the anastomotic region because of encapsulating peritonitis. He was admitted to the intensive care unit (ICU) for ventilator treatment, hemodialysis, and broad-spectrum antibiotic therapy. The abdominal drain left during the relaparotomy led gastric content and air.

Laboratory examinations

Elevated inflammatory markers were characteristic of both patients. C-reactive protein at the moment of leak detection were 401 mg/L for patient A and 310 mg/L for patient B. Patient's B procalcitonin level increased up to 20 ng/mL one day after relaparotomy. In turn, patient A manifested anemia on the fourth day after surgery and the level of white blood cells reached 40 G/L.

Imaging examinations

Patient A: Water-soluble contrast swallow showed the passage of contrast media beyond the gastrointestinal tract to the mediastinum (Figure 1). Endoscopic assessment revealed posterior disruption of esophagogastric anastomosis within 30% of the circumference (Figure 2A). Patient B: After relaparotomy and two-day stay at the ICU esophagogastroduodenoscopy was performed which revealed a small dehiscence of less than 10% of the anastomosis circumference in the form of a focal necrosis (Figure 2B). Computed tomography (CT) performed next day revealed a large amount of gas and fluid in the abdominal cavity (Figure 3).

FINAL DIAGNOSIS

Both patients showed postoperative gastroesophageal leakage classified as type II according Consensus for Defining and Reporting Complications After Esophagectomy.

TREATMENT

In both cases after the decision to apply E-VAC, a hand-prepared drain consisting of a nasogastric catheter wrapped with a polyurethane foam (VivanoMed Foam, Paul Hartmann AG, Germany), was inserted into the lumen of the gastrointestinal tract (Figure 4).

A significant disruption of esophagogastric anastomosis diagnosed in patient A required the introduction of vacuum dressing into mediastinal cavity, preceded with aspiration of discharge for culture (Figure 2C). Throughout the treatment a stable negative pressure of 100 mmHg was maintained. E-VAC was changed four times in a fortnight and during each change either size of the foam was reduced and the catheter was gradually removed from the shrinking cavity with the aim to collapse it. Finally, E-VAC therapy was finished when the sinus reached a size of a small shallow esophageal diverticulum and when inflammatory markers levels normalized (Figure 2D). At the first session of vacuum therapy surgical treatment was combined with parenteral nutrition modified with immune modulatory amino acids such as L-arginine and L-glutamine, and medium chain triglycerides for hypoalbuminemia and lymphopenia. Next the realimentation was then continued *via* the enteral route through an enteric probe. Basal metabolic rate was evaluated according to European Society for Clinical Nutrition and Metabolism including anthropometric grade, and laboratory tests.

In the case of patient B, because of a very narrow range of dehiscence, a nasogastric catheter with a polyurethane foam was left in the lumen of the digestive tract to close to the anastomosis region (Figure 2E). Throughout the treatment a fluctuating negative pressure between 60- and 80-mmHg and changing every 5 min was applied to avoid damage to the mucosa. In addition, a nasoenteric tube was inserted for enteral nutrition. E-VAC was changed three times every third day. The patient's general condition improved in 2 wk and he was finally discharged from the Clinic on oral diet.

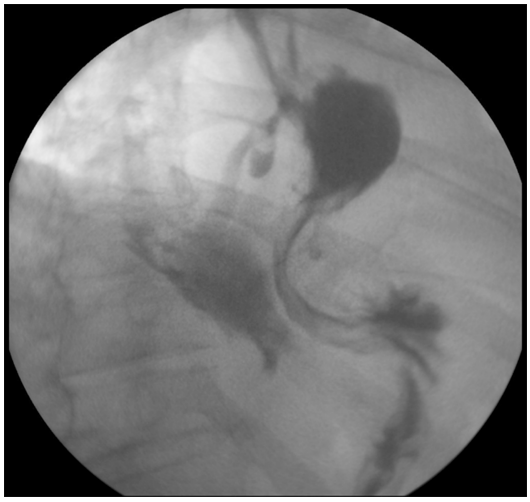

Figure 1 Gastrografin swallow showing esophagogastric leakage.

OUTCOME AND FOLLOW-UP

Both patients were treated successfully with E-VAC of dehiscent anastomoses with concomitant correction of fluid and electrolyte disturbances, and treatment of sepsis with appropriate antibiotics. In both cases, a CT was performed at the end of the treatment to exclude a fluid reservoir (abscess, hematoma, intestinal fluid, *etc*.). A control gastroscopy performed in both patients after three months revealed complete healing of previous anastomotic disruption. In a case of Patient A, a small anastomotic stricture with shallow diverticulum was found (Figure 2F).

DISCUSSION

However, esophagogastric leakage after GEJ resection is one of the most severe complication with a relatively high mortality the management mainly depends on a patient's general condition and the cause of leakage. According to Consensus for Defining and Reporting Complications After Esophagectomy reached by ECCG type II of anastomotic leak requires intervention but not surgical therapy[8]. This type of dehiscence might be treated successfully with conservative measures either with well-established endoscopic stenting or E-VAC with concomitant correction of fluid and electrolyte disturbances, and treatment of sepsis with appropriate antibiotics[4-6]. Although, stenting allows for prompt oral feeding, its migration occurs in over 25% of cases and it is not fully tight. In addition, late complications of stenting include difficulties with its retrieval, perforations, fistulas, and bleeding[9]. What is more, there was no communication between the collection of fluid and the pleural cavity in the presented case. Therefore, the anastomotic dehiscence which could have been sealed with a possible stent was the only approach for evacuation of septic discharge. Treatment of the leakage with E-VAC appears a significant alternative to stenting[7,9,10]. The advantage of vacuum treatment is a continuous evacuation of septic discharge, reduction of inflammatory edema, improvement of blood supply and lymphatic drainage. Negative pressure wound therapy (NPWT) result in shrinkage of a cavity and promotes formation of fresh granulation tissue[6,7]. The application of endoluminal closure is simple since the dressing consists of a polyurethane foam sutured to a regular nasogastric tube. That catheter equipped with a foam might be located either within a dehiscence for extended disruption of an anastomosis or close to it in the lumen of the gastrointestinal tract in a case of small defects. That tube is supposed to be connected then with every negative-pressure port. Immediate application of E-VAC just after diagnosis of esophagogastric leakage is of utmost importance[11]. The method is recommended today even to prevent esophagogastric leakage in jeopardized anastomoses[12]. E-VAC is today a widely used method of therapy for complications developing after operations within the upper part of the gastrointestinal tract with satisfactory early as well as long-term results and with good quality of life[13].

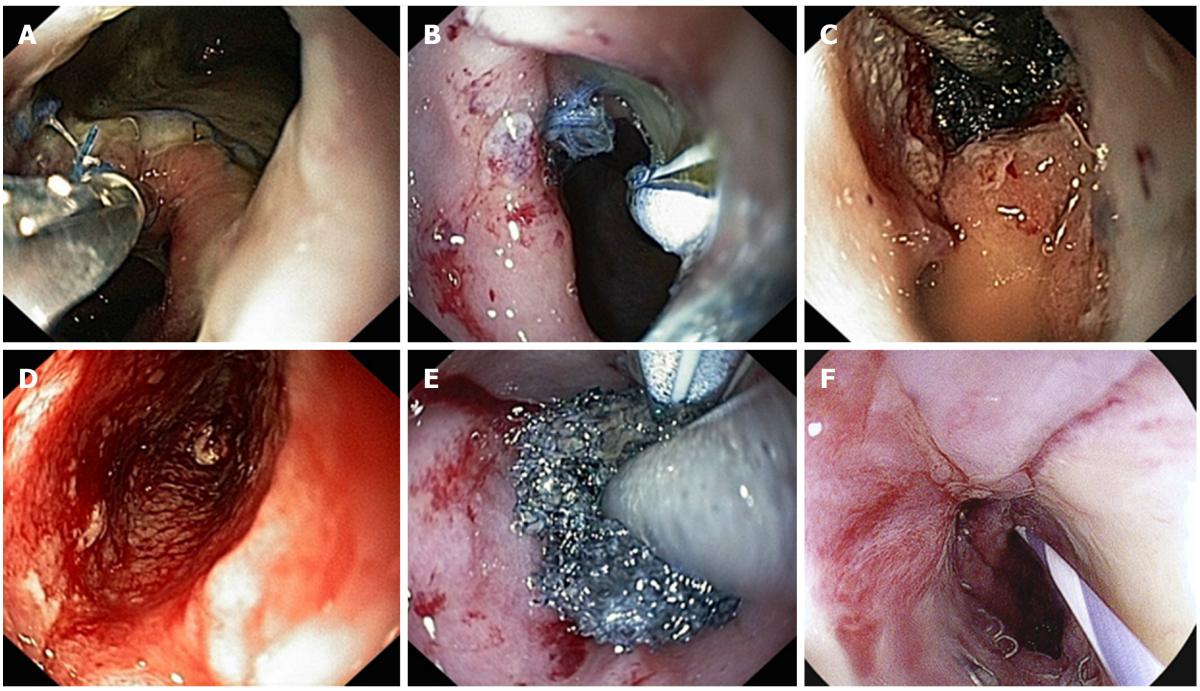

Figure 2 Gastroscopy results. A: Dehiscence of the anastomosis with 30% of the circumference; B: Anastomotic leak in the suture line; C: Endoscopic vacuum assisted closure (E-VAC) introduced into the mediastinal cavity; D: Mediastinal cavity reduced to a small and shallow like an esophageal diverticulum; E: E-VAC introduced into the lumen of the gastrointestinal tract close to the anastomotic leak; F: Follow-up gastroscopy: anastomotic stricture with shallow diverticulum.

CONCLUSION

Our experience shows that E-VAC in the treatment of gastrointestinal anastomotic leakage is a valuable and effective method. In contrast to stenting, vacuum therapy provides constant access to the site of leakage, allowing the evaluation of healing and modification of surgical treatment. We hope endoscopic NPWT will be approved and becomes a valuable alternative in the treatment of surgical complications.

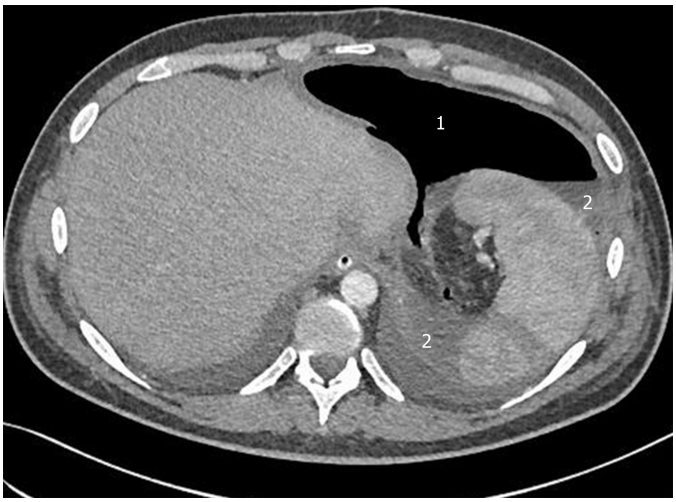

Figure 3 Computed tomography on the third day after relaparotomy. A large amount of gas (1) and liquid (2) as a result of leakage anastomosis.

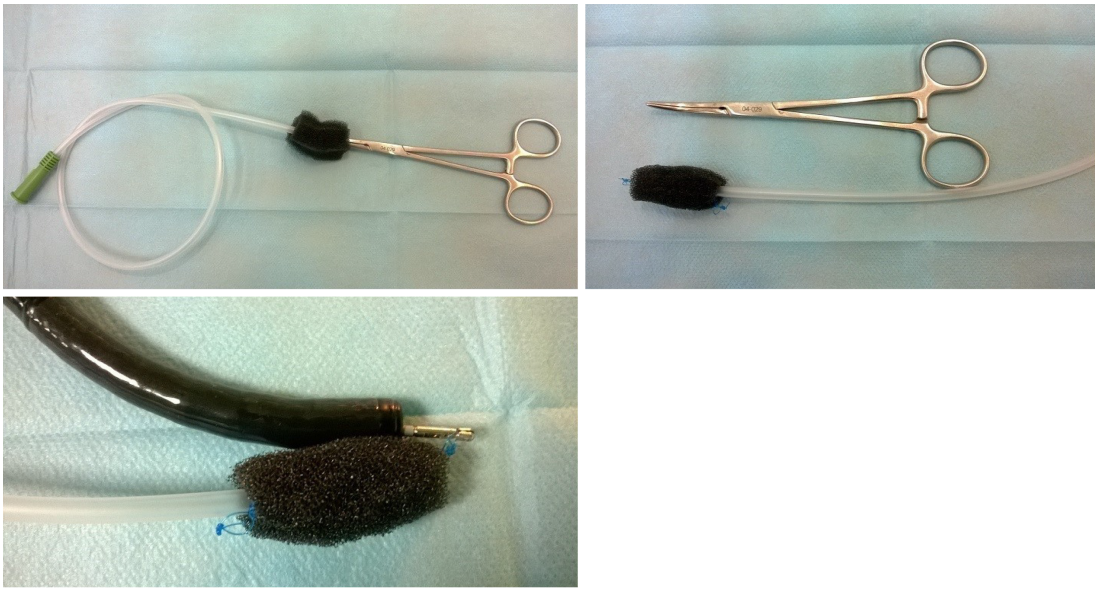

Figure 4 Endoscopic vacuum assisted closure prepared before the introduction.

REFERENCES

1 **Dewar L**, Gelfand G, Finley RJ, Evans K, Inculet R, Nelems B. Factors affecting cervical anastomotic leak and stricture formation following esophagogastrectomy and gastric tube interposition. *Am J Surg* 1992; **163**: 484-489 [PMID: 1575303 DOI: 10.1016/0002-9610(92)90393-6]

2 **Mishra PK**, Shah H, Gupta N, Varshney V, Patil NS, Jain A, Saluja SS. Stapled versus hand-sewn cervical esophagogastric anastomosis in patients undergoing esophagectomy: A Retrospective Cohort Study. *Ann Med Surg (Lond)* 2016; **5**: 118-124 [PMID: 27222711 DOI: 10.1016/j.amsu.2015.12.063]

3 **Persson S**, Rouvelas I, Irino T, Lundell L. Outcomes following the main treatment options in patients with a leaking esophagus: a systematic literature review. *Dis Esophagus* 2017; **30**: 1-10 [PMID: 28881894 DOI: 10.1093/dote/dox108]

4 **Low DE**, Alderson D, Cecconello I, Chang AC, Darling GE, D'Journo XB, Griffin SM, Hölscher AH, Hofstetter WL, Jobe BA, Kitagawa Y, Kucharczuk JC, Law SY, Lerut TE, Maynard N, Pera M, Peters JH, Pramesh CS, Reynolds JV, Smithers BM, van Lanschot JJ. International Consensus on Standardization of Data Collection for Complications Associated With Esophagectomy: Esophagectomy Complications Consensus Group (ECCG). *Ann Surg* 2015; **262**: 286-294 [PMID: 25607756 DOI: 10.1097/SLA.0000000000001098]

5 **Anderloni A**, Genco C, Massidda M, Di Leo M, Fumagalli UR, Rosati R, Correale L, Maselli R, Ferrara EC, Jovani M, Repici A. Self-Expanding Metal Stents for the Treatment of Post-Surgical Esophageal Leaks: A Tertiary Referral Center Experience. *Dig Surg* 2019; **36**: 309-316 [PMID: 29870974 DOI: 10.1159/000489817]

6 **Noh SM**, Ahn JY, Lee JH, Jung HY, AlGhamdi Z, Kim HR, Kim YH. Endoscopic Vacuum-Assisted Closure Therapy in Patients with Anastomotic Leakage after Esophagectomy: A Single-Center Experience. *Gastroenterol Res Pract* 2018; **2018**: 1697968 [PMID: 29849581 DOI: 10.1155/2018/1697968]

7 **Borejsza-Wysocki M**, Szmyt K, Bobkiewicz A, Malinger S, Świrkowicz J, Hermann J, Drews M, Banasiewicz T. Endoscopic vacuum-assisted closure system (E-VAC): case report and review of the literature. *Wideochir Inne Tech Maloinwazyjne* 2015; **10**: 299-310 [PMID: 26240633 DOI: 10.5114/wiitm.2015.52080]

8 **Pera M**, Low DE. Consensus for defining and reporting complications after esophagectomy: an important new step in place for using the same language. *Cir Esp* 2015; **93**: 549-551 [PMID: 26549879 DOI: 10.1016/j.ciresp.2015.09.009]

9 **Hwang JJ**, Jeong YS, Park YS, Yoon H, Shin CM, Kim N, Lee DH. Comparison of Endoscopic Vacuum Therapy and Endoscopic Stent Implantation With Self-Expandable Metal Stent in Treating Postsurgical Gastroesophageal Leakage. *Medicine (Baltimore)* 2016; **95**: e3416 [PMID: 27100431 DOI: 10.1097/MD.0000000000003416]

10 **Aryaie AH**, Singer JL, Fayezizadeh M, Lash J, Marks JM. Efficacy of endoscopic management of leak after foregut surgery with endoscopic covered self-expanding metal stents (SEMS). *Surg Endosc* 2017; **31**: 612-617 [PMID: 27317034 DOI: 10.1007/s00464-016-5005-8]

11 **Wedemeyer J**, Brangewitz M, Kubicka S, Jackobs S, Winkler M, Neipp M, Klempnauer J, Manns MP, Schneider AS. Management of major postsurgical gastroesophageal intrathoracic leaks with an endoscopic vacuum-assisted closure system. *Gastrointest Endosc* 2010; **71**: 382-386 [PMID: 19879566 DOI: 10.1016/j.gie.2009.07.011]

12 **Neumann PA**, Mennigen R, Palmes D, Senninger N, Vowinkel T, Laukoetter MG. Pre-emptive endoscopic vacuum therapy for treatment of anastomotic ischemia after esophageal resections. *Endoscopy* 2017; **49**: 498-503 [PMID: 28107761 DOI: 10.1055/s-0042-123188]

13 **Dhayat SA**, Schacht R, Mennigen R, Palmes D, Vogel T, Vowinkel T, Senninger N, Laukoetter MG. Long-Term Quality of Life Assessment After Successful Endoscopic Vacuum Therapy of Defects in the Upper Gastrointestinal Tract Quality of Life After EVT. *J Gastrointest Surg* 2019; **23**: 280-287 [PMID: 30430432 DOI: 10.1007/s11605-018-4038-9]

World Journal of Gastrointestinal Endoscopy

Submit a Manuscript: https://www.f6publishing.com

World J Gastrointest Endosc 2020 January 16; 12(1): 49-52

DOI: 10.4253/wjge.v12.i1.49

ISSN 1948-5190 (online)

LETTER TO THE EDITOR

Lack of proper reimbursement is hampering adoption of minimally invasive gastrointestinal endoscopy in North America

Shahzad Iqbal, Aman Ali, Arham Razzaq, Eman Shahzad

ORCID number: Shahzad Iqbal (0000-0001-7149-9724); Aman Ali (0000-0003-4543-6556); Arham Razzaq (0000-0001-7771-0578); Eman Shahzad (0000-0002-7803-3705).

Author contributions: All authors equally contributed to the following criteria for authorship: drafting of the article, critical revision of the article for important intellectual content, and final approval of the article.

Conflict-of-interest statement: There are no conflicts of interest to declare in relation to this article.

Manuscript source: Unsolicited manuscript

Received: May 8, 2019
Peer-review started: May 10, 2019
First decision: August 2, 2019
Revised: October 18, 2019
Accepted: November 4, 2019
Article in press: November 4, 2019
Published online: January 16, 2020

Shahzad Iqbal, Department of Gastroenterology, Good Samaritan Hospital, West Islip, NY 11795, United States

Aman Ali, Department of Gastroenterology, Lancaster General Hospital, Lancaster, PA 17602, United States

Arham Razzaq, Eman Shahzad, Herricks High School, New Hyde Park, NY 11040, United States

Corresponding author: Shahzad Iqbal, AGAF, FACG, FASGE, MD, Associate Professor, Department of Gastroenterology, Good Samaritan Hospital, 1111 Montauk Highway, Floor 3rd, West Islip, NY 11795, United States. siqbal50@gmail.com

Abstract

Endoscopic submucosal dissection (ESD) and related procedures are minimally invasive and cost-effective alternates to surgery. However, there is no approved or listed current procedural terminology (CPT) for ESD. We aimed to review the current reimbursement process hurdles for ESD procedures in private practice model in United States. We reviewed the data of two advanced endoscopists (one in New York and other in Pennsylvania State) performing ESD in their private practice set-ups. We found the reimbursement process was complex, with number of refusals varied from 0-9 for ESD procedures. It was not paid at all in 8.3% of cases by the medical insurance. Endoscopic mucosal resection, which is considered inferior as compared to ESD, but has a listed CPT, was denied in only 0.83% cases. Our data highlights the billing hurdles by the endoscopists to adopt ESD-related procedures in private practice model.

Key words: Endoscopic submucosal dissection; Lack of reimbursement; Current procedural terminology; Minimally invasive gastrointestinal endoscopy; North America

Core tip: Despite being minimally invasive and cost-effective alternates to surgery for removal of large gastrointestinal mucosal lesions, Endoscopic submucosal dissection has no approved or listed current procedural terminology for billing. It leads to much higher denial rate by the health insurance companies in North America. This scenario is highlighted in our article and is a hurdle in adoption of such useful techniques in private practice set-up.

P-Reviewer: Han JH, Huang HJ
S-Editor: Ma RY
L-Editor: A
E-Editor: Ma YJ

Citation: Iqbal S, Ali A, Razzaq A, Shahzad E. Lack of proper reimbursement is hampering adoption of minimally invasive gastrointestinal endoscopy in North America. *World J Gastrointest Endosc* 2020; 12(1): 49-52
URL: https://www.wjgnet.com/1948-5190/full/v12/i1/49.htm
DOI: https://dx.doi.org/10.4253/wjge.v12.i1.49

TO THE EDITOR

Patients with large gastrointestinal (GI) mucosal polyps and lesions including carcinoids, muscle tumors including GI stromal tumor, and achalasia, traditionally undergo surgery. Not only there is morbidity and mortality involved, surgical procedures are costly. The total cost for elective colectomy varies with type of surgery performed. According to an estimate, the total average costs were $31601 with open versus $24196 with laparoscopic surgical approach[1].

Endoscopic submucosal dissection (ESD) and related GI procedures are minimally invasive as well as cost-effective alternates to surgery for above conditions. According to a decision analysis model, the cost of endoscopic removal for complex colon polyp was $5570 per patient versus $18717 per patient for laparoscopic surgery[2]. Medicare reimbursements for physicians are significantly lower for endoscopic procedures compared to invasive surgery even though by performing these ultra-minimally invasive endoscopic procedures, significant morbidity is avoided, organs are preserved and minimal or no recovery time is needed hence preventing work loss days. Total gastrectomy is reimbursed at $2028.89 *vs* endoscopic mucosal resection (EMR) is paid $280.22[3]. Total esophagectomy is paid $3080.89 *vs* EMR at $280.22. Abdominoperineal resection is paid $2024.27 *vs* colonoscopy EMR at $345.18. ESD is more time consuming, complex procedure with higher skills sets requirements however since these are lumped together in "unlisted code" category, at times it's not compensated at all and other times reimbursed at much lower skill level of EMR or standard polypectomy. This is one of the discouraging factors for dissemination of these valuable techniques amongst skilled endoscopist in United States.

ESD and related procedures are increasingly being performed in Asia as well as in Europe. However, these procedures are limited to selective tertiary care facilities in United States. Due to lack of proper reimbursement, these procedures remain unknown in private practice system. At present, there remains no approved or listed current procedural terminology (CPT) for ESD[4]. Only unlisted CPT can be used for reimbursement: 45399 for lower, and 43499 for upper GI tract endoscopic procedures. It first requires approval and authorization from the insurance carrier. Documentation is provided by the endoscopist's office in terms of the need for ESD and any other alternates. Many times, it leads to peer-to-peer review between the performing endoscopist and the reviewer physician at the insurance office. This article will highlight the billing and reimbursement hurdles to adopt ESD-related procedures in private practice model in United States healthcare system.

We reviewed the data of two advanced endoscopists (one in New York and other in Pennsylvania State) who been performing ESD-related procedures in their private practice set-ups from last three years. Both endoscopists had dedicated training in ESD-related procedures. All such procedures were performed in the nearby hospitals under deep sedation (either intravenous propofol or general anesthesia). Prophylactic antibiotics were administered as necessary. Patients were mostly discharged home the same day or hospitalized for few days (depending upon the nature of ESD procedure, like per-oral endoscopic myotomy for achalasia treatment or endoscopic Zenker's diverticulectomy).

Table 1 shows the data of all the patients who underwent ESD-related procedures in both states. Both lower and upper GI tract ESD-related procedures were performed. The main indication was GI tract mucosal polyps/lesions (67.5%). It was a mixed health insurance payer population (Commercial and Medicare). The unlisted CPT for lower GI endoscopy ESD used was 45399, while 43499 were used for upper ESD. These CPT were denied initially in 42 patients, with initial denial rate of 35%. After each denial, the bill was re-processed with more documentation. The number of denials varied from 0-9. The procedure ultimately got paid as a listed CPT like 45385 (colonoscopy with removal of lesion), 45390 (colonoscopy with EMR), or 43251 (EGD with biopsy). However, 10 cases remain unpaid with final denial rate of 8.33%. It is much higher as compared to other endoscopic procedures with listed CPT. The average denial rate for a GI endoscopic procedure is reported to be very low (< 1%). In some cases in our data, more than one lesion was removed in the same session

either by ESD or other endoscopic techniques.

ESD-related complications were noted in only three patients (2.5% rate): 2 post-procedural bleeding that were managed conservatively, and 1 esophageal stricture that was successfully managed by balloon dilation. Not listed in Table 1 are additional 120 patients with sessile-flat colorectal lesions 15 mm and above that were removed by EMR technique. There already exits a listed CPT for EMR: 45390 (colonoscopy with EMR), and 43254 (EGD with EMR). Only 3 cases (2.5%) were initially denied. After re-processing, only one EMR case remain denied (with final denial rate of 0.83%). However, piecemeal EMR is considered inferior as compared to ESD. In a meta-analysis, piecemeal EMR had lower en-bloc resection and higher local recurrence rates for colorectal lesions[5]. Had there been a listed CPT for ESD or health insurance authorized unlisted CPT for ESD in our cases, these patients could have benefited from ESD-related technique.

ESD-related procedures are time consuming. The procedure time (from introduction of the endoscope to complete removal of the target ESD lesion) ranged from 20-120 min. Our data shows the financial frustrations of the advanced endoscopists who may like to perform such procedures so as to benefit patients in their practices. There needs to be proper CPT for ESD-related technique (separate for upper and lower GI endoscopic procedures). It should reimburse the endoscopists appropriately considering in-view of the complexity of the procedure as well as time-spent by the endoscopist. If any other lesion besides the ESD target lesion is noted during the endoscopy, there is a need to develop a mechanism where by the endoscopist can remove and bill for the second lesion as well. Otherwise, the patient may need a separate endoscopic procedure. If more than one lesion is removed *via* ESD technique, there also need to be a mechanism to bill accordingly. Different medical societies including American Medical Association, American Gastroenterology Association, American Society of Gastrointestinal Endoscopy and American College of Gastroenterology should play their roles and pull legal strings.

Table 1 Billing data for endoscopic submucosal dissection-related endoscopic procedures

Total patients	**120**
Gender	Male 64; female 56
Type of GI endoscopy	Lower 76; upper 44
Age (yr)	Range 22-92
Indication of procedure	Mucosal polyps/lesions 81, submucosal lesions 15, myotomy 24
Length of ESD (min)	Range 20-120
Complications	3 (2.5%) (2 post-ESD bleed; 1 esophageal stricture requiring dilation)
Type of health insurance	Commercial 52 (43%), medicare 49 (40.8%), HMO 19 (15.8%)
Not paid as unlisted CPT	42
Initial denial rate	35%
Not paid at all	10
Final denial rate	8.33%
Number of denials	Range 0 to 9

GI: Gastrointestinal; ESD: Endoscopic submucosal dissection; CPT: Current procedural terminology.

REFERENCES

1 **Crawshaw BP**, Chien HL, Augestad KM, Delaney CP. Effect of laparoscopic surgery on health care utilization and costs in patients who undergo colectomy. *JAMA Surg* 2015; **150**: 410-415 [PMID: 25806476 DOI: 10.1001/jamasurg.2014.3171]

2 **Law R**, Das A, Gregory D, Komanduri S, Muthusamy R, Rastogi A, Vargo J, Wallace MB, Raju GS, Mounzer R, Klapman J, Shah J, Watson R, Wilson R, Edmundowicz SA, Wani S. Endoscopic resection is cost-effective compared with laparoscopic resection in the management of complex colon polyps: an economic analysis. *Gastrointest Endosc* 2016; **83**: 1248-1257 [PMID: 26608129 DOI: 10.1016/j.gie.2015.11.014]

3 **FeeLookup**. Available from: https://www.novitas-solutions.com/webcenter/portal/MedicareJL/FeeLookup

4 **Rex DK**, Hassan C, Dewitt JM. Colorectal endoscopic submucosal dissection in the United States: Why do we hear so much about it and do so little of it? *Gastrointest Endosc* 2017; **85**: 554-558 [PMID: 28215767 DOI: 10.1016/j.gie.2016.09.015]

5 **Wang J**, Zhang XH, Ge J, Yang CM, Liu JY, Zhao SL. Endoscopic submucosal dissection vs endoscopic mucosal resection for colorectal tumors: a meta-analysis. *World J Gastroenterol* 2014; **20**: 8282-8287 [PMID: 25009404 DOI: 10.3748/wjg.v20.i25.8282]

Published By Baishideng Publishing Group Inc
7041 Koll Center Parkway, Suite 160, Pleasanton, CA 94566, USA
Telephone: +1-925-2238242
E-mail: bpgoffice@wjgnet.com
Help Desk: https://www.f6publishing.com/helpdesk
https://www.wjgnet.com