ISSN 1948-5182 (online)

World Journal of *Hepatology*

World J Hepatol 2015 January 27; 7(1): 1-126

Published by Baishideng Publishing Group Inc

WJH World Journal of Hepatology

A peer-reviewed, online, open-access journal of hepatology

Editorial Board

2014-2017

The *World Journal of Hepatology* Editorial Board consists of 469 members, representing a team of worldwide experts in hepatology. They are from 53 countries, including Algeria (1), Argentina (6), Armenia (1), Australia (1), Austria (4), Bangladesh (2), Belgium (3), Botswana (2), Brazil (13), Bulgaria (2), Canada (3), Chile (1), China (98), Czech Repoublic (1), Denmark (2), Egypt (12), France (6), Germany (19), Greece (11), Hungary (5), India (15), Indonesia (2), Iran (4), Israel (1), Italy (52), Japan (35), Jordan (1), Malaysia (2), Mexico (3), Moldova (1), Netherlands (3), Nigeria (1), Pakistan (1), Philippines (2), Poland (1), Portugal (2), Qatar (1), Romania (6), Russia (2), Saudi Arabia (4), Singapore (1), South Korea (11), Spain (20), Sri Lanka (1), Sudan (1), Sweden (1), Switzerland (1), Thailand (4), Turkey (21), Ukraine (3), United Kingdom (17), and United States (56).

Alfonso W Avolio, *Rome*
Francesco Bellanti, *Foggia*
Marcello Bianchini, *Modena*
Guglielmo Borgia, *Naples*
Mauro Borzio, *Milano*
Enrico Brunetti, *Pavia*
Valeria Cento, *Roma*
Beatrice Conti, *Rome*
Francesco D'Amico, *Padova*
Samuele De Minicis, *Fermo*
Fabrizio De Ponti, *Bologna*
Giovan Giuseppe Di Costanzo, *Napoli*
Luca Fabris, *Padova*
Giovanna Ferraioli, *Pavia*
Andrea Galli, *Florencee*
Matteo Garcovich, *Rome*
Edoardo G Giannini, *Genova*
Rossano Girometti, *Udine*
Alessandro Granito, *Bologna*
Alberto Grassi, *Rimini*
Alessandro Grasso, *Savona*
Salvatore Gruttadauria, *Palermo*
Francesca Guerrieri, *Rome*
Quirino Lai, *Aquila*
Andrea Lisotti, *Bologna*
Marcello F Maida, *Palermo*
Lucia Malaguarnera, *Catania*
Andrea Mancuso, *Palermo*
Luca Maroni, *Ancona*
Francesco Marotta, *Milano*
Pierluigi Marzuillo, *Naples*
Sara Montagnese, *Padova*
Giuseppe Nigri, *Rome*
Claudia Piccoli, *Foggia*
Camillo Porta, *Pavia*
Chiara Raggi, *Rozzano (MI)*
Maria Rendina, *Bari*
Maria Ripoli, *San Giovanni Rotondo*
Kryssia I Rodriguez-Castro, *Padua*
Raffaella Romeo, *Milan*
Amedeo Sciarra, *Milano*
Antonio Solinas, *Sassari*
Aurelio Sonzogni, *Bergamo*
Giovanni Squadrito, *Messina*
Salvatore Sutti, *Novara*
Valentina Svicher, *Rome*
Luca Toti, *Rome*
Elvira Verduci, *Milan*
Umberto Vespasiani-Gentilucci, *Rome*
Maria A Zocco, *Rome*

Japan

Yasuhiro Asahina, *Tokyo*
Nabil AS Eid, *Takatsuki*
Kenichi Ikejima, *Tokyo*
Shoji Ikuo, *Kobe*
Yoshihiro Ikura, *Takatsuki*
Shinichi Ikuta, *Nishinomiya*
Kazuaki Inoue, *Yokohama*
Toshiya Kamiyama, *Sapporo*
Takanobu Kato, *Tokyo*
Saiho Ko, *Nara*
Haruki Komatsu, *Sakura*
Masanori Matsuda, *Chuo-city*
Yasunobu Matsuda, *Niigata*
Yoshifumi Nakayama, *Kitakyushu*
Taichiro Nishikawa, *Kyoto*
Satoshi Oeda, *Saga*
Kenji Okumura, *Urayasu*
Michitaka Ozaki, *Sapporo*
Takahiro Sato, *Sapporo*
Junichi Shindoh, *Tokyo*
Ryo Sudo, *Yokohama*
Atsushi Suetsugu, *Gifu*
Haruhiko Sugimura, *Hamamatsu*
Reiji Sugita, *Sendai*
Koichi Takaguchi, *Takamatsu*
Shinji Takai, *Takatsuki*
Akinobu Takaki, *Okayama*
Yasuhito Tanaka, *Nagoya*
Takuji Tanaka, *Gifu City*
Atsunori Tsuchiya, *Niigata*
Koichi Watashi, *Tokyo*
Hiroshi Yagi, *Tokyo*
Taro Yamashita, *Kanazawa*
Shuhei Yoshida, *Chiba*
Hitoshi Yoshiji, *Kashihara*

Jordan

Kamal E Bani-Hani, *Zarqa*

Malaysia

Peng Soon Koh, *Kuala Lumpur*
Yeong Yeh Lee, *Kota Bahru*

Mexico

Francisco J Bosques-Padilla, *Monterrey*
María de F Higuera-de la Tijera, *Mexico City*
José A Morales-Gonzalez, *México City*

Moldova

Angela Peltec, *Chishinev*

Netherlands

Wybrich R Cnossen, *Nijmegen*
Frank G Schaap, *Maastricht*
Fareeba Sheedfar, *Groningen*

Nigeria

CA Asabamaka Onyekwere, *Lagos*

Pakistan

Bikha Ram Devrajani, *Jamshoro*

Philippines

Janus P Ong, *Pasig*
JD Decena Sollano, *Manila*

Poland

Jacek Zielinski, *Gdansk*

Portugal

Rui T Marinho, *Lisboa*
Joao B Soares, *Braga*

Qatar

Reem Al Olaby, *Doha*

Romania

Bogdan Dorobantu, *Bucharest*
Liana Gheorghe, *Bucharest*
George S Gherlan, *Bucharest*
Romeo G Mihaila, *Sibiu*
Bogdan Procopet, *Cluj-Napoca*
Streba T Streba, *Craiova*

Russia

Anisa Gumerova, *Kazan*
Pavel G Tarazov, *St.Petersburg*

Saudi Arabia

Abdulrahman A Aljumah, *Riyadh*
Ihab MH Mahmoud, *Riyadh*
Ibrahim Masoodi, *Riyadh*
Mhoammad K Parvez, *Riyadh*

Singapore

Ser Yee Lee, *Singapore*

South Korea

Young-Hwa Chung, *Seoul*
Dae-Won Jun, *Seoul*
Bum-Joon Kim, *Seoul*
Do Young Kim, *Seoul*
Ji Won Kim, *Seoul*
Moon Young Kim, *Wonu*
Mi-Kyung Lee, *Suncheon*
Kwan-Kyu Park, *Daegu*
Young Nyun Park, *Seoul*
Jae-Hong Ryoo, *Seoul*
Jong Won Yun, *Kyungsan*

Spain

Ivan G Marina, *Madrid*
Juan G Acevedo, *Barcelona*
Javier Ampuero, *Sevilla*
Jaime Arias, *Madrid*
Andres Cardenas, *Barcelona*
Agustin Castiella, *Mendaro*
Israel Fernandez-Pineda, *Sevilla*
Rocio Gallego-Duran, *Sevilla*
Rita Garcia-Martinez, *Barcelona*

José M González-Navajas, *Alicante*
Juan C Laguna, *Barcelona*
Elba Llop, *Madrid*
Laura Ochoa-Callejero, *La Rioja*
Albert Pares, *Barcelona*
Sonia Ramos, *Madrid*
Francisco Rodriguez-Frias, *Córdoba*
Manuel L Rodriguez-Peralvarez, *Córdoba*
Marta R Romero, *Salamanca*
Carlos J Romero, *Madrid*
Maria Trapero-Marugan, *Madrid*

Sri Lanka

Niranga M Devanarayana, *Ragama*

Sudan

Hatim MY Mudawi, *Khartoum*

Sweden

Evangelos Kalaitzakis, *Lund*

Switzerland

Christoph A Maurer, *Liestal*

Thailand

Taned Chitapanarux, *Chiang mai*
Temduang Limpaiboon, *Khon Kaen*
Sith Phongkitkarun, *Bangkok*
Yong Poovorawan, *Bangkok*

Turkey

Osman Abbasoglu, *Ankara*
Mesut Akarsu, *Izmir*
Umit Akyuz, *Istanbul*
Hakan Alagozlu, *Sivas*
Yasemin H Balaban, *Istanbul*
Bulent Baran, *Van*
Mehmet Celikbilek, *Yozgat*
Levent Doganay, *Istanbul*
Fatih Eren, *Istanbul*
Abdurrahman Kadayifci, *Gaziantep*
Ahmet Karaman, *Kayseri*
Muhsin Kaya, *Diyarbakir*
Ozgur Kemik, *Van*
Serdar Moralioglu, *Uskudar*
A Melih Ozel, *Gebze - Kocaeli*
Seren Ozenirler, *Ankara*
Ali Sazci, *Kocaeli*
Goktug Sirin, *Kocaeli*
Mustafa Sunbul, *Samsun*
Nazan Tuna, *Sakarya*
Ozlem Yonem, *Sivas*

Ukraine

Rostyslav V Bubnov, *Kyiv*
Nazarii K Kobyliak, *Kyiv*
Igor N Skrypnyk, *Poltava*

United Kingdom

Safa Al-Shamma, *Bournemouth*
Jayantha Arnold, *Southall*
Marco Carbone, *Cambridge*
Rajeev Desai, *Birmingham*
Ashwin Dhanda, *Bristol*
Matthew Hoare, *Cambridge*
Stefan G Hubscher, *Birmingham*
Nikolaos Karidis, *London*
Lemonica J Koumbi, *London*
Patricia Lalor, *Birmingham*
Ji-Liang Li, *Oxford*
Evaggelia Liaskou, *Birmingham*
Rodrigo Liberal, *London*
Wei-Yu Lu, *Edinburgh*
Richie G Madden, *Truro*
Christian P Selinger, *Leeds*
Esther Una Cidon, *Bournemouth*

United States

Naim Alkhouri, *Cleveland*
Robert A Anders, *Baltimore*
Mohammed Sawkat Anwer, *North Grafton*
Kalyan Ram Bhamidimarri, *Miami*
Brian B Borg, *Jackson*
Ronald W Busuttil, *Los Angeles*
Andres F Carrion, *Miami*
Saurabh Chatterjee, *Columbia*
Disaya Chavalitdhamrong, *Gainesville*
Mark J Czaja, *Bronx*
Jonathan M Fenkel, *Philadelphia*
Catherine Frenette, *La Jolla*
Lorenzo Gallon, *Chicago*
Kalpana Ghoshal, *Columbus*
Grigoriy E Gurvits, *New York*
Hie-Won L Hann, *Philadelphia*
Shuang-Teng He, *Kansas City*
Wendong Huang, *Duarte*
Rachel Hudacko, *Suffern*
Lu-Yu Hwang, *Houston*
Ijaz S Jamall, *Sacramento*
Neil L Julie, *Bethesda*
Hetal Karsan, *Atlanta*
Ahmed O Kaseb, *Houston*
Zeid Kayali, *Pasadena*
Kusum K Kharbanda, *Omaha*
Timothy R Koch, *Washington*
Gursimran S Kochhar, *Cleveland*
Steven J Kovacs, *East Hanover*
Mary C Kuhns, *Abbott Park*
Jiang Liu, *Silver Spring*
Li Ma, *Stanford*
Francisco Igor Macedo, *Southfield*
Sandeep Mukherjee, *Omaha*
Natalia A Osna, *Omaha*
Jen-Jung Pan, *Houston*
Christine Pocha, *Minneapolis*
Yury Popov, *Boston*
Davide Povero, *La Jolla*
Phillip Ruiz, *Miami*
Takao Sakai, *Cleveland*
Nicola Santoro, *New Haven*
Eva Schmelzer, *Pittsburgh*
Zhongjie Shi, *Philadelphia*
Nathan J Shores, *New Orleans*
Siddharth Singh, *Rochester*
Veysel Tahan, *Iowa City*
Mehlika Toy, *Boston*
Hani M Wadei, *Jacksonville*
Gulam Waris, *North Chicago*
Ruliang Xu, *New York*
Jun Xu, *Los Angeles*
Matthew M Yeh, *Seattle*
Xuchen Zhang, *West Haven*
Lixin Zhu, *Buffalo*
Sasa Zivkovic, *Pittsburgh*

WJH World Journal of Hepatology

Contents

Monthly Volume 7 Number 1 January 27, 2015

TOPIC HIGHLIGHT

1 Diagnostic and therapeutic application of noncoding RNAs for hepatocellular carcinoma
Shibata C, Otsuka M, Kishikawa T, Ohno M, Yoshikawa T, Takata A, Koike K

7 Management of hepatocellular carcinoma: Predictive value of immunohistochemical markers for postoperative survival
Niu ZS, Niu XJ, Wang M

28 Hagen-Poiseuille's law: The link between cirrhosis, liver stiffness, portal hypertension and hepatic decompensation
Lake-Bakaar G, Ahmed M, Evenson A, Bonder A, Faintuch S, Sundaram V

33 Assessment of clinical and radiological response to sorafenib in hepatocellular carcinoma patients
Sacco R, Mismas V, Romano A, Bertini M, Bertoni M, Federici G, Metrangolo S, Parisi G, Tumino E, Bresci G, Giacomelli L, Marceglia S, Bargellini I

40 Review of preoperative transarterial chemoembolization for resectable hepatocellular carcinoma
Gao ZH, Bai DS, Jiang GQ, Jin SJ

44 Adiponectin serum level in chronic hepatitis C infection and therapeutic profile
Peta V, Torti C, Milic N, Focà A, Abenavoli L

53 Immune mechanisms of vaccine induced protection against chronic hepatitis C virus infection in chimpanzees
Verstrepen BE, Boonstra A, Koopman G

70 Surgical approach for hepatitis C virus-related hepatocellular carcinoma
Shindoh J, Hashimoto M, Watanabe G

78 Hepatitis C and kidney disease: An overview and approach to management
Azmi AN, Tan SS, Mohamed R

93 From minimal to maximal surgery in the treatment of hepatocarcinoma: A review
Perini MV, Starkey G, Fink MA, Bhandari R, Muralidharan V, Jones R, Christophi C

REVIEW

101 Role of radiotherapy in the management of hepatocellular carcinoma: A systematic review
Kalogeridi MA, Zygogianni A, Kyrgias G, Kouvaris J, Chatziioannou S, Kelekis N, Kouloulias V

MINIREVIEWS

113 Clinical utility of complex mutations in the core promoter and proximal precore regions of the hepatitis B virus genome
Park YM

121 HBV and HIV co-infection: Impact on liver pathobiology and therapeutic approaches
Parvez MK

World Journal of Hepatology
Volume 7 Number 1 January 27, 2015

Contents

ABOUT COVER Editorial Board Member of *World Journal of Hepatology*, Runjan Chetty, BM BCh, DPhil, FACP, FRCP(C), FRCPA, Director, Professor, Department of Pathology, University Health Network/University of Toronto, Toronto M5G 2C4, Canada

AIM AND SCOPE

INDEXING/ ABSTRACTING

FLYLEAF I-IV Editorial Board

World Journal of Hepatology (*World J Hepatol*, *WJH*, online ISSN 1948-5182, DOI: 10.4254), is a peer-reviewed open access academic journal that aims to guide clinical practice and improve diagnostic and therapeutic skills of clinicians.

WJH covers topics concerning liver biology/pathology, cirrhosis and its complications, liver fibrosis, liver failure, portal hypertension, hepatitis B and C and inflammatory disorders, steatohepatitis and metabolic liver disease, hepatocellular carcinoma, biliary tract disease, autoimmune disease, cholestatic and biliary disease, transplantation, genetics, epidemiology, microbiology, molecular and cell biology, nutrition, geriatric and pediatric hepatology, diagnosis and screening, endoscopy, imaging, and advanced technology. Priority publication will be given to articles concerning diagnosis and treatment of hepatology diseases. The following aspects are covered: Clinical diagnosis, laboratory diagnosis, differential diagnosis, imaging tests, pathological diagnosis, molecular biological diagnosis, immunological diagnosis, genetic diagnosis, functional diagnostics, and physical diagnosis; and comprehensive therapy, drug therapy, surgical therapy, interventional treatment, minimally invasive therapy, and robot-assisted therapy.

We encourage authors to submit their manuscripts to *WJH*. We will give priority to manuscripts that are supported by major national and international foundations and those that are of great basic and clinical significance.

World Journal of Hepatology is now indexed in PubMed Central, PubMed, Digital Object Identifier, Directory of Open Access Journals, and Scopus.

NAME OF JOURNAL
World Journal of Hepatology

ISSN
ISSN 1948-5182 (online)

LAUNCH DATE
October 31, 2009

FREQUENCY
Monthly

EDITORIAL OFFICE
Jin-Lei Wang, Director
Xiu-Xia Song, Vice Director
World Journal of Hepatology
Room 903, Building D, Ocean International Center, No. 62 Dongsihuan Zhonglu, Chaoyang District, Beijing 100025, China
Telephone: +86-10-59080039
Fax: +86-10-85381893
E-mail: editorialoffice@wjgnet.com
Help Desk: http://www.wjgnet.com/esps/helpdesk.aspx
http://www.wjgnet.com

PUBLISHER
Baishideng Publishing Group Inc
8226 Regency Drive,
Pleasanton, CA 94588, USA
Telephone: +1-925-223-8242
Fax: +1-925-223-8243
E-mail: bpgoffice@wjgnet.com
Help Desk: http://www.wjgnet.com/esps/helpdesk.aspx
http://www.wjgnet.com

PUBLICATION DATE
January 27, 2015

INSTRUCTIONS TO AUTHORS
Full instructions are available online at http://www.wjgnet.com/1948-5182/g_info_20100316080002.htm

ONLINE SUBMISSION
http://www.wjgnet.com/esps/

World Journal of Hepatology

Submit a Manuscript: http://www.wjgnet.com/esps/
Help Desk: http://www.wjgnet.com/esps/helpdesk.aspx
DOI: 10.4254/wjh.v7.i1.1

World J Hepatol 2015 January 27; 7(1): 1-6
ISSN 1948-5182 (online)

TOPIC HIGHLIGHT

WJH 6th Anniversary Special Issues (1): Management of hepatocellular carcinoma

Diagnostic and therapeutic application of noncoding RNAs for hepatocellular carcinoma

Chikako Shibata, Motoyuki Otsuka, Takahiro Kishikawa, Motoko Ohno, Takeshi Yoshikawa, Akemi Takata, Kazuhiko Koike

Chikako Shibata, Motoyuki Otsuka, Takahiro Kishikawa, Motoko Ohno, Takeshi Yoshikawa, Akemi Takata, Kazuhiko Koike, Department of Gastroenterology, Graduate School of Medicine, The University of Tokyo, Tokyo 113-8655, Japan
Motoyuki Otsuka, Japan Science and Technology Agency, PRESTO, Kawaguchi, Saitama 332-0012, Japan
Author contributions: Shibata C, Otsuka M and Koike K designed and wrote the manuscript; Kishikawa T, Ohno M, Yoshikawa T and Takata A prepared the tables and references.
Supported by Grants-in-Aid from the Ministry of Education, Culture, Sports, Science and Technology, Japan, Nos. #25293076, #26860492, #25860520, and #24390183 (to Otsuka M, Kishikawa T, Yoshikawa T and Koike K); by Health Sciences Research Grants of The Ministry of Health, Labour and Welfare of Japan (to Koike K); by grants from the Japanese Society of Gastroenterology, Okinaka Memorial Institute for Medical Research, and Honjo International Scholarship Foundation (to Otsuka M); by a grant from the Mishima Kaiun Memorial Foundation (to Ohno M)

Correspondence to: Motoyuki Otsuka, MD, Department of Gastroenterology, Graduate School of Medicine, The University of Tokyo, 5-3-1 Hongo, Bunkyo-ku, Tokyo 113-8655, Japan. otsukamo-tky@umin.ac.jp
Telephone: +81-3-38155411
Fax: +81-3-38140021
Received: August 19, 2014
Peer-review started: August 20, 2014
First decision: September 16, 2014
Revised: September 21, 2014
Accepted: November 17, 2014
Article in press: November 19, 2014
Published online: January 27, 2015

Abstract

MicroRNAs (miRNAs) are small, noncoding RNA molecules that regulate gene expression posttranscriptionally, targeting thousands of messenger RNAs. Long noncoding RNAs (lncRNAs), another class of noncoding RNAs, have been determined to be also involved in transcription regulation and translation of target genes. Since deregulated expression levels or functions of miRNAs and lncRNAs in hepatocellular carcinoma (HCC) are frequently observed, clinical use of noncoding RNAs for novel diagnostic and therapeutic applications in the management of HCCs is highly and emergently expected. Here, we summarize recent findings regarding deregulated miRNAs and lncRNAs for their potential clinical use as diagnostic and prognostic biomarkers of HCC. Specifically, we emphasize the deregulated expression levels of such noncoding RNAs in patients' sera as noninvasive biomarkers, a field that requires urgent improvement in the clinical surveillance of HCC. Since nucleotide-based strategies are being applied to clinical therapeutics, we further summarize clinical and preclinical trials using oligonucleotides involving the use of miRNAs and small interfering RNAs against HCC as novel therapeutics. Finally, we discuss current open questions, which must be clarified in the near future for realistic clinical applications of these new strategies.

Key words: MicroRNA; Long noncoding RNA; Hepatocellular carcinoma; Clinical trials; Biomarker

Core tip: In this review, we summarize the latest findings on deregulated microRNAs (miRNAs) and long noncoding RNAs in hepatocellular carcinomas (HCCs) with a focus on their clinical use as novel diagnostic and prognostic

biomarkers. In addition, we summarize the current status of clinical and preclinical oligonucleotide therapies including miRNAs and small interfering RNAs as novel HCC therapeutics. This review will enable the readers to understand the current status of clinical applications and knowledge of noncoding RNAs in HCC management.

Shibata C, Otsuka M, Kishikawa T, Ohno M, Yoshikawa T, Takata A, Koike K. Diagnostic and therapeutic application of noncoding RNAs for hepatocellular carcinoma. *World J Hepatol* 2015; 7(1): 1-6 Available from: URL: http://www.wjgnet.com/1948-5182/full/v7/i1/1.htm DOI: http://dx.doi.org/10.4254/wjh.v7.i1.1

INTRODUCTION

Noncoding RNAs contain multiple classes of RNAs that are not transcribed into proteins. While most noncoding RNAs studied to date are microRNAs (miRNAs), many noncoding RNAs with various lengths have also been reported.

MiRNAs are short, single-stranded RNAs that are expressed in most organisms[1-3]. Through gene expression regulation at a posttranscriptional level, miRNAs are involved in various physiological and pathological processes[4,5]. Since the discovery of miRNA lin-4 in Caenorhabditis elegans[6,7], as of August 2014, 1881 miRNA precursors and 2588 mature miRNA sequences in humans are deposited in miRBase, a miRNA database by the Sanger Institute[8]. MiRNAs are dysregulated in nearly all types of cancer[9,10], and specific signatures of aberrantly expressed miRNAs in specific cancers may have diagnostic and therapeutic implications[11,12].

Long noncoding RNAs (lncRNAs) also play crucial roles in transcription and translation[13,14]. Similar to miRNAs, their dysregulation is also associated with human cancers[15]. One of the most well-studied lncRNAs is the *HOX* transcript antisense intergenic RNA (HOTAIR). Class I homeobox genes (*HOX* in humans) encode 39 transcriptional factors initially described as master regulators of embryonic development[16] and display a unique gene network organization. HOTAIR, a 2.2-kb-long RNA residing within the *HOXC* locus, was initially described in breast cancer tissues, where it is highly expressed[17]. In addition to HOTAIR, many other lncRNAs are dysregulated in cancer tissues. Thus, lncRNAs may also be candidates for biomarker discovery and therapeutic applications in hepatocellular carcinomas (HCCs)[18].

In contrast to miRNAs and lncRNAs, short interfering RNAs (siRNAs) are double-stranded RNAs that degrade mRNAs through perfect matches with their target sequences. Although human telomerase reverse transcriptase was recently found to function as an RNA-dependent RNA polymerase and contribute to RNA silencing[19], its activities are not dominant in mammals. Additionally, endogenously produced siRNAs may play functional roles under limited circumstances in humans[20]. However, the exogenous application of synthesized siRNAs is an attractive method that could be used to intervene in crucial gene expression under pathological conditions, including cancers[21].

HCC is the third leading cause of cancer-related mortality worldwide[22]. Although advances have been made in early detection and interventional therapies, a continuing need exists to develop novel approaches for the management of advanced HCC[23]. While many reports have described deregulated expression levels or functions of miRNAs and lncRNAs in HCCs, we will focus on the potential clinical use of noncoding RNAs in the very near future for novel diagnostic and therapeutic applications in the management of HCCs.

NONCODING RNAS AS BIOMARKERS FOR HCC

Deregulated expression levels of noncoding RNAs in HCC tissues

Although several published reports have described deregulated expression levels of miRNAs and lncRNAs in HCC tissues[18,24,25], the data thus far vary greatly. The differences may be because of several reasons, including the use of different techniques or samples as controls, normal liver tissues *vs* nonneoplastic tissues around tumors, background livers with various fibrosis staging, inflammation activities, or etiologies, such as hepatitis B, hepatitis C, or steatohepatitis, as well as the age or sex of the tissue-derived patients; any of these factors may cause the differential expression status of miRNAs. Regardless of these limitations, the plenty data about dysregulated miRNAs in HCCs suggests that noncoding RNAs play crucial roles in hepatocarcinogenesis[24].

Deregulated expression of noncoding RNAs in HCC as prognostic/diagnostic markers

Deregulated expression levels of noncoding RNAs in HCC tissues that may be clinically useful as prognostic/diagnostic markers will be described herein. The landmark paper that initially addressed this issue focused on *miR26* expression levels in HCC tissues and was published in the New England Journal of Medicine[26]. In this study, HCC showed frequently reduced levels of *miR26*, and patients exhibited low *miR26* expression with a shorter overall survival but a better response to interferon therapy, indicating that miRNA expression status is associated with survival and response to therapy.

Expression levels of miRNAs have tissue specificities. In the liver, *miR122*, *miR192*, and *miR199a/b-3p* are highly expressed miRNAs of all mRNAs in the liver[27]. The role of *miR122* loss in hepatocarcinogenesis was confirmed in a mouse model[28,29], and its expression is decreased in HCCs, especially non-viral HCCs[27]. Decreased expression of *miR122* is also linked with poor prognosis of HCC[30]. Although *miR192* was not deregulated in HCCs in previous studies, *miR199a/b-3p*

Table 1 Representative noncoding RNAs in sera for Hepatocellular carcinoma diagnosis

MiRNA	Expression levels in HCC	Possible targets	Ref.
MiR21	Upregulated	PTEN, AKT, C/EBPb	[32,39,58]
MiR222	Upregulated	PP2A, p27, DDIT4	[42,43,59]
MiR223	Upregulated	Stathmin	[44]
HULC	Upregulated	IGF2BP1	[45-47]

HCC: Hepatocellular carcinoma; HULC: Highly up-regulated in liver cancer; PTEN: Phosphatase and tensin-like protein; AKT: V-akt murine thymoma viral oncogene homolog; C/EBPb: CCAAT/enhancer-binding protein beta; PP2A: Protein phosphatase 2A; IGF2BP1: Insulin-like growth factor 2 MRNA binding protein 1.

is frequently decreased in HCCs[27]. In contrast, *miR21*, whose expression is increased when rat hepatectomy[31], is upregulated as an onco-miRNA, resulting in the promotion of HCC[32]. *MiR21* expression in HCC tissues confers resistance to the antitumor effect of interferon-α and 5FU combination therapy[33].

Similar to miRNAs, expression levels of lncRNAs are also dysregulated in HCC tissues[18]. Among them, HOTAIR is overexpressed in HCC tissues and may confer chemoresistance[34]. Metastasis-associated lung adenocarcinoma transcript 1, which was initially discovered as an lncRNA associated with metastasis[35], is also upregulated in HCC tissues and may be useful as a biomarker for tumor recurrence. Recently, *HOXA* transcript at the distal tip (HOTTIP) was discovered to be located in physical contiguity with the *HOXA13* gene and upregulated in HCC tissues, and this was also associated with metastasis formation and poor patient survival[36]. These results show the functional importance of lncRNA dysregulation in HCC tissues and indicate their possible use as novel prognostic and diagnostic biomarkers.

Noncoding RNAs in the sera of patients with HCC as diagnostic markers

Although α-fetoprotein (AFP), AFP-L3, and des-gamma-carboxy prothrombin are useful noninvasive biomarkers for HCC surveillance[37], novel and sensitive biomarkers that can detect early HCC are needed. The identification of tumor-specific alterations in circulating nucleic acids of patients with cancer as noninvasive methods of cancer diagnosis is encouraging[38]. Although RNAs are generally considered unstable, they are actually quite stable and readily detected in patient serum and plasma. Microarrays, polymerase chain reaction methods, and next-generation sequencing technologies are generally utilized to detect circulating noncoding RNAs.

Although many reports have described circulating miRNA levels in patients with HCC, only a few tests have been reproducible. For example, data regarding upregulation of circulating *miR21*, *miR222*, and *miR223* in patients with HCC are inconsistent[32,33,38-44]. Highly upregulated in liver cancer, a 1.6-kb lncRNA, is also upregulated in HCC tissues[45-47] and is detected in the plasma of patients with HCC[18,48]. Although these results are encouraging, more work is needed to make the usability of circulating noncoding RNAs as novel biomarkers more reliable (Table 1). Specificity and sensitivity, as well as methods to quantitate small amounts of RNAs in sera with high reproducibility and the universal control to adjust the obtained data from differing times and samples, need to be urgently determined[49].

NONCODING RNAS AS NOVEL THERAPEUTICS AGAINST HCC

Ongoing clinical trials

Mounting evidence suggests that noncoding RNAs are frequently dysregulated in HCCs and possibly involved in oncogenesis and may therefore provide novel molecular targets as a therapeutic intervention. However, due to the complexity associated with pleiotropic miRNA functions and lncRNAs, the number of clinical trials is presently limited[50]. The leading nucleotide-targeting therapy, Miravirsen, an LNA-based *anti-miR122* against hepatitis C virus replication, has been successful in a Phase Ⅱa study[51]. In addition, MRX34, a liposome-formulated *miR-34* mimic developed by Mirna Therapeutics, produced complete HCC regression in mouse models[52], and a Phase I study is currently recruiting patients with advanced liver cancer for HCC therapeutic intervention (NCT01829971).

While siRNAs are not endogenous noncoding RNAs, they can be described as noncoding RNAs that have been tried as novel therapeutics against HCC. ALN-VSP (Alnylam Pharmaceuticals), an RNAi therapeutic targeting vascular endothelial growth factor and kinesin spindle protein, has been shown to be well tolerated in Phase I studies (NCT008822180 and NCT01158079) for the treatment of primary and metastatic liver cancer. The results demonstrated disease control lasting more than 6 mo in the majority of patients, including a complete response in a patient with endometrial cancer who had multiple liver metastases. TMK-polo-like kinase 1 (PLK1) (Tekmira Pharmaceuticals), an RNAi targeting PLK1, is also under a Phase Ⅰ/Ⅱ trial (NCT01437007). Early results show that TKM-PLK is well tolerated and demonstrates clinical benefits. Although primary results from these potential therapeutics are encouraging, the benefits and unexpected side effects need to be determined, especially under long-term use.

Preclinical trials

Anti-miR21 and *anti-miR221* are under development for clinical use (Regulus Therapeutics). *MiR21* is one of the most validated microRNA targets, with numerous scientific publications suggesting that *miR21* plays an important role in the initiation and progression of cancers, including liver cancer[32,53,54]. Similarly, *miR221* has been identified to be upregulated in multiple cancers including liver cancer[54-56]. *Anti-miR21* and *anti-miR221* prolonged survival time in a preclinical mouse model

Table 2 Representative noncoding RNAs under clinical and preclinical trials for hepatocellular carcinoma therapeutics

Target	Name	Content	Vendor	Current status
MiR34	MRX34	Liposome-formulated miR-34 mimic	Mirna Therapeutics	Phase Ⅰ
VEGF/KSP	ALN-VSP	RNAi targeting VEGF/KSP	Alnylam Pharmaceuticals	Phase Ⅰ
PLK1	TMK-PLK1	RNAi targeting PLK1	Tekmira Pharmaceuticals	Phase Ⅰ/Ⅱ
MiR21	Anti-miR21	Antisense against miR21	Regulus Therapeutics	Preclinical
MiR221	Anti-miR221	Antisense against miR221	Regulus Therapeutics	Preclinical
MiR7	MiR7 mimic	MiR7 mimic	MiReven	Preclinical

VEGF: Vascular endothelial growth factor; KSP: Kidney-specific cadherin; PLK1: Polo-like kinase 1.

that genetically develops HCC. An *miR7* mimic is also under development (MiReven). Mir7 targets the phosphoinositide 3-kinase (PI3K) pathway and decreases tumor growth both *in vitro* and *in vivo*[57]. These results are summarized in Table 2.

CHALLENGES FOR BETTER CLINICAL TRANSLATION

Several other miRNAs, including lncRNAs, which are dysregulated in HCCs, can be attractive therapeutic targets by RNA mimics, antisense RNA, or siRNA. In fact, many publications have reported their efficacy. However, obstacles remain to be addressed[24]: (1) The more reproducibility of the results should be achieved to make the data more reliable; (2) Identification of driver miRNAs in oncogenesis is important to develop therapeutics targeting such miRNAs, although we may be able to use passive miRNAs as prognostic and diagnostic bio-markers; and (3) The delivery methods of oligonucleotides into specific tissues with improved oligonucleotide modification, and safety need to be seriously considered for utilizing miRNAs in clinical applications. Because miRNAs generally target multiple mRNAs, unexpected outcomes, "off-target effects," may occur, even when targeting a single miRNA.

More research to solve these issues is definitely needed for the improved translational application utilizing the data about miRNAs in HCCs.

CONCLUSION

The discovery of miRNAs and lncRNAs has opened up new possibilities for novel diagnostic and therapeutic tools against HCCs. However, several important issues remain to be resolved. We must conduct continuous research to develop innovative and useful applications of the miRNA data in the clinical management of HCCs.

REFERENCES

1 **Ebert MS**, Sharp PA. Roles for microRNAs in conferring robustness to biological processes. *Cell* 2012; **149**: 515-524 [PMID: 22541426 DOI: 10.1016/j.cell.2012.04.005]

2 **Cech TR**, Steitz JA. The noncoding RNA revolution-trashing old rules to forge new ones. *Cell* 2014; **157**: 77-94 [PMID: 24679528 DOI: 10.1016/j.cell.2014.03.008]

3 **Mendell JT**, Olson EN. MicroRNAs in stress signaling and human disease. *Cell* 2012; **148**: 1172-1187 [PMID: 22424228 DOI: 10.1016/j.cell.2012.02.005]

4 **Ambros V**. The functions of animal microRNAs. *Nature* 2004; **431**: 350-355 [PMID: 15372042 DOI: 10.1038/nature02871]

5 **Bartel DP**. MicroRNAs: genomics, biogenesis, mechanism, and function. *Cell* 2004; **116**: 281-297 [PMID: 14744438 DOI: 10.1016/S0092-8674(04)00045-5]

6 **Lee RC**, Feinbaum RL, Ambros V. The C. elegans heterochronic gene lin-4 encodes small RNAs with antisense complementarity to lin-14. *Cell* 1993; **75**: 843-854 [PMID: 8252621 DOI: 10.1016/0092-8674(93)90529-Y]

7 **Wightman B**, Ha I, Ruvkun G. Posttranscriptional regulation of the heterochronic gene lin-14 by lin-4 mediates temporal pattern formation in C. elegans. *Cell* 1993; **75**: 855-862 [PMID: 8252622 DOI: 10.1016/0092-8674(93)90530-4]

8 **Kozomara A**, Griffiths-Jones S. miRBase: integrating microRNA annotation and deep-sequencing data. *Nucleic Acids Res* 2011; **39**: D152-D157 [PMID: 21037258 DOI: 10.1093/nar/gkq1027]

9 **Lu J**, Getz G, Miska EA, Alvarez-Saavedra E, Lamb J, Peck D, Sweet-Cordero A, Ebert BL, Mak RH, Ferrando AA, Downing JR, Jacks T, Horvitz HR, Golub TR. MicroRNA expression profiles classify human cancers. *Nature* 2005; **435**: 834-838 [PMID: 15944708 DOI: 10.1038/nature03702]

10 **Volinia S**, Calin GA, Liu CG, Ambs S, Cimmino A, Petrocca F, Visone R, Iorio M, Roldo C, Ferracin M, Prueitt RL, Yanaihara N, Lanza G, Scarpa A, Vecchione A, Negrini M, Harris CC, Croce CM. A microRNA expression signature of human solid tumors defines cancer gene targets. *Proc Natl Acad Sci USA* 2006; **103**: 2257-2261 [PMID: 16461460 DOI: 10.1073/pnas.0510565103]

11 **Esteller M**. Non-coding RNAs in human disease. *Nat Rev Genet* 2011; **12**: 861-874 [PMID: 22094949 DOI: 10.1038/nrg3074]

12 **Ling H**, Fabbri M, Calin GA. MicroRNAs and other non-coding RNAs as targets for anticancer drug development. *Nat Rev Drug Discov* 2013; **12**: 847-865 [PMID: 24172333 DOI: 10.1038/nrd4140]

13 **Wilusz JE**, Sunwoo H, Spector DL. Long noncoding RNAs: functional surprises from the RNA world. *Genes Dev* 2009; **23**: 1494-1504 [PMID: 19571179 DOI: 10.1101/gad.1800909]

14 **Kung JT**, Colognori D, Lee JT. Long noncoding RNAs: past, present, and future. *Genetics* 2013; **193**: 651-669 [PMID: 23463798 DOI: 10.1534/genetics.112.146704]

15 **Gutschner T**, Diederichs S. The hallmarks of cancer: a long non-coding RNA point of view. *RNA Biol* 2012; **9**: 703-719 [PMID: 22664915 DOI: 10.4161/rna.20481]

16 **Graham A**, Papalopulu N, Krumlauf R. The murine and Drosophila homeobox gene complexes have common features of organization and expression. *Cell* 1989; **57**: 367-378 [PMID: 2566383]

17 **Gupta RA**, Shah N, Wang KC, Kim J, Horlings HM, Wong DJ, Tsai MC, Hung T, Argani P, Rinn JL, Wang Y, Brzoska P, Kong B, Li R, West RB, van de Vijver MJ, Sukumar S, Chang HY. Long non-coding RNA HOTAIR reprograms chromatin state to promote cancer metastasis. *Nature* 2010;

464: 1071-1076 [PMID: 20393566 DOI: 10.1038/nature08975]
18 **He Y**, Meng XM, Huang C, Wu BM, Zhang L, Lv XW, Li J. Long noncoding RNAs: Novel insights into hepatocelluar carcinoma. *Cancer Lett* 2014; **344**: 20-27 [PMID: 24183851 DOI: 10.1016/j.canlet.2013.10.021]
19 **Maida Y**, Yasukawa M, Furuuchi M, Lassmann T, Possemato R, Okamoto N, Kasim V, Hayashizaki Y, Hahn WC, Masutomi K. An RNA-dependent RNA polymerase formed by TERT and the RMRP RNA. *Nature* 2009; **461**: 230-235 [PMID: 19701182 DOI: 10.1038/nature08283]
20 **Watanabe T**, Totoki Y, Toyoda A, Kaneda M, Kuramochi-Miyagawa S, Obata Y, Chiba H, Kohara Y, Kono T, Nakano T, Surani MA, Sakaki Y, Sasaki H. Endogenous siRNAs from naturally formed dsRNAs regulate transcripts in mouse oocytes. *Nature* 2008; **453**: 539-543 [PMID: 18404146 DOI: 10.1038/nature06908]
21 **Sehgal A**, Vaishnaw A, Fitzgerald K. Liver as a target for oligonucleotide therapeutics. *J Hepatol* 2013; **59**: 1354-1359 [PMID: 23770039 DOI: 10.1016/j.jhep.2013.05.045]
22 **Parkin DM**, Bray F, Ferlay J, Pisani P. Global cancer statistics, 2002. *CA Cancer J Clin* 2005; **55**: 74-108 [PMID: 15761078]
23 **Greten TF**, Korangy F, Manns MP, Malek NP. Molecular therapy for the treatment of hepatocellular carcinoma. *Br J Cancer* 2009; **100**: 19-23 [PMID: 19018262]
24 **Otsuka M**, Kishikawa T, Yoshikawa T, Ohno M, Takata A, Shibata C, Koike K. The role of microRNAs in hepato-carcinogenesis: current knowledge and future prospects. *J Gastroenterol* 2014; **49**: 173-184 [PMID: 24258409 DOI: 10.1007/s00535-013-0909-8]
25 **Petrelli A**, Perra A, Cora D, Sulas P, Menegon S, Manca C, Migliore C, Kowalik MA, Ledda-Columbano GM, Giordano S, Columbano A. MicroRNA/gene profiling unveils early molecular changes and nuclear factor erythroid related factor 2 (NRF2) activation in a rat model recapitulating human hepatocellular carcinoma (HCC). *Hepatology* 2014; **59**: 228-241 [PMID: 23857252 DOI: 10.1002/hep.26616]
26 **Ji J**, Shi J, Budhu A, Yu Z, Forgues M, Roessler S, Ambs S, Chen Y, Meltzer PS, Croce CM, Qin LX, Man K, Lo CM, Lee J, Ng IO, Fan J, Tang ZY, Sun HC, Wang XW. MicroRNA expression, survival, and response to interferon in liver cancer. *N Engl J Med* 2009; **361**: 1437-1447 [PMID: 19812400 DOI: 10.1056/NEJMoa0901282]
27 **Hou J**, Lin L, Zhou W, Wang Z, Ding G, Dong Q, Qin L, Wu X, Zheng Y, Yang Y, Tian W, Zhang Q, Wang C, Zhang Q, Zhuang SM, Zheng L, Liang A, Tao W, Cao X. Identification of miRNomes in human liver and hepatocellular carcinoma reveals miR-199a/b-3p as therapeutic target for hepatocellular carcinoma. *Cancer Cell* 2011; **19**: 232-243 [PMID: 21316602 DOI: 10.1016/j.ccr.2011.01.001]
28 **Hsu SH**, Wang B, Kota J, Yu J, Costinean S, Kutay H, Yu L, Bai S, La Perle K, Chivukula RR, Mao H, Wei M, Clark KR, Mendell JR, Caligiuri MA, Jacob ST, Mendell JT, Ghoshal K. Essential metabolic, anti-inflammatory, and anti-tumorigenic functions of miR-122 in liver. *J Clin Invest* 2012; **122**: 2871-2883 [PMID: 22820288]
29 **Tsai WC**, Hsu SD, Hsu CS, Lai TC, Chen SJ, Shen R, Huang Y, Chen HC, Lee CH, Tsai TF, Hsu MT, Wu JC, Huang HD, Shiao MS, Hsiao M, Tsou AP. MicroRNA-122 plays a critical role in liver homeostasis and hepatocarcinogenesis. *J Clin Invest* 2012; **122**: 2884-2897 [PMID: 22820290]
30 **Kojima K**, Takata A, Vadnais C, Otsuka M, Yoshikawa T, Akanuma M, Kondo Y, Kang YJ, Kishikawa T, Kato N, Xie Z, Zhang WJ, Yoshida H, Omata M, Nepveu A, Koike K. MicroRNA122 is a key regulator of α-fetoprotein expression and influences the aggressiveness of hepatocellular carcinoma. *Nat Commun* 2011; **2**: 338 [PMID: 21654638 DOI: 10.1038/ncomms1345]
31 **Castro RE**, Ferreira DM, Zhang X, Borralho PM, Sarver AL, Zeng Y, Steer CJ, Kren BT, Rodrigues CM. Identification of microRNAs during rat liver regeneration after partial hepatectomy and modulation by ursodeoxycholic acid. *Am J Physiol Gastrointest Liver Physiol* 2010; **299**: G887-G897 [PMID: 20689055 DOI: 10.1152/ajpgi.00216.2010]
32 **Meng F**, Henson R, Wehbe-Janek H, Ghoshal K, Jacob ST, Patel T. MicroRNA-21 regulates expression of the PTEN tumor suppressor gene in human hepatocellular cancer. *Gastroenterology* 2007; **133**: 647-658 [PMID: 17681183 DOI: 10.1053/j.gastro.2007.05.022]
33 **Tomimaru Y**, Eguchi H, Nagano H, Wada H, Tomokuni A, Kobayashi S, Marubashi S, Takeda Y, Tanemura M, Umeshita K, Doki Y, Mori M. MicroRNA-21 induces resistance to the anti-tumour effect of interferon-α/5-fluorouracil in hepatocellular carcinoma cells. *Br J Cancer* 2010; **103**: 1617-1626 [PMID: 20978511 DOI: 10.1038/sj.bjc.6605958]
34 **Yang F**, Zhang L, Huo XS, Yuan JH, Xu D, Yuan SX, Zhu N, Zhou WP, Yang GS, Wang YZ, Shang JL, Gao CF, Zhang FR, Wang F, Sun SH. Long noncoding RNA high expression in hepatocellular carcinoma facilitates tumor growth through enhancer of zeste homolog 2 in humans. *Hepatology* 2011; **54**: 1679-1689 [PMID: 21769904 DOI: 10.1002/hep.24563]
35 **Ji P**, Diederichs S, Wang W, Böing S, Metzger R, Schneider PM, Tidow N, Brandt B, Buerger H, Bulk E, Thomas M, Berdel WE, Serve H, Müller-Tidow C. MALAT-1, a novel noncoding RNA, and thymosin beta4 predict metastasis and survival in early-stage non-small cell lung cancer. *Oncogene* 2003; **22**: 8031-8041 [PMID: 12970751 DOI: 10.1038/sj.onc.1206928]
36 **Quagliata L**, Matter MS, Piscuoglio S, Arabi L, Ruiz C, Procino A, Kovac M, Moretti F, Makowska Z, Boldanova T, Andersen JB, Hämmerle M, Tornillo L, Heim MH, Diederichs S, Cillo C, Terracciano LM. Long noncoding RNA HOTTIP/HOXA13 expression is associated with disease progression and predicts outcome in hepatocellular carcinoma patients. *Hepatology* 2014; **59**: 911-923 [PMID: 24114970 DOI: 10.1002/hep.26740]
37 **Huang J**, Zeng Y. Current clinical uses of the biomarkers for hepatocellular carcinoma. *Drug Discov Ther* 2014; **8**: 98-99 [PMID: 24815586 DOI: 10.5582/ddt.8.98]
38 **Qu KZ**, Zhang K, Li H, Afdhal NH, Albitar M. Circulating microRNAs as biomarkers for hepatocellular carcinoma. *J Clin Gastroenterol* 2011; **45**: 355-360 [PMID: 21278583 DOI: 10.1097/MCG.0b013e3181f18ac2]
39 **Xu J**, Wu C, Che X, Wang L, Yu D, Zhang T, Huang L, Li H, Tan W, Wang C, Lin D. Circulating microRNAs, miR-21, miR-122, and miR-223, in patients with hepatocellular carcinoma or chronic hepatitis. *Mol Carcinog* 2011; **50**: 136-142 [PMID: 21229610 DOI: 10.1002/mc.20712]
40 **Li J**, Wang Y, Yu W, Chen J, Luo J. Expression of serum miR-221 in human hepatocellular carcinoma and its prognostic significance. *Biochem Biophys Res Commun* 2011; **406**: 70-73 [PMID: 21295551 DOI: 10.1016/j.bbrc.2011.01.111]
41 **Tomimaru Y**, Eguchi H, Nagano H, Wada H, Kobayashi S, Marubashi S, Tanemura M, Tomokuni A, Takemasa I, Umeshita K, Kanto T, Doki Y, Mori M. Circulating microRNA-21 as a novel biomarker for hepatocellular carcinoma. *J Hepatol* 2012; **56**: 167-175 [PMID: 21749846 DOI: 10.1016/j.jhep.2011.04.026]
42 **Qi P**, Cheng SQ, Wang H, Li N, Chen YF, Gao CF. Serum microRNAs as biomarkers for hepatocellular carcinoma in Chinese patients with chronic hepatitis B virus infection. *PLoS One* 2011; **6**: e28486 [PMID: 22174818 DOI: 10.1371/journal.pone.0028486]
43 **Wong QW**, Ching AK, Chan AW, Choy KW, To KF, Lai PB, Wong N. MiR-222 overexpression confers cell migratory advantages in hepatocellular carcinoma through enhancing AKT signaling. *Clin Cancer Res* 2010; **16**: 867-875 [PMID: 20103675 DOI: 10.1158/1078-0432.CCR-09-1840]
44 **Wong QW**, Lung RW, Law PT, Lai PB, Chan KY, To KF, Wong N. MicroRNA-223 is commonly repressed in hepatocellular carcinoma and potentiates expression of

Stathmin1. *Gastroenterology* 2008; **135**: 257-269 [PMID: 18555017 DOI: 10.1053/j.gastro.2008.04.003]

45 **Hämmerle M**, Gutschner T, Uckelmann H, Ozgur S, Fiskin E, Gross M, Skawran B, Geffers R, Longerich T, Breuhahn K, Schirmacher P, Stoecklin G, Diederichs S. Posttranscriptional destabilization of the liver-specific long noncoding RNA HULC by the IGF2 mRNA-binding protein 1 (IGF2BP1). *Hepatology* 2013; **58**: 1703-1712 [PMID: 23728852 DOI: 10.1002/hep.26537]

46 **Panzitt K**, Tschernatsch MM, Guelly C, Moustafa T, Stradner M, Strohmaier HM, Buck CR, Denk H, Schroeder R, Trauner M, Zatloukal K. Characterization of HULC, a novel gene with striking up-regulation in hepatocellular carcinoma, as noncoding RNA. *Gastroenterology* 2007; **132**: 330-342 [PMID: 17241883 DOI: 10.1053/j.gastro.2006.08.026]

47 **Liu Y**, Pan S, Liu L, Zhai X, Liu J, Wen J, Zhang Y, Chen J, Shen H, Hu Z. A genetic variant in long non-coding RNA HULC contributes to risk of HBV-related hepatocellular carcinoma in a Chinese population. *PLoS One* 2012; **7**: e35145 [PMID: 22493738 DOI: 10.1371/journal.pone.0035145]

48 **Xie H**, Ma H, Zhou D. Plasma HULC as a promising novel biomarker for the detection of hepatocellular carcinoma. *Biomed Res Int* 2013; **2013**: 136106 [PMID: 23762823 DOI: 10.1155/2013/136106]

49 **Zhang LY**, Liu M, Li X, Tang H. miR-490-3p modulates cell growth and epithelial to mesenchymal transition of hepatocellular carcinoma cells by targeting endoplasmic reticulum-Golgi intermediate compartment protein 3 (ERGIC3). *J Biol Chem* 2013; **288**: 4035-4047 [PMID: 23212913 DOI: 10.1074/jbc.M112.410506]

50 **Shibata C**, Otsuka M, Kishikawa T, Yoshikawa T, Ohno M, Takata A, Koike K. Current status of miRNA-targeting therapeutics and preclinical studies against gastroenterological carcinoma. *Molecular and Cellular Therapies* 2013; **1**: 5 [DOI: 10.1186/2052-8426-1-5]

51 **Janssen HL**, Reesink HW, Lawitz EJ, Zeuzem S, Rodriguez-Torres M, Patel K, van der Meer AJ, Patick AK, Chen A, Zhou Y, Persson R, King BD, Kauppinen S, Levin AA, Hodges MR. Treatment of HCV infection by targeting microRNA. *N Engl J Med* 2013; **368**: 1685-1694 [PMID: 23534542 DOI: 10.1056/NEJMoa1209026]

52 **Xu Y**, Liu L, Liu J, Zhang Y, Zhu J, Chen J, Liu S, Liu Z, Shi H, Shen H, Hu Z. A potentially functional polymorphism in the promoter region of miR-34b/c is associated with an increased risk for primary hepatocellular carcinoma. *Int J Cancer* 2011; **128**: 412-417 [PMID: 20309940 DOI: 10.1002/ijc.25342]

53 **Bao L**, Yan Y, Xu C, Ji W, Shen S, Xu G, Zeng Y, Sun B, Qian H, Chen L, Wu M, Su C, Chen J. MicroRNA-21 suppresses PTEN and hSulf-1 expression and promotes hepatocellular carcinoma progression through AKT/ERK pathways. *Cancer Lett* 2013; **337**: 226-236 [PMID: 23684551 DOI: 10.1016/j.canlet.2013.05.007]

54 **Gao P**, Wong CC, Tung EK, Lee JM, Wong CM, Ng IO. Deregulation of microRNA expression occurs early and accumulates in early stages of HBV-associated multistep hepatocarcinogenesis. *J Hepatol* 2011; **54**: 1177-1184 [PMID: 21145831 DOI: 10.1016/j.jhep.2010.09.023]

55 **Gramantieri L**, Fornari F, Ferracin M, Veronese A, Sabbioni S, Calin GA, Grazi GL, Croce CM, Bolondi L, Negrini M. MicroRNA-221 targets Bmf in hepatocellular carcinoma and correlates with tumor multifocality. *Clin Cancer Res* 2009; **15**: 5073-5081 [PMID: 19671867 DOI: 10.1158/1078-0432.CCR-09-0092]

56 **Callegari E**, Elamin BK, Giannone F, Milazzo M, Altavilla G, Fornari F, Giacomelli L, D'Abundo L, Ferracin M, Bassi C, Zagatti B, Corrà F, Miotto E, Lupini L, Bolondi L, Gramantieri L, Croce CM, Sabbioni S, Negrini M. Liver tumorigenicity promoted by microRNA-221 in a mouse transgenic model. *Hepatology* 2012; **56**: 1025-1033 [PMID: 22473819 DOI: 10.1002/hep.25747]

57 **Fang Y**, Xue JL, Shen Q, Chen J, Tian L. MicroRNA-7 inhibits tumor growth and metastasis by targeting the phosphoinositide 3-kinase/Akt pathway in hepatocellular carcinoma. *Hepatology* 2012; **55**: 1852-1862 [PMID: 22234835 DOI: 10.1002/hep.25576]

58 **Wang Z**, Gerstein M, Snyder M. RNA-Seq: a revolutionary tool for transcriptomics. *Nat Rev Genet* 2009; **10**: 57-63 [PMID: 19015660 DOI: 10.1038/nrg2484]

59 **Pineau P**, Volinia S, McJunkin K, Marchio A, Battiston C, Terris B, Mazzaferro V, Lowe SW, Croce CM, Dejean A. miR-221 overexpression contributes to liver tumorigenesis. *Proc Natl Acad Sci USA* 2010; **107**: 264-269 [PMID: 20018759 DOI: 10.1073/pnas.0907904107]

P- Reviewer: Tarazov PG, Vespasiani-Gentilucci U
S- Editor: Gong XM **L- Editor**: A **E- Editor**: Liu SQ

World Journal of Hepatology

Submit a Manuscript: http://www.wjgnet.com/esps/
Help Desk: http://www.wjgnet.com/esps/helpdesk.aspx
DOI: 10.4254/wjh.v7.i1.28

World J Hepatol 2015 January 27; 7(1): 28-32
ISSN 1948-5182 (online)

TOPIC HIGHLIGHT

WJH 6th Anniversary Special Issues (2): Hepatocellular carcinoma

Hagen-Poiseuille's law: The link between cirrhosis, liver stiffness, portal hypertension and hepatic decompensation

Gerond Lake-Bakaar, Muneeb Ahmed, Amy Evenson, Alan Bonder, Salomao Faintuch, Vinay Sundaram

Gerond Lake-Bakaar, Muneeb Ahmed, Amy Evenson, Alan Bonder, Salomao Faintuch, Vinay Sundaram, Liver Tumor Center, Department of Medicine, Beth Israel Deaconess Medical Center, Harvard Medical School, Boston, MA 02215, United States
Author contributions: Lake-Bakaar G was responsible for the original conception and preparation of the manuscript; Ahmed M, Evenson A, Bonder A, Faintuch S and Sundaram V individually contributed equally to the work applying their areas of specialty to the core hypothesis and researching articles for the work; all authors approved the final version of the manuscript.
Conflict-of-interest: The authors do not have any conflicts of interest.

Correspondence to: Gerond Lake-Bakaar, MD, PhD, Liver Tumor Center, Department of Medicine, Beth Israel Deaconess Medical Center, Harvard Medical School, 110 Francis Street, Suite 7A-055, Boston, MA 02215,
United States. glakebak@bidmc.harvard.edu
Telephone: +1-617-6329838
Fax: +1-617-6329820
Received: June 19, 2014
Peer-review started: June 20, 2014
First decision: July 10, 2014
Revised: November 5, 2014
Accepted: November 17, 2014
Article in press: November 19, 2014
Published online: January 27, 2015

Abstract

The onset of hepatic decompensation in cirrhosis heralds an accelerated downhill course with poor outcome. The sole predictor of this decompensation in cirrhosis is increased hepatic vein to portal vein gradient hepatic venous pressure gradient (HVPG). Surrogate markers of liver function or hepatic reserve appear to be less relevant. The hepatic sinusoids become less elastic and more rigid as liver fibrosis and cirrhosis progress. We propose that the Hagen-Poiseuille's law, which applies to rigid, but not elastic vessels, determines the pressure-flow characteristics in the sinusoids. In the rigid cirrhotic liver, HVPG rises dramatically with any change in net surface area or radius, r^4 of the vasculature that follows surgical resection. This review relates liver stiffness to the risk of decompensation in patients with cirrhosis. The liver has a unique dual blood supply comprising a low pressure portal vein and high pressure hepatic artery. We compare the complexity of autoregulation in the normal elastic liver with that in the rigid cirrhotic liver. Therapeutic modalities to reduce portal pressure may reduce the risk of hepatic decompensation and improve outcomes in cirrhosis.

Key words: Portal hypertension; Liver stiffness; Hagen-Poiseuille's law

Core tip: Unlike the elastic normal liver, hepatic sinusoidal vessels become progressively more rigid with advancing cirrhosis and thus subject to Hagen-Poiseuille's law. Thereafter, pressure gradient is inversely proportional to the fourth power of vessel radius, r^4. Surgical resection reduces liver volume and thus net diameter of sinusoids, without reducing hepatic blood inflow. The net reduction in r, at the same flow rates increases pressure gradient by a factor r^4 and likely accounts for the poor outcomes in patients with cirrhosis and established portal hypertension. Reducing hepatic venous pressure gradient reduction

as part of the management of cirrhosis may reduce the risk of decompensation.

Lake-Bakaar G, Ahmed M, Evenson A, Bonder A, Faintuch S, Sundaram V. Hagen-Poiseuille's law: The link between cirrhosis, liver stiffness, portal hypertension and hepatic decompensation. *World J Hepatol* 2015; 7(1): 28-32 Available from: URL: http://www.wjgnet.com/1948-5182/full/v7/i1/28.htm DOI: http://dx.doi.org/10.4254/wjh.v7.i1.28

INTRODUCTION

Functional hepatic reserve and liver regenerative potential

The normal healthy liver has a large functional redundancy or reserve (FHR)[1,2] and a significant regenerative potential (RP)[3] that allows it to withstand major damage and injury. Thus, over 75 percent of an adult liver, in which surrogate markers of FHR such as bilirubin and hepatic indocyanine green clearance are normal, can be resected without risk of liver failure. As cirrhosis advances these markers become less predictive of post resection decompensation[4].

Cirrhosis occupies a broad, complex, dynamic pathologic spectrum, with two distinct stages, both with different prognostic implications. There is the compensated stage, with a median survival of 12 years and the decompensated (variceal bleeding, hepatic encephalopathy and ascites) with a median survival of only two years[5].

In the cirrhotic patient, the hepatic venous pressure gradient, hepatic venous pressure gradient (HVPG) stands alone, in multiple logistic regression analysis, as the only independent variable predictive of post resection decompensation[6-12]. This pivotal role of HVPG is unexplained.

Increased HVPG also influences the regenerative potential of the cirrhotic liver. In the presence of increased HVPG, resection is associated with the differential expression of genes associated with apoptosis, rather than regeneration[13]. Several explanations have been proposed. The repeated cell divisions that underlie the process of cirrhosis may have led to senescence and telomere shortening and reduced the regenerative potential RP of the cirrhotic liver[14]. DNA damage checkpoint activation could also reduce the RP of the cirrhotic liver[15,16].

In this review, we propose that in contrast to the elastic vessel walls in the normal liver, cirrhotic sinusoids are rigid and therefore subject to the Hagen-Poiseuille's law. Thus, we argue that progression from the well compensated to the decompensated stage is merely a function of loss of elasticity. For any change in net sinusoidal surface area or radius r that follows surgical resection, sinusoidal pressure gradient rises dramatically by a factor equal to the fourth power of the radius, r^4, if blood flow is held constant. The resulting shearing forces can induce endothelial damage at high HVPG.

AUTOREGULATION OF BLOOD FLOW IN THE NORMAL AND CIRRHOTIC LIVER

The ability to maintain adequate blood flow, in the face of changes in the inflow perfusion pressure and consistent with metabolic demands is termed "autoregulation". This phenomenon, first described, for the kidneys, has since been demonstrated in several other organs[17] and classically involves active changes in the caliber of the inflow arterioles.

AUTOREGULATION: NORMAL *VS* CIRRHOTIC LIVER

The microvasculature of the liver is unique in that the blood supply is dual. Approximately 80 percent originates from the portal venous system at low pressure around 15 mmHg. The rest, around 20 percent derives from the hepatic artery, at considerably higher pressures that peak around 120 mmHg, in the terminal hepatic arteriole. The combined systems perfuse the hepatic sinusoids at pressures around 3-6 mmHg.

The portal venous system in the normal liver is a passive vascular bed. Active portal venous autoregulation has not been observed in the dog[18]. A myogenic response has been described in arterial resistance vessels that control blood flow in the liver.

Evidence for effective autoregulation in the normal pig liver is illustrated by the fact that a 62 percent resection increases portal venous pressure from 6.1 mmHg to just 8.2 mmHg, in spite of the significantly reduced net surface area or radius of the perfused sinusoids in the liver remnant. A 50% reduction in the radius of a rigid tube would be expected to increase the pressure gradient 16-fold at constant flow rate. After 75 percent resection, portal venous pressure merely doubles to 12 mmHg, suggesting a compensatory increase in r, likely related to autoregulation. It is only after more than 90 percent of the liver is resected that a major rise in sinusoidal pressure occurs. The rise in pressure leads to a marked increase in sinusoidal diameter and concomitant histological liver damage[19].

Several compounds have been designated as potential candidates for liver autoregulation: acetylcholine, endothelium derived relaxing factor NO, carbon monoxide CO and hydrogen sulphide H_2S are possible vasodilators; the three isopeptides of endothelium constricting factor endothelin ET, ET-1, ET-2 and ET-3 are possible vasoconstrictors. The adenosine washout hypothesis suggests that adenosine might exert physiological control and that the hepatic arterioles dilate, when adenosine builds up in the space of Mall. The targets for the candidate compounds include hepatic stellate cells that have a peri-sinusoidal distribution and smooth muscle cells that are

located proximal or distal to the hepatic sinusoids.

It is highly significant that in the normal liver, hepatic arterial flow is not essential to maintain liver viability. Acute ligation of the hepatic artery has little impact on liver metabolism. By contrast, when the main portal trunk is ligated, sinusoidal flow is significantly reduced[20].

The normal liver has symmetric architecture allowing blood to flow in an orderly fashion from portal vein and hepatic artery radicals within the portal triads and across the sinusoids to the hepatic vein. By contrast, disorganized nodules disrupt the symmetrical, acinar structure in the cirrhotic liver[21].

Scant data are available on hepatic blood flow in the cirrhotic liver in man, but some are available in animals. In the CCl_4 cirrhotic rat model, total hepatic flow is significantly reduced[22]. This is due mainly to reduced flow in the low-pressure portal venous system. There is some compensation for this from an increased hepatic artery flow, which doubles its contribution from 20 percent in the normal liver to 40 percent in the well-compensated cirrhotic liver.

The contribution may be higher in the decompensated cirrhotic. The hepatic arterial supply becomes even more important for maintaining viability of the cirrhotic liver, especially as the HVPG increases.

PRESSURE GRADIENT IN THE NORMAL AND CIRRHOTIC LIVER

The Hagen-Poiseuille equation $\Delta P = 128\ \mu LQ/\pi r^4$ is a physical law in fluid dynamics, which governs the pressure gradient ΔP, in a fluid with a viscosity μ, flowing through a rigid cylindrical pipe of length L, and radius r, at volumetric flow rate Q. Thus, the pressure gradient ΔP is inversely related to r^4 and any change in radius will result in an exponential change in the pressure gradient.

The normal liver is elastic. The sinusoidal vessels are distensible and thus not directly subject to the Hagen-Poiseuille law. Passive increases in vessel radius at least partially accommodate for any increase in flow, buffering changes in the hepatic vein to portal vein pressure gradient.

By contrast, with advancing cirrhosis, there is progressive rigidity associated with reduction in the radius of the vessel walls, which exponentially increase the pressure gradient. Increased HVPG increase sinusoidal shear stress and can worsen liver ischemia.

Liver elasticity can be independently assessed using magnetic resonance elastography magnetic resonance elastography or elastography, and liver stiffness by Fibroscan[23]. Liver stiffness is an independent predictor of hepatocellular carcinoma (HCC) outcome[24]. A number of recent studies have shown that transient elastography correlates well with HVPG[12,25]. These tests may be more predictive of post resection outcomes[10]. Meta-analysis of studies of liver stiffness suggest an association with risk of decompensation, liver cancer and death in patients with chronic liver disease[26].

DRUGS THAT REDUCE PORTAL HYPERTENSION

Systemic therapy-sorafenib

Sorafenib is an oral multi-kinase inhibitor that inhibits cell proliferation and angiogenesis. It targets several tyrosine kinases such as Raf kinase, vascular endothelial growth factor receptor 2 and 3 as well as platelet derived growth factor receptor beta. It is the only drug currently approved for the treatment of HCC[27].

An interesting and potentially important observation from animal models is that sorafenib reduces developing and established portal hypertension[28-30]. Two recent studies in patients with cirrhosis and HCC have demonstrated a decrease in portal venous flow or pressure on sorafenib[31,32], with a trend towards better survival in those patients with reduced HVPG (20.5 mo *vs* 10.6 mo). Two of the four responders received concomitant beta-blockers.

The effect of sorafenib on portal venous flow and portal pressure in patients with cirrhosis and HCC deserves further study. Sorafenib might exert this protective effect through reduction of portal pressure.

In the pivotal trial of sorafenib in HCC[27], liver tumor arising within a background of hepatitis C virus (HCV) cirrhosis faired better than with chronic HBV or other chronic liver disorders. One possible explanation might be that unlike HBV related HCC that can arise in non-cirrhotic livers, HCV infected patients are almost invariably cirrhotic[33]. Improved survival in these patients might reflect an effect of sorafenib on portal pressure.

Since a trend towards improved survival was observed in HCC patients on sorafenib that had reductions in HVPG[32], a combination of sorafenib plus propranolol, nadolol or carvedilol, obeticholic acid or statins in HCC patients might prove useful in increasing patient survival or in reducing the risk of decompensation post resection or trans-arterial chemo-embolization.

CONCLUSION

Scarring and nodule formation in the cirrhotic liver reduces elasticity and increases stiffness. With increasing stiffness, the sinusoidal vessel walls become rigid. Hagen-Poiseuille's law governs pressure-flow characteristics in the cirrhotic liver. Thus, HVPG increases exponentially in cirrhosis with reduction in sinusoidal vessel well, but less so in the normal liver. The consequent shearing forces can lead to severe damage to endothelial cells. Trials correlating portal pressure reduction using drugs such as sorafenib, propranolol, nadolol or carvedilol, obeticholic acid and statins, with outcomes in patients with increased portal pressure or cirrhosis may be warranted.

REFERENCES

1 **Hur H**, Ko YT, Min BS, Kim KS, Choi JS, Sohn SK, Cho CH, Ko HK, Lee JT, Kim NK. Comparative study of resection and radiofrequency ablation in the treatment of solitary colorectal liver metastases. *Am J Surg* 2009; **197**: 728-736 [PMID: 18789428 DOI: 10.1016/j.amjsurg.2008.04.013]

2 **MacIntosh EL**, Minuk GY. Hepatic resection in patients with cirrhosis and hepatocellular carcinoma. *Surg Gynecol Obstet* 1992; **174**: 245-254 [PMID: 1311868]

3 **Hammond JS**, Guha IN, Beckingham IJ, Lobo DN. Prediction, prevention and management of postresection liver failure. *Br J Surg* 2011; **98**: 1188-1200 [PMID: 21725970 DOI: 10.1002/bjs.7630]

4 **Manizate F**, Hiotis SP, Labow D, Roayaie S, Schwartz M. Liver functional reserve estimation: state of the art and relevance to local treatments. *Oncology* 2010; **78** Suppl 1: 131-134 [PMID: 20616595]

5 **D'Amico G**, Garcia-Tsao G, Pagliaro L. Natural history and prognostic indicators of survival in cirrhosis: a systematic review of 118 studies. *J Hepatol* 2006; **44**: 217-231 [PMID: 16298014 DOI: 10.1016/j.jhep.2005.10.013]

6 **Bosch J**, Abraldes JG, Berzigotti A, García-Pagan JC. The clinical use of HVPG measurements in chronic liver disease. *Nat Rev Gastroenterol Hepatol* 2009; **6**: 573-582 [PMID: 19724251 DOI: 10.1038/nrgastro.2009.149]

7 **Stremitzer S**, Tamandl D, Kaczirek K, Maresch J, Abbasov B, Payer BA, Ferlitsch A, Gruenberger T. Value of hepatic venous pressure gradient measurement before liver resection for hepatocellular carcinoma. *Br J Surg* 2011; **98**: 1752-1758 [PMID: 22009385 DOI: 10.1002/bjs.7672]

8 **Figueras J**, Llado L, Ruiz D, Ramos E, Busquets J, Rafecas A, Torras J, Fabregat J. Complete versus selective portal triad clamping for minor liver resections: a prospective randomized trial. *Ann Surg* 2005; **241**: 582-590 [PMID: 15798459]

9 **An M**, Park JW, Shin JA, Choi JI, Kim TH, Kim SH, Lee WJ, Park SJ, Hong EK, Kim CM. [The adverse effect of indirectly diagnosed portal hypertension on the complications and prognosis after hepatic resection of hepatocellular carcinoma]. *Korean J Hepatol* 2006; **12**: 553-561 [PMID: 17237634]

10 **Llop E**, Berzigotti A, Reig M, Erice E, Reverter E, Seijo S, Abraldes JG, Bruix J, Bosch J, García-Pagan JC. Assessment of portal hypertension by transient elastography in patients with compensated cirrhosis and potentially resectable liver tumors. *J Hepatol* 2012; **56**: 103-108 [PMID: 21827733 DOI: 10.1016/j.jhep.2011.06.027]

11 **Blasco A**, Forns X, Carrión JA, García-Pagán JC, Gilabert R, Rimola A, Miquel R, Bruguera M, García-Valdecasas JC, Bosch J, Navasa M. Hepatic venous pressure gradient identifies patients at risk of severe hepatitis C recurrence after liver transplantation. *Hepatology* 2006; **43**: 492-499 [PMID: 16496308]

12 **Castera L**, Pinzani M, Bosch J. Non invasive evaluation of portal hypertension using transient elastography. *J Hepatol* 2012; **56**: 696-703 [PMID: 21767510 DOI: 10.1016/j.jhep.2011.07.005]

13 **Mortensen KE**, Conley LN, Hedegaard J, Kalstad T, Sorensen P, Bendixen C, Revhaug A. Regenerative response in the pig liver remnant varies with the degree of resection and rise in portal pressure. *Am J Physiol Gastrointest Liver Physiol* 2008; **294**: G819-G830 [PMID: 18187521 DOI: 10.1152/ajpgi.00179.2007]

14 **El-Serag HB**, Rudolph KL. Hepatocellular carcinoma: epidemiology and molecular carcinogenesis. *Gastroenterology* 2007; **132**: 2557-2576 [PMID: 17570226 DOI: 10.1053/j.gastro.2007.04.061]

15 **Merle P**, Trepo C. Molecular mechanisms underlying hepatocellular carcinoma. *Viruses* 2009; **1**: 852-872 [PMID: 21994573 DOI: 10.3390/v1030852]

16 **Daugherity EK**, Balmus G, Al Saei A, Moore ES, Abi Abdallah D, Rogers AB, Weiss RS, Maurer KJ. The DNA damage checkpoint protein ATM promotes hepatocellular apoptosis and fibrosis in a mouse model of non-alcoholic fatty liver disease. *Cell Cycle* 2012; **11**: 1918-1928 [PMID: 22544329 DOI: 10.4161/cc.20259]

17 **Stainsby WN**. Local control of regional blood flow. *Annu Rev Physiol* 1973; **35**: 151-168 [PMID: 4575160 DOI: 10.1146/annurev.ph.35.030173.001055]

18 **Hanson KM**, Johnson PC. Local control of hepatic arterial and portal venous flow in the dog. *Am J Physiol* 1966; **211**: 712-720 [PMID: 5927901]

19 **McCuskey RS**. Morphological mechanisms for regulating blood flow through hepatic sinusoids. *Liver* 2000; **20**: 3-7 [PMID: 10726955]

20 **Oda M**, Yokomori H, Han JY. Regulatory mechanisms of hepatic microcirculatory hemodynamics: hepatic arterial system. *Clin Hemorheol Microcirc* 2006; **34**: 11-26 [PMID: 16543613]

21 **Onori P**, Morini S, Franchitto A, Sferra R, Alvaro D, Gaudio E. Hepatic microvascular features in experimental cirrhosis: a structural and morphometrical study in CCl4-treated rats. *J Hepatol* 2000; **33**: 555-563 [PMID: 11059860]

22 **Richter S**, Mücke I, Menger MD, Vollmar B. Impact of intrinsic blood flow regulation in cirrhosis: maintenance of hepatic arterial buffer response. *Am J Physiol Gastrointest Liver Physiol* 2000; **279**: G454-G462 [PMID: 10915656]

23 **Cescon M**, Colecchia A, Cucchetti A, Peri E, Montrone L, Ercolani G, Festi D, Pinna AD. Value of transient elastography measured with FibroScan in predicting the outcome of hepatic resection for hepatocellular carcinoma. *Ann Surg* 2012; **256**: 706-712; discussion 712-713 [PMID: 23095613 DOI: 10.1097/SLA.0b013e3182724ce8]

24 **Kuo YH**, Lu SN, Hung CH, Kee KM, Chen CH, Hu TH, Lee CM, Changchien CS, Wang JH. Liver stiffness measurement in the risk assessment of hepatocellular carcinoma for patients with chronic hepatitis. *Hepatol Int* 2010; **4**: 700-706 [PMID: 21286340 DOI: 10.1007/s12072-010-9223-1]

25 **Shi KQ**, Fan YC, Pan ZZ, Lin XF, Liu WY, Chen YP, Zheng MH. Transient elastography: a meta-analysis of diagnostic accuracy in evaluation of portal hypertension in chronic liver disease. *Liver Int* 2013; **33**: 62-71 [PMID: 22973991 DOI: 10.1111/liv.12003]

26 **Singh S**, Fujii LL, Murad MH, Wang Z, Asrani SK, Ehman RL, Kamath PS, Talwalkar JA. Liver stiffness is associated with risk of decompensation, liver cancer, and death in patients with chronic liver diseases: a systematic review and meta-analysis. *Clin Gastroenterol Hepatol* 2013; **11**: 1573-1584.e1-2; quiz e88-9 [PMID: 23954643 DOI: 10.1016/j.cgh.2013.07.034]

27 **Llovet JM**, Ricci S, Mazzaferro V, Hilgard P, Gane E, Blanc JF, de Oliveira AC, Santoro A, Raoul JL, Forner A, Schwartz M, Porta C, Zeuzem S, Bolondi L, Greten TF, Galle PR, Seitz JF, Borbath I, Häussinger D, Giannaris T, Shan M, Moscovici M, Voliotis D, Bruix J. Sorafenib in advanced hepatocellular carcinoma. *N Engl J Med* 2008; **359**: 378-390 [PMID: 18650514 DOI: 10.1056/NEJMoa0708857]

28 **Hennenberg M**, Trebicka J, Stark C, Kohistani AZ, Heller J, Sauerbruch T. Sorafenib targets dysregulated Rho kinase expression and portal hypertension in rats with secondary biliary cirrhosis. *Br J Pharmacol* 2009; **157**: 258-270 [PMID: 19338580 DOI: 10.1111/j.1476-5381.2009.00158.x]

29 **Mejias M**, Garcia-Pras E, Tiani C, Miquel R, Bosch J, Fernandez M. Beneficial effects of sorafenib on splanchnic, intrahepatic, and portocollateral circulations in portal hypertensive and cirrhotic rats. *Hepatology* 2009; **49**: 1245-1256 [PMID: 19137587 DOI: 10.1002/hep.22758]

30 **Reiberger T**, Rasoul-Rockenschaub S, Rieger A, Ferenci P, Gangl A, Peck-Radosavljevic M. Efficacy of interferon in

immunocompromised HCV patients after liver transplantation or with HIV co-infection. *Eur J Clin Invest* 2008; **38**: 421-429 [PMID: 18489402]

31 **Coriat R**, Gouya H, Mir O, Ropert S, Vignaux O, Chaussade S, Sogni P, Pol S, Blanchet B, Legmann P, Goldwasser F. Reversible decrease of portal venous flow in cirrhotic patients: a positive side effect of sorafenib. *PLoS One* 2011; **6**: e16978 [PMID: 21340026 DOI: 10.1371/journal.pone.0016978]

32 **Pinter M**, Sieghart W, Reiberger T, Rohr-Udilova N, Ferlitsch A, Peck-Radosavljevic M. The effects of sorafenib on the portal hypertensive syndrome in patients with liver cirrhosis and hepatocellular carcinoma--a pilot study. *Aliment Pharmacol Ther* 2012; **35**: 83-91 [PMID: 22032637 DOI: 10.1111/j.1365-2036.2011.04896.x]

33 **Lata J**. Chronic liver diseases as liver tumor precursors. *Dig Dis* 2010; **28**: 596-599 [PMID: 21088408 DOI: 10.1159/000320057]

P- Reviewer: Neri V, Tang Y, Yu HP **S- Editor**: Ji FF
L- Editor: A **E- Editor**: Liu SQ

World Journal of Hepatology

Submit a Manuscript: http://www.wjgnet.com/esps/
Help Desk: http://www.wjgnet.com/esps/helpdesk.aspx
DOI: 10.4254/wjh.v7.i1.33

World J Hepatol 2015 January 27; 7(1): 33-39
ISSN 1948-5182 (online)

TOPIC HIGHLIGHT

WJH 6th Anniversary Special Issues (2): Hepatocellular carcinoma

Assessment of clinical and radiological response to sorafenib in hepatocellular carcinoma patients

Rodolfo Sacco, Valeria Mismas, Antonio Romano, Marco Bertini, Michele Bertoni, Graziana Federici, Salvatore Metrangolo, Giuseppe Parisi, Emanuele Tumino, Giampaolo Bresci, Luca Giacomelli, Sara Marceglia, Irene Bargellini

Rodolfo Sacco, Valeria Mismas, Antonio Romano, Marco Bertini, Michele Bertoni, Graziana Federici, Salvatore Metrangolo, Giuseppe Parisi, Emanuele Tumino, Giampaolo Bresci, Luca Giacomelli, Dipartimento di Gastroenterologia-UO Gastroenterologia e Malattie del Ricambio, Azienda Ospedaliero Universitaria Pisana, 56124 Pisa, Italy
Sara Marceglia, Dipartimento di Elettronica, Informazione e Bioingegneria, Politecnico di Milano, 20100 Milan, Italy
Irene Bargellini, Dipartimento di Radiologia-Azienda Ospedaliero Universitaria Pisana, 56124 Pisa, Italy
Author contributions: All the authors provided substantial contributions to conception of the manuscript; helped drafting the article or making critical revisions related to important intellectual content of the manuscript; and approved the final version of the article to be published.

Correspondence to: Rodolfo Sacco, MD, PhD, Dipartimento di Gastroenterologia-UO Gastroenterologia e Malattie del Ricambio, Azienda Ospedaliero Universitaria Pisana, Via Paradisa 2, 56124 Pisa, Italy. r.sacco@ao-pisa.toscana.it
Telephone: +39-50-997411
Fax: +39-50-997412
Received: August 29, 2014
Peer-review started: August 30, 2014
First decision: September 28, 2014
Revised: October 10, 2014
Accepted: November 17, 2014
Article in press: November 19, 2014
Published online: January 27, 2015

Abstract

Sorafenib is an effective anti-angiogenic treatment for hepatocellular carcinoma (HCC). The assessment of tumor progression in patients treated with sorafenib is crucial to help identify potentially-resistant patients, avoiding unnecessary toxicities. Traditional methods to assess tumor progression are based on variations in tumor size and provide unreliable results in patients treated with sorafenib. New methods to assess tumor progression such as the modified Response Evaluation Criteria in Solid Tumors or European Association for the Study of Liver criteria are based on imaging to measure the vascularization and tumor volume (viable or necrotic). These however fail especially when the tumor response results in irregular development of necrotic tissue. Newer assessment techniques focus on the evaluation of tumor volume, density or perfusion. Perfusion computed tomography and Dynamic Contrast-Enhanced-UltraSound can measure the vascularization of HCC lesions and help predict tumor response to anti-angiogenic therapies. Mean Transit Time is a possible predictive biomarker to measure tumor response. Volumetric techniques are reliable, reproducible and time-efficient and can help measure minimal changes in viable tumor or necrotic tissue, allowing the prompt identification of non-responders. Volume ratio may be a reproducible biomarker for tumor response. Larger trials are needed to confirm the use of these techniques in the prediction of response to sorafenib.

Key words: Hepatocellular carcinoma; Sorafenib; Response Evaluation Criteria in Solid Tumors; Perfusion computed tomography; Dynamic Contrast-Enhanced-UltraSound; Volumetric assessment

Core tip: The development of new treatment options for hepatocellular carcinoma has changed not only the way in which cancer is treated, but also how it is diagnosed

and especially the assessment of tumor response. The traditional radiologic methods, which are mainly based on the evaluation of variations in tumor size, are considered insufficiently sensitive and unreliable in determining tumor progression when targeted therapies like sorafenib are involved. New assessment tools trying to combine morphological and vascular functional data to obtain an accurate measurement of tumor characteristics such as volume, density or vascularization, showed positive results in assessing patient's response to therapy.

Sacco R, Mismas V, Romano A, Bertini M, Bertoni M, Federici G, Metrangolo S, Parisi G, Tumino E, Bresci G, Giacomelli L, Marceglia S, Bargellini I. Assessment of clinical and radiological response to sorafenib in hepatocellular carcinoma patients. *World J Hepatol* 2015; 7(1): 33-39 Available from: URL: http://www.wjgnet.com/1948-5182/full/v7/i1/33.htm DOI: http://dx.doi.org/10.4254/wjh.v7.i1.33

INTRODUCTION

With an incidence doubled in the last decades, increased mortality rates, and important risk factors associated with its development, hepatocellular carcinoma (HCC) is considered the most common primary liver malignancy[1]. The management of HCC is complex and often requires a multidisciplinary approach in order to select the most appropriate treatment and to reduce toxicity[2].

The only medical treatment approved for HCC is the oral multikinase inhibitor sorafenib (SO)[3,4]. Its mechanism of action is based on the inhibition of a number of pro-angiogenic signaling pathways, that, stimulating angiogenesis, are responsible of the characteristic hypervascular pattern of HCC lesions[5]. The therapeutic response to SO correlates with changes in tumor structure, including decreased vascularization and increased tissue necrosis or cavitation, but it is not always associated with reduction in tumor size[6,7]. Clinical trials showed that SO is an effective treatment for advanced-stage HCC[8]. Moreover, the efficacy and safety of the combination of SO with other standard treatments for intermediate and advanced-stage HCC, such as Transarterial Chemo Embolization (TACE), is still under investigation[8-10].

Present research efforts are devoted to the refinement of prognosis prediction by molecular profiling and enhanced clinical characterization to further improve therapies and, in turn, increase life expectancy of patients[3].

The assessment of tumor progression during SO treatment is an open issue: traditional radiologic methods mainly based on the evaluation of changes in tumor size are considered insufficiently sensitive and unreliable[11]. The phase Ⅲ SHARP trial[4] showed that the Response Evaluation Criteria in Solid Tumors (RECIST) 1.1[12] did not correlate with the SO-induced positive clinical outcome and that its ability to predict patient's response was very limited[4].

In this paper, we will review the new available tools that showed promising results for the assessment of HCC patients' response to Sorafenib treatment.

TRADITIONAL ASSESSMENT TOOLS: MODIFIED RECIST AND THE EUROPEAN ASSOCIATION FOR THE STUDY OF LIVER

The modified RECIST (mRECIST) was recently proposed by the American Association for the Study of Liver Diseases (AASLD) as a new assessment method able to overcome the main limitations of RECIST criteria by including, among the evaluation criteria, the changes in tumor structure induced by anti-angiogenic treatments[13]. mRECIST assesses the vascularization of a lesion and the changes in tumor arterial enhancement through imaging techniques, such as the contrast-enhanced spiral computed tomography (CT) or dynamic magnetic resonance imaging (MRI). Neo-angiogenesis is in fact well-enhanced both in the arterial phase of MRI and in CT although MRI contrast agents provide better visualization[14]. However, for an appropriate evaluation, the AASLD guidelines recommend the assessment of tumor lesions also at baseline, as well as the optimization of image acquisition protocols and interpretation[13].

The European Association for the Study of Liver (EASL), in 2000, suggested a similar approach that included the evaluation of changes in tumor enhancement through contrast-enhanced imaging also to establish variations in viable tumor and necrotic areas[15].

The ability of mRECIST and EASL criteria to assess patients with HCC treated both with loco-regional therapy or systemic agents were compared with the traditional RECIST criteria in different studies[16-21]. Results showed that mRECIST and EASL criteria are sufficiently reliable in assessing response to loco-regional treatment, but some uncertainties remain whether using these criteria after target agents[22]. Necrotic areas after loco-regional therapy are usually predictable and well-defined necrotic areas. Conversely, SO can result in an irregular and unpredictable development of necrosis since the decreased tumor vascularization does not always translate in necrotic tissue[20,23]. A recent study however showed that EASL and mRECIST responses are independent predictors for overall survival in patients treated with the combination of SO and TACE, and that this response can be evaluated early (3 mo)[21].

This scattered scenario suggests that criteria based on an overall visual assessment can be misleading and may lead to inaccurate measurements; therefore, there is a strong need to develop new and more reliable assessment tools.

NEW ASSESSMENT TOOLS

The research effort towards the development of new assessment tools for SO response grounds on the consideration that, provided the high impact of SO on tumor vascularity, techniques able to combine morphological and vascular functional data can be more effective than the traditional criteria[24]. In addition, EASL and AASLD guidelines underline that the portion of viable tumor, and not the whole tumor mass, is the most important evaluation parameter, which depends on the blood flow within and vascularization of the lesions.

Hence, perfusion-CT (pCT) and Dynamic Contrast-Enhanced-UltraSound (D-CEUS) are at the basis of some current strategies for the evaluation of tumor perfusion and tumor density[24-26], whereas other authors propose volumetric assessment of tumor as possible marker of progression[27-29].

Last, several tumor biomarkers are under investigations as possible prognostic and predictive factors for SO response aimed to help identifying candidate resistant patients, possibly candidate with alternative treatments, and avoiding unnecessary toxicities.

New tools for the evaluation of tumor perfusion and density

pCT and D-CEUS were recently identified as possible practical and non-invasive radiological techniques that, enabling the visualization of tissue microcirculation, are able to provide information related to the diagnosis, stratification, and prediction of the response to treatment in oncologic patients[30,31]. Moreover, the sensitivity, rapidity, and efficacy of these imaging techniques was further advanced with the introduction of multidetector CT scanners and of commercially-available software for data analysis[32]. Provided their ability to evaluate tissue vascularization, these techniques were also explored as possible tools to measure the efficacy of anti-angiogenic therapies[31,33,34]. The studies investigating pCT and D-CEUS ability to measure treatment response were conducted both in patients treated with SO and in patients treated with bevacizumab. These two therapies are comparable in terms of tumor response, that is similar with the two molecules; however, from a clinical viewpoint, they greatly differ in relation to HCC treatment as bevacizumab is not used to treat HCC patients.

Another very recent approach concerned the use of the apparent diffusion coefficient (ADC), reflecting diffusion of water in tissue, measured by DW-MRI that was already demonstrated to correlated with response to chemotherapy[35].

pCT parameters: pCT parameters such as blood flow (BF), blood volume (BV), mean transit time (MTT) and permeability surface area (PS) are significantly different in HCC lesions compared with normal liver tissue and correlate to the tumor stage[26,30,36]: whereas BF, BV, and PS were reported to be higher in advanced HCC than in moderately differentiated HCC tissue, MTT was lower in advanced HCC[30].

pCT was compared to RECIST and tumor density in a phase Ⅱ clinical trial involving 23 patients with advanced HCC undergoing bevacizumab for the evaluation of the response to treatment[33]. Whereas no variations in tumor size (RECIST) and only a mild reduction in tumor density were observed, pCT parameters significantly correlated to patient's response [progression free survival (PFS)]: higher MTT baseline values were directly correlated to better clinical outcome and 6-mo PFS[33]. Similar results were reported on 33 advanced HCC patients under bevacizumab, who showed a significant decrease in tumor perfusion and an increase in MTT values after treatment administration[31]. Also, patients in which the disease progressed had lower baseline MTT levels that highly increased after treatment when compared to those with partial or complete response to treatment[31].

The results obtained in patients treated with bevacizumab and evaluated through pCT were recently confirmed in a series of 10 patients treated with SO[26]: at 3 mo after the initiation of SO treatment, patients showed a progressive decrease of BF, BV, and PS and a significant increase of MTT compared to baseline values[26]. All together, these results support the hypothesis that pCT, and, more specifically, MTT, can be a valuable candidate predictive biomarker for SO response in HCC patients[26].

D-CEUS: D-CEUS was used to study tumor perfusion and dynamic changes in tumor vascularity in patients under bevacizumab treatment[34]. Changes were detected as early as 3 d after bevacizumab administration, suggesting that they could be used to predict tumor response and, in turn, measure the effectiveness of anti-angiogenic therapies[34]. In patients treated with SO, positive tumor response and longer survival rates were associated to increased or unchanged time to peak intensity (Tp) and MTT values, as well as decreased area under the curve (AUC)[37]. Moreover, AUC, Tp and slope of wash in (Pw) positively correlated to PFS, thus suggesting that D-CEUS is able to provide a measure of the efficacy of anti-angiogenic therapy and a reliable help in the selection of patients who could benefit from SO treatment[37].

pCT and D-CEUS as measure of tumor response were recently compared in 11 HCC patients treated with SO[24]. Despite decreasing consistently after treatment, pCT parameters were not able to discriminate between responders and non-responders. Conversely, a decrease of more than 40% in the AUC measured through D-CEUS after 1-mo treatment was found as a strong predictor of lack of progression at 2-mo, thus enabling the differentiation between patients who responded to therapy and those who did not[24]. D-CEUS was then suggested as possible marker of SO response, although the results of pCT analysis may have been biased by the small number of patients[24]. As a further application of CEUS, in a murine HCC mode CEUS obtained using vascular endothelial growth factor receptor-2 (VEGFR-2)

targeted microbubbles was demonstrated to be effective in measuring SO response: the differential targeted enhancement due to bound microbubbles in the tumor significantly decreased in the mice treated with SO, and was able to discriminate the non-responder group from the responders[38].

Last, the ADC obtained from DW-MRI was applied in mice to investigate its ability as an indicator of response to SO in HCC. Lower ADC values and a stronger progressive ADC decrease were observed in mice treated with SO than in the control group, thus prompting further research on this technique for the evaluation of SO response[35].

New tools for volumetric assessment

Volumetric techniques are regarded to as possible alternative methods to measure the whole tumor volume instead of the traditional approach of RECIST and EASL that, being based on the evaluation of a representative axial slice of the tumor, do not take into account its entire volume[22,27-29]. In fact, SO and other anti-angiogenic treatments induce the development of an often irregular and not-homogeneous necrotic area, so that the area selected for evaluation may not be representative of the whole tumor. Volumetric techniques take into consideration the entire tumor load and are able to detect even minimal changes in viable tumor or necrotic tissue, thus allowing the prompt identification of non-responders[22]. In addition, the introduction of automatic and semi-automatic software for image segmentation, have provided faster, more reliable and user-friendly tools for volume measurement, leading to rapid spread of these techniques[27-29].

In 17 HCC patients treated with TACE, semi-automatic 3D volume segmentation technique based on a voxel-by-voxel analysis for measuring tumor volume and enhancement pattern was reported to be reproducible and time-effective, and to provide a more accurate estimation of tumor burden than 2D techniques[28]. Similarly, HCC necrosis measured by volumetric assay was more reproducible than that obtain with the 2D measurement in 29 HCC patients, treated with yttrium-90 radioembolization[29]. According to the results of this study, the mean values of necrosis obtained with the two methods significantly differed[29].

In small retrospective involving 23 HCC or liver metastasis patients undergoing radioembolization, volumetric assessment demonstrated good intra/intra-observer reproducibility[27]. Both whole tumor and necrotic areas were measured providing good accuracy and reliability. Also, the authors observed a significant difference in survival time, in a Kaplan-Meier analysis, between patients whose change in necrotic area was ⩾ 10% compared with those with necrosis ⩽ 10%, thus suggesting a possible correlation between survival rates and tumor necrosis measured through this technique[27].

To our knowledge, response to SO using tumor volume assessment was investigated only in one prospective study involving 22 HCC patients in which the response to therapy was evaluated by multiple criteria[22], including traditional radiological criteria (RECIST1.1., EASL and mRECIST). The results showed that none of the three radiological criteria showed a significant correlation with patients' survival and that the only parameter associated with survival was volume rate: an increase ⩾ 10% in tumor volume after 2-mo was found as negative predictive factor for survival. The study also confirmed[27-29] the reproducibility of measurements, with high degree of inter- and intra-observer agreement, thus suggesting that, whereas traditional criteria to measure tumor response are not reliable in the case of SO administration, volume assessment seem to be an early and reproducible biomarker for tumor response[22].

Despite these promising results, larger trials are needed to confirm data on volumetric assessment as tool for measuring tumor volume in HCC patients, especially if treated with SO, and to investigate the correlation between measurement of changes in tumor volume and response to therapy.

The prognostic and predictive values of tumor biomarkers

Several studies are investigating new and more accurate predictive and prognostic factors for response to SO. They include the evaluations of alpha-fetoprotein (AFP) levels[26,39-44], genotype and phenotype features, such as VEGF family single nucleotide polymorphisms (SNPs)[45,46], and the differential blood cell counts, particularly the neutrophil-lymphocyte ratio (NLR)[47-49].

AFP is a glycoprotein secreted in approximately 70% of HCC, and it is considered as an useful biomarker for HCC diagnosis[39,40]. The mechanism of action could be related to SNPs in human AFP promoter that lead to uncontrolled transcriptional activities[50]. It has also been suggested that AFP could act possible predictor of response to anti-cancer and anti-angiogenic treatment[39-41,43]. The role of AFP in measuring the response to SO is however debated and deserves further considerations[43,51] since authors reported heterogeneous results[22,40-44].

Some studies suggest that, in patients treated with SO, AFP decrease is an independent predictors of good response to sorafenib[41,44] and that the early increase in AFP is associated with poor survival[40]. In a nationwide retrospective study, high AFP levels at baseline were consistently shown to be prognostic for a shorter survival, and SO responders showed a significant decline in AFP during the first month treatment[43]. Conversely, in the study evaluating different measures of tumor progression in 10 patients receiving SO, authors reported an inverse correlation between baseline MTT values, that were predictive of SO response, and changes in AFP after 3 mo, but changes in AFP levels were not associated with response rate[26].

Gene expression is believed as one of the main responsible of responsiveness to treatments in HCC patients[52]. The lack of response to SO in HCC patients was shown to be correlated to a mesenchymal-like phenotype and expression of CD44, linked to activation

of the transforming growth factor-β pathway[53] and the combined HTATIP2 expression and microvessel density was found to be a predictor of SO response[54]. Some studies also highlighted the role of VEGF[45], suggesting that patients responsiveness to SO may be well defined through the analysis of VEGF and VEGFR SNPs[46].

NLR was investigated as prognostic factor both in patients receiving SO[47,48] and in those not receiving SO[49]. In HCC patients not treated with SO, low NLR was associated with higher survival[49]. Similarly, high periprocedural NLR was associated with poor survival in patients with unresectable HCC on SO treatment[47,48] even if these results deserve further consideration[55].

CONCLUSION

The traditional assessment criteria for the evaluation of SO response in HCC treatments demonstrated to be inappropriate to reliably predict the clinical response to treatment. Despite adjustments resulting in the development of modified criteria such as mRECIST and EASL, these tools still show important limitations, especially when the tumor response results in irregular development of necrotic tissue. The introduction of new and efficient biomarkers to measure patients' response to SO could enable the early assessment of patients' response, reducing unnecessary costs and adverse events, and improving final patients' outcome.

New tools for the evaluation of tumor progression were developed and are under investigation. They focus on providing a precise estimate of the changes in viable tumor volume, through the measurement of tumor perfusion or through volumetric assessment. More specifically, the perfusion parameter MTT and the volume ratio were identified as predictive biomarkers of therapeutic response.

Despite these promising positive results of both these techniques, available data are still scant and prompt new larger systematic validation studies. Although there is no gold standard for response evaluation in HCC, these validation studies should be based on the suggestions reported in current guidelines. As already done in the available studies, the validation of these new approaches should rely on the comparison between their results and those obtained through standard assessment methods (EASL, mRECIST), while bearing in mind the limitations of each approach.

Once the necessary technological advancements will be completed, it is expected the introduction of these new assessment methods in the clinical practice, enabling the prompt identification of subjects not responding to a specific therapy, resulting in a reduction in adverse events and unnecessary costs and leading to a more rapid identification of the best treatment approach for each subject.

ACKNOWLEDGMENTS

The authors wish to thank Ambra Corti for her useful contribution in drafting manuscript content.

REFERENCES

1 **Crissien AM**, Frenette C. Current management of hepatocellular carcinoma. *Gastroenterol Hepatol* (N Y) 2014; **10**: 153-161 [PMID: 24829542]

2 **Bruera G**, Cannita K, Giordano AV, Manetta R, Vicentini R, Carducci S, Saltarelli P, Iapadre N, Coletti G, Ficorella C, Ricevuto E. Multidisciplinary management of hepatocellular carcinoma in clinical practice. *Biomed Res Int* 2014; **2014**: 806391 [PMID: 24900987 DOI: 10.1155/2014/806391]

3 **Liccioni A**, Reig M, Bruix J. Treatment of hepatocellular carcinoma. *Dig Dis* 2014; **32**: 554-563 [PMID: 25034288 DOI: 10.1159/000360501]

4 **Llovet JM**, Ricci S, Mazzaferro V, Hilgard P, Gane E, Blanc JF, de Oliveira AC, Santoro A, Raoul JL, Forner A, Schwartz M, Porta C, Zeuzem S, Bolondi L, Greten TF, Galle PR, Seitz JF, Borbath I, Häussinger D, Giannaris T, Shan M, Moscovici M, Voliotis D, Bruix J. Sorafenib in advanced hepatocellular carcinoma. *N Engl J Med* 2008; **359**: 378-390 [PMID: 18650514 DOI: 10.1056/NEJMoa0708857]

5 **Messerini L**, Novelli L, Comin CE. Microvessel density and clinicopathological characteristics in hepatitis C virus and hepatitis B virus related hepatocellular carcinoma. *J Clin Pathol* 2004; **57**: 867-871 [PMID: 15280410 DOI: 10.1136/jcp.2003.015784]

6 **Chen MY**, Bechtold RE, Savage PD. Cystic changes in hepatic metastases from gastrointestinal stromal tumors (GISTs) treated with Gleevec (imatinib mesylate). *AJR Am J Roentgenol* 2002; **179**: 1059-1062 [PMID: 12239065 DOI: 10.2214/ajr.179.4.1791059]

7 **Lassau N**, Lamuraglia M, Leclère J, Rouffiac V. [Functional and early evaluation of treatments in oncology: interest of ultrasonographic contrast agents]. *J Radiol* 2004; **85**: 704-712 [PMID: 15238871 DOI: 10.1016/S0221-0363(04)97651-2]

8 **Kim HY**, Park JW. Clinical trials of combined molecular targeted therapy and locoregional therapy in hepatocellular carcinoma: past, present, and future. *Liver Cancer* 2014; **3**: 9-17 [PMID: 24804173 DOI: 10.1159/000343854]

9 **Zheng J**, Shao G, Luo J. Analysis of survival factors in patients with intermediate-advanced hepatocellular carcinoma treated with transcatheter arterial chemoembolization combined with sorafenib. *Clin Transl Oncol* 2014; **16**: 1012-1017 [PMID: 24894839 DOI: 10.1007/s12094-014-1189-3]

10 **Sacco R**, Gadaleta-Caldarola G, Galati G, Lombardi G, Mazza G, Cabibbo G. EASL HCC summit: liver cancer management. *Future Oncol* 2014; **10**: 1129-1132 [PMID: 24947253 DOI: 10.2217/fon.14.68]

11 **Desar IM**, van Herpen CM, van Laarhoven HW, Barentsz JO, Oyen WJ, van der Graaf WT. Beyond RECIST: molecular and functional imaging techniques for evaluation of response to targeted therapy. *Cancer Treat Rev* 2009; **35**: 309-321 [PMID: 19136215 DOI: 10.1016/j.ctrv.2008.12.001]

12 **Therasse P**, Arbuck SG, Eisenhauer EA, Wanders J, Kaplan RS, Rubinstein L, Verweij J, Van Glabbeke M, van Oosterom AT, Christian MC, Gwyther SG. New guidelines to evaluate the response to treatment in solid tumors. European Organization for Research and Treatment of Cancer, National Cancer Institute of the United States, National Cancer Institute of Canada. *J Natl Cancer Inst* 2000; **92**: 205-216 [PMID: 10655437 DOI: 10.1093/jnci/92.3.205]

13 **Lencioni R**, Llovet JM. Modified RECIST (mRECIST) assessment for hepatocellular carcinoma. *Semin Liver Dis* 2010; **30**: 52-60 [PMID: 20175033 DOI: 10.1055/s-0030-1247132]

14 **Choi JI**, Imagawa DK, Bhosale P, Bhargava P, Tirkes T, Seery TE, Lall C. Magnetic resonance imaging following treatment of advanced hepatocellular carcinoma with sorafenib. *Clin Mol Hepatol* 2014; **20**: 218-222 [PMID: 25032190 DOI: 10.3350/cmh.2014.20.2.218]

15 **Bruix J**, Sherman M, Llovet JM, Beaugrand M, Lencioni R, Burroughs AK, Christensen E, Pagliaro L, Colombo M,

Rodés J. Clinical management of hepatocellular carcinoma. Conclusions of the Barcelona-2000 EASL conference. European Association for the Study of the Liver. *J Hepatol* 2001; **35**: 421-430 [PMID: 11592607 DOI: 10.1016/S0168-8278(01)00130-1]

16 **Gillmore R**, Stuart S, Kirkwood A, Hameeduddin A, Woodward N, Burroughs AK, Meyer T. EASL and mRECIST responses are independent prognostic factors for survival in hepatocellular cancer patients treated with transarterial embolization. *J Hepatol* 2011; **55**: 1309-1316 [PMID: 21703196 DOI: 10.1016/j.jhep.2011.03.007]

17 **Shim JH**, Lee HC, Kim SO, Shin YM, Kim KM, Lim YS, Suh DJ. Which response criteria best help predict survival of patients with hepatocellular carcinoma following chemoembolization? A validation study of old and new models. *Radiology* 2012; **262**: 708-718 [PMID: 22187634 DOI: 10.1148/radiol.11110282]

18 **Jung ES**, Kim JH, Yoon EL, Lee HJ, Lee SJ, Suh SJ, Lee BJ, Seo YS, Yim HJ, Seo TS, Lee CH, Yeon JE, Park JJ, Kim JS, Bak YT, Byun KS. Comparison of the methods for tumor response assessment in patients with hepatocellular carcinoma undergoing transarterial chemoembolization. *J Hepatol* 2013; **58**: 1181-1187 [PMID: 23395691 DOI: 10.1016/j.jhep.2013.01.039]

19 **Edeline J**, Boucher E, Rolland Y, Vauléon E, Pracht M, Perrin C, Le Roux C, Raoul JL. Comparison of tumor response by Response Evaluation Criteria in Solid Tumors (RECIST) and modified RECIST in patients treated with sorafenib for hepatocellular carcinoma. *Cancer* 2012; **118**: 147-156 [PMID: 21713764 DOI: 10.1002/cncr.26255]

20 **Kawaoka T**, Aikata H, Murakami E, Nakahara T, Naeshiro N, Tanaka M, Honda Y, Miyaki D, Nagaoki Y, Takaki S, Hiramatsu A, Waki K, Takahashi S, Chayama K. Evaluation of the mRECIST and α-fetoprotein ratio for stratification of the prognosis of advanced-hepatocellular-carcinoma patients treated with sorafenib. *Oncology* 2012; **83**: 192-200 [PMID: 22890083 DOI: 10.1159/000341347]

21 **Liu L**, Wang W, Chen H, Zhao Y, Bai W, Yin Z, He C, Jia J, Yang M, Xia J, Fan D, Han G. EASL- and mRECIST-evaluated responses to combination therapy of sorafenib with transarterial chemoembolization predict survival in patients with hepatocellular carcinoma. *Clin Cancer Res* 2014; **20**: 1623-1631 [PMID: 24493832 DOI: 10.1158/1078-0432.CCR-13-1716]

22 **Bargellini I**, Scionti A, Mismas V, Masi G, Vivaldi C, Bartolozzi C, Sacco R. Identification of responders to sorafenib in hepatocellular carcinoma: is tumor volume measurement the way forward? *Oncology* 2014; **86**: 191-198 [PMID: 24800837 DOI: 10.1159/000358599]

23 **Horger M**, Lauer UM, Schraml C, Berg CP, Koppenhöfer U, Claussen CD, Gregor M, Bitzer M. Early MRI response monitoring of patients with advanced hepatocellular carcinoma under treatment with the multikinase inhibitor sorafenib. *BMC Cancer* 2009; **9**: 208 [PMID: 19558720 DOI: 10.1186/1471-2407-9-208]

24 **Frampas E**, Lassau N, Zappa M, Vullierme MP, Koscielny S, Vilgrain V. Advanced Hepatocellular Carcinoma: early evaluation of response to targeted therapy and prognostic value of Perfusion CT and Dynamic Contrast Enhanced-Ultrasound. Preliminary results. *Eur J Radiol* 2013; **82**: e205-e211 [PMID: 23273822 DOI: 10.1016/j.ejrad.2012.12.004]

25 **Faivre S**, Zappa M, Vilgrain V, Boucher E, Douillard JY, Lim HY, Kim JS, Im SA, Kang YK, Bouattour M, Dokmak S, Dreyer C, Sablin MP, Serrate C, Cheng AL, Lanzalone S, Lin X, Lechuga MJ, Raymond E. Changes in tumor density in patients with advanced hepatocellular carcinoma treated with sunitinib. *Clin Cancer Res* 2011; **17**: 4504-4512 [PMID: 21531821 DOI: 10.1158/1078-0432.CCR-10-1708]

26 **Sacco R**, Faggioni L, Bargellini I, Ginanni B, Battaglia V, Romano A, Bertini M, Bresci G, Bartolozzi C. Assessment of response to sorafenib in advanced hepatocellular carcinoma using perfusion computed tomography: results of a pilot study. *Dig Liver Dis* 2013; **45**: 776-781 [PMID: 23578581 DOI: 10.1016/j.dld.2013.03.004]

27 **Monsky WL**, Garza AS, Kim I, Loh S, Lin TC, Li CS, Fisher J, Sandhu P, Sidhar V, Chaudhari AJ, Lin F, Deutsch LS, Badawi RD. Treatment planning and volumetric response assessment for Yttrium-90 radioembolization: semiautomated determination of liver volume and volume of tumor necrosis in patients with hepatic malignancy. *Cardiovasc Intervent Radiol* 2011; **34**: 306-318 [PMID: 20683722 DOI: 10.1007/s00270-010-9938-3]

28 **Lin M**, Pellerin O, Bhagat N, Rao PP, Loffroy R, Ardon R, Mory B, Reyes DK, Geschwind JF. Quantitative and volumetric European Association for the Study of the Liver and Response Evaluation Criteria in Solid Tumors measurements: feasibility of a semiautomated software method to assess tumor response after transcatheter arterial chemoembolization. *J Vasc Interv Radiol* 2012; **23**: 1629-1637 [PMID: 23177109 DOI: 10.1016/j.jvir.2012.08.028]

29 **Galizia MS**, Töre HG, Chalian H, McCarthy R, Salem R, Yaghmai V. MDCT necrosis quantification in the assessment of hepatocellular carcinoma response to yttrium 90 radioembolization therapy: comparison of two-dimensional and volumetric techniques. *Acad Radiol* 2012; **19**: 48-54 [PMID: 22054801 DOI: 10.1016/j.acra.2011.09.005]

30 **Sahani DV**, Holalkere NS, Mueller PR, Zhu AX. Advanced hepatocellular carcinoma: CT perfusion of liver and tumor tissue--initial experience. *Radiology* 2007; **243**: 736-743 [PMID: 17517931 DOI: 10.1148/radiol.2433052020]

31 **Zhu AX**, Holalkere NS, Muzikansky A, Horgan K, Sahani DV. Early antiangiogenic activity of bevacizumab evaluated by computed tomography perfusion scan in patients with advanced hepatocellular carcinoma. *Oncologist* 2008; **13**: 120-125 [PMID: 18305056 DOI: 10.1634/theoncologist.2007-0174]

32 **Hennedige T**, Venkatesh SK. Imaging of hepatocellular carcinoma: diagnosis, staging and treatment monitoring. *Cancer Imaging* 2013; **12**: 530-547 [PMID: 23400006 DOI: 10.1102/1470-7330.2012.0044]

33 **Jiang T**, Kambadakone A, Kulkarni NM, Zhu AX, Sahani DV. Monitoring response to antiangiogenic treatment and predicting outcomes in advanced hepatocellular carcinoma using image biomarkers, CT perfusion, tumor density, and tumor size (RECIST). *Invest Radiol* 2012; **47**: 11-17 [PMID: 21512396 DOI: 10.1097/RLI.0b013e3182199bb5]

34 **Lassau N**, Koscielny S, Chami L, Chebil M, Benatsou B, Roche A, Ducreux M, Malka D, Boige V. Advanced hepatocellular carcinoma: early evaluation of response to bevacizumab therapy at dynamic contrast-enhanced US with quantification--preliminary results. *Radiology* 2011; **258**: 291-300 [PMID: 20980447 DOI: 10.1148/radiol.10091870]

35 **Zhao YL**, Guo QQ, Yang GR, Wang QD. Early changes in apparent diffusion coefficient as an indicator of response to sorafenib in hepatocellular carcinoma. *J Zhejiang Univ Sci B* 2014; **15**: 713-719 [PMID: 25091989 DOI: 10.1631/jzus.B1400010]

36 **Wang S**, Zhou C, Zhao X. Perfusion study of hepatic tumors: use of multi-detector row helical CT and liver perfusion software [abstr]. In: Radiological Society of North America scientific assembly and annual meeting program. Oak Brook, Ill: Radiological Society of North America, 2004: 238

37 **Zocco MA**, Garcovich M, Lupascu A, Di Stasio E, Roccarina D, Annicchiarico BE, Riccardi L, Ainora ME, Ponziani F, Caracciolo G, Rapaccini GL, Landolfi R, Siciliano M, Pompili M, Gasbarrini A. Early prediction of response to sorafenib in patients with advanced hepatocellular carcinoma: the role of dynamic contrast enhanced ultrasound. *J Hepatol* 2013; **59**: 1014-1021 [PMID: 23811306 DOI: 10.1016/j.jhep.2013.06.011]

38 **Baron Toaldo M**, Salvatore V, Marinelli S, Palamà C,

Milazzo M, Croci L, Venerandi L, Cipone M, Bolondi L, Piscaglia F. Use of VEGFR-2 Targeted Ultrasound Contrast Agent for the Early Evaluation of Response to Sorafenib in a Mouse Model of Hepatocellular Carcinoma. *Mol Imaging Biol* 2014; Epub ahead of print [PMID: 25082536 DOI: 10.1007/s11307-014-0764-x]

39 **Shao YY**, Lin ZZ, Hsu C, Shen YC, Hsu CH, Cheng AL. Early alpha-fetoprotein response predicts treatment efficacy of antiangiogenic systemic therapy in patients with advanced hepatocellular carcinoma. *Cancer* 2010; **116**: 4590-4596 [PMID: 20572033 DOI: 10.1002/cncr.25257]

40 **Nakazawa T**, Hidaka H, Takada J, Okuwaki Y, Tanaka Y, Watanabe M, Shibuya A, Minamino T, Kokubu S, Koizumi W. Early increase in α-fetoprotein for predicting unfavorable clinical outcomes in patients with advanced hepatocellular carcinoma treated with sorafenib. *Eur J Gastroenterol Hepatol* 2013; **25**: 683-689 [PMID: 23395995 DOI: 10.1097/MEG.0b013e32835d913b]

41 **Personeni N**, Bozzarelli S, Pressiani T, Rimassa L, Tronconi MC, Sclafani F, Carnaghi C, Pedicini V, Giordano L, Santoro A. Usefulness of alpha-fetoprotein response in patients treated with sorafenib for advanced hepatocellular carcinoma. *J Hepatol* 2012; **57**: 101-107 [PMID: 22414760 DOI: 10.1016/j.jhep.2012.02.016]

42 **Raoul JL**, Bruix J, Greten TF, Sherman M, Mazzaferro V, Hilgard P, Scherubl H, Scheulen ME, Germanidis G, Dominguez S, Ricci S, Nadel A, Moscovici M, Voliotis D, Llovet JM. Relationship between baseline hepatic status and outcome, and effect of sorafenib on liver function: SHARP trial subanalyses. *J Hepatol* 2012; **56**: 1080-1088 [PMID: 22245896 DOI: 10.1016/j.jhep.2011.12.009]

43 **Køstner AH**, Sorensen M, Olesen RK, Grønbæk H, Lassen U, Ladekarl M. Sorafenib in advanced hepatocellular carcinoma: a nationwide retrospective study of efficacy and tolerability. *ScientificWorldJournal* 2013; **2013**: 931972 [PMID: 23431262 DOI: 10.1155/2013/931972]

44 **Takeda H**, Nishikawa H, Osaki Y, Tsuchiya K, Joko K, Ogawa C, Taniguchi H, Orito E, Uchida Y, Izumi N; Japanese Red Cross Liver Study Group. Clinical features associated with radiological response to sorafenib in unresectable hepatocellular carcinoma: a large multicenter study in Japan. *Liver Int* 2014; Epub ahead of print [PMID: 24836552 DOI: 10.1111/liv.12591]

45 **Llovet JM**. Focal gains of VEGFA: candidate predictors of sorafenib response in hepatocellular carcinoma. *Cancer Cell* 2014; **25**: 560-562 [PMID: 24823635 DOI: 10.1016/j.ccr.2014.04.019]

46 **Scartozzi M**, Faloppi L, Svegliati Baroni G, Loretelli C, Piscaglia F, Iavarone M, Toniutto P, Fava G, De Minicis S, Mandolesi A, Bianconi M, Giampieri R, Granito A, Facchetti F, Bitetto D, Marinelli S, Venerandi L, Vavassori S, Gemini S, D'Errico A, Colombo M, Bolondi L, Bearzi I, Benedetti A, Cascinu S. VEGF and VEGFR genotyping in the prediction of clinical outcome for HCC patients receiving sorafenib: the ALICE-1 study. *Int J Cancer* 2014; **135**: 1247-1256 [PMID: 24510746 DOI: 10.1002/ijc.28772]

47 **Tanoglu A**, Karagoz E. Predictive role of the neutrophil-to-lymphocyte ratio in patients with advanced hepatocellular carcinoma receiving sorafenib. *Asian Pac J Cancer Prev* 2014; **15**: 1063 [PMID: 24568452 DOI: 10.7314/APJCP.2014.15.2.1063]

48 **Wei K**, Wang M, Zhang W, Mu H, Song TQ. Neutrophil-lymphocyte ratio as a predictor of outcomes for patients with hepatocellular carcinoma undergoing TAE combined with Sorafenib. *Med Oncol* 2014; **31**: 969 [PMID: 24793745 DOI: 10.1007/s12032-014-0969-5]

49 **Li X**, Chen ZH, Ma XK, Chen J, Wu DH, Lin Q, Dong M, Wei L, Wang TT, Ruan DY, Lin ZX, Xing YF, Deng Y, Wu XY, Wen JY. Neutrophil-to-lymphocyte ratio acts as a prognostic factor for patients with advanced hepatocellular carcinoma. *Tumour Biol* 2014; **35**: 11057-11063 [PMID: 25095975 DOI: 10.1007/s13277-014-2360-8]

50 **Hu BG**, Liu LP, Chen GG, Ye CG, Leung KK, Ho RL, Lin MC, Lai PB. Therapeutic efficacy of improved α-fetoprotein promoter-mediated tBid delivered by folate-PEI600-cyclodextrin nanopolymer vector in hepatocellular carcinoma. *Exp Cell Res* 2014; **324**: 183-191 [PMID: 24726886 DOI: 10.1016/j.yexcr.2014.04.005]

51 **Jelic S**; ESMO Guidelines Working Group. Hepatocellular carcinoma: ESMO clinical recommendations for diagnosis, treatment and follow-up. *Ann Oncol* 2009; **20** Suppl 4: 41-45 [PMID: 19454459 DOI: 10.1093/annonc/mdp124]

52 **Lavi O**, Skinner J, Gottesman MM. Network features suggest new hepatocellular carcinoma treatment strategies. *BMC Syst Biol* 2014; **8**: 88 [PMID: 25070212 DOI: 10.1186/s12918-014-0088-0]

53 **Fernando J**, Malfettone A, Cepeda EB, Vilarrasa-Blasi R, Bertran E, Raimondi G, Fabra A, Alvarez-Barrientos A, Fernández-Salguero P, Fernández-Rodríguez CM, Giannelli G, Sancho P, Fabregat I. A mesenchymal-like phenotype and expression of CD44 predict lack of apoptotic response to sorafenib in liver tumor cells. *Int J Cancer* 2015; **136**: E161-E172 [PMID: 25053293 DOI: 10.1002/ijc.29097]

54 **Wang WQ**, Liu L, Xu HX, Sun HC, Wu CT, Zhu XD, Zhang W, Xu J, Liu C, Long J, Ni QX, Tang ZY, Yu XJ. The combination of HTATIP2 expression and microvessel density predicts converse survival of hepatocellular carcinoma with or without sorafenib. *Oncotarget* 2014; **5**: 3895-3906 [PMID: 25008315]

55 **Agilli M**, Aydin FN, Kurt YG. Value of neutrophil lymphocyte ratio in patients with hepatocellular carcinoma undergoing TAE combined with Sorafenib. *Med Oncol* 2014; **31**: 68 [PMID: 24927956 DOI: 10.1007/s12032-014-0068-7]

P- Reviewer: Castiella A, He JY **S- Editor**: Tian YL
L- Editor: A **E- Editor**: Liu SQ

World Journal of Hepatology

Submit a Manuscript: http://www.wjgnet.com/esps/
Help Desk: http://www.wjgnet.com/esps/helpdesk.aspx
DOI: 10.4254/wjh.v7.i1.40

World J Hepatol 2015 January 27; 7(1): 40-43
ISSN 1948-5182 (online)

TOPIC HIGHLIGHT

WJH 6th Anniversary Special Issues (2): Hepatocellular carcinoma

Review of preoperative transarterial chemoembolization for resectable hepatocellular carcinoma

Zhi-Hui Gao, Dou-Sheng Bai, Guo-Qing Jiang, Sheng-Jie Jin

Zhi-Hui Gao, Dou-Sheng Bai, Guo-Qing Jiang, Sheng-Jie Jin, Hepato-bilio-pancreatic Surgery Department, Subei People's Hospital, Yangzhou University, Yangzhou 225001, Jiangsu Province, China

Author contributions: Gao ZH and Bai DS performed the majority of the work for this review; Bai DS designed the review; Gao ZH wrote the manuscript; Jiang GQ and Jin SJ assisted with designing, literature searching and manuscript editing.

Correspondence to: Dou-Sheng Bai, MD, Professor, Chief, Hepato-bilio-pancreatic Surgery Department, Subei People's Hospital, Yangzhou University, 98 Nantong West Road, Yangzhou 225001, Jiangsu Province, China. bdsno1@hotmail.com
Telephone: +86-514-87373375
Fax: +86-514-87990188

Received: July 20, 2014
Peer-review started: July 20, 2014
First decision: October 14, 2014
Revised: October 28, 2014
Accepted: November 17, 2014
Article in press: November 19, 2014
Published online: January 27, 2015

Abstract

Hepatocellular carcinoma (HCC) is one of the few cancers whose incidence has been continually increasing over recent years. Resection of HCC offers the only hope for cure. However, recurrences are common in patients who have undergone resection. In our opinion, the effectiveness with which transarterial chemoembolization (TACE) as a neoadjuvant therapy for resectable HCC prevents recurrence and prolongs survival has not been conclusively demonstrated. All published meta-analyses have consistently failed to demonstrate that preoperative TACE improves the prognosis of resectable HCC. We believe that these published articles have several limitations and have our own views about the results of meta-analyses. It is very important that the scientific community shed more light on the pathogenesis of HCC and relate this to choice of therapy. This review mainly concerns our understanding of preoperative TACE for resectable HCC and briefly addresses desirable directions for future studies.

Key words: Hepatocellular carcinoma; Surgical resection; Transarterial chemoembolization; Preoperative; Review

Core tip: Hepatocellular carcinoma (HCC) is the sixth most common neoplasm and third most frequent cause of cancer deaths. Resection of HCC offers the only hope for a cure, yet post-resection recurrence is common. The effectiveness of transarterial chemoembolization (TACE) as a neoadjuvant therapy for resectable HCC has not been conclusively demonstrated. All published meta-analyses have consistently failed to demonstrate its effectiveness. We believe these articles have several limitations and TACE is theoretically helpful in multinodular or infiltrative types of HCC.

Gao ZH, Bai DS, Jiang GQ, Jin SJ. Review of preoperative transarterial chemoembolization for resectable hepatocellular carcinoma. *World J Hepatol* 2015; 7(1): 40-43 Available from: URL: http://www.wjgnet.com/1948-5182/full/v7/i1/40.htm DOI: http://dx.doi.org/10.4254/wjh.v7.i1.40

INTRODUCTION

Hepatocellular carcinoma (HCC), the commonest

primary liver malignancy, sixth most common neoplasm, and third most frequent cause of cancer deaths, is increasing in incidence and prevalence both nationally and internationally. Potentially curative treatments for HCC include surgical resection, liver transplantation, and local ablative therapy. Among these, hepatectomy is considered the standard treatment for offering a chance of cure to patients with preserved liver function[1-3]. However, long-term survival after hepatectomy is unsatisfactory because of the high incidence of tumor recurrence. Even after radical surgery, tumor recurrence occurs in 75%-100% of HCC patients and is their major cause of death. This has led to many efforts to devise effective therapeutic strategies aimed at controlling tumor recurrence and thus prolonging long-term survival after HCC resection[4].

With improvements in interventional radiology, transarterial embolization (TAE) and transarterial chemoembolization (TACE) have been advocated as standard loco-regional palliative treatments for inoperable HCC. Some researchers believe that combining TACE and hepatectomy would improve long-term outcomes. This possibility has generated significant debate and numerous studies of the combination of TACE and curative resection for HCC since it was first described in the early 1990s. Some clinicians have attempted to employ TACE preoperatively as a loco-regional therapy to affect the course of the disease by decreasing tumor size, inducing tumor necrosis and by preventing tumor cell dissemination during surgery. However, others feel that this rationale may not be justified, and if the tumor is already resectable, administering TACE may complicate liver mobilization owing to the perihepatic adhesions that may occur following the TACE procedure[5-8]. This review summarizes current published reports linking TACE or TAE with surgical resection of HCC with the aim to suggest generally acceptable guidelines.

CONTROVERSIAL RESULTS OF PREOPERATIVE TACE

HCC commonly arises in patients with chronic viral or alcoholic liver disease: these patients' livers are likely to harbor multiple and independent clones of premalignant cells and, when these cells are further exposed to carcinogenic insults, unicentric or multicentric carcinogenesis follows. Intrahepatic recurrence can represent either *de novo* tumor formation or intrahepatic metastasis of a clonally identical neoplasm. Early recurrence is primarily attributable to intrahepatic metastases, whereas late recurrence tends to be multicentric in origin. No matter how recurrences occur, it is generally believed that recurrences in the early postoperative period arise not because of inadequate resection of the primary tumor but either because of pre-existing microscopic tumor foci that were not detected by imaging modalities or because of malignant cells that were disseminated during surgical manipulation. Nowadays, the recurrence rate after resection is approximately 50% at 2 years and 75% at 5 years according to most series[9]. If any neoadjuvant therapy reduced the viability of HCC cells and prevented or effectively managed recurrences, the survival after resection of HCC would improve.

HCCs are supplied for the most part by the hepatic artery. Catheter-based techniques take advantage of this unusual architecture to deliver intra-arterial therapy directly to the tumor bed. Thus, TACE induces ischemic necrosis of tumors by arterial injection of chemotherapeutic drugs and embolizing agents. The aims of neoadjuvant therapy are to reduce tumor mass, thus making surgery easier, and destroy microscopic tumor foci and reduce the vascularity of tumors. Preoperative arterial injection of chemotherapeutic drugs and embolizing agents (TACE) reportedly can achieve all of the above-stated aims, as well as reduce the viability of HCC cells[10-12]. However, although several studies have demonstrated that preoperative TACE prevents tumor recurrence and prolongs survival in patients with HCC, others have failed to demonstrate these outcomes. Arguments against the use of preoperative TACE include: first, the associated complications, namely, liver function impairment and increased risk of liver failure; second, the associated delay in performing definitive surgery, during which time some resectable tumors become unresectable; third, this form of therapy mainly affects well-differentiated HCC and fails to completely kill poorly differentiated cells, thus the residual HCC cells are more aggressive; and last, incomplete HCC necrosis weakens adhesiveness within the tumor, thus facilitating the release of cancer cells from the primary tumor into the bloodstream. In addition, the effects of preoperative TACE on long-term outcome are controversial: it has not been proven that it prevents tumor recurrence and prolongs survival.

SYSTEMATIC REVIEW AND META-ANALYSIS

To produce more reliable evidence for clinical decision-making, randomized controlled studies and nonrandomized controlled studies have been subjected to meta-analysis. Several such meta-analyses provide the largest body of information currently available for assessing the role of preoperative TACE in patients with HCC. Their findings are mainly expressed in terms of disease-free and overall survival. To minimize heterogeneity, these studies have utilized strict inclusion criteria. For example, the most recently published meta-analysis, authored by Cheng *et al*[13], defined cure of HCC strictly as: (1) tumor had been resected; (2) negative surgical margins had been confirmed histologically; (3) no evidence of extrahepatic metastasis; and (4) no residual tumor according to dynamic contrast-enhanced computed tomography or ultrasonography performed 3-5 wk postoperatively. All published meta-analyses have failed to show that preoperative TACE improves the prognosis[14-19]. Although the cited meta-analyses are well designed and conducted, and, more importantly, have reported consistent findings, we

believe it is prudent to recommend TACE as a routine preoperative procedure for resectable HCC for the reasons explained below.

NEW QUESTIONS AND IDEAS

Although the mechanisms of recurrence after surgical resection of HCC remain controversial, it is noteworthy that early recurrence mainly takes the form of intrahepatic recurrence, which correlates strongly with tumor-related variables, whereas late recurrence mainly takes the form of multicentric foci, this correlating strongly with the condition of the remnant liver. Relevant tumor-related variables include vascular infiltration, tumor size, tumor capsule, and satellite nodules or dissemination of tumor cells during hepatectomy. Thus, both main tumor and the surrounding tissue may contain detectable or undetectable satellite nodules and the main route of early post-resection intrahepatic recurrence is spread *via* the portal vein. Clearly, hepatectomy cannot address all of these possibilities. In theory, TACE could; however, published meta-analyses studies do not support this contention[20-23].

However, the available studies have several limitations. We have found that the various meta-analyses use very heterogeneous definitions of resectable HCC. They also use different definitions of cure of HCC and different inclusion criteria. Thus, their findings indicate only that preoperative TACE does not improve the prognosis of resectable HCC as defined in that particular study.

Morphologic types of HCC include focal/nodular, massive, and diffuse/infiltrative. The infiltrative type accounts for 7%-15% of HCC cases. Although infiltrative HCC is not uncommon, especially in regions where hepatitis B virus is predominant, there are few published data concerning treatment of patients with this variant because infiltrative HCC almost always presents as an advanced diffuse tumor and surgery is therefore rarely indicated. The cumulative survival rates of patients with infiltrative HCC are reportedly 33.3% at 1 year and 13.6% at 3 years, independent of the treatment received[24-27]. About 15.9 % of reported patients with infiltrative HCC have undergone TACE repeatedly, with curative intent, and have survived more than 2 years. These long-term survivors are over 60 years old, have preserved hepatic function at the time of initial diagnosis, and have a major portal vein thrombosis without parasitic supply. In addition, published studies have also ignored the multinodular type of HCC[28-31]. Taking these observations into consideration allows the following improved understanding of the findings of published meta-analyses. First, TACE would indeed be helpful for treating small satellite nodules and destroying microscopic tumor foci, thus facilitating achievement of adequate resection, which would prolong the duration of survival. However, these considerations apply only in certain types of HCC, namely, to the best of our knowledge, multinodular and infiltrative types. Second, these are not the main types and have often been excluded from published meta-analyses. In conclusion, we still provocatively recommend preoperative TACE for resectable HCC, especially for multinodular and infiltrative types, to reduce recurrence rates. We also believe it is prudent to recommend TACE for patients with definite single nodular or massive HCC. We also recommend assessing the effects of preoperative TACE according to the various morphologic types.

CONCLUSION

We still cannot be certain whether preoperative TACE for resectable HCC is beneficial. Although we believe it is helpful in multinodular or infiltrative types of HCC, there is limited evidence for this. We believe it makes sense to assess the effects of preoperative TACE according to the various morphologic types. Thus, larger, well designed, randomized clinical trials are needed to detect realistically achievable treatment benefits.

REFERENCES

1 **Maluccio M**, Covey A. Recent progress in understanding, diagnosing, and treating hepatocellular carcinoma. *CA Cancer J Clin* 2012; **62**: 394-399 [PMID: 23070690 DOI: 10.3322/caac.21161]

2 **Kim HY**, Park JW. Clinical trials of combined molecular targeted therapy and locoregional therapy in hepatocellular carcinoma: past, present, and future. *Liver Cancer* 2014; **3**: 9-17 [PMID: 24804173 DOI: 10.1159/000343854]

3 **Zheng YB**, Meng QW, Zhao W, Liu B, Huang JW, He X, Li Y, Hu BS, Lu LG. Prognostic value of serum vascular endothelial growth factor receptor 2 response in patients with hepatocellular carcinoma undergoing transarterial chemoembolization. *Med Oncol* 2014; **31**: 843 [PMID: 24442426 DOI: 10.1007/s12032-014-0843-5]

4 **Kaibori M**, Tanigawa N, Kariya S, Ikeda H, Nakahashi Y, Hirohara J, Koreeda C, Seki T, Sawada S, Okazaki K, Kwon AH. A prospective randomized controlled trial of preoperative whole-liver chemolipiodolization for hepatocellular carcinoma. *Dig Dis Sci* 2012; **57**: 1404-1412 [PMID: 22271410 DOI: 10.1007/s10620-012-2029-3]

5 **Zhang L**, Hu P, Chen X, Bie P. Transarterial chemoembolization (TACE) plus sorafenib versus TACE for intermediate or advanced stage hepatocellular carcinoma: a meta-analysis. *PLoS One* 2014; **9**: e100305 [PMID: 24945380]

6 **Chen BB**, Shih IL, Wu CH, Hsu C, Chen CH, Shih TT, Liu KL, Liang PC. Comparison of characteristics and transarterial chemoembolization outcomes in patients with unresectable hepatocellular carcinoma and different viral etiologies. *J Vasc Interv Radiol* 2014; **25**: 371-378 [PMID: 24468045 DOI: 10.1016/j.jvir.2013.10.027]

7 **Roayaie S**. TACE vs. surgical resection for BCLC stage B HCC. *J Hepatol* 2014; **61**: 3-4 [PMID: 24727122 DOI: 10.1016/j.jhep.2014.04.005]

8 **Zhang L**, Yin X, Gan YH, Zhang BH, Zhang JB, Chen Y, Xie XY, Ge NL, Wang YH, Ye SL, Ren ZG. Radiofrequency ablation following first-line transarterial chemoembolization for patients with unresectable hepatocellular carcinoma beyond the Milan criteria. *BMC Gastroenterol* 2014; **14**: 11 [PMID: 24410841 DOI: 10.1186/1471-230X-14-11]

9 **Gluer AM**, Cocco N, Laurence JM, Johnston ES, Hollands MJ, Pleass HC, Richardson AJ, Lam VW. Systematic review of actual 10-year survival following resection for hepatocellular carcinoma. *HPB* (Oxford) 2012; **14**: 285-290 [PMID: 22487065 DOI: 10.1111/j.1477-2574.2012.00446.x]

10 **Fiore F**, Del Prete M, Franco R, Marotta V, Ramundo V,

Marciello F, Di Sarno A, Carratù AC, de Luca di Roseto C, Colao A, Faggiano A. Transarterial embolization (TAE) is equally effective and slightly safer than transarterial chemoembolization (TACE) to manage liver metastases in neuroendocrine tumors. *Endocrine* 2014; **47**: 177-182 [PMID: 24385266 DOI: 10.1007/s12020-013-0130-9]

11 **Kim JW**, Kim JH, Sung KB, Ko HK, Shin JH, Kim PN, Choi HK, Ko GY, Yoon HK, Chun SY, Gwon DI. Transarterial chemoembolization vs. radiofrequency ablation for the treatment of single hepatocellular carcinoma 2 cm or smaller. *Am J Gastroenterol* 2014; **109**: 1234-1240 [PMID: 24935276 DOI: 10.1038/ajg.2014.152]

12 **Cheung TT**, Poon RT, Jenkins CR, Chu FS, Chok KS, Chan AC, Tsang SH, Dai WC, Yau TC, Chan SC, Fan ST, Lo CM. Survival analysis of high-intensity focused ultrasound therapy vs. transarterial chemoembolization for unresectable hepatocellular carcinomas. *Liver Int* 2014; **34**: e136-e143 [PMID: 24451026 DOI: 10.1111/liv.12474]

13 **Cheng X**, Sun P, Hu QG, Song ZF, Xiong J, Zheng QC. Transarterial (chemo)embolization for curative resection of hepatocellular carcinoma: a systematic review and meta-analyses. *J Cancer Res Clin Oncol* 2014; **140**: 1159-1170 [PMID: 24752339 DOI: 10.1007/s00432-014-1677-4]

14 **Zhou WP**, Lai EC, Li AJ, Fu SY, Zhou JP, Pan ZY, Lau WY, Wu MC. A prospective, randomized, controlled trial of preoperative transarterial chemoembolization for resectable large hepatocellular carcinoma. *Ann Surg* 2009; **249**: 195-202 [PMID: 19212170 DOI: 10.1097/SLA.0b013e3181961c16]

15 **Choi J**, Shim JH, Shin YM, Kim KM, Lim YS, Lee HC. Clinical significance of the best response during repeated transarterial chemoembolization in the treatment of hepatocellular carcinoma. *J Hepatol* 2014; **60**: 1212-1218 [PMID: 24486088 DOI: 10.1016/j.jhep.2014.01.014]

16 **Beheshti MV**, Meek J. Calculation of operating expenses for conventional transarterial chemoembolization in an academic medical center: a step toward defining the value of transarterial chemoembolization. *J Vasc Interv Radiol* 2014; **25**: 567-574 [PMID: 24462006 DOI: 10.1016/j.jvir.2013.10.023]

17 **Zhou Y**, Zhang X, Wu L, Ye F, Su X, Shi L, Li B. Meta-analysis: preoperative transcatheter arterial chemoembolization does not improve prognosis of patients with resectable hepatocellular carcinoma. *BMC Gastroenterol* 2013; **13**: 51 [PMID: 23509884 DOI: 10.1186/1471-230X-13-51]

18 **Sellers MT**, Huggins S, Kegley K, Pollinger HS, Shrestha R, Johnson MW, Stein LL, Panjala C, Tan M, Arepally A, Jacobs L, Caldwell C, Bosley M, Citron SJ. Multivariate analysis of prognostic factors for survival following doxorubicin-eluting bead transarterial chemoembolization for hepatocellular carcinoma. *J Vasc Interv Radiol* 2013; **24**: 647-654 [PMID: 23384831 DOI: 10.1016/j.jvir.2012.12.003]

19 **Chua TC**, Liauw W, Saxena A, Chu F, Glenn D, Chai A, Morris DL. Systematic review of neoadjuvant transarterial chemoembolization for resectable hepatocellular carcinoma. *Liver Int* 2010; **30**: 166-174 [PMID: 19912531 DOI: 10.1111/j.1478-3231.2009.02166.x]

20 **Jang ES**, Yoon JH, Chung JW, Cho EJ, Yu SJ, Lee JH, Kim YJ, Lee HS, Kim CY. Survival of infiltrative hepatocellular carcinoma patients with preserved hepatic function after treatment with transarterial chemoembolization. *J Cancer Res Clin Oncol* 2013; **139**: 635-643 [PMID: 23283527 DOI: 10.1007/s00432-012-1364-2]

21 **Rosenkrantz AB**, Lee L, Matza BW, Kim S. Infiltrative hepatocellular carcinoma: comparison of MRI sequences for lesion conspicuity. *Clin Radiol* 2012; **67**: e105-e111 [PMID: 23026725 DOI: 10.1016/j.crad.2012.08.019]

22 **Mehta N**, Fidelman N, Sarkar M, Yao FY. Factors associated with outcomes and response to therapy in patients with infiltrative hepatocellular carcinoma. *Clin Gastroenterol Hepatol* 2013; **11**: 572-578 [PMID: 23333661 DOI: 10.1016/j.cgh.2012.12.030]

23 **Mathews P**, Lee D, Chung YH, Kim JA, Lee JH, Jin YJ, Park W, Lyu H, Jaffee E, Zheng L, Yu E, Lee YJ. Effects of genomic changes in hepatitis B virus on postoperative recurrence and survival in patients with hepatocellular carcinoma. *Ann Surg Oncol* 2013; **20**: 1216-1222 [PMID: 23104706 DOI: 10.1245/s10434-012-2706-7]

24 **Liu L**, Wang W, Chen H, Zhao Y, Bai W, Yin Z, He C, Jia J, Yang M, Xia J, Fan D, Han G. EASL- and mRECIST-evaluated responses to combination therapy of sorafenib with transarterial chemoembolization predict survival in patients with hepatocellular carcinoma. *Clin Cancer Res* 2014; **20**: 1623-1631 [PMID: 24493832 DOI: 10.1158/1078-0432.CCR-13-1716]

25 **Kneuertz PJ**, Demirjian A, Firoozmand A, Corona-Villalobos C, Bhagat N, Herman J, Cameron A, Gurakar A, Cosgrove D, Choti MA, Geschwind JF, Kamel IR, Pawlik TM. Diffuse infiltrative hepatocellular carcinoma: assessment of presentation, treatment, and outcomes. *Ann Surg Oncol* 2012; **19**: 2897-2907 [PMID: 22476754 DOI: 10.1245/s10434-012-2336-0]

26 **Lee D**, Chung YH, Kim JA, Lee YS, Lee D, Jang MK, Kim KM, Lim YS, Lee HC, Lee YS. Transforming growth factor beta 1 overexpression is closely related to invasiveness of hepatocellular carcinoma. *Oncology* 2012; **82**: 11-18 [PMID: 22269311 DOI: 10.1159/000335605]

27 **Liu L**, Zhang C, Zhao Y, Qi X, Chen H, Bai W, He C, Guo W, Yin Z, Fan D, Han G. Transarterial chemoembolization for the treatment of advanced hepatocellular carcinoma with portal vein tumor thrombosis: prognostic factors in a single-center study of 188 patients. *Biomed Res Int* 2014; **2014**: 194278 [PMID: 24800212 DOI: 10.1155/2014/194278]

28 **Liu PH**, Lee YH, Hsia CY, Hsu CY, Huang YH, Chiou YY, Lin HC, Huo TI. Surgical resection versus transarterial chemoembolization for hepatocellular carcinoma with portal vein tumor thrombosis: a propensity score analysis. *Ann Surg Oncol* 2014; **21**: 1825-1833 [PMID: 24499831 DOI: 10.1245/s10434-014-3510-3]

29 **Jin YJ**, Lee JW, Choi YJ, Chung HJ, Kim YS, Lee KY, Ahn SI, Shin WY, Cho SG, Jeon YS. Surgery versus transarterial chemoembolization for solitary large hepatocellular carcinoma of BCLC stage A. *J Gastrointest Surg* 2014; **18**: 555-561 [PMID: 24420729 DOI: 10.1007/s11605-013-2440-x]

30 **Du ZG**, Wei YG, Chen KF, Li B. Risk factors associated with early and late recurrence after curative resection of hepatocellular carcinoma: a single institution's experience with 398 consecutive patients. *Hepatobiliary Pancreat Dis Int* 2014; **13**: 153-161 [PMID: 24686542]

31 **Kokabi N**, Camacho JC, Xing M, Qiu D, Kitajima H, Mittal PK, Kim HS. Apparent diffusion coefficient quantification as an early imaging biomarker of response and predictor of survival following yttrium-90 radioembolization for unresectable infiltrative hepatocellular carcinoma with portal vein thrombosis. *Abdom Imaging* 2014; **39**: 969-978 [PMID: 24740759 DOI: 10.1007/s00261-014-0127-8]

P- Reviewer: Bester L **S- Editor**: Qi Y
L- Editor: A **E- Editor**: Liu SQ

World Journal of Hepatology

Submit a Manuscript: http://www.wjgnet.com/esps/
Help Desk: http://www.wjgnet.com/esps/helpdesk.aspx
DOI: 10.4254/wjh.v7.i1.44

World J Hepatol 2015 January 27; 7(1): 44-52
ISSN 1948-5182 (online)

TOPIC HIGHLIGHT

WJH 6th Anniversary Special Issues (5): Hepatitis C virus

Adiponectin serum level in chronic hepatitis C infection and therapeutic profile

Valentina Peta, Carlo Torti, Natasa Milic, Alfredo Focà, Ludovico Abenavoli

Valentina Peta, Alfredo Focà, Ludovico Abenavoli, Department of Health Sciences, University Magna Græcia, Campus Germaneto, 88100 Catanzaro, Italy
Carlo Torti, Department of Medical and Surgical Sciences, University Magna Graecia, Campus Germaneto, 88100 Catanzaro, Italy
Natasa Milic, Department of Pharmacy, University of Novi Sad, 21000 Novi Sad, Serbia
Author contributions: Peta V designed the paper, performed research of literature data and wrote the paper; Milic N performed research of literature data; Torti C and Focà A critically revised the paper; Abenavoli L critically revised the paper and drafted the article.

Correspondence to: Ludovico Abenavoli, MD, PhD, Department of Health Sciences, University Magna Græcia, Campus Germaneto, Viale Europa, 88100 Catanzaro, Italy. l.abenavoli@unicz.it
Telephone: +39-0961-3694387
Fax: +39-0961-754220
Received: June 5, 2014
Peer-review started: June 8, 2014
First decision: July 10, 2014
Revised: July 20, 2014
Accepted: November 17, 2014
Article in press: November 19, 2014
Published online: January 27, 2015

Abstract

Hepatic steatosis is commonly seen in the patients with chronic hepatitis C virus (HCV) infection. HCV is closely associated with lipid metabolism, and viral steatosis is more common in genotype 3 infection owing to a direct cytopathic effect of HCV core protein. In non-genotype 3 infection, hepatic steatosis is considered largely to be the result of the alterations in host metabolism; metabolic steatosis is primarily linked with HCV genotype 1. Adipose tissue secretes different hormones involved in glucose and lipid metabolisms. It has been demonstrated that adipocytokines are involved in the pathogenesis of non-alcoholic fatty liver disease, as the decreased plasma adiponectin levels, a soluble matrix protein expressed by adipoctyes and hepatocyte, are associated with liver steatosis. Various studies have shown that steatosis is strongly correlated negatively with adiponectin in the patients with HCV infection. The role of adiponectin in hepatitis C virus induced steatosis is still not completely understood, but the relationship between adiponectin low levels and liver steatosis is probably due to the ability of adiponectin to protect hepatocytes from triglyceride accumulation by increasing β-oxidation of free fatty acid and thus decreasing *de novo* free fatty acid production.

Key words: Hepatitis C virus; Adiponectin; Metabolism; Insulin resistance; Hepatitis C virus core protein

Core tip: Three main types of steatosis in the patients with hepatitis C virus (HCV) infection are known: a metabolic type associated with metabolic syndrome, viral steatosis directly triggered by the virus and a "middle ground" between metabolic and viral mechanisms. Liver steatosis is a common histological feature of chronic hepatitis C infection, and the recent studies have shown that it is strongly correlated negatively with adiponectin levels. This finding suggests that adiponectin may have a role in modulating the progression of hepatic steatosis in HCV infected patients.

Peta V, Torti C, Milic N, Focà A, Abenavoli L. Adiponectin serum level in chronic hepatitis C infection and therapeutic

profile. *World J Hepatol* 2015; 7(1): 44-52 Available from: URL: http://www.wjgnet.com/1948-5182/full/v7/i1/44.htm DOI: http://dx.doi.org/10.4254/wjh.v7.i1.44

INTRODUCTION

Hepatitis C virus (HCV) infection is a common liver disease with an estimated 3% of the world's population chronically infected with this viral pathogen. The majority of the infected individuals (60%-80%) develop chronic hepatitis C (CHC), which is associated with progressive liver fibrosis and a risk of cirrhosis after 20 years[1-3].

About 20%-30% of chronic HCV infections are associated with hepatic steatosis, type Ⅱ diabetes[4], insulin resistance (IR) and cardiovascular diseases[5]. Hepatic steatosis, defined as an excessive lipid accumulation in the cytoplasm of hepatocytes, is a frequent histological feature in the patients chronically infected with HCV. However, the mechanisms that have induced hepatic steatosis in HCV-infected patients are difficult to understand, due to the possible co-existence of several factors[6]. Different studies have shown that there are three main types of steatosis defined in the HCV patients: metabolic steatosis, viral steatosis and a "middle ground" between metabolic and viral mechanisms[7,8]. The first type has been described in the patients infected with HCV who also suffer from other metabolic disorders such as obesity, dyslipidemia and diabetes mellitus[9]. Metabolic steatosis is primarily linked with HCV genotype 1, but one study has shown the absence of the relationship with viral load and the severity of steatosis in the patients infected by genotype 1[10]. Viral steatosis develops in the absence of other steatogenic co-factors and is linked with HCV genotype 3 infection[11]. In viral steatosis lipid accumulation in hepatocytes may be the result of a direct cytopathic effect of HCV core protein. Different experiments conducted *in vitro* and in transgenic mice, have suggested that the nucleocapsid protein of HCV may be involved in the pathogenesis of triglyceride accumulation in hepatocytes[12,13]. Some other experiments have provided a correlation between the level of intrahepatic HCV genotype 3 ribonucleic acid (RNA) and severity of the steatosis[14] and identified specific "steatogenic" sequences in HCV-3, particularly phenylalanine (F) has been shown to be specifically associated with higher levels of lipid accumulation in cellular models *in vitro*[15]. All these findings are also supported by the observation that the degree of liver steatosis is directly related to the level of HCV replication as measured by serum HCV RNA, at least in the patients with HCV-3 infection in the absence of confounding metabolic causes of steatosis[16].

The third type of steatosis can be considered a "middle ground" between the first and the second one. Undoubtedly, this kind of steatosis is a combination of viral and metabolic factors and is associated with a direct interference of HCV core protein in the intracellular, post-receptorial pathways of insulin. This evidence, mostly found in the HCV genotype 1b patients, has convinced some authors to coin the term virus associated steato-hepatitis[17,18]. Numerous studies have shown the involvement of HCV in steatosis. Some insights into the pathways of steato-hepatitis are defined by impaired lipid accumulation due to hepatic loss of adiponectin receptors, which play an important role in fatty acid accumulation by elevating the expression levels of the enzyme AMP-activated protein kinase (AMPK), acetyl-CoA carboxylase (ACC), fatty acid synthase, liver gluconeogenic enzyme and phosphoenol pyruvate carboxy kinase due to HCV infection[6,19-21]. Various studies have shown that steatosis is strongly correlated negatively with adiponectin in the patients with chronic HCV infection, and this finding suggests that adiponectin may have a role in modulating the progression of hepatic steatosis, fibrosis and inflammation[22]. The main objective of this review is to discuss the biological effect of adiponectin and its receptors in the progression of liver steatosis in the HCV-infected patients and the possible role of adiponectin as a therapeutic target for the treatment of fatty liver diseases.

PHYSIOLOGICAL AND HEPATO-PROTECTIVE ROLE OF ADIPONECTIN

Adipose tissue is an active endocrine organ which secretes a number of hormones involved in glucose/lipid metabolism. Adiponectin is a soluble matrix protein expressed exclusively by adipocytes and hepatocytes[23]. Recent studies have demonstrated adiponectin mRNA expression in liver after injury and skeletal muscle and that its expression and serum levels are reduced in humans and animals with obesity and insulin resistance[24,25]. Adiponectin exists in three forms: low molecular weight trimers, medium molecular weight hexamers, and high molecular weight (HMW) multimers.

HMW adiponectin is thought to have more biological activity than other two forms. Human adiponectin gene is located at chromosome 3q27, and it codes for a 244 amino acid polypeptide. The primary sequence of adiponectin contains a signal peptide at the N-terminus, short hypervariable region and C-terminal half of the protein with a globular domain[26].

Adiponectin expression is reduced in obesity[27], insulin resistance and type 2 diabetes, and the plasma concentrations are inversely related to body weight, especially visceral adiposity[27-29]. Adiponectin is also inversely associated with other traditional cardiovascular risk factors, such as blood pressure, low-density lipoprotein cholesterol and triglyceride levels[30,31], and is positively related to high-density lipoprotein cholesterol levels[32]. A Recent research has indicated that adiponectin has anti-inflammatory properties, producing the anti-inflammatory mediator interleukin (IL)-10 in primary human monocytes, monocyte-derived macrophages and dendritic cells. In addition, adiponectin significantly impaired the production of the pro-inflammatory cytokine interferon-γ in human

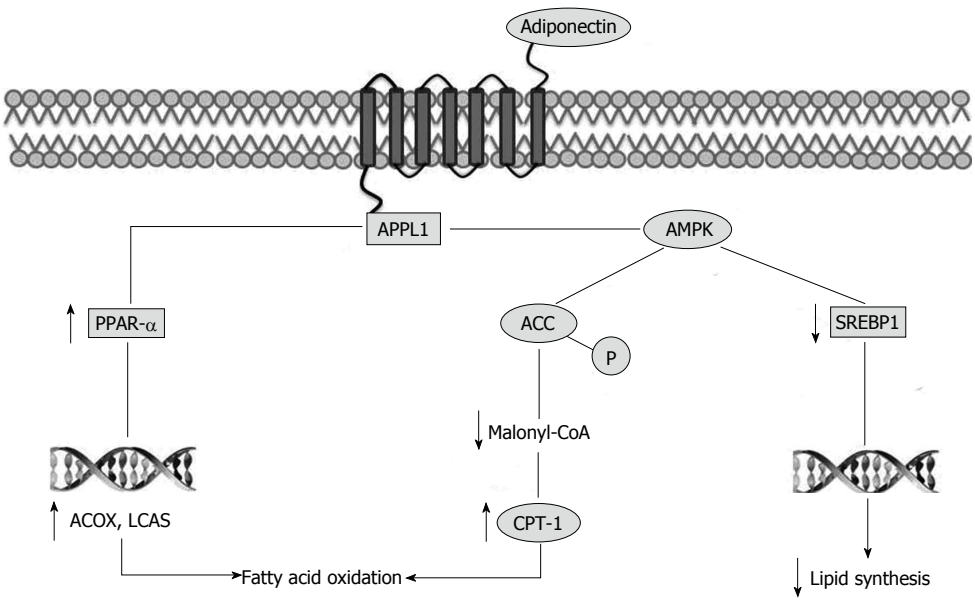

Figure 1 Molecular pathways involved in anti-steatotic effect of adiponectin. The interaction between adiponectin receptor and APPL1 causes activation of AMPK. AMPK inhibits ACC by phosphorylation. Inhibition of ACC increases fatty acid oxidation by blocking the production of malonyl-CoA, the allosteric inhibitor of carnitine palmitoyl transferase 1. AMPK downregulates the expression of SREBP1c, a transcription factor that regulates different genes involved in lipid synthesis. Finally, APPL1 stimulates PPAR-α, another transcriptional factor controlling genes involved in fat oxidation. APPL1: Phosphotyrosine interaction, PH domain and leucine zipper containing 1; AMPK: AMP-activated protein kinase; ACC: Acetyl-CoA carboxylase; SREBP1: Sterol regulatory element-binding protein 1; PPAR-α: Peroxisome proliferator-activated receptor alpha; CPT-1: Carnitine palmitoyl transferase 1; ACOX: Acyl-CoA oxidase; LCAS: Long chain acyl-CoA synthetase.

macrophages[33].

Adiponectin exerts its action *via* its two receptors, adiponectin receptor1 (Adipo R1) and Adipo R2. In mice, Adipo R1 is expressed abundantly in skeletal muscles, while Adipo R2 is considered as the primary transcript in liver. Adipo R1 and Adipo R2 are structurally related integral plasma membrane proteins with seven membrane-spanning domains. AdipoR1 possesses high affinity to the globular form of adiponectin and low affinity to full-length adiponectin, whereas Adipo R2 exhibits intermediate binding affinity to both the globular and the full-length adiponectin[34]. Adipo R1 and R2 mediate increased AMPK activities, peroxisome proliferator-activated receptor alpha (PPAR-α) activities, fatty-acid oxidation and glucose uptake[35]. To confirm the physiological role of these receptors, Adipo R knockout mice have been generated, and in wild-type mice, adiponectin have lowered plasma glucose levels, whereas this effect of adiponectin has completely been abrogated in Adipo R1 and R2 double knockout mice[36,37].

It is known that adiponectin and its receptors have hepato-protective role in fatty liver diseases and steatosis development[35,38]. Adiponectin is believed to protect hepatocytes from triglyceride accumulation by increasing β-oxidation of free fatty acid and/or decreasing *de novo* free fatty acid production in hepatocytes[39]. Indeed, it has been shown that adiponectin stimulates AMPK in different tissues including liver. The precise mechanisms whereby adiponectin activates AMPK remain to be determined. However, phosphotyrosine interaction, PH domain and leucine zipper containing 1 (APPL1), an adaptor protein, appears to be the molecule that promotes the interaction between adiponectin and its receptors and the AMPK activation. The interaction between adiponectin receptor and APPL1 causes phosphorylation and activation of AMPK and AMPK phosphorylates ACC. The inhibition of ACC reduces lipid synthesis and increases fatty acid oxidation by blocking the production of malonyl-CoA, the allosteric inhibitor of carnitine palmitoyl transferase 1, which is the rate-limiting enzyme in fatty acid oxidation[40,41].

Moreover, AMPK downregulates the expression of sterol regulatory element-binding protein 1c, a transcription factor that regulates cholesterol and lipid synthesis[39,42]. Finally, adiponectin stimulates PPAR-α, a transcriptional factor controlling different genes involved in fat oxidation, such as acyl-CoA oxidase and long chain acyl-CoA synthetase[43] (Figure 1).

Recent data suggest that gut bacteria contribute to differences in body weight, insulin sensitivity, glucose metabolism and liver steatosis, in fact the imbalance of small intestinal bacterial overgrowth occurs in a large percentage of patients with chronic liver diseases, and has been associated with the severity of steatosis[44]. In particular some studies showed that the use of antibiotics to alter gut microbiota in obese mice reduces body weight, improves fasting glycaemia, glucose tolerance, and increases adiponectin levels. However, it is not clear how the gut microbiota plays a role in the production of adiponectin in adipose tissue, but this finding suggest that the gut microbiota could be a novel target for treating metabolic diseases, in fact high adiponectin levels enhance the insulin sensitivity and glycogen storage and decrease triglyceride accumulation[45,46].

ADIPONECTIN AND LIVER STEATOSIS IN CHRONIC HEPATITIS C INFECTION

Liver steatosis is a histological feature of CHC. CHC-related steatosis is chiefly virus-induced in HCV genotype 3 infection, while the host factors seem to play the major pathogenic role in HCV genotype non-3 infection. The evidence suggests that steatosis has an important role in the progression of liver fibrosis in CHC.

It has been demonstrated that adipocytokines are involved in the pathogenesis of non-alcoholic fatty liver disease, and the decreased plasma adiponectin levels are related to liver steatosis[47]. Hypoadiponectinemia has been implicated in the development of obesity-related morbidities such as dyslipidemia and cardiovascular diseases[48]. In addition, it is known that hypoadiponectinemia enhances hepatic steatosis, inflammation, fibrosis, and hepatocarcinogenesis in animal models of liver diseases[49]. Some studies have shown that steatosis is strongly correlated negatively with adiponectin in the patients with CHC infection[50-52]. These findings indicate a significant relationship between hepatic steatosis and adiponectin level. However, the role of adiponectin in HCV induced steatosis is still not completely understood, but the relationship between adiponectin low levels and liver steatosis is probably due to the ability of adiponectin to protect hepatocytes from triglyceride accumulation by increasing β-oxidation of free fatty acid and thus decreasing *de novo* free fatty acid production[40].

To clarify this point Durante-Mangoni *et al*[52] have found lower serum adiponectin levels and higher levels of tumour necrosis factor-α (TNF-α) in the chronic HCV patients. The higher tumour necrosis factor-α levels have particularly been observed in the patients with low adiponectin levels, and especially, in the patients infected whit HCV genotype-3. The extension of steatosis has inversely been correlated with adiponectin levels[52].

The substantial evidence in the available literature demonstrates that TNF-α inhibits adiponectin expression, and the decreased TNF-α level possibly contributes to the increased adiponectin level[53,54]. The expression level of adiponectin in cultured adipocytes has significantly been reduced by co-culture with macrophages or upon the exposure to the conditioned media from macrophages, suggesting that macrophage secreted factors, possibly TNF-α, are responsible for repressing adiponectin production[55]. Moreover, Bruun *et al*[56] have shown that the increase in TNF-α and IL-6 serum levels and decrease in adiponectin serum levels may be involved in insulin resistance. During the HCV infection, the immune response against HCV releases reactive oxygen species (ROS) from sequestered phagocytes and activates Kupffer cells in the liver[57]. High levels of ROS can activate nuclear factor kappa-light-chain-enhancer of activated B cells (NF-κB), which is a transcription factor. As a consequence of NF-κB activation, the expression of a variety of cytokines is increased, including tumour necrosis factors (TNF-α and TNF-β), IL-1, 6 and interferon-γ[58].

TNF-α modulates adipocytes and induces changes and reductions in the production of cytokines, adiponectin and leptin[52,59]. Thus, the reduced levels of adiponectin may increase influx and synthesis of free fatty acids into the liver of the patients with HCV infection, generating liver steatosis (Figure 2)[35,60].

Jonsson *et al*[22] have studied 194 patients with chronic HCV to assess the relationship between serum adiponectin levels and hepatic steatosis. The authors have found that a decreased serum level of adiponectin is associated with steatosis only in males, so they have suggested that the role of adiponectin in the HCV infected patients might be linked to gender[22]. Various studies hypothesized a possible interaction between HCV core protein-PPARs-adiponectin. It has been reported that the HCV core protein impairs the expression of the PPAR-α which plays an important role as a target of adiponectin in lipid metabolism[61]. Undoubtedly, the administration of recombinant adiponectin has been shown to increase PPAR-α ligand activity and the administration of a PPAR-γ agonist is associated with a significant increase of adiponectin levels and reversal of steatosis[62,63].

In another study, Ashour *et al*[64] have demonstrated that the Egyptian patients with HCV genotype-4 infection and with steatosis have shown the reduced serum levels of adiponectin, with a significant inverse correlation between adiponectin level and steatosis grade, homeostatic model assessments index, body mass index and fibrosis stage. Moreover, they have proved that serum levels of adiponectin and leptin show no significant differences between males and females[64].

Corbetta *et al*[65] have hypothesized that hyperadiponectinemia might be sustained by down-regulation of hepatic Adipo Rs. In order to test this hypothesis, they have assessed the expression levels of Adipo R1 and Adipo R2 in CHC biopsies and have shown that Adipo R2 mRNA levels are similar in normal liver and HCV-infected liver biopsies, but the Adipo R1 mRNA expression levels have been reduced in HCV-infected liver biopsies compared with normal liver biopsies. This reduction was also confirmed at protein level[65].

Tiftikci *et al*[66] have shown that the leptin-to-adiponectin ratio is significantly reduced in the HCV chronic patients. The increased leptin concentration, corrected by reduced adiponectin values (leptin-to-adiponectin ratio), has been linked to the development of metabolic abnormalities[67], so the data obtained by Tiftikci about a reduced leptin-to-adiponectin ratio in the chronic HCV patients, lend a new support to the argument that protein adiponectin may be involved in the pathogenesis of liver injury in the patients with HCV infection.

In contrast with these results, Aksõz *et al*[68] have suggested that a decrease in the level of adiponectin may be associated with metabolic disorders, independent from chronic HCV infection. In fact, they have tried to investigate the effects of the virus in the patients without visceral obesity and metabolic disorders, so they have suggested that a decrease in the level of adiponectin may

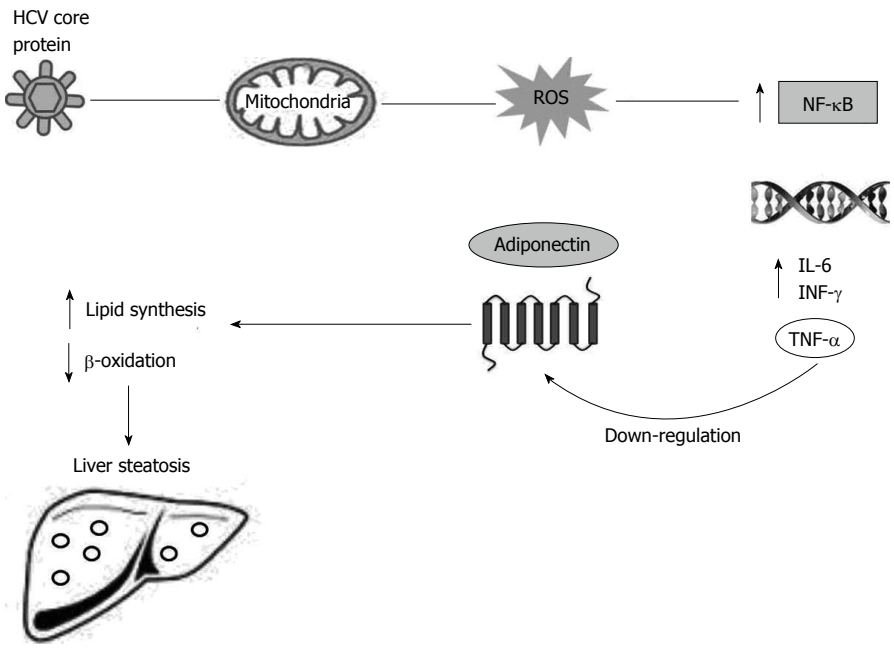

Figure 2 Liver steatosis induced by down-regulation of adiponectin and its receptor in chronic hepatitis C virus infection. HCV core protein associated with the mitochondria leads to increased ROS that activates NF-κB. As a consequence of NF-κB activation, expression of a variety of cytokines is increased, including TNF-α, IL-6 and INF-γ. TNF-α modulates adipocytes and induces reduction in the production of adiponectin and its receptor. Reduced levels of adiponectin induce the increase in the synthesis of free fatty acids and reduce β-oxidation, causing liver steatosis in the HCV chronic infected patients. HCV: Hepatitis C virus; NF-κB: Nuclear factor kappa-light-chain-enhancer of activated B cells; IL: Interleukin; IFN-γ: Interferon-γ; TNF-α: Tumour necrosis factor α; ROS: Reactive oxygen species.

be associated with metabolic disorders in association with HCV infection, but HCV virus alone has not altered adiponectin serum concentration[68].

Different studies showed the influence of genetic factors in the development of HCV-induced liver steatosis. In this contest Valenti *et al*[69] have suggested that rs738409 single nucleotide polymorphism of patatin-like phospholipase domain-containing 3 (PNPLA3), encoding for a protein variant (I148M) that influences hepatic triglycerides accumulation and the susceptibility to fibrosis and steatosis, may represent a genetic determinant of serum adiponectin levels in non-alcoholic fatty liver disease (NAFLD) and CHC patients. In another work Valenti *et al*[70] showed that this genetic variant in CHC patients affects steatosis development, is independently associated with fibrosis and cirrhosis, and may influence response to antiviral treatment. Finally Nakamura *et al*[71] showed that in Japanese CHC patients there is no association between PNPLA3 rs738409 genotype, hepatic steatosis or liver fibrosis, suggesting that in HCV infection the mechanism of hepatic steatosis might be different from that of NAFLD.

ADIPONECTIN AS THERAPEUTIC TARGET

The biological effect of adiponectin and its receptors and their hepato-protective role in fatty liver diseases suggest that controlling the level of adiponectin receptors might be an important therapeutic target for the treatment of fatty liver diseases. There are no data on the potential therapeutic role of adiponectin in HCV chronic infection, but there are a lot of data showing that adiponectin is a therapeutic strategy for the treatment of insulin resistance, metabolic syndrome and steatosis that are common features of CHC, especially, in the patients infected with genotypes 3 and 1 virus. On the other hand, hepatic steatosis and IR reduce the probability of achieving a sustained virological response to pegylated interferon and ribavirin combination therapy[72], so reducing liver steatosis can be useful as a response to antiviral treatment in the patients with chronic HCV infection. Adiponectin replacement therapy is not yet available as a treatment option, but an alternative approach would be to identify and use the classes of the agents that can induce secretion or expression of adiponectin. In this context, some reports indicate that thiazolidinediones (TZDs) might up-regulate adiponectin, possibly, by increasing its rate of secretion[73,74], TZDs may up-regulate adiponectin by generating small adipocytes that express and secrete adiponectin and/or directly activating adiponectin gene transcription[75,76]. Other studies have shown that the inhibitors of the renin-angiotensin pathway, such as angiotensin converting enzyme inhibitor, increase serum adiponectin concentration, in fact, the blockers of the angiotensin pathway promote adipocyte differentiation[77].

Xu *et al*[78] have reported the identification of two structurally related natural compounds, astragaloside Ⅱ and isoastragaloside Ⅰ, from the medicinal herb Radix Astragali, that increase adiponectin secretion in primary adipocytes, without any effects on other adipokines. An alternative approach could be the design of the agents

that serve as adiponectin mimetics. AMPK activators fall into such category because numerous adiponectin effects might be mediated *via* activation of AMPK. Moreover, the design of stable peptides or drugs, structurally and biologically simulating adiponectin production, could be another alternative[79].

In vitro studies have shown that adiponectin reduces free fatty acid-induced CD95/Fas expression and apoptosis of HepG2 hepatoma cells, which suggests that this hormone has a protective role with promising therapeutic implications, in fact, the receptor mediated apoptosis is a prominent feature in various liver diseases, including HCV chronic infection[80]. Finally, it is known that adiponectin has anti-inflammatory activity and this can be a promising therapeutic implication in numerous diseases including HCV. The anti-inflammatory effects attributed to adiponectin include the inhibition of TNF-α production and activity, inhibition of NF-κB activation and the induction of anti-inflammatory cytokines[81].

CONCLUSION

Steatosis development and CHC infection are clearly linked; about 20%-30% of chronic HCV infections are associated with hepatic steatosis. The biological mechanisms of the underlying steatosis occurrence and the progression to the liver disease are not entirely understood and are probably due to a number of factors: direct effect of the virus, genetic factors, metabolic syndrome and other unknown factors. The recent data suggest a significant link between hepatic steatosis and adiponectin low level. It is known that adiponectin and its receptors have hepato-protective role in fatty liver diseases and steatosis development. This relationship is probably due to the ability of adiponectin to increase β-oxidation of free fatty acid and to decrease *de novo* free fatty acid production. However, the role of adiponectin in HCV induced steatosis is still not completely understood. The biological effect, the hepato-protective role and the anti-inflammatory activity of adiponectin suggest that controlling the level of adiponectin, by increasing adiponectin production and using the drugs that structurally and biologically stimulate adiponectin, might be a potential therapeutic tool for the treatment of fatty liver diseases including steatosis induced by HCV chronic infection.

REFERENCES

1 **Björnsson E**, Angulo P. Hepatitis C and steatosis. *Arch Med Res* 2007; **38**: 621-627 [PMID: 17613353 DOI: 10.1016/j.arcmed.2006.09.001]

2 **Torti C**, Zazzi M, Abenavoli L, Trapasso F, Cesario F, Corigliano D, Cosco L, Costa C, Curia RL, De Rosa M, Foti G, Giraldi C, Leone R, Liberto MC, Lucchino D, Marascio N, Masciari R, Matera G, Pisani V, Serrao N, Surace L, Zicca E, Castelli F, Ciccozzi M, Puoti M, Focà A. Future research and collaboration: the "SINERGIE" project on HCV (South Italian Network for Rational Guidelines and International Epidemiology). *BMC Infect Dis* 2012; **12** Suppl 2: S9 [PMID: 23173812 DOI: 10.1186/1471-2334-12-S2-S9]

3 **Freeman AJ**, Dore GJ, Law MG, Thorpe M, Von Overbeck J, Lloyd AR, Marinos G, Kaldor JM. Estimating progression to cirrhosis in chronic hepatitis C virus infection. *Hepatology* 2001; **34**: 809-816 [PMID: 11584380]

4 **Abenavoli L**, Rouabhia S. Type 2 diabetes mellitus in chronic hepatitis C virus infection: risk factor or consequence? *Expert Rev Gastroenterol Hepatol* 2013; **7**: 295-297 [PMID: 23639086 DOI: 10.1586/egh.13.13]

5 **Abenavoli L**, Almasio PL. Chronic hepatitis C infection and insulin resistance: two best friends. *Expert Rev Anti Infect Ther* 2011; **9**: 555-558 [PMID: 21819320 DOI: 10.1586/eri.11.72]

6 **Khan M**, Jahan S, Khaliq S, Ijaz B, Ahmad W, Samreen B, Hassan S. Interaction of the hepatitis C virus (HCV) core with cellular genes in the development of HCV-induced steatosis. *Arch Virol* 2010; **155**: 1735-1753 [PMID: 20842391 DOI: 10.1007/s00705-010-0797-7]

7 **Roingeard P**. Hepatitis C virus diversity and hepatic steatosis. *J Viral Hepat* 2013; **20**: 77-84 [PMID: 23301542 DOI: 10.1111/jvh.12035]

8 **Solis-Herruzo JA**, Pérez-Carreras M, Rivas E, Fernández-Vázquez I, Garfia C, Bernardos E, Castellano G, Colina F. Factors associated with the presence of nonalcoholic steatohepatitis in patients with chronic hepatitis C. *Am J Gastroenterol* 2005; **100**: 1091-1098 [PMID: 15842583 DOI: 10.1111/j.1572-0241.2005.41059.x]

9 **Monto A**, Alonzo J, Watson JJ, Grunfeld C, Wright TL. Steatosis in chronic hepatitis C: relative contributions of obesity, diabetes mellitus, and alcohol. *Hepatology* 2002; **36**: 729-736 [PMID: 12198667 DOI: 10.1053/jhep.2002.35064]

10 **Hézode C**, Roudot-Thoraval F, Zafrani ES, Dhumeaux D, Pawlotsky JM. Different mechanisms of steatosis in hepatitis C virus genotypes 1 and 3 infections. *J Viral Hepat* 2004; **11**: 455-458 [PMID: 15357652 DOI: 10.1111/j.1365-2893.2004.00528.x]

11 **Bochud PY**, Cai T, Overbeck K, Bochud M, Dufour JF, Müllhaupt B, Borovicka J, Heim M, Moradpour D, Cerny A, Malinverni R, Francioli P, Negro F. Genotype 3 is associated with accelerated fibrosis progression in chronic hepatitis C. *J Hepatol* 2009; **51**: 655-666 [PMID: 19665246 DOI: 10.1016/j.jhep.2009.05.016]

12 **Barba G**, Harper F, Harada T, Kohara M, Goulinet S, Matsuura Y, Eder G, Schaff Z, Chapman MJ, Miyamura T, Bréchot C. Hepatitis C virus core protein shows a cytoplasmic localization and associates to cellular lipid storage droplets. *Proc Natl Acad Sci USA* 1997; **94**: 1200-1205 [PMID: 9037030]

13 **Moriya K**, Yotsuyanagi H, Shintani Y, Fujie H, Ishibashi K, Matsuura Y, Miyamura T, Koike K. Hepatitis C virus core protein induces hepatic steatosis in transgenic mice. *J Gen Virol* 1997; **78** (Pt 7): 1527-1531 [PMID: 9225025]

14 **Rubbia-Brandt L**, Quadri R, Abid K, Giostra E, Malé PJ, Mentha G, Spahr L, Zarski JP, Borisch B, Hadengue A, Negro F. Hepatocyte steatosis is a cytopathic effect of hepatitis C virus genotype 3. *J Hepatol* 2000; **33**: 106-115 [PMID: 10905593 DOI: 10.1016/S0168-8278(00)80166-X]

15 **Hourioux C**, Patient R, Morin A, Blanchard E, Moreau A, Trassard S, Giraudeau B, Roingeard P. The genotype 3-specific hepatitis C virus core protein residue phenylalanine 164 increases steatosis in an in vitro cellular model. *Gut* 2007; **56**: 1302-1308 [PMID: 17213339]

16 **Adinolfi LE**, Gambardella M, Andreana A, Tripodi MF, Utili R, Ruggiero G. Steatosis accelerates the progression of liver damage of chronic hepatitis C patients and correlates with specific HCV genotype and visceral obesity. *Hepatology* 2001; **33**: 1358-1364 [PMID: 11391523]

17 **Koike K**, Moriya K. Metabolic aspects of hepatitis C viral infection: steatohepatitis resembling but distinct from NASH. *J Gastroenterol* 2005; **40**: 329-336 [PMID: 15868369 DOI: 10.1007/s00535-005-1586-z]

18 **Masarone M**, La Mura V, Bruno S, Gaeta GB, Vecchione R, Carrino F, Moschella F, Torella R, Persico M. Steatohepatitis is associated with diabetes and fibrosis in genotype 1b HCV-

related chronic liver disease. *J Viral Hepat* 2007; **14**: 714-720 [PMID: 17875006 DOI: 10.1111/j.1365-2893.2007.00861.x]

19 **Sheikh MY**, Choi J, Qadri I, Friedman JE, Sanyal AJ. Hepatitis C virus infection: molecular pathways to metabolic syndrome. *Hepatology* 2008; **47**: 2127-2133 [PMID: 18446789 DOI: 10.1002/hep.22269]

20 **Perlemuter G**, Sabile A, Letteron P, Vona G, Topilco A, Chrétien Y, Koike K, Pessayre D, Chapman J, Barba G, Bréchot C. Hepatitis C virus core protein inhibits microsomal triglyceride transfer protein activity and very low density lipoprotein secretion: a model of viral-related steatosis. *FASEB J* 2002; **16**: 185-194 [PMID: 11818366 DOI: 10.1096/fj.01-0396com]

21 **Leone TC**, Weinheimer CJ, Kelly DP. A critical role for the peroxisome proliferator-activated receptor alpha (PPARalpha) in the cellular fasting response: the PPARalpha-null mouse as a model of fatty acid oxidation disorders. *Proc Natl Acad Sci USA* 1999; **96**: 7473-7478 [PMID: 10377439]

22 **Jonsson JR**, Moschen AR, Hickman IJ, Richardson MM, Kaser S, Clouston AD, Powell EE, Tilg H. Adiponectin and its receptors in patients with chronic hepatitis C. *J Hepatol* 2005; **43**: 929-936 [PMID: 16139921 DOI: 10.1016/j.jhep.2005.05.030]

23 **Maeda K**, Okubo K, Shimomura I, Funahashi T, Matsuzawa Y, Matsubara K. cDNA cloning and expression of a novel adipose specific collagen-like factor, apM1 (AdiPose Most abundant Gene transcript 1). *Biochem Biophys Res Commun* 1996; **221**: 286-289 [PMID: 8619847 DOI: 10.1006/bbrc.1996.0587]

24 **Waki H**, Yamauchi T, Kamon J, Ito Y, Uchida S, Kita S, Hara K, Hada Y, Vasseur F, Froguel P, Kimura S, Nagai R, Kadowaki T. Impaired multimerization of human adiponectin mutants associated with diabetes. Molecular structure and multimer formation of adiponectin. *J Biol Chem* 2003; **278**: 40352-40363 [PMID: 12878598 DOI: 10.1074/jbc.M300365200]

25 **Kaser S**, Moschen A, Cayon A, Kaser A, Crespo J, Pons-Romero F, Ebenbichler CF, Patsch JR, Tilg H. Adiponectin and its receptors in non-alcoholic steatohepatitis. *Gut* 2005; **54**: 117-121 [PMID: 15591515 DOI: 10.1136/gut.2003.037010]

26 **Tsao TS**, Lodish HF, Fruebis J. ACRP30, a new hormone controlling fat and glucose metabolism. *Eur J Pharmacol* 2002; **440**: 213-221 [PMID: 12007537 DOI: 10.1016/S0014-2999(02)01430-9]

27 **Sheng T**, Yang K. Adiponectin and its association with insulin resistance and type 2 diabetes. *J Genet Genomics* 2008; **35**: 321-326 [PMID: 18571119 DOI: 10.1016/S1673-8527(08)60047-8]

28 **Arita Y**, Kihara S, Ouchi N, Takahashi M, Maeda K, Miyagawa J, Hotta K, Shimomura I, Nakamura T, Miyaoka K, Kuriyama H, Nishida M, Yamashita S, Okubo K, Matsubara K, Muraguchi M, Ohmoto Y, Funahashi T, Matsuzawa Y. Paradoxical decrease of an adipose-specific protein, adiponectin, in obesity. 1999. *Biochem Biophys Res Commun* 2012; **425**: 560-564 [PMID: 22925674 DOI: 10.1016/j.bbrc.2012.08.024]

29 **Abenavoli L**. Adiponectin levels in nonalcoholic fatty liver disease. *Metabolism* 2011; **60**: e3 [PMID: 21917277 DOI: 10.1016/j.metabol.2011.08.002]

30 **Lautamäki R**, Rönnemaa T, Huupponen R, Lehtimäki T, Iozzo P, Airaksinen KE, Knuuti J, Nuutila P. Low serum adiponectin is associated with high circulating oxidized low-density lipoprotein in patients with type 2 diabetes mellitus and coronary artery disease. *Metabolism* 2007; **56**: 881-886 [PMID: 17570246 DOI: 10.1016/j.metabol.2007.01.018]

31 **Kazumi T**, Kawaguchi A, Hirano T, Yoshino G. Serum adiponectin is associated with high-density lipoprotein cholesterol, triglycerides, and low-density lipoprotein particle size in young healthy men. *Metabolism* 2004; **53**: 589-593 [PMID: 15131762 DOI: 10.1016/j.metabol.2003.12.008]

32 **Christou GA**, Tellis KC, Elisaf MC, Tselepis AD, Kiortsis DN. High density lipoprotein is positively correlated with the changes in circulating total adiponectin and high molecular weight adiponectin during dietary and fenofibrate treatment. *Hormones* (Athens) 2012; **11**: 178-188 [PMID: 22801564]

33 **Wolf AM**, Wolf D, Rumpold H, Enrich B, Tilg H. Adiponectin induces the anti-inflammatory cytokines IL-10 and IL-1RA in human leukocytes. *Biochem Biophys Res Commun* 2004; **323**: 630-635 [PMID: 15369797 DOI: 10.1016/j.bbrc.2004.08.145]

34 **Yamauchi T**, Kamon J, Ito Y, Tsuchida A, Yokomizo T, Kita S, Sugiyama T, Miyagishi M, Hara K, Tsunoda M, Murakami K, Ohteki T, Uchida S, Takekawa S, Waki H, Tsuno NH, Shibata Y, Terauchi Y, Froguel P, Tobe K, Koyasu S, Taira K, Kitamura T, Shimizu T, Nagai R, Kadowaki T. Cloning of adiponectin receptors that mediate antidiabetic metabolic effects. *Nature* 2003; **423**: 762-769 [PMID: 12802337 DOI: 10.1038/nature01705]

35 **Yamauchi T**, Kamon J, Minokoshi Y, Ito Y, Waki H, Uchida S, Yamashita S, Noda M, Kita S, Ueki K, Eto K, Akanuma Y, Froguel P, Foufelle F, Ferre P, Carling D, Kimura S, Nagai R, Kahn BB, Kadowaki T. Adiponectin stimulates glucose utilization and fatty-acid oxidation by activating AMP-activated protein kinase. *Nat Med* 2002; **8**: 1288-1295 [PMID: 12368907 DOI: 10.1038/nm788]

36 **Tomas E**, Tsao TS, Saha AK, Murrey HE, Zhang Cc Cc, Itani SI, Lodish HF, Ruderman NB. Enhanced muscle fat oxidation and glucose transport by ACRP30 globular domain: acetyl-CoA carboxylase inhibition and AMP-activated protein kinase activation. *Proc Natl Acad Sci USA* 2002; **99**: 16309-16313 [PMID: 12456889 DOI: 10.1073/pnas.222657499]

37 **Yamauchi T**, Nio Y, Maki T, Kobayashi M, Takazawa T, Iwabu M, Okada-Iwabu M, Kawamoto S, Kubota N, Kubota T, Ito Y, Kamon J, Tsuchida A, Kumagai K, Kozono H, Hada Y, Ogata H, Tokuyama K, Tsunoda M, Ide T, Murakami K, Awazawa M, Takamoto I, Froguel P, Hara K, Tobe K, Nagai R, Ueki K, Kadowaki T. Targeted disruption of AdipoR1 and AdipoR2 causes abrogation of adiponectin binding and metabolic actions. *Nat Med* 2007; **13**: 332-339 [PMID: 17268472 DOI: 10.1038/nm1557]

38 **Fruebis J**, Tsao TS, Javorschi S, Ebbets-Reed D, Erickson MR, Yen FT, Bihain BE, Lodish HF. Proteolytic cleavage product of 30-kDa adipocyte complement-related protein increases fatty acid oxidation in muscle and causes weight loss in mice. *Proc Natl Acad Sci USA* 2001; **98**: 2005-2010 [PMID: 11172066 DOI: 10.1073/pnas.98.4.2005]

39 **Yamauchi T**, Kamon J, Waki H, Imai Y, Shimozawa N, Hioki K, Uchida S, Ito Y, Takakuwa K, Matsui J, Takata M, Eto K, Terauchi Y, Komeda K, Tsunoda M, Murakami K, Ohnishi Y, Naitoh T, Yamamura K, Ueyama Y, Froguel P, Kimura S, Nagai R, Kadowaki T. Globular adiponectin protected ob/ob mice from diabetes and ApoE-deficient mice from atherosclerosis. *J Biol Chem* 2003; **278**: 2461-2468 [PMID: 12431986 DOI: 10.1074/jbc.M209033200]

40 **Kadowaki T**, Yamauchi T, Kubota N, Hara K, Ueki K, Tobe K. Adiponectin and adiponectin receptors in insulin resistance, diabetes, and the metabolic syndrome. *J Clin Invest* 2006; **116**: 1784-1792 [PMID: 16823476 DOI: 10.1172/JCI29126]

41 **Liu Q**, Gauthier MS, Sun L, Ruderman N, Lodish H. Activation of AMP-activated protein kinase signaling pathway by adiponectin and insulin in mouse adipocytes: requirement of acyl-CoA synthetases FATP1 and Acsl1 and association with an elevation in AMP/ATP ratio. *FASEB J* 2010; **24**: 4229-4239 [PMID: 20667975 DOI: 10.1096/fj.10-159723]

42 **Yamauchi T**, Kadowaki T. Physiological and pathophysiological roles of adiponectin and adiponectin receptors in the integrated regulation of metabolic and cardiovascular diseases. *Int J Obes* (Lond) 2008; **32** Suppl 7: S13-S18 [PMID: 19136982 DOI: 10.1038/ijo.2008.233]

43 **Tsuchida A**, Yamauchi T, Takekawa S, Hada Y, Ito Y, Maki T, Kadowaki T. Peroxisome proliferator-activated receptor (PPAR)alpha activation increases adiponectin receptors

and reduces obesity-related inflammation in adipose tissue: comparison of activation of PPARalpha, PPARgamma, and their combination. *Diabetes* 2005; **54**: 3358-3370 [PMID: 16306350 DOI: 10.2337/diabetes.54.12.3358]

44 **Abenavoli L**, Scarpellini E, Rouabhia S, Balsano C, Luzza F. Probiotics in non-alcoholic fatty liver disease: which and when. *Ann Hepatol* 2013; **12**: 357-363 [PMID: 23619251]

45 **Membrez M**, Blancher F, Jaquet M, Bibiloni R, Cani PD, Burcelin RG, Corthesy I, Macé K, Chou CJ. Gut microbiota modulation with norfloxacin and ampicillin enhances glucose tolerance in mice. *FASEB J* 2008; **22**: 2416-2426 [PMID: 18326786 DOI: 10.1096/fj.07-102723]

46 **Vrieze A**, Holleman F, Zoetendal EG, de Vos WM, Hoekstra JB, Nieuwdorp M. The environment within: how gut microbiota may influence metabolism and body composition. *Diabetologia* 2010; **53**: 606-613 [PMID: 20101384 DOI: 10.1007/s00125-010-1662-7]

47 **Targher G**, Bertolini L, Scala L, Poli F, Zenari L, Falezza G. Decreased plasma adiponectin concentrations are closely associated with nonalcoholic hepatic steatosis in obese individuals. *Clin Endocrinol* (Oxf) 2004; **61**: 700-703 [PMID: 15579183 DOI: 10.1111/j.1365-2265.2004.02151.x]

48 **Im JA**, Kim SH, Lee JW, Shim JY, Lee HR, Lee DC. Association between hypoadiponectinemia and cardiovascular risk factors in nonobese healthy adults. *Metabolism* 2006; **55**: 1546-1550 [PMID: 17046559 DOI: 10.1016/j.metabol.2006.06.027]

49 **Asano T**, Watanabe K, Kubota N, Gunji T, Omata M, Kadowaki T, Ohnishi S. Adiponectin knockout mice on high fat diet develop fibrosing steatohepatitis. *J Gastroenterol Hepatol* 2009; **24**: 1669-1676 [PMID: 19788607 DOI: 10.1111/j.1440-1746.2009.06039.x]

50 **Petit JM**, Minello A, Jooste V, Bour JB, Galland F, Duvillard L, Verges B, Olsson NO, Gambert P, Hillon P. Decreased plasma adiponectin concentrations are closely related to steatosis in hepatitis C virus-infected patients. *J Clin Endocrinol Metab* 2005; **90**: 2240-2243 [PMID: 15644404 DOI: 10.1210/jc.2004-1266]

51 **Liu CJ**, Chen PJ, Jeng YM, Huang WL, Yang WS, Lai MY, Kao JH, Chen DS. Serum adiponectin correlates with viral characteristics but not histologic features in patients with chronic hepatitis C. *J Hepatol* 2005; **43**: 235-242 [PMID: 15964656 DOI: 10.1016/j.jhep.2005.02.044]

52 **Durante-Mangoni E**, Zampino R, Marrone A, Tripodi MF, Rinaldi L, Restivo L, Cioffi M, Ruggiero G, Adinolfi LE. Hepatic steatosis and insulin resistance are associated with serum imbalance of adiponectin/tumour necrosis factor-alpha in chronic hepatitis C patients. *Aliment Pharmacol Ther* 2006; **24**: 1349-1357 [PMID: 17059516 DOI: 10.1111/j.1365-2036.2006.03114.x]

53 **Zhang L**, Sugiyama T, Murabayashi N, Umekawa T, Ma N, Kamimoto Y, Ogawa Y, Sagawa N. The inflammatory changes of adipose tissue in late pregnant mice. *J Mol Endocrinol* 2011; **47**: 157-165 [PMID: 21697073 DOI: 10.1530/JME-11-0030]

54 **Lira FS**, Rosa JC, Cunha CA, Ribeiro EB, do Nascimento CO, Oyama LM, Mota JF. Supplementing alpha-tocopherol (vitamin E) and vitamin D3 in high fat diet decrease IL-6 production in murine epididymal adipose tissue and 3T3-L1 adipocytes following LPS stimulation. *Lipids Health Dis* 2011; **10**: 37 [PMID: 21352586 DOI: 10.1186/1476-511X-10-37]

55 **Feng B**, Jiao P, Nie Y, Kim T, Jun D, van Rooijen N, Yang Z, Xu H. Clodronate liposomes improve metabolic profile and reduce visceral adipose macrophage content in diet-induced obese mice. *PLoS One* 2011; **6**: e24358 [PMID: 21931688 DOI: 10.1371/journal.pone.0024358]

56 **Bruun JM**, Lihn AS, Verdich C, Pedersen SB, Toubro S, Astrup A, Richelsen B. Regulation of adiponectin by adipose tissue-derived cytokines: in vivo and in vitro investigations in humans. *Am J Physiol Endocrinol Metab* 2003; **285**: E527-E533 [PMID: 12736161]

57 **De Maria N**, Colantoni A, Fagiuoli S, Liu GJ, Rogers BK, Farinati F, Van Thiel DH, Floyd RA. Association between reactive oxygen species and disease activity in chronic hepatitis C. *Free Radic Biol Med* 1996; **21**: 291-295 [PMID: 8855439 DOI: 10.1016/0891-5849(96)00044-5]

58 **Wright E**, Scism-Bacon JL, Glass LC. Oxidative stress in type 2 diabetes: the role of fasting and postprandial glycaemia. *Int J Clin Pract* 2006; **60**: 308-314 [PMID: 16494646 DOI: 10.1111/j.1368-5031.2006.00825.x]

59 **Neuman MG**, Benhamou JP, Marcellin P, Valla D, Malkiewicz IM, Katz GG, Trepo C, Bourliere M, Cameron RG, Cohen L, Morgan M, Schmilovitz-Weiss H, Ben-Ari Z. Cytokine--chemokine and apoptotic signatures in patients with hepatitis C. *Transl Res* 2007; **149**: 126-136 [PMID: 17320798 DOI: 10.1016/j.trsl.2006.11.002]

60 **Pajvani UB**, Du X, Combs TP, Berg AH, Rajala MW, Schulthess T, Engel J, Brownlee M, Scherer PE. Structure-function studies of the adipocyte-secreted hormone Acrp30/adiponectin. Implications fpr metabolic regulation and bioactivity. *J Biol Chem* 2003; **278**: 9073-9085 [PMID: 12496257 DOI: 10.1074/jbc.M207198200]

61 **Dharancy S**, Malapel M, Perlemuter G, Roskams T, Cheng Y, Dubuquoy L, Podevin P, Conti F, Canva V, Philippe D, Gambiez L, Mathurin P, Paris JC, Schoonjans K, Calmus Y, Pol S, Auwerx J, Desreumaux P. Impaired expression of the peroxisome proliferator-activated receptor alpha during hepatitis C virus infection. *Gastroenterology* 2005; **128**: 334-342 [PMID: 15685545 DOI: 10.1053/j.gastro.2004.11.016]

62 **Díez JJ**, Iglesias P. The role of the novel adipocyte-derived hormone adiponectin in human disease. *Eur J Endocrinol* 2003; **148**: 293-300 [PMID: 12611609 DOI: 10.1530/eje.0.1480293]

63 **Bajaj M**, Suraamornkul S, Piper P, Hardies LJ, Glass L, Cersosimo E, Pratipanawatr T, Miyazaki Y, DeFronzo RA. Decreased plasma adiponectin concentrations are closely related to hepatic fat content and hepatic insulin resistance in pioglitazone-treated type 2 diabetic patients. *J Clin Endocrinol Metab* 2004; **89**: 200-206 [PMID: 14715850 DOI: 10.1210/jc.2003-031315]

64 **Ashour E**, Samy N, Sayed M, Imam A. The relationship between serum adiponectin and steatosis in patients with chronic hepatitis C genotype-4. *Clin Lab* 2010; **56**: 103-110 [PMID: 20476641]

65 **Corbetta S**, Redaelli A, Pozzi M, Bovo G, Ratti L, Redaelli E, Pellegrini C, Beck-Peccoz P, Spada A. Fibrosis is associated with adiponectin resistance in chronic hepatitis C virus infection. *Eur J Clin Invest* 2011; **41**: 898-905 [PMID: 21539538 DOI: 10.1111/j.1365-2362.2011.02498.x]

66 **Tiftikci A**, Atug O, Yilmaz Y, Eren F, Ozdemir FT, Yapali S, Ozdogan O, Celikel CA, Imeryuz N, Tozun N. Serum levels of adipokines in patients with chronic HCV infection: relationship with steatosis and fibrosis. *Arch Med Res* 2009; **40**: 294-298 [PMID: 19608019 DOI: 10.1016/j.arcmed.2009.04.008]

67 **Oda N**, Imamura S, Fujita T, Uchida Y, Inagaki K, Kakizawa H, Hayakawa N, Suzuki A, Takeda J, Horikawa Y, Itoh M. The ratio of leptin to adiponectin can be used as an index of insulin resistance. *Metabolism* 2008; **57**: 268-273 [PMID: 18191059 DOI: 10.1016/j.metabol.2007.09.011]

68 **Aksöz K**, Unsal B, Kirci A, Alper E, Buyraç Z, Aslan F, Cekiç C, Cengiz O, Ozcan Ari F, Akpinar Z. The relationship between chronic HCV infection and the level of plasma adiponectin. *Turk J Gastroenterol* 2008; **19**: 254-257 [PMID: 19119485]

69 **Valenti L**, Rametta R, Ruscica M, Dongiovanni P, Steffani L, Motta BM, Canavesi E, Fracanzani AL, Mozzi E, Roviaro G, Magni P, Fargion S. The I148M PNPLA3 polymorphism influences serum adiponectin in patients with fatty liver and healthy controls. *BMC Gastroenterol* 2012; **12**: 111 [PMID: 22898488 DOI: 10.1186/1471-230X-12-111]

70 **Valenti L**, Rumi M, Galmozzi E, Aghemo A, Del Menico B, De Nicola S, Dongiovanni P, Maggioni M, Fracanzani AL,

Rametta R, Colombo M, Fargion S. Patatin-like phospholipase domain-containing 3 I148M polymorphism, steatosis, and liver damage in chronic hepatitis C. *Hepatology* 2011; **53**: 791-799 [PMID: 21319195 DOI: 10.1002/hep.24123]

71 **Nakamura M**, Kanda T, Nakamoto S, Miyamura T, Jiang X, Wu S, Yokosuka O. No correlation between PNPLA3 rs738409 genotype and fatty liver and hepatic cirrhosis in Japanese patients with HCV. *PLoS One* 2013; **8**: e81312 [PMID: 24349054 DOI: 10.1371/journal.pone.0081312.]

72 **Agnello V**, Abel G, Elfahal M, Knight GB, Zhang QX. Hepatitis C virus and other flaviviridae viruses enter cells via low density lipoprotein receptor. *Proc Natl Acad Sci USA* 1999; **96**: 12766-12771 [PMID: 10535997 DOI: 10.1073/pnas.96.22.12766]

73 **Bodles AM**, Banga A, Rasouli N, Ono F, Kern PA, Owens RJ. Pioglitazone increases secretion of high-molecular-weight adiponectin from adipocytes. *Am J Physiol Endocrinol Metab* 2006; **291**: E1100-E1105 [PMID: 16803857 DOI: 10.1152/ajpendo.00187.2006]

74 **Rasouli N**, Yao-Borengasser A, Miles LM, Elbein SC, Kern PA. Increased plasma adiponectin in response to pioglitazone does not result from increased gene expression. *Am J Physiol Endocrinol Metab* 2006; **290**: E42-E46 [PMID: 16118250 DOI: 10.1152/ajpendo.00240.2005]

75 **Okuno A**, Tamemoto H, Tobe K, Ueki K, Mori Y, Iwamoto K, Umesono K, Akanuma Y, Fujiwara T, Horikoshi H, Yazaki Y, Kadowaki T. Troglitazone increases the number of small adipocytes without the change of white adipose tissue mass in obese Zucker rats. *J Clin Invest* 1998; **101**: 1354-1361 [PMID: 9502777 DOI: 10.1172/JCI1235]

76 **Iwaki M**, Matsuda M, Maeda N, Funahashi T, Matsuzawa Y, Makishima M, Shimomura I. Induction of adiponectin, a fat-derived antidiabetic and antiatherogenic factor, by nuclear receptors. *Diabetes* 2003; **52**: 1655-1663 [PMID: 12829629 DOI: 10.2337/diabetes.52.7.1655]

77 **Furuhashi M**, Ura N, Higashiura K, Murakami H, Tanaka M, Moniwa N, Yoshida D, Shimamoto K. Blockade of the renin-angiotensin system increases adiponectin concentrations in patients with essential hypertension. *Hypertension* 2003; **42**: 76-81 [PMID: 12796280 DOI: 10.1161/01.HYP.0000078490.59735.6E]

78 **Xu A**, Wang H, Hoo RL, Sweeney G, Vanhoutte PM, Wang Y, Wu D, Chu W, Qin G, Lam KS. Selective elevation of adiponectin production by the natural compounds derived from a medicinal herb alleviates insulin resistance and glucose intolerance in obese mice. *Endocrinology* 2009; **150**: 625-633 [PMID: 18927219 DOI: 10.1210/en.2008-0999]

79 **Shetty S**, Kusminski CM, Scherer PE. Adiponectin in health and disease: evaluation of adiponectin-targeted drug development strategies. *Trends Pharmacol Sci* 2009; **30**: 234-239 [PMID: 19359049 DOI: 10.1016/j.tips.2009.02.004]

80 **Wedemeyer I**, Bechmann LP, Odenthal M, Jochum C, Marquitan G, Drebber U, Gerken G, Gieseler RK, Dienes HP, Canbay A. Adiponectin inhibits steatotic CD95/Fas up-regulation by hepatocytes: therapeutic implications for hepatitis C. *J Hepatol* 2009; **50**: 140-149 [PMID: 19019483 DOI: 10.1016/j.jhep.2008.08.023]

81 **Palmer C**, Hampartzoumian T, Lloyd A, Zekry A. A novel role for adiponectin in regulating the immune responses in chronic hepatitis C virus infection. *Hepatology* 2008; **48**: 374-384 [PMID: 18666256 DOI: 10.1002/hep.22387]

P- Reviewer: Chen EQ, Higuera-de la Tijera MDF, Invernizzi P, Kanda T, Lisotti A
S- Editor: Gong XM **L- Editor**: A **E- Editor**: Liu SQ

World Journal of Hepatology

Submit a Manuscript: http://www.wjgnet.com/esps/
Help Desk: http://www.wjgnet.com/esps/helpdesk.aspx
DOI: 10.4254/wjh.v7.i1.53

World J Hepatol 2015 January 27; 7(1): 53-69
ISSN 1948-5182 (online)

TOPIC HIGHLIGHT

WJH 6th Anniversary Special Issues (5): Hepatitis C virus

Immune mechanisms of vaccine induced protection against chronic hepatitis C virus infection in chimpanzees

Babs E Verstrepen, André Boonstra, Gerrit Koopman

Babs E Verstrepen, Gerrit Koopman, Department of Virology, Biomedical Primate Research Centre, 2280GH Rijswijk, The Netherlands
André Boonstra, Department of Gastroenterology and Hepatology, Erasmus University Medical Center Rotterdam, 3015 CE Rotterdam, The Netherlands
Author contributions: Verstrepen BE, Boonstra A and Koopman G wrote the paper.
Supported by In part the Fifth framework program from the EU, No. BIO-CT98-0357, QLK2-CT-1999-00356 and ERC-2008-AdG-233130-HEPCENT (Verstrepen BE); by the Virgo consortium, funded by the Dutch government project, No. FES0908 (Boonstra A)

Correspondence to: Gerrit Koopman, PhD, Department of Virology, Biomedical Primate Research Centre, PO Box 3306, 2280GH Rijswijk, The Netherlands. koopman@bprc.nl
Telephone: +31-15-2842761
Received: August 27, 2014
Peer-review started: August 31, 2014
First decision: September 28, 2014
Revised: October 22, 2014
Accepted: November 7, 2014
Article in press: November 10, 2014
Published online: January 27, 2015

Abstract

Hepatitis C virus (HCV) infection is characterized by a high propensity for development of life-long viral persistence. An estimated 170 million people suffer from chronic hepatitis caused by HCV. Currently, there is no approved prophylactic HCV vaccine available. With the near disappearance of the most relevant animal model for HCV, the chimpanzee, we review the progression that has been made regarding prophylactic vaccine development against HCV. We describe the results of the individual vaccine evaluation experiments in chimpanzees, in relation to what has been observed in humans. The results of the different studies indicate that partial protection against infection can be achieved, but a clear correlate of protection has thus far not yet been defined.

Key words: Hepatitis C virus; Vaccines; Chimpanzees; Review; Prophylactic; Antibodies; T-cells

Core tip: With the near disappearance of the most relevant animal model for hepatitis C virus (HCV), the chimpanzee, we review the progression that has been made regarding vaccine development against this virus infection. An estimated 3 million people suffering from chronic hepatitis caused by HCV die each year. Currently, there is no approved vaccine available to prevent new infection.

Verstrepen BE, Boonstra A, Koopman G. Immune mechanisms of vaccine induced protection against chronic hepatitis C virus infection in chimpanzees. *World J Hepatol* 2015; 7(1): 53-69 Available from: URL: http://www.wjgnet.com/1948-5182/full/v7/i1/53.htm DOI: http://dx.doi.org/10.4254/wjh.v7.i1.53

INTRODUCTION

Chronic hepatitis, caused by persistent infection with hepatitis C virus (HCV) is a major health threat worldwide[1]. The number of chronic HCV carriers is estimated

to be 170 million, about 1% to 2% of the population. HCV is a 9600 nucleotide, single-stranded positive-sense RNA virus belonging to the Flaviviridae. The open reading frame encodes for a large polyprotein with three structural proteins, Core (C), E1 and E2 that are linked *via* the presumed viroporin p7, to the nonstructural proteins NS1, NS2, NS3, NS5A and NS5B. The structural proteins form the viral particle, while the nonstructural proteins are involved in replication and maturation of the virus particle.

HCV infection is characterized by a high propensity for development of life-long viral persistence. Only one in five acute infections is spontaneously eradicated, normally within the first six months after infection.

During acute HCV infections, clinical symptoms are mild or absent. For that reason acute HCV infections are often not recognized. However, when acute HCV infection develops into a persistent infection, the majority of the patients develop chronic hepatitis and over decades the virus causes subtle but cumulative hepatic damage. Ultimately this may lead either to cirrhosis, decompensating liver congestion or hepatocellular carcinoma. To give a sense of the impact of HCV infection on the health care system, it has been calculated that worldwide, 27% of the cases of cirrhosis can be accounted for by HCV and population-based studies in the United States indicate that 40% of chronic liver disease is HCV related[2,3]. Overall, persistent HCV infection accounts for 3 million deaths each year[4].

TRANSMISSION

Transmission of HCV occurs *via* blood-blood contact. Nowadays in the western world, the majority of the new infections are associated with intravenous drug use, *via* sharing of contaminated needles[5]. There are several examples of drastically declined numbers of new HCV cases, after the introduction of surveillance programs and the distribution of fresh disposable needles amongst intravenous drug users[6,7].

In other geographical regions, the mode of transmission is different. The situation is especially worrying in Egypt, where an estimated 12% of the population is infected with HCV as a result of an unsafe treatment-procedure of an endemic schistosoma infection in rural areas during the years 60-80 s of the last century. Currently, the infrastructural organization of the Egyptian health care system is still seen as, at least partially, responsible for ongoing transmission in the region[8]. Recently, World Health Organization (WHO) has declared the large reservoir of chronic HCV carriers a serious risk, as tourism and migration contribute to spreading of the virus to places outside the region.

HIGH PROPENSITY FOR CHRONIC INFECTION

There are 7 major genotypes of HCV[9,10], each genotype consists of a cluster of different subtypes, and within each patient closely related quasi-species are present. The difference between two distantly related isolates can be as high as 30% at the nucleotide level[11]. Circulating quasi-species have the ability to mutate very quickly and can easily evade the immune system, and/or drugs that are used for treatment. In addition, the treatment protocol depends on the specific HCV genotype. Hence, it is difficult to develop a universal treatment regime for chronic HCV.

As indicated by the rapid upregulation of interferon-stimulated genes (ISGs) in the host's liver[12,13], HCV is present and recognized early after infection. However, differential HCV strains[14], the activation of distinct molecular pathways[15], kinetics of the ISG response[16] and even cellular composition of the microenvironment in the liver[17] may be responsible for inadequate mobilization of an effective immune response, ultimately leading to chronic infections. In this review we will focus on the role of the adaptive immune system in clearance of HCV infection, and place this in perspective of HCV vaccine evaluation studies in chimpanzees.

THERAPEUTIC DRUGS OR A VACCINE

For decades chronic HCV infection could only be treated with the broadly acting antiviral (pegylated) interferon, which was often accompanied by serious side effects and frequently not successful. Only in one out of five patients, a so-called sustained virological response was achieved, meaning that HCV RNA had declined to undetectable levels in peripheral blood after treatment. In 1998, the nucleoside analogue ribavirin (RBV) was added to standard therapy-protocols and this improved treatment efficacy to about 40%[18-20].

The year 2011 can be considered as a breakthrough in the treatment of chronic HCV infection. In that year, two direct-acting antiviral drugs (DAAs)-telaprevir and boceprevir-received regulatory approval and became available for patients. In combination with pegylated-interferon and RBV, these NS3/4A protease inhibitors have shown marked efficacy in patients infected with HCV genotype 1. However, this combination was found to be less effective against other genotypes, and patients still experienced the severe side-effects characteristic for treatment with interferon and RBV. In addition, the genetic background of the host can negatively affect treatment efficacy[21] and viral-resistance has been reported[22].

Regulatory approval of NS5B-targeting DAAs, like sofosbuvir has leads to further improvements in the treatment of chronic HCV infection. Not only do they have a better efficacy against genotypes other than genotype 1, also duration of the treatment is shorter[23,24]. In addition, these compounds can be administered orally and may possibly lead to interferon and ribavirin free treatment regimens.

More effective, more tolerable and safer treatment options however come with a price. Currently, oral DAA therapy is very expensive and therefore currently

not affordable in developing countries. Consequently, a prophylactic vaccine is imperative to contain HCV infection globally.

CHIMPANZEES IN BIOMEDICAL RESEARCH

Humans and chimpanzees (pan troglodytes) share a common ancestor who lived approximately 30 million years ago, before the hominoid lineage split. Chimpanzees are humans' closest living relatives with 98.9% identity at DNA level[25]. Since the 40 s of the last century, chimpanzees have been used in the United States space program and later also in biomedical research. The colonies of chimpanzees in research facilities were founded from animals that were imported from the wild in Western Africa. Soon, breeding programs assured enough offspring for experimental work and facilities became self-sustainable and no longer required import of chimpanzees from the wild.

Public concerns about research with non-human primates, chimpanzees in particular, has eventually led to stop the use of apes for HCV research in Europe, and a significant reduction of the number of animals used in the United States[26]. With the near disappearance of the most relevant animal model for HCV, we review the progression that has been made regarding vaccine development against HCV describing the results in chimpanzees in relation to what has been observed in humans. To obtain a complete overview, a literature search was performed in PubMed combining the keywords chimpanzee(s) and hepatitis or HCV in combination with any of the following keywords; vaccine(s), vaccination, immunization or immunized. Furthermore, there are only a limited number of groups working on this subject and animals used can be identified by name or number and thereby tracked through the literature.

CHIMPANZEES AND HCV RESEARCH

No doubt, chimpanzees have been the most important animal model to study HCV[27]. In the late 80 s, after it became clear that the majority of blood borne chronic liver inflammations were not caused by hepatitis A or B virus, serum from a non-A-non-B hepatitis patient was inoculated into a chimpanzee[28]. From this chimpanzee, a cDNA bank was derived and in 1989 Michael Houghton and his coworkers at Chiron Inc. identified HCV as the main causative agent for non-A-non-B hepatitis[28].

Only chimpanzees and humans can be productively infected with HCV and this limited host range has seriously hampered HCV research. To date, the chimpanzee is the only validated animal model to study immunity associated with acute resolving infection, and protective immunity against HCV reinfection. Over the past 35 years, experimental infection of chimpanzees with HCV has provided groundbreaking information regarding identification, characterization, transmission, early responses after HCV infection and triggering of the innate as well as the adaptive immune system. Studies in chimpanzees have enabled us to identify immune mechanisms associated with viral clearance and chronic infection, critical for optimal prophylactic vaccine design. Subsequently, chimpanzees were used to evaluate the efficacy of vaccine candidates and vaccination strategies.

PRIMARY HCV INFECTION IN CHIMPANZEES

To be able to study the effect of a vaccine or vaccination strategy, it was necessary to identify the virological characteristics of HCV without any intervention. There are numerous reasons why it is difficult to study early events in HCV infection in humans. Firstly, in the vast majority of the cases acute HCV infection is asymptomatic and patients therefore rarely seek medical attention. Secondly, collecting serial blood samples (and occasional liver-biopsy material) from one individual during acute HCV infection is very difficult and, getting pre-exposed biospecimen from humans is complicated. Therefore, experimental inoculation of chimpanzees was pivotal to study early events of HCV infection.

In chimpanzees, similar to humans, intravenous exposure to HCV can either lead to a transient self-limiting infection or it may develop into a persistent infection[29]. In both humans and chimpanzees, viral RNA is detectable by reverse transcription polymerase chain reaction in plasma and liver tissue[30]. In addition, anti-HCV antibodies appear in peripheral blood of both species 6 to 8 wk after HCV exposure[31,32]. In the majority of human individuals, antibodies remain detectable in blood after viral clearance, while in chimpanzees sometimes a gradual loss of HCV specific antibodies after viral elimination has been reported[30,33]. However, in humans, HCV specific cellular immune responses have been found in seronegative individuals, implying also there the loss of HCV-specific antibodies after viral clearance[34-37].

Published data on cellular immune responses showed that HCV specific CD4 and CD8 T-cell responses in both humans and chimpanzees were weak after HCV infection. Spontaneous clearance was associated with somewhat stronger cellular responses compared to the individuals that became persistently infected[38-42]. Also in liver biopsies taken from HCV infected patients and chimpanzees CD4 and CD8 T-cells were observed[43-46] and relatively strong liver-associated T-cell responses were associated with viral clearance[46].

VIRAL PERSISTENCE IN HUMANS AND CHIMPANZEES

Based on antibody data, WHO estimates that 70% to 90% of the infections eventually develop into a persistent HCV infection. However, this percentage may be an overestimation as exposed seronegative individuals are

not included in these calculations[34-37]. The documented percentages of chimpanzees with persisting HCV infection varies between different laboratories from 39% to 70%[33,47-49]. This wide range reflects the heterogeneous nature of infection with HCV. Not only do virological differences, like genotype and dose of infection, play a role but also genetic factors of the host. In humans, the outcome of HCV infection is associated with protective human leukocyte antigen alleles HLA-B27, HLA-B57 and HLA-A3. And although the exact same major histocompatibility complex class I alleles are not present in chimpanzees, homologues with similar peptide-binding characteristics have been identified in these animals[50]. Genome wide association studies have also shown genetic variation linked to the *IL28B* gene, whose product directly interferes with the antiviral interferon (IFN)-pathways and determines the ability of patients to spontaneously resolve HCV infection[51,52]. In chimpanzees similar mechanisms may play a role[53].

Chimpanzee colonies in research facilities are not fully outbred. As a result higher frequencies of certain MHC class I molecules may be present in one facility compared to another facility. This so called "founder effect", in combination with the fact that the total number of human patients outnumbers the total number of chimpanzees used in experimental infection studies may affect the percentage of chronic infection per institute.

In conclusion, these contributing factors make it difficult to directly compare the percentage of persistent infection between humans and chimpanzees. Maybe even more relevant is the difference in "life-style" regarding diet and alcohol intake. Also differences in HCV inocula, route and dose of exposure may partly explain the difference. Similar factors may apply to distinct effects on changes in liver enzyme levels and progression to fibrosis. To our knowledge, it has never been documented that a chimpanzee developed liver fibrosis as a result of persistent HCV infection.

HCV REINFECTION IN CHIMPANZEES

Documented reinfection studies in humans are relatively sparce[54-57]. Longitudinal analysis of human intravenous drug users were performed, but results were inconclusive as to whether a previously cleared HCV infection induces functional immunological memory[55,56,58] that correlate with a shortened viremia and decreased HCV persistence. Important insights were obtained from chimpanzees in which experimental HCV re-exposure was studied in a controlled setting (genotype, dose and route of infection) and longitudinal follow up studies could be performed[59-66].

Reinfection studies in chimpanzees have demonstrated that all of the three possible outcomes: *i.e.*, protection from infection[63,64], protection from viral persistence[59,63-65] or persistent HCV infection[59], can occur.

Pairwise comparison of virological parameters during primary infection in naïve chimpanzees *vs* animals that were rechallenged[47] showed that previous HCV clearance provided some protection, characterized by reduced duration, peak virus load and reduced frequency of development of persistent HCV infection[47]. Understanding the underlying mechanisms through which a cleared HCV infection can contribute to protection against infection, or virus persistence, and the involvement of the adaptive immune system has been an important research goal and pivotal for further HCV vaccine development. Since HCV-induced liver damage only leads to a fatal condition after decades of ongoing immunopathogenesis, a vaccine that could achieve a similar rate of protection from chronic infection as observed after a cleared infection, would already be of great value.

IMMUNE CORRELATES

Virus neutralizing antibodies

In 1994 it was already described that plasma components had an important role in protection against HCV infection[67]. In a hallmark experiment by Farci *et al*[67], *in vitro* neutralizing capacity was determined by mixing infectious virus with heat inactivated plasma from the same patient and subsequently testing it for residual infectivity by inoculating the mixture into a naïve chimpanzee. Patient plasma collected 2 years after infection was able to prevent infection, while plasma collected 13 years after infection could not. At that time there was no *in vitro* system to confirm the presence of neutralizing antibodies. However, simultaneous appearance of envelope HCV specific antibodies in circulation 7 to 8 wk after infection[32] and mutations in viral RNA in the hypervariable region of E2[61,68-70] substantiated the involvement of antibodies and demonstrated the flexibility of the virus to escape from immune pressure through mutation.

In vitro virus neutralization assays

Subsequently, several strategies were used to develop a technique to measure neutralizing capacity of antibodies in plasma of HCV infected individuals. However, it was not until 2003 that HCV envelope based neutralization could be adequately determined. The HCV pseudoparticle (HCVpp) system[71] is based on the expression of HCV envelope proteins on the surface of retroviral particles. After co-transfecting 293T cells with plasmids encoding for HCV envelope protein, a retroviral backbone and green fluorescent protein/luciferase, HCVpp are being secreted into the culture medium. Next, after mixing serum and HCVpp, residual infectivity can be determined in hepatocellular carcinoma cells. The system is very flexible with regard to envelope sequences expressed that can be expressed on the viral surface.

Because pseudoviruses may act different from HCV particles, a subgenomic replicon system was developed[72]. A robust cell culture-derived *in vitro* system was obtained when a replicon was constructed from a HCV genotype 2a clone named JFH-1, which was isolated from a Japanese patient with fulminant hepatitis. Transfection of Huh-7 cells with the *in vitro* transcribed full length JFH-1

resulted in the secretion cell-culture-derived infectious HCV particles (HCVcc)[73]. Similar to the HCVpp system, the HCVcc assay is based on the binding of antibodies to HCV envelope expressing particles before testing residual infectivity on hepatocellular carcinoma cells. Because of the high specificity of the neutralizing antibodies, this system did not suffice for measuring neutralization of genotype 2a based HCVcc and intergenotype clones were constructed[74]. Unfortunately, replacing the JFH-1 envelope proteins by envelopes from other genotypes resulted in less efficient production of viral particles.

Nevertheless, both HCVpp and HCVcc techniques have been shown to be very valuable in improving the understanding of viral entry and antibody neutralization[75].

Antibody correlates

HCV specific antibodies generated during the acute phase of the infection are mainly directed against linear epitopes within structural and non-structural viral proteins, while neutralizing antibodies have been mapped to conformational epitopes within the E1 and E2 envelope proteins[76-82]. While most neutralizing antibodies are rather strain specific[82-84], broadly neutralizing antibodies, antibodies that recognize epitopes that are highly conserved between genotypes, have also been described for E2[83,85,86].

Only for glycoprotein E2, specific targets for receptor binding have been identified: CD81 and scavenger receptor class B member 1 (SRB1) and coreceptors[87]. Neutralizing antibodies directed against domain I and Ⅲ of E2 interfere with its binding to CD81, while neutralizing antibodies directed against hypervariable region 1 (HVR-1) interfere with the binding of E2 to SRB1.

In humans, early induction of strain specific neutralizing antibodies was found to be associated with spontaneous recovery[88,89]. Unfortunately, in most cases these antibodies are only formed during the chronic phase of the infection, when viral clearance is more difficult to achieve. Nonetheless, these antibodies may exert immune pressure that could potentially lead to decreased viral fitness.

The paradigm that neutralizing antibodies play a less prominent role in chimpanzees compared to humans, is mostly based on data collected by Logvinoff *et al*[89]. In patient H, from which HCV clone H77 was derived, strain specific neutralizing capacity was observed 7 wk post infection[89], while in the majority of humans neutralizing antibodies are observed after 100 wk post infection[89]. In chimpanzees infected with H77, specific neutralization was detected only 15 to 20 wk post infection. This relatively late detection in chimpanzees may possibly be explained by the fact that the HCVpp were based on the exact same H77 sequence that was present in patient H. After inoculation of the RNA clone H77 in chimpanzees, it may however have rapidly adapted to its new host and therefore be slightly different from the original H77 clone, showing decreased HCVpp-H77 neutralizing capacity.

ROLE OF T-CELL RESPONSES

Since these early studies, it has been reported that hypogammaglobulinaemic patients have the ability to spontaneously clear HCV infection[90]. Hence, T-cell responses may have contributed to the protection against HCV challenge described above. Furthermore, antibody-mediated depletion experiments in chimpanzees showed that when CD8 T-cells were depleted, virus replication was prolonged despite the presence of memory CD4 T-cells and HCV was only cleared after recovery of HCV-specific CD8 T-cells in the liver[66]. But on the other hand, CD4 T-cells were required for a complete control of HCV replication despite the presence of functional intrahepatic CD8 T-cells[91]. Similarly, the association between HLA-class I molecules HLA-A*03, HLA-B27 and HLA-B57 and class Ⅱ molecules HLA-DRβ1*0101, HLA-DRB1*0401, HLA-DRB1*1101 and HLA-DRB1*0301, and HCV clearance, emphasizes the role of respectively, CD8 and CD4 cells (reviewed in[21]).

T-CELL RESPONSE PATTERNS

HCV specific T-cell responses have been reviewed in detail elsewhere[92-95]. As schematically depicted in Figure 1, four different scenarios can be used to describe HCV specific adaptive immune responses in relation to HCV clearance or viral persistence: (1) a spontaneous clearance of HCV infection, associated with early and effective T-cell responses (Figure 1A). The most important characteristics of this successful cellular immunity against HCV are relatively strongly expanding T-cells that are fully functional with respect to cytolytic capacity, reflected by granzyme and perforin secretion, or cytokine production[96-104]; (2) Transient immune control (Figure 1B) and ensuing viral escape that may be the result of either immune mediated viral selection or an exhausted immune response. Immune pressure may drive the generation of virus variants in which relevant T- or B-cell epitopes are mutated and therefore no longer recognized when they are presented on infected hepatocytes. During tolerance and/or exhaustion on the other hand, immune modulatory mechanisms result in dysfunctional T- or B-cells but with an intact and specific T- (or B-) cell receptor on its surface[105]; (3) Chronic or persistent HCV infection occurs when T-cells are not fully differentiated into functional effector cells (Figure 1C) or no neutralizing antibodies are produced; and (4) Protection of chronic HCV infection by vaccine-induced immune responses. Hypothetically, vaccine-induced neutralizing antibodies may prevent infection while functional HCV specific T-cells may protect from chronic infection (Figure 1D).

VACCINES

Several prophylactic vaccine efficacy experiments have been performed in chimpanzees[106-120]. Relevant information regarding vaccine components, strategy, adjuvants, genotype of the vaccine and the challenge virus and the

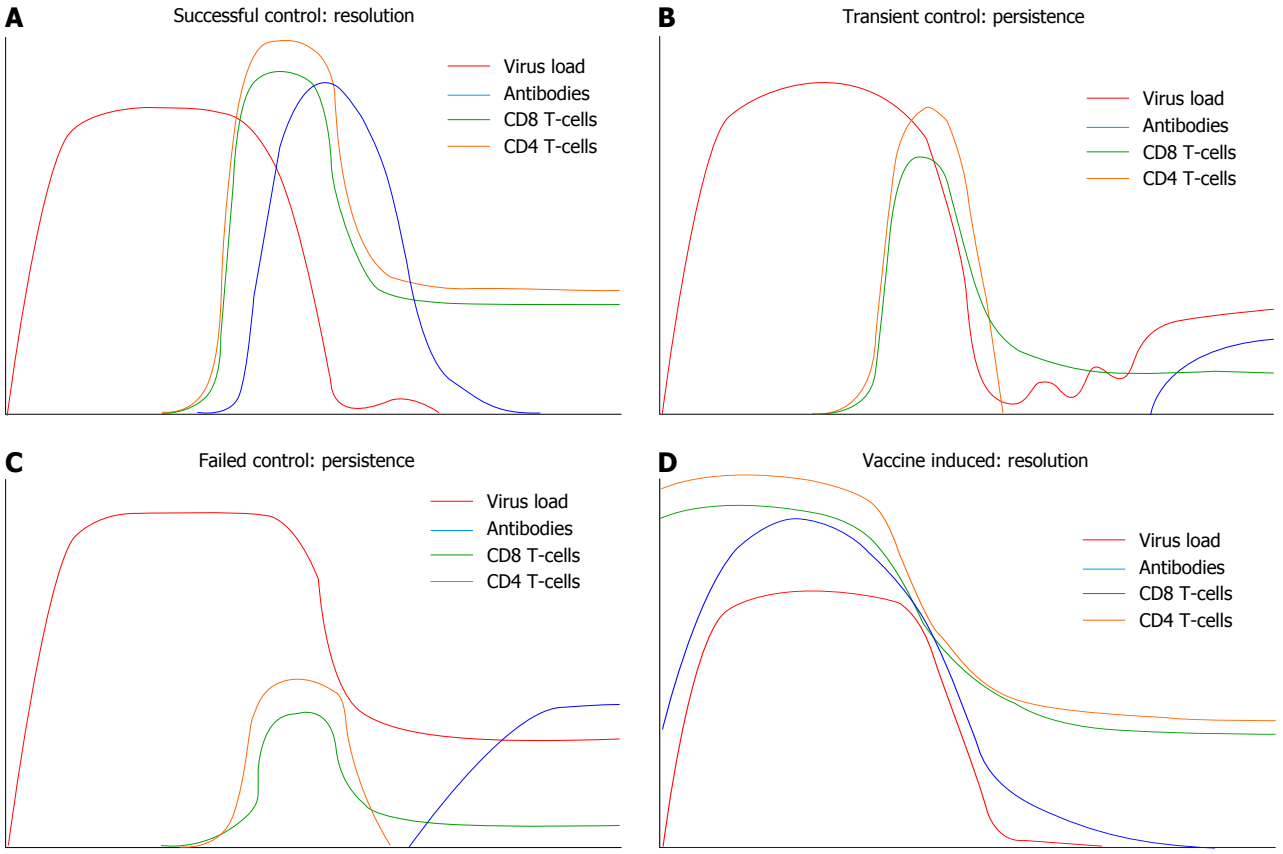

Figure 1 Schematic overview of the different causes of hepatitis C virus infection in relation to modulation of the adaptive immune response. A: Viral clearance. Viral RNA (red line) is normally detected in blood within 1-2 wk after exposure. The virus load will increase until the emergence of HCV specific CD4 (yellow line) and CD8 T-cell (green line) responses 4 to 8 wk after infection[98]. Ideally, strain specific neutralizing antibodies (blue line) are present around the same time[88,89]. After viral elimination, antibody responses can either remain present or decrease to undetectable levels. Memory T-cells remain usually present and can be detected by *in vitro* assays; B: Transient control. After the initial peak viremia (red line), T-cell responses emerge and virus load decreases but remains detectable in serum. CD8 T-cells (green line) remain detectable but CD4 T-cell (yellow line) responses decrease to low levels. There appears to be a constant battle between virus and the immune system. *De novo* escape variants are able to evade the T and B-cell responses but at the same time lose viral fitness. When effective T and B-cell responses contract because the correct epitopes are no longer present, the virus "mutates back" to a more fit variant and virus load may increase again. Thinner lines of the adaptive immune responses represent decreased functionality of CD4 (yellow), CD8 T-cell (green) and antibodies (blue); C: Failed control leading to persistent infection; After the initial peak viremia, T-cell responses emerge and virus load decrease to lower levels but virus remains detectable in serum. T and B cells are functionally impaired or present in too low numbers to efficiently eliminate the virus. The virus remains present at steady state levels. Thinner lines of the adaptive immune responses represent decreased functionality of CD4 (yellow), CD8 T-cell (green) and antibodies (blue); D: Vaccine induced protection model. Vaccine-induced broadly neutralizing antibodies are present at the time of exposure and prevent virus production by infected hepatocytes. The hepatocytes that are infected are successfully eliminated by cytolytic T-cells in the liver.

challenge outcome are summarized in Table 1. We will first focus on vaccine candidates that were developed for the induction of neutralizing antibody responses to protect against infection. Subsequently, vaccine strategies aiming to induce cellular immune responses to control viral infection are discussed.

The envelope glycoproteins as vaccine antigens

Structure and function of envelope glycoproteins: As stated above, HCV envelope glycoproteins E1 and E2 are key determinants for HCV entry. They mediate receptor binding, and the ensuing fusion process between the viral envelope and an endosomal host cell membrane[121,122]. E1 and E2 are heavily glycosylated proteins with a C-terminal transmembrane domain anchored in the lipid envelope of the virus particle. On the surfaces of HCV particles, the envelope glycoproteins are present as large disulphide-linked oligomers[123].

Little is known about the structure of the E1E2 heterodimer, but a proposed model of the E2 ectodomain[124] is comprised of three separate domains (D Ⅰ; described to be a discontinuous region containing the CD81 binding site, D Ⅱ; predicted to possess the fusion peptide and D Ⅲ; described to contain antigenic neutralization epitopes and to be involved in heterodimerization with E1[125]), and three immunogenic HVR1 (384-411), HVR2 (473-480) and HVR3; (431-466).

E1 is even less well characterized, and may be important for the correct folding of E2[126] and the E2 mediated fusion process[127]. E1 may also be involved in controlling virus assembly[87]. The structure of the E1E2 heterodimer is still largely unresolved. Both the functional characteristics of E1E2 and the detection of neutralizing antibody responses against these proteins make them obvious candidates as vaccine-antigen. Long before the presence of HCV neutralizing antibodies was actually confirmed, the

Table 1 Summary of vaccine experiments in chimpanzees

	Vaccine				Challenge		Outcome					
	Components	Adjuvant	Route (prime-boost)	GT	Strain	Dose (CID50)	# Sterile	# Chronic	# Resolved	#Total	%Chronic	Ref.
Recombinant protein												
	E1E2	MF59/MF57	i.m.	1a	HCV-1	10	5		2	7	0	[106]
	E1E2			1a	HCV-1			2	12	14	14	[107]
	E1	ALUM	i.m.	1b	HCV 1b J4	100			2	2	0	[109]
	E2deltaHVR-1	ALUM	i.m.	1b	HCV 1b J4	100		2		2	0	[109]
Recombinant protein-peptides												
	E1, E2, HVRpeptides	(In)complete Freund's	s.c.	4	HCV#6	10			1	1	0	[108]
DNA												
	E2	None		1a	1a	100			2	2	0	[110]
Virus like particle												
	Core, E1, E2	AS01B	i.m.	1b	HCV CG 1b	100			4	4	0	[111]
DNA protein												
	Core, E1, E2 and NS3	ALUM	i.m./i.d.-i.m.	1a/1b	HCV 1b J4	25		1	1	2	50	[112]
DNA-peptide protein												
	E1/E2 + HVR peptides	ALUM/RIBI	i.m.	1a	H7	100		1		1	100	[113]
DNA prime-vaccinia boost												
	NS3, NS5A, NS5B	CpG, rVV B7.1; ICAM-1; LFA-3	i.m./s.c.	1a	H77	100		1		1	100	[114]
DNA prime-MVA boost												
	Core, E1, E2 and NS3	None	i.m./i.d.-i.m/i.d.	1b	HCV 1b J4	25		3	1	4	75	[115]
Replicating rVV												
	Core, E1, E2, p7, NS2 and NS3	None	i.d.	1b	HCV 1b BK	2.5 and 24			4	4	0	[116]
DNA prime-adeno boost												
	Core, E1, E2, NS3-NS5	With/without IL-12	i.m.-i.m.	1b	HCV 1b BK	100	1	4	1	6	67	[117]
	NS3-NS5B	None	i.m./i.m.	1b	H77	100		1	4	5	20	[118]
	NS3, NS4, NS5A, NS5B	Liposomes/pIL-12	*iv-iv*	1b	H77	100		2	2	4	50	[120,134]

i.m.: Intramuscular; *iv*: Intravenous; rVV: Recombinant vaccinia virus; HCV: Hepatitis C virus; IL-12: Interleukin 12; ICAM-1: Intercellular adhesion molecule 1; LFA-3: Lymphocyte function associated antigen 3; HVR: Hypervariable region; s.c.: Subcutaneously; MVA: Modified vaccinia virus Ankara; GT: Genotype.

first envelope based vaccine experiments were already performed. Unfortunately, the envelope glycoproteins also show the largest genetic variance (30%) within HCV[9]. This variance not only poses problems for vaccine development with respect to target antigen selection, but it may also facilitate the formation of variants that escape vaccine-induced immunity giving rise to HCV persistence.

E1/E1 protein immunizations in chimpanzees: The first prophylactic HCV vaccine aimed at the induction of neutralizing antibody responses and was evaluated in chimpanzees by Choo *et al*[106] in 1994. The HCV envelope heterodimer gpE1/E2 was produced in mammalian cells infected with recombinant vaccinia virus that expressed the HCV E1/E2-genes. The protein was formulated in an oil/water micro-emulsion[106], and used to immunize seven chimpanzees. All seven vaccinees developed strong E1E2 antibody responses after the second protein immunization. After intravenous HCV exposure, the challenge control animals developed an acute HCV infection that persisted into a chronic HCV infection. In contrast, five out of seven gpE1/gpE2 vaccinated animals were fully protected from homologous HCV exposure and protection from infection

correlated with vaccine induced antibody responses (Table 1). The other two vaccinees showed overall lower viremia compared to the control animals and only minimal transient elevation of the liver enzyme alanine aminotransferase levels in plasma. From this experiment it was concluded that protection from-chronic-HCV infection was achieved by gpE1/gpE2 vaccination and the level of protection correlated with the level of antibodies directed against gpE1/gpE2.

During this vaccine-study, the lack of an efficient *in vitro* culture system made it impossible to determine the neutralizing capacity of the vaccine-induced antibodies. Retrospective analysis performed by Meunier *et al*[128] demonstrated robust neutralization in four out of five of the protected animals. However, since one of the protected animals showed only minimal HCVpp neutralizing capacity, and another animal with high neutralizing titers was not protected, neutralizing antibody responses alone cannot fully explain the results. Furthermore, vaccine antigens were derived from the same HCV strain that was used for the challenge.

Dahari *et al*[47] reported the results from 21 animals immunized with gpE1/E2. Included in these numbers were the seven animals described by Choo *et al*[106]. From the 14 animals that received a similar recombinant protein vaccine 12 vaccinees resolved HCV infection while 2 animals developed persistent HCV infection[47,107,119].

In conclusion, while very promising results have been obtained with this vaccine candidate, there is some note of caution since these results could not be reproduced.

Induction of cross neutralizing antibodies: At the time of these experiments, heterogeneity in the envelope regions became evident, and it was assumed that multivalent vaccines were required to provide protection to heterologous virus stains. In order to broaden the immune response, and offer protection against a wider range of HCV isolates, Esumi *et al*[108] used truncated E1 and E2 glycoproteins produced in insect cells together with HVR-1 peptides from a different HCV isolate and immunized one chimpanzee. The vaccine, delivered in Freund's (in)complete adjuvant, induced E1 and E2 specific humoral responses, but only a low antibody titer against HVR-1. Upon challenge with HCV#6, the animal showed a transient peak of HCV RNA, which in view of the low propensity of this virus to cause chronic infection implies that the vaccine did not confer protection.

E1 neutralizing capacity: Because these HCV-envelope protein vaccines were based on the E1E2 heterodimer, the role of the individual glycoproteins could not be determined. Only recently, the gpE1 and a gpE2 lacking the HVR-1 were evaluated separately[109]. In two animals immunized with gpE1 HCV neutralizing antibodies were induced and after a heterologous HCV-1b challenge, both animals were able to resolve HCV infection shortly after challenge. In contrast, the two E2 delta HVR-1 immunized animals showed no HCVpp 1b neutralizing capacity, and despite the presence of E2 specific cellular responses both animals were not protected from chronic HCV infection. For the first time, this study showed that E1 neutralization can be achieved and has protecting potential. Possibly, epitopes within E1 are masked when administered as a heterodimer and may therefore have been missed until now. However, the exact role of E1 during the cell entry process needs to be further elucidated.

New insights in the role of E1 indicate that a better understanding of the interaction between E1 and E2 as well as the exact mechanisms of virus/receptor interaction and cell entry are needed.

Vaccine strategies for induction of protective T-cell responses

Although traditionally most vaccination strategies have relied on the induction of neutralizing antibody responses, the emergence of human immunodeficiency virus (HIV) and the realization that cellular immune responses are important in suppressing replication of this virus has boosted the development of new vaccine strategies for the induction of effective T-cell responses. The HCV vaccine research has greatly benefited from these developments and modeled their experimental vaccines on the knowledge gained in the HIV-field.

DNA vaccines encoding for HIV antigens have been proven efficient in the induction of HIV specific T-cell responses[129]. In the year 2000, Forns *et al*[110] performed a proof of principle experiment in two chimpanzees, using a DNA plasmid encoding for surface-expressed E2. One animal developed antibodies directed against E2 and HVR-1, while the other animal had only very low levels of E2 specific antibodies. However, no HCV specific T-cells could be detected. Nonetheless, upon challenge with the heterologous HCV, both vaccinees resolved HCV infection, while the control animal developed a persistent HCV infection. From this experiment it appears that DNA immunization can provide protection against infection, although the underlying mechanism is still unclear.

Virus-like particles: Delivery of antigens in the form of virus-like particles has been described as an efficient strategy to elicit T-cell responses[130]. This was evaluated in a study in chimpanzees, by giving four immunizations with HCV-like particles[111] consisting of the structural proteins Core, E1 and E2, in AS01B adjuvant. All four chimpanzees showed broad and strong T-cell responses, determined by IFN Enzyme-Linked ImmunoSpot (ELISPOT) and proliferation assay, in peripheral blood. In the liver antigen specific CD4 as well as CD8 T-cells were observed, comparable in magnitude to the blood. All four animals were able to control an intravenous challenge with HCV clone CG1b within 12 wk.

Multicomponent prime-boost vaccine strategies: Experience from the HIV vaccine field has shown that

the induction of cellular immune responses is greatly enhanced when two different vaccine modalities are given in a so-called "prime-boost" combination[131].

A multicomponent prime-boost vaccine strategy was evaluated by Rollier *et al*[112] using the relatively conserved regions, Core and NS3, in combination with the variable E1 and E2, as vaccine antigens to induce an immune response against a broad range of HCV variants. DNA plasmids expressing the individual antigens were used to prime the immune system and subsequently three recombinant protein immunization were given as boosts. Both immunized animals developed strong humoral as well as strong cellular responses. Animals were challenged with a heterologous HCV-1b strain and in contrast to the control animal, both vaccinees suppressed virus replication to below the detection limit early after exposure. However, in one vaccinee the virus kept reappearing in plasma at very low levels while no evidence for HCV replication could be observed in the other chimpanzee.

Puig *et al*[113] aimed to induce neutralizing antibodies by giving a prime with DNA encoding for E1E2 in combination with HVR peptides in ALUM adjuvant. The responses were boosted with recombinant E1E2 heterodimer in RIBI (squalene which is emulsified with saline containing Tween 80)[113]. Strong HVR-1 specific antibody responses were observed in peripheral blood and cellular proliferative responses and cytokine production were found in the liver. Despite these vaccine-induced responses, the animal became persistently infected after exposure to an homologous challenge strain. Compared to the naïve non-vaccinated control animal, a delay in the peak of virus replication was observed, but not a reduced viremia.

In another experiment performed by the same research group, priming with DNA plasmids encoding HCV-NS3, NS5A or NS5B, followed by a booster immunization with recombinant vaccinia constructs expressing the same HCV proteins, resulted in strong T-cell responses. After experimental HCV exposure, initially virus replication was controlled. However, the virus reemerged. Losing immune control coincided with emergence of new virus variants and the loss of CD4 T-cell recognition[114].

In a similar DNA prime modified vaccinia virus (MVA) boost strategy, but now directed against HCV core-E1-E2 and NS3, strong and broad T- and B-cell responses were reported[115]. However, despite strong humoral responses, no virus neutralizing capacity was found and after challenge with HCV-1b, all four animals showed acute viremia. Only one animal was able to control virus replication to undetectable levels. The other three animals became chronically infected. The vaccine induced vigorous T-cell responses as reflected by strong proliferation and HCV specific IFNγ, interleukin-2 (IL-2) and IL-4 cytokine responses. Retrospectively, vaccine induced T-cell responses were analyzed in more detail. It was found that, although the vaccine elicited NS3 specific cytokine producing CD4 and CD8 T-cells in all four vaccinees, only in the chimpanzee that cleared HCV infection, CD8 T-cells were found to have cytolytic capacity[132]. Interestingly, the animals that became chronically infected had higher mRNA expression levels of exhaustion markers programmed cell death protein 1 (PD-1), cytotoxic T-lymphocyte-associated protein 4 (CTLA-4) (Figure 2) and indoleamine 2,3-dioxygenase in the liver, suggesting the induction of T-cells with regulatory functions that might have prevented formation of a cytotoxic T-cell response[115].

In 2008, a replicating recombinant vaccinia virus (rVV) vaccine; PolyVax (rVV-HBV-HCV) was evaluated in chimpanzees[116]. After immunization with PolyVax the animals were exposed to HBV and after resolution of the HBV infection, they were boosted with HCV-rVV, expressing HCV-1b based E1, E2, p7, NS2 and NS3. To assess the efficacy against HCV infection, animals were intravenously exposed to 2.5 CID50 of a homologous HCV strain. Unfortunately, this challenge was not successful and 17 wk later a second challenge was performed with the same inoculum with 24 CID50. After peak viremia, viral titers declined to non-detectable levels within 4 wk in all four vaccines while two controls became persistently infected. Eighteen months after the initial HCV clearance a multigenotype rechallenge was performed. Only one animal was able to clear infection while in three other animals, genotype HCV-1a remained detectable in plasma. PolyVax transiently induced HCV neutralizing antibodies. However, these were not present at the time of HCV exposure. On the other hand long lasting IFNγ secretion and proliferative responses were observed after PolyVax immunization and these cellular responses were boosted by HCV-rVV. To what extend these responses may have contributed to control of virus replication after the second challenge is difficult to establish due to possible contribution of the first 2.5 CID50 HCV exposure.

Adenoviruses are efficient vehicles for gene transfer and have a natural tropism for the liver[133], the site of HCV replication and therefore a good candidate for the delivery of HCV antigens. Youn *et al*[117] described a vaccine study with 6 chimpanzees, in which animals were primed with DNA encoding for HCV-Core, E1, E2, NS3-5 with three out of six animals receiving an additional plasmid encoding for IL-12 to promote the development of IFNγ producing Th1 cells. The prime was followed by an immunization with replication incompetent adenovirus expressing the same HCV antigens. Strong vaccine induced humoral as well as cellular responses were measured in proliferation assays, E2 specific enzyme-linked immunosorbent assay and neutralization assays. In the animal with the strongest responses at the day of challenge, no HCV RNA could be detected. All other animals had a delayed and lower peak virus load and four animals became persistently infected.

While viral vectors typically induce high cellular immune responses, they have the disadvantage that anti-vector responses are formed that limit their repeated application. To circumvent this problem, Folgori *et al*[118] used two different types of replication defective adenoviral

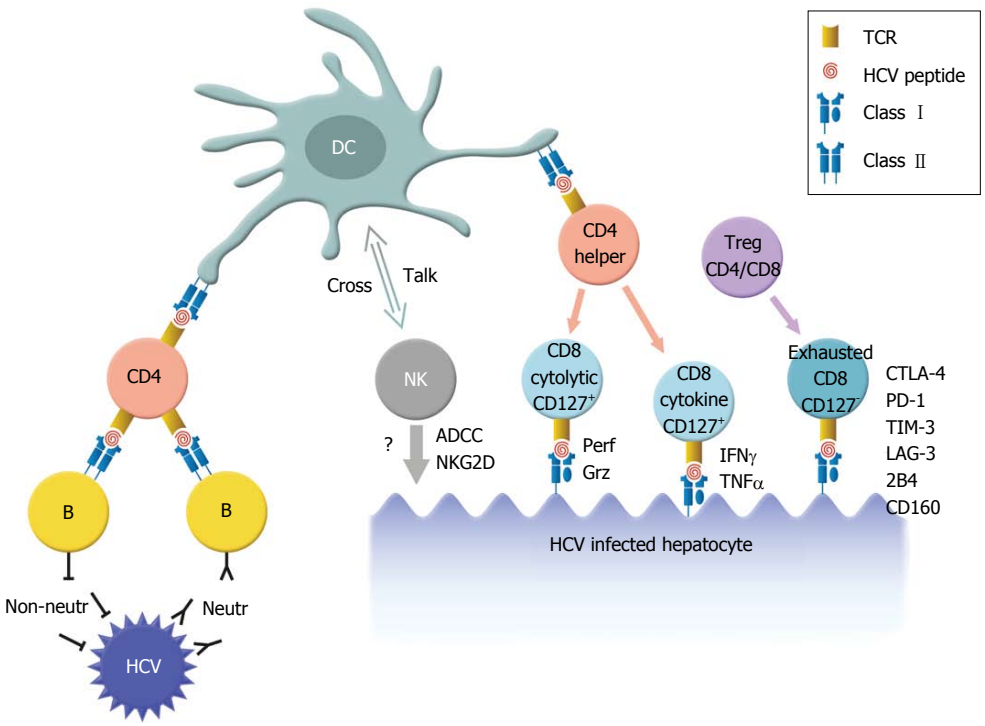

Figure 2 Summary of immune responses in hepatitis C virus immunized chimpanzees. Antigen presenting cells (DCs or Kupffer cells in the liver) present HCV peptides in the context of major histocompatibility complex class Ⅱ molecules to the T-cell receptor (TCR) on CD4 T-cells. CD4 cells may activate B-cells. Antibodies produced may be neutralizing and bind to circulating HCV particles and prevent the infection of hepatocytes. Or the antibodies may be non-neutralizing antibodies and potentially play a role in ADCC. CD4-helper T-cells can also stimulate cytolytic T-cells. CD8 T-cells may be directly responsible for lysis when they produce degranulation molecules like granzymes or perforin after the recognition of a peptide on the surface of an HCV infected hepatocyte. Or *via* indirect lysis, mediated by the secretion of cytokines. CD8 T-cells affected by Tregs and exhausted CD8 T-cells are functionally impaired and are incapable of lysing HCV infected hepatocytes. HCV: Hepatitis C virus; CTLA-4: Cytotoxic T-lymphocyte-associated protein 4; IFN: Interferon; TNFα: Tumor necrosis factor alpha; ADCC: Antibody dependent cellular cytotoxicity; DC: Dentritic cell; PD-1: Programmed cell death protein 1; TIM-3: T cell immunoglobulin and mucin protein 3; LAG-3: Lymphocyte-activation gene 3.

vectors for two subsequent booster immunizations[118]. For an optimal booster effect, the adenoviruses were selected based on low seroprevalence in humans and little or no immunological cross-reactivity between the two types. Both prime and booster immunizations were directed against the non structural proteins NS3 to NS5B. Upon HCV challenge, the immunized animals showed a reduction of acute viremia, which coincided with expansion of HCV specific CD8 T-cells in peripheral blood as well as the liver. In 4 out of 5 immunized animals, virus load was reduced to undetectable levels, while in the control group 3 out of 5 animals cleared the infection.

Similar results were reported in a study, where chimpanzees received a DNA prime followed by an adenovirus boost, both expressing NS3-5B + pIL-12[134]. One animal cleared the infection while the other became persistently infected. Evidence was found for the selection of escape mutants that evaded vaccine induced T-cells. Comparison of the nucleotide sequence of the circulating viruses in the two immunized animals and the control animal, showed a nonsynonymous/synonymous ratio indicative for positive selection. The exact same immunization strategy was then used to vaccinate two additional chimpanzees[120] and again one chimpanzee was able to control the infection early after challenge while in the other animal the virus persisted and the animal became chronically infected.

In conclusion, all immunization strategies that were evaluated in chimpanzees induced either humoral or cellular immune responses, or both. As nicely shown in the meta analysis performed by Dahari *et al*[47], compared to non-immunized animals, vaccinees generally showed reduced virus replication in the early phase of the infection, although complete protection from infection was rare. In addition, the analysis showed that the proportion of HCV persistence in vaccinees (28.3%) is much lower compared to 61.9% observed in the control animals that were included[47].

VACCINE INDUCED T-CELL RESPONSES IN BLOOD AND PREDICTION OF OUTCOME

A direct comparison between the individual chimpanzee experiments is not always possible because of disparity in experimental design, vaccine-antigens, vaccine regimen, heterologous or homologous challenge virus and challenge dose. Also, various methods have been used to assess the magnitude of vaccine induced T-cell responses. For instance for the quantification of cytokine production, real-time quantitative polymerase chain reaction, intracellular cytokine staining and ELISPOT assays have been used,

which do not necessarily yield the same answer. Despite these differences, important conclusions can be drawn on immune regulatory mechanisms that are potentially involved in HCV clearance.

Clearly, neither the magnitude of the vaccine induced immune responses nor the breadth of the responses could predict the protective effect of a vaccine within one experiment. There is a striking heterogeneity in vaccine-induced responses between individuals. This not only reflects the genetic variation of a population but also differences in pathways as well as regulatory mechanisms of T-cell responses, similar to the variation observed in human patients suffering from HCV infection[135]. Larger study groups would be needed to cover this diversity, but the special nature of the animals and the high costs involved, precludes larger experiments.

As an example, in the Folgori study, where a DNA-prime was followed by an adenovirus boost expressing the same antigens, it was not the animal with strong and broad vaccine-induced cytotoxic T-cell (CTL) responses that was protected from infection[118]. On the other hand the vaccinee with the lowest CTL response was the one animal that became persistently infected. Youn *et al*[117] described an association between E2-specific adaptive immunity and protection from (chronic) infection. However, in other experiments E2 was not identified as the key-antigen for protection against chronic infection.

ESCAPING VACCINE INDUCED IMMUNITY

HCV is notorious for its ability to mutate, resulting in development of different *de novo* variants that are generated under immune pressure and result in escape from T and B-cell responses. Data generated by Lavillette *et al*[127] describe two patterns of progressive emergence of neutralizing antibodies, which were correlated with a fluctuating decrease in virus load, leading to control of virus replication and ultimately viral clearance. These data strongly suggest escaping functional B-cell responses is at least one of the mechanisms for viral persistence. In addition, escape mutations have been described for both CD4[114] and CD8 T-cell[118] epitopes. Vaccine induced immune escape is therefore of great concern.

On the positive side, mutations induced by immune pressure can lead to a reduction in viral fitness that could potentially limit viral persistence. It was demonstrated that immune pressure induced changes of non-structural regions can be lethal to the virus[136], while specific changes in envelope glycoproteins may have serious implications in selective outgrowth[137], virus entry and sensitivity to neutralization[138].

OTHER MECHANISMS TO EVADE VACCINE INDUCED IMMUNITY

Apart from generation of escape mutants, HCV may evade immune pressure by modulating immune responses. HCV specific T-cells with an exhausted phenotype in terms of loss of CD127 expression, cytokine expression and increased levels of the inhibitory markers PD-1 and CTLA-4 have been described[139-141] (Figure 2). Moreover, the negative immune modulator Tim-3, LAG-3, CD160 and 2B4 have been associated with exhausted HCV specific T-cells[139,142,143].

Also active suppression of HCV-specific T-cell responses by regulatory T-cells or by the immunosuppressive cytokines IL-10 and transforming growth factor-β have been described[144]. The contribution of each of these immuno-regulatory mechanisms during HCV persistence varies between individual patients and also synergistic effects were found[135]. Restoration of dysfunctional HCV-specific T-cell responses by blocking inhibitory molecules temporarily restored anti-HCV T-cell responses resulting in a transient drop in virus load[143,145-147]. Combining the recovery of functional T-cells with a boost of T-cell responses will be of interest as a therapeutic vaccine strategy.

Natural killer (NK) cells play an important role during HCV infections[148] because of their potential to lyse infected hepatocytes *via* antibody dependent cellular cytotoxicity. However, because NK cell function has not been studied in the context of vaccine induced clearance of HCV in chimpanzees, this is not documented.

Some of the prophylactic vaccine candidates and regimen that were found beneficial in chimpanzees have been, or are currently, tested in humans. For two HCV-envelope vaccines, E1/E2[119] and E1[149], T-cell and antibody responses in healthy volunteers were comparable to the responses found in chimpanzees. Despite these promising results, the development of both candidates is currently on hold.

Both adenovirus and MVA were successful as vaccine delivery vehicles in chimpanzees and both platforms have advanced to human trails. To overcome vector specific immunity much effort was put into the design of even less immunogenic vectors or, when multiple immunizations are required, the design of immunization protocols with different serotypes of the vector. MVA and adenovirus based vaccines are currently incorporated in-mainly-therapeutic vaccination strategies in chronically infected patients.

CONCLUSION AND FUTURE VACCINE PERSPECTIVES

Studies in chimpanzees have provided important insights into the efficacy of different vaccine strategies and provided evidence for the central role of neutralizing antibodies in obtaining protection against infection. While most vaccine candidates that induce cellular immune responses, do not protect from infection they do lead to reduced viremia in the acute phase of the infection and reduce the risk for development of chronicity. The current challenge is to translate this newly acquired knowledge into an efficient prophylactic HCV vaccine that protects

from chronic HCV infection.

Due to further restrictions on the use of chimpanzees for biomedical research, future evaluation of a new vaccine candidates or strategies in these apes will be severely limited. We have summarized the work performed so far, discussing the different immunization strategies used and types of immune response induced. Although partial protection, defined as decreased chance to develop chronic HCV infection, can be achieved by immunization, a clear correlate of protection has not yet been established. Further studies are required and have to be based to a large extent on clinical trials.

ACKNOWLEDGMENTS

The authors would like to thank Henk van Westbroek for the illustrations and Thea de Koning for editing the manuscript.

REFERENCES

1 **Gravitz L**. Introduction: a smouldering public-health crisis. *Nature* 2011; **474**: S2-S4 [PMID: 21666731 DOI: 10.1038/474S2a]

2 **Williams I**. Epidemiology of hepatitis C in the United States. *Am J Med* 1999; **107**: 2S-9S [PMID: 10653448]

3 **Perz JF**, Armstrong GL, Farrington LA, Hutin YJ, Bell BP. The contributions of hepatitis B virus and hepatitis C virus infections to cirrhosis and primary liver cancer worldwide. *J Hepatol* 2006; **45**: 529-538 [PMID: 16879891 DOI: 10.1016/j.jhep.2006.05.013]

4 A dozen good ideas to battle hepatitis. *Lancet* 2008; **371**: 1637 [PMID: 18486721 DOI: 10.1016/S0140-6736(08)60699-6]

5 **Valdiserri R**, Khalsa J, Dan C, Holmberg S, Zibbell J, Holtzman D, Lubran R, Compton W. Confronting the emerging epidemic of HCV infection among young injection drug users. *Am J Public Health* 2014; **104**: 816-821 [PMID: 24625174 DOI: 10.2105/AJPH.2013.301812]

6 **Van Den Berg C**, Smit C, Van Brussel G, Coutinho R, Prins M. Full participation in harm reduction programmes is associated with decreased risk for human immunodeficiency virus and hepatitis C virus: evidence from the Amsterdam Cohort Studies among drug users. *Addiction* 2007; **102**: 1454-1462 [PMID: 17697278 DOI: 10.1111/j.1360-0443.2007.01912.x]

7 **Abdul-Quader AS**, Feelemyer J, Modi S, Stein ES, Briceno A, Semaan S, Horvath T, Kennedy GE, Des Jarlais DC. Effectiveness of structural-level needle/syringe programs to reduce HCV and HIV infection among people who inject drugs: a systematic review. *AIDS Behav* 2013; **17**: 2878-2892 [PMID: 23975473 DOI: 10.1007/s10461-013-0593-y]

8 **Yahia M**. Global health: a uniquely Egyptian epidemic. *Nature* 2011; **474**: S12-S13 [PMID: 21666728 DOI: 10.1038/474S12a]

9 **Simmonds P**, Bukh J, Combet C, Deléage G, Enomoto N, Feinstone S, Halfon P, Inchauspé G, Kuiken C, Maertens G, Mizokami M, Murphy DG, Okamoto H, Pawlotsky JM, Penin F, Sablon E, Shin-I T, Stuyver LJ, Thiel HJ, Viazov S, Weiner AJ, Widell A. Consensus proposals for a unified system of nomenclature of hepatitis C virus genotypes. *Hepatology* 2005; **42**: 962-973 [PMID: 16149085 DOI: 10.1002/hep.20819]

10 **Smith DB**, Bukh J, Kuiken C, Muerhoff AS, Rice CM, Stapleton JT, Simmonds P. Expanded classification of hepatitis C virus into 7 genotypes and 67 subtypes: updated criteria and genotype assignment web resource. *Hepatology* 2014; **59**: 318-327 [PMID: 24115039 DOI: 10.1002/hep.26744]

11 **Simmonds P**. Genetic diversity and evolution of hepatitis C virus--15 years on. *J Gen Virol* 2004; **85**: 3173-3188 [PMID: 15483230 DOI: 10.1099/vir.0.80401-0]

12 **Su AI**, Pezacki JP, Wodicka L, Brideau AD, Supekova L, Thimme R, Wieland S, Bukh J, Purcell RH, Schultz PG, Chisari FV. Genomic analysis of the host response to hepatitis C virus infection. *Proc Natl Acad Sci USA* 2002; **99**: 15669-15674 [PMID: 12441396 DOI: 10.1073/pnas.202608199]

13 **Bigger CB**, Brasky KM, Lanford RE. DNA microarray analysis of chimpanzee liver during acute resolving hepatitis C virus infection. *J Virol* 2001; **75**: 7059-7066 [PMID: 11435586 DOI: 10.1128/JVI.75.15.7059-7066.2001]

14 **Bigger CB**, Guerra B, Brasky KM, Hubbard G, Beard MR, Luxon BA, Lemon SM, Lanford RE. Intrahepatic gene expression during chronic hepatitis C virus infection in chimpanzees. *J Virol* 2004; **78**: 13779-13792 [PMID: 15564486 DOI: 10.1128/JVI.78.24.13779-13792.2004]

15 **Marcello T**, Grakoui A, Barba-Spaeth G, Machlin ES, Kotenko SV, MacDonald MR, Rice CM. Interferons alpha and lambda inhibit hepatitis C virus replication with distinct signal transduction and gene regulation kinetics. *Gastroenterology* 2006; **131**: 1887-1898 [PMID: 17087946 DOI: 10.1053/j.gastro.2006.09.052]

16 **Olagnier D**, Hiscott J. Type I and type III interferon-induced immune response: it's a matter of kinetics and magnitude. *Hepatology* 2014; **59**: 1225-1228 [PMID: 24677190 DOI: 10.1002/hep.26959]

17 **McGilvray I**, Feld JJ, Chen L, Pattullo V, Guindi M, Fischer S, Borozan I, Xie G, Selzner N, Heathcote EJ, Siminovitch K. Hepatic cell-type specific gene expression better predicts HCV treatment outcome than IL28B genotype. *Gastroenterology* 2012; **142**: 1122-1131.e1 [PMID: 22285807 DOI: 10.1053/j.gastro.2012.01.028]

18 **Davis GL**, Esteban-Mur R, Rustgi V, Hoefs J, Gordon SC, Trepo C, Shiffman ML, Zeuzem S, Craxi A, Ling MH, Albrecht J. Interferon alfa-2b alone or in combination with ribavirin for the treatment of relapse of chronic hepatitis C. International Hepatitis Interventional Therapy Group. *N Engl J Med* 1998; **339**: 1493-1499 [PMID: 9819447 DOI: 10.1056/NEJM199811193392102]

19 **McHutchison JG**, Gordon SC, Schiff ER, Shiffman ML, Lee WM, Rustgi VK, Goodman ZD, Ling MH, Cort S, Albrecht JK. Interferon alfa-2b alone or in combination with ribavirin as initial treatment for chronic hepatitis C. Hepatitis Interventional Therapy Group. *N Engl J Med* 1998; **339**: 1485-1492 [PMID: 9819446 DOI: 10.1056/NEJM199811193392101]

20 **Poynard T**, Marcellin P, Lee SS, Niederau C, Minuk GS, Ideo G, Bain V, Heathcote J, Zeuzem S, Trepo C, Albrecht J. Randomised trial of interferon alpha2b plus ribavirin for 48 weeks or for 24 weeks versus interferon alpha2b plus placebo for 48 weeks for treatment of chronic infection with hepatitis C virus. International Hepatitis Interventional Therapy Group (IHIT). *Lancet* 1998; **352**: 1426-1432 [PMID: 9807989]

21 **Rauch A**, Gaudieri S, Thio C, Bochud PY. Host genetic determinants of spontaneous hepatitis C clearance. *Pharmacogenomics* 2009; **10**: 1819-1837 [PMID: 19891557 DOI: 10.2217/pgs.09.121]

22 **Macartney MJ**, Irish D, Bridge SH, Garcia-Diaz A, Booth CL, McCormick AL, Labbett W, Smith C, Velazquez C, Tanwar S, Trembling P, Jacobs M, Dusheiko G, Rosenberg W, Haque T. Telaprevir or boceprevir based therapy for chronic hepatitis C infection: development of resistance-associated variants in treatment failure. *Antiviral Res* 2014; **105**: 112-117 [PMID: 24594347 DOI: 10.1016/j.antiviral.2014.02.019]

23 **Kohli A**, Shaffer A, Sherman A, Kottilil S. Treatment of hepatitis C: a systematic review. *JAMA* 2014; **312**: 631-640 [PMID: 25117132 DOI: 10.1001/jama.2014.7085]

24 **Izumi N**. Efficacy of daclatasvir in hepatitis C virus. *Expert Rev Anti Infect Ther* 2014; **12**: 1025-1031 [PMID: 25059552 DOI: 10.1586/14787210.2014.942282]

25 **Wooding S**, Jorde LB. Duplication and divergence in humans and chimpanzees. *Bioessays* 2006; **28**: 335-338 [PMID: 16547951 DOI: 10.1002/bies.20385]

26 **Altevogt BM,** Pankevich DE, Shelton-Davenport MK, Kahn JP. Institute of Medicine (US) and National Research Council (US) Committee on the Use of Chimpanzees in Biomedical and Behavioral Research; Chimpanzees in Biomedical and Behavioral Research: Assessing the Necessity. Washington (DC): National Academies Press (US), 2011

27 **Bettauer RH**. Chimpanzees in hepatitis C virus research: 1998-2007. *J Med Primatol* 2010; **39**: 9-23 [PMID: 19900169 DOI: 10.1111/j.1600-0684.2009.00390.x]

28 **Farci P**. Choo QL, Kuo G, Weiner AJ, Overby LR, Bradley DW, Houghton M. Isolation of a cDNA clone derived from a blood-borne non-A, non-B viral hepatitis genome [Science 1989; 244: 359-362]. *J Hepatol* 2002; **36**: 582-585 [PMID: 11983439]

29 **Walker CM**. Comparative features of hepatitis C virus infection in humans and chimpanzees. *Springer Semin Immunopathol* 1997; **19**: 85-98 [PMID: 9266633]

30 **Lanford RE**, Bigger C, Bassett S, Klimpel G. The chimpanzee model of hepatitis C virus infections. *ILAR J* 2001; **42**: 117-126 [PMID: 11406714]

31 **Netski DM**, Mosbruger T, Depla E, Maertens G, Ray SC, Hamilton RG, Roundtree S, Thomas DL, McKeating J, Cox A. Humoral immune response in acute hepatitis C virus infection. *Clin Infect Dis* 2005; **41**: 667-675 [PMID: 16080089 DOI: 10.1086/432478]

32 **Pawlotsky JM**. Diagnostic tests for hepatitis C. *J Hepatol* 1999; **31** Suppl 1: 71-79 [PMID: 10622564]

33 **Bassett SE**, Brasky KM, Lanford RE. Analysis of hepatitis C virus-inoculated chimpanzees reveals unexpected clinical profiles. *J Virol* 1998; **72**: 2589-2599 [PMID: 9525575]

34 **Takaki K**, Itono Y, Nagafuji A, Naito Y, Shishido T, Takehira K, Makioka Y, Taniguchi Y, Fujiwara Y. Three-component coupling of acylphosphonates and two carbonyl compounds promoted by low-valent samariums: one-Pot synthesis of beta-hydroxyphosphonates. *J Org Chem* 2000; **65**: 475-481 [PMID: 10813960]

35 **Koziel MJ**, Wong DK, Dudley D, Houghton M, Walker BD. Hepatitis C virus-specific cytolytic T lymphocyte and T helper cell responses in seronegative persons. *J Infect Dis* 1997; **176**: 859-866 [PMID: 9333142]

36 **Barrett S**, Ryan E, Crowe J. Association of the HLA-DRB1*01 allele with spontaneous viral clearance in an Irish cohort infected with hepatitis C virus via contaminated anti-D immunoglobulin. *J Hepatol* 1999; **30**: 979-983 [PMID: 10406173]

37 **Veerapu NS**, Park SH, Tully DC, Allen TM, Rehermann B. Trace amounts of sporadically reappearing HCV RNA can cause infection. *J Clin Invest* 2014; **124**: 3469-3478 [PMID: 25003189 DOI: 10.1172/JCI73104]

38 **Botarelli P**, Brunetto MR, Minutello MA, Calvo P, Unutmaz D, Weiner AJ, Choo QL, Shuster JR, Kuo G, Bonino F. T-lymphocyte response to hepatitis C virus in different clinical courses of infection. *Gastroenterology* 1993; **104**: 580-587 [PMID: 8425701]

39 **Diepolder HM**, Zachoval R, Hoffmann RM, Wierenga EA, Santantonio T, Jung MC, Eichenlaub D, Pape GR. Possible mechanism involving T-lymphocyte response to non-structural protein 3 in viral clearance in acute hepatitis C virus infection. *Lancet* 1995; **346**: 1006-1007 [PMID: 7475549]

40 **Ferrari C**, Valli A, Galati L, Penna A, Scaccaglia P, Giuberti T, Schianchi C, Missale G, Marin MG, Fiaccadori F. T-cell response to structural and nonstructural hepatitis C virus antigens in persistent and self-limited hepatitis C virus infections. *Hepatology* 1994; **19**: 286-295 [PMID: 8294086]

41 **Missale G**, Bertoni R, Lamonaca V, Valli A, Massari M, Mori C, Rumi MG, Houghton M, Fiaccadori F, Ferrari C. Different clinical behaviors of acute hepatitis C virus infection are associated with different vigor of the anti-viral cell-mediated immune response. *J Clin Invest* 1996; **98**: 706-714 [PMID: 8698862 DOI: 10.1172/JCI118842]

42 **Thimme R**, Oldach D, Chang KM, Steiger C, Ray SC, Chisari FV. Determinants of viral clearance and persistence during acute hepatitis C virus infection. *J Exp Med* 2001; **194**: 1395-1406 [PMID: 11714747]

43 **He XS**, Rehermann B, López-Labrador FX, Boisvert J, Cheung R, Mumm J, Wedemeyer H, Berenguer M, Wright TL, Davis MM, Greenberg HB. Quantitative analysis of hepatitis C virus-specific CD8(+) T cells in peripheral blood and liver using peptide-MHC tetramers. *Proc Natl Acad Sci USA* 1999; **96**: 5692-5697 [PMID: 10318946]

44 **Schirren CA**, Jung MC, Gerlach JT, Worzfeld T, Baretton G, Mamin M, Hubert Gruener N, Houghton M, Pape GR. Liver-derived hepatitis C virus (HCV)-specific CD4(+) T cells recognize multiple HCV epitopes and produce interferon gamma. *Hepatology* 2000; **32**: 597-603 [PMID: 10960455 DOI: 10.1053/jhep.2000.9635]

45 **Grüner NH**, Gerlach TJ, Jung MC, Diepolder HM, Schirren CA, Schraut WW, Hoffmann R, Zachoval R, Santantonio T, Cucchiarini M, Cerny A, Pape GR. Association of hepatitis C virus-specific CD8+ T cells with viral clearance in acute hepatitis C. *J Infect Dis* 2000; **181**: 1528-1536 [PMID: 10823750 DOI: 10.1086/315450]

46 **Cooper S**, Erickson AL, Adams EJ, Kansopon J, Weiner AJ, Chien DY, Houghton M, Parham P, Walker CM. Analysis of a successful immune response against hepatitis C virus. *Immunity* 1999; **10**: 439-449 [PMID: 10229187]

47 **Dahari H**, Feinstone SM, Major ME. Meta-analysis of hepatitis C virus vaccine efficacy in chimpanzees indicates an importance for structural proteins. *Gastroenterology* 2010; **139**: 965-974 [PMID: 20621699 DOI: 10.1053/j.gastro.2010.05.077]

48 **Bukh J**, Forns X, Emerson SU, Purcell RH. Studies of hepatitis C virus in chimpanzees and their importance for vaccine development. *Intervirology* 2001; **44**: 132-142 [PMID: 11509874]

49 **Abe K**, Inchauspe G, Shikata T, Prince AM. Three different patterns of hepatitis C virus infection in chimpanzees. *Hepatology* 1992; **15**: 690-695 [PMID: 1312987]

50 **de Groot NG**, Heijmans CM, Zoet YM, de Ru AH, Verreck FA, van Veelen PA, Drijfhout JW, Doxiadis GG, Remarque EJ, Doxiadis II, van Rood JJ, Koning F, Bontrop RE. AIDS-protective HLA-B*27/B*57 and chimpanzee MHC class I molecules target analogous conserved areas of HIV-1/SIVcpz. *Proc Natl Acad Sci USA* 2010; **107**: 15175-15180 [PMID: 20696916 DOI: 10.1073/pnas.1009136107]

51 **Thomas DL**, Thio CL, Martin MP, Qi Y, Ge D, O'Huigin C, Kidd J, Kidd K, Khakoo SI, Alexander G, Goedert JJ, Kirk GD, Donfield SM, Rosen HR, Tobler LH, Busch MP, McHutchison JG, Goldstein DB, Carrington M. Genetic variation in IL28B and spontaneous clearance of hepatitis C virus. *Nature* 2009; **461**: 798-801 [PMID: 19759533 DOI: 10.1038/nature08463]

52 **Rauch A**, Kutalik Z, Descombes P, Cai T, Di Iulio J, Mueller T, Bochud M, Battegay M, Bernasconi E, Borovicka J, Colombo S, Cerny A, Dufour JF, Furrer H, Günthard HF, Heim M, Hirschel B, Malinverni R, Moradpour D, Müllhaupt B, Witteck A, Beckmann JS, Berg T, Bergmann S, Negro F, Telenti A, Bochud PY. Genetic variation in IL28B is associated with chronic hepatitis C and treatment failure: a genome-wide association study. *Gastroenterology* 2010; **138**: 1338-1345, 1345.e1-7 [PMID: 20060832 DOI: 10.1053/j.gastro.2009.12.056]

53 **Verstrepen BE**, de Groot NG, Groothuismink ZM, Verschoor EJ, de Groen RA, Bogers WM, Janssen HL, Mooij P, Bontrop RE, Koopman G, Boonstra A. Evaluation of IL-28B polymorphisms and serum IP-10 in hepatitis C infected

chimpanzees. *PLoS One* 2012; **7**: e46645 [PMID: 23118858 DOI: 10.1371/journal.pone.0046645]

54 **Mehta SH**, Cox A, Hoover DR, Wang XH, Mao Q, Ray S, Strathdee SA, Vlahov D, Thomas DL. Protection against persistence of hepatitis C. *Lancet* 2002; **359**: 1478-1483 [PMID: 11988247 DOI: 10.1016/S0140-6736(02)08435-0]

55 **Osburn WO**, Fisher BE, Dowd KA, Urban G, Liu L, Ray SC, Thomas DL, Cox AL. Spontaneous control of primary hepatitis C virus infection and immunity against persistent reinfection. *Gastroenterology* 2010; **138**: 315-324 [PMID: 19782080 DOI: 10.1053/j.gastro.2009.09.017]

56 **Gerlach JT**, Diepolder HM, Zachoval R, Gruener NH, Jung MC, Ulsenheimer A, Schraut WW, Schirren CA, Waechtler M, Backmund M, Pape GR. Acute hepatitis C: high rate of both spontaneous and treatment-induced viral clearance. *Gastroenterology* 2003; **125**: 80-88 [PMID: 12851873]

57 **van de Laar TJ**, Molenkamp R, van den Berg C, Schinkel J, Beld MG, Prins M, Coutinho RA, Bruisten SM. Frequent HCV reinfection and superinfection in a cohort of injecting drug users in Amsterdam. *J Hepatol* 2009; **51**: 667-674 [PMID: 19646773 DOI: 10.1016/j.jhep.2009.05.027]

58 **Grebely J**, Prins M, Hellard M, Cox AL, Osburn WO, Lauer G, Page K, Lloyd AR, Dore GJ. Hepatitis C virus clearance, reinfection, and persistence, with insights from studies of injecting drug users: towards a vaccine. *Lancet Infect Dis* 2012; **12**: 408-414 [PMID: 22541630 DOI: 10.1016/S1473-3099(12)70010-5]

59 **Bukh J**, Thimme R, Meunier JC, Faulk K, Spangenberg HC, Chang KM, Satterfield W, Chisari FV, Purcell RH. Previously infected chimpanzees are not consistently protected against reinfection or persistent infection after reexposure to the identical hepatitis C virus strain. *J Virol* 2008; **82**: 8183-8195 [PMID: 18550671 DOI: 10.1128/JVI.00142-08]

60 **Weiner AJ**, Paliard X, Selby MJ, Medina-Selby A, Coit D, Nguyen S, Kansopon J, Arian CL, Ng P, Tucker J, Lee CT, Polakos NK, Han J, Wong S, Lu HH, Rosenberg S, Brasky KM, Chien D, Kuo G, Houghton M. Intrahepatic genetic inoculation of hepatitis C virus RNA confers cross-protective immunity. *J Virol* 2001; **75**: 7142-7148 [PMID: 11435595 DOI: 10.1128/JVI.75.15.7142-7148.2001]

61 **Bassett SE**, Thomas DL, Brasky KM, Lanford RE. Viral persistence, antibody to E1 and E2, and hypervariable region 1 sequence stability in hepatitis C virus-inoculated chimpanzees. *J Virol* 1999; **73**: 1118-1126 [PMID: 9882313]

62 **Major ME**, Mihalik K, Puig M, Rehermann B, Nascimbeni M, Rice CM, Feinstone SM. Previously infected and recovered chimpanzees exhibit rapid responses that control hepatitis C virus replication upon rechallenge. *J Virol* 2002; **76**: 6586-6595 [PMID: 12050371]

63 **Nascimbeni M**, Mizukoshi E, Bosmann M, Major ME, Mihalik K, Rice CM, Feinstone SM, Rehermann B. Kinetics of CD4+ and CD8+ memory T-cell responses during hepatitis C virus rechallenge of previously recovered chimpanzees. *J Virol* 2003; **77**: 4781-4793 [PMID: 12663785]

64 **Lanford RE**, Guerra B, Chavez D, Bigger C, Brasky KM, Wang XH, Ray SC, Thomas DL. Cross-genotype immunity to hepatitis C virus. *J Virol* 2004; **78**: 1575-1581 [PMID: 14722311]

65 **Prince AM**, Brotman B, Lee DH, Pfahler W, Tricoche N, Andrus L, Shata MT. Protection against chronic hepatitis C virus infection after rechallenge with homologous, but not heterologous, genotypes in a chimpanzee model. *J Infect Dis* 2005; **192**: 1701-1709 [PMID: 16235167 DOI: 10.1086/496889]

66 **Shoukry NH**, Grakoui A, Houghton M, Chien DY, Ghrayeb J, Reimann KA, Walker CM. Memory CD8+ T cells are required for protection from persistent hepatitis C virus infection. *J Exp Med* 2003; **197**: 1645-1655 [PMID: 12810686 DOI: 10.1084/jem.20030239]

67 **Farci P**, Shimoda A, Wong D, Cabezon T, De Gioannis D, Strazzera A, Shimizu Y, Shapiro M, Alter HJ, Purcell RH. Prevention of hepatitis C virus infection in chimpanzees by hyperimmune serum against the hypervariable region 1 of the envelope 2 protein. *Proc Natl Acad Sci USA* 1996; **93**: 15394-15399 [PMID: 8986822]

68 **Farci P**, Shimoda A, Coiana A, Diaz G, Peddis G, Melpolder JC, Strazzera A, Chien DY, Munoz SJ, Balestrieri A, Purcell RH, Alter HJ. The outcome of acute hepatitis C predicted by the evolution of the viral quasispecies. *Science* 2000; **288**: 339-344 [PMID: 10764648]

69 **Okamoto H**, Kojima M, Okada S, Yoshizawa H, Iizuka H, Tanaka T, Muchmore EE, Peterson DA, Ito Y, Mishiro S. Genetic drift of hepatitis C virus during an 8.2-year infection in a chimpanzee: variability and stability. *Virology* 1992; **190**: 894-899 [PMID: 1325713]

70 **van Doorn LJ**, Quint W, Tsiquaye K, Voermans J, Paelinck D, Kos T, Maertens G, Schellekens H, Murray K. Longitudinal analysis of hepatitis C virus infection and genetic drift of the hypervariable region. *J Infect Dis* 1994; **169**: 1226-1235 [PMID: 7545928]

71 **Bartosch B**, Dubuisson J, Cosset FL. Infectious hepatitis C virus pseudo-particles containing functional E1-E2 envelope protein complexes. *J Exp Med* 2003; **197**: 633-642 [PMID: 12615904]

72 **Wakita T**, Pietschmann T, Kato T, Date T, Miyamoto M, Zhao Z, Murthy K, Habermann A, Kräusslich HG, Mizokami M, Bartenschlager R, Liang TJ. Production of infectious hepatitis C virus in tissue culture from a cloned viral genome. *Nat Med* 2005; **11**: 791-796 [PMID: 15951748 DOI: 10.1038/nm1268]

73 **Kato T**, Choi Y, Elmowalid G, Sapp RK, Barth H, Furusaka A, Mishiro S, Wakita T, Krawczynski K, Liang TJ. Hepatitis C virus JFH-1 strain infection in chimpanzees is associated with low pathogenicity and emergence of an adaptive mutation. *Hepatology* 2008; **48**: 732-740 [PMID: 18712792 DOI: 10.1002/hep.22422]

74 **Lohmann V**, Bartenschlager R. On the history of hepatitis C virus cell culture systems. *J Med Chem* 2014; **57**: 1627-1642 [PMID: 24164647 DOI: 10.1021/jm401401n]

75 **Sabahi A**. Hepatitis C Virus entry: the early steps in the viral replication cycle. *Virol J* 2009; **6**: 117 [PMID: 19643019 DOI: 10.1186/1743-422X-6-117]

76 **Johansson DX**, Voisset C, Tarr AW, Aung M, Ball JK, Dubuisson J, Persson MA. Human combinatorial libraries yield rare antibodies that broadly neutralize hepatitis C virus. *Proc Natl Acad Sci USA* 2007; **104**: 16269-16274 [PMID: 17911260 DOI: 10.1073/pnas.0705522104]

77 **Kato N**, Sekiya H, Ootsuyama Y, Nakazawa T, Hijikata M, Ohkoshi S, Shimotohno K. Humoral immune response to hypervariable region 1 of the putative envelope glycoprotein (gp70) of hepatitis C virus. *J Virol* 1993; **67**: 3923-3930 [PMID: 7685404]

78 **Keck ZY**, Li TK, Xia J, Gal-Tanamy M, Olson O, Li SH, Patel AH, Ball JK, Lemon SM, Foung SK. Definition of a conserved immunodominant domain on hepatitis C virus E2 glycoprotein by neutralizing human monoclonal antibodies. *J Virol* 2008; **82**: 6061-6066 [PMID: 18400849 DOI: 10.1128/JVI.02475-07]

79 **Meunier JC**, Russell RS, Goossens V, Priem S, Walter H, Depla E, Union A, Faulk KN, Bukh J, Emerson SU, Purcell RH. Isolation and characterization of broadly neutralizing human monoclonal antibodies to the e1 glycoprotein of hepatitis C virus. *J Virol* 2008; **82**: 966-973 [PMID: 17977972 DOI: 10.1128/JVI.01872-07]

80 **Owsianka A**, Tarr AW, Juttla VS, Lavillette D, Bartosch B, Cosset FL, Ball JK, Patel AH. Monoclonal antibody AP33 defines a broadly neutralizing epitope on the hepatitis C virus E2 envelope glycoprotein. *J Virol* 2005; **79**: 11095-11104 [PMID: 16103160 DOI: 10.1128/JVI.79.17.11095-11104.2005]

81 **Perotti M**, Mancini N, Diotti RA, Tarr AW, Ball JK, Owsianka A, Adair R, Patel AH, Clementi M, Burioni R.

Identification of a broadly cross-reacting and neutralizing human monoclonal antibody directed against the hepatitis C virus E2 protein. *J Virol* 2008; **82**: 1047-1052 [PMID: 17989176 DOI: 10.1128/JVI.01986-07]

82 **Shimizu YK**, Igarashi H, Kiyohara T, Cabezon T, Farci P, Purcell RH, Yoshikura H. A hyperimmune serum against a synthetic peptide corresponding to the hypervariable region 1 of hepatitis C virus can prevent viral infection in cell cultures. *Virology* 1996; **223**: 409-412 [PMID: 8806581 DOI: 10.1006/viro.1996.0497]

83 **Bartosch B**, Bukh J, Meunier JC, Granier C, Engle RE, Blackwelder WC, Emerson SU, Cosset FL, Purcell RH. In vitro assay for neutralizing antibody to hepatitis C virus: evidence for broadly conserved neutralization epitopes. *Proc Natl Acad Sci USA* 2003; **100**: 14199-14204 [PMID: 14617769 DOI: 10.1073/pnas.2335981100]

84 **Vieyres G**, Dubuisson J, Patel AH. Characterization of antibody-mediated neutralization directed against the hypervariable region 1 of hepatitis C virus E2 glycoprotein. *J Gen Virol* 2011; **92**: 494-506 [PMID: 21084495 DOI: 10.1099/vir.0.028092-0]

85 **Broering TJ**, Garrity KA, Boatright NK, Sloan SE, Sandor F, Thomas WD, Szabo G, Finberg RW, Ambrosino DM, Babcock GJ. Identification and characterization of broadly neutralizing human monoclonal antibodies directed against the E2 envelope glycoprotein of hepatitis C virus. *J Virol* 2009; **83**: 12473-12482 [PMID: 19759151 DOI: 10.1128/JVI.01138-09]

86 **Tarr AW**, Owsianka AM, Timms JM, McClure CP, Brown RJ, Hickling TP, Pietschmann T, Bartenschlager R, Patel AH, Ball JK. Characterization of the hepatitis C virus E2 epitope defined by the broadly neutralizing monoclonal antibody AP33. *Hepatology* 2006; **43**: 592-601 [PMID: 16496330 DOI: 10.1002/hep.21088]

87 **Wahid A**, Dubuisson J. Virus-neutralizing antibodies to hepatitis C virus. *J Viral Hepat* 2013; **20**: 369-376 [PMID: 23647953 DOI: 10.1111/jvh.12094]

88 **Lavillette D**, Morice Y, Germanidis G, Donot P, Soulier A, Pagkalos E, Sakellariou G, Intrator L, Bartosch B, Pawlotsky JM, Cosset FL. Human serum facilitates hepatitis C virus infection, and neutralizing responses inversely correlate with viral replication kinetics at the acute phase of hepatitis C virus infection. *J Virol* 2005; **79**: 6023-6034 [PMID: 15857988 DOI: 10.1128/JVI.79.10.6023-6034.2005]

89 **Logvinoff C**, Major ME, Oldach D, Heyward S, Talal A, Balfe P, Feinstone SM, Alter H, Rice CM, McKeating JA. Neutralizing antibody response during acute and chronic hepatitis C virus infection. *Proc Natl Acad Sci USA* 2004; **101**: 10149-10154 [PMID: 15220475 DOI: 10.1073/pnas.0403519101]

90 **Razvi S**, Schneider L, Jonas MM, Cunningham-Rundles C. Outcome of intravenous immunoglobulin-transmitted hepatitis C virus infection in primary immunodeficiency. *Clin Immunol* 2001; **101**: 284-288 [PMID: 11726220 DOI: 10.1006/clim.2001.5132]

91 **Grakoui A**, Shoukry NH, Woollard DJ, Han JH, Hanson HL, Ghrayeb J, Murthy KK, Rice CM, Walker CM. HCV persistence and immune evasion in the absence of memory T cell help. *Science* 2003; **302**: 659-662 [PMID: 14576438 DOI: 10.1126/science.1088774]

92 **Klenerman P**, Thimme R. T cell responses in hepatitis C: the good, the bad and the unconventional. *Gut* 2012; **61**: 1226-1234 [PMID: 21873736 DOI: 10.1136/gutjnl-2011-300620]

93 **Bowen DG**, Walker CM. Adaptive immune responses in acute and chronic hepatitis C virus infection. *Nature* 2005; **436**: 946-952 [PMID: 16107834 DOI: 10.1038/nature04079]

94 **Abdel-Hakeem MS**, Shoukry NH. Protective immunity against hepatitis C: many shades of gray. *Front Immunol* 2014; **5**: 274 [PMID: 24982656 DOI: 10.3389/fimmu.2014.00274]

95 **Claassen MA**, Janssen HL, Boonstra A. Role of T cell immunity in hepatitis C virus infections. *Curr Opin Virol* 2013; **3**: 461-467 [PMID: 23735335 DOI: 10.1016/j.coviro.2013.05.006]

96 **Timm J**, Lauer GM, Kavanagh DG, Sheridan I, Kim AY, Lucas M, Pillay T, Ouchi K, Reyor LL, Schulze zur Wiesch J, Gandhi RT, Chung RT, Bhardwaj N, Klenerman P, Walker BD, Allen TM. CD8 epitope escape and reversion in acute HCV infection. *J Exp Med* 2004; **200**: 1593-1604 [PMID: 15611288 DOI: 10.1084/jem.20041006]

97 **Fukuda R**, Ishimura N, Nguyen XT, Chowdhury A, Ishihara S, Sakai S, Akagi S, Tokuda A, Watanabe M, Fukumoto S. Gene expression of perforin and granzyme A in the liver in chronic hepatitis C: comparison with peripheral blood mononuclear cells. *Microbiol Immunol* 1995; **39**: 873-877 [PMID: 8657014]

98 **Lauer GM**, Lucas M, Timm J, Ouchi K, Kim AY, Day CL, Schulze Zur Wiesch J, Paranhos-Baccala G, Sheridan I, Casson DR, Reiser M, Gandhi RT, Li B, Allen TM, Chung RT, Klenerman P, Walker BD. Full-breadth analysis of CD8+ T-cell responses in acute hepatitis C virus infection and early therapy. *J Virol* 2005; **79**: 12979-12988 [PMID: 16189000 DOI: 10.1128/JVI.79.20.12979-12988.2005]

99 **Cox AL**, Mosbruger T, Lauer GM, Pardoll D, Thomas DL, Ray SC. Comprehensive analyses of CD8+ T cell responses during longitudinal study of acute human hepatitis C. *Hepatology* 2005; **42**: 104-112 [PMID: 15962289 DOI: 10.1002/hep.20749]

100 **Urbani S**, Amadei B, Fisicaro P, Tola D, Orlandini A, Sacchelli L, Mori C, Missale G, Ferrari C. Outcome of acute hepatitis C is related to virus-specific CD4 function and maturation of antiviral memory CD8 responses. *Hepatology* 2006; **44**: 126-139 [PMID: 16799989 DOI: 10.1002/hep.21242]

101 **Watanabe H**, Wells F, Major ME. Clearance of hepatitis C in chimpanzees is associated with intrahepatic T-cell perforin expression during the late acute phase. *J Viral Hepat* 2010; **17**: 245-253 [PMID: 19709361 DOI: 10.1111/j.1365-2893.2009.01172.x]

102 **Scottà C**, Garbuglia AR, Ruggeri L, Spada E, Laurenti L, Perrone MP, Girelli G, Mele A, Capobianchi MR, Folgori A, Nicosia A, Del Porto P, Piccolella E. Influence of specific CD4+ T cells and antibodies on evolution of hypervariable region 1 during acute HCV infection. *J Hepatol* 2008; **48**: 216-228 [PMID: 18180071 DOI: 10.1016/j.jhep.2007.09.011]

103 **Diepolder HM**, Zachoval R, Hoffmann RM, Jung MC, Gerlach T, Pape GR. The role of hepatitis C virus specific CD4+ T lymphocytes in acute and chronic hepatitis C. *J Mol Med* (Berl) 1996; **74**: 583-588 [PMID: 8912179]

104 **Schulze Zur Wiesch J**, Ciuffreda D, Lewis-Ximenez L, Kasprowicz V, Nolan BE, Streeck H, Aneja J, Reyor LL, Allen TM, Lohse AW, McGovern B, Chung RT, Kwok WW, Kim AY, Lauer GM. Broadly directed virus-specific CD4+ T cell responses are primed during acute hepatitis C infection, but rapidly disappear from human blood with viral persistence. *J Exp Med* 2012; **209**: 61-75 [PMID: 22213804 DOI: 10.1084/jem.20100388]

105 **Hakim MS**, Spaan M, Janssen HL, Boonstra A. Inhibitory receptor molecules in chronic hepatitis B and C infections: novel targets for immunotherapy? *Rev Med Virol* 2014; **24**: 125-138 [PMID: 24757728]

106 **Choo QL**, Kuo G, Ralston R, Weiner A, Chien D, Van Nest G, Han J, Berger K, Thudium K, Kuo C. Vaccination of chimpanzees against infection by the hepatitis C virus. *Proc Natl Acad Sci USA* 1994; **91**: 1294-1298 [PMID: 7509068]

107 **Coates S CQ-L**, Kuo G, Crawford K, Dong C, Wininger M, Houghton M. Protection of chimpanzees against heterologous 1a viral challenge using a gpE1/gpE2 heterodimer vaccine. Jilbert AR, Gragacic EVL, Vickery K, Burrell C, Cossart YE, editors. Proceedings of the 11th international symposium on viral hepatitis and liver disease, 2003: 118-123

108 **Esumi M**, Rikihisa T, Nishimura S, Goto J, Mizuno K, Zhou YH, Shikata T. Experimental vaccine activities of recombinant E1 and E2 glycoproteins and hypervariable region 1 peptides of hepatitis C virus in chimpanzees. *Arch*

Virol 1999; **144**: 973-980 [PMID: 10416378]
109 **Verstrepen BE**, Depla E, Rollier CS, Mares G, Drexhage JA, Priem S, Verschoor EJ, Koopman G, Granier C, Dreux M, Cosset FL, Maertens G, Heeney JL. Clearance of genotype 1b hepatitis C virus in chimpanzees in the presence of vaccine-induced E1-neutralizing antibodies. *J Infect Dis* 2011; **204**: 837-844 [PMID: 21849281 DOI: 10.1093/infdis/jir423]
110 **Forns X**, Payette PJ, Ma X, Satterfield W, Eder G, Mushahwar IK, Govindarajan S, Davis HL, Emerson SU, Purcell RH, Bukh J. Vaccination of chimpanzees with plasmid DNA encoding the hepatitis C virus (HCV) envelope E2 protein modified the infection after challenge with homologous monoclonal HCV. *Hepatology* 2000; **32**: 618-625 [PMID: 10960458 DOI: 10.1053/jhep.2000.9877]
111 **Elmowalid GA**, Qiao M, Jeong SH, Borg BB, Baumert TF, Sapp RK, Hu Z, Murthy K, Liang TJ. Immunization with hepatitis C virus-like particles results in control of hepatitis C virus infection in chimpanzees. *Proc Natl Acad Sci USA* 2007; **104**: 8427-8432 [PMID: 17485666 DOI: 10.1073/pnas.0702162104]
112 **Rollier C**, Depla E, Drexhage JA, Verschoor EJ, Verstrepen BE, Fatmi A, Brinster C, Fournillier A, Whelan JA, Whelan M, Jacobs D, Maertens G, Inchauspé G, Heeney JL. Control of heterologous hepatitis C virus infection in chimpanzees is associated with the quality of vaccine-induced peripheral T-helper immune response. *J Virol* 2004; **78**: 187-196 [PMID: 14671100]
113 **Puig M**, Major ME, Mihalik K, Feinstone SM. Immunization of chimpanzees with an envelope protein-based vaccine enhances specific humoral and cellular immune responses that delay hepatitis C virus infection. *Vaccine* 2004; **22**: 991-1000 [PMID: 15161076 DOI: 10.1016/j.vaccine.2003.09.010]
114 **Puig M**, Mihalik K, Tilton JC, Williams O, Merchlinsky M, Connors M, Feinstone SM, Major ME. CD4+ immune escape and subsequent T-cell failure following chimpanzee immunization against hepatitis C virus. *Hepatology* 2006; **44**: 736-745 [PMID: 16941702 DOI: 10.1002/hep.21319]
115 **Rollier CS**, Paranhos-Baccala G, Verschoor EJ, Verstrepen BE, Drexhage JA, Fagrouch Z, Berland JL, Komurian-Pradel F, Duverger B, Himoudi N, Staib C, Meyr M, Whelan M, Whelan JA, Adams VC, Larrea E, Riezu JI, Lasarte JJ, Bartosch B, Cosset FL, Spaan WJ, Diepolder HM, Pape GR, Sutter G, Inchauspe G, Heeney JL. Vaccine-induced early control of hepatitis C virus infection in chimpanzees fails to impact on hepatic PD-1 and chronicity. *Hepatology* 2007; **45**: 602-613 [PMID: 17326154 DOI: 10.1002/hep.21573]
116 **Youn JW**, Hu YW, Tricoche N, Pfahler W, Shata MT, Dreux M, Cosset FL, Folgori A, Lee DH, Brotman B, Prince AM. Evidence for protection against chronic hepatitis C virus infection in chimpanzees by immunization with replicating recombinant vaccinia virus. *J Virol* 2008; **82**: 10896-10905 [PMID: 18753204 DOI: 10.1128/JVI.01179-08]
117 **Youn JW**, Park SH, Lavillette D, Cosset FL, Yang SH, Lee CG, Jin HT, Kim CM, Shata MT, Lee DH, Pfahler W, Prince AM, Sung YC. Sustained E2 antibody response correlates with reduced peak viremia after hepatitis C virus infection in the chimpanzee. *Hepatology* 2005; **42**: 1429-1436 [PMID: 16317673 DOI: 10.1002/hep.20934]
118 **Folgori A**, Capone S, Ruggeri L, Meola A, Sporeno E, Ercole BB, Pezzanera M, Tafi R, Arcuri M, Fattori E, Lahm A, Luzzago A, Vitelli A, Colloca S, Cortese R, Nicosia A. A T-cell HCV vaccine eliciting effective immunity against heterologous virus challenge in chimpanzees. *Nat Med* 2006; **12**: 190-197 [PMID: 16462801 DOI: 10.1038/nm1353]
119 **Frey SE**, Houghton M, Coates S, Abrignani S, Chien D, Rosa D, Pileri P, Ray R, Di Bisceglie AM, Rinella P, Hill H, Wolff MC, Schultze V, Han JH, Scharschmidt B, Belshe RB. Safety and immunogenicity of HCV E1E2 vaccine adjuvanted with MF59 administered to healthy adults. *Vaccine* 2010; **28**: 6367-6373 [PMID: 20619382 DOI: 10.1016/j.vaccine.2010.06.084]
120 **Zubkova I**, Duan H, Wells F, Mostowski H, Chang E, Pirollo K, Krawczynski K, Lanford R, Major M. Hepatitis C virus clearance correlates with HLA-DR expression on proliferating CD8+ T cells in immune-primed chimpanzees. *Hepatology* 2014; **59**: 803-813 [PMID: 24123114 DOI: 10.1002/hep.26747]
121 **Drummer HE**. Challenges to the development of vaccines to hepatitis C virus that elicit neutralizing antibodies. *Front Microbiol* 2014; **5**: 329 [PMID: 25071742 DOI: 10.3389/fmicb.2014.00329]
122 **Kim CW**, Chang KM. Hepatitis C virus: virology and life cycle. *Clin Mol Hepatol* 2013; **19**: 17-25 [PMID: 23593605 DOI: 10.3350/cmh.2013.19.1.17]
123 **Vieyres G**, Thomas X, Descamps V, Duverlie G, Patel AH, Dubuisson J. Characterization of the envelope glycoproteins associated with infectious hepatitis C virus. *J Virol* 2010; **84**: 10159-10168 [PMID: 20668082 DOI: 10.1128/JVI.01180-10]
124 **Krey T**, d'Alayer J, Kikuti CM, Saulnier A, Damier-Piolle L, Petitpas I, Johansson DX, Tawar RG, Baron B, Robert B, England P, Persson MA, Martin A, Rey FA. The disulfide bonds in glycoprotein E2 of hepatitis C virus reveal the tertiary organization of the molecule. *PLoS Pathog* 2010; **6**: e1000762 [PMID: 20174556 DOI: 10.1371/journal.ppat.1000762]
125 **Sautto G**, Tarr AW, Mancini N, Clementi M. Structural and antigenic definition of hepatitis C virus E2 glycoprotein epitopes targeted by monoclonal antibodies. *Clin Dev Immunol* 2013; **2013**: 450963 [PMID: 23935648 DOI: 10.1155/2013/450963]
126 **Brazzoli M**, Helenius A, Foung SK, Houghton M, Abrignani S, Merola M. Folding and dimerization of hepatitis C virus E1 and E2 glycoproteins in stably transfected CHO cells. *Virology* 2005; **332**: 438-453 [PMID: 15661174 DOI: 10.1016/j.virol.2004.11.034]
127 **Lavillette D**, Pécheur EI, Donot P, Fresquet J, Molle J, Corbau R, Dreux M, Penin F, Cosset FL. Characterization of fusion determinants points to the involvement of three discrete regions of both E1 and E2 glycoproteins in the membrane fusion process of hepatitis C virus. *J Virol* 2007; **81**: 8752-8765 [PMID: 17537855 DOI: 10.1128/JVI.02642-06]
128 **Meunier JC**, Gottwein JM, Houghton M, Russell RS, Emerson SU, Bukh J, Purcell RH. Vaccine-induced cross-genotype reactive neutralizing antibodies against hepatitis C virus. *J Infect Dis* 2011; **204**: 1186-1190 [PMID: 21917891 DOI: 10.1093/infdis/jir511]
129 **Koup RA**, Douek DC. Vaccine design for CD8 T lymphocyte responses. *Cold Spring Harb Perspect Med* 2011; **1**: a007252 [PMID: 22229122 DOI: 10.1101/cshperspect.a007252]
130 **Roldão A**, Mellado MC, Castilho LR, Carrondo MJ, Alves PM. Virus-like particles in vaccine development. *Expert Rev Vaccines* 2010; **9**: 1149-1176 [PMID: 20923267 DOI: 10.1586/erv.10.115]
131 **Paris RM**, Kim JH, Robb ML, Michael NL. Prime-boost immunization with poxvirus or adenovirus vectors as a strategy to develop a protective vaccine for HIV-1. *Expert Rev Vaccines* 2010; **9**: 1055-1069 [PMID: 20822348 DOI: 10.1586/erv.10.106]
132 **Verstrepen BE**, Verschoor EJ, Fagrouch ZC, Mooij P, de Groot NG, Bontrop RE, Bogers WM, Heeney JL, Koopman G. Strong vaccine-induced CD8 T-cell responses have cytolytic function in a chimpanzee clearing HCV infection. *PLoS One* 2014; **9**: e95103 [PMID: 24740375 DOI: 10.1371/journal.pone.0095103]
133 **Schmitz V**, Qian C, Ruiz J, Sangro B, Melero I, Mazzolini G, Narvaiza I, Prieto J. Gene therapy for liver diseases: recent strategies for treatment of viral hepatitis and liver malignancies. *Gut* 2002; **50**: 130-135 [PMID: 11772981]
134 **Zubkova I**, Choi YH, Chang E, Pirollo K, Uren T, Watanabe H, Wells F, Kachko A, Krawczynski K, Major ME. T-cell vaccines that elicit effective immune responses against HCV in chimpanzees may create greater immune pressure for viral mutation. *Vaccine* 2009; **27**: 2594-2602 [PMID: 19428866

DOI: 10.1016/j.vaccine.2009.02.045]

135 **Claassen MA**, de Knegt RJ, Turgut D, Groothuismink ZM, Janssen HL, Boonstra A. Negative regulation of hepatitis C virus specific immunity is highly heterogeneous and modulated by pegylated interferon-alpha/ribavirin therapy. *PLoS One* 2012; **7**: e49389 [PMID: 23145169 DOI: 10.1371/journal.pone.0049389]

136 **Söderholm J**, Ahlén G, Kaul A, Frelin L, Alheim M, Barnfield C, Liljeström P, Weiland O, Milich DR, Bartenschlager R, Sällberg M. Relation between viral fitness and immune escape within the hepatitis C virus protease. *Gut* 2006; **55**: 266-274 [PMID: 16105887 DOI: 10.1136/gut.2005.072231]

137 **Brown RJ**, Hudson N, Wilson G, Rehman SU, Jabbari S, Hu K, Tarr AW, Borrow P, Joyce M, Lewis J, Zhu LF, Law M, Kneteman N, Tyrrell DL, McKeating JA, Ball JK. Hepatitis C virus envelope glycoprotein fitness defines virus population composition following transmission to a new host. *J Virol* 2012; **86**: 11956-11966 [PMID: 22855498 DOI: 10.1128/JVI.01079-12]

138 **Fafi-Kremer S**, Fofana I, Soulier E, Carolla P, Meuleman P, Leroux-Roels G, Patel AH, Cosset FL, Pessaux P, Doffoël M, Wolf P, Stoll-Keller F, Baumert TF. Viral entry and escape from antibody-mediated neutralization influence hepatitis C virus reinfection in liver transplantation. *J Exp Med* 2010; **207**: 2019-2031 [PMID: 20713596 DOI: 10.1084/jem.20090766]

139 **Bengsch B**, Seigel B, Ruhl M, Timm J, Kuntz M, Blum HE, Pircher H, Thimme R. Coexpression of PD-1, 2B4, CD160 and KLRG1 on exhausted HCV-specific CD8+ T cells is linked to antigen recognition and T cell differentiation. *PLoS Pathog* 2010; **6**: e1000947 [PMID: 20548953 DOI: 10.1371/journal.ppat.1000947]

140 **Rutebemberwa A**, Ray SC, Astemborski J, Levine J, Liu L, Dowd KA, Clute S, Wang C, Korman A, Sette A, Sidney J, Pardoll DM, Cox AL. High-programmed death-1 levels on hepatitis C virus-specific T cells during acute infection are associated with viral persistence and require preservation of cognate antigen during chronic infection. *J Immunol* 2008; **181**: 8215-8225 [PMID: 19050238]

141 **Kasprowicz V**, Schulze Zur Wiesch J, Kuntzen T, Nolan BE, Longworth S, Berical A, Blum J, McMahon C, Reyor LL, Elias N, Kwok WW, McGovern BG, Freeman G, Chung RT, Klenerman P, Lewis-Ximenez L, Walker BD, Allen TM, Kim AY, Lauer GM. High level of PD-1 expression on hepatitis C virus (HCV)-specific CD8+ and CD4+ T cells during acute HCV infection, irrespective of clinical outcome. *J Virol* 2008; **82**: 3154-3160 [PMID: 18160439 DOI: 10.1128/JVI.02474-07]

142 **McMahan RH**, Golden-Mason L, Nishimura MI, McMahon BJ, Kemper M, Allen TM, Gretch DR, Rosen HR. Tim-3 expression on PD-1+ HCV-specific human CTLs is associated with viral persistence, and its blockade restores hepatocyte-directed in vitro cytotoxicity. *J Clin Invest* 2010; **120**: 4546-4557 [PMID: 21084749 DOI: 10.1172/JCI43127]

143 **Golden-Mason L**, Palmer BE, Kassam N, Townshend-Bulson L, Livingston S, McMahon BJ, Castelblanco N, Kuchroo V, Gretch DR, Rosen HR. Negative immune regulator Tim-3 is overexpressed on T cells in hepatitis C virus infection and its blockade rescues dysfunctional CD4+ and CD8+ T cells. *J Virol* 2009; **83**: 9122-9130 [PMID: 19587053 DOI: 10.1128/JVI.00639-09]

144 **Belkaid Y**. Regulatory T cells and infection: a dangerous necessity. *Nat Rev Immunol* 2007; **7**: 875-888 [PMID: 17948021 DOI: 10.1038/nri2189]

145 **Sangro B**, Gomez-Martin C, de la Mata M, Iñarrairaegui M, Garralda E, Barrera P, Riezu-Boj JI, Larrea E, Alfaro C, Sarobe P, Lasarte JJ, Pérez-Gracia JL, Melero I, Prieto J. A clinical trial of CTLA-4 blockade with tremelimumab in patients with hepatocellular carcinoma and chronic hepatitis C. *J Hepatol* 2013; **59**: 81-88 [PMID: 23466307 DOI: 10.1016/j.jhep.2013.02.022]

146 **Fuller MJ**, Callendret B, Zhu B, Freeman GJ, Hasselschwert DL, Satterfield W, Sharpe AH, Dustin LB, Rice CM, Grakoui A, Ahmed R, Walker CM. Immunotherapy of chronic hepatitis C virus infection with antibodies against programmed cell death-1 (PD-1). *Proc Natl Acad Sci USA* 2013; **110**: 15001-15006 [PMID: 23980172 DOI: 10.1073/pnas.1312772110]

147 **Raziorrouh B**, Ulsenheimer A, Schraut W, Heeg M, Kurktschiev P, Zachoval R, Jung MC, Thimme R, Neumann-Haefelin C, Horster S, Wächtler M, Spannagl M, Haas J, Diepolder HM, Grüner NH. Inhibitory molecules that regulate expansion and restoration of HCV-specific CD4+ T cells in patients with chronic infection. *Gastroenterology* 2011; **141**: 1422-1431, 1431.e1-6 [PMID: 21763239 DOI: 10.1053/j.gastro.2011.07.004]

148 **Nellore A**, Fishman JA. NK cells, innate immunity and hepatitis C infection after liver transplantation. *Clin Infect Dis* 2011; **52**: 369-377 [PMID: 21217184 DOI: 10.1093/cid/ciq156]

149 **Leroux-Roels G**, Depla E, Hulstaert F, Tobback L, Dincq S, Desmet J, Desombere I, Maertens G. A candidate vaccine based on the hepatitis C E1 protein: tolerability and immunogenicity in healthy volunteers. *Vaccine* 2004; **22**: 3080-3086 [PMID: 15297058 DOI: 10.1016/j.vaccine.2004.02.002]

P- Reviewer: Irshad M, Lichtor T, Qiu HJ, Robaeys GKMM, Tabarkiewicz J
S- Editor: Ji FF **L- Editor**: A **E- Editor**: Liu SQ

World Journal of Hepatology

Submit a Manuscript: http://www.wjgnet.com/esps/
Help Desk: http://www.wjgnet.com/esps/helpdesk.aspx
DOI: 10.4254/wjh.v7.i1.7

World J Hepatol 2015 January 27; 7(1): 7-27
ISSN 1948-5182 (online)

TOPIC HIGHLIGHT

WJH 6th Anniversary Special Issues (1): Management of hepatocellular carcinoma

Management of hepatocellular carcinoma: Predictive value of immunohistochemical markers for postoperative survival

Zhao-Shan Niu, Xiao-Jun Niu, Mei Wang

Zhao-Shan Niu, Lab of Micromorphology, Medical College of Qingdao University, Qingdao 266071, Shandong Province, China
Xiao-Jun Niu, Clinical Medicine Specialty, Medical College of Qingdao University, Qingdao 266071, Shandong Province, China
Mei Wang, Institute of Education, the University of Reading, RG6 1HY Reading, United Kingdom
Author contributions: Niu ZS designed the review's objectives; Niu XJ and Wang M searched the literature for latest developments in the field; Niu ZS and Wang M were involved in reviewing the literature, writing and editing the manuscript.

Correspondence to: Zhao-Shan Niu, MD, Lab of Micromorphology, Medical College of Qingdao University, 308 Ningxia Road, Qingdao 266071, Shandong Province, China. niumiao1993@hotmail.com
Telephone: +86-532-83780012
Fax: +86-532-83780012
Received: July 22, 2014
Peer-review started: July 23, 2014
First decision: August 14, 2014
Revised: September 2, 2014
Accepted: November 7, 2014
Article in press: November 10, 2014
Published online: January 27, 2015

Abstract

Hepatocellular carcinoma (HCC) accounts for over 90% of all primary liver cancers. With an ever increasing incidence trend year by year, it has become the third most common cause of death from cancer worldwide. Hepatic resection is generally considered to be one of the most effective therapies for HCC patients, however, there is a high risk of recurrence in postoperative HCC. In clinical practice, there exists an urgent need for valid prognostic markers to identify patients with prognosis, hence the importance of studies on prognostic markers in improving the prediction of HCC prognosis. This review focuses on the most promising immunohistochemical prognostic markers in predicting the postoperative survival of HCC patients.

Key words: Hepatocellular carcinoma; Management; Immunohistochemical; Prognostic marker; Predictive marker

Core tip: Hepatocellular carcinoma (HCC) is a leading cause of cancer-related death worldwide. Hepatic resection is generally considered to be one of the most effective therapies for HCC patients, however, the overall post-hepatic resection survival of HCC patients remains unsatisfactory as indicated by the high recurrence rate. Therefore, there is an urgent need to identify prognostic biomarkers for the prediction of postoperative recurrence or metastasis, and to develop better strategies for HCC management. The purpose of this paper is to review the most promising immunohistochemical prognostic markers so far for predicting the postoperative survival of HCC patients.

Niu ZS, Niu XJ, Wang M. Management of hepatocellular carcinoma: Predictive value of immunohistochemical markers for postoperative survival. *World J Hepatol* 2015; 7(1): 7-27 Available from: URL: http://www.wjgnet.com/1948-5182/full/v7/i1/7.htm DOI: http://dx.doi.org/10.4254/wjh.v7.i1.7

INTRODUCTION

Hepatocellular carcinoma (HCC) is a leading cause

of cancer-related death worldwide, with an increasing incidence[1]. The major risk factor associated with HCC is liver cirrhosis, which is predominantly caused by chronic B virus (HBV) and/or hepatitis C virus (HCV) infections, aflatoxin B1 exposure, and alcoholic liver disease. It is estimated that HBV and HCV account for approximately 75%-80% of HCC cases worldwide. In particular, chronic HBV infection is a predominant risk factor for HCC in Asia and Africa[2]. Hepatic resection (HR) is a potentially curative and popular therapy for HCC patients[3], however, the postoperative outcome remains unsatisfactory, with a 5-year post-HR recurrence rate of approximately 80%[4,5]. In fact, the high postoperative incidence of recurrence is the most frequent cause of postoperative death in HCC patients, and the main reason for the low postoperative survival rate is either intrahepatic metastasis or metachronous multicentric HCC[6].

So far, it has been still difficult to predict the probability of HCC metastasis and post-HR recurrence. There have been many studies on the risk factors contributing to post-HR recurrence of HCC where a number of prognostic factors related to clinicopathological parameters of HCC have been considered, including tumor size, stage, and grade. Due to lack of a systemic/uniformed approach, these researches results are not consistent. More investigations are required in the search for better markers for HCC prognosis, as a better prediction of postoperative recurrence or metastasis ultimately helps develop better strategies for HCC management.

Immunohistochemistry (IHC) is the most widely applied pathological technique in determining the expression status of tumor-associated proteins and in studying the prognostic and clinical relevance of biomarkers[7-9]. In spite of the paramount importance of IHC in determining the utility of a biomarker in clinical practice, the lack of universally accepted standardization guidelines has rendered the translation of promising biomarkers into clinical application. Having elaborated on nearly all the promising biomarkers so far in the main body of this review, we will discuss in conclusion the various limitations and technical challenges that need to be addressed when validating *via* IHC a predictive biomarker for clinical endpoint. More specific to HCC, although many immunohistochemical markers have been reported to have a prognostic value for HCC patients, some of which are also validated as independent prognostic markers, so far, there has been no consensus on how these markers could add prognostic value to the clinical parameters. An ideal IHC biomarker for HCC needs to be repeatable, with strong localized staining, valid across a number of patient groups and HCC subtypes, easily quantifiable, and associated with clear clinical outcome measures. Based on our extensive review of relevant literature (Table 1), this review intends to find out why no immunohistochemical markers are applicable in clinical practice, and focuses on the most promising immunohistochemical markers among existing ones in predicting the postoperative survival of HCC patients.

TUMOR SUPPRESSORS

Tumor suppressor p53

Alteration of p53 is one of the most frequent genetic changes found in HCC, and the biological function of p53 in tumor initiation and progression has been well characterized[10]. Numerous studies have investigated the prognostic value of p53 protein expression in HCC patients, but reports on the prognostic significance of p53 protein in HCC are often inconsistent and even conflicting, making it difficult to assess the clinical benefit of p53. So far, many studies have demonstrated that p53 protein expression is closely related to the occurrence, progression, metastasis, and survival of HCC. The over-expression of p53 protein is not only closely related to clinicopathological parameters, such as poorly-differentiated HCC, advanced HCC stages[11,12], but also to microvascular invasion, portal vein invasion, and high risk of tumor recurrence, and overall survival (OS) as well as recurrence-free survival (RFS) post-HR[13-16], especially within the first year post-HR in HCC patients[17]. Collectively, these findings indicate that the presence of p53 over-expression in HCC is identified as a major risk factor associated with the aggressive behavior of tumor, as well as a significant predictive marker for postoperative recurrence and survival in HCC patients[18].

Nevertheless, in some reports with either univariate or multivariate analysis, p53 protein expression in HCC has not been found to be an independent prognostic indicator of survival, despite that the over-expression of p53 protein is more frequent in tumors with poor cellular differentiation[19], > 5 cm in diameter[20], and vascular invasion[21]. Having said that, tumor differentiation and tumor size ⩾ 5 cm and vascular invasion are reported to be at high risk of HCC recurrence postoperatively[22-24], and they are independent poor prognostic factors for OS and disease free survival (DFS) in post-HR HCC patients[25,26]. These findings indicate that p53 expression in HCC may serve as a marker of a more aggressive behavior, and it could have an indirect adverse impact on survival.

Aiming at establishing whether those conclusions could provide solid grounds for applying p53 protein into prognostic clinical practice, the authors of this review carefully studied and compared the included studies. To our surprise, we have noticed several drawbacks in those studies that may affect the reliability of their own conclusions.

To begin with, variation in the immunohistochemical methods with respect to specific antibody clones, dilutions, antigen retrieval methods, as well as the cut-off values for positive expression, could have significant impact on the analysis of the prognostic value of p53 detection in HCC. Most studies used the monoclonal DO-7 antibody, with dilution ranging from 1:50 to 1:100, and citrate buffer for antigen retrieval, neither of which seems to have

Table 1 Immunohistochemical markers of hepatocellular carcinoma associated with prognosis in this review

Marker	Association with poor prognosis	Quoted literature examples
Tumor suppressors		
Mutant *p53*	Increased expression	Schöniger-Hekele *et al*[18]
Proliferation associated proteins		
Ki67 (detected by Mib1)	Increased expression	Schmilovitz-Weiss *et al*[40]
Proteins associated with angiogenesis		
CD105	Increased microvessel density	Yao *et al*[57]
Proteins involved in angiogenesis		Tseng *et al*[11]
VEGF	Increased expression	
MMPs (matrix metalloproteinases)		
MMP-2 and MMP-9	Increased expression	Xiang *et al*[74]; Nanashima *et al*[48]
Molecules involved in cell adhesion		
E-Cadherin	Decreased expression	Cho *et al*[94]
CD44 (CD44s and CD44v6)	Increased expression	Ryu *et al*[112]; Endo K *et al*[113]
OPN	Increased expression	Huang *et al*[130]
Cell cycle regulators		
p27 (Kip1)	Decreased expression	Wan *et al*[137]
DNA-binding nuclear protein		
HMGB1	Increased expression	Xiao *et al*[171]
Cancer stem cells		
CD133	Increased expression	Chan *et al*[188]
EpCAM	Increased expression	Chan *et al*[188]
CK19	Increased expression	Xu *et al*[197]
Cell surface proteins		
GPC3	Increased expression	Fu *et al*[211]
mTOR Pathway	Increased expression	Baba *et al*[223]

VEGF: Vascular endothelial growth factor; MMP-2: Matrix metalloproteinases 2; CD44s: CD44 standard isoform; CD44v6: CD44 variant isoforms; OPN: Osteopontin; HMGB1: High-mobility group box 1 protein; EpCAM: Epithelial cell adhesion molecule; CK19: Cytokeratin19; GPC3: Glypican-3; mTOR: Mammalian target of rapamycin.

Table 2 p53 antibody used in different studies in this review

Ref.	Clone	Source	Dilution	Antigen retrieval	Cut-off value[1]
Tseng *et al*[11]	DO-7	DAKO	1:100	Citrate buffer	> 5% nuclear p53 staining
Hu *et al*[13]	DO-7	DAKO	1:1000	Citrate buffer	> 10% nuclear p53 staining
Kang *et al*[14]	DO-7	DAKO	1:100	Citrate buffer	> 5% nuclear p53 staining
Stroescu *et al*[16]	DO-7	DAKO	Not reported	Citrate buffer	< 24% nuclear p53 staining
Sung *et al*[17]	Bp53-12	Zymed	1:80	Citrate buffer	> 5% nuclear p53 staining
Qin *et al*[19]	DO-7	DAKO	Not reported	Citrate buffer	≥ 10% nuclear p53 staining
Guo *et al*[20]	CM1	SDC	1:2000	Citrate buffer	> 5% nuclear p53 staining
Umemura *et al*[21]	DO-7	DAKO	1:50	Citrate buffer	≥ 10% nuclear p53 staining

[1]Immunohistochemical cut-off value indicates the percentage of cells with p53 positively staining nuclei. DAKO: Dako Denmark A/S, Glostrup, Denmark; Zymed: Zymed Lab Inc, CA, United States; SDC: San Diego, CA, United States.

any impact on the association between p53 expression and prognosis. In the meantime, we have noticed that different researchers adopted different cut-off values for determining positive p53 expression without any explanation or justification, which has significantly affected the association between p53 expression and prognosis in HCC (Table 2). Since p53 protein expression as detected by IHC does not always reflect the presence of mutant p53 protein, the predictive value of p53 IHC in detecting *TP53* mutations is currently under debate. So far, an optimal threshold is yet to be defined.

In general, a cut-off value of > 10% p53 immunopositive cells appears to be predictive of *TP53* mutations in HCC[27].

What's more, some studies used retrospective analyses in small series of patients. Naturally, without sufficient resolution and reproducibility, it is unlikely to accurately predict disease progression by means of these study designs.

Furthermore, inappropriate proportion of important variables was included in some studies, such as tumor grade, tumor size, tumor stage. For example, too many cases for Edmondson-Steiner Grade Ⅰ, tumor-node-metastasis (TNM) stage Ⅰ, or tumors ≤ 5 cm in diameter were selected, which easily resulted in the comparatively low positive rate of p53. And the reliability of their conclusions suffers.

Finally, we have noticed that compared with HCV

Table 3 Clinicopathological parameters affecting the association between p53 expression and prognosis in this review (*n*)

Ref.	Number of patients	Positive rate (%)	HBsAg/HCVAb positive	Edmondson grade		TNM stage		Tumor size	
				Ⅰ + Ⅱ	Ⅲ + Ⅳ (1)	Ⅰ + Ⅱ	Ⅲ + Ⅳ	≤ 5 cm	> 5 cm
				Well/moderate/poor (2)					
Tseng *et al*[11]	113	37.1	79/34	84	29 (1)	54	59	Not reported	
Hu *et al*[13]	124	41.9	83/30	20/38/13 (2)		61	63	Not reported	
Kang *et al*[14]	83	96.4	59/8	27	56 (1)	Not reported		57	26
Stroescu *et al*[16]	47	68	40/0	19	28 (1)	Not reported		20	27
Sung *et al*[17]	105	19	82/6	78	27 (1)	Not reported		> 3 cm	52
Qin *et al*[19]	113	22	40/25	55	58 (1)	Not reported		48	55
Guo *et al*[20]	104	34.6	14/55	18/56/31 (2)		67	37	Not reported	
Umemura *et al*[21]	90	33.3	Not reported	65	25 (1)	Not reported		37	53

TNM: Tumor-node-metastasis; HBsAg: Hepatitis B surface antigen; HCVAb: Hepatitis C virus antibody.

infection, where HCCs were caused mainly by the synergistic effect of HBV infection and aflatoxin B1, studies are more likely to confirm the over-expression of p53 and its prognostic value in HCC (Table 3). This has been partly echoed by studies on the relationship between p53 and pathogenic factors. HBV infection and exposure to AFB1 have been demonstrated to induce the point mutation of p53 in HCC tissue[28], especially exposure to AFB1 can affect the over-expression of p53 in the development of HBV-associated HCC[29]. Other studies also reported p53 protein expression in HCC has racial and regional differences[30]. Therefore, there is a higher chance of reaching a more reliable conclusion on the prognostic value of p53 protein in HCC, researchers should consider HCC cases induced by the same or similar pathogenic factors.

The detection of p53 expression by using IHC has another noteworthy problem. The p53 protein expression as detected by IHC does not always reflect the mutation status of TP53, with one cause being that not all mutations always result in stable protein formation, and another being that some tumors may also express wild-type p53. Nevertheless, in fact, lack of standardized IHC may be partly responsible for the inconsistencies in frequency of *p53* mutations and p53 protein levels. TP53 most often has missense rather than truncating mutations, and IHC antibodies will always have difficulty in detecting proteins with a small number of missense amino acid substitutions. Therefore, the studies with high p53 expression by IHC may reflect both high wild-type and mutant *p53*. Given this, when determining p53 status in HCC, we should analyze it by standardized IHC in combination with *p53* mutation analysis.

In conclusion, p53 protein expression comes short to be recommended as a universal predictive marker for survival in HCC patients, speaking from the available evidence. The prognostic value of p53 protein expression in HCC may vary according to different racial and regional groups. In area where HBV infection and AFB1 account for the major attributive risk of HCC, such as western Africa and south-east China, p53 protein tends to be high expression, and could be considered as a predictive marker for survival in HCC patients. Nevertheless, in order to identify the actual prognostic value of p53 expression in HCC, further studies are required by standardized IHC with larger populations, uniform pathological samples, homogeneous patient populations. It is also worthwhile to point out that it would help us lead to a sound conclusion the studies should include a > 10% nuclear staining as a cut-off value of p53 expression.

Due to the diversity and complexity in the research conclusions on p53, Tables 2 and 3 have been created to help with understanding. These two tables are of reference value in the following discussions on the rest of markers in this review, and hence will not be repeated.

PROLIFERATION MARKERS

The proliferative activity of tumor cells is an important indicator for assessing aggressiveness and could be useful for predicting clinicopathological and prognostic significance. Many antigens, such as proliferating cell nuclear antigen (PCNA) and Ki-67, have been used as proliferation markers for cancer cells. Compared with assessments by Ki-67, cell growth fraction is often overestimated when assessed by PCNA. Thus Ki-67 is considered a more accurate marker for the proliferative stage of tumor cells than PCNA[31,32].

Ki67

Ki-67 is a nuclear non-histone protein initially expressed in cell-cycle phases G_1, S, G_2 and mitosis, and absent in the G_0 phase. The expression of the Ki-67 protein in humans is closely associated with cell proliferation. Naturally, Ki-67 is an excellent marker for proliferating cells[33]. MIB-1 is a monoclonal antibody that identifies Ki-67 protein in paraffin-embedded tissue. Numerous studies have shown that Ki-67 immunohistochemical staining is an effective method to predict prognosis in various tumors.

Ki-67 expression is significantly associated with histological grade of HCC patients[34,35], in other words, the increased expression of Ki-67 in poorly differentiated tissues implies that the single fact of tumor cells losing growth control in hepatocarcinogenesis is a reflection of malignant behavior of tumor cells. Therefore, Ki-67

is an objective indicator of the proliferative ability of HCC cells, and can serve as an important index of the proliferation and differentiation of HCC cells. In addition, Ki-67 expression is significantly higher in HCC cases with shorter DFS; The same applies to the HCC cases with biologically aggressive features such as advanced stages, portal invasion and intra-hepatic metastasis[36]. Therefore, Ki-67 expression could serve as a useful marker for evaluating the progressive activity and predicting DFS in HCC patients. Furthermore, multivariate analysis shows that Ki-67 expression is an independent prognostic factor for DFS and OS[35]. Hence it's been concluded that the expression of Ki-67 is an independent prognostic indicator for post-HR HCC patients[37-40].

In short, Ki-67 expression is an objective factor for predicting survival for post-HR HCC patients, and it could be considered a promising independent prognostic immunohistochemical marker in HCC patients. Therefore, Ki-67 should be taken into consideration when making decisions on adjuvant therapy. HCC patients with high expression of Ki-67 protein may need intensive surveillance and adjuvant therapy.

In spite of the above discussions, lack of standardized IHC and cut-off value has hindered Ki-67 from routine clinical application. Different studies use different methods of antigen retrieval, antibodies concentrations; In addition, the time of incubation varies from study to study; as to cut-off value, some studies have chosen median values while others an arbitrary value (*e.g.*, 10%, 20% and so on) without any explanation or justification. All of these significantly influence the final results. Ironically, the choice of the cut-off value has a major impact on clinical practice, simply because it determines which patients are classified as "high Ki-67 expression"- those who in turn have a poorer prognosis should generally receive more aggressive therapy. We believe future researchers should work towards a standardized IHC and validated cut-off level before Ki-67 could be established as a reproducible and robust prognostic factor in HCC.

To throw in some light, a study has demonstrated that when determining the clinically relevant threshold for immunohistochemical tumor positivity, receiver operating characteristic (ROC) curve analysis could be a reproducible and reliable alternative in selecting and validating cut-off scores[41]. The term "ROC" came from tests of the ability of World War II radar operators to determine whether a blip on the radar screen represented an object (signal) or noise. At present, ROC curve analysis is a well established analytic tool and has been widely applied in various fields, including Medicine. Applications in a number of cancers have proved that cut-off scores based on ROC curve analysis guarantee maximum sensitivity and specificity, and therefore allow the greatest number of tumors to be correctly classified as carrying or not carrying the clinical outcomes[42,43].

Therefore, we propose that Ki-67 cut-off value should be set up according to ROC curve analysis.

MARKERS OF ANGIOGENESIS

Markers of Microvascular Density

Angiogenesis is critical for the growth, invasion and metastasis of cancers. Microvascular density (MVD) is commonly used to assess tumor neovascularization. This is especially true in HCC, characteristically a highly vascular tumor. However, there are conflicting reports in regard to whether MVD in HCC is associated with prognosis. This could be explained by the fact that different studies use different antibodies to calculate MVD.

The evaluation of MVD is generally identified by immunohistochemical staining of endothelial cells with the so-called pan-endothelial cell markers, such as CD34, CD31, and von Willebrand factor. Among them: Firstly, MVD appears to be better assessed by CD31 than by von Willebrand factor (vWF)[44]. Secondly, antibody against CD31 fails to stain sinusoid endothelial cells in many HCC cases, therefore the prognostic value of CD31 could at most be used as a marker of vascular changes in the liver[45]. Thirdly, although CD34 has proven to be a more sensitive and specific endothelial cell marker for microvessels in HCC[46], MVD determined by CD34 appears to be closely correlated with the prognosis of HCC[11,47] in some studies, while such correlation is not identified by others[48,49]. Differences in methodology, *i.e.*, different counting techniques, selection of microvessels, *etc.*, contribute to the conflicting results. The non-specificity in CD34 determines that CD34 can not be an ideal marker for neovascularization. In addition, all the above mentioned markers react with not only newly formed vessels but also normal vessels trapped within tumor tissues.

The conclusion is the MVD identified by anti-pan-endothelial antibodies is not an ideal prognostic marker[50].

The good news is MVD assessment using CD105 as marker (CD105-MVD) has demonstrated a higher MVD specificity in tumor tissues, and it has been more widely adopted, compared with vWF, CD31, or CD34[51-53], as a predictor for progression and prognosis in a variety of cancers.

Endoglin

Endoglin (CD105) is a transforming growth factor-β co-receptor mainly expressed in the endothelium of tissues' blood vessels, particularly in de novo formed blood vessels within tumor. It has been used as a marker for tumor angiogenesis, with a potential for prognostic prediction[54,55].

In HCC, some studies have demonstrated CD105 excels CD34 in marking new microvessels in HCC[56,57]. When median scores of MVD are used as cut-off points, patients with higher score of MVD-CD105 have a significantly poorer prognosis in either DFS or OS analysis, whereas similar prognostic significance of MVD-CD34 is

observed only in DFS analysis[57]. One study reveals that no prognostic significance is observed when median values are used as cut-off points using either IMVD-CD105 or IMVD-CD34, however, the presence of the diffuse pattern of CD105 expression in the adjacent non-tumorous liver tissues can predict a poorer DFS[58]. Collectively, compared with CD34-MVD, CD105-MVD is a significant and independent prognostic indicator for recurrence and metastasis in HCC patients. Having said that, some study found that MVD-CD105 did not show prognostic influence in a cohort of predominantly large HCCs (> 5 cm)[58]. Further studies need to be conducted in larger cohorts of patients with a longer follow-up period.

In summary, CD105, by specifically staining newly formed tumor vessels, is a promising and independent prognostic marker for HCC, which could in turn lead to future therapeutic trials with antiangiogenic therapy. To date, however, the lack of commonly accepted objective criteria in counting microvessels under light microscopy has hampered the clinical use of tumor MVD for prognostication. The authors of this review propose that, before other better microvessel counting methods have been established, microvessel counting should be performed in accordance with Weidner's standards[59].

MARKERS OF PROTEINS INVOLVED IN ANGIOGENESIS

Vascular endothelial growth factor

Angiogenesis is crucial for tumor growth and metastasis, and could be stimulated by several regulators, among which vascular endothelial growth factor (VEGF) seems to be most important[60]. The VEGF family comprises six glycoproteins: VEGF-A, VEGF-B, VEGF-C, VEGF-D, VEGF-E, and placental growth factor. These major VEGF subtypes are in the nature of multiple isoforms. The best representative of VEGF family is VEGF-A (commonly referred to as VEGF). VEGF mediates its angiogenic effects *via* several different receptors, including VEGFR1 and VEGFR2[61].

VEGF plays an important role in tumor angiogenesis and progression, including HCC, and elevated VEGF levels in serum and tissues are related to poor prognosis in HCC patients[62]. So far, numerous studies have explored and confirmed the prognostic value of VEGF for survival in HCC patients. Some studies found the VEGF over-expression was closely correlated with MVD, high alpha-fetoprotein levels, tumor size, dedifferentiation, advanced TNM stage, vascular invasion, capsular invasion, intrahepatic metastasis, and lymph node metastasis (LNM)[63,64]. These findings suggested that VEGF over-expression was useful in predicting progression, metastasis, and recurrence of post-HR HCC[65,66]. In addition, survival analyses indicated that VEGF over-expression was an independent factor for poor-prognosis DFS and OS[11]. Therefore, VEGF expression in HCC tissues could be regarded as a valuable indicator in estimating prognosis of HCC patients[20].

More recent studies suggested that co-expression of platelet-derived growth factor receptors-α, PDGFR-β and VEGF could be considered an independent prognostic biomarker for predicting DFS and OS in HCC patients, and that this co-expression could be used to identify patients at a higher risk of tumor recurrence and poor prognosis, and to select therapeutic schemes for HCC treatment[67]. In addition, the co-index [VEGF/platelet-derived endothelial cell growth factor (PD-ECGF)] was an independent prognostic factor for OS and RFS; Furthermore, the co-index of VEGF and PD-ECGF was a promising independent predictor for recurrence and survival of alpha-fetoprotein (AFP)-negative HCC patients after curative resection[68].

In spite of all the research efforts in establishing VEGF expression status as a promising prognostic marker, there is still a long way to go before the findings could have any impact on clinical practice.

Metalloproteinase

Matrix metalloproteinases (MMPs) comprise a large family of zinc- and calcium-dependent proteolytic enzymes that have been repeatedly implicated in invasion and metastasis. MMPs are capable of degrading most components of the extracellular matrix (ECM), including the basement membrane which serves as a barrier between tissue compartments[69]. Type Ⅳ collagen (Col Ⅳ) is a major component of the ECM and basement membrane, and plays an important role in regulating and limiting tumor invasion and metastasis[70]. Among MMPs, MMP-2 (gelatinase A) and MMP-9 (gelatinase B) are of particular importance as far as tumor invasion and metastasis are concerned, because they are capable of degrading ColⅣ[71,72]. Furthermore, high MMP-2 or MMP-9 expression in tumor or stromal cells might serve as a poor-prognosis predictor in various cancers[72,73]. This applies to HCC according to some researches.

MMP-2: Quite a few researches concluded that high intratumoral MMP-2 expression in HCC was correlated with high Edmondson grade, advanced TNM stage, and barcelona clinic liver cancer stage[66,74], and that MMP-2 was related to HCC invasion, metastasis and recurrence[75]. As a result of these research findings, it is widely acknowledged that MMP-2 expression could serve as a predictive marker for HCC progression, metastasis, and recurrence, and that MMP-2 expression is an independent prognostic factor for DFS and OS in HCC patients with LNM[74].

MMP-9: The expression of MMP-9 in HCC was proved by a number of researches to be closely correlated to tumor nodule, vein invasion, advanced TNM stage, extrahepatic metastasis, and the formation of portal vein tumor thrombus[48,76,77]. These researches suggest that the expression of MMP-9 reflects the biologically aggressive behavior of HCC, and that MMP-9 is an important molecule which participates in the progression,

metastasis and invasion of HCC. Some studies demonstrated that MMP-9 expression was up-regulated in HBV-associated HCC compared with HCV-associated HCC[78]. Other studies concluded that MMP-9 expression was a significant predictive factor for post-HR recurrence in HCC patients with the background of HBV[79]. Still other studies found that increased expression of MMP-9 protein was an independent prognostic factor after HCC resection[48].

It is worthwhile to note that, when both MMP-2 and MMP-9 were analyzed in the same set of patients, MMP-2 was predominantly involved in hepatocarcinogenesis and progression, while MMP-9 was predominantly involved in the capsular infiltration and portal vein invasion[80]; and that the MMP-2 expression only had weak correlations to HCC recurrence, while positive MMP-9 expression was an independent recurrence-risk factor[25]. Moreover, multivariate analysis confirmed that MMP-9 expression was an independent predictor of time to recurrence (TTR) and OS, whereas high MMP-2 expression was only correlated with TTR[81]. This suggests that MMP-9 is superior to MMP-2 in predicting tumor recurrence and survival in post-HR HCC patients.

One study concluded that high expression of MMP-9 and MMP-2 in peritumoral stromal cells was related to poorer prognosis in HCC patients[82]; However, this was overturned by another study[83]. Still, one study found that MMP-2 or MMP-9 expression was not related with the histological differentiation of HCC[84]; And yet another study claimed that MMP-2 and MMP-9 protein could serve as independent prognostic factors for poor survival regardless of the age, tumor size, tumor grades, TNM classification[85].

The question is: What has contributed to the discrepancies in those research findings? It could be a long list that includes the differences in pathological samples, antibodies used, different IHC methods, different patient populations and different cut-off values. It is advisable that further studies enroll larger scale of clinical HCC samples and use standardized IHC. This has an add-on value of ultimately benefiting the clinical application of MMP inhibitors as chemopreventive and antiangiogenetic drugs.

ADHESION MOLECULES

E-cadherin

Tumor progression is characterized by loss of cell adhesion and increase of invasion and metastasis. Cell adhesion molecules play a significant role in cancer progression and metastasis[86]. E-cadherin is a key molecule for the maintenance of intracellular adhesion, and down-regulation of this protein has been associated with tumor progression in diverse human cancer types[87,88].

Many researches have concluded that E-cadherin expression is very weak in HCC tumors but very strong in the cell membranes of non-tumor tissues, and E-cadherin expression is significantly correlated inversely with histological grade, *i.e.*, with the highest in well-differentiated[89] as put in one study, or the increased loss of E-cadherin expression is observed particularly in poorly-differentiated[90] as put in another; In addition, low expression of E-cadherin in HCC is also related to pathological stage and later TNM stage[91]. Therefore, it is safe to say that low expression of E-cadherin is a strong indicator of malignant HCC progression. There are also some researches that suggest low expression of E-cadherin is significantly associated with intrahepatic metastasis and regional lymph node metastasis[92,93]. When you combine the findings of these two types of researches, it seems natural to conclude that loss of E-cadherin expression in HCC could predict a high risk of post-HR recurrence[94]. Taken together, these findings indicate that detection of E-cadhein expression could be useful in predicting HCC prognosis.

On the opposite side, two studies revealed low expression of E-cadherin had no direct correlation with the post-HR recurrence[95], and it did not predict poor survival even when there was increased loss of E-cadherin in tumors of higher histologic grade[96]. The researchers themselves admitted insufficient number of and lack of homogeneity in the included patients could have contributed to the opposite findings[95]. Another two studies confirmed atypical cytosolic expression of E-cadherin or high E-cadherin membrane/cytoplasm ratio was correlated with a poorer patient prognosis[97,98].

Decreased expression of E-cadherin has been found in all three types of epithelial-mesenchymal transition (EMT) and is thought to be the prototypical marker of EMT[99]. EMT has been shown to be a pivotal mechanism contributing to cancer invasion and metastasis, as epithelial cells lose their polarity and acquire the migratory properties of mesenchymal cells. The characteristic changes during EMT include the downregulation of epithelial markers such as E-cadherin and the upregulation of mesenchymal markers such as vimentin[100]. The EMT of HCC cells is thought to be a key event in intrahepatic dissemination and distal metastasis[101]. A recent study suggests that the loss of E-cadherin followed by the overexpression of vimentin may play a vital role in the invasive and metastatic phenotype and in the process of EMT, leading to unfavorable outcomes in patients with HCC[102].

The authors of this review carefully studied all the related articles, in the course of which differences in antibodies, cut-off values, or race stood out. Further investigation is necessary for assessing these discrepancies.

CD44

CD44, is a transmembrane glycoprotein and has been implicated in numerous biological processes, including cell-cell interactions, cell adhesion, and cell migration[103]. Through alternative mRNA splicing, cells produce numerous CD44 protein isoforms: standard isoform (CD44s) and variant isoforms (CD44v). CD44s is a cell adhesion molecule known for mediating cellular adhesion

to the extracellular matrix-a prerequisite for tumor cell migration. Some researchers argue CD44s is involved in invasion and metastasis of various cancers[104]. Among the CD44 variant isoforms, CD44v6 has reportedly been associated with increased invasion, metastasis, and poor prognosis[105,106]. Recent studies also suggest CD44 is one of the cancer stem cell markers associated with poor prognosis[107].

CD44s: Many studies have indicated that high CD44s expression in HCC is correlated with high AFP level, large tumor size, multiple tumors, poor tumor differentiation, advanced tumor stage, portal vein tumor thrombus, and early tumor recurrence or metastasis[108-110]. These findings suggest that CD44s expression may serve as a predictive marker for HCC progression, metastasis, and recurrence. However, it is not always the case. For example, one study found that there was a significant correlation between CD44s expression and the presence of vascular invasion, but not between CD44s expression and tumor grade, from which the author concluded that high CD44s expression may have implications relating to metastasis and prognosis in HCC patients[111]. Another study found that statistically Edmondson grades had a significant correlation with CD44s expression, and yet such correlation did not exist between CD44s expression and vascular invasion, from which the conclusion is CD44s expression was significantly correlated with DFS and independent factor in multivariate analysis[112].

Some other studies suggested either high CD44s expression was a poor prognostic factor following curative HR of primary HCC, including reduced DFS and OS[108,109], or high CD44s expression was an independent factor for OS[113]. One study failed to present a significant correlation between patient survival and CD44s expression, however , it did show expression of CD44s as a significant predictable marker for LNM[110].

The inconsistency in CD44s expression and clinicopathological parameters is obvious, however, all relevant studies endorse that CD44s expression could serve as a predictive marker for HCC metastasis and survival.

CD44v6: Some studies suggest that high expression of CD44v6 is related to aggressive clinical behavior in HCC, more specifically it is correlated with high tumor grades, advanced TNM stage[114,115]; In addition, CD44v6 overexpression presents a positive correlation with HCC metastatic potential[116]. These findings indicate that high expression of CD44v6 may serve as a predictive marker for HCC progression and metastasis. As to its relationship with vascular invasion, some studies concluded that high CD44v6 expression significantly correlated with the presence of vascular invasion[113,115], while one study demonstrated that a low expression level of CD44v6 tended to be associated with vascular invasion[117]. These studies adopted different scoring systems and cut-off values, which could have contributed to the discrepancy in the results.

In multivariate survival analysis, some studies demonstrated high expression of CD44v6 was significantly correlated with OS and TTR[115], or that it was an independent factor for OS[113]. Thus, detection of CD44v6 expression could be useful in predicting prognosis of HCC.

The authors of this review would tentatively recommend that, for CD44v6 expression evaluation, cut-off value be selected on the basis of ROC curve analysis. In addition to a valid cut-off value, future studies should consider a larger sample and a longer follow-up period. Only then could relevant studies add clinical value to CD44v6 expression in HCC.

Osteopontin

Osteopontin (OPN) is a multifunctional secrete phosphorylated glycoprotein that belongs to the small integrin-binding ligand N-linked glycoprotein family, and it is implicated in promoting malignant cell proliferation, detachment, invasive and metastatic progression of many carcinomas[118-120]. The expression level of OPN is elevated in a variety of human cancers, particularly those that metastasize preferentially to the skeleton[121]. Recent studies have indicated that OPN is involved in HCC progression and metastasis.

It is widely acknowledged that OPN expression is localized predominantly in the cytoplasm, and OPN expression in HCC is stronger than those in paracarcinoma tissues and normal liver tissues[122]; And that higher expression of OPN in HCC is closely associated with poor differentiation and advanced tumor stage[123,124]; And that it is positively correlated with tumor size, capsular invasion, portal vein tumor thrombus, lymph node metastasis[122,125,126]. Therefore, it is safe to say OPN could serve as novel biomarker for monitoring HCC progression and metastasis.

In addition, numerous studies have suggested OPN could serve as a useful marker for predicting early recurrence in HCC patients[122,127], and that OPN could help determine whether individual patient needs adjuvant therapy to prevent early post-HR recurrence[128], and that OPN expression is an independent prognostic factor either for DFS in HBV-positive small HCC (< 5 cm)[129], or for OS and DFS in patients with the TNM stage I HCC[127]. These findings suggest that OPN could be solely identified as an independent prognostic biomarker for post-HR HCC patients[130].

Recent studies have suggested that the combination of OPN and some other markers seem promising for HCC prognosis. For example, the combinations of tumor OPN with either caspase-3, or Bcl-2, or CD44, have all been announced as promising independent predictors of tumor recurrence and survival in HCC patients[130,131]; It is especially true for those with early-stage disease when tumor OPN is combined with microenvironment-associated peritumoral macrophages[132]. Nevertheless, the interaction between tumor OPN and these markers, which facilitates tumor progression and metastasis, still

remains unclear in clinical practice. Further large-scale studies are required to confirm their clinical value[133].

CELL CYCLE REGULATORS

p27

The functional alterations of cell-cycle regulators, such as Cyclin Dependent Kinases (CDK) and their inhibitors, occur frequently in cancers. As a critical CDK inhibitor, p27 (Kip1) is involved in G1 phase progression, and is widely regarded as adverse prognostic biomarker for various types of cancers, since decreased or absent expression of p27 (Kip1) is frequently observed in various types of human cancers with poor prognoses[134,135]. It has been reported that p27 (Kip1) is exclusively inactivated by proteasome-mediated protein degradation[136]. p27 (Kip1) is frequently inactivated in HCC and is considered a potent tumor suppressor.

So far, many studies have reported that decreased p27 expression is significantly lower in HCC than those in the adjacent noncancerous tissues or in normal liver tissues, and it is a risk factor in HCC[137-139]. Furthermore, some studies have indicated decreased p27 expression is closely related to the aggressive HCC tumor behaviors[139,140]. In addition, some studies indicated that p27 expression was decreased in advanced cases in a series of curatively resected HCCs[141], and the p27 labeling index was significantly decreased in the cases with advanced tumor stages, portal invasion, poor differentiation, larger size, and intrahepatic metastasis[142,143]. As concluded by a researcher, p27 expression in HCC could act as an independent predictor of post-HR recurrence[142].

It has been reported that in multivariate analysis, p27 expression could be recognized as an independent prognostic marker for OS[144], and OS and loco-regional recurrence-free[145], which suggests low expression level of p27 is associated with significantly worse prognosis in HCC patients[137,146]. Similar findings have been reported that high expression of p27 is a favorable independent prognostic parameter[147]. Taken together, p27 could be regarded as a powerful clinical indicator for prognosis prediction in individual HCC patient.

An interesting point is that it is in both nucleus and cytoplasm that tumor cells were found to have expressed p27 protein[148]. The significance of cytoplasmic p27 protein is still under debate, and cytoplasmic p27 protein is rarely considered in assessing p27 IHC score. Decreased or absent expression of p27 (Kip1) in nucleus is frequently observed in various types of human cancers with poor prognoses[149-153]; however, some researchers argue over-expression of cytoplasmic p27 may also serve as a marker for poor prognosis in several types of human cancers[154-156]. Further studies suggest that the nuclear localization of p27 is essential for its growth-inhibiting function[157]. When narrowing down to HCC, the expression of p27 is mainly found in nucleus and cytoplasm[144]. It has been generally accepted that low expression of nuclear p27 protein is associated with poorer prognosis, while cytoplasmic expression of p27 is positively associated with poor cellular differentiation-the higher the expression, the higher incidence in HCC patients[140]. This is echoed by a study that concluded cytoplasmic localization of p27 could be an early event during hepatocarcinogenesis[158].

It remains unclear whether the cytoplasmic staining represents a methodological artifact or a finding of biological and/or prognostic importance. In view of this uncertainty, the authors of this review propose that only nuclear p27 (kip-1) staining for HCC survival analyses be considered in staining evaluation.

Taken together, IHC detection of p27 on routine tissue sections could be useful in predicting survival of individual HCC patient and in determining future therapeutic strategies. Therefore, p27 is worthy of further evaluation as a potential prognostic marker in clinical trial samples of large cohorts.

DNA-BINDING NUCLEAR PROTEIN

High-mobility group box 1 protein

High-mobility group box (HMGB) proteins are non-histone nuclear proteins with different functions in the cell[159]. HMGB1, HMGB2, and HMGB3 are the members of the HMGB protein family, with HMGB1 being the most important one. While the expressions of HMGB2 and HMGB3 are limited, HMGB1 plays a role in cancer progression, angiogenesis, invasion, and metastasis development[160]. The function of HMGB1 is complicated by its cellular localization. In nucleus, HMGB1 binds with DNA and serves as a structural component[161]. Cytoplasmic localization of HMGB1 is associated with the proliferation and metastasis of different tumor types. The process could be dramatically sped up when cytoplasmic localization of HMGB1 binds with the receptor for advanced glycation end products[162]. As for the "sped up" process, one study has deduced that the interaction between receptor for advanced glycan endproducts and HMGB1 activates mitogen-activated protein kinases, nuclear factor kappa B, and phosphoinositide 3-kinases (PI3K)/AKT signaling pathways to promote cellular proliferation and metastasis[163].

There are many relevant studies that focus on HCC and their findings include: In HCC cells, downregulation of HMGB1 could remarkably inhibit the growth of HCCLM3 cells, as well as their migration and invasion ability[164]; HMGB1 knockdown inhibited the proliferative activities and metastatic potential of SMMC-7721 cells. That is to say, the expression of HMGB1 was closely correlated with pathological grade and distant metastases of liver cancer, and HMGB1 knockdown inhibited liver cancer growth and metastasis[165]. In addition, HMGB1-siRNA could inhibit the invasion and migration abilities of human hepatoma cell line HepG2[166]. In the liver tumor model, stable knockdown of HMGB1 suppressed HCC invasion and metastasis[167]. In detection of serum

HMGB1, serum HMGB1 was positively correlated with clinicopathological features in HCC patients, higher serum HMGB1 level was correlated with bigger tumor size, poor Edmondson grade and advanced TNM stage[168]. Collectively, these findings suggest that HMGB1 in HCC is significant in tumor progression, invasion and metastasis.

In recent years, many studies have explored the clinical significance of HMGB1 expression in various human tumors, including HCC. Some study reported that over-expression of HMGB1 was significantly associated with HCC incomplete encapsulation and advanced TNM stage[169]; similarly, another study demonstrated that, by detecting fresh samples, over-expression of MGB1 mRNA was correlated with HCC high Edmondson grade, advanced TNM stage, vascular invasion and capsule invasion[170]. These findings indicate that over-expression of HMGB1 is associated with HCC tumor growth and invasion.

Recent studies have also demonstrated the expression of HMGB1 could serve as an independent prognostic factor for poor OS and DFS for post-HR HCC patients; more importantly, subgroup analysis showed the expression of HMGB1 was significantly associated with poor prognosis in HCC patients > 5 cm, but not in HCC patients ≤ 5 cm[169]. This trend suggests that HMGB1 could be an important prognostic marker for late stage HCC; in addition, multivariate analysis has also concluded that HMGB1 expression is a key independent prognostic factor that could be associated with OS of HCC patients[171]. Therefore, HMGB1 expression could be taken as an independent predictor of prognosis for post-HR HCC patients. However, further studies are necessary before we could tell for sure whether HMGB1 is a reliable clinical predictor of survival for individual post-HR HCC patient.

STEM CELL MARKERS

In recent years, many findings have suggested that tumors are comprised of heterogeneous cell populations, only a small fraction of which are tumorigenic with the ability to self-renew and produce phenotypically diverse tumor cell populations[172]. Cells in this fraction are called cancer stem cells (CSCs) or tumor-initiating cells or cancer progenitor cells, and they have the ability to self-renew, proliferate, and maintain the neoplastic clone. Accumulating evidence has shown that these CSCs have long-term proliferative potential and the ability to regenerate tumors with phenotypically heterogeneous cell types, and that these CSCs are important mediators of tumor metastasis and cancer relapse[173].

So far, various cell surface and transmembrane proteins expressed by CSCs have been identified, including CD44, CD47, CD123, epithelial cell adhesive molecule (EpCAM) (CD326), CD133[174]. In HCC, the three major types of liver CSCs (LCSCs) are dedifferentiated hepatocytes, hepatic oval cells, and bone marrow cells. To date, CD133, CD90, and EpCAM, CD44, CD24, and CD13 have been identified as specific antigenic markers for HCC stem cells[175]; The oval cell-specific marker (OV6) is identified as a marker for hepatic oval cells[176], in addition, cytokeratin 7 (CK7) and CK19 are identified as markers for dedifferentiated hepatocytes[177].

LCSCs can be observed by IHC and electron microscope. In HCC, the phenotypes of LCSCs express as OV6, CK7, CK19, CD133 and EpCAM[178]. There have been a number of studies reporting that the expression of LCSCs markers in HCC is associated with poor clinical outcome after surgical resection[179,180]. Among them, the expression of EpCAM, CK19 and CD 133 has demonstrated association with intrahepatic recurrence in HCC patients[181].

To our knowledge, EpCAM, CK19, and CD 133 have been so far the most widely studied LCSCs markers in HCC using IHC.

CD133

Prominin 1 (CD133) is a pentaspan transmembrane glycoprotein with uncertain physiological function, and it is often expressed by various epithelial and non-epithelial cells, notably by stem and cancer stem cells. CD133 is currently recognized as a marker for LCSCs[182-184]. A number of studies have demonstrated *via* IHC that CD133 expression is associated with poorer tumor grade and advanced tumor stage[185]; Moreover, CD133 expression is associated with the absence of tumor capsule; and CD133 tends to be expressed in tumors showing stronger potential for invasion and metastasis[186]. These findings suggest that CD133 expression is associated with HCC progression, invasion and metastasis. In addition, several studies have demonstrated that CD133 expression is a significant risk factor for the OS of HCC patients, especially patients with Stage Ⅲ and ⅣA HCC[187]; And that Cox proportional hazard model has shown that CD133 expression is an independent predictor for DFS[177]; and the multivariate survival analysis has demonstrated that CD133 expression is an independent adverse prognostic factor for OS and DFS, especially for patients with early-stage HCC[188]. All the above mentioned studies agree to the basic point that increased CD133 expression could serve as an independent prognostic factor for survival in HCC patients.

EpCAM

EpCAM, also known as 17-1A, GA733-2, KSA, ESA, and EGP-40, is a type I transmembrane glycoprotein and acts as a homotypic calcium-independent cell adhesion molecule. It is expressed in almost all carcinomas. EpCAM is currently recognized as a marker for LCSCs[189-191]. Many studies have demonstrated *via* IHC that EpCAM expression is associated with younger age[181], poorer histological differentiation, vascular invasion and/or more advanced stage[180,188,192]. These findings suggest that EpCAM expression is associated with HCC progression. Furthermore, several studies have demonstrated that EpCAM expression could serve as an independent factor

for DFS in HCCs at all stages[188]; And the multivariate survival analysis has demonstrated that EpCAM expression is a significant predictor for shorter survival time in HCC patients[186], especially patients with T1 HCC[180]. Taken together, increased EpCAM expression could serve as an independent prognostic factor for survival in HCC patients.

CK19

CK19 has been considered as a marker for the biliary phenotype[193], and it is not expressed in normal hepatocytes[194]. CK19 is currently recognized as a marker for LCSCs[181,183,195,196]. Increased CK19 expression is correlated with high histological differentiation, advanced BCLC stage, TNM stage[197], tumor non-encapsulation[198], the presence of satellite lesions[74], number of tumor foci, and vascular tumor embolism[199]. These findings dictate that increased CK19 expression could serve as a new biomarker predicting HCC progression and recurrence. In addition, some studies have identified association between CK19 expression in HCC and increased vascular invasion, lymph node metastasis, and intrahepatic spread[200,201], dictating that CK19 expression is an independent risk factor for developing LNM, and that it is an important risk factor for early tumor recurrence. In addition, increased CK19 expression has also been found to be both an independent poor prognostic factor for OS, DFS, and RFS in post-HR HCC patients[74,197], and an independent prognostic factor for HCC with LNM[202]. However, other studies have come to a different conclusion. Some studies have demonstrated that CK19 is an independent prognosticator for OS, but not for DFS[194,199]. Still some studies have suggested that CK19 expression has prognostic significance for DFS, though CK19 fails to offer independent prognostic value[188].

Taken together, the expressions of CD133, EpCAM and CK19 could be readily assessed by IHC and they are clinically significant biomarkers for surgically resected HCCs. However, predictive values of single LCSCs markers remain controversial and further validation is required in independent cohorts ahead of any clinical utilization[203]. More importantly, because of high degree of HCC heterogeneity, the predictive range of a single marker is limited to a very small subpopulation. A combination of several LCSCs markers may provide greater specificity and reliability in predicting HCC prognosis[178].

CELL SURFACE PROTEINS

Glypican-3

Glypican-3 (GPC3) is an oncofetal protein considered as a relatively specific HCC biomarker that is not detectable in hepatic para-carcinomatous and cirrhotic tissues[204], and it is over-expressed in HCC using IHC[205,206]. Recently, much evidence has shown that GPC3 could be a useful tool to identify early HCC development. More recently, GPC3 has been reported to be a new prognostic factor after curative hepatectomy in HCC patients.

In addition to being a marker for HCC, GPC3 plays a role in the progression of the disease[207]. GPC3 expression has been less frequently observed in well-differentiated HCC than in moderately and poorly differentiated HCC[205,208,209]; furthermore, it has been found significantly correlated with serum AFP level, tumor number and presence of satellite nodules, and TNM stage[210,211]; in addition, GPC3 expression has also been found to be associated with postoperative metastasis/recurrence in HCC patients[129,208,212]. These findings indicate that GPC3 expression might be a valuable marker closely related with post-operative progression, metastasis/recurrence in HCC patients. Multivariate analysis has identified GPC3 expression as an independent prognostic factor for OS[129]. However, in other studies, for HCC patients with HCV infection in particular, the high membranous GPC3 immunoreactivity has been identified as an independent prognostic factor for DFS[213]; one study has even suggested that over-expression of GPC3 is an independent prognostic factor for DFS in HBV-positive small HCC (< 5 cm)[129]. Recently an extensive study has shown that high GPC3 expression is an independent risk factor for poor postoperative tumor recurrence, DFS, and OS[211], again suggesting that GPC3 expression is a potential and reliable biomarker for predicting tumor recurrence and OS in post-HR HCC patients.

Overall, these studies indicate that GPC3 expression has the potential to serve as a valuable predictive marker for survival in post-HR HCC patients. Further studies are required to confirm GPC3 is one of the reliable clinical predictors of survival for individual post-HR HCC patient.

MAMMALIAN TARGET OF RAPAMYCIN PATHWAY

Currently there is evidence suggesting that phospho-specific antibodies could serve as potential biomarkers for HCC. These markers provide useful reagents for analysis of signaling pathways in clinical samples, and therefore has the potential for actionable targets[214]. So far, the molecular biology of hepatocarcinogenesis and HCC progression has been widely investigated. Many studies have indicated that signaling pathways dysregulated in HCC are important steps towards understanding HCC pathogenesis and developing new therapeutic approaches. Over recent years, several molecular pathways have been identified contributing to the molecular pathogenesis of HCC, among which the mammalian target of rapamycin (mTOR) signaling pathway has been identified to play a critical role in the pathogenesis of HCC[215]. And many studies have investigated the relationship between mTOR pathway and HCC prognosis.

mTOR pathway, an important regulator of multiple cellular functions including proliferation, differentiation, tumorigenesis, and apoptosis, is up-regulated in many cancers[216]. Deregulation of the mTOR signaling pathway has been reported in many malignancies, and some of the

signaling molecules in this pathway could predict prognosis in different cancers. PI3K/AKT is considered a critical upstream mediator of the mTOR signaling pathway. Recent data from a genomic sequence of HCC samples identified mutations in PIK3CA, an upstream regulator of AKT, in 50% of patients with poor prognosis and survival length of < 3 years following partial liver resection, whereas only 10% of the HCC patients with a good prognosis had a mutation in PIK3CA[217]. Activation of AKT is a risk factor for early disease recurrence and poor prognosis in patients with HCC[218]. Activated AKT positively modulates mTOR function. mTOR is a key component of PI3K and AKT pathways that activate downstream kinases required for G1 to S phase transition[219]. mTOR acts by directly activating p70S6 kinase (p70S6K/S6K1) and inhibiting 4E binding protein 1 (4E-BP1)[220], both regulating the translation of important factors involved in cell proliferation (such as c-myc, cyclic D1 and pRb) and angiogenesis (such as HIF1-α)[221]. The p70S6 kinase and 4E-BP1 have shown to be independent predictors of prognosis in several types of solid tumors including liver[216,222,223]. Therefore, the expression of mTOR pathway could be used as prognostic indicator in HCC.

In addition, one study has indicated that c-Jun N-Terminal Protein Kinase 1 (JNK1) activation contributes to poorer HCC prognosis, and there is similarity in gene expression patterns between the HCC with abnormal mTOR signaling and JNK1 HCC[224], which further supports the assumption that HCCs with abnormal mTOR signaling are tumors of a highly aggressive nature and with poorer prognosis.

Recently, mTOR has emerged as an exciting target for cancer therapy including HCC. mTOR inhibitors have been tested successfully in clinical trials for their antineoplastic potency and good tolerability[225]. A second generation of mTOR pathway inhibitors has been utilized in preclinical HCC models[226] and the results suggest that mTOR inhibitors in HCC treatment could have a bright future.

Noticeably, although phospho-specific antibodies used in IHC are expected to detect phosphorylated proteins[227-229], some preanalytic variables (such as fixation technique and duration) may critically affect the signal[230], and in some cases these antibodies may also cross-react with nonphosphorylated proteins[231]. Therefore, it is of ultimate importance to standardize preanalytic variables and to employ a control in determining whether the staining pattern is specific.

CONCLUSION

In this review, we give an overview of the literature published on immunohistochemical prognostic markers in HCC. Out of 17 markers that have been investigated by ten groups (summarized in Table 1), there are twelve markers (over-expression of Ki67, VEGF, MMP-2, MMP-9, CD44s, CD44v6, OPN, HMGB1, CD133, EpCAM, CK19, GPC3 and mTOR pathway, and increased microvascular density of CD105) that have shown to be independent prognostic factors for survival in HCC patients. However, studies on some markers, such as p53, E-cadherin and p27, have all reported inconsistent results. Lack of standardized IHC has contributed to these discrepancies; other possible contributors include small sample sizes, pathological differences in samples, heterogeneous patient populations, various follow-up periods of the patients, and different racial and regional groups.

So far, numerous investigations have demonstrated many immunohistochemical markers could be potential prognostic/predictive indicators of HCC. However, their clinical utilization is severely hindered by the lack of standardized IHC methodology.

Although IHC is the most widely applied technique in pathology to determine the expression status of tumor-associated proteins and to study the clinical prognostic relevance of biomarkers, IHC results are subject to a variety of pre-analytical variables (*e.g.*, fixation method or the duration of fixation, methods of tissue processing), analytic variables (*e.g.*, antibodies, dilutions, antigen retrieval, time of incubation), and post-analytic variables, most importantly, subjectivity in determining scoring system for protein expression (cut-off values, *i.e.*, thresholds for positivity and interpretation criteria). Throughout IHC, each and every variable may greatly affect the accuracy and reliability of IHC results.

In view of the urgent demand from clinical practice, it is prerequisite to rigorously standardize IHC methodology, and this standardization should include all aspects of pre-analytical, analytic and post-analytic variables.

It sounds like a mission impossible to exercise full control over all pre-analytic variables, not to mention a complete standardization. Having said that, the collaboration among laboratories in Europe and the States has proven to be effective in tackling them. Analytic variables could to some degree be compensated for by using a large sample series. It is worthwhile to highlight that, because polyclonal antibodies have higher chances to cross-react with other antigens, it is important to further validate if the results presented in the study are specific by comparing staining patterns obtained with polyclonal antibodies with staining patterns generated by monoclonal antibodies. In addition, in order to improve reliability and interpretability of immunohistochemical markers, it has been advocated that standardized reporting criteria be used for biomarker studies[232]. A wide-spread adoption of these recommendations will help overcome some of these methodological issues.

Nevertheless, subjectivity in applying a scoring system for protein expression is probably the biggest obstacle for the pathology laboratories. Therefore, we put strong emphasis on post-analytic variables, *i.e.*, cut-off values and interpretation criteria.

Prognostic significance of immunohistochemical marker fluctuates sharply with different cut-off values,

which in itself makes it difficult to determine a valid cut-off value for clinical use. ROC curve analysis could be used as an alternative method in the selection and validation of cut-off scores for determining the most clinically relevant threshold for immunohistochemical tumor positivity[41]. Where contradictory results have been yielded from researches on established biomarkers, this tool should be adopted to re-evaluate protein expression. In addition, the authors of this review would tentatively recommend future investigations on novel tumor markers use ROC curve analysis.

No IHC scoring methods have been strictly agreed on. Researchers have been relying on percentage of positivity or intensity of positive staining, or a combination of these two, to estimate protein level. The intensity of positive staining in liver tissue sections could be easily affected by such pigments as iron deposition or brown granules in Kuppfer cells, and therefore is not a valid indicator of specific immunostaining. Additionally, IHC is a technique that detects specific antigens present in the target cells by labeling them with antibodies against them which are tagged with enzymes to convert a soluble colorless substrate to a colored insoluble precipitate which can be detected under the microscope. The intensity of positive staining is easily affected by individual researcher's skill and experience both in operating IHC and in reading slides, as well as technical conditions for IHC operation. Therefore, IHC intensity is not an appropriate criterion to be used in HCC research. The authors of this review would tentatively recommend that, for protein positive expression evaluation in liver tissue sections, percentage of stained area/field be selected as a quantitative method for IHC results. To ensure objectivity, the scoring methods of immunohistochemical markers should be assessed by independent observers.

It is worthwhile to highlight that IHC in itself could never tell us about the mutation status of these proteins. That is to say, in order to better understand the relevance between immunohistochemical markers and clinical outcomes, standardized IHC should be combined with gene mutation analysis using polymerase chain reaction methods in the same patients.

A number of studies have demonstrated that although single marker could provide useful information on the prediction of patients' survival and treatment outcomes, and could monitor efficacy of individualization of therapy, the heterogeneity of HCC tumors requires a combination of biomarkers in order to yield better clinical performance. In the foreseeable future it is likely that multiple markers need to be integrated into a prognostic signature to accurately predict outcomes. In fact, the HCC biomarkers in combination are increasingly becoming part of surveillance protocols in United States clinics[233]. Still a further long way to go before their routine use in clinical practice becomes an reality, which requires immunohistochemical markers of prognosis and prediction to be validated in carefully designed large-scale, prospective clinical trials, using standardized IHC techniques. Then, and only until then, could the validation of prognostic and predictive markers eventually guide our clinical decision making in regard to follow-up scheduling and treatment choice.

REFERENCES

1 **Iliescu L**, Mindrut E, Grasu M, Orban C, Tanase A, Toma L. Management of hepatocellular carcinoma -- experience of a single center. *Chirurgia* (Bucur) 2014; **109**: 204-207 [PMID: 24742411]

2 **Ishikawa T**. Anti-viral therapy to reduce recurrence and improve survival in hepatitis B virus-related hepatocellular carcinoma. *World J Gastroenterol* 2013; **19**: 8861-8866 [PMID: 24379608 DOI: 10.3748/wjg.v19.i47.8861]

3 **Cucchetti A**, Piscaglia F, Cescon M, Ercolani G, Pinna AD. Systematic review of surgical resection vs radiofrequency ablation for hepatocellular carcinoma. *World J Gastroenterol* 2013; **19**: 4106-4118 [PMID: 23864773 DOI: 10.3748/wjg.v19.i26.4106]

4 **Furtado R**, Crawford M, Sandroussi C. Systematic review and meta-analysis of adjuvant i(131) lipiodol after excision of hepatocellular carcinoma. *Ann Surg Oncol* 2014; **21**: 2700-2707 [PMID: 24743904 DOI: 10.1245/s10434-014-3511-2]

5 **Ishikawa T**. Strategy for improving survival and reducing recurrence of HCV-related hepatocellular carcinoma. *World J Gastroenterol* 2013; **19**: 6127-6130 [PMID: 24115808 DOI: 10.3748/wjg.v19.i37.6127]

6 **Yang Z**, Zhang Y, Wang L. A feedback inhibition between miRNA-127 and TGFβ/c-Jun cascade in HCC cell migration via MMP13. *PLoS One* 2013; **8**: e65256 [PMID: 23762330 DOI: 10.1371/journal.pone.0065256]

7 **Matsumoto A**, Ishibashi Y, Urashima M, Omura N, Nakada K, Nishikawa K, Shida A, Takada K, Kashiwagi H, Yanaga K. High UBCH10 protein expression as a marker of poor prognosis in esophageal squamous cell carcinoma. *Anticancer Res* 2014; **34**: 955-961 [PMID: 24511039]

8 **Nosrati M**, Kashani-Sabet M. Immunohistochemical diagnostic and prognostic markers for melanoma. *Methods Mol Biol* 2014; **1102**: 259-273 [PMID: 24258983 DOI: 10.1007/978-1-62703-727-3_14]

9 **Zeestraten EC**, Benard A, Reimers MS, Schouten PC, Liefers GJ, van de Velde CJ, Kuppen PJ. The prognostic value of the apoptosis pathway in colorectal cancer: a review of the literature on biomarkers identified by immunohistochemistry. *Biomark Cancer* 2013; **5**: 13-29 [PMID: 24179395 DOI: 10.4137/BIC.S11475]

10 **Wang Z**, Jiang Y, Guan D, Li J, Yin H, Pan Y, Xie D, Chen Y. Critical roles of p53 in epithelial-mesenchymal transition and metastasis of hepatocellular carcinoma cells. *PLoS One* 2013; **8**: e72846 [PMID: 24023784 DOI: 10.1371/journal.pone.0072846]

11 **Tseng PL**, Tai MH, Huang CC, Wang CC, Lin JW, Hung CH, Chen CH, Wang JH, Lu SN, Lee CM, Changchien CS, Hu TH. Overexpression of VEGF is associated with positive p53 immunostaining in hepatocellular carcinoma (HCC) and adverse outcome of HCC patients. *J Surg Oncol* 2008; **98**: 349-357 [PMID: 18646041 DOI: 10.1002/jso.21109]

12 **Tu K**, Zheng X, Zan X, Han S, Yao Y, Liu Q. Evaluation of Fbxw7 expression and its correlation with the expression of c-Myc, cyclin E and p53 in human hepatocellular carcinoma. *Hepatol Res* 2012; **42**: 904-910 [PMID: 22548670 DOI: 10.1111/j.1872-034X.2012.01005.x]

13 **Hu TH**, Wang CC, Huang CC, Chen CL, Hung CH, Chen CH, Wang JH, Lu SN, Lee CM, Changchien CS, Tai MH. Down-regulation of tumor suppressor gene PTEN, overexpression of p53, plus high proliferating cell nuclear

antigen index predict poor patient outcome of hepatocellular carcinoma after resection. *Oncol Rep* 2007; **18**: 1417-1426 [PMID: 17982625]

14 **Kang GH**, Lee BS, Lee ES, Kim SH, Lee HY, Kang DY. Prognostic significance of p53, mTOR, c-Met, IGF-1R, and HSP70 overexpression after the resection of hepatocellular carcinoma. *Gut Liver* 2014; **8**: 79-87 [PMID: 24516705 DOI: 10.5009/gnl.2014.8.1.79]

15 **Srivastava S**, Wong KF, Ong CW, Huak CY, Yeoh KG, Teh M, Luk JM, Salto-Tellez M. A morpho-molecular prognostic model for hepatocellular carcinoma. *Br J Cancer* 2012; **107**: 334-339 [PMID: 22713659 DOI: 10.1038/bjc.2012.230]

16 **Stroescu C**, Dragnea A, Ivanov B, Pechianu C, Herlea V, Sgarbura O, Popescu A, Popescu I. Expression of p53, Bcl-2, VEGF, Ki67 and PCNA and prognostic significance in hepatocellular carcinoma. *J Gastrointestin Liver Dis* 2008; **17**: 411-417 [PMID: 19104702]

17 **Sung CO**, Yoo BC, Koh KC, Cho JW, Park CK. Prognostic significance of p53 overexpression after hepatic resection of hepatocellular carcinoma. *Korean J Gastroenterol* 2005; **45**: 425-430 [PMID: 15973077]

18 **Schöniger-Hekele M**, Hänel S, Wrba F, Müller C. Hepatocellular carcinoma--survival and clinical characteristics in relation to various histologic molecular markers in Western patients. *Liver Int* 2005; **25**: 62-69 [PMID: 15698400 DOI: 10.1111/j.1478-3231.2004.0997.x]

19 **Qin HX**, Nan KJ, Yang G, Jing Z, Ruan ZP, Li CL, Xu R, Guo H, Sui CG, Wei YC. Expression and clinical significance of TAp73alpha, p53, PCNA and apoptosis in hepatocellular carcinoma. *World J Gastroenterol* 2005; **11**: 2709-2713 [PMID: 15884108]

20 **Guo RP**, Zhong C, Shi M, Zhang CQ, Wei W, Zhang YQ, Li JQ. Clinical value of apoptosis and angiogenesis factors in estimating the prognosis of hepatocellular carcinoma. *J Cancer Res Clin Oncol* 2006; **132**: 547-555 [PMID: 16763805 DOI: 10.1007/s00432-006-0097-5]

21 **Umemura A**, Itoh Y, Itoh K, Yamaguchi K, Nakajima T, Higashitsuji H, Onoue H, Fukumoto M, Okanoue T, Fujita J. Association of gankyrin protein expression with early clinical stages and insulin-like growth factor-binding protein 5 expression in human hepatocellular carcinoma. *Hepatology* 2008; **47**: 493-502 [PMID: 18161051 DOI: 10.1002/hep.22027]

22 **Eguchi S**, Kanematsu T, Arii S, Omata M, Kudo M, Sakamoto M, Takayasu K, Makuuchi M, Matsuyama Y, Monden M. Recurrence-free survival more than 10 years after liver resection for hepatocellular carcinoma. *Br J Surg* 2011; **98**: 552-557 [PMID: 21267990 DOI: 10.1002/bjs.7393]

23 **Liao KF**, Lai SW, Lin CY, Huang CH, Lin YY. Risk factors of recurrence after curative resection of hepatocellular carcinoma in Taiwan. *Am J Med Sci* 2011; **341**: 301-304 [PMID: 21441859 DOI: 10.1097/MAJ.0b013e3181ff5d93]

24 **Yang S**, Yan HL, Tao QF, Yuan SX, Tang GN, Yang Y, Wang LL, Zhang YL, Sun SH, Zhou WP. Low CADM2 expression predicts high recurrence risk of hepatocellular carcinoma patients after hepatectomy. *J Cancer Res Clin Oncol* 2014; **140**: 109-116 [PMID: 24240726 DOI: 10.1007/s00432-013-1536-8]

25 **Hu T**, Guo H, Wang W, Yu S, Han L, Jiang L, Ma J, Yang C, Guo Q, Nan K. Loss of p57 expression and RhoA overexpression are associated with poor survival of patients with hepatocellular carcinoma. *Oncol Rep* 2013; **30**: 1707-1714 [PMID: 23842948 DOI: 10.3892/or.2013.2608]

26 **Park SK**, Jung YK, Chung DH, Kim KK, Park YH, Lee JN, Kwon OS, Kim YS, Choi DJ, Kim JH. Factors influencing hepatocellular carcinoma prognosis after hepatectomy: a single-center experience. *Korean J Intern Med* 2013; **28**: 428-438 [PMID: 23864801 DOI: 10.3904/kjim.2013.28.4.428]

27 **Liu J**, Ma Q, Zhang M, Wang X, Zhang D, Li W, Wang F, Wu E. Alterations of TP53 are associated with a poor outcome for patients with hepatocellular carcinoma: evidence from a systematic review and meta-analysis. *Eur J Cancer* 2012; **48**: 2328-2338 [PMID: 22459764 DOI: 10.1016/j.ejca.2012.03.001]

28 **Qi LN**, Bai T, Chen ZS, Wu FX, Chen YY, De Xiang B, Peng T, Han ZG, Li LQ. The p53 mutation spectrum in hepatocellular carcinoma from Guangxi, China : role of chronic hepatitis B virus infection and aflatoxin B1 exposure. *Liver Int* 2014; Epub ahead of print [PMID: 24461059 DOI: 10.1111/liv.12460]

29 **Chen Ban K**, Singh H, Krishnan R, Fong Seow H. Comparison of the expression of beta-catenin in hepatocellular carcinoma in areas with high and low levels of exposure to aflatoxin B1. *J Surg Oncol* 2004; **86**: 157-163 [PMID: 15170655 DOI: 10.1002/jso.20051]

30 **Song TJ**, Fong Y, Cho SJ, Gönen M, Hezel M, Tuorto S, Choi SY, Kim YC, Suh SO, Koo BH, Chae YS, Jarnagin WR, Klimstra DS. Comparison of hepatocellular carcinoma in American and Asian patients by tissue array analysis. *J Surg Oncol* 2012; **106**: 84-88 [PMID: 22234941 DOI: 10.1002/jso.23036]

31 **Jiang YH**, Cheng B, Ge MH, Zhang G. The prognostic significance of p63 and Ki-67 expression in myoepithelial carcinoma. *Head Neck Oncol* 2012; **4**: 9 [PMID: 22452794 DOI: 10.1186/1758-3284-4-9]

32 **Le Page C**, Huntsman DG, Provencher DM, Mes-Masson AM. Predictive and prognostic protein biomarkers in epithelial ovarian cancer: recommendation for future studies. *Cancers* (Basel) 2010; **2**: 913-954 [PMID: 24281100 DOI: 10.3390/cancers2020913]

33 **Bologna-Molina R**, Mosqueda-Taylor A, Molina-Frechero N, Mori-Estevez AD, Sánchez-Acuña G. Comparison of the value of PCNA and Ki-67 as markers of cell proliferation in ameloblastic tumors. *Med Oral Patol Oral Cir Bucal* 2013; **18**: e174-e179 [PMID: 23229269 DOI: 10.4317/medoral.18573]

34 **Hsu HT**, Wu PR, Chen CJ, Hsu LS, Yeh CM, Hsing MT, Chiang YS, Lai MT, Yeh KT. High cytoplasmic expression of Krüppel-like factor 4 is an independent prognostic factor of better survival in hepatocellular carcinoma. *Int J Mol Sci* 2014; **15**: 9894-9906 [PMID: 24897024 DOI: 10.3390/ijms15069894]

35 **Huang X**, Liu F, Zhu C, Cai J, Wang H, Wang X, He S, Liu C, Yao L, Ding Z, Zhang Y, Zhang T. Suppression of KIF3B expression inhibits human hepatocellular carcinoma proliferation. *Dig Dis Sci* 2014; **59**: 795-806 [PMID: 24368420 DOI: 10.1007/s10620-013-2969-2]

36 **Ito Y**, Matsuura N, Sakon M, Takeda T, Umeshita K, Nagano H, Nakamori S, Dono K, Tsujimoto M, Nakahara M, Nakao K, Monden M. Both cell proliferation and apoptosis significantly predict shortened disease-free survival in hepatocellular carcinoma. *Br J Cancer* 1999; **81**: 747-751 [PMID: 10574266 DOI: 10.1038/sj.bjc.6690758]

37 **Chen H**, Miao J, Li H, Wang C, Li J, Zhu Y, Wang J, Wu X, Qiao H. Expression and prognostic significance of p21-activated kinase 6 in hepatocellular carcinoma. *J Surg Res* 2014; **189**: 81-88 [PMID: 24576777 DOI: 10.1016/j.jss.2014.01.049]

38 **Cao X**, Xia Y, Yang J, Jiang J, Chen L, Ni R, Li L, Gu Z. Clinical and biological significance of never in mitosis gene A-related kinase 6 (NEK6) expression in hepatic cell cancer. *Pathol Oncol Res* 2012; **18**: 201-207 [PMID: 21725899 DOI: 10.1007/s12253-011-9429-0]

39 **Ke Q**, Ji J, Cheng C, Zhang Y, Lu M, Wang Y, Zhang L, Li P, Cui X, Chen L, He S, Shen A. Expression and prognostic role of Spy1 as a novel cell cycle protein in hepatocellular carcinoma. *Exp Mol Pathol* 2009; **87**: 167-172 [PMID: 19686732 DOI: 10.1016/j.yexmp.2009.07.011]

40 **Schmilovitz-Weiss H**, Tobar A, Halpern M, Levy I, Shabtai E, Ben-Ari Z. Tissue expression of squamous cellular carcinoma antigen and Ki67 in hepatocellular carcinoma-correlation with prognosis: a historical prospective study. *Diagn Pathol* 2011; **6**: 121 [PMID: 22151825 DOI: 10.1186/1746-1596-6-121]

41 **Zlobec I**, Steele R, Terracciano L, Jass JR, Lugli A. Selecting immunohistochemical cut-off scores for novel biomarkers

of progression and survival in colorectal cancer. *J Clin Pathol* 2007; **60**: 1112-1116 [PMID: 17182662 DOI: 10.1136/jcp.2006.044537]

42 **Yang H**, Liu J, Yu H, Sun P, Hu Y, Zhong J, Zhu Z. Expression and association of CD44v6 with prognosis in T2-3N0M0 esophageal squamous cell carcinoma. *J Thorac Dis* 2014; **6**: 91-98 [PMID: 24605222 DOI: 10.3978/j.issn.2072-1439.2013.11.16]

43 **Spira A**, Ettinger DS. Multidisciplinary management of lung cancer. *N Engl J Med* 2004; **350**: 379-392 [PMID: 14736930 DOI: 10.1056/NEJMra035536]

44 **Wang D**, Stockard CR, Harkins L, Lott P, Salih C, Yuan K, Buchsbaum D, Hashim A, Zayzafoon M, Hardy RW, Hameed O, Grizzle W, Siegal GP. Immunohistochemistry in the evaluation of neovascularization in tumor xenografts. *Biotech Histochem* 2008; **83**: 179-189 [PMID: 18846440 DOI: 10.1080/10520290802451085]

45 **Wang SN**, Chuang SC, Yeh YT, Yang SF, Chai CY, Chen WT, Kuo KK, Chen JS, Lee KT. Potential prognostic value of leptin receptor in hepatocellular carcinoma. *J Clin Pathol* 2006; **59**: 1267-1271 [PMID: 16565226 DOI: 10.1136/jcp.2005.033464]

46 **Chebib I**, Shabani-Rad MT, Chow MS, Zhang J, Gao ZH. Microvessel density and clinicopathologic characteristics in hepatocellular carcinoma with and without cirrhosis. *Biomark Insights* 2007; **2**: 59-68 [PMID: 19662192]

47 **Yang P**, Yuan W, He J, Wang J, Yu L, Jin X, Hu Y, Liao M, Chen Z, Zhang Y. Overexpression of EphA2, MMP-9, and MVD-CD34 in hepatocellular carcinoma: Implications for tumor progression and prognosis. *Hepatol Res* 2009; **39**: 1169-1177 [PMID: 19788698 DOI: 10.1111/j.1872-034X.2009.00563.x]

48 **Nanashima A**, Nakayama T, Sumida Y, Abo T, Takeshita H, Shibata K, Hidaka S, Sawai T, Yasutake T, Nagayasu T. Relationship between microvessel count and post-hepatectomy survival in patients with hepatocellular carcinoma. *World J Gastroenterol* 2008; **14**: 4915-4922 [PMID: 18756600 DOI: 10.3748/wjg.14.4915]

49 **Zeng W**, Gouw AS, van den Heuvel MC, Molema G, Poppema S, van der Jagt EJ, de Jong KP. Hepatocellular carcinomas in cirrhotic and noncirrhotic human livers share angiogenic characteristics. *Ann Surg Oncol* 2010; **17**: 1564-1571 [PMID: 20087783 DOI: 10.1245/s10434-009-0900-z]

50 **Yang LY**, Lu WQ, Huang GW, Wang W. Correlation between CD105 expression and postoperative recurrence and metastasis of hepatocellular carcinoma. *BMC Cancer* 2006; **6**: 110 [PMID: 16650286 DOI: 10.1186/1471-2407-6-110]

51 **Miyata Y**, Sagara Y, Watanabe S, Asai A, Matsuo T, Ohba K, Hayashi T, Sakai H. CD105 is a more appropriate marker for evaluating angiogenesis in urothelial cancer of the upper urinary tract than CD31 or CD34. *Virchows Arch* 2013; **463**: 673-679 [PMID: 23975255 DOI: 10.1007/s00428-013-1463-8]

52 **Saroufim A**, Messai Y, Hasmim M, Rioux N, Iacovelli R, Verhoest G, Bensalah K, Patard JJ, Albiges L, Azzarone B, Escudier B, Chouaib S. Tumoral CD105 is a novel independent prognostic marker for prognosis in clear-cell renal cell carcinoma. *Br J Cancer* 2014; **110**: 1778-1784 [PMID: 24594997 DOI: 10.1038/bjc.2014.71]

53 **Gurzu S**, Cimpean AM, Kovacs J, Jung I. Counting of angiogenesis in colorectal carcinomas using double immunostain. *Tumori* 2012; **98**: 485-490 [PMID: 23052166 DOI: 10.1700/1146.12644]

54 **Pappa CA**, Alexandrakis MG, Boula A, Psarakis FE, Kolovou A, Bantouna V, Stavroulaki E, Tsirakis G. Emerging roles of endoglin/CD105 and angiogenic cytokines for disease development and progression in multiple myeloma patients. *Hematol Oncol* 2013; **31**: 201-205 [PMID: 23576184 DOI: 10.1002/hon.2044]

55 **Bodnar M**, Szylberg Ł, Kaźmierczak W, Marszałek A. [Evaluation of microvessel density (MVD) in laryngeal squamous cell carcinoma]. *Przegl Lek* 2012; **69**: 726-730 [PMID: 23421020]

56 **Wang Y**, Zhang XH, Guo P, Yan LN, He D. [Tumor microvascular density detected by anti-CD105 and anti-CD34 in hepatocellular carcinoma patients and its predictive value of tumor recurrence after liver transplantation]. *Sichuan Daxue Xuebao Yixueban* 2010; **41**: 818-821 [PMID: 21302449]

57 **Yao Y**, Pan Y, Chen J, Sun X, Qiu Y, Ding Y. Endoglin (CD105) expression in angiogenesis of primary hepatocellular carcinomas: analysis using tissue microarrays and comparisons with CD34 and VEGF. *Ann Clin Lab Sci* 2007; **37**: 39-48 [PMID: 17311868]

58 **Ho JW**, Poon RT, Sun CK, Xue WC, Fan ST. Clinico-pathological and prognostic implications of endoglin (CD105) expression in hepatocellular carcinoma and its adjacent non-tumorous liver. *World J Gastroenterol* 2005; **11**: 176-181 [PMID: 15633211 DOI: 10.3748/wjg.v11.i2.176]

59 **Weidner N**. Current pathologic methods for measuring intratumoral microvessel density within breast carcinoma and other solid tumors. *Breast Cancer Res Treat* 1995; **36**: 169-180 [PMID: 8534865 DOI: 10.1007/BF00666038]

60 **Sobczyńska-Rak A**, Polkowska I, Silmanowicz P. Elevated Vascular Endothelial Growth Factor (VEGF) levels in the blood serum of dogs with malignant neoplasms of the oral cavity. *Acta Vet Hung* 2014; **62**: 362-371 [PMID: 24659713 DOI: 10.1556/AVet.2014.009]

61 **Kaseb AO**, Hanbali A, Cotant M, Hassan MM, Wollner I, Philip PA. Vascular endothelial growth factor in the management of hepatocellular carcinoma: a review of literature. *Cancer* 2009; **115**: 4895-4906 [PMID: 19637355 DOI: 10.1002/cncr.24537]

62 **Kong SY**, Park JW, Lee JA, Park JE, Park KW, Hong EK, Kim CM. Association between vascular endothelial growth factor gene polymorphisms and survival in hepatocellular carcinoma patients. *Hepatology* 2007; **46**: 446-455 [PMID: 17659575 DOI: 10.1002/hep.21720]

63 **Wang D**, Luo L, Chen W, Chen LZ, Zeng WT, Li W, Huang XH. Significance of the vascular endothelial growth factor and the macrophage migration inhibitory factor in the progression of hepatocellular carcinoma. *Oncol Rep* 2014; **31**: 1199-1204 [PMID: 24366206 DOI: 10.3892/or.2013.2946]

64 **Thelen A**, Scholz A, Benckert C, von Marschall Z, Schröder M, Wiedenmann B, Neuhaus P, Rosewicz S, Jonas S. VEGF-D promotes tumor growth and lymphatic spread in a mouse model of hepatocellular carcinoma. *Int J Cancer* 2008; **122**: 2471-2481 [PMID: 18338756 DOI: 10.1002/ijc.23439]

65 **Minata M**, Harada KH, Kudo M, Ikai I, Nishida N. The prognostic value of vascular endothelial growth factor in hepatocellular carcinoma for predicting metastasis after curative resection. *Oncology* 2013; **84** Suppl 1: 75-81 [PMID: 23428863 DOI: 10.1159/000345894]

66 **Xiang ZL**, Zeng ZC, Fan J, Tang ZY, Zeng HY, Gao DM. Gene expression profiling of fixed tissues identified hypoxia-inducible factor-1α, VEGF, and matrix metalloproteinase-2 as biomarkers of lymph node metastasis in hepatocellular carcinoma. *Clin Cancer Res* 2011; **17**: 5463-5472 [PMID: 21712445]

67 **Chen L**, Shi Y, Jiang CY, Wei LX, Lv YL, Wang YL, Dai GH. Coexpression of PDGFR-alpha, PDGFR-beta and VEGF as a prognostic factor in patients with hepatocellular carcinoma. *Int J Biol Markers* 2011; **26**: 108-116 [PMID: 21574155 DOI: 10.5301/JBM.2011.8322]

68 **Hu J**, Xu Y, Shen ZZ, Wang Z, Lu Q, Yang GH, Ding ZB, Fan J, Zhou J. High expressions of vascular endothelial growth factor and platelet-derived endothelial cell growth factor predict poor prognosis in alpha-fetoprotein-negative hepatocellular carcinoma patients after curative resection. *J Cancer Res Clin Oncol* 2009; **135**: 1359-1367 [PMID: 19350273 DOI: 10.1007/s00432-009-0577-5]

69 **Herszényi L**, Hritz I, Lakatos G, Varga MZ, Tulassay Z. The behavior of matrix metalloproteinases and their inhibitors in

colorectal cancer. *Int J Mol Sci* 2012; **13**: 13240-13263 [PMID: 23202950 DOI: 10.3390/ijms131013240]

70 **Fan HX**, Li HX, Chen D, Gao ZX, Zheng JH. Changes in the expression of MMP2, MMP9, and ColIV in stromal cells in oral squamous tongue cell carcinoma: relationships and prognostic implications. *J Exp Clin Cancer Res* 2012; **31**: 90 [PMID: 23107277 DOI: 10.1186/1756-9966-31-90]

71 **Dodd T**, Jadhav R, Wiggins L, Stewart J, Smith E, Russell JC, Rocic P. MMPs 2 and 9 are essential for coronary collateral growth and are prominently regulated by p38 MAPK. *J Mol Cell Cardiol* 2011; **51**: 1015-1025 [PMID: 21884701 DOI: 10.1016/j.yjmcc.2011.08.012]

72 **Puzovic V**, Brcic I, Ranogajec I, Jakic-Razumovic J. Prognostic values of ETS-1, MMP-2 and MMP-9 expression and co-expression in breast cancer patients. *Neoplasma* 2014; **61**: 439-446 [PMID: 24645837 DOI: 10.4149/neo_2014_054]

73 **Puljiz M**, Puljiz Z, Vucemilo T, Ramić S, Knezević F, Culo B, Alvir I, Tomica D, Danolić D. Prognostic significance of matrix metalloproteinases 2 and 9 in endometrial cancer. *Coll Antropol* 2012; **36**: 1367-1372 [PMID: 23390835]

74 **Xiang ZL**, Zeng ZC, Tang ZY, Fan J, Sun HC, Tan YS. Expression of cytokeratin 19 and matrix metalloproteinase 2 predicts lymph node metastasis in hepatocellular carcinoma. *Mol Biol Rep* 2011; **38**: 3531-3539 [PMID: 21104440 DOI: 10.1007/s11033-010-0463-x]

75 **Guo RP**, Zhong C, Shi M, Zhang CQ, Wei W, Zhang YQ, Li JQ. [Expression and clinical impact of vascular endothelial growth factor and matrix metalloproteinase-2 in hepatocellular carcinoma]. *Zhonghua Zhongliu Zazhi* 2006; **28**: 285-288 [PMID: 16875630]

76 **Nart D**, Yaman B, Yilmaz F, Zeytunlu M, Karasu Z, Kiliç M. Expression of matrix metalloproteinase-9 in predicting prognosis of hepatocellular carcinoma after liver transplantation. *Liver Transpl* 2010; **16**: 621-630 [PMID: 20440771 DOI: 10.1002/lt.22028]

77 **Hou YK**, Wang Y, Cong WM, Wu MC. [Expression of tumor metastasis-suppressor gene KiSS-1 and matrix metalloproteinase-9 in portal vein tumor thrombus of hepatocellular carcinoma]. *Ai Zheng* 2007; **26**: 591-595 [PMID: 17562263]

78 **Lee CF**, Ling ZQ, Zhao T, Lee KR. Distinct expression patterns in hepatitis B virus- and hepatitis C virus-infected hepatocellular carcinoma. *World J Gastroenterol* 2008; **14**: 6072-6077 [PMID: 18932288 DOI: 10.3748/wjg.14.6072]

79 **Chen ZB**, Shen SQ, Ding YM, Wang WX, Tao JP, Liang LJ, Hu WJ. The angiogenic and prognostic implications of VEGF, Ang-1, Ang-2, and MMP-9 for hepatocellular carcinoma with background of hepatitis B virus. *Med Oncol* 2009; **26**: 365-371 [PMID: 19082771 DOI: 10.1007/s12032-008-9130-7]

80 **Ishii Y**, Nakasato Y, Kobayashi S, Yamazaki Y, Aoki T. A study on angiogenesis-related matrix metalloproteinase networks in primary hepatocellular carcinoma. *J Exp Clin Cancer Res* 2003; **22**: 461-470 [PMID: 14582707]

81 **Chen R**, Cui J, Xu C, Xue T, Guo K, Gao D, Liu Y, Ye S, Ren Z. The significance of MMP-9 over MMP-2 in HCC invasiveness and recurrence of hepatocellular carcinoma after curative resection. *Ann Surg Oncol* 2012; **19** Suppl 3: S375-S384 [PMID: 21681378 DOI: 10.1245/s10434-011-1836-7]

82 **Altadill A**, Rodríguez M, González LO, Junquera S, Corte MD, González-Dieguez ML, Linares A, Barbón E, Fresno-Forcelledo M, Rodrigo L, Vizoso FJ. Liver expression of matrix metalloproteases and their inhibitors in hepatocellular carcinoma. *Dig Liver Dis* 2009; **41**: 740-748 [PMID: 19372066 DOI: 10.1016/j.dld.2009.01.016]

83 **Gao ZH**, Tretiakova MS, Liu WH, Gong C, Farris PD, Hart J. Association of E-cadherin, matrix metalloproteinases, and tissue inhibitors of metalloproteinases with the progression and metastasis of hepatocellular carcinoma. *Mod Pathol* 2006; **19**: 533-540 [PMID: 16474379 DOI: 10.1038/modpathol.3800554]

84 **Matsunaga Y**, Koda M, Murawaki Y. Expression of matrix metalloproiteinases (MMPs) and tissue inhibitors of metalloproteinases (TIMPs) in hepatocellular carcinoma tissue, compared with the surrounding non-tumor tissue. *Res Commun Mol Pathol Pharmacol* 2004; **115-116**: 143-150 [PMID: 17564313]

85 **Wei QY**, Wu YQ, Fan SQ. [Expression of matrix metalloproteinases and tissue inhibitors of matrix metalloproteinases in the hepatocellular carcinomas]. *Hunan Yike Daxue Xuebao* 2003; **28**: 212-216 [PMID: 14653069]

86 **Bendas G**, Borsig L. Cancer cell adhesion and metastasis: selectins, integrins, and the inhibitory potential of heparins. *Int J Cell Biol* 2012; **2012**: 676731 [PMID: 22505933 DOI: 10.1155/2012/676731]

87 **Techasen A**, Loilome W, Namwat N, Khuntikeo N, Puapairoj A, Jearanaikoon P, Saya H, Yongvanit P. Loss of E-cadherin promotes migration and invasion of cholangiocarcinoma cells and serves as a potential marker of metastasis. *Tumour Biol* 2014; **35**: 8645-8652 [PMID: 24867095 DOI: 10.1007/s13277-014-2087-6]

88 **Pectasides E**, Rampias T, Sasaki C, Perisanidis C, Kouloulias V, Burtness B, Zaramboukas T, Rimm D, Fountzilas G, Psyrri A. Markers of epithelial to mesenchymal transition in association with survival in head and neck squamous cell carcinoma (HNSCC). *PLoS One* 2014; **9**: e94273 [PMID: 24722213 DOI: 10.1371/journal.pone.0094273]

89 **Endo K**, Ueda T, Ueyama J, Ohta T, Terada T. Immunoreactive E-cadherin, alpha-catenin, beta-catenin, and gamma-catenin proteins in hepatocellular carcinoma: relationships with tumor grade, clinicopathologic parameters, and patients' survival. *Hum Pathol* 2000; **31**: 558-565 [PMID: 10836294 DOI: 10.1053/hp.2000.6683]

90 **Wei Y**, Van Nhieu JT, Prigent S, Srivatanakul P, Tiollais P, Buendia MA. Altered expression of E-cadherin in hepatocellular carcinoma: correlations with genetic alterations, beta-catenin expression, and clinical features. *Hepatology* 2002; **36**: 692-701 [PMID: 12198663 DOI: 10.1053/jhep.2002.35342]

91 **Guo C**, Liu QG, Yang W, Zhang ZL, Yao YM. Relation among p130Cas, E-cadherin and beta-catenin expression, clinicopathologic significance and prognosis in human hepatocellular carcinoma. *Hepatobiliary Pancreat Dis Int* 2008; **7**: 490-496 [PMID: 18842495]

92 **Hashiguchi M**, Ueno S, Sakoda M, Iino S, Hiwatashi K, Minami K, Ando K, Mataki Y, Maemura K, Shinchi H, Ishigami S, Natsugoe S. Clinical implication of ZEB-1 and E-cadherin expression in hepatocellular carcinoma (HCC). *BMC Cancer* 2013; **13**: 572 [PMID: 24304617 DOI: 10.1186/1471-2407-13-572]

93 **Minata M**, Kudo M, Harada KH, Ikai I, Nishida N. Expression of E-cadherin and vascular endothelial growth factor in noncancerous liver is associated with recurrence of hepatocellular carcinoma after curative resection. *Oncology* 2013; **84** Suppl 1: 88-92 [PMID: 23428865 DOI: 10.1159/000345896]

94 **Cho SB**, Lee KH, Lee JH, Park SY, Lee WS, Park CH, Kim HS, Choi SK, Rew JS. Expression of E- and N-cadherin and clinicopathology in hepatocellular carcinoma. *Pathol Int* 2008; **58**: 635-642 [PMID: 18801083 DOI: 10.1111/j.1440-1827.2008.02282.x]

95 **Woo HY**, Min AL, Choi JY, Bae SH, Yoon SK, Jung CK. Clinicopathologic significance of the expression of Snail in hepatocellular carcinoma. *Korean J Hepatol* 2011; **17**: 12-18 [PMID: 21494073 DOI: 10.3350/kjhep.2011.17.1.12]

96 **Korita PV**, Wakai T, Shirai Y, Matsuda Y, Sakata J, Cui X, Ajioka Y, Hatakeyama K. Overexpression of osteopontin independently correlates with vascular invasion and poor prognosis in patients with hepatocellular carcinoma. *Hum Pathol* 2008; **39**: 1777-1783 [PMID: 18701136 DOI: 10.1016/j.humpath.2008.05.006]

97 **Schneider MR**, Hiltwein F, Grill J, Blum H, Krebs S, Klanner A, Bauersachs S, Bruns C, Longerich T, Horst D, Brandl

L, de Toni E, Herbst A, Kolligs FT. Evidence for a role of E-cadherin in suppressing liver carcinogenesis in mice and men. *Carcinogenesis* 2014; **35**: 1855-1862 [PMID: 24840851 DOI: 10.1093/carcin/bgu109]

98 **Jiang XM**, Zhang JB, Xiong J, Huang XX, Ren ZG. Altered distribution and expression pattern of E-cadherin in hepatocellular carcinomas: correlations with prognosis and clinical features. *Asian Pac J Cancer Prev* 2012; **13**: 6455-6461 [PMID: 23464474 DOI: 10.7314/APJCP.2012.13.12.6455]

99 **Kalluri R**, Neilson EG. Epithelial-mesenchymal transition and its implications for fibrosis. *J Clin Invest* 2003; **112**: 1776-1784 [PMID: 14679171 DOI: 10.1172/JCI200320530]

100 **Thiery JP**, Acloque H, Huang RY, Nieto MA. Epithelial-mesenchymal transitions in development and disease. *Cell* 2009; **139**: 871-890 [PMID: 19945376 DOI: 10.1016/j.cell.2009.11.007]

101 **Zucchini-Pascal N**, Peyre L, Rahmani R. Crosstalk between beta-catenin and snail in the induction of epithelial to mesenchymal transition in hepatocarcinoma: role of the ERK1/2 pathway. *Int J Mol Sci* 2013; **14**: 20768-20792 [PMID: 24135872 DOI: 10.3390/ijms141020768]

102 **Mima K**, Hayashi H, Kuroki H, Nakagawa S, Okabe H, Chikamoto A, Watanabe M, Beppu T, Baba H. Epithelial-mesenchymal transition expression profiles as a prognostic factor for disease-free survival in hepatocellular carcinoma: Clinical significance of transforming growth factor-β signaling. *Oncol Lett* 2013; **5**: 149-154 [PMID: 23255911]

103 **Xiao S**, Zhou Y, Jiang J, Yuan L, Xue M. CD44 affects the expression level of FOS-like antigen 1 in cervical cancer tissues. *Mol Med Rep* 2014; **9**: 1667-1674 [PMID: 24604526 DOI: 10.3892/mmr.2014.2010]

104 **Ko YH**, Won HS, Jeon EK, Hong SH, Roh SY, Hong YS, Byun JH, Jung CK, Kang JH. Prognostic significance of CD44s expression in resected non-small cell lung cancer. *BMC Cancer* 2011; **11**: 340 [PMID: 21819617 DOI: 10.1186/1471-2407-11-340]

105 **Okada T**, Nakamura T, Watanabe T, Onoda N, Ashida A, Okuyama R, Ito K. Coexpression of EpCAM, CD44 variant isoforms and claudin-7 in anaplastic thyroid carcinoma. *PLoS One* 2014; **9**: e94487 [PMID: 24727741 DOI: 10.1371/journal.pone.0094487]

106 **Ni J**, Cozzi PJ, Hao JL, Beretov J, Chang L, Duan W, Shigdar S, Delprado WJ, Graham PH, Bucci J, Kearsley JH, Li Y. CD44 variant 6 is associated with prostate cancer metastasis and chemo-/radioresistance. *Prostate* 2014; **74**: 602-617 [PMID: 24615685 DOI: 10.1002/pros.22775]

107 **Dan T**, Hewitt SM, Ohri N, Ly D, Soule BP, Smith SL, Matsuda K, Council C, Shankavaram U, Lippman ME, Mitchell JB, Camphausen K, Simone NL. CD44 is prognostic for overall survival in the NCI randomized trial on breast conservation with 25 year follow-up. *Breast Cancer Res Treat* 2014; **143**: 11-18 [PMID: 24276281 DOI: 10.1007/s10549-013-2758-9]

108 **Hu S**, Wu X, Zhou B, Xu Z, Qin J, Lu H, Lv L, Gao Y, Deng L, Yin J, Li G. IMP3 combined with CD44s, a novel predictor for prognosis of patients with hepatocellular carcinoma. *J Cancer Res Clin Oncol* 2014; **140**: 883-893 [PMID: 24647926 DOI: 10.1007/s00432-014-1639-x]

109 **Mima K**, Okabe H, Ishimoto T, Hayashi H, Nakagawa S, Kuroki H, Watanabe M, Beppu T, Tamada M, Nagano O, Saya H, Baba H. CD44s regulates the TGF-β-mediated mesenchymal phenotype and is associated with poor prognosis in patients with hepatocellular carcinoma. *Cancer Res* 2012; **72**: 3414-3423 [PMID: 22552294 DOI: 10.1158/0008-5472.CAN-12-0299]

110 **Beckebaum S**, Chen X, Sotiropoulos GC, Radtke A, Daoudaki M, Baba HA, Wohlschlaeger J, Broelsch CE, Gerken G, Cicinnati VR. Role of osteopontin and CD44s expression for patients with hepatocellular carcinoma undergoing liver transplantation or resection. *Transplant Proc* 2008; **40**: 3182-3184 [PMID: 19010227 DOI: 10.1016/j.transproceed.2008.08.034]

111 **Mathew J**, Hines JE, Obafunwa JO, Burr AW, Toole K, Burt AD. CD44 is expressed in hepatocellular carcinomas showing vascular invasion. *J Pathol* 1996; **179**: 74-79 [PMID: 8691349 DOI: 10.1002/(SICI)1096-9896(199605)179:1<74::AID-PATH531>3.0.CO;2-E]

112 **Ryu HS**, Park SH, Lee KB, Shin E, Jang JJ. Expression of the Transmembrane Glycoprotein CD44s Is Potentially an Independent Predictor of Recurrence in Hepatocellular Carcinoma. *Gut Liver* 2011; **5**: 204-209 [PMID: 21814602 DOI: 10.5009/gnl.2011.5.2.204]

113 **Endo K**, Terada T. Protein expression of CD44 (standard and variant isoforms) in hepatocellular carcinoma: relationships with tumor grade, clinicopathologic parameters, p53 expression, and patient survival. *J Hepatol* 2000; **32**: 78-84 [PMID: 10673070 DOI: 10.1016/S0168-8278(00)80192-0]

114 **Zhang BY**, Dai XW, Chen QY, Fang L, Qian B, Sun GY, Cui HH. [Expression of epithelial-cadherin, CD44v6 and connexin43 in hepatocellular carcinoma]. *Zhonghua Binglixue Zazhi* 2006; **35**: 616-619 [PMID: 17134571]

115 **Zhou ZJ**, Dai Z, Zhou SL, Fu XT, Zhao YM, Shi YH, Zhou J, Fan J. Overexpression of HnRNP A1 promotes tumor invasion through regulating CD44v6 and indicates poor prognosis for hepatocellular carcinoma. *Int J Cancer* 2013; **132**: 1080-1089 [PMID: 22821376 DOI: 10.1002/ijc.27742]

116 **Chen BL**, Guo K, Liu YK. [Relationship between CD44 expression or glycosylation and hepatocellular carcinoma metastasis]. *Zhonghua Ganzangbing Zazhi* 2011; **19**: 898-903 [PMID: 22525501 DOI: 10.3760/cma.j.issn.1007-3418.2011.12.005]

117 **Mima K**, Okabe H, Ishimoto T, Hayashi H, Nakagawa S, Kuroki H, Miyake K, Takamori H, Beppu T, Baba H. The expression levels of CD44v6 are correlated with the invasiveness of hepatocellular carcinoma in vitro, but do not appear to be clinically significant. *Oncol Lett* 2012; **3**: 1047-1051 [PMID: 22783389]

118 **Etiz D**, Ataizi FC, Bayman E, Akcay M, Acikalin MF, Colak E, Ciftci E. Prognostic value of osteopontin in patients treated with primary radiotherapy for head and neck cancer. *Asian Pac J Cancer Prev* 2013; **14**: 5175-5178 [PMID: 24175796 DOI: 10.7314/APJCP.2013.14.9.5175]

119 **Thorat D**, Sahu A, Behera R, Lohite K, Deshmukh S, Mane A, Karnik S, Doke S, Kundu GC. Association of osteopontin and cyclooxygenase-2 expression with breast cancer subtypes and their use as potential biomarkers. *Oncol Lett* 2013; **6**: 1559-1564 [PMID: 24260046]

120 **Gimba ER**, Tilli TM. Human osteopontin splicing isoforms: known roles, potential clinical applications and activated signaling pathways. *Cancer Lett* 2013; **331**: 11-17 [PMID: 23246372 DOI: 10.1016/j.canlet.2012.12.003]

121 **Kruger TE**, Miller AH, Godwin AK, Wang J. Bone sialoprotein and osteopontin in bone metastasis of osteotropic cancers. *Crit Rev Oncol Hematol* 2014; **89**: 330-341 [PMID: 24071501 DOI: 10.1016/j.critrevonc.2013.08.013]

122 **Lin F**, Li Y, Cao J, Fan S, Wen J, Zhu G, Du H, Liang Y. Overexpression of osteopontin in hepatocellular carcinoma and its relationships with metastasis, invasion of tumor cells. *Mol Biol Rep* 2011; **38**: 5205-5210 [PMID: 21188534 DOI: 10.1007/s11033-010-0671-4]

123 **Hua Z**, Chen J, Sun B, Zhao G, Zhang Y, Fong Y, Jia Z, Yao L. Specific expression of osteopontin and S100A6 in hepatocellular carcinoma. *Surgery* 2011; **149**: 783-791 [PMID: 21310450 DOI: 10.1016/j.surg.2010.12.007]

124 **Tsai WC**, Tsai WC, Lee HS, Jin JS, Gao HW, Chao TK, Chen A, Nieh S, Chan DC, Chang FN, Lin CK. Association between Osteopontin and EGFR Expression with Clinicopathological Parameters in Hepatocellular Carcinoma. *Chin J Physiol* 2012; **55**: 412-420 [PMID: 23286449 DOI: 10.4077/CJP.2012.BAA082]

125 **Qin L**. Osteopontin is a promoter for hepatocellular carcinoma metastasis: a summary of 10 years of studies. *Front Med* 2014; **8**: 24-32 [PMID: 24464486 DOI: 10.1007/s11684-014-0312-8]

126 **Jin Y**, Chen JN, Feng ZY, Zhang ZG, Fan WZ, Wang Y, Li JP. OPN and αvβ3 expression are predictors of disease severity and worse prognosis in hepatocellular carcinoma. *PLoS One* 2014; **9**: e87930 [PMID: 24498405 DOI: 10.1371/journal.pone.0087930]

127 **Chen RX**, Xia YH, Cui JF, Xue TC, Ye SL. Osteopontin, a single marker for predicting the prognosis of patients with tumor-node-metastasis stage I hepatocellular carcinoma after surgical resection. *J Gastroenterol Hepatol* 2010; **25**: 1435-1442 [PMID: 20659235 DOI: 10.1111/j.1440-1746.2010.06277.x]

128 **Cao DX**, Li ZJ, Jiang XO, Lum YL, Khin E, Lee NP, Wu GH, Luk JM. Osteopontin as potential biomarker and therapeutic target in gastric and liver cancers. *World J Gastroenterol* 2012; **18**: 3923-3930 [PMID: 22912540 DOI: 10.3748/wjg.v18.i30.3923]

129 **Yu MC**, Lee YS, Lin SE, Wu HY, Chen TC, Lee WC, Chen MF, Tsai CN. Recurrence and poor prognosis following resection of small hepatitis B-related hepatocellular carcinoma lesions are associated with aberrant tumor expression profiles of glypican 3 and osteopontin. *Ann Surg Oncol* 2012; **19** Suppl 3: S455-S463 [PMID: 21822558 DOI: 10.1245/s10434-011-1946-2]

130 **Huang H**, Zhang XF, Zhou HJ, Xue YH, Dong QZ, Ye QH, Qin LX. Expression and prognostic significance of osteopontin and caspase-3 in hepatocellular carcinoma patients after curative resection. *Cancer Sci* 2010; **101**: 1314-1319 [PMID: 20345480 DOI: 10.1111/j.1349-7006.2010.01524.x]

131 **Deng B**, Zhang XF, Zhu XC, Huang H, Jia HL, Ye QH, Dong QZ, Qin LX. Correlation and prognostic value of osteopontin and Bcl-2 in hepatocellular carcinoma patients after curative resection. *Oncol Rep* 2013; **30**: 2795-2803 [PMID: 24065086 DOI: 10.3892/or.2013.2737]

132 **Zhu W**, Guo L, Zhang B, Lou L, Lin Z, Zhu X, Ren N, Dong Q, Ye Q, Qin L. Combination of osteopontin with peritumoral infiltrating macrophages is associated with poor prognosis of early-stage hepatocellular carcinoma after curative resection. *Ann Surg Oncol* 2014; **21**: 1304-1313 [PMID: 24366422 DOI: 10.1245/s10434-013-3445-0]

133 **Weber GF**. The cancer biomarker osteopontin: combination with other markers. *Cancer Genomics Proteomics* 2011; **8**: 263-288 [PMID: 22086896]

134 **Kim N**, Kim JE, Choung HK, Lee MJ, Khwarg SI. Expression of cell cycle regulatory proteins in eyelid sebaceous gland carcinoma: low p27 expression predicts poor prognosis. *Exp Eye Res* 2014; **118**: 46-52 [PMID: 24216315 DOI: 10.1016/j.exer.2013.10.022]

135 **Aoyagi K**, Kouhuji K, Miyagi M, Imaizumi T, Kizaki J, Isobe T, Shirouzu K. Expression of p27Kip1 protein in gastric carcinoma. *Hepatogastroenterology* 2013; **60**: 390-394 [PMID: 23858559]

136 **Matsuda Y**, Wakai T, Kubota M, Takamura M, Yamagiwa S, Aoyagi Y, Osawa M, Fujimaki S, Sanpei A, Genda T, Ichida T. Clinical significance of cell cycle inhibitors in hepatocellular carcinoma. *Med Mol Morphol* 2013; **46**: 185-192 [PMID: 23640750 DOI: 10.1007/s00795-013-0047-7]

137 **Wan C**, Hou S, Ni R, Lv L, Ding Z, Huang X, Hang Q, He S, Wang Y, Cheng C, Gu XX, Xu G, Shen A. MIF4G domain containing protein regulates cell cycle and hepatic carcinogenesis by antagonizing CDK2-dependent p27 stability. *Oncogene* 2013; Epub ahead of print [PMID: 24336329 DOI: 10.1038/onc.2013.536]

138 **Fu X**, Wang Q, Chen J, Huang X, Chen X, Cao L, Tan H, Li W, Zhang L, Bi J, Su Q, Chen L. Clinical significance of miR-221 and its inverse correlation with p27Kip¹ in hepatocellular carcinoma. *Mol Biol Rep* 2011; **38**: 3029-3035 [PMID: 20146005 DOI: 10.1007/s11033-010-9969-5]

139 **Shen DY**, Fang ZX, You P, Liu PG, Wang F, Huang CL, Yao XB, Chen ZX, Zhang ZY. Clinical significance and expression of cyclin kinase subunits 1 and 2 in hepatocellular carcinoma. *Liver Int* 2010; **30**: 119-125 [PMID: 19845855 DOI: 10.1111/j.1478-3231.2009.02106.x]

140 **Shehata MA**, Nosseir HR, Nagy HM, Farouk G. Cyclin dependent kinase inhibitor p27(kip1) expression and subcellular localization in relation to cell proliferation in hepatocellualr carcinoma. *Egypt J Immunol* 2006; **13**: 115-130 [PMID: 17974156]

141 **Tannapfel A**, Grund D, Katalinic A, Uhlmann D, Köckerling F, Haugwitz U, Wasner M, Hauss J, Engeland K, Wittekind C. Decreased expression of p27 protein is associated with advanced tumor stage in hepatocellular carcinoma. *Int J Cancer* 2000; **89**: 350-355 [PMID: 10956409 DOI: 10.1002/1097-0215(20000720)89:4<350::AID-IJC6>3.0.CO;2-3]

142 **Armengol C**, Boix L, Bachs O, Solé M, Fuster J, Sala M, Llovet JM, Rodés J, Bruix J. p27(Kip1) is an independent predictor of recurrence after surgical resection in patients with small hepatocellular carcinoma. *J Hepatol* 2003; **38**: 591-597 [PMID: 12713869 DOI: 10.1016/S0168-8278(03)00025-4]

143 **Zhou Q**, He Q, Liang LJ. Expression of p27, cyclin E and cyclin A in hepatocellular carcinoma and its clinical significance. *World J Gastroenterol* 2003; **9**: 2450-2454 [PMID: 14606074]

144 **Chen L**, Yuan D, Wang GL, Wang Y, Wu YY, Zhu J. Clinicopathological significance of expression of Tspan-1, Jab1 and p27 in human hepatocellular carcinoma. *J Korean Med Sci* 2010; **25**: 1438-1442 [PMID: 20890423 DOI: 10.3346/jkms.2010.25.10.1438]

145 **Huang CW**, Lin CY, Huang HY, Liu HW, Chen YJ, Shih DF, Chen HY, Juan CC, Ker CG, Huang CY, Li CF, Shiue YL. CKS1B overexpression implicates clinical aggressiveness of hepatocellular carcinomas but not p27(Kip1) protein turnover: an independent prognosticator with potential p27 (Kip1)-independent oncogenic attributes? *Ann Surg Oncol* 2010; **17**: 907-922 [PMID: 19866239 DOI: 10.1245/s10434-009-0779-8]

146 **Matsuda Y**. Molecular mechanism underlying the functional loss of cyclindependent kinase inhibitors p16 and p27 in hepatocellular carcinoma. *World J Gastroenterol* 2008; **14**: 1734-1740 [PMID: 18350604 DOI: 10.3748/wjg.14.1734]

147 **Fiorentino M**, Altimari A, D'Errico A, Cukor B, Barozzi C, Loda M, Grigioni WF. Acquired expression of p27 is a favorable prognostic indicator in patients with hepatocellular carcinoma. *Clin Cancer Res* 2000; **6**: 3966-3972 [PMID: 11051245]

148 **Wander SA**, Zhao D, Slingerland JM. p27: a barometer of signaling deregulation and potential predictor of response to targeted therapies. *Clin Cancer Res* 2011; **17**: 12-18 [PMID: 20966355 DOI: 10.1158/1078-0432.CCR-10-0752]

149 **Liu Z**, Long Y, Zhang Y, Huang W, Long X, Yang H, Long J, Cheng C, Fang W. Nuclear p27 expression confers a favorable outcome for nasopharyngeal carcinoma patients. *Dis Markers* 2013; **35**: 925-932 [PMID: 24427780 DOI: 10.1155/2013/251209]

150 **Shen J**, Yin JY, Li XP, Liu ZQ, Wang Y, Chen J, Qu J, Xu XJ, McLeod HL, He YJ, Xia K, Jia YW, Zhou HH. The prognostic value of altered eIF3a and its association with p27 in non-small cell lung cancers. *PLoS One* 2014; **9**: e96008 [PMID: 24789280 DOI: 10.1371/journal.pone.0096008]

151 **Watanabe A**, Suzuki H, Yokobori T, Tsukagoshi M, Altan B, Kubo N, Suzuki S, Araki K, Wada S, Kashiwabara K, Hosouchi Y, Kuwano H. Stathmin1 regulates p27 expression, proliferation and drug resistance, resulting in poor clinical prognosis in cholangiocarcinoma. *Cancer Sci* 2014; **105**: 690-696 [PMID: 24708177 DOI: 10.1111/cas.12417]

152 **Al-Maghrabi J**, Al-Ahwal M, Buhmeida A, Syrjänen K, Sibyani A, Emam E, Ghanim A, Al-Qahtani M. Expression of cell cycle regulators p21 and p27 as predictors of disease outcome in colorectal carcinoma. *J Gastrointest Cancer* 2012;

43: 279-287 [PMID: 21637966 DOI: 10.1007/s12029-011-9292-y]

153 **Farley J**, Smith LM, Darcy KM, Brady MF, Bell J, McGuire W, Birrer MJ. Nuclear P27 expression in benign, borderline (LMP) and invasive tumors of the ovary and its association with prognosis: a gynecologic oncology group study. *Gynecol Oncol* 2011; **121**: 395-401 [PMID: 21310472 DOI: 10.1016/j.ygyno.2010.11.023]

154 **Kruck S**, Merseburger AS, Hennenlotter J, Scharpf M, Eyrich C, Amend B, Sievert KD, Stenzl A, Bedke J. High cytoplasmic expression of p27(Kip1) is associated with a worse cancer-specific survival in clear cell renal cell carcinoma. *BJU Int* 2012; **109**: 1565-1570 [PMID: 21981759 DOI: 10.1111/j.1464-410X.2011.10649.x]

155 **Chen G**, Cheng Y, Zhang Z, Martinka M, Li G. Prognostic significance of cytoplasmic p27 expression in human melanoma. *Cancer Epidemiol Biomarkers Prev* 2011; **20**: 2212-2221 [PMID: 21828232 DOI: 10.1158/1055-9965.EPI-11-0472]

156 **Lee YH**, Heo JH, Kim TH, Kang H, Kim G, Kim J, Cho SH, An HJ. Significance of cell cycle regulatory proteins as malignant and prognostic biomarkers in ovarian epithelial tumors. *Int J Gynecol Pathol* 2011; **30**: 205-217 [PMID: 21464733 DOI: 10.1097/PGP.0b013e3182063e71]

157 **Singh SP**, Lipman J, Goldman H, Ellis FH, Aizenman L, Cangi MG, Signoretti S, Chiaur DS, Pagano M, Loda M. Loss or altered subcellular localization of p27 in Barrett's associated adenocarcinoma. *Cancer Res* 1998; **58**: 1730-1735 [PMID: 9563491]

158 **Nan KJ**, Jing Z, Gong L. Expression and altered subcellular localization of the cyclin-dependent kinase inhibitor p27Kip1 in hepatocellular carcinoma. *World J Gastroenterol* 2004; **10**: 1425-1430 [PMID: 15133847]

159 **Zhang J**, McCauley MJ, Maher LJ, Williams MC, Israeloff NE. Mechanism of DNA flexibility enhancement by HMGB proteins. *Nucleic Acids Res* 2009; **37**: 1107-1114 [PMID: 19129233 DOI: 10.1093/nar/gkn1011]

160 **Süren D**, Yıldırım M, Demirpençe Ö, Kaya V, Alikanoğlu AS, Bülbüller N, Yıldız M, Sezer C. The role of high mobility group box 1 (HMGB1) in colorectal cancer. *Med Sci Monit* 2014; **20**: 530-537 [PMID: 24681824 DOI: 10.12659/MSM.890531]

161 **Chen RC**, Yi PP, Zhou RR, Xiao MF, Huang ZB, Tang DL, Huang Y, Fan XG. The role of HMGB1-RAGE axis in migration and invasion of hepatocellular carcinoma cell lines. *Mol Cell Biochem* 2014; **390**: 271-280 [PMID: 24510323 DOI: 10.1007/s11010-014-1978-6]

162 **Tang D**, Kang R, Zeh HJ, Lotze MT. High-mobility group box 1 and cancer. *Biochim Biophys Acta* 2010; **1799**: 131-140 [PMID: 20123075 DOI: 10.1016/j.bbagrm.2009.11.014]

163 **Tang D**, Kang R, Zeh HJ, Lotze MT. High-mobility group box 1, oxidative stress, and disease. *Antioxid Redox Signal* 2011; **14**: 1315-1335 [PMID: 20969478 DOI: 10.1089/ars.2010.3356]

164 **Jiang W**, Wang Z, Li X, Li J, Huang Y, Fan X, Duan Y. Reduced high-mobility group box 1 expression induced by RNA interference inhibits the bioactivity of hepatocellular carcinoma cell line HCCLM3. *Dig Dis Sci* 2012; **57**: 92-98 [PMID: 22038506 DOI: 10.1007/s10620-011-1944-z]

165 **Dong YD**, Cui L, Peng CH, Cheng DF, Han BS, Huang F. Expression and clinical significance of HMGB1 in human liver cancer: Knockdown inhibits tumor growth and metastasis in vitro and in vivo. *Oncol Rep* 2013; **29**: 87-94 [PMID: 23042506 DOI: 10.3892/or.2012.2070]

166 **Wang C**, Tang C, Chang X, Li Z. [Effect of HMGB1 on invasion and migration of human hepatoma cell line HepG2 and its mechanism]. *Xibao Yu Fenzi Mianyixue Zazhi* 2013; **29**: 1159-1162 [PMID: 24200063]

167 **Yan W**, Chang Y, Liang X, Cardinal JS, Huang H, Thorne SH, Monga SP, Geller DA, Lotze MT, Tsung A. High-mobility group box 1 activates caspase-1 and promotes hepatocellular carcinoma invasiveness and metastases. *Hepatology* 2012; **55**: 1863-1875 [PMID: 22234969 DOI: 10.1002/hep.25572]

168 **Cheng BQ**, Jia CQ, Liu CT, Lu XF, Zhong N, Zhang ZL, Fan W, Li YQ. Serum high mobility group box chromosomal protein 1 is associated with clinicopathologic features in patients with hepatocellular carcinoma. *Dig Liver Dis* 2008; **40**: 446-452 [PMID: 18294942 DOI: 10.1016/j.dld.2007.11.024]

169 **Liu F**, Zhang Y, Peng Z, Gao H, Xu L, Chen M. High expression of high mobility group box 1 (hmgb1) predicts poor prognosis for hepatocellular carcinoma after curative hepatectomy. *J Transl Med* 2012; **10**: 135 [PMID: 22747650 DOI: 10.1186/1479-5876-10-135]

170 **Jiang W**, Wang Z, Li X, Fan X, Duan Y. High-mobility group box 1 is associated with clinicopathologic features in patients with hepatocellular carcinoma. *Pathol Oncol Res* 2012; **18**: 293-298 [PMID: 21953322 DOI: 10.1007/s12253-011-9442-3]

171 **Xiao J**, Ding Y, Huang J, Li Q, Liu Y, Ni W, Zhang Y, Zhu Y, Chen L, Chen B. The association of HMGB1 gene with the prognosis of HCC. *PLoS One* 2014; **9**: e89097 [PMID: 24586525 DOI: 10.1371/journal.pone.0089097]

172 **Adhikari AS**, Agarwal N, Iwakuma T. Metastatic potential of tumor-initiating cells in solid tumors. *Front Biosci* (Landmark Ed) 2011; **16**: 1927-1938 [PMID: 21196274 DOI: 10.2741/3831]

173 **Guo W**. Concise review: breast cancer stem cells: regulatory networks, stem cell niches, and disease relevance. *Stem Cells Transl Med* 2014; **3**: 942-948 [PMID: 24904174 DOI: 10.5966/sctm.2014-0020]

174 **Naujokat C**. Monoclonal antibodies against human cancer stem cells. *Immunotherapy* 2014; **6**: 290-308 [PMID: 24762074 DOI: 10.2217/imt.14.4]

175 **Shen Y**, Cao D. Hepatocellular carcinoma stem cells: origins and roles in hepatocarcinogenesis and disease progression. *Front Biosci* (Elite Ed) 2012; **4**: 1157-1169 [PMID: 22201943 DOI: 10.2741/E448]

176 **Yamashita T**, Wang XW. Cancer stem cells in the development of liver cancer. *J Clin Invest* 2013; **123**: 1911-1918 [PMID: 23635789 DOI: 10.1172/JCI66024]

177 **Yeh CT**, Kuo CJ, Lai MW, Chen TC, Lin CY, Yeh TS, Lee WC. CD133-positive hepatocellular carcinoma in an area endemic for hepatitis B virus infection. *BMC Cancer* 2009; **9**: 324 [PMID: 19744348 DOI: 10.1186/1471-2407-9-324]

178 **Yang XR**, Xu Y, Yu B, Zhou J, Qiu SJ, Shi GM, Zhang BH, Wu WZ, Shi YH, Wu B, Yang GH, Ji Y, Fan J. High expression levels of putative hepatic stem/progenitor cell biomarkers related to tumour angiogenesis and poor prognosis of hepatocellular carcinoma. *Gut* 2010; **59**: 953-962 [PMID: 20442200 DOI: 10.1136/gut.2008.176271]

179 **Bae JS**, Noh SJ, Jang KY, Park HS, Chung MJ, Park CK, Moon WS. Expression and role of epithelial cell adhesion molecule in dysplastic nodule and hepatocellular carcinoma. *Int J Oncol* 2012; **41**: 2150-2158 [PMID: 22993038 DOI: 10.3892/ijo.2012.1631]

180 **Kim H**, Choi GH, Na DC, Ahn EY, Kim GI, Lee JE, Cho JY, Yoo JE, Choi JS, Park YN. Human hepatocellular carcinomas with "Stemness"-related marker expression: keratin 19 expression and a poor prognosis. *Hepatology* 2011; **54**: 1707-1717 [PMID: 22045674 DOI: 10.1002/hep.24559]

181 **Izumi N**. Prediction and prevention of intrahepatic recurrence of hepatocellular carcinoma. *Hepatol Res* 2012; **42**: 226-232 [PMID: 22181559 DOI: 10.1111/j.1872-034X.2011.00922.x]

182 **Zhang KZ**, Zhang QB, Zhang QB, Sun HC, Ao JY, Chai ZT, Zhu XD, Lu L, Zhang YY, Bu Y, Kong LQ, Tang ZY. Arsenic trioxide induces differentiation of CD133+ hepatocellular carcinoma cells and prolongs posthepatectomy survival by targeting GLI1 expression in a mouse model. *J Hematol Oncol* 2014; **7**: 28 [PMID: 24678763 DOI: 10.1186/1756-8722-7-28]

183 **Shi JH**, Scholz H, Huitfeldt HS, Line PD. The effect of hepatic progenitor cells on experimental hepatocellular carcinoma in the regenerating liver. *Scand J Gastroenterol* 2014; **49**: 99-108 [PMID: 24188385 DOI: 10.3109/00365521.201

3.854406]
184 **Tsuchiya A**, Kamimura H, Takamura M, Yamagiwa S, Matsuda Y, Sato Y, Nomoto M, Ichida T, Aoyagi Y. Clinicopathological analysis of CD133 and NCAM human hepatic stem/progenitor cells in damaged livers and hepatocellular carcinomas. *Hepatol Res* 2009; **39**: 1080-1090 [PMID: 19619253 DOI: 10.1111/j.1872-034X.2009.00559.x]
185 **Song W**, Li H, Tao K, Li R, Song Z, Zhao Q, Zhang F, Dou K. Expression and clinical significance of the stem cell marker CD133 in hepatocellular carcinoma. *Int J Clin Pract* 2008; **62**: 1212-1218 [PMID: 18479363 DOI: 10.1111/j.1742-1241.2008.01777.x]
186 **Guo Z**, Li LQ, Jiang JH, Ou C, Zeng LX, Xiang BD. Cancer stem cell markers correlate with early recurrence and survival in hepatocellular carcinoma. *World J Gastroenterol* 2014; **20**: 2098-2106 [PMID: 24616575 DOI: 10.3748/wjg.v20.i8.2098]
187 **Sasaki A**, Kamiyama T, Yokoo H, Nakanishi K, Kubota K, Haga H, Matsushita M, Ozaki M, Matsuno Y, Todo S. Cytoplasmic expression of CD133 is an important risk factor for overall survival in hepatocellular carcinoma. *Oncol Rep* 2010; **24**: 537-546 [PMID: 20596644 DOI: 10.3892/or_00000890]
188 **Chan AW**, Tong JH, Chan SL, Lai PB, To KF. Expression of stemness markers (CD133 and EpCAM) in prognostication of hepatocellular carcinoma. *Histopathology* 2014; **64**: 935-950 [PMID: 24506513 DOI: 10.1111/his.12342]
189 **Kimura O**, Kondo Y, Kogure T, Kakazu E, Ninomiya M, Iwata T, Morosawa T, Shimosegawa T. Expression of EpCAM increases in the hepatitis B related and the treatment-resistant hepatocellular carcinoma. *Biomed Res Int* 2014; **2014**: 172913 [PMID: 24696843 DOI: 10.1155/2014/172913]
190 **Terris B**, Cavard C, Perret C. EpCAM, a new marker for cancer stem cells in hepatocellular carcinoma. *J Hepatol* 2010; **52**: 280-281 [PMID: 20006402 DOI: 10.1016/j.jhep.2009.10.026]
191 **Kimura O**, Takahashi T, Ishii N, Inoue Y, Ueno Y, Kogure T, Fukushima K, Shiina M, Yamagiwa Y, Kondo Y, Inoue J, Kakazu E, Iwasaki T, Kawagishi N, Shimosegawa T, Sugamura K. Characterization of the epithelial cell adhesion molecule (EpCAM)+ cell population in hepatocellular carcinoma cell lines. *Cancer Sci* 2010; **101**: 2145-2155 [PMID: 20707805 DOI: 10.1111/j.1349-7006.2010.01661.x]
192 **Shan YF**, Huang YL, Xie YK, Tan YH, Chen BC, Zhou MT, Shi HQ, Yu ZP, Song QT, Zhang QY. Angiogenesis and clinicopathologic characteristics in different hepatocellular carcinoma subtypes defined by EpCAM and α-fetoprotein expression status. *Med Oncol* 2011; **28**: 1012-1016 [PMID: 20571936 DOI: 10.1007/s12032-010-9600-6]
193 **Chung GE**, Lee JH, Yoon JH, Myung SJ, Lee K, Jang JJ, Lee JM, Kim SH, Suh KS, Kim YJ, Lee HS. Prognostic implications of tumor vascularity and its relationship to cytokeratin 19 expression in patients with hepatocellular carcinoma. *Abdom Imaging* 2012; **37**: 439-446 [PMID: 21584634 DOI: 10.1007/s00261-011-9756-3]
194 **Yang XR**, Xu Y, Shi GM, Fan J, Zhou J, Ji Y, Sun HC, Qiu SJ, Yu B, Gao Q, He YZ, Qin WZ, Chen RX, Yang GH, Wu B, Lu Q, Wu ZQ, Tang ZY. Cytokeratin 10 and cytokeratin 19: predictive markers for poor prognosis in hepatocellular carcinoma patients after curative resection. *Clin Cancer Res* 2008; **14**: 3850-3859 [PMID: 18559605 DOI: 10.1158/1078-0432.CCR-07-4338]
195 **Ariizumi S**, Kotera Y, Katagiri S, Nakano M, Yamamoto M. Combined hepatocellular-cholangiocarcinoma had poor outcomes after hepatectomy regardless of Allen and Lisa class or the predominance of intrahepatic cholangiocarcinoma cells within the tumor. *Ann Surg Oncol* 2012; **19**: 1628-1636 [PMID: 22113592 DOI: 10.1245/s10434-011-2150-0]
196 **Andersen JB**, Loi R, Perra A, Factor VM, Ledda-Columbano GM, Columbano A, Thorgeirsson SS. Progenitor-derived hepatocellular carcinoma model in the rat. *Hepatology* 2010; **51**: 1401-1409 [PMID: 20054870 DOI: 10.1002/hep.23488]
197 **Xu M**, Xie F, Qian G, Jing Y, Zhang S, Gao L, Zheng T, Wu M, Yang J, Wei L. Peritumoral ductular reaction: a poor postoperative prognostic factor for hepatocellular carcinoma. *BMC Cancer* 2014; **14**: 65 [PMID: 24495509 DOI: 10.1186/1471-2407-14-65]
198 **Lee CW**, Kuo WL, Yu MC, Chen TC, Tsai CN, Lee WC, Chen MF. The expression of cytokeratin 19 in lymph nodes was a poor prognostic factor for hepatocellular carcinoma after hepatic resection. *World J Surg Oncol* 2013; **11**: 136 [PMID: 23758804 DOI: 10.1186/1477-7819-11-136]
199 **Wang ZS**, Wu LQ, Yi X, Geng C, Li YJ, Yao RY, Hu WY, Han B. [CK19 can be used to predict the early recurrence and prognosis of HBV-related hepatocellular carcinoma patients with low AFP serum concentration after R0 radical hepatectomy]. *Zhonghua Zhongliu Zazhi* 2012; **34**: 753-758 [PMID: 23291069 DOI: 10.3760/cma.j.issn.0253-3766.2012.10.008]
200 **Yuan RH**, Jeng YM, Hu RH, Lai PL, Lee PH, Cheng CC, Hsu HC. Role of p53 and β-catenin mutations in conjunction with CK19 expression on early tumor recurrence and prognosis of hepatocellular carcinoma. *J Gastrointest Surg* 2011; **15**: 321-329 [PMID: 21061181 DOI: 10.1007/s11605-010-1373-x]
201 **Xiang ZL**, Zeng ZC, Tang ZY, Fan J, Sun HC, Wu WZ, Tan YS. [Nuclear accumulation of CXCR4 and overexpressions of VEGF-C and CK19 are associated with a higher risk of lymph node metastasis in hepatocellular carcinoma]. *Zhonghua Zhongliu Zazhi* 2010; **32**: 344-349 [PMID: 20723431]
202 **Zhuang PY**, Zhang JB, Zhu XD, Zhang W, Wu WZ, Tan YS, Hou J, Tang ZY, Qin LX, Sun HC. Two pathologic types of hepatocellular carcinoma with lymph node metastasis with distinct prognosis on the basis of CK19 expression in tumor. *Cancer* 2008; **112**: 2740-2748 [PMID: 18412155 DOI: 10.1002/cncr.23488]
203 **Ji J**, Wang XW. Clinical implications of cancer stem cell biology in hepatocellular carcinoma. *Semin Oncol* 2012; **39**: 461-472 [PMID: 22846863 DOI: 10.1053/j.seminoncol.2012.05.011]
204 **Zhang L**, Liu H, Sun L, Li N, Ding H, Zheng J. Glypican-3 as a potential differential diagnosis marker for hepatocellular carcinoma: a tissue microarray-based study. *Acta Histochem* 2012; **114**: 547-552 [PMID: 22119409 DOI: 10.1016/j.actbis.2011.10.003]
205 **Nassar A**, Cohen C, Siddiqui MT. Utility of glypican-3 and survivin in differentiating hepatocellular carcinoma from benign and preneoplastic hepatic lesions and metastatic carcinomas in liver fine-needle aspiration biopsies. *Diagn Cytopathol* 2009; **37**: 629-635 [PMID: 19405109 DOI: 10.1002/dc.21075]
206 **Liu H**, Li P, Zhai Y, Qu CF, Zhang LJ, Tan YF, Li N, Ding HG. Diagnostic value of glypican-3 in serum and liver for primary hepatocellular carcinoma. *World J Gastroenterol* 2010; **16**: 4410-4415 [PMID: 20845507 DOI: 10.3748/wjg.v16.i35.4410]
207 **Filmus J**, Capurro M. Glypican-3: a marker and a therapeutic target in hepatocellular carcinoma. *FEBS J* 2013; **280**: 2471-2476 [PMID: 23305321 DOI: 10.1111/febs.12126]
208 **Shirakawa H**, Suzuki H, Shimomura M, Kojima M, Gotohda N, Takahashi S, Nakagohri T, Konishi M, Kobayashi N, Kinoshita T, Nakatsura T. Glypican-3 expression is correlated with poor prognosis in hepatocellular carcinoma. *Cancer Sci* 2009; **100**: 1403-1407 [PMID: 19496787 DOI: 10.1111/j.1349-7006.2009.01206.x]
209 **Shirakawa H**, Kuronuma T, Nishimura Y, Hasebe T, Nakano M, Gotohda N, Takahashi S, Nakagohri T, Konishi M, Kobayashi N, Kinoshita T, Nakatsura T. Glypican-3 is a useful diagnostic marker for a component of hepatocellular carcinoma in human liver cancer. *Int J Oncol* 2009; **34**: 649-656 [PMID: 19212669]
210 **Du JL**, Wang YL, Shi HY, Guo AT, Wei LX. [Expression of

glypican-3, hepatocyte antigen, alpha-fetoprotein, CD34 and CD10 in hepatocellular carcinoma: a clinicopathologic analysis of 375 cases]. *Zhonghua Binglixue Zazhi* 2012; **41**: 309-313 [PMID: 22883669 DOI: 10.3760/cma.j.issn.0529-5807.2012.05.006]

211 **Fu SJ**, Qi CY, Xiao WK, Li SQ, Peng BG, Liang LJ. Glypican-3 is a potential prognostic biomarker for hepatocellular carcinoma after curative resection. *Surgery* 2013; **154**: 536-544 [PMID: 23601901 DOI: 10.1016/j.surg.2013.02.014]

212 **Ning S**, Bin C, Na H, Peng S, Yi D, Xiang-hua Y, Fang-yin Z, Da-yong Z, Rong-cheng L. Glypican-3, a novel prognostic marker of hepatocellular cancer, is related with postoperative metastasis and recurrence in hepatocellular cancer patients. *Mol Biol Rep* 2012; **39**: 351-357 [PMID: 21655958 DOI: 10.1007/s11033-011-0745-y]

213 **Yorita K**, Takahashi N, Takai H, Kato A, Suzuki M, Ishiguro T, Ohtomo T, Nagaike K, Kondo K, Chijiiwa K, Kataoka H. Prognostic significance of circumferential cell surface immunoreactivity of glypican-3 in hepatocellular carcinoma. *Liver Int* 2011; **31**: 120-131 [PMID: 20964802 DOI: 10.1111/j.1478-3231.2010.02359.x]

214 **Serrels A**, Macpherson IR, Evans TR, Lee FY, Clark EA, Sansom OJ, Ashton GH, Frame MC, Brunton VG. Identification of potential biomarkers for measuring inhibition of Src kinase activity in colon cancer cells following treatment with dasatinib. *Mol Cancer Ther* 2006; **5**: 3014-3022 [PMID: 17148760 DOI: 10.1158/1535-7163.MCT-06-0382]

215 **Villanueva A**, Chiang DY, Newell P, Peix J, Thung S, Alsinet C, Tovar V, Roayaie S, Minguez B, Sole M, Battiston C, Van Laarhoven S, Fiel MI, Di Feo A, Hoshida Y, Yea S, Toffanin S, Ramos A, Martignetti JA, Mazzaferro V, Bruix J, Waxman S, Schwartz M, Meyerson M, Friedman SL, Llovet JM. Pivotal role of mTOR signaling in hepatocellular carcinoma. *Gastroenterology* 2008; **135**: 1972-1983, 1983.e1-11 [PMID: 18929564 DOI: 10.1053/j.gastro.2008.08.008]

216 **Zhou L**, Huang Y, Li J, Wang Z. The mTOR pathway is associated with the poor prognosis of human hepatocellular carcinoma. *Med Oncol* 2010; **27**: 255-261 [PMID: 19301157 DOI: 10.1007/s12032-009-9201-4]

217 **Calvisi DF**, Ladu S, Gorden A, Farina M, Lee JS, Conner EA, Schroeder I, Factor VM, Thorgeirsson SS. Mechanistic and prognostic significance of aberrant methylation in the molecular pathogenesis of human hepatocellular carcinoma. *J Clin Invest* 2007; **117**: 2713-2722 [PMID: 17717605 DOI: 10.1172/JCI31457]

218 **Nakanishi K**, Sakamoto M, Yamasaki S, Todo S, Hirohashi S. Akt phosphorylation is a risk factor for early disease recurrence and poor prognosis in hepatocellular carcinoma. *Cancer* 2005; **103**: 307-312 [PMID: 15593087 DOI: 10.1002/cncr.20774]

219 **Rowinsky EK**. Targeting the molecular target of rapamycin (mTOR). *Curr Opin Oncol* 2004; **16**: 564-575 [PMID: 15627018 DOI: 10.1097/01.cco.0000143964.74936.d1]

220 **Vignot S**, Faivre S, Aguirre D, Raymond E. mTOR-targeted therapy of cancer with rapamycin derivatives. *Ann Oncol* 2005; **16**: 525-537 [PMID: 15728109 DOI: 10.1093/annonc/mdi113]

221 **Cervello M**, McCubrey JA, Cusimano A, Lampiasi N, Azzolina A, Montalto G. Targeted therapy for hepatocellular carcinoma: novel agents on the horizon. *Oncotarget* 2012; **3**: 236-260 [PMID: 22470194]

222 **Sahin F**, Kannangai R, Adegbola O, Wang J, Su G, Torbenson M. mTOR and P70 S6 kinase expression in primary liver neoplasms. *Clin Cancer Res* 2004; **10**: 8421-8425 [PMID: 15623621 DOI: 10.1158/1078-0432.CCR-04-0941]

223 **Baba HA**, Wohlschlaeger J, Cicinnati VR, Hilgard P, Lang H, Sotiropoulos GC, Takeda A, Beckebaum S, Schmitz KJ. Phosphorylation of p70S6 kinase predicts overall survival in patients with clear margin-resected hepatocellular carcinoma. *Liver Int* 2009; **29**: 399-405 [PMID: 18492014 DOI: 10.1111/j.1478-3231.2008.01798.x]

224 **Chang Q**, Chen J, Beezhold KJ, Castranova V, Shi X, Chen F. JNK1 activation predicts the prognostic outcome of the human hepatocellular carcinoma. *Mol Cancer* 2009; **8**: 64 [PMID: 19686584 DOI: 10.1186/1476-4598-8-64]

225 **Wang Z**, Jin W, Jin H, Wang X. mTOR in viral hepatitis and hepatocellular carcinoma: function and treatment. *Biomed Res Int* 2014; **2014**: 735672 [PMID: 24804240 DOI: 10.1155/2014/735672]

226 **Matter MS**, Decaens T, Andersen JB, Thorgeirsson SS. Targeting the mTOR pathway in hepatocellular carcinoma: current state and future trends. *J Hepatol* 2014; **60**: 855-865 [PMID: 24308993 DOI: 10.1016/j.jhep.2013.11.031]

227 **Fleming S**, Mayer NJ, Vlatkovic LJ, McLean J, McConachie M, Baty D. Signalling pathways in succinate dehydrogenase B-associated renal carcinoma. *Histopathology* 2014; **64**: 477-483 [PMID: 24236567 DOI: 10.1111/his.12250]

228 **Prodromidis G**, Nikitakis NG, Sklavounou A. Immunohistochemical Analysis of the Activation Status of the Akt/mTOR/pS6 Signaling Pathway in Oral Lichen Planus. *Int J Dent* 2013; **2013**: 743456 [PMID: 24228033]

229 **Rouleau C**, Rico C, Hapkova I, de Santa Barbara P. Immunohistochemical analysis of bone morphological protein signaling pathway in human myometrium. *Exp Mol Pathol* 2012; **93**: 56-60 [PMID: 22537545 DOI: 10.1016/j.yexmp.2012.04.007]

230 **Siddiqui S**, Rimm DL. Pre-analytic variables and phospho-specific antibodies: the Achilles heel of immunohistochemistry. *Breast Cancer Res* 2010; **12**: 113 [PMID: 21176180 DOI: 10.1186/bcr2782]

231 **Schoephoerster J**, Frisch J, Grahek M, Wu C, He Y, Wang W, Nguyen J, Schwartz D, Kalyuzhny AE. Absorption control in immunohistochemistry using phospho-peptides immobilized on magnetic beads. *Methods Mol Biol* 2011; **717**: 291-300 [PMID: 21370038 DOI: 10.1007/978-1-61779-024-9_17]

232 **O'Hurley G**, Sjöstedt E, Rahman A, Li B, Kampf C, Pontén F, Gallagher WM, Lindskog C. Garbage in, garbage out: a critical evaluation of strategies used for validation of immunohistochemical biomarkers. *Mol Oncol* 2014; **8**: 783-798 [PMID: 24725481 DOI: 10.1016/j.molonc.2014.03.008]

233 **Gish RG**. Early detection of hepatocellular carcinoma through surveillance using biomarkers. *Gastroenterol Hepatol* (N Y) 2014; **10**: 121-123 [PMID: 24803876]

P- Reviewer: Hoare M, Lin ZY, Minuk G, Zhu X
S- Editor: Tian YL **L- Editor**: A **E- Editor**: Liu SQ

World Journal of Hepatology

Submit a Manuscript: http://www.wjgnet.com/esps/
Help Desk: http://www.wjgnet.com/esps/helpdesk.aspx
DOI: 10.4254/wjh.v7.i1.70

World J Hepatol 2015 January 27; 7(1): 70-77
ISSN 1948-5182 (online)

TOPIC HIGHLIGHT

WJH 6th Anniversary Special Issues (5): Hepatitis C virus

Surgical approach for hepatitis C virus-related hepatocellular carcinoma

Junichi Shindoh, Masaji Hashimoto, Goro Watanabe

Junichi Shindoh, Masaji Hashimoto, Goro Watanabe, Hepatobiliary-pancreatic Surgery Division, Department of Digestive Surgery, Toranomon Hospital, Tokyo 105-8470, Japan
Junichi Shindoh, Okinaka Memorial Research Center for Adult Diseases, Tokyo 105-8470, Japan
Author contributions: Shindoh J, Hashimoto M and Watanabe G contributed to this paper.
Supported by Grand-in-aid for Science Research from the Japanese Ministry of Education, Culture, Sports, Science and Technology, No. 26861063

Correspondence to: Junichi Shindoh, MD, PhD, Hepatobiliary-pancreatic Surgery Division, Department of Digestive Surgery, Toranomon Hospital, 2-2-2 Toranomon, Minato-ku, Tokyo 105-8470, Japan. shindou-tky@umin.ac.jp
Telephone: +81-3-35881111
Fax: +81-3-35881111
Received: August 19, 2014
Peer-review started: August 20, 2014
First decision: October 14, 2014
Revised: October 30, 2014
Accepted: November 17, 2014
Article in press: November 19, 2014
Published online: January 27, 2015

Abstract

Hepatitis C is a strong prognostic factor for patients with hepatocellular carcinoma (HCC). Although liver resection and liver transplantation offer the chance of a cure for HCC, adequate management of co-existing infection with hepatitis C virus (HCV) is important to enable better long-term outcomes after surgery for HCV-related HCC. For patients undergoing liver resection, perioperative anti-viral treatment is recommended, since a decreased HCV viral load itself is reportedly associated with a lower tumor recurrence rate and a longer overall survival. For patients undergoing transplanatations for HCC complicated by end-stage liver disease, the post-transplant management of HCV infection is also necessary to prevent progressive graft injury caused by active hepatitis under the immunosuppressive condition that is needed after liver transplantation. Although only a few lines of solid evidence are available for postoperative antiviral treatment because of the limited indication and frequent adverse events caused by conventional high-dose combination interferon therapy, new direct acting anti-viral agents would enable interferon-free anti-viral treatment with a higher virologic response and minimal side effects.

Key words: Hepatocellular carcinoma; Hepatitis C; Liver resection; Liver transplantation; Adjuvant therapy

Core tip: Hepatitis C infection is associated with a poor survival outcome after curative surgical resection or liver transplantation in patients with hepatocellular carcinoma (HCC). For patients undergoing liver resection, the adequate perioperative management of hepatitis C is vital for reducing the carcinogenic potential of the liver remnant and obtaining a longer disease-free interval. For patients undergoing transplantations for HCC with end-stage liver disease, the control of hepatitis C is also needed to avoid progressive graft dysfunction because of active hepatitis under immunosuppressive condition.

Shindoh J, Hashimoto M, Watanabe G. Surgical approach for hepatitis C virus-related hepatocellular carcinoma. *World J Hepatol* 2015; 7(1): 70-77 Available from: URL: http://www.

wjgnet.com/1948-5182/full/v7/i1/70.htm DOI: http://dx.doi.org/10.4254/wjh.v7.i1.70

INTRODUCTION

Primary liver cancer is one of the most common solid tumors and is the second leading cause of cancer-related deaths worldwide[1]. Despite recent developments in the prevention and treatment of viral hepatitis, approximately 746000 deaths were reported in 2012 among patients with primary liver cancer. Nowadays, various treatment options are available for the most common type of primary liver cancer, hepatocellular carcinoma (HCC), including surgical resection, ablation therapies, arterial chemoembolization, radioembolization, and systemic therapies. However, the presence of chronic liver disease in the underlying liver and a high tumor recurrence rate even after curative-intent treatment make the management of HCC difficult[2,3].

HCC usually arises in liver tissue that has been injured because of chronic hepatitis or cirrhosis; accordingly, the impaired hepatic functional reserve often precludes curative treatment options. Therefore, several clinical algorithms have been proposed for the optimal selection of HCC treatments, with consideration given to (1) the size and number of tumors; (2) the presence of extra-hepatic disease; (3) the hepatic functional reserve; and (4) the performance status of the patient[4,5]. Currently, surgical resection and liver transplantation are the two mainstays of surgical treatment for patients with a limited number of HCC lesions. These approaches may offer a higher chance of a cure through the eradication of micrometastases surrounding the main tumor, thereby improving the recurrence-free survival rate compared with those after ablation therapies[6-10]. However, the presence of hepatitis C virus (HCV) is significantly related to a poor survival outcome, compared with other etiologies of HCC, among patients undergoing liver resection[11] or liver transplantation[10]. Therefore, careful perioperative management is required for patients with HCV-related HCC.

Because persistent viremia and active hepatitis after surgical resection are thought to be potent risk factors for progressive histopathologic injury and multicentric carcinogenesis in the underlying liver, adjuvant antiviral therapy is theoretically preferable after curative treatment for HCV-related HCC. Nevertheless, only a few lines of evidence regarding the efficacy of postoperative antiviral therapy are available[12,13] partially because of the limited indication for conventional high-dose antiviral therapy among elderly or cirrhotic patients and the genetic variability of HCV, which determines its refractoriness to interferon (IFN)-based combination therapies. In the present era of new direct-acting antiviral agents (DAAs), however, the virologic response rate has been dramatically improved[14-16] and these new drugs may change the current perioperative management of HCV-related HCC. The purpose of this review was to summarize the clinical features of HCV-related HCC, to clarify the current clinical problems, and to discuss optimal surgical approaches based on reported evidence.

RESEARCH

The MEDLINE electronic database for English-language articles was searched for reports published between January 1991 and October 2014 by using the keywords "hepatocellular carcinoma", "hepatitis C", and "surgery". The reference lists of the relevant articles were also scanned for additional studies.

CLINICAL FEATURES OF HCV-RELATED HCC

Differences in the etiologies and pathogenic mechanisms of carcinogenesis may reflect the clinical characteristics of HCC[17-19]. Hepatitis C is one of the leading causes of HCC[20] and a Japanese nationwide survey performed by the Liver Cancer Study Group of Japan (LCSGJ) reported that 67.7% of patients with HCC were positive for hepatitis C[21]. Patients infected with HCV reportedly have a higher risk of HCC compared with those infected with HBV[22-24]. This situation can probably be explained by the fact that no effective treatment for hepatitis C that can be used for all patients with minimal adverse events has been available until recently.

When a patient is diagnosed as having HCC, the current clinical algorithms[4,5,25] offer similar therapeutic options irrespective of the etiology of the disease. However, several studies have reported that HCC emerging on a background of viral hepatitis was associated with a poorer long-term survival, compared with HCC without viral hepatitis[26-29]. A recent large cohort study from LCSGJ has shown that hepatitis C infection is a significant prognostic factor and that HCV-related HCC was associated with poorer survival outcomes in terms of both the recurrence-free survival rate and the overall survival rate after surgical resection, compared with those of HCC patients without viral hepatitis[11].

Given these natural history and clinical features of HCV-related HCC, the management of patients should be considered in terms of the following 3 steps: (1) treatment BEFORE emerging HCC; (2) treatment FOR HCC; and (3) adjuvant management AFTER treatment for HCC.

MANAGEMENT OF PATIENTS WITH CHRONIC HEPATITIS C INFECTION-TREATMENT BEFORE EMERGING HCC

A recent meta-analysis has reported that a sustained virologic response (SVR) after treatment for HCV is associated with a reduced incidence of HCC at any stage of fibrosis[30]. Conventionally, combination therapy using

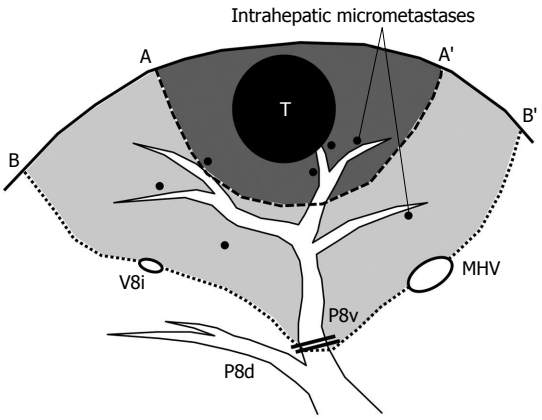

Figure 1 Concept of anatomic resection of the liver. This schema shows an example of resection for hepatocellular carcinoma located in ventral part of Segment Ⅷ. The line A-A' indicates non-anatomic limited resection with adequate surgical margin and the line B-B' represents anatomic resection of ventral part of Segment Ⅷ. Because the "tumor-bearing" portal territory is at high risk of harboring micrometastases scattered *via* portal veins, systematic removal of the corresponding portal region would offer higher chance of eradicating cancer cells. T: Tumor; P8v: Ventral branch of Segment Ⅷ portal pedicle; P8d: Dorsal branch of Segment Ⅷ portal pedicle; MHV: Middle hepatic vein; V8i: Intermediate vein for Segment Ⅷ.

IFN and ribavirin has been used for patients with chronic active hepatitis C. However, the SVR rate associated with the conventional IFN-based treatment was not satisfactory because of the high prevalence of HCV genotype 1b which is associated with a poor response to anti-viral therapy. Also, adverse effects such as fever, pancytopenia, interstitial pneumonia, and depression, frequently preclude treatment with an adequate intensity and duration in elderly and cirrhotic patients.

However, with the recent introduction of DAAs, the SVR rate of HCV has changed dramatically, and adverse events caused by conventional IFN-based therapies have been avoided using these new IFN-free regimens[14-16]. Although the efficacy of these new drugs with regard to the incidence of HCC needs to be clarified in the near future, anti-viral treatment is recommended for all patients with serologically positive hepatitis C based on the expected reduction in the carcinogenic potential of the underlying liver tissue.

TREATMENT ALGORITHM FOR HCC AND INDICATIONS FOR SURGERY

When HCC is diagnosed incidentally or during a follow-up examination for chronic liver disease, the optimal treatment options are selected according to the oncologic and physical status of the patient. In the Barcelona Clinic Liver Cancer (BCLC) algorithm[5,25], surgical resection is indicated for patients with a good performance status and solitary HCC when there is no evidence of portal hypertension. Liver transplantation is recommended for patients with HCC who meet the Milan criteria (solitary tumor ≤ 5 cm or ≤ 3 tumors with each tumor ≤ 3 cm)[31], regardless of the hepatic functional reserve. In the guideline for liver cancer treatment proposed by the Japan Society of Hepatology[4], surgical resection is currently indicated for Child-Pugh class A or class B patients with HCC less than or equal to 3 nodules irrespective of the size of each tumor, while liver transplantation is limited to only Child-Pugh class C patients who meet the Milan criteria.

LIVER RESECTION FOR HCC

Liver resection is usually indicated for patients with oligonodular HCC and a preserved hepatic functional reserve[4,5,25]. Portal hypertension is basically considered to be a contraindication for surgery. However, favorable surgical outcomes have also been reported in a carefully selected population with portal hypertension who received meticulous perioperative management[32]. The basic principles of liver resection are not influenced by the etiologies of HCC. However, careful preoperative assessment and surgical planning are needed to maximize both the surgical curability and the safety of the surgery.

To secure the curability of surgery, an accurate preoperative assessment of the tumor extent is important. Dynamic computed tomography (CT) and enhanced magnetic resonance imaging (MRI) can sensitively delineate HCCs, and ultrasonography allows surgeons to confirm the three-dimensional (3-D) relationship between the tumors and the surrounding major vascular structures. In these imaging studies, the location of the tumor should be described according to the Couinaud's classification of liver segments for the adequate selection of surgical maneuvers. Because HCC tends to spread *via* portal veins, the "anatomic resection" of the tumor-bearing portal territory (Figure 1) is a theoretically reasonable approach for HCC. Although the true efficacy of anatomic resection remains uncertain, various studies have reported a superior outcome after anatomic resection with an apparently lower rate of local recurrence, compared with non-anatomic limited resections of the liver[33-35].

Next to these accurate assessments of tumor distribution and the selection of a surgical maneuver for a cure, the risk of resection should be evaluated using systematic volumetry and hepatic functional tests such as the indocyanine green clearance test or ^{99m}Tc-GSA scintigraphy. Because the excessive removal of the hepatic parenchyma increases the risk of postoperative hepatic insufficiency according to the quality of the underlying liver[36-39], the extent of the resection should be balanced between the surgical curability and the hepatic functional reserve[40].

With recent developments in 3-D simulation techniques, surgical planning procedures have become easier through the simulation of various hepatic resections on a computer prior to surgery. This technique offers accurate anatomic confirmation and automatic calculation of the absolute volume of an interested part of the liver. When planning a complex anatomic resection, preoperative 3-D liver simulation is mandatory and volume estimation

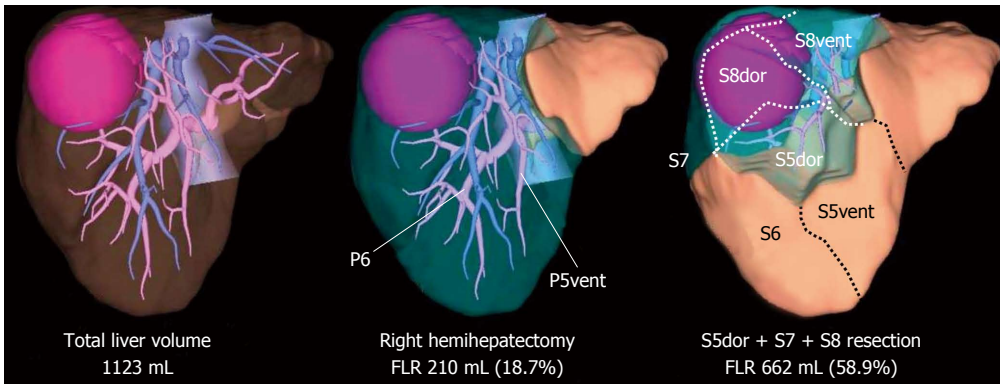

Figure 2 Surgical planning by three-dimensional simulation technique. The three-dimensional liver simulation enables virtual hepatectomy and volume estimation of future liver remnant (FLR). In this case, a large hepatocellular carcinoma is located in segment 7 and 8, and partially extending to dorsal part of segment 5. Right hemihepatectomy is impossible due to very small FLR volume. However, when preserving the territory fed by a thick ventral branch for segment 5 (P5vent) and segment 6, the tumor is resectable leaving sufficient volume of the liver parenchyma. S5vent: Ventral part of segment 5; S5dor: Dorsal part of segment 5; S8vent: Ventral part of segment 8; S8dor: Dorsal part of segment 8.

using the simulation software is helpful in determining the surgical indications, especially for patients with a marginal hepatic functional reserve (Figure 2).

LIVER TRANSPLANTATION FOR HCC

Liver transplantation is a reasonable approach with a theoretically higher chance of tumor eradication, especially in patients with severe hepatic dysfunction. The clinical outcomes of liver transplantation for HCC were initially poor in the early era of this treatment[41,42]. However, since the publication of the landmark study by Mazzaferro *et al*[31] it has become widely recognized that preferable survival outcomes can be expected in a selected population with a limited tumor size and number of HCCs (Milan criteria). Nowadays, these criteria have been extended including tumor markers or biopsy findings in several high-volume transplant centers[43-50].

Several studies have suggested that HCV infection has an additional negative impact on the outcomes of patients undergoing transplantations for HCC[51-54], and other studies have reported similar survival outcomes in HCV and non-HCV patients with HCC[55,56]. Small sample sizes, heterogeneous populations, and non-adjustments for multiple confounders in liver transplant recipients may explain these variations in observations. However, both HCC and HCV seem to have a deleterious impact on long-term patient and graft survival. Dumitra *et al*[57] reviewed 601 liver transplant recipients and reported that the coexistence of HCC and HCV had the largest deleterious impact on the long-term survival rate, doubling the risk of mortality after liver transplantation.

With the introduction of DAAs, however, the safety and efficacy of protease inhibitors compared with conventional combination therapy with IFN and ribavirin have been reported in patients undergoing liver transplantation for hepatitis C[58]. Because the deleterious effect of HCV can be attributed to uncontrollable viremia after transplantation, these new effective drugs could improve the long-term outcomes of liver transplant recipients complicated with HCC and end-stage liver disease.

SIGNIFICANCE OF POSTOPERATIVE HCV VIRAL LOAD AND ADJUVANT ANTI-VIRAL THERAPY

Although adequate surgical intervention contributes to an improvement in long-term survival, the postoperative management of hepatitis C is also important for patients with HCV-related HCC. After liver resection, HCC shows two modes of recurrence: recurrence from residual intrahepatic micrometastases, and neocarcinogenesis in the underlying liver. The former type of recurrence can be reduced by adequate surgical maneuvers and the complete removal of the hepatic parenchyma, including both the main tumor and the surrounding latent micrometastases, while the latter type of recurrence is closely associated with the carcinogenic potential of the underlying liver itself. Because sustained viremia is associated with chronic histopathological injury and an increased risk of tumor recurrence and a poor survival outcome[59], adjuvant anti-viral therapy may be preferable for patients with a positive serology for HCV.

Recent meta-analyses have revealed that postoperative IFN treatment for HCV-related HCC prevents HCC recurrence and improves survival[12,13]. Conventionally, the eradication of HCV and a sustained status of undetectable HCV-RNA have been regarded as the most important factors for obtaining better clinical outcomes. However, a recent study based on a prospective population has revealed that a lower HCV viral load itself predicts better long-term surgical outcomes in patients with HCC regardless of the serologic eradication of HCV (Figure 3)[60,61]. Therefore, postoperative antiviral therapy with individually adjusted intensities might be advantageous for reducing HCC recurrence, even among patients who cannot tolerate the currently used standard high dose anti-viral therapy.

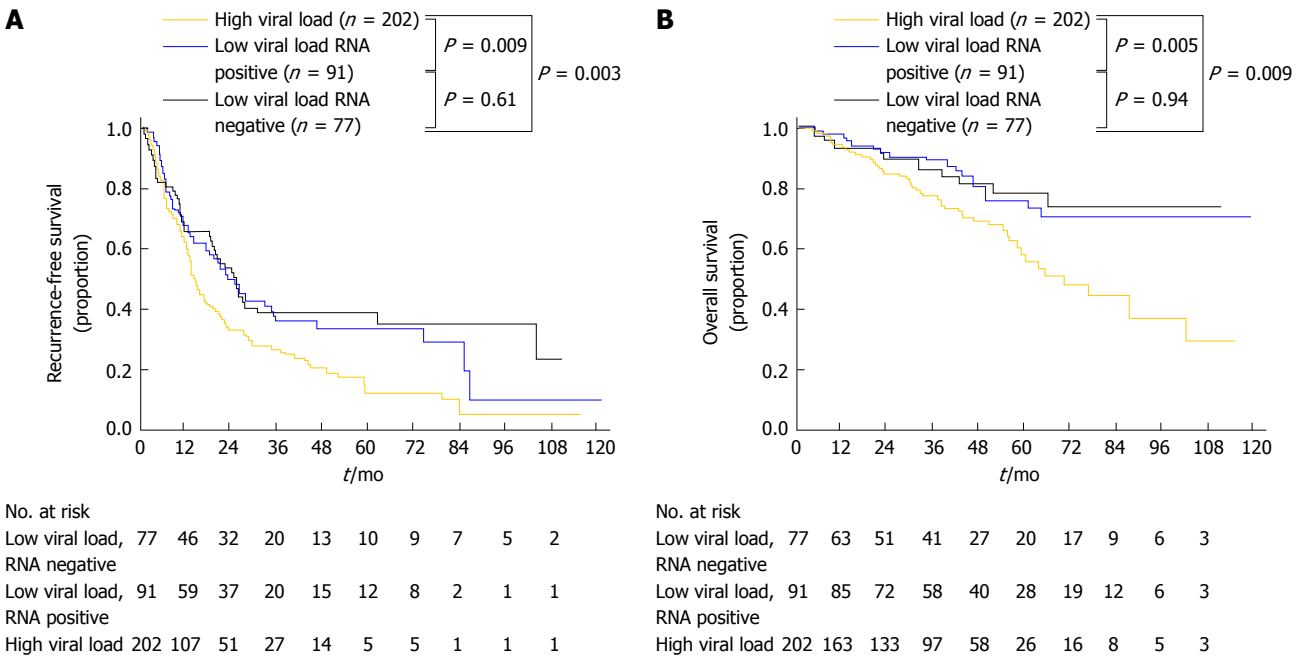

Figure 3 Cumulative recurrence rate (A) and cumulative overall survival (B) curves of low and high viral load groups stratified according to the results of hepatitis C virus RNA quantification. (Adapted from Shindoh *et al*[60] with permission).

After liver transplantation, the control of HCV infection is also necessary for the protection of the liver graft. Although the risk of tumor recurrence is relatively low as long as the patient meets the Milan criteria, re-infection with HCV is inevitable, and the rapid progression of graft fibrosis toward cirrhosis is sometimes observed because of the active HCV infection that occurs under the immunosuppressive conditions. As for the efficacy of prophylactic anti-viral therapy during the early posttransplant period, a recent multicenter randomized study denied its efficacy in terms of patient/graft survival rates[62]; therefore, most Western surgeons do not support the routine use of preemptive antiviral therapy. However, this study was performed prior to recent effective combination therapies with DAAs, and the reported SVR rate was only 22%. The University of Tokyo has recently reported that preemptive antiviral therapy is feasible, with acceptable tolerance and an end-of-treatment response rate of 56% and SVR rates of 44% under a strict treatment protocol[63]. Several recent studies have also reported that patients who achieved an SVR after antiviral therapy showed significantly better patient/graft survival rates[64-66]. Given the improved SVR rates that have been achieved in the era of DAAs, prophylactic treatment during the early post-transplant period may be able to reduce the HCV viral load effectively and to suppress histopathological injury to grafted livers.

CONCLUSION

Hepatitis C infection is associated with a poor survival outcome after surgical resection and liver transplantation for the treatment of HCC. Because chronic infection with HCV and increased carcinogenic potential of the underlying liver are the main reasons for the poor survival outcome after liver resection, adjuvant anti-viral therapy at an individually adjusted intensity may be important for achieving a longer survival period after surgery. Liver transplantation offers a higher chance of cure for HCC, regardless of the hepatic functional reserve. However, post-transplant re-infection with HCV is troublesome and sometimes causes the rapid progression of liver damage, resulting in graft failure. Although only a few lines of solid evidence have been available for postoperative antiviral treatment because of limited indications and frequent adverse events caused by the conventional high-dose combination interferon therapy, new DAAs enable interferon-free anti-viral treatment with a higher virologic response and minimal side effects.

REFERENCES

1 World Cancer Report 2014. Lyon, France: The International Agency for Research on Cancer, 2014
2 **Belghiti J**, Panis Y, Farges O, Benhamou JP, Fekete F. Intrahepatic recurrence after resection of hepatocellular carcinoma complicating cirrhosis. *Ann Surg* 1991; **214**: 114-117 [PMID: 1714267]
3 **Imamura H**, Matsuyama Y, Miyagawa Y, Ishida K, Shimada R, Miyagawa S, Makuuchi M, Kawasaki S. Prognostic significance of anatomical resection and des-gamma-carboxy prothrombin in patients with hepatocellular carcinoma. *Br J Surg* 1999; **86**: 1032-1038 [PMID: 10460639 DOI: 10.1046/j.1365-2168.1999.01185.x]
4 **Kudo M**. Hepatocellular carcinoma 2009 and beyond: from the surveillance to molecular targeted therapy. *Oncology* 2008; **75** Suppl 1: 1-12 [PMID: 19092266 DOI: 10.1159/000181865]
5 **Llovet JM**, Burroughs A, Bruix J. Hepatocellular carcinoma. *Lancet* 2003; **362**: 1907-1917 [PMID: 14667750 DOI: 10.1016/S0140-6736(03)14964-1]
6 **Arii S**, Yamaoka Y, Futagawa S, Inoue K, Kobayashi K, Kojiro M, Makuuchi M, Nakamura Y, Okita K, Yamada R.

Results of surgical and nonsurgical treatment for small-sized hepatocellular carcinomas: a retrospective and nationwide survey in Japan. The Liver Cancer Study Group of Japan. *Hepatology* 2000; **32**: 1224-1229 [PMID: 11093728 DOI: 10.1053/jhep.2000.20456]

7 **Hasegawa K**, Kokudo N, Makuuchi M, Izumi N, Ichida T, Kudo M, Ku Y, Sakamoto M, Nakashima O, Matsui O, Matsuyama Y. Comparison of resection and ablation for hepatocellular carcinoma: a cohort study based on a Japanese nationwide survey. *J Hepatol* 2013; **58**: 724-729 [PMID: 23178708 DOI: 10.1016/j.jhep.2012.11.009]

8 **Hasegawa K**, Makuuchi M, Takayama T, Kokudo N, Arii S, Okazaki M, Okita K, Omata M, Kudo M, Kojiro M, Nakanuma Y, Takayasu K, Monden M, Matsuyama Y, Ikai I. Surgical resection vs. percutaneous ablation for hepatocellular carcinoma: a preliminary report of the Japanese nationwide survey. *J Hepatol* 2008; **49**: 589-594 [PMID: 18620773 DOI: 10.1016/j.jhep.2008.05.018]

9 **Akamatsu N**, Sugawara Y, Kokudo N. Living donor liver transplantation for patients with hepatocellular carcinoma. *Liver Cancer* 2014; **3**: 108-118 [PMID: 24945001 DOI: 10.1159/000343866]

10 **Akamatsu N**, Sugawara Y, Kokudo N, Eguchi S, Fujiwara T, Ohdan H, Nagano H, Taketomi A, Kitagawa Y, Shimada M, Ku Y, Yanaga K, Shirabe K, Ikegami T, Mizokami M, Takeuchi M, Maehara Y. Outcomes of living donor liver transplantation for hepatitis C virus-positive recipients in Japan: results of a nationwide survey. *Transpl Int* 2014; **27**: 767-774 [PMID: 24684710 DOI: 10.1111/tri.12329]

11 **Utsunomiya T**, Shimada M, Kudo M, Ichida T, Matsui O, Izumi N, Matsuyama Y, Sakamoto M, Nakashima O, Ku Y, Takayama T, Kokudo N; for the Liver Cancer Study Group of Japan. A Comparison of the Surgical Outcomes Among Patients With HBV-Positive, HCV-Positive, and Non-B Non-C Hepatocellular Carcinoma: A Nationwide Study of 11,950 Patients. *Ann Surg* 2014; Epub ahead of print [PMID: 25072437 DOI: 10.1097/SLA.0000000000000821]

12 **Breitenstein S**, Dimitroulis D, Petrowsky H, Puhan MA, Müllhaupt B, Clavien PA. Systematic review and meta-analysis of interferon after curative treatment of hepatocellular carcinoma in patients with viral hepatitis. *Br J Surg* 2009; **96**: 975-981 [PMID: 19672926 DOI: 10.1002/bjs.6731]

13 **Singal AK**, Freeman DH, Anand BS. Meta-analysis: interferon improves outcomes following ablation or resection of hepatocellular carcinoma. *Aliment Pharmacol Ther* 2010; **32**: 851-858 [PMID: 20659285 DOI: 10.1111/j.1365-2036.2010.04414.x]

14 **Kumada H**, Suzuki Y, Ikeda K, Toyota J, Karino Y, Chayama K, Kawakami Y, Ido A, Yamamoto K, Takaguchi K, Izumi N, Koike K, Takehara T, Kawada N, Sata M, Miyagoshi H, Eley T, McPhee F, Damokosh A, Ishikawa H, Hughes E. Daclatasvir plus asunaprevir for chronic HCV genotype 1b infection. *Hepatology* 2014; **59**: 2083-2091 [PMID: 24604476 DOI: 10.1002/hep.27113]

15 **Lawitz E**, Poordad FF, Pang PS, Hyland RH, Ding X, Mo H, Symonds WT, McHutchison JG, Membreno FE. Sofosbuvir and ledipasvir fixed-dose combination with and without ribavirin in treatment-naive and previously treated patients with genotype 1 hepatitis C virus infection (LONESTAR): an open-label, randomised, phase 2 trial. *Lancet* 2014; **383**: 515-523 [PMID: 24209977 DOI: 10.1016/S0140-6736(13)62121-2]

16 **Lawitz E**, Sulkowski MS, Ghalib R, Rodriguez-Torres M, Younossi ZM, Corregidor A, DeJesus E, Pearlman B, Rabinovitz M, Gitlin N, Lim JK, Pockros PJ, Scott JD, Fevery B, Lambrecht T, Ouwerkerk-Mahadevan S, Callewaert K, Symonds WT, Picchio G, Lindsay KL, Beumont M, Jacobson IM. Simeprevir plus sofosbuvir, with or without ribavirin, to treat chronic infection with hepatitis C virus genotype 1 in non-responders to pegylated interferon and ribavirin and treatment-naive patients: the COSMOS randomised study. *Lancet* 2014;**384**: 1756-1765 [PMID: 25078309 DOI: 10.1016/S0140-6736(14)61036-9]

17 **Arzumanyan A**, Reis HM, Feitelson MA. Pathogenic mechanisms in HBV- and HCV-associated hepatocellular carcinoma. *Nat Rev Cancer* 2013; **13**: 123-135 [PMID: 23344543 DOI: 10.1038/nrc3449]

18 **El-Serag HB**. Epidemiology of viral hepatitis and hepatocellular carcinoma. *Gastroenterology* 2012; **142**: 1264-1273.e1 [PMID: 22537432 DOI: 10.1053/j.gastro.2011.12.061]

19 **Schlaeger C**, Longerich T, Schiller C, Bewerunge P, Mehrabi A, Toedt G, Kleeff J, Ehemann V, Eils R, Lichter P, Schirmacher P, Radlwimmer B. Etiology-dependent molecular mechanisms in human hepatocarcinogenesis. *Hepatology* 2008; **47**: 511-520 [PMID: 18161050 DOI: 10.1002/hep.22033]

20 **Tsukuma H**, Hiyama T, Tanaka S, Nakao M, Yabuuchi T, Kitamura T, Nakanishi K, Fujimoto I, Inoue A, Yamazaki H. Risk factors for hepatocellular carcinoma among patients with chronic liver disease. *N Engl J Med* 1993; **328**: 1797-1801 [PMID: 7684822 DOI: 10.1056/NEJM199306243282501]

21 **Ikai I**, Arii S, Okazaki M, Okita K, Omata M, Kojiro M, Takayasu K, Nakanuma Y, Makuuchi M, Matsuyama Y, Monden M, Kudo M. Report of the 17th Nationwide Follow-up Survey of Primary Liver Cancer in Japan. *Hepatol Res* 2007; **37**: 676-691 [PMID: 17617112 DOI: 10.1111/j.1872-034X.2007.00119.x]

22 **Kao WY**, Su CW, Chau GY, Lui WY, Wu CW, Wu JC. A comparison of prognosis between patients with hepatitis B and C virus-related hepatocellular carcinoma undergoing resection surgery. *World J Surg* 2011; **35**: 858-867 [PMID: 21207029 DOI: 10.1007/s00268-010-0928-z]

23 **Sasaki Y**, Yamada T, Tanaka H, Ohigashi H, Eguchi H, Yano M, Ishikawa O, Imaoka S. Risk of recurrence in a long-term follow-up after surgery in 417 patients with hepatitis B- or hepatitis C-related hepatocellular carcinoma. *Ann Surg* 2006; **244**: 771-780 [PMID: 17060771 DOI: 10.1097/01.sla.0000225126.56483.b3]

24 **Takenaka K**, Yamamoto K, Taketomi A, Itasaka H, Adachi E, Shirabe K, Nishizaki T, Yanaga K, Sugimachi K. A comparison of the surgical results in patients with hepatitis B versus hepatitis C-related hepatocellular carcinoma. *Hepatology* 1995; **22**: 20-24 [PMID: 7601413]

25 **Bruix J**, Sherman M. Management of hepatocellular carcinoma: an update. *Hepatology* 2011; **53**: 1020-1022 [PMID: 21374666 DOI: 10.1002/hep.24199]

26 **Cescon M**, Vetrone G, Grazi GL, Ramacciato G, Ercolani G, Ravaioli M, Del Gaudio M, Pinna AD. Trends in perioperative outcome after hepatic resection: analysis of 1500 consecutive unselected cases over 20 years. *Ann Surg* 2009; **249**: 995-1002 [PMID: 19474679 DOI: 10.1097/SLA.0b013e3181a63c74]

27 **Kaneda K**, Kubo S, Tanaka H, Takemura S, Ohba K, Uenishi T, Kodai S, Shinkawa H, Urata Y, Sakae M, Yamamoto T, Suehiro S. Features and outcome after liver resection for non-B non-C hepatocellular carcinoma. *Hepatogastroenterology* 2012; **59**: 1889-1892 [PMID: 22819910 DOI: 10.5754/hge10778]

28 **Kondo K**, Chijiiwa K, Funagayama M, Kai M, Otani K, Ohuchida J. Differences in long-term outcome and prognostic factors according to viral status in patients with hepatocellular carcinoma treated by surgery. *J Gastrointest Surg* 2008; **12**: 468-476 [PMID: 17999119 DOI: 10.1007/s11605-007-0402-x]

29 **Li Q**, Li H, Qin Y, Wang PP, Hao X. Comparison of surgical outcomes for small hepatocellular carcinoma in patients with hepatitis B versus hepatitis C: a Chinese experience. *J Gastroenterol Hepatol* 2007; **22**: 1936-1941 [PMID: 17914973 DOI: 10.1111/j.1440-1746.2006.04619.x]

30 **Morgan RL**, Baack B, Smith BD, Yartel A, Pitasi M, Falck-Ytter Y. Eradication of hepatitis C virus infection and the development of hepatocellular carcinoma: a meta-analysis of observational studies. *Ann Intern Med* 2013; **158**: 329-337 [PMID: 23460056 DOI: 10.7326/0003-4819-158-5-201303050-00005]

31 **Mazzaferro V**, Regalia E, Doci R, Andreola S, Pulvirenti

A, Bozzetti F, Montalto F, Ammatuna M, Morabito A, Gennari L. Liver transplantation for the treatment of small hepatocellular carcinomas in patients with cirrhosis. *N Engl J Med* 1996; **334**: 693-699 [PMID: 8594428 DOI: 10.1056/NEJM199603143341104]

32 **Ishizawa T**, Hasegawa K, Aoki T, Takahashi M, Inoue Y, Sano K, Imamura H, Sugawara Y, Kokudo N, Makuuchi M. Neither multiple tumors nor portal hypertension are surgical contraindications for hepatocellular carcinoma. *Gastroenterology* 2008; **134**: 1908-1916 [PMID: 18549877 DOI: 10.1053/j.gastro.2008.02.091]

33 **Hasegawa K**, Kokudo N, Imamura H, Matsuyama Y, Aoki T, Minagawa M, Sano K, Sugawara Y, Takayama T, Makuuchi M. Prognostic impact of anatomic resection for hepatocellular carcinoma. *Ann Surg* 2005; **242**: 252-259 [PMID: 16041216]

34 **Shindoh J**, Hasegawa K, Inoue Y, Ishizawa T, Nagata R, Aoki T, Sakamoto Y, Sugawara Y, Makuuchi M, Kokudo N. Risk factors of post-operative recurrence and adequate surgical approach to improve long-term outcomes of hepatocellular carcinoma. *HPB* (Oxford) 2013; **15**: 31-39 [PMID: 23216777 DOI: 10.1111/j.1477-2574.2012.00552.x]

35 **Eguchi S**, Kanematsu T, Arii S, Okazaki M, Okita K, Omata M, Ikai I, Kudo M, Kojiro M, Makuuchi M, Monden M, Matsuyama Y, Nakanuma Y, Takayasu K. Comparison of the outcomes between an anatomical subsegmentectomy and a non-anatomical minor hepatectomy for single hepatocellular carcinomas based on a Japanese nationwide survey. *Surgery* 2008; **143**: 469-475 [PMID: 18374043 DOI: 10.1016/j.surg.2007.12.003]

36 **Kishi Y**, Abdalla EK, Chun YS, Zorzi D, Madoff DC, Wallace MJ, Curley SA, Vauthey JN. Three hundred and one consecutive extended right hepatectomies: evaluation of outcome based on systematic liver volumetry. *Ann Surg* 2009; **250**: 540-548 [PMID: 19730239 DOI: 10.1097/SLA.0b013e3181b674df]

37 **Shindoh J**, Truty MJ, Aloia TA, Curley SA, Zimmitti G, Huang SY, Mahvash A, Gupta S, Wallace MJ, Vauthey JN. Kinetic growth rate after portal vein embolization predicts posthepatectomy outcomes: toward zero liver-related mortality in patients with colorectal liver metastases and small future liver remnant. *J Am Coll Surg* 2013; **216**: 201-209 [PMID: 23219349 DOI: 10.1016/j.jamcollsurg.2012.10.018]

38 **Shindoh J**, Tzeng CW, Aloia TA, Curley SA, Zimmitti G, Wei SH, Huang SY, Mahvash A, Gupta S, Wallace MJ, Vauthey JN. Optimal future liver remnant in patients treated with extensive preoperative chemotherapy for colorectal liver metastases. *Ann Surg Oncol* 2013; **20**: 2493-2500 [PMID: 23377564 DOI: 10.1245/s10434-012-2864-7]

39 **Zorzi D**, Laurent A, Pawlik TM, Lauwers GY, Vauthey JN, Abdalla EK. Chemotherapy-associated hepatotoxicity and surgery for colorectal liver metastases. *Br J Surg* 2007; **94**: 274-286 [PMID: 17315288 DOI: 10.1002/bjs.5719]

40 **Makuuchi M**, Kosuge T, Takayama T, Yamazaki S, Kakazu T, Miyagawa S, Kawasaki S. Surgery for small liver cancers. *Semin Surg Oncol* 1993; **9**: 298-304 [PMID: 8210909]

41 **Iwatsuki S**, Gordon RD, Shaw BW, Starzl TE. Role of liver transplantation in cancer therapy. *Ann Surg* 1985; **202**: 401-407 [PMID: 2996449]

42 **Ringe B**, Pichlmayr R, Wittekind C, Tusch G. Surgical treatment of hepatocellular carcinoma: experience with liver resection and transplantation in 198 patients. *World J Surg* 1991; **15**: 270-285 [PMID: 1851588]

43 **DuBay D**, Sandroussi C, Sandhu L, Cleary S, Guba M, Cattral MS, McGilvray I, Ghanekar A, Selzner M, Greig PD, Grant DR. Liver transplantation for advanced hepatocellular carcinoma using poor tumor differentiation on biopsy as an exclusion criterion. *Ann Surg* 2011; **253**: 166-172 [PMID: 21294289]

44 **Herrero JI**, Sangro B, Pardo F, Quiroga J, Iñarrairaegui M, Rotellar F, Montiel C, Alegre F, Prieto J. Liver transplantation in patients with hepatocellular carcinoma across Milan criteria. *Liver Transpl* 2008; **14**: 272-278 [PMID: 18306328 DOI: 10.1002/lt.21368]

45 **Kaido T**, Ogawa K, Mori A, Fujimoto Y, Ito T, Tomiyama K, Takada Y, Uemoto S. Usefulness of the Kyoto criteria as expanded selection criteria for liver transplantation for hepatocellular carcinoma. *Surgery* 2013; **154**: 1053-1060 [PMID: 24074704 DOI: 10.1016/j.surg.2013.04.056]

46 **Mazzaferro V**, Llovet JM, Miceli R, Bhoori S, Schiavo M, Mariani L, Camerini T, Roayaie S, Schwartz ME, Grazi GL, Adam R, Neuhaus P, Salizzoni M, Bruix J, Forner A, De Carlis L, Cillo U, Burroughs AK, Troisi R, Rossi M, Gerunda GE, Lerut J, Belghiti J, Boin I, Gugenheim J, Rochling F, Van Hoek B, Majno P. Predicting survival after liver transplantation in patients with hepatocellular carcinoma beyond the Milan criteria: a retrospective, exploratory analysis. *Lancet Oncol* 2009; **10**: 35-43 [PMID: 19058754 DOI: 10.1016/S1470-2045(08)70284-5]

47 **Silva M**, Moya A, Berenguer M, Sanjuan F, López-Andujar R, Pareja E, Torres-Quevedo R, Aguilera V, Montalva E, De Juan M, Mattos A, Prieto M, Mir J. Expanded criteria for liver transplantation in patients with cirrhosis and hepatocellular carcinoma. *Liver Transpl* 2008; **14**: 1449-1460 [PMID: 18825681 DOI: 10.1002/lt.21576]

48 **Sugawara Y**, Tamura S, Makuuchi M. Living donor liver transplantation for hepatocellular carcinoma: Tokyo University series. *Dig Dis* 2007; **25**: 310-312 [PMID: 17960065 DOI: 10.1159/000106910]

49 **Yao FY**, Ferrell L, Bass NM, Watson JJ, Bacchetti P, Venook A, Ascher NL, Roberts JP. Liver transplantation for hepatocellular carcinoma: expansion of the tumor size limits does not adversely impact survival. *Hepatology* 2001; **33**: 1394-1403 [PMID: 11391528 DOI: 10.1053/jhep.2001.24563]

50 **Zheng SS**, Xu X, Wu J, Chen J, Wang WL, Zhang M, Liang TB, Wu LM. Liver transplantation for hepatocellular carcinoma: Hangzhou experiences. *Transplantation* 2008; **85**: 1726-1732 [PMID: 18580463 DOI: 10.1097/TP.0b013e31816b67e4]

51 **Bozorgzadeh A**, Orloff M, Abt P, Tsoulfas G, Younan D, Kashyap R, Jain A, Mantry P, Maliakkal B, Khorana A, Schwartz S. Survival outcomes in liver transplantation for hepatocellular carcinoma, comparing impact of hepatitis C versus other etiology of cirrhosis. *Liver Transpl* 2007; **13**: 807-813 [PMID: 17539001 DOI: 10.1002/lt.21054]

52 **Moya A**, Berenguer M, Aguilera V, Juan FS, Nicolás D, Pastor M, López-Andujar R, Rayón M, Orbis F, Mora J, De Juan M, Carrasco D, Vila JJ, Prieto M, Berenguer J, Mir J. Hepatocellular carcinoma: Can it be considered a controversial indication for liver transplantation in centers with high rates of hepatitis C? *Liver Transpl* 2002; **8**: 1020-1027 [PMID: 12424715 DOI: 10.1053/jlts.2002.35664]

53 **Schwartz M**. Liver transplantation for hepatocellular carcinoma. *Gastroenterology* 2004; **127**: S268-S276 [PMID: 15508093]

54 **Shimoda M**, Ghobrial RM, Carmody IC, Anselmo DM, Farmer DG, Yersiz H, Chen P, Dawson S, Durazo F, Han S, Goldstein LI, Saab S, Hiatt J, Busuttil RW. Predictors of survival after liver transplantation for hepatocellular carcinoma associated with Hepatitis C. *Liver Transpl* 2004; **10**: 1478-1486 [PMID: 15558585 DOI: 10.1002/lt.20303]

55 **Figueras J**, Ibañez L, Ramos E, Jaurrieta E, Ortiz-de-Urbina J, Pardo F, Mir J, Loinaz C, Herrera L, López-Cillero P, Santoyo J. Selection criteria for liver transplantation in early-stage hepatocellular carcinoma with cirrhosis: results of a multicenter study. *Liver Transpl* 2001; **7**: 877-883 [PMID: 11679986 DOI: 10.1053/jlts.2001.27856]

56 **Yao FY**, Kinkhabwala M, LaBerge JM, Bass NM, Brown R, Kerlan R, Venook A, Ascher NL, Emond JC, Roberts JP. The impact of pre-operative loco-regional therapy on outcome

after liver transplantation for hepatocellular carcinoma. *Am J Transplant* 2005; **5**: 795-804 [PMID: 15760404 DOI: 10.1111/j.1600-6143.2005.00750.x]

57 **Dumitra S**, Alabbad SI, Barkun JS, Dumitra TC, Coutsinos D, Metrakos PP, Hassanain M, Paraskevas S, Chaudhury P, Tchervenkov JI. Hepatitis C infection and hepatocellular carcinoma in liver transplantation: a 20-year experience. *HPB* (Oxford) 2013; **15**: 724-731 [PMID: 23490176 DOI: 10.1111/hpb.12041]

58 **Coilly A**, Roche B, Dumortier J, Leroy V, Botta-Fridlund D, Radenne S, Pageaux GP, Si-Ahmed SN, Guillaud O, Antonini TM, Haïm-Boukobza S, Roque-Afonso AM, Samuel D, Duclos-Vallée JC. Safety and efficacy of protease inhibitors to treat hepatitis C after liver transplantation: a multicenter experience. *J Hepatol* 2014; **60**: 78-86 [PMID: 23994384 DOI: 10.1016/j.jhep.2013.08.018]

59 **Zhou Y**, Si X, Wu L, Su X, Li B, Zhang Z. Influence of viral hepatitis status on prognosis in patients undergoing hepatic resection for hepatocellular carcinoma: a meta-analysis of observational studies. *World J Surg Oncol* 2011; **9**: 108 [PMID: 21933440 DOI: 10.1186/1477-7819-9-108]

60 **Shindoh J**, Hasegawa K, Matsuyama Y, Inoue Y, Ishizawa T, Aoki T, Sakamoto Y, Sugawara Y, Makuuchi M, Kokudo N. Low hepatitis C viral load predicts better long-term outcomes in patients undergoing resection of hepatocellular carcinoma irrespective of serologic eradication of hepatitis C virus. *J Clin Oncol* 2013; **31**: 766-773 [PMID: 23129744 DOI: 10.1200/JCO.2012.44.3234]

61 **Shindoh J**, Hasegawa K, Takemura N, Omichi K, Ishizawa T, Aoki T, Sakamoto Y, Suagawara Y, Kokudo N. Hepatitis C viral load predicts tumor recurrence after curative resection of hepatocellular carcinoma regardless of the genotype of hepatitis C virus. *Hepatol Int* 2014; In press

62 **Bzowej N**, Nelson DR, Terrault NA, Everson GT, Teng LL, Prabhakar A, Charlton MR. PHOENIX: A randomized controlled trial of peginterferon alfa-2a plus ribavirin as a prophylactic treatment after liver transplantation for hepatitis C virus. *Liver Transpl* 2011; **17**: 528-538 [PMID: 21506241 DOI: 10.1002/lt.22271]

63 **Sugawara Y**, Tamura S, Yamashiki N, Kaneko J, Aoki T, Sakamoto Y, Hasegawa K, Kokudo N. Preemptive antiviral treatment for hepatitis C virus after living donor liver transplantation. *Transplant Proc* 2012; **44**: 791-793 [PMID: 22483497 DOI: 10.1016/j.transproceed.2012.01.031]

64 **Firpi RJ**, Clark V, Soldevila-Pico C, Morelli G, Cabrera R, Levy C, Machicao VI, Chaoru C, Nelson DR. The natural history of hepatitis C cirrhosis after liver transplantation. *Liver Transpl* 2009; **15**: 1063-1071 [PMID: 19718647 DOI: 10.1002/lt.21784]

65 **Veldt BJ**, Poterucha JJ, Watt KD, Wiesner RH, Hay JE, Kremers WK, Rosen CB, Heimbach JK, Charlton MR. Impact of pegylated interferon and ribavirin treatment on graft survival in liver transplant patients with recurrent hepatitis C infection. *Am J Transplant* 2008; **8**: 2426-2433 [PMID: 18727694 DOI: 10.1111/j.1600-6143.2008.02362.x]

66 **Berenguer M**, Palau A, Aguilera V, Rayón JM, Juan FS, Prieto M. Clinical benefits of antiviral therapy in patients with recurrent hepatitis C following liver transplantation. *Am J Transplant* 2008; **8**: 679-687 [PMID: 18294165 DOI: 10.1111/j.1600-6143.2007.02126.x]

P- Reviewer: Bianchini M, Chetty R, Sertoglu E, Waisberg J
S- Editor: Qi Y **L- Editor**: A **E- Editor**: Liu SQ

World Journal of Hepatology

Submit a Manuscript: http://www.wjgnet.com/esps/
Help Desk: http://www.wjgnet.com/esps/helpdesk.aspx
DOI: 10.4254/wjh.v7.i1.78

World J Hepatol 2015 January 27; 7(1): 78-92
ISSN 1948-5182 (online)

TOPIC HIGHLIGHT

WJH 6th Anniversary Special Issues (5): Hepatitis C virus

Hepatitis C and kidney disease: An overview and approach to management

Ahmad Najib Azmi, Soek-Siam Tan, Rosmawati Mohamed

Ahmad Najib Azmi, Department of Medicine, Faculty of Medicine and Health Sciences, Universiti Sains Islam Malaysia, Kuala Lumpur 55100, Malaysia
Soek-Siam Tan, Department of Hepatology, Selayang Hospital, Selangor 68100, Malaysia
Rosmawati Mohamed, Department of Medicine, Faculty of Medicine, University of Malaya, Kuala Lumpur 50603, Malaysia
Author contributions: Azmi AN, Tan SS and Mohamed R equally contributed to the present work; Azmi AN drafted, wrote, edited and revised the article; Tan SS and Mohamed R equally contributed to revising, editing and writing the article.

Correspondence to: Ahmad Najib Azmi, MBBS, MMed, Senior Lecturer, Department of Medicine, Faculty of Medicine and Health Sciences, Universiti Sains Islam Malaysia, 13th Floor, Menara B, Persiaran MPAJ, Jalan Pandan Utama, Pandan Indah, Kuala Lumpur 55100, Malaysia. najibaz@usim.edu.my
Telephone: +60-3-42892400
Fax: +60-3-42892477
Received: September 4, 2014
Peer-review started: September 5, 2014
First decision: September 28, 2014
Revised: October 13, 2014
Accepted: November 7, 2014
Article in press: November 10, 2014
Published online: January 27, 2015

Abstract

Hepatitis C infection and chronic kidney disease are major health burden worldwide. Hepatitis C infection is associated with a wide range of extra-hepatic manifestations in various organs including the kidneys. A strong association between hepatitis C and chronic kidney disease has come to light. Hemodialysis in supporting the end stage renal disease patients unfortunately carries a risk for hepatitis C infection. Despite much improvement in the care of this group of patients, the prevalence of hepatitis C infection in hemodialysis patients is still higher than the general population. Hepatitis C infection has a negative effect on the survival of hemodialysis and renal transplant patients. Treatment of hepatitis C in end stage renal disease patients using conventional or pegylated interferon with or without ribavirin remains a clinical challenge with low response rate, high dropout rate due to poor tolerability and many unmet needs. The approval of new direct acting antiviral agents for hepatitis C may dramatically change the treatment approach in hepatitis C infected patients with mild to moderate renal impairment. However it remains to be confirmed if the newer Hepatitis C therapies are safe in individuals with severe renal impairment. This review article discusses the relationship between hepatitis C and chronic kidney disease, describe the various types of renal diseases associated with hepatitis C and the newer as well as the existing treatments for hepatitis C in the context of this subpopulation of hepatitis C patients.

Key words: Chronic hepatitis C; Kidney disease; Management

Core tip: There is a strong association between hepatitis C virus (HCV) infection and chronic kidney disease with negative impact on survival in hemodialysis and post renal transplant HCV infected patients. Recent data showed that treatment of HCV improves outcomes. In HCV infected diabetics, effective anti-HCV treatment reduces the incidence of end stage renal disease. There are now major advances in HCV treatment which may dramatically change the treatment approach in hepatitis

C infected patients.

Azmi AN, Tan SS, Mohamed R. Hepatitis C and kidney disease: An overview and approach to management. *World J Hepatol* 2015; 7(1): 78-92 Available from: URL: http://www.wjgnet.com/1948-5182/full/v7/i1/78.htm DOI: http://dx.doi.org/10.4254/wjh.v7.i1.78

INTRODUCTION

There are approximately 130-150 million people infected with hepatitis C virus (HCV) while the prevalence of chronic kidney disease (CKD) is between 10%-16% worldwide[1,2]. The prevalence of HCV positive among hemodialysis patients can vary from < 5% to as high as 60% from different regions in the world[3,4]. The link between HCV infection and kidney disease is well recognized[5,6]. In a large population-based study in Taiwan, the prevalence of CKD among those who are seropositive for hepatitis C was 16.5% and chronic hepatitis C infection was found to be an independent risk factor for development of CKD[5,7]. In another study, the presence of anti-HCV antibody is associated with renal disease progression with a higher rate of positive anti-HCV in those with more severe stages of CKD[8].

The survival of HCV-infected CKD patients at stage 1 and 2 CKD is thought to be similar to the non-uremic HCV patients[9]. In contrast, a meta-analysis reported negative impact of anti-HCV positivity on survival in hemodialysis patients; the adjusted relative risks for all-cause mortality was 1.35 (95%CI: 1.25-1.47) and for liver disease related mortality was 3.82 (95%CI: 1.92-7.61)[10].

The treatment for hepatitis C is rapidly evolving with many new agents in the pipeline either in late phases of development or awaiting approval. Direct acting anti-virals (DAAs) target various parts of the HCV lifecycle. In 2011, two new DAAs, the first generation of HCV-NS3/NS4A serine protease inhibitors (PI) telaprevir and boceprevir were approved for treatment of genotype 1 HCV. Two more DAAs were approved more recently; sofosbuvir, a nucleotide analog NS5B polymerase inhibitor which is effective against HCV genotypes 1, 2, 3 and 4 and simeprevir, the third NS3/NS4Aprotease inhibitor approved is effective against HCV genotype 1[11]. The newer generation of DAAs are associated with increased sustained viral response and good safety profiles.

This review describes the various types of clinical manifestations of HCV in patients with CKD and their management, which remains challenging with many unmet needs.

HEPATITIS C RESULTING IN KIDNEY DISEASE

HCV primarily affects the liver causing hepatitis; chronic hepatitis may progress to liver fibrosis and subsequently cirrhosis and hepatocellular carcinoma, which are the major burden of disease in people living with chronic hepatitis C. However, there are also extra-hepatic manifestations of HCV which include glomerulonephritis, thyroiditis, insulin resistance, diabetes mellitus, porphyria cutanea tarda, lichen planus, vitiligo, seronegative arthritis, cryoglobulinemia and lymphoproliferative disorders[6]. It has been reported that approximately 40% of the HCV infected patients have at least one extra-hepatic manifestation[12].

Large-scale community observational studies and others showed that HCV infection carries a risk for CKD and end stage renal disease (ESRD)[5,7,8,13]. Similarly in CKD patients, HCV infection increases the risk of developing ESRD with an estimated 5-year cumulative incidence rate of 52.6% compared to 38.4% in those without HCV infection[14]. This study also reported that HCV infection is an independent risk factor for developing ESRD[14]. The risk for CKD is higher in HCV patients with other co-morbidities such as diabetes, hyperlipidemia, cirrhosis, male gender, age < 50 years, and those on more than 6 years follow-up for HCV[7].

Several factors may contribute to the development of ESRD in HCV infected patients. HCV may trigger a cascade of immune reactions that subsequently attack the kidneys and result in glomerulonephritis. HCV was also found to be associated with insulin resistance and dyslipidemia[15], thus, indirectly increasing the risk of renal disease.

Kidney diseases associated with HCV may present clinically as nephritic, nephrotic syndrome or isolated proteinuria with or without impairment in renal function. The pathological changes on renal biopsy are membranoproliferative glomerulonephritis (MPGN), membranous glomerulopathy (MG), IgA nephropathy, focal segmental glomerulosclerosis, mesangial proliferative glomerular nephritis or tubulointerstitial nephritis[16]. In an Italian multi-centre study of 146 cryoglobulinemic glomerulonephritis, 87% was HCV infected[17]. Diffuse MPGN was the most common renal biopsy finding in 83% of patients and type Ⅱ cryoglobulin was detected in 74.4% of cases.

In a case-control study, it was also found that MPGN was significantly more prevalent than membranous glomerulopathy among HCV associated kidney disease patients (0.36% *vs* 0.05%; $P < 0.0001$), with the most common involvement being type I MPGN associated with type Ⅱ mixed cryoglobulinemia[6].

Glomerulonephritis may occur many years or even decades after HCV infection. The mechanism for MPGN related to HCV is thought to be immune-complex mediated (antigen-antibody immune complexes formation from chronic infection) and these immune complexes activate the classical pathway of complements and cause deposition of immunoglobulins, complement factors and both kappa and lambda light chains in the mesangium and the capillary walls[18]. HCV-NS3 viral antigen deposits were detected in kidney tissues of patients with positive HCV

RNA and MPGN[19,20]. Cryoglobulins are immunoglobulins which become insoluble at below body temperature and dissolve when rewarmed. In individuals with HCV infection, these cryoglobulins are immune complexes formed by monoclonal immunoglobulin M (usually IgM Rheumatoid factor), polyclonal immunoglobulin G and HCV RNA which are deposited in the small and medium-sized vessels of the skin, kidneys and peripheral nerves. The deposition of these immune complexes in the mesangium of the kidneys triggers glomerulonephritis. Although proteinuria below nephrotic range, microscopic hematuria, mild to moderate renal insufficiency and arterial hypertension are among the classical clinical features, 30% of chronic hepatitis C with cryoglobulinemia have non-specific features like purpura, asthenia and arthralgia. Less than 10% have vasculitis affecting the kidney, skin and nerves[21,22]. Alanine transaminases are raised in 70% of patients, complements like C4, C1q are very low while C3 is only slightly low and the majority are rheumatoid factor positive[21,23]. Patients with diffuse MPGN showed higher levels of proteinuria and lower C4 levels[17]. The clinical course of patients with MPGN and cryoglobulinemia is classically relapsing and remitting, the top three causes of death are cardiovascular, sepsis and liver failure[17]. ESRD requiring hemodialysis is infrequent due to early mortality during the course of CKD before approaching ESRD[17,23].

Interestingly, studies also found an association of occult HCV in immune-mediated glomerular nephropathies[24,25]. In these studies, occult HCV is defined as negative anti-HCV-antibodies and serum HCV RNA but presence of HCV RNA in mononuclear cells in peripheral blood or in serum after ultra-centrifugation or HCV antigen detection using immuno-histochemistry in frozen renal tissues. The clinical implication of this finding requires further studies.

In the management of HCV-infected individuals, it is imperative that clinicians actively screen for kidney disease and prevent or control the additional risk factors (diabetes, hyperlipidemia and cirrhosis) for CKD. The liver and renal clinical practice guidelines recommend annual surveillance for hematuria and proteinuria in HCV-infected patients for early detection of glomerulopathies[9,26].

HEPATITIS C AND HEMODIALYSIS

In 2004, the Dialysis Outcomes and Practice Patterns Study (DOPPS) reported that 13.5% of hemodialysis patients are infected with hepatitis C. The prevalence rates of hepatitis C among these patients exhibits regional variations with less than 5% in the United Kingdom and Germany and higher prevalence of more than 20% in Spain and Italy[27]. Among 10 countries studied within the Asia-Pacific region, the HCV seroprevalence among hemodialysis patients were between 0.7% and 18.1%[28]. In addition, the prevalence of HCV were higher in HD group compared to patients on peritoneal dialysis [(7.9% ± 5.5%) *vs* (3.0% ± 2.0%), $P = 0.01$]. More importantly, the prevalence of HCV patients with ESRD who underwent hemodialysis can be at least five times higher compared to the general population[3,9,29,30].

There are mainly two groups of HCV infected patients in the hemodialysis unit, either the patients already have HCV infection before entering into treatment with hemodialysis or the HCV infection was acquired during the maintenance hemodialysis. The mode of HCV transmission is parenteral through contaminations from surfaces, supplies, invasive procedures, direct contact among patients and from breach in infection control practices[9]. Before the era of screening blood donors for HCV and the use of erythropoetin, multiple blood transfusions to treat anemia in dialysis patients had contributed to the increased prevalence of HCV transmission[3]. In one prospective observational study conducted in three major continents, the prevalence of HCV in hemodialysis patients were higher among those who were on dialysis for longer duration, male gender, black ethnicity, concurrent illness like diabetes or hepatitis B infection, prior kidney transplant and alcohol or substance abuse[27]. In its guideline to prevent HCV transmission in hemodialysis unit, Kidney Disease Improving Global Outcome (KDIGO) guidelines stressed the importance of compliance to strict infection-control procedures at all times[9].

A meta-analysis on patients receiving maintenance hemodialysis, found that HCV-positive patients have higher mortality compared to HCV-negative patients. This study showed that liver-related death was higher than cardiovascular-related death among these groups [adjusted relative risk 3.82 (95%CI: 1.92; 7.61) *vs* 1.26 (95%CI: 1.10; 1.45) respectively][10]. Deaths due to hepatocellular carcinoma and liver cirrhosis was higher in HCV-positive group[31]. There is no observed difference between hemodialysis and peritoneal dialysis on the survival rate of these HCV infected dialysis dependent patients[32,33].

HEPATITIS C AND RENAL TRANSPLANT

Hemodialysis is a risk factor for HCV infection. KDIGO guidelines recommend all renal transplant candidates should be screened for HCV and state that HCV infection is not a contraindication to renal transplant. A meta-analysis on 13 observational studies by Fabrizi *et al*[34] found that most studies showed an increase in all-cause mortality and all-cause renal graft loss among renal transplant recipients with HCV[34]. This is likely due to post-transplant immunosuppression and undiagnosed HCV infection prior to transplant. Hepatitis C infection in the setting of post renal transplant had been reported to cause specific diseases in the liver and the transplanted kidney.

In a cohort study of 614 renal transplant recipients, 2.45% (15 recipients) were diagnosed with MG post transplant. In eleven of them were *de novo* MG and 6 out of the 11 *de novo* MG cases were associated with HCV infection. All but one of the HCV infected recipients were not treated before the transplant[35]. Other studies

also found that HCV is a strong aetiologic factor for development of MG post transplant[36,37].

Fibrosing cholestatic hepatitis had been reported in HCV-infected renal transplant recipients. It is a complication of immunosuppression resulting in extremely high serum HCV RNA levels causing rapid progression to liver failure, sepsis and associated with high mortality rates. Biochemical profiles showed progressive cholestatic jaundice with liver biopsy showing characteristic features of cholestasis and fibrosis. Withdrawal or reductions of immunosuppression tend to have significant impact on preventing the progression of liver failure[38,39] but at the expense of possible renal graft loss.

In a study by de Oliveira Uehara *et al*[40], 22 renal transplant recipients who were HCV-positive and have pre and post transplant liver biopsies, were followed up to 7 years post transplant. Fifty percent of the patients showed progression in liver fibrosis and 32% had worsening of liver necro-inflammatory activity. Post transplant worsening of liver fibrosis was also detected in patients with no histological changes prior to the transplant[40]. In another study by Roth *et al*[41], 44 patients with HCV-positive recipients were followed for slightly shorter interval showed no significant liver disease progression, 16% of the studied recipients showed histologic improvement, and 23% showed progression of liver disease[41]. It is likely that HCV infection post renal transplant will gradually cause worsening of liver disease in the majority of cases.

A prospective study showed that despite significant decrease in patient and renal graft survival post renal transplant in HCV positive recipients compared to their HCV negative counterparts, the survival of HCV positive ESRD is still better with renal transplant rather than remaining on maintenance hemodialysis[42]. Kidneys from anti-HCV positive donors have been used to transplant HCV infected renal recipients[43]. This approach will help to shorten the waiting time for HCV RNA positive renal transplant candidates[44,45]. In addition to the benefit of shorter waiting time, the use of kidneys from HCV positive donors had also been shown to improve the overall survival compared to staying on the waiting list (adjusted HR for death 0.76, 95%CI: 0.60, 0.96)[46]. However, transmission from infected donor may produce super-infection from a different HCV genotype[47].

ASSESSMENT OF HEPATITIS C AND LIVER DISEASE STATUS IN RENAL PATIENTS

The clinical tools used in assessing HCV and the liver disease in non-uremic patients are generally applicable to renal patients apart from a few notable differences. HCV infected patient on hemodialysis tend to have normal alanine transaminase possibly due to high lactate level, which cause rapid consumption of NADH co-enzyme or enzyme during dialysis[48].

All anti-HCV-positive CKD patients should be assessed for HCV RNA viral load, HCV genotyping as well as liver fibrosis. HCV genotype is a strong predictor of response to anti-HCV treatment. KDIGO recommended special steps in drawing blood sample for HCV RNA tests in hemodialysis patients because heparin is an inhibitor of polymerase chain reaction[49]. In order to avoid contamination with heparin which is used in hemodialysis session, the blood sample for HCV RNA should be taken from a peripheral vein before the dialysis session[9].

Assessment of severity of liver disease is recommended prior to anti-HCV therapy. KDIGO recommend that HCV-infected potential kidney transplant candidates to undergo liver biopsy as part of the pre-transplant assessment. In a study which had 284 HCV infected hemodialysis patients undergoing liver biopsies, the complications reported were local pain in 18.3%, shoulder soreness in 11.7%, oozing at puncture site in 11.3%, liver hematoma in 1.1% and only one patient suffered from hemoperitoneum[50]. Another study on percutaneous liver biopsy in chronic hepatitis C patient with or without renal failure also found the procedure to be safe without any increased risk in hepatitis C infected ESRD[51].

We look into several studies that analysed liver biopsy findings in this group of patients. These studies revealed that about 22%-81% of HCV positive ESRD patients had histological evidence of liver fibrosis on biopsy while a smaller percentage of approximately 13%-25% had biopsy proven cirrhosis[52-54].

Although serious complications of liver biopsy are uncommon, the procedure is not well accepted by patients, and is open to sampling as well as interpretation errors. Non-invasive methods to evaluate the severity of liver disease in management of hepatitis C patients have been recommended[26,55]. A combination of non-invasive tests improves the diagnostic accuracy. An easily available method for assessing liver fibrosis in HCV patients is by using amino transaminase-to-platelet ratio index (APRI). APRI is calculated by [(amino-transaminase/upper limit normal)/platelet count (10^9/L)] × 100. A study in HCV infected ESRD patients found that APRI > 0.4 and < 0.95 can correctly predict 50% patients with F3-F4 fibrosis, 33% of F3-F4 fibrosis patients may have been mislabeled and consequently did not have a liver biopsy as part of the renal transplant assessment. The authors concluded that APRI was not a good predictor of hepatic fibrosis in transplant evaluation of HCV-positive ESRD patients[56]. An earlier study showed that APRI is a precise and reproducible test in predicting hepatic fibrosis in hemodialysis patients[57]. The different findings in these two studies were probably due to the different cut-off values used in predicting fibrosis.

Transient elastography (TE) has been found to be superior to APRI in assessing the severity of liver fibrosis especially in hemodialysis HCV infected patients with significant liver fibrosis (⩾ F2 and ⩾ F3)[50]. Overnight fasting before TE measurement is recommended to minimize the effect of raised portal and central venous pressure. The optimal cut off values were 5.3 kPa, 8.3 kPa and 9.2 kPa for fibrosis stage ⩾ F2, ⩾ F3 and F4,

respectively. It is noteworthy that a systematic review of 12 studies showed that TE is an excellent tool to identify HCV-related cirrhosis but not accurate for early stages of liver damage[58].

Patients with clinical or histological evidence of cirrhosis should have further assessments to look for the complications of cirrhosis such as upper endoscopy for varices and liver ultrasound for hepatocellular carcinoma surveillance.

TREATING HEPATITIS C INFECTION IN CKD PATIENTS

KDIGO recommends that all CKD patients with HCV infection to be assessed for anti-HCV therapy. As there are risks of interferon (IFN) therapy and benefits of avoiding the complications related to HCV infection in post renal transplant setting, KDIGO and other liver guidelines state that HCV infected renal transplant candidates should be treated for hepatitis C before renal transplant[9,26]. In clinical practice, the decision to treat HCV infection in a patient with CKD must be individualized after discussion of the potential risks and benefits of therapy. Factors such as life expectancy, renal transplant candidacy, other co-morbidities and the available expertise should be taken into consideration[9,26,55]. CKD patients in Stages 1 and 2 have normal survival as in the general population but CKD stage 3 and 4 have lower 5 years survival at 76% and 54% respectively. However the survival of CKD stage 5 patients is markedly diminished compared to the general population without renal impairment[9]. The liver-related complications of HCV, namely cirrhosis and hepatocellular carcinoma, have been implicated in the lower survival of HCV infected CKD Stage 5D or hemodialysis patients[31].

The widely accepted standard of care (SoC) for HCV therapy is pegylated IFN (PegIFN) in combination with ribavirin[26]. Using this SoC in renal impaired patients has several limitations mainly due to aggravated side effects resulting in premature discontinuation of therapy, higher dropout rates and treatment related mortality. Consequently, only few HCV-infected kidney disease requiring hemodialysis patients are treated. DOPPS reported that 4735 out of 49762 patients on hemodialysis were HCV-positive (9.5%) but only 48 out of 4589 (1%) patients with prescription data receive anti-viral treatment[59]. In the same study, among 617 HCV-positive renal transplant candidates, only 3.7% receive anti-viral treatment. Nevertheless, HCV-positive dialysis patients who received treatment were found to have better survival than untreated group.

CKD patients mostly suffer from multiple co-morbidities. Diabetes mellitus, hypertension and cardiovascular disease are among the co-morbidities that reduce the survival rate among CKD patients but also render them poor candidates for the current SoC anti-HCV therapy. Management of HCV-infection in kidney disease patients with multiple co-morbidities remains a challenge.

Renal transplant candidates with HCV-infection are recommended to receive HCV treatment due to benefits in slowing the development of liver disease and reduce the risk of HCV-related post-transplant complications[41] such as new-onset diabetes mellitus[60] and chronic allograft nephropathy[61]. In a controlled clinical trial by Cruzado *et al*[62], renal transplant recipients who received pre-transplant IFN therapy were shown to have a significantly lower rate of *de novo* glomerulonephritis compared to recipients who were untreated[62].

The objective of anti-HCV treatment is to achieve sustained virological response (SVR), which is classically defined as undetectable HCV RNA by polymerase chain reaction at 6 mo after interferon-based treatment. Achieving SVR in advanced fibrosis patients is associated with a decrease in all cause mortality, reduce risk of liver transplantation as well as liver related deaths like liver failure and hepatocellular[63]. However the benefits span beyond the liver. A Taiwan population based cohort study stratified diabetes mellitus patients into 3 groups; HCV-infected patients who were treated with PegIFN and ribavirin, HCV-infected patients who were never treated and an uninfected group. The 8-year cumulative incidence of ESRD and acute coronary syndrome were significantly lower in those who received anti-HCV therapy[64]. The authors concluded that treatment of HCV-infected patients with PegIFN and ribavirin was associated with improvements in cardiovascular and renal outcomes in diabetes mellitus patients.

Moreover, a meta-analysis on the durability of SVR in successfully treated HCV showed 86% durability in those who remained on maintenance hemodialysis while in those who received renal transplant it was 95% durable after a follow-up of 48 mo[65].

APPROVED ANTI-HCV THERAPIES AND THEIR USE IN RENAL IMPAIRMENT

IFN is broken down mainly in the kidneys therefore IFN therapy in patients with kidney disease may result in a significant amount of IFN accumulation in the body. PegIFN was introduced where the polyethylene glycol is attached to the IFN molecule making it more stable and longer half-life in the plasma. Instead of thrice weekly IFN injection, PegIFN requires only weekly injection. The two formulations of pegylated interferon are PegIFN-α2a and PegIFN-α2b. The latter is weight based at 1.5 mcg/kg while PegIFN-α2a dose is 180 mcg regardless of body weight. PegIFN-α2a is metabolized in both the kidneys and liver while PegIFN-α2b only by the kidneys. Plasma concentration of PegIFN is significantly elevated in hemodialysis patients, thus, PegIFN dose has to be reduced. For patients with creatinine clearance (CrCl) of < 30 mL/min and on hemodialysis, PegIFN-α2a dose should be reduced from 180 mcg to 135 mcg weekly[66]. PegIFN-α2b dose should be reduced by 25% in patients with CrCl of 30-50 mL/min, and by 50% in patients with

CrCl of < 30 mL/min or on hemodialysis[67].

Ribavirin is a nucleoside analogue that when combined with PegIFN increases the rates of SVR. Ribavirin can accumulate in the red blood cells and may lead to hemolytic anemia due to the lack of phosphatase. Toxicity increases significantly with impaired CrCl as its plasma concentration increase when the CrCl is < 50 mL/min. Measuring plasma levels of ribavirin is not a widely available clinical tool. Studies have shown that ribavirin 200 mg or 400 mg on alternate days to be reasonably well tolerated by patients with moderate renal impairment, while in patients with severe renal impairment or on dialysis ribavirin 200 mg daily can be used[68]. Using low-dose ribavirin in CKD patients need more frequent monitoring of hemoglobin[69,70].

Boceprevir selectively inhibits NS3 serine protease, which is vital for HCV RNA replication into virions inside the host cells[71]. In phase 3 clinical trials, boceprevir combined with PegIFN and ribavirin in HCV genotype 1 achieved SVR of 60% for treatment naïve HCV patients, and 63% SVR for relapsers and previous partial responders[72,73]. A study by Treitel *et al*[74] showed no significant pharmacokinetic changes in patients with liver and renal impairments. The authors suggest that boceprevir dose modification is not necessary in patients on dialysis[74].

Telaprevir in combination with PegIFN and ribavirin achieved up to 75% SVR in treatment naïve HCV Genotype 1 patients, while in previous relapsers, partial responders and null responders the SVR were up to 88%, 59% and 33% respectively, *vs* 24%, 15% and 5% in the PegIFN/ribavirin arm[75]. Telaprevir plasma concentration increase by 21% in patients with renal impairment compared to normal renal functions[76]. According to the package insert, telaprevir does not require any dose adjustment in patients with mild, moderate or severe renal impairment[77].

A recent study by Mauss *et al*[78], reported that 4.7% patients on boceprevir and 6.6% patients on telaprevir experienced reduction in estimated glomerular filtration rate (eGFR) to < 60 mL/min compared to 0.9% in the PegIFN and ribavirin only group ($P < 0.05$). Several factors contributing to the reduction in GFR were older age ($P < 0.001$), hypertension ($P < 0.05$), higher serum baseline creatinine ($P < 0.001$) and being on triple therapy PegIFN/ribavirin with boceprevir or telaprevir ($P < 0.01$)[78]. Similar findings were also reported in other studies[79,80].

Simeprevir together with PegIFN plus ribavirin in phase Ⅲ studies achieved SVR rates of 80% and in treatment naïve HCV genotype 1 patients and previous relapsers to PegIFN/ribavirin compared to 36.1% in PegIFN/ribavirin group[81]. No dose adjustment is needed in mild, moderate or severe renal impairment but the data on simeprevir in ESRD or dialysis patients is lacking[82].

In treatment naïve HCV genotype 1, sofosbuvir with PegIFN plus ribavirin therapy for 12 wk achieved SVR up to 89%[83]. With the approval of sofosbuvir and ribavirin, interferon free regimen is now available for genotype 2 and 3 patients. For genotype 2 HCV patients, sofosbuvir with ribavirin for 12 wk yielded 95%-97% SVR in treatment naïve patients and 82%-90% SVR rate in previously treated patients. In HCV genotype 3 patients, sofosbuvir with ribavirin for 24 wk produced SVR rate of 93% in treatment naïve and 77% in previously treated patients[83,84]. No dose adjustment is required in renal impaired patients. However, sofosbuvir package insert does not recommend the use of this drug in those with severe renal impairment or ESRD due to higher exposures of the predominant sofosbuvir metabolite[85]. EASL and AASLD/IDSA/IAS-USA2014 guidelines on HCV treatment do not recommend sofosbuvir in patients with eGFR of < 30 mL/min per 1.73 m^2 or with ESRD until more data are available[55,86].

Apart from the above, there are also specific restrictions on co-administration of certain drug categories with each of DAAs mentioned above which may affect the plasma levels of these DAAs. For instance, sofosbuvir co-administration with drugs which induce P-glycoprotein like rifampin, carbamazepine, phenytoin or St. John's wort are not allowed[85]. In the case of simeprevir, dose adjustments are needed with some medications that are commonly prescribed in CKD patients like anti-arrhythmics, warfarin, calcium channel blockers, antibiotics, antifungals and 3-hydroxy-3-methyl-glutaryl-Co-A reductase inhibitors[82]. As CKD patients are likely to be prescribed various medications for their co-morbidities, taking a good medication history and checking for drug-drug interactions are important steps before initiating treatment with DAAs.

Table 1 shows a summary of recommendations on HCV therapy in various stages of renal impairment according to the various guidelines. A summary of systematic reviews on the treatment of HCV in patients with renal disease is shown in Table 2.

TREATMENT FOR HEPATITIS C RELATED GLOMERULONEPHRITIS

In the current understanding of HCV related glomerulonephritis (GN), HCV is the infectious agent which cause GN. The renal disease shows injury from immune complex deposition and cryoglobulins. According to the recent AASLD/IDSA/IAS-USA hepatitis C guideline, HCV patients with type 2 or 3 essential mixed cryoglobulinemia and end-organ manifestations (*e.g.*, vasculitis), proteinuria, nephrotic syndrome, or membranoproliferative glomerulonephritis are included in the highest priority for anti-HCV treatment due to the high risk for severe complications[87]. Progressive renal disease, proteinuria to the extent of nephrotic syndrome and hypertension are the main manifestations of GN. Therefore a multi-prong approach to the management of HCV related GN involves controlling the clinical manifestations and protecting the kidneys, eradicating HCV, and also reducing the formation and deposition of HCV containing immune complexes in the glomeruli. Anti-hypertensive and anti-proteinuric

Table 1 Summary of recommendations on hepatitis C virus therapy in various stages of renal impairment according to guidelines

CKD stage	KDIGO 2008	APASL 2012	EASL 2014	AASLD/IDSA/IAS-USA 2014
Stage 1 and 2 Stage 1 = GFR ⩾ 90 mL/min per 1.73 m^2 Stage 2 = GFR 60-89 mL/min per 1.73 m^2	PegIFN and ribavirin Dose of ribavirin to be titrated to patient's tolerance	PegIFN and ribavirin		PegIFN and ribavirin/sofosbuvir/simeprevir Dose of: (1) PegIFN 2a is 180 μg/wk (2) PegIFN 2b is 1.5 μg/kg per week (3) Ribavirin is 1000 mg or 1200 mg if body weight < 75 kg or ⩾ 75 kg (4) Sofosbuvir is 400 mg daily (5) Simeprevir is 150 mg daily
Stage 3, 4 and 5 Stage 3 = GFR 30-59 mL/min per 1.73 m^2 Stage 4 = GFR 15-29 mL/min per 1.73 m^2 Stage 5 = GFR < 15 mL/min per 1.73 m^2	PegIFN Dose of PegIFN to be adjusted to renal function	PegIFN and ribavirin Dose of: (1) PegIFN 2a is 135 μg/wk (2) PegIFN 2b is 1 μg/kg per week (3) Ribavirin is 200-800 mg/d		For GFR = 30-50 mL/min per 1.73 m^2 PegIFN and ribavirin/sofosbuvir/simeprevir Dose of: (1) PegIFN 2a is 180 μg/wk (2) PegIFN 2b is 1 μg/kg per week or 25% reduction (3) Ribavirin is alternating doses 200 and 400 mg every other day (4) Sofosbuvir is 400 mg daily (5) Simeprevir is 150 mg daily For GFR < 30 mL/min per 1.73 m^2 PegIFN and ribavirin/simeprevir Dose of: (1) PegIFN 2a is 135 μg/wk (2) PegIFN 2b is 1 μg/kg per week or 50% reduction (3) Ribavirin is 200 mg daily (4) Simeprevir is 150 mg daily
Stage 5D GFR < 15 mL/min per 1.73 m^2 on maintenance hemodialysis	Conventional IFN Dose to be adjusted to a GFR < 15 mL/min per 1.73 m^2	Conventional IFN or PegIFN and markedly reduced dose of ribavirin Dose of: (1) PegIFN 2a is 135 μg/wk (2) PegIFN 2b is 1 μg/kg per week	IFN free and if possible ribavirin free but no safety and efficacy data	PegIFN or conventional IFN and ribavirin Dose of: (1) PegIFN 2a is 135 μg/wk (2) PegIFN 2b is 1 μg/kg per week (3) Conventional IFN is 3 mU 3 x/wk (4) Ribavirin is 200 mg/d

CKD: Chronic kidney disease; KDIGO: Kidney Disease Improving Global Outcome; APASL: Asian Pacific Association for the Study of the Liver; EASL: European Association for the Study of the Liver; AASLD: American Association for the Study of Liver Disease; IDSA: Infectious Disease Society of America; IAS-USA: International Antiviral Society-United States of America; PegIFN: Pegylated interferon; IFN: Interferon; GFR: Glomerular filtration rate; KDIGO 2008: Patients with genotypes 1 or 4 is for 48 wk of therapy if an early virological response (EVR) is obtained at 12 wk (> 2 log fall in viral titer). Genotype 2 or 3 is for 24 wk[9]. APASL 2012: Patients with genotypes 1 is for 48 wk treatment if achieve a complete EVR at week 12, if achieved rapid virological response (HCV RNA undetectable) at week 4 and HCV RNA at baseline is < 400000 IU/mL for shorten treatment to 24 wk and if not achieve an EVR at week 12, but show a significant reduction in HCV RNA levels (partial EVR) and negativity of HCV RNA at week 24 (late virological response, LVR), treatment may be continued up to 72 wk. For Genotype 2 or 3 is 24 wk treatment[26]. EASL 2014: Regimens for patients with genotype 1 are 12 wk of sofosbuvir/ribavirin/PegIFN or 12 wk of sofosbuvir/simeprevir/ribavirin or 24 wk of sofosbuvir/ribavirin. For genotype 2 is 12 wk of sofosbuvir/ribavirin. For genotype 3 are 24 wk of sofosbuvir/ribavirin or 12 wk of sofosbuvir/ribavirin/PegIFN. For genotype 4 are 12 wk of sofosbuvir/ribavirin/PegIFN or 24 wk of sofosbuvir/ribavirin or 24 wk PegIFN/ribavirin/simeprevir for first 12 wk. For genotype 5 or 6 are 12 wk of sofosbuvir/ribavirin/PegIFN or 24 wk of sofosbuvir/ribavirin[55]. AASLD/IDSA/IAS-USA 2014: Regimens for patients with genotype 1 are 12 wk of sofosbuvir/ribavirin/PegIFN or 12 wk of sofosbuvir/ribavirin/simeprevir or 24 wk of PegIFN/ ribavirin/simeprevir for first 12 wk or 24 wk of sofosbuvir/ribavirin or 24 wk of sofosbuvir/simeprevir. For genotype 2 is 12 wk of sofosbuvir/ribavirin. For genotype 3 are 24 wk of sofosbuvir/ribavirin or 12 wk of sofosbuvir/ribavirin/PegIFN. For genotype 4 are 12 wk of sofosbuvir/ribavirin/PegIFN or 24 wk of sofosbuvir/ribavirin or 24-48 wk of PegIFN/ ribavirin/sofosbuvir for first 12 wk. For genotype 5 or 6 are 12 wk of sofosbuvir/ribavirin/PegIFN or 48 wk of PegIFN/ribavirin[132].

medications are reno-protective agents, which will delay progression of renal disease while anti-hyperlipidemic therapy may also be required. Diuretics administered together with angiotensin converting enzymes inhibitors and/or angiotensin receptor blockers were proven to be effective[88,89].

Data on specific treatment in HCV related GN was generally limited. Anti-viral therapies like IFN with or without ribavirin were studied in small number of clinical trials or pilot studies and the results were heterogenous. A systematic review on anti-viral therapy in symptomatic HCV-associated mixed cryoglobulinemia showed that combination therapy of PegIFN and ribavirin achieved SVR of 0.52 (95%CI: 0.40; 0.63) while conventional IFN plus ribavirin achieved SVR of 0.32 (95%CI: 0.15; 0.49)[90]. Other than anti-HCV treatment, immunosuppressive agents (cytotoxics and corticosteroids) and plasma exchange are also among the approach in treating HCV related GN. HCV related cryoglobulinemic GN is currently using a more targeted approach, which are anti-virals, B-cell depletion therapy and non-specific immunosuppressive therapy[91]. Fabrizi *et al*[92] in a recent review article on HCV-mixed cryoglobulinemia have divided treatment strategies based on clinical-biological presentation. The presentations were divided to mild to moderate disease, severe disease and life threatening[92]. Mild to moderate disease was

Table 2 Summary of systematic reviews on hepatitis C virus treatment in patients with renal disease

HCV and renal condition/ref. and year	No. of trials/patients	Types and duration of treatment	SVR	Notes
Glomerulonephritis				
Fabrizi *et al*[90] (2013)	Trials = 10	Combination of PegIFN plus ribavirin 6 mo to more than 12 mo	52%	Dropout rate = 15%
	Patients = 300	Conventional IFN plus ribavirin 6 mo to more than 12 mo	32%	
Acute Hepatitis C				
Fabrizi *et al*[116] (2012)	Trials = 8	Conventional or PegIFN	58%	Dropout rate = 9%
	Patients = 173	3 mo to 12 mo		Genotype 1 = 49%
Hemodialysis				
Fabrizi *et al*[117] (2008)	Trials = 28	Conventional IFN or PegIFN	31%-39%	Dropout rate = 19%-27%
	Patients = 645			
Fabrizi *et al*[118] (2010)	Trials = 16	PegIFN	33%-38%	Dropout rate = 23%
	Patients = 254	24-48 wk		
Fabrizi *et al*[122] (2011)	Trials = 10	Conventional interferon + ribavirin or Peg-IFN + ribavirin	56%	Dropout rate = 25%
	Patients = 151	24-48 wk		Genotype 1 = 58.3%
Renal transplant				
Wei *et al*[128] (2014)	Trials = 12	Conventional IFN monotherapy or Conventional IFN plus ribavirin or PegIFN + ribavirin	26.6% PegIFN base = 40.6%	Dropout rate = 21.1%
	Patients = 140	3.5 to 33 mo	Conventional IFN base = 20.9%	Graft rejection rates = 4%

HCV: Hepatitis C virus; SVR: Sustained viral response; IFN: Interferon; PegIFN: Pegylated interferon.

defined as no worsening nephritis, polyneuropathy or other complications. Severe disease was defined as progressive motor neuropathy, worsening nephritis and extensive skin involvement. Life-threatening disease was defined as rapidly progressing GN, central nervous system, gastrointestinal with or without respiratory involvement.

Studies on anti-viral agents used in HCV related GN were mainly explored in small observational studies. Most of these studies showed positive effects of anti-viral therapy in terms of achieving SVR and clinical improvement[93-97]. In HCV-mixed cryoglobulinemia, the use of standard IFN alpha monotherapy showed high frequency of viral and clinical relapse[98,99]. Combination of IFN alpha with ribavirin has shown improvement in HCV-mixed cryoglobulinemia patients with cutaneous, kidney and neurologic manifestation[100] together with better rate of clinical and viral response[95]. In HCV-related GN, IFN alpha monotherapy was shown to improve proteinuria and HCV RNA clearance compared to immunosuppressive therapy with corticosteroids, but no significant improvement of kidney function by either treatment was observed[101]. The authors suggested that further well-designed study is needed. In a recent meta-analysis of 11 controlled and uncontrolled clinical studies on IFN-based anti-HCV therapy in CKD patients showed significantly decrease in proteinuria and stabilization of serum creatinine. Improvement in proteinuria is related to SVR but there was no association between serum creatinine and HCV RNA clearance[102].

Rituximab is an anti-CD20 monoclonal antibody which cause rapid depletions of B-cells and therefore interferes with cryoglobulins and monoclonal IgM production. In HCV-mixed cryoglobulinemia, the use of rituximab was shown to reduce proteinuria significantly[103] and achieve complete clinical response in up to 60%-70% of patients[104]. A prospective cohort study by Saadoun *et al*[97] showed that rituximab plus PegIFN and ribavirin produced better renal response rate (normalization of serum creatinine and resolution of proteinuria and/or hematuria), shorter time to clinical remission and higher rate of cryoglobulin clearance compared to PegIFN and ribavirin only therapy in HCV-mixed cryoglobulinemia patients[97]. Hence rituximab may be considered in severe or life-threatening disease.

Corticosteroids and other immunosuppressive agents like cyclophosphamide or azathioprine may be considered in life threatening HCV-mixed cryoglobulinemic vasculitis. High dose corticosteroids may induce remission during the acute stage. However, several studies that evaluated the use of immunosuppressive agents gave variable results with small success rates[23,105,106].

A problem with the use of steroids or immuno-suppressive agents is the increase in HCV replications and consequent detrimental effects on the liver. Acute exacerbation with increase in serum transaminases and HCV RNA viral load had been reported in cancer patients with chronic hepatitis C who received treatment with chemotherapy and the use of rituximab is an associated risk factor[107]. The KDIGO guideline on GN noted that cyclical corticosteroids or alkylating agents is contrain-dicated in idiopathic membranous nephropathy when there is untreated infection including hepatitis C.

Plasmapheresis theoretically removes immune complexes and cryoglobulins[108]. It is usually performed during acute phase or life-threatening disease and is effective in rapidly progressive GN[109]. It may be useful in patients with poor response to anti-viral therapy or immunosuppressant.

The recent KDIGO clinical practice guideline for GN

recommended the use of PegIFN alpha plus ribavirin in patients with moderate proteinuria, stable renal functions (CKD stages 1 and 2) and mild to moderate histological changes[110]. In nephrotic range proteinuria and/or rapid progressive GN and acute flare of cryoglobulinemia, rituximab or plasmapheresis, cyclophosphamide and intravenous corticosteroids should be given[9]. Once the acute phase has resolved, IFN-alpha therapy may be initiated to prevent exacerbation of cryoglobulinemic vasculitis[111]. It is unclear how soon the anti-HCV therapy should be initiated after starting the immunosuppressive agents; further research in the optimal treatment of this group of patients is required[104].

TREATMENT FOR ACUTE HEPATITIS C IN CKD PATIENTS

Acute hepatitis C occur among CKD populations mainly due to past blood transfusions, horizontal transmissions or even from nosocomial infections in dialysis unit. This is a concern as 85%-90% of untreated acute hepatitis C progress to chronic hepatitis C[112]. Data on treatment in acute HCV infection among CKD patients is limited, partly due to the silent nature of an acute HCV infection causing difficulty in the diagnosis. Spontaneous clearance of HCV RNA in acute hepatitis C occur in 5%-30% of patients[112-114], hence, KDIGO 2008 recommended waiting for a minimum 12 wk before initiating HCV treatment in CKD patients[9]. Treatment of acute hepatitis C in hemodialysis patients with conventional IFN achieved higher rate of HCV RNA clearance compared to those not treated. Patients given high dose IFN (6-10 million units three times per week) therapy are more likely to stop therapy compared to those on low dose IFN (3 million units three times per week) due to adverse events[113]. A study on acute hepatitis C hemodialysis patients, showed high SVR rate at 88.6% in those receiving PegIFN 135 mcg once per week *vs* 16.7% spontaneous viral clearance rate in the control group[115]. A meta-analysis on treatment of acute HCV in patients on dialysis with conventional or PegIFN showed SVR rates of 58% (95%CI: 38:77) and dropout rates of 9% (95%CI: 4:14)[116]. The higher SVR rate achieved in dialysis patients with acute HCV compared to chronic HCV underscore the need to treat acute HCV infection in hemodialysis patients to reduce the risk of chronicity.

TREATMENT FOR CHRONIC HEPATITIS C IN HEMODIALYSIS PATIENTS

The higher prevalence of HCV infection in hemodialysis patients compared to the general population, as well as robust data showing increased mortality in HCV positive hemodialysis patients and renal transplants patients and the higher risk of all cause renal graft loss are some of the reasons why HCV positive hemodialysis patients need to be treated[3,9,29,30,34]. Two meta-analyses by Fabrizi *et al*[117] found that SVR rate for HCV infected hemodialysis patients treated with conventional IFN monotherapy resulted in SVR of 39% and a drop-out rate of 19%[117], while for PegIFN monotherapy the SVR was 33% and drop-out rate was 23%[118]. The adverse effects were mainly anemia and gastrointestinal symptoms. However, late side effects such as neurological and cardiovascular adverse effects were the main reasons for discontinuation of therapy. The reason for the high occurrence of side effects was probably due to altered pharmacokinetics of IFN in ESRD patients; doubling of the plasma IFN concentration-time curve was observed in ESRD patients compared to normal kidney function patients[119]. Gradual increase in the IFN-alpha is an option to improve tolerability and achieve adequate dose of treatment and consequently better SVR. Treatment with PegIFN-α2b monotherapy beginning with a dose of 0.5 μg/kg per week, and gradually increasing every 4 wk to a maximum of 1 μg/kg per week resulted in an overall SVR rate of 50% while in genotype 3 patients the SVR rate was 80%[120].

Ribavirin is mainly removed by the kidneys and there is very little elimination by hemodialysis. The use of ribavirin in patients with ESRD, therefore, carries a significant risk of hemolytic anemia. A recent randomized trial compared PegIFN monotherapy *vs* the combination of PegIFN and ribavirin 200 mg daily in treatment naïve HCV genotype 1 hemodialysis patients[121]. The combination therapy group had a significantly lower hemoglobin level (less than 8.5 g/dL) compared to monotherapy group (72% *vs* 6%, $P < 0.001$) but a significantly higher SVR rate (64% *vs* 33%, $P < 0.001$). The drop out rate was slightly higher in combination therapy group compared to monotherapy group (7% *vs* 4%). A systemic review revealed that combination therapy of PegIFN plus ribavirin in hemodialysis patients with HCV infection resulted in SVR rate of 56% and dropout rate of 25%[122]. Heart failure and anemia were recognized as the main reasons for the high dropout rate[102]. Patients for combination therapy with IFN and ribavirin are recommended to receive a lower dose of Ribavirin of 200-400 mg three times weekly with closer monitoring for anemia at weekly intervals. Other strategies to prevent worsening of anemia is to optimize the use of erythropoietin and intravenous iron supplement[9].

The role of triple therapy consisting of first generation PI with the backbone of PegIFN and ribavirin in long-term hemodialysis HCV-genotype 1 patients remains unclear. A pilot study on the use of telaprevir-based triple therapy reported efficacy with good tolerability in ESRD patients who previously failed to achieve SVR with PegIFN/ribavirin therapy. Three out of 4 patients achieved undetectable HCV RNA at 12 wk with telaprevir-based triple therapy[123]. In another study, therapy with telaprevir, PegIFN plus ribavirin was evaluated in 7 HCV-infected ESRD patients on hemodialysis; six out of 7 patients achieved SVR with the majority (5/7 patients) developing

anemia < 10 g/dL[124]. Newer direct-acting antiviral agents are in the horizon, however as most studies or clinical trials did not include patients with abnormal renal function, the use of these newer anti-HCV treatments in patients with renal impairment requires further evaluation.

TREATMENT FOR CHRONIC HEPATITIS C IN POST-KIDNEY TRANSPLANT PATIENTS

In organ transplant setting, hepatitis C viral replications have been shown to increase significantly with chronic immunosuppression use and after corticosteroids treatment for acute rejection[125,126]. Treatment of HCV with IFN alpha after renal transplant showed variable graft rejections rates of 15%-100% and a 20% chance for permanent renal allograft failure[127]. A recent meta-analysis in HCV infected renal transplant patients who received anti-HCV therapy with conventional IFN or PegIFN with or without ribavirin found that the SVR rate was 26.6 % (95%CI: 15.0%-38.1%), dropout rate of 21.1% (95%CI: 10.9%-31.2%) and the graft rejection rate was 4% (95%CI: 0.8%-7.1%). In the PegIFN-based therapy the SVR was up to 40.6% and graft rejection rate was 4% while in conventional IFN-based therapy group, the SVR was only 20.9%, and graft dysfunction was 19.2%. Combination therapy of conventional IFN or PegIFN with ribavirin led to a better SVR rate compared to monotherapy, with the best results achieved with PegIFN and ribavirin combination[128]. In another study, it was shown that the risk of renal allograft rejection is higher in the first year post transplantation therefore delaying interferon treatment after the first anniversary of transplant is preferred[129]. However most guidelines do not recommend IFN treatment for HCV in kidney transplant recipients[9,26,55]. Initiating IFN therapy with the possibility of renal graft loss and return to the need for hemodialysis is probably justifiable and unavoidable in cases of severe rapidly progressive liver failure from fibrosing cholestatic hepatitis and life-threatening vasculitis[9]. Comprehensive discussion on the risks and benefits of such therapy must be made with the individual patient. As IFN treatment has a limited role in patients post renal transplant, studies on the use of IFN-free therapy in this group of patients is urgently required. The newer generation DAAs like sofosbuvir and daclatasvir have been reported to salvage liver transplant patients with HCV related fibrosing cholestasis[130].

There are limited data on the use of the new DAAs together with the calcineurin inhibitors like cyclosporins and tacrolimus in HCV-infected post renal transplant recipients. Prescribing information from boceprevir and telaprevir showed significant increase in plasma concentration of cyclosporin, sirolimus or tacrolimus, thus the plasma concentration level of these drugs should be monitored closely[77,131]. The AASLD/IDSA guideline does not recommend the co-administration of simeprevir and cyclosporine[132] based on a pharmacokinetic study of simeprevir, daclatasvir and ribavirin in recurrent hepatitis C patients after orthotopic liver transplant, where the simeprevir plasma concentration was found to be raised by 6-fold in the presence of cyclosporin[133]. According to the AASLD/IDSA guidelines, no dose adjustment is required for combination therapy of sofosbuvir and simeprevir when co-administered with tacrolimus based on studies in liver transplant patients.

CONCLUSION

HCV infection is strongly associated with CKD, as both the cause and the consequence. Furthermore, HCV imparts a major medical burden in renal patients and increases the mortality of ESRD patients whether maintained on hemodialysis or after renal transplant. Successful anti-HCV therapy in this setting ameliorates these poor outcomes. It is vital for clinicians involved in the care of HCV patients to recognize, diagnose and manage the kidney component of this viral infection. Annual testing for proteinuria and hematuria should be part of the screening tests in chronic hepatitis C patients. The management of HCV patients should also include prevention of modifiable risk factors for HCV related CKD like diabetes and hyperlipidemia. However without large-scale clinical trials in this subpopulation of HCV patients with associated kidney disease, the current recommendations and common day-to-day practice are based on extrapolation from the non-CKD population and incorporating necessary dose adjustments based on the pharmacology of these drugs. The poor tolerability and efficacy from current PegIFN and low dose ribavirin in HCV patients with ESRD, call for an urgent need for interferon-free anti-HCV regimens. Clinical studies on pharmacokinetics, safety and efficacy of the newer anti-HCV agents in this group of patients are ongoing[134]. With the rapid pace of development of the newer DAAs that we have been observing, interferon-free regimen may soon become a reality and will offer a new hope for everyone living with HCV.

REFERENCES

1 Chapter 1: Definition and classification of CKD. *Kidney Int Suppl* (2011) 2013; **3**: 19-62 [PMID: 25018975 DOI: 10.1038/kisup.2012.64]

2 **WHO**. Hepatitis C Factsheets. [Accessed on 2014 August 1]. Available from: URL: http: //www.who.int/mediacentre/factsheets/fs164/en/

3 **Wreghitt TG**. Blood-borne virus infections in dialysis units--a review. *Rev Med Virol* 1999; **9**: 101-109 [PMID: 10386337]

4 **Chan TM**, Lok AS, Cheng IK, Chan RT. Prevalence of hepatitis C virus infection in hemodialysis patients: a longitudinal study comparing the results of RNA and antibody assays. *Hepatology* 1993; **17**: 5-8 [PMID: 7678575]

5 **Li WC**, Lee YY, Chen IC, Wang SH, Hsiao CT, Loke SS. Age and gender differences in the relationship between hepatitis C infection and all stages of Chronic kidney disease. *J Viral Hepat* 2014; **21**: 706-715 [PMID: 24304473 DOI: 10.1111/jvh.12199]

6 **El-Serag HB**, Hampel H, Yeh C, Rabeneck L. Extrahepatic

manifestations of hepatitis C among United States male veterans. *Hepatology* 2002; **36**: 1439-1445 [PMID: 12447870 DOI: 10.1053/jhep.2002.37191]

7 **Chen YC**, Lin HY, Li CY, Lee MS, Su YC. A nationwide cohort study suggests that hepatitis C virus infection is associated with increased risk of chronic kidney disease. *Kidney Int* 2014; **85**: 1200-1207 [PMID: 24257691 DOI: 10.1038/ki.2013.455]

8 **Lee JJ**, Lin MY, Yang YH, Lu SN, Chen HC, Hwang SJ. Association of hepatitis C and B virus infection with CKD in an endemic area in Taiwan: a cross-sectional study. *Am J Kidney Dis* 2010; **56**: 23-31 [PMID: 20400217 DOI: 10.1053/j.ajkd.2010.01.015]

9 **Kidney Disease: Improving Global Outcomes (KDIGO)**. KDIGO clinical practice guidelines for the prevention, diagnosis, evaluation, and treatment of hepatitis C in chronic kidney disease. *Kidney Int Suppl* 2008; (**109**): S1-99 [PMID: 18382440 DOI: 10.1038/ki.2008.81]

10 **Fabrizi F**, Dixit V, Messa P. Impact of hepatitis C on survival in dialysis patients: a link with cardiovascular mortality? *J Viral Hepat* 2012; **19**: 601-607 [PMID: 22863263 DOI: 10.1111/j.1365-2893.2012.01633.x]

11 **Pawlotsky JM**. New hepatitis C virus (HCV) drugs and the hope for a cure: concepts in anti-HCV drug development. *Semin Liver Dis* 2014; **34**: 22-29 [PMID: 24782255 DOI: 10.1055/s-0034-1371007]

12 **Cacoub P**, Renou C, Rosenthal E, Cohen P, Loury I, Loustaud-Ratti V, Yamamoto AM, Camproux AC, Hausfater P, Musset L, Veyssier P, Raguin G, Piette JC. Extrahepatic manifestations associated with hepatitis C virus infection. A prospective multicenter study of 321 patients. The GERMIVIC. Groupe d'Etude et de Recherche en Medecine Interne et Maladies Infectieuses sur le Virus de l'Hepatite C. *Medicine* (Baltimore) 2000; **79**: 47-56 [PMID: 10670409]

13 **Tsui JI**, Vittinghoff E, Shlipak MG, Bertenthal D, Inadomi J, Rodriguez RA, O'Hare AM. Association of hepatitis C seropositivity with increased risk for developing end-stage renal disease. *Arch Intern Med* 2007; **167**: 1271-1276 [PMID: 17592100 DOI: 10.1001/archinte.167.12.1271]

14 **Lee JJ**, Lin MY, Chang JS, Hung CC, Chang JM, Chen HC, Yu ML, Hwang SJ. Hepatitis C virus infection increases risk of developing end-stage renal disease using competing risk analysis. *PLoS One* 2014; **9**: e100790 [PMID: 24971499 DOI: 10.1371/journal.pone.0100790]

15 **Dai CY**, Yeh ML, Huang CF, Hou CH, Hsieh MY, Huang JF, Lin IL, Lin ZY, Chen SC, Wang LY, Chuang WL, Yu ML, Tung HD. Chronic hepatitis C infection is associated with insulin resistance and lipid profiles. *J Gastroenterol Hepatol* 2013; Epub ahead of print [PMID: 23808794 DOI: 10.1111/jgh.12313]

16 **Ozkok A**, Yildiz A. Hepatitis C virus associated glomerulopathies. *World J Gastroenterol* 2014; **20**: 7544-7554 [PMID: 24976695 DOI: 10.3748/wjg.v20.i24.7544]

17 **Roccatello D**, Fornasieri A, Giachino O, Rossi D, Beltrame A, Banfi G, Confalonieri R, Tarantino A, Pasquali S, Amoroso A, Savoldi S, Colombo V, Manno C, Ponzetto A, Moriconi L, Pani A, Rustichelli R, Di Belgiojoso GB, Comotti C, Quarenghi MI. Multicenter study on hepatitis C virus-related cryoglobulinemic glomerulonephritis. *Am J Kidney Dis* 2007; **49**: 69-82 [PMID: 17185147 DOI: 10.1053/j.ajkd.2006.09.015]

18 **Sethi S**, Fervenza FC. Membranoproliferative glomerulonephritis--a new look at an old entity. *N Engl J Med* 2012; **366**: 1119-1131 [PMID: 22435371 DOI: 10.1056/NEJMra1108178]

19 **Bataille S**, Kaplanski G, Boucraut J, Halfon P, Camus C, Daniel L, Burtey S, Berland Y, Dussol B. Membranoproliferative glomerulonephritis and mixed cryoglobulinemia after hepatitis C virus infection secondary to glomerular NS3 viral antigen deposits. *Am J Nephrol* 2012; **35**: 134-140 [PMID: 22248563 DOI: 10.1159/000335375]

20 **Cao Y**, Zhang Y, Wang S, Zou W. Detection of the hepatitis C virus antigen in kidney tissue from infected patients with various glomerulonephritis. *Nephrol Dial Transplant* 2009; **24**: 2745-2751 [PMID: 19377056 DOI: 10.1093/ndt/gfp167]

21 **Fabrizi F**, Lunghi G, Messa P, Martin P. Therapy of hepatitis C virus-associated glomerulonephritis: current approaches. *J Nephrol* 2008; **21**: 813-825 [PMID: 19034865]

22 **Monti G**, Galli M, Invernizzi F, Pioltelli P, Saccardo F, Monteverde A, Pietrogrande M, Renoldi P, Bombardieri S, Bordin G. Cryoglobulinaemias: a multi-centre study of the early clinical and laboratory manifestations of primary and secondary disease. GISC. Italian Group for the Study of Cryoglobulinaemias. *QJM* 1995; **88**: 115-126 [PMID: 7704562]

23 **Tarantino A**, Campise M, Banfi G, Confalonieri R, Bucci A, Montoli A, Colasanti G, Damilano I, D'Amico G, Minetti L. Long-term predictors of survival in essential mixed cryoglobulinemic glomerulonephritis. *Kidney Int* 1995; **47**: 618-623 [PMID: 7723249]

24 **Castillo I**, Martinez-Ara J, Olea T, Bartolomé J, Madero R, Hernández E, Bernis C, Aguilar A, Quiroga JA, Carreño V, Selgas R. High prevalence of occult hepatitis C virus infection in patients with primary and secondary glomerular nephropathies. *Kidney Int* 2014; **86**: 619-624 [PMID: 24646855 DOI: 10.1038/ki.2014.68]

25 **Kong D**, Wu D, Wang T, Li T, Xu S, Chen F, Jin X, Lou G. Detection of viral antigens in renal tissue of glomerulonephritis patients without serological evidence of hepatitis B virus and hepatitis C virus infection. *Int J Infect Dis* 2013; **17**: e535-e538 [PMID: 23474175 DOI: 10.1016/j.ijid.2013.01.017]

26 **Omata M**, Kanda T, Yu M-L, Yokosuka O, Lim S-G, Jafri W, Tateishi R, Hamid SS, Chuang W-L, Chutaputti A. APASL consensus statements and management algorithms for hepatitis C virus infection. *Hepa Inter* 2012; **6**: 409-435 [DOI: 10.1007/s12072-012-9342-y]

27 **Fissell RB**, Bragg-Gresham JL, Woods JD, Jadoul M, Gillespie B, Hedderwick SA, Rayner HC, Greenwood RN, Akiba T, Young EW. Patterns of hepatitis C prevalence and seroconversion in hemodialysis units from three continents: the DOPPS. *Kidney Int* 2004; **65**: 2335-2342 [PMID: 15149347 DOI: 10.1111/j.1523-1755.2004.00649.x]

28 **Johnson DW**, Dent H, Yao Q, Tranaeus A, Huang CC, Han DS, Jha V, Wang T, Kawaguchi Y, Qian J. Frequencies of hepatitis B and C infections among haemodialysis and peritoneal dialysis patients in Asia-Pacific countries: analysis of registry data. *Nephrol Dial Transplant* 2009; **24**: 1598-1603 [PMID: 19096083 DOI: 10.1093/ndt/gfn684]

29 **Finelli L**, Miller JT, Tokars JI, Alter MJ, Arduino MJ. National surveillance of dialysis-associated diseases in the United States, 2002. *Semin Dial* 2005; **18**: 52-61 [PMID: 15663766 DOI: 10.1111/j.1525-139X.2005.18108.x]

30 **Di Napoli A**, Pezzotti P, Di Lallo D, Petrosillo N, Trivelloni C, Di Giulio S. Epidemiology of hepatitis C virus among long-term dialysis patients: a 9-year study in an Italian region. *Am J Kidney Dis* 2006; **48**: 629-637 [PMID: 16997059 DOI: 10.1053/j.ajkd.2006.07.004]

31 **Fabrizi F**, Martin P, Dixit V, Bunnapradist S, Dulai G. Meta-analysis: Effect of hepatitis C virus infection on mortality in dialysis. *Aliment Pharmacol Ther* 2004; **20**: 1271-1277 [PMID: 15606388 DOI: 10.1111/j.1365-2036.2004.02290.x]

32 **Chou CY**, Wang IK, Liu JH, Lin HH, Wang SM, Huang CC. Comparing survival between peritoneal dialysis and hemodialysis treatment in ESRD patients with chronic hepatitis C infection. *Perit Dial Int* 2010; **30**: 86-90 [PMID: 20056985]

33 **Bose B**, McDonald SP, Hawley CM, Brown FG, Badve SV, Wiggins KJ, Bannister KM, Boudville N, Clayton P, Johnson DW. Effect of dialysis modality on survival of hepatitis C-infected ESRF patients. *Clin J Am Soc Nephrol* 2011; **6**: 2657-2661 [PMID: 21903989 DOI: 10.2215/CJN.02200311]

34 **Fabrizi F**, Martin P, Dixit V, Messa P. Meta-analysis of observational studies: hepatitis C and survival after renal

transplant. *J Viral Hepat* 2014; **21**: 314-324 [PMID: 24716634 DOI: 10.1111/jvh.12148]

35 **Aline-Fardin A**, Rifle G, Martin L, Justrabo E, Bour JB, D'Athis P, Tanter Y, Mousson C. Recurent and de novo membranous glomerulopathy after kidney transplantation. *Transplant Proc* 2009; **41**: 669-671 [PMID: 19328952 DOI: 10.1016/j.transproceed.2009.01.042]

36 **Morales JM**. Hepatitis C virus infection and renal disease after renal transplantation. *Transplant Proc* 2004; **36**: 760-762 [PMID: 15110654 DOI: 10.1016/j.transproceed.2004.03.041]

37 **Cruzado JM**, Carrera M, Torras J, Grinyó JM. Hepatitis C virus infection and de novo glomerular lesions in renal allografts. *Am J Transplant* 2001; **1**: 171-178 [PMID: 12099366]

38 **Delladetsima JK**, Boletis JN, Makris F, Psichogiou M, Kostakis A, Hatzakis A. Fibrosing cholestatic hepatitis in renal transplant recipients with hepatitis C virus infection. *Liver Transpl Surg* 1999; **5**: 294-300 [PMID: 10388502 DOI: 10.1002/lt.500050417]

39 **Delladetsima JK**, Makris F, Psichogiou M, Kostakis A, Hatzakis A, Boletis JN. Cholestatic syndrome with bile duct damage and loss in renal transplant recipients with HCV infection. *Liver* 2001; **21**: 81-88 [PMID: 11318976]

40 **de Oliveira Uehara SN**, Emori CT, da Silva Fucuta Pereira P, Perez RM, Pestana JO, Lanzoni VP, e Silva IS, Silva AE, Ferraz ML. Histological evolution of hepatitis C virus infection after renal transplantation. *Clin Transplant* 2012; **26**: 842-848 [PMID: 22594774 DOI: 10.1111/j.1399-0012.2012.01635.x]

41 **Roth D**, Gaynor JJ, Reddy KR, Ciancio G, Sageshima J, Kupin W, Guerra G, Chen L, Burke GW. Effect of kidney transplantation on outcomes among patients with hepatitis C. *J Am Soc Nephrol* 2011; **22**: 1152-1160 [PMID: 21546575 DOI: 10.1681/ASN.2010060668]

42 **Maluf DG**, Fisher RA, King AL, Gibney EM, Mas VR, Cotterell AH, Shiffman ML, Sterling RK, Behnke M, Posner MP. Hepatitis C virus infection and kidney transplantation: predictors of patient and graft survival. *Transplantation* 2007; **83**: 853-857 [PMID: 17460555 DOI: 10.1097/01.tp.0000259725.96694.0a]

43 **Pereira BJ**, Natov SN, Bouthot BA, Murthy BV, Ruthazer R, Schmid CH, Levey AS. Effects of hepatitis C infection and renal transplantation on survival in end-stage renal disease. The New England Organ Bank Hepatitis C Study Group. *Kidney Int* 1998; **53**: 1374-1381 [PMID: 9573555 DOI: 10.1046/j.1523-1755.1998.00883.x]

44 **Pereira BJ**, Wright TL, Schmid CH, Bryan CF, Cheung RC, Cooper ES, Hsu H, Heyn-Lamb R, Light JA, Norman DJ. Screening and confirmatory testing of cadaver organ donors for hepatitis C virus infection: a U.S. National Collaborative Study. *Kidney Int* 1994; **46**: 886-892 [PMID: 7527878]

45 **Kucirka LM**, Peters TG, Segev DL. Impact of donor hepatitis C virus infection status on death and need for liver transplant in hepatitis C virus-positive kidney transplant recipients. *Am J Kidney Dis* 2012; **60**: 112-120 [PMID: 22560841 DOI: 10.1053/j.ajkd.2012.03.015]

46 **Abbott KC**, Lentine KL, Bucci JR, Agodoa LY, Peters TG, Schnitzler MA. The impact of transplantation with deceased donor hepatitis c-positive kidneys on survival in wait-listed long-term dialysis patients. *Am J Transplant* 2004; **4**: 2032-2037 [PMID: 15575906 DOI: 10.1046/j.1600-6143.2004.00606.x]

47 **Widell A**, Månsson S, Persson NH, Thysell H, Hermodsson S, Blohme I. Hepatitis C superinfection in hepatitis C virus (HCV)-infected patients transplanted with an HCV-infected kidney. *Transplantation* 1995; **60**: 642-647 [PMID: 7570969]

48 **Wolf PL**, Williams D, Coplon N, Coulson AS. Low aspartate transaminase activity in serum of patients undergoing chronic hemodialysis. *Clin Chem* 1972; **18**: 567-568 [PMID: 5026769]

49 **Schrader C**, Schielke A, Ellerbroek L, Johne R. PCR inhibitors - occurrence, properties and removal. *J Appl Microbiol* 2012; **113**: 1014-1026 [PMID: 22747964 DOI: 10.1111/j.1365-2672.2012.05384.x]

50 **Liu CH**, Liang CC, Huang KW, Liu CJ, Chen SI, Lin JW, Hung PH, Tsai HB, Lai MY, Chen PJ, Chen JH, Chen DS, Kao JH. Transient elastography to assess hepatic fibrosis in hemodialysis chronic hepatitis C patients. *Clin J Am Soc Nephrol* 2011; **6**: 1057-1065 [PMID: 21393486 DOI: 10.2215/CJN.04320510]

51 **Pawa S**, Ehrinpreis M, Mutchnick M, Janisse J, Dhar R, Siddiqui FA. Percutaneous liver biopsy is safe in chronic hepatitis C patients with end-stage renal disease. *Clin Gastroenterol Hepatol* 2007; **5**: 1316-1320 [PMID: 17904916 DOI: 10.1016/j.cgh.2007.07.010]

52 **Fabrizi F**, Messa P, Martin P. Current status of renal transplantation from HCV-positive donors. *Int J Artif Organs* 2009; **32**: 251-261 [PMID: 19569034]

53 **Sterling RK**, Sanyal AJ, Luketic VA, Stravitz RT, King AL, Post AB, Mills AS, Contos MJ, Shiffman ML. Chronic hepatitis C infection in patients with end stage renal disease: characterization of liver histology and viral load in patients awaiting renal transplantation. *Am J Gastroenterol* 1999; **94**: 3576-3582 [PMID: 10606322 DOI: 10.1111/j.1572-0241.1999.01649.x]

54 **Martin P**, Carter D, Fabrizi F, Dixit V, Conrad AJ, Artinian L, Peacock V, Han S, Wilkinson A, Lassman CR, Danovitch G. Histopathological features of hepatitis C in renal transplant candidates [see comment]. *Transplantation* 2000; **69**: 1479-1484 [PMID: 10798774]

55 **European Association for the Study of the Liver**. EASL recommendations on treatment of hepatitis C 2014. *J Hepatol* 2014; **61**: 373-395 [PMID: 24818984 DOI: 10.1016/j.jhep.2014.05.001]

56 **Jiang Y**, Huang E, Mehrnia A, Kamgar M, Pham PT, Ogunorunyinka O, Brown I, Danovitch GM, Bunnapradist S. Can aminotransferase-to-platelet ratio index and other non-invasive markers effectively reduce liver biopsies for renal transplant evaluation of hepatitis C virus-positive patients? *Nephrol Dial Transplant* 2014; **29**: 1247-1252 [PMID: 24353319 DOI: 10.1093/ndt/gft485]

57 **Liu CH**, Liang CC, Liu CJ, Hsu SJ, Lin JW, Chen SI, Hung PH, Tsai HB, Lai MY, Chen PJ, Chen JH, Chen DS, Kao JH. The ratio of aminotransferase to platelets is a useful index for predicting hepatic fibrosis in hemodialysis patients with chronic hepatitis C. *Kidney Int* 2010; **78**: 103-109 [PMID: 20357753 DOI: 10.1038/ki.2010.74]

58 **Shaheen AA**, Wan AF, Myers RP. FibroTest and FibroScan for the prediction of hepatitis C-related fibrosis: a systematic review of diagnostic test accuracy. *Am J Gastroenterol* 2007; **102**: 2589-2600 [PMID: 17850410 DOI: 10.1111/j.1572-0241.2007.01466.x]

59 **Goodkin DA**, Bieber B, Gillespie B, Robinson BM, Jadoul M. Hepatitis C infection is very rarely treated among hemodialysis patients. *Am J Nephrol* 2013; **38**: 405-412 [PMID: 24192505 DOI: 10.1159/000355615]

60 **Gürsoy M**, Güvener N, Köksal R, Karavelioğlu D, Baysal C, Ozdemir N, Boyacioğlu S, Bilgin N, Erdal R. Impact of HCV infection on development of posttransplantation diabetes mellitus in renal allograft recipients. *Transplant Proc* 2000; **32**: 561-562 [PMID: 10812113]

61 **Mahmoud IM**, Sobh MA, El-Habashi AF, Sally ST, El-Baz M, El-Sawy E, Ghoneim MA. Interferon therapy in hemodialysis patients with chronic hepatitis C: study of tolerance, efficacy and post-transplantation course. *Nephron Clin Pract* 2005; **100**: c133-c139 [PMID: 15855796 DOI: 10.1159/000085442]

62 **Cruzado JM**, Casanovas-Taltavull T, Torras J, Baliellas C, Gil-Vernet S, Grinyó JM. Pretransplant interferon prevents hepatitis C virus-associated glomerulonephritis in renal allografts by HCV-RNA clearance. *Am J Transplant* 2003; **3**: 357-360 [PMID: 12614294]

63 **van der Meer AJ**, Veldt BJ, Feld JJ, Wedemeyer H, Dufour JF,

Lammert F, Duarte-Rojo A, Heathcote EJ, Manns MP, Kuske L, Zeuzem S, Hofmann WP, de Knegt RJ, Hansen BE, Janssen HL. Association between sustained virological response and all-cause mortality among patients with chronic hepatitis C and advanced hepatic fibrosis. *JAMA* 2012; **308**: 2584-2593 [PMID: 23268517 DOI: 10.1001/jama.2012.144878]

64 **Hsu YC**, Lin JT, Ho HJ, Kao YH, Huang YT, Hsiao NW, Wu MS, Liu YY, Wu CY. Antiviral treatment for hepatitis C virus infection is associated with improved renal and cardiovascular outcomes in diabetic patients. *Hepatology* 2014; **59**: 1293-1302 [PMID: 24122848 DOI: 10.1002/hep.26892]

65 **Gordon CE**, Uhlig K, Schmid CH, Levey AS, Wong JB. Long-term viral negativity after interferon for chronic hepatitis C virus infection in hemodialysis. *Clin J Am Soc Nephrol* 2011; **6**: 2226-2234 [PMID: 21784816 DOI: 10.2215/CJN.00410111]

66 Pegasys Prescribing Information. [Accessed on 15 July 2014]. Available from: URL: http: //www.gene.com/download/pdf/pegasys_prescribing.pdf

67 **Gupta SK**, Pittenger AL, Swan SK, Marbury TC, Tobillo E, Batra V, Sack M, Glue P, Jacobs S, Affrime M. Single-dose pharmacokinetics and safety of pegylated interferon-alpha2b in patients with chronic renal dysfunction. *J Clin Pharmacol* 2002; **42**: 1109-1115 [PMID: 12362925]

68 **Brennan BJ**, Wang K, Blotner S, Magnusson MO, Wilkins JJ, Martin P, Solsky J, Nieforth K, Wat C, Grippo JF. Safety, tolerability, and pharmacokinetics of ribavirin in hepatitis C virus-infected patients with various degrees of renal impairment. *Antimicrob Agents Chemother* 2013; **57**: 6097-6105 [PMID: 24080649 DOI: 10.1128/AAC.00608-13]

69 **Alavian SM**, Tabatabaei SV. Meta-analysis of factors associated with sustained viral response in patients on hemodialysis treated with standard or pegylated interferon for hepatitis C infection. *Iran J Kidney Dis* 2010; **4**: 181-194 [PMID: 20622305]

70 **Yu YC**, Wang Y, He CL, Wang MR, Wang YM. Management of hepatitis C virus infection in hemodialysis patients. *World J Hepatol* 2014; **6**: 419-425 [PMID: 25018852 DOI: 10.4254/wjh.v6.i6.419]

71 **Njoroge FG**, Chen KX, Shih NY, Piwinski JJ. Challenges in modern drug discovery: a case study of boceprevir, an HCV protease inhibitor for the treatment of hepatitis C virus infection. *Acc Chem Res* 2008; **41**: 50-59 [PMID: 18193821 DOI: 10.1021/ar700109k]

72 **Poordad F**, McCone J, Bacon BR, Bruno S, Manns MP, Sulkowski MS, Jacobson IM, Reddy KR, Goodman ZD, Boparai N, DiNubile MJ, Sniukiene V, Brass CA, Albrecht JK, Bronowicki JP. Boceprevir for untreated chronic HCV genotype 1 infection. *N Engl J Med* 2011; **364**: 1195-1206 [PMID: 21449783 DOI: 10.1056/NEJMoa1010494]

73 **Bacon BR**, Gordon SC, Lawitz E, Marcellin P, Vierling JM, Zeuzem S, Poordad F, Goodman ZD, Sings HL, Boparai N, Burroughs M, Brass CA, Albrecht JK, Esteban R. Boceprevir for previously treated chronic HCV genotype 1 infection. *N Engl J Med* 2011; **364**: 1207-1217 [PMID: 21449784 DOI: 10.1056/NEJMoa1009482]

74 **Treitel M**, Marbury T, Preston RA, Triantafyllou I, Feely W, O'Mara E, Kasserra C, Gupta S, Hughes EA. Single-dose pharmacokinetics of boceprevir in subjects with impaired hepatic or renal function. *Clin Pharmacokinet* 2012; **51**: 619-628 [PMID: 22799589 DOI: 10.2165/11633440-000000000-00000]

75 **Zeuzem S**, Andreone P, Pol S, Lawitz E, Diago M, Roberts S, Focaccia R, Younossi Z, Foster GR, Horban A, Ferenci P, Nevens F, Müllhaupt B, Pockros P, Terg R, Shouval D, van Hoek B, Weiland O, Van Heeswijk R, De Meyer S, Luo D, Boogaerts G, Polo R, Picchio G, Beumont M. Telaprevir for retreatment of HCV infection. *N Engl J Med* 2011; **364**: 2417-2428 [PMID: 21696308 DOI: 10.1056/NEJMoa1013086]

76 **Matthews SJ**, Lancaster JW. Telaprevir: a hepatitis C NS3/4A protease inhibitor. *Clin Ther* 2012; **34**: 1857-1882 [PMID: 22951253 DOI: 10.1016/j.clinthera.2012.07.011]

77 **Vertex**. Incivek (Telaprevir) Prescribing Information. [Accessed on 27th August 2014]. Available from: URL: http: //pi.vrtx.com/files/uspi_telaprevir.pdf

78 **Mauss S**, Hueppe D, Alshuth U. Renal impairment is frequent in chronic hepatitis C patients under triple therapy with telaprevir or boceprevir. *Hepatology* 2014; **59**: 46-48 [PMID: 23813604 DOI: 10.1002/hep.26602]

79 **Virlogeux V**, Pradat P, Bailly F, Funingana G, Gonçalves F, Maynard M, Hartig-Lavie K, Amiri M, Zoulim F. Boceprevir and telaprevir-based triple therapy for chronic hepatitis C: virological efficacy and impact on kidney function and model for end-stage liver disease score. *J Viral Hepat* 2014; **21**: e98-e107 [PMID: 24612466 DOI: 10.1111/jvh.12237]

80 **Loustaud-Ratti V**, Rousseau A, Carrier P, Vong C, Chambaraud T, Jacques J, Debette-Gratien M, Sautereau D, Essig M. eGFR decrease during antiviral C therapy with first generation protease inhibitors: a clinical significance? *Liver Int* 2014; Epub ahead of print [PMID: 25039814 DOI: 10.1111/liv.12631]

81 **Forns X**, Lawitz E, Zeuzem S, Gane E, Bronowicki JP, Andreone P, Horban A, Brown A, Peeters M, Lenz O, Ouwerkerk-Mahadevan S, Scott J, De La Rosa G, Kalmeijer R, Sinha R, Beumont-Mauviel M. Simeprevir with peginterferon and ribavirin leads to high rates of SVR in patients with HCV genotype 1 who relapsed after previous therapy: a phase 3 trial. *Gastroenterology* 2014; **146**: 1669-79.e3 [PMID: 24602923 DOI: 10.1053/j.gastro.2014.02.051]

82 **Janssen**. Olysio (Simeprevir) Prescribing Information. [Accessed 3rd August 2014]. Available from: URL: http: //www.olysio.com/shared/product/olysio/prescribing-information.pdf

83 **Lawitz E**, Mangia A, Wyles D, Rodriguez-Torres M, Hassanein T, Gordon SC, Schultz M, Davis MN, Kayali Z, Reddy KR, Jacobson IM, Kowdley KV, Nyberg L, Subramanian GM, Hyland RH, Arterburn S, Jiang D, McNally J, Brainard D, Symonds WT, McHutchison JG, Sheikh AM, Younossi Z, Gane EJ. Sofosbuvir for previously untreated chronic hepatitis C infection. *N Engl J Med* 2013; **368**: 1878-1887 [PMID: 23607594 DOI: 10.1056/NEJMoa1214853]

84 **Jacobson IM**, Gordon SC, Kowdley KV, Yoshida EM, Rodriguez-Torres M, Sulkowski MS, Shiffman ML, Lawitz E, Everson G, Bennett M, Schiff E, Al-Assi MT, Subramanian GM, An D, Lin M, McNally J, Brainard D, Symonds WT, McHutchison JG, Patel K, Feld J, Pianko S, Nelson DR. Sofosbuvir for hepatitis C genotype 2 or 3 in patients without treatment options. *N Engl J Med* 2013; **368**: 1867-1877 [PMID: 23607593 DOI: 10.1056/NEJMoa1214854]

85 **Gilead**. Sovaldi (Sofosbuvir) Prescribing Information. [Accessed on 2nd August 2014]. Available from: URL: http: //www.gilead.com/~/media/Files/pdfs/medicines/liver-disease/sovaldi/sovaldi_pi.pdf

86 **AASLD/IDSA/IAS-USA**. Unique Patient Populations: Renal Impairment Box. Summary of recommendations for Patients with Renal Impairment Including Severe Renal Impairment (CrCl <30 ML/min) or ESRD Requiring Hemodialysis or Peritoneal Dialysis. [Accessed 26th August 2014]. Available from: URL: http: //hcvguidelines.org/full-report/unique-patient-populations-renal-impairment-box-summary-recommendations-patients-renal

87 **AASLD/IDSA/IAS-USA**. When and in Whom to Initiate HCV Therapy. [Accessed 26th August 2014]. Available from: URL: http: //hcvguidelines.org/full-report/when-and-whom-initiate-hcv-therapy

88 **Klahr S**, Levey AS, Beck GJ, Caggiula AW, Hunsicker L, Kusek JW, Striker G. The effects of dietary protein restriction and blood-pressure control on the progression of chronic renal disease. Modification of Diet in Renal Disease Study Group. *N Engl J Med* 1994; **330**: 877-884 [PMID: 8114857 DOI: 10.1056/NEJM199403313301301]

89 Randomised placebo-controlled trial of effect of ramipril on decline in glomerular filtration rate and risk of terminal

renal failure in proteinuric, non-diabetic nephropathy. The GISEN Group (Gruppo Italiano di Studi Epidemiologici in Nefrologia). *Lancet* 1997; **349**: 1857-1863 [PMID: 9217756]

90 **Fabrizi F**, Dixit V, Messa P. Antiviral therapy of symptomatic HCV-associated mixed cryoglobulinemia: meta-analysis of clinical studies. *J Med Virol* 2013; **85**: 1019-1027 [PMID: 23588727 DOI: 10.1002/jmv.23562]

91 **Fabrizi F**, Donato F, Messa P. Hepatitis C virus infection and glomerular disease. *Minerva Urol Nefrol* 2014; **66**: 139-149 [PMID: 24988205]

92 **Fabrizi F**, Plaisier E, Saadoun D, Martin P, Messa P, Cacoub P. Hepatitis C virus infection, mixed cryoglobulinemia, and kidney disease. *Am J Kidney Dis* 2013; **61**: 623-637 [PMID: 23102733 DOI: 10.1053/j.ajkd.2012.08.040]

93 **Bruchfeld A**, Lindahl K, Ståhle L, Söderberg M, Schvarcz R. Interferon and ribavirin treatment in patients with hepatitis C-associated renal disease and renal insufficiency. *Nephrol Dial Transplant* 2003; **18**: 1573-1580 [PMID: 12897097]

94 **Alric L**, Plaisier E, Thébault S, Péron JM, Rostaing L, Pourrat J, Ronco P, Piette JC, Cacoub P. Influence of antiviral therapy in hepatitis C virus-associated cryoglobulinemic MPGN. *Am J Kidney Dis* 2004; **43**: 617-623 [PMID: 15042538]

95 **Saadoun D**, Resche-Rigon M, Thibault V, Piette JC, Cacoub P. Antiviral therapy for hepatitis C virus--associated mixed cryoglobulinemia vasculitis: a long-term followup study. *Arthritis Rheum* 2006; **54**: 3696-3706 [PMID: 17075881 DOI: 10.1002/art.22168]

96 **Garini G**, Allegri L, Lannuzzella F, Vaglio A, Buzio C. HCV-related cryoglobulinemic glomerulonephritis: implications of antiviral and immunosuppressive therapies. *Acta Biomed* 2007; **78**: 51-59 [PMID: 17687818]

97 **Saadoun D**, Resche Rigon M, Sene D, Terrier B, Karras A, Perard L, Schoindre Y, Coppéré B, Blanc F, Musset L, Piette JC, Rosenzwajg M, Cacoub P. Rituximab plus Peg-interferon-alpha/ribavirin compared with Peg-interferon-alpha/ribavirin in hepatitis C-related mixed cryoglobulinemia. *Blood* 2010; **116**: 326-334; quiz 504-505 [PMID: 20439619 DOI: 10.1182/blood-2009-10-248518]

98 **Naarendorp M**, Kallemuchikkal U, Nuovo GJ, Gorevic PD. Longterm efficacy of interferon-alpha for extrahepatic disease associated with hepatitis C virus infection. *J Rheumatol* 2001; **28**: 2466-2473 [PMID: 11708420]

99 **Casato M**, Agnello V, Pucillo LP, Knight GB, Leoni M, Del Vecchio S, Mazzilli C, Antonelli G, Bonomo L. Predictors of long-term response to high-dose interferon therapy in type II cryoglobulinemia associated with hepatitis C virus infection. *Blood* 1997; **90**: 3865-3873 [PMID: 9354653]

100 **Zuckerman E**, Keren D, Slobodin G, Rosner I, Rozenbaum M, Toubi E, Sabo E, Tsykounov I, Naschitz JE, Yeshurun D. Treatment of refractory, symptomatic, hepatitis C virus related mixed cryoglobulinemia with ribavirin and interferon-alpha. *J Rheumatol* 2000; **27**: 2172-2178 [PMID: 10990230]

101 **Fabrizi F**, Bruchfeld A, Mangano S, Dixit V, Messa P, Martin P. Interferon therapy for HCV-associated glomerulonephritis: meta-analysis of controlled trials. *Int J Artif Organs* 2007; **30**: 212-219 [PMID: 17417760]

102 **Feng B**, Eknoyan G, Guo ZS, Jadoul M, Rao HY, Zhang W, Wei L. Effect of interferon-alpha-based antiviral therapy on hepatitis C virus-associated glomerulonephritis: a meta-analysis. *Nephrol Dial Transplant* 2012; **27**: 640-646 [PMID: 21558431 DOI: 10.1093/ndt/gfr236]

103 **Quartuccio L**, Soardo G, Romano G, Zaja F, Scott CA, De Marchi G, Fabris M, Ferraccioli G, De Vita S. Rituximab treatment for glomerulonephritis in HCV-associated mixed cryoglobulinaemia: efficacy and safety in the absence of steroids. *Rheumatology* (Oxford) 2006; **45**: 842-846 [PMID: 16418196 DOI: 10.1093/rheumatology/kel004]

104 **Cacoub P**, Delluc A, Saadoun D, Landau DA, Sene D. Anti-CD20 monoclonal antibody (rituximab) treatment for cryoglobulinemic vasculitis: where do we stand? *Ann Rheum Dis* 2008; **67**: 283-287 [PMID: 17644544 DOI: 10.1136/ard.2006.065565]

105 **Misiani R**, Bellavita P, Fenili D, Vicari O, Marchesi D, Sironi PL, Zilio P, Vernocchi A, Massazza M, Vendramin G. Interferon alfa-2a therapy in cryoglobulinemia associated with hepatitis C virus. *N Engl J Med* 1994; **330**: 751-756 [PMID: 8107741 DOI: 10.1056/NEJM199403173301104]

106 **Dammacco F**, Sansonno D, Han JH, Shyamala V, Cornacchiulo V, Iacobelli AR, Lauletta G, Rizzi R. Natural interferon-alpha versus its combination with 6-methyl-prednisolone in the therapy of type II mixed cryoglobulinemia: a long-term, randomized, controlled study. *Blood* 1994; **84**: 3336-3343 [PMID: 7524736]

107 **Mahale P**, Kontoyiannis DP, Chemaly RF, Jiang Y, Hwang JP, Davila M, Torres HA. Acute exacerbation and reactivation of chronic hepatitis C virus infection in cancer patients. *J Hepatol* 2012; **57**: 1177-1185 [PMID: 22871500 DOI: 10.1016/j.jhep.2012.07.031]

108 **Koziolek MJ**, Scheel A, Bramlage C, Groene HJ, Mueller GA, Strutz F. Effective treatment of hepatitis C-associated immune-complex nephritis with cryoprecipitate apheresis and antiviral therapy. *Clin Nephrol* 2007; **67**: 245-249 [PMID: 17474561]

109 **Saadoun D**, Delluc A, Piette JC, Cacoub P. Treatment of hepatitis C-associated mixed cryoglobulinemia vasculitis. *Curr Opin Rheumatol* 2008; **20**: 23-28 [PMID: 18281853 DOI: 10.1097/BOR.0b013e3282f1330c]

110 Chapter 9: Infection-related glomerulonephritis. *Kidney Int Suppl* (2011) 2012; **2**: 200-208 [PMID: 25018934 DOI: 10.1038/kisup.2012.22]

111 **Cid MC**, Hernández-Rodríguez J, Robert J, del Río A, Casademont J, Coll-Vinent B, Grau JM, Kleinman HK, Urbano-Márquez A, Cardellach F. Interferon-alpha may exacerbate cryoblobulinemia-related ischemic manifestations: an adverse effect potentially related to its anti-angiogenic activity. *Arthritis Rheum* 1999; **42**: 1051-1055 [PMID: 10323463 DOI: 10.1002/1529-0131(199905)42:5<1051::AID-ANR26>3.0.CO;2-Q]

112 **Espinosa M**, Martin-Malo A, Alvarez de Lara MA, Gonzalez R, Rodriguez M, Aljama P. Natural history of acute HCV infection in hemodialysis patients. *Clin Nephrol* 2002; **58**: 143-150 [PMID: 12227687]

113 **Gürsoy M**, Gür G, Arslan H, Ozdemir N, Boyacioglu S. Interferon therapy in haemodialysis patients with acute hepatitis C virus infection and factors that predict response to treatment. *J Viral Hepat* 2001; **8**: 70-77 [PMID: 11155154]

114 **Furusyo N**, Hayashi J, Kakuda K, Ariyama I, Kanamoto-Tanaka Y, Shimizu C, Etoh Y, Shigematsu M, Kashiwagi S. Acute hepatitis C among Japanese hemodialysis patients: a prospective 9-year study. *Am J Gastroenterol* 2001; **96**: 1592-1600 [PMID: 11374705 DOI: 10.1111/j.1572-0241.2001.03701.x]

115 **Liu CH**, Liang CC, Liu CJ, Lin JW, Chen SI, Hung PH, Tsai HB, Lai MY, Chen PJ, Chen DS, Kao JH. Pegylated interferon alfa-2a monotherapy for hemodialysis patients with acute hepatitis C. *Clin Infect Dis* 2010; **51**: 541-549 [PMID: 20645865 DOI: 10.1086/655682]

116 **Fabrizi F**, Dixit V, Messa P, Martin P. Interferon therapy of acute hepatitis C in dialysis patients: meta-analysis. *J Viral Hepat* 2012; **19**: 784-791 [PMID: 23043385 DOI: 10.1111/j.1365-2893.2012.01607.x]

117 **Fabrizi F**, Dixit V, Messa P, Martin P. Interferon monotherapy of chronic hepatitis C in dialysis patients: meta-analysis of clinical trials. *J Viral Hepat* 2008; **15**: 79-88 [PMID: 18184190 DOI: 10.1111/j.1365-2893.2007.00907.x]

118 **Fabrizi F**, Dixit V, Messa P, Martin P. Pegylated interferon monotherapy of chronic hepatitis C in dialysis patients: Meta-analysis of clinical trials. *J Med Virol* 2010; **82**: 768-775 [PMID: 20336712 DOI: 10.1002/jmv.21542]

119 **Rostaing L**, Chatelut E, Payen JL, Izopet J, Thalamas C, Ton-That H, Pascal JP, Durand D, Canal P. Pharmacokinetics of alphaIFN-2b in chronic hepatitis C virus patients undergoing chronic hemodialysis or with normal renal function: clinical implications. *J Am Soc Nephrol* 1998; **9**: 2344-2348 [PMID: 9848789]

120 **Tan SS**, Abu Hassan MR, Abdullah A, Ooi BP, Korompis T, Merican MI. Safety and efficacy of an escalating dose regimen of pegylated interferon alpha-2b in the treatment of haemodialysis patients with chronic hepatitis C. *J Viral Hepat* 2010; **17**: 410-418 [PMID: 19758272 DOI: 10.1111/j.1365-2893.2009.01191.x]

121 **Liu CH**, Huang CF, Liu CJ, Dai CY, Liang CC, Huang JF, Hung PH, Tsai HB, Tsai MK, Chen SI, Lin JW, Yang SS, Su TH, Yang HC, Chen PJ, Chen DS, Chuang WL, Yu ML, Kao JH. Pegylated interferon-α2a with or without low-dose ribavirin for treatment-naive patients with hepatitis C virus genotype 1 receiving hemodialysis: a randomized trial. *Ann Intern Med* 2013; **159**: 729-738 [PMID: 24297189 DOI: 10.7326/0003-4819-159-11-201312030-00005]

122 **Fabrizi F**, Dixit V, Martin P, Messa P. Combined antiviral therapy of hepatitis C virus in dialysis patients: meta-analysis of clinical trials. *J Viral Hepat* 2011; **18**: e263-e269 [PMID: 21108701 DOI: 10.1111/j.1365-2893.2010.01405.x]

123 **Dumortier J**, Guillaud O, Gagnieu MC, Janbon B, Juillard L, Morelon E, Leroy V. Anti-viral triple therapy with telaprevir in haemodialysed HCV patients: is it feasible? *J Clin Virol* 2013; **56**: 146-149 [PMID: 23149155 DOI: 10.1016/j.jcv.2012.10.009]

124 **Wiegand J**, Maasoumy B, Buggisch P, Buslau A, Schiefke I, Berg T, Wedemeyer H, Sarrazin C, Hinrichsen H. Letter: Telaprevir triple therapy in chronic hepatitis C genotype 1 patients receiving haemodialysis. *Aliment Pharmacol Ther* 2014; **39**: 1342-1344 [PMID: 24803258 DOI: 10.1111/apt.12748]

125 **Rostaing L**, Izopet J, Sandres K, Cisterne JM, Puel J, Durand D. Changes in hepatitis C virus RNA viremia concentrations in long-term renal transplant patients after introduction of mycophenolate mofetil. *Transplantation* 2000; **69**: 991-994 [PMID: 10755563]

126 **Gane EJ**, Naoumov NV, Qian KP, Mondelli MU, Maertens G, Portmann BC, Lau JY, Williams R. A longitudinal analysis of hepatitis C virus replication following liver transplantation. *Gastroenterology* 1996; **110**: 167-177 [PMID: 8536853]

127 **Okoh EJ**, Bucci JR, Simon JF, Harrison SA. HCV in patients with end-stage renal disease. *Am J Gastroenterol* 2008; **103**: 2123-2134 [PMID: 18796105 DOI: 10.1111/j.1572-0241.2008.01981.x]

128 **Wei F**, Liu J, Liu F, Hu H, Ren H, Hu P. Interferon-based anti-viral therapy for hepatitis C virus infection after renal transplantation: an updated meta-analysis. *PLoS One* 2014; **9**: e90611 [PMID: 24699257 DOI: 10.1371/journal.pone.0090611]

129 **Baid S**, Tolkoff-Rubin N, Saidman S, Chung R, Williams WW, Auchincloss H, Colvin RB, Delmonico FL, Cosimi AB, Pascual M. Acute humoral rejection in hepatitis C-infected renal transplant recipients receiving antiviral therapy. *Am J Transplant* 2003; **3**: 74-78 [PMID: 12492714]

130 **Fontana RJ**, Hughes EA, Bifano M, Appelman H, Dimitrova D, Hindes R, Symonds WT. Sofosbuvir and daclatasvir combination therapy in a liver transplant recipient with severe recurrent cholestatic hepatitis C. *Am J Transplant* 2013; **13**: 1601-1605 [PMID: 23593993 DOI: 10.1111/ajt.12209]

131 **Merck**. Victrelis Prescribing Information. [Accessed 5th October 2014]. Available from: URL: http: //www.merck.com/product/usa/pi_circulars/v/victrelis/victrelis_pi.pdf

132 **AASLD/IDSA/IAS-USA**. Recommendations for Testing, Managing, and Treating Hepatitis C. [accessed on 26th August 2014]. Available from: URL: http: //hcvguidelines.org/full-report-view

133 **JanssenR&D**. A study of pharmacokinetics, efficacy, safety, tolerability, of the combination of simeprevir (TMC435), daclatasvir (BMS-790052), and ribavirin (RBV) in patients with recurrent chronic hepatitis C genotype 1b infection after orthotopic liver transplantation (posted 2013b). [Accessed on 2 October 2014]. Available from: URL: http: //www.clinicaltrials.gov/ct2/show/NCT01938625

134 ClinicalTrials.gov. Clinical Trials on Chronic Hepatitis C. [Accessed 26th August 2014]. Available from: URL: http: //clinicaltrials.gov/

P- Reviewer: Chang CC, Friedman EA, Salvadori M
S- Editor: Ji FF **L- Editor**: A **E- Editor**: Liu SQ

World Journal of Hepatology

Submit a Manuscript: http://www.wjgnet.com/esps/
Help Desk: http://www.wjgnet.com/esps/helpdesk.aspx
DOI: 10.4254/wjh.v7.i1.93

World J Hepatol 2015 January 27; 7(1): 93-100
ISSN 1948-5182 (online)

TOPIC HIGHLIGHT

WJH 6th Anniversary Special Issues (6): Liver transplantation

From minimal to maximal surgery in the treatment of hepatocarcinoma: A review

Marcos Vinicius Perini, Graham Starkey, Michael A Fink, Ramesh Bhandari, Vijayaragavan Muralidharan, Robert Jones, Christopher Christophi

Marcos Vinicius Perini, Graham Starkey, Michael A Fink, Ramesh Bhandari, Vijayaragavan Muralidharan, Robert Jones, Christopher Christophi, Austin Health, Department of Surgery, University of Melbourne, Heidelberg, VIC 3084, Australia

Author contributions: Perini MV designed the review, collected data, wrote the manuscript; Starkey G reviewed the manuscript; Fink MA, Bhandari R, Muralidharan V, Jones R and Christophi C reviewed the manuscript.

Correspondence to: Marcos Vinicius Perini, MD, PhD, Austin Health, Department of Surgery, University of Melbourne, 145 Studley Road, Level 8, Heidelberg, VIC 3084, Australia. marcos.perini@unimelb.edu.au
Telephone: +61-422-493101
Fax: +61-394-963670

Received: September 11, 2014
Peer-review started: September 13, 2014
First decision: October 14, 2014
Revised: October 28, 2014
Accepted: November 17, 2014
Article in press: November 19, 2014
Published online: January 27, 2015

Abstract

Hepatocellular carcinoma represents one of the most challenging frontiers in liver surgery. Surgeons have to face a broad spectrum of aspects, from the underlying liver disease to the new surgical techniques. Safe liver resection can be performed in patients with portal hypertension and well-compensated liver function with a 5-year survival rate of 50%, offering good long-terms results in selected patients. With the advances in laparoscopic surgery, major liver resections can be performed with minimal harm, avoiding the wound and leak complications related to the laparotomies. Studies have shown that oncological margins are the same as in open surgery. In patients submitted to liver resection (either laparoscopic or open) who experience recurrence, re-resection or salvage liver transplantation has been showing to be an alternative approach in well selected cases. The decision making approach to the cirrhotic patient is becoming more complex and should involve hepatologists, liver surgeons, radiologists and oncologists. Better understanding of the different risk factors for recurrence and survival should be aimed in these multidisciplinary discussions. We here in discuss the hot topics related to surgical risk factors regarding the surgical treatment of hepatocellular carcinoma: anatomical resection, margin status, macrovascular tumor invasion, the place of laparoscopy, salvage liver transplantation and liver transplantation.

Key words: Hepatectomy; Liver resection; Cirrhosis; Liver transplantation; Hepatocellular carcinoma; Survival

Core tip: The decision making approach to the cirrhotic patient with hepatocellular carcinoma (HCC) represents one of the most challenging frontiers in liver surgery and, as a result, should involve a multidisciplinary assessment. Despite the advances in non-surgical therapies, surgery is still the treatment that can offer the best survival. In patients submitted to liver resection who experience recurrence, re-resection or salvage liver transplantation has been shown to be an alternative approach in well-selected cases. We herein discuss some controversial topics regarding the surgical

treatment of HCC: anatomical resection, margin status, macro-vascular invasion, laparoscopic resection, salvage liver transplantation and liver transplantation.

Perini MV, Starkey G, Fink MA, Bhandari R, Muralidharan V, Jones R, Christophi C. From minimal to maximal surgery in the treatment of hepatocarcinoma: A review. *World J Hepatol* 2015; 7(1): 93-100 Available from: URL: http://www.wjgnet.com/1948-5182/full/v7/i1/93.htm DOI: http://dx.doi.org/10.4254/wjh.v7.i1.93

INTRODUCTION

Hepatocellular carcinoma (HCC) is the most common primary liver cancer and the fifth most common malignancy worldwide[1,2]. In about 90% of cases, it occurs in patients with chronic liver disease[2,3]. In recent years there has been a clear increase in the number of new cases of HCC due to hepatitis B and C infection[3,4].

Although focal ablation techniques can treat small HCCs, the only curative therapeutic options available are surgical resection and liver transplantation (LT). Controversial aspects regarding to the surgical treatment of HCC include the extent of resection, whether it should be achieved by laparoscopic or open approach and their impact on subsequent LT. The question of resection or transplantation and the impact of laparoscopic liver resection (LLR) needs to be addressed. We here in discuss the role of laparoscopic (minimal) and open liver resection and LT (maximal) in the treatment of HCC carcinoma in cirrhotic patients.

LIVER RESECTION

Liver resection, a therapeutic alternative that can be performed readily and with lower costs when compared to LT, is a safe procedure with mortality rates in specialized centers lower than 5%[5]. Survival after liver resection can reach 40%-60% in Eastern and Western series[6], but recurrence is still a major problem. Recurrence occurs in the liver in around 50%-80% of the cases, being consequence of metastatic spread from the tumor removed or "*de novo*" occurrence due to underlying liver disease[7-9].

In the context of a rising incidence of HCC and a shortage of cadaveric donors, there is a growing discrepancy between the number of transplant candidates on waiting lists and the organs available for transplantation. This shortage can lead to long waiting times, increasing the risk of tumor progression and waiting list drop out[10]. Studies comparing resection and transplantation for HCC have often analyzed only those patients who underwent transplantation-ignoring those patients who dropped off the waiting list due to tumor progression. This approach will tend to produce results in favor of transplantation. To be fair, an intention to treat analysis should be performed[11].

Resection has the advantages of being readily accessible and cheaper when compared to transplantation and doesn't preclude a future liver transplant in the case of tumor recurrence (salvage LT). Moreover, due to advances in surgical technique (mainly laparoscopic approach), care and patient selection, it has become a safe procedure, with mortality rates in specialized centers lower than 5%[12,13]. Good long-term results can be achieved (50%-70% 5-year overall survival) in selected patients[14].

However, resection is followed by high rates of morbidity and mortality in patients with chronic liver disease, being possible only in patients with preserved liver function[15]. In the context of long transplant waiting lists, some groups specialized in both liver surgery and transplantation have advocated resection for the treatment of solitary HCC in patients with preserved liver function[14,16].

It has also been shown that in patients within the Milan criteria, the long-term outcome of those listed for LT (intention to treat analysis) was similar when compared to patients who underwent resection[17]. A recent meta-analysis including studies using case controlled and intention to treat analysis showed that resection and transplantation lead to similar 5-year overall survival (OR = 0.84, 95%CI: 0.48-1.48, $P = 0.45$)[18].

Laparoscopic vs open liver resection

LLR is now considered the gold standard by many specialized hepatobiliary teams for the treatment of selected cases of benign and malignant liver tumors. Its feasibility and safety are reproducible by teams all over the world[19]. Recent series of laparoscopic resection of HCC have shown excellent short and ling long terms results[16,20-29]. A recent meta-analyses showed that LLR resulted in to shorter hospital stay, decreased blood loss, and lower rates of postoperative morbidity (specially ascites and pulmonary complications) when compared to open liver resection[12,16,21,22].

Despite selection bias in the laparoscopic group, rates of positive margins after LLR were lower than or similar to those after open approach[30]. An increase in peritoneal carcinomatosis and port site recurrence does not seem to have been a major issue[18]. Finally, in all studies comparing laparoscopic and open LR for HCC, there was no significant difference in recurrence free and overall survival, suggesting that LLR does not compromise oncological principles.

Anatomical vs non-anatomical resections

LR for HCC can be either anatomical (lobectomy, segmentectomy) or non-anatomical (wedge resection, subsegmental resection). In HCC, intrahepatic metastasis occurs mainly through the portal tract, and may be present before surgery. It has been proposed that the intrahepatic spread of hepatic tumors follows the pattern of step-by-step intrahepatic dissemination[31]. With small

tumors and early metastases, satellite nodules usually lie in the same segment of the main tumor. The anatomical approach is particularly important for the purpose of reducing postoperative intrahepatic tumor recurrence rates.

Anatomical resection, when possible, should be performed[32]. A recent study using meta-regression analysis indicated that the 5-year overall survival and disease-free survival are significantly better with anatomical resection[33]. Recent paper including 543 patients treated with HCC addressing this issue concluded that anatomical resection can lead to a lower recurrence rate in patients presenting tumors with unfavorable features (poorly differentiated and with vascular invasion), suggesting that the higher the invasiveness of the tumor, the greater the need for the removal of the entire liver functional unit[34].

On the other hand, when dealing with cirrhotic patients, leaving sufficient residual liver volume is critical. For small liver HCCs, non-anatomical resection can be carried out without impact on the overall survival[35]. The rationale for this approach is that it may lead to a decrease in the rate of postoperative liver failure and that for small lesions, the risk of local satellites or local portal venous invasion is lower than for lesions more than 5 cm in diameter[36].

Margin status

The optimal resection margin for HCC remains controversial. In a randomized trial comparing a wide 2 cm margin with a margin aiming for 1 cm, improved recurrence-free and overall survival were observed in the wide margin group. However, it is accepted that a 1 cm surgical margin is adequate for the majority of patients with HCC[37]. On the other hand, other authors found that a minimal resection margin (surgical margin less than 1 mm) did not negatively affect postoperative recurrence-free survival[37]. In a recent meta-analysis, Zhou *et al*[38] showed no differences in surgical margins when comparing the open with the LLR group.

Surgeons who are less familiar with liver surgery may be inclined to perform less radical resections. This may represent a lost opportunity for some patients who may have had better long-term prognoses with more radical surgery. In order to minimize the risk of local recurrence and maximize the overall survival chance, a surgical strategy that supports the preference for anatomical and adequate resection with free margins should be adopted whenever possible.

Repeated liver resection

Although not properly addressed in a prospective trial, repeated hepatic resection in patients with solitary liver recurrence resulted in better survival than palliative treatment (37%-86% in 5 years)[39]. The resectability rate varies and depends on the extent of primary resection and the functional status of the remnant liver[40] and even repeated laparoscopic resection can be carried out in selected patients[41]. Poor prognostic factors associated with repeated liver resection for HCC are: vascular invasion in the primary surgery, short recurrence interval, tumor size, gender, estimated blood loss[39,40,42].

Vascular invasion

Vascular invasion is a well-defined prognostic factor for overall and disease free survival in patients with HCC either submitted to resection or transplantation[43,44]. Macrovascular invasion is considered a formal contra-indication to resection and invariably patients with macrovascular invasion submitted to LT suffer from recurrence. As proposed by the barcelona clinic liver cancer, patients with macrovascular invasion are sent for palliative treatment (Sorafenib) or best supportive care[43,44]. Overall survival for patients with portal vein invasion or hepatic vein invasion is 2.7 mo and 5 mo, respectively. The overall survival for patients treated with Sorafenib is 6 mo[43-45].

Although not universally accepted, liver resection for HCC with macrovascular invasion may be an option in highly selected patients, in whom a survival of around 10% in 5 year can be offered. Equivalent survival is not achievable with other forms of treatment. In recent surgical series including HCC patients with macrovascular invasion, the postoperative mortality and morbidity ranges from 3.4% to 7.7% and from 30.8% to 37.1%, respectively[46]. In a multicentric study on 102 HCC patients with macrovascular invasion treated by surgical resection, Pawlik *et al*[47] reported a 5-year survival rate of 10%.

Chok *et al*[46] described the following three approaches for patients with portal vein thrombus based on the extension of the tumor thrombosis: group 1, HCC with ipsilateral portal vein tumor thrombus resected in a hepatectomy; group 2, HCC with portal vein tumor thrombus extending to or beyond the portal vein bifurcation, treated by en bloc resection followed by portal vein reconstruction; group 3, portal vein tumor trombosis extending to or beyond the portal vein bifurcation, treated by thrombectomy. The short and long-term results were similar among the three groups with a 5-year overall survival rate of 11.2%, 12.5% and 14.3%, respectively[46].

After HCC resection, the hepatic remnant is the most common site of tumor recurrence ranging from 68% to 91% of patients so a close follow up strategy should be adopted[48]. While macroscopic vascular invasion can be detected at imaging, microscopic vascular invasion is impossible to visualize before operation. The presence of microvascular invasion can only be confirmed by histological examination of resected specimen.

LT

LT has become a standard procedure adopted worldwide in the treatment of end stage liver disease with remarkable good results, even for malignancy (1 year overall survival of > 80% and 5-year around 70%)[49]. LT

has the advantage of removing the previous and potential carcinogenic diseased liver but has the disadvantage of organ allocation.

LT vs liver resection

The choice between LT and resection (LR) is controversial and there are no controlled trials comparing these modalities. Although some can argue that resection is cost effective when compared with LT[50], only LT has the advantage of simultaneously treating the tumor and the underlying liver disease[51]. To achieve good results with transplantation, it is only offered to patients with liver only disease fulfilling strict criteria[51-53]. There is considerable variation around the world in what criteria are used to assess transplant eligibility[52-55].

For many patients with cirrhosis and HCC, the ideal treatment is transplantation-treating the underlying liver condition and at the same time removing the tumor. This also reduces the "*de novo*" formation of cancer. It is crucial to be selective in choosing patients with HCC for transplantation, with many criteria in use around the world. Most criteria use radiological parameters such as tumor size and number as a surrogate marker for biological behavior[52,54-60]

Unfortunately many patients are delisted for transplantation due to progression of the underlying liver disease or tumor progression (beyond the accepted criteria). When comparing survival between LT and LR, many studies have commenced at the time of the transplant and fail to include analysis of the patients removed from the waiting list due to tumor progression (*i.e.,* not an intention to treat analysis). For optimal evaluation of the treatment effect of LT, the waiting time on the list should be included.

Llovet *et al*[45] found a dropout probability of 23%. This resulted in a reduction of 2-year overall survival from 84% to 54%. Waitlist time can serve as a selection period for patients with the best prognosis, because only patients with stable disease undergo transplantation. This might explain the higher recurrence-free survival after LT than in resected patients who did not undergo this selection process. Another reason for better overall survival in different studies might be that LT represents a cure for the underlying cirrhosis, which is the main risk factor for development of HCC. The recurrence rate is higher after LR than orthotopic liver transplant. Given the shortage of deceased donor organs, transplantation for resectable HCC may be considered by some groups an inappropriate use of a precious resource if LR alone in selected cases could achieve a similar overall survival, and together with salvage LT may cure recurrence[18].

For patients with HCC beyond transplant criteria, the Barcelona Clinic Liver Cancer (BCLC) system recommends palliative treatment[61]. Although this system is widely accepted, if followed strictly there are patients who may be denied a curative liver resection and treated with palliative intent with trans-arterial chemoembolization. Many studies criticizing this policy have shown 5-year overall survival of 50% even in patients with large HCC or in patients with multiple nodules[62].

Ruzzenente *et al*[63] conducted a study on 464 HCC patients from a multi-institutional database and found that patients with fewer than three nodules who underwent LR had a higher survival rate than those who were treated with local therapies [including percutaneous ablation and transarterial chemo-embolization (TACE)] with median survival of 58 and 20 mo ($P < 0.01$), respectively. These findings were confirmed by a subsequent randomised controlled trial. In patients with HCC meeting Milan Criteria, the authors reported a 5-year survival rate after liver resection and radiofrequency ablation of 69% and 45% ($P = 0.042$), respectively[64].

A Japanese national survey reported that liver resection has an advantage over local ablative therapies because it can prevent recurrence in individuals with fewer than three HCC nodules that are ≤ 3 cm[65]. Liver resection also appears to provide better long-term survival than percutaneous ablation in patients with less than 3 HCC nodules that are > 3 cm.

In selected patients with multinodular BCLC B (more than 3 nodules) HCC and preserved liver function, LR yielded better long-term results than TACE with 5-year survival rates of 36%-37% and 11%-14%, respectively[62]

Salvage LT

The major drawback of LR is a recurrence rate of about 40% in the first year[66]. Despite this, most authors have shown that those patients can be referred for salvage LT[67-70]. With this strategy, HCC patients who had undergone liver resection with pathological parameters at higher risk of recurrence (*i.e.*, microvascular invasion, satellite nodules) could enter the waiting list for LT directly without waiting for evidence of HCC liver recurrence[71]. On the other hand, Fuks *et al*[72] have shown in 329 transplantable patients enrolled in a intention to treat study that the presence of ≥ 3 poor prognostic factors (from a list of microscopic vascular invasion, presence of satellite nodules, tumor size > 3 cm, poor tumoral differentiation, and existence of cirrhosis) should warrant LT before recurrence. This strategy seemed to save 26 grafts that would otherwise have been used unnecessarily. However only 28% of patients included in intention-to-treat analysis and only 39% of patients with recurrence could receive ST, suggesting that tissue analysis should be used as selection criteria for salvage LT[72]. Whether this policy is clinically effective and would further improve the long-term outcomes of resected patients remains to be evaluated in prospective trials.

Belghiti *et al*[73] showed that patients submitted to salvage transplantation have the same long-term results as those submitted to transplantation as the primary treatment. Indeed, Cherqui *et al*[74] have shown that 77% of patients with recurrent HCC following LLR were transplantable (within Milan criteria). The same group found that the morbidity of salvage LT for HCC was lower following LLR, than open LR[75-77]. Some surgeons

argue that adhesion formation and previous hilar manipulation associated with LR can make subsequent LT difficult or even impossible. However, strategies such as Glissonian approach and the use of Pringle maneuver and intraparenchymal access to liver pedicles to avoid hilar manipulation can be employed in order to decrease the morbidity of repeat liver surgery. The use of anti-adhesive products (Seprafilm®) although proved to facilitate bowel surgery[78] have not been addressed in a randomized trial for liver surgery.

The impact of laparoscopic liver resection *vs* open resection on subsequent LT has not yet been analysed in prospective trials. Theoretical advantages of minimal dissection are less adhesions, minimal manipulation in liver hilum and decreased blood loss[79-81].

CONCLUSION

The main endpoint in the surgical treatment of HCC is to resect the tumor and at the same time preserve remnant liver function. This should be performed with refined techniques and respecting the oncological principals of any cancer surgery. Liver resection and LT are the only curative treatment of HCC. Meanwhile, there are some strategies to increase resectability or to downstage the tumor, such as portal vein embolization, TACE or radiofrequency ablation/percutaneous ethanol injection. Laparoscopic liver resection has gained acceptance and decreases post-operative complications (less ascites and wound related problems). Surgeons can improve disease-free survival by preventing recurrence adopting many strategies, such as > 1 cm surgical margin, anatomical resection encompassing portal area of tumor, using an anterior approach to minimize the risk of tumor cell dissemination, minimizing intraoperative blood loss. Repeat resection is an option in some suitable cases that can be used in the armamentarium of liver surgeons. Salvage transplantation should be offered in non aggressive tumors that recur after liver resection and may improve survival rates. Future clinical research should reveal the optimal combination of therapies in properly selected patients.

REFERENCES

1 **Bosch FX**, Ribes J, Díaz M, Cléries R. Primary liver cancer: worldwide incidence and trends. *Gastroenterology* 2004; **127**: S5-S16 [PMID: 15508102]

2 **El-Serag HB**. Hepatocellular carcinoma: recent trends in the United States. *Gastroenterology* 2004; **127**: S27-S34 [PMID: 15508094]

3 **Rahbari NN**, Mehrabi A, Mollberg NM, Müller SA, Koch M, Büchler MW, Weitz J. Hepatocellular carcinoma: current management and perspectives for the future. *Ann Surg* 2011; **253**: 453-469 [PMID: 21263310 DOI: 10.1097/SLA.0b013e31820d944f]

4 **Davila JA**, Morgan RO, Shaib Y, McGlynn KA, El-Serag HB. Hepatitis C infection and the increasing incidence of hepatocellular carcinoma: a population-based study. *Gastroenterology* 2004; **127**: 1372-1380 [PMID: 15521006]

5 **Fan ST**, Mau Lo C, Poon RT, Yeung C, Leung Liu C, Yuen WK, Ming Lam C, Ng KK, Ching Chan S. Continuous improvement of survival outcomes of resection of hepatocellular carcinoma: a 20-year experience. *Ann Surg* 2011; **253**: 745-758 [PMID: 21475015 DOI: 10.1097/SLA.0b013e3182111195]

6 **Pawlik TM**, Esnaola NF, Vauthey JN. Surgical treatment of hepatocellular carcinoma: similar long-term results despite geographic variations. *Liver Transpl* 2004; **10**: S74-S80 [PMID: 14762844 DOI: 10.1002/lt.20052]

7 **Belghiti J**, Panis Y, Farges O, Benhamou JP, Fekete F. Intrahepatic recurrence after resection of hepatocellular carcinoma complicating cirrhosis. *Ann Surg* 1991; **214**: 114-117 [PMID: 1714267]

8 **Arii S**, Tanaka J, Yamazoe Y, Minematsu S, Morino T, Fujita K, Maetani S, Tobe T. Predictive factors for intrahepatic recurrence of hepatocellular carcinoma after partial hepatectomy. *Cancer* 1992; **69**: 913-919 [PMID: 1310434]

9 **Huang ZY**, Liang BY, Xiong M, Zhan DQ, Wei S, Wang GP, Chen YF, Chen XP. Long-term outcomes of repeat hepatic resection in patients with recurrent hepatocellular carcinoma and analysis of recurrent types and their prognosis: a single-center experience in China. *Ann Surg Oncol* 2012; **19**: 2515-2525 [PMID: 22395985 DOI: 10.1245/s10434-012-2269-7]

10 **Llovet JM**, Burroughs A, Bruix J. Hepatocellular carcinoma. *Lancet* 2003; **362**: 1907-1917 [PMID: 14667750 DOI: 10.1016/S0140-6736(03)14964-1]

11 **Schlansky B**, Chen Y, Scott DL, Austin D, Naugler WE. Waiting time predicts survival after liver transplantation for hepatocellular carcinoma: a cohort study using the United Network for Organ Sharing registry. *Liver Transpl* 2014; **20**: 1045-1056 [PMID: 24838471 DOI: 10.1002/lt.23917]

12 **Simillis C**, Constantinides VA, Tekkis PP, Darzi A, Lovegrove R, Jiao L, Antoniou A. Laparoscopic versus open hepatic resections for benign and malignant neoplasms--a meta-analysis. *Surgery* 2007; **141**: 203-211 [PMID: 17263977 DOI: 10.1016/j.surg.2006.06.035]

13 **Sarpel U**, Hefti MM, Wisnievsky JP, Roayaie S, Schwartz ME, Labow DM. Outcome for patients treated with laparoscopic versus open resection of hepatocellular carcinoma: case-matched analysis. *Ann Surg Oncol* 2009; **16**: 1572-1577 [PMID: 19259738 DOI: 10.1245/s10434-009-0414-8]

14 **Silva MF**, Sapisochin G, Strasser SI, Hewa-Geeganage S, Chen J, Wigg AJ, Jones R, Saraiva R, Kikuchi L, Carrilho F, Fontes PR, Charco R. Liver resection and transplantation offer similar 5-year survival for Child-Pugh-Turcotte A HCC-patients with a single nodule up to 5 cm: a multicenter, exploratory analysis. *Eur J Surg Oncol* 2013; **39**: 386-395 [PMID: 23375469 DOI: 10.1016/j.ejso.2012.12.011]

15 **Santambrogio R**, Kluger MD, Costa M, Belli A, Barabino M, Laurent A, Opocher E, Azoulay D, Cherqui D. Hepatic resection for hepatocellular carcinoma in patients with Child-Pugh's A cirrhosis: is clinical evidence of portal hypertension a contraindication? *HPB* (Oxford) 2013; **15**: 78-84 [PMID: 23216782 DOI: 10.1111/j.1477-2574.2012.00594.x]

16 **Herman P**, Perini MV, Coelho FF, Kruger JA, Lupinacci RM, Fonseca GM, Lopes Fde L, Cecconello I. Laparoscopic resection of hepatocellular carcinoma: when, why, and how? A single-center experience. *J Laparoendosc Adv Surg Tech A* 2014; **24**: 223-228 [PMID: 24568364 DOI: 10.1089/lap.2013.0502]

17 **Pelletier SJ**, Fu S, Thyagarajan V, Romero-Marrero C, Batheja MJ, Punch JD, Magee JC, Lok AS, Fontana RJ, Marrero JA. An intention-to-treat analysis of liver transplantation for hepatocellular carcinoma using organ procurement transplant network data. *Liver Transpl* 2009; **15**: 859-868 [PMID: 19642139 DOI: 10.1002/lt.21778]

18 **Proneth A**, Zeman F, Schlitt HJ, Schnitzbauer AA. Is resection or transplantation the ideal treatment in patients with hepatocellular carcinoma in cirrhosis if both are possible? A systematic review and metaanalysis. *Ann Surg Oncol* 2014; **21**: 3096-3107 [PMID: 24866437 DOI: 10.1245/s10434-014-3808-1]

19 **Dagher I**, O'Rourke N, Geller DA, Cherqui D, Belli G, Gamblin TC, Lainas P, Laurent A, Nguyen KT, Marvin MR, Thomas M, Ravindra K, Fielding G, Franco D, Buell JF. Laparoscopic major hepatectomy: an evolution in standard of care. *Ann Surg* 2009; **250**: 856-860 [PMID: 19806057 DOI: 10.1097/SLA.0b013e3181bcaf46]

20 **Kluger MD**, Cherqui D. Laparoscopic resection of hepatocellular carcinoma. *Recent Results Cancer Res* 2013; **190**: 111-126 [PMID: 22941017 DOI: 10.1007/978-3-642-16037-0_8]

21 **Xiong JJ**, Altaf K, Javed MA, Huang W, Mukherjee R, Mai G, Sutton R, Liu XB, Hu WM. Meta-analysis of laparoscopic vs open liver resection for hepatocellular carcinoma. *World J Gastroenterol* 2012; **18**: 6657-6668 [PMID: 23236242 DOI: 10.3748/wjg.v18.i45.6657]

22 **Zhou YM**, Shao WY, Zhao YF, Xu DH, Li B. Meta-analysis of laparoscopic versus open resection for hepatocellular carcinoma. *Dig Dis Sci* 2011; **56**: 1937-1943 [PMID: 21259071 DOI: 10.1007/s10620-011-1572-7]

23 **Reddy SK**, Tsung A, Geller DA. Laparoscopic liver resection. *World J Surg* 2011; **35**: 1478-1486 [PMID: 21181472 DOI: 10.1007/s00268-010-0906-5]

24 **Belli G**, Fantini C, Belli A, Limongelli P. Laparoscopic liver resection for hepatocellular carcinoma in cirrhosis: long-term outcomes. *Dig Surg* 2011; **28**: 134-140 [PMID: 21540599 DOI: 10.1159/000323824]

25 **Tranchart H**, Di Giuro G, Lainas P, Roudie J, Agostini H, Franco D, Dagher I. Laparoscopic resection for hepatocellular carcinoma: a matched-pair comparative study. *Surg Endosc* 2010; **24**: 1170-1176 [PMID: 19915908 DOI: 10.1007/s00464-009-0745-3]

26 **Lai EC**, Tang CN, Ha JP, Li MK. Laparoscopic liver resection for hepatocellular carcinoma: ten-year experience in a single center. *Arch Surg* 2009; **144**: 143-147; discussion 148 [PMID: 19221325 DOI: 10.1001/archsurg.2008.536]

27 **Bryant R**, Laurent A, Tayar C, van Nhieu JT, Luciani A, Cherqui D. Liver resection for hepatocellular carcinoma. *Surg Oncol Clin N Am* 2008; **17**: 607-633, ix [PMID: 18486886 DOI: 10.1016/j.soc.2008.02.002]

28 **Dagher I**, Belli G, Fantini C, Laurent A, Tayar C, Lainas P, Tranchart H, Franco D, Cherqui D. Laparoscopic hepatectomy for hepatocellular carcinoma: a European experience. *J Am Coll Surg* 2010; **211**: 16-23 [PMID: 20610244 DOI: 10.1016/j.jamcollsurg.2010.03.012]

29 **Aldrighetti L**, Guzzetti E, Pulitanò C, Cipriani F, Catena M, Paganelli M, Ferla G. Case-matched analysis of totally laparoscopic versus open liver resection for HCC: short and middle term results. *J Surg Oncol* 2010; **102**: 82-86 [PMID: 20578084 DOI: 10.1002/jso.21541]

30 **Kim SJ**, Jung HK, Lee DS, Yun SS, Kim HJ. The comparison of oncologic and clinical outcomes of laparoscopic liver resection for hepatocellular carcinoma. *Ann Surg Treat Res* 2014; **86**: 61-67 [PMID: 24761410 DOI: 10.4174/astr.2014.86.2.61]

31 **Zhou XD**. Recurrence and metastasis of hepatocellular carcinoma: progress and prospects. *Hepatobiliary Pancreat Dis Int* 2002; **1**: 35-41 [PMID: 14607620]

32 **Hasegawa K**, Kokudo N, Imamura H, Matsuyama Y, Aoki T, Minagawa M, Sano K, Sugawara Y, Takayama T, Makuuchi M. Prognostic impact of anatomic resection for hepatocellular carcinoma. *Ann Surg* 2005; **242**: 252-259 [PMID: 16041216]

33 **Cucchetti A**, Cescon M, Ercolani G, Bigonzi E, Torzilli G, Pinna AD. A comprehensive meta-regression analysis on outcome of anatomic resection versus nonanatomic resection for hepatocellular carcinoma. *Ann Surg Oncol* 2012; **19**: 3697-3705 [PMID: 22722807 DOI: 10.1245/s10434-012-2450-z]

34 **Cucchetti A**, Qiao GL, Cescon M, Li J, Xia Y, Ercolani G, Shen F, Pinna AD. Anatomic versus nonanatomic resection in cirrhotic patients with early hepatocellular carcinoma. *Surgery* 2014; **155**: 512-521 [PMID: 24439747 DOI: 10.1016/j.surg.2013.10.009]

35 **Tomimaru Y**, Eguchi H, Marubashi S, Wada H, Kobayashi S, Tanemura M, Umeshita K, Doki Y, Mori M, Nagano H. Equivalent outcomes after anatomical and non-anatomical resection of small hepatocellular carcinoma in patients with preserved liver function. *Dig Dis Sci* 2012; **57**: 1942-1948 [PMID: 22407377 DOI: 10.1007/s10620-012-2114-7]

36 **Yamamoto Y**, Ikoma H, Morimura R, Konishi H, Murayama Y, Komatsu S, Shiozaki A, Kuriu Y, Kubota T, Nakanishi M, Ichikawa D, Fujiwara H, Okamoto K, Sakakura C, Ochiai T, Otsuji E. Clinical analysis of anatomical resection for the treatment of hepatocellular carcinoma based on the stratification of liver function. *World J Surg* 2014; **38**: 1154-1163 [PMID: 24305927 DOI: 10.1007/s00268-013-2369-y]

37 **Shi M**, Guo RP, Lin XJ, Zhang YQ, Chen MS, Zhang CQ, Lau WY, Li JQ. Partial hepatectomy with wide versus narrow resection margin for solitary hepatocellular carcinoma: a prospective randomized trial. *Ann Surg* 2007; **245**: 36-43 [PMID: 17197963 DOI: 10.1097/01.sla.0000231758.07868.71]

38 **Zhou Y**, Xu D, Wu L, Li B. Meta-analysis of anatomic resection versus nonanatomic resection for hepatocellular carcinoma. *Langenbecks Arch Surg* 2011; **396**: 1109-1117 [PMID: 21476060 DOI: 10.1007/s00423-011-0784-9]

39 **Tung-Ping Poon R**, Fan ST, Wong J. Risk factors, prevention, and management of postoperative recurrence after resection of hepatocellular carcinoma. *Ann Surg* 2000; **232**: 10-24 [PMID: 10862190]

40 **Roayaie S**, Bassi D, Tarchi P, Labow D, Schwartz M. Second hepatic resection for recurrent hepatocellular cancer: a Western experience. *J Hepatol* 2011; **55**: 346-350 [PMID: 21147184 DOI: 10.1016/j.jhep.2010.11.026]

41 **Chan AC**, Poon RT, Chok KS, Cheung TT, Chan SC, Lo CM. Feasibility of laparoscopic re-resection for patients with recurrent hepatocellular carcinoma. *World J Surg* 2014; **38**: 1141-1146 [PMID: 24305932 DOI: 10.1007/s00268-013-2380-3]

42 **Ho CM**, Lee PH, Shau WY, Ho MC, Wu YM, Hu RH. Survival in patients with recurrent hepatocellular carcinoma after primary hepatectomy: comparative effectiveness of treatment modalities. *Surgery* 2012; **151**: 700-709 [PMID: 22284764 DOI: 10.1016/j.surg.2011.12.015]

43 **Forner A**, Llovet JM, Bruix J. Hepatocellular carcinoma. *Lancet* 2012; **379**: 1245-1255 [PMID: 22353262 DOI: 10.1016/S0140-6736(11)61347-0]

44 **Vitale A**, Morales RR, Zanus G, Farinati F, Burra P, Angeli P, Frigo AC, Del Poggio P, Rapaccini G, Di Nolfo MA, Benvegnù L, Zoli M, Borzio F, Giannini EG, Caturelli E, Chiaramonte M, Trevisani F, Cillo U. Barcelona Clinic Liver Cancer staging and transplant survival benefit for patients with hepatocellular carcinoma: a multicentre, cohort study. *Lancet Oncol* 2011; **12**: 654-662 [PMID: 21684210 DOI: 10.1016/S1470-2045(11)70144-9]

45 **Llovet JM**, Bustamante J, Castells A, Vilana R, Ayuso Mdel C, Sala M, Brú C, Rodés J, Bruix J. Natural history of untreated nonsurgical hepatocellular carcinoma: rationale for the design and evaluation of therapeutic trials. *Hepatology* 1999; **29**: 62-67 [PMID: 9862851 DOI: 10.1002/hep.510290145]

46 **Chok KS**, Cheung TT, Chan SC, Poon RT, Fan ST, Lo CM. Surgical outcomes in hepatocellular carcinoma patients with portal vein tumor thrombosis. *World J Surg* 2014; **38**: 490-496 [PMID: 24132826 DOI: 10.1007/s00268-013-2290-4]

47 **Pawlik TM**, Poon RT, Abdalla EK, Ikai I, Nagorney DM, Belghiti J, Kianmanesh R, Ng IO, Curley SA, Yamaoka Y, Lauwers GY, Vauthey JN. Hepatectomy for hepatocellular carcinoma with major portal or hepatic vein invasion: results of a multicenter study. *Surgery* 2005; **137**: 403-410 [PMID: 15800485 DOI: 10.1016/j.surg.2004.12.012]

48 **Arnaoutakis DJ**, Mavros MN, Shen F, Alexandrescu S, Firoozmand A, Popescu I, Weiss M, Wolfgang CL, Choti MA, Pawlik TM. Recurrence patterns and prognostic factors in patients with hepatocellular carcinoma in noncirrhotic

liver: a multi-institutional analysis. *Ann Surg Oncol* 2014; **21**: 147-154 [PMID: 23959056 DOI: 10.1245/s10434-013-3211-3]

49 **Kim WR**, Stock PG, Smith JM, Heimbach JK, Skeans MA, Edwards EB, Harper AM, Snyder JJ, Israni AK, Kasiske BL. OPTN/SRTR 2011 Annual Data Report: liver. *Am J Transplant* 2013; **13** Suppl 1: 73-102 [PMID: 23237697 DOI: 10.1111/ajt.12021]

50 **Lim KC**, Wang VW, Siddiqui FJ, Shi L, Chan ES, Oh HC, Tan SB, Chow PK. Cost-effectiveness analysis of liver resection versus transplantation for early hepatocellular carcinoma within the Milan criteria. *Hepatology* 2014; Epub ahead of print [PMID: 24638991 DOI: 10.1002/hep.27135]

51 **Mazzaferro V**, Regalia E, Doci R, Andreola S, Pulvirenti A, Bozzetti F, Montalto F, Ammatuna M, Morabito A, Gennari L. Liver transplantation for the treatment of small hepatocellular carcinomas in patients with cirrhosis. *N Engl J Med* 1996; **334**: 693-699 [PMID: 8594428 DOI: 10.1056/NEJM199603143341104]

52 **Yao FY**, Ferrell L, Bass NM, Watson JJ, Bacchetti P, Venook A, Ascher NL, Roberts JP. Liver transplantation for hepatocellular carcinoma: expansion of the tumor size limits does not adversely impact survival. *Hepatology* 2001; **33**: 1394-1403 [PMID: 11391528 DOI: 10.1053/jhep.2001.24563]

53 **Toso C**, Trotter J, Wei A, Bigam DL, Shah S, Lancaster J, Grant DR, Greig PD, Shapiro AM, Kneteman NM. Total tumor volume predicts risk of recurrence following liver transplantation in patients with hepatocellular carcinoma. *Liver Transpl* 2008; **14**: 1107-1115 [PMID: 18668667 DOI: 10.1002/lt.21484]

54 **Mazzaferro V**, Llovet JM, Miceli R, Bhoori S, Schiavo M, Mariani L, Camerini T, Roayaie S, Schwartz ME, Grazi GL, Adam R, Neuhaus P, Salizzoni M, Bruix J, Forner A, De Carlis L, Cillo U, Burroughs AK, Troisi R, Rossi M, Gerunda GE, Lerut J, Belghiti J, Boin I, Gugenheim J, Rochling F, Van Hoek B, Majno P. Predicting survival after liver transplantation in patients with hepatocellular carcinoma beyond the Milan criteria: a retrospective, exploratory analysis. *Lancet Oncol* 2009; **10**: 35-43 [PMID: 19058754 DOI: 10.1016/S1470-2045(08)70284-5]

55 **Lee SG**, Hwang S, Moon DB, Ahn CS, Kim KH, Sung KB, Ko GY, Park KM, Ha TY, Song GW. Expanded indication criteria of living donor liver transplantation for hepatocellular carcinoma at one large-volume center. *Liver Transpl* 2008; **14**: 935-945 [PMID: 18581465 DOI: 10.1002/lt.21445]

56 **Chen JW**, Kow L, Verran DJ, McCall JL, Munn S, Balderson GA, Fawcett JW, Gow PJ, Jones RM, Jeffrey GP, House AK, Strasser SI. Poorer survival in patients whose explanted hepatocellular carcinoma (HCC) exceeds Milan or UCSF Criteria. An analysis of liver transplantation in HCC in Australia and New Zealand. *HPB* (Oxford) 2009; **11**: 81-89 [PMID: 19590628 DOI: 10.1111/j.1477-2574.2009.00022.x]

57 **DuBay D**, Sandroussi C, Sandhu L, Cleary S, Guba M, Cattral MS, McGilvray I, Ghanekar A, Selzner M, Greig PD, Grant DR. Liver transplantation for advanced hepatocellular carcinoma using poor tumor differentiation on biopsy as an exclusion criterion. *Ann Surg* 2011; **253**: 166-172 [PMID: 21294289]

58 **Herrero JI**, Sangro B, Quiroga J, Pardo F, Herraiz M, Cienfuegos JA, Prieto J. Influence of tumor characteristics on the outcome of liver transplantation among patients with liver cirrhosis and hepatocellular carcinoma. *Liver Transpl* 2001; **7**: 631-636 [PMID: 11460231 DOI: 10.1053/jlts.2001.25458]

59 **Ito T**, Takada Y, Ueda M, Haga H, Maetani Y, Oike F, Ogawa K, Sakamoto S, Ogura Y, Egawa H, Tanaka K, Uemoto S. Expansion of selection criteria for patients with hepatocellular carcinoma in living donor liver transplantation. *Liver Transpl* 2007; **13**: 1637-1644 [PMID: 18044766 DOI: 10.1002/lt.21281]

60 **Ravaioli M**, Grazi GL, Piscaglia F, Trevisani F, Cescon M, Ercolani G, Vivarelli M, Golfieri R, D'Errico Grigioni A, Panzini I, Morelli C, Bernardi M, Bolondi L, Pinna AD. Liver transplantation for hepatocellular carcinoma: results of down-staging in patients initially outside the Milan selection criteria. *Am J Transplant* 2008; **8**: 2547-2557 [PMID: 19032223 DOI: 10.1111/j.1600-6143.2008.02409.x]

61 **Forner A**, Reig ME, de Lope CR, Bruix J. Current strategy for staging and treatment: the BCLC update and future prospects. *Semin Liver Dis* 2010; **30**: 61-74 [PMID: 20175034 DOI: 10.1055/s-0030-1247133]

62 **Torzilli G**, Donadon M, Marconi M, Palmisano A, Del Fabbro D, Spinelli A, Botea F, Montorsi M. Hepatectomy for stage B and stage C hepatocellular carcinoma in the Barcelona Clinic Liver Cancer classification: results of a prospective analysis. *Arch Surg* 2008; **143**: 1082-1090 [PMID: 19015467 DOI: 10.1001/archsurg.143.11.1082]

63 **Ruzzenente A**, Capra F, Pachera S, Iacono C, Piccirillo G, Lunardi M, Pistoso S, Valdegamberi A, D'Onofrio M, Guglielmi A. Is liver resection justified in advanced hepatocellular carcinoma? Results of an observational study in 464 patients. *J Gastrointest Surg* 2009; **13**: 1313-1320 [PMID: 19418103 DOI: 10.1007/s11605-009-0903-x]

64 **Huang J**, Yan L, Cheng Z, Wu H, Du L, Wang J, Xu Y, Zeng Y. A randomized trial comparing radiofrequency ablation and surgical resection for HCC conforming to the Milan criteria. *Ann Surg* 2010; **252**: 903-912 [PMID: 21107100 DOI: 10.1097/SLA.0b013e3181efc656]

65 **Hasegawa K**, Makuuchi M, Takayama T, Kokudo N, Arii S, Okazaki M, Okita K, Omata M, Kudo M, Kojiro M, Nakanuma Y, Takayasu K, Monden M, Matsuyama Y, Ikai I. Surgical resection vs. percutaneous ablation for hepatocellular carcinoma: a preliminary report of the Japanese nationwide survey. *J Hepatol* 2008; **49**: 589-594 [PMID: 18620773 DOI: 10.1016/j.jhep.2008.05.018]

66 **Poon RT**, Fan ST, Lo CM, Liu CL, Wong J. Long-term survival and pattern of recurrence after resection of small hepatocellular carcinoma in patients with preserved liver function: implications for a strategy of salvage transplantation. *Ann Surg* 2002; **235**: 373-382 [PMID: 11882759]

67 **Majno PE**, Sarasin FP, Mentha G, Hadengue A. Primary liver resection and salvage transplantation or primary liver transplantation in patients with single, small hepatocellular carcinoma and preserved liver function: an outcome-oriented decision analysis. *Hepatology* 2000; **31**: 899-906 [PMID: 10733546 DOI: 10.1053/he.2000.5763]

68 **Belghiti J**, Cortes A, Abdalla EK, Régimbeau JM, Prakash K, Durand F, Sommacale D, Dondero F, Lesurtel M, Sauvanet A, Farges O, Kianmanesh R. Resection prior to liver transplantation for hepatocellular carcinoma. *Ann Surg* 2003; **238**: 885-892; discussion 892-893 [PMID: 14631225 DOI: 10.1097/01.sla.0000098621.74851.65]

69 **Adam R**, Azoulay D, Castaing D, Eshkenazy R, Pascal G, Hashizume K, Samuel D, Bismuth H. Liver resection as a bridge to transplantation for hepatocellular carcinoma on cirrhosis: a reasonable strategy? *Ann Surg* 2003; **238**: 508-518; discussion 518-519 [PMID: 14530722 DOI: 10.1097/01.sla.0000090449.87109.44]

70 **Del Gaudio M**, Ercolani G, Ravaioli M, Cescon M, Lauro A, Vivarelli M, Zanello M, Cucchetti A, Vetrone G, Tuci F, Ramacciato G, Grazi GL, Pinna AD. Liver transplantation for recurrent hepatocellular carcinoma on cirrhosis after liver resection: University of Bologna experience. *Am J Transplant* 2008; **8**: 1177-1185 [PMID: 18444925 DOI: 10.1111/j.1600-6143.2008.02229.x]

71 **Sala M**, Fuster J, Llovet JM, Navasa M, Solé M, Varela M, Pons F, Rimola A, García-Valdecasas JC, Brú C, Bruix J. High pathological risk of recurrence after surgical resection for hepatocellular carcinoma: an indication for salvage liver transplantation. *Liver Transpl* 2004; **10**: 1294-1300 [PMID: 15376311 DOI: 10.1002/lt.20202]

72 **Fuks D**, Durand F, Belghiti J. The role of biopsy of the nontumorous liver parenchyma in patients considered for

partial resection of small hepatocellular carcinoma. *Hepatology* 2013; **58**: 452 [PMID: 23315837 DOI: 10.1002/hep.26244]

73 **Belghiti J**, Carr BI, Greig PD, Lencioni R, Poon RT. Treatment before liver transplantation for HCC. *Ann Surg Oncol* 2008; **15**: 993-1000 [PMID: 18236111 DOI: 10.1245/s10434-007-9787-8]

74 **Cherqui D**, Laurent A, Mocellin N, Tayar C, Luciani A, Van Nhieu JT, Decaens T, Hurtova M, Memeo R, Mallat A, Duvoux C. Liver resection for transplantable hepatocellular carcinoma: long-term survival and role of secondary liver transplantation. *Ann Surg* 2009; **250**: 738-746 [PMID: 19801927 DOI: 10.1097/SLA.0b013e3181bd582b]

75 **Buell JF**, Cherqui D, Geller DA, O'Rourke N, Iannitti D, Dagher I, Koffron AJ, Thomas M, Gayet B, Han HS, Wakabayashi G, Belli G, Kaneko H, Ker CG, Scatton O, Laurent A, Abdalla EK, Chaudhury P, Dutson E, Gamblin C, D'Angelica M, Nagorney D, Testa G, Labow D, Manas D, Poon RT, Nelson H, Martin R, Clary B, Pinson WC, Martinie J, Vauthey JN, Goldstein R, Roayaie S, Barlet D, Espat J, Abecassis M, Rees M, Fong Y, McMasters KM, Broelsch C, Busuttil R, Belghiti J, Strasberg S, Chari RS. The international position on laparoscopic liver surgery: The Louisville Statement, 2008. *Ann Surg* 2009; **250**: 825-830 [PMID: 19916210]

76 **Giannini EG**, Cucchetti A, Vitale A. Prognostic prediction and identification of candidates for salvage liver transplantation among patients with early hepatocellular carcinoma. *Liver Transpl* 2014; **20**: 1150-1151 [PMID: 24916303 DOI: 10.1002/lt.23927]

77 **Chan DL**, Alzahrani NA, Morris DL, Chua TC. Systematic review of efficacy and outcomes of salvage liver transplantation after primary hepatic resection for hepatocellular carcinoma. *J Gastroenterol Hepatol* 2014; **29**: 31-41 [PMID: 24117517 DOI: 10.1111/jgh.12399]

78 **Becker JM**, Dayton MT, Fazio VW, Beck DE, Stryker SJ, Wexner SD, Wolff BG, Roberts PL, Smith LE, Sweeney SA, Moore M. Prevention of postoperative abdominal adhesions by a sodium hyaluronate-based bioresorbable membrane: a prospective, randomized, double-blind multicenter study. *J Am Coll Surg* 1996; **183**: 297-306 [PMID: 8843257]

79 **Perkins JD**. Is there any benefit to laparoscopic liver resection for hepatocellular carcinoma if a salvage liver transplant is needed later? *Liver Transpl* 2009; **15**: 813-814 [PMID: 19582953]

80 **Laurent A**, Tayar C, Andréoletti M, Lauzet JY, Merle JC, Cherqui D. Laparoscopic liver resection facilitates salvage liver transplantation for hepatocellular carcinoma. *J Hepatobiliary Pancreat Surg* 2009; **16**: 310-314 [PMID: 19280110 DOI: 10.1007/s00534-009-0063-0]

81 **Qu W**, Zhu ZJ, Sun LY, Wei L, Liu Y, Zeng ZG. Salvage liver transplantation for hepatocellular carcinoma recurrence after primary liver resection. *Clin Res Hepatol Gastroenterol* 2014; Epub ahead of print [PMID: 25150375 DOI: 10.1016/j.clinre.2014.07.006]

P- Reviewer: Robles R **S- Editor**: Qi Y
L- Editor: A **E- Editor**: Liu SQ

World Journal of Hepatology

Submit a Manuscript: http://www.wjgnet.com/esps/
Help Desk: http://www.wjgnet.com/esps/helpdesk.aspx
DOI: 10.4254/wjh.v7.i1.101

World J Hepatol 2015 January 27; 7(1): 101-112
ISSN 1948-5182 (online)

REVIEW

Role of radiotherapy in the management of hepatocellular carcinoma: A systematic review

Maria-Aggeliki Kalogeridi, Anna Zygogianni, George Kyrgias, John Kouvaris, Sofia Chatziioannou, Nikolaos Kelekis, Vassilis Kouloulias

Maria-Aggeliki Kalogeridi, Anna Zygogianni, George Kyrgias, Radiotherapy Department, Larissa University Hospital, 41110 Larisa, Greece
Anna Zygogianni, John Kouvaris, 1st Radiology Department, Radiotherapy Unit, Aretaieion University Hospital, 11528 Athens, Greece
Sofia Chatziioannou, Nikolaos Kelekis, Vassilis Kouloulias, 2nd Radiology Department, Radiotherapy Unit, Attikon University Hospital, 12642 Athens, Greece
Author contributions: All authors contributed to this work.

Correspondence to: Dr. Vassilis Kouloulias, MS, MD, PhD, Assistant Professor Radiation Oncology, 2nd Radiology Department, Radiotherapy Unit, Attikon University Hospital, Rimini 1, 12642 Athens, Greece. vkouloul@ece.ntua.gr
Telephone: +30-21-05831880
Fax: +30-21-05326418
Received: July 6, 2014
Peer-review started: July 6, 2014
First decision: August 28, 2014
Revised: October 26, 2014
Accepted: November 17, 2014
Article in press: November 19, 2014
Published online: January 27, 2015

Abstract

Many patients with hepatocellular carcinoma (HCC) present with advanced disease, not amenable to curative therapies such as surgery, transplantation or radiofrequency ablation. Treatment options for this group of patients include transarterial chemoembolization (TACE) and radiation therapy. Especially TACE, delivering a highly concentrated dose of chemotherapy to tumor cells while minimizing systemic toxicity of chemotherapy, has given favorable results on local control and survival. Radiotherapy, as a therapeutic modality of internal radiation therapy with radioisotopes, has also achieved efficacious tumor control in advanced disease. On the contrary, the role of external beam radiotherapy for HCC has been limited in the past, due to the low tolerance of surrounding normal liver parenchyma. However, technological innovations in the field of radiotherapy treatment planning and delivery, have provided the means of delivering radical doses to the tumor, while sparing normal tissues. Advanced and highly conformal radiotherapy approaches such as stereotactic body radiotherapy and proton therapy, evaluated for efficacy and safety for HCC, report encouraging results. In this review, we present the role of radiotherapy in hepatocellular carcinoma patients not suitable for radical treatment.

Key words: Hepatocellular carcinoma; Radiotherapy; Radio-embolization; Hyperthermia; Review

Core tip: Treatment of hepatocellular carcinoma is challenging since it is usually associate with underlying liver morbidity. The role of radiotherapy has evolved. The combination settings with radioisotopes, transarterial chemoembolization, hyperthermia, stereotactic radiotherapy and charged particles, support the efficacy and safety of the radiation therapy.

Kalogeridi MA, Zygogianni A, Kyrgias G, Kouvaris J, Chatziioannou S, Kelekis N, Kouloulias V. Role of radiotherapy in the management of hepatocellular carcinoma: A systematic review.

World J Hepatol 2015; 7(1): 101-112 Available from: URL: http://www.wjgnet.com/1948-5182/full/v7/i1/101.htm DOI: http://dx.doi.org/10.4254/wjh.v7.i1.101

INTRODUCTION

Hepatocellular carcinoma (HCC) accounts for the vast majority (85%-90%) of primary liver cancers[1] with the latter representing approximately 4% of annual cancer diagnosis. Although HCC is the fifth most common cancer in men and the seventh in women, its poor prognosis makes it the third leading cause of cancer-related death worldwide[2,3]. Overall, there are 500-1000000 new cases per year, causing 600000 deaths globally per year[4]. It is characterized by a great geographic variability, with the highest rates in East and South-East Asia and Sub-Saharan Africa[5]. Environmental factors have a predominant role in the etiology of HCC. The majority of cases are related to exposure to hepatitis B and C viruses[6]. Other risk factors include alcohol, aflatoxins, diabetes and non-alcoholic fatty liver disease, as well as immune-related factors such as autoimmune hepatitis and primary biliary cirrhosis[7].

Treatment of HCC is quite challenging since it is usually associated with underlying liver disease. Available curative treatment options include surgical resection, transplantation and radiofrequency ablation[8-10]. These are suitable for carefully selected patients with early stages of disease who may have a 5-years survival of 70% after treatment[11]. However, only 1/3 of HCC patients are detected with a disease amenable to curative therapy. Partial hepatectomy is the treatment of choice for patients medically fit for a major operation who have a solitary tumor, adequate liver reserve and no evidence of gross vascular invasion[12,13]. Transplantation is considered for patients who meet the Milan criteria: a single tumor ≤ 5 cm or 2-3 tumors ≤ 3 cm each, no macrovascular involvement and no extrahepatic disease. However, from 2013, the United Network for Organ Sharing administered the Organ Procurement and Transplantation Network (OPTN) criteria by using radiologic staging (up to three OPTN class 5A or 5B HCCs, each 1 cm or larger and 3 cm or smaller in diameter, or one OPTN class 5B HCC measuring 2 cm or larger and 5 cm or smaller in diameter)[14]. Liver transplantation offers a chance to cure the tumor and the underlying cirrhosis[15,16]. Although transplantation is a cornerstone in the treatment of HCC, the relative shortage of donors highlights the need of other therapeutic approaches.

Radiofrequency ablation (RFA) can be used with a curative intend for patients with lesions up to 5 cm, if they are properly located at a safety distance from major vessels or major bile duct and away from diaphragm and other intraabdominal organs. Randomized controlled trials have already reported comparable survival rates of RFA to resection[17] for carefully selected patients. However, even if the recent meta analysis of Duan confirms that there is no significant difference in 1-year overall survival between resection and radiofrequency ablation, it also shows that the long-term efficacy of surgery is better than that of RFA[18]. Recently, artificial ascites technique has been used to prevent visceral damage when RFA is applied for subdiaphragmatic tumors or HCC adjacent to vital organs.

Results are less satisfactory for more advanced stages of the disease, not amenable to curative therapies. Available options are local therapies such as transarterial chemoembolization (TACE) and radiation therapy. The purpose of TACE is to increase the exposure of tumor cells to cytotoxic agents and to induce ischemic necrosis. This approach has given encouraging results on local control and survival for patients ineligible for curative therapy[19,20]. However, TACE is relatively contraindicated in patients with main portal vein thrombosis and Child-Pugh (CP) Class A, increasing the need for another effective local therapy. Internal radiation therapy with the use of radioisotopes has been tested and achieved efficacious treatment control and encouraging results on survival according to literature[21,22].

Finally, sorafenib is the only molecular agent approved for the treatment of patients with advanced hepatocellular carcinoma. Sorafenib is a multikinase inhibitor that targets vascular endothelial growth factor receptor, platelet-derived growth factor receptor and RFA. The use also of CTLA-4 showed good safety profile and antitumor activity, supporting further investigation[23]. Studies have shown an overall survival benefit with diarrhea, fatigue, hand-foot skin reaction and rash being the most common drug-related adverse events[24,25].

Traditionally, the role of external beam radiation therapy (EBRT) has been limited to the palliation of HCC metastases associated with distressing symptoms. There are numerous reports of bone[26,27], lymph node[28,29] and soft tissue[30] metastases that were successfully treated with external beam radiation therapy, as shown in Table 1. HCC has been considered a radioresistant tumor for a long time. The dose delivered by conventional external beam radiotherapy could not exceed 30 Gy on the whole liver as this is the threshold for radiation-induced liver disease. However, this dose level is far less than standard tumoradical doses for most solid tumors. Technological advances in the field of radiotherapy precision delivery and sparing of normal tissues have given the opportunity of dose escalation. Nowadays, radiotherapy is gaining ground in the treatment of advanced-stage HCC patients, irrespectively of tumor location, with promising results.

OPTIONS OF RADIOTHERAPY

Internal radiotherapy

Internal radiotherapy is the delivery of radioisotopes either percutaneously or through transarterial approach. Yttrium-90 (Y^{90}) is a pure beta emitter isotope that decays to stable 90 Zr with a physical half-life of 64.2 h. It has been applied to unresectable HCC by intratumoral

Table 1 Palliative radiotherapy for hepatocellular carcinoma metastatic sites

Ref.	Metastatic lesion treated	Patient (*n*)	Total dose, fraction size	Response	Median survival
Yamashita *et al*[122] (Retro)	LNs	28	46-60 Gy, 2Gy	PR: 64%; CR: 18%	13 mo
Zeng *et al*[29] (Retro)	LNs	62	40-60 Gy, 2 Gy	PR: 37.1%; CR: 59.7%	9.4 mo
He *et al*[121] (Retro)	Bone	30	8-60 (median 40) Gy	96.7% pain relief	8.6 mo
Seong *et al*[26] (Retro)	Bone	51	12.5-50 (median 30) Gy	73% pain relief	5 mo
Kaizu *et al*[123] (Retro)	Bone	57	20-65 (mean 43) Gy	83.8% pain relief	6 mo

PR: Partial response; CR: Complete response; Retro: Retrospective study; LNs: Lymphnodes.

injection of glass microspheres by percutaneous assess to the hepatic artery[31,32]. This approach, called radioembolization, is based on the different arteriolar density between the hypervascular HCC and the normal liver parenchyma. Arterial administrated Y^{90} microspheres depose selectively in tumor nodules and limit tumor dose to surrounding normal liver[33]. This technique can be used in downstaging large tumors to bring within transplantable criteria, in patients with portal vein thrombosis and in the palliative setting[34]. Overall, radioembolization of unresectable HCC with Y^{90} is associated with acceptable toxicity and favorable median survival time[35-38]. Radioembolization-induced liver disease, defined as jaundice and ascites appearing 4-8 wk after treatment, has been described in the literature[39]. It is more common in cirrhotic patients with an incidence of < 10%.

Holmium-199 (Ho^{199}), moslty beta and a little gamma emission with a half-life of 26.8 h, has also been tried in chitosan complex either intratumorally or *via* transarterial approach. Sohn *et al*[40] reported, in a phase Ⅱ study, a 78% response rate of intraarterial Ho^{199} for single HCC with an acceptable toxicity, especially for tumors 3-5 cm. Percutaneous holmium injection also showed promising results with complete tumor necrosis in 91.7% of tumors < 2 cm (phase Ⅱb clinical trial)[41].

Iodine-131 (I^{131}), mostly beta and a little gamma emission with a half-life of 8 d, has been applied in a form of I^{131}-Lipiodol[42]. Intraarterial administration yields responses in 17%-92% of patients[21]. Fifty patients with advanced HCC given intraarterial injection of I-Lipiodol were compared to 36 untreated patients[43]. The I^{131}-lipiodol was associated with a survival benefit (32 wk *vs* 8 wk for the untreated group) and 1 year survival rate was 32% *vs* 8% for the untreated group.

Overall, encouraging results on efficacy and safety of radioisotope therapy for HCC have been reported. This approach is reasonable for large, inoperable tumors and small, inoperable tumors not amenable to percutaneous therapy as well as for tumor downstaging before transplantation or surgery[44].

Three-dimensional conformal radiotherapy

Since there is no standard therapy for Radiation-induced liver disease (RILD), radiation therapy to liver lesions is an acceptable option as long as normal tissue complication probability does not exceed tumor control probability. Technological advances in the field of treatment planning and radiotherapy delivery have provided the means to deliver tumoradical doses to a well-defined liver lesion more precisely and safely, thus achieving an acceptable therapeutic ratio.

Irradiation technique of three-dimensional conformal radiotherapy (3DCRT) uses three dimensional imaging data sets (contrast enhanced computed tomography studies) for the accurate delineation of the HCC target volume and surrounding normal tissues, such as normal liver parenchyma, kindey and duodenum. Treatment plans are individualized and use multiple fields to precisely irradiate the tumor and spare normal tissues.

3DCRT has been tested as an alternative treatment option for cirrhotic HCC patients not eligible for curative therapies such as surgical resection, liver transplantation and radiofrequency ablation.

Early attempts to treat unresectable hepatocellular carcinomas with radiation therapy combined it with intraarterial hepatic radiation sensitizer, fluorodeoxyuridine, with encouraging results[45,46]. The study of Ben-Josef *et al*[47], confirmed the hypothesis that high dose conformal radiotherapy (median dose of 60.75 Gy, 1.5 Gy twice daily) combined with hepatic arterial floxuridine could improve the survival of patients with intrahepatic cancer ineligible for surgical resection or ablation[47]. Moreover, total radiation dose was the only significant factor for survival.

Later on, three studies (two phase II and one retrospective) assessed the efficacy of 3DCRT[48-51].

Data from Mornex *et al*[48] (phase Ⅱ study) confirmed the efficacy of radiation therapy (RT), delivering 66 Gy at 2 Gy/fr to selected cirrhotic patients with one nodule ≤ 5 cm or two nodules ≤ 3 cm. Tumor response was observed for 92% overall, with 80% for complete response[48]. CP-A patients tolerated treatment well while 22% of CP-B patients experienced gr 4 toxicity. After a mean follow-up of 29 ± 9 mo, recurrence rate was 22% and 41% for lesions inside and outside the irradiated volume, respectively.

Liu *et al*[51] studied 45 patients with CP-A and -B cirrhosis who had either failed with or were unsuitable for TACE[50]. The response rate after a median radiation dose of 50.4 Gy was 61.4%. Survival rates at 1, 2 and 3 years were 60.5%, 40.3% and 32%, respectively. American Joint Committee on Cancer stage, portal vein thrombosis, pretreatment alpha-fetoprotein (AFP) level and total RT dose had a significant impact on overall survival. On the contrary, age, gender, karnofsky performance status, CP class, tumor size or the number of tumors did not

significantly influence survival.

Overall, the worldwide availability of 3DCRT, the opportunity to treat multiple lesions in a single course along with its non-invasive feature, as well as the favorable results in the literature makes it an appealing therapeutic approach for patients ineligible for curative interventions.

3DCRT and TACE

TACE has an advantage on survival in comparison with supportive treatment[52] and is an effective measure for prolonging the survival in selected patients with limited cirrhosis and early stage tumors[53,54]. However, TACE alone cannot always achieve complete tumor necrosis (range 40%-100%). Viable tumors remain in and around the capsule increasing the possibility of recurrence[55,56]. TACE alone has a median response rate of 38%, while complete response and partial response are at the range of 0%-35% and 3%-62%, respectively[57]. Moreover, TACE is relatively contraindicated for patients with main portal vein thrombosis. To overcome the above mentioned limitations of TACE, the combination of TACE with EBRT has been tested. The rationale for this approach is that radiotherapy can either eradicate residual hepatic tumor after TACE or increase the effectiveness of TACE by eradicating portal vein thrombi.

Seong *et al*[58] investigated the combination of TACE with 3DCRT in unresectable HCC. Thirty patients received local RT with 44 ± 9.3 Gy in daily 1.8 Gy fractions, starting 7-10 d after TACE. The combination therapy had acceptable toxicity and achieved a response rate of 63.3%. One and 3-year survival rate were 67% and 22.2%, respectively.

Data from the series of Guo *et al*[59], that compared chemoembolization alone with the combination of TACE and radiotherapy, confirmed the superiority of the combined modality for the treatment of large hepatocellular carcinomas. The study included 76 patients with unresectable HCC treated with RT and TACE and 89 patients in the control group treated with TACE alone. The response rate was significantly higher in the first group (47.4% *vs* 28.1%, $P < 0.05$). The combined therapeutic approach was also significantly superior for overall survival (64.1% and 28.6% for 1 and 3-year survival *vs* 39.9% and 9.5%, respectively). Finally, the metaanalysis of Meng *et al*[60] with 1476 patients showed that TACE plus RT seems superior to TACE alone, optimizing survival and tumor control rates.

For patients with portal vein thrombosis the combination treatment has also given favorable results. Ishikura *et al*[61] reported a response rate of 50% for 20 patients receiving 50 Gy in 25 fractions after TACE for HCC with portal vein thrombosis[61]. A study from Japan confirmed the feasibility and efficacy of TACE combined with radiation therapy delivering 60 Gy in daily fractions of 2 Gy[62]. Survival rate at 1 and 2 years was 40.6% and 10.2%, respectively while an objective response was observed in 57.9% of patients.

Overall, the literature supports the feasibility and efficacy of this combined approach for HCC patients with or without portal vein thrombosis[63-67].

Stereotactic body radiotherapy

Advanced technologies, such as stereotactic body radiotherapy (SBRT), have raised a new interest in HCC radiotherapy. SBRT is a highly conformal technique of non-coplanar RT delivered in a small number of large fractions. It is characterized by a high dose delivery to the target volume and a rapid fall off outside the target, thus sparing surrounding normal tissues. The use of SBRT presupposes accurate patient immobilization and positioning, precise target localization and image-guided techniques to improve set up accuracy and delivery of the treatment. Moreover, when treating liver lesions, techniques that account for tumor motion with respiration and breathing control devices should be available. Patients with lesions near the bowels are not optimal candidates for SBRT since there is the risk of gastrointestinal perforation and bleeding. On the contrary, SBRT can be used to treat lesions not amenable to surgery or ablation such as those adjacent to the central biliary system[68].

It's a fact that the few patients eligible for transplantation have to face the long waiting list for donor organ availability. The role of SBRT in this field is of paramount importance. There are several reports proving SBRT as a bridge to transplantation to be a highly effective therapeutic approach with low toxicity profile[69-71].

O' Connor *et al*[71] studied 10 patients with 11 HCCs and a median tumor size of 3.4 cm that received SBRT (median dose 51 Gy in 3 fractions) as a bridge to transplantation. Complete response rate was 27%. The remaining tumors decreased in size or remained stable and no patient dropped off the wait list because of tumor progression. After a median follow up of more than 5 years, overall survival and disease free survival were both 100%. Although 40% of patients experienced acute toxicity that was mainly grade I nausea, vomiting, fatigue and abdominal discomfort. There was no grade 3-5 toxicity.

A Belgian study gives high 1- and 2-year control rates of 95%, delivering 45 Gy in 3 fractions[72].

According to the study by Jang *et al*[73], there is a dose response relationship for local control and overall survival with SBRT for HCC[73]. The study included 108 patients with HCC < 7 cm that were unsuitable for resection or local ablation and had incomplete response to TACE. After a 30 mo follow up, 2-year local control and overall survival were 87% and 663%, respectively. Overall, 54 Gy in 3 fractions is an acceptable dose to achieve local control for lesions < 7 cm. However, the optimal dose for a certain local control rate differs according to tumor size. A tumor ≤ 5.0 cm requires a 51.1 Gy dose for a 2-year local control probability of 90%, while a larger tumor requires 61.2 Gy for the same local control probability.

SBRT has been also used in combination with TACE.

Table 2 Stereotactic body radiation therapy studies related to hepatocellular carcinoma, published the last five years

Ref.	Study design	Patient (*n*)	Median tumor size	Dose, No. of fractions	Median follow up (range), in months	Local control
Cárdenes *et al*[77]	Prosp Phase Ⅰ	17	34 mL (8-95)	CP-A: 36-48 Gy/3 fr CP-B: 40 Gy/5 fr	24 (10-42)	100%
Louis *et al*[72]	Retro	25	48 mL (7-363)	45 Gy/3 fr	12.7 (1-24)	95% (1 yr)
Kwon *et al*[79]	Retro	42	15 mL (3-82)	30-39 Gy/3 fr	28.7 (8.4-49.1)	72% (1 yr) 67.5% (3 yr)
Seo *et al*[80]	Retro	38	40.5 mL (11-464)	33-57 Gy/3-4 fr	15 (3-27)	66% (2 yr)
Andolino *et al*[69]	Retro	60	29 mL (2-12) 3.2 cm (1-6.5)	CP-A: 44 Gy/3 fr CP-B: 40 Gy/5 fr	27 (2-52)	90 (2 yr)
Huang *et al*[81]	Retro	36	4.4 cm (1.1-12)	37 (25-48) Gy/4-5 fr	14 (2-35)	88% (1 yr) 75% (2 yr)
Bae *et al*[82]	Retro	35	131 mL (21-2189)	45 (30-60) Gy/3-5 fr	14 (1-44)	69% (91 yr) 51% (93 yr)
Bujold *et al*[78]	Prosp Phase Ⅰ/Ⅱ	102	117 mL (1-1913) 7.2 cm (1.4-23.1)	36 (24-54) Gy/6 fr	31 (2-36)	87% (1 yr)
Xi *et al*[90]	Retro	41	65 mL (± 48)	36 (30-48) Gy/6 fr	10 (4-25)	95%
Sanuki *et al*[127]	Retro	185	8 mL (1.5-65)	CP-A: 40 Gy/5 fr CP-B: 35 Gy/5 fr	24 (3-80)	91% (3 yr)

Prosp: Prospective; Retro: Retrospective; fr: Fraction; CP: Child-Pugh class of liver disease.

Kang, in a phase Ⅱ study, investigated the efficacy and safety of SBRT for inoperable HCC after incomplete TACE for tumors < 10 cm. In this study patients received 3 fractions to a total dose of 42-60 Gy after 1-5 TACE. Complete remission after 6 mo of SBRT was observed to 38.3% of patients and partial response was at the same rate. The overall 2-year local control rate was 94.6%[74]. These results are in line with other series from Korea and Japan reporting encouraging local control rates[75,76].

Overall, studies have indicated that stereotactic body radiation therapy is a safe and effective modality treatment for HCC[77-82], as shown in Table 2. It can be applied for lesions not eligible for surgery or percutaneous ablation such as those located at a central portal area or just below the diaphragm and those adjacent to a great vessels or the biliary system.

National Comprehensive Cancer Network guidelines version 2.2014 have incorporated external beam radiation therapy, either 3DCRT or SBRT, to the therapeutic algorithm for HCC. SBRT can be safely considered for patients with 1-3 lesions, with sufficient uninvolved liver parenchyma and CP-A liver disease.

Stereotactic body radiation therapy for HCC with portal vein tumor thrombosis

A special issue raising questions about the optimal treatment of HCC is the high incidence of portal vein tumor thrombosis (PVTT). Although at the time of diagnosis only 6.5% of patients have demonstrable portal vein thrombosis[83] in autopsy series the incidence is reported to be as high as 44%-62.8%[84,85]. PTVV is associated with intrahepatic tumor spread and liver function deterioration.

First attempts to treat this group of patients with 3DCRT gave encouraging results of overall response rate in the range of 44.7%-62.3%[86-88]. However, the role of radiotherapy for this group of patients has become more appealing with the development of advanced radiotherapy techniques that deliver higher doses to liver lesions while reducing normal tissue exposure.

Kim *et al*[89] evaluated the efficacy of Helical Tomotherapy for patients with HCC in combination with PVTT in whom other treatment modalities were not indicated. Treatment protocol combined radiotherapy (50 Gy in 10 fractions with helical Tomotherapy) with Capecitabine 600 mg/m^2, given twice daily during radiotherapy. Computed tomography was used for response evaluation of 35 patients with thrombi either in the main trunk of portal vein (51.8%) or in the first or second order branches. Complete and partial response was reported on 14.3% and 28.6% of patients, respectively, while a 5.7% of patients had disease progression. Response was significantly different between CP class A and B (P = 0.01) and Japan integrated staging score (P = 0.026). Although tumor thrombi in the main trunk were significantly associated with inferior survival, results were favorable for those achieving complete response (13.9 mo).

Xi *et al*[90] reported on the results of a study treating patients with HCC and portal vein or inferior vena cava thrombosis with SBRT. Response rate was 36.6% and 39.0% for complete and partial response, respectively. Moreover, 76.7% of patients with elevated AFP levels before radiotherapy exhibited > 50% reduction of AFP levels within 3 mo after treatment. SBRT was proved effective and safe giving a median survival of 13 mo while maintaining a low toxicity profile, with grade 1 vomiting and nausea being the most common event.

Charged particle radiotherapy

More sophisticated techniques such as proton or carbon ion radiotherapy enable further dose escalation and precise dose delivery while maintaining a favorable toxicity profile. There are encouraging results from Tsukuba University's study treating patients unsuitable

for other treatment options with proton radiotherapy[91]. After a median follow-up of 318 patients for 19.3 mo, overall survival was 89.5% at 1 year and 44.6% at 2 years. Hepatic function, T classification, planning target volume and European Organization for Research and Treatment of Cancer performance status, were significant prognostic factors. Treatment related toxicity was minimal. There was no treatment discontinuation due to liver toxicity or treatment-related death.

The efficacy and safety of proton beam radiotherapy for peripherally located HCC, at least 2 cm away from the porta hepatis or gastrointestinal tract, was prospectively evaluated by Fukumitsu *et al*[92]. Fifty one patients received 66 Gy equivalents in 10 fractions. At 3 and 5 years OS was 49.2% and 38.7, respectively. None of the patients had tumor progression, while 29 had complete response and 10 a partial response. Despite a high local control rate of 94.5% at 3 years, 65% patients had a recurrence outside the irradiated field. Acute toxicity was minimal and no treatment-related liver failure was observed.

Proton and carbon ion therapy were comparable in terms of local control and survival in the series of Komatsu *et al*[93]. The study included 343 patients with tumors < than 15 cm. Two hundred and ten patients developed local recurrences in 3 years giving a 5-year local control rate of 90.2% for those receiving proton RT and 93% for those receiving carbon ion therapy. According to multivariate analysis, tumor size was an independent risk factor for local recurrence. For the whole series, 3-year OS was 59%.

Despite the favorable results of several studies of particle beam radiotherapy for HCC[94-97] we should keep in mind that proton and carbon ion radiotherapy is a quite expensive technique available in few facilities worldwide. Additionally, there is still room for photon radiotherapy (3DCRT, SBRT) for HCC patients. Dawson[98] suggests that photon RT is suitable for patients with CP. A liver function, and tumors that can be irradiated with sparing of the liver (tumors < 6 cm or at the dome of the diaphragm). Proton RT is advantageous mainly for patients with CP-B class liver function and tumor characteristics associated with higher liver doses after photon therapy (centrally located tumors > 8 cm). A dosimetric comparison of spot-scanning proton therapy *vs* intensity modulated radiation therapy suggests proton radiotherapy for HCC with nominal diameter > 6.3 cm with regard to radiation-induced liver toxicity[99].

Finally, neither photon or proton therapy is considered a suitable option for patients with CP-C liver function or diffuse, multifocal HCC.

3DCRT and hyperthermia

The full scope of the capabilities of radiation therapy is achieved particularly in combination settings with various anti-tumor modalities, the so-called multidisciplinary approach. To enhance the therapeutic efficacy of radiation sufficiently, one may choose radiation therapy in combination with hyperthermia treatment. Many studies concluded that local hyperthermia induced both direct and abscopal anti-tumor effects that might probably be the result of a systemic effect of hyperthermia in the host animal[100-102].

Lin *et al*[100] used nanosized Mn-Zn magnetic-fluid hyperthermia in combination with radiation therapy. The results, *in vivo* and *in vitro*, showed that the combination of magnetic fluid hyperthermia with Mn-Zn ferrite has better therapeutic effect than either of them alone. Zhang *et al*[101] used on extracorporeal HepG2 cells different temperatures, pressures of permeability and lengths of treatment time and they observed the killing effect on cell index. They concluded that the 46 ℃-distilled water-60 min achive to ideal killing effect on free cancer cells[101]. Linchun *et al*[102] showed that the toxicity after the combination of radiation therapy with hyperthermia was upper abdominal fullness, anorexia, nausea, vomiting, abdominal pain, marrow suppression. The combination is safe and effective in the treatment of hepatocellular carcinoma[102].

The logical inference from these researchs is that the abscopal effect is a desirable and common systemic reaction to localized cancer treatment. These data will encourage future therapeutic gain of hyperthermia in the treatment of hepatocellular carcinoma. The development of safer and reasonable therapies will be facilitated as we clarify the mechanisms for the abscopal effects. Future therapies will need to be optimized with tumor-type tailoring in consideration of various intra- or inter-tissue signals if these are to affect treatment outcome.

RADIATION INDUCED LIVER TOXICITY

Radiation delivery to liver lesions is limited by the tolerance of surrounding normal liver parenchyma. Hepatic radiation toxicity has for long been in the center of interest[103,104]. RILD has been defined as a clinical syndrome of anicteric hepatomegaly, ascites and elevated liver enzymes (particularly serum alkaline phosphatase) occurring from 2 wk to 4 mo after radiotherapy[105]. The underlying cause is a venoocclusive disease in the central portion of each lobe. Fibrous occlusion of central veins is the result of replacement by collagen of fibrin accumulated to endothelial cells of central veins after irradiation[106]. Dawson *et al*[105] have demonstrated a large volume effect for RILD. The mean liver dose is associated with the development of RILD with a threshold of 30 Gy with conventional fractionation. A mean liver dose of 31 Gy is associated with a 5% probability of RILD. This probability rises up to 50% for a mean dose of 43 Gy. These results are in line with the earlier work of Emami that defined the tolerance of normal tissue to therapeutic irradiation with an emphasis on partial volume effects[107].

Liver is a characteristic example of a radiobiologically parallel architecture model, with liver acini as functional subunits. The risk of developing a complication depends on dose distribution throughout the whole organ rather than the maximum dose to a small area. A complication

occurs if the fraction of liver damaged by RT exceeds the patients' functional reserve[108]. A high dose of RT can be delivered to a subvolume as long as the mean dose to normal parenchyma does not compromise its function. A dose as high as 100 Gy can safely be delivered to a small volume of normal liver (approximately 1/3 of whole liver) with a minimum or no risk of toxicity[105]. The Michigan group's study has shown that the tolerance of the liver is reduced in patients with primary liver cancer *vs* metastases. The mean liver dose associated with a 5% risk of RILD is 28 Gy at 2 Gy per fraction for primary liver cancer *vs* 32 Gy at conventional fractionation for metastatic live cancer[109].

In severe clinical cases, the RILD can lead to liver failure and death. Although many pharmacologic therapies have been tested in the past[103,110-112] there is still no standard therapy available for radiation-induced liver toxicity. Recently, new agents and strategies such as monoclonal antibodies against transforming growth factor-β[113] and transplantation of bone marrow-derived stem cells, adult hepatocytes or liver progenitor cells[114-116] have been tested in the treatment of liver disease. Their possible role in the setting of radiation-induced liver disease is still under investigation.

PALLIATIVE RADIOTHERAPY

For a long time, in terms of palliative setting, radiotherapy has been used for the treatment of distressing symptoms from HCC metastases. The lung, abdominal lymph nodes and the bones are the most common sites of extrahepatic metastatic HCC[117,118]. Unusual metastatic sites, such as central nervous system, have also been reported in the literature[119,120].

HCC lymph node metastases are sensitive to EBRT within a dose range of 8-60 Gy[121]. Sixty four per cent of patients subjected to RT with a dose 46-60 Gy achieved partial response and 18% a complete response[122]. In the series of Zeng *et al*[29], 50 Gy/25 fr was proven an effective palliative treatment for lymph node metastases, although survival decreases as the distance of lymph involvement from the liver increases, following the natural flow of lymph. The incidence of death resulting from lymph node-related complications was lower in the EBRT group in comparison to patients not receiving RT[29]. High rates (73% and 84%) of pain relief associated with HCC bone metastases have been reported in two series from South Korea and Japan, respectively[26,123].

Brain metastases are associated with extremely poor prognosis and median survival is 1-3 mo[120,124,125]. Increased survival is reported in patients that received aggressive treatment combing surgery and/or radiotherapy[120,124,125]. In the series of Han *et al*[126], patients treated with whole brain radiotherapy and/or gamma knife radiosurgery had a median survival time of 16 wk. Since brain metastases from HCC tend to bleed and rebleed after treatment, complete surgical resection should be attempted. However, decision for aggressive combination treatment is appropriate only for selected patients mainly without extra cranial tumor burden or viable liver disease.

Radiotherapy used with palliative intends is an effective and well tolerated treatment for common HCC metastases causing distressing symptoms.

CONCLUSION

The role of radiation therapy for hepatocellular carcinoma has evolved over the years. The technological advances that provided the means to deliver a tumoradical dose to liver lesions while sparing the surrounding normal parenchyma have given new insight to the treatment options for HCC. The literature supports the efficacy and safety of radiation therapy for HCC that has been for long considering a radioresistant tumor. Radiation therapies alone or in combination with other local therapies such as radiochemoembolization give encouraging results on local control and survival. We have successfully moved from the palliative role of radiotherapy for HCC to a new era of radiotherapy given as an effective treatment for patients not suitable for other therapeutic approaches.

ACKNOWLEDGMENTS

We wish to thank Dr. Alfred Banitz for his review in the language as a native speaking colleague.

REFERENCES

1 **El-Serag HB**, Rudolph KL. Hepatocellular carcinoma: epidemiology and molecular carcinogenesis. *Gastroenterology* 2007; **132**: 2557-2576 [PMID: 17570226 DOI: 10.1053/j.gastro.2007.04.061]

2 **Ferlay J**, Shin HR, Bray F, Forman D, Mathers C, Parkin DM. Estimates of worldwide burden of cancer in 2008: GLOBOCAN 2008. *Int J Cancer* 2010; **127**: 2893-2917 [PMID: 21351269]

3 **Parkin DM**, Bray F, Ferlay J, Pisani P. Global cancer statistics, 2002. *CA Cancer J Clin* 2005; **55**: 74-108 [PMID: 15761078]

4 **Gomaa AI**, Khan SA, Toledano MB, Waked I, Taylor-Robinson SD. Hepatocellular carcinoma: epidemiology, risk factors and pathogenesis. *World J Gastroenterol* 2008; **14**: 4300-4308 [PMID: 18666317]

5 **Jemal A**, Bray F, Center MM, Ferlay J, Ward E, Forman D. Global cancer statistics. *CA Cancer J Clin* 2011; **61**: 69-90 [PMID: 21296855 DOI: 10.3322/caac.20107]

6 **Bosch FX**, Ribes J, Cléries R, Díaz M. Epidemiology of hepatocellular carcinoma. *Clin Liver Dis* 2005; **9**: 191-211, v [PMID: 15831268 DOI: 10.1016/j.cld.2004.12.009]

7 **Parikh S**, Hyman D. Hepatocellular cancer: a guide for the internist. *Am J Med* 2007; **120**: 194-202 [PMID: 17349437 DOI: 10.1016/j.amjmed.2006.11.020]

8 **Nagasue N**, Kohno H, Chang YC, Taniura H, Yamanoi A, Uchida M, Kimoto T, Takemoto Y, Nakamura T, Yukaya H. Liver resection for hepatocellular carcinoma. Results of 229 consecutive patients during 11 years. *Ann Surg* 1993; **217**: 375-384 [PMID: 8385442]

9 **Hanish SI**, Knechtle SJ. Liver transplantation for the treatment of hepatocellular carcinoma. *Oncology* (Williston Park) 2011; **25**: 752-757 [PMID: 21874838]

10 **Nishikawa H**, Kimura T, Kita R, Osaki Y. Radiofrequency ablation for hepatocellular carcinoma. *Int J Hyperthermia*

2013; **29**: 558-568 [PMID: 23937321 DOI: 10.3109/02656736.2013.821528]
11 **Tremosini S**, Reig M, de Lope CR, Forner A, Bruix J. Treatment of early hepatocellular carcinoma: Towards personalized therapy. *Dig Liver Dis* 2010; **42** Suppl 3: S242-S248 [PMID: 20547310 DOI: 10.1016/S1590-8658(10)60512-9]
12 **Bruix J**, Sherman M. Management of hepatocellular carcinoma. *Hepatology* 2005; **42**: 1208-1236 [PMID: 16250051]
13 **Song TJ**, Ip EW, Fong Y. Hepatocellular carcinoma: current surgical management. *Gastroenterology* 2004; **127**: S248-S260 [PMID: 15508091 DOI: 10.1053/j.gastro.2004.09.039]
14 **Wald C**, Russo MW, Heimbach JK, Hussain HK, Pomfret EA, Bruix J. New OPTN/UNOS policy for liver transplant allocation: standardization of liver imaging, diagnosis, classification, and reporting of hepatocellular carcinoma. *Radiology* 2013; **266**: 376-382 [PMID: 23362092 DOI: 10.1148/radiol.12121698]
15 **Ishizaki Y**, Kawasaki S. The evolution of liver transplantation for hepatocellular carcinoma (past, present, and future). *J Gastroenterol* 2008; **43**: 18-26 [PMID: 18297431 DOI: 10.1007/s00535-007-2141-x]
16 **Mazzaferro V**, Chun YS, Poon RT, Schwartz ME, Yao FY, Marsh JW, Bhoori S, Lee SG. Liver transplantation for hepatocellular carcinoma. *Ann Surg Oncol* 2008; **15**: 1001-1007 [PMID: 18236119 DOI: 10.1245/s10434-007-9559-5]
17 **Chen MS**, Li JQ, Zheng Y, Guo RP, Liang HH, Zhang YQ, Lin XJ, Lau WY. A prospective randomized trial comparing percutaneous local ablative therapy and partial hepatectomy for small hepatocellular carcinoma. *Ann Surg* 2006; **243**: 321-328 [PMID: 16495695 DOI: 10.1097/01.sla.0000201480.65519.b8]
18 **Duan C**, Liu M, Zhang Z, Ma K, Bie P. Radiofrequency ablation versus hepatic resection for the treatment of early-stage hepatocellular carcinoma meeting Milan criteria: a systematic review and meta-analysis. *World J Surg Oncol* 2013; **11**: 190 [PMID: 23941614 DOI: 10.1186/1477-7819-11-190]
19 **Shin SW**. The current practice of transarterial chemoembolization for the treatment of hepatocellular carcinoma. *Korean J Radiol* 2009; **10**: 425-434 [PMID: 19721826 DOI: 10.3348/kjr.2009.10.5.425]
20 **Miraglia R**, Pietrosi G, Maruzzelli L, Petridis I, Caruso S, Marrone G, Mamone G, Vizzini G, Luca A, Gridelli B. Efficacy of transcatheter embolization/chemoembolization (TAE/TACE) for the treatment of single hepatocellular carcinoma. *World J Gastroenterol* 2007; **13**: 2952-2955 [PMID: 17589945]
21 **Lambert B**, Van de Wiele C. Treatment of hepatocellular carcinoma by means of radiopharmaceuticals. *Eur J Nucl Med Mol Imaging* 2005; **32**: 980-989 [PMID: 16032439]
22 **Keng GH**, Sundram FX. Radionuclide therapy of hepatocellular carcinoma. *Ann Acad Med Singapore* 2003; **32**: 518-524 [PMID: 12968558]
23 **Sangro B**, Gomez-Martin C, de la Mata M, Iñarrairaegui M, Garralda E, Barrera P, Riezu-Boj JI, Larrea E, Alfaro C, Sarobe P, Lasarte JJ, Pérez-Gracia JL, Melero I, Prieto J. A clinical trial of CTLA-4 blockade with tremelimumab in patients with hepatocellular carcinoma and chronic hepatitis C. *J Hepatol* 2013; **59**: 81-88 [PMID: 23466307 DOI: 10.1016/j.jhep.2013.02.022]
24 **Llovet JM**, Ricci S, Mazzaferro V, Hilgard P, Gane E, Blanc JF, de Oliveira AC, Santoro A, Raoul JL, Forner A, Schwartz M, Porta C, Zeuzem S, Bolondi L, Greten TF, Galle PR, Seitz JF, Borbath I, Häussinger D, Giannaris T, Shan M, Moscovici M, Voliotis D, Bruix J. Sorafenib in advanced hepatocellular carcinoma. *N Engl J Med* 2008; **359**: 378-390 [PMID: 18650514 DOI: 10.1056/NEJMoa0708857]
25 **Cheng AL**, Guan Z, Chen Z, Tsao CJ, Qin S, Kim JS, Yang TS, Tak WY, Pan H, Yu S, Xu J, Fang F, Zou J, Lentini G, Voliotis D, Kang YK. Efficacy and safety of sorafenib in patients with advanced hepatocellular carcinoma according to baseline status: subset analyses of the phase III Sorafenib Asia-Pacific trial. *Eur J Cancer* 2012; **48**: 1452-1465 [PMID: 22240282 DOI: 10.1016/j.ejca.2011.12.006]
26 **Seong J**, Koom WS, Park HC. Radiotherapy for painful bone metastases from hepatocellular carcinoma. *Liver Int* 2005; **25**: 261-265 [PMID: 15780048]
27 **He J**, Zeng ZC, Tang ZY, Fan J, Zhou J, Zeng MS, Wang JH, Sun J, Chen B, Yang P, Pan BS. Clinical features and prognostic factors in patients with bone metastases from hepatocellular carcinoma receiving external beam radiotherapy. *Cancer* 2009; **115**: 2710-2720 [PMID: 19382203 DOI: 10.1002/cncr.24300]
28 **Chen YX**, Zeng ZC, Fan J, Tang ZY, Zhou J, Zeng MS, Zhang JY, Sun J. Defining prognostic factors of survival after external beam radiotherapy treatment of hepatocellular carcinoma with lymph node metastases. *Clin Transl Oncol* 2013; **15**: 732-740 [PMID: 23381897 DOI: 10.1007/s12094-012-0997-6]
29 **Zeng ZC**, Tang ZY, Fan J, Qin LX, Ye SL, Zhou J, Sun HC, Wang BL, Wang JH. Consideration of role of radiotherapy for lymph node metastases in patients with HCC: retrospective analysis for prognostic factors from 125 patients. *Int J Radiat Oncol Biol Phys* 2005; **63**: 1067-1076 [PMID: 15913915 DOI: 10.1016/j.ijrobp.2005.03.058]
30 **Zeng ZC**, Tang ZY, Fan J, Zhou J, Qin LX, Ye SL, Sun HC, Wang BL, Zhang JY, Yu Y, Cheng JM, Wang XL, Guo W. Radiation therapy for adrenal gland metastases from hepatocellular carcinoma. *Jpn J Clin Oncol* 2005; **35**: 61-67 [PMID: 15709088]
31 **Geschwind JF**, Salem R, Carr BI, Soulen MC, Thurston KG, Goin KA, Van Buskirk M, Roberts CA, Goin JE. Yttrium-90 microspheres for the treatment of hepatocellular carcinoma. *Gastroenterology* 2004; **127**: S194-S205 [PMID: 15508085]
32 **Dancey JE**, Shepherd FA, Paul K, Sniderman KW, Houle S, Gabrys J, Hendler AL, Goin JE. Treatment of nonresectable hepatocellular carcinoma with intrahepatic 90Y-microspheres. *J Nucl Med* 2000; **41**: 1673-1681 [PMID: 11037997]
33 **Salem R**, Hunter RD. Yttrium-90 microspheres for the treatment of hepatocellular carcinoma: a review. *Int J Radiat Oncol Biol Phys* 2006; **66**: S83-S88 [PMID: 16979447 DOI: 10.1016/j.ijrobp.2006.02.061]
34 **Memon K**, Lewandowski RJ, Riaz A, Salem R. Yttrium 90 microspheres for the treatment of hepatocellular carcinoma. *Recent Results Cancer Res* 2013; **190**: 207-224 [PMID: 22941023 DOI: 10.1007/978-3-642-16037-0_14]
35 **Salem R**, Lewandowski R, Roberts C, Goin J, Thurston K, Abouljoud M, Courtney A. Use of Yttrium-90 glass microspheres (TheraSphere) for the treatment of unresectable hepatocellular carcinoma in patients with portal vein thrombosis. *J Vasc Interv Radiol* 2004; **15**: 335-345 [PMID: 15064336 DOI: 10.1097/01.RVI.0000123319.20705.92]
36 **Kulik LM**, Carr BI, Mulcahy MF, Lewandowski RJ, Atassi B, Ryu RK, Sato KT, Benson A, Nemcek AA, Gates VL, Abecassis M, Omary RA, Salem R. Safety and efficacy of 90Y radiotherapy for hepatocellular carcinoma with and without portal vein thrombosis. *Hepatology* 2008; **47**: 71-81 [PMID: 18027884 DOI: 10.1002/hep.21980]
37 **Iñarrairaegui M**, Thurston KG, Bilbao JI, D'Avola D, Rodriguez M, Arbizu J, Martinez-Cuesta A, Sangro B. Radioembolization with use of yttrium-90 resin microspheres in patients with hepatocellular carcinoma and portal vein thrombosis. *J Vasc Interv Radiol* 2010; **21**: 1205-1212 [PMID: 20598574 DOI: 10.1016/j.jvir.2010.04.012]
38 **Ibrahim SM**, Kulik L, Baker T, Ryu RK, Mulcahy MF, Abecassis M, Salem R, Lewandowski RJ. Treating and downstaging hepatocellular carcinoma in the caudate lobe with yttrium-90 radioembolization. *Cardiovasc Intervent Radiol* 2012; **35**: 1094-1101 [PMID: 22069121 DOI: 10.1007/s00270-011-0292-x]
39 **Gil-Alzugaray B**, Chopitea A, Iñarrairaegui M, Bilbao JI,

Rodriguez-Fraile M, Rodriguez J, Benito A, Dominguez I, D' Avola D, Herrero JI, Quiroga J, Prieto J, Sangro B. Prognostic factors and prevention of radioembolization-induced liver disease. *Hepatology* 2013; **57**: 1078-1087 [PMID: 23225191 DOI: 10.1002/hep.26191]

40 **Sohn JH**, Choi HJ, Lee JT, Lee JD, Kim JH, Moon YM, Park K, Park KB, Kim E, Yoo NC. Phase II study of transarterial holmium-166-chitosan complex treatment in patients with a single, large hepatocellular carcinoma. *Oncology* 2009; **76**: 1-9 [PMID: 19018149 DOI: 10.1159/000173735]

41 **Kim JK**, Han KH, Lee JT, Paik YH, Ahn SH, Lee JD, Lee KS, Chon CY, Moon YM. Long-term clinical outcome of phase IIb clinical trial of percutaneous injection with holmium-166/chitosan complex (Milican) for the treatment of small hepatocellular carcinoma. *Clin Cancer Res* 2006; **12**: 543-548 [PMID: 16428498 DOI: 10.1158/1078-0432.CCR-05-1730]

42 **Boucher E**, Garin E, Guylligomarc'h A, Olivié D, Boudjema K, Raoul JL. Intra-arterial injection of iodine-131-labeled lipiodol for treatment of hepatocellular carcinoma. *Radiother Oncol* 2007; **82**: 76-82 [PMID: 17141900 DOI: 10.1016/j.radonc.2006.11.001]

43 **Lintia-Gaultier A**, Perret C, Ansquer C, Eugène T, Kraeber-Bodéré F, Frampas E. Intra-arterial injection of 131I-labeled Lipiodol for advanced hepatocellular carcinoma: a 7 years' experience. *Nucl Med Commun* 2013; **34**: 674-681 [PMID: 23587835 DOI: 10.1097/MNM.0b013e32836141a0]

44 **Bal CS**, Kumar A. Radionuclide therapy for hepatocellular carcinoma: indication, cost and efficacy. *Trop Gastroenterol* 2008; **29**: 62-70 [PMID: 18972764]

45 **Lawrence TS**, Kessler ML, Robertson JM. Conformal high-dose radiation plus intraarterial floxuridine for hepatic cancer. *Oncology* (Williston Park) 1993; **7**: 51-57; discussion 57-58, 63 [PMID: 8251308]

46 **Robertson JM**, Lawrence TS, Andrews JC, Walker S, Kessler ML, Ensminger WD. Long-term results of hepatic artery fluorodeoxyuridine and conformal radiation therapy for primary hepatobiliary cancers. *Int J Radiat Oncol Biol Phys* 1997; **37**: 325-330 [PMID: 9069303 DOI: 10.1016/S0360-3016(96)00528-7]

47 **Ben-Josef E**, Normolle D, Ensminger WD, Walker S, Tatro D, Ten Haken RK, Knol J, Dawson LA, Pan C, Lawrence TS. Phase II trial of high-dose conformal radiation therapy with concurrent hepatic artery floxuridine for unresectable intrahepatic malignancies. *J Clin Oncol* 2005; **23**: 8739-8747 [PMID: 16314634 DOI: 10.1200/JCO.2005.01.5354]

48 **Mornex F**, Girard N, Beziat C, Kubas A, Khodri M, Trepo C, Merle P. Feasibility and efficacy of high-dose three-dimensional-conformal radiotherapy in cirrhotic patients with small-size hepatocellular carcinoma non-eligible for curative therapies--mature results of the French Phase II RTF-1 trial. *Int J Radiat Oncol Biol Phys* 2006; **66**: 1152-1158 [PMID: 17145534 DOI: 10.1016/j.ijrobp.2006.06.015]

49 **Park W**, Lim DH, Paik SW, Koh KC, Choi MS, Park CK, Yoo BC, Lee JE, Kang MK, Park YJ, Nam HR, Ahn YC, Huh SJ. Local radiotherapy for patients with unresectable hepatocellular carcinoma. *Int J Radiat Oncol Biol Phys* 2005; **61**: 1143-1150 [PMID: 15752895 DOI: 10.1016/j.ijrobp.2004.08.028]

50 **Kouloulias V**, Mosa E, Georgakopoulos J, Platoni K, Brountzos I, Zygogianni A, Antypas C, Kosmidis P, Mystakidou K, Tolia M, Beli I, Gouliamos A, Kouvaris J, Kelekis N. Three-dimensional conformal radiotherapy for hepatocellular carcinoma in patients unfit for resection, ablation, or chemotherapy: a retrospective study. *ScientificWorldJournal* 2013; **2013**: 780141 [PMID: 24379750 DOI: 10.1155/2013/780141]

51 **Liu MT**, Li SH, Chu TC, Hsieh CY, Wang AY, Chang TH, Pi CP, Huang CC, Lin JP. Three-dimensional conformal radiation therapy for unresectable hepatocellular carcinoma patients who had failed with or were unsuited for trans-catheter arterial chemoembolization. *Jpn J Clin Oncol* 2004; **34**: 532-539 [PMID: 15466827 DOI: 10.1093/jjco/hyh089]

52 **Huang YH**, Chen CH, Chang TT, Chen SC, Wang SY, Lee PC, Lee HS, Lin PW, Huang GT, Sheu JC, Tsai HM, Chau GY, Chiang JH, Lui WY, Lee SD, Wu JC. The role of transcatheter arterial embolization in patients with resectable hepatocellular carcinoma: a nation-wide, multicenter study. *Liver Int* 2004; **24**: 419-424 [PMID: 15482337 DOI: 10.1111/j.1478-3231.2004.0941.x]

53 **Ikeda K**, Kumada H, Saitoh S, Arase Y, Chayama K. Effect of repeated transcatheter arterial embolization on the survival time in patients with hepatocellular carcinoma. An analysis by the Cox proportional hazard model. *Cancer* 1991; **68**: 2150-2154 [PMID: 1655202 DOI: 10.1002/1097-0142(19911115)68:10<2150::AID-CNCR2820681011>3.0.CO;2-F]

54 **Taniguchi K**, Nakata K, Kato Y, Sato Y, Hamasaki K, Tsuruta S, Nagataki S. Treatment of hepatocellular carcinoma with transcatheter arterial embolization. Analysis of prognostic factors. *Cancer* 1994; **73**: 1341-1345 [PMID: 8111699]

55 **Sasaki Y**, Imaoka S, Kasugai H, Fujita M, Kawamoto S, Ishiguro S, Kojima J, Ishikawa O, Ohigashi H, Furukawa H. A new approach to chemoembolization therapy for hepatoma using ethiodized oil, cisplatin, and gelatin sponge. *Cancer* 1987; **60**: 1194-1203 [PMID: 2441837]

56 **Yu YQ**, Xu DB, Zhou XD, Lu JZ, Tang ZY, Mack P. Experience with liver resection after hepatic arterial chemoembolization for hepatocellular carcinoma. *Cancer* 1993; **71**: 62-65 [PMID: 8380123 DOI: 10.1002/1097-0142(19930101)71:1<62::AID-CNCR2820710111>3.0.CO;2-8]

57 **Marelli L**, Stigliano R, Triantos C, Senzolo M, Cholongitas E, Davies N, Tibballs J, Meyer T, Patch DW, Burroughs AK. Transarterial therapy for hepatocellular carcinoma: which technique is more effective? A systematic review of cohort and randomized studies. *Cardiovasc Intervent Radiol* 2007; **30**: 6-25 [PMID: 17103105 DOI: 10.1007/s00270-006-0062-3]

58 **Seong J**, Keum KC, Han KH, Lee DY, Lee JT, Chon CY, Moon YM, Suh CO, Kim GE. Combined transcatheter arterial chemoembolization and local radiotherapy of unresectable hepatocellular carcinoma. *Int J Radiat Oncol Biol Phys* 1999; **43**: 393-397 [PMID: 10030267 DOI: 10.1016/S0360-3016(98)00415-5]

59 **Guo WJ**, Yu EX, Liu LM, Li J, Chen Z, Lin JH, Meng ZQ, Feng Y. Comparison between chemoembolization combined with radiotherapy and chemoembolization alone for large hepatocellular carcinoma. *World J Gastroenterol* 2003; **9**: 1697-1701 [PMID: 12918103]

60 **Meng MB**, Cui YL, Lu Y, She B, Chen Y, Guan YS, Zhang RM. Transcatheter arterial chemoembolization in combination with radiotherapy for unresectable hepatocellular carcinoma: a systematic review and meta-analysis. *Radiother Oncol* 2009; **92**: 184-194 [PMID: 19042048 DOI: 10.1016/j.radonc.2008.11.002]

61 **Ishikura S**, Ogino T, Furuse J, Satake M, Baba S, Kawashima M, Nihei K, Ito Y, Maru Y, Ikeda H. Radiotherapy after transcatheter arterial chemoembolization for patients with hepatocellular carcinoma and portal vein tumor thrombus. *Am J Clin Oncol* 2002; **25**: 189-193 [PMID: 11943901 DOI: 10.1097/00000421-200204000-00019]

62 **Yamada K**, Izaki K, Sugimoto K, Mayahara H, Morita Y, Yoden E, Matsumoto S, Soejima T, Sugimura K. Prospective trial of combined transcatheter arterial chemoembolization and three-dimensional conformal radiotherapy for portal vein tumor thrombus in patients with unresectable hepatocellular carcinoma. *Int J Radiat Oncol Biol Phys* 2003; **57**: 113-119 [PMID: 12909223 DOI: 10.1016/S0360-3016(03)00434-6]

63 **Li B**, Yu J, Wang L, Li C, Zhou T, Zhai L, Xing L. Study of local three-dimensional conformal radiotherapy combined with transcatheter arterial chemoembolization for patients with stage III hepatocellular carcinoma. *Am J Clin Oncol* 2003; **26**: e92-e99 [PMID: 12902905 DOI: 10.1097/01.COC.0000077936.97997.AB]

64 **Cheng JC**, Chuang VP, Cheng SH, Huang AT, Lin YM, Cheng TI, Yang PS, You DL, Jian JJ, Tsai SY, Sung JL, Horng CF. Local radiotherapy with or without transcatheter arterial chemoembolization for patients with unresectable hepatocellular carcinoma. *Int J Radiat Oncol Biol Phys* 2000; **47**: 435-442 [PMID: 10802371 DOI: 10.1016/S0360-3016(00)00462-4]

65 **Yoon SM**, Lim YS, Won HJ, Kim JH, Kim KM, Lee HC, Chung YH, Lee YS, Lee SG, Park JH, Suh DJ. Radiotherapy plus transarterial chemoembolization for hepatocellular carcinoma invading the portal vein: long-term patient outcomes. *Int J Radiat Oncol Biol Phys* 2012; **82**: 2004-2011 [PMID: 21621346 DOI: 10.1016/j.ijrobp.2011.03.019]

66 **Xu LT**, Zhou ZH, Lin JH, Chen Z, Wang K, Wang P, Zhu XY, Shen YH, Meng ZQ, Liu LM. Clinical study of transarterial chemoembolization combined with 3-dimensional conformal radiotherapy for hepatocellular carcinoma. *Eur J Surg Oncol* 2011; **37**: 245-251 [PMID: 21195578 DOI: 10.1016/j.ejso.2010.12.002]

67 **Tazawa J**, Maeda M, Sakai Y, Yamane M, Ohbayashi H, Kakinuma S, Miyasaka Y, Nagayama K, Enomoto N, Sato C. Radiation therapy in combination with transcatheter arterial chemoembolization for hepatocellular carcinoma with extensive portal vein involvement. *J Gastroenterol Hepatol* 2001; **16**: 660-665 [PMID: 11422619 DOI: 10.1046/j.1440-1746.2001.02496.x]

68 **Eriguchi T**, Takeda A, Sanuki N, Oku Y, Aoki Y, Shigematsu N, Kunieda E. Acceptable toxicity after stereotactic body radiation therapy for liver tumors adjacent to the central biliary system. *Int J Radiat Oncol Biol Phys* 2013; **85**: 1006-1011 [PMID: 23102838 DOI: 10.1016/j.ijrobp.2012.09.012]

69 **Andolino DL**, Johnson CS, Maluccio M, Kwo P, Tector AJ, Zook J, Johnstone PA, Cardenes HR. Stereotactic body radiotherapy for primary hepatocellular carcinoma. *Int J Radiat Oncol Biol Phys* 2011; **81**: e447-e453 [PMID: 21645977 DOI: 10.1016/j.ijrobp.2011.04.011]

70 **Katz AW**, Chawla S, Qu Z, Kashyap R, Milano MT, Hezel AF. Stereotactic hypofractionated radiation therapy as a bridge to transplantation for hepatocellular carcinoma: clinical outcome and pathologic correlation. *Int J Radiat Oncol Biol Phys* 2012; **83**: 895-900 [PMID: 22172906 DOI: 10.1016/j.ijrobp.2011.08.032]

71 **O'Connor JK**, Trotter J, Davis GL, Dempster J, Klintmalm GB, Goldstein RM. Long-term outcomes of stereotactic body radiation therapy in the treatment of hepatocellular cancer as a bridge to transplantation. *Liver Transpl* 2012; **18**: 949-954 [PMID: 22467602 DOI: 10.1002/lt.23439]

72 **Louis C**, Dewas S, Mirabel X, Lacornerie T, Adenis A, Bonodeau F, Lartigau E. Stereotactic radiotherapy of hepatocellular carcinoma: preliminary results. *Technol Cancer Res Treat* 2010; **9**: 479-487 [PMID: 20815419 DOI: 10.1177/153303461000900506]

73 **Jang WI**, Kim MS, Bae SH, Cho CK, Yoo HJ, Seo YS, Kang JK, Kim SY, Lee DH, Han CJ, Kim J, Park SC, Kim SB, Cho EH, Kim YH. High-dose stereotactic body radiotherapy correlates increased local control and overall survival in patients with inoperable hepatocellular carcinoma. *Radiat Oncol* 2013; **8**: 250 [PMID: 24160944 DOI: 10.1186/1748-717X-8-250]

74 **Kang JK**, Kim MS, Cho CK, Yang KM, Yoo HJ, Kim JH, Bae SH, Jung da H, Kim KB, Lee DH, Han CJ, Kim J, Park SC, Kim YH. Stereotactic body radiation therapy for inoperable hepatocellular carcinoma as a local salvage treatment after incomplete transarterial chemoembolization. *Cancer* 2012; **118**: 5424-5431 [PMID: 22570179 DOI: 10.1002/cncr.27533]

75 **Choi BO**, Choi IB, Jang HS, Kang YN, Jang JS, Bae SH, Yoon SK, Chai GY, Kang KM. Stereotactic body radiation therapy with or without transarterial chemoembolization for patients with primary hepatocellular carcinoma: preliminary analysis. *BMC Cancer* 2008; **8**: 351 [PMID: 19038025 DOI: 10.1186/1471-2407-8-351]

76 **Honda Y**, Kimura T, Aikata H, Kobayashi T, Fukuhara T, Masaki K, Nakahara T, Naeshiro N, Ono A, Miyaki D, Nagaoki Y, Kawaoka T, Takaki S, Hiramatsu A, Ishikawa M, Kakizawa H, Kenjo M, Takahashi S, Awai K, Nagata Y, Chayama K. Stereotactic body radiation therapy combined with transcatheter arterial chemoembolization for small hepatocellular carcinoma. *J Gastroenterol Hepatol* 2013; **28**: 530-536 [PMID: 23216217]

77 **Cárdenes HR**, Price TR, Perkins SM, Maluccio M, Kwo P, Breen TE, Henderson MA, Schefter TE, Tudor K, Deluca J, Johnstone PA. Phase I feasibility trial of stereotactic body radiation therapy for primary hepatocellular carcinoma. *Clin Transl Oncol* 2010; **12**: 218-225 [PMID: 20231127 DOI: 10.1007/s12094-010-0492-x]

78 **Bujold A**, Massey CA, Kim JJ, Brierley J, Cho C, Wong RK, Dinniwell RE, Kassam Z, Ringash J, Cummings B, Sykes J, Sherman M, Knox JJ, Dawson LA. Sequential phase I and II trials of stereotactic body radiotherapy for locally advanced hepatocellular carcinoma. *J Clin Oncol* 2013; **31**: 1631-1639 [PMID: 23547075 DOI: 10.1200/JCO.2012.44.1659]

79 **Kwon JH**, Bae SH, Kim JY, Choi BO, Jang HS, Jang JW, Choi JY, Yoon SK, Chung KW. Long-term effect of stereotactic body radiation therapy for primary hepatocellular carcinoma ineligible for local ablation therapy or surgical resection. Stereotactic radiotherapy for liver cancer. *BMC Cancer* 2010; **10**: 475 [PMID: 20813065 DOI: 10.1186/1471-2407-10-475]

80 **Seo YS**, Kim MS, Yoo SY, Cho CK, Choi CW, Kim JH, Han CJ, Park SC, Lee BH, Kim YH, Lee DH. Preliminary result of stereotactic body radiotherapy as a local salvage treatment for inoperable hepatocellular carcinoma. *J Surg Oncol* 2010; **102**: 209-214 [PMID: 20740576 DOI: 10.1002/jso.21593]

81 **Huang WY**, Jen YM, Lee MS, Chang LP, Chen CM, Ko KH, Lin KT, Lin JC, Chao HL, Lin CS, Su YF, Fan CY, Chang YW. Stereotactic body radiation therapy in recurrent hepatocellular carcinoma. *Int J Radiat Oncol Biol Phys* 2012; **84**: 355-361 [PMID: 22342300 DOI: 10.1016/j.ijrobp.2011.11.058]

82 **Bae SH**, Kim MS, Cho CK, Kim KB, Lee DH, Han CJ, Park SC, Kim YH. Feasibility and efficacy of stereotactic ablative radiotherapy for Barcelona Clinic Liver Cancer-C stage hepatocellular carcinoma. *J Korean Med Sci* 2013; **28**: 213-219 [PMID: 23400333 DOI: 10.3346/jkms.2013.28.2.213]

83 **Ohnishi K**, Okuda K, Ohtsuki T, Nakayama T, Hiyama Y, Iwama S, Goto N, Nakajima Y, Musha N, Nakashima T. Formation of hilar collaterals or cavernous transformation after portal vein obstruction by hepatocellular carcinoma. Observations in ten patients. *Gastroenterology* 1984; **87**: 1150-1153 [PMID: 6090259]

84 **Pirisi M**, Avellini C, Fabris C, Scott C, Bardus P, Soardo G, Beltrami CA, Bartoli E. Portal vein thrombosis in hepatocellular carcinoma: age and sex distribution in an autopsy study. *J Cancer Res Clin Oncol* 1998; **124**: 397-400 [PMID: 9719503 DOI: 10.1007/s004320050189]

85 **Ikai I**, Itai Y, Okita K, Omata M, Kojiro M, Kobayashi K, Nakanuma Y, Futagawa S, Makuuchi M, Yamaoka Y. Report of the 15th follow-up survey of primary liver cancer. *Hepatol Res* 2004; **28**: 21-29 [PMID: 14734147 DOI: 10.1016/j.hepres.2003.08.002]

86 **Toya R**, Murakami R, Baba Y, Nishimura R, Morishita S, Ikeda O, Kawanaka K, Beppu T, Sugiyama S, Sakamoto T, Yamashita Y, Oya N. Conformal radiation therapy for portal vein tumor thrombosis of hepatocellular carcinoma. *Radiother Oncol* 2007; **84**: 266-271 [PMID: 17716760 DOI: 10.1016/j.radonc.2007.07.005]

87 **Kim DY**, Park W, Lim DH, Lee JH, Yoo BC, Paik SW, Kho KC, Kim TH, Ahn YC, Huh SJ. Three-dimensional conformal radiotherapy for portal vein thrombosis of hepatocellular carcinoma. *Cancer* 2005; **103**: 2419-2426 [PMID: 15822130 DOI: 10.1002/cncr.21043]

88 **Rim CH**, Yang DS, Park YJ, Yoon WS, Lee JA, Kim CY. Effectiveness of high-dose three-dimensional conformal

radiotherapy in hepatocellular carcinoma with portal vein thrombosis. *Jpn J Clin Oncol* 2012; **42**: 721-729 [PMID: 22689916 DOI: 10.1093/jjco/hys082]

89 **Kim JY**, Yoo EJ, Jang JW, Kwon JH, Kim KJ, Kay CS. Hypofractionated radiotheapy using helical tomotherapy for advanced hepatocellular carcinoma with portal vein tumor thrombosis. *Radiat Oncol* 2013; **8**: 15 [PMID: 23324259]

90 **Xi M**, Zhang L, Zhao L, Li QQ, Guo SP, Feng ZZ, Deng XW, Huang XY, Liu MZ. Effectiveness of stereotactic body radiotherapy for hepatocellular carcinoma with portal vein and/or inferior vena cava tumor thrombosis. *PLoS One* 2013; **8**: e63864 [PMID: 23737955 DOI: 10.1371/journal.pone.0063864]

91 **Nakayama H**, Sugahara S, Tokita M, Fukuda K, Mizumoto M, Abei M, Shoda J, Sakurai H, Tsuboi K, Tokuuye K. Proton beam therapy for hepatocellular carcinoma: the University of Tsukuba experience. *Cancer* 2009; **115**: 5499-5506 [PMID: 19645024 DOI: 10.1002/cncr.24619]

92 **Fukumitsu N**, Sugahara S, Nakayama H, Fukuda K, Mizumoto M, Abei M, Shoda J, Thono E, Tsuboi K, Tokuuye K. A prospective study of hypofractionated proton beam therapy for patients with hepatocellular carcinoma. *Int J Radiat Oncol Biol Phys* 2009; **74**: 831-836 [PMID: 19304408 DOI: 10.1016/j.ijrobp.2008.10.073]

93 **Komatsu S**, Fukumoto T, Demizu Y, Miyawaki D, Terashima K, Sasaki R, Hori Y, Hishikawa Y, Ku Y, Murakami M. Clinical results and risk factors of proton and carbon ion therapy for hepatocellular carcinoma. *Cancer* 2011; **117**: 4890-4904 [PMID: 21495022 DOI: 10.1002/cncr.26134]

94 **Kawashima M**, Furuse J, Nishio T, Konishi M, Ishii H, Kinoshita T, Nagase M, Nihei K, Ogino T. Phase II study of radiotherapy employing proton beam for hepatocellular carcinoma. *J Clin Oncol* 2005; **23**: 1839-1846 [PMID: 15774777 DOI: 10.1200/JCO.2005.00.620]

95 **Bush DA**, Kayali Z, Grove R, Slater JD. The safety and efficacy of high-dose proton beam radiotherapy for hepatocellular carcinoma: a phase 2 prospective trial. *Cancer* 2011; **117**: 3053-3059 [PMID: 21264826 DOI: 10.1002/cncr.25809]

96 **Sugahara S**, Nakayama H, Fukuda K, Mizumoto M, Tokita M, Abei M, Shoda J, Matsuzaki Y, Thono E, Tsuboi K, Tokuuye K. Proton-beam therapy for hepatocellular carcinoma associated with portal vein tumor thrombosis. *Strahlenther Onkol* 2009; **185**: 782-788 [PMID: 20013087 DOI: 10.1007/s00066-009-2020-x]

97 **Sugahara S**, Oshiro Y, Nakayama H, Fukuda K, Mizumoto M, Abei M, Shoda J, Matsuzaki Y, Thono E, Tokita M, Tsuboi K, Tokuuye K. Proton beam therapy for large hepatocellular carcinoma. *Int J Radiat Oncol Biol Phys* 2010; **76**: 460-466 [PMID: 19427743 DOI: 10.1016/j.ijrobp.2009.02.030]

98 **Dawson LA**. Protons or photons for hepatocellular carcinoma? Let's move forward together. *Int J Radiat Oncol Biol Phys* 2009; **74**: 661-663 [PMID: 19480966 DOI: 10.1016/j.ijrobp.2009.02.009]

99 **Toramatsu C**, Katoh N, Shimizu S, Nihongi H, Matsuura T, Takao S, Miyamoto N, Suzuki R, Sutherland K, Kinoshita R, Onimaru R, Ishikawa M, Umegaki K, Shirato H. What is the appropriate size criterion for proton radiotherapy for hepatocellular carcinoma? A dosimetric comparison of spot-scanning proton therapy versus intensity-modulated radiation therapy. *Radiat Oncol* 2013; **8**: 48 [PMID: 23497543 DOI: 10.1186/1748-717X-8-48]

100 **Lin M**, Zhang D, Huang J, Zhang J, Xiao W, Yu H, Zhang L, Ye J. The anti-hepatoma effect of nanosized Mn-Zn ferrite magnetic fluid hyperthermia associated with radiation in vitro and in vivo. *Nanotechnology* 2013; **24**: 255101 [PMID: 23708194 DOI: 10.1088/0957-4484/24/25/255101]

101 **Zhang KS**, Zhou Q, Wang YF, Liang LJ. Killing effects of different physical factors on extracorporeal HepG2 human hepatoma cells. *Asian Pac J Cancer Prev* 2012; **13**: 1025-1029 [PMID: 22631632 DOI: 10.7314/APJCP.2012.13.3.1025]

102 **Linchun W**, Chuanwen Y, Xiyan L, Jianzhang C, Lu X. The Analysis of Efficacy of Three Dimensional Conformal Radiotherapy Combined with Radio Frequency Hyperthermia in the Treatment of 42 Patients with Advanced Hepatocellular Carcinoma. *J Basic Clin Oncol* 2011; **4**: 311-313

103 **Guha C**, Kavanagh BD. Hepatic radiation toxicity: avoidance and amelioration. *Semin Radiat Oncol* 2011; **21**: 256-263 [PMID: 21939854 DOI: 10.1016/j.semradonc.2011.05.003]

104 **Ogata K**, Hizawa K, Yoshida M, Kitamuro T, Akagi G, Kagawa K, Fukuda F. Hepatic injury following irradiation--a morphologic study. *Tokushima J Exp Med* 1963; **43**: 240-251 [PMID: 14049847]

105 **Dawson LA**, Normolle D, Balter JM, McGinn CJ, Lawrence TS, Ten Haken RK. Analysis of radiation-induced liver disease using the Lyman NTCP model. *Int J Radiat Oncol Biol Phys* 2002; **53**: 810-821 [PMID: 12095546 DOI: 10.1016/S0360-3016(02)02846-8]

106 **Fajardo LF**, Colby TV. Pathogenesis of veno-occlusive liver disease after radiation. *Arch Pathol Lab Med* 1980; **104**: 584-588 [PMID: 6893535]

107 **Emami B**, Lyman J, Brown A, Coia L, Goitein M, Munzenrider JE, Shank B, Solin LJ, Wesson M. Tolerance of normal tissue to therapeutic irradiation. *Int J Radiat Oncol Biol Phys* 1991; **21**: 109-122 [PMID: 2032882 DOI: 10.1016/0360-3016(91)90171-Y]

108 **Jackson A**, Ten Haken RK, Robertson JM, Kessler ML, Kutcher GJ, Lawrence TS. Analysis of clinical complication data for radiation hepatitis using a parallel architecture model. *Int J Radiat Oncol Biol Phys* 1995; **31**: 883-891 [PMID: 7860402 DOI: 10.1016/0360-3016(94)00471-4]

109 **Dawson LA**, Ten Haken RK. Partial volume tolerance of the liver to radiation. *Semin Radiat Oncol* 2005; **15**: 279-283 [PMID: 16183482 DOI: 10.1016/j.semradonc.2005.04.005]

110 **Lightdale CJ**, Wasser J, Coleman M, Brower M, Tefft M, Pasmantier M. Anticoagulation and high dose liver radiation: a preliminary report. *Cancer* 1979; **43**: 174-181 [PMID: 104786 DOI: 10.1002/1097-0142(197901)43:1<174::AID-CNCR2820430126>3.0.CO;2-Q]

111 **DeLeve LD**, Wang X, Kuhlenkamp JF, Kaplowitz N. Toxicity of azathioprine and monocrotaline in murine sinusoidal endothelial cells and hepatocytes: the role of glutathione and relevance to hepatic venoocclusive disease. *Hepatology* 1996; **23**: 589-599 [PMID: 8617441 DOI: 10.1002/hep.510230326]

112 **Gençel O**, Naziroglu M, Celik O, Yalman K, Bayram D. Selenium and vitamin E modulates radiation-induced liver toxicity in pregnant and nonpregnant rat: effects of colemanite and hematite shielding. *Biol Trace Elem Res* 2010; **135**: 253-263 [PMID: 19763408 DOI: 10.1007/s12011-009-8513-8]

113 **Breitkopf K**, Haas S, Wiercinska E, Singer MV, Dooley S. Anti-TGF-beta strategies for the treatment of chronic liver disease. *Alcohol Clin Exp Res* 2005; **29**: 121S-131S [PMID: 16344596 DOI: 10.1097/01.alc.0000189284.98684.22]

114 **Shafritz DA**, Oertel M. Model systems and experimental conditions that lead to effective repopulation of the liver by transplanted cells. *Int J Biochem Cell Biol* 2011; **43**: 198-213 [PMID: 20080205 DOI: 10.1016/j.biocel.2010.01.013]

115 **Gilchrist ES**, Plevris JN. Bone marrow-derived stem cells in liver repair: 10 years down the line. *Liver Transpl* 2010; **16**: 118-129 [PMID: 20104479 DOI: 10.1002/lt.21965]

116 **Soltys KA**, Soto-Gutiérrez A, Nagaya M, Baskin KM, Deutsch M, Ito R, Shneider BL, Squires R, Vockley J, Guha C, Roy-Chowdhury J, Strom SC, Platt JL, Fox IJ. Barriers to the successful treatment of liver disease by hepatocyte transplantation. *J Hepatol* 2010; **53**: 769-774 [PMID: 20667616 DOI: 10.1016/j.jhep.2010.05.010]

117 **Katyal S**, Oliver JH, Peterson MS, Ferris JV, Carr BS, Baron RL. Extrahepatic metastases of hepatocellular carcinoma. *Radiology* 2000; **216**: 698-703 [PMID: 10966697 DOI: 10.1148/radiology.216.3.r00se24698]

118 **Uchino K**, Tateishi R, Shiina S, Kanda M, Masuzaki R, Kondo

Y, Goto T, Omata M, Yoshida H, Koike K. Hepatocellular carcinoma with extrahepatic metastasis: clinical features and prognostic factors. *Cancer* 2011; **117**: 4475-4483 [PMID: 21437884 DOI: 10.1002/cncr.25960]

119 **Terada T**, Maruo H. Unusual extrahepatic metastatic sites from hepatocellular carcinoma. *Int J Clin Exp Pathol* 2013; **6**: 816-820 [PMID: 23638212]

120 **Jiang XB**, Ke C, Zhang GH, Zhang XH, Sai K, Chen ZP, Mou YG. Brain metastases from hepatocellular carcinoma: clinical features and prognostic factors. *BMC Cancer* 2012; **12**: 49 [PMID: 22292912 DOI: 10.1186/1471-2407-12-49]

121 **He J**, Zeng ZC, Fan J, Zhou J, Sun J, Chen B, Yang P, Wang BL, Zhang BH, Zhang JY. Clinical features and prognostic factors in patients with bone metastases from hepatocellular carcinoma after liver transplantation. *BMC Cancer* 2011; **11**: 492 [PMID: 22107882 DOI: 10.1186/1471-2407-11-492]

122 **Yamashita H**, Nakagawa K, Shiraishi K, Tago M, Igaki H, Nakamura N, Sasano N, Siina S, Omata M, Ohtomo K. Radiotherapy for lymph node metastases in patients with hepatocellular carcinoma: retrospective study. *J Gastroenterol Hepatol* 2007; **22**: 523-527 [PMID: 17376045 DOI: 10.1111/j.1440-1746.2006.04450.x]

123 **Kaizu T**, Karasawa K, Tanaka Y, Matuda T, Kurosaki H, Tanaka S, Kumazaki T. Radiotherapy for osseous metastases from hepatocellular carcinoma: a retrospective study of 57 patients. *Am J Gastroenterol* 1998; **93**: 2167-2171 [PMID: 9820391 DOI: 10.1111/j.1572-0241.1998.00614.x]

124 **Choi HJ**, Cho BC, Sohn JH, Shin SJ, Kim SH, Kim JH, Yoo NC. Brain metastases from hepatocellular carcinoma: prognostic factors and outcome: brain metastasis from HCC. *J Neurooncol* 2009; **91**: 307-313 [PMID: 18949445 DOI: 10.1007/s11060-008-9713-3]

125 **Chang L**, Chen YL, Kao MC. Intracranial metastasis of hepatocellular carcinoma: review of 45 cases. *Surg Neurol* 2004; **62**: 172-177 [PMID: 15261518 DOI: 10.1016/j.surneu.2003.10.002]

126 **Han JH**, Kim DG, Park JC, Chung HT, Paek SH, Chung YS. Little response of cerebral metastasis from hepatocellular carcinoma to any treatments. *J Korean Neurosurg Soc* 2010; **47**: 325-331 [PMID: 20539790 DOI: 10.3340/jkns.2010.47.5.325]

127 **Sanuki N**, Takeda A, Oku Y, Eriguchi T, Nishimura S, Aoki Y, Kunieda E. Influence of liver toxicities on prognosis after stereotactic body radiation therapy for hepatocellular carcinoma. *Hepatol Res* 2014; Epub ahead of print [PMID: 24976460 DOI: 10.1111/hepr.12383]

P- Reviewer: Fu Q, Lee WC, Vitale A **S- Editor**: Ji FF
L- Editor: A **E- Editor**: Liu SQ

World Journal of Hepatology

Submit a Manuscript: http://www.wjgnet.com/esps/
Help Desk: http://www.wjgnet.com/esps/helpdesk.aspx
DOI: 10.4254/wjh.v7.i1.113

World J Hepatol 2015 January 27; 7(1): 113-120
ISSN 1948-5182 (online)

MINIREVIEWS

Clinical utility of complex mutations in the core promoter and proximal precore regions of the hepatitis B virus genome

Young Min Park

Young Min Park, Hepatology Center, Department of Internal Medicine, Bundang Jesaeng General Hospital, Seongnam-si, Kyungki-do 463-774, South Korea
Young Min Park, Biomedical Research Center, Bundang Jesaeng General Hospital, Seongnam-si, Kyungki-do 463-774, South Korea
Author contributions: Park YM solely contributed to this paper.

Correspondence to: Young Min Park, MD, PhD, Hepatology Center, Department of Internal Medicine, Bundang Jesaeng General Hospital, 255-2, Seohyun-dong, Bundang-gu, Seongnam-si, Kyungki-do 463-774, South Korea. ymp1@outlook.com
Telephone: +82-31-7790676
Fax: +82-31-7790164
Received: August 28, 2014
Peer-review started: August 28, 2014
First decision: September 28, 2014
Revised: October 12, 2014
Accepted: October 28, 2014
Article in press: October 29, 2014
Published online: January 27, 2015

Abstract

The core promoter and proximal precore regions are the most complex portions of the hepatitis B virus (HBV) genome. These regions cooperatively regulate viral replication and differentially regulate the synthesis of the viral proteins E, core, and X. Multiple mutations in these regions are associated with the persistency of viral infection and the development of cirrhosis and hepatocellular carcinoma (HCC). In South Korea, nearly all HBVs are classified as HBV genotype C2; the majority of these viruses have the basal core promoter double mutation, a precore stop mutation, or both. These mutations may play a role in the alteration of viral and clinical features, and abundant and complex mutations are particularly prevalent in the core promoter and proximal precore regions. We previously demonstrated that the accumulation of ⩾ 6 mutations at eight key nucleotides located in these regions (G1613A, C1653T, T1753V, A1762T, G1764A, A1846T, G1896A, and G1899A) is a useful marker to predict the development of HCC regardless of advanced liver disease. In addition, certain mutation combinations were predominant in cases with ⩾ 4 mutations. In cases with ⩽ 5 mutations, a low Hepatitis B e antigen titer (< 35 signal to noise ratio) was indicative of HCC risk. Viral mutation data of the single HBV genotype C2 suggest that the combined effect of the number and pattern of mutations in the core promoter and proximal precore regions is helpful in predicting HCC risk.

Key words: Hepatitis B virus; Point mutation; Hepatitis B virus X protein; Hepatocellular carcinoma; Cancer screening

Core tip: Multiple mutations in the core promoter and proximal precore regions of the hepatitis B virus (HBV) genome are associated with hepatocellular carcinoma (HCC), but mutations predictive of outcome in chronic HBV carriers have not been distinguished. In the Korean HBV genotype C2, the number of mutations at eight key nucleotides located in these regions (G1613A, C1653T, T1753V, A1762T, G1764A, A1846T, G1896A, and G1899A) is positively correlated with HCC. In addition, some selected mutation combinations among individuals with ⩾ 4 mutations are predominant in the HCC group.

Park YM. Clinical utility of complex mutations in the core promoter and proximal precore regions of the hepatitis B virus genome. *World J Hepatol* 2015; 7(1): 113-120 Available from: URL: http://www.wjgnet.com/1948-5182/full/v7/i1/113.htm DOI: http://dx.doi.org/10.4254/wjh.v7.i1.113

NATURAL HISTORY OF CHRONIC HEPATITIS B VIRUS INFECTION

Chronic hepatitis B virus (HBV) infection increases the risk of developing liver cirrhosis and hepatocellular carcinoma (HCC)[1-3]. The natural course of HBV infection involves three clinical phases: immune tolerance, immune eradication, and recovery. The phase of HBV infection is classified based on serum aminotransferase levels and HBV DNA titer, which represent hepatitis and viral replication, respectively[1-4]. When the HBV DNA titer is greater than 2000 IU/mL, host immune mechanisms trigger the flare-up of hepatitis and regulate hepatitis activities that bridge the gap between the virus replication phase and the development of liver cirrhosis or HCC. The majority of hepatitis patients are anicteric, and the process tends to repeat until HBV loses the capability to replicate in hepatocytes[5,6]. When serum viral loads are persistently less than 350 IU/mL, the progressive loss of HBV genomic activity and the inability to stimulate a host immune response are observed, indicating that the carrier is in the recovery phase[3]. Throughout chronic HBV infection, sex and age are important host factors for predicting HCC risk[2,7].

HISTOLOGICAL VIEWPOINT OF THE OUTCOME OF CHRONIC HBV INFECTION

Hepatitis is graded based on histological analysis of necro-inflammation and fibrosis, and severe hepatitis simultaneously promotes hepatic fibrogenesis and carcinogenesis[8]. For example, serial liver biopsy data indicate that chronic hepatitis B patients with severe necro-inflammation exhibited significantly poorer morbidity and mortality compared with patients with mild necro-inflammation[6]. The histological findings are occasionally paradoxical and indicate healing or aggravation of fibrosis. In cases of chronic hepatitis B with bridging hepatic necrosis, a feature of aggressive hepatitis, patients frequently recover after the flare-up, but fibrosis or cirrhosis remains[9]. These findings suggest that the degree of fibrosis, also referred to as the fibrosis stage, potentially reflects the sequential changes associated with progressive chronic liver disease and is a more efficient indicator of prognosis than the ongoing inflammation[3,7,10].

VIROLOGICAL VIEWPOINT OF THE OUTCOME OF CHRONIC HBV INFECTION

During the active hepatitis phase, the immune response significantly inhibits viral replication while simultaneously inducing mutation of the HBV genome, including so-called "escape mutants". HBV DNA titers in serum and hepatocytes have been associated with a less favorable course due to either poor clearance of the virus or increased virus production, whereas the long-term prognosis of patients with a low viral load is generally good[2,11-14]. However, HBV DNA titers are dynamic and depend on the type of mutation and anti-viral immunity, and are intricately connected to changes in hepatitis B surface antigen and hepatitis B e antigen (HBeAg) levels[15-18]. In particular, serum HBeAg and HBV DNA levels are closely associated with A1762T and G1764A, which are known as the basal core promoter (BCP) double mutation (A1762T/G1764A), and G1896A, the precore stop mutation; both A1762T/G1764A and G1896A are associated with e-suppressive phenotypes as well as decreased HBV genome replication[13,15,16,19-21]. The precore stop mutation synergistically modulates the influence of the BCP double mutation on HBV replication[22]. These mutations tend to increase HBV persistence[22,23]. The relationship between viral loads and hepatitis flare-ups in the immune eradication phase is not clear, and persistent infection by mutant HBV may influence the progression of chronic hepatitis[2,12-15,20,24], prompting interest in the identification of viral mutations that affect the outcome of chronic HBV infection.

HBV GENOTYPES, THE BCP DOUBLE MUTATION, AND THE PRECORE STOP MUTATION

Eight distinct genotypes of HBV have been reported (denoted A-H); each genotype includes variants with less than 8% divergence among their DNA sequences[25,26]. HBV genotypes B and C are more closely associated with the development of HCC than other genotypes[15,20,23,27] and are characterized by a higher prevalence of the BCP double mutation and the precore stop mutation[20,25,27]. Thus, genotypes B and C are apparently aggressive with respect to the development of HCC. However, in South Korea, nearly all HBV cases are genotype C2 (Ce)[28-33]. Although highly prevalent in HCC (86%), the prevalence of the precore stop mutation does not differ significantly among chronic HBV carriers with or without HCC[32,34,35]. Most isolates of HBV genotype C2 in South Korea carry the T1858 mutation[32,33], which attenuates the stability of the secondary structure of the pregenome encapsidation signal (epsilon signal). In contrast, C1858 prevents the formation of G1896A[36]. The BCP double mutation is also not a significant factor because it is present in the majority of HBV genotype C2 strains in South Korea. For instance, the BCP double mutation is identified in 93.5% of HBeAg-negative bDNA-positive patients, 94.9% of HBeAg-negative bDNA-negative patients, and 74% of HBeAg-positive patients[32]. Despite the high prevalence of G1896A and BCP double mutations, the single C2 genotype of South Korea represents an intriguing model system in which to identify viral mutations with prognostic utility. Complex mutations

in the core promoter and precore regions of the HBV genome are of particular interest.

CLINICAL FEATURES OF WILD TYPE HBV GENOTYPE C2

Because the literature regarding the clinical features of wild-type HBV genotype C2 is lacking, we analyzed this genotype in comparison with three mutation types using our published raw data (n = 442)[33,37]. The selected 109 patients consisted of four groups: wild-type (Ⅰ, n = 29), precore stop mutation alone (Ⅱ, n = 14), BCP double mutation only (Ⅲ, n = 44), and the A1762T, G1764A and G1896A triple mutation (Ⅳ, n = 22). The proportion of patients classified as group I decreased dramatically among those over 40 years of age, whereas the other groups experienced a relative increase in the proportion of individuals over 40 years of age. The proportions of HBeAg-negative patients and patients with serum HBV DNA levels < 15000 IU/mL (or 6 log copies/mL) were reduced in groups I and Ⅲ compared with groups Ⅱ and Ⅳ (HBeAg negative, 3.4% and 15.9% *vs* 57.1% and 50%, respectively; HBV DNA < 15000 IU/mL, 7.1% and 16.2% *vs* 33.3% and 36.4%, respectively). These results suggest that the precore stop mutation is more closely associated with the attenuation of self-replication and HBeAg production than the BCP double mutation. In group Ⅰ, active hepatitis, advanced liver disease, and HCC were uncommon regardless of age compared with groups Ⅱ-Ⅳ. In addition, half of the cases remained inactive for a long period (*i.e.*, greater than 5 years). In groups Ⅰ-Ⅳ, active hepatitis was noted in 44.8%, 57.1%, 72.7%, and 54.5% of patients, respectively. Advanced liver disease was noted in 6.9%, 28.6%, 22.7%, and 18.2% of patients, respectively. HCC was reported in 3.4%, 14.3%, 13.6%, and 13.6% of patients, respectively. In groups Ⅱ-Ⅳ, most of the patients with advanced liver disease and/or HCC were over the age of 40. Thus, the clinical features of wild-type HBV genotype C2 conversely reflect the aggressiveness and persistency of the mutant type, and the BCP double mutation is associated with the initiation of HCC regardless of age. Nevertheless, these three types of mutations are insufficient as viral markers for outcome prediction because their capacity to discriminate between high and low risk of HCC is minimal. However, other mutations are likely important, particularly among the BCP mutant type HBVs, and the potential combinations of mutations are abundant and complex.

KEY MUTATIONS IN THE CORE PROMOTER AND PROXIMAL PRECORE REGIONS OF THE HBV GENOME

The core promoter overlaps the distal part of the X gene, and the proximal precore includes the epsilon signal[38-40]. These two genetically distinct regions are the most complex portion of the HBV genome, which includes various functional gene clusters, such as enhancer Ⅱ, the basal core promoter, the X-termination signal, two pregenomic RNA start points, the poly A signal, epsilon, and other important sequences[38-40]. These regions differentially regulate the synthesis of pregenomic and pre-C mRNAs of HBV and the production of HBeAg and hepatitis B core antigen (HBcAg), and co-operatively regulate viral replication[39-42]. Any single mutation can induce some form of inherent change that affects viral loads and the levels of HBeAg in serum and HBcAg and X protein in hepatocytes. These effects can subsequently modulate the immune response to viral antigens and enhance the carcinogenic effects of altered X proteins[40]. In Far East Asia, HBV genotypes B and C are predominant, and five mutations are prominent in the core promoter and proximal precore regions: G1613A, C1653T, T1753V, A1846T, and G1899A[43-47]. These select mutations are associated with the development of HCC when combined with the BCP double mutation. Many additional mutants have been reported in the literature, but most of these mutations are sporadic. Our data indicate that these mutations, together with A1762T, G1764A, and G1896A, are the most important frequent mutations in HBV genotype C2[33]. Considering the accumulation of mutations with time and the age of HCC patients, analyses must focus on the complexity of mutations associated with HCC risk, particularly in chronic HBV carriers greater than 40 years of age.

TRIPLE OR QUADRUPLE MUTATIONS INCLUDING THE BCP DOUBLE MUTATION

Although single *G1613A* or *G1896A* mutations are commonly noted in HBV genotype C2 in South Korea, single *C1653T*, *T1753V*, *A1846T* or *G1899A* mutations are rarely identified. Most of these mutations occur in combination with the BCP double mutation[37]. These results suggest that the BCP double mutation (*A1762T/G1764A*) may function as a starting point for the generation of viral variants harboring *C1653T*, *T1753V*, *A1846T*, and *G1899A* mutations. Therefore, it is not surprising that T1753V is more frequently linked to HBV genotype C than genotype B (19.2% *vs* 1.9%; P = 0.013)[15]. G1899A combined with the BCP double mutation is the single risk factor indicating HCC risk in Thailand and Tunisia, but the linkages between mutations are less clear in South Korea[33,37,45,48]. Our data indicate that while G1896A increases steadily with time, the accumulation of A1846T begins to increase during the quadruple phase of mutations. In contrast, the other mutations begin to accumulate at the triple phase[33,37]. Various specific quadruple mutations are superior to the BCP double mutation for determining HCC risk, whereas any individual triple mutation is not superior[33,37,43,49]. The combination of G1613A and C1653T is associated with HCC in HBV genotype C patients[49], whereas the combination of C1653T and T1753V is associated with

HCC in HBV genotype B patients[43]. Among 15 different quadruple mutations containing the BCP double mutation, our analyses indicate that only five types are predominant [74.2% (72/97)], including the combinations (G1613A + C1653T), (C1653T + T1753V), (C1653T + G1896A), (T1753V + G1896A), and (A1846T + G1896A). These mutations account for 94.4% (34/36) of HCC cases that develop in the context of quadruple mutations. When exclusively compared with the BCP double mutation [HCC, 13.6% (6/44)], the prevalence of HCC among these five quadruple mutations was 46.2% (6/13, P = 0.02), 40% (2/5, P = 0.1821), 27.3% (6/20, P = 0.168), 66.7% (14/21, P = 0.00003) and 46.2% (6/13, P = 0.02), respectively. The respective odds ratios for HCC were 5.4286 (95%CI: 1.353-21.7821), 4.2222 (95%CI: 0.5797-30.7518), 2.7143 (95%CI: 0.7495-9.8293), 12.6667 (95%CI: 3.6262-44.2465) and 5.4286 (95%CI: 1.353-21.7821). The combination of C1766T and T1768A appears to enhance the carcinogenic effects of the X protein, but these mutations are rarely identified in South Korea[33,50]. Multivariate analyses of variables in relation to HCC indicate that mutation number is the only significantly independent viral factor[33]. These data indicate that complex mutations should be systematically evaluated as a function of the number of mutations.

THE UTILITY OF THE NUMBER OF MUTATIONS OF EIGHT KEY NUCLEOTIDES IN THE PREDICTION OF HCC

Although the development of HCC correlates with the accumulation of mutations, most studies have examined combinations of four mutations or less[43,51]. We analyzed the cumulative effects of complex mutations through a stratified analysis based on mutation number. The HCC rate in chronic HBV carriers increased linearly from wild-type to eight mutations as follows: 3.4% (1/29), 8.7% (2/23), 14.5% (8/55), 21.2% (21/99), 35.6% (36/101), 31.8% (21/66), 52.4% (22/42), 78.9% (15/19), and 75% (6/8), respectively (Y = 0.0917*X, r^2 = 0.9199). Quadruple mutations were the most prevalent among the study subjects; double and triple mutations were most common in the non-HCC group, whereas multiple mutations, including more than four mutations, were predominant in the HCC group[33]. Compared with the BCP double mutation, the odds ratios (95%CI, P-value) of three to eight mutations were 1.7561 (0.6131-5.0301, 0.3250), 3.4286 (1.2623-9.3127, 0.0513), 2.7143 (0.9333-7.8939, 0.0820), 4.8571 (1.5527-15.1942, 0.0079), 30.0000 (5.3429-168.4491, 0.0000), and 24.0000 (2.4104-238.9646, 0.0023), respectively[33]. Based on these findings, we hypothesize that the number of mutations is a more sensitive predictor of HCC risk than any specific mutation[33]. In particular, cases with ⩾ 6 mutations were associated with HCC with the greatest accuracy; the sensitivity, specificity, positive predictive value and negative predictive value were 44.0%, 97.3%, 94.3%, and 63.5%, respectively. The diagnostic efficiency of ⩾ 6 mutations was comparable to that of alpha-fetoprotein (AFP), a specific biomarker for HCC diagnosis. The AUROC was 0.824 (95%CI: 0.759-0.890) for ⩾ 6 mutations and 0.869 (95%CI: 0.812-0.925) for AFP[33].

SPECIFIC MUTATION COMBINATIONS ASSOCIATED WITH HCC

In a longitudinal cohort of 25 patients with serial serum samples spanning the years before and after HCC diagnosis, most of the patients with HCC (24/25, 96.0%) exhibited ⩾ 4 mutations including the BCP double mutation years prior to HCC development; these patients also exhibited an equal or increasing number of mutations until HCC development[33]. In particular, some mutation combinations were specifically associated with HCC, and the core mutations differed little among combinations of four, six, and seven mutations. Although the (G1613A + C1653T), (C1653T + T1753V), (C1653T + G1896A), (T1753V + G1896A), and (A1846T + G1896A) double mutations were prominent in HCC patients with quadruple mutations, the addition of any single mutation did not improve the combined effect of an existing quadruple mutation[37]. With regard to six mutations, the (G1613A + C1653T + A1846T + G1896A) and (G1613A + C1653T + A1846T + G1899A) combinations were observed in half of the HCC patients, whereas additional mutations were sporadic[37]. Compared with the BCP double mutation alone, the prevalence and odds ratios were 71.4% (5/7, P = 0.0032) and 15.8333 (95%CI: 2.4843-100.9110) for the (G1613A + C1653T + A1846T + G1896A), respectively, and 83.3% (5/6, P = 0.0012) and 31.6667 (95%CI: 3.1331-320.0591) for the (G1613A + C1653T + A1846T + G1899A), respectively[37]. With regard to seven mutations, the combinations (G1613A + C1653T + T1753V + A1846T + G1896A) and (G1613A + C1653T + A1846T + G1896A + G1899A) were observed in 86.7% of the HCC group; the rate of HCC was 100% (6/6) for the former combination and 85.7% (6/7) for the latter[37]. These data suggest that the acquisition of a new mutation is not incidental; however, the new mutation potentially follows the rules of association and linkage between a mutation and an existing mutation combination.

ASSOCIATION BETWEEN LOW-TITER HBeAg AND A NUMBER OF KEY MUTATIONS

In the data analyses, we arbitrarily defined low-titer HBeAg as a signal-to-noise ratio of less than 35 as measured by ELISA (Abbott Laboratories, Diagnostic Division, Abbott Park, IL 60064, United States)[52]. Of 442 cases, 57.2% (n = 253) were HBeAg-positive. Of 132 HCC cases, 47% (n = 62) were classified as HBeAg-

Table 1 Hepatocellular carcinoma rate of specific mutation combinations and odds ratio in comparison with basal core promoter double mutation only

Specific mutation combinations in combination with BCP[2] double mutations	HCC[1] rate	OR	95%CI	*P*-value
Wild-type	3.4% (1/29)	0.23	0.0048-2.0622	0.2391
BCP double mutations only [(A1762T + G1764A)][3]	13.6% (6/44)	1[3]		
Dominant quadruple mutations				
(G1613A + C1653T)	46.2% (6/13)	5.4286	5.4286-1.3530	0.0200
(C1653T + T1753V)	40.0% (2/5)	4.2222	4.2222-0.5797	0.1821
(C1653T + G1896A)	27.3% (6/20)	2.7143	2.7143-0.7495	0.1680
(T1753V + G1896A)	66.7% (14/21)	12.6667	12.6667-3.6262	0.0000
(A1846T + G1896A)	46.2% (6/13)	5.4286	5.4286-1.3530	0.0200
Dominant combinations in sextuplet mutations:				
(G1613A + C1653T + A1846T + G1896A)	71.4% (5/7)	14.5142	1.8869-185.1359	0.0033
(G1613A + C1653T + A1846T + G1899A)	83.3% (5/6)	28.2555	2.5885-1517.9673	0.0012
Dominant combinations in septuplet mutations:				
(G1613A + C1653T + T1753V + A1846T + G1896A)	100% (6/6)	Infinity	5.4236-infinity	0.0001
(G1613A + C1653T + A1846T + G1896A + G1899A)	85.7% (6/7)	39.3553	4.0487-2018.0433	0.0001

[1]Hepatocellular carcinoma; [2]Basal core promoter; [3]Reference of odds ratio analyses; *P*-value was calculated by Fisher's exact test for count data. BCP: Basal core promoter; HCC: Hepatocellular carcinoma.

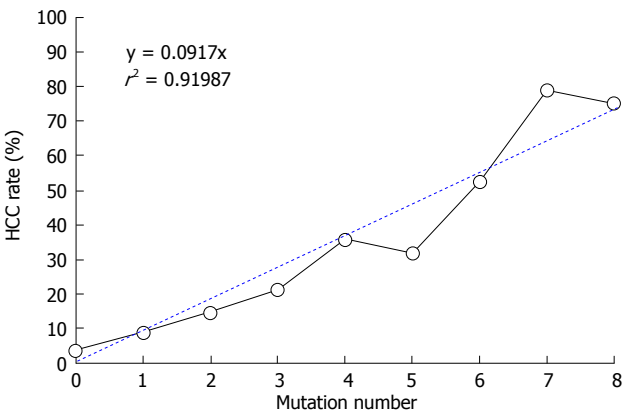

Figure 1 The number of mutations positively correlates with the rate of hepatocellular carcinoma: Pearson's correlation = 0.9614 (95%CI: 0.8225-0.9921; *P* = 0.0000). HCC: Hepatocellular carcinoma.

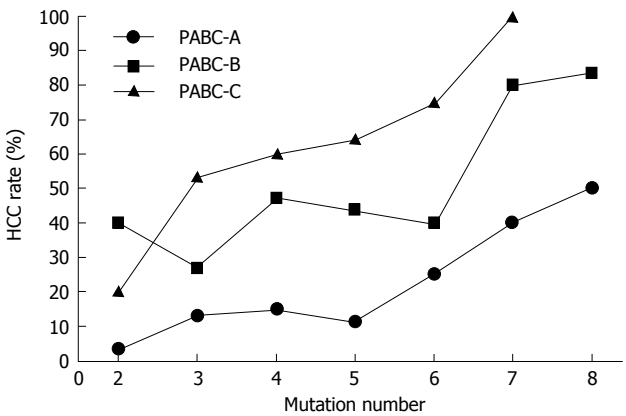

Figure 2 The number of mutations positively correlates with advanced liver disease, and advanced liver disease correlates with hepatocellular carcinoma. However, the number of mutations is correlated with hepatocellular carcinoma independent of advanced liver disease. We arbitrarily divided the clinical stages based on a combination of four laboratory parameters, including platelet counts, albumin levels, total bilirubin, and prothrombin time. The categories were defined according to PABC clinical staging: PABC-A exhibits normal values for the four parameters; PABC-B exhibits abnormal values for one or two biochemical parameter(s) in addition to abnormal platelet counts; and PABC-C exhibits abnormal values for all four laboratory parameters. Pearson's correlation coefficient was 0.933 for PABC-A (95%CI: 0.6061-0.9903; *P* = 0.0021), 0.822 for PABC-B (95%CI: 0.1822-0.9729; *P* = 0.0231), and 0.938 for PABC-C (95%CI: 0.5285-0.9933; *P* = 0.0057). PABC: Platelet-albumin-bilirubin-coagulation ability (prothrombin time).

positive HCC[37]. The HBeAg-positive rate inversely correlated with the number of key mutations (96.6%, 65.2%, 76.4%, 64.6%, 46.5%, 40.9%, 47.6%, 47.4%, and 12.5% for 0 to 8 mutations, respectively). However, the proportion of low-titer HBeAg in the 253 HBeAg-positive cases positively correlated with mutation numbers (7.1%, 13.3%, 21.4%, 25%, 42.6%, 44.4%, 65%, 100%, and 100% of the HBeAg-positive cases for 0 to 8 mutations, respectively). More than half of the 62 HBeAg-positive HCC cases were classified as low-titer HBeAg (HCC cases with low-titer HBeAg/total HBeAg-positive HCC cases for 0 to 8 mutations were 1/1, 0/0, 3/5, 5/10, 9/15, 5/10, 7/11, 9/9, and 1/1, respectively). Notably, HCC patients infected by wild-type or BCP double mutant HBV were exclusively low-titer HBeAg-positive. These data suggest that the quantity of HBeAg is associated with HBV-related hepatocarcinogenesis.

CONCLUSION

Although extracting useful data regarding *HBV* mutations in South Korea has been difficult, the present analyses demonstrate that HBV genotype C2 is a good model to investigate the significance of viral mutations. Based on our previous two studies, we proposed the following hypothesis: the presence of ⩾ 6 mutations is the most important viral factor in predictions of HCC risk in chronic HBV carriers infected by the BCP mutant virus (Figure 1). The number of mutations is positively correlated not only with advanced liver disease, but also with HCC independent of advanced liver disease (Figure 2). Although the eight key mutations can occur in various combinations, specific mutation combinations

Table 2 Comparison of hepatocellular carcinoma rate between low and high titers of hepatitis B e antigen in each mutation number group

Mutation number	HBeAg-positive rate		HCC rate			HBeAg < 35 or HBeAg-negative rate among HCCs % (No./total cases)	*P*-value[1]
	Total % (No./total cases)	HBeAg < 35 % (No./total cases)	HBeAg-positive HBeAg > 35 % (No./total cases)	HBeAg-positive HBeAg < 35 % (No./total cases)	HBeAg-negative % (No./total cases)		
0	96.6% (28/29)	7.1% (2/28)	0% (0/26)	50% (1/2)	0% (0/1)	100% (1/1)	-
1	65.2% (15/23)	13.3% (2/15)	0% (0/13)	0% (0/2)	25.0% (2/8)	100% (2/2)	-
2-1[2]	45.5% (5/11)	60.0% (3/5)	0% (0/2)	33.3% (1/3)	16.7% (1/6)	100% (2/2)	-
2-2[3]	84.1% (37/44)	16.2% (6/37)	6.5% (2/31)	33.3% (2/ 6)	28..6% (2/7)	66.7% (4/6)	0.0530
3	71.4% (60/84)	25.0% (15/60)	10.4% (5/48)	31.3% (5/16)	31.4% (11/35)	76.2% (16/21)	0.0137
4	48.5% (47/97)	42.6% (20/47)	22.2% (6/27)	45.0% (9/20)	38.9% (21/54)	83.3% (30/36)	0.1047
5	40.0% (26/65)	46.2% (12/26)	33.3% (5/15)	41.7% (5/12)	28.2% (11/39)	76.2% (16/21)	1.0000
6	46.2% (18/39)	66.7% (12/18)	57.1% (4/7)	53.8% (7/13)	50.0% (11/22)	81.8% (18/22)	1.0000
7	47.4% (9/19)	100% (9/9)	0% (0/9)	100% (9/9)	60.0% (6/10)	100% (15/15)	-
8	12.5% (1/8)	100% (1/1)	0% (0/1)	100% (1/1)	71.4% (5/7)	100% (6/6)	-

[1]Fisher's exact test for count data was carried out to compare the significance of HBeAg status in the prediction of HCC risk between HCC patients with HBeAg > 35 and with HBeAg < 35 or -negative. Low titer HBeAg or HBeAg-negativity is significantly predominant among HCC patients; [2]Only one of two mutations is A1762T or G1764A; [3]Basal core promoter double mutations (A1762T/G1764A). HCC: Hepatocellular carcinoma; HBeAg: Hepatitis B e antigen.

are predominant in the HCC group (Table 1). However, a low titer HBeAg (< 35 signal-to-noise ratio) is indicative of HCC risk for viruses containing ≤ 5 mutations or the BCP double mutation only (Table 2). Therefore, viral mutations and clinical features are complementary in the prediction of HCC risk.

REFERENCES

1 **Fattovich G**. Natural history and prognosis of hepatitis B. *Semin Liver Dis* 2003; **23**: 47-58 [PMID: 12616450 DOI: 10.1055/s-2003-37590]

2 **McMahon BJ**. The natural history of chronic hepatitis B virus infection. *Semin Liver Dis* 2004; **24** Suppl 1: 17-21 [PMID: 15192797 DOI: 10.1055/s-2004-828674]

3 **McMahon BJ**. The natural history of chronic hepatitis B virus infection. *Hepatology* 2009; **49**: S45-S55 [PMID: 19399792 DOI: 10.1002/hep.22898]

4 **Shi YH**, Shi CH. Molecular characteristics and stages of chronic hepatitis B virus infection. *World J Gastroenterol* 2009; **15**: 3099-3105 [PMID: 19575488 DOI: 10.3748/wjg.15.3099]

5 **Chung WK**, Moon SK, Popper H. Anicteric hepatitis in korea: comparative studies of asymptomatic and symptomatic series. *Gastroenterology* 1965; **48**: 1-11 [PMID: 14252750]

6 **Chung WK**. Chronic hepatitis in Korea. *Prog Liver Dis* 1986; **8**: 469-484 [PMID: 3520666]

7 **McMahon BJ**. Epidemiology and natural history of hepatitis B. *Semin Liver Dis* 2005; **25** Suppl 1: 3-8 [PMID: 16103976 DOI: 10.1055/s-2005-915644]

8 **Fattovich G**, Brollo L, Giustina G, Noventa F, Pontisso P, Alberti A, Realdi G, Ruol A. Natural history and prognostic factors for chronic hepatitis type B. *Gut* 1991; **32**: 294-298 [PMID: 2013423 DOI: 10.1136/gut.32.3.294]

9 **Chen TJ**, Liaw YF. The prognostic significance of bridging hepatic necrosis in chronic type B hepatitis: a histopathologic study. *Liver* 1988; **8**: 10-16 [PMID: 3367703 DOI: 10.1111/j.1600-0676.1988.tb00960.x]

10 **Lok AS**. Hepatitis B: liver fibrosis and hepatocellular carcinoma. *Gastroenterol Clin Biol* 2009; **33**: 911-915 [PMID: 19577871]

11 **Ohkubo K**, Kato Y, Ichikawa T, Kajiya Y, Takeda Y, Higashi S, Hamasaki K, Nakao K, Nakata K, Eguchi K. Viral load is a significant prognostic factor for hepatitis B virus-associated hepatocellular carcinoma. *Cancer* 2002; **94**: 2663-2668 [PMID: 12173334 DOI: 10.1002/cncr.10557]

12 **Lin CL**, Kao JH. Hepatitis B viral factors and clinical outcomes of chronic hepatitis B. *J Biomed Sci* 2008; **15**: 137-145 [PMID: 18058038 DOI: 10.1007/s11373-007-9225-8]

13 **Yeh CT**, So M, Ng J, Yang HW, Chang ML, Lai MW, Chen TC, Lin CY, Yeh TS, Lee WC. Hepatitis B virus-DNA level and basal core promoter A1762T/G1764A mutation in liver tissue independently predict postoperative survival in hepatocellular carcinoma. *Hepatology* 2010; **52**: 1922-1933 [PMID: 20814897 DOI: 10.1002/hep.23898]

14 **Chu CM**, Lin CC, Lin SM, Lin DY, Liaw YF. Viral load, genotypes, and mutants in hepatitis B virus-related hepatocellular carcinoma: special emphasis on patients with early hepatocellular carcinoma. *Dig Dis Sci* 2012; **57**: 232-238 [PMID: 21837473 DOI: 10.1007/s10620-011-1844-2]

15 **Huang YH**, Wu JC, Chang TT, Sheen IJ, Huo TI, Lee PC, Su CW, Lee SD. Association of core promoter/precore mutations and viral load in e antigen-negative chronic hepatitis B patients. *J Viral Hepat* 2006; **13**: 336-342 [PMID: 16637865 DOI: 10.1111/j.1365-2893.2005.00688.x]

16 **Liu CJ**, Chen PJ, Lai MY, Lin FY, Wang T, Kao JH, Chen DS. Viral factors correlate with hepatitis B e antigen seroconverson in patients with chronic hepatitis B. *Liver Int* 2006; **26**: 949-955 [PMID: 16953835 DOI: 10.1111/j.1478-3231.2006.01319.x]

17 **Tai DI**, Lin SM, Sheen IS, Chu CM, Lin DY, Liaw YF. Long-term outcome of hepatitis B e antigen-negative hepatitis B surface antigen carriers in relation to changes of alanine aminotransferase levels over time. *Hepatology* 2009; **49**: 1859-1867 [PMID: 19378345 DOI: 10.1002/hep.22878]

18 **Fang ZL**, Sabin CA, Dong BQ, Wei SC, Chen QY, Fang KX, Yang JY, Wang XY, Harrison TJ. The association of HBV core promoter double mutations (A1762T and G1764A) with viral load differs between HBeAg positive and anti-HBe positive individuals: a longitudinal analysis. *J Hepatol* 2009; **50**: 273-280 [PMID: 19070921 DOI: 10.1016/j.jhep.2008.09.014]

19 **Tacke F**, Gehrke C, Luedde T, Heim A, Manns MP, Trautwein C. Basal core promoter and precore mutations in the hepatitis B virus genome enhance replication efficacy of Lamivudine-resistant mutants. *J Virol* 2004; **78**: 8524-8535 [PMID: 15280461 DOI: 10.1128/JVI.78.16.8524-8535.2004]

20 **Yuen MF**, Tanaka Y, Shinkai N, Poon RT, But DY, Fong DY, Fung J, Wong DK, Yuen JC, Mizokami M, Lai CL. Risk for hepatocellular carcinoma with respect to hepatitis B virus genotypes B/C, specific mutations of enhancer II/core promoter/precore regions and HBV DNA levels. *Gut* 2008; **57**: 98-102 [PMID: 17483190]

21 **Herbers U**, Amini-Bavil-Olyaee S, Mueller A, Luedde T, Trautwein C, Tacke F. Hepatitis B e antigen-suppressing mutations enhance the replication efficiency of adefovir-resistant hepatitis B virus strains. *J Viral Hepat* 2013; **20**: 141-148

[PMID: 23301549 DOI: 10.1111/j.1365-2893.2012.01639.x]
22 **Lin CL**, Liao LY, Liu CJ, Chen PJ, Lai MY, Kao JH, Chen DS. Hepatitis B genotypes and precore/basal core promoter mutants in HBeAg-negative chronic hepatitis B. *J Gastroenterol* 2002; **37**: 283-287 [PMID: 11993512 DOI: 10.1007/s005350200036]
23 **Chan HL**, Hui AY, Wong ML, Tse AM, Hung LC, Wong VW, Sung JJ. Genotype C hepatitis B virus infection is associated with an increased risk of hepatocellular carcinoma. *Gut* 2004; **53**: 1494-1498 [PMID: 15361502 DOI: 10.1136/gut.2003.033324]
24 **Chu CM**, Lin CC, Chen YC, Jeng WJ, Lin SM, Liaw YF. Basal core promoter mutation is associated with progression to cirrhosis rather than hepatocellular carcinoma in chronic hepatitis B virus infection. *Br J Cancer* 2012; **107**: 2010-2015 [PMID: 23079574 DOI: 10.1038/bjc.2012.474]
25 **Pujol FH**, Navas MC, Hainaut P, Chemin I. Worldwide genetic diversity of HBV genotypes and risk of hepatocellular carcinoma. *Cancer Lett* 2009; **286**: 80-88 [PMID: 19683385 DOI: 10.1016/j.canlet.2009.07.013]
26 **McMahon BJ**. The influence of hepatitis B virus genotype and subgenotype on the natural history of chronic hepatitis B. *Hepatol Int* 2009; **3**: 334-342 [PMID: 19669359 DOI: 10.1007/s12072-008-9112-z]
27 **Yang HI**, Yeh SH, Chen PJ, Iloeje UH, Jen CL, Su J, Wang LY, Lu SN, You SL, Chen DS, Liaw YF, Chen CJ. Associations between hepatitis B virus genotype and mutants and the risk of hepatocellular carcinoma. *J Natl Cancer Inst* 2008; **100**: 1134-1143 [PMID: 18695135 DOI: 10.1093/jnci/djn243]
28 **Lee JM**, Ahn SH, Chang HY, Shin JE, Kim DY, Sim MK, Hong SP, Chung HJ, Kim SO, Han KH, Chon CY, Moon YM. [Reappraisal of HBV genotypes and clinical significance in Koreans using MALDI-TOF mass spectrometry]. *Korean J Hepatol* 2004; **10**: 260-270 [PMID: 15613801]
29 **Song BC**, Cui XJ, Kim H. Hepatitis B virus genotypes in Korea: an endemic area of hepatitis B virus infection. *Intervirology* 2005; **48**: 133-137 [PMID: 15812186]
30 **Kim H**, Jee YM, Song BC, Shin JW, Yang SH, Mun HS, Kim HJ, Oh EJ, Yoon JH, Kim YJ, Lee HS, Hwang ES, Cha CY, Kook YH, Kim BJ. Molecular epidemiology of hepatitis B virus (HBV) genotypes and serotypes in patients with chronic HBV infection in Korea. *Intervirology* 2007; **50**: 52-57 [PMID: 17164558]
31 **Cho JH**, Yoon KH, Lee KE, Park DS, Lee YJ, Moon HB, Lee KR, Choi CS, Cho EY, Kim HC. [Distribution of hepatitis B virus genotypes in Korea]. *Korean J Hepatol* 2009; **15**: 140-147 [PMID: 19581766]
32 **Kim JK**, Chang HY, Lee JM, Baatarkhuu O, Yoon YJ, Park JY, Kim do Y, Han KH, Chon CY, Ahn SH. Specific mutations in the enhancer II/core promoter/precore regions of hepatitis B virus subgenotype C2 in Korean patients with hepatocellular carcinoma. *J Med Virol* 2009; **81**: 1002-1008 [PMID: 19382267 DOI: 10.1002/jmv.21501]
33 **Jang JW**, Chun JY, Park YM, Shin SK, Yoo W, Kim SO, Hong SP. Mutational complex genotype of the hepatitis B virus X/precore regions as a novel predictive marker for hepatocellular carcinoma. *Cancer Sci* 2012; **103**: 296-304 [PMID: 22136288 DOI: 10.1111/j.1349-7006.2011.02170.x]
34 **Park YM**, Kim BS, Tabor E. Precore codon 28 stop mutation in hepatitis B virus from patients with hepatocellular carcinoma. *Korean J Intern Med* 1997; **12**: 201-207 [PMID: 9439156]
35 **Cho SW**, Shin YJ, Hahm KB, Jin JH, Kim YS, Kim JH, Kim HJ. Analysis of the precore and core promoter DNA sequence in liver tissues from patients with hepatocellular carcinoma. *J Korean Med Sci* 1999; **14**: 424-430 [PMID: 10485623 DOI: 10.3346/jkms.1999.14.4.424]
36 **Lok AS**, Akarca U, Greene S. Mutations in the pre-core region of hepatitis B virus serve to enhance the stability of the secondary structure of the pre-genome encapsidation signal. *Proc Natl Acad Sci USA* 1994; **91**: 4077-4081 [PMID: 8171038 DOI: 10.1073/pnas.91.9.4077]
37 **Park YM**, Jang JW, Yoo SH, Kim SH, Oh IM, Park SJ, Jang YS, Lee SJ. Combinations of eight key mutations in the X/preC region and genomic activity of hepatitis B virus are associated with hepatocellular carcinoma. *J Viral Hepat* 2014; **21**: 171-177 [PMID: 24344773 DOI: 10.1111/jvh.12134]
38 **Tong SP**, Li JS, Vitvitski L, Trépo C. Replication capacities of natural and artificial precore stop codon mutants of hepatitis B virus: relevance of pregenome encapsidation signal. *Virology* 1992; **191**: 237-245 [PMID: 1413504 DOI: 10.1016/0042-6822(92)90185-R]
39 **Liu CJ**, Jeng YM, Chen CL, Cheng HR, Chen PJ, Chen TC, Liu CH, Lai MY, Chen DS, Kao JH. Hepatitis B virus basal core promoter mutation and DNA load correlate with expression of hepatitis B core antigen in patients with chronic hepatitis B. *J Infect Dis* 2009; **199**: 742-749 [PMID: 19199543 DOI: 10.1086/596655]
40 **Lee JH**, Han KH, Lee JM, Park JH, Kim HS. Impact of hepatitis B virus (HBV) x gene mutations on hepatocellular carcinoma development in chronic HBV infection. *Clin Vaccine Immunol* 2011; **18**: 914-921 [PMID: 21490166 DOI: 10.1128/CVI.00474-10]
41 **Yu X**, Mertz JE. Promoters for synthesis of the pre-C and pregenomic mRNAs of human hepatitis B virus are genetically distinct and differentially regulated. *J Virol* 1996; **70**: 8719-8726 [PMID: 8970999]
42 **Cui XJ**, Cho YK, Song HJ, Choi EK, Kim HU, Song BC. Molecular characteristics and functional analysis of full-length hepatitis B virus quasispecies from a patient with chronic hepatitis B virus infection. *Virus Res* 2010; **150**: 43-48 [PMID: 20184927]
43 **Liu S**, Zhang H, Gu C, Yin J, He Y, Xie J, Cao G. Associations between hepatitis B virus mutations and the risk of hepatocellular carcinoma: a meta-analysis. *J Natl Cancer Inst* 2009; **101**: 1066-1082 [PMID: 19574418]
44 **Takahashi K**, Akahane Y, Hino K, Ohta Y, Mishiro S. Hepatitis B virus genomic sequence in the circulation of hepatocellular carcinoma patients: comparative analysis of 40 full-length isolates. *Arch Virol* 1998; **143**: 2313-2326 [PMID: 9930189 DOI: 10.1007/s007050050463]
45 **Tangkijvanich P**, Sa-Nguanmoo P, Mahachai V, Theamboonlers A, Poovorawan Y. A case-control study on sequence variations in the enhancer II/core promoter/precore and X genes of hepatitis B virus in patients with hepatocellular carcinoma. *Hepatol Int* 2010; **4**: 577-584 [PMID: 21063480 DOI: 10.1007/s12072-010-9197-z]
46 **Yin J**, Xie J, Liu S, Zhang H, Han L, Lu W, Shen Q, Xu G, Dong H, Shen J, Zhang J, Han J, Wang L, Liu Y, Wang F, Zhao J, Zhang Q, Ni W, Wang H, Cao G. Association between the various mutations in viral core promoter region to different stages of hepatitis B, ranging of asymptomatic carrier state to hepatocellular carcinoma. *Am J Gastroenterol* 2011; **106**: 81-92 [PMID: 20959817]
47 **Cho EY**, Choi CS, Cho JH, Kim HC. Association between Hepatitis B Virus X Gene Mutations and Clinical Status in Patients with Chronic Hepatitis B Infection. *Gut Liver* 2011; **5**: 70-76 [PMID: 21461076 DOI: 10.5009/gnl.2011.5.1.70]
48 **Ouneissa R**, Bahri O, Alaya-Bouafif NB, Chouaieb S, Ben Yahia A, Sadraoui A, Hammami W, Filali N, Azzouz MM, Mami NB, Triki H. Frequency and clinical significance of core promoter and precore region mutations in Tunisian patients infected chronically with hepatitis B. *J Med Virol* 2012; **84**: 1719-1726 [PMID: 22997074 DOI: 10.1002/jmv.23394]
49 **Tatsukawa M**, Takaki A, Shiraha H, Koike K, Iwasaki Y, Kobashi H, Fujioka S, Sakaguchi K, Yamamoto K. Hepatitis B virus core promoter mutations G1613A and C1653T are significantly associated with hepatocellular carcinoma in genotype C HBV-infected patients. *BMC Cancer* 2011; **11**: 458 [PMID: 22014121]
50 **Kitab B**, Essaid El Feydi A, Afifi R, Trepo C, Benazzouz M, Essamri W, Zoulim F, Chemin I, Alj HS, Ezzikouri S,

Benjelloun S. Variability in the precore and core promoter regions of HBV strains in Morocco: characterization and impact on liver disease progression. *PLoS One* 2012; **7**: e42891 [PMID: 22905181 DOI: 10.1371/journal.pone.0042891]

51 **Chen CH**, Hung CH, Lee CM, Hu TH, Wang JH, Wang JC, Lu SN, Changchien CS. Pre-S deletion and complex mutations of hepatitis B virus related to advanced liver disease in HBeAg-negative patients. *Gastroenterology* 2007; **133**: 1466-1474 [PMID: 17915220 DOI: 10.1053/j.gastro.2007.09.002]

52 **Thompson AJ**, Nguyen T, Iser D, Ayres A, Jackson K, Littlejohn M, Slavin J, Bowden S, Gane EJ, Abbott W, Lau GK, Lewin SR, Visvanathan K, Desmond PV, Locarnini SA. Serum hepatitis B surface antigen and hepatitis B e antigen titers: disease phase influences correlation with viral load and intrahepatic hepatitis B virus markers. *Hepatology* 2010; **51**: 1933-1944 [PMID: 20512987 DOI: 10.1002/hep.23571]

P- Reviewer: Bellanti F, Vespasiani-Gentilucci U, Wang SK
S- Editor: Tian YL **L- Editor**: Webster JR **E- Editor**: Liu SQ

World Journal of Hepatology

Submit a Manuscript: http://www.wjgnet.com/esps/
Help Desk: http://www.wjgnet.com/esps/helpdesk.aspx
DOI: 10.4254/wjh.v7.i1.121

World J Hepatol 2015 January 27; 7(1): 121-126
ISSN 1948-5182 (online)

MINIREVIEWS

HBV and HIV co-infection: Impact on liver pathobiology and therapeutic approaches

Mohammad Khalid Parvez

Mohammad Khalid Parvez, Department of Pharmacognosy, King Saud University College of Pharmacy, Riyadh 11451, Saudi Arabia
Author contributions: The author contributed solely to this work.

Correspondence to: Mohammad Khalid Parvez, PhD, Assistant Professor, Department of Pharmacognosy, King Saud University College of Pharmacy, PO Box 2457, Riyadh 11451, Saudi Arabia. khalid_parvez@yahoo.com
Telephone: +966-1-4675132
Fax: +966-1-4677254
Received: July 16, 2014
Peer-review started: July 17, 2014
First decision: July 29, 2014
Revised: August 15, 2014
Accepted: November 7, 2014
Article in press: November 10, 2014
Published online: January 27, 2015

Abstract

The consequences of hepatitis B virus (HBV) and human immunodeficiency virus (HIV) co-infection on progression of severe liver diseases is a serious public health issue, worldwide. In the co-infection cases, about 90% of HIV-infected population is seropositive for HBV where approximately 5%-40% individuals are chronically infected. In HIV co-infected individuals, liver-related mortality is estimated over 17 times higher than those with HBV mono-infection. The spectrum of HIV-induced liver diseases includes hepatitis, steatohepatitis, endothelialitis, necrosis, granulomatosis, cirrhosis and carcinoma. Moreover, HIV co-infection significantly alters the natural history of hepatitis B, and therefore complicates the disease management. Though several studies have demonstrated impact of HIV proteins on hepatocyte biology, only a few data is available on interactions between HBV and HIV proteins. Thus, the clinical spectrum as well as the complexity of the co-infection offers challenging fronts to study the underlying molecular mechanisms, and to design effective therapeutic strategies.

Key words: Hepatitis B virus; Human immunodeficiency virus; Human immunodeficiency virus-hepatotropism; Hepatitis B virus and human immunodeficiency virus co-infection; Chronic hepatitis B; Hepatopathogenesis

Core tip: The consequences of hepatitis B virus (HBV) and human immunodeficiency virus (HIV) co-infection on progression of severe liver diseases is a serious public health issue, worldwide. In HIV co-infected individuals, liver-related mortality is estimated over 17 times higher than those with HBV mono-infection. HIV co-infection significantly alters the natural history of hepatitis B, and therefore complicates the disease management. Thus, the clinical spectrum as well as the complexity of the HBV and HIV co-infection of liver offers challenging fronts to study the underlying molecular mechanisms, and to design effective therapeutic strategies.

Parvez MK. HBV and HIV co-infection: Impact on liver pathobiology and therapeutic approaches. *World J Hepatol* 2015; 7(1): 121-126 Available from: URL: http://www.wjgnet.com/1948-5182/full/v7/i1/121.htm DOI: http://dx.doi.org/10.4254/wjh.v7.i1.121

INTRODUCTION

Although inherently a non-hepatotropic virus, a direct cytopathic effect of human immunodeficiency virus-1 (HIV) on liver, independent of retroviral drug-toxicity or viral hepatitis is known, today. HIV co-infection with hepatitis B virus (HBV), and the consequences on progression of severe liver diseases further pose a serious health issue. HIV alone, infects nearly 40 million individuals leading to about 5% cases of mortality while HBV circulates in > 400 million persons causing about one million deaths, annually worldwide[1,2]. In the co-infection cases, approximately 90% of HIV-infected individuals have serological markers of HBV and approximately 5%-40% of them are clinically chronic[3,4]. As a consequence, HBV co-infection persists in almost 25% of HIV-infected adults and approximately 50%-90% of them acquire it at birth or in early age[5].

In HIV-infected patients, the CD4-independant tissue tropism, including liver and its impact on hepato-pathogenesis is well established[6]. The spectrum of HIV-induced liver diseases includes hepatitis, alcohol-associated steatohepatitis, non-alcoholic steatohepatitis, endothelialitis, necrosis and granulomatosis[7]. Moreover, HIV co-infection leads to further complications in liver diseases compared to HBV mono-infection[8]. It is found that in HIV co-infected individuals, liver-related mortality is over 17 times higher than those infected with HBV, alone[2]. Also, with the introduction of "highly active anti-retroviral therapy (HAART)" in high HBV endemic areas, greater chances of progressive liver diseases is expected in the HIV co-infected individuals[9]. Moreover, HIV co-infection severely alters the natural history of hepatitis B[9]. As a result, management of chronic hepatitis B is hampered by the late and/or improper diagnosis as well as by effectiveness of nucleos(t)ide-based anti-viral therapy, and risks of emergence of drug-resistance. While it is very rare for HBV, transmittance of drug resistant-mutants accounts for up to 15% of new HIV infections[10,11].

HIV-HEPATOTROPISM

HIV infection requires interaction of the viral envelop protein (gp^{120}) with cell surface receptor, CD4, aided by chemokine co-receptors, CCR5 and CXCR4[12,13]. While some HIV strains also require both of these co-receptors, few rare laboratory-adapted isolates are shown to utilize alternative co-receptors like, CCR1, CCR2b, CCR8, CXCR6, GPR1 and GPR15/Bob, *in vitro*[14]. Ample of reports has demonstrated cross-tissue tropism of HIV capable of infecting a variety of non-lymphoid tissues *in vivo*[15]. Further, HIV RNA, proviral-deoxyribonucleic acid (DNA) and capsid antigen (p^{24}) have been detected in liver sinusoidal endothelial cells, Kupffer cells, portal mononuclear inflammatory cells as well as hepatocytes of infected patients (Figure 1)[16]. Very interestingly, Iser *et al*[17] have recently demonstrated the indispensability of CCR5 and CXCR4 in HIV entry into multiple liver cell lines. Nevertheless, the limited sensitiveness of the techniques employed as well as the sub-detectable levels of CD4 after several passages of cultured cells, cannot rule out the possibility of CD4 expressions on these cells. Therefore, in HIV-positive patients, the retroviral CD4 receptor-independent entry of hepatocytes still remains controversial. Nevertheless, another possibility of HIV to utilize an alternative liver-specific receptor is recently described[18].

CO-INFECTION AND SEVERITY OF LIVER PATHOGENESIS

The spectrum of HIV-induced liver diseases includes hepatitis, alcohol-associated steatohepatitis, non-alcoholic steatohepatitis, endothelialitis, necrosis and granulomatosis[7,19]. The consequences of HIV mono-infection is also linked to liver portal obliteration with nodular regenerative hyperplasia, responsible for non-cirrhotic portal hypertension[20,21]. In adult-acquired HBV infected individuals, the secondary infection with HIV leads to the chances of developing chronic hepatitis B by six-fold compared to HBV mono-infected patients[22,23]. Furthermore, in co-infection cases, HIV severely alters the natural history of hepatitis B[3,24]. HIV co-infection significantly decreases the rate of hepatitis B e antigen (HBeAg) clearance up to five-fold and increases the level of HBV replication[9,25]. Even co-infected persons who seroconvert to protective antibody to hepatitis B surface antigen (HBsAg) [anti-hepatitis B surface antibody (HBsAb)], remain at risk of reverse-seroconversion, and subsequent reactivation of HBV[26,27]. Also, while liver cirrhosis is more common in cases of HBV and HIV co-infections, a more severe progression and complexity in the development of hepatocellular carcinoma (HCC) is also reported[28].

UNDERLYING MECHANISMS

Though the high HBV episomal DNA (cccDNA) accumulations are predictive of elevated hepatotoxicity and contrarily, the lower alanine amino transaminase (ALT) levels presenting less hepatic injury; the underlying mechanisms of HIV-induced liver pathology is largely unknown. Moreover, HBV core (C)/precore (pre-C) genetic variants, which can be more common in HIV co-infected individuals, are also suggested in disease progression[29,30]. In a closely related clinical study of HIV and hepatitis C virus co-infection cases, liver cirrhosis was found associated with higher systemic markers of gut-microbial translocation[31] that could be also true for HBV. Further, the activation of HBV-specific $CD8^+$ cells, crucial in controlling HBV replication as well as the liver pathogenesis[32], is shown to be clearly impaired during HIV secondary infection. This might partially explain the tendency of progression of acute hepatitis B towards chronicity in HIV co-infection cases[33]. In co-infected patients with lower ALT levels compared to HBV mono-

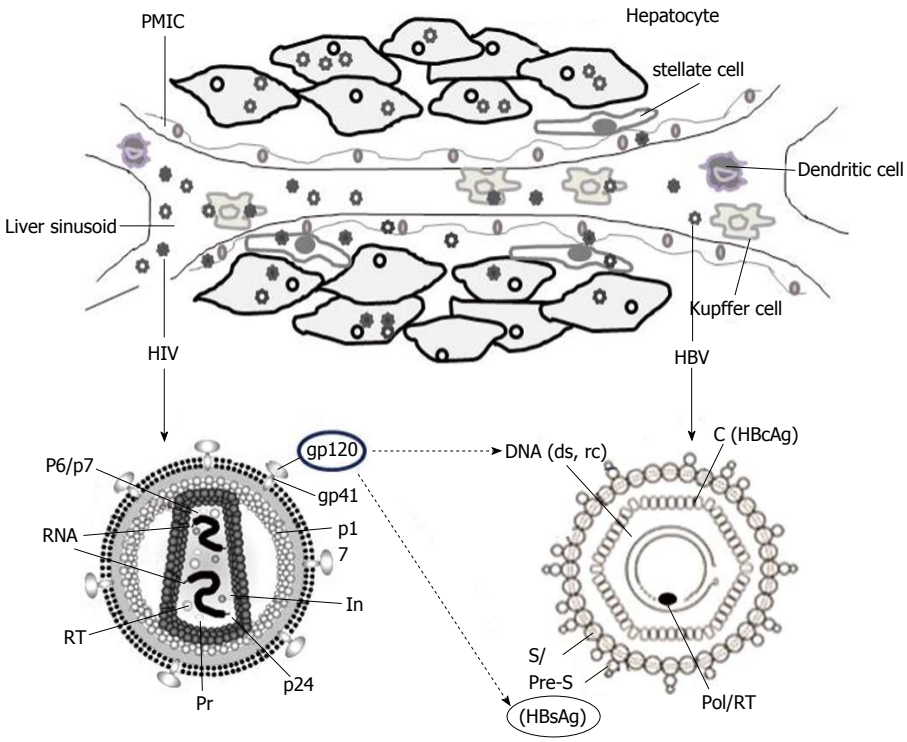

Figure 1 A cartoon depiction of hepatitis B virus and human immunodeficiency virus co-infection of liver. Intracellular locations of the two viruses in hepatocytes, liver sinusoidal endothelial cells, Kupffer cells, portal mononuclear inflammatory cells, stellate cells, dendritic cells and Kupffer cells are shown (upper panel). The structural and genomic organizations of HIV and HBV indicating the probable trans-regulation of HBV-DNA and HBsAg by HIVgp120 (lower panel). PMIC: Portal mononuclear inflammatory cell; HIV: Human immunodeficiency virus; HBV: Hepatitis B virus; DNA: Deoxyribonucleic acid; HBsAg: Hepatitis B surface antigen; HBcAg: Hepatitis B core antigen; RT: HIV reverse-transcriptase.

infection, the progression of cirrhosis and HCC is suggested to be related to lower $CD4^+$ cell counts[34,35]. In addition to higher levels of HBV DNA and lower rates of spontaneous HBeAg seroconversion, severe flares of hepatitis can occur in HIV co-infected patients with low $CD4^+$ counts who experience immune reconstitution after initiation of HAART[36]. Clinical studies in HBV and HIV co-infected patients have reported lower response rates to standard interferon (IFN)-α treatment than those with HBV mono-infection[34]. Responders tend to have a higher mean $CD4^+$ cell count than nonresponders. It is expected that pegIFN-α will have similar or better efficacy than standard IFN-α. However, a detailed study of the mechanisms underlying adaptive immune responses in such cases is not available.

Furthermore, the CCR5 and CXCR4 co-receptors of hepatocytes as well as stellate cells are reported to involve in fibrogenic developments[36]. Very recently, the viral gp^{120} has been demonstrated to modulate hepatic chemokine receptors as well as stellate cell biology, and linked to liver fibrogenesis[37,38]. The gp^{120} binding of hepatic CXCR4 is also reported to up-regulate tumor necrosis factor-related TRAIL-R2 expression in apoptosing hepatocytes[39]. Another protein "R" of HIV is shown to modulate host transcription factors, like peroxisome proliferator-activated receptor-γ, crucial in lipid metabolism, insulin sensitivity, inflammatory processes and fibrogenesis[40].

Though several studies have demonstrated impact of HIV proteins on hepatocyte biology[20,37-40], only a few data is available on viral interactions, *i.e.*, between HBV and HIV proteins (Figure 1). In the co-infection situation, the co-synthesized proteins of the two viruses might compete for host machinery involved in virion secretion pathways[41,42]. In *ex vivo* experimental set-up, the high retention of intrahepatic HBsAg had indicated its enhanced production or impaired secretion in the culture supernatant[43]. Moreover, in co-infected patients, exertion of gp^{120} on elevations and intracellular accumulation of HBV, DNA as well as HBsAg is proposed (Figure 1) to cause hepatotoxicity. In a clinical study, association of HBV and HIV co-infection with higher levels of HBV DNA has suggested that factors other than a direct virus-virus interaction might contribute to the increased HBV DNA levels[9]. While it has been shown that the HBV-X protein acts in alliance with HIV-tat in facilitating HIV replication[44], the synergistic effect of tat, if any, on HBV life cycle is not known.

DIAGNOSTIC AND THERAPEUTIC CHALLENGES

The primary objective of hepatitis B treatment in HIV co-infection cases is to suppress HBV viral replication and minimize progressive liver damage. Notably, in co-infected patients, HIV severely alters the natural history of hepatitis B and therefore, complicates the diagnosis

and disease management. HBsAg seronegativity and anti-HBsAb seroconversion that indicate resolution of active hepatitis B, are uncommon in HIV co-infection. Further, spontaneous reverse-seroconversion of anti-HBsAb can also occur in some co-infected patients and therefore, isolated anti-HBcAb test is recommended[45]. Since co-infected patients can have high levels of HBV DNA and hepatic necroinflammation with anti-HBc but not HBsAg, it is advised to test for both seromarkers first, and if either is positive, to test for HBV DNA[46].

Although, there is a limited therapeutic options for the treatment of chronic HBV, nearly twenty five approved drugs belonging to six classes [nucleos(t)ide RT-, protease-, nonnucleos(t)ide RT-, fusion-, integrase-, and CCR5-inhibitors] are available for HIV. In the co-infected individuals, the design of therapeutic regimens, like HAART are therefore, recommended to minimize the risk of hepatotoxicity. Also, due to association of continued anti-retroviral drug therapy with liver fibrogenesis and toxicity, it is prescribed for the necessity of balancing potential toxic effects with the need for increasing the $CD4^+$ cell counts to control the two viruses[47]. Moreover, due to the resistance of highly stable, nuclear cccDNA to the currently available nucleos(t)ide analogs (*e.g.*, Lamivudine, Adefovir, Emtricitabine, Tenofovir, *etc.*), a complete elimination of HBV has not been achieved. HBV therapy is recommended for all co-infected patients with abnormal aminotransferase values or HBV DNA levels of > 2000 IU/mL. Patients with an indication for HBV treatment should be started on fully active anti-retroviral regimen that contains nucleos(t)ide analogues, regardless of the CD4 cell count, to ensure that HIV is not partially treated[48]. Unlike in HBV mono-infection cases, combinatorial treatment with pegylated-Interferon plus Adefovir (preferred over Lamivudine resistance) has not led to any success in HIV co-infected individuals[49]. Further, because Entecavir can result in emergence of drug-resistant HIV muatants, its use is restricted in co-infected patients who are on a suppressive HIV regimen[50,51]. Although, Tenofovir is the most commonly used anti-viral analog in the co-infected patients, a few studies have examined the development of resistance in HIV as well as HBV. Since, in a proportion of Tenofovir treated patients, an undetectable serum HBV DNA still circulates, Tenofovir in combination with Emtricitabine is being preferred against the two viruses[52].

Though Lamivudine, Emtricitabine and Tenofovir are efficacious against both HBV and HIV, the rate of viral cross-resistance to Lamivudine, for example, in co-infected patients is high, reaching up to 90% at 4 years[53]. In view of this, the American Association of Study of Liver Diseases has the following guidelines for treatment of patients with HBV and HIV co-infection[54]: (1) Patients who meet criteria for chronic hepatitis B should be treated, and liver biopsy should be considered in those with fluctuating or mildly elevations in liver enzymes; (2) patients in whom treatment for both HBV and HIV is planned should receive therapies that are effective against both viruses-Lamivudine plus Tenofovir or Emtricitabine plus Tenofovir are preferred; (3) in co-infected patients with Lamivudine cross-resistance, Tenofovir or Adefovir should be added; and (4) when HAART regimens are altered, drug(s) that are effective against HBV should not be discontinued without substituting another drug that has activity against HBV, unless the patient has achieved anti-HBeAg seroconversion and has completed the prescribed course of treatment.

Furthermore, patients with HIV co-infection are less likely to develop protective HBsAb after HBV vaccination. Nevertheless, all HIV co-infected patients with serum HBsAb negativity and HBsAg positivity should be vaccinated for HBV[51,52]. Although low CD4 cell counts are associated with an impaired response to vaccination, HBV vaccination should not be deferred for patients with advanced HIV, as some individuals do develop protective antibody titers despite low CD4 cell counts. If feasible, it is recommended to vaccinate individuals with CD4 cell counts > 200/μL because response to vaccine is poor below this level. On the other hand, those with less CD4 counts should receive HAART first and HBV vaccine later when CD4 counts rise above 200/μL[55]. The patient's HBsAb titre should be checked 1-2 mo post-vaccination, and re-vaccination should be considered for those who have not attained protective titers (⩾ 10 IU/L)[47,56].

CONCLUSION

Co-infection of HBV and HIV, and the consequences on progression of severe liver diseases is a global public health issue. Despite the availability of extensive clinical data on the subject, the mechanisms of progressive hepatopathogenesis still remain inconclusive. The complexity of clinical manifestations in HBV and HIV co-infection cases therefore, offers challenging fronts to understand the basic pathobiology, and to formulate effective therapeutic strategies.

ACKNOWLEDGMENTS

The author is very grateful to Dr. Jameel S (Welcome Trust-India Alliance, India) for his continued mentoring and support. Also, the author is thankful to Dr. Gallo R (Institute of Human Virology, Baltimore, United States) for giving opportunity to work on HIV pathobiology.

REFERENCES

1 **Thio CL**. Hepatitis B and human immunodeficiency virus coinfection. *Hepatology* 2009; **49**: S138-S145 [PMID: 19399813 DOI: 10.1002/hep.22883]

2 **Sun HY**, Sheng WH, Tsai MS, Lee KY, Chang SY, Hung CC. Hepatitis B virus coinfection in human immunodeficiency virus-infected patients: a review. *World J Gastroenterol* 2014; **20**: 14598-14614 [PMID: 25356024]

3 **Thio CL**, Smeaton L, Saulynas M, Hwang H, Saravanan S, Kulkarni S, Hakim J, Nyirenda M, Iqbal HS, Lalloo UG, Mehta AS, Hollabaugh K, Campbell TB, Lockman S,

Currier JS. Characterization of HIV-HBV coinfection in a multinational HIV-infected cohort. *AIDS* 2013; **27**: 191-201 [PMID: 23032418 DOI: 10.1097/QAD.0b013e32835a9984]
4 **McGovern BH**. The epidemiology, natural history and prevention of hepatitis B: implications of HIV coinfection. *Antivir Ther* 2007; **12** Suppl 3: H3-13 [PMID: 18284178]
5 **Yim HJ**, Lok AS. Natural history of chronic hepatitis B virus infection: what we knew in 1981 and what we know in 2005. *Hepatology* 2006; **43**: S173-S181 [PMID: 16447285 DOI: 10.1002/hep.20956]
6 **Parvez MK**. HIV heaptotropism and pathogenesis: new challenges. *Fut Virol* 2013; **8**: 1-3 [DOI: 10.2217/FVL.13.12]
7 **Bongiovanni M**, Tordato F. Steatohepatitis in HIV-infected subjects: pathogenesis, clinical impact and implications in clinical management. *Curr HIV Res* 2007; **5**: 490-498 [PMID: 17896969 DOI: 10.2174/157016207781662407]
8 **Thio CL**, Seaberg EC, Skolasky R, Phair J, Visscher B, Muñoz A, Thomas DL. HIV-1, hepatitis B virus, and risk of liver-related mortality in the Multicenter Cohort Study (MACS). *Lancet* 2002; **360**: 1921-1926 [PMID: 12493258 DOI: 10.1016/S0140-6736(02)11913-1]
9 **Chun HM**, Mesner O, Thio CL, Bebu I, Macalino G, Agan BK, Bradley WP, Malia J, Peel SA, Jagodzinski LL, Weintrob AC, Ganesan A, Bavaro M, Maguire JD, Landrum ML. HIV outcomes in Hepatitis B virus coinfected individuals on HAART. *J Acquir Immune Defic Syndr* 2014; **66**: 197-205 [PMID: 24694929 DOI: 10.1097/QAI.0000000000000142]
10 **Geretti AM**. Epidemiology of antiretroviral drug resistance in drug-naïve persons. *Curr Opin Infect Dis* 2007; **20**: 22-32 [PMID: 17197878]
11 **Margeridon-Thermet S**, Shafer RW. Comparison of the Mechanisms of Drug Resistance among HIV, Hepatitis B, and Hepatitis C. *Viruses* 2010; **2**: 2696-2739 [PMID: 21243082 DOI: 10.3390/v2122696]
12 **Berger EA**, Murphy PM, Farber JM. Chemokine receptors as HIV-1 coreceptors: roles in viral entry, tropism, and disease. *Annu Rev Immunol* 1999; **17**: 657-700 [PMID: 10358771 DOI: 10.1146/annurev.immunol.17.1.657]
13 **Dalgleish AG**, Beverley PC, Clapham PR, Crawford DH, Greaves MF, Weiss RA. The CD4 (T4) antigen is an essential component of the receptor for the AIDS retrovirus. *Nature* 1984; **312**: 763-767 [PMID: 6096719]
14 **Berger EA**, Doms RW, Fenyö EM, Korber BT, Littman DR, Moore JP, Sattentau QJ, Schuitemaker H, Sodroski J, Weiss RA. A new classification for HIV-1. *Nature* 1998; **391**: 240 [PMID: 9440686 DOI: 10.1038/34571]
15 **Cao YZ**, Friedman-Kien AE, Huang YX, Li XL, Mirabile M, Moudgil T, Zucker-Franklin D, Ho DD. CD4-independent, productive human immunodeficiency virus type 1 infection of hepatoma cell lines in vitro. *J Virol* 1990; **64**: 2553-2559 [PMID: 2159530]
16 **Cao YZ**, Dieterich D, Thomas PA, Huang YX, Mirabile M, Ho DD. Identification and quantitation of HIV-1 in the liver of patients with AIDS. *AIDS* 1992; **6**: 65-70 [PMID: 1543567]
17 **Iser DM**, Warner N, Revill PA, Solomon A, Wightman F, Saleh S, Crane M, Cameron PU, Bowden S, Nguyen T, Pereira CF, Desmond PV, Locarnini SA, Lewin SR. Coinfection of hepatic cell lines with human immunodeficiency virus and hepatitis B virus leads to an increase in intracellular hepatitis B surface antigen. *J Virol* 2010; **84**: 5860-5867 [PMID: 20357083 DOI: 10.1128/JVI.02594-09]
18 **Fromentin R**, Tardif MR, Tremblay MJ. Human hepatoma cells transmit surface bound HIV-1 to CD4+ T cells through an ICAM-1/LFA-1-dependent mechanism. *Virology* 2010; **398**: 168-175 [PMID: 20034651 DOI: 10.1016/j.virol.2009.12.008]
19 **Waisman J**, Rotterdam H, Niedt GN, Lewin K, Racz P. AIDS: an overview of the pathology. *Pathol Res Pract* 1987; **182**: 729-754 [PMID: 2830602 DOI: 10.1016/S0344-0338(87)80039-0]
20 **Mallet VO**, Varthaman A, Lasne D, Viard JP, Gouya H, Borgel D, Lacroix-Desmazes S, Pol S. Acquired protein S deficiency leads to obliterative portal venopathy and to compensatory nodular regenerative hyperplasia in HIV-infected patients. *AIDS* 2009; **23**: 1511-1518 [PMID: 19512859 DOI: 10.1097/QAD.0b013e32832bfa51]
21 **Vispo E**, Morello J, Rodriguez-Novoa S, Soriano V. Non-cirrhotic portal hypertension in HIV infection. *Curr Opin Infect Dis* 2011; **24**: 12-18 [PMID: 21157331 DOI: 10.1097/QCO.0b013e3283420f08]
22 **Bodsworth NJ**, Cooper DA, Donovan B. The influence of human immunodeficiency virus type 1 infection on the development of the hepatitis B virus carrier state. *J Infect Dis* 1991; **163**: 1138-1140 [PMID: 2019762]
23 **Hadler SC**, Judson FN, O'Malley PM, Altman NL, Penley K, Buchbinder S, Schable CA, Coleman PJ, Ostrow DN, Francis DP. Outcome of hepatitis B virus infection in homosexual men and its relation to prior human immunodeficiency virus infection. *J Infect Dis* 1991; **163**: 454-459 [PMID: 1825315]
24 **Thio CL**. Hepatitis B in the human immunodeficiency virus-infected patient: epidemiology, natural history, and treatment. *Semin Liver Dis* 2003; **23**: 125-136 [PMID: 12800066 DOI: 10.1055/s-2003-39951]
25 **Gilson RJ**, Hawkins AE, Beecham MR, Ross E, Waite J, Briggs M, McNally T, Kelly GE, Tedder RS, Weller IV. Interactions between HIV and hepatitis B virus in homosexual men: effects on the natural history of infection. *AIDS* 1997; **11**: 597-606 [PMID: 9108941]
26 **Biggar RJ**, Goedert JJ, Hoofnagle J. Accelerated loss of antibody to hepatitis B surface antigen among immunodeficient homosexual men infected with HIV. *N Engl J Med* 1987; **316**: 630-631 [PMID: 3807959 DOI: 10.1056/NEJM198703053161015]
27 **Laukamm-Josten U**, Müller O, Bienzle U, Feldmeier H, Uy A, Guggenmoos-Holzmann I. Decline of naturally acquired antibodies to hepatitis B surface antigen in HIV-1 infected homosexual men. *AIDS* 1988; **2**: 400-401 [PMID: 3146272]
28 **Salmon-Ceron D**, Rosenthal E, Lewden C, Bouteloup V, May T, Burty C, Bonnet F, Costagliola D, Jougla E, Semaille C, Morlat P, Cacoub P, Chêne G. Emerging role of hepatocellular carcinoma among liver-related causes of deaths in HIV-infected patients: The French national Mortalité 2005 study. *J Hepatol* 2009; **50**: 736-745 [PMID: 19231018 DOI: 10.1016/j.jhep.2008.11.018]
29 **Revill PA**, Littlejohn M, Ayres A, Yuen L, Colledge D, Bartholomeusz A, Sasaduesz J, Lewin SR, Dore GJ, Matthews GV, Thio CL, Locarnini SA. Identification of a novel hepatitis B virus precore/core deletion mutant in HIV/hepatitis B virus co-infected individuals. *AIDS* 2007; **21**: 1701-1710 [PMID: 17690567]
30 **Warner N**, Locarnini S. The antiviral drug selected hepatitis B virus rtA181T/sW172* mutant has a dominant negative secretion defect and alters the typical profile of viral rebound. *Hepatology* 2008; **48**: 88-98 [PMID: 18537180 DOI: 10.1002/hep.22295]
31 **Balagopal A**, Philp FH, Astemborski J, Block TM, Mehta A, Long R, Kirk GD, Mehta SH, Cox AL, Thomas DL, Ray SC. Human immunodeficiency virus-related microbial translocation and progression of hepatitis C. *Gastroenterology* 2008; **135**: 226-233 [PMID: 18457674 DOI: 10.1053/j.gastro.2008.03.022]
32 **Chang JJ**, Sirivichayakul S, Avihingsanon A, Thompson AJ, Revill P, Iser D, Slavin J, Buranapraditkun S, Marks P, Matthews G, Cooper DA, Kent SJ, Cameron PU, Sasadeusz J, Desmond P, Locarnini S, Dore GJ, Ruxrungtham K, Lewin SR. Impaired quality of the hepatitis B virus (HBV)-specific T-cell response in human immunodeficiency virus type 1-HBV coinfection. *J Virol* 2009; **83**: 7649-7658 [PMID: 19458009 DOI: 10.1128/JVI.00183-09]
33 **Thimme R**, Wieland S, Steiger C, Ghrayeb J, Reimann KA, Purcell RH, Chisari FV. CD8(+) T cells mediate viral

clearance and disease pathogenesis during acute hepatitis B virus infection. *J Virol* 2003; **77**: 68-76 [PMID: 12477811 DOI: 10.1128/JVI.77.1.68-76.2003]

34 **Di Martino V**, Thevenot T, Colin JF, Boyer N, Martinot M, Degos F, Coulaud JP, Vilde JL, Vachon F, Degott C, Valla D, Marcellin P. Influence of HIV infection on the response to interferon therapy and the long-term outcome of chronic hepatitis B. *Gastroenterology* 2002; **123**: 1812-1822 [PMID: 12454838]

35 **Clifford GM**, Rickenbach M, Polesel J, Dal Maso L, Steffen I, Ledergerber B, Rauch A, Probst-Hensch NM, Bouchardy C, Levi F, Franceschi S. Influence of HIV-related immunodeficiency on the risk of hepatocellular carcinoma. *AIDS* 2008; **22**: 2135-2141 [PMID: 18832877 DOI: 10.1097/QAD.0b013e32831103ad]

36 **Hong F**, Tuyama A, Lee TF, Loke J, Agarwal R, Cheng X, Garg A, Fiel MI, Schwartz M, Walewski J, Branch A, Schecter AD, Bansal MB. Hepatic stellate cells express functional CXCR4: role in stromal cell-derived factor-1alpha-mediated stellate cell activation. *Hepatology* 2009; **49**: 2055-2067 [PMID: 19434726 DOI: 10.1002/hep.22890]

37 **Svegliati-Baroni G**, De Minicis S. HIV protein gp120 and chemokines receptor for liver fibrosis. *Gut* 2010; **59**: 428-429 [PMID: 20332514 DOI: 10.1136/gut.2009.195024]

38 **Bruno R**, Galastri S, Sacchi P, Cima S, Caligiuri A, DeFranco R, Milani S, Gessani S, Fantuzzi L, Liotta F, Frosali F, Antonucci G, Pinzani M, Marra F. gp120 modulates the biology of human hepatic stellate cells: a link between HIV infection and liver fibrogenesis. *Gut* 2010; **59**: 513-520 [PMID: 19736361 DOI: 10.1136/gut.2008.163287]

39 **Babu CK**, Suwansrinon K, Bren GD, Badley AD, Rizza SA. HIV induces TRAIL sensitivity in hepatocytes. *PLoS One* 2009; **4**: e4623 [PMID: 19247452 DOI: 10.1371/journal.pone.0004623]

40 **Shrivastav S**, Kino T, Cunningham T, Ichijo T, Schubert U, Heinklein P, Chrousos GP, Kopp JB. Human immunodeficiency virus (HIV)-1 viral protein R suppresses transcriptional activity of peroxisome proliferator-activated receptor {gamma} and inhibits adipocyte differentiation: implications for HIV-associated lipodystrophy. *Mol Endocrinol* 2008; **22**: 234-247 [PMID: 17932108]

41 **Lambert C**, Döring T, Prange R. Hepatitis B virus maturation is sensitive to functional inhibition of ESCRT-III, Vps4, and gamma 2-adaptin. *J Virol* 2007; **81**: 9050-9060 [PMID: 17553870 DOI: 10.1128/JVI.00479-07]

42 **Popov S**, Popova E, Inoue M, Göttlinger HG. Human immunodeficiency virus type 1 Gag engages the Bro1 domain of ALIX/AIP1 through the nucleocapsid. *J Virol* 2008; **82**: 1389-1398 [PMID: 18032513 DOI: 10.1128/JVI.01912-07]

43 **Xu Z**, Yen TS. Intracellular retention of surface protein by a hepatitis B virus mutant that releases virion particles. *J Virol* 1996; **70**: 133-140 [PMID: 8523517]

44 **Gómez-Gonzalo M**, Carretero M, Rullas J, Lara-Pezzi E, Aramburu J, Berkhout B, Alcamí J, López-Cabrera M. The hepatitis B virus X protein induces HIV-1 replication and transcription in synergy with T-cell activation signals: functional roles of NF-kappaB/NF-AT and SP1-binding sites in the HIV-1 long terminal repeat promoter. *J Biol Chem* 2001; **276**: 35435-35443 [PMID: 11457829 DOI: 10.1074/jbc.M103020200]

45 **Lacombe K**, Boyd A, Gozlan J, Lavocat F, Girard PM, Zoulim F. Drug-resistant and immune-escape HBV mutants in HIV-infected hosts. *Antivir Ther* 2010; **15**: 493-497 [PMID: 20516570 DOI: 10.3851/IMP1495]

46 **Soriano V**, Puoti M, Bonacini M, Brook G, Cargnel A, Rockstroh J, Thio C, Benhamou Y. Care of patients with chronic hepatitis B and HIV co-infection: recommendations from an HIV-HBV International Panel. *AIDS* 2005; **19**: 221-240 [PMID: 15718833]

47 **Centers for Disease Control and Prevention**. Guidelines for prevention and treatment of opportunistic infections in HIV-infected adults and adolescents: recommendations from CDC, the national institutes of health, and the HIV medicine association of the infectious diseases society of America. 2009

48 **Ingiliz P**, Valantin MA, Thibault V, Duvivier C, Dominguez S, Katlama C, Poynard T, Benhamou Y. Efficacy and safety of adefovir dipivoxil plus pegylated interferon-alpha2a for the treatment of lamivudine-resistant hepatitis B virus infection in HIV-infected patients. *Antivir Ther* 2008; **13**: 895-900 [PMID: 19043923]

49 **McMahon MA**, Jilek BL, Brennan TP, Shen L, Zhou Y, Wind-Rotolo M, Xing S, Bhat S, Hale B, Hegarty R, Chong CR, Liu JO, Siliciano RF, Thio CL. The HBV drug entecavir - effects on HIV-1 replication and resistance. *N Engl J Med* 2007; **356**: 2614-2621 [PMID: 17582071 DOI: 10.1056/NEJMoa067710]

50 **Sasadeusz J**, Audsley J, Mijch A, Baden R, Caro J, Hunter H, Matthews G, McMahon MA, Olender SA, Siliciano RF, Lewin SR, Thio CL. The anti-HIV activity of entecavir: a multicentre evaluation of lamivudine-experienced and lamivudine-naive patients. *AIDS* 2008; **22**: 947-955 [PMID: 18453854 DOI: 10.1097/QAD.0b013e3282ffde91]

51 **Pessôa MG**, Gazzard B, Huang AK, Brandão-Mello CE, Cassetti I, Mendes-Corrêa MC, Soriano V, Phiri P, Hall A, Brett-Smith H. Efficacy and safety of entecavir for chronic HBV in HIV/HBV coinfected patients receiving lamivudine as part of antiretroviral therapy. *AIDS* 2008; **22**: 1779-1787 [PMID: 18753861 DOI: 10.1097/QAD.0b013e32830b3ab5]

52 **Shire NJ**, Welge JA, Sherman KE. Efficacy of inactivated hepatitis A vaccine in HIV-infected patients: a hierarchical bayesian meta-analysis. *Vaccine* 2006; **24**: 272-279 [PMID: 16139398 DOI: 10.1016/j.vaccine.2005.07.102]

53 **Benhamou Y**, Bochet M, Thibault V, Di Martino V, Caumes E, Bricaire F, Opolon P, Katlama C, Poynard T. Long-term incidence of hepatitis B virus resistance to lamivudine in human immunodeficiency virus-infected patients. *Hepatology* 1999; **30**: 1302-1306 [PMID: 10534354]

54 **Kim HN**, Harrington RD, Crane HM, Dhanireddy S, Dellit TH, Spach DH. Hepatitis B vaccination in HIV-infected adults: current evidence, recommendations and practical considerations. *Int J STD AIDS* 2009; **20**: 595-600 [PMID: 19710329 DOI: 10.1258/ijsa.2009.009126]

55 **Lok AS**, McMahon BJ. Chronic hepatitis B. *Hepatology* 2007; **45**: 507-539 [PMID: 17256718]

56 **Mast EE**, Weinbaum CM, Fiore AE, Alter MJ, Bell BP, Finelli L, Rodewald LE, Douglas JM, Janssen RS, Ward JW. A comprehensive immunization strategy to eliminate transmission of hepatitis B virus infection in the United States: recommendations of the Advisory Committee on Immunization Practices (ACIP) Part II: immunization of adults. *MMWR Recomm Rep* 2006; **55**: 1-33; quiz CE1-4 [PMID: 17159833]

P- Reviewer: Kim YJ, Meng SD **S- Editor**: Gong XM
L- Editor: A **E- Editor**: Liu SQ

Published by **Baishideng Publishing Group Inc**
8226 Regency Drive, Pleasanton, CA 94588, USA
Telephone: +1-925-223-8242
Fax: +1-925-223-8243
E-mail: bpgoffice@wjgnet.com
Help Desk: http://www.wjgnet.com/esps/helpdesk.aspx
http://www.wjgnet.com