ISSN 1007-9327
CN 14-1219/R

World Journal of Gastroenterology®

Indexed and Abstracted in:
Current Contents®/Clinical Medicine, Science Citation Index Expanded (also known as SciSearch®), Journal Citation Reports®, Index Medicus, MEDLINE, PubMed, PubMed Central, Digital Object Identifer, and EMBASE/Excerpta Medica. ISI, Thomson Reuters, 2008 Impact Factor: 2.081 (32/55 Gastroenterology and Hepatology).

Volume 16 Number 6
February 14, 2010
World J Gastroenterol
2010 February 14; 16(6): 659-786
Online Submissions
www.wjgnet.com/1007-9327offce
www.wjgnet.com
Printed on Acid-free Paper
世界胃肠病学杂志

A Weekly Journal of Gastroenterology and Hepatology

WJG World Journal of Gastroenterology

A peer-reviewed, online, open-access journal of gastroenterology and hepatology

Editorial Board

2010-2013

The *World Journal of Gastroenterology* Editorial Board consists of 1096 members, representing a team of worldwide experts in gastroenterology and hepatology. They are from 60 countries, including Albania (1), Argentina (7), Australia (28), Austria (13), Belgium (11), Brazil (8), Brunei Darussalam (1), Bulgaria (2), Canada (18), Chile (3), China (66), Colombia (1), Croatia (2), Cuba (1), Czech (4), Denmark (8), **Ecuador (1), Egypt (2), Estonia (2), Finland** (7), France (22), **Germany (72), Greece (14), Hungary (10), India (25), Iran (6), Ireland (6), Israel (12), Italy (94),** Japan (107), Jordan (1), Kuwait (1), Lebanon (3), Lithuania (2), Malaysia (1), Mexico (9), Moldova (1), Netherlands (27), New Zealand (2), Norway (11), Pakistan (2), **Poland (10), Portugal (4), Romania (3), Russia (1), Saudi Arabia** (3), Serbia (3), Singapore (9), South Africa (2), South Korea (32), Spain (36), Sweden (17), Switzerland (11), Thailand (1), Trinidad and Tobago (1), Turkey (24), United Arab Emirates (2), United Kingdom (80), United States (242), and **Uruguay (1)**.

Boris Guiu, *Dijon*
Paul Hofman, *Nice*
Laurent Huwart, *Paris*
Abdel-Majid Khatib, *Paris*
Philippe Lehours, *Bordeaux*
Flavio Maina, *Marseille*
Patrick Marcellin, *Paris*
Rene Gerolami Santandera, *Marseille*
Annie Schmid-Alliana, *Nice cedex*
Alain L Servin, *Châtenay-Malabry*
Stephane Supiot, *Nantes*
Baumert F Thomas, *Strasbourg*
Jean-Jacques Tuech, *Rouen*
Frank Zerbib, *Bordeaux Cedex*

Germany

Erwin Biecker, *Siegburg*
Hubert Blum, *Freiburg*
Thomas Bock, *Tuebingen*
Dean Bogoevski, *Hamburg*
Elfriede Bollschweiler, *Köln*
Jürgen Borlak, *Hannover*
Christa Buechler, *Regensburg*
Jürgen Büning, *Lübeck*
Elke Cario, *Essen*
Bruno Christ, *Halle/Saale*
Christoph F Dietrich, *Bad Mergentheim*
Ulrich R Fölsch, *Kiel*
Nikolaus Gassler, *Aachen*
Markus Gerhard, *Munich*
Dieter Glebe, *Giessen*
Ralph Graeser, *Freiburg*
Axel M Gressner, *Aachen*
Nils Habbe, *Marburg*
Thilo Hackert, *Heidelberg*
Wolfgang Hagmann, *Heidelberg*
Dirk Haller, *Freising*
Philip D Hard, *Giessen*
Claus Hellerbrand, *Regensburg*
Klaus R Herrlinger, *Stuttgart*
Eberhard Hildt, *Berlin*
Andrea Hille, *Goettingen*
Joerg C Hoffmann, *Berlin*
Andrej Khandoga, *Munich*
Jorg Kleeff, *Munich*
Ingmar Königsrainer, *Tübingen*
Peter Konturek, *Erlangen*
Stefan Kubicka, *Hannover*
Joachim Labenz, *Siegen*
Michael Linnebacher, *Rostock*
Jutta Elisabeth Lüttges, *Riegelsberg*
Peter Malfertheiner, *Magdeburg*
Oliver Mann, *Hamburg*
Peter N Meier, *Hannover*
Sabine Mihm, *Göttingen*
Klaus Mönkemüller, *Bottrop*
Jonas Mudter, *Erlangen*
Sebastian Mueller, *Heidelberg*
Robert Obermaier, *Freiburg*
Matthias Ocker, *Erlangen*
Stephan Johannes Ott, *Kiel*
Christoph Reichel, *Bad Brückenau*
Markus Reiser, *Bochum*
Steffen Rickes, *Magdeburg*
Elke Roeb, *Giessen*
Christian Rust, *Munich*
Hans Scherubl, *Berlin*
Martin K Schilling, *Homburg*
Rene Schmidt, *Freiburg*
Andreas G Schreyer, *Regensburg*
Karsten Schulmann, *Bochum*
Henning Schulze-Bergkamen, *Mainz*
Manfred V Singer, *Mannheim*
Jens Standop, *Bonn*
Jurgen M Stein, *Frankfurt*
Ulrike S Stein, *Berlin*
Wolfgang R Stremmel, *Heidelberg*
Harald F Teutsch, *Ulm*
Hans L Tillmann, *Leipzig*
Christian Trautwein, *Aachen*
Joerg Trojan, *Frankfurt*
Arndt Vogel, *Hannover*
Siegfried Wagner, *Deggendorf*
Frank Ulrich Weiss, *Greifswald*
Fritz von Weizsäcker, *Berlin*
Thomas Wex, *Magdeburg*
Stefan Wirth, *Wuppertal*
Marty Zdichavsky, *Tübingen*

Greece

Helen Christopoulou-Aletra, *Thessaloniki*
T Choli-Papadopoulou, *Thessaloniki*
Tsianos Epameinondas, *Ioannina*
Ioannis Kanellos, *Thessaloniki*
Elias A Kouroumalis, *Heraklion*
Ioannis E Koutroubakis, *Heraklion*
Michael Koutsilieris, *Athens*
Andreas Larentzakis, *Athens*
Emanuel K Manesis, *Athens*
Spilios Manolakopoulos, *Athens*
Konstantinos Mimidis, *Alexandroupolis*
George Papatheodoridis, *Athens*
Spiros Sgouros, *Athens*
Evangelos Tsiambas, *Ag Paraskevi Attiki*

Hungary

György M Buzás, *Budapest*
László Czakó, *Szeged*
Gyula Farkas, *Szeged*
Peter Hegyi, *Szeged*
Peter L Lakatos, *Budapest*
Yvette Mándi, *Szeged*
Zoltan Rakonczay, *Szeged*
Ferenc Sipos, *Budapest*
Zsuzsa Szondy, *Debrecen*
Gabor Veres, *Budapest*

India

Philip Abraham, *Mumbai*
Vineet Ahuja, *New Delhi*
Devinder Kumar Dhawan, *Chandigarh*
Radha K Dhiman, *Chandigarh*
Pankaj Garg, *Panchkula*
Pramod Kumar Garg, *New Delhi*
Debidas Ghosh, *Midnpore*
Uday C Ghoshal, *Lucknow*
Bhupendra Kumar Jain, *Delhi*
Ashok Kumar, *Lucknow*
Bikash Medhi, *Chandigarh*
Sri P Misra, *Allahabad*
Gopal Nath, *Varanasi*
Samiran Nundy, *New Delhi*
Jagannath Palepu, *Mumbai*
Vandana Panda, *Mumbai*
Benjamin Perakath, *Tamil Nadu*
Ramesh Roop Rai, *Jaipur*
Nageshwar D Reddy, *Hyderabad*
Barjesh Chander Sharma, *New Delhi*
Virendra Singh, *Chandigarh*
Rupjyoti Talukdar, *Guwahati*
Rakesh Kumar Tandon, *New Delhi*
Jai Dev Wig, *Chandigarh*

Iran

Mohammad Abdollahi, *Tehran*
Peyman Adibi, *Isfahan*
Seyed-Moayed Alavian, *Tehran*
Seyed Mohsen Dehghani, *Shiraz*
Reza Malekzadeh, *Tehran*
Alireza Mani, *Tehran*

Ireland

Billy Bourke, *Dublin*
Ted Dinan, *Cork*
Catherine Greene, *Dublin*
Ross McManus, *Dublin*
Marion Rowland, *Dublin*

Israel

Simon Bar-Meir, *Hashomer*
Alexander Becker, *Afula*
Abraham R Eliakim, *Haifa*
Sigal Fishman, *Tel Aviv*
Boris Kirshtein, *Beer Sheva*
Eli Magen, *Ashdod*
Menachem Moshkowitz, *Tel-Aviv*
Assy Nimer, *Safed*
Shmuel Odes, *Beer Sheva*
Mark Pines, *Bet Dagan*
Ron Shaoul, *Haifa*
Ami D Sperber, *Beer-Sheva*

Italy

Donato F Altomare, *Bari*
Piero Amodio, *Padova*
Paolo Angeli, *Padova*
Bruno Annibale, *Rome*
Paolo Aurello, *Rome*
Salvatore Auricchio, *Naples*
Antonio Basoli, *Rome*
Claudio Bassi, *Verona*
Gabrio Bassotti, *Perugia*
Mauro Bernardi, *Bologna*
Alberto Biondi, *Rome*
Luigi Bonavina, *Milano*
Guglielmo Borgia, *Naples*
Roberto Berni Canani, *Naples*
Fausto Catena, *Bologna*
Giuseppe Chiarioni, *Valeggio*
Michele Cicala, *Rome*
Dario Conte, *Milano*
Francesco Costa, *Pisa*
Giuseppe Currò, *Messina*
Mario M D'Elios, *Florence*
Mirko D'Onofrio, *Verona*
Silvio Danese, *Milano*
Roberto de Franchis, *Milano*
Paola De Nardi, *Milan*
Giovanni D De Palma, *Naples*

Giuliana Decorti, *Trieste*
Gianlorenzo Dionigi, *Varese*
Massimo Falconi, *Verona*
Silvia Fargion, *Milan*
Giammarco Fava, *Ancona*
Francesco Feo, *Sassari*
Alessandra Ferlini, *Ferrara*
Alessandro Ferrero, *Torino*
Luca Frulloni, *Verona*
Giovanni B Gaeta, *Napoli*
Antonio Gasbarrini, *Rome*
Edoardo G Giannini, *Genoa*
Alessandro Granito, *Bologna*
Fabio Grizzi, *Milan*
Salvatore Gruttadauria, *Palermo*
Pietro Invernizzi, *Milan*
Achille Iolascon, *Naples*
Angelo A Izzo, *Naples*
Ezio Laconi, *Cagliari*
Giovanni Latella, *L'Aquila*
Massimo Levrero, *Rome*
Francesco Luzza, *Catanzaro*
Lucia Malaguarnera, *Catania*
Francesco Manguso, *Napoli*
Pier Mannuccio Mannucci, *Milano*
Giancarlo Mansueto, *Verona*
Giulio Marchesini, *Bologna*
Mara Massimi, *Coppito*
Giovanni Milito, *Rome*
Giuseppe Montalto, *Palermo*
Giovanni Monteleone, *Rome*
Luca Morelli, *Trento*
Giovanni Musso, *Torino*
Mario Nano, *Torino*
Gerardo Nardone, *Napoli*
Riccardo Nascimbeni, *Brescia*
Valerio Nobili, *Rome*
Fabio Pace, *Milano*
Nadia Peparini, *Rome*
Mario Pescatori, *Rome*
Raffaele Pezzilli, *Bologna*
Alberto Piperno, *Monza*
Anna C Piscaglia, *Rome*
Piero Portincasa, *Bari*
Michele Reni, *Milan*
Vittorio Ricci, *Pavia*
Oliviero Riggio, *Rome*
Mario Rizzetto, *Torino*
Ballarin Roberto, *Modena*
Franco Roviello, *Siena*
Cesare Ruffolo, *Treviso*
Massimo Rugge, *Padova*
Marco Scarpa, *Padova*
C armelo Scarpignato, *Parma*
Giuseppe Sica, *Rome*
Marco Silano, *Rome*
Pierpaolo Sileri, *Rome*
Vincenzo Stanghellini, *Bologna*
Fiorucci Stefano, *Perugia*
Giovanni Tarantino, *Naples*
Alberto Tommasini, *Trieste*
Guido Torzilli, *Rozzano Milano*
Cesare Tosetti, *Porretta Terme*
Antonello Trecca, *Rome*
Vincenzo Villanacci, *Brescia*
Lucia Ricci Vitiani, *Rome*
Marco Vivarelli, *Bologna*

Japan

Kyoichi Adachi, *Izumo*
Yasushi Adachi, *Sapporo*
Takafumi Ando, *Nagoya*
Akira Andoh, *Otsu*
Masahiro Arai, *Tokyo*
Hitoshi Asakura, *Tokyo*
Kazuo Chijiiwa, *Miyazaki*
Yuichiro Eguchi, *Saga*
Itaru Endo, *Yokohama*
Munechika Enjoji, *Fukuoka*
Yasuhiro Fujino, *Akashi*
Mitsuhiro Fujishiro, *Tokyo*
Kouhei Fukushima, *Sendai*
Masanori Hatakeyama, *Tokyo*
Keiji Hirata, *Kitakyushu*
Toru Hiyama, *Higashihiroshima*
Masahiro Iizuka, *Akita*
Susumu Ikehara, *Osaka*
Kenichi Ikejima, *Bunkyo-ku*
Yutaka Inagaki, *Kanagawa*
Hiromi Ishibashi, *Nagasaki*
Shunji Ishihara, *Izumo*
Toru Ishikawa, *Niigata*
Toshiyuki Ishiwata, *Tokyo*
Yoshiaki Iwasaki, *Okayama*
Satoru Kakizaki, *Gunma*
Terumi Kamisawa, *Tokyo*
Mototsugu Kato, *Sapporo*
Naoya Kato, *Tokyo*
Takumi Kawaguchi, *Kurume*
Yohei Kida, *Kainan*
Shogo Kikuchi, *Aichi*
Tsuneo Kitamura, *Chiba*
Takashi Kobayashi, *Tokyo*
Yasuhiro Koga, *Isehara*
Takashi Kojima, *Sapporo*
Norihiro Kokudo, *Tokyo*
Masatoshi Kudo, *Osaka*
Shin Maeda, *Tokyo*
Satoshi Mamori, *Hyogo*
Atsushi Masamune, *Sendai*
Yasushi Matsuzaki, *Tsukuba*
Kenji Miki, *Tokyo*
Hiroto Miwa, *Hyogo*
Kotaro Miyake, *Tokushima*
Manabu Morimoto, *Yokohama*
Yoshiharu Motoo, *Kanazawa*
Yoshiaki Murakami, *Hiroshima*
Kunihiko Murase, *Tusima*
Akihito Nagahara, *Tokyo*
Yuji Naito, *Kyoto*
Atsushi Nakajima, *Yokohama*
Hisato Nakajima, *Tokyo*
Hiroki Nakamura, *Yamaguchi*
Shotaro Nakamura, *Fukuoka*
Akimasa Nakao, *Nagogya*
Shuhei Nishiguchi, *Hyogo*
Mikio Nishioka, *Niihama*
Keiji Ogura, *Tokyo*
Susumu Ohmada, *Maebashi*
Hirohide Ohnishi, *Akita*
Kenji Okajima, *Nagoya*
Kazuichi Okazaki, *Osaka*
Morikazu Onji, *Ehime*
Satoshi Osawa, *Hamamatsu*
Hidetsugu Saito, *Tokyo*
Yutaka Saito, *Tokyo*
Naoaki Sakata, *Sendai*
Yasushi Sano, *Chiba*
Tokihiko Sawada, *Tochigi*
Tomohiko Shimatan, *Hiroshima*
Yukihiro Shimizu, *Kyoto*
Shinji Shimoda, *Fukuoka*
Yoshio Shirai, *Niigata*
Masayuki Sho, *Nara*
Shoichiro Sumi, *Kyoto*
Hidekazu Suzuki, *Tokyo*
Masahiro Tajika, *Nagoya*
Yoshihisa Takahashi, *Tokyo*
Toshinari Takamura, *Kanazawa*
Hiroaki Takeuchi, *Kochi*
Yoshitaka Takuma, *Okayama*
Akihiro Tamori, *Osaka*
Atsushi Tanaka, *Tokyo*
Shinji Tanaka, *Hiroshima*
Satoshi Tanno, *Hokkaido*
Shinji Togo, *Yokohama*
Hitoshi Tsuda, *Tokyo*
Hiroyuki Uehara, *Osaka*
Masahito Uemura, *Kashihara*
Yoshiyuki Ueno, *Sendai*
Mitsuyoshi Urashima, *Tokyo*
Satoshi Yamagiwa, *Niigata*
Taketo Yamaguchi, *Chiba*
Mitsunori Yamakawa, *Yamagata*
Takayuki Yamamoto, *Yokkaichi*
Yutaka Yata, *Maebashi*
Hiroshi Yoshida, *Tokyo*
Norimasa Yoshida, *Kyoto*
Yuichi Yoshida, *Osaka*
Kentaro Yoshika, *Toyoake*
Katsutoshi Yoshizato, *Higashihiroshima*
Tomoharu Yoshizumi, *Fukuoka*

Jordan

Ismail Matalka, *Irbid*

Kuwait

Islam Khan, *Safat*

Lebanon

Bassam N Abboud, *Beirut*
Ala I Sharara, *Beirut*
Rita Slim, *Beirut*

Lithuania

Giedrius Barauskas, *Kaunas*
Limas Kupcinskas, *Kaunas*

Malaysia

Andrew Seng Boon Chua, *Ipoh*

Mexico

Richard A Awad, *Mexico*
Aldo Torre Delgadillo, *Mexico*
Diego Garcia-Compean, *Monterrey*
Paulino M Hernández Magro, *Celaya*
Miguel Angel Mercado, *Distrito Federal*
Arturo Panduro, *Jalisco*
Omar Vergara-Fernandez, *Tlalpan*
Saúl Villa-Trevio, *Mexico*

Sara Lindén, *Göteborg*
Hanns-Ulrich Marschall, *Stockholm*
Pär Erik Myrelid, *Linköping*
Åke Nilsson, *Lund*
Helena Nordenstedt, *Stockholm*
Kjell Öberg, *Uppsala*
Lars A Pahlman, *Uppsala*
Stefan G Pierzynowski, *Lund*
Sara Regnér, *Malmö*
Bobby Tingstedt, *Lund*
Zongli Zheng, *Stockholm*

Switzerland

Pascal Bucher, *Geneva*
Michelangelo Foti, *Geneva*
Jean L Frossard, *Geneva*
Andreas Geier, *Zürich*
Pascal Gervaz, *Geneva*
Gerd A Kullak-Ublick, *Zürich*
Fabrizio Montecucco, *Geneva*
Paul M Schneider, *Zürich*
Felix Stickel, *Berne*
Bruno Stieger, *Zürich*
Inti Zlobec, *Basel*

Trinidad and Tobago

Shivananda Nayak, *Mount Hope*

Turkey

Sinan Akay, *Tekirdag*
Metin Basaranoglu, *Istanbul*
Yusuf Bayraktar, *Ankara*
A Mithat Bozdayi, *Ankara*
Hayrullah Derici, *Balıkesir*
Eren Ersoy, *Ankara*
Mukaddes Esrefoglu, *Malatya*
Can Goen, *Kutahya*
Selin Kapan, *Istanbul*
Aydin Karabacakoglu, *Konya*
Cuneyt Kayaalp, *Malatya*
Kemal Kismet, *Ankara*
Seyfettin Köklü, *Ankara*
Mehmet Refik Mas, *Etlik-Ankara*
Osman C Ozdogan, *Istanbul*
Bülent Salman, *Ankara*
Salih Sanlioglu, *Antalya*
Orhan Sezgin, *Mersin*
Ilker Tasci, *Ankara*
Ahmet Tekin, *Mersin*
Mesut Tez, *Ankara*
Ekmel Tezel, *Ankara*
Özlem Yilmaz, *Izmir*

United Arab Emirates

Fikri M Abu-Zidan, *Al-Ain*
Sherif M Karam, *Al-Ain*

United Kingdom

Simon Afford, *Birmingham*
Navneet K Ahluwalia, *Stockport*
Mohamed H Ahmed, *Southampton*
Basil Ammori, *Salford*
Lesley A Anderson, *Belfast*
Chin Wee Ang, *Liverpool*
Yeng S Ang, *Wigan*
Anthony TR Axon, *Leeds*
Kathleen B Bamford, *London*
Jim D Bell, *London*
John Beynon, *Swansea*
Chris Briggs, *Sheffield*
Geoffrey Burnstock, *London*
Alastair D Burt, *Newcastle*
Jeff Butterworth, *Shrewsbury*
Jeremy FL Cobbold, *London*
Jean E Crabtree, *Leeds*
Tatjana Crnogorac-Jurcevic, *London*
William Dickey, *Londonderry*
Sunil Dolwani, *Cardiff*
Emad M El-Omar, *Aberdeen*
A M El-Tawil, *Birmingham*
Charles B Ferguson, *Belfast*
Andrew Fowell, *Southampton*
Piers Gatenby, *London*
Daniel R Gaya, *Edinburgh*
Anil George, *London*
Rob Glynne-Jones, *Northwood*
Jason CB Goh, *Birmingham*
Gianpiero Gravante, *Leicester*
Brian Green, *Belfast*
William Greenhalf, *Liverpool*
Indra N Guha, *Nottingham*
Stefan G Hübscher, *Birmingham*
Robin Hughes, *London*
Pali Hungin, *Stockton*
Nawfal Hussein, *Nottingham*
Clement W Imrie, *Glasgow*
Janusz AZ Jankowski, *Oxford*
Sharad Karandikar, *Birmingham*
Peter Karayiannis, *London*
Shahid A Khan, *London*
Patricia F Lalor, *Birmingham*
John S Leeds, *Sheffield*
Ian Lindsey, *Oxford*
Hong-Xiang Liu, *Cambridge*
Dileep N Lobo, *Nottingham*
Graham MacKay, *Glasgow*
Anne McCune, *Bristol*
Donald Campbell McMillan, *Glasgow*
Giorgina Mieli-Vergani, *London*
Jamie Murphy, *London*
Guy Fairbairn Nash, *Poole*
James Neuberger, *Birmingham*
Patrick O'Dwyer, *Glasgow*
Christos Paraskeva, *Bristol*
Richard Parker, *North Staffordshire*
Thamara Perera, *Birmingham*
Kondragunta Rajendra Prasad, *Leeds*
D Mark Pritchard, *Liverpool*
Alberto Quaglia, *London*
Akhilesh B Reddy, *Cambridge*
Kevin Robertson, *Glasgow*
John B Schofield, *Kent*
Marco Senzolo, *Padova*
Venkatesh Shanmugam, *Derby*
Paul Sharp, *London*
Chew Thean Soon, *Manchester*
Aravind Suppiah, *East Yorkshire*
Noriko Suzuki, *Middlesex*
Simon D Taylor-Robinson, *London*
Frank I Tovey, *London*
A McCulloch Veitch, *Wolverhampton*
Vamsi R Velchuru, *Lowestoft*
Sumita Verma, *Brighton*
Catherine Walter, *Cheltenham*
Julian RF Walters, *London*
Roger Williams, *London*



United States

Kareem M Abu-Elmagd, *Pittsburgh*
Sami R Achem, *Florida*
Golo Ahlenstiel, *Bethesda*
Bhupinder S Anand, *Houston*
M Ananthanarayanan, *New York*
Balamurugan N Appakalal, *Minneapolis*
Dimitrios V Avgerinos, *New York*
Shashi Bala, *Worcester*
Anthony J Bauer, *Pittsburgh*
Kevin E Behrns, *Gainesville*
Roberto Bergamaschi, *New York*
Henry J Binder, *New Haven*
Edmund J Bini, *New York*
Wojciech Blonski, *Philadelphia*
Mark Bloomston, *Columbus*
Edward L Bradley III, *Sarasota*
Carla W Brady, *Durham*
David A Brenner, *San Diego*
Adeel A Butt, *Pittsburgh*
Shi-Ying Cai, *New Haven*
Justin MM Cates, *Nashville*
Eugene P Ceppa, *Durham*
Jianyuan Chai, *Long Beach*
Ronald S Chamberlain, *Livingston*
Xian-Ming Chen, *Omaha*
Ramsey Chi-man Cheung, *Palo Alto*
Denesh Chitkara, *East Brunswick*
Clifford S Cho, *Madison*
Parimal Chowdhury, *Arkansas*
John David Christein, *Birmingham*
Thomas Clancy, *Boston*
Ana J Coito, *Los Angeles*
Ricardo Alberto Cruciani, *New York*
Joseph J Cullen, *Iowa City*
Mark J Czaja, *New York*
Mariana D Dabeva, *Bronx*
Jessica A Davila, *Houston*
Conor P Delaney, *Cleveland*
Laurie DeLeve, *Los Angeles*
Anthony J Demetris, *Pittsburgh*
Sharon DeMorrow, *Temple*
Bijan Eghtesad, *Cleveland*
Yoram Elitsur, *Huntington*
Mohamad A Eloubeidi, *Alabama*
Wael El-Rifai, *Nashville*
Giamila Fantuzzi, *Chicago*
Ashkan Farhadi, *Irvine*
Ronnie Fass, *Tucson*
Martín E Fernández-Zapico, *Rochester*
Alessandro Fichera, *Chicago*
Josef E Fischer, *Boston*
Piero Marco Fisichella, *Maywood*
Fritz Francois, *New York*
Glenn T Furuta, *Aurora*
T Clark Gamblin, *Pittsburgh*
Henning Gerke, *Iowa City*
Jean-Francois Geschwind, *Baltimore*
R Mark Ghobrial, *Texas*
John F Gibbs, *Buffalo*
Shannon S Glaser, *Temple*
Ajay Goel, *Dallas*
Jon C Gould, *Madison*
Eileen F Grady, *San Francisco*
James H Grendell, *New York*

WJG

World Journal of Gastroenterology

Contents

Weekly Volume 16 Number 6 February 14, 2010

EDITORIAL

659 Is the DHEAS/cortisol ratio a potential filter for non-operable constipated cases?
El-Tawil AM

663 Iron: An emerging factor in colorectal carcinogenesis
Chua ACG, Klopcic B, Lawrance IC, Olynyk JK, Trinder D

TOPIC HIGHLIGHT

673 Recent developments in palliative chemotherapy for locally advanced and metastatic pancreas cancer
Bayraktar S, Bayraktar UD, Rocha-Lima CM

683 Experience of a single center with congenital hepatic fibrosis: A review of the literature
Shorbagi A, Bayraktar Y

691 How useful is rectal endosonography in the staging of rectal cancer?
Kav T, Bayraktar Y

REVIEW

698 *Capillaria hepatica* in China
Li CD, Yang HL, Wang Y

ORIGINAL ARTICLE

703 *Schistosoma mansoni* proteins attenuate gastrointestinal motility disturbances during experimental colitis in mice
Ruyssers NE, De Winter BY, De Man JG, Ruyssers ND, Van Gils AJ, Loukas A, Pearson MS, Weinstock JV, Pelckmans PA, Moreels TG

713 Involvement of PI3K and ERK1/2 pathways in hepatocyte growth factor-induced cholangiocarcinoma cell invasion
Menakongka A, Suthiphongchai T

723 Endoscopic findings and clinicopathologic characteristics of colonic schistosomiasis: A report of 46 cases
Cao J, Liu WJ, Xu XY, Zou XP

BRIEF ARTICLE

728 Endoscopic ultrasound-guided celiac plexus neurolysis using a reverse phase polymer
Obstein KL, Martins FP, Fernández-Esparrach G, Thompson CC

732 ABCG5-positivity in tumor buds is an indicator of poor prognosis in node-negative colorectal cancer patients
Hostettler I, Zlobec I, Terracciano L, Lugli A

740 Pericardiocentesis with cisplatin for malignant pericardial effusion and tamponade
Oida T, Mimatsu K, Kano H, Kawasaki A, Kuboi Y, Fukino N, Amano S

745 Surgery for gastrointestinal malignant melanoma: Experience from surgical training center
Akaraviputh T, Arunakul S, Lohsiriwat V, Iramaneerat C, Trakarnsanga A

749 Effects of *in vitro* cultivated *Calculus Bovis* compound on pulmonary lesions in rabbits with schistosomiasis
Li T, Yang Z, Cai HJ, Song LW, Lu KY, Zhou Z, Wu ZD

755 Methylation of *Dickkopf-3* as a prognostic factor in cirrhosis-related hepatocellular carcinoma
Yang B, Du Z, Gao YT, Lou C, Zhang SG, Bai T, Wang YJ, Song WQ

764 Therapy and prognostic features of primary clear cell carcinoma of the liver
Ji SP, Li Q, Dong H

770 Treatment of hepatitis B virus-associated glomerulonephritis: A meta-analysis
Zhang Y, Zhou JH, Yin XL, Wang FY

CASE REPORT

778 A case of gouty arthritis following percutaneous radiofrequency ablation for hepatocellular carcinoma
Choi DH, Lee HS

782 Multiple chronic non-specific ulcer of small intestine characterized by anemia and hypoalbuminemia
Chen Y, Ma WQ, Chen JM, Cai JT

LETTERS TO THE EDITOR

785 Meta-analysis of capsule endoscopy in patients diagnosed or suspected with esophageal varices
Ahn D, Guturu P

Contents

World Journal of Gastroenterology
Volume 16 Number 6 February 14, 2010

ACKNOWLEDGMENTS I Acknowledgments to reviewers of *World Journal of Gastroenterology*

APPENDIX I Meetings

I-IV Instructions to authors

AIM AND SCOPE

World Journal of Gastroenterology (*World J Gastroenterol*, *WJG*, print ISSN 1007-9327, DOI: 10.3748) is a weekly, open-access, peer-reviewed journal supported by an editorial board of 1096 experts in gastroenterology and hepatology from 60 countries.

The major task of *WJG* is to report rapidly the most recent results in basic and clinical research on esophageal, gastrointestinal, liver, pancreas and biliary tract diseases, *Helicobacter pylori*, endoscopy and gastrointestinal surgery, including: gastroesophageal reflux disease, gastrointestinal bleeding, infection and tumors; gastric and duodenal disorders; intestinal inflammation, microflora and immunity; celiac disease, dyspepsia and nutrition; viral hepatitis, portal hypertension, liver fibrosis, liver cirrhosis, liver transplantation, and metabolic liver disease; molecular and cell biology; geriatric and pediatric gastroenterology; diagnosis and screening, imaging and advanced technology.

FLYLEAF I-VII Editorial Board

NAME OF JOURNAL
World Journal of Gastroenterology

LAUNCH DATE
October 1, 1995

RESPONSIBLE INSTITUTION
Department of Science and Technology of Shanxi Province

SPONSOR
Taiyuan Research and Treatment Center for Digestive Diseases, 77 Shuangta Xijie, Taiyuan 030001, Shanxi Province, China

EDITING
Editorial Board of *World Journal of Gastroenterology*, Room 903, Building D, Ocean International Center, No. 62 Dongsihuan Zhonglu, Chaoyang District, Beijing 100025, China
Telephone: +86-10-5908-0039
Fax: +86-10-8538-1893
E-mail: wjg@wjgnet.com
http://www.wjgnet.com

PUBLISHING
Beijing Baishideng BioMed Scientific Co., Ltd., Room 903, Building D, Ocean International Center, No. 62 Dongsihuan Zhonglu, Chaoyang District, Beijing 100025, China
Telephone: +86-10-8538-1892
Fax: +86-10-8538-1893
E-mail: baishideng@wjgnet.com
http://www.wjgnet.com

SUBSCRIPTION
Beijing Baishideng BioMed Scientific Co., Ltd., Room 903, Building D, Ocean International Center, No. 62 Dongsihuan Zhonglu, Chaoyang District, Beijing 100025, China
Telephone: +86-10-8538-1892
Fax: +86-10-8538-1893
E-mail: baishideng@wjgnet.com
http://www.wjgnet.com

PRINT SUBSCRIPTION
RMB 245 Yuan for each issue, RMB 11760 Yuan for one year.

ONLINE SUBSCRIPTION
One-Year Price 864.00 USD

PUBLICATION DATE
February 14, 2010

CSSN
ISSN 1007-9327 (print)
CN 14-1219/R

EDITORIAL OFFICE
Jian-Xia Cheng, Director
World Journal of Gastroenterology
Room 903, Building D, Ocean International Center, No. 62 Dongsihuan Zhonglu, Chaoyang District, Beijing 100025, China
Telephone: +86-10-5908-0039
Fax: +86-10-8538-1893
E-mail: wjg@wjgnet.com
http://www.wjgnet.com

INSTRUCTIONS TO AUTHORS
Full instructions are available online at http://www.wjgnet.com/1007-9327/index.htm. If you do not have web access please contact the editorial office.

ONLINE SUBMISSION
http://www.wjgnet.com/1007-9327office

World Journal of Gastroenterology

Online Submissions: http://www.wjgnet.com/1007-9327office
wjg@wjgnet.com
doi:10.3748/wjg.v16.i6.659

World J Gastroenterol 2010 February 14; 16(6): 659-662
ISSN 1007-9327 (print)

EDITORIAL

Is the DHEAS/cortisol ratio a potential filter for non-operable constipated cases?

AM El-Tawil

AM El-Tawil, Department of Surgery, East Corridor, Ground Floor, University Hospital of Birmingham, Edgbaston, Birmingham, B15 2TH, United Kingdom
Author contributions: El-Tawil AM wrote this paper.
Correspondence to: AM El-Tawil, MSc, MRCS, PhD, Department of Surgery, East Corridor, Ground Floor, University Hospital of Birmingham, Edgbaston, Birmingham, B15 2TH, United Kingdom. atawil20052003@yahoo.co.uk
Telephone: +44-121-6978231 Fax: +44-121-4466220
Received: October 12, 2009 Revised: November 12, 2009
Accepted: November 19, 2009
Published online: February 14, 2010

Abstract

Constipation is a significant manifestation of a number of psychological disorders. Published papers recommend using self-assessment questionnaires for discriminating psychological from non-psychological constipated patients before operating on them but reports from major surveys revealed that general practitioners failed to diagnose 70% of depressed patients using self-assessment questionnaires. Lower circulating concentrations of progesterone, 17-hydroxyprogesterone, cortisol, testosterone, androstenedione, and dehydroepiandrostenedione sulfate (DHEAS) during the follicular phase in constipated young women compared with respective controls were found during the follicular phase of the menstrual cycles. During the luteal phase of the cycle, reductions were identified in estriol, cortisol and testosterone in the constipated group. Likewise, circulating concentrations of DHEAS were found to be lower in depressed patients than comparable healthy controls. DHEAS/cortisol ratios in morning serum and salivary samples were lower than those retrieved during other times of the day in depressed patients. The idea of recognizing major depression in constipated patients by measuring DHEAS/cortisol ratios in saliva and serum may be plausible but this possibility needs to be confirmed in well-designed studies.

Key words: Chronic constipation; Gastrointestinal motility; Colonic inertia; Steroid hormones; Adrenal hormones; Dehydroepiandrosterone; Depression; Anxiety

Peer reviewers: Akio Inui, MD, PhD, Professor, Department of Behavioral Medicine, Kagoshima University Graduate School of Medical and Dental Sciences, 8-35-1 Sakuragaoka, Kagoshima 890-8520, Japan; Steven D Wexner, MD, Professor of Surgery, The Cleveland Clinic Foundation Health Sciences Center of the Ohio State University, and Clinical Professor, Department of Surgery, Division of General Surgery, University of South Florida College of Medicine, 21st Century Oncology Chair in Colorectal Surgery, Chairman, Department of Colorectal Surgery, Chief of Staff, Cleveland Clinic Florida, 2950 Cleveland Clinic Boulevard, Weston, Florida, FL 33331, United States

El-Tawil AM. Is the DHEAS/cortisol ratio a potential filter for non-operable constipated cases? *World J Gastroenterol* 2010; 16(6): 659-662 Available from: URL: http://www.wjgnet.com/1007-9327/full/v16/i6/659.htm DOI: http://dx.doi.org/10.3748/wjg.v16.i6.659

INTRODUCTION

Constipation is a prominent feature amongst patients with depression[1-5], anorexia nervosa, weight loss, sleep disorders[6], fatigue, and decreased sexual interest, particularly with menarche or after a stressful emotional experience[7,8] or surgical operation[9,10].

The outcome of treatment in patients with chronic constipation is unpredictable. This may be a consequence of the lack of effectiveness of such treatment or may reflect heterogeneity within patient subgroups.

IDIOPATHIC CHRONIC CONSTIPATION AND PSYCHOLOGICAL VARIABLES

A positive link was identified by Martelli *et al*[11] between various psychiatric variables and both outlet obstruction and colonic inertia. These results were further confirmed

by others[12]. Fisher *et al*[13] conducted a survey in 50 patients, 21 of whom complained of chronic severe constipation, 29 had fecal incontinence, and none were receiving psychiatric therapy or had a history of a relevant medical condition or drug therapy that could lead to the development of any of these ailments. The participants were asked to complete the Hospital Anxiety & Depression Scale (HAD) questionnaire and the General Health Questionnaire (GHQ) before and after surgery to assess the surgical outcome. Constipated patients had significantly higher HAD depression scores in comparison with respective controls. Constipated patients who had improvement after surgery had significantly lower pre-operative HAD scores compared with those who had no improvement. Using the same parameters, incontinent patients did not differ from respective controls, but those who had bad results after surgery had significantly higher HAD scores than those who benefited from surgery.

Later on, a similar study was conducted where Ghosh *et al*[14] reported the HAD scores determined from a physician-administered questionnaire in patients with chronic constipation, ulcerative colitis, and cancer of the colon, and found a link between the score and the examined clinical symptoms, such as abdominal pain, straining at stool and urgency. The HAD scores were higher in the constipated group in comparison with others, and were significantly higher in those who complained of straining at stool.

However, use of a self-assessment questionnaire as a parameter in patients suffering from chronic disease could not be relied on without other evidence[15]. Published reports revealed that general practitioners could not diagnose a significant percentage of psychological cases using self-assessment questionnaires in patients with chronic diseases[16,17].

PHYSIOLOGY OF STEROIDS HORMONES AND MENSTRUAL CYCLE

Adrenal androgens represent an important component (> 50%) of the circulating androgens in menstruating females[18-25]. In males, the adrenal contribution is much less because of the testicular production of androgens. Adrenal secretion of androgens in men is about the same as in women during the follicular phase.

The adult adrenal gland secretes dehydroepiandrostenedione (DHEA) at approximately 4 mg/d, DHEA sulfate (DHEAS) at 7-15 mg/d, and androstenedione at 1.5 mg/d[26].

RELATIONSHIPS BETWEEN STEROID HORMONES AND BRAIN FUNCTIONS

The relationships between steroid hormones and brain functions have mostly been considered within the framework of endocrine mechanisms as genomic responses, elicited by secretory products from steroidogenic endocrine glands, transported through the bloodstream, and exerting actions on the brain. Ever since the biosynthesis of steroid hormones in the brain[27] and their rapid non-genomic actions[28,29] were first reported, specific targets for so-called "neurosteroids" in plasma membranes have been postulated.

DHEA and its metabolites, DHEAS and androsterone, have been identified recently as having neurosteroid activity.

DHEAS modulates the actions of the gamma-aminobutyric acid type A (GABAA) receptor, the N-methyl-D-aspartate receptor, and the sigma subtype 1 (r1) receptor[27,30-35] among others[36-38]. DHEA and DHEAS generally act as noncompetitive antagonists of the GABAA receptor. GABAA receptor-mediated regulation of 5-hydroxytryptamine (5-HT) neuronal firing was found to be sensitive to negative modulation by DHEA and DHEAS, and to positive modulation by androsterone. GABAA receptor-mediated regulation of 5-HT firing may be responsible for some of the reported behavioral and psychological effects of endogenous and exogenous DHEA[39]. An assessment of depression ratings in relation to plasma concentrations of several steroid hormones (estradiol, testosterone, estrone, androstenedione, cortisol, DHEA, and DHEAS) in 699 postmenopausal women (aged 50-90 years) who were not taking the contraceptive pill[40] found that only DHEAS concentrations were negatively correlated with ratings of depressed mood. Explicitly, higher DHEAS concentrations were associated with less depression, and this association was independent of age, physical activity and weight change. Furthermore, women with categorical diagnoses of depression had significantly lower plasma DHEAS concentrations compared to age-matched non-depressed women[41]. Similarly, in a large-scale study of 2855 well-functioning elderly men and women, serum DHEAS concentrations were inversely correlated with depressive symptoms[42]. Women whose first onset of major or minor depression occurred during the peri-menopause showed low morning plasma DHEA and DHEAS concentrations[43]. Lower plasma DHEA concentrations during pregnancy and during the postpartum period were associated with higher postpartum ratings of depression[44].

PATHOPHYSIOLOGY OF STEROID HORMONES IN SEVERELY CONSTIPATED PATIENTS

Levels of progesterone, 17-hydroxyprogesterone, cortisol, testosterone, androstenedione, and DHEAS were found to be lower during the follicular phase of the menstrual cycle in patients diagnosed with idiopathic chronic constipation compared with respective healthy controls[44].

A lack of estriol, cortisol and testosterone was identified during the luteal phase of the cycle in the constipated group[45]. The high prevalence of idiopathic constipation in pre-menopausal women is likely a result of the high affinity of progesterone for progesterone receptors together with the non-specific affinity for adrenal androgen receptors, and the lack of a stimulatory effect of estrogen on the wall of the bowel[45].

MEASUREMENT OF DHEAS/CORTISOL RATIO AND PSYCHOLOGICAL VARIABLES

A deficiency of DHEAS is thus identified in depression and constipation and it would be impossible to rely on it for distinguishing depressed, severely constipated patients. However, estimates of DHEA-to-cortisol ratios in serum and saliva, are likely to be more reliable than concentrations of either hormone alone, with lower morning ratios seen in depression[46-48]. The molar DHEAS/cortisol ratio was significantly lower in non-medicated depressed patients than in controls, and the evening salivary DHEA/cortisol ratio was inversely correlated with the length of the current depressive episode[49]. Morning salivary DHEA hyposecretion as well as evening cortisol hypersecretion were significantly and independently associated with major depression in young patients[49].

IMPLICATIONS IN RESEARCH AND IN CLINICAL PRACTICE

This review hypothesizes that measurement of the DHEAS/cortisol ratio in constipated patients could filter out those patients with a psychological disorder and improve the outcome after surgery.

For assessing the credibility of this measurement, a well-designed study needs to be conducted. The recruited constipated patients should have no personal or family background of a major psychological disorder. Participants should be asked to complete a stool diary. In this diary, they would be asked to report on the frequency, shape, consistency of stool, and whether they strained at defecation or not. The starting day would be their first menstruating day of the nearest menstruation cycle and the end would be the commencement of the next one. They would comment on the day and timing of defecation, stool consistency, stool form and the presence or absence of straining at stool.

They would also be asked to give 3 blood samples and 3 samples of saliva in any day during the mid-follicular period (days 7-10). The first samples would be collected early in the morning, the second on the afternoon and the third would be collected early in the evening.

Similarly, the same process would be repeated in any day during the mid-luteal period (days 18-20) to measure the DHEAS/cortisol ratio in serum and in saliva. The whole process would be repeated over the second consecutive menstrual cycle to obtain an average of each measurement. On these 2 d, participants would also be asked to fill in the Hospital Anxiety & Depression Scale questionnaire and General Health Questionnaire.

During the mid luteal period, the value of the DHEAS/cortisol ratio is supposed to be higher than that during the mid-follicular period in purely constipated patients. Because of ovarian secretions during the luteal phase, the concentration of DHEAS would be nearly normal but that of cortisol would still be low. However, in mixed cases, the ratio would be low, and in particular in the early morning samples.

CONCLUSION

The use of self-assessment questionnaires for excluding a psychological disorder in severely constipated patients seems insufficient, but the idea of measuring serum and salivary DHEAS/cortisol ratios before embarking upon invasive treatments appears to be more specific. This conclusion warrants confirmation in well-designed studies.

REFERENCES

1 **Donald IP**, Smith RG, Cruikshank JG, Elton RA, Stoddart ME. A study of constipation in the elderly living at home. *Gerontology* 1985; **31**: 112-118

2 **Heymen S**, Wexner SD, Gulledge AD. MMPI assessment of patients with functional bowel disorders. *Dis Colon Rectum* 1993 ; **36**: 593-596

3 **Sonnenberg A**, Tsou VT, Müller AD. The "institutional colon": a frequent colonic dysmotility in psychiatric and neurologic disease. *Am J Gastroenterol* 1994; **89**: 62-66

4 **Chami TN**, Andersen AE, Crowell MD, Schuster MM, Whitehead WE. Gastrointestinal symptoms in bulimia nervosa: effects of treatment. *Am J Gastroenterol* 1995; **90**: 88-92

5 **Meiring PJ**, Joubert G. Constipation in elderly patients attending a polyclinic. *S Afr Med J* 1998; **88**: 888-890

6 **Caranasos G**, Busby J. Sleep disorders, constipation, and pain: George Caranasos and Jan Busby. Interview by Richard L. Peck. *Geriatrics* 1985; **40**: 87-88, 90

7 **Devroede G**, Girard G, Bouchoucha M, Roy T, Black R, Camerlain M, Pinard G, Schang JC, Arhan P. Idiopathic constipation by colonic dysfunction. Relationship with personality and anxiety. *Dig Dis Sci* 1989; **34**: 1428-1433

8 **Brook A**. Bowel distress and emotional conflict. *J R Soc Med* 1991; **84**: 39-42

9 **Whitehead WE**. Twin studies used to prove that the comorbidity of major depressive disorder with IBS is NOT influenced by heredity. *Am J Gastroenterol* 2007; **102**: 2230-2231

10 **Blandizzi C**. Enteric alpha-2 adrenoceptors: pathophysiological implications in functional and inflammatory bowel disorders. *Neurochem Int* 2007; **51**: 282-288

11 **Martelli H**, Devroede G, Arhan P, Duguay C. Mechanisms of idiopathic constipation: outlet obstruction. *Gastroenterology* 1978; **75**: 623-631

12 **Glia A**, Lindberg G. Quality of life in patients with different types of functional constipation. *Scand J Gastroenterol* 1997; **32**: 1083-1089

13 **Fisher SE**, Breckon K, Andrews HA, Keighley MR. Psychiatric screening for patients with faecal incontinence or chronic constipation referred for surgical treatment. *Br J Surg* 1989; **76**: 352-355

14 **Ghosh S**, Papachrysostomou M, Batool M, Eastwood MA. Long-term results of subtotal colectomy and evidence of noncolonic involvement in patients with idiopathic slow-transit constipation. *Scand J Gastroenterol* 1996; **31**: 1083-1091

15 **El-Tawal AM**. Effects of five different drinks on patients with Crohn's disease. *Scand J Gastroenterol* 2009; **44**: 764

16 **Sireling LI**, Paykel ES, Freeling P, Rao BM, Patel SP. Depression in general practice: case thresholds and diagnosis. *Br J Psychiatry* 1985; **147**: 113-119

17 **Sartorius N**, Ustün TB, Lecrubier Y, Wittchen HU. Depression comorbid with anxiety: results from the WHO study on psychological disorders in primary health care. *Br J Psychiatry* Suppl 1996; 38-43

18 **Longcope C**. Adrenal and gonadal androgen secretion in normal females. *Clin Endocrinol Metab* 1986; **15**: 213-228
19 **Fotherby K**. Biosynthesis of oestrogen. In: Makin HLJ, editor. Biochemistry of steroid hormones. Oxford: Blackwell Scientific, 1984: 207-229
20 **Nelson DH**. The Adrenal Cortex: Physiological function and disease. Philadelphia: WB Saunders, 1980: 1122
21 **Abraham GE**. Ovarian and adrenal contribution to peripheral androgens during the menstrual cycle. *J Clin Endocrinol Metab* 1974; **39**: 340-346
22 **Orth DN**, Kovacs WJ. The adrenal cortex. In: Wilson JD, Foster DW, Kronenberg HM, Larsen PR, editors. Williams textbook of Endocrinology. Philadelphia, Pa: WB Saunders, 1998: 517-664
23 **Lachelin GC**, Barnett M, Hopper BR, Brink G, Yen SS. Adrenal function in normal women and women with the polycystic ovary syndrome. *J Clin Endocrinol Metab* 1979; **49**: 892-898
24 **Rosenfeld RS**, Rosenberg BJ, Fukushima DK, Hellman L. 24-Hour secretory pattern of dehydroisoandrosterone and dehydroisoandrosterone sulfate. *J Clin Endocrinol Metab* 1975; **40**: 850-855
25 **Parker LN**, Odell WD. Control of adrenal androgen secretion. *Endocr Rev* 1980; **1**: 392-410
26 **McKenna TJ**, Fearon U, Clarke D, Cunningham SK. A critical review of the origin and control of adrenal androgens. *Baillieres Clin Obstet Gynaecol* 1997; **11**: 229-248
27 **Compagnone NA**, Mellon SH. Neurosteroids: biosynthesis and function of these novel neuromodulators. *Front Neuroendocrinol* 2000; **21**: 1-56
28 **Harrison NL**, Simmonds MA. Modulation of the GABA receptor complex by a steroid anaesthetic. *Brain Res* 1984; **323**: 287-292
29 **Maggi A**, Perez J. Progesterone and estrogens in rat brain: modulation of GABA (gamma-aminobutyric acid) receptor activity. *Eur J Pharmacol* 1984; **103**: 165-168
30 **Baulieu EE**. Neurosteroids: of the nervous system, by the nervous system, for the nervous system. *Recent Prog Horm Res* 1997; **52**: 1-32
31 **Baulieu EE**. Neurosteroids: a novel function of the brain. *Psychoneuroendocrinology* 1998; **23**: 963-987
32 **Bergeron R**, de Montigny C, Debonnel G. Potentiation of neuronal NMDA response induced by dehydroepiandrosterone and its suppression by progesterone: effects mediated via sigma receptors. *J Neurosci* 1996; **16**: 1193-1202
33 **Majewska MD**. Neurosteroids: endogenous bimodal modulators of the GABAA receptor. Mechanism of action and physiological significance. *Prog Neurobiol* 1992; **38**: 379-395
34 **Maurice T**, Grégoire C, Espallergues J. Neuro(active)steroids actions at the neuromodulatory sigma1 (sigma1) receptor: biochemical and physiological evidences, consequences in neuroprotection. *Pharmacol Biochem Behav* 2006; **84**: 581-597
35 **Mellon SH**, Griffin LD. Neurosteroids: biochemistry and clinical significance. *Trends Endocrinol Metab* 2002; **13**: 35-43
36 **Pérez-Neri I**, Montes S, Ojeda-López C, Ramírez-Bermúdez J, Ríos C. Modulation of neurotransmitter systems by dehydroepiandrosterone and dehydroepiandrosterone sulfate: mechanism of action and relevance to psychiatric disorders. *Prog Neuropsychopharmacol Biol Psychiatry* 2008; **32**: 1118-1130
37 **Rupprecht R**. Neuroactive steroids: mechanisms of action and neuropsychopharmacological properties. *Psychoneuroendocrinology* 2003; **28**: 139-168
38 **Rupprecht R**, di Michele F, Hermann B, Ströhle A, Lancel M, Romeo E, Holsboer F. Neuroactive steroids: molecular mechanisms of action and implications for neuropsychopharmacology. *Brain Res Brain Res Rev* 2001; **37**: 59-67
39 **Gartside S**, Griffith N, Kaura V, Ingram C. The neurosteroid dehydroepiandrosterone (DHEA) and its metabolites alter 5-HT neuronal activity via modulation of GABAA receptors. *J Psychopharmacol* 2009; Epub ahead of print
40 **Barrett-Connor E**, von Mühlen D, Laughlin GA, Kripke A. Endogenous levels of dehydroepiandrosterone sulfate, but not other sex hormones, are associated with depressed mood in older women: the Rancho Bernardo Study. *J Am Geriatr Soc* 1999; **47**: 685-691
41 **Morsink LF**, Vogelzangs N, Nicklas BJ, Beekman AT, Satterfield S, Rubin SM, Yaffe K, Simonsick E, Newman AB, Kritchevsky SB, Penninx BW. Associations between sex steroid hormone levels and depressive symptoms in elderly men and women: results from the Health ABC study. *Psychoneuroendocrinology* 2007; **32**: 874-883
42 **Schmidt PJ**, Murphy JH, Haq N, Danaceau MA, St Clair L. Basal plasma hormone levels in depressed perimenopausal women. *Psychoneuroendocrinology* 2002; **27**: 907-920
43 **Buckwalter JG**, Stanczyk FZ, McCleary CA, Bluestein BW, Buckwalter DK, Rankin KP, Chang L, Goodwin TM. Pregnancy, the postpartum, and steroid hormones: effects on cognition and mood. *Psychoneuroendocrinology* 1999; **24**: 69-84
44 **Kamm MA**, Farthing MJ, Lennard-Jones JE, Perry LA, Chard T. Steroid hormone abnormalities in women with severe idiopathic constipation. *Gut* 1991; **32**: 80-84
45 **Assies J**, Visser I, Nicolson NA, Eggelte TA, Wekking EM, Huyser J, Lieverse R, Schene AH. Elevated salivary dehydroepiandrosterone-sulfate but normal cortisol levels in medicated depressed patients: preliminary findings. *Psychiatry Res* 2004; **128**: 117-122
46 **Michael A**, Jenaway A, Paykel ES, Herbert J. Altered salivary dehydroepiandrosterone levels in major depression in adults. *Biol Psychiatry* 2000; **48**: 989-995
47 **Osran H**, Reist C, Chen CC, Lifrak ET, Chicz-DeMet A, Parker LN. Adrenal androgens and cortisol in major depression. *Am J Psychiatry* 1993; **150**: 806-809
48 **Young AH**, Gallagher P, Porter RJ. Elevation of the cortisol-dehydroepiandrosterone ratio in drug-free depressed patients. *Am J Psychiatry* 2002; **159**: 1237-1239
49 **Goodyer IM**, Herbert J, Altham PM, Pearson J, Secher SM, Shiers HM. Adrenal secretion during major depression in 8- to 16-year-olds, I. Altered diurnal rhythms in salivary cortisol and dehydroepiandrosterone (DHEA) at presentation. *Psychol Med* 1996; **26**: 245-256

S- Editor Tian L **L- Editor** Cant MR **E- Editor** Wang YR

World Journal of Gastroenterology

Online Submissions: http://www.wjgnet.com/1007-9327office
wjg@wjgnet.com
doi:10.3748/wjg.v16.i6.663

World J Gastroenterol 2010 February 14; 16(6): 663-672
ISSN 1007-9327 (print)

EDITORIAL

Iron: An emerging factor in colorectal carcinogenesis

Anita CG Chua, Borut Klopcic, Ian C Lawrance, John K Olynyk, Debbie Trinder

Anita CG Chua, Borut Klopcic, Ian C Lawrance, John K Olynyk, Debbie Trinder, School of Medicine and Pharmacology, The University of Western Australia, Fremantle Hospital, Fremantle 6160, Western Australia, Australia
Anita CG Chua, John K Olynyk, Debbie Trinder, Western Australian Institute for Medical Research, Fremantle Hospital, Fremantle 6160, Western Australia, Australia
Borut Klopcic, Ian C Lawrance, The Centre for Inflammatory Bowel Diseases, Fremantle Hospital, Fremantle 6160, Western Australia, Australia
Author contributions: Chua ACG and Klopcic B contributed equally to this work; Chua ACG, Klopcic B and Trinder D organised the Editorial; Chua ACG and Klopcic B wrote the Editorial; Trinder D, Lawrance IC and Olynyk JK revised the article.
Supported by Grants from the Cancer Council of Western Australia and Fremantle Hospital Medical Research Foundation
Correspondence to: Debbie Trinder, Professor, School of Medicine and Pharmacology, The University of Western Australia, Fremantle Hospital, PO Box 480, Fremantle 6160, Western Australia, Australia. debbie.trinder@uwa.edu.au
Telephone: +61-8-94313640 Fax: +61-8-94312977
Received: November 2, 2009 Revised: November 26, 2009
Accepted: December 3, 2009
Published online: February 14, 2010

Abstract

The carcinogenic potential of iron in colorectal cancer (CRC) is not fully understood. Iron is able to undergo reduction and oxidation, making it important in many physiological processes. This inherent redox property of iron, however, also renders it toxic when it is present in excess. Iron-mediated generation of reactive oxygen species *via* the Fenton reaction, if uncontrolled, may lead to cell damage as a result of lipid peroxidation and oxidative DNA and protein damage. This may promote carcinogenesis through increased genomic instability, chromosomal rearrangements as well as mutations of proto-oncogenes and tumour suppressor genes. Carcinogenesis is also affected by inflammation which is exacerbated by iron. Population studies indicate an association between high dietary iron intake and CRC risk. In this editorial, we examine the link between iron-induced oxidative stress and inflammation on the pathogenesis of CRC.

Key words: Iron; Haem; Colorectal cancer; Oxidative stress; Inflammation; Haemochromatosis

Peer reviewer: William Dickey, MD, PhD, Altnagelvin Hospital, Londonderry, BT47 6SB, Northern Ireland, United Kingdom

Chua ACG, Klopcic B, Lawrance IC, Olynyk JK, Trinder D. Iron: An emerging factor in colorectal carcinogenesis. *World J Gastroenterol* 2010; 16(6): 663-672 Available from: URL: http://www.wjgnet.com/1007-9327/full/v16/i6/663.htm DOI: http://dx.doi.org/10.3748/wjg.v16.i6.663

INTRODUCTION

Colorectal cancer (CRC) is the second most common cancer in developed countries. Apart from genetic mutations, environmental factors appear to play a role in intestinal carcinogenesis. Results from numerous population studies support the idea that dietary iron and/or elevated iron levels increase the risk of cancers including CRC, hepatocellular carcinoma (HCC) and lung cancer[1-6]. HCC occurs at a higher incidence in hereditary haemochromatosis (HH) patients with hepatic iron overload than in the normal population[7] and recently, an increased risk for CRC and breast cancer development in patients with HH has also been demonstrated[8,9]. Further support for a role of iron in carcinogenesis comes from animal studies. Multiple injections of iron compounds, such as iron dextran complex, ferric nitriloacetate and ferric saccharate in rodents result in the formation of sarcomas, renal cell carcinoma and mesothelioma, respectively[10-12]. Iron has also been implicated in intestinal carcinogenesis in rodent models of CRC[13,14].

Iron, whilst indispensable for life, can cause tissue injury through the formation of reactive oxygen species (ROS) and the high oxidative potential of iron and its

participation in oxidative stress-related carcinogenesis have been reviewed in detail elsewhere[15-17]. The excessive generation of oxidative stress can lead to carcinogenic events, and this has been the premise for the hypothesis that high iron levels may potentiate the risk of cancer. In addition, iron is a source of sustenance for cancer cell growth and proliferation. Cancer cell growth is enhanced by iron administration and has been shown to be retarded by both dietary iron deprivation[18] and treatment with iron chelators[19-21]. It is thought that genetic modifications and continual activation of the signalling pathways of cell proliferation by ROS synergistically promote carcinogenesis[16,22]. Chronic inflammation also induces cell oxidative stress, which promotes the onset of dysplasia[23] and is accompanied by a dysregulation in iron metabolism[24]. Nonetheless, the mechanistic link among iron, oxidative stress, inflammation and colorectal carcinogenesis remains to be elucidated.

CRC

The incidence of CRC varies among countries and this has been mainly attributed to environmental factors, although genetic factors are also important. Environmental risk factors for colorectal carcinogenesis include many dietary factors such as high red meat and alcohol consumption as well as low fibre and vegetable intake[25,26].

The majority of CRCs originate from pre-existing adenomatous polyps of the colonic mucosa[27]. These are defined as well demarcated masses of epithelial mucosa with increased crypt proliferation. Eventually, neoplastic cells migrate through the muscularis mucosa and it is once the basement membrane surrounding these cells is breached that the lesions are classified as malignant. These morphological and histopathological changes are accompanied by sequential dysregulation of key molecular pathways of cell division and tissue homeostasis[28]. Several syndromes have been described in families with a history of CRC, which involve mutations in components of these pathways[29]. Affected persons with familial adenomatous polyposis (FAP) develop hundreds of adenomatous polyps throughout their lifetime, some of which inevitably progress to malignancy. Genetic studies in subjects with FAP led to the discovery of the adenomatous polyposis coli (*APC*) gene, a key gene in the regulation of mucosal epithelial maturation *via* the Wnt signalling pathway[30,31]. In contrast, hereditary non-polyposis colorectal cancer (HNPCC) is characterised by an increased risk for developing CRC in the absence of a germ line mutation in the *APC* gene and is typically accompanied by the loss of DNA mismatch repair genes which impacts on other signalling pathways[32,33]. Although there is currently no evidence that iron plays a role in the pathology of these syndromes, it is interesting to note that iron can increase Wnt signalling in the absence of APC[34] and that mutations in the haemochromatosis gene (*HFE*) act as a genetic modifier of HNPCC disease expression[35].

Although there is a strong role for genes in the pathogenesis of CRC in the above-mentioned risk groups, environmental factors seem to play a more significant role. Population based studies have shown that in immigrant groups, the incidence of CRC changes towards that observed in the host country[36,37]. Another indication of the importance of environmental factors is that in Japan, a country with a traditionally low incidence of CRC, the rate has rapidly increased in recent years, a circumstance that has been primarily attributed to changes in life-style in the recent decades[29]. It is also interesting to note, that one of the highest incidences of CRC in the United States can be found in Japanese Hawaiians, highlighting the significance of environment *vs* genes[38].

Of the environmental risk factors, the diet is of particular interest since it impacts on the composition of the intestinal luminal contents, which are in direct contact with the colonic mucosa. Diets between countries vary significantly in their iron content and iron-rich food components, suggesting that iron intake could be one of the factors influencing CRC incidence in different populations. Dietary iron as an environmental modifier of CRC has been examined in population-based studies and there is evidence that both dietary iron[4,5,39] and/or increased body iron stores[1,2,40] enhance the risk of CRC.

IRON METABOLISM

Iron is a vital trace element participating in numerous biological and cellular processes such as electron transfer, oxygen transport and DNA synthesis as well as cell cycle progression and growth[41]. Iron absorption from the diet occurs mainly in the duodenum by a tightly regulated process. Most of the absorbed iron is utilized for erythropoiesis and any excessive iron is stored mainly in the liver[42]. Dietary iron occurs in two forms, haem iron from red meat and non-haem iron from plants and dairy products. Both forms of iron are taken up from the intestinal lumen into the enterocyte by different pathways. Haem iron is taken up as an intact metalloporphyrin by a haem transporter, the identity of which has yet to be confirmed. After entering the enterocyte, haem is broken down by haem oxygenase into free iron, biliverdin that is rapidly converted to bilirubin and carbon monoxide[43,44]. In contrast, non-haem ferric iron is reduced to ferrous iron by a ferrireductase and is then taken up by divalent metal transporter 1 at the apical surface of enterocytes. The iron from both sources enters a common intracellular iron pool and is stored as ferritin or transferred across the basolateral membrane of the enterocyte into the circulation by ferroportin. Upon release, iron is oxidised by hephaestin and binds to plasma transferrin. Transferrin-bound iron is taken up by cells *via* transferrin receptors. Iron absorption is inversely regulated by body iron levels, increasing during iron deficiency and decreasing in conditions of iron excess. Iron metabolism is regulated by the hepatic hormone, hepcidin, and its expression is controlled by many factors including iron stores, hypoxia, inflammation, anaemia and erythropoiesis[45,46]. The regulation of cellular iron metabolism has been extensively reviewed elsewhere[42,47-49].

Iron and CRC risk

The association between dietary iron and CRC risk has been examined in many population-based studies. A meta-analysis of studies investigating dietary iron intake, body iron stores and CRC demonstrated a positive correlation between iron in the diet and CRC risk[50]. Notably, two large prospective cohort studies have found that high iron intake and CRC risk were associated with other factors such as a high fat diet or bile acids[4,5] and at least three other case control studies have corroborated the positive correlation between dietary iron and CRC[39,51,52]. Of the studies analysing body iron stores and CRC, one large cohort study observed an association between transferrin saturation and CRC risk[2] whilst three case control studies found a positive correlation between serum ferritin levels and the formation of colorectal adenomatous polyps[1,40,53]. Other studies, however, reported inverse correlations between transferrin saturation[54] or ferritin levels[5] and CRC risk. The role of body iron stores in CRC appears more complex than that of dietary iron and the influence of genetic factors on body iron stores will be discussed in more detail below.

The effect of high red meat consumption, as a dietary source of iron, on the pathogenesis of CRC has been of considerable interest. Red meat is a major component of the human diet in some societies and contains a high amount of myoglobin and haemoglobin. Both contain haem, a porphyrin structure that contains a central iron atom and it has been suggested that the haem content in red meat promotes colorectal carcinogenesis[55,56]. A meta-analysis of 48 studies specifically addressing red meat consumption showed a significantly increased risk of developing CRC in people with a high intake of red meat as well as processed meat in most of the studies[57]. Of interest is a recent very large prospective cohort study investigating nutrition and disease that described an increased risk of CRC in people who consumed red meat rich in haem, whilst no increased risk was identified for poultry and an inverse correlation was observed for fish, both of which have a lower haem content[58]. Another two prospective cohort studies also reported that haem iron was associated with a higher risk of CRC especially in those who consumed alcohol[59] or those with a low intake of chlorophyll[26]. It is, however, unclear whether the effects of red meat on colorectal carcinogenesis are due to haem, the iron bound to haem, or a combination of both.

HH is a common disorder of iron metabolism that usually results from a homozygous C282Y mutation in the *HFE* gene. HFE protein is a key regulator of hepcidin, and in HH, the HFE-mediated regulation of hepcidin is impaired resulting in excessive absorption of iron and increased deposition of iron primarily in the liver[47,60]. As mentioned earlier, these individuals have an increased risk of developing CRC. This is exemplified by the recent findings that patients homozygous for the C282Y mutation have a 2.4-fold increased risk of developing CRC[9]. This is of particular significance considering that the C282Y mutation is one of the most abundant autosomal mutations in some Western societies with homozygosity rates ranging from 1/102 in Northern Ireland to less than 1/100 000 in Greece[61]. The homozygosity rate of 1/385 in the United States of America calculates as an estimated number of 718 000 affected individuals with an increased risk of CRC[61]. Another study describing a 7.7-fold increased risk of developing CRC in patients with homozygous mutations in both *HFE* and *TFR1* genes, further implicates a dysregulation in iron metabolism as a possible mechanism contributing to colorectal carcinogenesis[62]. An increased risk for CRC has also been described for compound C282Y/H63D heterozygotes, single C282Y or H63D heterozygotes and H63D homozygotes[35,63-65], but not all studies detected a significant correlation between *HFE* mutations and CRC[65-73]. Knekt *et al*[2], however, reported a 3-fold increased risk for CRC that was associated with a transferrin saturation level exceeding 60% in a large cohort from Finland, which may include subjects with mutations in the *HFE* gene. Furthermore, systemic iron reduction by phlebotomy decreases visceral malignancies and mortality in patients with peripheral arterial disease[74] and in blood donors the number of non-haematological malignancies is significantly reduced[75] indicating that reduction of iron levels might decrease CRC risk. The availability of mouse models of HH enables future studies to investigate the interaction of dietary iron, regulation of body iron stores and colorectal carcinogenesis.

Role of luminal iron in colorectal carcinogenesis

There is evidence suggesting that significant iron absorption may occur in the colon[76,77]. Increased iron intake results in higher levels of iron in colonic epithelial cells in rats[78], and although divalent metal transporter 1, ferroportin and hephaestin mRNA expression is highest in the duodenum and decreases along with the length of the small intestine[79], their expression is still relatively high in the colon, especially hephaestin and ferroportin. These findings suggest that there may be significant colonic iron transport, which impacts on cell proliferation and cancer development. In a recent study, it was shown that there was increased iron staining in human colorectal tumours[80]. The expression of proteins involved in cellular iron uptake such as divalent metal transporter 1 and transferrin receptor 1 was also upregulated. The expression of the iron exporter, ferroportin, was increased but it was located intracellularly whilst hephaestin expression was decreased, suggesting decreased release of iron from the cells. These results suggest that the retention of iron by tumours may facilitate cell proliferation.

Further support for the concept of iron as a risk factor for CRC has been demonstrated in animal studies. Elevated dietary iron levels increased the incidence of tumours in rodent models of CRC induced by inflammatory or carcinogenic agents[13,14]. In these experiments, however, iron was supplemented with inorganic carbonyl iron, a form that does not constitute a major component of natural diets. Interestingly, in the inflammatory model, Seril and colleagues demonstrated that systemic iron supplementation did not increase tumour incidence. This

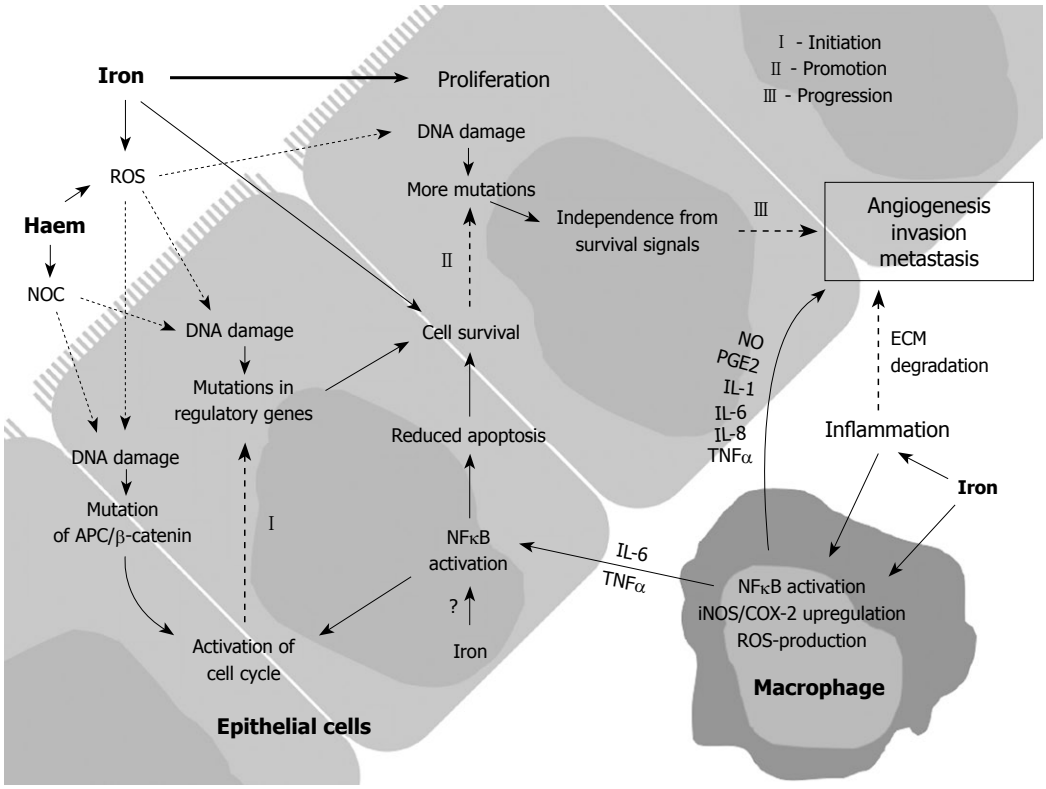

Figure 1 Potential roles of iron in the development of colorectal cancer. Luminal iron may cause DNA damage through the generation of reactive oxygen species (ROS) *via* the Fenton reaction. Haem may also stimulate the production of N-nitroso compounds (NOC) in the colon which are mutagenic. (Ⅰ) In the initiation phase of tumorigenesis, DNA damage leads to mutations in key genes regulating cell proliferation and survival such as APC or β-catenin of the Wnt pathway; (Ⅱ) In the promotion phase, the increase in cell proliferation and survival due to the deleterious effects of NOC and ROS leads to further genetic instability and an accumulation of more mutations. Iron is an important nutrient required for proliferation during this phase. Iron also increases intestinal inflammation and the pro-inflammatory cytokines, TNFα and IL-6 released from inflammatory cells increase cell survival through inhibition of apoptosis *via* the activation of NFκB; (Ⅲ) In the progression phase, tumour cells gain independence from survival signals and progress towards a malignant phenotype. Iron has been shown to activate NFκB increasing inducible nitric oxide synthase (iNOS) and cyclo-oxygenase (COX)-2 expression in macrophages. Activated macrophages produce more ROS, increase infiltration through degradation of the extracellular matrix (ECM) and promote angiogenesis by release of nitric oxide (NO), prostaglandin E2 (PGE2), IL-1, -6 and -8 as well as TNFα, ultimately leading to tissue invasion and metastasis.

suggests that increased luminal iron but not systemic iron levels increase colorectal carcinogenesis in an inflammatory model of CRC[81]. In a carcinogen-induced CRC model, the number of preneoplastic lesions increased with the amount of haem in the diet[82]. Haem iron is more bioavailable than non-haem iron and has been shown to increase mucosal proliferation and cytotoxicity, indicating that haem may have a greater propensity for inducing malignancy compared with other forms of dietary iron[55,56]. Haem has been shown to stimulate the production of endogenous N-nitroso compounds in the large intestine after red meat ingestion, many of which are pro-carcinogenic[83]. The genotoxic effect of haem has also been demonstrated in human colonic cells, where DNA damage was induced by haemoglobin and haemin[84]. The exact mechanism by which luminal iron (haem and/or non-haem), iron transport, systemic iron levels and their regulation impact the pathogenesis of CRC, however, remains to be elucidated.

Iron and molecular pathways of colorectal carcinogenesis

Colorectal carcinogenesis is a multi-step process involving the formation of adenomatous polyps and their subsequent progression to malignancy. At the molecular level, this process is reflected by sequential events of gene mutation and activation of key molecular pathways[85,86]. Some of these pathways may be altered by iron and iron-mediated generation of ROS (Figure 1). The *APC* gene was initially identified in patients with FAP and subsequently shown to be mutated in > 80% of human colorectal neoplasia[85]. *APC* mutations involved in carcinogenesis led to nuclear accumulation of β-catenin and constitutive activation of the wnt/β-catenin/T cell factor (TCF) signalling pathway. In rodent models of azoxymethane-induced CRC, the majority of colonic tumours harbour mutations in *APC* and/or *β-catenin* genes[87,88]. Activation of the wnt/β-catenin/TCF pathway results in increased expression of cyclin D1 and c-myc, both of which are positive regulators of cell proliferation[89,90]. Iron has been implicated in *APC* loss[34] and iron chelators decrease the expression of cyclin D1 and c-myc[41].

The molecular pathogenesis of ulcerative colitis-associated colorectal carcinogenesis has been extensively studied[91]. Events such as chromosomal and microsatellite instability and alterations in tumour suppressor genes (*p53* and *APC* mutations) and DNA mismatch repair genes have been documented[92,93]. The inhibitor of NFκB kinase

(IKKβ)/nuclear factor kappa B (NFκB) signalling pathway constitutes a key molecular link between inflammation and carcinogenesis. NFκB is activated in colorectal carcinogenesis and is influenced by both inflammation and oxidative stress[94]. NFκB targets the genes that control cell proliferation, apoptosis, angiogenesis and metastasis[94,95]. A direct stimulatory effect of iron on NFκB signalling has also been demonstrated in hepatic macrophages[96,97].

Other pathways involved in colorectal carcinogenesis include cyclo-oxygenase (COX)-2 mediated prostaglandin E2 synthesis and inducible nitric oxide synthase (iNOS)-mediated generation of nitric oxide[98]. Prostaglandin E2 is involved in regulating angiogenesis and inhibiting apoptosis[99] whilst iNOS activity induces DNA damage and promotes microvascularisation[100]. Both COX-2 and iNOS are frequently over-expressed in human CRC[101,102] and inhibition of their activity has been shown to decrease tumorigenesis in rodent models of CRC[103,104]. Furthermore, iNOS is a target of the wnt/β-catenin/TCF pathway and its production of ROS through nitric oxide is catalysed by iron[105].

OXIDATIVE STRESS AND COLORECTAL CARCINOGENESIS

Oxidative stress occurs when the body or cell is unable to combat the deleterious effects of overproduction of oxidants or free radicals due to decreased anti-oxidant activity to counterbalance or eliminate them. Oxidative stress is related to many pathological conditions such as infection, inflammation, iron and other transition metal overload. It has also been implicated in carcinogenesis[15,106,107]. Although many reactive species and free radicals such as reactive nitrogen species contribute to oxidative stress, the role of ROS in colorectal carcinogenesis will mainly be discussed here. ROS is generated through the partial reduction of oxygen which results in superoxide anion, singlet oxygen, hydrogen peroxide and hydroxyl radical formation. ROS plays a dual role in biological systems. When the balance between oxidant and anti-oxidant activity is maintained, ROS can participate as secondary messengers in intracellular signal transduction cascades, whilst the presence of excessive ROS induces tissue damage.

Iron is a strong oxidant and when present at high levels, it generates ROS *via* the Haber-Weiss-Fenton reaction. Iron-mediated generation of ROS can cause oxidative damage to lipids, nucleic acids or proteins[86]. Oxidative damage to proteins and lipids can generate reactive intermediates that can couple to DNA bases resulting in DNA lesions[86]. DNA damage as a consequence of prolonged oxidative stress can result in mutation of proto-oncogenes and tumour suppressor genes, microsatellite instability and chromosomal rearrangements as well as a dysregulation in transcription, signal transduction and replication, all of which are associated with carcinogenesis[15,86,108]. Haem is also an oxidant[109], and despite being essential for many biological processes and enzyme systems, excessive free haem catalyses ROS production, resulting in oxidative stress[110]. The degradation of haem by haem oxygenase-1 alleviates oxidative stress[111] and bilirubin, a by-product of haem breakdown, is anti-oxidative and has been shown to scavenge peroxyl radicals in plasma[112,113]. In mice lacking copper-and zinc-containing superoxide dismutase, oxidative damage is pervasive and the rate of liver cancer development is increased later in life[114] whilst, mice with decreased manganese-containing superoxide dismutase activity have an increased risk for lymphoma and adenocarcinoma[115]. These results suggest that reduced anti-oxidant activity can lead to cancer.

Oxidative stress is enhanced in neoplastic tissue from the colonic mucosa of CRC patients[116,117]. In these patients, lipid peroxidation is increased in colonic tumours compared with normal mucosa[116]. In addition, there is a greater extent of DNA strand breakage in colonic mucosal cells isolated from neoplastic tissues compared with normal tissues from cancer patients[117]. Oxidative damage is also more evident in the earlier stages of CRC than in the more advanced stages of cancer. The accumulation of iron in a human colon cancer cell line has been shown to correlate with increased oxidative protein and DNA damage[118]. In rodent studies, mice and rats fed a diet high in iron[119-122] and haem[82] exhibited greater lipid peroxidation activity in the colon and increased colonic aberrant crypt foci, which are pre-neoplastic lesions[82,123,124]. Oxidative damage markers are increased in the colons of *Hfe* knockout mice[125], indicating an increased presence of ROS in these iron-loaded mice. Oxidative stress due to high iron and/or haem levels may, therefore, be instrumental in mediating colorectal carcinogenesis.

INFLAMMATION AND CRC

The relationship between inflammation and tumour development has been a major focus in recent cancer research. Persistent inflammation as a result of infection promotes carcinogenesis; for example, infection with hepatitis B and C and human papilloma viruses are associated with HCC and cervical cancer, respectively, whilst *Helicobacter pylori* infection is linked to gastric cancer[126]. Furthermore, subjects with inflammatory bowel disease such as ulcerative colitis and Crohn's disease suffer from recurring inflammation in the colonic mucosa and are at an increased risk of developing CRC[127].

Chronic inflammation and metabolites from phagocytic processes result in formation of excessive ROS and nitric oxide[98,128], which as mentioned above, can directly cause damage to DNA, protein or lipids. Inflammatory cells active in chronic inflammation are also present within a tumour and its surrounding tissue. This suggests that the presence of oxidative stress and the network of inflammatory cytokines and chemokines in a tumour microenvironment may perpetuate carcinogenesis by promoting genotoxicity, proliferation and survival as well as angiogenesis, cell invasion and metastasis[129]. Cytokines that are frequently associated with carcinogenesis include TNFα and IL-6, which promote cell proliferation and

survival[130]. Angiogenesis, invasion and metastasis are influenced by the cytokines, TNFα, IL-1, -6 and -8[129].

CRC occurs in approximately 4% of patients with ulcerative colitis[131] where the risk for CRC has been reported to be approximately 10-fold higher than in the normal population[127,132]. The risk for cancer increases with longer duration and the extent of colon affected by this disease, and how well the inflammation is controlled, indicating that it is the prolonged inflammatory stimulus that directly affects the pathogenesis of CRC in these patients. In addition to the blood loss and iron deficiency due to the chronic intestinal inflammation, patients with ulcerative colitis and Crohn's disease may also develop iron deficiency anaemia secondary to inflammation and reduced mobilization of bone marrow iron and are frequently treated with oral iron supplementation. Hence, the effects of iron on colitis-associated colorectal carcinogenesis have also been examined. Chronic inflammation induced in mice treated with dextran sodium sulphate resulted in colorectal tumorigenesis which became worse with dietary iron supplementation, indicating the tumour-promoting role of iron when inflammation was present[13]. This was accompanied by the increased presence of enhanced nitrotyrosine and iNOS expression, which implicates a role for oxidative stress in inflammation-associated carcinogenesis. Further evidence comes from experimental models where colitis is attenuated when anti-oxidant activity is increased[133,134]. In addition, the formation of pro-oxidants due to increased activity of phagocytic leukocytes in the colons of ulcerative colitis patients has been reported[135]. These findings suggest that oxidative stress induced by both inflammation and iron plays a major role in inflammation-associated colorectal carcinogenesis.

Better understanding about the relationship between inflammation and iron metabolism has been achieved since the identification of hepcidin. Inflammation affects iron homeostasis by inducing hepcidin through an IL-6-mediated pathway[45]. Increased hepcidin levels caused decreased iron absorption[136,137] as well as iron retention by reticulo-endothelial macrophages, which may result in hypoferraemia (low serum iron concentration)[138]. Hypoferraemia is associated with the anaemia of chronic disease, also known as anaemia of inflammation. Haem, like iron, is pro-inflammatory and increases the expression of inflammatory adhesion molecules in endothelial cells[109]. Haem oxygenase 1 knockout mice suffer from anaemia, tissue iron loading and severe inflammation, having enlarged spleens and lymph nodes, vasculitis and inflammatory cell infiltrates in the liver[139]. Carbon monoxide, a by-product of haem degradation, ameliorates inflammation in a mouse model of colitis[140]. High dietary iron and/or haem levels are likely to contribute to the pathogenesis of inflammation-associated colorectal carcinogenesis.

FUTURE PERSPECTIVES

Population-based studies as well as animal studies point to a role for dietary and/or systemic body iron levels in colorectal carcinogenesis. The effect of high iron levels on regulatory pathways of iron metabolism through HFE and hepcidin as well as the increased production of ROS in the presence of iron provide potential mechanisms. The interference of high iron levels with ROS and/or inflammation and their effects on pathways involved in colorectal carcinogenesis remains poorly understood. Future studies in mouse models of HH, dietary iron overload and colorectal carcinogenesis will provide valuable insights into this fascinating aspect of iron biology and CRC.

REFERENCES

1 **Nelson RL**, Davis FG, Sutter E, Sobin LH, Kikendall JW, Bowen P. Body iron stores and risk of colonic neoplasia. *J Natl Cancer Inst* 1994; **86**: 455-460

2 **Knekt P**, Reunanen A, Takkunen H, Aromaa A, Heliövaara M, Hakulinen T. Body iron stores and risk of cancer. *Int J Cancer* 1994; **56**: 379-382

3 **Hsing AW**, McLaughlin JK, Olsen JH, Mellemkjar L, Wacholder S, Fraumeni JF Jr. Cancer risk following primary hemochromatosis: a population-based cohort study in Denmark. *Int J Cancer* 1995; **60**: 160-162

4 **Wurzelmann JI**, Silver A, Schreinemachers DM, Sandler RS, Everson RB. Iron intake and the risk of colorectal cancer. *Cancer Epidemiol Biomarkers Prev* 1996; **5**: 503-507

5 **Kato I**, Dnistrian AM, Schwartz M, Toniolo P, Koenig K, Shore RE, Zeleniuch-Jacquotte A, Akhmedkhanov A, Riboli E. Iron intake, body iron stores and colorectal cancer risk in women: a nested case-control study. *Int J Cancer* 1999; **80**: 693-698

6 **Zhou W**, Park S, Liu G, Miller DP, Wang LI, Pothier L, Wain JC, Lynch TJ, Giovannucci E, Christiani DC. Dietary iron, zinc, and calcium and the risk of lung cancer. *Epidemiology* 2005; **16**: 772-779

7 **Niederau C**, Fischer R, Sonnenberg A, Stremmel W, Trampisch HJ, Strohmeyer G. Survival and causes of death in cirrhotic and in noncirrhotic patients with primary hemochromatosis. *N Engl J Med* 1985; **313**: 1256-1262

8 **Kallianpur AR**, Hall LD, Yadav M, Christman BW, Dittus RS, Haines JL, Parl FF, Summar ML. Increased prevalence of the HFE C282Y hemochromatosis allele in women with breast cancer. *Cancer Epidemiol Biomarkers Prev* 2004; **13**: 205-212

9 **Osborne NJ**, Gurrin LC, Allen KJ, Constantine CC, Delatycki MB, McLaren CE, Gertig DM, Anderson GJ, Southey MC, Olynyk JK, Powell LW, Hopper JL, Giles GG, English DR. HFE C282Y homozygotes are at increased risk of breast and colorectal cancer. *Hepatology* 2010; In press

10 **Richmond HG**. Induction of sarcoma in the rat by iron-dextran complex. *Br Med J* 1959; **1**: 947-949

11 **Li JL**, Okada S, Hamazaki S, Ebina Y, Midorikawa O. Subacute nephrotoxicity and induction of renal cell carcinoma in mice treated with ferric nitrilotriacetate. *Cancer Res* 1987; **47**: 1867-1869

12 **Okada S**, Hamazaki S, Toyokuni S, Midorikawa O. Induction of mesothelioma by intraperitoneal injections of ferric saccharate in male Wistar rats. *Br J Cancer* 1989; **60**: 708-711

13 **Seril DN**, Liao J, Ho KL, Warsi A, Yang CS, Yang GY. Dietary iron supplementation enhances DSS-induced colitis and associated colorectal carcinoma development in mice. *Dig Dis Sci* 2002; **47**: 1266-1278

14 **Ilsley JN**, Belinsky GS, Guda K, Zhang Q, Huang X, Blumberg JB, Milbury PE, Roberts LJ 2nd, Stevens RG, Rosenberg DW. Dietary iron promotes azoxymethane-induced colon tumors in mice. *Nutr Cancer* 2004; **49**: 162-169

15 **Klaunig JE**, Kamendulis LM. The role of oxidative stress in

carcinogenesis. *Annu Rev Pharmacol Toxicol* 2004; **44**: 239-267
16 **Galaris D**, Skiada V, Barbouti A. Redox signaling and cancer: the role of "labile" iron. *Cancer Lett* 2008; **266**: 21-29
17 **Toyokuni S**. Role of iron in carcinogenesis: cancer as a ferrotoxic disease. *Cancer Sci* 2009; **100**: 9-16
18 **Weinberg ED**. Iron withholding: a defense against infection and neoplasia. *Physiol Rev* 1984; **64**: 65-102
19 **Kicic A**, Chua AC, Baker E. The desferrithiocin (DFT) class of iron chelators: potential as antineoplastic agents. *Anticancer Drug Des* 2001; **16**: 195-207
20 **Kicic A**, Chua AC, Baker E. Effect of iron chelators on proliferation and iron uptake in hepatoma cells. *Cancer* 2001; **92**: 3093-3110
21 **Yuan J**, Lovejoy DB, Richardson DR. Novel di-2-pyridyl-derived iron chelators with marked and selective antitumor activity: in vitro and in vivo assessment. *Blood* 2004; **104**: 1450-1458
22 **Toyokuni S**, Okamoto K, Yodoi J, Hiai H. Persistent oxidative stress in cancer. *FEBS Lett* 1995; **358**: 1-3
23 **Rakoff-Nahoum S**. Why cancer and inflammation? *Yale J Biol Med* 2006; **79**: 123-130
24 **Ganz T**, Nemeth E. Iron sequestration and anemia of inflammation. *Semin Hematol* 2009; **46**: 387-393
25 **Bingham SA**, Day NE, Luben R, Ferrari P, Slimani N, Norat T, Clavel-Chapelon F, Kesse E, Nieters A, Boeing H, Tjønneland A, Overvad K, Martinez C, Dorronsoro M, Gonzalez CA, Key TJ, Trichopoulou A, Naska A, Vineis P, Tumino R, Krogh V, Bueno-de-Mesquita HB, Peeters PH, Berglund G, Hallmans G, Lund E, Skeie G, Kaaks R, Riboli E. Dietary fibre in food and protection against colorectal cancer in the European Prospective Investigation into Cancer and Nutrition (EPIC): an observational study. *Lancet* 2003; **361**: 1496-1501
26 **Balder HF**, Vogel J, Jansen MC, Weijenberg MP, van den Brandt PA, Westenbrink S, van der Meer R, Goldbohm RA. Heme and chlorophyll intake and risk of colorectal cancer in the Netherlands cohort study. *Cancer Epidemiol Biomarkers Prev* 2006; **15**: 717-725
27 **Tanaka T**. Colorectal carcinogenesis: Review of human and experimental animal studies. *J Carcinog* 2009; **8**: 5
28 **Vogelstein B**, Fearon ER, Hamilton SR, Kern SE, Preisinger AC, Leppert M, Nakamura Y, White R, Smits AM, Bos JL. Genetic alterations during colorectal-tumor development. *N Engl J Med* 1988; **319**: 525-532
29 **Potter JD**. Colorectal cancer: molecules and populations. *J Natl Cancer Inst* 1999; **91**: 916-932
30 **Bodmer WF**, Bailey CJ, Bodmer J, Bussey HJ, Ellis A, Gorman P, Lucibello FC, Murday VA, Rider SH, Scambler P. Localization of the gene for familial adenomatous polyposis on chromosome 5. *Nature* 1987; **328**: 614-616
31 **Leppert M**, Dobbs M, Scambler P, O'Connell P, Nakamura Y, Stauffer D, Woodward S, Burt R, Hughes J, Gardner E. The gene for familial polyposis coli maps to the long arm of chromosome 5. *Science* 1987; **238**: 1411-1413
32 **Bronner CE**, Baker SM, Morrison PT, Warren G, Smith LG, Lescoe MK, Kane M, Earabino C, Lipford J, Lindblom A. Mutation in the DNA mismatch repair gene homologue hMLH1 is associated with hereditary non-polyposis colon cancer. *Nature* 1994; **368**: 258-261
33 **Rodriguez-Bigas MA**, Boland CR, Hamilton SR, Henson DE, Jass JR, Khan PM, Lynch H, Perucho M, Smyrk T, Sobin L, Srivastava S. A National Cancer Institute Workshop on Hereditary Nonpolyposis Colorectal Cancer Syndrome: meeting highlights and Bethesda guidelines. *J Natl Cancer Inst* 1997; **89**: 1758-1762
34 **Brookes MJ**, Boult J, Roberts K, Cooper BT, Hotchin NA, Matthews G, Iqbal T, Tselepis C. A role for iron in Wnt signalling. *Oncogene* 2008; **27**: 966-975
35 **Shi Z**, Johnstone D, Talseth-Palmer BA, Evans TJ, Spigelman AD, Groombridge C, Milward EA, Olynyk JK, Suchy J, Kurzawski G, Lubinski J, Scott RJ. Haemochromatosis HFE gene polymorphisms as potential modifiers of hereditary nonpolyposis colorectal cancer risk and onset age. *Int J Cancer* 2009; **125**: 78-83
36 **Haenszel W**. Cancer mortality among the foreign-born in the United States. *J Natl Cancer Inst* 1961; **26**: 37-132
37 **McMichael AJ**, Giles GG. Cancer in migrants to Australia: extending the descriptive epidemiological data. *Cancer Res* 1988; **48**: 751-756
38 **Parkin DM**, Muir CS. Cancer Incidence in Five Continents. Comparability and quality of data. *IARC Sci Publ* 1992; 45-173
39 **Senesse P**, Meance S, Cottet V, Faivre J, Boutron-Ruault MC. High dietary iron and copper and risk of colorectal cancer: a case-control study in Burgundy, France. *Nutr Cancer* 2004; **49**: 66-71
40 **Bird CL**, Witte JS, Swendseid ME, Shikany JM, Hunt IF, Frankl HD, Lee ER, Longnecker MP, Haile RW. Plasma ferritin, iron intake, and the risk of colorectal polyps. *Am J Epidemiol* 1996; **144**: 34-41
41 **Le NT**, Richardson DR. The role of iron in cell cycle progression and the proliferation of neoplastic cells. *Biochim Biophys Acta* 2002; **1603**: 31-46
42 **Chua AC**, Graham RM, Trinder D, Olynyk JK. The regulation of cellular iron metabolism. *Crit Rev Clin Lab Sci* 2007; **44**: 413-459
43 **Raffin SB**, Woo CH, Roost KT, Price DC, Schmid R. Intestinal absorption of hemoglobin iron-heme cleavage by mucosal heme oxygenase. *J Clin Invest* 1974; **54**: 1344-1352
44 **Montellano PR**. The mechanism of heme oxygenase. *Curr Opin Chem Biol* 2000; **4**: 221-227
45 **Nicolas G**, Chauvet C, Viatte L, Danan JL, Bigard X, Devaux I, Beaumont C, Kahn A, Vaulont S. The gene encoding the iron regulatory peptide hepcidin is regulated by anemia, hypoxia, and inflammation. *J Clin Invest* 2002; **110**: 1037-1044
46 **Viatte L**, Vaulont S. Hepcidin, the iron watcher. *Biochimie* 2009; **91**: 1223-1228
47 **Olynyk JK**, Trinder D, Ramm GA, Britton RS, Bacon BR. Hereditary hemochromatosis in the post-HFE era. *Hepatology* 2008; **48**: 991-1001
48 **Fleming MD**. The regulation of hepcidin and its effects on systemic and cellular iron metabolism. *Hematology Am Soc Hematol Educ Program* 2008; 151-158
49 **Zhang AS**, Enns CA. Iron homeostasis: recently identified proteins provide insight into novel control mechanisms. *J Biol Chem* 2009; **284**: 711-715
50 **Nelson RL**. Iron and colorectal cancer risk: human studies. *Nutr Rev* 2001; **59**: 140-148
51 **Freudenheim JL**, Graham S, Marshall JR, Haughey BP, Wilkinson G. A case-control study of diet and rectal cancer in western New York. *Am J Epidemiol* 1990; **131**: 612-624
52 **Deneo-Pellegrini H**, De Stéfani E, Boffetta P, Ronco A, Mendilaharsu M. Dietary iron and cancer of the rectum: a case-control study in Uruguay. *Eur J Cancer Prev* 1999; **8**: 501-508
53 **Tseng M**, Greenberg ER, Sandler RS, Baron JA, Haile RW, Blumberg BS, McGlynn KA. Serum ferritin concentration and recurrence of colorectal adenoma. *Cancer Epidemiol Biomarkers Prev* 2000; **9**: 625-630
54 **Herrinton LJ**, Friedman GD, Baer D, Selby JV. Transferrin saturation and risk of cancer. *Am J Epidemiol* 1995; **142**: 692-698
55 **Sesink AL**, Termont DS, Kleibeuker JH, Van der Meer R. Red meat and colon cancer: the cytotoxic and hyperproliferative effects of dietary heme. *Cancer Res* 1999; **59**: 5704-5709
56 **Sesink AL**, Termont DS, Kleibeuker JH, Van Der Meer R. Red meat and colon cancer: dietary haem, but not fat, has cytotoxic and hyperproliferative effects on rat colonic epithelium. *Carcinogenesis* 2000; **21**: 1909-1915
57 **Norat T**, Lukanova A, Ferrari P, Riboli E. Meat consumption

and colorectal cancer risk: dose-response meta-analysis of epidemiological studies. *Int J Cancer* 2002; **98**: 241-256
58 **Norat T**, Bingham S, Ferrari P, Slimani N, Jenab M, Mazuir M, Overvad K, Olsen A, Tjønneland A, Clavel F, Boutron-Ruault MC, Kesse E, Boeing H, Bergmann MM, Nieters A, Linseisen J, Trichopoulou A, Trichopoulos D, Tountas Y, Berrino F, Palli D, Panico S, Tumino R, Vineis P, Bueno-de-Mesquita HB, Peeters PH, Engeset D, Lund E, Skeie G, Ardanaz E, González C, Navarro C, Quirós JR, Sanchez MJ, Berglund G, Mattisson I, Hallmans G, Palmqvist R, Day NE, Khaw KT, Key TJ, San Joaquin M, Hémon B, Saracci R, Kaaks R, Riboli E. Meat, fish, and colorectal cancer risk: the European Prospective Investigation into cancer and nutrition. *J Natl Cancer Inst* 2005; **97**: 906-916
59 **Lee DH**, Anderson KE, Harnack LJ, Folsom AR, Jacobs DR Jr. Heme iron, zinc, alcohol consumption, and colon cancer: Iowa Women's Health Study. *J Natl Cancer Inst* 2004; **96**: 403-407
60 **Ayonrinde OT**, Milward EA, Chua AC, Trinder D, Olynyk JK. Clinical perspectives on hereditary hemochromatosis. *Crit Rev Clin Lab Sci* 2008; **45**: 451-484
61 **Heath AL**, Fairweather-Tait SJ. Health implications of iron overload: the role of diet and genotype. *Nutr Rev* 2003; **61**: 45-62
62 **Beckman LE**, Van Landeghem GF, Sikström C, Wahlin A, Markevärn B, Hallmans G, Lenner P, Athlin L, Stenling R, Beckman L. Interaction between haemochromatosis and transferrin receptor genes in different neoplastic disorders. *Carcinogenesis* 1999; **20**: 1231-1233
63 **Nelson RL**, Davis FG, Persky V, Becker E. Risk of neoplastic and other diseases among people with heterozygosity for hereditary hemochromatosis. *Cancer* 1995; **76**: 875-879
64 **Shaheen NJ**, Silverman LM, Keku T, Lawrence LB, Rohlfs EM, Martin CF, Galanko J, Sandler RS. Association between hemochromatosis (HFE) gene mutation carrier status and the risk of colon cancer. *J Natl Cancer Inst* 2003; **95**: 154-159
65 **Robinson JP**, Johnson VL, Rogers PA, Houlston RS, Maher ER, Bishop DT, Evans DG, Thomas HJ, Tomlinson IP, Silver AR. Evidence for an association between compound heterozygosity for germ line mutations in the hemochromatosis (HFE) gene and increased risk of colorectal cancer. *Cancer Epidemiol Biomarkers Prev* 2005; **14**: 1460-1463
66 **Altés A**, Gimferrer E, Capella G, Barceló MJ, Baiget M. Colorectal cancer and HFE gene mutations. *Haematologica* 1999; **84**: 479-480
67 **Macdonald GA**, Tarish J, Whitehall VJ, McCann SJ, Mellick GD, Buttenshaw RL, Johnson AG, Young J, Leggett BA. No evidence of increased risk of colorectal cancer in individuals heterozygous for the Cys282Tyr haemochromatosis mutation. *J Gastroenterol Hepatol* 1999; **14**: 1188-1191
68 **Nelson RL**, Persky V, Davis F, Becker E. Risk of disease in siblings of patients with hereditary hemochromatosis. *Digestion* 2001; **64**: 120-124
69 **Elmberg M**, Hultcrantz R, Ekbom A, Brandt L, Olsson S, Olsson R, Lindgren S, Lööf L, Stål P, Wallerstedt S, Almer S, Sandberg-Gertzén H, Askling J. Cancer risk in patients with hereditary hemochromatosis and in their first-degree relatives. *Gastroenterology* 2003; **125**: 1733-1741
70 **van der A DL**, van der Hel O, Roest M, van der Schouw YT, van Gils CH, Marx JJ, van Noord PA, Peeters PH. Heterozygosity for the Cys282Tyr mutation in the HFE gene and the risk of colorectal cancer (Netherlands). *Cancer Causes Control* 2003; **14**: 541-545
71 **McGlynn KA**, Sakoda LC, Hu Y, Schoen RE, Bresalier RS, Yeager M, Chanock S, Hayes RB, Buetow KH. Hemochromatosis gene mutations and distal adenomatous colorectal polyps. *Cancer Epidemiol Biomarkers Prev* 2005; **14**: 158-163
72 **Chan AT**, Ma J, Tranah GJ, Giovannucci EL, Rifai N, Hunter DJ, Fuchs CS. Hemochromatosis gene mutations, body iron stores, dietary iron, and risk of colorectal adenoma in women. *J Natl Cancer Inst* 2005; **97**: 917-926
73 **Ellervik C**, Birgens H, Tybjaerg-Hansen A, Nordestgaard BG. Hemochromatosis genotypes and risk of 31 disease endpoints: meta-analyses including 66,000 cases and 226,000 controls. *Hepatology* 2007; **46**: 1071-1080
74 **Zacharski LR**, Chow BK, Howes PS, Shamayeva G, Baron JA, Dalman RL, Malenka DJ, Ozaki CK, Lavori PW. Decreased cancer risk after iron reduction in patients with peripheral arterial disease: results from a randomized trial. *J Natl Cancer Inst* 2008; **100**: 996-1002
75 **Merk K**, Mattsson B, Mattsson A, Holm G, Gullbring B, Björkholm M. The incidence of cancer among blood donors. *Int J Epidemiol* 1990; **19**: 505-509
76 **Wheby MS**, Jones LG, Crosby WH. Studies on Iron Absorption. Intestinal Regulatory Mechanisms. *J Clin Invest* 1964; **43**: 1433-1442
77 **Chernelch M**, Fawwaz R, Sargent T, Winchell HS. Effect of phlebotomy and pH on iron absorption from the colon. *J Nucl Med* 1970; **11**: 25-27
78 **Jeffrey GP**, Basclain KA, Allen TL. Molecular regulation of transferrin receptor and ferritin expression in the rat gastrointestinal tract. *Gastroenterology* 1996; **110**: 790-800
79 **Frazer DM**, Vulpe CD, McKie AT, Wilkins SJ, Trinder D, Cleghorn GJ, Anderson GJ. Cloning and gastrointestinal expression of rat hephaestin: relationship to other iron transport proteins. *Am J Physiol Gastrointest Liver Physiol* 2001; **281**: G931-G939
80 **Brookes MJ**, Hughes S, Turner FE, Reynolds G, Sharma N, Ismail T, Berx G, McKie AT, Hotchin N, Anderson GJ, Iqbal T, Tselepis C. Modulation of iron transport proteins in human colorectal carcinogenesis. *Gut* 2006; **55**: 1449-1460
81 **Seril DN**, Liao J, Yang CS, Yang GY. Systemic iron supplementation replenishes iron stores without enhancing colon carcinogenesis in murine models of ulcerative colitis: comparison with iron-enriched diet. *Dig Dis Sci* 2005; **50**: 696-707
82 **Pierre F**, Freeman A, Taché S, Van der Meer R, Corpet DE. Beef meat and blood sausage promote the formation of azoxymethane-induced mucin-depleted foci and aberrant crypt foci in rat colons. *J Nutr* 2004; **134**: 2711-2716
83 **Cross AJ**, Pollock JR, Bingham SA. Haem, not protein or inorganic iron, is responsible for endogenous intestinal N-nitrosation arising from red meat. *Cancer Res* 2003; **63**: 2358-2360
84 **Glei M**, Klenow S, Sauer J, Wegewitz U, Richter K, Pool-Zobel BL. Hemoglobin and hemin induce DNA damage in human colon tumor cells HT29 clone 19A and in primary human colonocytes. *Mutat Res* 2006; **594**: 162-171
85 **Kinzler KW**, Vogelstein B. Lessons from hereditary colorectal cancer. *Cell* 1996; **87**: 159-170
86 **Valko M**, Rhodes CJ, Moncol J, Izakovic M, Mazur M. Free radicals, metals and antioxidants in oxidative stress-induced cancer. *Chem Biol Interact* 2006; **160**: 1-40
87 **Takahashi M**, Nakatsugi S, Sugimura T, Wakabayashi K. Frequent mutations of the beta-catenin gene in mouse colon tumors induced by azoxymethane. *Carcinogenesis* 2000; **21**: 1117-1120
88 **Takahashi M**, Wakabayashi K. Gene mutations and altered gene expression in azoxymethane-induced colon carcinogenesis in rodents. *Cancer Sci* 2004; **95**: 475-480
89 **He TC**, Sparks AB, Rago C, Hermeking H, Zawel L, da Costa LT, Morin PJ, Vogelstein B, Kinzler KW. Identification of c-MYC as a target of the APC pathway. *Science* 1998; **281**: 1509-1512
90 **Tetsu O**, McCormick F. Beta-catenin regulates expression of cyclin D1 in colon carcinoma cells. *Nature* 1999; **398**: 422-426
91 **Seril DN**, Liao J, Yang GY, Yang CS. Oxidative stress and ulcerative colitis-associated carcinogenesis: studies in

humans and animal models. *Carcinogenesis* 2003; **24**: 353-362
92 **Kern SE**, Redston M, Seymour AB, Caldas C, Powell SM, Kornacki S, Kinzler KW. Molecular genetic profiles of colitis-associated neoplasms. *Gastroenterology* 1994; **107**: 420-428
93 **Fogt F**, Zhuang Z, Poremba C, Dockhorn-Dworniczak B, Vortmeyer A. Comparison of p53 immunoexpression with allelic loss of p53 in ulcerative colitis-associated dysplasia and carcinoma. *Oncol Rep* 1998; **5**: 477-480
94 **Naugler WE**, Karin M. NF-kappaB and cancer-identifying targets and mechanisms. *Curr Opin Genet Dev* 2008; **18**: 19-26
95 **Grivennikov S**, Karin E, Terzic J, Mucida D, Yu GY, Vallabhapurapu S, Scheller J, Rose-John S, Cheroutre H, Eckmann L, Karin M. IL-6 and Stat3 are required for survival of intestinal epithelial cells and development of colitis-associated cancer. *Cancer Cell* 2009; **15**: 103-113
96 **She H**, Xiong S, Lin M, Zandi E, Giulivi C, Tsukamoto H. Iron activates NF-kappaB in Kupffer cells. *Am J Physiol Gastrointest Liver Physiol* 2002; **283**: G719-G726
97 **Xiong S**, She H, Takeuchi H, Han B, Engelhardt JF, Barton CH, Zandi E, Giulivi C, Tsukamoto H. Signaling role of intracellular iron in NF-kappaB activation. *J Biol Chem* 2003; **278**: 17646-17654
98 **Singer II**, Kawka DW, Scott S, Weidner JR, Mumford RA, Riehl TE, Stenson WF. Expression of inducible nitric oxide synthase and nitrotyrosine in colonic epithelium in inflammatory bowel disease. *Gastroenterology* 1996; **111**: 871-885
99 **Cianchi F**, Cortesini C, Bechi P, Fantappiè O, Messerini L, Vannacci A, Sardi I, Baroni G, Boddi V, Mazzanti R, Masini E. Up-regulation of cyclooxygenase 2 gene expression correlates with tumor angiogenesis in human colorectal cancer. *Gastroenterology* 2001; **121**: 1339-1347
100 **Jenkins DC**, Charles IG, Thomsen LL, Moss DW, Holmes LS, Baylis SA, Rhodes P, Westmore K, Emson PC, Moncada S. Roles of nitric oxide in tumor growth. *Proc Natl Acad Sci USA* 1995; **92**: 4392-4396
101 **Eberhart CE**, Coffey RJ, Radhika A, Giardiello FM, Ferrenbach S, DuBois RN. Up-regulation of cyclooxygenase 2 gene expression in human colorectal adenomas and adenocarcinomas. *Gastroenterology* 1994; **107**: 1183-1188
102 **Ambs S**, Merriam WG, Bennett WP, Felley-Bosco E, Ogunfusika MO, Oser SM, Klein S, Shields PG, Billiar TR, Harris CC. Frequent nitric oxide synthase-2 expression in human colon adenomas: implication for tumor angiogenesis and colon cancer progression. *Cancer Res* 1998; **58**: 334-341
103 **Ahn B**, Ohshima H. Suppression of intestinal polyposis in Apc(Min/+) mice by inhibiting nitric oxide production. *Cancer Res* 2001; **61**: 8357-8360
104 **Oshima M**, Murai N, Kargman S, Arguello M, Luk P, Kwong E, Taketo MM, Evans JF. Chemoprevention of intestinal polyposis in the Apcdelta716 mouse by rofecoxib, a specific cyclooxygenase-2 inhibitor. *Cancer Res* 2001; **61**: 1733-1740
105 **Philippe MA**, Ruddell RG, Ramm GA. Role of iron in hepatic fibrosis: one piece in the puzzle. *World J Gastroenterol* 2007; **13**: 4746-4754
106 **Halliwell B**. Oxidative stress and cancer: have we moved forward? *Biochem J* 2007; **401**: 1-11
107 **Toyokuni S**. Molecular mechanisms of oxidative stress-induced carcinogenesis: from epidemiology to oxygenomics. *IUBMB Life* 2008; **60**: 441-447
108 **Turker MS**, Gage BM, Rose JA, Elroy D, Ponomareva ON, Stambrook PJ, Tischfield JA. A novel signature mutation for oxidative damage resembles a mutational pattern found commonly in human cancers. *Cancer Res* 1999; **59**: 1837-1839
109 **Wagener FA**, Volk HD, Willis D, Abraham NG, Soares MP, Adema GJ, Figdor CG. Different faces of the heme-heme oxygenase system in inflammation. *Pharmacol Rev* 2003; **55**: 551-571
110 **Jeney V**, Balla J, Yachie A, Varga Z, Vercellotti GM, Eaton JW, Balla G. Pro-oxidant and cytotoxic effects of circulating heme. *Blood* 2002; **100**: 879-887
111 **Oates PS**, West AR. Heme in intestinal epithelial cell turnover, differentiation, detoxification, inflammation, carcinogenesis, absorption and motility. *World J Gastroenterol* 2006; **12**: 4281-4295
112 **Stocker R**, Glazer AN, Ames BN. Antioxidant activity of albumin-bound bilirubin. *Proc Natl Acad Sci USA* 1987; **84**: 5918-5922
113 **Minetti M**, Mallozzi C, Di Stasi AM, Pietraforte D. Bilirubin is an effective antioxidant of peroxynitrite-mediated protein oxidation in human blood plasma. *Arch Biochem Biophys* 1998; **352**: 165-174
114 **Elchuri S**, Oberley TD, Qi W, Eisenstein RS, Jackson Roberts L, Van Remmen H, Epstein CJ, Huang TT. CuZnSOD deficiency leads to persistent and widespread oxidative damage and hepatocarcinogenesis later in life. *Oncogene* 2005; **24**: 367-380
115 **Van Remmen H**, Ikeno Y, Hamilton M, Pahlavani M, Wolf N, Thorpe SR, Alderson NL, Baynes JW, Epstein CJ, Huang TT, Nelson J, Strong R, Richardson A. Life-long reduction in MnSOD activity results in increased DNA damage and higher incidence of cancer but does not accelerate aging. *Physiol Genomics* 2003; **16**: 29-37
116 **Rainis T**, Maor I, Lanir A, Shnizer S, Lavy A. Enhanced oxidative stress and leucocyte activation in neoplastic tissues of the colon. *Dig Dis Sci* 2007; **52**: 526-530
117 **Ribeiro ML**, Priolli DG, Miranda DD, Arçari DP, Pedrazzoli J Jr, Martinez CA. Analysis of oxidative DNA damage in patients with colorectal cancer. *Clin Colorectal Cancer* 2008; **7**: 267-272
118 **Núñez MT**, Tapia V, Toyokuni S, Okada S. Iron-induced oxidative damage in colon carcinoma (Caco-2) cells. *Free Radic Res* 2001; **34**: 57-68
119 **Younes M**, Trepkau HD, Siegers CP. Enhancement by dietary iron of lipid peroxidation in mouse colon. *Res Commun Chem Pathol Pharmacol* 1990; **70**: 349-354
120 **Rimbach G**, Markant A, Most E, Pallauf J. Liver and colon oxidant status in growing rats fed increasing levels of dietary iron. *J Trace Elem Med Biol* 1997; **11**: 99-104
121 **Carrier J**, Aghdassi E, Platt I, Cullen J, Allard JP. Effect of oral iron supplementation on oxidative stress and colonic inflammation in rats with induced colitis. *Aliment Pharmacol Ther* 2001; **15**: 1989-1999
122 **Lund EK**, Fairweather-Tait SJ, Wharf SG, Johnson IT. Chronic exposure to high levels of dietary iron fortification increases lipid peroxidation in the mucosa of the rat large intestine. *J Nutr* 2001; **131**: 2928-2931
123 **Liu Z**, Tomotake H, Wan G, Watanabe H, Kato N. Combined effect of dietary calcium and iron on colonic aberrant crypt foci, cell proliferation and apoptosis, and fecal bile acids in 1,2-dimethylhydrazine-treated rats. *Oncol Rep* 2001; **8**: 893-897
124 **Pierre F**, Taché S, Petit CR, Van der Meer R, Corpet DE. Meat and cancer: haemoglobin and haemin in a low-calcium diet promote colorectal carcinogenesis at the aberrant crypt stage in rats. *Carcinogenesis* 2003; **24**: 1683-1690
125 **Stevens RG**, Morris JE, Cordis GA, Anderson LE, Rosenberg DW, Sasser LB. Oxidative damage in colon and mammary tissue of the HFE-knockout mouse. *Free Radic Biol Med* 2003; **34**: 1212-1216
126 **Parkin DM**. The global health burden of infection-associated cancers in the year 2002. *Int J Cancer* 2006; **118**: 3030-3044
127 **Ekbom A**, Helmick C, Zack M, Adami HO. Ulcerative colitis and colorectal cancer. A population-based study. *N Engl J Med* 1990; **323**: 1228-1233
128 **Babbs CF**. Free radicals and the etiology of colon cancer. *Free Radic Biol Med* 1990; **8**: 191-200
129 **Balkwill F**, Mantovani A. Inflammation and cancer: back to Virchow? *Lancet* 2001; **357**: 539-545

130 **Lin WW**, Karin M. A cytokine-mediated link between innate immunity, inflammation, and cancer. *J Clin Invest* 2007; **117**: 1175-1183
131 **Eaden JA**, Abrams KR, Mayberry JF. The risk of colorectal cancer in ulcerative colitis: a meta-analysis. *Gut* 2001; **48**: 526-535
132 **Prior P**, Gyde SN, Macartney JC, Thompson H, Waterhouse JA, Allan RN. Cancer morbidity in ulcerative colitis. *Gut* 1982; **23**: 490-497
133 **Keshavarzian A**, Morgan G, Sedghi S, Gordon JH, Doria M. Role of reactive oxygen metabolites in experimental colitis. *Gut* 1990; **31**: 786-790
134 **Keshavarzian A**, Haydek J, Zabihi R, Doria M, D'Astice M, Sorenson JR. Agents capable of eliminating reactive oxygen species. Catalase, WR-2721, or Cu(II)2(3,5-DIPS)4 decrease experimental colitis. *Dig Dis Sci* 1992; **37**: 1866-1873
135 **Babbs CF**. Oxygen radicals in ulcerative colitis. *Free Radic Biol Med* 1992; **13**: 169-181
136 **Nicolas G**, Bennoun M, Porteu A, Mativet S, Beaumont C, Grandchamp B, Sirito M, Sawadogo M, Kahn A, Vaulont S. Severe iron deficiency anemia in transgenic mice expressing liver hepcidin. *Proc Natl Acad Sci USA* 2002; **99**: 4596-4601
137 **Laftah AH**, Ramesh B, Simpson RJ, Solanky N, Bahram S, Schümann K, Debnam ES, Srai SK. Effect of hepcidin on intestinal iron absorption in mice. *Blood* 2004; **103**: 3940-3944
138 **Weiss G**. Pathogenesis and treatment of anaemia of chronic disease. *Blood Rev* 2002; **16**: 87-96
139 **Poss KD**, Tonegawa S. Heme oxygenase 1 is required for mammalian iron reutilization. *Proc Natl Acad Sci USA* 1997; **94**: 10919-10924
140 **Hegazi RA**, Rao KN, Mayle A, Sepulveda AR, Otterbein LE, Plevy SE. Carbon monoxide ameliorates chronic murine colitis through a heme oxygenase 1-dependent pathway. *J Exp Med* 2005; **202**: 1703-1713

S- Editor Tian L **L- Editor** Ma JY **E- Editor** Lin YP

World Journal of Gastroenterology

Online Submissions: http://www.wjgnet.com/1007-9327office
wjg@wjgnet.com
doi:10.3748/wjg.v16.i6.673

World J Gastroenterol 2010 February 14; 16(6): 673-682
ISSN 1007-9327 (print)

TOPIC HIGHLIGHT

Yusuf Bayraktar, Professor, *Series Editor*

Recent developments in palliative chemotherapy for locally advanced and metastatic pancreas cancer

Soley Bayraktar, Ulas Darda Bayraktar, Caio Max Rocha-Lima

Soley Bayraktar, Ulas Darda Bayraktar, Caio Max Rocha-Lima, Division of Hematology/Oncology, Sylvester Comprehensive Cancer Center, University of Miami, Miami, FL 33136, United States
Author contributions: Bayraktar S, Bayraktar UD and Rocha-Lima CM equally contributed to the preparation of this manuscript.
Correspondence to: Soley Bayraktar, MD, Division of Hematology/Oncology, Sylvester Comprehensive Cancer Center, University of Miami, 1475 NW 12th Ave St 3300, Miami, FL 33136, United States. sbayraktar@med.miami.edu
Telephone: +1-305-4580999 Fax: +1-305-5851145
Received: December 7, 2009 Revised: January 4, 2010
Accepted: January 11, 2010
Published online: February 14, 2010

Abstract

In spite of advances made in the management of the other more common cancers of the gastrointestinal tract, significant progress in the treatment of pancreatic cancer remains elusive. Nearly as many deaths occur from pancreatic cancer as are diagnosed each year reflecting the poor prognosis typically associated with this disease. Until recently, the only treatment with an impact on survival was surgery. In the palliative setting, gemcitabine (Gem) has been a standard treatment for advanced pancreatic cancer since it was shown a decade ago to result in a superior clinical benefit response and survival compared with bolus 5-fluorouracil. Since then, clinical trials have explored the pharmacokinetic modulation of Gem by fixed dose administration and the combination of Gem with other cytotoxic or the biologically "targeted" agents. However, promising trial results in small phase Ⅱ trials have not translated into survival improvements in larger phase Ⅲ randomized trials in the advanced disease setting. Two trials have recently reported modest survival improvements with the use of combination treatment with Gem and capecitabine (United Kingdom National Cancer Research GEMCAP trial) or erlotinib (National Cancer Institute of Canada Clinical Trials Group PA.3 trial). This review will focus on the use of systemic therapy for advanced and metastatic pancreatic cancer, summarizing the results of several recent clinical trials and discuss their implications for clinical practice. We will also discuss briefly the second-line chemotherapy options for advanced pancreatic cancer.

Key words: Adjuvant therapy; Chemotherapy; Palliative therapy; Pancreas cancer; Radiotherapy

Peer reviewers: Jorg Kleeff, MD, Consultant Surgeon, Department of Surgery, Klinikum rechts der Isar, Technical University of Munich, Ismaninger Str. 22, 81675 Munich, Germany; Edward L Bradley III, MD, Professor of Surgery, Department of Clinical Science, Florida State University College of Medicine, 1600 Baywood Way, Sarasota, FL 34231, United States

Bayraktar S, Bayraktar UD, Rocha-Lima CM. Recent developments in palliative chemotherapy for locally advanced and metastatic pancreas cancer. *World J Gastroenterol* 2010; 16(6): 673-682 Available from: URL: http://www.wjgnet.com/1007-9327/full/v16/i6/673.htm DOI: http://dx.doi.org/10.3748/wjg.v16.i6.673

INTRODUCTION

Pancreatic cancer is responsible for approximately 5% of cancer-related deaths and is the eighth most common cause of cancer-related death for both genders combined worldwide[1]. Recent estimates indicate that approximately 42 000 new cases and deaths are expected to occur in the United States during 2009. For all the stages combined, the 1- and 5-year survival rates are only 23% and 5%, respectively[2].

The prognosis is even poorer for patients with advanced pancreatic cancer. At the time of diagnosis, approximately half of the patients have metastases, and their median overall survival (OS) with treatment is around 6 mo; whe-

reas approximately one third of patients diagnosed with locally advanced disease have an OS ranging between 6 and 9 mo[3]. Only 15%-20% of patients are eligible for surgery at diagnosis[3]. Only about 20% of surgically resected patients with localized disease will survive 5 years. There is a clear need for better systemic treatments.

This review will summarize and discuss the various clinical trials of chemotherapy for locally advanced and metastatic pancreatic cancer, including the more recent trials, which have investigated the novel targeted agents.

PALLIATIVE CHEMOTHERAPY FOR ADVANCED PANCREATIC CANCER

Patients with metastatic or locally advanced inoperable pancreatic cancer are enrolled in clinical trials as a group, although these patients have different prognoses. The role of radiation therapy for patients with locally advanced disease remains controversial. In addition to a survival benefit, the palliative role of chemotherapy in addition to best supportive care compared to supportive care alone has been demonstrated in advanced pancreatic cancer[4-6]. Patients treated with 5-fluorouracil (5-FU) based chemotherapy had an OS of 6-10 mo compared with 2-3.5 mo in patients who did not receive chemotherapy. Glimelius *et al*[4] also reported that quality of life (QOL) was better, and quality-adjusted survival time was longer, for patients who were randomized to chemotherapy (median of 4 mo *vs* 1 mo, $P = 0.01$) since gemcitabine (Gem) was established as a standard therapeutic agent.

Single agent Gem

The improvement in survival with 5-FU-based chemotherapy compared to best supportive care, and of Gem compared to bolus 5-FU has established Gem as the standard treatment in advanced or metastatic pancreatic cancer[7]. In phase Ⅱ studies, single-agent Gem has shown modest response rates (RR) of 6%-11% with disease stabilization occurring in a further 19%-32%[8]. The toxicities observed with Gem include bone marrow suppression, lethargy, a flu-like syndrome, nausea and vomiting, and peripheral edema. Several trials have attempted to improve upon the efficacy of Gem.

Fixed dose Gem: The administration of Gem usually involves a fixed dose rate (FDR) of 10 mg/m^2 per min. Gem is a pro-drug that is converted to its active tri-phosphate form intracellularly. FDR infusion maximizes the intracellular concentrations of the phosphorylated forms of Gem[9].

In a randomized phase Ⅱ trial[10], Gem at FDR infusion led to a higher RR and better survival, although the primary end point of time to treatment failure (TTF) was similar for both arms. (2.1 mo for FDR Gem *vs* 1.8 mo, $P = 0.09$). The median survivals were 8.0 and 5.0 mo, and the 1-year survivals were 28.8 and 9%, for both arms, respectively. The incidence of hematological toxicity, particularly grade 3-4 neutropenia, was higher in the FDR Gem arm (48.8% *vs* 26.5%).

However in a phase Ⅲ trial by the Eastern Cooperative Oncology Group (ECOG)[11], the FDR of Gem or GemOx [Gem and oxaliplatin (Ox)] did not meet the survival superiority endpoint of the trial compared to standard infusion Gem. Table 1 shows the efficacy results from this trial.

Table 1 Progression-free and overall survival analyses from the ECOG 6201 trial[11]

Parameter	PFS		OS	
	Median (mo)	Log-rank *P*	Median (mo)	Log-rank *P*
All eligible patients (n = 824)	2.9		5.6	
Gem (n = 275)	2.6		4.9	
FDR Gem (n = 277)	3.5	0.09	6.2	0.15
GemOx (n = 272)	2.7		5.7	

PFS: Progression-free survival; OS: Overall survival; ECOG: Eastern Cooperative Oncology Group; Gem: Gemcitabine; GemOx: Gem and oxaliplatin.

Gem-based combination chemotherapy

Despite promising phase Ⅱ trials, the combination of Gem with other cytotoxic drugs has not been proved to be superior to Gem alone in survival (Table 2).

Gem and FU: Phase Ⅲ trials of Gem plus FU compared with single-agent Gem in patients with advanced disease have not shown any benefit in terms of survival[12,13]. In a phase Ⅲ ECOG trial, 322 patients with advanced pancreatic cancer were randomized to Gem alone *vs* Gem combined with FU. OS was 5.4 mo for Gem alone and 6.7 mo for Gem plus FU ($P = 0.09$). Progression-free survival (PFS) for Gem alone was 2.2 mo, compared with 3.4 mo for Gem plus FU ($P = 0.022$).

Gem and capecitabine: The combination of capecitabine and Gem (GemCap) has shown promising clinical activity in phase Ⅰ and Ⅱ clinical studies in advanced pancreatic cancer patients[14,15]. A phase Ⅲ trial conducted by Herrmann *et al*[16] also showed positive results for good performance status (PS) patients. Of 319 patients in the study, median OS, the primary end point, was 8.4 and 7.2 mo in the combination and Gem alone arms, respectively ($P = 0.234$). In addition, there was no statistically significant difference in PFS between the arms (4.8 mo *vs* 4.0 mo, $P = 0.0207$). Only the subgroup analysis of patients with good performance status [Karnofsky performance status (KPS) score of 90-100] have shown significant prolongation of median OS in the GemCap group compared with the control group (10.1 mo *vs* 7.4 mo, respectively, $P = 0.014$)[16].

In the more recently reported United Kingdom Phase Ⅲ trial[17] (UK NCRI study), a higher dose intensity of Gem and capecitabine was used than in the previous trial. Capecitabine dose was approximately 44% higher, and the Gem dose in the combined arm was approximately 12% higher. The dose of Gem in the control arm was identical in the two trials. Median OS was shown to be significantly superior in the GemCap group compared with the Gem group (7.4 mo *vs* 6 mo, respectively, $P = 0.014$), as were the ORR (14% *vs* 7%, respectively, $P = 0.001$) and

Table 2 Phase Ⅲ trials of gemcitabine doublets

Phase Ⅲ trial	Combination	OS (mo)	*P*	PFS (mo)	*P*
Berlin *et al*[12] (*n* = 322)	Gem + FU	6.7	0.09	3.4	0.022
	Gem	5.4		2.2	
Herrmann *et al*[16] (*n* = 319)	Gem + Cap	8.4	0.234	4.8	0.0207
	Gem	7.2		4.0	
Heinemann *et al*[19] (*n* = 219)	Gem + Cisplatin	7.6	0.12	5.3	0.053
	Gem	6.0		3.1	
Colucci *et al*[20] (*n* = 107)	Gem + Cisplatin	6.9	0.48	5	0.048
	Gem	4.6		2	
Louvet *et al*[23] (*n* = 326)	GemOx	9.0	0.13	5.8	0.04
	Gem	7.1		3.7	
Poplin *et al*[11] (*n* = 824)	GemOx	5.7	0.09	2.7	0.15
	Gem	4.9		2.6	
	Gem FDR	6.2		3.5	
Rocha Lima *et al*[27] (*n* = 342)	IRINOGEM	6.3	0.789	3.5	0.352
	Gem	6.6		3.0	
O'Reilly *et al*[29] (*n* = 339)	Gem + Exatecan	6.7	0.52	3.9	0.22
	Gem	6.2		4.0	

FU: Fluorouracil.

the 1-year survival rates (26% and 19%, respectively). Although, higher doses of chemotherapy were used in this study, there was no significant difference in the frequency of grade 3 or 4 adverse events between the two trials. These data were presented in 2005. However, the final results of this trial have not been reported and a full manuscript has not been produced.

Additionally, Bernhard *et al*[18] assessed the clinical benefit response (CBR) and QOL in patients treated with GemCap or Gem alone. CBR was defined as improvement from baseline for 4 consecutive weeks in pain (pain intensity or analgesic consumption) and KPS, stability in one but improvement in the other, or stability in pain and performance status but improvement in weight. Of 319 patients, 19% of patients treated with the combination regimen and 20% of patients treated with Gem alone experienced a CBR, with a median duration of 9.5 and 6.5 wk, respectively (P = 0.02). There was no treatment difference in QOL (n = 311) between the two treatment arms. Regardless of their initial condition, some patients experienced an improvement in QOL on chemotherapy by symptom control; however, this was followed by a worsening 1-2 mo before treatment failure (all $P < 0.05$)[18].

Gem and platinums: A recent randomized phase Ⅲ trial evaluating Gem with or without cisplatin in patients with advanced pancreatic cancer demonstrated a trend toward increased OS (7.6 mo *vs* 6.0 mo, P = 0.12) and PFS in the combination arm relative to the control arm but these differences were not statistically significant[19]. Also, there was no significant difference in QOL between the arms and only nausea and vomiting were significantly increased in the combination arm (22.2% *vs* 5.8%, P = 0.002). Similarly, another randomized study did not show a benefit in survival for combination treatment (6.9 mo *vs* 4.6 mo, P = 0.48) despite a marked improvement in response rate (26.4% *vs* 9.2%, P = 0.02)[20].

On the basis of published preclinical *in vitro* synergy data between Gem and Ox[21], the French Multidisciplinary Clinical Research Group in Oncology (GERCOR) has conducted a phase Ⅱ study in 64 patients with advanced or metastatic pancreatic cancer[22]. The encouraging results observed with GemOx in this phase Ⅱ study has prompted the initiation of a phase Ⅲ trial, conducted by both GERCOR and the Italian Group for the Study of Gastrointestinal Tract Cancer (GISCAD). In this phase Ⅲ study, GemOx was superior in terms of PFS (5.8 mo *vs* 3.7 mo, P = 0.04), RR (26.8% *vs* 17.3%, P = 0.04) and clinical benefit (38.2% *vs* 26.9%, P = 0.03)[23] in both the metastatic and locally advanced population. The 1-year survivals observed in both arms of the study were impressive (34.7% and 27.8%, respectively, P = 0.22). However, median OS did not significantly improve (9.0 mo *vs* 7.1 mo, P = 0.13). For patients with locally advanced disease, median OS was identical in both arms (10.3 mo), whereas in patients with metastatic disease, median OS was 8.5 and 6.7 mo for GemOx and Gem alone, respectively (P = 0.17)[23]. The identical OS in patients with locally advanced disease and failure of this study to demonstrate the statistical significance of its primary end point has been attributed to the assignment of some patients to chemoradiotherapy after 3 mo of chemotherapy. Thirty percent and 32% of patients in the Gem and GemOx arms, respectively, presented with locally advanced disease. Chemoradiotherapy was recommended after 3 mo of chemotherapy in the case of stable disease or response, at the discretion of each investigator. Sixteen out of 40 (40%) and 11 out of 33 (33.3%) patients in the GemOx and Gem arms, respectively, received chemoradiotherapy. The incidence of grade 3-4 thrombocytopenia, vomiting and peripheral sensory neuropathy was increased in the combination arm[23]. An ECOG study[11] was designed to compare the survival impact of single-agent Gem *vs* Gem FDR or GemOx in metastatic or locally advanced pancreatic cancer, and performance status 0 to 2. Of 824 patients enrolled, there was no significant difference in median survival and PFS among the 3 treatment arms (Table 1). A meta-analysis of 5 randomized trials (two oxaliplatin-based and three

cisplatin-based Gem combinations) by Heinemann *et al*[24] demonstrated a significant improvement in ORR and PFS in 2 trials, while the level of significance was not reached in the other 3 trials. The platinum-based combination regimens consistently prolonged OS. However, none of the individual trials showed a statistically significant superiority compared to Gem alone. A significant improvement in OS was detected only when a combined analysis of the five trials was performed (HR = 0.85, $P = 0.010$).

Gem and topoisomerase inhibitors: Irinotecan alone has a response rate of 9% in advanced pancreatic cancer[25]. In a phase Ⅱ, multicenter, single-arm study with irinotecan and Gem (IRINOGEM), 11/45 patients (24%) had 50% or greater reductions in tumor area with a RR of 20% (95% CI, 8%-32%). CA 19-9 was found to decrease during therapy in 50% of patients and was reduced by ⩾ 50% in 30% of patients[26]. There were significant ($P < 0.001$) correlations between proportional changes in CA 19-9 and radiographic changes in the tumor area. Median TTP, median survival and 1-year survival rate were modest at 2.8 mo, 5.7 mo and 27%, respectively. Severe toxicities were uncommon and primarily limited to grade 4 neutropenia (2%), grade 4 vomiting (2%), and grade 3 diarrhea (7%)[26]. This phase Ⅱ data was followed by a phase Ⅲ randomized study conducted by Rocha Lima *et al*[27] to compare the OS of 180 patients randomly assigned to IRINOGEM ($n = 173$) *vs* Gem ($n = 169$). Unfortunately, the combination was not found to improve OS (6.3 mo *vs* 6.6 mo, $P = 0.789$), although the combination had a significantly better tumor RR (16.1% *vs* 4.4%, $P < 0.001$)[27]. Median TTP was 3.5 mo for the IRINOGEM group *vs* 3.0 mo for the Gem group ($P = 0.352$). However, subset analyses in patients with locally advanced disease suggested a TTP advantage with IRINOGEM *vs* Gem (7.7 mo *vs* 3.9 mo). CA 19-9 progression was positively correlated with tumor progression as shown in the previous phase Ⅱ trial conducted by the same author. The incidence of grade 3 diarrhea was higher in the IRINOGEM group but grade 3 to 4 hematologic toxicities and QOL measures were similar[27].

Another topoisomerase inhibitor exatecan (DX-8951f) was studied in a randomized phase Ⅲ trial and was shown to be inferior to Gem in RR and improvement in QOL[28]. Furthermore, the combination of exatecan and Gem failed to show any significant survival benefit over Gem alone in a phase Ⅲ study (6.7 mo *vs* 6.2 mo, $P = 0.52$)[29]. Patients in the combination treatment arm experienced significantly more grade 3-4 toxicity, in particular neutropenia (30% *vs* 15%, $P = 0.001$), thrombocytopenia (17% *vs* 5%, $P = 0.004$) and vomiting (11% *vs* 5%, $P = 0.04$)[29].

The oral topoisomerase I inhibitor rubitecan (9NC) has also been tested in pancreatic cancer in phase Ⅰ/Ⅱ trials[30,31]. In the phase Ⅱ trial of 19 enrolled patients, an objective response was documented in 4 of the 14 evaluable patients (28.6%). Overall median survival was 21 wk and the 1-year survival was 16.7%. Toxicity leading to temporary discontinuation of 9NC was encountered in seven patients (36.8%), all related to a prior dose increase, while milder toxicity was observed in eight patients (42.1%)[31].

Gem and taxanes: Although the taxanes (docetaxel and paclitaxel) have both single-agent activity and activity in combination chemotherapy in advanced pancreatic cancer, they are associated with significant toxicity, particularly myelosuppression. In a phase Ⅰ/Ⅱ study of Gem with docetaxel, the dose-limiting toxicity was grade 3-4 neutropenia[32]. Subsequent phase Ⅱ combination studies have reported RR of 12%-18% and median survivals of 4.7-8.9 mo[33-35]. The incidence of grade 3-4 neutropenia was improved by the addition of prophylactic GCSF (31%) or ciprofloxacin (48%), although these studies still reported an incidence of febrile neutropenia in 12% of patients[33,34].

Gem with other agents: Gem has also been investigated in a multidrug combination chemotherapy regimen. A very small randomized study comparing the combination of cisplatin, epirubicin, FU and Gem (PEFG regimen, $n = 51$) to Gem alone ($n = 46$) showed better 4-mo PFS (primary end point) (60% *vs* 28%) and RR (38.5% *vs* 8.5%, $P = 0.008$)[36] in the PEFG group than in the control group. Both the 1-year OS (38.5% *vs* 21.3%, $P = 0.119$) and the median OS (5.4 mo *vs* 3.3 mo, $P = 0.0033$) were impressive in the PEFG group. There was no significant difference in QOL between the treatment arms, although there was a higher CBR in the PEFG arm (65% *vs* 25%, $P = 0.0139$). However, grade 3-4 neutropenia (43% *vs* 14%, $P = 0.0001$) and thrombocytopenia (30% *vs* 1%, $P = 0.0001$) occurred more frequently in the PEFG arm. Subsequently, this regimen was modified by increasing the dose intensity of cisplatin and epirubicin (both at 30 mg/m^2 every 14 d) and of Gem (at 800 mg/m^2 every 14 d) in an attempt to further improve activity and efficacy, to reduce toxicity and to yield a schedule more suitable to the patient[37]. When compared with 84 patients treated with classical PEFG at the same institution, dose-intense PEFG was not inferior in terms of PFS at 6 mo (63% *vs* 57%), 1-year OS (48% *vs* 42%) and RR (49% *vs* 49%); it allowed an increase in dose intensity for Gem of 32%, for cisplatin and epirubicin of 36% (FU reduced by 3%) which significantly reduced grade 3-4 hematological toxicity (neutropenia: 26% *vs* 86%, $P < 0.00001$; thrombocytopenia: 4% *vs* 58%, $P < 0.00001$) and reduced the number of outpatient accesses by one-third[37].

Emerging role of the novel targeted agents in pancreatic cancer

A better understanding of the biology of cancer has led to the development of novel agents targeting pathways of cancer cell survival. Since Gem has been considered a standard treatment for advanced pancreatic cancer for the past decade, clinical trials have explored the combination of Gem and biological "targeted" agents. However, despite their promise in preclinical studies, most of the clinical trials with the newer agents have not shown survival advantage when compared with standard Gem. A questionable exception is the combination of Gem and erlotinib which showed superiority in median survival compared to Gem alone, but only a net gain of two weeks

Table 3 Phase Ⅰ/Ⅲ trials of gemcitabine in combination with novel targeted therapies

	Combination	OS (mo)	*P*	PFS (mo)	*P*	ORR (%)	SD (%)
Phase Ⅱ trial							
Xiong *et al*[41] (*n* = 61)	Gem + Cetuximab	7.1		3.8		12.2	63.4
Fogelman *et al*[47] (*n* = 50)	GemOx + BEV	12.1		NR		NR	39
Kim *et al*[48] (*n* = 82)	GemOx + BEV	8.1		5.7		11.3	NR
Ko *et al*[49] (*n* = 57)	Gem + Cetuximab + BEV	NR		3.5		10.7	29
	Cetuximab + BEV			1.8		0	24
Kindler *et al*[50] (*n* = 139)	Gem + BEV + Erlotinib	7.8		5.0		23	49
	Gem + BEV + Cetuximab	7.2		5.1		18	45
Phase Ⅲ trial							
Moore *et al*[40] (*n* = 569)	Gem + Erlotinib	6.37	0.038	NR	0.004		
	Gem	5.91					
Philip *et al*[43] (*n* = 735)	Gem + Cetuximab	6.5	0.14	3.5	0.058		
	Gem	6.0		3.0			
Kindler *et al*[45] (*n* = 602)	Gem + BEV	5.7	NS	4.8	NS		
	Gem	6.0		4.3			
Vervenne *et al*[46] (*n* = 607)	Gem + BEV	7.1	NS	4.6	0.0002		
	Gem	6.0		3.6			

ORR: Overall response rate; SD: Stable disease; NR: Not reported; NS: Not significant; BEV: Bevacizumab; Gem: Gemcitabine; Gem FDR: Gemcitabine fixed-dose rate; GemOx: Gemcitabine 1000 mg/m^2 iv over 100 min on day 1 plus oxaliplatin 100 mg/m^2 on day 2 every 14 d.

was observed, questioning the true clinical significance of this superiority[5] (Table 3).

Gem based chemotherapy with novel targeted agents

Gem and erlotinib: Preclinical synergy with Gem and erlotinib in inducing apoptosis in pancreatic xenograft models was demonstrated[38], and a phase I study established the dose of erlotinib for single-agent daily dosing to be 150 mg/d, with which the incidence of severe diarrhea and/or skin rash was unacceptably high[39]. In a phase Ⅲ trial by Moore *et al*[40], 569 patients with locally advanced and metastatic pancreatic cancer were randomly assigned to receive erlotinib plus Gem *vs* Gem alone. The study showed statistically significant improvements in OS (6.37 mo in the erlotinib arm and 5.91 mo in the control arm, $P = 0.038$) and PFS ($P = 0.004$). Median survival in the erlotinib group was 6.24 mo and the 1-year survival rate was 23% compared with 5.91 mo and 17% in the control arm. There was a slight increase in the incidence of grade 3-4 skin rash and diarrhea (6% *vs* 1%) in the group receiving erlotinib, although there was no overall difference in QOL between the arms. As in studies of anti-EGFR agents in colorectal cancer, the presence of rash was associated with a higher likelihood of achieving disease control[40] ($P = 0.05$). This study did not require EGFR positivity to be demonstrated prior to study entry and the overall rate of EGFR expression observed was 57%, which was lower than has been reported in previous studies[41,42]. A subgroup analysis by EGFR status suggested a trend towards benefit from erlotinib regardless of EGFR status, but there was inadequate power to show statistical significance.

Gem and cetuximab: In a phase Ⅱ study[41], 41 patients with EGFR expressing advanced pancreatic cancer were treated with the combination of Gem and cetuximab. A reasonable RR of 12.2% was reported, with a further 63.4% of patients achieving disease stabilization. These results led to a randomized phase Ⅲ trial[43] undertaken by The South Western Oncology Group (SWOG, S0205), the results of which were presented at the 43rd American Society of Clinical Oncology (ASCO) Annual Meeting in 2007 and did not show any survival benefit[43]. Seven hundred and thirty five patients were enrolled between January 2004 and April 2006. The median survival was 6 mo in the Gem arm and 6.5 mo in the Gem plus cetuximab arm for an overall HR of 1.09 (95% CI: 0.93-1.27, $P = 0.14$). The corresponding PFS was 3.0 and 3.5 mo, for the Gem and Gem-cetuximab arms, respectively (HR: 1.13; 95% CI: 0.97-1.30, $P = 0.058$). The unconfirmed responses yielded 14% in the Gem arm and 12% in the Gem-cetuximab arm.

Gem and bevacizumab: Another targeted agent with promising efficacy in pancreatic cancer is bevacizumab which was studied in combination with Gem in a phase Ⅱ trial that resulted in a RR of 19%[44]. However, the results of the US Cancer and Leukemia Group B (CALBG) phase Ⅲ randomized trial of Gem with or without bevacizumab did not reveal any improvement in survival upon addition of bevacizumab[45]. Median OS in the bevacizumab arm *vs* the control arm was 5.7 mo *vs* 6.0 mo (95% CI: 4.9-6.5 mo *vs* 5.0-6.9 mo) and PFS of 4.8 mo *vs* 4.3 mo, respectively (95% CI: 4.3-5.7 mo *vs* 3.8-5.6 mo). This result did not prevent completion of a similar, Roche sponsored trial, AVITA, in which 607 patients with metastatic pancreatic cancer were randomized to Gem and erlotinib with or without bevacizumab[46]. There was no significant prolongation of survival with the addition of bevacizumab, although disease-free survival (DFS) was statistically significantly improved (from 3.6 to 4.6 mo). Bevacizumab was reported to be safe in this combination, despite an increase in the incidence of epistaxis, hypertension and proteinuria. Interestingly, there was no reported increase in thrombotic events with bevacizumab[3]. The AVITA study suggests that antiangiogenic strategies may have merit in the treatment of

advanced pancreatic cancer, although the margin of benefit with bevacizumab is modest.

Two phase Ⅱ trials were presented at the 2009 ASCO Gastrointestinal Cancer Symposium which evaluated the efficacy of Gem in combination with biologic agents. Fogelman *et al*[47] reported the final results of a 3-drug combination consisting of Gem, Ox and bevacizumab in 50 patients with advanced pancreatic cancer. This triple drug combination achieved 1 and 2-year survival rates of 40% and 16%, respectively with a high response rate of 39%[47]. In addition, this regimen demonstrated a higher RR and longer median survival compared to a previously reported Gem and Ox study[23]. Of note, there was a correlation between CA 19-9 levels and median survival. Another phase Ⅱ trial[48] assessing the combination of GemOx plus bevacizumab included 82 patients with advanced pancreatic cancer. This study showed 6-mo survival of 65.0% (95% CI: 53.5%-75.3%), median survival of 8.1 mo (95% CI: 6.5-9.3 mo) and median TTP of 5.7 mo (95% CI: 4.4-6.4 mo).

On the other hand, Gem with a dual monoclonal antibody regimen was disappointing. Ko *et al*[49] designed a phase Ⅱ trial to evaluate the efficacy of dual EGFR/VEGF monoclonal antibodies cetuximab and bevacizumab with or without Gem. Fifty-seven patients received dual antibodies. Overall RR was only 10.7% in the Gem arm and OS data has not been presented yet[49]. The above results were confirmed by another phase Ⅱ trial by Kindler *et al*[50]. One hundred and thirty-nine patients with locally advanced pancreatic cancer received Gem, bevacizumab and erlotinib or Gem, bevacizumab and cetuximab[50]. Interestingly, a correlation between early hypertension and response to treatment was observed. There was no significant difference between the two arms in either OS or PFS. Therefore, cetuximab or bevacizumab is not recommended for the treatment of advanced pancreatic cancer in the current clinical setting outside of an investigational trial.

Other combined regimens

There have been very few attempts to address the role of alternative cytotoxic agents other than Gem in the first-line setting which may represent better platforms for the addition of targeted therapies. One such study conducted by Ducreux *et al*[51] evaluated the efficacy of oxaliplatin alone (OXA), infusional FU alone (FU) and an oxaliplatin/infusional 5-FU combination (OXFU) in the phase Ⅱ setting. 90% of patients had metastatic disease (81% with liver metastases) and 83% of patients had PS 0-1. Median TTP and OS were higher in the combination arm (4.2 and 9.0 mo, respectively) than either of the single-agent arms (OXA, 2.0 and 3.4 mo; FU, 1.5 and 2.4 mo, respectively). Response rate was 10% in the OXFU arm and the safety profile was encouraging[51].

In the FFCD 0301 trial[52], a large phase Ⅲ trial presented in the first-line setting, 202 patients with advanced pancreatic cancer were randomized to either FU and leucovorin plus cisplatin followed by Gem or *vice versa*. Patients received therapy until progression after which they could cross to the opposite arm. After a median follow-up of 44 mo, the majority of patients (n = 192) died. There was no significant difference in survival between the two arms. One-year and two-year survival figures were also identical between the Gem and FU plus cisplatin arms. Although it is unlikely that FU and cisplatin will replace Gem due to toxicity concerns, these data provided the rationale for non-Gem containing regimens in the first-line setting. One may consider a pharmacogenomic profile in the future to select either therapy.

EndoTAG-1 is a novel cationic liposomal formulation of paclitaxel. It increases the microvascular permeability probably due to vascular damage. Manipulation of the blood-tumor barrier with EndoTAG-1 can increase the effectiveness of conventional chemotherapy. The combination of Gem plus liposomal paclitaxel at three different dose levels (11, 22, or 44 mg/m^2) was compared to Gem alone in 200 patients with metastatic pancreatic cancer[53]. Preliminary results were presented at the 2009 ESMO meeting. This regimen achieved a disease control rate of 53%-69% depending on the dosage of paclitaxel. Median PFS was 18, 20, and 19 wk, respectively, in the Gem/EndoTAG-1 low, medium, and high dose groups, compared with 12 wk in the Gem monotherapy group. Median OS was 7.2 mo with Gem alone *vs* 8.4, 8.7, and 9.4 mo with Gem plus low, medium, and high dose EndoTAG-1. Twelve-month survival rates were 17% with Gem alone *vs* 22%, 36% and 33% for Gem plus low, medium and high dose EndoTAG-1.

The results of a randomized phase Ⅱ trial of 3 different regimens in patients with advanced pancreatic cancer suggested that capecitabine plus Ox is comparable to Gem combined with either capecitabine or Ox[54]. A phase Ⅱ trial conducted by Burtness *et al*[55] confirmed the activity of another non-Gem regimen. Ninety-two patients with advanced pancreatic cancer were randomly assigned to receive irinotecan/docetaxel (Arm A) or irinotecan/docetaxel/cetuximab (Arm B). Median OS were reported to be 6.5 (95% CI: 4.8-8.6 mo) and 7.4 mo (95% CI: 4.4-10.7 mo) in Arm A and B, respectively. However, this triple regimen was associated with high rates of grade 3-4 neutropenia and diarrhea[55].

Other agents

Numerous studies employing other novel targeted agents are currently being developed. The CALGB presented the results of a single-arm phase Ⅱ study of sunitinib for patients with advanced pancreatic cancer who had previously been treated with Gem-based therapy. No responses were reported in 77 treated patients, and stable disease in only 7 patients[56]. The California consortium reported similar disappointing results with sorafenib when combined with Gem[57]. In this randomized study, chemo-naive pancreatic cancer patients received sorafenib as a single agent or in combination with Gem. No responses resulted with sorafenib alone and the median survival in the Gem plus sorafenib arm was only 6 mo. Wolpin *et al*[58] treated 31 Gem-refractory pancreatic cancer patients with everolimus, an oral mTOR inhibitor. Although the agent was tolerable, there was no response and disease stability

was uncommon. These targeted agents do not merit further study in pancreatic cancer due to their insufficient anti-tumor activity. Other targeted agents, which have been tested in pancreatic cancer and not found to add any survival benefit, include the farnesyl transferase inhibitor tipifarnib[59,60] and the matrix metalloproteinase inhibitors marimastat[61-63] and BAY 12-9566[64].

Another new agent, AMG 655, is a fully humanized monoclonal antibody that targets human death receptor 5 (DR5), activates caspases, and induces apoptosis in sensitive tumor cells. In pancreatic cancer xenografts, the anti-tumor activity of AMG 655 was enhanced by adding Gem. In a phase Ⅰ trial[65], patients with metastatic pancreas cancer were enrolled into sequential cohorts of 3- or 10-mg/kg AMG 655 iv on days 1 and 15 plus Gem 1000 mg/m^2 iv on days 1, 8, and 15 every 28 d. Best overall tumor response assessed by RECIST criteria showed that 3 (23%) patients had partial responses, 6 (46%) had stable disease (range 15-34+ wk), and 4 (31%) patients had progressive disease. Four of 7 patients (57%) with baseline CA19-9 > 100 U/mL had a ⩾ 70% decrease on study. The median PFS was 5.3 mo and the 6-mo survival rate was 76.2% (42.7%-91.7%)[65]. A randomized phase Ⅱ trial of 10 mg/kg AMG 655 every 2 wk plus Gem has been completed in patients with metastatic pancreatic cancer and the results are forthcoming.

SECOND-LINE CHEMOTHERAPY FOR ADVANCED PANCREATIC CANCER

There is no standard second-line regimen for advanced pancreatic cancer after Gem failure and there is a paucity of trials in this setting. Gem may offer palliative benefits in the second-line setting in patients that have not been treated with Gem previously[66], and results from a phase Ⅱ study (n = 30) suggest that FDR Gem and Ox may have activity in patients who become refractory to standard Gem therapy[67]. All patients received at least one cycle of GemOx (median 5). Response in 31 evaluable patients was as follows: Partial response: 7/31 (22.6%), ⩾ 8 wk: 11/31 (35.5%), s.d. < 8 wk: 1/31 (3.2%), Progressive disease: 12/31 (38.7%). Median duration of response and TTP were 4.5 and 4.2 mo, respectively. Median survival was 6 mo (range 0.5-21 mo). The CONKO-3 study[68] randomized 168 patients who had Gem-refractory pancreatic cancer to 5-FU, LV and oxaliplatin (OFF) or 5-FU and LV (FF). The study showed an improved OS by 2 mo in the OFF arm (4.8 mo *vs* 2.3 mo respectively, P = 0.0077). Both regimens were tolerable, with the exception of higher neuropathy in the OFF arm. There was also a significant prolongation of PFS in the treatment arm (13 wk *vs* 9 wk)[68]. After those significant results, this regimen has been regarded as an appropriate second-line regimen for Gem refractory pancreatic cancer patients.

In a phase Ⅲ study patients with advanced pancreatic cancer who had failed at least one line of chemotherapy were randomized to rubitecan or physicians' choice of treatment[69]. Eighty-five percent of patients in both arms had previously received Gem; 70% and 73% had received FU; 60% and 63% had received both drugs in combination, respectively. The study was unable to show a statistically significant improvement in OS (3.7 mo *vs* 3.1 mo, P = 0.626), and PFS was only marginally improved (1.9 mo *vs* 1.6 mo, P = 0.001).

In a phase Ⅱ trial by Cartwright *et al*[70], 42 patients were treated with oral capecitabine 1250 mg/m^2 administered twice daily in 3-weekly cycles consisting of 2 wk of treatment followed by 1 wk without treatment. Twenty-four percent of patients experienced a significant CBR as evidenced by improvement in pain intensity, analgesic consumption, and/or KPS. Three (7.3%) of the 41 patients with measurable disease had an objective partial response. The median time to objective response was 85 d (range, 47 to 91 d) and duration of response was 208, 260, and 566 d for the three responding patients. One patient with non-measurable but assessable disease had improved residual disease with a positive CBR. For a total of 4 responders among the 42 assessable patients, the OS rate was 9.5%[70]. Of note, the capecitabine dose (1000 mg/m^2 *po* twice daily) recommended in the guidelines was less than the dose described by Cartwright *et al*[70], because the higher dose has been associated with increased toxicity (diarrhea, hand and foot syndrome).

In another phase Ⅱ trial[71], pancreatic cancer patients were administered capecitabine (1000 mg/m^2 twice daily for 14 d) combined with Ox (130 mg/m^2 given on day 1 for 14 d) every 21 d (patients aged > 65 years or with an ECOG PS of 2 received Ox 110 mg/m^2 on day 1 and capecitabine 750 mg/m^2 twice daily for 14 d). The treatment was repeated every 3 wk. Of the 39 evaluable patients, 1 patient had a partial response and 10 patients demonstrated stable disease. The median OS was 23 wk and PFS was 9.9 wk. The 6-mo and 1-year survival rates were 44% and 21%, respectively. The most common grade 3-4 non-hematologic toxicity was fatigue[71].

Currently, it is recommended that physicians enroll their patients in a clinical trial if they progress on first-line therapy; however, when investigational therapy is not available, alternatives for good PS patients include capecitabine with or without Ox or OFF.

CONCLUSION

In the first-line setting, Gem with or without erlotinib has been the standard treatment for pancreatic cancer since 1997, despite low response rates and short survival outcome. The recent introduction of targeted therapies in the therapeutic armamentarium against cancer raised hopes in the treatment of patients with advanced or metastatic cancers. Unfortunately, the target agents studied to date have fallen short of these expectations. Knowledge of the molecular events occurring in the malignant transformation processes should allow the development of more efficient targeted therapies. Metastatic and locally advanced pancreatic cancers have consistently been observed as independent predictors of outcome in randomized clinical trials. One should study these two different pancreatic cancer populations separately.

REFERENCES

1 **Jemal A**, Siegel R, Ward E, Hao Y, Xu J, Thun MJ. Cancer statistics, 2009. *CA Cancer J Clin* 2009; **59**: 225-249

2 **American Cancer Society**. Cancer Facts and Figures 2009. Available from: URL: http://www.cancer.org/downloads/2009-500809web.pdf

3 **Evans DB**, Abbruzzese JL, Rich TA. Cancer of the pancreas. In: De Vita VT Jr, Hellman S, Rosenberg SA, editors. Cancer: Principles and Practice of Oncology. 5th ed. Philadelphia, PA, Lippincott-Raven, 1997: 1054-1087

4 **Glimelius B**, Hoffman K, Sjödén PO, Jacobsson G, Sellström H, Enander LK, Linné T, Svensson C. Chemotherapy improves survival and quality of life in advanced pancreatic and biliary cancer. *Ann Oncol* 1996; **7**: 593-600

5 **Palmer KR**, Kerr M, Knowles G, Cull A, Carter DC, Leonard RC. Chemotherapy prolongs survival in inoperable pancreatic carcinoma. *Br J Surg* 1994; **81**: 882-885

6 **Mallinson CN**, Rake MO, Cocking JB, Fox CA, Cwynarski MT, Diffey BL, Jackson GA, Hanley J, Wass VJ. Chemotherapy in pancreatic cancer: results of a controlled, prospective, randomised, multicentre trial. *Br Med J* 1980; **281**: 1589-1591

7 **Burris HA 3rd**, Moore MJ, Andersen J, Green MR, Rothenberg ML, Modiano MR, Cripps MC, Portenoy RK, Storniolo AM, Tarassoff P, Nelson R, Dorr FA, Stephens CD, Von Hoff DD. Improvements in survival and clinical benefit with gemcitabine as first-line therapy for patients with advanced pancreas cancer: a randomized trial. *J Clin Oncol* 1997; **15**: 2403-2413

8 **Casper ES**, Green MR, Kelsen DP, Heelan RT, Brown TD, Flombaum CD, Trochanowski B, Tarassoff PG. Phase II trial of gemcitabine (2,2'-difluorodeoxycytidine) in patients with adenocarcinoma of the pancreas. *Invest New Drugs* 1994; **12**: 29-34

9 **Grunewald R**, Abbruzzese JL, Tarassoff P, Plunkett W. Saturation of 2',2'-difluorodeoxycytidine 5'-triphosphate accumulation by mononuclear cells during a phase I trial of gemcitabine. *Cancer Chemother Pharmacol* 1991; **27**: 258-262

10 **Tempero M**, Plunkett W, Ruiz Van Haperen V, Hainsworth J, Hochster H, Lenzi R, Abbruzzese J. Randomized phase II comparison of dose-intense gemcitabine: thirty-minute infusion and fixed dose rate infusion in patients with pancreatic adenocarcinoma. *J Clin Oncol* 2003; **21**: 3402-3408

11 **Poplin E**, Feng Y, Berlin J, Rothenberg ML, Hochster H, Mitchell E, Alberts S, O'Dwyer P, Haller D, Catalano P, Cella D, Benson AB 3rd. Phase III, randomized study of gemcitabine and oxaliplatin versus gemcitabine (fixed-dose rate infusion) compared with gemcitabine (30-minute infusion) in patients with pancreatic carcinoma E6201: a trial of the Eastern Cooperative Oncology Group. *J Clin Oncol* 2009; **27**: 3778-3785

12 **Berlin JD**, Catalano P, Thomas JP, Kugler JW, Haller DG, Benson AB 3rd. Phase III study of gemcitabine in combination with fluorouracil versus gemcitabine alone in patients with advanced pancreatic carcinoma: Eastern Cooperative Oncology Group Trial E2297. *J Clin Oncol* 2002; **20**: 3270-3275

13 **Riess H**, Helm A, Niedergethmann M, Schmidt-Wolf I, Moik M, Hammer C, Zippel K, Weigang-Köhler K, Stauch M, Oettle H. A randomized, prospective, multicenter, phase III trial of gemcitabine, 5-fluorouracil (5-FU), folinic acid vs. gemcitabine alone in patients with advanced pancreatic cancer. *J Clin Oncol* 2005; **23**: 310s (abstract LBA4009)

14 **Hess V**, Salzberg M, Borner M, Morant R, Roth AD, Ludwig C, Herrmann R. Combining capecitabine and gemcitabine in patients with advanced pancreatic carcinoma: a phase I/II trial. *J Clin Oncol* 2003; **21**: 66-68

15 **Scheithauer W**, Schüll B, Ulrich-Pur H, Schmid K, Raderer M, Haider K, Kwasny W, Depisch D, Schneeweiss B, Lang F, Kornek GV. Biweekly high-dose gemcitabine alone or in combination with capecitabine in patients with metastatic pancreatic adenocarcinoma: a randomized phase II trial. *Ann Oncol* 2003; **14**: 97-104

16 **Herrmann R**, Bodoky G, Ruhstaller T, Glimelius B, Saletti P, Bajetta E, Schueller J, Bernhard J, Dietrich D, Scheithauer W. Gemcitabine (G) plus Capecitabine (C) versus alone in locally advanced or metastatic pancreatic cancer. A randomized phase III study of the Swiss Group for Clinical Cancer Research (SAKK) and the Central European Cooperative Oncology Group (CECOG). *J Clin Oncol* 2005; **23** Suppl 1: 310s (abstract LBA4010)

17 **Cunningham D**, Chau I, Stocken DD, Valle JW, Smith D, Steward W, Harper PG, Dunn J, Tudur-Smith C, West J, Falk S, Crellin A, Adab F, Thompson J, Leonard P, Ostrowski J, Eatock M, Scheithauer W, Herrmann R, Neoptolemos JP. Phase III randomized comparison of gemcitabine versus gemcitabine plus capecitabine in patients with advanced pancreatic cancer. *J Clin Oncol* 2009; **27**: 5513-5518

18 **Bernhard J**, Dietrich D, Scheithauer W, Gerber D, Bodoky G, Ruhstaller T, Glimelius B, Bajetta E, Schüller J, Saletti P, Bauer J, Figer A, Pestalozzi BC, Köhne CH, Mingrone W, Stemmer SM, Tàmas K, Kornek GV, Koeberle D, Herrmann R. Clinical benefit and quality of life in patients with advanced pancreatic cancer receiving gemcitabine plus capecitabine versus gemcitabine alone: a randomized multicenter phase III clinical trial--SAKK 44/00-CECOG/PAN.1.3.001. *J Clin Oncol* 2008; **26**: 3695-3701

19 **Heinemann V**, Quietzsch D, Gieseler F, Gonnermann M, Schönekäs H, Rost A, Neuhaus H, Haag C, Clemens M, Heinrich B, Vehling-Kaiser U, Fuchs M, Fleckenstein D, Gesierich W, Uthgenannt D, Einsele H, Holstege A, Hinke A, Schalhorn A, Wilkowski R. Randomized phase III trial of gemcitabine plus cisplatin compared with gemcitabine alone in advanced pancreatic cancer. *J Clin Oncol* 2006; **24**: 3946-3952

20 **Colucci G**, Giuliani F, Gebbia V, Biglietto M, Rabitti P, Uomo G, Cigolari S, Testa A, Maiello E, Lopez M. Gemcitabine alone or with cisplatin for the treatment of patients with locally advanced and/or metastatic pancreatic carcinoma: a prospective, randomized phase III study of the Gruppo Oncologia dell'Italia Meridionale. *Cancer* 2002; **94**: 902-910

21 **Faivre S**, Raymond E, Woynarowski JM, Cvitkovic E. Supra-additive effect of 2',2'-difluorodeoxycytidine (gemcitabine) in combination with oxaliplatin in human cancer cell lines. *Cancer Chemother Pharmacol* 1999; **44**: 117-123

22 **Louvet C**, André T, Lledo G, Hammel P, Bleiberg H, Bouleuc C, Gamelin E, Flesch M, Cvitkovic E, de Gramont A. Gemcitabine combined with oxaliplatin in advanced pancreatic adenocarcinoma: final results of a GERCOR multicenter phase II study. *J Clin Oncol* 2002; **20**: 1512-1518

23 **Louvet C**, Labianca R, Hammel P, Lledo G, Zampino MG, André T, Zaniboni A, Ducreux M, Aitini E, Taïeb J, Faroux R, Lepere C, de Gramont A. Gemcitabine in combination with oxaliplatin compared with gemcitabine alone in locally advanced or metastatic pancreatic cancer: results of a GERCOR and GISCAD phase III trial. *J Clin Oncol* 2005; **23**: 3509-3516

24 **Heinemann V**, Boeck S, Hinke A, Labianca R, Louvet C. Meta-analysis of randomized trials: evaluation of benefit from gemcitabine-based combination chemotherapy applied in advanced pancreatic cancer. *BMC Cancer* 2008; **8**: 82

25 **Wagener DJ**, Verdonk HE, Dirix LY, Catimel G, Siegenthaler P, Buitenhuis M, Mathieu-Boué A, Verweij J. Phase II trial of CPT-11 in patients with advanced pancreatic cancer, an EORTC early clinical trials group study. *Ann Oncol* 1995; **6**: 129-132

26 **Rocha Lima CM**, Savarese D, Bruckner H, Dudek A, Eckardt J, Hainsworth J, Yunus F, Lester E, Miller W, Saville W, Elfring GL, Locker PK, Compton LD, Miller LL, Green MR. Irinotecan plus gemcitabine induces both radiographic and CA 19-9 tumor marker responses in patients with previously untreated advanced pancreatic cancer. *J Clin Oncol* 2002; **20**: 1182-1191

27 **Rocha Lima CM**, Green MR, Rotche R, Miller WH Jr, Jeffrey GM, Cisar LA, Morganti A, Orlando N, Gruia G, Miller LL. Irinotecan plus gemcitabine results in no survival advantage compared with gemcitabine monotherapy in patients with locally advanced or metastatic pancreatic cancer despite increased tumor response rate. *J Clin Oncol* 2004; **22**: 3776-3783

28 **Cheverton P**, Friess H, Andras C, Salek T, Geddes C, Bodoky G, Valle J, Humblet Y. Phase III results of exatecan (DX-8951f) versus gemcitabine (Gem) in chemotherapy-naive patients with advanced pancreatic cancer (APC). *J Clin Oncol* 2004; **23** Suppl 15: abstract LBA4005

29 **O'Reilly EM**, Lenzi R, Mani S, Schwartz GK, Sharma S, Kelsen DP, Levin A, Danna M, Bridget H, Jager RD. A randomized phase III trial of DX 8951f (exatecan mesylate; DX) and gemcitabine (GEM) vs. gemcitabine alone in advanced pancreatic cancer (APC). *J Clin Oncol* 2004; **23** Suppl 15: abstract LBA4006

30 **Stehlin JS**, Giovanella BC, Natelson EA, De Ipolyi PD, Coil D, Davis B, Wolk D, Wallace P, Trojacek A. A study of 9-nitrocamptothecin (RFS-2000) in patients with advanced pancreatic cancer. *Int J Oncol* 1999; **14**: 821-831

31 **Konstadoulakis MM**, Antonakis PT, Tsibloulis BG, Stathopoulos GP, Manouras AP, Mylonaki DB, Golematis BX. A phase II study of 9-nitrocamptothecin in patients with advanced pancreatic adenocarcinoma. *Cancer Chemother Pharmacol* 2001; **48**: 417-420

32 **Cascinu S**, Gasparini G, Catalano V, Silva RR, Pancera G, Morabito A, Giordani P, Gattuso D, Catalano G. A phase I-II study of gemcitabine and docetaxel in advanced pancreatic cancer: a report from the Italian Group for the Study of Digestive Tract Cancer (GISCAD). *Ann Oncol* 1999; **10**: 1377-1379

33 **Stathopoulos GP**, Mavroudis D, Tsavaris N, Kouroussis C, Aravantinos G, Agelaki S, Kakolyris S, Rigatos SK, Karabekios S, Georgoulias V. Treatment of pancreatic cancer with a combination of docetaxel, gemcitabine and granulocyte colony-stimulating factor: a phase II study of the Greek Cooperative Group for Pancreatic Cancer. *Ann Oncol* 2001; **12**: 101-103

34 **Ryan DP**, Kulke MH, Fuchs CS, Grossbard ML, Grossman SR, Morgan JA, Earle CC, Shivdasani R, Kim H, Mayer RJ, Clark JW. A Phase II study of gemcitabine and docetaxel in patients with metastatic pancreatic carcinoma. *Cancer* 2002; **94**: 97-103

35 **Shepard RC**, Levy DE, Berlin JD, Stuart K, Harris JE, Aviles V, Thomas JP, Benson AB 3rd. Phase II study of gemcitabine in combination with docetaxel in patients with advanced pancreatic carcinoma (E1298). A trial of the eastern cooperative oncology group. *Oncology* 2004; **66**: 303-309

36 **Reni M**, Cordio S, Milandri C, Passoni P, Bonetto E, Oliani C, Luppi G, Nicoletti R, Galli L, Bordonaro R, Passardi A, Zerbi A, Balzano G, Aldrighetti L, Staudacher C, Villa E, Di Carlo V. Gemcitabine versus cisplatin, epirubicin, fluorouracil, and gemcitabine in advanced pancreatic cancer: a randomised controlled multicentre phase III trial. *Lancet Oncol* 2005; **6**: 369-376

37 **Reni M**, Cereda S, Bonetto E, Viganò MG, Passoni P, Zerbi A, Balzano G, Nicoletti R, Staudacher C, Di Carlo V. Dose-intense PEFG (cisplatin, epirubicin, 5-fluorouracil, gemcitabine) in advanced pancreatic adenocarcinoma. *Cancer Chemother Pharmacol* 2007; **59**: 361-367

38 **Ng SS**, Tsao MS, Nicklee T, Hedley DW. Effects of the epidermal growth factor receptor inhibitor OSI-774, Tarceva, on downstream signaling pathways and apoptosis in human pancreatic adenocarcinoma. *Mol Cancer Ther* 2002; **1**: 777-783

39 **Hidalgo M**, Siu LL, Nemunaitis J, Rizzo J, Hammond LA, Takimoto C, Eckhardt SG, Tolcher A, Britten CD, Denis L, Ferrante K, Von Hoff DD, Silberman S, Rowinsky EK. Phase I and pharmacologic study of OSI-774, an epidermal growth factor receptor tyrosine kinase inhibitor, in patients with advanced solid malignancies. *J Clin Oncol* 2001; **19**: 3267-3279

40 **Moore MJ**, Goldstein D, Hamm J, Figer A, Hecht JR, Gallinger S, Au HJ, Murawa P, Walde D, Wolff RA, Campos D, Lim R, Ding K, Clark G, Voskoglou-Nomikos T, Ptasynski M, Parulekar W. Erlotinib plus gemcitabine compared with gemcitabine alone in patients with advanced pancreatic cancer: a phase III trial of the National Cancer Institute of Canada Clinical Trials Group. *J Clin Oncol* 2007; **25**: 1960-1966

41 **Xiong HQ**, Rosenberg A, LoBuglio A, Schmidt W, Wolff RA, Deutsch J, Needle M, Abbruzzese JL. Cetuximab, a monoclonal antibody targeting the epidermal growth factor receptor, in combination with gemcitabine for advanced pancreatic cancer: a multicenter phase II Trial. *J Clin Oncol* 2004; **22**: 2610-2616

42 **Lemoine NR**, Hughes CM, Barton CM, Poulsom R, Jeffery RE, Klöppel G, Hall PA, Gullick WJ. The epidermal growth factor receptor in human pancreatic cancer. *J Pathol* 1992; **166**: 7-12

43 **Philip PA**, Benedetti J, Fenoglio-Preiser C, Zalupski M, Lenz H, O'Reilly E, Wong R, Atkins J, Abruzzese J, Blanke C. Phase III study of gemcitabine plus cetuximab versus gemcitabine in patients with locally advanced or metastatic pancreatic adenocarcinoma: SWOG S0205 study. *J Clin Oncol* 2007; **25**: No. 18S

44 **Kindler HL**, Friberg G, Stadler WM, Singh Da, Locker G, Nattam S, Kozloff M, Kasza K, Vokes EE. Bevacizumab (B) plus gemcitabine (G) in patient (pts) with advanced pancreatic cancer (PC): updated results of a multi-center phase II trial. *J Clin Oncol* 2004; **23** Suppl 15: 314 (abstract 4009)

45 **Kindler HL**, Niedzwiecki D, Hollis D, Oraefo E, Schrag D, Hurwitz H, McLeod HL, Mulcahy MF, Schilsky RL, Goldberg RM. A double-blind placebo-controlled, randomized phase III trial of gemcitabine plus bevacizumab versus gemcitabine plus placebo in patients with advanced pancreatic cancer: A preliminary analysis of Cancer and Leukemia Group B (CALGB) 80303. ASCO Gastrointestinal Cancers Symposium, 2007: Abstract 108

46 **Vervenne W**, Bennouna J, Humblet Y, Gill S, Moore MJ, Van Laethem J, Shang A, Cosaert J, Verslype C, Van Cutsem E. A randomized, double-blind, placebo (P) controlled, multicenter phase III trial to evaluate the efficacy and safety of adding bevacizumab (B) to erlotinib (E) and gemcitabine (G) in patients (pts) with metastatic pancreatic cancer. *J Clin Oncol* (Meeting Abstracts) 2008; **26**: 4507

47 **Fogelman DR**, Varadhachary G, Xiong HQ, Chang DZ, Bullock SA, Ozer H, Wolff RA, Abbruzzese JL. Final results of a bi-institution phase II study of gemcitabine, oxaliplatin, and bevacizumab for advanced pancreatic cancer. ASCO Gastrointestinal Cancers Symposium, 2009: Abstract #182

48 **Kim GP**, Alberts SR, Oberg AL, Foster NR, Grothey A, Flynn PJ, Schaefer PL, Wiesenfeld M, Campbell D, Hedrick E. Phase II trial of bevacizumab, gemcitabine, and oxaliplatin in patients with metastatic pancreatic adenocarcinoma. ASCO Gastrointestinal Cancers Symposium, 2007: Abstract No. 159

49 **Ko AH**, Dicke K, Gurtler J, Keaton M, Lenz H, Firstenberg B, Zhang Y, Katz T, Youssoufian H. Phase II, randomized, open-label study of cetuximab and bevacizumab alone or in combination with fixed-dose rate (FDR) gemcitabine as first-line therapy for patients with metastatic adenocarcinoma of the pancreas (MPC). ASCO Gastrointestinal Cancers Symposium, 2009: Abstract #183

50 **Kindler HL**, Gangadhar T, Karrison T, Hochster HS, Moore MJ, Micetich K, Sun W, Catenacci DV, Stadler WM, Vokes EE. Final analysis of a randomized phase II study of bevacizumab (B) and gemcitabine (G) plus cetuximab (C) or erlotinib (E) in patients (pts) with advanced pancreatic cancer (PC). *J Clin Oncol* (Meeting Abstracts) 2008; **26**: 4502

51 **Ducreux M**, Mitry E, Ould-Kaci M, Boige V, Seitz JF, Bugat R, Breau JL, Bouché O, Etienne PL, Tigaud JM, Morvan F, Cvitkovic E, Rougier P. Randomized phase II study evaluating oxaliplatin alone, oxaliplatin combined with

infusional 5-FU, and infusional 5-FU alone in advanced pancreatic carcinoma patients. *Ann Oncol* 2004; **15**: 467-473

52 **Mitry E**, Dahan L, Ychou M, Arthaud J, Gasmi M, Raoul J, Mariette C, Phelip JM, Bedenne L, Seitz J, Federation Francophone de Cancerologie D. LV5FU2-cisplatin followed by gemcitabine or the reverse sequence in metastatic pancreatic cancer: Preliminary results of a randomized phase III trial (FFCD 0301). *J Clin Oncol* (Meeting Abstracts) 2008; **26**: 4513

53 **Löhr M**, Haas S, Bechstein W, Bodoky G, Maerten A, Fischbach W, Lilla C, Mescheder A, Pap A, Fölsch UR. A phase II trial of cationic liposomal paclitaxel in combination with gemcitabine in patients with unresectable pancreatic cancer. ASCO Gastrointestinal Cancers Symposium, 2009: Abstract #LBA120

54 **Heinemann V**, Golf A, Seipelt G, Bauer J, Höhler T, Clemens M, Löhr JM, Stauch M, Lordick F, Hinke A. Capecitabine plus oxaliplatin (CapOx) versus capecitabine plus gemcitabine (CapGem) versus gemcitabine plus oxaliplatin (GemOx): A randomized phase II trial in advanced pancreatic cancer. *J Clin Oncol* 2005; **23**: No. 16S (Abstract 4030)

55 **Burtness BA**, Powell ME, Berlin JD, Liles DK, Chapman AE, Mitchell EP, Benson AB. Phase II trial of irinotecan/docetaxel for advanced pancreatic cancer with randomization between irinotecan/docetaxel and irinotecan/docetaxel plus C225, a monoclonal antibody to the epidemal growth factor (EGFR). Eastern Cooperative Oncology (ECOG). *J Clin Oncol* 2007; **25**: No. 18S (Abstract 4519)

56 **O'Reilly EM**, Niedzwiecki D, Hollis DR, Bekaii-Saab TS, Pluard T, Duffy A, Overcash F, Ivy SP, Goldberg RM. A phase II trial of sunitinib (S) in previously-treated pancreas adenocarcinoma (PAC), CALGB 80603. *J Clin Oncol* (Meeting Abstracts) 2008; **26**: 4515

57 **Iqbal S**, Lenz HJ, Yang D, Ramanathan RK, Bahary N, Shibata S, Morgan RJ Jr, Gandara DR. A randomized phase II study of BAY 43-9006 in combination with gemcitabine in metastatic pancreatic carcinoma: A California Cancer Consortium study (CCC-P). *J Clin Oncol* (Meeting Abstracts) 2008; **26**: 11082

58 **Wolpin BM**, Hezel AF, Ryan DP, Abrams TA, Meyerhardt JA, Blaszkowsky LS, Clark JW, Allen B, Regan EM, Fuchs CS. Phase II study of RAD001 in previously treated patients with metastatic pancreatic cancer. *J Clin Oncol* (Meeting Abstracts) 2008; **26**: 4614

59 **Cohen SJ**, Ho L, Ranganathan S, Abbruzzese JL, Alpaugh RK, Beard M, Lewis NL, McLaughlin S, Rogatko A, Perez-Ruixo JJ, Thistle AM, Verhaeghe T, Wang H, Weiner LM, Wright JJ, Hudes GR, Meropol NJ. Phase II and pharmacodynamic study of the farnesyltransferase inhibitor R115777 as initial therapy in patients with metastatic pancreatic adenocarcinoma. *J Clin Oncol* 2003; **21**: 1301-1306

60 **Van Cutsem E**, van de Velde H, Karasek P, Oettle H, Vervenne WL, Szawlowski A, Schoffski P, Post S, Verslype C, Neumann H, Safran H, Humblet Y, Perez Ruixo J, Ma Y, Von Hoff D. Phase III trial of gemcitabine plus tipifarnib compared with gemcitabine plus placebo in advanced pancreatic cancer. *J Clin Oncol* 2004; **22**: 1430-1438

61 **Evans JD**, Stark A, Johnson CD, Daniel F, Carmichael J, Buckels J, Imrie CW, Brown P, Neoptolemos JP. A phase II trial of marimastat in advanced pancreatic cancer. *Br J Cancer* 2001; **85**: 1865-1870

62 **Bramhall SR**, Rosemurgy A, Brown PD, Bowry C, Buckels JA. Marimastat as first-line therapy for patients with unresectable pancreatic cancer: a randomized trial. *J Clin Oncol* 2001; **19**: 3447-3455

63 **Bramhall SR**, Schulz J, Nemunaitis J, Brown PD, Baillet M, Buckels JA. A double-blind placebo-controlled, randomised study comparing gemcitabine and marimastat with gemcitabine and placebo as first line therapy in patients with advanced pancreatic cancer. *Br J Cancer* 2002; **87**: 161-167

64 **Moore MJ**, Hamm J, Dancey J, Eisenberg PD, Dagenais M, Fields A, Hagan K, Greenberg B, Colwell B, Zee B, Tu D, Ottaway J, Humphrey R, Seymour L. Comparison of gemcitabine versus the matrix metalloproteinase inhibitor BAY 12-9566 in patients with advanced or metastatic adenocarcinoma of the pancreas: a phase III trial of the National Cancer Institute of Canada Clinical Trials Group. *J Clin Oncol* 2003; **21**: 3296-3302

65 **Kindler HL**, Garbo LE, Stephenson J, Wiezorek J, Sabin T, Hsu M, Civoli F, Richards DA. Safety and efficacy of AMG 655 in combination with gemcitabine in patients with metastatic pancreatic cancer. ASCO Gastrointestinal Cancers Symposium, 2009: Abstract #192

66 **Rothenberg ML**, Moore MJ, Cripps MC, Andersen JS, Portenoy RK, Burris HA 3rd, Green MR, Tarassoff PG, Brown TD, Casper ES, Storniolo AM, Von Hoff DD. A phase II trial of gemcitabine in patients with 5-FU-refractory pancreas cancer. *Ann Oncol* 1996; **7**: 347-353

67 **Van Laethem J**, Polus M, Marechal R, Demols A, Gay F, Marijken M, Hendlisz A, Peeters M. Gemcitabine and oxaliplatin in gemcitabine-refractory advanced pancreatic cancer: a phase II study. *J Clin Oncol* 2004; **22** Suppl 15: No. 14S (abstract 4119)

68 **Pelzer U**, Kubica K, Stieler J, Schwaner I, Heil G, Gorner M, Molle M, Hilbig A, Dorken B, Riess H, Oettle H. A randomized trial in patients with gemcitabine refractory pancreatic cancer. Final results of the CONKO 003 study. *J Clin Oncol* (Meeting Abstracts) 2008; **26**: 4508

69 **Jacobs AD**, Burris HA, Rivkin S, Ritch PS, Eisenberg PD, Mettinger KL. A randomized phase III study of rubitecan (ORA) vs. best choice (BC) in 409 patients with refractory pancreatic cancer report from a North-American multi-center study. *J Clin Oncol* 2004; **22** Suppl 15: 315 (abstract 4013)

70 **Cartwright TH**, Cohn A, Varkey JA, Chen YM, Szatrowski TP, Cox JV, Schulz JJ. Phase II study of oral capecitabine in patients with advanced or metastatic pancreatic cancer. *J Clin Oncol* 2002; **20**: 160-164

71 **Xiong HQ**, Varadhachary GR, Blais JC, Hess KR, Abbruzzese JL, Wolff RA. Phase 2 trial of oxaliplatin plus capecitabine (XELOX) as second-line therapy for patients with advanced pancreatic cancer. *Cancer* 2008; **113**: 2046-2052

S- Editor Tian L **L- Editor** Webster JR **E- Editor** Lin YP

World Journal of Gastroenterology

Online Submissions: http://www.wjgnet.com/1007-9327office
wjg@wjgnet.com
doi:10.3748/wjg.v16.i6.683

World J Gastroenterol 2010 February 14; 16(6): 683-690
ISSN 1007-9327 (print)

TOPIC HIGHLIGHT

Yusuf Bayraktar, Professor, *Series Editor*

Experience of a single center with congenital hepatic fibrosis: A review of the literature

Ali Shorbagi, Yusuf Bayraktar

Ali Shorbagi, Yusuf Bayraktar, Faculty of Medicine, Department of Internal Medicine, Gastroenterology Clinic, Hacettepe University, 06100 Sihhiye, Ankara, Turkey
Author contributions: Shorbagi A was responsible for the literature review and preparation of the manuscript; Bayraktar Y provided patient details and photographs which were used in describing the experience of a single center, as well as finalizing the final draft for submission.
Correspondence to: Ali Shorbagi, MD, Faculty of Medicine, Department of Internal Medicine, Gastroenterology Clinic, Hacettepe University, 06100 Sihhiye, Ankara, Turkey. shorbagi@hacettepe.edu.tr
Telephone: +90-312-3051712 Fax: +90-312-4429429
Received: October 29, 2009 Revised: December 21, 2009
Accepted: December 28, 2009
Published online: February 14, 2010

Abstract

Congenital hepatic fibrosis (CHF) is an autosomal recessive inherited malformation defined pathologically by a variable degree of periportal fibrosis and irregularly shaped proliferating bile ducts. It is one of the fibropolycystic diseases, which also include Caroli disease, autosomal dominant polycystic kidney disease, and autosomal recessive polycystic kidney disease. Clinically it is characterized by hepatic fibrosis, portal hypertension, and renal cystic disease. CHF is known to occur in association with a range of both inherited and non-inherited disorders, with multiorgan involvement, as a result of ductal plate malformation. Because of the similarities in the clinical picture, it is necessary to differentiate CHF from idiopathic portal hypertension and early liver cirrhosis, for which a liver biopsy is essential. Radiological tests are important for recognizing involvement of other organ systems. With regards to our experience at Hacettepe University, a total of 26 patients have been diagnosed and followed-up between 1974 and 2009 with a diagnosis of CHF. Presentation with Caroli syndrome was the most common diagnosis, with all such patients presenting with symptoms of recurrent cholangitis and symptoms related to portal hypertension. Although portal fibrosis is known to contribute to the ensuing portal hypertension, it is our belief that portal vein cavernous transformation also plays an important role in its pathogenesis. In all patients with CHF portal vein morphology should be evaluated by all means since portal vein involvement results in more severe and complicated portal hypertension. Other associations include the Joubert and Bardet-Biedl syndromes.

Key words: Congenital hepatic fibrosis; Fibropolycystic disorders; Portal hypertension; Bardet Biedl syndrome

Peer reviewer: Fabrizio Montecucco, MD, Assistant Professor, Division of Cardiology, Department of Internal Medicine, University of Geneva, Avenue de la Roseraie 64, 1211 Geneva, Switzerland

Shorbagi A, Bayraktar Y. Experience of a single center with congenital hepatic fibrosis: A review of the literature. *World J Gastroenterol* 2010; 16(6): 683-690 Available from: URL: http://www.wjgnet.com/1007-9327/full/v16/i6/683.htm DOI: http://dx.doi.org/10.3748/wjg.v16.i6.683

INTRODUCTION

Congenital hepatic fibrosis (CHF) is an autosomal recessive inherited malformation defined pathologically by a variable degree of periportal fibrosis and irregularly shaped proliferating bile ducts. The hepatic manifestations of CHF were first described in 1856[1]. The term CHF, with its varied clinical manifestations, was recognized in 1960[2], and later on elaborated in 1961[3]. CHF is one of the fibropolycystic diseases, which also include Caroli disease, autosomal dominant polycystic kidney disease (ADPKD), and autosomal recessive polycystic kidney disease (ARPKD). Clinically it is characterized by hepatic fibrosis,

portal hypertension, and renal cystic disease.

The exact incidence and prevalence of CHF are not known, but it is a rare disease. By 1988, only 200 patients with CHF had been reported in the literature[4]. In most patients, the first manifestations of the disease are signs or symptoms related to portal hypertension, especially splenomegaly and varices, often with gastrointestinal bleeding[5]. The clinical manifestations of CHF are, however, nonspecific, making the diagnosis of this disorder extremely difficult. Onset of symptoms and signs is highly variable and ranges from early childhood to the 5th or 6th decade of life, although this disorder is diagnosed in most patients during adolescence or young adulthood[6]. The late appearance of symptoms and their clinical evolution suggest that CHF is a dynamic and progressive condition.

ASSOCIATED SYNDROMES

CHF occurs in association with a range of both inherited and non-inherited disorders, with multiorgan involvement (Table 1). Several gene mutations have been established for more commonly encountered conditions that have been better investigated (e.g. Joubert syndrome, Bardet-Biedl syndrome). In these conditions, hepatic fibrosis has been reported to occur to varying degrees; however, in most cases, the main cause of morbidity and mortality is involvement of other organ systems, particularly the kidneys and central nervous system. Patients rarely reach adulthood, and in many cases death occurs intrauterine or in early childhood.

PATHOPHYSIOLOGY

It has been established that congenital hepatic fibrosis, and indeed Caroli's disease closely resemble each other pathophysiologically, in that both occur as a result of ductal plate malformation. The ductal plate is a cylindrical layer of cells that surround a branch of the portal vein, and is the embryonic precursor of the intrahepatic bile ducts, as both interlobular and intralobular bile ductules develop from the ductal plate. Progressive remodeling starts at 12 wk of gestation, and full maturation is usually complete by 20 wk. Arrest of maturation and the lack of remodeling of the ductal plate that occurs as a result leads to the persistence of an excess number of immature embryonic duct structures. This abnormality has been termed the ductal plate malformation. The persistence of these immature duct elements stimulates the formation of portal fibrous tissue, and it is this periportal fibrosis that contributes to the clinical picture of recurrent cholangitis or portal hypertension and associated symptoms (Figure 1). Although long standing portal hypertension is known to result in secondary portal vein thrombosis, and eventually portal vein cavernous transformation (PVCT), it is firmly believed that PVCT is actually a component of the disorder, present at the onset rather than developing at a later stage. Embryologically speaking, the development of bile ducts and hepatic vasculature are closely related. The ductal plate malformation has been shown to be associated with a "pollard willow" malformation of the portal vein, which results in too many small and closely branched portal veins, which supports the idea that PVCT may be congenital. Histologically, enlarged portal tracts containing immature ductal plates surrounding several hypoplastic or even obliterated portal vein branches are observed[7]. In one report, PVCT was observed in almost 50% of patients with congenital hepatic fibrosis, and such patients had relatively larger splenomegaly than those without PVCT, as well as suffering from more frequent bleeding episodes from esophageal varices[8].

Furthermore, depending on the stage of arrest of maturation, either the small interlobular bile ducts (congenital hepatic fibrosis), or the medium intrahepatic bile ducts (Caroli's disease) may be involved. Involvement of both simultaneously results in what is known as Caroli's syndrome. In this context, the clinical picture of Caroli's disease (recurrent cholangitis) may be so predominant that co-existing congenital hepatic fibrosis may easily be overlooked. A liver biopsy is therefore warranted in all patients with suspected Caroli's disease to confirm the presence or absence of Caroli's syndrome[9,10].

The hepatic stellate cell (HSC) is at the center of the hepatic fibrotic process associated with liver disease, and has also been shown to play a role in the progression of the disease in congenital hepatic fibrosis. It is widely accepted that transforming growth factor (TGF)-β is a potent growth inhibitory and profibrotic cytokine which plays a pivotal role in the physiological process of wound healing as well as in the pathogenesis of organ fibrosis[11]. TGF-β expression has been shown to be increased in a wide range of fibrotic diseases. Initiation of HSC activation is primarily induced by TGF-β1 derived from Kupffer cells. TGF-β1 mediates its profibrotic actions by stimulating fibroblasts and related cell types, including the HSC in the liver, to secrete a wide range of extracellular matrix proteins. In pathological conditions this leads to accumulation of fibrotic matrix or in a more physiological context to the efficient healing of wounds[12-14]. Latent TGF-β is also activated by MMP-9, another product of Kuppfer cells. TGF-β has other important actions, namely its immunomodulatory properties and its antiproliferative effects on epithelial cells, including hepatocytes.

Several studies have attempted to establish the pathophysiological mechanism behind the abnormal and excessive fibrotic response associated with CHF. Degradation of the basement membrane and extracellular matrix (ECM) constituents, and the remodeling of the ECM are important processes of embryonic development. Basal laminar components such as laminin and type Ⅳ collagen along with the coordinated expression of proteolytic enzymes are thought to be essential for the normal development of intrahepatic bile ducts[15-18]. Most of the proteolytic enzymes involved in these processes belong to the matrix metalloproteinases (MMPs) and the serine proteinases, in particular the plasminogen activator (PA)/plasmin system[19,20]. Both tissue PA (tPA) and urokinase type PA have been shown to contribute to the plasminogen-

Table 1 Syndromes with associated congenital hepatic fibrosis

Associated disorder	Genetic anomaly [chromosome (gene)]	Characteristic clinical features
Caroli syndrome	6p21.1-p12 (*PKHD1* gene)	Caroli's disease - ectasia or segmental dilatation of the larger intrahepatic ducts
Polycystic kidney disease	6p21.1-p12 (*PKHD1* gene)	Progressive cystic dilation of the renal tubule (resulting in renal failure), hepatic cysts, cerebral aneurysms, cardiac valvular abnormalities
Joubert syndrome	9q34.3; 11p12-q13; 6q23 (*AHI1* gene); 2q13 (*NPHP1* gene); 12q21.32 (*CEP290* or *NPHP6* gene); 8q21 (*TMEM67* gene); 16q12.2 (*RPGRIP1L* gene)	Cerebellar vermis hypoplasia retinitis pigmentosa, nystagmus, ataxia
Senior-Loken syndrome	2q13 (*NPHP1*, *NPHP4*, *NPHP5* genes); 3q22 (*NPHP3* gene)	Cerebellar ataxia and skeletal abnormalities, nephronophthisis, retinal dystrophy, sensorineural hearing loss
COACH syndrome	4p15.3 (*CC2D2A* gene)	Cerebellar vermis hypo/aplasia, oligophrenia, ataxia, coloboma, polydactyly
Cogan syndrome	2q13 (*NPHP1* gene)	Oculomotor apraxia, nephronophthisis, cerebellar ataxia
Arima syndrome	Not yet established	Cerebellar vermis hypoplasia, renal abnormalities, psychomotor retardation
Meckel syndrome	17q23 (*MKS1* gene); 8q (*TMEM67* gene); 12q (*CEP290* gene); 16q12.2 (*RPGRIP1L* gene); 4p15 (*CC2D2A* gene); 11q	Microcephaly, renal cystic disease, hypoplastic or ambiguous genitalia, polydactyly, congenital heart defect, cleft palate, ocular defects
Bardet-Biedl syndrome	11q13; 16q21; 3p12-q13 (*ADP-ribosylation factor* gene); 15q22.3; 2q31; 20p12 (*MKKS* gene); 4q27; 14q32.11 (*tetratricopeptide repeat domain-containing* gene); 7p14; 12q; 9q33.1; 4q27; 17q23 (*MKS1* gene); 12q21.3 (*CEP290* gene)	Rod-cone dystrophy (atypical retinitis pigmentosa), postaxial polydactyly, central obesity, mental retardation, hypogonadism, and renal dysfunction
Alstrom syndrome	2p13 (*ALMS1* gene)	Childhood obesity congenital retinal dystrophy, sensorineural hearing loss, endocrinopathies, cardiomyopathy, renal failure
Oral-Facial-Digital type Ⅳ - Mohr-Majewski syndrome	Not yet established	Lobulated tongue, pseudo-cleft of lip, hyperplastic frenula, polydactyly, severe bilateral deafness

dependent lysis of basement membrane laminin in human carcinoma cell lines. Furthermore, plasmin contributes to the activation of MMP-9 and MMP-13 which also play an important role in the degradation of basement membrane components including type Ⅳ collagen. In a recent study by Yasoshima *et al*[21], it was postulated that biliary overexpression of plasminogen and tPA leads to the generation of excessive amounts of plasmin, and subsequent plasmin dependent lysis of the ECM molecules which may contribute to biliary dysgenesis in CHF.

Overexpression of the osteopontin gene has also been implicated in the pathophysiology of biliary atresia, as well as congenital cholestatic syndromes such as CHF and Caroli's disease. Osteopontin is a stimulant of fibroinflammation, and its overexpression has been shown to be regulated by the presence of excessive amounts of regulatory factors such as NF-κB and TGF-β1[22].

In an effort to establish how the presence of excessive immature bile ducts contributes to the process of fibrosis, Sato *et al*[23] managed to demonstrate in a rat model that in the presence of TGF-β1, cholangiocytes acquire mesenchymal features, thus resembling fibroblasts. They speculated that excess production of extracellular matrix molecules by these transformed cells may contribute to the progressive periportal/hepatic fibrosis.

On a different note, a possible role of microRNA has been postulated in the pathogenesis of fibropolycystic disorders involving both the liver and the kidneys. Chu *et al*[24] demonstrated decreases in the levels of the microRNA miR15a in the livers of patients with ARPKD, ADPKD and CHF. They reported that this resulted in an increase in the expression of a cell-cycle regulator known as cell division cycle 25A gene product (Cdc25A), which is directly responsible for cellular proliferation and cystogenesis *in vitro*.

CLINICAL PICTURE

The age of onset of presentation and the severity of symptoms varies greatly, with patients usually being diagnosed in childhood or early adulthood, although presentations as late as in the fifth decade have been reported. Although patients usually present with symptoms involving other organ symptoms (e.g. renal, central nervous system, *etc.*), cases referred for gastroenterologic/hepatologic consultation generally have complaints attributed to CHF. Four clinical forms have been defined[25]: (1) Portal hypertension (most common; more severe in the presence of portal vein abnormality); (2) Cholangitic - cholestasis and recurrent cholangitis; (3) Mixed; and (4) Latent - presentation at a late age.

Most patients are asymptomatic, while some may complain of mild right upper quadrant pain. Patients with a predominant portal hypertensive picture may present with upper gastrointestinal variceal bleeding. Physical examination findings include hepatomegaly, with predominant involvement of the left lobe, splenomegaly and nephromegaly. The liver is firm, with a mildly nodular surface. Laboratory workup may reveal mild elevations in liver enzymes. Patients with a predominantly cholangitic clinical picture may have marked elevations in alkaline phosphatase (ALP), γ-glutamyl transpeptidase (GGT) and bilirubin. Varying cytopenias (leukopenia, thrombocytopenia) secondary to hypersplenism may be seen on a blood count. Abnormal renal func-

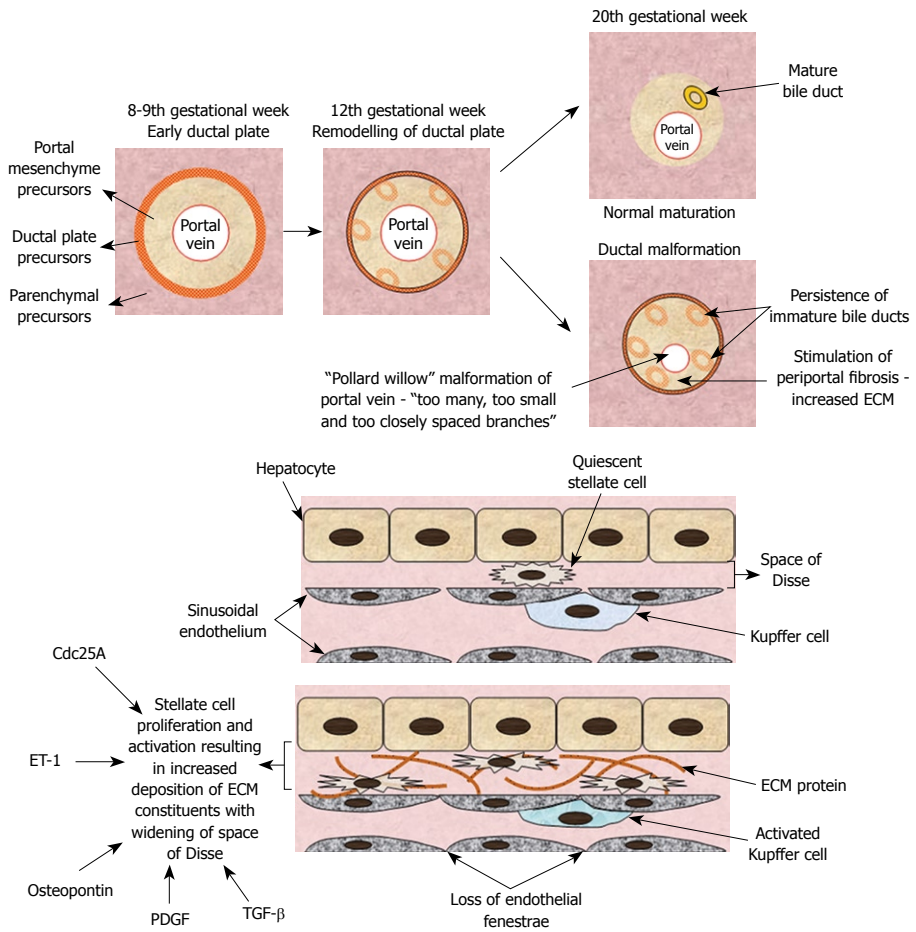

Figure 1 Pathogenesis of congenital hepatic fibrosis. Embryological and molecular perspective. ET-1: Endothelin 1; PDGF: Platelet-derived growth factor; TGF: Transforming growth factor; ECM: Extracellular matrix; Cdc25A: Cell division cycle 25A gene product (cell-cycle regulator).

tions tests are associated with extensive cystic renal disease, which may even progress to end-stage renal failure[26].

COMPLICATIONS

Cholangiocellular carcinoma

The association of cholangiocellular carcinoma (CCC) with congenital cystic malformation of the biliary tree, as seen in Caroli's disease and Caroli's syndrome, has been well established, ranging from 2.5%-16% of afflicted individuals. However, pure congenital fibrosis has also been reported to result in CCC[27,28].

DIAGNOSIS

Role of radiology

Ultrasonography (US) is generally regarded as the first line modality used in the diagnostic process with its high utility, lack of radiation exposure and its capability of detecting the bile duct and liver parenchymal abnormality. In particular, its unique capability of detecting the parenchymal heterogeneity and the associated kidney abnormalities accentuates its role in the diagnosis. Findings include hypertrophy of the left lateral segment and caudate, normal or hypertrophic left medial segment, atrophic right lobe, presence of hepatosplenomegaly, dilatation of the intrahepatic and extrahepatic bile ducts with concomitant focal cystic or solid lesions such as regenerative liver nodules and periportal thickening, dilated intrahepatic bile ducts and stones in the ducts (Caroli's disease), hepatic and renal cysts, and portal vein cavernous transformation (Figure 2).

Computed tomography (CT) offers an advantage to US in that it provides a better depiction of gross morphology of the liver with accurate volume measurements and imaging of liver vasculature, as well as demonstrating any changes in the biliary tree (Figure 3A and B). Periportal cuffing, indicative of the fibrotic process, may also be easily detected with CT. Moreover, imaging of the central nervous system, particularly by CT is essential in the differential diagnosis of syndromes with associated congenital hepatic fibrosis.

Magnetic resonance imaging (MRI), on the other hand, is an attractive alternative, especially since it does not involve the use of radiating energy. Magnetic resonance cholangiopancreatography (MRCP) allows for detailed and thorough evaluation of the biliary tree and renal abnormalities, where lesions that were missed by US may even be detected. Some authors advocate that with the advent of newer technologies like half-fourier-acquisition single-shot turbo spin-echo (HASTE) it may even be possible to quantify the extent of parenchymal fibrosis. Brain MRI is also essential to identify cerebellar malformations associated with disorders such as the Arima, Joubert and COACH syndromes (Figure 4).

Histopathological findings

A unequivocal diagnosis of congenital hepatic fibrosis can only be made by a examination of a liver biopsy. The

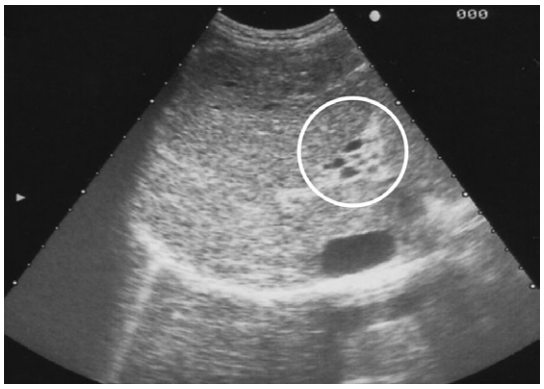

Figure 2 Ultrasound image of a patient with congenital hepatic fibrosis (CHF). Heterogenous appearance of hepatic parenchyma. The circled area depicts the presence of portal vein cavernous transformation.

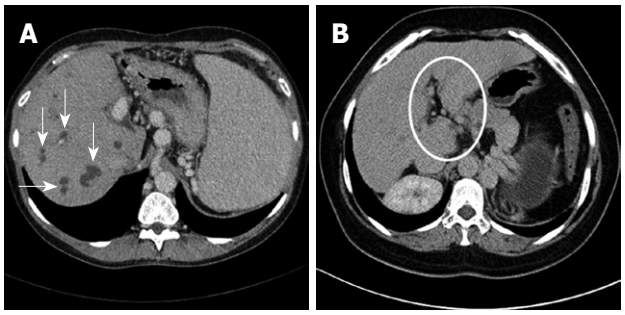

Figure 3 Abdominal computerized tomography (CT) scans of two patients with CHF. A: White arrows depict cystic dilatations of the biliary tree associated with Caroli's syndrome; B: Circled area shows portal vein cavernous transformation in a patient with Bardet-Biedl syndrome.

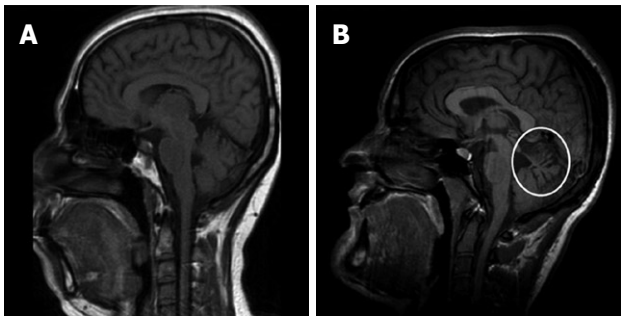

Figure 4 Brain magnetic resonance imaging (MRI) scans of two patients with congenital hepatic fibrosis. A: A patient with Bardet-Biedl syndrome with normal findings; B: The circled area depicts cerebellar vermis atrophy manifested by more prominent folds/sulci, associated with Joubert syndrome.

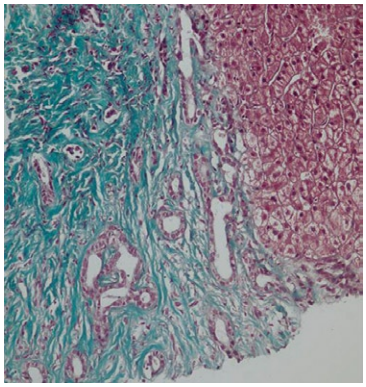

Figure 5 Liver biopsy of a patient with CHF. The left side of the image depicts a portal area with extensive fibrosis and the presence of several bile ducts with cuboidal epithelium that have arrested at different stages of the maturation process. On the right, hepatocytes with normal morphology may be seen (× 230, trichrome stain).

classical histological findings of this disorder are varying degrees of hepatic fibrosis with nodular formation, which may become extensive as the disease progresses. In the eyes of inexperienced pathologists, histopathological findings may easily be mistaken for cirrhosis. In CHF, widened fibrous bands may be encountered in the portal tract containing an increased number of irregularly shaped proliferating bile ducts lined by normal cuboidal epithelium. Unlike cirrhosis, hepatic lobules are usually normal with normal hepatocyte morphology, particularly in the early stages (Figure 5). Signs of cholestasis may be observed in the setting of associated cholangitis. Other findings include cystic dilatation of bile ducts (Caroli's disease), and hypoplasia of the portal vein branches in association with supernumerous hepatic artery branches. In fact, congenital absence of the portal vein has been reported in a pediatric patient with CHF[29]. Similarly, considering the close association of portal vein cavernous transformation with CHF, it has been postulated that such a portal vein anomaly may be a component of the disorder, rather than a consequence, since bile ducts and portal veins share embryonic origins[7].

TREATMENT

As yet, no treatment modality has been shown to actually stop or even reverse the pathological process in congenital hepatic fibrosis, and it remains a progressive and debilitating condition. However, extensive research has been underway into the pathogenesis of fibrosis of the liver, particularly in the setting of chronic liver diseases, and some of the treatment options available may in fact be extended to CHF patients. Instead, for CHF, treatment is directed at the management of its complications.

Anti-fibrotic therapy

Several agents have been studied, particularly in the setting of chronic liver disease. Although results have been promising, especially in animal studies, the clinical impact on humans has failed to live up to expectations. For example, colchicine is a plant alkaloid that inhibits polymerization of microtubules, and is believed to be antifibrotic, preventing collagen secretion and deposition. It had been shown to effectively inhibit collagen synthesis and fibrosis in experimental animal models, however almost all clinical trials, as well as several meta analyses, failed to show any benefits in humans, and current recommendations do not include colchicine as an antifibrotic agent[30].

The angiotensin Ⅱ system, on the other hand, represents an extremely attractive antifibrotic target, as overproduction of angiotensin Ⅱ has been shown to stimulate stellate cell activation and fibrogenesis in the liver.

Table 2 Several antifibrotic agents studied in the setting of hepatic fibrosis of different etiologies[33-43]

Authors	Antifibrotic agent studied	Patient group (*n*)	Dose used	Therapeutic efficacy
Kershenobich *et al*[33], 1988	Colchicine	Cirrhosis - all causes (100)	0.6-1.8 mg/d	5-yr survival rates: colchicine 75%, placebo 34%; Histological improvement: colchicine 30%, placebo 0%
Pockros *et al*[34], 2007	IFN-γ	Cirrhosis - HCV-related (488)	IFN-γ 1b 100 mg and 200 mg	Histological improvement in select group with IFN-inducible T cell a chemoattractant (I-TAC),
Weng *et al*[35], 2005	IFN-γ	Cirrhosis - HBV-related (99)	50 mg IFN-γ intramuscularly on a daily basis for 3 mo	Histological improvement: treatment group 63%, control group 24.1%
Debernardi-Venon *et al*[36], 2007	Angiotensin Ⅱ receptor blockers (candesartan)	Cirrhosis - all causes (47)	8 mg/d	Has been shown to decrease hepatic venous pressure gradient in patients with cirrhotic portal hypertension; studies investigating histological improvement still underway
Neuschwander-Tetri *et al*[37], 2003	PPAR ligands (rosiglitazone)	NASH associated fibrosis (30)	4-8 mg/d	Significant improvements in zone 3 perisinusoidal fibrosis
Armendáriz-Borunda *et al*[38], 2006	Pirfenidone	HCV-related fibrosis (15)	1200 mg/d	Histological improvement in 30% of patients
Ferenci *et al*[39], 1989	Silymarin	Cirrhosis - all causes (170)	140 mg three times daily	4-yr survival rate: silymarin 58%, placebo 39%; no histopathological studies available
Nelson *et al*[40], 2003	Interleukin-10	HCV related fibrosis (30)	subcutaneously at a daily or thrice weekly dose of 8 pg/kg or a thrice weekly dose of 4 pg/kg	Significant improvements in histology
Poupon *et al*[41], 2003	Ursodeoxycholic acid	PBC (367)	15-20 mg/kg per day	Significantly delayed progression of histopathological changes
Lieber *et al*[42,43], 2003	Polyenyl-phosphatidylcholine	Chronic alcoholics (789)	1.5 g three times daily	No improvement in fibrosis; new study underway

HCV: hepatitis C virus; HBV: Hepatitis B virus; IFN-γ: Interferon-γ; PPAR: Peroxisome proliferator-activated receptor; NASH: Non-alcoholic steatohepatitis; PBC: Primary biliary cirrhosis.

Angiotensin Ⅱ may also play a role in the pathogenesis of portal hypertension, thus providing an added benefit to attempts inhibiting the system. The data in humans, however, has been mixed, with no conclusive evidence supporting the use of angiotensin receptor blockers for the prevention of liver fibrosis[30].

Pirfenidone, another promising antifibrotic agent, whose mechanism of action is not clearly understood, was found to be useful in the management of idiopathic pulmonary fibrosis. Its benefit on liver fibrosis has yet to be sufficiently investigated. Other potential antifibrotic agents have been listed in Table 2[30].

Endoscopic therapy

Endoscopic treatment is the mainstay for primary and secondary prophylactic management of esophageal and gastric varices, as well as in the setting of acute bleeding. Similarly, for the management of recurrent cholangitis attacks associated with Caroli's syndrome, besides the use of antibiotics, drainage and stone extraction using endoscopic retrograde cholangiopancreatography (ERCP) may be indicated.

Radiological intervention

Transjugular intrahepatic portosystemic shunts are considered for patients not amenable to sclerotherapy, and is particularly valuable in treating patients with refractory bleeding to buy time until liver transplantation.

Surgery

Surgical shunts may also be indicated with the aim of portal decompression in patients with variceal bleeding not satisfactorily managed endoscopically. Procedures of choice include nonselective total portosystemic shunts, nonselective partial portosystemic shunts that maintain some antegrade blood flow to the liver and selective portosystemic shunts, which decompress the gastroesophageal junction and the spleen through the splenic vein to the left renal vein. On the other hand, for Caroli's disease with recurrent bouts of cholangitis, partial liver resection may be indicated in case of extensive heterogenous involvement of a segment of the liver.

Liver transplantation

Liver transplantation is the only known cure for CHF, and is indicated at the later stages of the disease, with the development of signs of liver failure. In Caroli's syndrome, frequent recurrence of cholangitis with diffuse involvement of the liver is also an indication for transplantation[9,10,31]. In 2008, Rossi *et al*[32] reported on three patients who had co-incidental hepatic failure due to CHF and end-stage renal failure as a result of polycystic kidney disease. All three underwent successful liver and kidney transplantation (1 simultaneous and 2 sequential) with excellent long term results.

HACETTEPE EXPERIENCE

Throughout the 35 years between 1974-2009 in the history of the Department of Gastroenterology at Hacettepe University, Ankara, a total of 26 patients, 16 female and 10 male, with an average age of presentation of 28.4 years, have been diagnosed with congenital hepatic fibrosis. While up to the year 1985 only 3 patients were diagnosed,

the remaining 23 patients were diagnosed in the 1990s and particularly after the year 2000. This may be attributed to better recognition of the disorder by both clinicians and pathologists.

The most common presenting symptom was abdominal distention (11/26 - 42.3%) attributed to hepatosplenomegaly, with a history of recurrent cholangitis present in 6/26 (23%) of patients. In only two patients (7.7%) bleeding from esophageal varices was the presenting finding.

In 8/26 patients (31%) CHF was found to be in association with Caroli's disease (a combination otherwise known as Caroli syndrome). Incidentally, all patients who presented with signs of cholangitis suffered from Caroli's disease, where cholangitis is an expected manifestation. Joubert's syndrome with associated cerebellar vermis anomalies was diagnosed in 2 patients. In 2008, three siblings were referred to the department with common findings including mental retardation, blurred vision, nystagmus, truncal obesity, optic fundal and neurological abnormalities. Further investigation into the possible etiology of co-incidental hepatosplenomegaly resulted in a diagnosis of CHF after liver biopsy. All three were diagnosed as suffering from Bardet Biedl syndrome.

All but three of the patients under follow-up in our department are alive and well. Two patients died after contracting cholangiocellular cancer, while the third patient with Caroli's disease who had undergone several endoscopic gall stone extraction procedures died of biliary sepsis in 2002. Three patients, all of whom had Caroli's syndrome, underwent successful liver transplantation.

CONCLUSION

CHF is a very rare disorder usually occurring in association with other fibropolycystic disorders, including renal involvement. Thus, pure/isolated CHF is very rare. It is necessary to differentiate it from idiopathic portal hypertension and early liver cirrhosis. After a diagnosis of CHF is established, the physician must investigate other organ systems, particularly for neuromuscular or renal involvement. A liver biopsy is essential in the diagnosis and differential diagnosis of CHF, as the presence of small bile duct dilatation and proliferation would rule out other metabolic disorders of the liver.

REFERENCES

1 **Bristowe F**. Cystic disease of the liver associated with a similar disease of the kidneys. *Trans Pathol Soc Lond* 1856; **7**: 229-234

2 **Dobbs RH**. Congenital hepatic fibrosis with portal hypertension. *Proc R Soc Med* 1960; **53**: 327-328

3 **Kerr DN**, Harrison CV, Sherlock S, Walker RM. Congenital hepatic fibrosis. *Q J Med* 1961; **30**: 91-117

4 **De Vos M**, Barbier F, Cuvelier C. Congenital hepatic fibrosis. *J Hepatol* 1988; **6**: 222-228

5 **Yönem O**, Ozkayar N, Balkanci F, Harmanci O, Sökmensüer C, Ersoy O, Bayraktar Y. Is congenital hepatic fibrosis a pure liver disease? *Am J Gastroenterol* 2006; **101**: 1253-1259

6 **Zeitoun D**, Brancatelli G, Colombat M, Federle MP, Valla D, Wu T, Degott C, Vilgrain V. Congenital hepatic fibrosis: CT findings in 18 adults. *Radiology* 2004; **231**: 109-116

7 **Yonem O**, Bayraktar Y. Is portal vein cavernous transformation a component of congenital hepatic fibrosis? *World J Gastroenterol* 2007; **13**: 1928-1929

8 **Bayraktar Y**, Balkanci F, Kayhan B, Uzunalimoglu B, Ozenc A, Ozdemir A, Dündar S, Arslan S, Sivri B, Telatar H. Congenital hepatic fibrosis associated with cavernous transformation of the portal vein. *Hepatogastroenterology* 1997; **44**: 1588-1594

9 **Yonem O**, Bayraktar Y. Clinical characteristics of Caroli's disease. *World J Gastroenterol* 2007; **13**: 1930-1933

10 **Yonem O**, Bayraktar Y. Clinical characteristics of Caroli's syndrome. *World J Gastroenterol* 2007; **13**: 1934-1937

11 **Border WA**, Noble NA. Transforming growth factor beta in tissue fibrosis. *N Engl J Med* 1994; **331**: 1286-1292

12 **Alcolado R**, Arthur MJ, Iredale JP. Pathogenesis of liver fibrosis. *Clin Sci* (Lond) 1997; **92**: 103-112

13 **Friedman SL**. Seminars in medicine of the Beth Israel Hospital, Boston. The cellular basis of hepatic fibrosis. Mechanisms and treatment strategies. *N Engl J Med* 1993; **328**: 1828-1835

14 **Gressner AM**. Perisinusoidal lipocytes and fibrogenesis. *Gut* 1994; **35**: 1331-1333

15 **Crawford JM**. Development of the intrahepatic biliary tree. *Semin Liver Dis* 2002; **22**: 213-226

16 **Terada T**, Okada Y, Nakanuma Y. Expression of matrix proteinases during human intrahepatic bile duct development. A possible role in biliary cell migration. *Am J Pathol* 1995; **147**: 1207-1213

17 **Sanzen T**, Yoshida K, Sasaki M, Terada T, Nakanuma Y. Expression of glycoconjugates during intrahepatic bile duct development in the rat: an immunohistochemical and lectin-histochemical study. *Hepatology* 1995; **22**: 944-951

18 **Terada T**, Nakanuma Y. Expression of tenascin, type IV collagen and laminin during human intrahepatic bile duct development and in intrahepatic cholangiocarcinoma. *Histopathology* 1994; **25**: 143-150

19 **Andreasen PA**, Egelund R, Petersen HH. The plasminogen activation system in tumor growth, invasion, and metastasis. *Cell Mol Life Sci* 2000; **57**: 25-40

20 **Deryugina EI**, Quigley JP. Matrix metalloproteinases and tumor metastasis. *Cancer Metastasis Rev* 2006; **25**: 9-34

21 **Yasoshima M**, Sato Y, Furubo S, Kizawa K, Sanzen T, Ozaki S, Harada K, Nakanuma Y. Matrix proteins of basement membrane of intrahepatic bile ducts are degraded in congenital hepatic fibrosis and Caroli's disease. *J Pathol* 2009; **217**: 442-451

22 **Huang L**, Wei MF, Feng JX. Abnormal activation of OPN inflammation pathway in livers of children with biliary atresia and relationship to hepatic fibrosis. *Eur J Pediatr Surg* 2008; **18**: 224-229

23 **Sato Y**, Harada K, Ozaki S, Furubo S, Kizawa K, Sanzen T, Yasoshima M, Ikeda H, Sasaki M, Nakanuma Y. Cholangiocytes with mesenchymal features contribute to progressive hepatic fibrosis of the polycystic kidney rat. *Am J Pathol* 2007; **171**: 1859-1871

24 **Chu AS**, Friedman JR. A role for microRNA in cystic liver and kidney diseases. *J Clin Invest* 2008; **118**: 3585-3587

25 **Di Bisceglie AM**, Befeler AS. Cystic and nodular diseases on the liver. In: Schiff ER, Maddrey WC, Sorrell M, editors. Schiff's Diseases of the Liver. 10th ed. Philadelphia: Lippincott Williams & Wilkins, 2007: 1231-1251

26 **Desmet VJ**. What is congenital hepatic fibrosis? *Histopathology* 1992; **20**: 465-477

27 **Daroca PJ Jr**, Tuthill R, Reed RJ. Cholangiocarcinoma arising in congenital hepatic fibrosis. A case report. *Arch Pathol* 1975; **99**: 592-595

28 **Yamato T**, Sasaki M, Hoso M, Sakai J, Ohta H, Watanabe Y, Nakanuma Y. Intrahepatic cholangiocarcinoma arising in congenital hepatic fibrosis: report of an autopsy case. *J Hepatol* 1998; **28**: 717-722

29 **Gocmen R**, Akhan O, Talim B. Congenital absence of the portal vein associated with congenital hepatic fibrosis. *Pediatr Radiol* 2007; **37**: 920-924
30 **Rockey DC**. Current and future anti-fibrotic therapies for chronic liver disease. *Clin Liver Dis* 2008; **12**: 939-962, xi
31 **Ananthakrishnan AN**, Saeian K. Caroli's disease: identification and treatment strategy. *Curr Gastroenterol Rep* 2007; **9**: 151-155
32 **Rossi S**, Assis DN, Awsare M, Brunner M, Skole K, Rai J, Andrel J, Herrine SK, Reddy RK, Navarro VJ. Use of over-the-counter analgesics in patients with chronic liver disease: physicians' recommendations. *Drug Saf* 2008; **31**: 261-270
33 **Kershenobich D**, Vargas F, Garcia-Tsao G, Perez Tamayo R, Gent M, Rojkind M. Colchicine in the treatment of cirrhosis of the liver. *N Engl J Med* 1988; **318**: 1709-1713
34 **Pockros PJ**, Jeffers L, Afdhal N, Goodman ZD, Nelson D, Gish RG, Reddy KR, Reindollar R, Rodriguez-Torres M, Sullivan S, Blatt LM, Faris-Young S. Final results of a double-blind, placebo-controlled trial of the antifibrotic efficacy of interferon-gamma1b in chronic hepatitis C patients with advanced fibrosis or cirrhosis. *Hepatology* 2007; **45**: 569-578
35 **Weng HL**, Wang BE, Jia JD, Wu WF, Xian JZ, Mertens PR, Cai WM, Dooley S. Effect of interferon-gamma on hepatic fibrosis in chronic hepatitis B virus infection: a randomized controlled study. *Clin Gastroenterol Hepatol* 2005; **3**: 819-828
36 **Debernardi-Venon W**, Martini S, Biasi F, Vizio B, Termine A, Poli G, Brunello F, Alessandria C, Bonardi R, Saracco G, Rizzetto M, Marzano A. AT1 receptor antagonist Candesartan in selected cirrhotic patients: effect on portal pressure and liver fibrosis markers. *J Hepatol* 2007; **46**: 1026-1033
37 **Neuschwander-Tetri BA**, Brunt EM, Wehmeier KR, Oliver D, Bacon BR. Improved nonalcoholic steatohepatitis after 48 weeks of treatment with the PPAR-gamma ligand rosiglitazone. *Hepatology* 2003; **38**: 1008-1017
38 **Armendáriz-Borunda J**, Islas-Carbajal MC, Meza-García E, Rincón AR, Lucano S, Sandoval AS, Salazar A, Berumen J, Alvarez A, Covarrubias A, Aréchiga G, García L. A pilot study in patients with established advanced liver fibrosis using pirfenidone. *Gut* 2006; **55**: 1663-1665
39 **Ferenci P**, Dragosics B, Dittrich H, Frank H, Benda L, Lochs H, Meryn S, Base W, Schneider B. Randomized controlled trial of silymarin treatment in patients with cirrhosis of the liver. *J Hepatol* 1989; **9**: 105-113
40 **Nelson DR**, Tu Z, Soldevila-Pico C, Abdelmalek M, Zhu H, Xu YL, Cabrera R, Liu C, Davis GL. Long-term interleukin 10 therapy in chronic hepatitis C patients has a proviral and anti-inflammatory effect. *Hepatology* 2003; **38**: 859-868
41 **Poupon RE**, Lindor KD, Parés A, Chazouillères O, Poupon R, Heathcote EJ. Combined analysis of the effect of treatment with ursodeoxycholic acid on histologic progression in primary biliary cirrhosis. *J Hepatol* 2003; **39**: 12-16
42 **Lieber CS**, Weiss DG, Groszmann R, Paronetto F, Schenker S. II. Veterans Affairs Cooperative Study of polyenylphosp hatidylcholine in alcoholic liver disease. *Alcohol Clin Exp Res* 2003; **27**: 1765-1772
43 **Lieber CS**, Weiss DG, Groszmann R, Paronetto F, Schenker S. I. Veterans Affairs Cooperative Study of polyenylphosp hatidylcholine in alcoholic liver disease: effects on drinking behavior by nurse/physician teams. *Alcohol Clin Exp Res* 2003; **27**: 1757-1764

S- Editor Wang YR **L- Editor** O'Neill M **E- Editor** Lin YP

World Journal of Gastroenterology

Online Submissions: http://www.wjgnet.com/1007-9327office
wjg@wjgnet.com
doi:10.3748/wjg.v16.i6.691

World J Gastroenterol 2010 February 14; 16(6): 691-697
ISSN 1007-9327 (print)

TOPIC HIGHLIGHT

Yusuf Bayraktar, Professor, *Series Editor*

How useful is rectal endosonography in the staging of rectal cancer?

Taylan Kav, Yusuf Bayraktar

Taylan Kav, Yusuf Bayraktar, Division of Gastroenterology, Department of Medicine, Hacettepe University School of Medicine, Sihhiye, Ankara 06100, Turkey
Author contributions: Kav T and Bayraktar Y contributed equally to this work.
Correspondence to: Taylan Kav, MD, Division of Gastroenterology, Department of Medicine, Hacettepe University School of Medicine, Sihhiye, Ankara 06100, Turkey. tkav@hacettepe.edu.tr
Telephone: +90-312-3051712 Fax: +90-312-4429429
Received: September 2, 2009 Revised: October 12, 2009
Accepted: October 19, 2009
Published online: February 14, 2010

Abstract

It is essential in treating rectal cancer to have adequate preoperative imaging, as accurate staging can influence the management strategy, type of resection, and candidacy for neoadjuvant therapy. In the last twenty years, endorectal ultrasound (ERUS) has become the primary method for locoregional staging of rectal cancer. ERUS is the most accurate modality for assessing local depth of invasion of rectal carcinoma into the rectal wall layers (T stage). Lower accuracy for T2 tumors is commonly reported, which could lead to sonographic overstaging of T3 tumors following preoperative therapy. Unfortunately, ERUS is not as good for predicting nodal metastases as it is for tumor depth, which could be related to the unclear definition of nodal metastases. The use of multiple criteria might improve accuracy. Failure to evaluate nodal status could lead to inadequate surgical resection. ERUS can accurately distinguish early cancers from advanced ones, with a high detection rate of residual carcinoma in the rectal wall. ERUS is also useful for detection of local recurrence at the anastomosis site, which might require fine-needle aspiration of the tissue. Overstaging is more frequent than understaging, mostly due to inflammatory changes. Limitations of ERUS are operator and experience dependency, limited tolerance of patients, and limited range of depth of the transducer. The ERUS technique requires a learning curve for orientation and identification of images and planes. With sufficient time and effort, quality and accuracy of the ERUS procedure could be improved.

Key words: Rectal cancer; Colorectal cancer; Staging; Endorectal ultrasonography; Endorectal ultrasound; Accuracy; Tumor invasion; Nodal metastases; Other rectal tumors; Diagnostics

Peer reviewer: Dr. Herwig R Cerwenka, Professor, Department of Surgery, Medical University of Graz, Auenbruggerplatz 29, A-8036 Graz, Austria

Kav T, Bayraktar Y. How useful is rectal endosonography in the staging of rectal cancer? *World J Gastroenterol* 2010; 16(6): 691-697 Available from: URL: http://www.wjgnet.com/1007-9327/full/v16/i6/691.htm DOI: http://dx.doi.org/10.3748/wjg.v16.i6.691

INTRODUCTION

Colorectal cancer is the most common gastrointestinal malignancy and the second most common cause of cancer-related deaths in Western countries[1]. Nearly 30% of these cancers arise in the rectum[2]. It is essential to determine prognostic factors in a patient before primary therapy is instituted. If examination has been delayed, it might be too late to influence the survival of a patient because of the lost opportunity to downstage the tumor before surgery. Primary surgery is no longer the only treatment due to recent advances in oncology and availability of therapeutic options. The potential advantages of preoperative treatment are to shrink the tumor size and thereby enhance the resectability rate

and facilitate sphincter-saving surgery, to reduce local recurrences, and possibly to improve long-term survival[3]. The prognosis of rectal cancer is closely related to several factors, including depth of tumoral invasion, number of metastatic lymph nodes, and involvement of the circumferential margin. Assessment of the cancer invasion through the bowel wall (T stage) remains the primary and most important factor in treatment of patients with rectal cancer[1-4].

The TNM system for staging cancer of the colon and rectum to guide treatment and prognosis corresponds with the Dukes system: Stage Ⅰ, Dukes A; stage Ⅱ, Dukes B; and stage Ⅲ, Dukes C. Stage Ⅳ corresponds to the presence of distant metastases[5]. Survival rates differ between T stages, and identifying poor prognostic groups within each stage has been the object of research. Early rectal cancers (T0) have a high, five-year survival rate of 95%. T3N0M0 and T4N0M0 lesions are stage Ⅱ. Invasion of one or two lymph nodes but no distant metastasis (T1-4N1-2M0) with any T level represents stage Ⅲ disease. Stage Ⅳ disease is the most severe, with distal metastasis (T1-4N1-2M1). The five-year survival rate for stage Ⅳ disease is poor (Table 1). There is a marked improvement in survival with early disease. A number of authors have shown a relationship between survival and the depth of extramural spread that is independent of other prognostic factors, including the circumferential margin status[6-8].

The presence of lymph node (LN) involvement is important for the clinical decision, as early and locally advanced disease are managed differently. Endorectal ultrasound (ERUS) is a safe diagnostic method that allows both tumor invasion and lymph node metastatic involvement to be staged, and it contributes significantly to the selection of an adequate surgical strategy in patients with rectal cancer[7-9].

Lesions confined to the wall may be resected by transanal excision or low anterior resection. Lesions involving, or in close proximity to, the anus might need abdominoperineal resection (APR). Patients with locoregionally-advanced lesions (extension onto the perirectal fat and/or perirectal or pelvic adenopathy) should be considered for neoadjuvant chemoradiotherapy. Neoadjuvant therapy has been shown to reduce local recurrence and permit an increased likelihood of a sphincter-sparing operation, with less toxicity compared with postoperative regimes. Thus, unlike more proximal colon cancers, the optimal method of management of rectal carcinoma is critically dependent on accurate preoperative staging of the disease[9,10].

These therapeutic strategies appear to reduce local recurrence rates, increase sphincter-preserving surgeries, and possibly improve overall survival. Surgeries, and possibly improve overall survival. Therefore, staging of rectal cancer is important for selecting patients for adequate management prior to disturbing the tumor bed and potentially disseminating the disease. In daily practice we have been using newly developed and improved technologies that enable us to assess the extent of rectal cancer, which in turn influences choice of therapy. At present, existing modalities for the preoperative staging of rectal cancer include computed tomography (CT); magnetic resonance imaging (MRI) with traditional body, endorectal, or phased-array coils; ERUS with rigid or flexible probes; and positron emission tomography (PET) with and without CT. The choice of modality is often influenced by local expertise and availability. This article reviews the current literature on the usefulness of ERUS in the staging of rectal cancer.

ENDORECTAL SONOGRAPHY

Endorectal sonography was introduced to clinical practice in 1983 and has been successfully used in clinical practice for the evaluation of both the prostate and the rectum. In 1985, Hildebrant and Feifel introduced endorectal ultrasound as a means of staging rectal carcinoma[11]. In the last decade ERUS has become a widely accepted tool for staging of gastrointestinal cancers. Availability of ERUS in developing countries is limited, and there is a variation in availability and use of ERUS across Europe; the United Kingdom being the country in which ERUS is most widely used[12]. When ERUS is available, oncologists usually prefer to use it for staging of rectal cancer, which is the second most common cause of consultation with endosonographic examination indicated by surveyed oncologists. Most oncologists (89.5%) thought ERUS made an important impact on the management of patients with rectal cancer[13].

Primary rectal adenocarcinoma is a common cause of a rectal mass on imaging. Other, less-common, lesions of the anorectum and perirectal tissues might resemble an adenocarcinoma. Transrectal sonography has proved to be a fast, safe, and accurate initial method for the staging of known rectal cancers or masses, although not for the screening of suspected rectum tumors, and is widely accepted as the diagnostic modality of first choice[14,15]. Imaging of the anorectum and perirectal tissues is technically challenging and can be difficult to interpret, as fecal material might be present, rectal lesions can be mobile or large, and general orientation is difficult[16]. The technique of transrectal sonography requires a learning curve for orientation and identification of ultrasound images and planes of rectal tumors. With sufficient effort, time, and meticulous technique, however, the rectum can be easily examined[15,16].

Technique

To perform ERUS it is preferable to have an empty rectum, because fecal material can distort the images obtained. Laxative enemas are usually sufficient for rectal lesions, but standard colonoscopy preparation, even for rectal end sigmoid lesions, could optimize imaging so that it is free of artifacts. For endosonographic examination of proximal colonic lesions, such a preparation is a prerequisite. Pre-examination sigmoidoscopy should be routinely performed to ensure the lumen is clear of debris. The procedure is well tolerated and can be performed without sedation. Intraluminal rectal ultrasound examination of

Table 1 Tumor stage on endorectal ultrasound to determine the management strategy, and corresponding survival rates[2,10]

Stage	T and N groups	Management	Five year survival
I	T 1-2, N0, M0	Snare polypectomy, EMR-	> 90%
II	T3 - 4, N0, M0	ESD, TAEX, LAR, APR	60%-85%
III	T1-4, N1, M0	LAR, RT followed by APR	25%-60%
IV	T1-4, N0-2, M1	RT-CT followed by APR	5%-7%

N0: No regional lymph node metastasis; N1: Metastasis in one to three regional lymph nodes; N2: Metastasis in four or more regional lymph nodes; EMR: Endoscopic mucosal resection; ESD: Endoscopic submucosal dissection; TAEX: Transanal excision; LAR: Low anterior resection; APR: Abdominoperineal resection; RT: Neoadjuvant radiotherapy; RT-CT: Neoadjuvant radiochemotherapy.

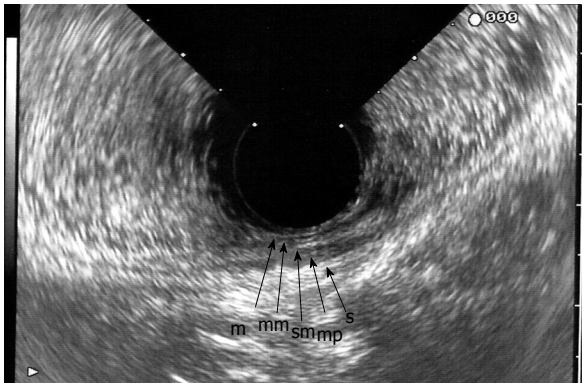

Figure 1 Normal endorectal sonogram image acquired by flexible echo-endoscope. The layers of the rectum are as follows: hyperechoic mucosa (m), hypoechoic muscularis mucosa (mm), hyperechoic submucosa (sm), hypoechoic muscularis propria (mp), and hyperechoic serosa (s).

rectal lesions can be done with a rigid probe or a flexible echoendoscope with a radial transducer. At our institution, we use a front-viewing upper echoendoscope, which can be advanced under direct vision to the level of the lesion. Linear echoendoscopes are normally used for fine-needle aspiration in case tissue sampling is needed, but could be used for routine ERUS[9]. For the purpose of this discussion, both techniques are considered as ERUS. Commonly, a dedicated blind rectal probe is used for ERUS. The probe is inserted and advanced into the rectum, where a water-filled balloon at the tip of the probe is inflated for evaluation of the rectum. High-frequency miniprobes are available and can be used with standard endoscopes to image the gastrointestinal wall and focal lesions under endoscopic vision. ERUS accurately visualizes the layers of the rectal wall and the precise localization of the layers of the rectal wall disrupted by the tumor, and the presence of perirectal lymph node metastases can be established[17].

Endosonographically, the bowel wall is seen as five alternating hyper- and hypoechoic layers (Figure 1)[9,17-19], as a result of differences in acoustic impedance, corresponding to histological layers. The first (hyperechoic) layer is the interface between the superficial mucosa and water or a water-filled balloon; the second (hypoechoic) layer represents the mucosa and muscularis mucosae; the

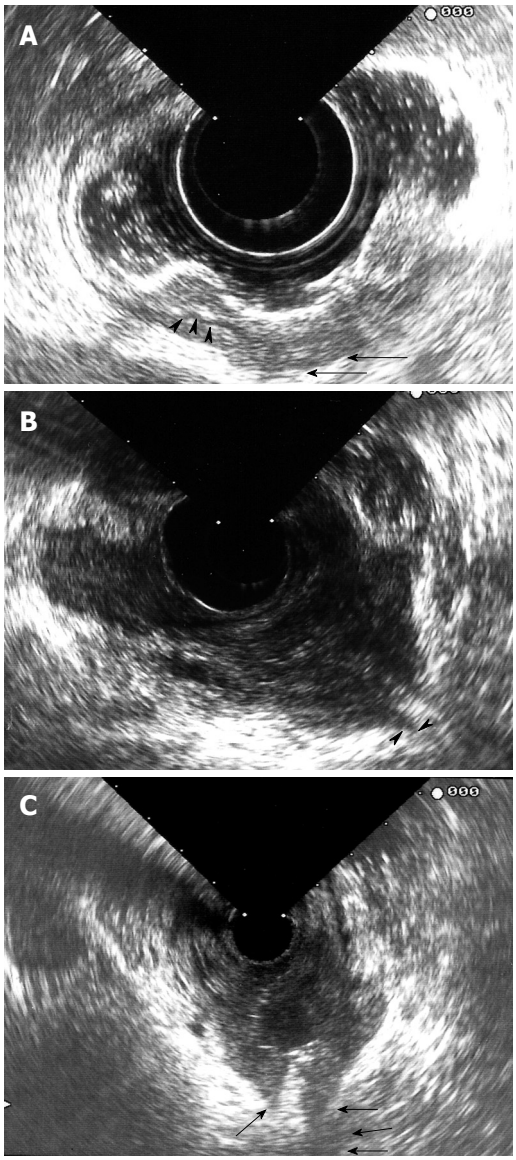

Figure 2 Endorectal ultrasound (ERUS) image. A: A rectal carcinoma that appears to be T1 (penetration into submucosa) in one part (arrowheads show intact muscularis propria) and T2 (penetration into muscularis propria-arrows) in another part; B: A T3 rectal adenocarcinoma. Arrowheads show that the lesion penetrated into perirectal fat; C: A locally invasive cervical cancer, which invaded the rectum (arrows show tumor breach).

third (hyperechoic) layer denotes the submucosa and its interfaces; the fourth (hypoechoic) layer represents the muscularis propria; and the fifth (hyperechoic) layer is the interface between the serosa and perirectal fat.

Carcinomas are hypoechoic, and the degree to which they disrupt and penetrate the rectal wall layers suggests the local stage[4]. Ultrasonographic staging of tumor depth is denoted by the prefix "u". The ultrasonographic staging corresponds to the TNM classification[5]. A uT1 tumor does not penetrate the muscularis propria. A uT2 tumor penetrates the muscularis propria (Figure 2A). A uT3 tumor proceeds beyond the muscularis propria, infiltrating the perirectal fat to a variable degree (Figure 2B). A uT4 tumor infiltrates surrounding organs[10,18]. As the tumor stage is advanced, a marked decrease in survival is

observed. ERUS, however, cannot reliably visualize the mesorectal fascia and thus cannot indicate whether the planned surgical circumferential resection margin will be successful[1-5].

The sonographic criteria for identifying involved lymph nodes consist of size greater than 5 mm, mixed signal intensity, irregular margins, and spherical rather than ovoid or flat shape. ERUS can distinguish the different anatomic layers of the bowel, and thus it appears to have advantages over both CT and MRI in assessing mural penetration, and is invaluable in assessing patients considered for local resection[10,20].

Indications for ERUS in rectal cancer are as follows[21]: (1) to choose endoscopic mucosal resection or transanal excision in case of a large polyp or small rectal cancer (lesion is T1 by ERUS); (2) to determine whether preoperative chemotherapy and radiation is needed; and (3) surveillance after surgery for rectal cancer.

T and LN staging

As outlined above, appropriate staging guides the treatment. Many other modalities, including CT and MRI of the abdomen, have been utilized to correctly determine the TNM stage. In 80 consecutive patients with newly diagnosed rectal cancer who were prospectively evaluated, Harewood *et al*[22] reported T staging accuracy of 91%, compared to 71% for CT, and N staging accuracy of 82%, compared to 76% for CT.

The accuracy of ERUS for assessing local depth of invasion of rectal carcinoma (T stage) ranges from 80% to 95%, compared to 65%-75% for CT and 75%-85% for MRI[20]. ERUS has been demonstrated to be very accurate for staging superficial rectal tumors, with accuracy in evaluating tumor ingrowth into rectal wall layers ranging from 69% to 97%[23,24].

A recent meta-analysis evaluating all ERUS studies from 1980 to 2008 showed that accuracy was high (88%-95%). The sensitivity and specificity of ERUS to diagnose stage T1 cancer were 87.8% and 98.3%, respectively. For stage T2, ERUS had a sensitivity and specificity of 80.5% and 95.6%, respectively. For stage T3, ERUS had a sensitivity and specificity of 96.4% and 90.6%, respectively. In diagnosing stage T4 cancer, ERUS had a sensitivity of 95.4% and specificity of 98.3%[25]. One common finding is a lower accuracy for T2 tumors. Several reasons have been suggested, including the difficulty in distinguishing those tumors that have deep invasion into the muscularis propria from those with microscopic invasion into the perirectal fat. This could raise problems with sonographic T3 cancers that have been overstaged, because there is an increased tendency to give preoperative radiotherapy to T3 cancers.

Zorcolo *et al*[26] evaluated the accuracy of ERUS for the distinction of early *vs* advanced rectal lesions before transanal endoscopic microsurgery and they found ERUS differentiated early and advanced rectal lesions with 96% sensitivity, 85% specificity, and 94% accuracy. Similarly, another retrospective series reached 89.2% accuracy for staging of early rectal carcinomas[27].

ERUS is also helpful in determining the presence of residual cancer in the rectal wall. A retrospective series with 63 patients showed the presence of residual cancer in patients who underwent surgery (n = 30) with 54% accuracy. Authors stated that ERUS was more useful than morphological or histological criteria for determining residual cancer[28].

Transanal endoscopic microsurgery (TEM) and endoscopic submucosal dissections have been becoming more popular because of they offer function-preserving resections. An important problem that has arisen in this setting is the assessment of the tumor breach to the submucosa, which changes the mode of surgery. Other imaging modalities are known to be poor at staging in early cancers. According to a prospective study involving 156 patients, of whom 62 underwent TEM, no understaging was observed with an accuracy of 95%, and only 5% were overstaged. ERUS is accurate at predicting early disease[29].

ERUS was useful in detecting cancer recurrence at the anastomosis site. This often requires serial examination to differentiate postoperative scars from local recurrences. In sonographically equivocal cases, tissue characterization and sampling *via* FNA make ERUS very accurate; although the surveillance period was not assessed, a recommendation was made of every 3-6 mo during the first two years after low anterior resection[20].

Assessment for nodal metastases is less accurate than that for tumor depth. According to a recent meta-analysis of 35 studies by Puli *et al*[30], which involved more than 2700 patients, the sensitivity of ERUS in diagnosing nodal involvement in rectal cancer was 73.2% and it had a specificity of 75.8%.

Discrepancies in accuracies could be partly due to the variable criteria used for defining nodal metastases. For rectal cancer in particular, over half of the metastatic nodes secondary to rectal cancer are $\leqslant$ 5 mm and are located within 3 cm of the primary tumor[31]. In a large trial, lymph node metastatic disease was shown to predict local recurrence. There is a wide variation in accuracy for metastatic nodal detection with ERUS (62%-87%), CT (22%-73%), and MRI (39%-95%)[32]. ERUS criteria are a lack of ovoid morphology and central echogenic nidus, but its limited field of view is a major limitation[4]. Data from pooled analyses, as well as from recent smaller studies, reveal that the sensitivity of ERUS in detecting LN metastasis ranges from 50% to 83%, which is comparable with that of MRI (sensitivity 45% to 79%)[9,10]. Assessment of nodal metastases is difficult because most small lymph nodes are not easily observed with ERUS, and 18% of lymph nodes less than 5 mm harbor metastases[17]. More recent studies suggest that multiple criteria should be used to improve accuracy. Gleeson *et al*[20] conducted a study with ERUS guided FNA to identify nodal echo characteristics and size for prediction of malign infiltration, and to determine if any combination of standard nodal criteria had sufficient predictive value to preclude FNA. Nodal hypoechogenicity and short axis $\geqslant$ 5 mm were independent factors for malignancy. If all four

malignant nodal echo features of node were present, it distinguished the malignant from the benign node. These US features were node size, echogenicity, shape, and the border. A long axis length greater than 9 mm was 95% specific for the presence of malignancy.

Accuracies of ERUS might vary with different tumor stages. Overstaging is more frequent than understaging. As with MRI, overstaged T2 lesions are the most common causes of inaccuracy. ERUS cannot reliably or precisely differentiate an irregular outer rectal wall due to peritumoral inflammation or real transmural tumor extension[7-9,33]. Staging of the stenotic lesions might also be difficult; they are probably suboptimally staged because of the inability of the probe to traverse the lesion. This problem is greater with rigid probes. Flexible probes have the ability to evaluate the iliac region for adenopathy, which is clinically important because these nodes are retained in standard resection with total mesorectal excision. In one study, up to 28% of lymph node-positive distal tumors showed iliac adenopathy, with 6% of patients having only iliac adenopathy. Thus, failure to evaluate this region could lead to inadequate surgical margins in up to 6% of patients with low rectal lesions. Lymph nodes > 5 mm in size have a 50% to 70% chance of being malignant compared with only 20% of nodes < 4 mm. ERUS-guided FNA allows confirmation of malignancy in suspicious nodes during the same examination, as long as the primary tumor does not lie in the path of the needle[33].

Preoperative chemoradiation is a main reason for lower staging accuracy rate. Napoleon *et al*[34] found a variation in the accuracy of T staging from 86% (in patients referred directly to surgery) to 46% (in patients after neoadjuvant radiation therapy).

Overstaging is mainly caused by inflammatory and associated reactive changes in the rectum wall after preoperative radiotherapy. They are presented as hypoechoic lesions and can be confused with carcinoma. However, radiotherapy affects the wall thickness but does not change the five-layered image. In one particular study, comparison of postradiation ERUS correlated with histopathology findings revealed that ultrasound was actually assessing the fibrosis that had replaced the tumor; therefore, after radiotherapy, what is staged by ERUS is no longer the tumor but the extent of fibrosis in the rectal wall. A histopathological examination showed that the residual tumor, when present, was always within the fibrosis, never outside or separate from it[33,35].

In general, ERUS is better at detecting lymph nodes in the distal and middle thirds of the rectum[21,33]. The overstaging of lymph node status is primarily caused by the presence of reactive swollen lymph nodes that could be considered as malignant. The small blood vessels, urethra, and seminal vesicle are known to be mistaken for metastatic lymph nodes. Blood vessels can simulate malignant nodes, but they can be differentiated by moving the transducer to outline the linear or branching course of the vessel and by power Doppler. The main reasons for nodal status understaging are difficulty in detecting very small involved nodes (less than 2 mm) and nodes outside the perirectal tissue[21,33].

The three-dimensional reconstruction is also thought to improve visualization of subtle protrusions of tumors infiltrating into adjacent tissues and organs, allowing for improved T and N staging. A study of 25 patients undergoing three-dimensional ERUS, two-dimensional ERUS, and MRI showed no significant difference in T- or N-stage accuracy, but it was thought that MRI and three-dimensional ERUS improved understanding of the spatial relationship of the tumor due to their ability to obtain multiplanar images[36].

The limitations of ERUS are that it is heavily operator dependent; it has poor patient acceptability; it has limited depth of penetration; it cannot be performed in stenotic tumors[16,21]; and it is unable to visualize tumors located in the upper rectum with a rigid probe, detect lymph nodes outside the range of the transducer, or visualize mesorectal fascia because of its limited field of view. In addition, accuracy is affected by postbiopsy peritumoral inflammation, hemorrhage, and villous or pedunculated tumors[22,31]. Overstaging of tumor depth frequently occurs as a result of paraneoplastic inflammation, as ultrasound cannot clearly differentiate between inflammatory and neoplastic tissue[22,31].

Several authors suggest that obstructive tumors interfere with accurate staging. In such tumors, inadequate probe contact perpendicular to the tumor makes it more likely to be mis-staged. Some authors reported better accuracy rates for high compared to low rectal tumors, while others found the opposite[32].

The tumor margin cannot be assessed accurately, which in turn causes mis-staging, because of inadequate bowel preparation and bulky tumors that lie outside the focal length of the transducer.

There is a learning curve with operator variability[33]. Badger *et al*[37] found that experience does not affect the T and N staging accuracy, suggesting that there was no learning curve. Others supported the effect of experience and appropriate training for accurate staging[38]. Inexperience has been cited as contributing to many of the poor accuracies in tumor depth infiltration[17].

Orrom *et al*[39] reported an increase in diagnostic accuracy of ultrasound from 59.3% to 95% over a period of three years when ERUS was performed by several operators and a single skilled operator performed the later exams. More time and meticulous training are required for improvements in the accuracy of ERUS, a statement supported by different studies showing a progress from 50% to over 90%[39-42]. It is has also been suggested that centralization of ERUS could provide more caseloads to experienced operators and result in a high-quality service[41].

Studies suggest a learning curve of up to 50 cases for tumor depth and more than 75 cases for accurate node status assessments[41]. Interpretation is often more difficult after a partial excision or neoadjuvant chemoradiation, which can result in a hematoma or local inflammation with obliteration of sonographic layers of the rectal wall.

Presence of inflammatory changes, desmoplastic changes, and hypervascularity could lead to overstaging because the echogenicity of tumors is similar to that of muscularis propria and inflammatory infiltrate[42].

OTHER MALIGNANCIES OF THE RECTUM

Transrectal sonography is useful to differentiate extramural lesions, extrinsic compression, vascular lesions, and solid tumors. Other types of malignancies resembling rectal adenocarcinoma include neuroendocrine tumors, which usually manifest as small, mobile, submucosal nodules or focal areas of submucosal thickening, and primary squamous cell carcinomas, which seem to be frequently locally invasive and involve regional lymphatic vessels. Lymphomas are rare, and can be a primary lesion or a secondary infiltration of the large intestine, which characteristically involves the deeper layers of the intestinal wall. Anorectal melanoma is another rare rectal tumor. Gastrointestinal stromal tumor (GIST) is the most common mesenchymal tumor that originates in the alimentary tract, but it rarely involves the anorectal region. The tissue of origin is the muscle layer of the bowel wall, and the size can be variable. On sonography, a GIST appears as a hypoechoic mass[15]. ERUS is also helpful for determining local invasion of the rectum by other pelvic malignancies (Figure 2C).

CONCLUSION

ERUS is a safe and accurate technique for the local staging of rectal carcinoma with reported high accuracy rates for T and N staging. Although availability is limited, it has been implemented into clinical practice in clinical decision making regarding treatment modality. A growing body of expertise has confirmed the clinical impact. ERUS is also helpful in assessing recurrence of rectal cancer and evaluation of subepithelial masses. Technological improvements in ultrasound might improve accuracy and reduce the overstaging problem.

REFERENCES

1 **Rovera F**, Dionigi G, Boni L, Cutaia S, Diurni M, Dionigi R. The role of EUS and MRI in rectal cancer staging. *Surg Oncol* 2007; **16** Suppl 1: S51-S52

2 **Meredith KL**, Hoffe SE, Shibata D. The multidisciplinary management of rectal cancer. *Surg Clin North Am* 2009; **89**: 177-215, ix-x

3 **Wolpin BM**, Meyerhardt JA, Mamon HJ, Mayer RJ. Adjuvant treatment of colorectal cancer. *CA Cancer J Clin* 2007; **57**: 168-185

4 **Karantanas AH**, Yarmenitis S, Papanikolaou N, Gourtsoyiannis N. Preoperative imaging staging of rectal cancer. *Dig Dis* 2007; **25**: 20-32

5 **Smith N**, Brown G. Preoperative staging of rectal cancer. *Acta Oncol* 2008; **47**: 20-31

6 **Puli SR**, Bechtold ML, Reddy JB, Choudhary A, Antillon MR. Can Endoscopic Ultrasound Predict Early Rectal Cancers That Can Be Resected Endoscopically? A Meta-Analysis and Systematic Review. *Dig Dis Sci* 2009; Epub ahead of print

7 **Siddiqui AA**, Fayiga Y, Huerta S. The role of endoscopic ultrasound in the evaluation of rectal cancer. *Int Semin Surg Oncol* 2006; **3**: 36

8 **Assenat E**, Thezenas S, Samalin E, Bibeau F, Portales F, Azria D, Quenet F, Rouanet P, Saint Aubert B, Senesse P. The value of endoscopic rectal ultrasound in predicting the lateral clearance and outcome in patients with lower-third rectal adenocarcinoma. *Endoscopy* 2007; **39**: 309-313

9 **Bhutani MS**. Colorectal endoscopic ultrasound. In: Gress FG, Savides TJ, editors. Endoscopic ultrasonography. 2nd ed. West Sussex: Wiley-Blackwell, 2009: 160-171

10 **Giovannini M**, Ardizzone S. Anorectal ultrasound for neoplastic and inflammatory lesions. *Best Pract Res Clin Gastroenterol* 2006; **20**: 113-135

11 **Hildebrandt U**, Feifel G. Preoperative staging of rectal cancer by intrarectal ultrasound. *Dis Colon Rectum* 1985; **28**: 42-46

12 **Kalaitzakis E**, Panos M, Sadik R, Aabakken L, Koumi A, Meenan J. Clinicians' attitudes towards endoscopic ultrasound: a survey of four European countries. *Scand J Gastroenterol* 2009; **44**: 100-107

13 **Reddy NK**, Markowitz AB, Abbruzzese JL, Bhutani MS. Knowledge of indications and utilization of EUS: a survey of oncologists in the United States. *J Clin Gastroenterol* 2008; **42**: 892-896

14 **Berton F**, Gola G, Wilson SR. Perspective on the role of transrectal and transvaginal sonography of tumors of the rectum and anal canal. *AJR Am J Roentgenol* 2008; **190**: 1495-1504

15 **Rouse HC**, Godoy MC, Lee WK, Phang PT, Brown CJ, Brown JA. Imaging findings of unusual anorectal and perirectal pathology: a multi-modality approach. *Clin Radiol* 2008; **63**: 1350-1360

16 **Saranovic D**, Barisic G, Krivokapic Z, Masulovic D, Djuric-Stefanovic A. Endoanal ultrasound evaluation of anorectal diseases and disorders: technique, indications, results and limitations. *Eur J Radiol* 2007; **61**: 480-489

17 **Skandarajah AR**, Tjandra JJ. Preoperative loco-regional imaging in rectal cancer. *ANZ J Surg* 2006; **76**: 497-504

18 **Halefoglu AM**, Yildirim S, Avlanmis O, Sakiz D, Baykan A. Endorectal ultrasonography versus phased-array magnetic resonance imaging for preoperative staging of rectal cancer. *World J Gastroenterol* 2008; **14**: 3504-3510

19 **Bartram C**, Brown G. Endorectal ultrasound and magnetic resonance imaging in rectal cancer staging. *Gastroenterol Clin North Am* 2002; **31**: 827-839

20 **Gleeson FC**, Clain JE, Papachristou GI, Rajan E, Topazian MD, Wang KK, Levy MJ. Prospective assessment of EUS criteria for lymphadenopathy associated with rectal cancer. *Gastrointest Endosc* 2009; **69**: 896-903

21 **Bhutani MS**. Recent developments in the role of endoscopic ultrasonography in diseases of the colon and rectum. *Curr Opin Gastroenterol* 2007; **23**: 67-73

22 **Harewood GC**, Wiersema MJ, Nelson H, Maccarty RL, Olson JE, Clain JE, Ahlquist DA, Jondal ML. A prospective, blinded assessment of the impact of preoperative staging on the management of rectal cancer. *Gastroenterology* 2002; **123**: 24-32

23 **Garcia-Aguilar J**, Pollack J, Lee SH, Hernandez de Anda E, Mellgren A, Wong WD, Finne CO, Rothenberger DA, Madoff RD. Accuracy of endorectal ultrasonography in preoperative staging of rectal tumors. *Dis Colon Rectum* 2002; **45**: 10-15

24 **Gualdi GF**, Casciani E, Guadalaxara A, d'Orta C, Polettini E, Pappalardo G. Local staging of rectal cancer with transrectal ultrasound and endorectal magnetic resonance imaging: comparison with histologic findings. *Dis Colon Rectum* 2000; **43**: 338-345

25 **Puli SR**, Bechtold ML, Reddy JB, Choudhary A, Antillon MR, Brugge WR. How good is endoscopic ultrasound in differentiating various T stages of rectal cancer? Meta-analysis and systematic review. *Ann Surg Oncol* 2009; **16**: 254-265

26 **Zorcolo L**, Fantola G, Cabras F, Marongiu L, D'Alia G, Casula G. Preoperative staging of patients with rectal tumors suitable for transanal endoscopic microsurgery (TEM): comparison of endorectal ultrasound and histopathologic findings. *Surg Endosc* 2009; **23**: 1384-1389

27 **Kulig J**, Richter P, Gurda-Duda A, Gach T, Klek S. The role and value of endorectal ultrasonography in diagnosing T1 rectal tumors. *Ultrasound Med Biol* 2006; **32**: 469-472

28 **García-Aguilar J**, Hernández de Anda E, Rothenberger DA, Finne CO, Madoff RD. Endorectal ultrasound in the management of patients with malignant rectal polyps. *Dis Colon Rectum* 2005; **48**: 910-916; discussion 916-917

29 **Glancy DG**, Pullyblank AM, Thomas MG. The role of colonoscopic endoanal ultrasound scanning (EUS) in selecting patients suitable for resection by transanal endoscopic microsurgery (TEM). *Colorectal Dis* 2005; **7**: 148-150

30 **Puli SR**, Reddy JB, Bechtold ML, Choudhary A, Antillon MR, Brugge WR. Accuracy of endoscopic ultrasound to diagnose nodal invasion by rectal cancers: a meta-analysis and systematic review. *Ann Surg Oncol* 2009; **16**: 1255-1265

31 **Bipat S**, Glas AS, Slors FJ, Zwinderman AH, Bossuyt PM, Stoker J. Rectal cancer: local staging and assessment of lymph node involvement with endoluminal US, CT, and MR imaging--a meta-analysis. *Radiology* 2004; **232**: 773-783

32 **Maor Y**, Nadler M, Barshack I, Zmora O, Koller M, Kundel Y, Fidder H, Bar-Meir S, Avidan B. Endoscopic ultrasound staging of rectal cancer: diagnostic value before and following chemoradiation. *J Gastroenterol Hepatol* 2006; **21**: 454-458

33 **Muthusamy VR**, Chang KJ. Optimal methods for staging rectal cancer. *Clin Cancer Res* 2007; **13**: 6877s-6884s

34 **Napoleon B**, Pujol B, Berger F, Valette PJ, Gerard JP, Souquet JC. Accuracy of endosonography in the staging of rectal cancer treated by radiotherapy. *Br J Surg* 1991; **78**: 785-788

35 **Gavioli M**, Bagni A, Piccagli I, Fundaro S, Natalini G. Usefulness of endorectal ultrasound after preoperative radiotherapy in rectal cancer: comparison between sonographic and histopathologic changes. *Dis Colon Rectum* 2000; **43**: 1075-1083

36 **Hünerbein M**, Pegios W, Rau B, Vogl TJ, Felix R, Schlag PM. Prospective comparison of endorectal ultrasound, three-dimensional endorectal ultrasound, and endorectal MRI in the preoperative evaluation of rectal tumors. Preliminary results. *Surg Endosc* 2000; **14**: 1005-1009

37 **Badger SA**, Devlin PB, Neilly PJ, Gilliland R. Preoperative staging of rectal carcinoma by endorectal ultrasound: is there a learning curve? *Int J Colorectal Dis* 2007; **22**: 1261-1268

38 **Rafaelsen SR**, Sørensen T, Jakobsen A, Bisgaard C, Lindebjerg J. Transrectal ultrasonography and magnetic resonance imaging in the staging of rectal cancer. Effect of experience. *Scand J Gastroenterol* 2008; **43**: 440-446

39 **Orrom WJ**, Wong WD, Rothenberger DA, Jensen LL, Goldberg SM. Endorectal ultrasound in the preoperative staging of rectal tumors. A learning experience. *Dis Colon Rectum* 1990; **33**: 654-659

40 **Carmody BJ**, Otchy DP. Learning curve of transrectal ultrasound. *Dis Colon Rectum* 2000; **43**: 193-197

41 **Marusch F**, Koch A, Schmidt U, Zippel R, Kuhn R, Wolff S, Pross M, Wierth A, Gastinger I, Lippert H. Routine use of transrectal ultrasound in rectal carcinoma: results of a prospective multicenter study. *Endoscopy* 2002; **34**: 385-390

42 **Mackay SG**, Pager CK, Joseph D, Stewart PJ, Solomon MJ. Assessment of the accuracy of transrectal ultrasonography in anorectal neoplasia. *Br J Surg* 2003; **90**: 346-350

S- Editor Tian L **L- Editor** Stewart GJ **E- Editor** Ma WH

World Journal of Gastroenterology

Online Submissions: http://www.wjgnet.com/1007-9327office
wjg@wjgnet.com
doi:10.3748/wjg.v16.i6.698

World J Gastroenterol 2010 February 14; 16(6): 698-702
ISSN 1007-9327 (print)

REVIEW

Capillaria hepatica in China

Chao-Ding Li, Hui-Lin Yang, Ying Wang

Chao-Ding Li, Hui-Lin Yang, Department of Orthopedics, First Affiliated Hospital of Soochow University, Soochow 215006, Jiangsu Province, China
Ying Wang, Department of Hematology, First Affiliated Hospital of Soochow University, Soochow 215006, Jiangsu Province, China
Author contributions: Li CD, Yang HL and Wang Y all contributed to this paper.
Correspondence to: Hui-Lin Yang, Professor, Department of Orthopedics, First Affiliated Hospital of Soochow University, Soochow 215006, Jiangsu Province, China. hlyangsd@126.com
Telephone: +86-512-67780429 Fax: +86-512-67780999
Received: October 11, 2009 Revised: December 9, 2009
Accepted: December 16, 2009
Published online: February 14, 2010

Abstract

Capillaria hepatica (*C. hepatica*) is a parasitic nematode causing hepatic capillariasis in numerous mammals. Ecologic studies showed that the first hosts of *C. hepatica* were rodents, among which rats had relatively high infection rates, which explains why *C. hepatica* spreads globally. Anatomical studies showed that the liver was the principal site of colonization by these parasites and physical damage tended to occur. Although *C. hepatica* might lead to serious liver disorders, relevant clinical reports were rare, because of the non-specific nature of clinical symptoms, leading to misdiagnosis. This review mainly focuses on the biological characteristics and epidemiology of *C. hepatica* in China and histopathologic changes in the liver, with expectation of gaining a better understanding of the disease and seeking more effective treatment.

Key words: *Capillaria hepatica*; Enoplida infections; Liver diseases; Host-parasite interactions; Diagnosis; Treatment

Peer reviewer: Dr. Assy Nimer, Assistant Professor, Liver Unit, Ziv Medical Centre, Box 1008, Safed 13100, Israel

Li CD, Yang HL, Wang Y. *Capillaria hepatica* in China. *World J Gastroenterol* 2010; 16(6): 698-702 Available from: URL: http://www.wjgnet.com/1007-9327/full/v16/i6/698.htm DOI: http://dx.doi.org/10.3748/wjg.v16.i6.698

INTRODUCTION

Capillaria hepatica (*C. hepatica*) is a nematode parasite of wild rodents and other mammals and has worldwide distribution[1-8]. Adult worms colonize the liver of the host[6,9-11]. They can cause hepatica capillariasis, a serious liver disorder, which may be found both in humans and animals[11-14]. These parasites could be accidentally transmitted to humans by ingestion of embryonated eggs. Up to the year 2000, 37 cases of human infections had been documented[15]. However, there are few reports of the pathology of the infection, which results in serious effects in subjects because of the special anatomic area in which *C. hepatica* congregates. Clinical symptoms of hepatica capillariasis were non-specific with manifestations of persistent fever, hepatomegaly, eosinophilia and, more seriously, death.

MORPHOLOGY AND BIOLOGICAL FEATURES

Morphology

A typical adult *C. hepatica* takes the shape of a slender nematode, with the anterior part of the body narrow, and the posterior part gradually swelling. The females measure about 53-78 mm × 0.11-0.20 mm, but males are approximately 24-37 mm × 0.07-0.10 mm. The esophagus is long, occupying half of the body of the female and a third of the male body. The cauda of *C. hepatica* bears a copulatory spicule and sheath. The eggs of *C. hepatica* resemble those of *Trichuris trichiura*, but differ in size. The *C. hepatica* egg is about 48-66 μm × 28-36 μm, and numerous minipores can be seen in the outer shell[16].

Biological features

C. hepatica parasites live in liver parenchyma, where they

Table 1 Three cases of hepatica capillariasis in China

Reporter	Date	Area in China	Diagnostic basis
Bing-Kun Xu[27]	1979	Guangdong Province	*Capillaria hepatica* (*C. hepatica*) detected by liver biopsy
Xi-Meng Lin[28]	2003	Tangzhuang, Xinxiang City	Persistent fever (40℃), hepatomegaly eosinophilia, and adult *C. hepatica* detected by liver biopsy
Jia-Nin Huang[29]	2003	Fuzhou City, Fujian Province	Persistent fever, anemia, hepatomegaly, eosinophilia, and eggs detected by liver biopsy

Table 2 Infection rate in distinct areas with different rodent species

Reporter	Date	Area in China	Investigated species	Infection rate (%)
Zhou *et al*[33]	1990	Wuhan City, Hubei Province	Norway rat	61.90
			Rattus flavipectus	61.90
			Mus musculus	19.10
Liu *et al*[40]	1997	Shandong Province	Various rodent species including those of rodent-shaped animals	27.36 (Norway rat dominant)
Zhou *et al*[34]	1998	Kunming City, Yunnan Province	Norway rat	66.67
			Yellow breasted rat	65.13
			Mus musculus	21.11
Yuan *et al*[36]	1998	Ningde City, Fujian Province	Chestnut rat	55.56
			Norway rat	66.67
			Rattus flavipectus	44.33
			Rattus losea	38.94
			Rattus confucianus	30.00
Xue *et al*[37]	1998	Fuqing City, Fujian Province	*Rattus flavipectus*	13.11
			Norway rat	12.34
			Shrew	5.29
			Mus musculus	4.59
Zhang *et al*[35]	2002	Jiangle Location, Fujian Province	Norway rat	46.15
			Rattus flavipectus	66.67
Shen *et al*[39]	2003	Dali City, Yunnan Province	Commensal Mus	76.83
			Norway rat	77.01
			Rattus flavipectus	77.46
			Wild Mus	4.47
			Rattus rattus sladerni	38.81
Lin *et al*[41]	2007	Henan Province	Norway rat	25.83
			Rattus flavipectus	12.90
			Mus musculus	10.00
Tung *et al*[38]	2009	Taichung	Various species of rodents	49.50

become biologically mature, then lay eggs in this site. Eggs are immature when produced in the first 4 wk, and these eggs will develop into larvae under favorable conditions of appropriate temperature and moisture. When embryonated, eggs can be ingested by a predator, their larvae then hatch and invade the intestinal mucosa, transporting themselves *via* the mesenteric vein and portal vein to the liver. The first ecdysis takes place 3-4 d after their arrival in the liver, followed by the second, third (5-7 d) and fourth (9-16 d) larval stages. In the fourth stage, sexual differentiation starts. After sexual differentiation (male, 18 d; female, 20 d), they will experience their final ecdysis and become fifth-stage larvae. The life-span of the female lasts about 59 d, with 40 d for males[17]. It is worthy of note that eggs produced by females in the liver are metabolically active for a prolonged period of time, but remain immature. The host which has ingested these immature eggs displays a "spurious infection". In contrast, "true infection" occurs when the host ingests embryonated eggs, which will result in the production of larvae that can invade the intestine wall and lead to hepatica capillariasis.

EPIDEMIOLOGY IN CHINA

Epidemiology in the human population

Reports of the 37 cases of hepatica capillariasis indicate they were scattered predominantly in Japan, India, America, Canada, Brazil, Germany, Italy, Korea and Czechoslovakia[15,18-26]. While only 3 cases of "true infection" had been confirmed in China[27-29], those few cases found in China do not necessarily encompass the overall actual morbidity, as the final diagnosis would have to rely on biopsy or necropsy[30,31], so both the rate of misdiagnosis and missed diagnosis could be higher. Table 1 shows the 3 cases with detailed clinical symptoms.

Epidemiology in the animal population

The chief hosts of *C. hepatica* are various rodents, including more than 70 species, and the principal hosts include *Tamias striatus*, squirrel, mole, shrew, opossum, weasel and skunk[32]. In mainland China, the total infection rate of hepatica capillariasis in rodent species ranges widely. Table 2 highlights the infection rate in distinct areas with different rodent species[33-41].

PATHOLOGY OF HEPATICA CAPILLARIASIS

C. hepatica primarily invade the sinus hepaticus, where they experience maturation and egg-laying. Both the worms and their eggs cause focal chronic inflammation in the liver, and around these worms and eggs appear diverse inflammatory cells, including macrophages, eosinophils, and some multinucleate giant cells. Inflammatory infiltration may persist until the final formation of encapsulation or calcification of dead worms. After the focal parasitic necroinflammatory lesions, septal fibrosis occurs. Although the pathological course of the formation of fibrosis has not been well established, it was speculated that the slow and continuous release of disintegrated products from encapsulated parasitic lesions activated the Kupffer cells, which then promoted the development of fibrosis in the liver[42]. Whether there is a relationship between the focal parasitic hepatic lesions and septal fibrosis remain to be resolved. In the experiment of Gomes *et al*[12], rats were first infected with 600 embryonated eggs, and then injected with a corticoid and *C. hepatica* antigen. After treatment, focal inflammation ceased, but there was no evident alteration in the formation of septal fibrosis. These findings indicated that, although focal lesions and septal fibrosis were both caused by *C. hepatica* infection, they played different roles in the pathological course of the infection. Further studies should be conducted to explore the pathological course of hepatic fibrosis.

DIAGNOSIS

Hepatica capillariasis is an exceptionally rare infection in humans with non-specific clinical manifestations, and frequent misdiagnoses have been made[43]. More importantly, the main difficulties interfering with correct diagnosis were related to the unique biological characteristics of the parasite. Apart from those cases of "spurious infection", both worms and eggs could not be detected in the peripheral blood and stools of infected hosts, so routine laboratory tests of blood and stools invariably showed negative results. Although liver biopsy was a precise and quick method in confirming *C. hepatica* infection, it was not the most appropriate one, as biopsy was a traumatic diagnostic approach. With introduction of immuno-techniques, the detection of *C. hepatica* became more convenient and efficient. Assis and colleagues[12] employed an indirect immunofluorescence test to diagnose hepatica capillariasis successfully. Huang *et al*[44] developed a diagnostic test for experimental rat hepatica capillariasis using an enzyme-linked immunosorbent assay, with high sensitivity and specificity, which was specific for *C. hepatica* infection. The tests described above have been considered practical, reliable and sensitive. A sensitive immunological test is useful for particular clinical situations, but it is essential to take account of the epidemiological surveys in local areas, which may help lead to a more comprehensive diagnosis.

The differential diagnosis should include accidental tissue infection by nematodes, including *Toxocara cati*, *Toxocara canis*, *Fasciola hepatica*, and *Schistosoma japonicum*, hepatitis B virus, hepatitis C virus and visceral larva migrants[45-48].

TREATMENT

Pereira *et al*[30] reported a case of hepatica capillariasis in Brazil where the male subject with massive *C. hepatica* infection survived after treatment with prednisone, disophenol, and pyrantel tartrate. Thanks to marked eosinophilia in the peripheral blood and hepatic lesions, the patient underwent initial therapy with prednisone (60 mg/d) for a session of 10 d and sequential maintenance by 10 mg every other 10 d. To kill the parasites, or at least to prevent the production of eggs, the patient was treated with disophenol (2-6-diiodo-4-nitrophenol) intramuscularly in a single dose of 7.5 mg/kg body weight and with pyrantel tartrate orally in a single dose of 30 mg/kg body weight. Three years after the treatment, a needle biopsy of the liver, showed sparse portal fibrosis but it was otherwise normal, and the patient remained well during an 8-year follow-up. Also, medication with albendazole was generally effective[31].

Other than chemical treatment, partial hepatectomy or some distinct surgical intervention proved therapeutically effective in animal experiments in rats. The results revealed morphologically that the fibrosis was unaffected, but its relative quantity within the microscopic field appeared significantly decreased, as a consequence of the increased liver tissue mass following regeneration[49].

RESEARCH ACHIEVEMENTS

While prevalence of *C. hepatica* is dominant in rodents, other mammalian species showed slight resistance to this infection even in laboratory conditions. Yang *et al*[50] examined the predisposition to *C. hepatica* between rats and cats by injecting each animal with embryonated eggs at high density. The long-term investigation revealed that every rat became infected with *C. hepatica*, while, as was expected, the liver biopsy from cats showed negative results. To further confirm whether there were some differences between rats and mice in the course of the formation of hepatic fibrosis, Andrade *et al*[13] infected both rats and mice with embryonated eggs, and he found that, although rats and mice both had the same pathological changes in the first stage, there were distinct features in the development of hepatic fibrosis. Researching into the immunological mechanisms of hepatica capillariasis, Kim *et al*[51] measured cytokine mRNA expression in mice spleen cells and mesenteric lymph node cells. In the earlier stages, expression of T-helper, Th1 and Th2, cells were at a high level, as well as the expression of immunoglobulin G1 and G2. Expression in functional cells in the spleen was relatively higher than in mesenteric lymph node cells, which indicated that the spleen was the main location of the

response to the infection rather than the mesenteric lymph node. With the density of egg production, expression of interferon-γ became stronger, suggesting that it had significant importance in the defense against infection.

CONCLUSION

C. hepatica can cause a serious liver disorder in its hosts including humans and animals. More simple and accurate diagnostic methods and more effective treatment measures need to be further developed. A better understanding of *C. hepatica* and hepatica capillariasis would help humans to better combat the disease.

REFERENCES

1 **Stidworthy MF**, Lewis JC, Masters NJ, Boardman SI, Hopper JS, de Linan FJ, Redrobe SP, Sayers G. Capillaria hepatica in primates in zoological collections in the British Isles. *Vet Rec* 2009; **164**: 66

2 **Resendes AR**, Amaral AF, Rodrigues A, Almeria S. Prevalence of Calodium hepaticum (Syn. Capillaria hepatica) in house mice (Mus musculus) in the Azores archipelago. *Vet Parasitol* 2009; **160**: 340-343

3 **Quadros RM**, Pilati C, Marques SM, Mazzolli M, Benedet RC. Capillaria hepatica in Puma concolor: first report in Brazil. *J Zoo Wildl Med* 2009; **40**: 586-587

4 **Carvalho-Costa FA**, Silva AG, de Souza AH, Moreira CJ, de Souza DL, Valverde JG, Jaeger LH, Martins PP, de Meneses VF, Araújo A, Bóia MN. Pseudoparasitism by Calodium hepaticum (syn. Capillaria hepatica; Hepaticola hepatica) in the Negro River, Brazilian Amazon. *Trans R Soc Trop Med Hyg* 2009; **103**: 1071-1073

5 **Pizzi R**, Gordon JC, Flach EJ, Routh AD, Clark B, Boardman WS. Capillaria hepatica (syn Calodium hepaticum) in primates in a zoological collection in the UK. *Vet Rec* 2008; **163**: 690-691

6 **Tesana S**, Puapairoj A, Saeseow O. Granulomatous, hepatolithiasis and hepatomegaly caused by Capillaria hepatica infection: first case report of Thailand. *Southeast Asian J Trop Med Public Health* 2007; **38**: 636-640

7 **Reperant LA**, Deplazes P. Cluster of Capillaria hepatica infections in non-commensal rodents from the canton of Geneva, Switzerland. *Parasitol Res* 2005; **96**: 340-342

8 **Redrobe SP**, Patterson-Kane JC. Calodium hepaticum (syn. Capillaria hepatica) in captive rodents in a zoological garden. *J Comp Pathol* 2005; **133**: 73-76

9 **Mowat V**, Turton J, Stewart J, Lui KC, Pilling AM. Histopathological features of Capillaria hepatica infection in laboratory rabbits. *Toxicol Pathol* 2009; **37**: 661-666

10 **Jeong WI**, Do SH, Hong IH, Ji AR, Park JK, Ki MR, Park SC, Jeong KS. Macrophages, myofibroblasts and mast cells in a rat liver infected with Capillaria hepatica. *J Vet Sci* 2008; **9**: 211-213

11 **Oliveira L**, de Souza MM, Andrade ZA. Capillaria hepatica-induced hepatic fibrosis in rats: paradoxical effect of repeated infections. *Rev Soc Bras Med Trop* 2004; **37**: 123-127

12 **Gomes AT**, Cunha LM, Bastos CG, Medrado BF, Assis BC, Andrade ZA. Capillaria hepatica in rats: focal parasitic hepatic lesions and septal fibrosis run independent courses. *Mem Inst Oswaldo Cruz* 2006; **101**: 895-898

13 **Andrade SB**, Andrade ZA. Experimental hepatic fibrosis due to Capillaria hepatica infection (differential features presented by rats and mice). *Mem Inst Oswaldo Cruz* 2004; **99**: 399-406

14 **Ferreira LA**, Andrade ZA. Capillaria hepatica: a cause of septal fibrosis of the liver. *Mem Inst Oswaldo Cruz* 1993; **88**: 441-447

15 **Juncker-Voss M**, Prosl H, Lussy H, Enzenberg U, Auer H, Nowotny N. Serological detection of Capillaria hepatica by indirect immunofluorescence assay. *J Clin Microbiol* 2000; **38**: 431-433

16 **Hamir AN**, Rupprecht CE. Hepatic capillariasis (Capillaria hepatica) in porcupines (Erethizon dorsatum) in Pennsylvania. *J Vet Diagn Invest* 2000; **12**: 463-465

17 **Wright KA**. Observation on the life cycle of Capillaria hepatica (Bancroft, 1893) with a description of the adult. *Can J Zool* 1961; **39**: 167-182

18 **Govil H**, Desai M. Capillaria hepatica parasitism. *Indian J Pediatr* 1996; **63**: 698-700

19 **Choe G**, Lee HS, Seo JK, Chai JY, Lee SH, Eom KS, Chi JG. Hepatic capillariasis: first case report in the Republic of Korea. *Am J Trop Med Hyg* 1993; **48**: 610-625

20 **Cislaghi F**, Radice C. Infection by Capillaria hepatica. First case report in Italy. *Helv Paediatr Acta* 1970; **25**: 647-654

21 **Slais J**, Stěrba J. Solitary liver granulomas in man caused by Capillaria hepatica (Bancroft, 1893) in Czechoslovakia. *Folia Parasitol* (Praha) 1972; **19**: 373-374

22 **Pereira VG**, França LC. [Human Capillaria hepatica infection. Report of a case treated successfully] *Rev Hosp Clin Fac Med Sao Paulo* 1981; **36**: 31-34

23 **Slais J**. The finding and identification of solitary Capillaria hepatica (Bancroft, 1893) in man from Europe. *Folia Parasitol* (Praha) 1973; **20**: 149-161

24 **Vargas Carreto G**, López Martínez H, Victoria Victoria R, Hernández Muñoz G. [Capillaria hepatica. Report of the 2nd cased found in the Mexican Republic] *Bol Med Hosp Infant Mex* 1979; **36**: 909-917

25 **Silverman NH**, Katz JS, Levin SE. Capillaria hepatica infestation in a child. *S Afr Med J* 1973; **47**: 219-221

26 **Fan PC**, Chung WC, Chen ER. Capillaria hepatica: a spurious case with a brief review. *Kaohsiung J Med Sci* 2000; **16**: 360-367

27 **Xu BK**, Li DN. General condition on the rare human parasites in China. *Zhonghua Yixue Zazhi* 1979; **59**: 286-290

28 **Lin XM**, Li H, Zhao XD, Lin XD, Li H, Zhao XD, Deng Y. 1 case of capillaria hepatica infection. *Zhongguo Jishengchongbing Fangzhi Zahi* 2004; **17**: 230

29 **Huang JN**, Lin JX. The pathological diagnosis of the first case of capillaria hepatica in Fujian province. *Zhongguo Renshou Gonghuanbing Zazhi* 2004; **20**: 556

30 **Pereira VG**, Mattosinho Franca LC. Successful treatment of Capillaria hepatica infection in an acutely ill adult. *Am J Trop Med Hyg* 1983; **32**: 1272-1274

31 **Nabi F**, Palaha HK, Sekhsaria D, Chiatale A. Capillaria hepatica infestation. *Indian Pediatr* 2007; **44**: 781-782

32 **Solomon GB**, Handley CO. Capillaria hepatica (Bancroft, 1893) in Appalachian mammals. *J Parasitol* 1971; **57**: 1142-1144

33 **Zhou ZL**, Wu HY, Mao XP, Fang ZM. Investigate the infection rate of capillaria hepatica on rats. *Zhongguo Bingyuan Shengwuxue Zazhi* 1991; **4**: 225

34 **Zhou XM**, Zhang GF, Li C, Li FH, Yin ZH, Yang JL, Su P. Investigation on rats infected with Capillaria hepatica in Kunming. *Zhongguo Renshou Gonghuanbing Zazhi* 1998; **14**: 33

35 **Zhang LY**, Huang JY, Yang FZ. Investigate on rats infected with capillaria hepatica in Jiangle. *Zhongguo Jishengchoubing Fangzhi Zazhi* 2003: **16**: 19-20

36 **Yuan GL**, Li XY, Chen WJ. Investigation on Rattus losea infected with Capillaria hepatica in Ningde. *Zhongguo Meijie Shengwuxue Ji Kongzhi Zazhi* 2000; **11**: 301-302

37 **Xue YS**, Wu CH, Huang MS,Li RH. Investigation on rats infected with capillaria hepatica in Fuqing. *Haixia Yufang Yixue Zazhi* 1998; **4**: 31-32

38 **Tung KC**, Hsiao FC, Yang CH, Chou CC, Lee WM, Wang KS, Lai CH. Surveillance of endoparasitic infections and the first report of Physaloptera sp. and Sarcocystis spp. in farm rodents and shrews in central Taiwan. *J Vet Med Sci* 2009; **71**: 43-47

39 **Shen LJ**, Luo ZY, Li W, Li ZH, Gao C, Yang WB, Li LY, Qian

TJ. Investigation on rats infected with capillaria hepatica in Dali. *Zhongguo Jishengchoubing Fangzhi Zazhi* 2003; **16**: 296-298
40 **Liu YX**, Yang ZQ, Meng XR, Wu QY. Investigation on rats infected with capillaria hepatica in some region of Shandong province. *Dongwuxue Zazhi* 1997; **32**: 1-3
41 **Lin XM**, Xu BL, Zhao XD, Li H, Huang Q, Deng Y, Hao ZY, Zhang AM. Epidemiological investigation on capillaria hepatica infection among little animal in henan province. *Zhongguo Jishengchoubing Fangzhi Zazhi* 2007; **2**: 44-46
42 **Lemos QT**, Magalhães-Santos IF, Andrade ZA. Immunological basis of septal fibrosis of the liver in Capillaria hepatica-infected rats. *Braz J Med Biol Res* 2003; **36**: 1201-1207
43 **Galvão VA**. [Capillaria hepatica: an evaluation of its pathogenic role in man] *Mem Inst Oswaldo Cruz* 1981; **76**: 415-433
44 **Huang HC**, Ling HB, Liang SH, Xing WL, Pan CW. Diagnosis of Experimental rat hepatica capillariasis by ELISA. *Wenzhou Yixueyuan Xuebao* 2001; **31**: 299-300, 302
45 **Chen H**, He YW, Liu WQ, Zhang JH. Rosiglitazone prevents murine hepatic fibrosis induced by Schistosoma japonicum. *World J Gastroenterol* 2008; **14**: 2905-2911
46 **Dobrucali A**, Yigitbasi R, Erzin Y, Sunamak O, Polat E, Yakar H. Fasciola hepatica infestation as a very rare cause of extrahepatic cholestasis. *World J Gastroenterol* 2004; **10**: 3076-3077
47 **Yan KK**, Guirgis M, Dinh T, George J, Dev A, Lee A, Zekry A. Treatment responses in Asians and Caucasians with chronic hepatitis C infection. *World J Gastroenterol* 2008; **14**: 3416-3420
48 **Zheng M**, Cai WM, Weng HL, Liu RH. ROC curves in evaluation of serum fibrosis indices for hepatic fibrosis. *World J Gastroenterol* 2002; **8**: 1073-1076
49 **Santos CC**, Onofre-Nunes Z, Andrade ZA. Role of partial hepatectomy on Capillaria hepatica-induced hepatic fibrosis in rats. *Rev Soc Bras Med Trop* 2007; **40**: 495-498
50 **Yang FZ**, Huang XH, Tu ZP, Zhang YZ. Establishment of an animal model of capillaria hepatica infection among little animal in Henan province. *Zhongguo Jishengchouxue Yu Jishengchoubing Zazhi* 2000; **18**: 229-231
51 **Kim DK**, Joo KH, Chung MS. Changes of cytokine mRNA expression and IgG responses in rats infected with Capillaria hepatica. *Korean J Parasitol* 2007; **45**: 95-102

S- Editor Tian L **L- Editor** Cant MR **E- Editor** Lin YP

World Journal of Gastroenterology

Online Submissions: http://www.wjgnet.com/1007-9327office
wjg@wjgnet.com
doi:10.3748/wjg.v16.i6.703

World J Gastroenterol 2010 February 14; 16(6): 703-712
ISSN 1007-9327 (print)

ORIGINAL ARTICLE

Schistosoma mansoni proteins attenuate gastrointestinal motility disturbances during experimental colitis in mice

Nathalie E Ruyssers, Benedicte Y De Winter, Joris G De Man, Natacha D Ruyssers, Ann J Van Gils, Alex Loukas, Mark S Pearson, Joel V Weinstock, Paul A Pelckmans, Tom G Moreels

Nathalie E Ruyssers, Benedicte Y De Winter, Joris G De Man, Natacha D Ruyssers, Ann J Van Gils, Paul A Pelckmans, Tom G Moreels, Laboratory of Experimental Medicine and Pediatrics, Division of Gastroenterology, University of Antwerp, 2610 Antwerp, Belgium
Alex Loukas, Mark S Pearson, Division of Infectious Diseases and Immunology, Queensland Institute of Medical Research, 4006 Brisbane, Australia
Joel V Weinstock, Division of Gastroenterology-Hepatology, Tufts New England Medical Center, Boston, MA 02111, United States
Author contributions: Ruyssers NE, De Winter BY, De Man JG, Ruyssers ND and Van Gils AJ performed the experiments; Ruyssers NE analyzed the data; Loukas A, Pearson MS and Weinstock JV provided the proteins and the analytic tools and were also involved in editing the manuscript; De Winter BY, De Man JG, Pelckmans PA and Moreels TG coordinated the work and were also involved in editing the manuscript; Ruyssers NE wrote the paper.
Supported by The Fund of Scientific Research (FWO), Flanders, Project G.0134.07 and by the University of Antwerp, BOF Grant FA02/3/3257
Correspondence to: Tom G Moreels, Professor, Division of Gastroenterology and Hepatology, Antwerp University Hospital, Wilrijkstraat 10, 2650 Antwerp, Belgium. tom.moreels@uza.be
Telephone: +32-3-8213323 Fax: +32-3-8214478
Received: October 14, 2009 Revised: November 12, 2009
Accepted: November 19, 2009
Published online: February 14, 2010

Abstract

AIM: To investigate the therapeutic effect of *Schistosoma mansoni* (*S. mansoni*) soluble worm proteins on gastrointestinal motility disturbances during experimental colitis in mice.

METHODS: Colitis was induced by intrarectal injection of trinitrobenzene sulphate (TNBS) and 6 h later, mice were treated ip with *S. mansoni* proteins. Experiments were performed 5 d after TNBS injection. Inflammation was quantified using validated inflammation parameters. Gastric emptying and geometric center were measured to assess *in vivo* gastrointestinal motility. Peristaltic activity of distal colonic segments was studied *in vitro* using a modified Trendelenburg set-up. Cytokine profiles of T-lymphocytes isolated from the colon were determined by real time reverse transcriptase-polymerase chain reaction.

RESULTS: Intracolonic injection of TNBS caused severe colitis. Treatment with *S. mansoni* proteins significantly ameliorated colonic inflammation after 5 d. TNBS did not affect gastric emptying but significantly decreased the geometric center and impaired colonic peristaltic activity 5 d after the induction of colitis. Treatment with *S. mansoni* proteins ameliorated these *in vivo* and *in vitro* motility disturbances. In addition, TNBS injection caused a downregulation of effector T cell cytokines after 5 d, whereas a *S. mansoni* protein effect was no longer observed at this time point.

CONCLUSION: Treatment with *S. mansoni* proteins attenuated intestinal inflammation and ameliorated motility disturbances during murine experimental colitis.

Key words: *Schistosoma mansoni*; Helminth proteins; Colitis; Peristalsis; Crohn's disease; Gastrointestinal motility; Trinitrobenzene sulphate

Peer reviewer: Angelo A Izzo, Professor, Department of Experimental Pharmacology, University of Naples Federico II, via D Montesano 49, Naples 80131, Italy

Ruyssers NE, De Winter BY, De Man JG, Ruyssers ND, Van Gils AJ, Loukas A, Pearson MS, Weinstock JV, Pelckmans PA, Moreels TG. *Schistosoma mansoni* proteins attenuate gastrointestinal motility disturbances during experimental colitis in mice. *World J Gastroenterol* 2010; 16(6): 703-712 Available

from: URL: http://www.wjgnet.com/1007-9327/full/v16/i6/703.htm DOI: http://dx.doi.org/10.3748/wjg.v16.i6.703

INTRODUCTION

Crohn's disease and ulcerative colitis, the two most common forms of inflammatory bowel diseases (IBD), are idiopathic inflammatory disorders of the intestine. The current hypothesis states that IBD results from an uncontrolled immune response against intraluminal bacterial antigens in genetically predisposed individuals[1,2]. Genetic factors as well as environmental factors contribute to the development of the inappropriate immune response[3].

The incidence of Crohn's disease is highest in well-developed countries[4]. According to the hygiene hypothesis, this is directly related to the higher hygienic standards in these countries[5]. It is suggested that the lack of exposure to intestinal parasites (e.g. helminths) contributes to the susceptibility to Crohn's disease[6-8]. Several experimental and clinical studies showed the beneficial effect of helminth infections in IBD[9-12]. Current research is focusing on identifying helminth molecules with immunomodulatory function that exert this protective effect[13].

Patients with Crohn's disease often suffer from disturbed gastrointestinal motility leading to symptoms such as abdominal pain, cramps, diarrhea, weight loss, rectal bleeding and malnutrition[14,15]. It is well established that inflammation of the gut results in functional and structural changes of the enteric nervous system[16,17] and changes in smooth muscle contractility[18,19]. For instance, patients with ulcerative colitis have increased propagating contractions with lower peak amplitudes coupled with variable transit[20], whereas delayed gastric emptying and prolongation of orocecal transit time have been reported in patients with Crohn's disease[21-23]. Dysmotility can also occur in non-inflamed sites of the gastrointestinal tract. Gastroparesis often occurs in patients with inflammation restricted to the small or large intestine[14,24]. Motility disturbances may also persist in the period following an episode of gastrointestinal inflammation, resulting in the development of irritable bowel syndrome or functional dyspepsia[14,25].

The aim of this study was to investigate the therapeutic potential of *Schistosoma mansoni* (*S. mansoni*) soluble worm proteins (SmSWP) on gastrointestinal motility disturbances 5 d after induction of experimental colitis in mice both *in vivo* and *in vitro*. In addition, the inflammatory reaction was quantified and the balance between different T cell subsets was investigated based on their cytokine profile to elucidate the underlying immunological pathways.

MATERIALS AND METHODS

TNBS-induced colitis

Colitis was induced by intraluminal injection of 2,4,6-trinitrobenzene sulfonic acid (TNBS) as previously described[26]. Briefly, male Swiss mice (weight 26-28 g, Charles River, France) were fasted for 24 h and subsequently anesthetized by ketamine (90 mg/kg, ip) and xylazine (10 mg/kg, ip). Next, 100 μL of a 10 mg TNBS in 30% ethanol solution was injected intrarectally. Ethanol is required to break the intestinal epithelial barrier, whereas TNBS is a haptenating agent that immunogenizes autologous proteins. Control animals received an intrarectal injection of 100 μL saline. Afterwards, mice were held upside-down for 1 min to prevent leakage of TNBS solution. The Medical Ethical Committee on animal experimentation of the University of Antwerp, Belgium, approved all experiments.

Preparation of antigen mixtures

SmSWP were prepared as described previously[27]. Briefly, *S. mansoni* adult worms were recovered from mice (housed at the Queensland Institute of Medical Research, Brisbane, Australia), washed and homogenized in PBS and soluble proteins were extracted by centrifugation. Mice were treated with 25 μg SmSWP ip. Proteins were diluted to a final volume of 100 μL in PBS. Control animals were injected ip with 100 μL PBS.

Experimental protocol

In a previous study we investigated the time course of inflammation during TNBS colitis and found that inflammation peaked at day 3 and that colitis was self-limiting with near complete remission after 1 wk. In the present study, we wanted to evaluate the effect of helminth protein treatment after the peak of inflammation but when overt signs of colitis were still present.

In a first set of experiments, we scored the therapeutic effect of SmSWP on colonic inflammation 5 d after the induction of colitis. Six hours after TNBS injection, mice were treated once ip with 25 μg *S. mansoni* proteins or phosphate-buffered saline (PBS). Five days later, mice were sacrificed and inflammation was scored based on 5 parameters: clinical disease activity, macroscopic and microscopic inflammation score, extent of colonic inflammation and myeloperoxidase activity. Two different groups were studied: TNBS mice treated with PBS (TNBS-PBS) after 5 d and TNBS mice treated with 25 μg SmSWP (TNBS-SmSWP) after 5 d (n = 8-10 in each group).

In a second set of experiments, we investigated the effect of SmSWP treatment on *in vivo* gastrointestinal motility and *in vitro* colonic peristalsis 5 d after induction of colitis. Four different groups were studied: control-PBS mice, control mice treated with 25 μg SmSWP (control-SmSWP), TNBS-PBS mice and TNBS-SmSWP mice (n = 7-10 in each group). In preliminary experiments we also investigated the effect of colitis on gastrointestinal motility disturbances 3 d after the induction of colitis, and the effect of SmSWP treatment as these experiments were not performed previously.

In a third set of experiments, we investigated the

cytokine profile of colonic T cells 5 d after induction of colitis. Cytokine profiles were studied in 4 different groups: control-PBS, control-SmSWP, TNBS-PBS, TNBS-SmSWP (n = 5-8 in each group, for each n, colonic tissue of 3 mice was pooled).

Inflammatory scores

Briefly, the clinical disease score (0-8) was based on the following characteristic parameters (0-2 score each): weight loss, piloerection, immobility and blepharitis[27].

After sacrifice, the colon was removed and opened to score colonic damage macroscopically. Four parameters were taken into account: presence of adhesions, degree of colonic ulcerations, wall thickness, and degree of mucosal edema. The total score ranged from 0 to 12[28]. The extent of inflammation in the colon was also measured and expressed in cm. Tissue samples were harvested for histological assessment of the inflammatory infiltrate and for myeloperoxidase (MPO) assay. Colonic segments were fixed in 4% formaldehyde and embedded in paraffin for hematoxylin-eosin staining. Microscopic inflammation score ranged from 0 to 10 based on the following parameters: inflammatory infiltrate, number of gut wall layers infiltrated, loss of mucosal architecture, and edema[27]. MPO activity was measured to monitor the degree of myeloid cell infiltration in the colon. Colonic MPO activity was assayed according to published methods[29] and expressed as units MPO per gram tissue.

In vivo measurement of gastrointestinal motility: Evans blue technique

Mice were fasted for 18 h and *in vivo* semi-liquid meal motility was assessed according to published methods[30]. Briefly, mice received an intragastric injection of 0.1 mL Evans blue (50 mg/mL + 0.5% methylcellulose) *via* an orogastric cannula. Fifteen minutes later, mice were anesthetized and a laparotomy was performed. The stomach and small intestine were resected and the small intestine was divided into 5 segments of equal length. The amount of Evans blue in the segments was measured spectrophotometrically to assess gastric emptying (GE) and geometric center (GC): %GE = [ΣA_{565} (intestine 1-5)/ΣA_{565} (stomach + intestine 1-5)] × 100; GC = Σ (A_{565} of Evans blue per segment × segment number)/total A_{565}.

In vivo measurement of gastrointestinal motility: Solid beads technique

Mice were fasted for 18 h and *in vivo* solid meal motility was assessed as previously described[31]. Mice received an intragastric gavage of 25 green glass beads (0.4-0.5 mm in diameter) together with 0.5 mL H_2O solution *via* an orogastric cannula and were transferred to a wired bottom cage to prevent coprophagy[32]. Subsequently, 30, 120 and 360 min after gavage, mice were anesthetized, the gastrointestinal tract was resected and divided into different segments: stomach, 5 small intestinal segments, cecum, 2 colonic segments and feces. The number of beads in each segment was counted under a stereomicroscope and GE and GC were calculated by the following equations: %GE = [number of beads (small intestine 1-5 + cecum + colon 1-2 + feces)/total number of beads] × 100; GC = Σ (beads per segment × segment number)/total number of beads.

In vitro evaluation of colonic peristaltic activity

Assessment of colonic peristalsis was performed as previously described[31]. Briefly, mice were anesthetized, the colon was removed, flushed and put in cold aerated Krebs-ringer solution. The distal colon segment (3 cm in length) was mounted horizontally in an organ bath. For each segment, the oral end was connected to a perfusion pump for intraluminal infusion of Krebs solution and the other end was attached to a pressure transducer and a vertical tube of which the outlet could be raised in height. After 30 min of equilibration, the outlet was increased from 0 to 7.5 cm. Under these circumstances, spontaneous peristaltic contractions occurred. This activity was associated with regular pressure increases which were recorded by the pressure transducer and analyzed by a data-acquisition system (CED 1401, Cambridge Electronic Design, Cambridge, UK). After an equilibration period of 20 min, the mean amplitude (cmH_2O) of 3 consecutive peristaltic contractions as well as the mean time interval(s) between 4 subsequent peristaltic contractions were calculated and compared.

Investigation of T cell cytokine profiles

Colonic lamina propria mononuclear cells were isolated based on a 30%:70% gradient Percoll column as previously described[27,33]. Colonic lamina propria T cells were subsequently isolated by positive selection using the EasySep enrichment procedure employing antibody-coated, magnetic particles as described by the manufacturer (Stem Cell Technologies, Vancouver, Canada). Total RNA was extracted from isolated colonic T cells by using the Absolutely RNA microprep kit as described by the manufacturer (Stratagene, La Jolla, CA, USA).

Using real time reverse transcriptase-polymerase chain reaction (RT-PCR), we performed a quantitative analysis of the mRNA expression of different cytokines to determine the balance between T helper (Th) 1, Th17, Th2 and Treg (regulatory T) cells in colonic tissue. TaqMan Gene Expression assays (Applied Biosystems, Lennik, Belgium) specific for IFNγ produced by Th1 cells, IL17 produced by Th17 cells, IL-5 produced by Th2 cells and IL-10 produced by Treg cells were performed on a ABI Prism 7300 sequence detector system (Applied Biosystems, Lennik, Belgium) in 25 μL reaction volumes containing One step Universal PCR master mix (Applied Biosystems, Lennik, Belgium) as previously described[27].

Drugs

NaCl 0.9% (Plurule®, Baxter, Lessines, Belgium); 2,4,6 trinitrobenzene sulfonic acid solution (Fluka, Neu-Ulm, Germany); PBS (GIBCO BRL, Merelbeke, Belgium); diethyl ether, ethanol absolute, 30% hydrogen peroxide, methanol absolute, potassium dihydrogen phosphate, dipotassium hydrogen phosphate trihydrate (Merck, Darmstadt, Germany); xylazine (Rompun®, Bayer, Brussels, Belgium); ketamine (Ketalar®, Pfizer, Brussels, Belgium); hexadecyltrimethylammonium bromide, *o*-dianisidine dihydrochloride, FCS, collagenase, Percoll, Evans blue (Sigma Chemical, St. Louis, Missouri, USA); RPMI 1640, EDTA, HBSS, HEPES, L-glutamine, β-mercaptoethanol, sodium pyruvate, penicillin, streptomycin (Invitrogen, Merelbeke, Belgium), glass beads (0.4-0.5 mm in diameter) (VWR international, Leuven, Belgium) were purchased from the respective companies mentioned in parentheses. Helminth protein preparation was described earlier.

Presentation of results and statistical analysis

Data are presented as mean ± SE. Statistical analysis was performed in SPSS 16.0 for Windows. Analyses of the non-parametric data (clinical disease score, macroscopic and microscopic inflammation score) were performed by Mann-Whitney *U* tests. Parametric data (extent of inflammation, MPO, GE, GC, amplitude, interval and RT-PCR results) were analyzed by Student's *t*-tests or by two-way ANOVA (with TNBS colitis as factor 1 and protein treatment as factor 2). When the interaction was significant one-way ANOVA and Student-Newman-Keuls post hoc analysis was performed. P values $\leqslant 0.05$ were considered to be significant.

RESULTS

Effect of SmSWP on TNBS-induced colitis after 5 d

The injection of TNBS caused an increase in all inflammatory parameters (Figure 1A-E) as compared to control mice that did not show any signs of inflammation (data not shown).

Treatment of TNBS-injected mice with SmSWP caused a significant decrease in clinical disease score (Figure 1A), macroscopic inflammation score (Figure 1B), extent of colonic inflammation (Figure 1C), microscopic inflammation score (Figure 1D) and a tendency to decrease the MPO activity (Figure 1E) as compared to TNBS-PBS mice.

Effect of TNBS-induced colitis per se on gastrointestinal motility

In preliminary experiments, 3 d after the induction of colitis, GE and GC of a semi-liquid Evans blue solution were not significantly different between control and TNBS mice: GE was 43% ± 9% in controls and 48% ± 10% in TNBS colitis mice and GC was 2.1 ± 0.3 in controls and 2.2 ± 0.3 in TNBS colitis mice (n = 7-9). We also evaluated

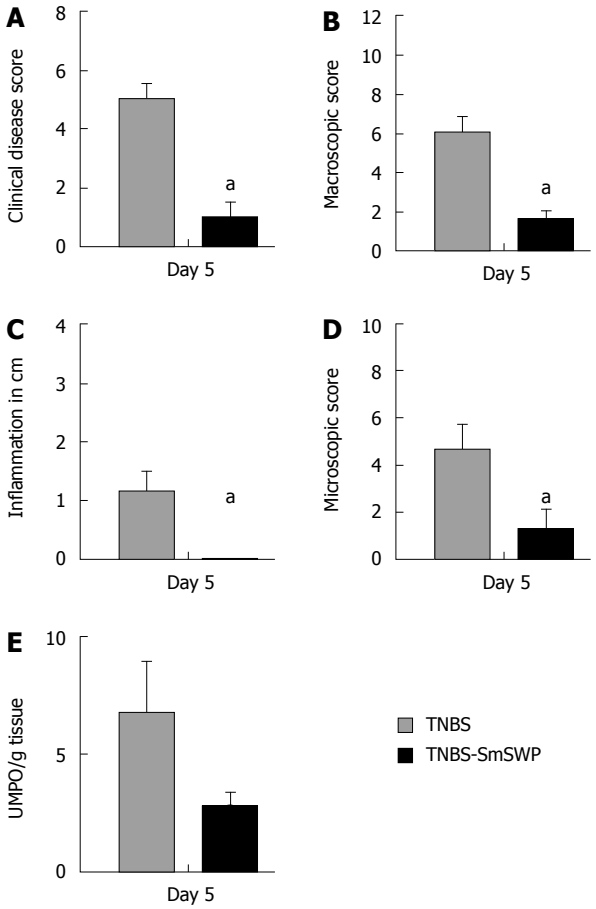

Figure 1 Effect of 25 μg Schistosoma mansoni soluble worm (SmSWP) proteins on clinical disease score (A), macroscopic score (B), extent of inflammation (C), microscopic score (D) and myeloperoxidase (MPO) activity (E) 5 d after trinitrobenzene sulphate (TNBS)-induced colitis. Grey bars represent phosphate-buffered saline (PBS)-treated TNBS mice; black bars represent SmSWP-treated TNBS mice. Data are presented as mean ± SE. Non-parametric data (A, B, D) were analyzed by the Mann-Whitney *U* test, parametric data (C, E) were analyzed by the Student's *t*-test; n = 8-10; $^aP \leqslant 0.05$, significant effect of SmSWP treatment.

the effect of colitis on gastrointestinal motility after intragastric gavage of 25 glass beads 3 d after the injection of TNBS. Experiments were performed 30 min, 120 min and 360 min after intragastric gavage of the marker: GE progressed over time in control mice (from 32% ± 12% to 61% ± 14% and 100% ± 0%, respectively) and in TNBS mice (from 42% ± 13% to 81% ± 9% and 97% ± 2%, respectively) but no significant differences between the control and TNBS groups were observed. The GC also increased over time from 1.5 ± 0.2 (30 min) to 3.2 ± 0.7 (120 min) and to 7.3 ± 0.2 (360 min) in control mice. This time-dependent increase in GC was also observed in mice with colitis (from 1.7 ± 0.3 to 2.9 ± 0.5 and 5.5 ± 0.6). When measured 360 min after gavage of the beads, GC in mice with colitis (5.5 ± 0.6) was significantly lower as compared to control mice (7.33 ± 0.2). Based on these preliminary results, further measurements studying the effect of worm protein treatment on GC were performed 360 min after intragastric gavage of 25 glass beads.

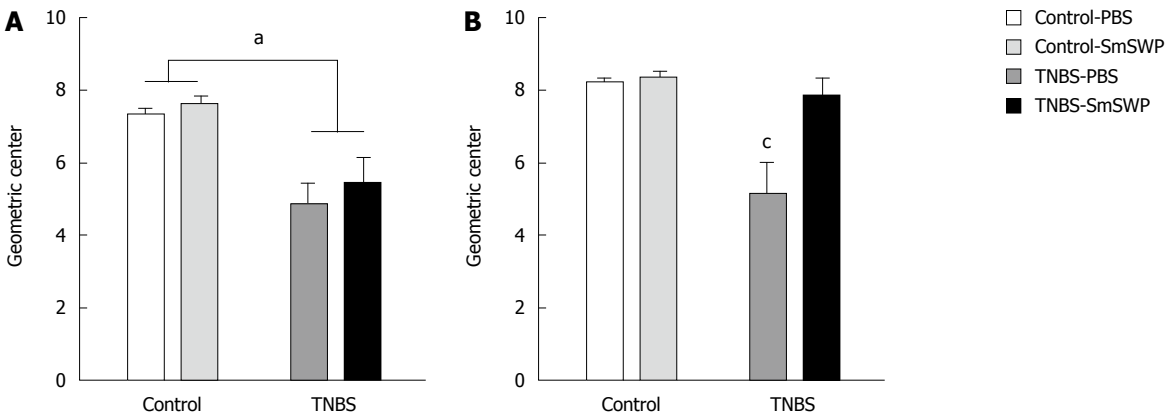

Figure 2 Effect of 25 μg *S. mansoni* proteins on geometric center 3 d (A) and 5 d (B) after the induction of colitis. Data were analyzed by two-way ANOVA with the Student-Newman-Keuls (SNK) post hoc test; n = 7-10; $^{a}P \leqslant 0.05$, significant colitis effect; $^{c}P \leqslant 0.05$, post hoc analysis showed a statistically significant difference from the other 3 groups.

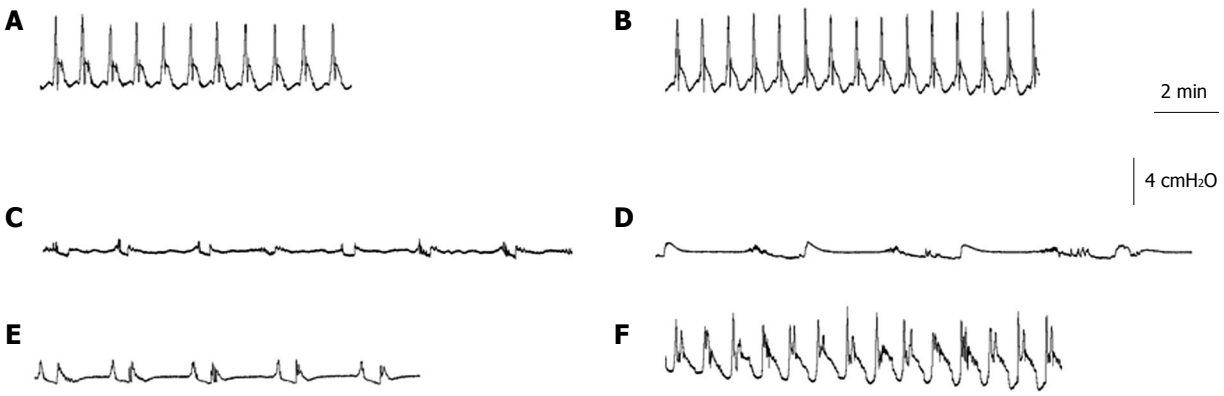

Figure 3 Peristaltic tracings as recorded in the control-PBS group (A), the control-25 μg SmSWP group (B), the TNBS-PBS group on day 3 (C), the TNBS-PBS group on day 5 (D), the TNBS-25 μg SmSWP group on day 3 (E) and the TNBS-25 μg SmSWP group on day 5 (F).

Effect of SmSWP treatment on delayed gastrointestinal transit during TNBS colitis

Experiments were performed 3 d (Figure 2A) and 5 d (Figure 2B) after TNBS injection. Treatment of control mice with SmSWP had no effect *per se* on GC at both time points (Figure 2A and B). TNBS-colitis significantly reduced GC 360 min after intragastric gavage of the beads both at day 3 and at day 5 (Figure 2A and B). Treatment of colitis mice with SmSWP had no effect on GC 3 d after the injection of TNBS (Figure 2A). However, treatment of colitis mice with SmSWP reversed the TNBS-induced decrease in GC at day 5 (Figure 2B).

Effect of SmSWP treatment on colonic peristalsis

Distention-induced peristaltic contractions were recorded (Figure 3) and, subsequently, the amplitude and the interval between the peristaltic waves were measured.

Peristaltic activity of distal colonic segments was measured 3 d (Figure 4A and B) and 5 d (Figure 4C and D) after TNBS enema. Treatment of control mice with SmSWP had no significant effect on colonic peristaltic activity at the two different time points (Figure 3B and Figure 4A-D). The induction of colitis caused significant impairment of peristaltic activity as shown by a significant decrease in amplitude and an increase in interval between the waves. These TNBS-induced disturbances in peristalsis were significant both on day 3 and on day 5 (Figure 3C and D, Figure 4A-D). Furthermore, it is important to note that in 4 of 8 TNBS-PBS mice on day 3 we were not able to measure any peristaltic activity whereas this was only the case in 1 of 8 TNBS-SmSWP mice.

Treatment with SmSWP did not ameliorate the disturbed peristaltic activity caused by intestinal inflammation after 3 d (Figure 3E, Figure 4A and B). However, 5 d after the induction of colitis the amplitude of the distension-induced peristaltic contractions was significantly increased to normal control values when mice were treated with SmSWP (Figure 3F and Figure 4C). At this time point, the mean interval between the waves remained increased after treatment with SmSWP as compared to control animals (Figure 4D).

Measurement of cytokine profiles in colonic T cells

We recently showed the importance of the differential roles of Th1, Th17, Th2 and Treg cells in colonic tissue 3 d after the induction of TNBS colitis and the effect of SmSWP treatment on these T cell subsets[27]. In this study we investigated the cytokine profiles of

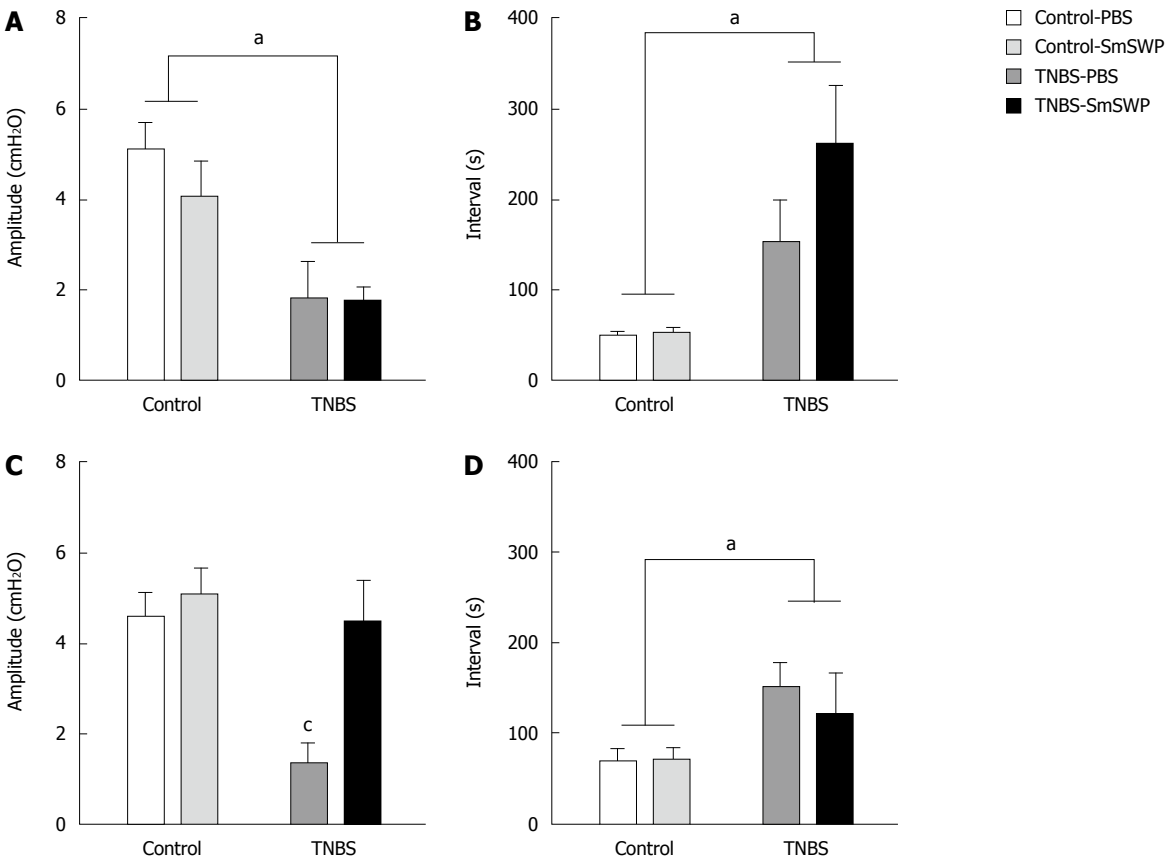

Figure 4 Effect of 25 μg *S. mansoni* proteins on the amplitude and interval of peristaltic waves 3 d (A, B) and 5 d (C, D) after the induction of colitis. Data are presented as mean ± SE. Data were analyzed by two-way ANOVA with SNK post hoc test; n = 7-9 (except for the TNBS-PBS group on day 3 n = 4) ; $^{a}P \leqslant 0.05$, significant colitis effect; $^{c}P \leqslant 0.05$, post hoc analysis showed a significant difference from the other 3 groups.

T cells isolated from colonic tissue on day 5 after the induction of colitis. As shown in Figure 5A, interferon (IFN)-γ mRNA expression was not significantly altered in colonic T cells 5 d after the induction of colitis. On the other hand, we found a significant downregulation of interleukin (IL)-17 and IL-5 expression 5 d after the induction of colitis in both PBS- and SmSWP-treated mice (Figure 5B and D). Investigating the Treg response, we found that injection of TNBS and treatment with SmSWP had no significant effect on IL-10 mRNA expression 5 d after TNBS injection (Figure 5C).

DISCUSSION

In this study we showed that treatment with SmSWP ameliorated *in vivo* and *in vitro* motility disturbances in a murine model of TNBS-induced colitis after 5 d.

Experimental and clinical data support the idea that helminths provide protection against IBD[34]. To avoid the possible disadvantages of a therapy with living parasites, current research is now focusing on the identification and characterization of helminth-derived immunosuppressive molecules that contribute to the protective effect[13]. Furthermore, it is well established that gut inflammation leads to disturbed gastrointestinal motility[14]. The model of TNBS-induced colitis is widely used to investigate motility disturbances occurring in the inflamed colon. We previously showed that contractility of colonic longitudinal smooth muscle strips was time-dependently decreased during TNBS colitis in rats and concurrent infection with *S. mansoni* abrogated these TNBS-induced contractility disturbances[10].

In a previous study we showed that TNBS colitis caused clear signs of inflammation 3 d after the induction of colitis and that our model of TNBS colitis was self-limiting with near complete remission after 1 wk[27]. In this study we focused on a later phase during murine TNBS-induced colitis. We showed that 5 d after TNBS injection, treatment with SmSWP also caused a significant decrease in clinical disease score, macroscopic inflammation score, extent of colonic inflammation and microscopic inflammation score at this later time point along the course of colitis. There was however no significant difference in MPO activity between TNBS-PBS and TNBS-SmSWP mice at this time point although a clear tendency of inhibition was observed. Taken together, these results indicate that treatment with helminth proteins ameliorated colonic inflammation leading to accelerated healing of colitis. A similar beneficial effect has been described previously by our group: rats with TNBS colitis showed spontaneous and complete healing of inflammation 4 wk after the induction of colitis and this was reduced to 2 wk

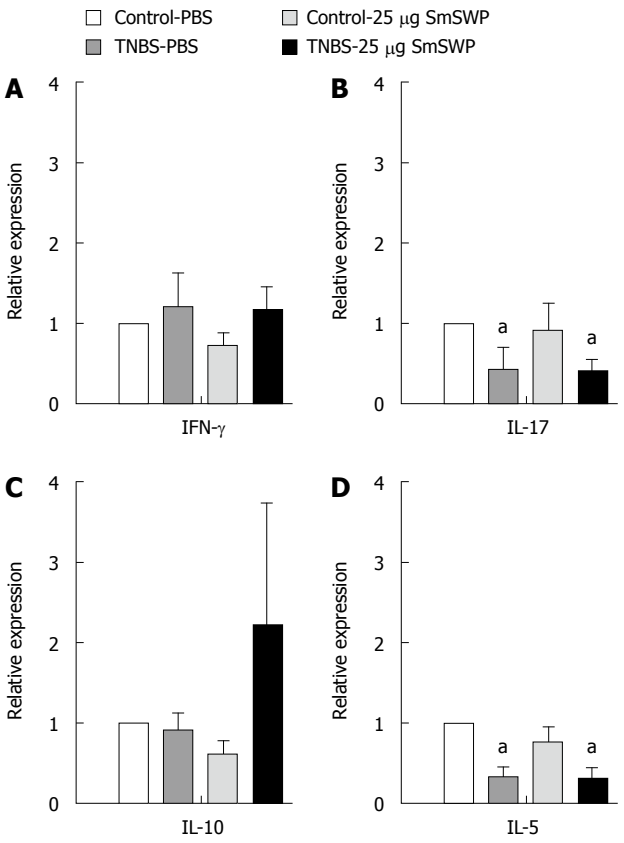

Figure 5 Interferon (IFN) and interleukin (IL) mRNA expression of T helper (Th) 1 (A), Th17 (B), regulatory T (Treg) (C) and Th2 (D) cells isolated from colonic tissue at day 5. Data are expressed as relative expression and the control-PBS group was chosen as calibrator. Data are presented as mean ± SE. Data were analyzed by two-way ANOVA with SNK post hoc test when appropriate; n = 5-8 (except for IL-17 n = 2-5); $^aP \leqslant 0.05$, significant colitis effect, no significant effect of worm protein treatment was shown at day 5.

in rats infected with *S. mansoni*[10].

Investigation of the effect of TNBS colitis on gastrointestinal motility failed to show an effect on gastrointestinal transit of a semi-liquid meal. In other words, colitis did not affect gastric emptying in our murine model. Nevertheless, delayed gastric emptying has been described in a clinical setting[21,23] as well as in the rat TNBS model[35]. Literature on TNBS-induced motility disturbances in mice is scarce and gastric emptying disturbances have not been reported so far. In addition to species differences, this lack of effect of colitis on gastric emptying in mice might be linked to the type and severity of inflammation induced and to the time point chosen to perform motility experiments.

On the other hand, assessment of gastrointestinal transit of a solid meal showed that the geometric distribution of solid beads in the gastrointestinal tract was significantly decreased 3 d after the induction of colitis and this decrease was still evident after helminth protein treatment by day 3. Five days after the induction of colitis, the geometric distribution was still significantly altered in mice with colitis but treatment with worm proteins significantly reversed transit to normal values at this time point. These results indicate that although the healing process of intestinal inflammation is ongoing in untreated TNBS mice by day 5, gastrointestinal motility of the gastrointestinal tract remains disturbed. Only when inflammatory signs are almost completely absent, as in the SmSWP-treated TNBS mice on day 5, was *in vivo* gastrointestinal motility of the distal gastrointestinal tract restored.

Comparable results were found on *in vitro* colonic peristalsis. The amplitude of distension-induced pressure waves as well as the interval between the waves were significantly altered in the colon of mice with TNBS-induced colitis, both at day 3 and day 5. Treatment with SmSWP did not have any ameliorating effect after 3 d whereas the amplitude was significantly increased to normal control values after 5 d. The interval between the waves was nevertheless still significantly augmented as compared to controls at day 5. This suggests that some signs of disturbed peristalsis persisted although inflammation is resolving and that the disturbed interval of *in vitro* peristaltic waves 5 d after colitis and worm treatment did not have any repercussion on *in vivo* colonic motility which, at that time point, was normalized in these mice.

With regard to the clinical setting, treatment of IBD patients with *Trichuris suis* ova caused clinical amelioration of both Crohn's disease and ulcerative colitis as shown by a decrease in Crohn's disease activity index and ulcerative colitis disease activity index[11,12]. This decrease in clinical disease scores might indicate that symptoms such as diarrhea and abdominal pain are less frequent after treatment with helminths. It is well known that infection with intestinal helminths can alter gastrointestinal motility thus contributing to worm expulsion[36]. The role of T cells in those circumstances was previously investigated, leading to the understanding that infection-induced intestinal muscle hypercontractility is CD4+ T cell-dependent[37].

Cytokines produced by mucosal leucocytes can also mediate neurogastrointestinal function. We previously showed that the pro-inflammatory cytokine IL-1β modulates gastrointestinal neuromuscular function[38]. In addition, Th2 cytokines IL-4 and IL-13 contribute to intestinal muscle hypercontractility[39]. Treatment with exogenous IL-10 has been shown to abrogate the delayed gastrointestinal transit during postoperative ileus[40]. Gastrointestinal inflammation during Crohn's disease is mediated *via* Th1 lymphocytes as well as through the recently described Th17 cells[41]. On the other hand, it is well established that helminths have the potential to evoke strong regulatory T cell responses with immunosuppressive properties[42]. In this way, we might hypothesize that infection with helminths induce Th2 and Treg immune responses that contribute to the amelioration of motility disturbances during colitis.

As such, we measured the cytokine profile of colonic T cells. We previously showed that a Th1 response (upregulation of IFN-γ) in the colon was evident 3 d after induction of TNBS colitis. This Th1 response

was significantly suppressed after administration of *S. mansoni* proteins. Treatment with SmSWP also caused an upregulation of regulatory T cell cytokines in the colon after 3 d[27]. In this study we identified the balance between the different T cell subsets in the colon at a later time point along the course of colitis, 5 d after the injection of TNBS. Our results showed there was no longer a significant effect on IFN-γ mRNA expression after the induction of colitis, indicating that the Th1 response seen on day 3 in the colon of TNBS-PBS mice had subsided by day 5. Furthermore, injection of helminth proteins decreased the expression of IL-17 after 3 d, both in control mice and in TNBS mice[27]. After 5 d we found decreased IL-17 mRNA expression due to a colitis effect instead of a protein effect. These differential results on IL-17 mRNA expression at both time points are interesting: at day 3 the effect on IL-17 expression was related to helminth protein, whereas it was colitis mediated at day 5. Although we did not detect a significant effect of colitis or worm protein treatment on IL-5 expression after 3 d, a significant downregulation of IL-5 expression on day 5 was apparent both in the PBS treated group and in the helminth protein treated group. One might hypothesize that the naturally occurring healing response leads to the production of regulatory cytokines which are able to suppress cytokines produced by T effector cells including IL-17 and IL-5. This coincides with the attenuation of inflammatory parameters at this time point as described above.

Experiments performed 3 d after the induction of colitis showed a significant upregulation of the mRNA expression of regulatory cytokines IL-10 and transforming growth factor-β after treatment with SmSWP that had subsided by day 5. Our results showed that the immunological effect of helminth protein treatment on Th1 and Treg cells, which is present after 3 d as shown previously[27], has diminished after 5 d. This might be explained by the fact that proteins were only injected once 6 h after TNBS or PBS injection and not repeatedly until day 5. Nevertheless, this single injection with helminth proteins evoked a protective effect that was almost immediate, leading us to assume that these proteins might also have an effect on innate immunity. It was previously reported that infection with *S. mansoni* prevented experimental colitis in mice by a mechanism dependent on macrophages[43]. Furthermore, dendritic cells are key regulators in the immune defence of the gut and are also influenced by helminth infections[44,45]. Investigation on how helminth proteins affect cells of the innate immune system might contribute to a better understanding of the immunological pathways by which helminth proteins suppress ongoing colonic inflammation.

In this study, we provide evidence that treatment with helminth proteins contributes to amelioration of gastrointestinal motility disturbances. Inhibition of inflammation and amelioration of motility disturbances after treatment with helminth proteins both appear at the same time. However, whether the beneficial effect of helminth protein treatment on gastrointestinal motility is directly or indirectly related to amelioration of inflammation needs to be further established. If helminth proteins provoke a reaction that not only leads to a reduction in inflammation but also influences the enteric nervous system and/or smooth muscle cells directly, these proteins might be useful in the treatment of gastrointestinal motility disturbances.

Taken together, we showed that treatment with *S. mansoni* proteins significantly attenuated the course of TNBS-induced colitis leading to reversal of *in vivo* gastrointestinal motility disturbances and amelioration of *in vitro* colonic peristalsis 5 d after induction. We conclude that SmSWP have therapeutic potential in gut inflammation leading to a marked reduction in inflammation and in gastrointestinal motility disturbances, accelerating the natural course of remission.

COMMENTS

Background

Gastrointestinal inflammation during inflammatory bowel diseases (IBD) results from an uncontrolled immune response against intraluminal antigens in genetically predisposed persons and might lead to motility disturbances with related symptoms. The lack of exposure to helminth infections, as a result of improved living standards and medical conditions, has contributed to the increased incidence of IBD in the developed world.

Research frontiers

Epidemiological, experimental and clinical data support the idea that helminths provide protection against IBD. However, treatment with living helminths may have serious drawbacks such as infection and/or invasion of the parasite to other tissues in the human host where they might cause pathology. Therefore, in this study the authors evaluated the therapeutic potential of helminth-derived proteins on inflammation and associated motility disturbances.

Innovations and breakthroughs

This study investigates the effect of TNBS colitis and exposure *to Schistosoma mansoni* proteins on murine gastrointestinal motility. This is a novel pursuit. The effects of inflammation and therapeutic interventions on gastrointestinal motility are largely ignored but critically important. The authors showed that treatment of experimental colitis with helminth proteins restored gastrointestinal motility.

Applications

Treatment with helminth soluble proteins attenuates inflammation and ameliorates motility disturbances during experimental colitis. These results suggest that helminth soluble proteins represent an attractive therapeutic option in the management of IBD.

Peer review

This is an interesting study dealing with the effect of *Schistosoma mansoni* proteins on inflammatory and motility response in a rat model of inflammatory bowel disease. The experimental methods are described comprehensively and the interpretations and conclusions justified by the results.

REFERENCES

1 **Bamias G**, Cominelli F. Novel strategies to attenuate immune activation in Crohn's disease. *Curr Opin Pharmacol* 2006; **6**: 401-407

2 **Podolsky DK**. Inflammatory bowel disease. *N Engl J Med* 2002; **347**: 417-429

3 **Fiocchi C**. Inflammatory bowel disease: etiology and pathogenesis. *Gastroenterology* 1998; **115**: 182-205

4 **Alic M**. Inflammatory bowel diseases are diseases of higher

socioeconomic status: dogma or reality? *Am J Gastroenterol* 2000; **95**: 3332-3333
5 **Strachan DP**. Family size, infection and atopy: the first decade of the "hygiene hypothesis". *Thorax* 2000; **55** Suppl 1: S2-S10
6 **Lashner BA**, Loftus EV Jr. True or false? The hygiene hypothesis for Crohn's disease. *Am J Gastroenterol* 2006; **101**: 1003-1004
7 **Weinstock JV**, Summers RW, Elliott DE, Qadir K, Urban JF Jr, Thompson R. The possible link between de-worming and the emergence of immunological disease. *J Lab Clin Med* 2002; **139**: 334-338
8 **Moreels TG**, Pelckmans PA. Gastrointestinal parasites: potential therapy for refractory inflammatory bowel diseases. *Inflamm Bowel Dis* 2005; **11**: 178-184
9 **Elliott DE**, Li J, Blum A, Metwali A, Qadir K, Urban JF Jr, Weinstock JV. Exposure to schistosome eggs protects mice from TNBS-induced colitis. *Am J Physiol Gastrointest Liver Physiol* 2003; **284**: G385-G391
10 **Moreels TG**, Nieuwendijk RJ, De Man JG, De Winter BY, Herman AG, Van Marck EA, Pelckmans PA. Concurrent infection with Schistosoma mansoni attenuates inflammation induced changes in colonic morphology, cytokine levels, and smooth muscle contractility of trinitrobenzene sulphonic acid induced colitis in rats. *Gut* 2004; **53**: 99-107
11 **Summers RW**, Elliott DE, Urban JF Jr, Thompson R, Weinstock JV. Trichuris suis therapy in Crohn's disease. *Gut* 2005; **54**: 87-90
12 **Summers RW**, Elliott DE, Urban JF Jr, Thompson RA, Weinstock JV. Trichuris suis therapy for active ulcerative colitis: a randomized controlled trial. *Gastroenterology* 2005; **128**: 825-832
13 **Ruyssers NE**, De Winter BY, De Man JG, Loukas A, Herman AG, Pelckmans PA, Moreels TG. Worms and the treatment of inflammatory bowel disease: are molecules the answer? *Clin Dev Immunol* 2008; **2008**: 567314
14 **De Schepper HU**, De Man JG, Moreels TG, Pelckmans PA, De Winter BY. Review article: gastrointestinal sensory and motor disturbances in inflammatory bowel disease - clinical relevance and pathophysiological mechanisms. *Aliment Pharmacol Ther* 2008; **27**: 621-637
15 **Kraneveld AD**, Rijnierse A, Nijkamp FP, Garssen J. Neuro-immune interactions in inflammatory bowel disease and irritable bowel syndrome: future therapeutic targets. *Eur J Pharmacol* 2008; **585**: 361-374
16 **Collins SM**. The immunomodulation of enteric neuromuscular function: implications for motility and inflammatory disorders. *Gastroenterology* 1996; **111**: 1683-1699
17 **Geboes K**, Collins S. Structural abnormalities of the nervous system in Crohn's disease and ulcerative colitis. *Neurogastroenterol Motil* 1998; **10**: 189-202
18 **Vermillion DL**, Huizinga JD, Riddell RH, Collins SM. Altered small intestinal smooth muscle function in Crohn's disease. *Gastroenterology* 1993; **104**: 1692-1699
19 **Vrees MD**, Pricolo VE, Potenti FM, Cao W. Abnormal motility in patients with ulcerative colitis: the role of inflammatory cytokines. *Arch Surg* 2002; **137**: 439-445; discussion 445-446
20 **Reddy SN**, Bazzocchi G, Chan S, Akashi K, Villanueva-Meyer J, Yanni G, Mena I, Snape WJ Jr. Colonic motility and transit in health and ulcerative colitis. *Gastroenterology* 1991; **101**: 1289-1297
21 **Kristinsson JO**, Hopman WP, Oyen WJ, Drenth JP. Gastroparesis in patients with inactive Crohn's disease: a case series. *BMC Gastroenterol* 2007; **7**: 11
22 **Castiglione F**, Del Vecchio Blanco G, Rispo A, Petrelli G, Amalfi G, Cozzolino A, Cuccaro I, Mazzacca G. Orocecal transit time and bacterial overgrowth in patients with Crohn's disease. *J Clin Gastroenterol* 2000; **31**: 63-66
23 **Annese V**, Bassotti G, Napolitano G, Frusciante V, Bruno M, Conoscitore P, Germani U, Morelli A, Andriulli A. Gastric emptying of solids in patients with nonobstructive Crohn's disease is sometimes delayed. *J Clin Gastroenterol* 1995; **21**: 279-282
24 **Kohno N**, Nomura M, Okamoto H, Kaji M, Ito S. The use of electrogastrography and external ultrasonography to evaluate gastric motility in Crohn's disease. *J Med Invest* 2006; **53**: 277-284
25 **Moreels TG**, De Man JG, De Winter BY, Timmermans JP, Herman AG, Pelckmans PA. Effect of 2,4,6-trinitrobenzenes ulphonic acid (TNBS)-induced ileitis on the motor function of non-inflamed rat gastric fundus. *Neurogastroenterol Motil* 2001; **13**: 339-352
26 **Neurath MF**, Fuss I, Kelsall BL, Stüber E, Strober W. Antibodies to interleukin 12 abrogate established experimental colitis in mice. *J Exp Med* 1995; **182**: 1281-1290
27 **Ruyssers NE**, De Winter BY, De Man JG, Loukas A, Pearson MS, Weinstock JV, Van den Bossche RM, Martinet W, Pelckmans PA, Moreels TG. Therapeutic potential of helminth soluble proteins in TNBS-induced colitis in mice. *Inflamm Bowel Dis* 2009; **15**: 491-500
28 **Menachem Y**, Trop S, Kolker O, Shibolet O, Alper R, Nagler A, Ilan Y. Adoptive transfer of NK 1.1+ lymphocytes in immune-mediated colitis: a pro-inflammatory or a tolerizing subgroup of cells? *Microbes Infect* 2005; **7**: 825-835
29 **Moreels TG**, De Man JG, Bogers JJ, De Winter BY, Vrolix G, Herman AG, Van Marck EA, Pelckmans PA. Effect of Schistosoma mansoni-induced granulomatous inflammation on murine gastrointestinal motility. *Am J Physiol Gastrointest Liver Physiol* 2001; **280**: G1030-G1042
30 **Seerden TC**, De Winter BY, Van Den Bossche RM, Herman AG, Pelckmans PA, De Man JG. Regional differences in gastrointestinal motility disturbances during acute necrotising pancreatitis. *Neurogastroenterol Motil* 2005; **17**: 671-679
31 **Seerden TC**, De Man JG, Holzer P, Van den Bossche RM, Herman AG, Pelckmans PA, De Winter BY. Experimental pancreatitis disturbs gastrointestinal and colonic motility in mice: effect of the prokinetic agent tegaserod. *Neurogastroenterol Motil* 2007; **19**: 856-864
32 **Mashimo H**, Kjellin A, Goyal RK. Gastric stasis in neuronal nitric oxide synthase-deficient knockout mice. *Gastroenterology* 2000; **119**: 766-773
33 **Setiawan T**, Metwali A, Blum AM, Ince MN, Urban JF Jr, Elliott DE, Weinstock JV. Heligmosomoides polygyrus promotes regulatory T-cell cytokine production in the murine normal distal intestine. *Infect Immun* 2007; **75**: 4655-4663
34 **Weinstock JV**, Summers RW, Elliott DE. Role of helminths in regulating mucosal inflammation. *Springer Semin Immunopathol* 2005; **27**: 249-271
35 **De Schepper HU**, De Man JG, Van Nassauw L, Timmermans JP, Herman AG, Pelckmans PA, De Winter BY. Acute distal colitis impairs gastric emptying in rats via an extrinsic neuronal reflex pathway involving the pelvic nerve. *Gut* 2007; **56**: 195-202
36 **Khan WI**, Collins SM. Immune-mediated alteration in gut physiology and its role in host defence in nematode infection. *Parasite Immunol* 2004; **26**: 319-326
37 **Khan WI**, Collins SM. Gut motor function: immunological control in enteric infection and inflammation. *Clin Exp Immunol* 2006; **143**: 389-397
38 **Moreels TG**, De Man JG, De Winter BY, Herman AG, Pelckmans PA. Effect of Interleukin-1beta on cholinergic contractions in the gastrointestinal tract of the rat. *Anaesthesiol Intensivmed Notfallmed Schmerzther* 1998; **33**: 610
39 **Akiho H**, Blennerhassett P, Deng Y, Collins SM. Role

of IL-4, IL-13, and STAT6 in inflammation-induced hypercontractility of murine smooth muscle cells. *Am J Physiol Gastrointest Liver Physiol* 2002; **282**: G226-G232

40 **Stoffels B**, Schmidt J, Nakao A, Nazir A, Chanthaphavong RS, Bauer AJ. Role of interleukin 10 in murine postoperative ileus. *Gut* 2009; **58**: 648-660

41 **Zhang Z**, Hinrichs DJ, Lu H, Chen H, Zhong W, Kolls JK. After interleukin-12p40, are interleukin-23 and interleukin-17 the next therapeutic targets for inflammatory bowel disease? *Int Immunopharmacol* 2007; **7**: 409-416

42 **Elliott DE**, Summers RW, Weinstock JV. Helminths and the modulation of mucosal inflammation. *Curr Opin Gastroenterol* 2005; **21**: 51-58

43 **Smith P**, Mangan NE, Walsh CM, Fallon RE, McKenzie AN, van Rooijen N, Fallon PG. Infection with a helminth parasite prevents experimental colitis via a macrophage-mediated mechanism. *J Immunol* 2007; **178**: 4557-4566

44 **Kane CM**, Cervi L, Sun J, McKee AS, Masek KS, Shapira S, Hunter CA, Pearce EJ. Helminth antigens modulate TLR-initiated dendritic cell activation. *J Immunol* 2004; **173**: 7454-7461

45 **Niess JH**, Reinecker HC. Dendritic cells: the commanders-in-chief of mucosal immune defenses. *Curr Opin Gastroenterol* 2006; **22**: 354-360

S- Editor Wang YR **L- Editor** Cant MR **E- Editor** Ma WH

World Journal of Gastroenterology

Online Submissions: http://www.wjgnet.com/1007-9327office
wjg@wjgnet.com
doi:10.3748/wjg.v16.i6.713

World J Gastroenterol 2010 February 14; 16(6): 713-722
ISSN 1007-9327 (print)

ORIGINAL ARTICLE

Involvement of PI3K and ERK1/2 pathways in hepatocyte growth factor-induced cholangiocarcinoma cell invasion

Apaporn Menakongka, Tuangporn Suthiphongchai

Apaporn Menakongka, Tuangporn Suthiphongchai, Department of Biochemistry, Faculty of Science, Mahidol University, Bangkok 10400, Thailand
Author contributions: Menakongka A performed the experiments, analyzed the data and wrote the manuscript; Suthiphongchai T designed the study, analyzed the data and wrote the manuscript.
Supported by Mahidol University, Thailand and Thailand Research Fund (Suthiphongchai T); Strategic Consortia for Capacity Building of University Faculties and Staff Scholarship, Commission on Higher Education, Ministry of Education, Thailand (Menakongka A)
Correspondence to: Tuangporn Suthiphongchai, Associate Professor, Department of Biochemistry, Faculty of Science, Mahidol University, 272 Rama 6 Road, Bangkok 10400, Thailand. sctsc@mahidol.ac.th
Telephone: +662-2015609 Fax: +662-3547174
Received: October 21, 2009 Revised: November 27, 2009
Accepted: December 4, 2009
Published online: February 14, 2010

Abstract

AIM: To investigate the role of hepatocyte growth factor (HGF) in cholangiocarcinoma (CCA) cell invasiveness and the mechanisms underlying such cellular responses.

METHODS: Effects of HGF on cell invasion and motility were investigated in two human CCA cell lines, HuCCA-1 and KKU-M213, using Transwell *in vitro* assay. Levels of proteins of interest and their phosphorylated forms were determined by Western blotting. Localization of E-cadherin was analyzed by immunofluorescence staining and visualized under confocal microscope. Activities of matrix degrading enzymes were determined by zymography.

RESULTS: Both CCA cell lines expressed higher Met levels than the H69 immortalized cholangiocyte cell line. HGF induced invasion and motility of the cell lines and altered E-cadherin from membrane to cytoplasm localization, but did not affect the levels of secreted matrix metalloproteinase (MMP)-2, MMP-9 and urokinase plasminogen activator, key matrix degrading enzymes involved in cell invasion. Concomitantly, HGF stimulated Akt and extracellular signal-regulated kinase (ERK)1/2 phosphorylation but with slightly different kinetic profiles in the two cell lines. Inhibition of the phosphoinositide 3-kinase (PI3K)/Akt pathway by the PI3K inhibitor, LY294002, markedly suppressed HGF-stimulated invasion of both CCA cell lines, and inhibition of the ERK pathway by U0126 suppressed HGF-induced invasion of the KKU-M213 cell line but had a moderate effect on HuCCA-1 cells.

CONCLUSION: These data indicate that HGF promotes CCA cell invasiveness through dys-localization of E-cadherin and induction of cell motility by distinct signaling pathways depending on cell line type.

Key words: Hepatocyte growth factor; Invasion; Cholangiocarcinoma; Phosphoinositide 3-kinase; Extracellular signal-regulated kinase

Peer reviewers: Hong Joo Kim, MD, PRO, Department of Internal Medicine, Sungkyunkwan University Kangbuk Samsung Hospital, 108, Pyung-Dong, Jongro-Ku, Seoul, 110-746, South Korea; Yu-Yuan Li, Professor, Department of Gastroenterology, First Municipal People's Hospital of Guangzhou, Guangzhou Medical College, Guangzhou 510180, Guangdong Province, China

Menakongka A, Suthiphongchai T. Involvement of PI3K and ERK1/2 pathways in hepatocyte growth factor-induced cholangiocarcinoma cell invasion. *World J Gastroenterol* 2010; 16(6): 713-722 Available from: URL: http://www.wjgnet.com/1007-9327/full/v16/i6/713.htm DOI: http://dx.doi.org/10.3748/wjg.v16.i6.713

INTRODUCTION

Cholangiocarcinoma (CCA) is a malignant tumor of the

biliary epithelium associated with a high metastatic and mortality rate[1]. Incidence of this cancer has increased worldwide[2], and in Thailand the highest incidence is in the northeastern region, where *Opisthorchis viverrini* infection is also prevalent[3]. Although the exact molecular mechanisms of cholangiocarcinogenesis are still under investigation, alterations in important growth factor pathways, such as hepatocyte growth factor (HGF)/Met and ErbB2, have been suggested as being involved[4].

Overexpression and deregulation of Met, a receptor tyrosine kinase, have been reported in many types of cancers[5]. Met is activated *via* binding to its ligand, HGF, also known as scatter factor (SF), a soluble factor first identified as a growth factor for hepatocytes and a dissociation factor for epithelial cells[6]. Hitherto there have been a limited number of investigations into the role of Met in cholangiocarcinoma. Several reports have demonstrated a correlation between Met expression and CCA[7-10]. Immunohistochemical data indicate high expression of Met in well-differentiated CCA and hyperplastic bile ducts of nontumorous liver surrounding CCA, whereas Met expression is low in poorly differentiated tumor[7,8]. Met expression is increased in early developmental stages of CCA, suggesting a role in cholangiocarcinogenesis[9]. Moreover, there is a correlation between Met expression and CCA invasion through adjacent connective tissues[11]. HGF level has been shown also to correlate with CCA differentiation stages in both human and rat models[10,12].

HGF/Met activation induces a variety of biological processes, including cell scattering, invasion, proliferation and survival[13-15]. Among the various cellular responses induced by HGF, cell invasion and metastasis have been implicated strongly in numerous cancer types. HGF has been reported to promote the main requirements of tumor invasion, namely, disruption of cell-cell adhesion complex, cell adhesion to extracellular matrix (ECM), cell motility and production of matrix degrading enzymes, such as matrix metalloproteinases (MMPs) and urokinase plasminogen activator (uPA)[15-18]. Phosphoinositide 3-kinase (PI3K) and mitogen-activated protein kinases/extracellular signal-regulated kinases (MAPKs/ERKs) are the main intracellular signaling pathways implicated in HGF-induced invasion[19,20].

The present study focuses on the role of HGF/Met in CCA cell invasion and the mechanisms underlying cellular responses. Here, we demonstrate that Met is overexpressed in human CCA cell lines and that HGF stimulation induces CCA cell invasion, motility and E-cadherin translocation, but has no effect on MMPs or uPA activity. Use of inhibitors of MEK and PI3K indicate that HGF induces invasion in two different CCA cell lines *via* distinct signaling pathways.

MATERIALS AND METHODS

Cell culture

Human CCA cell lines HuCCA-1 and KKU-M213 were kindly provided by Professor S Sirisinha (Mahidol University, Bangkok, Thailand)[21,22] and Associate Professor B Sripa (Khon Kaen University, Khon Kaen, Thailand)[23,24], respectively. Cholangiocyte H69 cell line was kindly provided by Professor G Alpini (Texas A&M University, TX, USA) and Professor G Gores (Mayo Clinic, MN, USA). CCA cells were grown in HAM/F12 medium (Gibco Invitrogen Co., Auckland, NZ) supplemented with 10% fetal bovine serum (FBS), 100 U/mL penicillin G sodium, 100 μg/mL streptomycin sulfate, 0.25 μg/mL amphotericin B (Invitrogen Co., Auckland, NZ) and 15 mmol/L HEPES (USB Co., OH, USA) at 37℃ under a humidified 50 mL/L CO_2 atmosphere. H69 cells were cultured in DMEM/F12 and DMEM (1:1) (Gibco Invitrogen Co., Auckland, NZ) supplemented with hormones, epidermal growth factor and 10% FBS as previously described[25].

Western blotting analysis

Levels of Met, ERK1/2 and Akt and their phosphorylated forms, and E-cadherin, were determined by Western blotting. Cells (2×10^5) were cultured in 30-mm plates for two days, then incubated with 50 ng/mL recombinant NSO-produced human HGF (R&D Systems, Inc., MN, USA) in serum-free media for 15, 60 and 360 min in the presence or absence of LY294002 (Calbiochem, CA, USA) or U0126 (Tocris Bioscience, MO, USA). Cells were then lysed with 1 × SDS loading buffer (50 mmol/L Tris-HCl pH 6.8, 2% SDS, 10% glycerol and 100 mmol/L β-mercaptoethanol) and lysate proteins were separated by 8% SDS polyacrylamide gel-electrophoresis. Proteins were transferred to nitrocellulose membrane (Hybond ECL, GE healthcare, Buckinghamshire, UK), which was incubated with antibodies specific for Akt, ERK1/2 and their phospho-forms (Cell Signaling Technology, Danvers, MA) or with anti-Met, anti-E-Cadherin, anti-β-actin (Santa Cruz Biotechnology, Santa Cruz, CA) and anti-phospho-Met (Cell Signaling Technology, Danvers, MA) antibodies, followed by HRP-conjugated secondary antibodies. Signals were developed using Enhance Chemiluminescence kit (GE Healthcare, Buckinghamshire, UK) and detected with FluorChem SP (Alpha Innotech Corporation, San Leandro, CA). Band densities were quantitated using AlphaEaseFC software (Alpha Innotech Corporation, San Leandro, CA). The data were presented in the relative band density when compared to those at zero time points.

Invasion and motility assay

HGF-induced CCA cell invasiveness was determined by Matrigel Transwell *in vitro* invasion assay as described by Albini *et al*[26] with some modification. In brief, the upper chamber of a Transwell unit (6.5-mm diameter polycarbonate membrane with 8-μm pore size) (Corning Incorporated Life Science, Corning, NY), was coated with 30 μg of Matrigel (BD Biosciences, Bedford, MA). Cells (80% confluent) were harvested using TrypLE Express (Invitrogen, Co., Grand Island, NY) and resuspended in serum-free media in the presence or absence of 50 and 100 μmol/L LY294002 or 1 and 5 μmol/L U0126. A 200 μL aliquot of cell (10^5) suspension was added to the upper chamber. The lower chamber was filled with 600 μL of serum-free media containing 10, 50 or

100 ng/mL human HGF as chemoattractant. BSA (0.1% in serum-free medium) was used as negative control. After 6 h of incubation at 37℃ under CO_2 atmosphere, non-invading cells in the upper chamber were removed and cells that invaded the Matrigel and had attached to the lower surface of the Transwell membrane were fixed with 25% methanol for 30 min and stained with 0.5% crystal violet. Invaded cells were counted in 5 random fields under light microscope at 100 × magnification. The reported values represent mean ± SE of the results obtained from three independent experiments.

Motility assay was performed using the Transwell chamber in the same manner as in the invasion assay but Matrigel coating was omitted.

Determination of gelatinase and urokinase plasminogen activator activities

Gelatinase (MMP-2 and MMP-9) and uPA levels secreted into conditioned media were determined by gelatin and plasminogen gelatin zymography under non-reducing conditions. Cells (80% confluent) were incubated with serum-free media in the presence of HGF (0, 10, 50 and 100 ng/mL) for 6 h. For gelatinase activity assay, 20 × concentrated conditioned media was mixed with SDS loading buffer in the absence of sulfhydryl reducing agent and electrophoresed in 7.5% SDS-polyacrylamide gel containing 1 mg/mL gelatin. uPA zymography was performed in a similar manner except that 10 μg/mL plasminogen and 1 mg/mL gelatin were copolymerized with 10% SDS-polyacrylamide gel and conditioned media was not concentrated. Gels were washed twice with 2.5% TritonX-100 for 1 h to remove SDS, then incubated for 18 h in reaction buffer (for gelatinase: 50 mmol/L Tris-HCl pH 7.5, 10 mmol/L $CaCl_2$, 1 μmol/L $ZnCl_2$ and 1% TritonX-100; for uPA: 100 mmol/L Tris-HCl pH 7.8, 150 mmol/L NaCl and 1% Triton X-100). Gels were stained for 2 h with 0.25% Coomassie blue and destained with 45% methanol and 10% acetic acid. Unstained bands in gelatin gel with estimated molecular weight of 65 and 85 kDa corresponded to MMP-2 and MMP-9 respectively, and that of 45 kDa in plasminogen-gelatin gel corresponded to uPA.

Immunofluorescence analysis

CCA cells (3×10^5) were grown on sterile coverslips for two days. Then the monolayer cells were treated with 0-100 ng/mL HGF for 6 h. Cells were washed twice with PBS, fixed in solution containing 3% paraformaldehyde and 2% sucrose, permeabilized with 0.5% Triton X-100 and incubated with 10% FBS, 0.1% Triton X-100 in PBS. Cells were then incubated overnight at 4℃ with mouse anti-E-cadherin monoclonal antibodies (Santa Cruz Biotechnology, Santa Cruz, CA), followed by fluorescent Alexa Fluor® 568-conjugated goat anti-mouse IgG secondary antibodies (Molecular Probes, Eugene, OR). After washing with PBS, the coverslips were mounted with 0.01% para-phenylenediamine dihydrochloride (Sigma Aldrich, Inc., St. Louis, MO) in 70% glycerol, and visualized under a confocal laser scanning microscope (Olympus FV1000; Olympus Co. Tokyo, Japan) equipped with Olympus FV10-ASW 1.7 software.

Statistical analysis

Invasion and motility results are expressed as mean ± SE. Multiple comparisons were performed using one-way analysis of variance (ANOVA) with P value < 0.05 considered statistically significant.

RESULTS

Met expression and phosphorylation in CCA cells

Western blotting analysis of both CCA cell lines (HuCCA-1 and KKU-M213) showed higher Met expression than in normal cholangiocytes (H69) (Figure 1A). Stimulation of cells by exogenous HGF resulted in induction of tyrosine phosphorylation at the critical autophosphorylation sites (pY1234/1235) in the catalytic domain of Met, but with a slight difference in the kinetics of Met activation between the two CCA cell lines; i.e. HGF stimulated a more rapid Met phosphorylation in HuCCA-1 cells (reaching a maximum at 15 min) than in KKU-M213 (maximum at about 15-60 min) (Figure 1B and C).

Effects of HGF on CCA cell invasiveness and motility

HGF has been reported as being able to induce invasion of several cancer cell types[27]. Here, CCA cell invasiveness and motility in response to HGF were investigated using a Transwell *in vitro* invasion/motility assay. In the absence of HGF, CCA cells showed abilities to migrate and invade, which were stimulated further by HGF in a dose-dependent manner over the concentration range of 10-100 ng/mL (Figure 2). Although basal migration and invasion abilities of HuCCA-1 were relatively low when compared to that of KKU-M213, they were dramatically stimulated by HGF to levels comparable to those of HGF-induced KKU-M213.

H69 cells, immortalized cholangiocytes, possessed very low invasive ability. Of 10^5 cells added to the upper compartment of the Transwell chamber, only 70 ± 21 cells invaded in the control and 335 ± 72 cells invaded upon HGF treatment. Although the HGF could induce H69 invasion, the level of invasion was marginal when compare to those of CCA cell lines.

Effects of HGF on E-cadherin expression and localization and matrix metalloproteinase and uPA secretion

HGF is able to induce changes in expression and localization of E-cadherin resulting in cell movement in several type of cancers[28-30]. To investigate the possibility of an involvement of E-cadherin in HGF-induced CCA cell migration, we determined the effects of HGF on E-cadherin expression by Western blotting and on localization by immunofluorescence staining. E-cadherin protein level did not change within 6 h of HGF treatment (Figure 3A). However, immunofluoresence demonstrated that HGF altered E-cadherin localization from the cell boundary to the cytoplasmic compartment

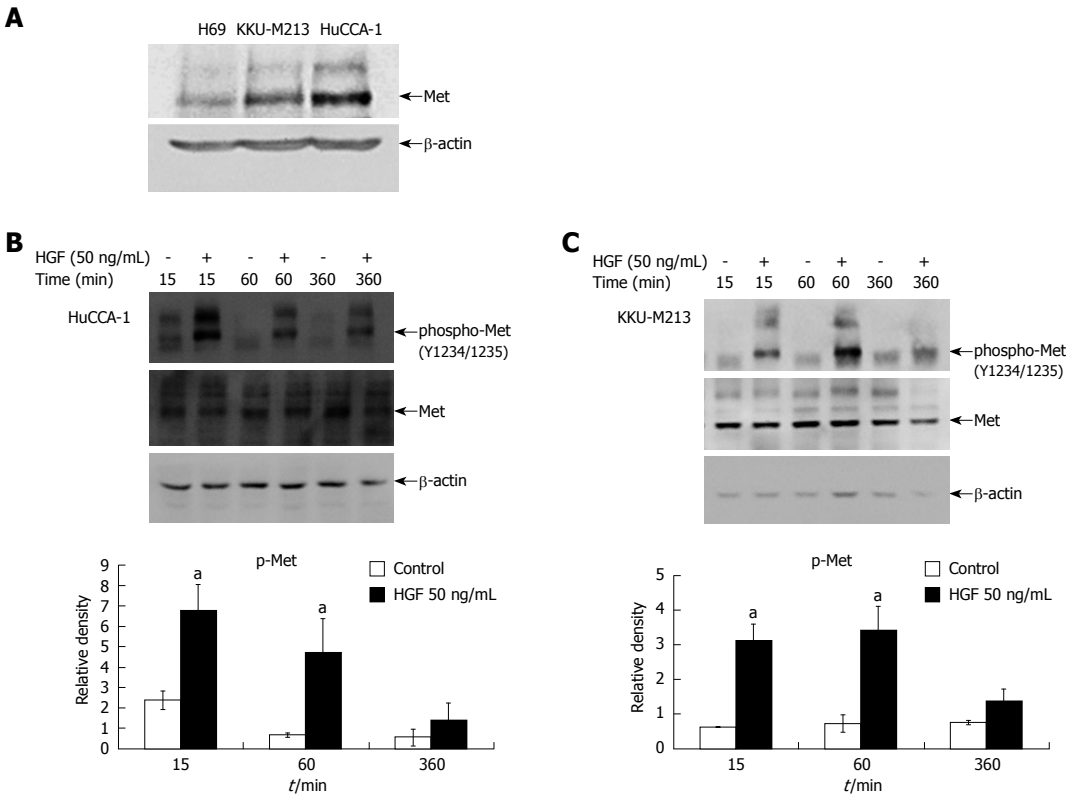

Figure 1 Steady state level of Met expression in cholangiocarcinoma cell lines and activation by hepatocyte growth factor (HGF). Cell lysates from 80% confluent cells cultured in 10% fetal bovine serum (FBS) medium were examined for Met expression by Western blotting analysis (A). Lysates from HuCCA-1 (B) and KKU-M213 (C) cells treated with or without 50 ng/mL HGF for various times were analyzed by Western blotting for levels of Met and phospho-Met (pY1234/1235). The graphs show band densities of phospho-Met relative to those at zero time points. Data are presented as mean ± SE of results obtained from three independent experiments. $^{a}P < 0.05$ *vs* untreated control.

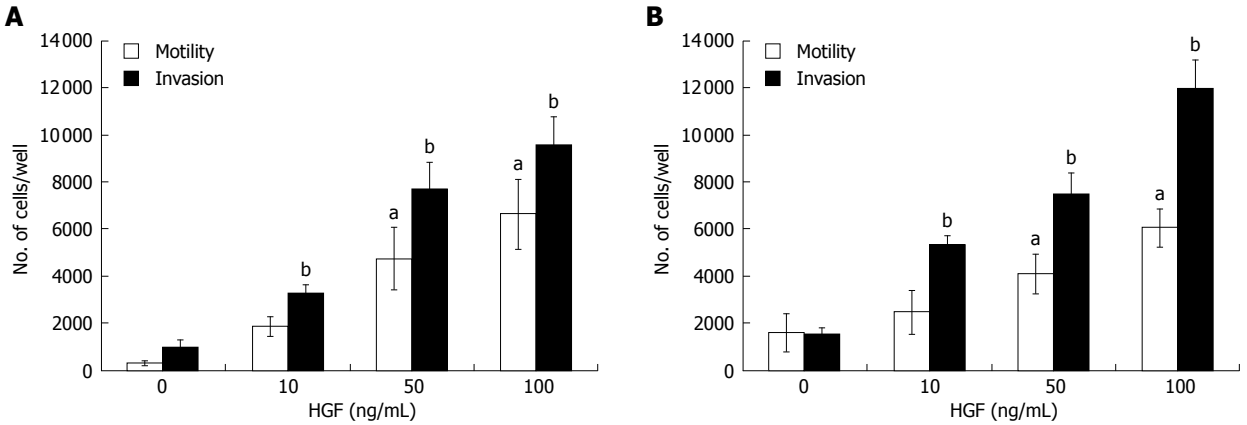

Figure 2 HGF induction of cholangiocarcinoma motility and invasiveness. *In vitro* invasion and motility assays of HuCCA-1 (A) and KKU-M213 (B) cells were conducted in a Transwell unit coated with and without Matrigel. Cells (10^5) in serum-free medium were plated in the upper chamber of a Transwell unit and 0-100 ng/mL HGF added to the lower chamber. After 6 h of incubation, cells invading to the lower compartment of the Transwell unit were stained and counted. The numbers of invaded/motile cells are presented as mean ± SE of results obtained from three independent experiments. $^{a}P < 0.05$, $^{b}P < 0.01$, *vs* untreated control.

(Figure 3B and C).

The effect of HGF on secretion of matrix degrading enzymes, a major factor contributing to cell invasiveness, was investigated by gelatin zymography. Zymograms from conditioned media of HuCCA-1 cells showed a clear band indicating MMP-2 activity, while those of KKU-M213 cells revealed both MMP-2 and MMP-9 activities (Figure 4A), demonstrating that the two CCA cell lines constitutively expressed high amounts of MMP-2 and/or MMP-9 at basal levels. However, these enzyme activities were not increased following HGF treatment (Figure 3A). Similarly, high basal activity of uPA was found in both CCA cell lines, which was not affected by the presence of HGF (Figure 4B).

Involvement of ERK1/2 and PI3K signaling pathways in HGF-induced CCA cell invasiveness

The mechanism responsible for HGF-induced inva-

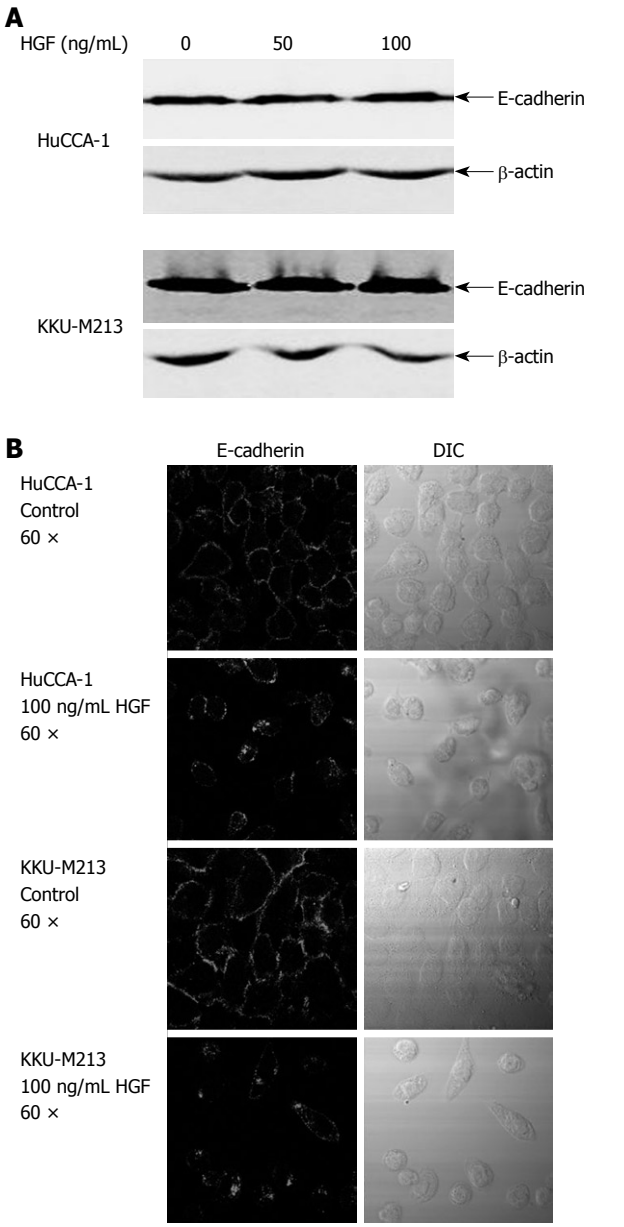

Figure 3 Effects of HGF on E-cadherin expression and localization. A: cholangiocarcinoma (CCA) cells were treated with HGF for 6 h, then cell lysate was analyzed by Western blotting with anti-E-cadherin and -β-actin monoclonal antibodies; B: After treatment with 0 and 100 ng/mL HGF for 6 h, cells were analyzed by immunofluorescence using anti-E-cadherin antibody and visualized under confocal laser scanning microscopy (60 × objective magnification plus 2 × digital magnification).

siveness of CCA cell lines was investigated by examining the signaling pathways of ERK1/2 and PI3K. HGF (50 ng/mL) stimulated both HuCCA-1 and KKU-M213 phosphorylation of ERK1/2 and Akt, with the latter being the major downstream effector of PI3K (Figure 5A and B). However, different time response profiles were observed between these two cell lines in HGF-induced ERK1/2 and Akt activation. In KKU-M213 cells, HGF significantly induced activation of ERK1/2 and Akt at up to 360 min, whereas in HuCCA-1 cells, after 360 min of induction, activation decreased to nearly those of unstimulated levels.

To confirm the roles of these two signaling pathways

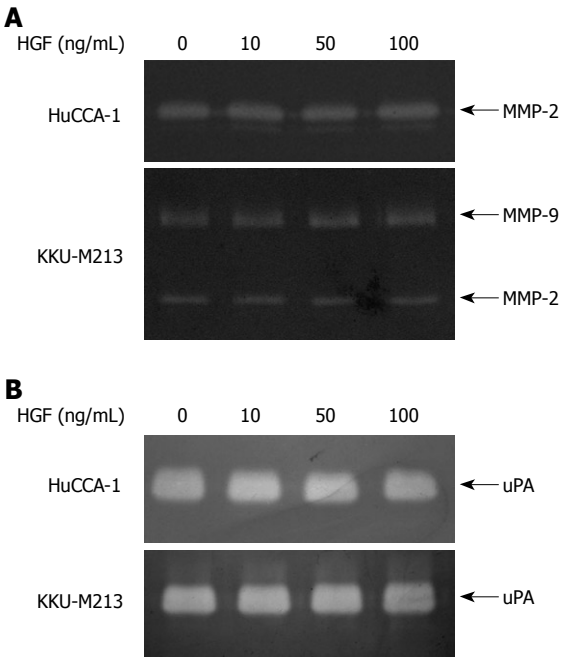

Figure 4 Effect of HGF on levels of secreted matrix degrading enzymes from cholangiocarcinoma HuCCA-1 and KKU-M213 cell lines. Cells were treated with various concentrations of HGF (0-100 ng/mL) in serum-free medium for 6 h. Conditioned media were then analyzed for MMP-2 (approximate 65 kDa) and MMP-9 (approximate 85 kDa) gelatinolytic activity by gelatin zymography (A) and for uPA by plasminogen-gelatin zymography (B).

in response to HGF stimulation, we tested the antagonistic effect of U0126 and LY294002; a MEK1 and a PI3K inhibitor, respectively. LY294002 (50 μmol/L) inhibited HGF-stimulated phosphorylation of Akt in both CCA cell lines to an undetectable level (Figure 6A) and markedly inhibited HGF-induced cell invasion, but did not have any significant effect on the invasion of non HGF-stimulated cells (Figure 6B and C). U0126 (1 and 5 μmol/L) reduced HGF-induced invasion of KKU-M213 cells (to 29% and 18% of untreated control, respectively) (Figure 7C). However, U0126 only had a marginal inhibitory effect on HGF-induced invasion of the HuCCA-1 cell line (Figure 7B). Nevertheless, U0126 completely inhibited ERK1/2 phosphorylation of HuCCA-1 cells, whereas phospho-ERK1/2 was still detectable in KKU-M213 cells even at the highest U0126 concentration used (Figure 7A).

DISCUSSION

Overexpression of Met has been reported in CCA and is correlated with progression and invasion of this type of cancer[9,11]. In this study, we demonstrated that HGF induced cell invasion, motility and change in E-cadherin localization in two human CCA cell lines, HuCCA-1 and KKU-M213, both of which overexpress Met; but without affecting secretion of the matrix degrading enzymes, MMP-2, MMP-9 and uPA. However, the signaling pathways underlying HGF-induced invasiveness of the two cell lines were different, with ERK1/2 activation being more important for HGF-induced KKU-M213 cell invasion than for HuCCA-1 cell invasion.

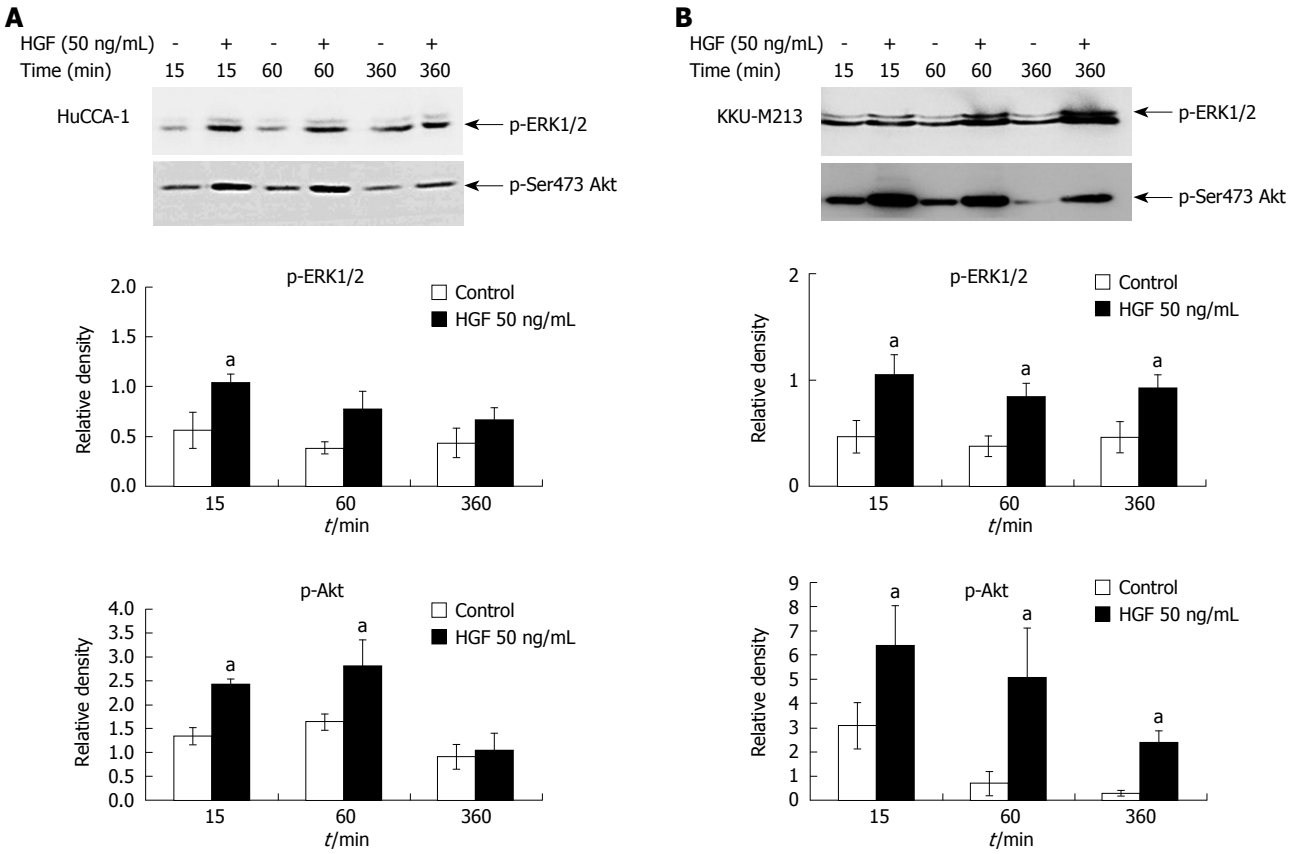

Figure 5 HGF induction of ERK1/2 and Akt phosphorylation in cholangiocarcinoma HuCCA-1 and KKU-M213 cell lines. About 80% confluent cells were treated with 50 ng/mL HGF in serum-free medium for 15, 60, 360 min. Lysates from HuCCA-1 (A) and KKU-M213 (B) cells were assessed for total and phosphorylated forms of ERK1/2 and Akt by Western blotting assay. The graphs showed band densities of phospho-ERK1/2 and phospho-Akt relative to those at zero time points. Data are presented as mean ± SE of results obtained from three independent experiments. $^{a}P < 0.05$ *vs* untreated control.

Two major factors contributing to an increase in cancer cell invasiveness are enhancement of extracellular matrix degradation and activation of cell motility. The effects of HGF on induction of these phenomena vary with different cell types. For instance, HGF enhances cell motility but not MMP-9 or uPA activities in breast cancer MDA-MB-231 cell line[16], while it induces both motility and matrix degrading enzyme expression in colon cancer Caco-2, prostate cancer PC-3 and DU-145 cells[31,32]. In our study, HGF induced invasion of both CCA cell lines by increasing motility but not MMP-2, MMP-9 or uPA levels. As the expression of the basal levels of these matrix degrading enzymes was already high in both CCA cell lines, this may be sufficient for providing cellular transmigration. Therefore, induction of cell motility alone by HGF, without augmenting extracellular matrix degrading enzyme levels, appears to be sufficient for cell invasiveness. Alterations of only some process(es) required for cell invasion have been reported as being able to alter cell invasiveness. For instance, inhibitors of ERK1/2[33] and myosin light chain kinase[34] suppress prostate cancer cell invasion by decreasing cell motility but not matrix degrading enzyme activity.

E-cadherin is the key mediator of cell-cell adhesion. Cell scattering induced by HGF results from disruption of E-cadherin function, either by reducing expression or changing its cellular localization[29]. In this study, we found that HGF caused E-cadherin to move from membrane to cytoplasm but had no effect on amount. These results are consistent with previous studies in a keratinocyte cell line, in which HGF reduced E-cadherin at cell-cell boundaries without changing its protein level[35,36]. Although we did not investigate the mechanism of HGF-disrupted E-cadherin function, previous reports have implicated the involvement of Ras-RIN2-Rab5 and β-catenin in this process. Kimura *et al*[37] demonstrated in a cell free system that HGF activates Ras which binds and activates RIN2, a Rab5-GEF (guanine nucleotide exchange factor of Rab5), leading to Rab5 activation. This active Rab5, a small G protein regulating endocytosis, in turn promotes E-cadherin endocytosis. In addition, Shibamoto *et al*[36] showed that HGF promotes tyrosine phosphorylation of β-catenin and decreases E-cadherin at the cell-cell boundaries resulting in the reduction of cell-cell adhesion mediated by E-cadherin.

Basement membrane normally acts as a barrier for tumor cell invasion; therefore, it is generally expected that the rate of invasion at which a cell degrades this barrier should be slower than or equal to the rate of cell migration. However, with the HuCCA-1 cell line, the basal cell invasion rate (with no HGF stimulation) was higher than that of migration. This suggests that some component(s) in Matrigel may have a role in inducing HuCCA-1 cell invasion. In support of this notion,

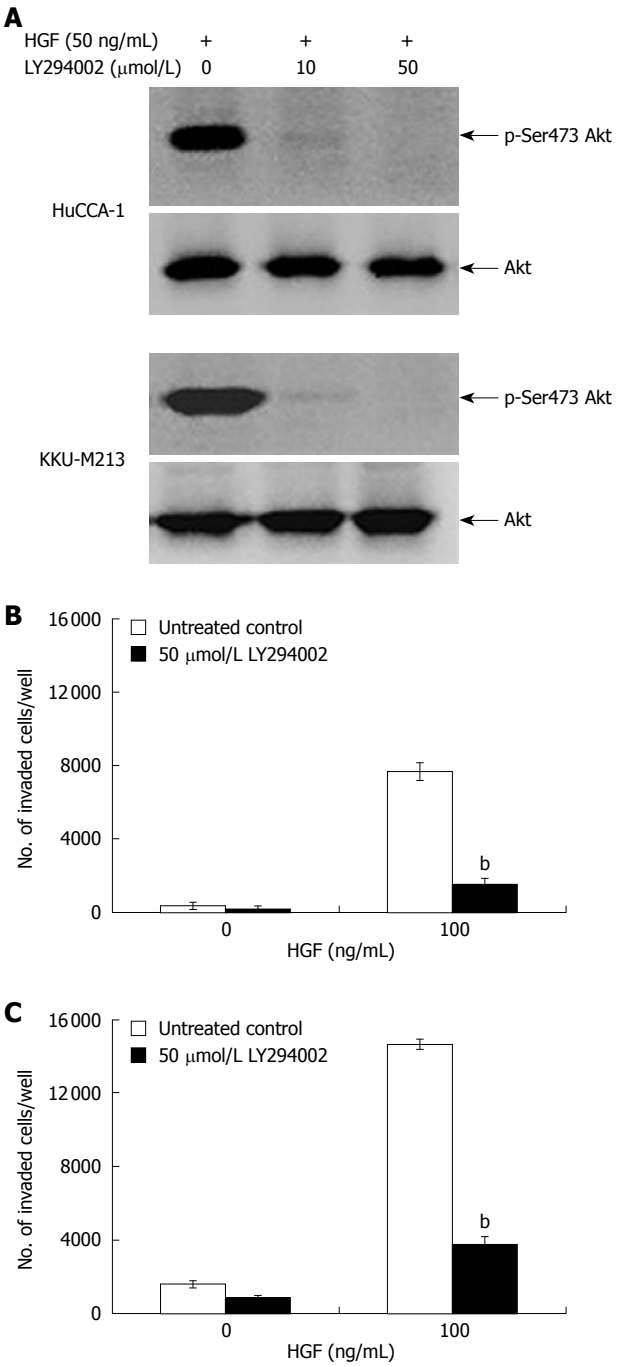

Figure 6 Suppression of HGF-induced cholangiocarcinoma cell invasiveness by PI3-kinase inhibitor, LY294002. HuCCA-1 and KKU-M213 cells were treated with 50 ng/mL HGF in the absence (control) or presence of 10 and 50 μmol/L LY294002 for 6 h, and subsequently Akt phosphorylation was determined by Western blotting (A). *In vitro* invasion of HuCCA-1 (B) and KKU-M213 (C) cells was evaluated in the absence or presence of HGF with or without 50 μmol/L LY294002. Numbers of invaded cells are presented as mean ± SE of results obtained from three independent experiments. $^{b}P < 0.01$ *vs* control.

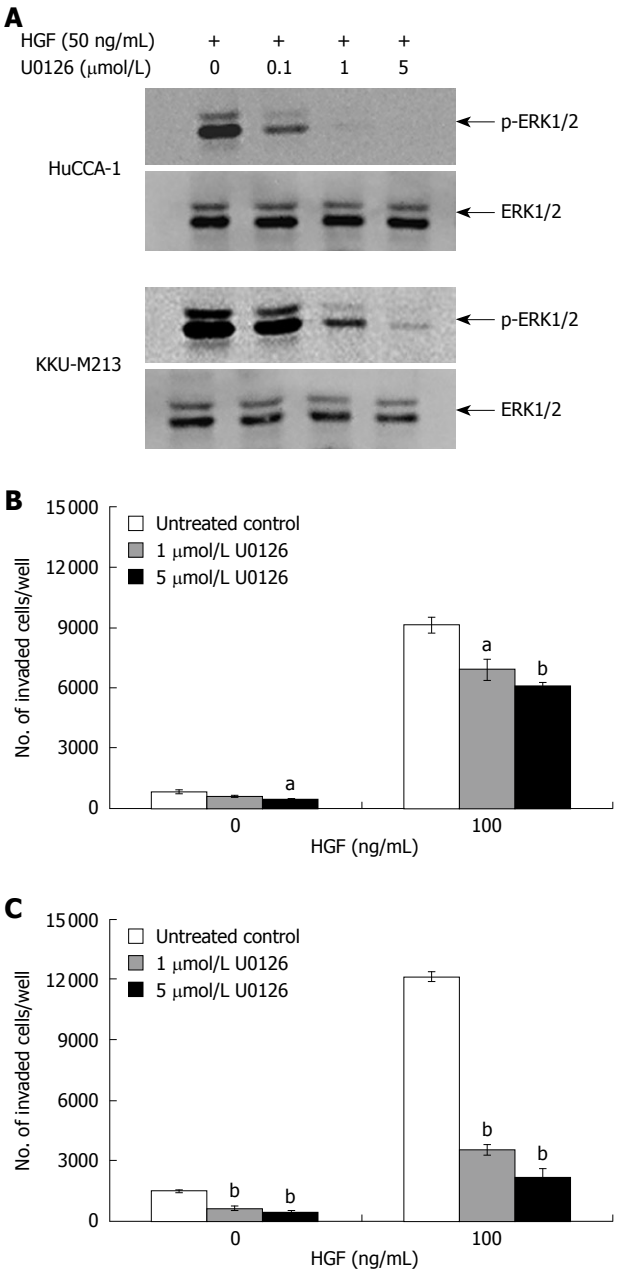

Figure 7 Suppression of HGF-induced cholangiocarcinoma cell invasiveness by MEK1 inhibitor, U0126. HuCCA-1 and KKU-M213 cells were treated with 50 ng/mL HGF in the absence (control) or presence of 0.1, 1 and 5 μmol/L U0126 for 6 h, and subsequently ERK1/2 phosphorylation was determined by Western blotting (A). *In vitro* invasion of HuCCA-1 (B) and KKU-M213 (C) cells was evaluated in the absence or presence of HGF with or without 1 and 5 μmol/L U0126. Numbers of invaded cells are presented as mean ± SE of results obtained from three independent experiments. $^{a}P < 0.05$ and $^{b}P < 0.01$ *vs* control.

Chintala *et al*[38] have shown that Matrigel and components of ECM (namely, type Ⅳ collagen and fibronectin) induce migration and invasion of many glioma cell lines.

In the KKU-M213 cell line, HGF was better at inducing invasion than migration, and this was not related to the stimulation of secretion of matrix degrading enzymes. A possible explanation is the existence of a synergism between HGF and extracellular matrix component(s) in the Matrigel. A combination of HGF and Matrigel induced higher motility than HGF alone (data not shown). Cooperation between HGF and ECM component(s) to promote cell migration could occur by enhancing the function of integrins[16,39], adhesion molecules regulating a variety of cellular properties including adhesion and migration by binding to ECM components. HGF induces cell scattering and migration by

increasing integrin α2 expression in MDCK cells[39] and also promotes breast cancer MDA-MB-231 cell invasion and adhesion by inducing integrin aggregation at lamellipodia, thereby enhancing avidity of integrins to their ligands in ECM and increasing association of integrin to actin, which may participate in cell migration[16].

A variety of signaling pathways are involved in HGF-induced cell invasiveness, including PI3K, ERK1/2 and Src[40]. In CCA, Src, FAK[41] and ERK1/2[42] are involved in HGF-induced HuCCA-1 cell invasion. Here, we showed that HGF induced Met activation concomitant with the promotion of both ERK1/2 and Akt phosphorylation in these two CCA cell lines. To reveal the involvement of ERK and PI3K pathways in HGF-induced invasion, inhibitors of specific signaling transduction pathways were used. PI3K inhibitor (LY294002) significantly inhibited both HuCCA-1 and KKU-M213 cell invasion stimulated by HGF, while basal invasion was marginally affected. As for the ERK pathway, U0126, a specific inhibitor of MEK1, drastically reduced HGF-promoted KKU-M213 cell invasion, while slightly reducing HGF-induced HuCCA-1 invasion, even though it inhibited ERK1/2 phosphorylation of the latter cell line to a greater extent than in the former. The insensitivity of HGF-stimulated HuCCA-1 invasion to U0126 treatment suggests a reduced dependence of this CCA cell line on the ERK signaling pathway, whereas HGF-induced KKU-M213 invasion is dependent on both PI3K and ERK1/2 activation.

ERK1/2 activation is known to regulate a variety of cellular functions, such as proliferation, differentiation, migration, and invasion in response to diverse extracellular stimuli[43]. Duration of ERK1/2 activation is one of the factors determining a particular cellular response[39,44]. McCawley *et al*[45] showed that EGF and HGF have the ability to induce SCC-12F keratinocyte migration. These two growth factors induce sustained ERK1/2 activation, which is associated with enhanced MMP-9 expression and SCC cell migration[45,46]. In MDCK cells, HGF induces sustained ERK1/2 activation, promoting cell scattering and migration *via* the enhancement of integrin-α2 expression, whereas EGF induces transient ERK1/2 activation, which has no effect on cell scattering[39]. Our data indicated that prolonged ERK1/2 activation was crucial for HGF-induced invasion of KKU-M213 cells, but was not necessary for HuCCA-1 cells in which HGF rapidly and transiently activated ERK. Thus, sustained ERK activation provides a possible explanation for the difference in downstream signaling pathways observed in HGF-induced invasion of the two CCA cell lines. Moreover, this sustained ERK1/2 activation may be responsible for a synergism between HGF and Matrigel in KKU-M213 cells by inducing integrin expression, as in MDCK cells[39].

In summary, this study provides evidence for the contribution of a HGF signaling pathway to the induction of CCA cell invasion. HGF promoted invasion *via* stimulation of cell motility, but not MMP or uPA secretion. HGF regulated invasiveness of two independent CCA cell lines by different signaling pathways, with PI3K being a common pathway underlying HGF-induced invasiveness in both cell lines, whereas the importance of ERK1/2 was determined by the duration of ERK1/2 activation. However, the mechanisms regulating temporal ERK1/2 activation and possible synergism between HGF and matrix in inducing invasion remains to be elucidated. Understanding the signaling mechanism responsible for CCA invasiveness will be valuable to help identify better targets for cancer therapy, such as that associated with a common rather than a cell specific pathway.

ACKNOWLEDGMENTS

The authors thank Professor Sirisinha S, Dr. Sripa B, Professor Gores G and Professor Alpini G for their generous gifts of cholangiocarcinoma and cholangiocyte cell lines and Professor Wilairat P for critical reading of the manuscript.

COMMENTS

Background

Cholangiocarcinoma (CCA) is a malignant tumor of the biliary epithelium associated with a high metastatic and mortality rate. Incidence of this cancer has increased worldwide, and the highest incidence occurs in northeast Thailand. Overexpression of Met has been reported in CCA and is correlated with progression and invasion of this type of cancer.

Research frontiers

Hepatocyte growth factor (HGF)/Met activation induces a variety of biological processes, including cell scattering, invasion, proliferation and survival. Although several reports have demonstrated a correlation between Met expression and CCA, hitherto there have been only a limited number of detailed investigations into the role of Met in cholangiocarcinoma.

Innovations and breakthroughs

HGF induced cell invasion and motility and altered E-cadherin localization in two human CCA cell lines overexpressing Met, without affecting the matrix degrading enzymes, matrix metalloproteinase (MMP)-2, MMP-9 and urokinase plasminogen activator (uPA). This is the first report of a difference in the signaling pathways responsible for the HGF-induced invasiveness of the two human CCA cell lines, in that extracellular signal-regulated kinase (ERK)1/2 activation is more important for HGF-induced invasion of one cell line than of the other.

Applications

Understanding the role of HGF/Met in CCA invasiveness and the molecular mechanisms underlying this process provides valuable information to help identify targets for future treatment of CCA patients.

Terminology

Phosphoinositide 3-kinase (PI3K) and ERK are signaling molecules downstream of many receptor tyrosine kinases including Met. These proteins have been shown to play an important role in cell invasion, a crucial factor of cancer metastasis. In this study HGF is shown to stimulate cell invasion and motility of CCA cell lines through PI3K and/or ERK pathways.

Peer review

CCA is a common malignant tumor with a high metastatic and mortality rate. Investigation into its molecular mechanism is important for understanding the pathogenesis of CCA. This study focused on the role of HGF/Met in CCA cell invasion and the mechanisms underlying cellular responses. Although a number of papers on this field have been published, this study still adds some new information into the knowledge already documented.

REFERENCES

1 **Sirica AE**. Cholangiocarcinoma: molecular targeting strategies for chemoprevention and therapy. *Hepatology* 2005; **41**: 5-15

2 **Patel T**. Cholangiocarcinoma. *Nat Clin Pract Gastroenterol*

Hepatol 2006; **3**: 33-42
3 **Sripa B**, Pairojkul C. Cholangiocarcinoma: lessons from Thailand. *Curr Opin Gastroenterol* 2008; **24**: 349-356
4 **Sirica AE**, Lai GH, Zhang Z. Biliary cancer growth factor pathways, cyclo-oxygenase-2 and potential therapeutic strategies. *J Gastroenterol Hepatol* 2001; **16**: 363-372
5 **Maulik G**, Shrikhande A, Kijima T, Ma PC, Morrison PT, Salgia R. Role of the hepatocyte growth factor receptor, c-Met, in oncogenesis and potential for therapeutic inhibition. *Cytokine Growth Factor Rev* 2002; **13**: 41-59
6 **Tamagnone L**, Comoglio PM. Control of invasive growth by hepatocyte growth factor (HGF) and related scatter factors. *Cytokine Growth Factor Rev* 1997; **8**: 129-142
7 **Endo K**, Yoon BI, Pairojkul C, Demetris AJ, Sirica AE. ERBB-2 overexpression and cyclooxygenase-2 up-regulation in human cholangiocarcinoma and risk conditions. *Hepatology* 2002; **36**: 439-450
8 **Terada T**, Nakanuma Y, Sirica AE. Immunohistochemical demonstration of MET overexpression in human intrahepatic cholangiocarcinoma and in hepatolithiasis. *Hum Pathol* 1998; **29**: 175-180
9 **Aishima SI**, Taguchi KI, Sugimachi K, Shimada M, Sugimachi K, Tsuneyoshi M. c-erbB-2 and c-Met expression relates to cholangiocarcinogenesis and progression of intrahepatic cholangiocarcinoma. *Histopathology* 2002; **40**: 269-278
10 **Varnholt H**, Asayama Y, Aishima S, Taguchi K, Sugimachi K, Tsuneyoshi M. C-met and hepatocyte growth factor expression in combined hepatocellular and cholangiocarcinoma. *Oncol Rep* 2002; **9**: 35-41
11 **Joo HH**, Song EY, Jin SH, Oh SH, Choi YK. [Expressions and clinical significances of c-met, c-erbB-2, COX-2, and IL-6 in the biliary tract cancers] *Korean J Gastroenterol* 2007; **50**: 370-378
12 **Lai GH**, Radaeva S, Nakamura T, Sirica AE. Unique epithelial cell production of hepatocyte growth factor/scatter factor by putative precancerous intestinal metaplasias and associated "intestinal-type" biliary cancer chemically induced in rat liver. *Hepatology* 2000; **31**: 1257-1265
13 **Hammond DE**, Carter S, Clague MJ. Met receptor dynamics and signalling. *Curr Top Microbiol Immunol* 2004; **286**: 21-44
14 **Birchmeier C**, Birchmeier W, Gherardi E, Vande Woude GF. Met, metastasis, motility and more. *Nat Rev Mol Cell Biol* 2003; **4**: 915-925
15 **Trusolino L**, Comoglio PM. Scatter-factor and semaphorin receptors: cell signalling for invasive growth. *Nat Rev Cancer* 2002; **2**: 289-300
16 **Trusolino L**, Cavassa S, Angelini P, Andó M, Bertotti A, Comoglio PM, Boccaccio C. HGF/scatter factor selectively promotes cell invasion by increasing integrin avidity. *FASEB J* 2000; **14**: 1629-1640
17 **Maulik G**, Madhiwala P, Brooks S, Ma PC, Kijima T, Tibaldi EV, Schaefer E, Parmar K, Salgia R. Activated c-Met signals through PI3K with dramatic effects on cytoskeletal functions in small cell lung cancer. *J Cell Mol Med* 2002; **6**: 539-553
18 **Jiang WG**, Martin TA, Parr C, Davies G, Matsumoto K, Nakamura T. Hepatocyte growth factor, its receptor, and their potential value in cancer therapies. *Crit Rev Oncol Hematol* 2005; **53**: 35-69
19 **Lee WJ**, Wu LF, Chen WK, Wang CJ, Tseng TH. Inhibitory effect of luteolin on hepatocyte growth factor/scatter factor-induced HepG2 cell invasion involving both MAPK/ERKs and PI3K-Akt pathways. *Chem Biol Interact* 2006; **160**: 123-133
20 **Ueoka Y**, Kato K, Wake N. Hepatocyte growth factor modulates motility and invasiveness of ovarian carcinomas via ras mediated pathway. *Mol Cell Endocrinol* 2003; **202**: 81-88
21 **Sirisinha S**, Tengchaisri T, Boonpucknavig S, Prempracha N, Ratanarapee S, Pausawasdi A. Establishment and characterization of a cholangiocarcinoma cell line from a Thai patient with intrahepatic bile duct cancer. *Asian Pac J Allergy Immunol* 1991; **9**: 153-157
22 **Sriurairatana S**, Tengchaisri T, Sirisinha S. Ultrastructural characteristics of liver fluke associated human cholangiocarcinoma cell lines. *Southeast Asian J Trop Med Public Health* 1996; **27**: 57-62
23 **Seubwai W**, Wongkham C, Puapairoj A, Khuntikeo N, Wongkham S. Overexpression of vitamin D receptor indicates a good prognosis for cholangiocarcinoma: implications for therapeutics. *Cancer* 2007; **109**: 2497-2505
24 **Sripa B**, Leungwattanawanit S, Nitta T, Wongkham C, Bhudhisawasdi V, Puapairoj A, Sripa C, Miwa M. Establishment and characterization of an opisthorchiasis-associated cholangiocarcinoma cell line (KKU-100). *World J Gastroenterol* 2005; **11**: 3392-3397
25 **Grubman SA**, Perrone RD, Lee DW, Murray SL, Rogers LC, Wolkoff LI, Mulberg AE, Cherington V, Jefferson DM. Regulation of intracellular pH by immortalized human intrahepatic biliary epithelial cell lines. *Am J Physiol* 1994; **266**: G1060-G1070
26 **Albini A**, Iwamoto Y, Kleinman HK, Martin GR, Aaronson SA, Kozlowski JM, McEwan RN. A rapid in vitro assay for quantitating the invasive potential of tumor cells. *Cancer Res* 1987; **47**: 3239-3245
27 **Matsumoto K**, Nakamura T. Hepatocyte growth factor and the Met system as a mediator of tumor-stromal interactions. *Int J Cancer* 2006; **119**: 477-483
28 **Royal I**, Park M. Hepatocyte growth factor-induced scatter of Madin-Darby canine kidney cells requires phosphatidylinositol 3-kinase. *J Biol Chem* 1995; **270**: 27780-27787
29 **Miura H**, Nishimura K, Tsujimura A, Matsumiya K, Matsumoto K, Nakamura T, Okuyama A. Effects of hepatocyte growth factor on E-cadherin-mediated cell-cell adhesion in DU145 prostate cancer cells. *Urology* 2001; **58**: 1064-1069
30 **Kim CH**, Kim J, Kahng H, Choi EC. Change of E-cadherin by hepatocyte growth factor and effects on the prognosis of hypopharyngeal carcinoma. *Ann Surg Oncol* 2007; **14**: 1565-1574
31 **Kermorgant S**, Aparicio T, Dessirier V, Lewin MJ, Lehy T. Hepatocyte growth factor induces colonic cancer cell invasiveness via enhanced motility and protease overproduction. Evidence for PI3 kinase and PKC involvement. *Carcinogenesis* 2001; **22**: 1035-1042
32 **Fujiuchi Y**, Nagakawa O, Murakami K, Fuse H, Saiki I. Effect of hepatocyte growth factor on invasion of prostate cancer cell lines. *Oncol Rep* 2003; **10**: 1001-1006
33 **Suthiphongchai T**, Phimsen S, Sakulkhu U, Tohtong R. PD98059-inhibited invasion of Dunning rat prostate cancer cells involves suppression of motility but not MMP-2 or uPA secretion. *Oncol Rep* 2006; **15**: 1605-1610
34 **Tohtong R**, Phattarasakul K, Jiraviriyakul A, Sutthiphongchai T. Dependence of metastatic cancer cell invasion on MLCK-catalyzed phosphorylation of myosin regulatory light chain. *Prostate Cancer Prostatic Dis* 2003; **6**: 212-216
35 **Watabe M**, Matsumoto K, Nakamura T, Takeichi M. Effect of hepatocyte growth factor on cadherin-mediated cell-cell adhesion. *Cell Struct Funct* 1993; **18**: 117-124
36 **Shibamoto S**, Hayakawa M, Takeuchi K, Hori T, Oku N, Miyazawa K, Kitamura N, Takeichi M, Ito F. Tyrosine phosphorylation of beta-catenin and plakoglobin enhanced by hepatocyte growth factor and epidermal growth factor in human carcinoma cells. *Cell Adhes Commun* 1994; **1**: 295-305
37 **Kimura T**, Sakisaka T, Baba T, Yamada T, Takai Y. Involvement of the Ras-Ras-activated Rab5 guanine nucleotide exchange factor RIN2-Rab5 pathway in the hepatocyte growth factor-induced endocytosis of E-cadherin. *J Biol Chem* 2006; **281**: 10598-10609
38 **Chintala SK**, Gokaslan ZL, Go Y, Sawaya R, Nicolson GL,

Rao JS. Role of extracellular matrix proteins in regulation of human glioma cell invasion in vitro. *Clin Exp Metastasis* 1996; **14**: 358-366

39 **Liang CC**, Chen HC. Sustained activation of extracellular signal-regulated kinase stimulated by hepatocyte growth factor leads to integrin alpha 2 expression that is involved in cell scattering. *J Biol Chem* 2001; **276**: 21146-21152

40 **Christensen JG**, Burrows J, Salgia R. c-Met as a target for human cancer and characterization of inhibitors for therapeutic intervention. *Cancer Lett* 2005; **225**: 1-26

41 **Pongchairerk U**, Guan JL, Leardkamolkarn V. Focal adhesion kinase and Src phosphorylations in HGF-induced proliferation and invasion of human cholangiocarcinoma cell line, HuCCA-1. *World J Gastroenterol* 2005; **11**: 5845-5852

42 **Leelawat K**, Leelawat S, Tepaksorn P, Rattanasinganchan P, Leungchaweng A, Tohtong R, Sobhon P. Involvement of c-Met/hepatocyte growth factor pathway in cholangiocarcinoma cell invasion and its therapeutic inhibition with small interfering RNA specific for c-Met. *J Surg Res* 2006; **136**: 78-84

43 **Reddy KB**, Nabha SM, Atanaskova N. Role of MAP kinase in tumor progression and invasion. *Cancer Metastasis Rev* 2003; **22**: 395-403

44 **Marshall CJ**. Specificity of receptor tyrosine kinase signaling: transient versus sustained extracellular signal-regulated kinase activation. *Cell* 1995; **80**: 179-185

45 **McCawley LJ**, O'Brien P, Hudson LG. Epidermal growth factor (EGF)- and scatter factor/hepatocyte growth factor (SF/HGF)- mediated keratinocyte migration is coincident with induction of matrix metalloproteinase (MMP)-9. *J Cell Physiol* 1998; **176**: 255-265

46 **McCawley LJ**, Li S, Wattenberg EV, Hudson LG. Sustained activation of the mitogen-activated protein kinase pathway. A mechanism underlying receptor tyrosine kinase specificity for matrix metalloproteinase-9 induction and cell migration. *J Biol Chem* 1999; **274**: 4347-4353

S- Editor Wang JL **L- Editor** Logan S **E- Editor** Lin YP

World Journal of Gastroenterology

Online Submissions: http://www.wjgnet.com/1007-9327office
wjg@wjgnet.com
doi:10.3748/wjg.v16.i6.723

World J Gastroenterol 2010 February 14; 16(6): 723-727
ISSN 1007-9327 (print)

ORIGINAL ARTICLE

Endoscopic findings and clinicopathologic characteristics of colonic schistosomiasis: A report of 46 cases

Jun Cao, Wen-Jia Liu, Xin-Yun Xu, Xiao-Ping Zou

Jun Cao, Wen-Jia Liu, Xiao-Ping Zou, Department of Gastroenterology, Nanjing Gulou Hospital Affiliated to Medical School of Nanjing University, Nanjing 210008, Jiangsu Province, China
Xin-Yun Xu, Department of Pathology, Nanjing Gulou Hospital Affiliated to Medical School of Nanjing University, Nanjing 210008, Jiangsu Province, China
Author contributions: Cao J designed the study and wrote the paper; Liu WJ collected the data; Xu XY was responsible for pathology of schistosomal colonic disease; Zou XP designed mainly the study and revised the manuscript.
Correspondence to: Xiao-Ping Zou, MD, PhD, Department of Gastroenterology, Nanjing Gulou Hospital Affiliated to Medical School of Nanjing University, 321 Zhongshan Road, Nanjing 210008, Jiangsu Province, China. zouxiaoping795@hotmail.com
Telephone: +86-25-88304616-20601 Fax: +86-25-88042292
Received: October 29, 2009 Revised: December 3, 2009
Accepted: December 10, 2009
Published online: February 14, 2010

Abstract

AIM: To make a retrospective analysis of endoscopy findings and clinicopathologic characteristics of colonic schistosomiasis in order to further improve our understanding of the disease and decrease its misdiagnosis.

METHODS: Endoscopy findings and clinicopathologic characteristics of 46 intestinal schistosomiasis patients were retrospectively analyzed. All the patients underwent colonoscopy and all biopsy specimens stained with hematoxylin and eosin were observed under a light microscope.

RESULTS: Of the 46 colonic schistosomiasis patients, 1 was diagnosed as acute schistosomal colitis, 16 as chronic schistosomal colitis and 29 as chronic active schistosomal colitis according to their endoscopic findings and pathology. Not all patients were suspected of or diagnosed as colonic schistosomiasis. Of the 12 misdiagnosed patients, 4 were misdiagnosed as ulcerative colitis, 1 as Crohn's disease, and 7 as ischemic colitis. The segments of rectum and sigmoid colon were involved in 29 patients (63.0%). Intact Schistosoma ova were deposited in colonic mucosa accompanying infiltration of eosinocytes, lymphocytes, and plasma cells in acute schistosomal colitis patients. Submucosal fibrosis was found in chronic schistosomal colitis patients. Among the 17 patients with a signal polyp, hyperplastic polyp, canalicular adenoma with a low-grade intraepithelial neoplastic change, tubulovillous adenoma with a high-grade intraepithelial neoplastic change were observed in 10, 5, and 2 patients, respectively. Eight out of the 46 patients were diagnosed as colonic carcinoma.

CONCLUSION: Endoscopy contributes to the diagnosis of colonic schistosomiasis although it is nonspecific. A correct diagnosis of colonic schistosomiasis can be established by endoscopy in combination with its clinicopathologic characteristics.

Key words: Colonic schistosomiasis; Colonoscopy; Diagnosis; Pathology

Peer reviewer: Patrick O'Dwyer, MB, BCh, BAO, FRCS, MCh, FRCS (Glasg), Professor, University Department of Surgery, Western Infirmary, Glasgow, G11 6NT, United Kingdom

Cao J, Liu WJ, Xu XY, Zou XP. Endoscopic findings and clinicopathologic characteristics of colonic schistosomiasis: A report of 46 cases. *World J Gastroenterol* 2010; 16(6): 723-727 Available from: URL: http://www.wjgnet.com/1007-9327/full/v16/i6/723.htm DOI: http://dx.doi.org/10.3748/wjg.v16.i6.723

INTRODUCTION

Colonic schistosomiasis is defined as a specific acute or chronic inflammatory reaction of Schistosoma ova that

are deposited mainly in colorectal mucosa. The majority of humans are infected with Schistosoma japonicum, hematobium and mansoni. Schistosoma japonicum and mansoni often lead to intestinal disease[1]. Chinese people are commonly infected with Schistosoma japonicum. In the 1950s, schistosomiasis was epidemic at a large scale in regions along the Yangtze River and in more than 400 counties in South China[2-4]. Because of the effective prevention and cure measures taken in China in recent years, schistosomiasis has been eliminated in most epidemic regions. However, its spread is not yet completely controlled and schistosomiasis occurs every year in a small number of people in the epidemic regions of China[3,4]. Since the number of colonic schistosomiasis patients is small, physicians know little about it, thus often misdiagnosing intestinal schistosomiasis. In the present study, we made a retrospective analysis of endoscopy findings and clinicopathologic characteristics of 46 colonic schistosomiasis patients in order to further improve our understanding of the disease and decrease its misdiagnosis.

MATERIALS AND METHODS

From May 2005 to May 2009, 46 patients with colonic schistosomiasis were admitted to Endoscopy Center, Affiliated Gulou Hospital of Medical School of Nanjing University (Nanjing, China). Their endoscopy findings and clinicopathologic characteristics were retrospectively analyzed. The patients gave their written informed consent before colonoscopy (Olympus CF-240I or CF-H260AZI, Tokyo, Japan). When a lesion was detected at colonoscopy, tumor tissue samples were taken and fixed in 4% buffered paraformaldehyde, embedded in paraffin, and stained with hematoxylin-eosin. Two pathologists independently examined the tumor tissue sections under a light microscope (Olympus, Tokyo, Japan).

RESULTS

Clinical characteristics

Of the 46 colonic schistosomiasis patients (32 men and 14 women) at the age of 65.4 ± 10.8 years (range 40-80 years), 31 were from the epidemic areas of schistosomiasis and 15 from the non-epidemic areas with a history of contacting water containing Schistosoma ova.

The time from onset of symptoms to visit of a doctor ranged 4 d to 7 years (mean 4.5 years). The common symptoms were repeated fever and hematochezia. Among the symptoms occurred in 46 patients, diarrhea was found in 31 (67.3%), bloody stool in 8 (17.3%), abdominal pain in 35 (76.1%), incomplete intestinal obstruction in 3 (4.7%), turgescent spleen in 6 (8.4%) and hepatosplenic schistosomiasis in 1 patients (1.5%), respectively.

Endoscopy features

All the patients underwent colonoscopy with a success in 41 patients and a failure in 5 patients. The whole colon, right colon, and left colon were involved in 4 (8.7%), 4 (8.7%), and 38 (82.6%) patients, respectively (Table 1). Among the 38 patients with their left colon involved, only descending colon, descending and transverse colon, only sigmoid colon, sigmoid colon and rectum, and only rectum were involved in 8, 1, 3, 9, and 17 patients, respectively. The lesion was mainly located in rectum and sigmoid colon of 29 patients (63.0%).

Table 1 Location of affected colon

Location of colonic injury	*n*	Percent
Cecum	2	4.3
Whole colon	4	8.7
Ascending + transverse colon	1	2.2
Descending colon	8	17.4
Descending + transverse colon	1	2.2
Hepatic flexure of colon	1	2.2
Sigmoid colon	3	6.5
Sigmoid colon + rectum	9	19.6
Rectum	17	37.0

Among the 46 patients, acute submucosal colitis, chronic submucosal colitis, chronic active submucosal colitis were diagnosed in 1, 16, and 29 patients, respectively. Friable or edematous mucosa with more mucus exudates, scattered petechial hemorrhage, invisible submucosal blood vessels, erythema and granularity of mucosa with irregular ulcerations could be observed in acute submucosal colitis patients by colonoscopy. Chronic submucosal colitis was characterized by pale intestinal mucosa, confused vascular net with more flat or elevated yellow nodules, even intestine stricture, single polyp or more polyps. Acute and chronic inflammation reactions occurred simultaneously in the same or different segments of colon, and a clear dividing line emerged between the two types of inflammation in chronic active submucosal colitis patients. Acute inflammation was often observed in the right colon and chronic inflammation usually occurred in the left colon. Acute and chronic inflammation was also observed in the same segment of colon (Figure 1).

Pathology characteristics

Intact Schistosoma ova were deposited in lamina propria with infiltration of eosinocytes and neutrophilic granulocytes in acute schistosomal colitis patients. Schistosoma ova were calcified and deposited with infiltration of lymphocytes and plasma cells in submucosa, lamina propria in chronic schistosomal colitis patients. Atrophy of intestinal mucosa epithelium, reduction of intestinal glands, submucosal hyperblastosis and different degrees of fibrosis were also observed in chronic schistosomal colitis patients. Two different types of Schistosoma ova were found in chronic and acute schistosomal colitis patients. In addition, Schistosoma oviposition was associated with the clinical and histopathological changes in colonic schistosomiasis (Figure 2).

Colonoscopy showed that a single polyp in 17 out of the 46 patients. Among the 17 patients, hyperplastic polyps, canalicular adenoma with a low-grade intraepithelial neoplastic change and tubulovillous adenoma with a high-

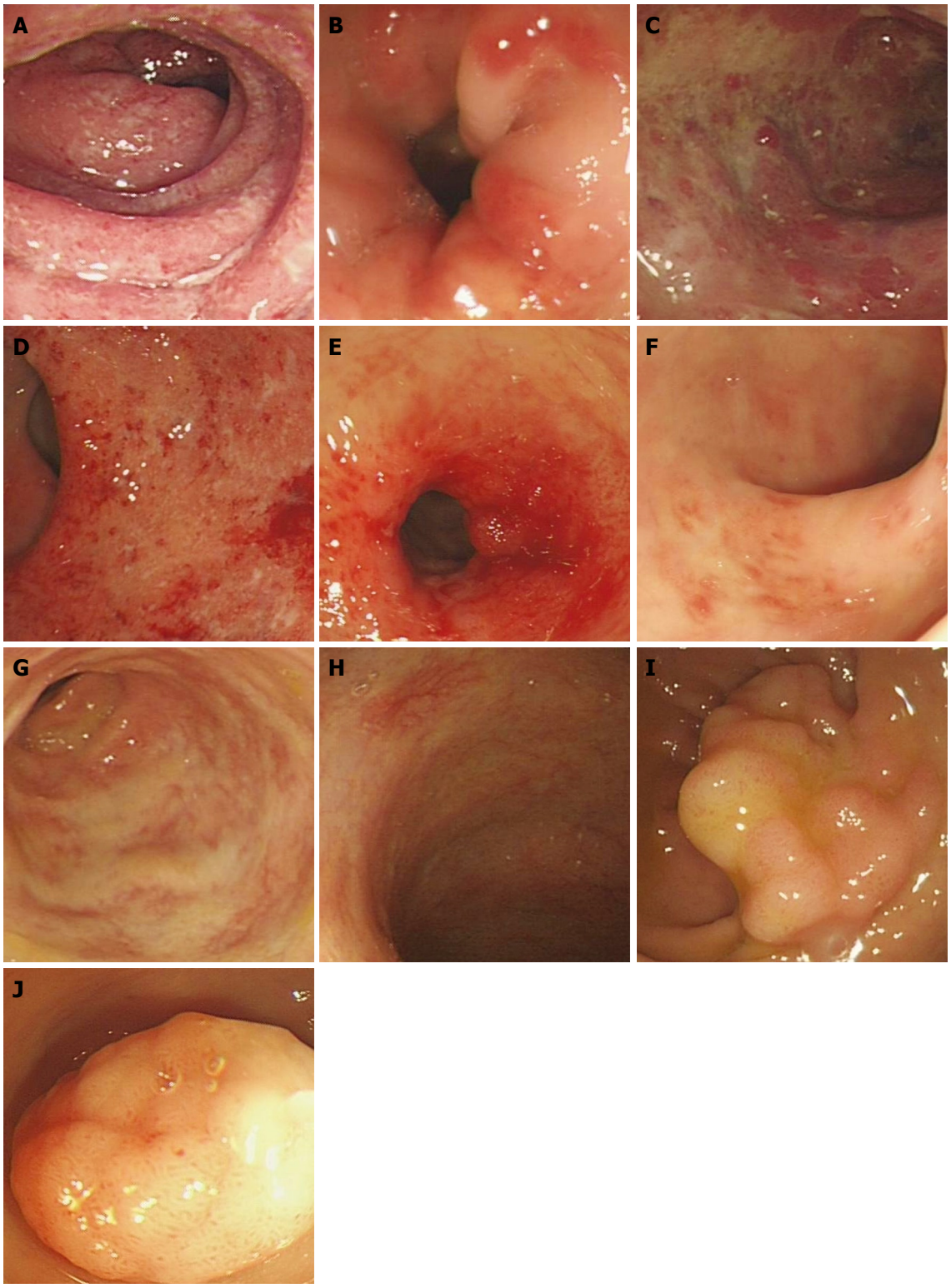

Figure 1 Endoscopic findings of schistosomal colonic disease. A: Congestive, edematous mucosa in rectum with purulent secretion in mixed colitis; B: Congestive and edematous mucosa of sigmoid colon and intestinal stricture in mixed colitis; C: Mucosal erosion, superficial ulcer and granular change in descending colon with invisible submucosal blood vessels in mixed colitis; D: Congestive, edematous and erosive mucosa in rectum with invisible submucosal blood vessels in mixed colitis; E: Coarse, congestive, ulcerative mucosa and intestinal stricture in descending colon in mixed colitis; F: Patchy congestion and vague vascular net in mucosa of sigmoid colon in mixed colitis; G: Vascular net like map of sigmoid colon in chronic colitis; H: Cobwebbed vessels in rectum in chronic colitis; I: Giant flat, lobulated polypus in rectum in chronic colitis; J: Giant polypus in sigmoid colon in chronic colitis.

grade intraepithelial neoplastic change were detected in 10, 5 and 2 patients, respectively. Of the 46 patients, 8 were diagnosed as colonic carcinoma, including papillary adenocarcinoma in 2, mucinous adenocarcinoma in 1, signet-ring cell carcinoma in 1, and tubular adenocarcinoma in 4 patients, respectively.

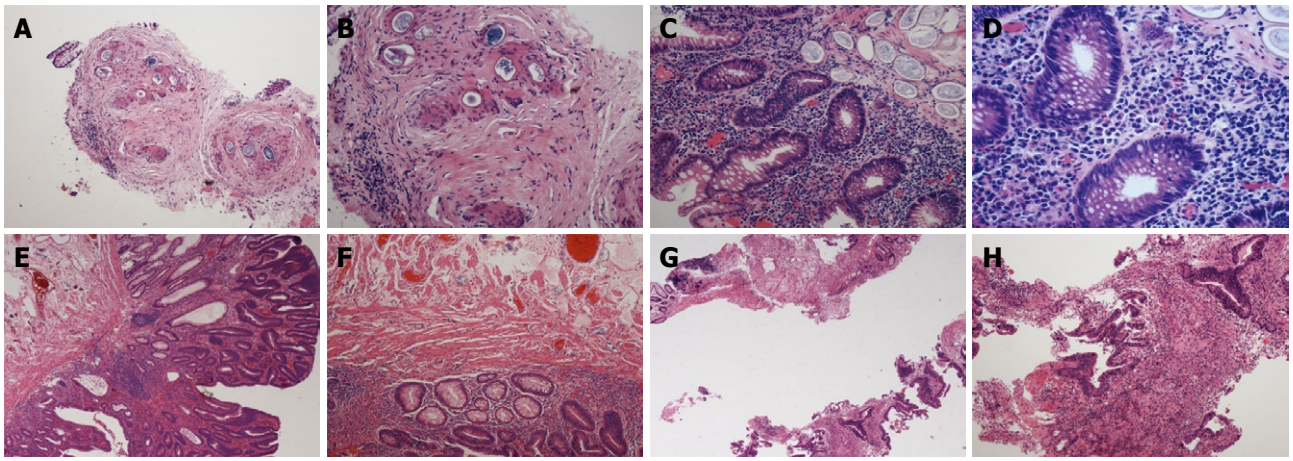

Figure 2 Pathology of schistosomal colonic disease (HE staining). A: Chronic inflammation in rectal mucosa and calcified schistosomal ova around fibroplasia and foreign-body giant cell reaction in submucosa (original magnification × 100); B: Same view as A, at a different magnification (original magnification × 200); C: Chronic inflammation accompanying acute activity and deposited schistosomal ova in submucosa (original magnification × 200); D: Same view as A, at a different magnification (original magnification × 400); E: Canalicular adenoma accompanying low-grade intraepithelial neoplastic change and more deposited schistosomal ova in rectum (original magnification × 40); F: Same view as A, at a different magnification (original magnification × 100); G: Rectal adenocarcinoma and deposited schistosomal ova in rectum (original magnification × 40); H: Same view as A, at a different magnification (original magnification × 100).

Therapy

High frequency electric snare of colonic polyps was performed under a colonoscope for 17 colonic schistosomiasis patients. Among these patients, colonic carcinoma was radically removed in 8 patients, schistosomiasis was treated with antischistosomiasis drug (praziquantel) in 1 patient and the other patients received symptomatic treatment.

DISCUSSION

Schistosoma ova are mainly parasitized in the inferior mesenteric and portal vein when one is infected with them. Intestinal schistosomiasis occurs due to deposition of Schistosoma ova in submucosa producing a granulomatous reaction[5]. Mucosal edema, hemorrhage and ulceration may occur in bowel wall at its early stage, while thickened bowel wall, polyps, or enteric cavity stricture, *etc*, can be detected at its advanced stage[6]. In our study, colonic schistosomiasis was divided into acute schistosomal colitis, chronic schistosomal colitis, and chronic active schistosomal colitis according to the inflammation reaction in colon. In the present study, 46 colonic schistosomiasis patients included 1 acute schistosomal colitis, 16 chronic schistosomal colitis and 29 chronic active schistosomal colitis patients. The difference between acute and chronic schistosomal colitis depends on whether Schistosoma ova are intact. A Schistosoma ovum or several Schistosoma ova are deposited in submucosa and lamina propria in acute schistosomal colitis patients with infiltration of eosinocytes. Schistosoma ova are calcified and deposited in submucosa and lamina propria with infiltration of lymphocytes and epithelioid cells in chronic schistosomal colitis patients. Fibroplasia could be observed in colonic submucosa of chronic schistosomal colitis patients. The deposition sites of Schistosoma ova are sigmoid colon, upper segment of rectum, descending colon, transverse colon, cecum and ascending colon. In our study, the lesion was located in the rectum and sigmoid colon of 29 patients (63.0%) and in the colon segments of 17 patients (37.0%).

Although nonspecific, colonoscopy may provide valuable information for the diagnosis of colonic schistosomiasis. Colonoscopy can show edematous, congestive mucosa and petechial hemorrhage in acute schistosomal colitis patients, and confused vascular net with more close-set flat or elevated yellow nodules, polyps and intestine stricture in chronic schistosomal colitis patients. Acute and chronic inflammation could be observed in colon segments of chronic active schistosomal colitis patients. The most characteristic finding is the gray-yellow or yellowish white schistosomal nodules similar to those of pseudomembranous enterocolitis. In our study, colonoscopy showed schistosomal nodules in only 6 patients (16.2%), which may be the reason why physicians cannot make a correct diagnosis of the disease based only on colonoscopic findings. Schistosomal oviposition is the golden diagnostic standard for colonic schistosomiasis. Schistosoma ova are deposited in lamina propria and/or in submucosa[7] with infiltration of eosinocytes and neutrophilic granulocytes in acute schistosomal colitis patients. Schistosoma ova are calcified or ruptured with infiltration of lymphocytes and plasma cells in submucosa and lamina propria of chronic schistosomal colitis patients. Submucosal hyperblastosis and fibrosis could also be found in chronic schistosomal colitis patients. Two types of Schistosoma ova can be detected in chronic acute schistosomal colitis patients.

In our study, a definite diagnosis was not made only based on endoscopic findings. Four patients were misdiagnosed as ulcerative colitis, 1 as Crohn's disease, and 7 as ischemic colitis, indicating that physicians know little about the disease.

Colorectal cancer is one of the most common malignant gastrointestinal tumors and its occurrence has in-

creased in recent years. Its pathogenesis remains unclear, thus requiring further study. Schistosoma japonicum infection is considered a significant risk factor for colonic cancer in Asia although it is still controversial[5]. A total of 454 colorectal carcinoma specimens have been studied in China, showing that 289 of them are associated with Schistosoma japonicum infection[8]. Kaw *et al*[9] studied 1277 colonic carcinoma patients and found that schistosomiasis is often accompanied with rectal carcinoma. Mei *et al*[10] studied 352 colonic carcinoma patients and found that 14.3% of them have the complication of schistosomiasis. These colonic carcinomas are moderately-differentiated tubular and mucinous adenocarcinomas. In the present study, 8 colonic schistosomiasis patients (17.3%) had complication of colonic carcinoma, and 2 had complications of a high-grade intraepithelial neoplastic change and precancerous lesion. However, the mechanism of Schistosoma japonicum infection leading to carcinoma is unclear, which may be associated with chronic inflammation, ulceration and mucosa repair due to Schistosoma ova. Tumorigenesis may result from gene mutations in epithelial cells of glands due to the long time stimulation of mucosa by Schistosoma ova.

The incidence of colonic schistosomiasis has been greatly declined. However, many complications may occur if it is not early diagnosed and treated. Colonic schistosomiasis should be diagnosed based on its clinical symptoms and signs, coloscopic findings and pathologic characteristics. If Schistosoma ova are found in biopsy, it can be diagnosed. If Schistosoma ova are not observed in biopsy, the near-normal crypts with excess mucus and diffuse or focal infiltration of eosinophilic granulocytes may be highly suggestive of colonic schistosomiasis[11].

COMMENTS

Background

Schistosomiasis was epidemic at a large scale in the regions along the Yangtze River and more than 400 counties in South China 50 years ago. Thanks to the effective prevention and cure measures taken in recent years, schistosomiasis has been eliminated in most epidemic regions. However, its spread is not completely controlled in several regions and schistosomiasis still occurs in a small number of people in its endemic region, which threatens their health. Since the number of patients with still suffer from schistosomiasis has greatly declined, physicians know little about it and often misdiagnose it.

Research frontiers

Colonic schistosomiasis is seldom reported at present. In this study, the endoscopy findings and clinicopathologic characteristics of 46 colonic schistosomiasis patients were retrospectively analyzed, showing that Schistosoma japonicum infection may be a risk factor for colonic cancer.

Innovations and breakthroughs

The endoscopy findings and clinicopathologic characteristics of 46 colonic schistosomiasis patients were analyzed. The disease was classified into acute schistosomal colitis, chronic schistosomal colitis, and chronic active schistosomal colitis. The results indicate that Schistosoma japonicum infection may be a risk factor for colonic cancer and schistosomal polyps should be removed under an endoscope.

Applications

The endoscopy findings and clinicopathologic characteristics of colonic schistosomiasis were described, which may improve our further understanding of the disease and decrease its misdiagnosis.

Terminology

Colonic schistosomiasis: An acute and chronic specific inflammatory reaction due to Schistosoma ova in colonic and rectal mucosa. Pseudomembranous enterocolitis: An infection of the colon with Clostridium difficile, characterized by diarrhea, fever, vomiting and abdominal pain.

Peer review

This paper is interesting and should be published. The authors, however, need to highlight the high incidence of cancer in their populations.

REFERENCES

1 **Mohamed AR**, al Karawi M, Yasawy MI. Schistosomal colonic disease. *Gut* 1990; **31**: 439-442

2 **Zheng J**. Schistosomiasis control and its prospects in China. *Zhongguo Xuexichongbing Fangzhi Zazhi* 2003; **15**: 1-2

3 **Cao ZG**, Wang TP. Epidemic situation of urban schistosomiasis and measures for prevention and control in China. *Zhongguo Xuexichongbing Fangzhi Zazhi* 2007; **19**: 315-316, 320

4 **Zheng J**. Prevention and control of Chinese schistosomiasis in the 21st century. *Zhonghua Liuxingbingxue Zazhi* 2002; **23**: 81-82

5 **Yosry A**. Schistosomiasis and neoplasia. *Contrib Microbiol* 2006; **13**: 81-100

6 **Ohmae H**, Sy OS, Chigusa Y, Portillo GP. Imaging diagnosis of schistosomiasis japonica--the use in Japan and application for field study in the present endemic area. *Parasitol Int* 2003; **52**: 385-393

7 **Godyn JJ**, Siderits R, Hazra A. Schistosoma mansoni in colon and liver. *Arch Pathol Lab Med* 2005; **129**: 544-545

8 **Ming-Chai C**, Chi-Yuan C, Pei-Yu C, Jen-Chun H. Evolution of colorectal cancer in schistsosomiasis: transitional mucosal changes adjacent to large intestinal carcinoma in colectomy specimens. *Cancer* 1980; **46**: 1661-1675

9 **Kaw LL Jr**, Punzalan CK, Crisostomo AC, Bowyer MW, Wherry DC. Surgical pathology of colorectal cancer in Filipinos: implications for clinical practice. *J Am Coll Surg* 2002; **195**: 188-195

10 **Mei J**, Hong HL, Ding YP, Fang YM. Clinicopathologic characteristics of chronic schistosomiasis complicating carcinoma of large intestine. *Zhonghua Xiaohuaneijing Zazhi* 2004; **21**: 49-50

11 **Radhakrishnan S**, Al Nakib B, Shaikh H, Menon NK. The value of colonoscopy in schistosomal, tuberculous, and amebic colitis. Two-year experience. *Dis Colon Rectum* 1986; **29**: 891-895

S- Editor Wang JL **L- Editor** Wang XL **E- Editor** Yang C

World Journal of Gastroenterology

Online Submissions: http://www.wjgnet.com/1007-9327office
wjg@wjgnet.com
doi:10.3748/wjg.v16.i6.728

World J Gastroenterol 2010 February 14; 16(6): 728-731
ISSN 1007-9327 (print)

BRIEF ARTICLE

Endoscopic ultrasound-guided celiac plexus neurolysis using a reverse phase polymer

Keith L Obstein, Fernanda P Martins, Gloria Fernández-Esparrach, Christopher C Thompson

Keith L Obstein, Christopher C Thompson, Gastroenterology Division, Brigham and Women's Hospital, 75 Francis Street, Boston, MA 02115, United States
Fernanda P Martins, Federal University of São Paulo, Rua Botucatu, 640 2° andar, São Paulo 04023-062, Brazil
Gloria Fernández-Esparrach, Department of Gastroenterology, Endoscopy Unit, Hospital Clinic, Villarroel 170, Barcelona 08036, Spain
Author contributions: Obstein KL, Martins FP, Fernández-Esparrach G and Thompson CC contributed equally to this work; Obstein KL, Martins FP, Fernández-Esparrach G and Thompson CC performed the research; Obstein KL, Martins FP, Fernández-Esparrach G and Thompson CC analyzed the data; Obstein KL, Martins FP, Fernández-Esparrach G and Thompson CC wrote the paper.
Supported by A grant from Generalitat de Catalunya (AGAUR, BE-100022)
Correspondence to: Christopher C Thompson, MD, MSc, FACG, FASGE, Gastroenterology Division, Brigham and Women's Hospital, 75 Francis Street, Thorn 1123, Boston, MA 02115, United States. ccthompson@partners.org
Telephone: +1-617-5258266 Fax: +1-617-2646342
Received: April 25, 2009 Revised: November 4, 2009
Accepted: November 11, 2009
Published online: February 14, 2010

Abstract

AIM: To assess the feasibility of endoscopic ultrasound (EUS)-guided celiac plexus neurolysis (CPN) using a poloxamer.

METHODS: In this prospective evaluation, six Yorkshire pigs underwent EUS-guided CPN. Three received an injection of 10 mL of 0.25% Lidocaine plus methylene blue (group 1) and three received an injection of 10 mL of 0.25% Lidocaine plus blue colored poloxamer (PS137-25) (group 2). Necropsy was performed immediately after the animals were sacrificed. The abdominal and pelvic cavities were examined for the presence of methylene blue and the blue colored poloxamer.

RESULTS: EUS-guided CPN was successfully performed in all 6 pigs without immediate complication. Methylene blue was identified throughout the peritoneal and retroperitoneal cavity in group 1. The blue colored poloxamer was found in the retroperitoneal cavity immediately adjacent to the aorta, in the exact location of the celiac plexus in group 2.

CONCLUSION: EUS-guided CPN using a reverse phase polymer in a non-survival porcine model was technically feasible. The presence of a poloxamer gel at the site of the celiac plexus at necropsy indicates a precise delivery of the neurolytic agent.

Key words: Celiac plexus neurolysis; Celiac plexus blockade; Endoscopic ultrasound; Polymer

Peer reviewer: Dr. Massimo Raimondo, Division of Gastroenterology and Hepatology, Mayo Clinic, 4500 San Pablo Road, Jacksonville, FL 32224, United States

Obstein KL, Martins FP, Fernández-Esparrach G, Thompson CC. Endoscopic ultrasound-guided celiac plexus neurolysis using a reverse phase polymer. *World J Gastroenterol* 2010; 16(6): 728-731 Available from: URL: http://www.wjgnet.com/1007-9327/full/v16/i6/728.htm DOI: http://dx.doi.org/10.3748/wjg.v16.i6.728

INTRODUCTION

Pancreatic cancer and chronic pancreatitis commonly cause pain that is difficult to control[1-3]. Opioids are frequently used in an attempt to mitigate pain, however, tolerance, nausea, constipation and other side effects develop[4,5]. Non-pharmacologic therapies are often employed to improve pain control and quality of life while reducing drug-related side effects. Celiac plexus blockade (CPB) using steroids or celiac plexus neurolysis (CPN) using alco-

hol has been utilized and considered safe. Endoscopic ultrasound (EUS)-guided CPB and CPN have demonstrated safety and efficacy through real-time imaging and anterior access to the celiac plexus from the posterior gastric wall, thereby avoiding complications related to the puncture of spinal nerves, arteries and the diaphragm.

Unfortunately, EUS-guided CPN and CPB provide limited benefit in terms of degree and duration of pain relief[3]. While benefit duration of EUS CPN diminishes after 8-12 wk, the etiology remains unknown[6,7]. One theory is that the neurolytic or blockade agent washes away from the celiac plexus injection site due to its liquid free-flowing form and does not remain in the ideal anatomical location. Thus, if a neurolytic or blockade agent could be delivered in an alternate phase (solid or gel), it could offer the potential for enhanced efficacy and safety[8].

Recently, non-ionic surfactant triblock (ABA) copolymers of polyethylene oxide$_a$-polypropylene oxide$_b$-polyethylene oxide$_a$ (PEO$_a$-PPO$_b$-PEO$_a$), also termed as poloxamers, have been widely used in industrial and medical applications[9-14]. Certain poloxamers have demonstrated rapid reverse phase thermosensitive properties at certain concentrations. Purified poloxamers PS138-25, PS107-20 and PS137-25 (Pluromed Inc., Woburn, MA, USA) are thin liquids at room temperature while at body temperature they are solid gel plugs (Figure 1). Therefore using a neurolytic or blockade agent as an additive in a purified poloxamer will potentially form a solid gel plug at the exact location of injection at the celiac plexus with enhancement of efficacy and safety. This study will assess the feasibility of EUS-guided CPN/CPB using a poloxamer in a non-survival porcine model.

MATERIALS AND METHODS

Six Yorkshire pigs (25-30 kg) were food restricted for 24 h prior to the procedure. Intravenous (iv) Telazol (4.4 mg/kg), Atropine sulfate (0.04 mg/kg) and Xylazine (2.2 mg/kg) were used for anesthesia induction followed by inhaled Isoflurane (1% to 3%) on a semi-closed circuit for anesthesia maintenance after endotracheal intubation.

EUS-guided CPN was then performed using a linear echoendoscope (GF-UC140P, Olympus, Tokyo, Japan). Once the location of the celiac plexus was identified by its position relative to the celiac artery, a 19-guage needle (Wilson-Cook Medical, Inc., Winston-Salem, NC, USA) was introduced under direct EUS visualization (Figure 2). The needle was flushed with 2 mL normal saline and aspiration was performed to evaluate for vessel penetration prior to additional injections.

Three pigs were randomly assigned to receive a single injection of 10 mL of Lidocaine (0.25%) plus methylene blue (group 1) and three pigs randomly received a single injection of 10 mL of Lidocaine (0.25%) plus blue colored poloxamer PS137-25 (LeGoo-endo™, Pluromed, Inc., Woburn, MA, USA) (group 2). Due to the increased viscosity of the poloxamer, a greater amount of force was required for injection. This was easily overcome with the use of a Controlled Radial Expansion (CRE) balloon dilator inflation hand pump system (Boston Scientific, Natick, MA, USA). During the procedure, the blood pressure, heart rate, temperature, ventilation, and oxygenation status of the pigs were continuously monitored by the professional veterinary team of the Animal Research at Children's Hospital (ARCH) (Boston, MA, USA). The investigators were not blinded to the injection group.

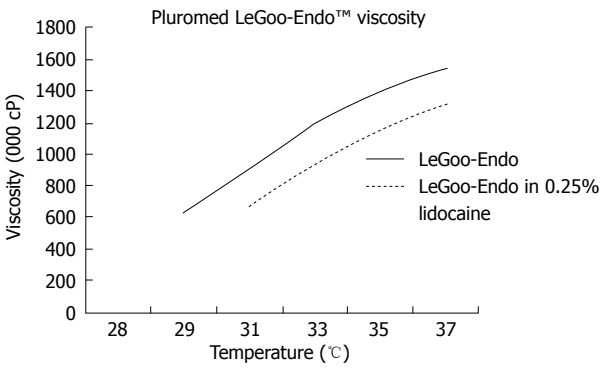

Figure 1 Temperature profile of LeGoo-Endo™ (PS137-25) that transits from liquid to gel at body temperature. The viscosity of LeGoo-Endo™ with Lidocaine is slightly higher than LeGoo-Endo™ at body temperature.

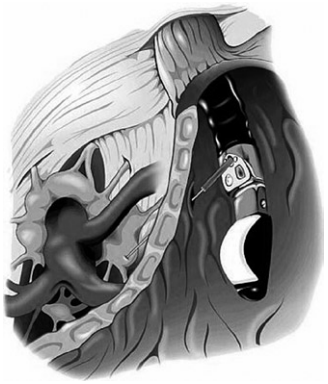

Figure 2 Illustration of endoscopic ultrasound (EUS)-guided celiac plexus neurolysis (CPN). Figure from Arcidiacono PG, Rossi M. Celiac Plexus Neurolysis. *J Pancreas* 2004; **5**: 315-321.

Using Fatal Plus (86 mg/kg), the group 1 pigs were immediately sacrificed after the procedure and the group 2 pigs were sacrificed at 60 min after the procedure. Necropsy was performed immediately upon death of the pigs and close examinations of the peritoneal and retroperitoneal cavities were made. Photographic and video records were obtained. This study was approved by the Animal Research Committee of the ARCH and complied with the National Academy of Sciences Guide for the Care and Use of Laboratory animals.

RESULTS

All the six pigs tolerated the procedure well with no immediate complications. EUS-guided CPN was successfully performed in both groups. An echodense smudge was endosonographically visualized after injection of Lidocaine plus methylene blue and Lidocaine plus blue colored poloxamer PS 137-25 (Figure 3).

At necropsy, methylene blue was identified spread throughout the peritoneal and retroperitoneal cavities in group 1. In group 2, a blue gel plug was identified in the retroperitoneal cavity, adjacent to the aorta, in the exact

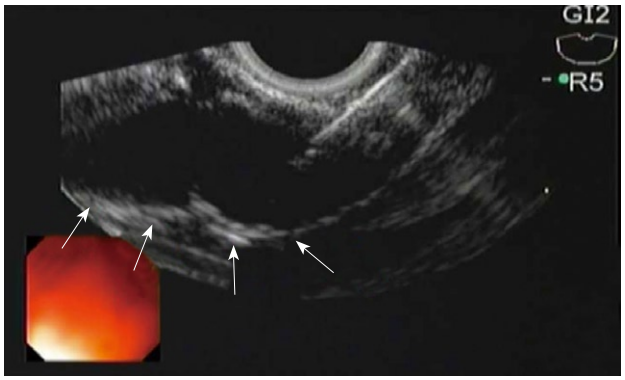

Figure 3 EUS-guided injection of Lidocaine plus blue colored poloxamer PS 137-25. The outer margin of the hypoechoic poloxamer is visualized upon injection into the celiac plexus (arrows).

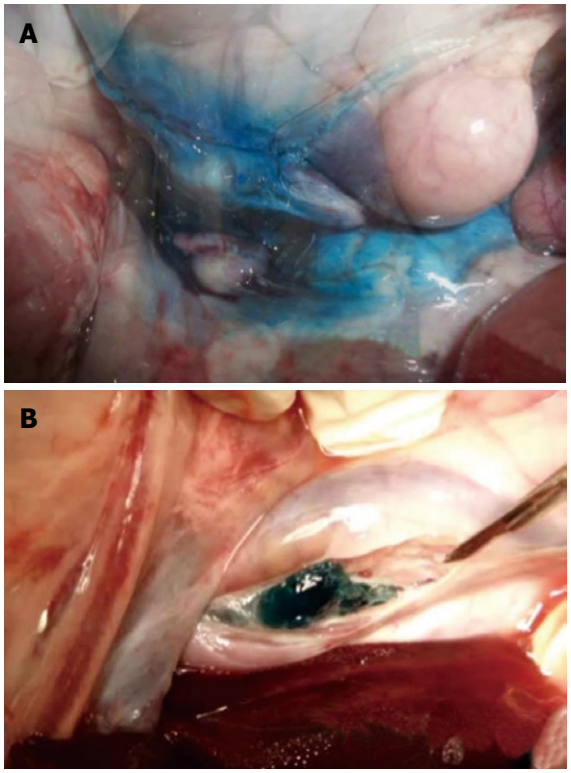

Figure 4 Group 1 (A) and group 2 (B) at necropsy.

location of the celiac plexus without evidence of any blue gel elsewhere in the peritoneal or retroperitoneal cavity (Figure 4).

DISCUSSION

EUS-guided CPN and CPB are safe and effective methods for pain control in patients with pancreatic neoplasms and chronic pancreatitis[3-6,15-18]. Unfortunately, the degree and duration of therapeutic effect vary. Gress *et al*[18] performed EUS-guided CPB in 90 patients with chronic pancreatitis and found that 55% of patients had decreased pain scores at a mean follow-up of 8 wk. This included a reduction in pain medication requirements as reported by the patients in the study. Persistent benefit was found in 26% of patients at week 12 and in 10% at week 24. Gunaratnam *et al*[6] performed EUS-guided CPN in 58 patients with pancreatic cancer, 78% of whom experienced a decline on a continuous 11-point visual analog pain scale 2 wk after the procedure. Only 54% experienced a decline of greater than 2 points after EUS-guided CPN and the efficacy diminished 8-12 wk after the procedure in those not receiving adjuvant therapy. Those authors also found that opioid administration increased throughout the study, however this increase was not statistically significant. Levy *et al*[3] administered EUS-guided direct ganglia injection in 33 patients with pancreatic cancer and chronic pancreatitis, 94% and 80% of the patients reported pain relief with alcohol injection at 2-4 wk after the procedure, however long-term follow-up data was not recorded.

In a report in 1996, fluoroscopic evaluation of the abdomen was conducted in patients who underwent EUS-guided CPN. Of those examined, all were noted to have injected material spread in a periaortic distribution with dye spread anterior and lateral to the aorta with extension in both the cranial and caudal direction[16]. This study supports our findings in group 1 pigs where the injected methylene blue was identified spread throughout the peritoneal and retroperitoneal cavities.

While short-term reduction in pain has been indicated, long-term benefit with this technique is limited. This may be explained by the fact that until recently, the celiac ganglia was unable to be directly visualized, leading to a less precise delivery of therapy[3,19,20]. Other possibilities include interference with direct visualization due to the echodense smudge and potential alterations in anatomy after injecting one side of the aorta with the therapeutic agent using the double injection technique. Additionally, dispersion of the therapeutic agent away from the desired location may act to influence the efficacy and duration.

The goal of this study was to evaluate the feasibility of EUS-guided CPN using a poloxamer that would potentially remain in the desired target location. This may yield a safer and more durable therapeutic result. In group 2, where the PS137-25 was injected, a gel plug was successfully created at the intended location of the celiac ganglia. The gel maintained the therapeutic agent in the celiac plexus and potentially released the drug slowly over time, thereby optimizing long-term therapeutic results.

A limitation of this study is that it is an acute, non-survival evaluation without long-term follow-up. It is therefore unclear how the injected gel plug interacts with the porcine model over time. Additionally, the study was performed using Lidocaine instead of a steroid or alcohol as it was simpler to integrate into the PS137-25. Steroid or alcohol integration may influence the temperature phase transition point of the poloxamer, however, the formation of a gel at body temperature and liquid at room temperature would remain intact. Lastly, the quantity and rate of drug release from the gel plug was unable to be determined in this current study.

In conclusion, EUS-guided CPN using a reverse phase polymer is feasible in a non-survival porcine model. The formation of a gel plug at the exact location of the celiac ganglia

may avoid dispersion of the injected therapeutic agent and increase the duration of analgesic effect. A survival study is now necessary to determine the duration and breakdown of the gel plug within the body. This would provide useful information on potential complications related to the plugs presence and allow for assessment of the therapy from the gel plug over time. Future studies will also integrate the use of steroids and alcohols into the poloxamer.

COMMENTS

Background

Pancreatic cancer and chronic pancreatitis commonly cause pain that is difficult to control. Nonpharmacologic therapies are often employed to improve pain control and quality of life while reducing drug-related side effects. Endoscopic ultrasound (EUS)-guided celiac plexus blockade (CPB) using steroids or celiac plexus neurolysis (CPN) have demonstrated safety and efficacy. Unfortunately, the neurolytic or blockade agent may wash away from the celiac plexus injection site due to its liquid free-flowing form and does not remain in the ideal anatomical location. Therefore, using a neurolytic or blockade agent as an additive in a reverse thermodynamic phase poloxamer will potentially form a solid gel plug at the exact location of injection at the celiac plexus with enhancement of efficacy and safety.

Research frontiers

Expanded research utilizing reverse phase poloxamers for additional applications in medical practice. Survival studies utilizing reverse phase poloxamers to determine the duration and breakdown of the gel plug within the body. Enhancement of the efficacy and safety of CPB and CPN.

Innovations and breakthroughs

Recently, non-ionic surfactant triblock (ABA) copolymers of polyethylene oxide$_a$-polypropylene oxide$_b$-polyethylene oxide$_a$ (PEO_a-PPO_b-PEO_a), also termed as poloxamers, have been widely used in industrial and medical applications. Certain poloxamers have demonstrated rapid reverse phase thermosensitive properties at certain concentrations. Purified poloxamers PS138-25, PS107-20 and PS137-25 (Pluromed Inc., Woburn, MA, USA) are thin liquids at room temperature while at body temperature they are solid gel plugs. Therefore, the novel use of a neurolytic or blockade agent as an additive in a purified poloxamer will potentially form a solid gel plug at the exact location of injection at the celiac plexus.

Applications

EUS-guided CPN using a reverse phase polymer is feasible in a non-survival porcine model. The formation of a gel plug at the exact location of the celiac ganglia may avoid dispersion of the injected therapeutic agent and increase the duration of analgesic effect. A survival study is now necessary to determine the duration and breakdown of the gel plug within the body. Future studies will also integrate the use of steroids and alcohols into the poloxamer.

Terminology

Poloxamer: A non-ionic surfactant triblock (ABA) copolymer of polyethylene oxide$_a$-polypropylene oxide$_b$-polyethylene oxide$_a$ (PEO_a-PPO_b-PEO_a). Reverse phase thermosensitivity: When a material or substance is in its liquid phase at cold temperature and in its solid phase at hot temperature.

Peer review

Dr. Thompson *et al* present an animal experience on the use of reverse phase polymer to increase the efficacy of EUS-guided celiac plexus injection for pancreatic pain control. This represent an interesting experiment outlining the possible improvement of the procedure by using a compound which facilitate the retention of the injectate at the local level (celiac plexus).

REFERENCES

1 **Ventafridda GV**, Caraceni AT, Sbanotto AM, Barletta L, De Conno F. Pain treatment in cancer of the pancreas. *Eur J Surg Oncol* 1990; **16**: 1-6

2 **Lankisch PG**. Natural course of chronic pancreatitis. *Pancreatology* 2001; **1**: 3-14

3 **Levy MJ**, Topazian MD, Wiersema MJ, Clain JE, Rajan E, Wang KK, de la Mora JG, Gleeson FC, Pearson RK, Pelaez MC, Petersen BT, Vege SS, Chari ST. Initial evaluation of the efficacy and safety of endoscopic ultrasound-guided direct Ganglia neurolysis and block. *Am J Gastroenterol* 2008; **103**: 98-103

4 **Tran QN**, Urayama S, Meyers FJ. Endoscopic ultrasound-guided celiac plexus neurolysis for pancreatic cancer pain: a single-institution experience and review of the literature. *J Support Oncol* 2006; **4**: 460-462, 464; discussion 463-464

5 **Michaels AJ**, Draganov PV. Endoscopic ultrasonography guided celiac plexus neurolysis and celiac plexus block in the management of pain due to pancreatic cancer and chronic pancreatitis. *World J Gastroenterol* 2007; **13**: 3575-3580

6 **Gunaratnam NT**, Sarma AV, Norton ID, Wiersema MJ. A prospective study of EUS-guided celiac plexus neurolysis for pancreatic cancer pain. *Gastrointest Endosc* 2001; **54**: 316-324

7 **Polati E**, Finco G, Gottin L, Bassi C, Pederzoli P, Ischia S. Prospective randomized double-blind trial of neurolytic coeliac plexus block in patients with pancreatic cancer. *Br J Surg* 1998; **85**: 199-201

8 **Qiu Y**, Park K. Environment-sensitive hydrogels for drug delivery. *Adv Drug Deliv Rev* 2001; **53**: 321-339

9 **Nace VM**. Nonionic surfactants: polyoxyalkylene block copolymers. Surfactant Science Series, vol. 60. New York: Marcel Dekker, 1996: 280

10 **Maynard C**, Swenson R, Paris JA, Martin JS, Hallstrom AP, Cerqueira MD, Weaver WD. Randomized, controlled trial of RheothRx (poloxamer 188) in patients with suspected acute myocardial infarction. RheothRx in Myocardial Infarction Study Group. *Am Heart J* 1998; **135**: 797-804

11 **O'Keefe JH**, Grines CL, DeWood MA, Schaer GL, Browne K, Magorien RD, Kalbfleisch JM, Fletcher WO Jr, Bateman TM, Gibbons RJ. Poloxamer-188 as an adjunct to primary percutaneous transluminal coronary angioplasty for acute myocardial infarction. *Am J Cardiol* 1996; **78**: 747-750

12 **Orringer EP**, Casella JF, Ataga KI, Koshy M, Adams-Graves P, Luchtman-Jones L, Wun T, Watanabe M, Shafer F, Kutlar A, Abboud M, Steinberg M, Adler B, Swerdlow P, Terregino C, Saccente S, Files B, Ballas S, Brown R, Wojtowicz-Praga S, Grindel JM. Purified poloxamer 188 for treatment of acute vaso-occlusive crisis of sickle cell disease: A randomized controlled trial. *JAMA* 2001; **286**: 2099-2106

13 **Raymond J**, Metcalfe A, Salazkin I, Schwarz A. Temporary vascular occlusion with poloxamer 407. *Biomaterials* 2004; **25**: 3983-3989

14 **Boodhwani M**, Cohn WE, Feng J, Ramlawi B, Mieno S, Schwarz A, Sellke FW. Safety and efficacy of a novel gel for vascular occlusion in off-pump surgery. *Ann Thorac Surg* 2005; **80**: 2333-2337

15 **Levy MJ**, Wiersema MJ. EUS-guided celiac plexus neurolysis and celiac plexus block. *Gastrointest Endosc* 2003; **57**: 923-930

16 **Wiersema MJ**, Wiersema LM. Endosonography-guided celiac plexus neurolysis. *Gastrointest Endosc* 1996; **44**: 656-662

17 **Gress F**, Schmitt C, Sherman S, Ikenberry S, Lehman G. A prospective randomized comparison of endoscopic ultrasound- and computed tomography-guided celiac plexus block for managing chronic pancreatitis pain. *Am J Gastroenterol* 1999; **94**: 900-905

18 **Gress F**, Schmitt C, Sherman S, Ciaccia D, Ikenberry S, Lehman G. Endoscopic ultrasound-guided celiac plexus block for managing abdominal pain associated with chronic pancreatitis: a prospective single center experience. *Am J Gastroenterol* 2001; **96**: 409-416

19 **Gleeson FC**, Levy MJ, Papachristou GI, Pelaez-Luna M, Rajan E, Clain JE, Topazian MD. Frequency of visualization of presumed celiac ganglia by endoscopic ultrasound. *Endoscopy* 2007; **39**: 620-624

20 **Levy M**, Rajan E, Keeney G, Fletcher JG, Topazian M. Neural ganglia visualized by endoscopic ultrasound. *Am J Gastroenterol* 2006; **101**: 1787-1791

S- Editor Tian L **L- Editor** Ma JY **E- Editor** Lin YP

World Journal of Gastroenterology

Online Submissions: http://www.wjgnet.com/1007-9327office
wjg@wjgnet.com
doi:10.3748/wjg.v16.i6.732

World J Gastroenterol 2010 February 14; 16(6): 732-739
ISSN 1007-9327 (print)

BRIEF ARTICLE

ABCG5-positivity in tumor buds is an indicator of poor prognosis in node-negative colorectal cancer patients

Isabel Hostettler, Inti Zlobec, Luigi Terracciano, Alessandro Lugli

Isabel Hostettler, Inti Zlobec, Luigi Terracciano, Alessandro Lugli, Institute for Pathology, University Hospital of Basel, Schoenbeinstrasse 40, Basel, CH-4031, Switzerland
Author contributions: Hostettler I and Zlobec I contributed equally to the research; Hostettler I collected and interpreted the data; Lugli A designed the study, conceptualized the project and interpreted the data; Zlobec I analyzed and interpreted the data and drafted the manuscript; Terracciano L provided the material and administrative support; All authors played a role in the editing, revision and final approval of this manuscript.
Supported by The Krebsliga Beider Basel (Zlobec I, Terracciano L and Lugli A)
Correspondence to: Dr. Alessandro Lugli, MD, Institute for Pathology, University Hospital of Basel, Schoenbeinstrasse 40, Basel, CH-4031, Switzerland. alugli@uhbs.ch
Telephone: +41-61-2652390 Fax: +41-61-2653194
Received: September 18, 2009 Revised: November 2, 2009
Accepted: November 9, 2009
Published online: February 14, 2010

Abstract

AIM: To analyze the expression of 8 putative cancer stem cell (CSC) markers within colorectal cancer tumor buds and to determine their prognostic impact in patients with this disease.

METHODS: Immunohistochemistry was performed on 101 colorectal cancer resections for CK22 (to identify tumor buds) as well as CD133, CD166, CD24, CD44s, CD90, EpCAM, ALDH1, and ABCG5, and their expression within tumor buds was evaluated.

RESULTS: CD90, CD44s, and CD133 expression in tumor buds was found in less than 5% of all cases. ALDH1, CD24, CD166 were expressed in 16.5%, 16.2%, and 34% cases, respectively, while ABCG5 and EpCAM expression was more frequent and found in 35% and 69% of cases, respectively. Of the 8 markers studied, EpCAM and ABCG5 positivity in tumor buds were significantly associated with poor prognosis (P = 0.023, P = 0.038, respectively) in multivariable analysis with pT and pN classification [P = 0.048; hazard ratio (HR): 2.64; 95% CI: 1.0-6.9, for EpCAM and P = 0.029; HR: 2.22; 95% CI: 1.0-4.5, for ABCG5]. Poor survival time was particularly striking for lymph node-negative patients with ABCG5-positive buds (P < 0.001).

CONCLUSION: Expression of putative stem cell markers EpCAM and ABCG5 within the tumor buds of colorectal cancer are frequently noted and are associated with poor prognosis.

Key words: Colorectal cancer; Cancer stem cells; Tumor budding; ABCG5; Prognosis

Peer reviewers: Dr. Abdel-Majid Khatib, PhD, INSERM, UMRS 940, Equipe Avenir, Cibles Thérapeutiques, I.G.M. 27 Rue Juliette Dodu, 75010 Paris, France; Evangelos Tsiambas, MD, PhD, Lecturer in Molecular Cytopathology, Department of Pathology, Medical School, University of Athens, Athens 15341, Greece; Toshiyuki Ishiwata, Associate Professor, Department of Pathology, Integrative Oncological Pathology, Nippon Medical School, 1-1-5 Sendagi, Bunkyo-ku, Tokyo 113-8602, Japan

Hostettler I, Zlobec I, Terracciano L, Lugli A. ABCG5-positivity in tumor buds is an indicator of poor prognosis in node-negative colorectal cancer patients. *World J Gastroenterol* 2010; 16(6): 732-739 Available from: URL: http://www.wjgnet.com/1007-9327/full/v16/i6/732.htm DOI: http://dx.doi.org/10.3748/wjg.v16.i6.732

INTRODUCTION

In 1985, Gabbert and colleagues described a peculiar feature at the invasive border of differentiated colonic tumors: neoplastic glands irregularly arranged into small strands or single cells without junctional complexes and often missing even rudimentary basement membranes[1,2].

Their observation of the tumor front of differentiated adenocarcinomas focally acquiring the phenotype of undifferentiated tumors is credited for pioneering the concept commonly referred to today as epithelial mesenchymal transition (EMT) and represented in colorectal cancer by its histological hallmark "tumor budding".

Defined as single cells or clusters of up to 4 or 5 cells at the invasive tumor front, tumor budding can easily be spotted using pan-cytokeratin stains and is highly associated with an infiltrating tumor border configuration[3]. The adverse prognostic impact of tumor budding in colorectal cancer has consistently been reported and recognized by the American Joint Committee on Cancer/Union International Contre le Cancer (AJCC/UICC) as an additional prognostic factor to complement Tumor Node Metastases (TNM) staging[4-13]. Moreover, tumor budding is frequently linked to high-grade tumors, lymph node positivity, vascular and lymphatic invasion, as well as to both local tumor recurrence and distant metastasis[11,14-17].

Several lines of evidence seem to suggest that tumor buds may, to some extent, represent malignant colorectal cancer stem cells (CSC) because of their potential for migration and re-differentiation locally and at sites of metastasis[18]. "Pseudopodia-like" cytoplasmic protrusions have been described in tumor buds, which seem to be in direct contact with adjacent interstitial tissue suggesting their formation during cell migration[2,19,20]. Previous studies on EMT and events occurring at the invasive tumor front implicate, in particular, Wnt pathway signaling in the process of tumor budding[21]. This is evidenced by increased β-catenin immunohistochemical staining in tumor buds, a concomitant loss of E-cadherin, as well as overexpression of laminin5γ2 along with activation of transcriptional repressors SLUG, and ZEB1[19,22,23]. Other groups have described changes in the expression of several matrix metalloproteinases (MMP-2, MMP-7, MMP-9), and extensive staining of β(Ⅲ)-tubulin, a major constituent of microtubules, all suggestive of invasion and migration potential of tumor buds[24-26]. Together with loss of epithelial-like properties and cell-cell adhesion, in addition to the ability to re-differentiate at distant sites, the hypothesis that tumor buds could represent putative migrating stem cells is not far-fetched.

Phenotypic characterization of colorectal CSC is still debated although putative CSC populations have been identified in several solid tumors based on functional stem cell-like properties and expression of specific markers. Recently, 4 such markers have been proposed for colorectal cancer; CD133, a glycoprotein expressed on CD34+ stem and progenitor cells in fetal liver, endothelial precursors and fetal neural stem cells; CD44s, an adhesion molecule with roles in signaling, migration, and homing, EpCAM, a homophilic Ca^{2+}-independent cell adhesion molecule expressed on the basolateral surfaces of most epithelial cells; and CD166 or activated leukocyte cell adhesion molecule (ALCAM) known as a mesenchymal stem cell marker[27]. Other putative stem cell markers have also generated interest in other tumor types including ABCG5, a member of the ATP binding cassette family involved in transport of sterol and other lipids, ALDH1, a member of the aldehyde dehydrogenase family of enzymes with roles in proliferation, differentiation, and survival, CD24, an adhesion molecule and ligand for P-selectin, and CD90, a mediator of thymocyte adhesion to thymic stroma[28].

Considering the apparent stem cell-like properties of tumor buds and adverse effect of budding on clinical outcome, we hypothesized that expression of a subset of these 8 putative stem cell markers could have significant implications for prognosis in patients with positive tumor budding. Thus, the aim of this study was to determine the impact of CD166, CD44s, EpCAM, ALDH1, CD133, CD24, CD90, and ABCG5 expressed within tumor buds on prognosis in patients with colorectal cancer.

MATERIALS AND METHODS

Patients

Three hundred patients with pre-operatively untreated tumors who underwent tumor resection between 1987 and 1996 at the University Hospital of Basel, Switzerland were initially included in this study. These patients were randomly selected from a larger previously described cohort of 938 colorectal cancer patients with full clinicopathological information[29]. Histopathological features were re-reviewed from the corresponding hematoxylin and eosin slides by an experienced gastrointestinal pathologist (LT) and included histological subtype, pT classification, pN classification, tumor grade, and vascular invasion. Tumor border configuration and peritumoral lymphocytic inflammation were diagnosed according to Jass *et al*[30]. Clinical data were retrieved from patient reports including age at diagnosis, tumor diameter, and tumor location. The clinical endpoint of interest was cancer-specific survival time. Censored observations included patients who died for reasons other than colorectal cancer, who were alive or who were lost to follow-up. The study design is outlined in Figure 1.

Specimen characteristics

The paraffin-embedded colorectal cancer resection specimens for all 300 patients were retrieved from the archives of the Institute of Pathology, University Hospital of Basel as well as at the Institute of Clinical Pathology, Basel, Switzerland. The use of material for this study was approved by the local ethics committee of the University of Basel.

Assay methods

Immunohistochemistry for CK22 staining: All 300 specimens were cut at 4 μm and underwent immunostaining for CK22, a marker of epithelial cells that served to highlight areas of tumor budding, and which is routinely performed in our laboratories for diagnostic purposes. Briefly, tissues were de-waxed and re-hydrated in dH_2O. Following pressure cooker-mediated antigen retrieval in 0.001 mol/L ethylenediaminetetraacetic acid pH 8.0, endogenous peroxidase activity was blocked using 0.5% H_2O_2. Sections were incubated with 10% normal

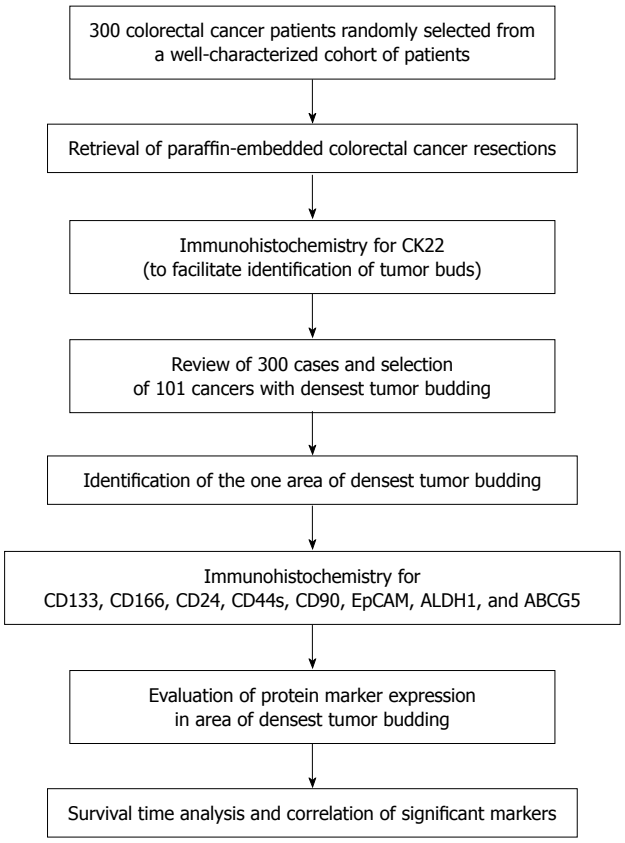

Figure 1 Study design.

goat serum for 20 min. After incubation with primary antibody (CK22 polyclonal, Genetex, Inc., 1:100), sections were incubated with horseradish peroxidase-conjugated secondary antibody (DakoCytomation) for 30 min at room temperature, immersed in amino-ethylcarbazole (DakoCytomation) for 30 min, and counterstained with hematoxylin.

Selection of densest budding cases: All 300 cases were evaluated using a 10 × magnification for the presence of tumor budding (AL). Since this study was designed to focus on expression of putative stem cell markers within the tumor buds themselves, cases with the densest number of budding cells were selected for the analysis (n = 101). These 101 cases were then carefully re-scored for tumor budding according to the method proposed by Ueno *et al*[11]. Briefly, the tumor border was scanned at 10 × power and the area of most dense budding identified. In the center of this area, tumor buds (single cells or clusters of up to 5 cells) were counted at 20 × magnification. In order to locate this same region of dense budding on serial sections, the area was circled with a felt-tip pen. The clinico-pathological features for these 101 patients are outlined in Table 1.

Immunohistochemistry for putative stem cell markers: Following a similar protocol as described above, the 101 cases with densest tumor budding were immunostained for CD166 (clone 110G/07; 1:200; Novocastra), CD44s (clone DF1485; 1:50; Dako), EpCAM (clone VU-1D9; 1:200; Cell Signaling), ALDH1 (isoform α1, clone Polyclonal; 1:500; AbCam), CD133 (clone 24139; 1:100; Cell Signaling), ABCG5 (1:200, Sigma-Aldrich), CD90 (clone 5E10, 1:100, BD Pharmingen), CD24 (clone SN3B, Neomarkers, 1:100). CD133, CD166, CD44, CD24, CD90, EpCAM, and ABCG5 were evaluated for both membrane and cytoplasmic staining; ALDH1 was exclusively evaluated in the cytoplasm of tumor buds. The number of CD166, CD44s, EpCAM, ALDH1, CD133, CD24, CD90, and ABCG5 positive tumor buds was then evaluated in the area of densest tumor budding as determined by CK22 staining.

Table 1 Patient characteristics (n = 101)

Clinico-pathological features		Frequency n (%)
Gender (n = 101)	Female	63 (62.4)
	Male	38 (37.6)
Tumor location (n = 101)	Left-sided	64 (63.4)
	Right-sided	37 (36.6)
Histological subtype (n = 101)	Mucinous	7 (6.9)
	Non-mucinous	94 (93.1)
pT classification (n = 99)	pT1-2	16 (16.2)
	pT3-4	83 (83.8)
pN classification (n = 100)	pN0	52 (52.0)
	pN1-2	48 (48.0)
Tumor grade (n = 99)	G1-2	92 (92.9)
	G3	7 (7.1)
Vascular invasion (n = 99)	Absence	80 (80.8)
	Presence	19 (19.2)
Tumor border configuration (n = 99)	Pushing	23 (23.2)
	Infiltrating	76 (76.8)
Peritumoral lymphocytic inflammation (n = 99)	Absent	79 (79.8)
	Present	20 (20.2)
Age (n = 101)	Mean (range)	67.4 (41-89)
Tumor diameter (n = 101)	Mean (range)	54.9 (20-170)
5-year survival rate (n = 101)	% (95% CI)	69.3 (59-78)

Statistical analysis

Univariate survival analysis was carried out using the Kaplan-Meier method and log rank test. Two multivariable Cox regression analyses were performed. First, to test the independent prognostic value of tumor budding, the effects of pT stage, pN stage, tumor grade, and vascular invasion were adjusted for. Subsequently, because of the small number of positive cases, only 2 variables could be entered into the multivariable Cox regression analysis along with positive expression of the protein in tumor buds, hence pT classification and pN classification were selected. The assumption of proportional hazards was verified prior to this analysis. Hazard ratios (HR) and 95% CI were obtained to determine the prognostic effect of positive cases adjusting for pT and pN. Kendall's correlation coefficient (r) was obtained for correlation analysis of markers. $P < 0.05$ was considered statistically significant.

RESULTS

Prognostic value of tumor budding

In order to confirm the prognostic value of tumor budding in our series, cases were divided into 3 groups

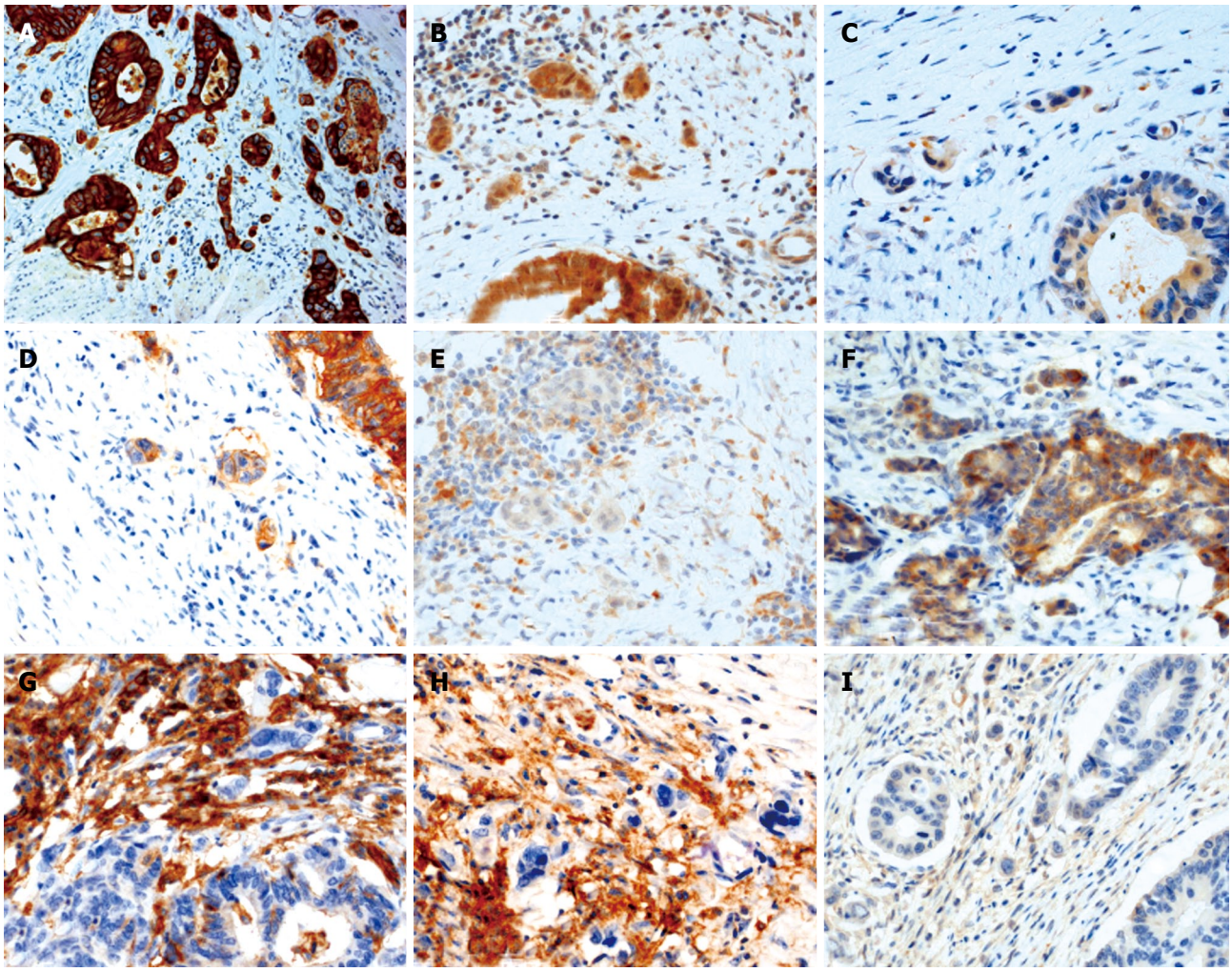

Figure 2 Immunohistochemical expression of putative cancer stem cell markers by tumor buds in colorectal cancer. A: Cytokeratin 22 staining highlighting the presence of tumor buds in low power magnification (5 ×); B-I: 40 × magnification. Positive expression of ABCG5 (B), ALDH1 (C), and EpCAM (D) in tumor buds with scattered positive staining of stromal cells, absence of staining of CD133 in tumor buds with positive staining of stromal cells (E), positive expression of CD166 in tumor buds with occasional positivity of stromal cells (F), absence of CD24 (G), CD44s (H), and CD90 staining (I) in tumor buds with positive stromal cell expression.

based on the distribution of number of tumor buds: those with < 40 buds, between 41-60 buds, and finally those with > 60 buds per 20 × field. The greater the number of tumor buds the more unfavorable was the prognosis both in univariate ($P < 0.001$) and multivariable analysis with pT, pN, tumor grade, and vascular invasion (HR: 1.6, 95% CI: 1.2-2.1).

Expression of putative stem cell markers within tumor buds

CK22 staining was used to identify regions of densest tumor budding with epithelial cells exclusively immunoreactive for the protein. Staining for ABCG5, ALDH1, CD133, CD166, CD24, and CD44s could be observed in both tumor cells and inflammatory or stromal cells. EpCAM staining was predominantly limited to expression in tumor cells whereas CD90 was almost always expressed by stromal cells and only in 3 cases in the tumor itself.

Marker expression was then evaluated in the area of densest budding. Representative immunostains for all markers are shown in Figure 2. Only one case (1.03%) was positive for CD90, while 5 (5.1%) and 6 (6.1%) cases were positive for CD44s and CD133, respectively. On the other hand, a considerably larger number of positive cases was found to express ALDH1 (16/97, 16.5%), CD24 (16/99, 16.2%) and CD166 (34/100, 34%). Finally, ABCG5 and EpCAM staining were frequent events with 39/97 (40.2%) and 69/100 (69%) positive cases, respectively (Figure 3).

Prognostic differences with putative stem cell marker expression in tumor buds

No relationship between survival time and ALDH1, CD24 and CD166 was observed. Patients with positive EpCAM or ABCG5 within tumor buds had a significantly poorer outcome in comparison to patients with no expression of these markers ($P = 0.023$ and $P = 0.038$, respectively) (Figure 4). Multivariable analysis was performed for EpCAM and ABCG5 along with pT and pN classification. EpCAM maintained its significant association with a negative effect on outcome (HR: 2.64, 95% CI: 1.0-6.9, $P = 0.048$), adjusted for pT and pN classification, a result

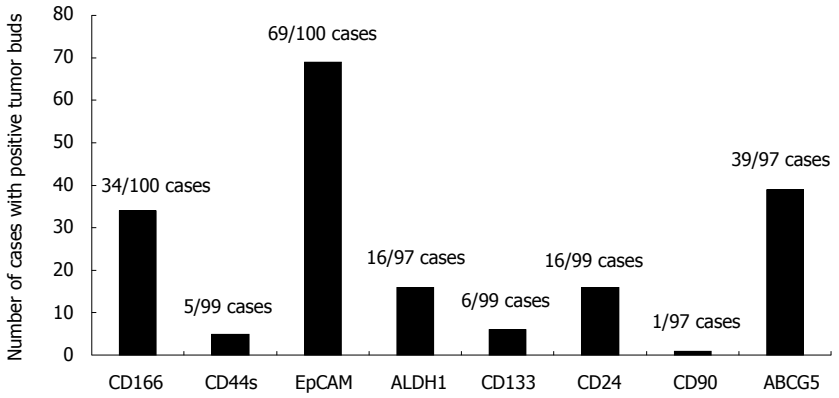

Figure 3 Histogram showing the number of cases with any degree of positive staining for the 8 putative stem cells markers.

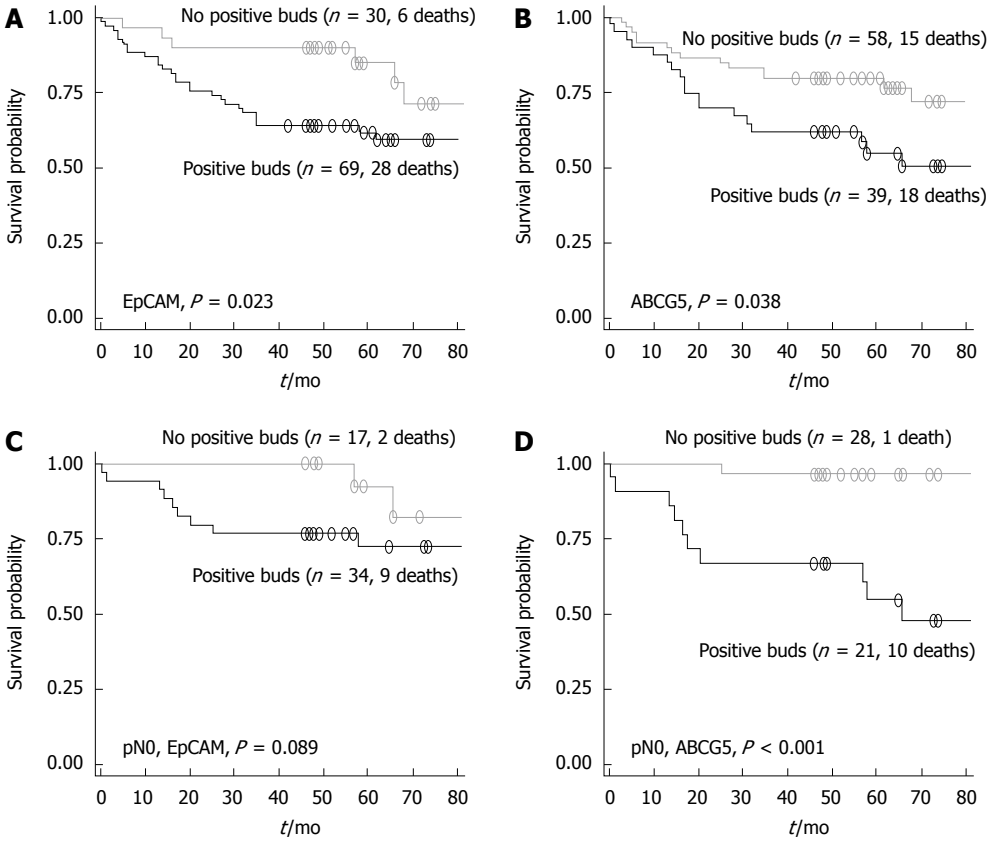

Figure 4 Kaplan-Meier survival curves illustrating the prognostic differences in patients with or without positive staining of EpCAM (A) and positive staining of ABCG5 (B) in tumor buds; differences in prognosis are further analyzed for lymph node-negative patients differing in EpCAM (C) and ABCG5 (D) expression in tumor buds.

which was also pronounced in patients with lymph node-negative disease. Similarly, positive ABCG5 expression in tumor buds was again associated with a poor patient prognosis ($P = 0.029$) underlined by a relative risk of death of 2.22 (95% CI: 1.0-4.5) compared to patients lacking expression of ABCG5. ABCG5-positive patients with lymph node-negative cancers had a particularly poor outcome in comparison to their node-negative and ABCG5-negative counterparts ($P < 0.001$).

Correlation between EpCAM and ABCG5 expression

In order to determine whether the same cases expressed both EpCAM and ABCG5, the correlation between these markers was tested. The correlation coefficient $r = 0.17$ and $P = 0.08$, indicated a positive but non-significant trend in the expression of these markers. Of the 96 patients evaluable for both EpCAM and ABCG5, 31 (32.3%) were positive and 21 (21.9%) were negative for both markers. We subsequently tested whether the combination of these markers could additionally stratify patients into prognostic subgroups. Prognosis was worse in patients positive for both EpCAM and ABCG5 ($P = 0.013$) with a relative risk of death of 2.39 (95% CI: 1.2-4.7) compared to patients negative for both. In comparison to

the relative risk of death for either EpCAM or ABCG5 alone, the combination of both markers does not suggest a superior discrimination of patients into better and worse prognostic subgroups. A negative but statistically non-significant correlation between CD44s and EpCAM (r = -0.15, P = 0.145) and ABCG5 (r = -0.1, P = 0.328) was observed.

DISCUSSION

In this study we evaluated 8 of the most promising putative cancer stem cell markers CD166, CD44s, EpCAM, ALDH1, CD133, CD24, CD90, and ABCG5 and their expression in colorectal tumor buds using 101 whole tissue sections from a well-characterized cohort of patients. Our main findings suggest that positive expression of EpCAM and ABCG5 within tumor buds is a frequent event and may confer a significant and adverse prognosis in patients with colorectal cancer, particularly in lymph node-negative patients expressing ABCG5.

Several of these putative CSC markers have previously been evaluated in tumor buds. Horst *et al*[31] assessed CD133 in colorectal cancers using 3 different antibodies. They reported pronounced expression of CD133 in tumor glands close to the invasive margin but restricted to glandular differentiated cells and a general lack of CD133 in the tumor buds themselves. They further found that nuclear β-catenin expression and CD133 were not correlated and that the 2 protein markers may stain different, yet overlapping populations of tumor cells[32]. Our results of only a few CD133-positive tumor budding cases and no prognostic differences between patients with CD133-positive and -negative tumor budding are in line with these findings. Investigating rectal cancers, Gosens *et al*[33] found strong membranous EpCAM staining in the tumor center and a progressive loss at the tumor front associated with high tumor grade, tumor budding, and a poor local and distant recurrence-free survival. This was also accompanied by a concomitant increase in cytoplasmic EpCAM staining as well as overexpression of β-catenin. We also observed a pronounced loss of EpCAM toward the invasive tumor front, particularly in tumors with infiltrating margins, as well as a shift in localization of EpCAM expression from membrane to cytoplasm. The findings of this study indicate that despite this loss towards the border, patients with EpCAM-positive tumor buds have a most unfavorable survival time, a result which was maintained in multivariable analysis. Although EpCAM, like CD44, is known for its cell-adhesion function, it seems to have versatile roles in signaling, cell migration, proliferation, and differentiation depending on the microenvironment[34]. In the normal epithelium, EpCAM supports adhesion, whereas in carcinoma it seems to prevent strong cell-cell adhesion, enabling cell migration and metastasis similar to E-cadherin. The intracellular localization of EpCAM and its identification by immunohistochemistry may represent differential roles of this protein in colorectal cancer progression and partially explain why, despite loss of expression from normal at tumor center to tumor border, the positive expression in buds is linked to a poorer patient outcome.

Masaki *et al*[35] have also described associations between membranous CD44 and CD44v6 expression and a higher degree of tumor budding. However, it is unclear from these studies whether expression was evaluated in the tumor center, then correlated with tumor budding or whether expression was evaluated in buds themselves. Our group has also previously found that loss of membranous expression of both CD44s and CD44v6 within the tumor center is highly correlated with an infiltrating tumor border configuration, a result which is in line with the findings of this study showing only rare cases expressing CD44s in tumor buds, too few in fact for adequate survival analysis.

ABCG5 is a member of the ATP-binding cassette subfamily G and plays a role in the efflux transport of cholesterol[36,37]. Its expression has been correlated with clinical melanoma progression and it is hypothesized to contribute to the refractoriness of metastatic cancer to chemotherapy[38]. Indeed, specific targeting of ABCG5 with monoclonal antibodies appears to significantly inhibit cell growth. To date, ABCG5 does not appear to have been investigated in colorectal cancer, and moreover in tumor buds. However, our findings of ABCG5 expression in a considerable number of colorectal cancer tumor buds as well as an adverse prognosis in particular in patients with lymph node-negative disease suggests that the role of ABCG5 in colorectal pathogenesis warrants further investigation.

Our results of adverse prognosis in EpCAM-positive and ABCG5-positive patients may be to some extent affected by the lack of information regarding cancer treatment. Despite this limitation, the unfavorable outcome associated with EpCAM and, particularly with ABCG5-positivity was maintained in patients with lymph node-negative colorectal cancers who, by today's treatment guidelines, are not generally considered for adjuvant chemotherapy[39]. The findings of this study regarding the prognostic value and expression of EpCAM and ABCG5 within colorectal tumor buds should be considered preliminary and require validation on independent patient cohorts.

To summarize, in contrast to CD133, CD166, CD24, CD44s, CD90, and ALDH1, the expression of putative stem cell markers EpCAM and ABCG5 within the tumor buds of colorectal tumors are frequent events indicating poor prognosis. In particular, patients with lymph node-negative disease expressing EpCAM or ABCG5 have a particularly unfavorable prognosis suggesting that the immunohistochemically analyzed EpCAM and ABCG5 in tumor buds may be useful biomarkers of poor outcome in this subgroup of patients. Further studies are necessary to address the important issue of whether EpCAM- or ABCG5-positive tumor buds indeed represent migrating colorectal CSC.

COMMENTS

Background

Tumor budding at the invasive tumor front of colorectal cancer is recognized as an important independent prognostic factor. Several lines of evidence seem to suggest that tumor buds may to some extent represent malignant colorectal cancer stem cells because of their potential for migration and re-differentiation locally and at sites of metastasis.

Research frontiers

Phenotypic characterization of cancer stem cells is still debated although at least 8 putative stem cell markers have been suggested including CD166, CD44s, EpCAM, ALDH1, CD133, CD24, CD90, and ABCG5. The research hotspot is how the expression of putative cancer stem cell markers can be potentially used as prognostic biomarkers in patients with colorectal cancer.

Innovations and breakthroughs

Considering the apparent stem cell-like properties of tumor buds and adverse effect of budding on clinical outcome, in this study the authors performed immunohistochemical staining of 8 promising putative cancer stem cell markers, namely CD166, CD44s, EpCAM, ALDH1, CD133, CD24, CD90, and ABCG5 and assessed their expression within tumor buds to determine their frequency and potential prognostic significance in patients with colorectal cancer.

Applications

The study results suggest that, in contrast to CD133, CD166, CD24, CD44s, CD90, and ALDH1, the expression of putative cancer stem cell markers EpCAM and ABCG5 within the tumor buds of colorectal cancer are frequent events associated with poor prognosis.

Terminology

Tumor budding: single cells or clusters of up to 4 or 5 cells at the invasive tumor front of colorectal cancer which are diagnosed at high magnification and highly associated with an infiltrating tumor growth pattern. Cancer stem cells: tumorigenic cell populations with the potential to self-renew and differentiate.

Peer review

The study is characterized technically by an excellent application of immunohistochemistry and provides interesting evidence to aid in understanding the correlation between cancer stem cell markers in the invasive front of colorectal cancer and prognosis.

REFERENCES

1 **Gabbert H**. Mechanisms of tumor invasion: evidence from in vivo observations. *Cancer Metastasis Rev* 1985; **4**: 293-309

2 **Gabbert H**, Wagner R, Moll R, Gerharz CD. Tumor dedifferentiation: an important step in tumor invasion. *Clin Exp Metastasis* 1985; **3**: 257-279

3 **Prall F**. Tumour budding in colorectal carcinoma. *Histopathology* 2007; **50**: 151-162

4 **Choi HJ**, Park KJ, Shin JS, Roh MS, Kwon HC, Lee HS. Tumor budding as a prognostic marker in stage-III rectal carcinoma. *Int J Colorectal Dis* 2007; **22**: 863-868

5 **Compton C**, Fenoglio-Preiser CM, Pettigrew N, Fielding LP. American Joint Committee on Cancer Prognostic Factors Consensus Conference: Colorectal Working Group. *Cancer* 2000; **88**: 1739-1757

6 **Hase K**, Shatney C, Johnson D, Trollope M, Vierra M. Prognostic value of tumor "budding" in patients with colorectal cancer. *Dis Colon Rectum* 1993; **36**: 627-635

7 **Okuyama T**, Oya M, Ishikawa H. Budding as a useful prognostic marker in pT3 well- or moderately-differentiated rectal adenocarcinoma. *J Surg Oncol* 2003; **83**: 42-47

8 **Prall F**, Nizze H, Barten M. Tumour budding as prognostic factor in stage I/II colorectal carcinoma. *Histopathology* 2005; **47**: 17-24

9 **Spaderna S**, Schmalhofer O, Hlubek F, Berx G, Eger A, Merkel S, Jung A, Kirchner T, Brabletz T. A transient, EMT-linked loss of basement membranes indicates metastasis and poor survival in colorectal cancer. *Gastroenterology* 2006; **131**: 830-840

10 **Ueno H**, Mochizuki H, Hashiguchi Y, Hatsuse K, Fujimoto H, Hase K. Predictors of extrahepatic recurrence after resection of colorectal liver metastases. *Br J Surg* 2004; **91**: 327-333

11 **Ueno H**, Mochizuki H, Hashiguchi Y, Shimazaki H, Aida S, Hase K, Matsukuma S, Kanai T, Kurihara H, Ozawa K, Yoshimura K, Bekku S. Risk factors for an adverse outcome in early invasive colorectal carcinoma. *Gastroenterology* 2004; **127**: 385-394

12 **Wang LM**, Kevans D, Mulcahy H, O'Sullivan J, Fennelly D, Hyland J, O'Donoghue D, Sheahan K. Tumor budding is a strong and reproducible prognostic marker in T3N0 colorectal cancer. *Am J Surg Pathol* 2009; **33**: 134-141

13 **Baker K**, Zlobec I, Tornillo L, Terracciano L, Jass JR, Lugli A. Differential significance of tumour infiltrating lymphocytes in sporadic mismatch repair deficient versus proficient colorectal cancers: a potential role for dysregulation of the transforming growth factor-beta pathway. *Eur J Cancer* 2007; **43**: 624-631

14 **Ishikawa Y**, Akishima-Fukasawa Y, Ito K, Akasaka Y, Yokoo T, Ishii T. Histopathologic determinants of regional lymph node metastasis in early colorectal cancer. *Cancer* 2008; **112**: 924-933

15 **Kazama S**, Watanabe T, Ajioka Y, Kanazawa T, Nagawa H. Tumour budding at the deepest invasive margin correlates with lymph node metastasis in submucosal colorectal cancer detected by anticytokeratin antibody CAM5.2. *Br J Cancer* 2006; **94**: 293-298

16 **Park SY**, Choe G, Lee HS, Jung SY, Park JG, Kim WH. Tumor budding as an indicator of isolated tumor cells in lymph nodes from patients with node-negative colorectal cancer. *Dis Colon Rectum* 2005; **48**: 292-302

17 **Tanaka M**, Hashiguchi Y, Ueno H, Hase K, Mochizuki H. Tumor budding at the invasive margin can predict patients at high risk of recurrence after curative surgery for stage II, T3 colon cancer. *Dis Colon Rectum* 2003; **46**: 1054-1059

18 **Brabletz T**, Jung A, Spaderna S, Hlubek F, Kirchner T. Opinion: migrating cancer stem cells - an integrated concept of malignant tumour progression. *Nat Rev Cancer* 2005; **5**: 744-749

19 **Shinto E**, Baker K, Tsuda H, Mochizuki H, Ueno H, Matsubara O, Foulkes WD, Jass JR. Tumor buds show reduced expression of laminin-5 gamma 2 chain in DNA mismatch repair deficient colorectal cancer. *Dis Colon Rectum* 2006; **49**: 1193-1202

20 **Shinto E**, Mochizuki H, Ueno H, Matsubara O, Jass JR. A novel classification of tumour budding in colorectal cancer based on the presence of cytoplasmic pseudo-fragments around budding foci. *Histopathology* 2005; **47**: 25-31

21 **Schmalhofer O**, Brabletz S, Brabletz T. E-cadherin, beta-catenin, and ZEB1 in malignant progression of cancer. *Cancer Metastasis Rev* 2009; **28**: 151-166

22 **Baldus SE**, Mönig SP, Huxel S, Landsberg S, Hanisch FG, Engelmann K, Schneider PM, Thiele J, Hölscher AH, Dienes HP. MUC1 and nuclear beta-catenin are coexpressed at the invasion front of colorectal carcinomas and are both correlated with tumor prognosis. *Clin Cancer Res* 2004; **10**: 2790-2796

23 **Brabletz T**, Hlubek F, Spaderna S, Schmalhofer O, Hiendlmeyer E, Jung A, Kirchner T. Invasion and metastasis in colorectal cancer: epithelial-mesenchymal transition, mesenchymal-epithelial transition, stem cells and beta-catenin. *Cells Tissues Organs* 2005; **179**: 56-65

24 **Masaki T**, Matsuoka H, Sugiyama M, Abe N, Izumisato Y, Sakamoto A, Atomi Y. Laminin-5 gamma2 chain expression as a possible determinant of tumor aggressiveness in T1 colorectal carcinomas. *Dig Dis Sci* 2003; **48**: 272-278

25 **Masaki T**, Sugiyama M, Matsuoka H, Abe N, Izumisato Y, Sakamoto A, Atomi Y. Coexpression of matrilysin and laminin-5 gamma2 chain may contribute to tumor cell migration in colorectal carcinomas. *Dig Dis Sci* 2003; **48**: 1262-1267

26 **Portyanko A**, Kovalev P, Gorgun J, Cherstvoy E. beta(III)-tubulin at the invasive margin of colorectal cancer: possible

link to invasion. *Virchows Arch* 2009; **454**: 541-548
27 **Brabletz S**, Schmalhofer O, Brabletz T. Gastrointestinal stem cells in development and cancer. *J Pathol* 2009; **217**: 307-317
28 **Visvader JE**, Lindeman GJ. Cancer stem cells in solid tumours: accumulating evidence and unresolved questions. *Nat Rev Cancer* 2008; **8**: 755-768
29 **Zlobec I**, Lugli A, Baker K, Roth S, Minoo P, Hayashi S, Terracciano L, Jass JR. Role of APAF-1, E-cadherin and peritumoral lymphocytic infiltration in tumour budding in colorectal cancer. *J Pathol* 2007; **212**: 260-268
30 **Jass JR**, Atkin WS, Cuzick J, Bussey HJ, Morson BC, Northover JM, Todd IP. The grading of rectal cancer: historical perspectives and a multivariate analysis of 447 cases. *Histopathology* 1986; **10**: 437-459
31 **Horst D**, Kriegl L, Engel J, Kirchner T, Jung A. CD133 expression is an independent prognostic marker for low survival in colorectal cancer. *Br J Cancer* 2008; **99**: 1285-1289
32 **Horst D**, Kriegl L, Engel J, Jung A, Kirchner T. CD133 and nuclear beta-catenin: the marker combination to detect high risk cases of low stage colorectal cancer. *Eur J Cancer* 2009; **45**: 2034-2040
33 **Gosens MJ**, van Kempen LC, van de Velde CJ, van Krieken JH, Nagtegaal ID. Loss of membranous Ep-CAM in budding colorectal carcinoma cells. *Mod Pathol* 2007; **20**: 221-232
34 **Trzpis M**, McLaughlin PM, de Leij LM, Harmsen MC. Epithelial cell adhesion molecule: more than a carcinoma marker and adhesion molecule. *Am J Pathol* 2007; **171**: 386-395
35 **Masaki T**, Goto A, Sugiyama M, Matsuoka H, Abe N, Sakamoto A, Atomi Y. Possible contribution of CD44 variant 6 and nuclear beta-catenin expression to the formation of budding tumor cells in patients with T1 colorectal carcinoma. *Cancer* 2001; **92**: 2539-2546
36 **Hirata T**, Okabe M, Kobayashi A, Ueda K, Matsuo M. Molecular mechanisms of subcellular localization of ABCG5 and ABCG8. *Biosci Biotechnol Biochem* 2009; **73**: 619-626
37 **Kusuhara H**, Sugiyama Y. ATP-binding cassette, subfamily G (ABCG family). *Pflugers Arch* 2007; **453**: 735-744
38 **Schatton T**, Murphy GF, Frank NY, Yamaura K, Waaga-Gasser AM, Gasser M, Zhan Q, Jordan S, Duncan LM, Weishaupt C, Fuhlbrigge RC, Kupper TS, Sayegh MH, Frank MH. Identification of cells initiating human melanomas. *Nature* 2008; **451**: 345-349
39 **Benson AB 3rd**, Schrag D, Somerfield MR, Cohen AM, Figueredo AT, Flynn PJ, Krzyzanowska MK, Maroun J, McAllister P, Van Cutsem E, Brouwers M, Charette M, Haller DG. American Society of Clinical Oncology recommendations on adjuvant chemotherapy for stage II colon cancer. *J Clin Oncol* 2004; **22**: 3408-3419

S- Editor Wang JL **L- Editor** Cant MR **E- Editor** Ma WH

World Journal of Gastroenterology

Online Submissions: http://www.wjgnet.com/1007-9327office
wjg@wjgnet.com
doi:10.3748/wjg.v16.i6.740

World J Gastroenterol 2010 February 14; 16(6): 740-744
ISSN 1007-9327 (print)

BRIEF ARTICLE

Pericardiocentesis with cisplatin for malignant pericardial effusion and tamponade

Takatsugu Oida, Kenji Mimatsu, Hiso Kano, Atsushi Kawasaki, Youichi Kuboi, Nobutada Fukino, Sadao Amano

Takatsugu Oida, Kenji Mimatsu, Hiso Kano, Atsushi Kawasaki, Youichi Kuboi, Nobutada Fukino, Department of Surgery, Social Insurance Yokohama Central Hospital, 268 Yamashita-cho, Naka-ku, Yokohama 231-8553, Japan
Sadao Amano, Department of Surgery, Nihon University School of Medicine, 30-1 Kami-cho, Oyaguchi, Itabashi-ku, Tokyo 177-0023, Japan
Author contributions: Oida T, Mimatsu K, Kano H, Kawasaki A, Kuboi Y and Fukino N carried out the operation and were consultants overseeing the patient's care; Oida T wrote the manuscript; Amano S drafted the manuscript and revised it critically.
Correspondence to: Takatsugu Oida, MD, PhD, Department of Surgery, Social Insurance Yokohama Central Hospital, 268 Yamashita-cho, Naka-ku, Yokohama 231-8553, Japan. ooida.takatsugu@yokochu.jp
Telephone: +81-45-6411921 Fax: +81-45-6719871
Received: October 22, 2009 Revised: November 24, 2009
Accepted: December 1, 2009
Published online: February 14, 2010

Abstract

AIM: To evaluate the role and outcome of pericardiocentesis with intrapericardial cisplatin instillation for malignant pericardial effusion resulting from esophageal cancer.

METHODS: We retrospectively studied 7 patients who underwent pericardiocentesis with intrapericardial cisplatin instillation for malignant pericardial effusion resulting from esophageal cancer. After pericardiocentesis, we performed catheterization of the pericardial space under ultrasonogram guidance. Malignant etiology of the pericardial fluid was confirmed by cytological examination. Subsequently, cisplatin (10 mg in 20 mL normal saline) was instilled into the pericardial space.

RESULTS: The mean total volume of the aspirated effusion fluid was 782 ± 264 mL (range, 400-1200 mL). The drainage catheter was successfully removed in all patients, and the mean duration of pericardial drainage was 7.7 ± 2.7 d (range, 5-13 d). No fluid reaccumulation was observed. Mean survival time was 120 ± 71 d (range, 68-268 d).

CONCLUSION: Pericardiocentesis along with catheter drainage appears to be a safe and effective for pericardial malignant effusion and tamponade, and cisplatin instillation prevents recurrence.

Key words: Malignant pericardial effusion; Cardiac tamponade; Esophageal cancer; Pericardiocentesis; Cisplatin

Peer reviewers: Nadia Peparini, MD, PhD, Department of General Surgery "Francesco Durante", La Sapienza University, Viale del Policlinico, 155, 00161 Rome, Italy; Mark Bloomston, MD, FACS, Assistant Professor, Division of Surgical Oncology, The Ohio State University, N924 Doan Hall, 410W. 10th Avenue, Columbus, OH 43082, United States

Oida T, Mimatsu K, Kano H, Kawasaki A, Kuboi Y, Fukino N, Amano S. Pericardiocentesis with cisplatin for malignant pericardial effusion and tamponade. *World J Gastroenterol* 2010; 16(6): 740-744 Available from: URL: http://www.wjgnet.com/1007-9327/full/v16/i6/740.htm DOI: http://dx.doi.org/10.3748/wjg.v16.i6.740

INTRODUCTION

The most frequent causes of spontaneous pericardial tamponade are neoplastic invasion, idiopathic or infectious pericarditis, and uremia. Pericardial effusion is a known complication of many advanced malignancies, and has a strong impact on both the quality of life and prognosis. Malignant pericardial effusion and tamponade is a rare medical-surgical emergency that impairs cardiac function and causes death. To facilitate the diagnosis, it is necessary to identify the clinical features of this condition, and

design adequate management strategies. Esophagectomy with reconstruction of the esophagus is associated with many fatal complications such as infection, anastomotic leakage, and respiratory and hemodynamic instability. The clinical syndrome of pericardial tamponade after esophagectomy has been relatively well reported. Acute distension of the stomach[1], herniation of the omentum[2], mediastinal bleeding[3] and even volvulus of the interposed colon[4] have been implicated as the clinical syndromes of pericardial tamponade. Moreover, the development of cardiac tamponade due to intra-pericardial fluid accumulation after esophagectomy has also been reported[5,6].

Here, we report the outcome of intrapericardial instillation of cisplatin (CDDP) for the treatment of malignant pericardial effusion and tamponade resulting from esophageal carcinoma.

MATERIALS AND METHODS

Patients

We retrospectively studied 7 male patients who underwent pericardiocentesis with intrapericardial instillation of CDDP for the treatment of esophageal cancer at the Department of Surgery, Social Insurance Yokohama Central Hospital, Yokohama, Japan, between March 1997 and April 2009. Their mean age was 67 ± 3.4 years (range, 61-71 years). Of the 7 patients, 5 underwent subtotal esophagectomy *via* a standard right thoracoabdominal approach along with three-field lymphadenectomy and reconstruction was performed using gastric pull-up with cervical anastomosis *via* the poststernal route, and the remaining 2 patients had undergone chemoradiotherapy previously.

Diagnosis and definition of severity of pericardial effusion and tamponade

Echocardiography was used for the diagnosis of pericardial effusion and tamponade. When the diastolic echo-free space between the left ventricular posterior wall and the pericardium was < 10 mm, the condition was classified as mild; when the space was 10-20 mm, the condition was classified as moderate; and when the space was > 20 mm, the condition was classified as severe pericardial effusion[7]. Cardiac tamponade was defined according to the clinical and echocardiographic criteria[8]. The presence of the classic tamponade symptoms such as tachycardia, dyspnea, or tachypnea with clear lungs, or signs of increased systemic venous pressure, hypotension, or pulsus paradoxus, or accompanied by echocardiographic findings was accepted as cardiac tamponade[7]. We performed pericardiocentesis on the patients with cardiac tamponade and moderate to severe pericardial effusion.

Percutaneous pericardiocentesis and cytology

Echocardiography with fluoroscopy-guided subxiphoid pericardiocentesis using an 8-French pigtail drainage catheter with multiple side holes (Aspiration Seldinger Kit/Nippon Sherwood Medical Industries LTD) was performed under local anesthesia with mild sedation. After the catheter was placed into the pericardial space, we aspirated the fluid. Cytological examination was performed using the aspirate culture.

Instillation of CDDP

After the cytological examination-based confirmation of the malignant etiology of the pericardial fluid and the complete drainage of the fluid, we administered 10 mg of CDDP into the pericardial space during each pericardiocentesis *via* the catheter; subsequently, the catheter was clamped. The catheter was declamped the following day, and the fluid was re-aspirated. When the volume of the re-aspirated fluid was more than 30 mL, 10 mg CDDP was re-administered. When the volume of the re-aspirated fluid was less than 30 mL, the catheter was removed.

RESULTS

Echocardiography with fluoroscopy-guided pericardiocentesis using extended catheter drainage was performed in 7 patients with malignant cardiac tamponade resulting from esophageal cancer. Table 1 shows the patients' characteristics. Staging of esophageal cancer was performed according to guidelines of the International Union Against Cancer Classification of Malignant Tumors (UICC), and the distribution of the various stages among the patients was as follows: ⅡB, 1/7 (14.3%); Ⅲ, 3/7 (42.8%); and ⅣA, 3/7 (42.8%). The following clinical symptoms were observed in the patients; dyspnea was observed in all the patients (100%), and tachycardia was observed in 5 patients (71.4%).

Table 2 lists the outcomes of the patients who underwent pericardiocentesis with CDDP instillation. Total volume of the aspirated effusion fluid ranged from 400 to 1200 mL (median, 782 ± 264 mL). Pericardiocentesis with CDDP instillation was required twice in 2 patients (28.6%), 3 times in 4 patients (57.1%), and 5 times was in 1 patient (14.3%), (median, 3 times). The drainage catheter was successfully removed in all the patients. The duration of pericardial drainage ranged from 5 to 13 d (median, 7.7 ± 2.7 d). None of the patients showed fluid accumulation. Nausea, as a side effect of pericardiocentesis with CDDP instillation, was observed in 2 patients (28.6%); however, hematologic and renal toxicity did not develop in any of the patients. After pericardiocentesis with CDDP instillation, we performed systemic chemotherapy [5-fluorouracil (5-FU) + CDDP] in 3 patients (43%). The overall median survival time for these 7 patients was 120 ± 71 d (range, 68-268 d) (Table 3).

DISCUSSION

Cardiac tamponade can occur in any type of pericarditis case, but it is more commonly observed in neoplastic, tuberculous, and purulent pericarditis cases than in viral or idiopathic pericarditis cases. Pericardial effusion is a known complication of many advanced malignancies,

Table 1 Characteristics of the patients

Patient No.	Age	Sex	Stage of esophageal cancer	Former treatment	Symptoms
1	68	M	T2, N1, M0: Stage ⅡB	Esophagectomy + chemotherapy	Dyspnea, tachycardia
2	69	M	T3, N1, M0: Stage Ⅲ	Esophagectomy + chemotherapy	Dyspnea, tachycardia
3	64	M	T2, N1, M0: Stage Ⅲ	Esophagectomy + chemotherapy	Dyspnea
4	70	M	T3, N1, M1a: Stage ⅣA	Esophagectomy + chemotherapy	Dyspnea, tachycardia
5	71	M	T2, N1, M1a: Stage ⅣA	Chemoradiotherapy	Dyspnea, tachycardia
6	65	M	T2, N1, M0: Stage ⅡB	Esophagectomy + chemotherapy	Dyspnea, tachycardia
7	62	M	T2, N1, M1a: Stage ⅣA	Chemoradiotherapy	Dyspnea

Table 2 Outcomes of intrapericardial instillation of cisplatin

Patient No.	Amount of fluid (mL)	CDDP instillation (mg) × times	Duration of drainage (d)	Side effect	Reaccumulation of fluid
1	580	10 × 2	5	-	-
2	400	10 × 2	5	-	-
3	760	10 × 3	8	-	-
4	980	10 × 3	8	Nausea	-
5	1200	10 × 5	13	Nausea	-
6	685	10 × 3	8	-	-
7	870	10 × 3	8	-	-

CDDP: Cisplatin.

Table 3 Outcomes of the patients

Patient No.	Additional therapy (systemic)	Survival (d)	Cause of death
1	5-Fu + CDDP	126	Lung and pleural metastases
2	5-Fu + CDDP	268	Pleural metastases
3	5-Fu + CDDP	137	Lung and bone metastases
4	-	68	Lung and pleural metastases
5	-	61	Lung and bone metastases
6	-	104	Lung and pleural metastases
7	-	77	Pleural metastases

5-Fu: 5-fluorouracil.

and it has a strong impact on both the quality of life and prognosis. To facilitate the diagnosis of patients with malignant disease, it is necessary to identify the clinical features of cardiac tamponade and design adequate management strategies. Cardiac tamponade, observed in up to 15% of patients with cancer, can develop because of the malignant involvement of the pericardium under metastatic disease conditions, contiguous extension, or primary involvement[9]. Pericardial effusion in patients with esophageal carcinoma is most commonly associated with radiation and/or chemotherapy, and rarely with esophago-pericardial fistula[10]. All our 7 patients had advanced esophageal cancer; of them, 5 patients underwent esophagectomy and chemotherapy and the remaining 2 had undergone chemoradiotherapy previously.

The following are the typical signs of acute cardiac tamponade; a decrease in the arterial blood pressure, increase in the central venous pressure, and a small, quiet heart. The diagnosis of pericardial effusion and cardiac tamponade was confirmed using echocardiography and according to the clinical and echocardiographic criteria[8]. Because all our patients showed symptoms of dyspnea with or without tachycardia, it was necessary to confirm the diagnosis using echocardiography.

Accumulation of fluid in the pericardial space in patients is often not evident until the development of cardiac tamponade. Pericardiocentesis is generally performed as an initial treatment for symptomatic pericardia effusion and cardiac tamponade; however, re-accumulation of the fluid after pericardiocentesis is often observed. Hence, alternative procedures to pericardiocentesis, including insertion of a pleuropericardial window[11], total or partial pericardiectomy[12], external radiotherapy[13], local instillation of a chemotherapeutic agent[14], local instillation of a sclerosing agents[15], and systemic chemotherapy[16], are often performed. A review article that summarized the results of previous studies showed that the overall success rate of pericardiocentesis was 44.4%; indwelling pericardial catheters, 76.3%; and intrapericardial administration of sclerosing or cytotoxic agents, 81.6%, and that intra-pericardial instillation was an effective treatment strategy for malignant pericardial effusion[17].

The most serious complications of pericardiocentesis are laceration and perforation of the myocardium and the coronary vessels. Safe execution of pericardiocentesis was achieved by performing echocardiography under fluoroscopic guidance. Recent large echocardiographic series have shown that the incidence of major compli-

cations after echocardiography was 1.3%-1.6%. In fluoroscopy-guided percutaneous pericardiocentesis, cardiac perforations occurred in 0.9% cases, serious arrhythmias in 0.6%, arterial bleeding in 1.1%, pneumothorax in 0.6%, infection in 0.3%, and a major vagal reaction in 0.3%[8,18]. In our study, pericardiocentesis was performed echocardiographically under fluoroscopy guidance, and no complications developed. We believe that echocardiography with fluoroscopy-guided pericardiocentesis appears to be a safer alternative for pericardiocentesis.

The most appropriate type of pericardial drainage is subject to debate. In principle, less aggressive procedures are preferred, but at the same time, the procedures must be able to prevent recurrence of effusion accumulation. Simple needle pericardiocentesis can often resolve tamponade initially, but the probability of relapse is very high.

Recurrence, which is observed in 40%-70% of patients with large malignant pericardial effusion, may be prevented by intrapericardial instillation of sclerotic or cytotoxic agents, immunomodulators, systemic antitumor treatment, radiation therapy, percutaneous balloon pericardiotomy, or surgical methods[19,20]. Surgical drainage (or pericardiectomy, its major equivalent) is excessively required for many patients. The best option is to perform pericardiocentesis using the Seldinger technique, i.e. inserting a pigtail drainage catheter that can be retained in the pericardium until the drainage is complete[17]. If effusion recurs after the removal of the pigtail catheter, a sclerosing agent (tetracycline or bleomycin) can be instilled into the pericardial sac, or subxiphoid balloon pericardiotomy can be performed[17].

With regard to the cytotoxic agents that can be used for intrapericardial instillation, Maisch *et al*[20] studied the effectiveness of tetracycline, 5-FU, and CDDP in 20 patients with recurrent malignant pericardial effusion, and observed favorable outcomes (no fluid re-accumulation) only after CDDP instillation.

With regard to the side effects and complications of CDDP instillation, Maisch *et al*[19] reported that myocardial ischemia occurred in 1 of 42 patients studied, and there were no other complications. Fiorentino *et al*[21] reported that mild nausea occurred in all patients, but hematologic and renal toxicity and local or infectious complications did not occur in any patients in their study. In our study, 2 patients (28.6%) developed nausea. However, no significant side-effects were observed in the study of Tondini *et al*[22] CDDP instillation did not cause hypotension and retrosternal pain, as is observed after the instillation of some other agents[19]; hence, it is thought to be a reasonable cytotoxic agent for intrapericardial administration. After the intrapericardial instillation of CDDP, 3 of the 7 patients in our study underwent systemic chemotherapy (5-FU + CDDP). The overall mean survival time after intrapericardial instillation of CDDP was reported to be 2.8 ± 1.3 mo by Maisch *et al*[19] and it was 120 ± 71 d (range, 68-268 d) in our study. Maisch *et al*[19] performed intrapericardial instillation of CDDP for patients with neoplastic pericardial effusion without esophageal cancer, but our patients had esophageal cancer. Moreover, the overall mean survival time in our study was longer than that of the study by Maisch *et al*[19].

We conclude that pericardiocentesis with intrapericardial instillation of CDDP is effective for the treatment of malignant pericardial effusion resulting from esophageal cancer. In our study, the number of patients with pericardial constriction was very small for conducting statistical evaluation, but it is thought that pericardiocentesis with intrapericardial instillation of CDDP is a safe and feasible treatment in cases of medical-surgical emergency. Moreover, additional systemic chemotherapy after pericardiocentesis with intrapericardial instillation of CDDP may prolong the survival time of patient.

COMMENTS

Background

Pericardial effusion in patients with esophageal carcinoma is most commonly associated with radiation and/or chemotherapy, and rarely with esophago-pericardial fistula. Here, the authors report the outcome of intrapericardial instillation of cisplatin (CDDP) for the treatment of malignant pericardial effusion and tamponade resulting from esophageal carcinoma.

Research frontiers

After the intrapericardial instillation of CDDP, 3 of the 7 patients in this study underwent systemic chemotherapy (5-fluorouracil + CDDP). The overall mean survival time after intrapericardial instillation of CDDP was 120 ± 71 d (range, 68-268 d) in this study. And the overall mean survival time in this study was longer.

Innovations and breakthroughs

The authors conclude that pericardiocentesis with intrapericardial instillation of CDDP is effective for the treatment of malignant pericardial effusion resulting from esophageal cancer.

Applications

In this study, the number of patients with pericardial constriction was too small to conduct statistical evaluation, but it is thought that pericardiocentesis with intrapericardial instillation of CDDP is a safe and feasible treatment in cases of medical-surgical emergency. Moreover, additional systemic chemotherapy after pericardiocentesis with intrapericardial instillation of CDDP may prolong the survival time of patient.

Peer review

This is a well written manuscript describing a series of well organized experiments. It is about malignant pericardial effusion and tamponade resulting from esophageal carcinoma. Not many cases of this disease have been reported and this is an original case series.

REFERENCES

1 **Cherian V**, Divatia JV, Kulkarni A, Dasgupta D. Cardiomediastinal tamponade and shock following three-stage transthoracic oesophagectomy. *J Postgrad Med* 2001; **47**: 185-187

2 **Granke K**, Hoshal VL Jr, Vanden Belt RJ. Extrapericardial tamponade with herniated omentum after transhiatal esophagectomy. *J Surg Oncol* 1990; **44**: 273-275

3 **Thangathurai D**, Roffey P, Mogos M, Riad M, Bohorguez A. Mediastinal haemorrhage mimicking tamponade during en-bloc oesophagectomy. *Eur J Anaesthesiol* 2005; **22**: 555-556

4 **Canivet JL**, Piret S, Hick G, Damas P. Cardiac tamponade and pulmonary compression due to volvulus of oesophageal coloplasty. *Acta Anaesthesiol Belg* 2004; **55**: 125-127

5 **Mizuguchi Y**, Takeda S, Miyashita M, Ikezaki H, Nakajima Y, Akada S, Makino H, Futami R, Arai M, Sasajima K, Tajiri T, Tanaka K. A case of cardiac tamponade following esophageal resection. *J Anesth* 2005; **19**: 249-251

6 **Kats S**, Nieuwenhuijzen GA, van Straten BH, Schönberger JP. Cardiac tamponade: an unusual, lifethreatening complication after transhiatal resection of the esophagus.

Interact Cardiovasc Thorac Surg 2007; **6**: 238-239
7 **Becit N**, Unlü Y, Ceviz M, Koçogullari CU, Koçak H, Gürlertop Y. Subxiphoid pericardiostomy in the management of pericardial effusions: case series analysis of 368 patients. *Heart* 2005; **91**: 785-790
8 **Maisch B**, Seferović PM, Ristić AD, Erbel R, Rienmüller R, Adler Y, Tomkowski WZ, Thiene G, Yacoub MH. Guidelines on the diagnosis and management of pericardial diseases executive summary; The Task force on the diagnosis and management of pericardial diseases of the European society of cardiology. *Eur Heart J* 2004; **25**: 587-610
9 **Spodick DH**. Pericardial disease. In: Braunwald E, Zipes DP, Libby P, editors. Heart disease: A textbook of cardiovascular medicine. Philadelphia, PA: WB Saunders, 2001: 1823-1876
10 **Renshaw AA**, Nappi D, Sugarbaker DJ, Swanson S. Effusion cytology of esophageal carcinoma. *Cancer* 1997; **81**: 365-372
11 **Hill GJ 2nd**, Cohen BI. Pleural pericardial window for palliation of cardiac tamponade due to cancer. *Cancer* 1970; **26**: 81-93
12 **Piehler JM**, Pluth JR, Schaff HV, Danielson GK, Orszulak TA, Puga FJ. Surgical management of effusive pericardial disease. Influence of extent of pericardial resection on clinical course. *J Thorac Cardiovasc Surg* 1985; **90**: 506-516
13 **Cham WC**, Freiman AH, Carstens PH, Chu FC. Radiation therapy of cardiac and pericardial metastases. *Radiology* 1975; **114**: 701-704
14 **Maher ER**, Buckman R. Intrapericardial installation of bleomycin in malignant pericardial effusion. *Am Heart J* 1986; **111**: 613-614
15 **Davis S**, Sharma SM, Blumberg ED, Kim CS. Intrapericardial tetracycline for the management of cardiac tamponade secondary to malignant pericardial effusion. *N Engl J Med* 1978; **299**: 1113-1114
16 **Reynolds PM**, Byrne MJ. The treatment of malignant pericardial effusion in carcinoma of the breast. *Aust N Z J Med* 1977; **7**: 169-171
17 **Vaitkus PT**, Herrmann HC, LeWinter MM. Treatment of malignant pericardial effusion. *JAMA* 1994; **272**: 59-64
18 **Maisch B**, Ristić AD. Practical aspects of the management of pericardial disease. *Heart* 2003; **89**: 1096-1103
19 **Maisch B**, Ristić AD, Pankuweit S, Neubauer A, Moll R. Neoplastic pericardial effusion. Efficacy and safety of intrapericardial treatment with cisplatin. *Eur Heart J* 2002; **23**: 1625-1631
20 **Maisch B**, Ristić AD, Pankuweit S. Intrapericardial treatment of autoreactive pericardial effusion with triamcinolone; the way to avoid side effects of systemic corticosteroid therapy. *Eur Heart J* 2002; **23**: 1503-1508
21 **Fiorentino MV**, Daniele O, Morandi P, Aversa SM, Ghiotto C, Paccagnella A, Fornasiero A. Intrapericardial instillation of platin in malignant pericardial effusion. *Cancer* 1988; **62**: 1904-1906
22 **Tondini M**, Rocco G, Bianchi C, Severi C, Corbellini D. Intracavitary cisplatin (CDDP) in the treatment of metastatic pericardial involvement from breast and lung cancer. *Monaldi Arch Chest Dis* 1995; **50**: 86-88

S- Editor Wang JL **L- Editor** O'Neill M **E- Editor** Lin YP

World Journal of Gastroenterology

Online Submissions: http://www.wjgnet.com/1007-9327office
wjg@wjgnet.com
doi:10.3748/wjg.v16.i6.745

World J Gastroenterol 2010 February 14; 16(6): 745-748
ISSN 1007-9327 (print)

BRIEF ARTICLE

Surgery for gastrointestinal malignant melanoma: Experience from surgical training center

Thawatchai Akaraviputh, Satida Arunakul, Varut Lohsiriwat, Cherdsak Iramaneerat, Atthaphorn Trakarnsanga

Thawatchai Akaraviputh, Satida Arunakul, Varut Lohsiriwat, Cherdsak Iramaneerat, Atthaphorn Trakarnsanga, Division of General Surgery, Department of Surgery, Faculty of Medicine Siriraj Hospital, Mahidol University, Bangkok 10700, Thailand

Author contributions: Akaraviputh T originated the idea and drafted the manuscript; Arunakul S collected the data and conducted statistical analyses; Lohsiriwat V wrote part of the manuscript; Iramaneerat C critically reviewed and edited the manuscript; Trakarnsanga A gave comment and wrote part of the manuscript.

Correspondence to: Dr. Thawatchai Akaraviputh, MD, Endo-Laparoscopic Surgery Unit, Division of General Surgery, Department of Surgery, Faculty of Medicine Siriraj Hospital, Mahidol University, Bangkok 10700, Thailand. sitak@mahidol.ac.th

Telephone: +66-2-4198005-6 Fax: +66-2-4121370

Received: August 24, 2009 Revised: November 30, 2009
Accepted: December 7, 2009
Published online: February 14, 2010

Abstract

AIM: To characterize clinical features, surgery, outcome, and survival of malignant melanoma (MM) of the gastrointestinal (GI) tract in a surgical training center in Bangkok, Thailand.

METHODS: A retrospective review was performed for all patients with MM of the GI tract treated at our institution between 1997 and 2007.

RESULTS: Fourteen patients had GI involvement either in a metastatic form or as a primary melanoma. Thirteen patients with sufficient data were reviewed. The median age of the patients was 66 years (range: 32-87 years). Ten patients were female and three were male. Seven patients had primary melanomas of the anal canal, stomach and the sigmoid colon (5, 1 and 1 cases, respectively). Seven patients underwent curative resections: three abdominoperineal resections, two wide local excisions, one total gastrectomy and one sigmoidectomy. Six patients had distant metastatic lesions at the time of diagnosis, which made curative resection an inappropriate choice. Patients who underwent curative resection exhibited a longer mean survival time (29.7 mo, range: 10-96 mo) than did patients in the palliative group (4.8 mo, P = 0.0006).

CONCLUSION: GI MM had an unfavorable prognosis, except in patients who underwent curative resection (53.8% of cases), who had a mean survival of 29.7 mo.

Key words: Melanoma; Gastrointestinal tract; Neoplasm metastasis

Peer reviewers: Nadia Peparini, MD, PhD, Department of General Surgery "Francesco Durante", La Sapienza University, Viale del Policlinico, 155, Rome, 00161, Italy; Dr. Oliver Mann, MD, Senior Attending Physician and Deputy Director, Department of General, Visceral and Thoracic Surgery, University of Hamburg, Martini Str. 52, D-20246 Hamburg, Germany; Dr. Yuk Him Tam, Department of Surgery, Prince of Wales Hospital, Shatin, Hong Kong, China

Akaraviputh T, Arunakul S, Lohsiriwat V, Iramaneerat C, Trakarnsanga A. Surgery for gastrointestinal malignant melanoma: Experience from surgical training center. *World J Gastroenterol* 2010; 16(6): 745-748 Available from: URL: http://www.wjgnet.com/1007-9327/full/v16/i6/745.htm DOI: http://dx.doi.org/10.3748/wjg.v16.i6.745

INTRODUCTION

Malignant melanoma (MM) of the gastrointestinal (GI) tract is a rare condition, especially in Eastern countries. However, its incidence is rising with unclear reason[1]. It may be either primary or metastatic. GI metastasis of MM is frequently found during autopsy (50%-60% of cases), but a small proportion of melanoma patients are

diagnosed with GI metastasis while living (2%-5% of patients)[2,3]. The most common sites of the metastasis are the stomach and small intestine. Meanwhile, primary MM can arise in any GI mucosal site, but is most common in the anorectal region and esophagus.

The prognosis of GI MM is very poor with a 5-year survival of < 10%[4]. Surgery is still the mainstay of treatment. Recent studies have reported a trend toward less radical resection because there is no significant advantage of aggressive surgery over limited surgery in terms of local disease control, recurrence, and survival time[4,5].

In Thailand, MM is less common than in western countries and the data are limited. This study, therefore, was conducted to evaluate clinical features, surgical options, and outcome including recurrence and survival of MM of the GI tract in a surgical training center in Bangkok, Thailand.

MATERIALS AND METHODS

A retrospective review was conducted on patients diagnosed with MM of the GI tract who were admitted to Siriraj Hospital between 1997 and 2007. Patients were identified from the hospital computer database using an ICD-10 system. Patients' charts were reviewed retrospectively for patient characteristics, presenting symptoms, physical examination findings, imaging results, operative records, presence of complications, recurrence, follow-up time, survival time, and cause of death. Diagnosis was confirmed in all patients by histological study and immunochemistry for S-100 protein or HMB45 monoclonal antibody. Survival time was defined as the number of months from the time of diagnosis of GI MM to the time of death or the last follow-up evaluation. The long-term follow-up data were collected by direct contact with patients or their relatives. A Kaplan-Meier method was used for statistical analysis of survival outcome. This study was approved by Siriraj ethics committee, Mahidol University (EC1 2550/307).

RESULTS

Between 1997 and 2007, there were 14 patients diagnosed with MM of the GI tract in Siriraj Hospital. One patient was excluded from this study due to insufficient data in the medical records; thus, only 13 cases were included in this study. Ten patients were female and three were male. The median age of the patients at presentation was 66 years (range: 32-87 years). Seven patients had a primary GI MM (anorectal, $n = 5$; sigmoid colon, $n = 1$; and stomach, $n = 1$), whereas the others (three patients, 23.1%) had metastatic MM of the GI tract. The primary melanoma sites of these three patients were ocular, thumb, and ovary. There were three patients who had advanced GI MM of unknown primary origin.

The most common presenting symptom was abdominal pain (5 patients, 38.5%), followed by intra-abdominal mass in four patients (30.8%). Other presenting symptoms included obstructive jaundice, small bowel obstruction, bowel habit change, and tenesmus. The anorectal region was the most common site of GI MM (7 patients, 53.8%), followed by the stomach (3 patients, 23.1%) (Table 1).

Table 1 Characteristic of patients with MM of the GI tract

	Curative group	Palliative group	All
n	7	6	13
Median age (range) (yr)	66 (32-87)	57 (42-78)	66 (32-87)
Gender (M/F)	2/5	1/5	3/10
Presenting symptoms *n* (%)			
Abdominal pain	1	4	5 (38.5)
Intra-abdominal mass	4	0	4 (30.8)
Obstructive jaundice	0	1	2 (15.4)
Small bowel obstruction	0	1	1 (7.7)
Bowel habit change	1	0	1 (7.7)
Tenesmus	1	0	1 (7.7)
Investigation *n* (%)			
Abdominal CT	5	3	8 (61.5)
Endoscopy	1	1	2 (15.1)
Upper GI study	0	1	1 (7.7)
Barium enema	1	0	1 (7.7)
Origin of GI MM *n* (%)			
Primary	7	0	7 (53.8)
Secondary	0	3	3 (23.1)
Unknown primary	0	3	3 (23.1)
Site of the tumor *n* (%)			
Anorectal	5	2	7 (53.8)
Stomach	1	2	3 (23.1)
Jejunum	0	1	1 (7.7)
Pancreas	0	1	1 (7.7)
Sigmoid colon	1	0	1 (7.7)
Survival times (mo)			
Mean	29.7	4.8	17
Range	10-96	4-12	4-96

MM: Malignant melanoma; GI: Gastrointestinal; CT: Computed tomography.

Seven patients (53.8%) underwent curative resection, which consisted of three abdominoperineal resections, two wide local excisions, one total gastrectomy, and one sigmoidectomy. There was no perioperative mortality in this study. Meanwhile, another six patients (46.2%) had distant metastatic lesions at the time of diagnosis. They therefore received only palliative surgical treatment such as colostomy, small bowel resection, and enteroenterostomy anastomosis. Patients who underwent curative resection exhibited a longer mean survival time (29.7 mo, range: 10-96 mo) than patients in the palliative group (4.8 mo, range: 4-12 mo) (Figure 1). Survival was significantly increased in patients who underwent curative resection ($P = 0.0006$).

DISCUSSION

In Thailand, MM is a rare disease. The estimated incidence rate of cutaneous melanoma in Thailand is 0.4 and 0.1 per 100 000 in men and women, respectively[5]. Incidence of MM of the GI tract is exceedingly rare[6]. There have

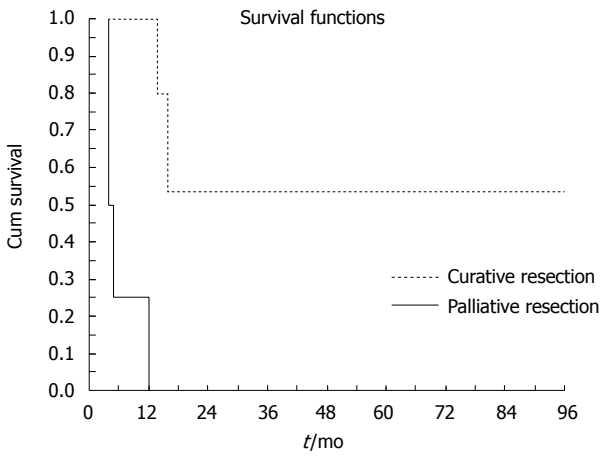

Figure 1 Kaplan-Meier curve demonstrating survival of patients with malignant melanoma of the gastrointestinal tract, who underwent curative resection and palliative resection.

been only a few reported cases of documented anorectal MM in Thailand[7]. MM of the GI tract can be either primary or metastatic. Primary GI melanoma must be differentiated from metastatic disease by previous history of melanoma and complete physical examination.

Patients often present with bleeding, pain or intestinal obstruction. If the patients present with GI bleeding, an endoscopy with magnification might be the procedure of choice to diagnose MM of the GI tract[8-10]. Multiple black, depressed lesions (1 ± 5 mm in diameter) with a "bull's eye" appearance are usually viewed in the GI mucosa[9]. In the present study, approximately half of the patients presented with pain. A lower number of patients presented with gross GI bleeding and obstruction.

MM of the GI tract remains a fatal disease. Patients often present with advanced disease. In our study, almost half of the patients had metastatic disease at the time of presentation. The prognosis of GI MM is poor. The mean survival time of patients with a local or locoregional disease who underwent curative resection was only 29.7 mo. Several investigators have reported that the overall survival varies from 12 to 18 mo, with a 5-year survival of < 10%[11]. When systemic metastasis has occurred, mean survival is only 6-8 mo[12,13].

As a result of the poor prognosis of this disease, operative intervention has been discouraged. However, several recent studies have demonstrated better survival outcome in the patients who had complete surgical resection[14-19]. Our experiences compare favorably with those of other centers. Our study demonstrated seven patients with GI MM who underwent curative resection with a mean survival comparable to that in other centers. Several adjuvant treatment of GI MM such as chemotherapy, radiotherapy and immunotherapy have been utilized in many countries, but no such treatment was given in our center because of their unclear effectiveness. One recent randomized trial has demonstrated no survival benefit of adjuvant therapy[20].

In conclusion, patients with GI MM had a poor prognosis, especially in nonoperable cases. Surgical resection of the tumor resulted in a longer survival time. In selected patients with local or locally advanced disease, surgery should be performed where possible.

COMMENTS

Background

Gastrointestinal (GI) malignant melanoma (MM) is a rare malignancy. As a result of the paucity of cases, the available data about its clinical features, treatment options, and outcomes are very limited, especially in Eastern countries.

Research frontiers

As a result of the poor prognosis of GI MM, improvement of its treatment options is an area that is in need of research. However, in order to reach that point, some basic understanding of the clinical characteristics and treatment outcomes of current surgical approaches is required. This study provides a picture of clinical experience with this rare disease from one surgical training center in Thailand.

Innovations and breakthroughs

This study revealed that the nature of MM of the GI tract and its treatment outcomes in Thailand were similar and comparable to those from other centers.

Applications

With a better understanding of GI MM and its poor prognosis, future research should look at how to improve the treatment outcome, through early diagnosis, selection of patients undergoing surgery, and improvement of surgical techniques.

Peer review

This is a retrospective study on surgical management of MM of the GI tract. Patients who underwent curative resection exhibited a longer mean survival time than patients in the palliative group. Survival was significantly increased in patients who underwent curative resection.

REFERENCES

1 **Klaase JM**, Kroon BB. Surgery for melanoma metastatic to the gastrointestinal tract. *Br J Surg* 1990; **77**: 60-61
2 **Dasgupta T**, Brasfield R. Metastatic melanoma. A clinicopathological study. *Cancer* 1964; **17**: 1323-1339
3 **Cagir B**, Whiteford MH, Topham A, Rakinic J, Fry RD. Changing epidemiology of anorectal melanoma. *Dis Colon Rectum* 1999; **42**: 1203-1208
4 **Bullard KM**, Tuttle TM, Rothenberger DA, Madoff RD, Baxter NN, Finne CO, Spencer MP. Surgical therapy for anorectal melanoma. *J Am Coll Surg* 2003; **196**: 206-211
5 **Promtatvethi V**, Gojaseni P, Buri P, Censarn N. Malignant melanoma: a clinical experience in a Thai hospital. *J Med Assoc Thai* 1978; **61**: 210-216
6 **Crombie IK**. Racial differences in melanoma incidence. *Br J Cancer* 1979; **40**: 185-193
7 **Somran J**, Kanngurn S, Porncharoenpong S, Lertkajornsin O. Anorectal malignant melanoma: report of two cases from Buddhachinnaraj Hospital. *J Med Assoc Thai* 2005; **88**: 1128-1133
8 **Pommer B**, Probst A, Messmann H. Gastric metastases from malignant melanoma. *Endoscopy* 2008; **40** Suppl 2: E30-E31
9 **Tanaka K**, Toyoda H, Hamada Y, Aoki M, Kosaka R, Noda T, Katsurahara M, Nakamura M, Ninomiya K, Inoue H, Imoto I. Duodenal metastasis of malignant melanoma observed by magnification endoscopy. *Endoscopy* 2008; **40** Suppl 2: E6-E7
10 **Galloro G**, Inzirillo A, Magno L, Diamantis G, Inzirillo M, Pastore A, Ruggiero S, Mosella G. Multiple nodular lesions by colonic metastatic malignant melanoma. *Dig Liver Dis* 2009; **41**: 169
11 **Yang JI**, Byun HJ, Kang JM. Education and imaging. Gastrointestinal: anorectal malignant melanoma. *J Gastroenterol Hepatol* 2009; **24**: 697
12 **Liang KV**, Sanderson SO, Nowakowski GS, Arora AS.

Metastatic malignant melanoma of the gastrointestinal tract. *Mayo Clin Proc* 2006; **81**: 511-516
13 **Lens M**, Bataille V, Krivokapic Z. Melanoma of the small intestine. *Lancet Oncol* 2009; **10**: 516-521
14 **Berger AC**, Buell JF, Venzon D, Baker AR, Libutti SK. Management of symptomatic malignant melanoma of the gastrointestinal tract. *Ann Surg Oncol* 1999; **6**: 155-160
15 **Agrawal S**, Yao TJ, Coit DG. Surgery for melanoma metastatic to the gastrointestinal tract. *Ann Surg Oncol* 1999; **6**: 336-344
16 **Ishizone S**, Koide N, Karasawa F, Akita N, Muranaka F, Uhara H, Miyagawa S. Surgical treatment for anorectal malignant melanoma: report of five cases and review of 79 Japanese cases. *Int J Colorectal Dis* 2008; **23**: 1257-1262
17 **Sanki A**, Scolyer RA, Thompson JF. Surgery for melanoma metastases of the gastrointestinal tract: indications and results. *Eur J Surg Oncol* 2009; **35**: 313-319
18 **Huang YJ**, Wu MH, Lin MT. Multiple small-bowel intussusceptions caused by metastatic malignant melanoma. *Am J Surg* 2008; **196**: e1-e2
19 **Slaby J**, Suri U. Metastatic melanoma with multiple small bowel intussusceptions. *Clin Nucl Med* 2009; **34**: 483-485
20 **Spitler LE**, Grossbard ML, Ernstoff MS, Silver G, Jacobs M, Hayes FA, Soong SJ. Adjuvant therapy of stage III and IV malignant melanoma using granulocyte-macrophage colony-stimulating factor. *J Clin Oncol* 2000; **18**: 1614-1621

S- Editor Tian L **L- Editor** Kerr C **E- Editor** Ma WH

World Journal of Gastroenterology

Online Submissions: http://www.wjgnet.com/1007-9327office
wjg@wjgnet.com
doi:10.3748/wjg.v16.i6.749

World J Gastroenterol 2010 February 14; 16(6): 749-754
ISSN 1007-9327 (print)

BRIEF ARTICLE

Effects of *in vitro* cultivated *Calculus Bovis* compound on pulmonary lesions in rabbits with schistosomiasis

Tao Li, Zhen Yang, Hong-Jiao Cai, Li-Wei Song, Ke-Yu Lu, Zheng Zhou, Zai-De Wu

Tao Li, Li-Wei Song, Ke-Yu Lu, Zheng Zhou, Department of General Surgery and Oncology, China Mei Tan General Hospital, Beijing 100028, China
Zhen Yang, Hong-Jiao Cai, Zai-De Wu, Department of General Surgery, Tongji Hospital, Tongji Medical College, Huazhong University of Science and Technology, Wuhan 430030, Hubei Province, China
Author contributions: Li T designed and performed the research and wrote the paper; Yang Z, Cai HJ and Wu ZD performed the clinical and pathological studies and data acquisition; Song LW, Lu KY and Zhou Z analyzed the data.
Supported by National Natural Science Foundation of China, No. A30170920
Correspondence to: Tao Li, MD, Department of General Surgery and Oncology, China Mei Tan General Hospital, Beijing 100028, China. litaoforgood2009@tom.com
Telephone: +86-10-88680627 Fax: +86-10-62560298
Received: September 29, 2009 Revised: December 16, 2009
Accepted: December 23, 2009
Published online: February 14, 2010

Abstract

AIM: To explore the interventional effects and mechanism of *in vitro* cultivated *Calculus Bovis* compound preparation (ICCBco) on pulmonary lesions in portal hypertensive rabbits with schistosomiasis.

METHODS: The experimental group included 20 portal hypertensive rabbits with schistosomiasis treated by ICCBco. The control group included 20 portal hypertensive rabbits with schistosomiasis treated by praziquantel. The morphological changes of the pulmonary tissues were observed under light and electron microscopy. The expression of fibronectin (FN) and laminin (LN) in the lung tissues was analyzed by immunohistochemistry.

RESULTS: Under light microscope, the alveolar exudation in the lung tissue was more frequently observed in the control group, while the alveolar space was fairly dry in the lung tissue of ICCBco group. Under electron microscope, more alveolar exudation in the lung tissue, and more macrophages, alveolar angiotelectasis and the blurred three-tier structure of alveolar-capillary barrier could be seen in the control group. In ICCBco group, fibers within the alveolar interspace slightly increased in some lung regions, and the structure of type Ⅰ epithelium, basement membrane and endodermis was complete, and no obvious exudation from the alveolar space, and novascular congestion could be observed. There was a positive or strong positive expression of FN and LN in the lung tissue of the control group, while there was a negative or weak positive expression of FN and LN in ICCBco group.

CONCLUSION: ICCBco can effectively prevent pulmonary complications in portal hypertensive rabbits with schistosomiasis by means of improving lung microcirculation and lowering the content of extracellular matrix.

Key words: *In vitro* cultivated *Calculus Bovis* compound preparation; Schistosomiasis; Portal hypertension; Lung lesion; Fibronectin; Laminin; Pulmonary microcirculation

Peer reviewer: Heitor Rosa, Professor, Department of Gastroenterology and Hepatology, Federal University School of Medicine, Rua 126 n.21, Goiania - GO 74093-080, Brazil

Li T, Yang Z, Cai HJ, Song LW, Lu KY, Zhou Z, Wu ZD. Effects of *in vitro* cultivated *Calculus Bovis* compound on pulmonary lesions in rabbits with schistosomiasis. *World J Gastroenterol* 2010; 16(6): 749-754 Available from: URL: http://www.wjgnet.com/1007-9327/full/v16/i6/749.htm DOI: http://dx.doi.org/10.3748/wjg.v16.i6.749

INTRODUCTION

Portal hypertension is a vascular lesion that initially arises in liver, but is also accompanied with structural and functional changes of blood vessels in extrahepatic portal

system, systemic circulation and pulmonary circulation, which now collectively called portal hypertensive vascular lesions[1]. In clinical practice, much attention has been paid to the prevention and treatment of complications such as ascites, esophagogastric variceal bleeding; however the management of pulmonary complications is ignored which affects the prognosis of patients. Hence, drugs used for prevention and treatment of pulmonary complications seems to be very important. *In vitro* cultivated *Calculus Bovis* (ICCB)[2] developed by Tongji Hospital of Tongji Medical College, Huazhong University of Science and Technology, with independent intellectual property rights, is one of the first-class national Chinese herbal medicine certificate of new drugs. ICCB is bilirubin calcium stones from *in vitro* cultivated bovine bile by simulating the formation principle and biochemical processes of gallstone *in vivo* using the modern bio-medical technology. The pharmacy, pharmacology and toxicology of the drug and phase I -Ⅳ clinical trials show that ICCB is consistent with natural bezoar in property, structure, composition, content and clinical efficacy, and no obvious toxicity and adverse effects could been observed (SFDA approval number Z20010075). *Calculus Bovis* has effects of clearing heat and toxic materials, promoting blood circulation and reducing swelling, eliminating stasis and facilitating tissue recovery, lowering vascular permeability, clearing softened blood vessels, scavenging free radicals and anti-anoxia in the principle of traditional Chinese medicine. *In vitro* cultivated *Calculus Bovis* compound preparation (ICCBco)[3-5] is mainly composed of ICCB, Chinese *Paris Rhizome, polygonum cuspidatum, appendiculate cremastra pseudobulb, frankincense,* and *myrrh*, with functions of clearing away heat and toxic materials, removing blood stasis, reducing swelling, eliminating blood stasis and promoting tissue regeneration. To evaluate the efficacy of ICCBco in the treatment of lung lesions in portal hypertensive rabbits with schistosomiasis as the experimental animal model, we performed a randomized, double-blind, controlled trial to observe the pathological changes and pathological mechanism of fibronectin (FN) and laminin (LN) expressions in the lung tissue of portal hypertensive rabbits with schistosomiasis.

MATERIALS AND METHODS

Materials

Experimental animal: Forty healthy adult rabbits (male, 2.5 kg in weight) provided by the Medical Experimental Animal Center of Tongji Medical College, Huazhong University of Science and Technology.

Medicine: ICCBco (0.25 g/granule, 60 granules/bottle), Levo-praziquantel (0.1 g/tablet, 10/box), both offered by Tongji Medical College, Huazhong University of Science and Technology.

Reagents: Sheep serum, rabbit anti-human FN and LN primary antibody serum (1:100) were purchased from Boster Company, Wuhan. SABC kit was obtained from Zhongshan Company, Beijing.

Instruments: OPTON transmission electron microscopy (TEM, Carl Zeiss EM 10 C, Oberkochen, Germany) and optical microscopy (Olympus, Japan) were used.

Methods

Animal model establishment: The hair over the abdomen was shaved off, and the rabbits were infected by cercarie of oncomelania hupensis by the sticking and pasting method[6]. The solution containing 200 ± 5 cercarie was dripped on the shaved area of each rabbit and covered by a slide for 15 min, which led to acute infection. After 40 d, ICCBco was administered to the rabbits (6 granules/d). After 60 d, levo-praziquantel was perfused to kill parasites with a dosage of 500 mg/d for two consecutive days. The pulmonary fibrosis model was established in 120 d or so, and the experimental animals were killed by necropsy procedure in 4 mo. Pulmonary samples were obtained by autopsy. The experimental animals were divided into two groups: group A (control group), treated with praziquantel (n = 20); group B, treated with praziquantel plus ICCBco (n = 20).

Sample collection: Batches of rabbits were sacrificed by injecting an overdose of anesthesia with 1% Thiopental Sodium (50 mg/kg) *via* the ear vein. A small sample of the left lung tissue about the size of 2 cm × 1 cm × 1 cm was harvested after laparotomy, routinely fixed with 10% formaldehyde solution, and embedded in paraffin wax within 12 h for pathological examination. Another sample of the left lung tissue with a size of 1 mm × 1 mm × 0.5 mm was immediately put in a vial containing 20 g/L glutaraldehyde, and then sent to the department of ultrastructural pathology for TEM examination in 1 h.

Staining method: Samples of lung tissue were fixed in 40 g/L neutral buffered formaldehyde solution, routinely embedded in paraffin wax, and serial sections were made at a thickness of 5 μm for hematoxylin and eosin (HE) staining and observed under optical microscopy.

Samples were fixed in 10% formaldehyde solution, and then treated with 2.5% potassium dichromate mordant prepared by 5% acetic acid for 12-18 h, and immersed in water washing for 10 min. Sections were treated with sodium thiosulfate in order to remove mercury deposition, and then fully washed with water, and stained for 2-5 min in Ehrlich's hematoxylin followed by wash in water. Differentiation was done in acid alcohol and thoroughly washed in running water until the sections turned blue, and then stained in 1% aqueous acid fuchsin solution for 5 min followed by rinsing sections in running water for 30 s or longer until color of collagen disappeared, and rinsed in distilled water. Sections were stained in Aniline Blue/Orange G for 20 min, washed in running water for 2-5 min, dehydrated, differentiated through 95% alcohols, washed in absolute alcohol and then passed into xylene for tissue transparent. At last, sections were mounted with gelatin and observed under optical microscopy.

Flesh sample of the lung tissue were cut into slices about a size of 1 cm × 1 cm × 1 cm, and placed in 25 mg/L

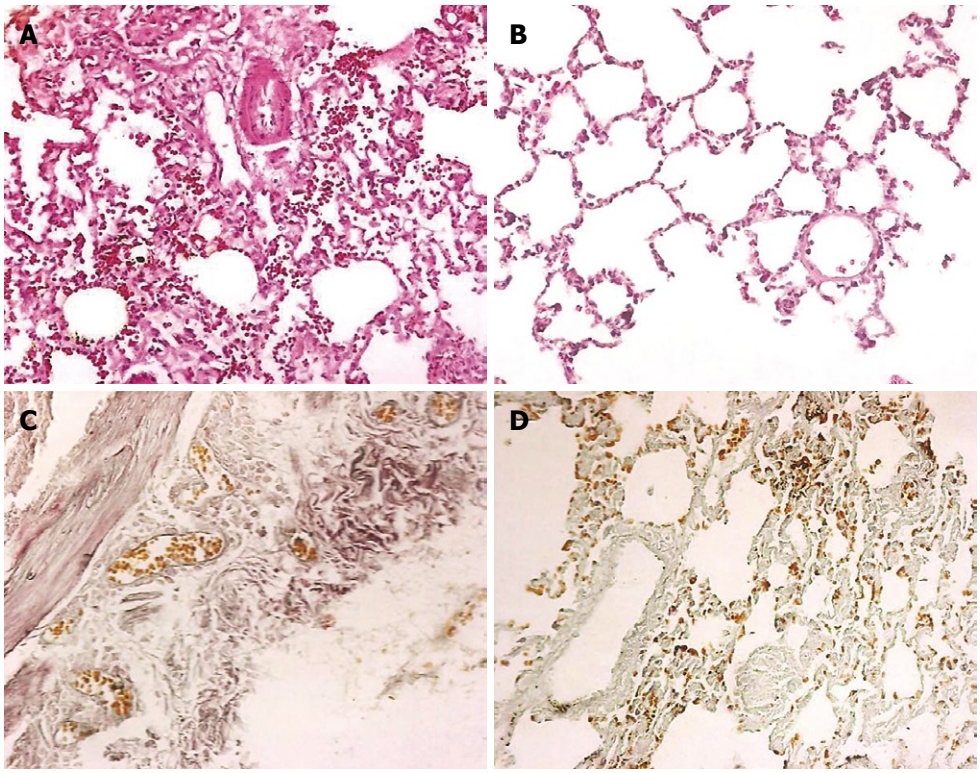

Figure 1 HE staining observation of lung tissues in control group (A) and *in vitro* cultivated *Calculus Bovis* compound preparation (ICCBco) group (B); Mallory trichrome staining in control group (C) and ICCBco group (D).

glutaraldehyde for 2 h as pre-fixation, then washed in pH 7.4 phosphate buffer solution followed by post- fixation in 10 g/L osmium acid under 4℃ for 2 h. The slices were dehydrated with progressively increased concentration of alcohol and acetone, embedded in epoxy resin EPON 812. Ultrathin sections were cut and stained with double staining of uranium and lead (acetic acid-uranium-lead citrate) so as to be observed under TEM.

Sections were routinely deparaffinized, treated with 30 mL/L hydrogen peroxide, which was freshly prepared by distilled water, for 10 min at room temperature to inactive endogenous peroxidases and rinsed three times in distilled water. Normal goat serum blocking solution was added and incubated at room temperature for 30 min in order to reduce non-specific background staining. Excessive liquid was removed without rinse. Sections were incubated in primary antibody (1:100) at 4℃ overnight, then washed thrice in PBS (0.1 mol/L), and incubated in biotinylated secondary antibody for 30 min at room temperature, then rinsed thrice in PBS for 5 min. And they were incubated with SABC for 30 min at 37℃ followed by rinse four times in PBS for 5 min. Sections were incubated in DAB with DAB reagent kit: One drop of reagent A and reagent B were added in 1 mL distilled water, and placed the well-mixed reagents onto the slices. The reaction was allowed to develop for 3-10 min under the control of microscopy at room temperature, and rinsed in distilled water. Sections were lightly counterstained with hematoxylin. After dehydration, transparent, and mounting process, slides were observed under microscopy. PBS was used as negative control instead of primary antibody and a known positive slice was taken as positive control. Brownish yellow granules in the cytoplasm were considered as positive FN and LN. Selected regions containing endothelial cells under optical microscopy were input into HPIAS-l000 automatic color image analysis system and the results were shown as the average absorbance.

Statistical analysis

All data were presented as the mean ± SD. Statistical analysis was done using SPSS software version 11.0. Statistical differences between the two groups were analyzed using ANOVA and *t* tests. *P* values less than 0.05 were considered significant.

RESULTS

Morphological results

HE staining results showed that the alveolar exudation in the lung tissue was seen more frequently in group A, while the alveolar space was fairly dry in the lung tissue of group B (Figure 1A and B). Mallory trichrome staining results showed more alveolar exudation and collagen fibers in the lung tissue of group A, while fairly dry alveolar space and less collagen fibers were seen in group B (Figure 1C and D). More alveolar exudation was found in group A, and more macrophages, alveolar angiotelectasis and the blurred three-tier structure of alveolar-capillary barrier could also be seen under TEM observation (Figure 2A and B). In group B, fibers within the alveolar interspace slightly increased in some lung regions, and the structure of type I epithelium, basement membrane and endodermis was complete, and no obvious exudation in alveolar space and no vascular congestion were observed (Figure 2C and D).

Immunohistochemical staining results

There was a positive or strong positive expression of FN

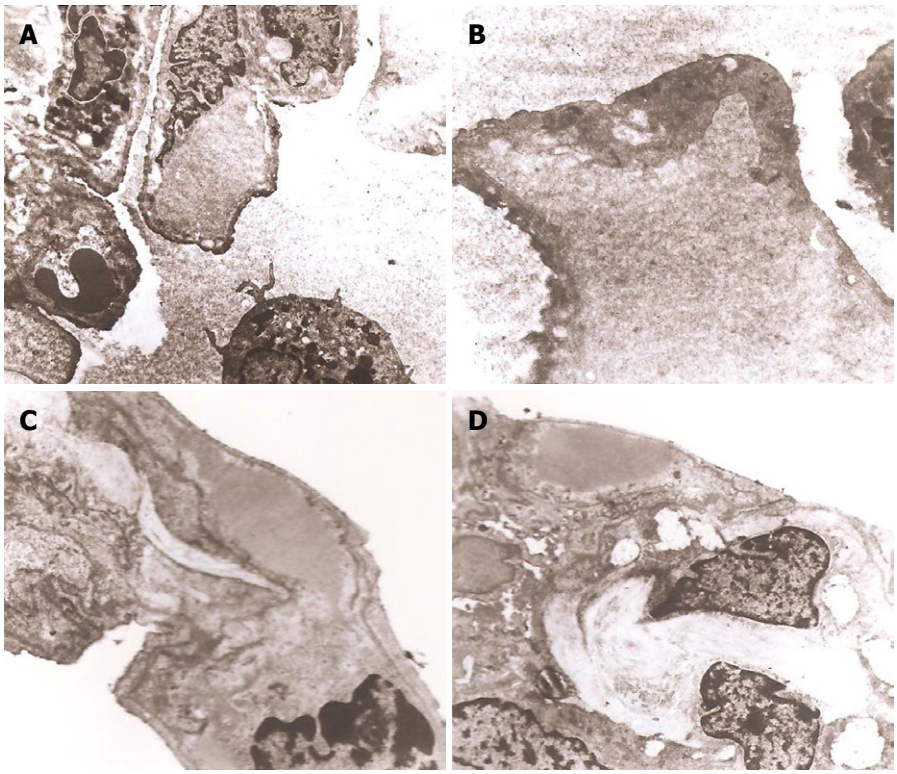

Figure 2 Observation of lung tissues in control group (A, B), and ICCBco group (C, D) under transmission electron microscope.

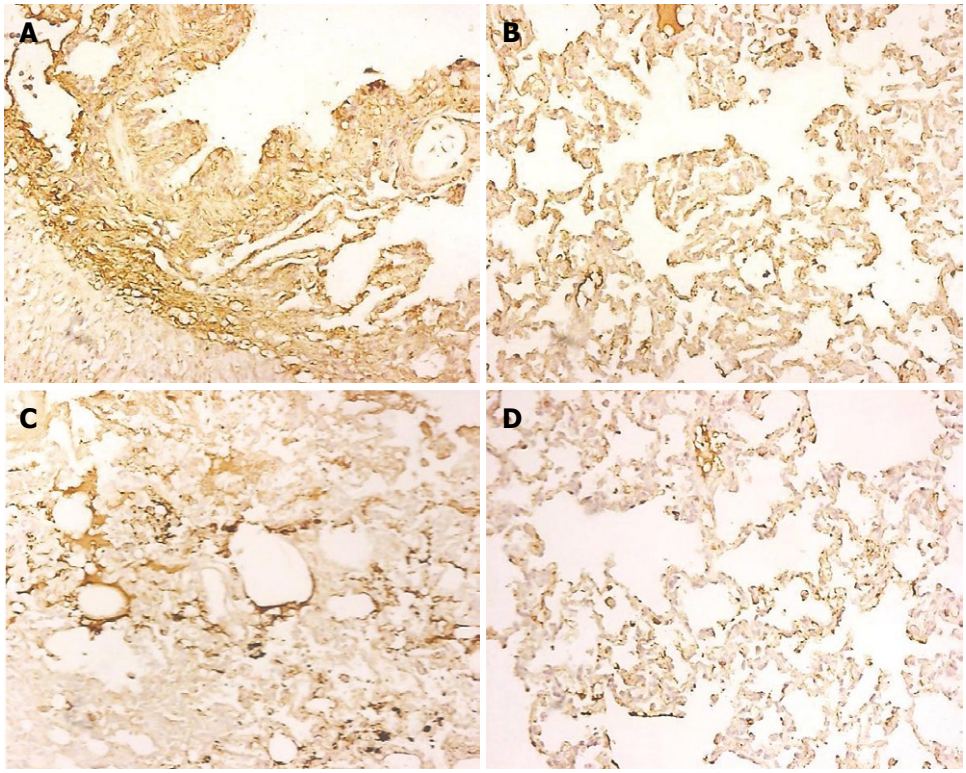

Figure 3 Expression of fibronectin (FN) and laminin (LN) of lung tissues in control group (A, C) and ICCBco group (B, D) by histochemical staining.

in the lung tissue of group A, while a negative or weak positive expression of FN in group B (Figure 3A and B). Group A showed a positive or strong positive expression of LN in the lung tissue, while group B showed a negative or weak positive expression of LN (Figure 3C and D). The integrated optical density (IOD) values are shown in Table 1.

DISCUSSION

Rabbit model of hepatic fibrosis of schistosomiasis was consistent with the natural course and pathological development process of human liver fibrosis; previous studies have confirmed that 4 mo after rabbits were infected with schistosomiasis, the hepatic fibrosis

Table 1 IOD values in lung tissues of both groups (mean ± SD)

Group	*n*	IOD value of FN	IOD value of LN
Control group	20	19.47 ± 1.21	20.23 ± 0.87
ICCBco group	20	13.15 ± 0.94	12.08 ± 1.26

A marked decrease in the expression of FN and LN in the lung tissue was seen in ICCBco group ($P < 0.01$). IOD: Integrated optical density; FN: Fibronectin; LN: Laminin; ICCBco: *In vitro* cultivated *Calculus Bovis* compound preparation.

formed, indicating it is a mature model of liver fibrosis.

Schistosomiasis can not only cause liver fibrosis and portal hypertension, but also cause tissue lesions. The most dangerous lesion is pulmonary vascular lesion characterized by hypoxemia and decreased oxygen saturation. However, the exact mechanisms of hypoxemia are still controversial, and it is currently believed to be caused by the three factors together - intrapulmonary shunt, ventilation - perfusion imbalance and pulmonary diffusion dysfunction. The important fundamental cause of these pathologic changes is pulmonary vasodilation[7]. Our results showed that there was a slight increase in fibers between alveolar gap in some parts of the lung tissue, and the structure of type I epithelium, basement membrane and endodermis was complete, and there was no obvious exudation in alveolar space, and no vascular congestion in the ICCBco group, while more alveolar exudation, more macrophages, alveolar angiotelectasis and the blurred three-tier structure of alveolar-capillary barrier were seen in praziquantel control group. This indicates that ICCBco could make a marked improvement in pulmonary ischemia, hypoxia, pulmonary function, blood flow blockade, damage, and connective tissue hyperplasia, which would shed light on pathological basis of clinical manifestations.

Extracellular matrix (ECM) proteins can be categorized into two kinds: collagen and non-collagen protein. ECM not only provides supporting structure and attachment for tissues but also regulates cell adhesion, migration, proliferation, differentiation, and tissue trauma repair and fibrosis. FN is a glycoprotein of large molecular weight with highly active adhesion, mainly derived from macrophage. FN induces chemotactic migration of interstitial cells[8], and promotes fibroblast division and proliferation[9]. Studies have found that FN mRNA and protein expression of alveolar macrophages and interstitial fibroblasts were markedly elevated in patients with pulmonary fibrosis[10], FN can transmit messages into cells through adhesion molecules on the surface of fibroblast cells and plays an initial role in the lung fibrosis process. It is currently believed that FN first appears in the early pulmonary fibrosis, and after then other interstitial elements occurs. LN is a large-molecular-weight non-collagen glycoprotein existing in the transparent layer of the basement membrane, which plays an important role in the maintenance of structure and function of alveolar and capillary basement membrane. Basement membrane provides a support for the regeneration of injured epithelial cells, and is the barrier for the entry of molecules and cells into the alveolar cavity[11,12]. The normal lung tissue contains very little LN. There is a significant increase of LN in pulmonary fibrosis or liver cirrhosis, which is about 10 times the level of LN in the normal lung and is consistent with collagen content in fibrosis[13]. Some scholars found that LN fluorescence in alveolar septa was enhanced in rats with early stage pulmonary fibrosis, later became thicker and deranged, presuming that LN participated in the whole process of experimental pulmonary fibrosis, and might play an important role in the development of fibrosis[14]. Previous experiments showed that abnormal accumulation of type I and Ⅲ collagen, FN and LN in extracellular matrix at the early stage of schistosomiasis-induced liver fibrosis[15]. FN and LN are, therefore, better indicators for pulmonary fibrosis. In this study, we found that there was a significant decrease in the expression of FN and LN in ICCBco group compared with praziquantel control group, which suggests ICCBco could effectively inhibit the formation of pulmonary fibrosis. With functions of clearing away heat and toxic materials, removing blood stasis, reducing swelling, eliminating blood stasis and promoting tissue regeneration, it could improve pulmonary microcirculation, inhibit connective tissue proliferation, degrade extracellular matrix, reduce pulmonary damage, hence inhibiting the formation of pulmonary fibrosis.

In summary, ICCBco can effectively prevent pulmonary complications of portal hypertensive rabbits with schistosomiasis. Its function in suppressing pulmonary lesions is achieved by removing heat, toxic materials and blood stasis, reducing swelling, eliminating blood stasis and promoting tissue regeneration to block the activation of alveolar macrophages, improve pulmonary microcirculation, and reduce ECM. The successful development of ICCB and the preliminary study on portal hypertensive pulmonary lesions caused by schistosomiasis suggest that it is of great significance and prospects for further basic and clinical research, development and clinical application of new drugs and preparations to treat portal hypertensive pulmonary lesions induced by schistosomiasis.

COMMENTS

Background

Portal hypertension is a vascular lesion that initially arises in liver, but structural and functional changes of blood vessels in extrahepatic portal system, systemic circulation and pulmonary circulation also accompany, which now collectively called portal hypertensive vascular lesions. In clinical practice, much attention has been paid to the prevention and treatment of complications such as ascites, esophagogastric variceal bleeding; however the management of pulmonary complications is ignored which affects the prognosis of patients. Hence, drugs used for prevention and treatment of pulmonary complications seem to be very important.

Research frontiers

In vitro cultivated *Calculus Bovis* compound preparation (ICCBco) is composed of ICCB, Chinese *Paris Rhizome*, *polygonum cuspidatum*, *appendiculate cremastra pseudobulb*, *frankincense*, and *myrrh*, and has the functions of clearing away heat and toxic materials, removing blood stasis, reducing swelling, eliminating blood stasis and promoting tissue regeneration, according to the principle of traditional Chinese medicine. However, the topic has not been unequivocally addressed. This study evaluated the efficacy of ICCBco in the

treatment of lung lesions in portal hypertensive rabbits with schistosomiasis as the experimental animal model.

Innovations and breakthroughs

The present study explored the pathogenesis of portal hypertension and the prevention and treatment of its pulmonary complications (hepatopulmonary syndrome, pulmonary fibrosis, pulmonary hypertension, pulmonary venous hypertension) from a new perspective of portal hypertensive vascular disease. ICCB is a Class 1 new Chinese medicine developed by Wuhan Tongji Hospital with independent intellectual property rights, is a treasure of traditional Chinese medicine. To investigate its role in the treatment of schistosomiasis-induced pulmonary complications of portal hypertension has far-reaching significance.

Applications

The successful development of ICCB and the preliminary study on portal hypertensive pulmonary lesions caused by schistosomiasis suggest that it is of great significance and prospects for further basic and clinical research, development and clinical application of new drugs and preparations to treat portal hypertensive pulmonary lesions induced by schistosomiasis.

Terminology

Composed of ICCB, Chinese *Paris Rhizome*, *polygonum cuspidatum*, *appendiculate cremastra pseudobulb*, *frankincense*, and *myrrh*, ICCBco can effectively prevent pulmonary complications of portal hypertensive rabbits with schistosomiasis. ICCBco could improve pulmonary microcirculation, inhibit connective tissue proliferation, degrade extracellular matrix, reduce pulmonary damage, hence inhibiting the formation of pulmonary fibrosis.

Peer review

This is a very interesting research but not well planned.

REFERENCES

1 **Yang Z**, Tian L, Mba M, Qiu F. Portal Hypertensive Vasculopathy. *J Tongji Med Univ* 1996; **25**: 309-310

2 **Cai HJ**, Qiu FZ, Liu RZ. Studies on the pharmacy of in-vitro Cultivated Calculus bovis (ICCB). *Zhongguo Tianran Yaowu* 2004; **2**: 335-338

3 **Du ZH**, Cai HJ, Yang RG, Liu RZ, Cao FD, Qiu FZ. Experimental studies on anti-inflammatory effect of in-vitro Cultivated Calculus bovis (ICCB). *Zhongyao Xinyao Yu Linchuang Yaoli* 1996; **7**: 27-29

4 **Cai HJ**, Wang SY, Zhang YH, Li QM, Xia JY, Wang Q, Xie H, Lai SL. In vitro Cultured Calculus Bovis in the Treatment of Epidemic Encephalitis B. *Huazhong Keji Daxue Xuebao* (Health Sci) 2003; **32**: 604-606

5 **Cai HJ**, Wang SY, Liu LG, Yao P, Guan Y. Effect of anti-hypoxia and elimination of free radicals of in vitro Cultured Calculus. *Zhongyao Yaoli Yu Linchuang* 2003; **19**: 20-22

6 **Yang Z**, Qiu FZ, Wang ZH. Establishment and characteristic rabbit model of schistosomiasis. *Zhonghua Shiyan Waike Zazhi* 1993; **10**: 145-146

7 **Fallon MB**, Abrams GA. Pulmonary dysfunction in chronic liver disease. *Hepatology* 2000; **32**: 859-865

8 **Shoji S**, Rickard KA, Ertl RF, Robbins RA, Linder J, Rennard SI. Bronchial epithelial cells produce lung fibroblast chemotactic factor: fibronectin. *Am J Respir Cell Mol Biol* 1989; **1**: 13-20

9 **Bitterman PB**, Rennard SI, Adelberg S, Crystal RG. Role of fibronectin as a growth factor for fibroblasts. *J Cell Biol* 1983; **97**: 1925-1932

10 **Limper AR**, Broekelmann TJ, Colby YV, McDonald JA. Analysis of local Mrna expression for extracellular matrix proteins and growth factors using insitu hybridization in fibroproliferative lung disorders. *Chest* 1991; **99** Supple 3: 55S-56S

11 **Vracko R**. Significance of basal lamina for regeneration of injured lung. *Virchows Arch A Pathol Pathol Anat* 1972; **355**: 264-274

12 **Vracko R**. Basal lamina scaffold-anatomy and significance for maintenance of orderly tissue structure. *Am J Pathol* 1974; **77**: 314-346

13 **Iredale JP**, Arthur MJ. Hepatocyte-matrix interactions. *Gut* 1994; **35**: 729-732

14 **Jiang L**, Chen BY, Hou XM. Changes of extracellular matrix proteins in rats with pulmonary fibrosis. *Zhongguo Yike Daxue Xuebao* 1998; **27**: 26-29

15 **Yang Z**, Liu RZ, Yang RG, Cai HJ. Changes of hepatic extracellular matrix in schistosomiasis rats at early stage of liver fibrosis. *Zhonghua Shiyan Waike Zazhi* 1995; **12**: 157-158

S- Editor Wang YR **L- Editor** Ma JY **E- Editor** Lin YP

World Journal of Gastroenterology

Online Submissions: http://www.wjgnet.com/1007-9327office
wjg@wjgnet.com
doi:10.3748/wjg.v16.i6.755

World J Gastroenterol 2010 February 14; 16(6): 755-763
ISSN 1007-9327 (print)

BRIEF ARTICLE

Methylation of *Dickkopf-3* as a prognostic factor in cirrhosis-related hepatocellular carcinoma

Bin Yang, Zhi Du, Ying-Tang Gao, Cheng Lou, Shi-Guang Zhang, Tong Bai, Yi-Jun Wang, Wen-Qin Song

Bin Yang, Zhi Du, Ying-Tang Gao, Key Laboratory of Artificial Cells, Third Central Hospital, Tianjin 300170, China
Zhi Du, Cheng Lou, Yi-Jun Wang, Department of Hepatobiliary Surgery, Third Central Hospital, Tianjin 300170, China
Tong Bai, Graduate School of Tianjin Medical University, Tianjin 300070, China
Bin Yang, Ying-Tang Gao, Shi-Guang Zhang, Wen-Qin Song, College of Life Science, Nankai University, Tianjin 300071, China
Bin Yang, Postdoctoral Workstation of TEDA, Tianjin 300457, China
Author contributions: Du Z and Song WQ designed the research and revised the manuscript; Yang B, Zhang SG and Bai T performed the research; Gao YT provided the analytic tools; Lou C collected the clinical pathological data; Wang YJ collected the tumor tissues; Yang B analyzed the data and wrote the manuscript.
Supported by China Postdoctoral Science Foundation, No. 20070410753; Tianjin Science and Technology Commission, No. 05YFSZSF02500; and Tianjin Health Bureau, No. 07KZ10
Correspondence to: Zhi Du, Professor, Key Laboratory of Artificial Cells, Third Central Hospital, Tianjin 300170, China. zhi-du@163.com
Telephone: +86-22-84112148 Fax: +86-22-24315132
Received: October 20, 2009 Revised: November 26, 2009
Accepted: December 3, 2009
Published online: February 14, 2010

Abstract

AIM: To investigate the prevalence and time of Dickkopf (DKK) family methylation and its clinical significance in hepatocarcinogenesis.

METHODS: Methylation of *DKK* family genes was quantitatively analyzed in 115 liver tissue samples, including 50 pairs of primary hepatocellular carcinoma (HCC) and matched noncancerous cirrhotic tissue samples, as well as 15 liver cirrhosis biopsy samples.

RESULTS: The methylation level of *DKK3* was significantly higher in HCC tissue samples than in matched noncancerous cirrhotic tissue samples ($P < 0.0001$) or in liver cirrhosis biopsy samples ($P = 0.0139$). Receiver operator characteristic curve analysis confirmed that the percent of methylated reference (PMR) values of *DKK3* could effectively discriminate HCC tissue samples from noncancerous tissue samples (AUC = 0.8146) or liver cirrhosis biopsy samples (AUC = 0.7093). Kaplan-Meier survival curves revealed that the progression-free survival time of patients with a higher *DKK3* methylation level (PMR > 1%) was significantly shorter than that of those with a lower *DKK3* methylation level (PMR ≤ 1%) ($P = 0.0255$). Multivariate Cox analysis indicated that methylated *DKK3* was significantly and independently related with a shorter survival time (relative risk = 2.527, 95% CI: 1.063-6.008, $P = 0.036$) of HCC patients.

CONCLUSION: Methylation of *DKK3* is an important event in early malignant transformation and HCC progression, and therefore might be a prognostic indicator for risk assessment of HCC.

Key words: Dickkopf; Hepatocellular carcinoma; Methylation; Biomarker; Prognosis

Peer reviewer: Dr. Paolo Del Poggio, Hepatology Unit, Department of Internal Medicine, Treviglio Hospital, Piazza Ospedale 1, Treviglio Bg 24047, Italy

Yang B, Du Z, Gao YT, Lou C, Zhang SG, Bai T, Wang YJ, Song WQ. Methylation of *Dickkopf-3* as a prognostic factor in cirrhosis-related hepatocellular carcinoma. *World J Gastroenterol* 2010; 16(6): 755-763 Available from: URL: http://www.wjgnet.com/1007-9327/full/v16/i6/755.htm DOI: http://dx.doi.org/10.3748/wjg.v16.i6.755

INTRODUCTION

Hepatocellular carcinoma (HCC) is one of the most common malignancies in the world, leading to more than 500000 deaths every year[1]. Most HCC cases (> 80%)

occur in either sub-Saharan Africa or Eastern Asia. HCC cases in China alone account for more than 40% of all cases in the world[2]. It was recently reported that the incidence of HCC is increasing worldwide[3]. Treatment of HCC is still a great challenge for clinical oncologists because most HCC patients are diagnosed at its advanced stage with distant metastasis[4].

Dysplastic cirrhotic nodules are considered precursors of HCC because of their association with HCC occurrence. Development of HCC is closely associated with cirrhosis and 90% of the tumors are found in chronic hepatitis or cirrhotic patients[5]. One reasonable explanation for this close correlation is that necrosis and regeneration of hepatocytes due to chronic liver damage provide the stepwise accumulation of genetic and epigenetic changes necessary for hepatocarcinogenesis[2]. Therefore, elucidation of these aberrant alterations involving hepatocellular transformation at the cirrhosis stage is not only crucial to understand the molecular basis of hepatocarcinogenesis but also to provide potentially useful markers for the early diagnosis, risk assessment, treatment, and chemoprevention of HCC.

Aberrant promoter hypermethylation of tumor suppressor genes is a common event during the pathogenesis of human cancers and one of the important epigenetic mechanisms in carcinogenesis. It has been shown that methylation of multiple tumor suppressor genes in HCC may contribute to the pathogenesis of this disease[5,6]. Dickkopf (DKK) family is one class of the secreted Wnt antagonists and its functional loss can contribute to activation of the Wnt pathway and result in carcinogenesis through dysregulation of cell proliferation and differentiation[7]. It has been recently shown that methylation of *DKK* gene family contributes to carcinogenesis and serves as a potential biomarker for the diagnosis or prognosis of several human malignancies[8]. However, few reports are available on the epigenetic silencing of *DKK* gene and its clinical significance in HCC[9].

In the present study, we examined the promoter hypermethylation of human *DKK* family genes in HCC and cirrhosis tissue samples by quantitative methylation-specific polymerase chain reaction (Q-MSP), and evaluated whether quantitative methylation of *DKK* genes can serve as a potentially diagnostic or prognostic biomarker for HCC.

MATERIALS AND METHODS

Patients and sample collection

A total of 115 liver tissue samples, including 50 pairs of primary HCC and matched noncancerous cirrhotic liver (NCL) tissue samples, as well as 15 liver cirrhotic (LC) biopsy samples, were analyzed in this study. Tumor tissue samples were collected from patients who underwent surgery in Third Central Hospital of Tianjin between December 2003 and August 2006 and stored at -80℃ for further processing. Clinicopathological data were collected from patient records and pathology reports. Written informed consent was obtained from each patient and the study protocol was approved by the Clinical Research Ethics Committee of Third Central Hospital, Tianjin.

DNA extraction and bisulfite treatment

Genomic DNA was extracted from tumor tissue samples by digesting with SDS/proteinase K in TE buffer followed by a standard phenol/chloroform extraction. The extracted DNA was subjected to bisulfite treatment as previously described[10]. Briefly, 1-2 μg genomic DNA was denatured with 0.3 mol/L NaOH at 37℃ for 20 min, and incubated in 3.0 mol/L sodium bisulfite and 10 mmol/L hydroquinone at 55℃ for 16 h. The DNA was desalted with a QIAquick gel extraction kit (Qiagen, Valencia, CA) and dissolved in 50 μL of 10 mmol/L TE buffer (pH 8.0). Then, 5.5 μL of 3.0 mol/L NaOH was added and incubated at 37℃ for 20 min to desulfonate it. The modified DNA was neutralized with 30 μL of 10 mol/L ammonium acetate, precipitated using 2 volumes of ethanol, and resuspended in 40 μL of 1.0 mmol/L TE buffer (pH 7.6).

Q-MSP

Fluorogenic quantitative MSP assay was carried out in the ABI Prism 7000 sequence detection system (Applied Biosystems, Foster City, CA). For each gene of the *DKK* family, a set of primers and a probe covering multiple CpG dinucleotides were designed within the putative CpG islands around the gene promoters. For the endogenous reference gene, *ACTB* (β-actin), the primers and probe were designed to avoid CpG dinucleotides. All primers and probes were designed according to the bisulfite-converted DNA sequences. Genes of interest were amplified in proportional to the degree of CpG methylation, while *ACTB* was amplified independently of its methylation. The sequences of primers and probes are as follows: (1) *DKK1*, 5'-GGGTTCGCGGTATAAAGGTAGTC-3' (sense), 5'-TCCGAAAACCCCCTACGATC-3' (antisense), 5'-FAM-TGGCGGTGGCGGCGTAGAGT-BHQ1-3' (Probe); (2) *DKK2*, 5'-GCGAGCGTAGCGTAAGTTCGT-3' (sense), 5'-CACTCACAATTACCCCGAAACG-3' (antisense), 5'-FAM-AGGTATCGTTGCGTTGGTAGCGATTCG-BHQ1-3' (Probe); (3) *DKK3*, 5'-GGTATCGGCGTTGTCGTATTTC- 3' (sense), 5'-CCACCCCGACTAAACCGAAT-3' (antisense), 5'-FAM-TCGCGGTTCGTTTATCGCGTC-BHQ1-3' (Probe); and (4) *ACTB*, 5'-TGGTGATGGAGGAGGTTTAGTAAGT-3' (sense), 5'-AACCAATAAAACCTACTCCTCCCTTAA-3' (antisense), 5'-FAM-ACCACCACCCAACACACAATAACAAACACA-BHQ1-3' (Probe).

Q-MSP assay was performed in a reaction volume of 20 μL in 96-well plates, and the final reaction mixture was consisted of 1 × real-time PCR master mix (Toyobo Co., Ltd. Shanghai), 200 nmol/L probe, 400 nmol/L primers of each gene, and 2 μL bisulfite-converted DNA templates. PCR was performed at 95℃ for 2 min, followed by 45 cycles at 95℃ for 15 s, and at 60℃ for 45 s. Reactions were done in duplicate and each plate included at least 3 controls with no template (NTC), as well as negative and positive controls on each plate. Leukocyte

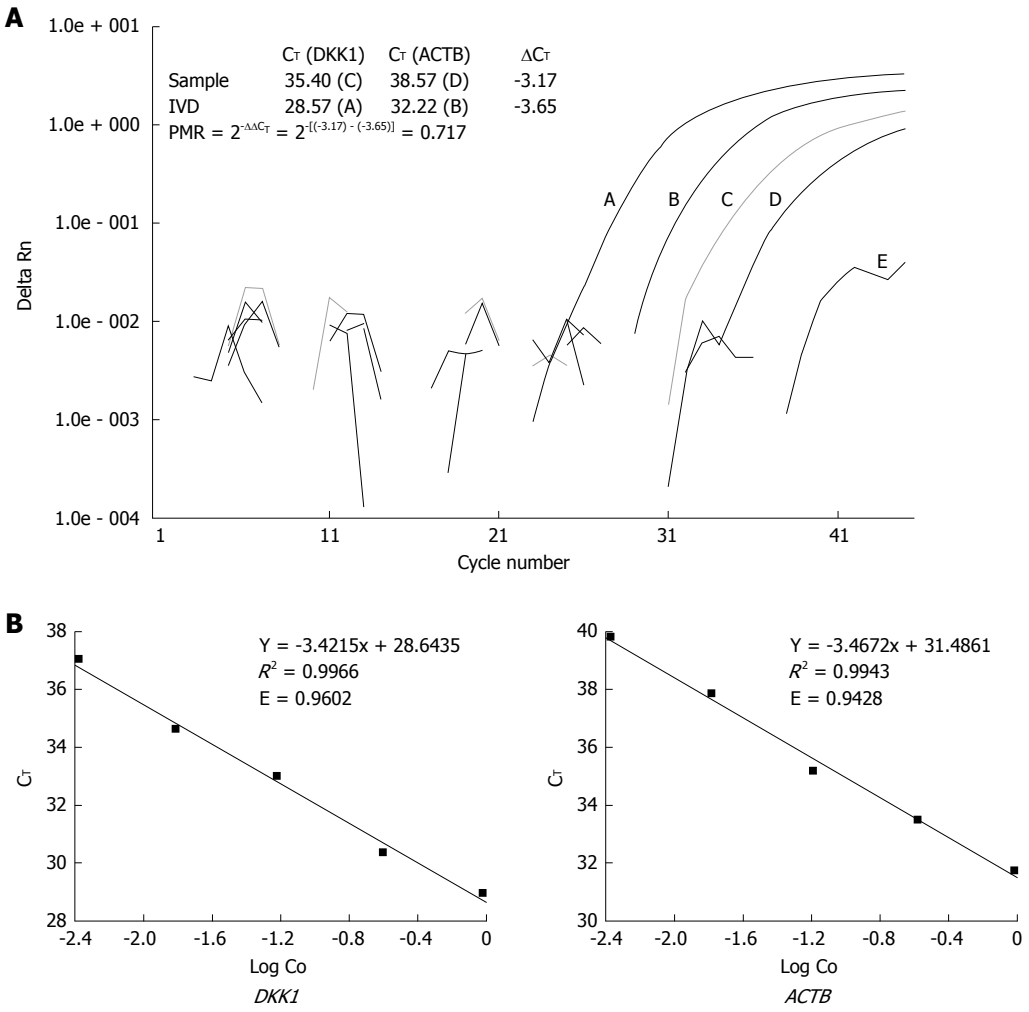

Figure 1 Quantitative methylation analysis using comparative C_T method. A: Representative quantitative methylation-specific polymerase chain reaction (Q-MSP) amplification plots for *DKK1* and illustration for percent of methylated reference (PMR) calculation with comparative C_T method; B: Validation experiment for comparative C_T method, $E = 10^{(-1/Slope)} - 1$, where E: PCR efficiency; Slope: Slope of calibration curve. DKK: Dickkopf.

DNA collected from a healthy individual was used as a negative control. The DNA methylated *in vitro* with SssI methyltransferase (New England Biolabs Inc., Beverly, MA) was used as a positive control for all studied genes.

PMR values

Abbreviation PMR was used to define the percentage of fully methylated molecules at a specific locus as previously described[11]. Briefly, the PMR value was calculated by dividing the *GENE*: *ACTB* ratio in a sample by the *GENE*: *ACTB* ratio in SssI-treated leukocyte DNA (IVD) and multiplied by 100. Parallel PCR reactions were done for the genes of interest and reference. Given the high efficiency of Q-MSP amplification for both *DKK* and *ACTB* genes in this study, PMR values were detected with the comparative C_T method instead of the relative standard curve method, which needs serial dilutions of bisulfite-treated universally methylated DNA to construct a relative standard curve for each gene[12]. Relation between the percentages of methylated DNA molecules and C_T was described as $PMR = 2^{-\Delta\Delta C_T} \times 100\%$ where $\Delta\Delta C_T = \Delta C_{T(Gene)} - \Delta C_{T(ACTB)} = [C_{T(Gene)} - C_{T(ACTB)}]_{(Sample)} - [C_{T(Gene)} - C_{T(ACTB)}]_{(IVD)}$.

The number of cycles at which the fluorescence signal crossed a detection threshold was determined automatically with the ABI prism 7000 detection system, and referred to as C_T. Representative Q-MSP amplification plots for *DKK1* and corresponding calculation for PMR are illustrated in Figure 1A. For the $\Delta\Delta C_T$ calculation to be valid, the efficiencies in target and reference amplification should be within 10%. PCR efficiency was calculated and compared according to the following equation recommended in technical manual of Applied Biosystems (Figure 1B).

RNA preparation and real-time quantitative PCR

RNA was extracted from HCC and matched NCL tissue samples using Trizol (Tiangen, Beijing) according to its manufacturer's instructions. Total mRNA was digested with DNase I (Ambion, Austin, TX) to remove genomic DNA contamination and then subjected to reverse transcription using the reverse transcription system (Promega, Madison, WI). For the reverse-transcriptase PCR of *DKK3*, the sense primer (5'-ATCACCTGGGAG CTAGAGCCTGATG-3') and anti-sense primer (5'-ACC TCTCTGGGCAGCAGGGATCTC-3') were designed. PCR was done on the ABI Prism 7000 sequence detection

system in combination with the SYBR green teal-time PCR master mix (Toyobo Co., Ltd, Shanghai). Melting curve analyses following amplification were performed to assure the product specificity. Relative expression of *DKK3* mRNA was normalized to the housekeeping gene *GAPDH* in the same cDNA using the comparative C_T method. Primer sequences for *GAPDH* are 5'-CTCAT GACCACAGTCCATGCCATCACTG-3' (sense) and 5'-CATGAGGTCCACCACCCTGTTGCTGTA-3' (anti-sense).

Receiver operator characteristic (ROC) curve analysis

ROC curves were plotted to assess the PMR values of *DKK* family as diagnosis biomarkers, and their discriminatory capacity was evaluated by calculating the area under the curve (AUC). Generally, a truly useless test has an AUC of 0.5, while a perfect test (one that has zero false positives and zero false negatives) has an AUC of 1.0. For each gene of *DKK* family, the PMR values in HCC tissue samples were considered patient results, while the values in matched NCL tissue samples were considered control results.

Statistical analysis

Relation between categorical variables was determined by Pearson χ^2 test or Fisher's exact test. Difference in median of PMR values between paired HCC and NCL tissue samples was detected by Wilcoxon matched pairs test, difference in HCC tissue and LC biopsy samples was revealed by Mann-Whitney *U* test. Variables associated with overall survival or progression-free survival rate were tested using Kaplan-Meier estimates and compared by log-rank test. Relative risk (RR) of *DKK3* methylation-related death and other clinical variables were estimated from a univariate Cox proportional hazards model. Multivariate Cox models were also constructed to estimate the RR for *DKK3* methylation with adjustments for potential confounding risk factors. All statistical tests were two-sided and $P < 0.05$ was considered statistically significant. Statistical analyses were performed with GraphPad Prism V5.0 (GraphPad Software, San Diego, CA) and SPSS V11.0 software for Windows (SPSS Inc., Chicago, IL), respectively.

RESULTS

Quantitative analysis of DKK gene methylation in HCC and cirrhotic liver tissue samples

The methylation levels of *DKK* family in 3 kinds of tumor tissue sample were quantified by Q-MSP. The distribution of PMR values is illustrated in Figure 2. The methylation levels of *DKK* family in the 50 paired HCC tissue samples and NCL tissue samples were compared. Wilcoxon matched pairs test demonstrated that the methylation levels of *DKK2* and *DKK3* were significantly higher in HCC tissue samples than in corresponding NCL tissue samples ($P = 0.0080$, $P < 0.0001$), whereas no significant difference was found in the methylation level of *DKK1*. The difference in median PMR value was further compared between the 50 HCC and 15 LC tissue samples by Mann-Whitney test and a significant difference was only found in the median PMR value for *DKK3* gene ($P = 0.0139$).

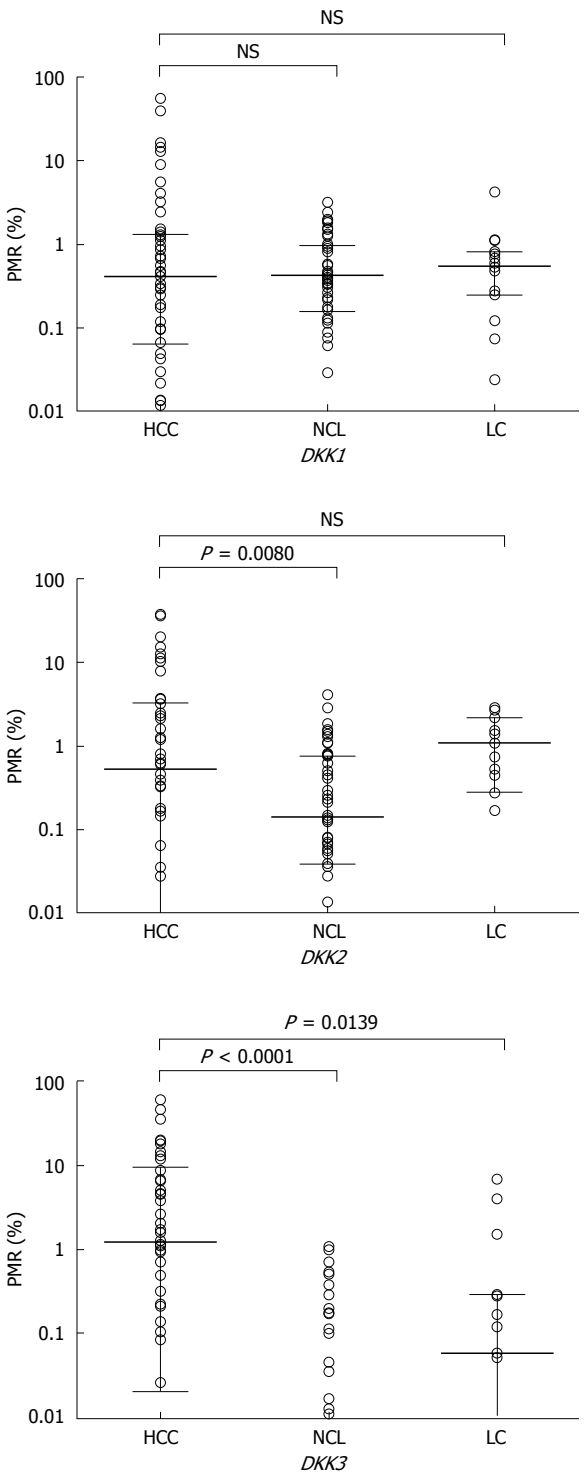

Figure 2 Methylation levels of *DKK* family genes in hepatocellular carcinoma (HCC) and corresponding noncancerous cirrhotic liver (NCL) tissue samples and liver cirrhosis (LC) biopsy samples. Horizontal bar denotes the median PMR value, and range indicates 25%-75% quartile.

Expression of DKK3 mRNA in HCC tissue samples

The expression of *DKK3* mRNA in primary HCC tissue samples was detected by real-time PCR. Fifty pairs of HCC

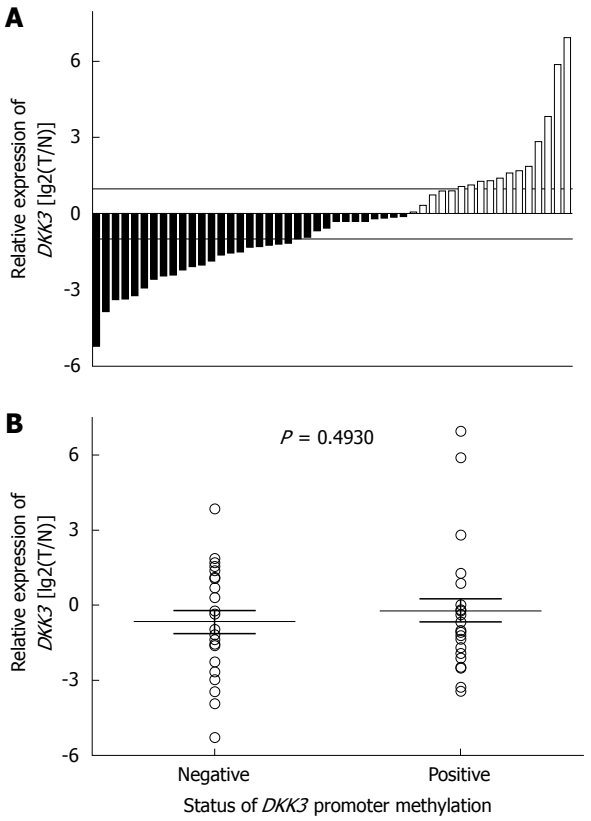

Figure 3 Expression of *DKK3* mRNA in HCC (A) and NCL (B) tissue samples. Horizontal lines represent the median FC value, and range indicates 25%-75% quartile.

tissue samples and corresponding NCL tissue samples were analyzed. The expression level of *DKK3* mRNA was lower in tumor tissue samples than in its adjacent tissue samples (Figure 3A). However, the median of *DKK3* RNA expression was not statistically different between the methylated and unmethylated *DKK3* genes ($P = 0.4930$) (Figure 3B).

ROC curve analysis of PMR values in HCC and liver cirrhosis tissue samples

To assess whether quantitative methylation assay of *DKK* family can serve as a diagnosis tool to discriminate malignant from non-malignant liver tissue samples, ROC curves were plotted with PMR values as test results. The overall discriminatory ability of the test was evaluated by calculating the AUC (Figure 4). Two ROC curves were plotted for each gene. The PMR values in HCC tissue samples and the values in two types of liver cirrhosis tissue samples (NCL and LC) were considered patient results and control results, respectively. ROC curve analysis revealed that the AUC value for the PMR of *DKK3* was relatively higher in the two kinds of tumor tissue samples (0.8146 for HCC *vs* NCL tissue samples and 0.7093 for HCC *vs* LC tissue samples, respectively).

DKK gene methylation and clinicopathological correlation

To investigate the correlation between *DKK* family methylation and clinicopathological variables, the continuous PMR values were converted into discrete binary data, and the patients were also divided into two subgroups. To exclude the low *DKK* methylation level in a mere minority of cells, which may have little effect on gene activity in tumor tissue samples, PMR (1%) was selected as a criterion for the methylation of *DKK*. That is, the *DKK* methylation was classified into positive (PMR > 1%) and negative (PMR ≤ 1%) groups.

Table 1 *DKK* methylation frequencies in HCC and NCL tissue samples

	Positive (PMR > 1%)	Negative (PMR ≤ 1%)	*P*
DKK1			
HCC	14	36	0.6484
NCL	12	38	
DKK2			
HCC	21	29	0.0076
NCL	8	42	
DKK3			
HCC	27	23	< 0.0001
NCL	2	48	

DKK: Dickkopf; HCC: Hepatocellular carcinoma; PMR: Percent of methylated reference; NCL: Noncancerous cirrhotic liver.

The methylation patterns of *DKK* genes in paired HCC and NCL tissue samples are summarized in Table 1. Consistent with the quantitative analysis above, significantly different methylation patterns of *DKK3* were found in HCC and NCL tissue samples ($P < 0.0001$). The methylation frequency of *DKK2* in HCC (64%, 32 of 50) and NCL (60%, 30 of 50) tissue samples was similar, while the methylation level of *DKK2* was higher in HCC tissue samples (42%, 21 of 50) than in NCL tissue samples (16%, 8 of 50) ($P = 0.0076$). No significant difference of *DKK1* methylation was found in HCC and NCL tissue samples.

Whether methylation of *DKK* family is related with certain clinicopathological variables was further determined. Statistical analysis showed that the methylation frequency of *DKK1* or *DKK2* was not related with the clinicopathological variables (data not shown). The frequency of *DKK3* methylation was higher in multicentric HCC (Table 2).

Overall and progression-free survival analysis

To analyze the overall and progression-free survival rate associated with *DKK3* methylation levels, patients were divided into methylation positive and negative groups according to their PMR values. The overall survival rate was not significantly different between the two groups, while the progression-free survival rate of patients with a high *DKK3* methylation level was significantly lower than that of those with a low methylation level ($P = 0.0255$) (Figure 5). Univariate Cox proportional hazards model showed that the portal vein invasion and high *DKK3* methylation level were related with an increased risk of disease progression when the tumor size was larger. Multivariate analysis model further showed that these three factors were the independently prognostic indicators for HCC (Table 3).

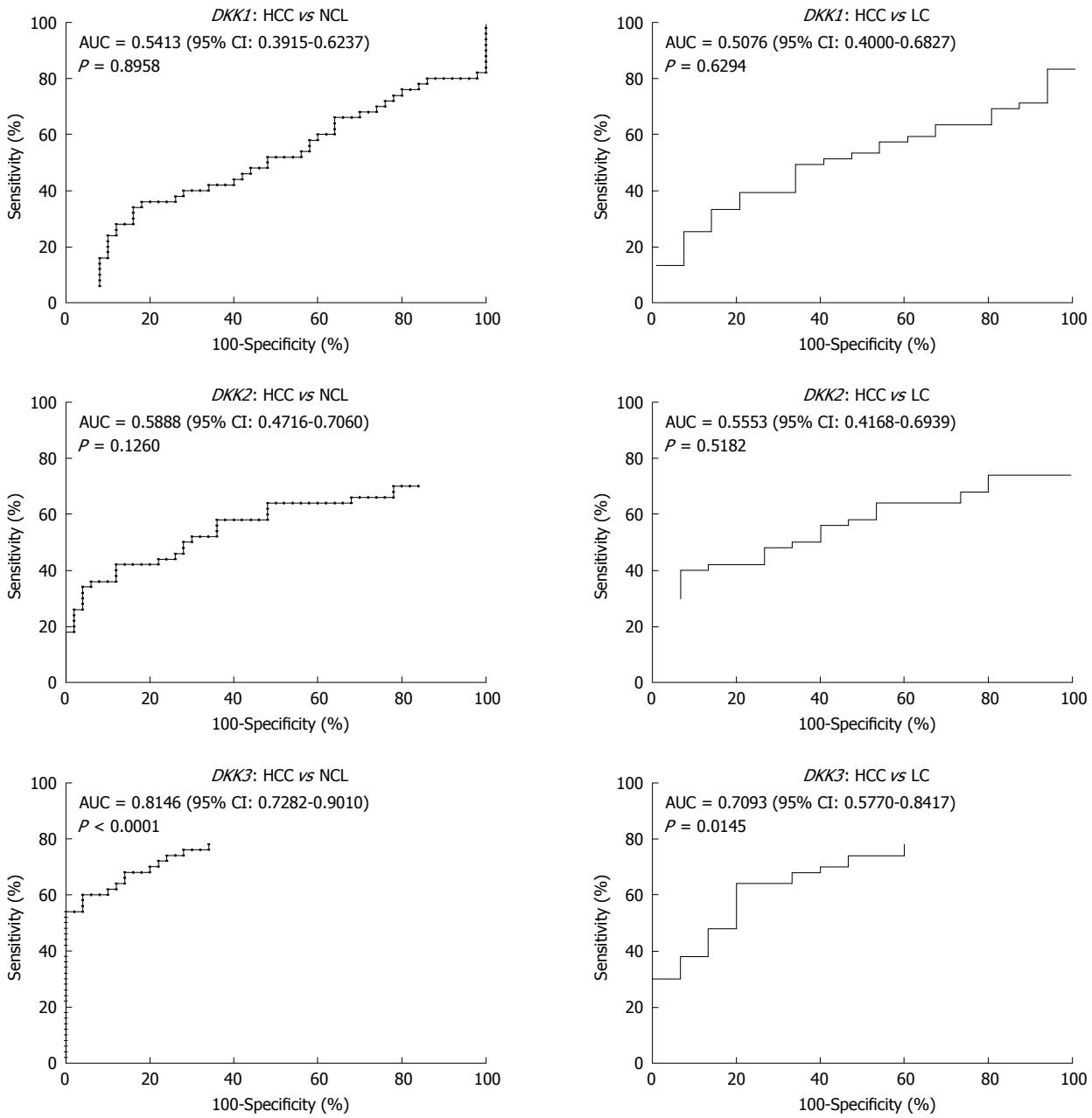

Figure 4 ROC curves for *DKK* genes used to evaluate the ability of methylation levels to distinguish tumor tissue samples from cirrhotic tissue samples.

DISCUSSION

Development of HCC is a multistep process associated with genetic and epigenetic alterations. Methylation of multiple tumor suppressor genes is frequently observed in the development of cancer and may occur at different stages of HCC. However, not all these epigenetic alterations are directly involved in hepatocarcinogenesis. Aberrant methylation observed in HCC may be a consequence of the normal aging process, persistent viral infection, and chronic inflammation. Nishida *et al*[13] demonstrated that methylation of tumor suppressor genes in HCC is frequent but occurs in a gene-specific and disease-specific manner. Therefore, it is important to determine the prevalence and time of promoter hypermethylation in hepatocarcinogenesis, especially at the stage of hepatocellular transformation from a cirrhotic background. DKK1 acts as a powerful inhibitor of the Wnt signaling pathway, and epigenetic inactivation of *DKK1* has been observed in various cancers[14-16]. In our study, a high frequency of *DKK1* methylation was also observed in liver tissue samples (Table 1), whereas quantitative methylation analysis revealed that there was no statistically different *DKK1* methylation in HCC and liver cirrhosis tissue samples, including tumor-adjacent cirrhosis and cirrhotic biopsy samples (Figure 2), suggesting that methylation of *DKK1* may be involved in early hepatocarcinogenesis but not directly contributes to neoplasitc transformation from the liver cirrhotic background. Methylation of *DKK2* has been observed in some kinds of tumor, but there is little direct evidence that epigenetic inactivation of *DKK2* contributes to tumor development[14-16]. In our

Table 2 Correlation between *DKK3* methylation and clinicopathological characteristics

	Positive (PMR > 1%)	Negative (PMR ≤ 1%)	*P*
Total	27	23	
Sex			
Male (n = 43)	23	20	
Female (n = 7)	4	3	1.000
Age (yr)			
≤ 55 (n = 28)	14	14	
> 55 (n = 22)	13	9	0.5773
Virus status			
Positive (n = 44)[1]	22	22	
Negative (n = 6)	3	3	1.000
AFP (ng/mL)			
≤ 400 (n = 30)	17	13	
> 400 (n = 20)	11	9	1.000
Tumor size (cm)			
≤ 5.0 (n = 19)	9	10	
> 5.0 (n = 31)	18	13	0.5630
Number of tumor			
Single (n = 31)	13	18	
Multiple (n = 19)	14	5	0.0417
Portal vein invasion			
Positive (n = 17)	9	8	
Negative (n = 33)	18	15	1.000

[1]Including 42 cases of hepatitis B virus and 2 cases of hepatitis C virus carriers. AFP: α-fetoprotein.

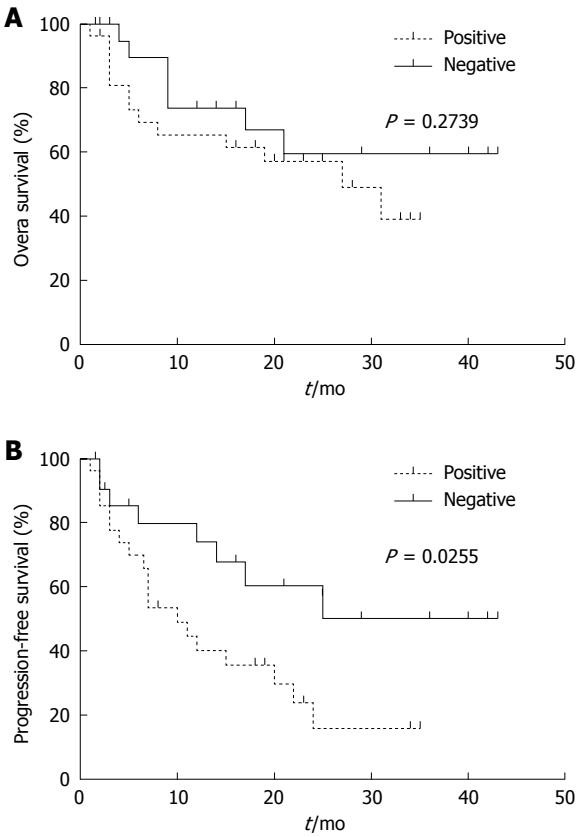

Figure 5 Overall (A) and progression-free (B) survival analysis of patients with different *DKK3* methylation levels.

study, although *DKK2* methylation occurred in tumor and corresponding cirrhosis tissue samples with a similar frequency (Table 1), the methylation level of *DKK2* was obviously higher in tumor tissue samples than in its adjacent cirrhosis tissue samples (Figure 2), indicating that methylation of *DKK2* may accumulate with the development of HCC. Interestingly, the *DKK2* methylation level was higher in cirrhotic biopsy samples than in HCC tissue samples with no statistical significance, possibly due to the aberrant methylation in fibroblasts and stromal cells of cirrhotic biopsies[17].

In contrast to *DKK1* and *DKK2*, *DKK3* is methylated in a tumor-specific manner during hepatocarcinogenesis. In our study, *DKK3* methylation occurred more frequently in HCC tissue samples than in cirrhosis tissue samples and the *DKK3* methylation level was also dramatically higher in HCC tissue samples than in cirrhosis tissue samples, indicating that *DKK3* promoter methylation may be an important event in the hepatocellular transformation from a cirrhotic background. Hsieh *et al*[18] found that DKK3 expression level is lower in human hepatoma tissue samples than in noncancerous liver tissue samples. It is thus reasonable to postulate that methylation and subsequently epigenetic inactivation of *DKK3* gene may play an important role in hepatocarcinogenesis.

Although distinct methylation patterns of *DKK3* were observed in HCC tissue samples and its adjacent liver cirrhosis tissue samples, no significant difference in mRNA expression was observed between the methylated and unmethylated groups. Similar results showing a lack of clear inverse correlation between the methylation and gene expression data have also been observed[19]. HCC tissue is very heterogeneous and our tissue samples were not microdissected to remove contaminated normal cells. The presence of a substantial amount of normal tissue in specimens prevents an exact assessment of the gene inactivation effects of CpG island hypermethylation. Gene expression in normal stromal and epithelial cells can mask a lack of expression in a subset of cells with CpG island hypermethylation[19]. Therefore, analysis of aberrant DNA hypermethylation is advantageous over gene expression analysis in that it has a greater sensitivity in the presence of contaminated normal cells[19].

The potential values of *DKK* gene methylation were further assessed in our study for clinical diagnosis purpose. The distinct methylation patterns of *DKK* gene (methylation frequencies or levels) in benign and malignant tissues are the prerequisite to determine a certain gene methylation as an effective molecular biomarker. Therefore, in addition to comparison of methylation frequencies in tumor and non-tumor groups, we further evaluated the discriminatory ability of quantitative methylation levels (PMR values) to distinguish HCC tissue from liver cirrhosis tissue using ROC analysis. Our results showed that the PMR values of *DKK3* could discriminate HCC from liver cirrhosis with high sensitivity and specificity (Figure 4), suggesting that *DKK3* methylation in combination with other diagnostic tools, may be a promising epigenetic biomarker for early detection of HCC.

It has been reported that aberrant *DKK3* methylation is a major event in early and late liver malignant trans-

Table 3 Cox regression model of progression-free survival

	Univariate analysis			Multivariate analysis[1]		
	RR	95% CI	*P*	RR	95% CI	*P*
Tumor size (cm)						
> 5.0	3.653	1.085-12.304	0.036	3.345	1.312-8.526	0.011
≤ 5.0	1			1		
Portal vein invasion						
Positive	2.657	1.023-6.900	0.045	3.188	1.294-7.852	0.012
Negative	1			1		
DKK3 methylation						
Positive (PMR > 1%)	2.370	0.965-5.823	0.060	2.527	1.063-6.008	0.036
Negative (PMR ≤ 1%)	1			1		
AFP (ng/mL)						
> 400	1.829	0.759-4.409	0.179			-
≤ 400	1					
Age (yr)						
> 55	1.552	0.569-4.234	0.391			-
≤ 55	1					
Number of tumor						
Multiple	0.922	0.280-3.036	0.893			-
Single	1					

[1]Only the variables with *P* values less than 0.05 are included in the equation. RR: Relative risk.

formation and may constitute a critical target for risk assessment, treatment, and chemoprevention of HCC[20]. Therefore, another major question addressed in the present study concerns the prognostic value of *DKK3* methylation in human HCC. In the present study, progression-free survival analysis showed that patients with *DKK3* methylation tended to have relapse or metastasis shortly after resection (Figure 5). Multivariate Cox regression analysis further confirmed that *DKK3* methylation was an independent prognostic indicator (Table 3). Interestingly, the number of tumors (single or multiple) was the only clinicopathological variable associated with *DKK3* methylation in this study. HCC is prone to multicentric occurrence, and some other tumor suppressor genes are specifically methylated in multicentric HCC and can act as clonal markers[21]. Epigenetic inactivation of genes associated with multicentric occurrence may play an important role in the relapse or progression of HCC, thus patients with a high *DKK3* methylation level can represent a subset of poor prognosis after surgical resection. Our results showed that a high *DKK3* methylation level may serve as a potential prognostic factor for HCC. However, since the number of patients in the present study was relatively small, the prognostic significance of *DKK3* methylation levels needs to be further investigated in a larger cohort of patients with a longer follow-up period.

In conclusion, methylation of *DKK3* is an important event during early malignant transformation and progression of HCC, thus representing a prognostic indicator for risk assessment of HCC.

COMMENTS

Background

Aberrant promoter hypermethylation of tumor suppressor genes is very common in human cancers. It not only presents one of the important mechanisms in carcinogenesis, but also severs as a type of promising biomarkers for the diagnosis or prognosis of cancer patients.

Research frontiers

Dickkopf (DKK) family is one class of the secreted Wnt antagonists. Its functional loss can contribute to activation of the Wnt pathway and result in carcinogenesis. Inactivation of Wnt antagonist genes and its epigenetic mechanism have been recently characterized in many cancers. However, few reports are available on the epigenetic silencing of *DKK* gene and its clinical significance in hepatocellular carcinoma (HCC).

Innovations and breakthroughs

Using quantitative methylation-specific polymerase chain reaction (Q-MSP) technology, the authors investigated the prevalence and time of DKK family methylation in adequate tumor tissue and biopsy samples. The results of this study demonstrate that methylation of *DKK3* is an important event during early malignant transformation and progression of HCC, thus representing a prognostic indicator for risk assessment of HCC.

Applications

DKK3 methylation was identified as a specific epigenetic event involving hepatocellular transformation at cirrhosis stage, which not only provides a clue to the molecular basis of hepatocarcinogenesis, but also offers a potentially useful marker for the early diagnosis or prognosis of HCC.

Terminology

Percent of methylated reference (PMR) is calculated by dividing the *GENE/ACTB* ratio in a sample by the *GENE/ACTB* ratio in SssI-treated DNA and multiplied by 100. The normalization performed to obtain PMR can simplify the cross-gene comparison, since the data range 0-100.

Peer review

This is a very well-written paper trying to find anomalies in genes and their functions that may contribute to the prognostication and differential diagnosis of HCC with dysplastic nodules.

REFERENCES

1 **Fung SK**, Lok AS. Management of patients with hepatitis B virus-induced cirrhosis. *J Hepatol* 2005; **42** Suppl: S54-S64

2 **El-Serag HB**, Rudolph KL. Hepatocellular carcinoma: epidemiology and molecular carcinogenesis. *Gastroenterology* 2007; **132**: 2557-2576

3 **Jemal A**, Siegel R, Ward E, Hao Y, Xu J, Murray T, Thun MJ. Cancer statistics, 2008. *CA Cancer J Clin* 2008; **58**: 71-96

4 **Rivenbark AG**, Coleman WB. The use of epigenetic biomarkers for preclinical detection of hepatocellular carcinoma: potential for noninvasive screening of high-risk populations. *Clin Cancer Res* 2007; **13**: 2309-2312

5 **Laurent-Puig P**, Zucman-Rossi J. Genetics of hepatocellular

tumors. *Oncogene* 2006; **25**: 3778-3786
6 **Herath NI**, Leggett BA, MacDonald GA. Review of genetic and epigenetic alterations in hepatocarcinogenesis. *J Gastroenterol Hepatol* 2006; **21**: 15-21
7 **Niehrs C**. Function and biological roles of the Dickkopf family of Wnt modulators. *Oncogene* 2006; **25**: 7469-7481
8 **Zitt M**, Untergasser G, Amberger A, Moser P, Stadlmann S, Zitt M, Müller HM, Mühlmann G, Perathoner A, Margreiter R, Gunsilius E, Ofner D. Dickkopf-3 as a new potential marker for neoangiogenesis in colorectal cancer: expression in cancer tissue and adjacent non-cancerous tissue. *Dis Markers* 2008; **24**: 101-109
9 **Ding Z**, Qian YB, Zhu LX, Xiong QR. Promoter methylation and mRNA expression of DKK-3 and WIF-1 in hepatocellular carcinoma. *World J Gastroenterol* 2009; **15**: 2595-2601
10 **Lou C**, Du Z, Yang B, Gao Y, Wang Y, Fang S. Aberrant DNA methylation profile of hepatocellular carcinoma and surgically resected margin. *Cancer Sci* 2009; **100**: 996-1004
11 **Eads CA**, Lord RV, Wickramasinghe K, Long TI, Kurumboor SK, Bernstein L, Peters JH, DeMeester SR, DeMeester TR, Skinner KA, Laird PW. Epigenetic patterns in the progression of esophageal adenocarcinoma. *Cancer Res* 2001; **61**: 3410-3418
12 **Schmittgen TD**, Livak KJ. Analyzing real-time PCR data by the comparative C(T) method. *Nat Protoc* 2008; **3**: 1101-1108
13 **Nishida N**, Nagasaka T, Nishimura T, Ikai I, Boland CR, Goel A. Aberrant methylation of multiple tumor suppressor genes in aging liver, chronic hepatitis, and hepatocellular carcinoma. *Hepatology* 2008; **47**: 908-918
14 **Aguilera O**, Fraga MF, Ballestar E, Paz MF, Herranz M, Espada J, García JM, Muñoz A, Esteller M, González-Sancho JM. Epigenetic inactivation of the Wnt antagonist DICKKOPF-1 (DKK-1) gene in human colorectal cancer. *Oncogene* 2006; **25**: 4116-4121
15 **Lee J**, Yoon YS, Chung JH. Epigenetic silencing of the WNT antagonist DICKKOPF-1 in cervical cancer cell lines. *Gynecol Oncol* 2008; **109**: 270-274
16 **Suzuki R**, Onizuka M, Kojima M, Shimada M, Fukagawa S, Tsuboi K, Kobayashi H, Shintani A, Ogawa Y, Kawada H, Hotta T, Ando K. Preferential hypermethylation of the Dickkopf-1 promoter in core-binding factor leukaemia. *Br J Haematol* 2007; **138**: 624-631
17 **Harder J**, Opitz OG, Brabender J, Olschewski M, Blum HE, Nomoto S, Usadel H. Quantitative promoter methylation analysis of hepatocellular carcinoma, cirrhotic and normal liver. *Int J Cancer* 2008; **122**: 2800-2804
18 **Hsieh SY**, Hsieh PS, Chiu CT, Chen WY. Dickkopf-3/REIC functions as a suppressor gene of tumor growth. *Oncogene* 2004; **23**: 9183-9189
19 **Eads CA**, Lord RV, Kurumboor SK, Wickramasinghe K, Skinner ML, Long TI, Peters JH, DeMeester TR, Danenberg KD, Danenberg PV, Laird PW, Skinner KA. Fields of aberrant CpG island hypermethylation in Barrett's esophagus and associated adenocarcinoma. *Cancer Res* 2000; **60**: 5021-5026
20 **Calvisi DF**, Ladu S, Gorden A, Farina M, Lee JS, Conner EA, Schroeder I, Factor VM, Thorgeirsson SS. Mechanistic and prognostic significance of aberrant methylation in the molecular pathogenesis of human hepatocellular carcinoma. *J Clin Invest* 2007; **117**: 2713-2722
21 **Nomoto S**, Kinoshita T, Kato K, Otani S, Kasuya H, Takeda S, Kanazumi N, Sugimoto H, Nakao A. Hypermethylation of multiple genes as clonal markers in multicentric hepatocellular carcinoma. *Br J Cancer* 2007; **97**: 1260-1265

S- Editor Tian L **L- Editor** Wang XL **E- Editor** Lin YP

World Journal of Gastroenterology

Online Submissions: http://www.wjgnet.com/1007-9327office
wjg@wjgnet.com
doi:10.3748/wjg.v16.i6.764

World J Gastroenterol 2010 February 14; 16(6): 764-769
ISSN 1007-9327 (print)

BRIEF ARTICLE

Therapy and prognostic features of primary clear cell carcinoma of the liver

Sheng-Pu Ji, Qiang Li, Hui Dong

Sheng-Pu Ji, Qiang Li, Hui Dong, Department of Hepatobiliary Surgery, Cancer Hospital of Tianjin Medical University, Tianjin 300060, China
Author contributions: Ji SP performed the research and wrote the paper; Li Q analyzed and interpreted the data; Dong H contributed the new analytic tools.
Correspondence to: Qiang Li, PhD, Professor, Department of Hepatobiliary Surgery, Cancer Hospital of Tianjin Medical University, Huanhu Western Road, Hexi District, Tianjin 300060, China. jishengpu_2007@qq.com
Telephone: +86-22-23340123-3051 Fax: +86-22-23359984
Received: November 7, 2009 Revised: December 10, 2009
Accepted: December 17, 2009
Published online: February 14, 2010

Abstract

AIM: To clarify the therapeutic strategies and prognosis factors of primary clear cell carcinoma of the liver (PCCCL).

METHODS: The clinical pathological data of 64 patients with PCCCL treated with hepatectomy in our hospital from January 2000 to January 2006 were analyzed retrospectively. The patients were divided into two groups to make treatment analysis: curative resection only (n = 40); and curative resection and postoperative chemotherapy with calcium folinate and tegafur (n = 24). Meanwhile, the PCCCL patients were subdivided into two subgroups on the basis of the proportion of clear cells in the tumor for pathological analysis. There were 36 cases in subgroup A for which the proportion of clear cells was more than 70%, and 28 cases in subgroup B for which the proportion was less or equal to 70%, comparing analysis of median survival time of the counterpart groups. Univariate and multivariate analyses were performed to examine factors that affected clinical prognosis, recurrence and metastasis.

RESULTS: Median survival period of the curative surgery group was 38 mo, while the counterpart was 41 mo. Median survival period for group A was 41 mo, while group B was 19 mo. The Kaplan-Meier method showed that capsule formation, preoperative liver function, hepatitis C virus infection, large vascular invasion and multiple tumor occurrences were related to disease-free survival. Cox regression analysis showed that the clear cell ratio, capsule formation, preoperative liver function and large vascular invasion were independent risk factors for overall survival.

CONCLUSION: Postoperative chemotherapy has no obvious effect on survival of patients with PCCCL. Clear cell ratio, capsule formation, preoperative liver function, and vascular invasion were independent risk factors for prognosis.

Key words: Clear cell carcinoma; Hepatectomy; Prognosis; Treatment; Risk factor

Peer reviewers: Martin K Schilling, MD, FRCS, Professor of Surgery, Chairman, Department of General, Visceral, Vascular and Pediatric Surgery, University of Saarland, Kirrbergerstrasse, Homburg, D-66424, Germany; Takashi Kobayashi, MD, PhD, Department of Surgery, Showa General Hospital, 2-450 Tenjincho, Kodaira, Tokyo 187-8510, Japan

Ji SP, Li Q, Dong H. Therapy and prognostic features of primary clear cell carcinoma of the liver. *World J Gastroenterol* 2010; 16(6): 764-769 Available from: URL: http://www.wjgnet.com/1007-9327/full/v16/i6/764.htm DOI: http://dx.doi.org/10.3748/wjg.v16.i6.764

INTRODUCTION

Hepatocellular carcinoma (HCC) is a major cause of cancer mortality worldwide and is increasing in incidence; driven largely by the growing hepatitis B and hepatitis C epidemics[1,2], which comprise approximately 75% of all HCC and liver cirrhosis (70%-80% of all cases)[3,4]. Surgical resection has long been the only curative treatment;

conventional chemotherapy and radiotherapy are ineffective for HCC[5]. Despite recent advances in diagnostic and therapeutic modalities, prognosis is usually poor, particularly in patients with coexisting liver cirrhosis. Survival rates are 3%-5% in cancer registries for the United States and developing countries. In total, 55% of cases (and deaths) are in China alone[6]. Many investigations have suggested that tumor size, number of nodules, vascular invasion, tumor encapsulation, blood transfusion, high α-fetoprotein (AFP) level, and resection margin status are the main prognostic factors associated with the postoperative recurrence of HCC[7].

Primary clear cell carcinoma of liver (PCCCL) is a particular histological type of HCC, PCCCL is not frequent and has been reported to account for 7.5%-12.5% of all liver cancer cases[8]. Microscopically, all cases of PCCCL show moderate to marked cytoplasmic accumulation of glycogen and/or macro- and microvascular intracytoplasmic fat droplets that dissolve during hematoxylin-eosin (HE) staining, which leaves behind a clear cytoplasm. Generally, the tumor cells are mainly in the mid-range degree of differentiation, and low-grade malignancy. PCCCL usually has capsule formation and is localized. Surgical resection is the most promising therapeutic method for PCCCL. The outcome for patients with PCCCL is better than for those with common type counterparts, and survival improves with an increasing proportion of clear cells[9,10]. Treatment and prognosis of PCCCL are reported rarely in the literature. Also, treatment and clinical prognostic features are not fully clarified.

MATERIALS AND METHODS

Subjects

The participants of this study were 64 patients [40 male, 24 female (ratio 1.67:1), aged 23-73 years, mean 55.16 ± 10.56 years], who received curative hepatic resection for PCCCL at the Tianjin Medical University Cancer Hospital between January 2000 and January 2006. We used the diagnostic criteria generally accepted by pathologists in China to diagnose PCCCL as follows: (1) only when it contained > 50% clear cells; (2) exception for metastatic clear cell carcinoma from other organs; and (3) diagnosis by more than two pathologists. A total of 64 patients were eligible for this study.

Treatment method

All 64 patients underwent surgical tumor resection. Anatomical resection included hemi-hepatectomy, segmentectomy and sub-segmentectomy, based on Child-Pugh classification. Resection margin was 1 cm beyond the tumor, and surgical margins were negative when examined by the pathologists. Clear cell ratio, large vascular invasion (large blood vessels including the portal vein, hepatic vein and/or first level branch), and lymph node metastasis were confirmed by pathology.

Patients with PCCCL who had undergone their first curative hepatic resection at the Cancer Hospital of Tianjin Medical University were eligible for postoperative adjuvant chemotherapy if they met the following entry criteria: (1) absence of detectable residual or recurrent tumors at 1 mo after curative resection; (2) age < 70 years; (3) liver function belonging to Child A or B class; (4) absence of severe cardiac complications; and (5) general health satisfactory for toleration of the contemplated chemotherapy. The exclusion criteria were the presence of clinically confirmed extrahepatic metastasis, macroscopic evidence of tumor thrombus in the inferior vena cava or the main portal vein, other previous or synchronous malignant disorders, and postoperative dysfunction of any organ. Finally 24 patients were considered as suitable candidates for our studies.

Postoperative chemotherapy of 24 cases consisted of calcium folinate and tegafur. Calcium folinate was administered at a starting dose of 200 mg/m^2, as a continuous intravenous infusion over 2 h on days 1-5. Tegafur was administered at a starting dose of 850 mg/m^2 given intravenously over 3 h on days 1-5. Adequate intravenous hydration and antiemetic therapy were routinely administered. Chemotherapy courses were repeated every 21 d, provided patients recovered from all toxic effects. Based on the predetermined criteria of toxicity grades, the doses of chemotherapy drugs were increased or decreased by 25%. Criteria for dose reduction included development of grade 3 non-hematological toxicity or grade 4 hematological toxicity. Complete blood, differential, and platelet counts were evaluated at least once weekly and more frequently when patients were myelosuppressed during the rest period. Serum creatinine, blood urea nitrogen, electrolyte, and magnesium levels were monitored regularly during each course.

Survival analysis methods

The prognostic factors were examined in cumulative and disease-free survival, using the following variables: age (older or younger than 50 years); sex (male *vs* female); serum hepatitis B virus (HBV) surface antigen (HBsAg) (negative *vs* positive); serum hepatitis C virus (HCV) antibody (HCVAb) (negative *vs* positive); proportion of clear cell more than *vs* less than or equal to 70%; tumor size (greater than *vs* less than or equal to 5.0 cm); liver cirrhosis (negative *vs* positive); serum levels of AFP (greater than *vs* less than or equal to 200 ng/mL); operative procedures (anatomical *vs* non-anatomical resection); lymph node metastases (negative *vs* positive); vessel invasion (negative *vs* positive); Child-Pugh classification (Grade A *vs* Grade B or C); capsule formation (negative *vs* positive); number of nodules (solitary *vs* multiple); therapeutic strategies (curative resection *vs* curative resection and postoperative chemotherapy); TNM staging (Ⅰ , Ⅱ *vs* Ⅲ, Ⅳ).

Follow-up

All patients were followed up to January 2009, or up to the time of death; all patients were followed up for > 3 years. Patients were examined regularly with measurement of the serum AFP level, hepatic ultrasonography and chest radiography every month after surgical resection to check

metastasis and recurrence. Six months later, we examined serum AFP level, hepatic ultrasonography and chest radiography every 3 mo. When recurrence was suspected, further evaluations were made by abdominal, chest and brain enhanced computed tomography (CT), if necessary, by ultrasound-guided biopsy or positive electron tomography/CT examination to confirm the diagnosis. Patients who died of another disease were lost to follow-up.

Statistical analysis

Differences in the means were assessed with the χ^2 test. The cumulative survival and the life table and Kaplan-Meier method, calculated recurrence-free survival rates and the difference between the two groups was analyzed by the log-rank test. The survival curve was described using the Kaplan-Meier method. Cox regression (proportional hazard model) was adopted for the multivariate analysis of prognostic factors. Statistical software package SPSS 13.0 (SPSS Inc., Chicago, IL, USA) was employed for all of the analyses. *P* values less than 0.05 were considered statistically significant. SPSS 13.0 was employed for all of the analyses.

RESULTS

In 36 cases (56.25%), the proportion of clear cells was > 70%; 46 cases (71.88%) were positive for HBsAg, 10 cases (14%) were positive for HCVAb, and six cases (9.32%) were negative for both HBsAg and HCVAb. Fifty-six patients had liver cirrhosis (87.50%). In 50 patients, tumor diameter was > 5.0 cm (78.13%). In 26 patients, serum AFP level was > 200 ng/mL (40.63%). Forty-four patients had a solitary tumor (68.75%); 30 had large vessel invasion (46.86%); 12 had lymph node metastasis (18.75%); 24 received postoperative chemotherapy with calcium folinate and tegafur (37.50%); and 40 received curative hepatic resection without chemotherapy (62.50%). The liver function was evaluated using Child-Pugh classification. Forty patients had grade A liver function (62.50%), 21 (32.81%) had grade B, and three (4.69%) had grade C. Forty-six patients had tumor capsule formation (71.88%). Pathological stage of PCCCL was evaluated using TNM staging. Three patients had stage Ⅰ, nine had stage Ⅱ, 40 patients had stage Ⅲ, and two had stage Ⅳ.

Postoperative follow-up

Seventeen patients suffered intrahepatic recurrence during follow-up; extra-hepatic metastasis occurred in 13 cases, and six patients suffered metastasis and recurrence. One patient in the curative surgical group died of perioperative complications, which resulted in a perioperative mortality of 1.56% (1/64). One patient died from traffic accidents, and two from the resection and postoperative chemotherapy group missed postoperative follow-up. After excluding the perioperative deaths and the missing patients, the postoperative cumulative and disease-free survival rates at 1, 3 and 5 years were 78.13%, 49.88% and 37.50% (mean ± SD, 41.56 ± 3.72 mo; median, 39.6 mo) and 71.82%, 40.63% and 25.00% (mean ± SD, 34.56 ± 3.93 mo; median, 33.0 mo), respectively. Median survival period in the curative surgical group was 38 mo, and 41 mo in its counterpart. There was no statistical significance in the survival time between the two groups (χ^2 = 0.196, *P* = 0.658). The survival curves are shown in Figure 1. Median survival period of the group with > 70% clear cells was 41 mo, and 29 mo in its counterpart. The proportion of clear cells had an obvious effect on the median survival period of patients (χ^2 = 7.432, *P* = 0.006). The survival curves are shown in Figure 2. The prognosis of the patients with a higher proportion of clear cells was better than that in patients with a lower proportion of clear cells.

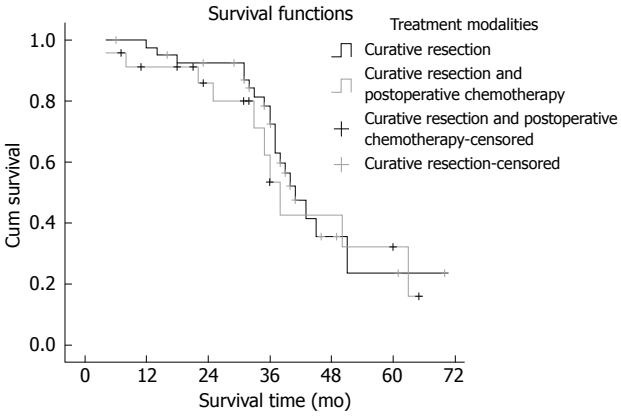

Figure 1 Comparison of survival rates of different treatment modalities.

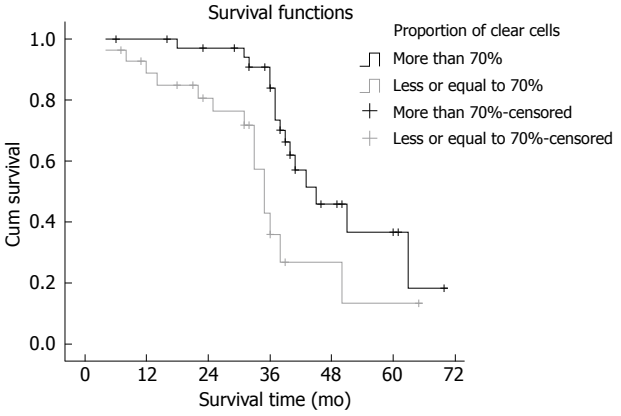

Figure 2 Comparison of survival of patients with different percentage of clear cells.

Prognostic analyses

Univariate and multivariate analyses: For the univariate analysis, age, sex, serum HBsAg, serum HCVAb, tumor diameter, vascular invasion, capsule formation, background of liver cirrhosis, serum AFP level, Child-Pugh classification, vascular invasion, proportion of clear cells, and lymph node metastases were included. We found that the parameters of vascular invasion, capsule formation, background of liver cirrhosis, number of nodules, proportion of clear cells, and Child-Pugh classification were statistically significant in cumulative survival (Table 1).

Table 1 Univariate analysis of clinicopathological variables associated with the prognosis of PCCCL

Parameters	Cases	Median survival time (95% CI) (mo)	χ^2-value	*P*-value
AFP range (ng/mL)				
≥ 200	26	31 (27.302-34.698)	1.413	0.285
< 200	38	49 (42.211-55.789)		
Liver cirrhosis (+)				
Positive	56	31 (28.013-33.987)	6.032	0.014
Negative	8	43 (38.303-47.697)		
Capsule formation				
Positive	46	61 (53.106-68.894)	10.241	0.001
Negative	18	19 (16.690-21.310)		
Number of nodules				
Single	44	61 (53.014-68.986)	4.028	0.045
Multiple	20	11 (9.675-12.325)		
Child-Pugh classification				
A	35	60 (51.023-68.977)	11.330	0.003
B or C	21	25 (23.302-28.698)		
Vascular invasion				
Positive	30	27 (23.346-30.654)	11.755	0.001
Negative	34	41 (35.437-46.563)		
lymph node metastases				
Positive	12	31 (26.012-35.988)	0.023	0.880
Negative	52	40 (37.342-44.658)		
TNM staging				
Ⅰ, Ⅱ	12	43 (39.211-46.789)	16.192	0.001
Ⅲ, Ⅳ	52	27 (25.371-28.629)		
Proportion of clear cells				
≥ 70%	36	41 (35.535-46.465)	7.342	0.006
< 70%	28	19 (16.964-21.036)		

PCCCL: Primary clear cell carcinoma of the liver.

Table 2 Multivariate analysis of clinicopathological variables associated with the prognosis of PCCCL

Parameters	Regression coefficient	Wald value	*P* value	RR (95% CI)
Proportion of clear cells	1.409	6.898	0.009	4.090 (1.430-11.702)
Capsule formation	-1.364	5.172	0.023	0.256 (0.079-0.828)
Vascular invasion	1.686	9.923	0.002	5.395 (1.890-15.398)
Child-Pugh classification	1.917	4.119	0.042	6.798 (3.253-17.334)

Then, the parameters of significances were all contained in the Cox regression analysis. Using the Cox regression analysis, four clinic pathological variables were shown to have potential of predicting overall or disease-free survival of PCCCL patients, including rate of capsule formation, vascular invasion, Child-Pugh classification, and proportion of clear cells (Table 2).

Cumulative recurrence-free survival rates and disease-free prognosis: The life table and Kaplan-Meier method, calculated the cumulative recurrence-free survival rates and the difference between two groups were analyzed by the log-rank test. The 1-, 3- and 5-year disease-free survival rates were 71.82%, 40.63% and 25.00% (mean ± SD, 34.56 ± 3.93 mo; median, 33.0 mo). Kaplan-Meier univariate analysis showed that the disease-free prognosis of the patients with capsule formation, better liver function, negative HCVAb, no vascular invasion, and solitary tumor were better than the patients with no capsule formation, poor liver function, positive HCVAb, vascular invasion and multiple tumors. Patients with no capsule formation, poor liver function, positive HCVAb, vascular invasion and multiple tumors were prone to metastasis and/or recurrence.

DISCUSSION

PCCCL is a particular and relatively rare histological type of HCC. Microscopically, it is similar to the clear cell cancers (kidney, ovarian or adrenal), which makes it difficult to differentiate from the metastatic clear cell cancers of the liver. Murakata *et al*[11] have recommended hepatocyte antibody as a screening immunostain in working up a clear cell tumor in the liver when diagnostic histological criteria of HCC are absent. In this setting, it distinguishes PCCCL from other clear cell malignancies with a sensitivity of 90% and specificity of 100%. Some other studies have indicated *in situ* hybridization for albumin mRNA as a useful method to distinguish PCCCL from other clear cell tumors metastasizing to the liver[12]. In the present study, we made the diagnosis using features that point toward the diagnosis of HCC. This study integrated the patient's pathological features, biopsy, and clinical manifestations, imaging studies, endoscope bile stasis and postoperative long-term follow-up to make a clear diagnosis[4,13]. There was no misdiagnosis in our study. Some authors consider < 30% of clear cells within the tumor as sufficient[9], whereas others diagnose PCCCL when the tumor contains > 30% clear cells, however, tumors with clear cells ranging from 90% to 100% are extremely rare[14]. We used the diagnostic criteria generally accepted by pathologists in China to diagnose PCCCL, that is, only when it contained > 50% clear cells[10]. In our further studies, we formed a group according to whether the clear cell count was 70% of all cells. We found that the group with > 70% clear cells had significantly longer survival (χ^2 = 7.432, P = 0.006). This shows that the prognosis was related to the proportion of clear cells. The greater the number of clear cells, the better the prognosis.

Surgical resection is an effective way to achieve favorable outcomes and long-term survival of patients with PCCCL. Lao *et al*[15] have reported 1- and 3-year survival rates of 76.5% (13/18) and 47.1% (8/18), in all 13 surgical resection patients; the longest survival was 97 mo, and surgical resection was an effective treatment to achieve long-term survival. Compared with HCC, PCCCL has a slower development process, good differentiation, lower grade malignancy, and easier capsule formation, therefore, the tumor is more limited and prone to resection. Surgical resection is the most important means of achieving long-term survival. If there is recurrence after resection, tumor re-resection is possible, but if it cannot be removed, development is slower than for HCC. In the present study, there were 24 patients in the surgical resection and chemotherapy

group; the median survival period was 38.2 mo, and the median survival of the curative surgical resection group was 39.1 mo. The difference between these two groups was not significant ($\chi^2 = 0.196$, $P = 0.658$), which indicated that postoperative adjuvant chemotherapy with calcium folinate and tegafur was not sensitive to PCCCL and had no obvious effect on the survival time of patients. Other postoperative chemotherapy regimens for PCCCL were not investigated in this study. The prognosis of patients with postoperative chemotherapy requires further study.

Pecorella *et al*[16] have reported that a 35-year-old patient who was treated with liver transplantation survived for 17 mo, which was lower than the median survival in our study. Emile *et al*[17] have shown that prognosis was better in a large series of transplanted Caucasian patients with PCCCL than in those with other liver malignancies. In the present study, the prognosis of patients with surgical resection was better than for HCC, which may be related to better tumor differentiation, capsule formation, less vascular invasion and lymph node metastasis, and high resectability rate. The prognosis of patients with PCCCL is still controversial. Many studies have reported PCCCL has better prognosis than other HCCs[8,18]. Lai *et al*[9] have reported that the outcome for patients with PCCCL is better than those with common-type cancers, and survival improves with an increasing proportion of clear cells. Conversely, other investigators have found that the prognosis of patients with PCCCL is similar to that of their common-type counterparts and perhaps even worse[19,20]. Yang *et al*[14] have reported that the 3- and 5-year survival rate was 54.5% and 33.3%, respectively, which was slightly lower than the rate for non-PCCCL patients (including HCC). However, all these data failed to disclose any statistical significance, or were not statistically analyzed according to the number of cases. Our study confirmed the former results in a series of postoperative patients, and showed significantly higher 1-, 3- and 5-year survival rates in PCCCL patients. The Kaplan-Meier method showed that capsule formation, preoperative liver function, HCV infection, large vascular invasion and multiple tumor occurrences were related to disease-free survival. The prognosis of patients in the PCCCL group was related to clear cell ratio, preoperative liver function, liver cirrhosis, HCV infection, capsule formation, large vascular invasion and multiple tumor occurrences. In this study, lymph node metastasis did not significantly affect survival, which may have been related to the comparatively small number of cases in this study, therefore, we need to increase the number of sample cases for further study. Cox multivariate analysis showed that clear cell ratio, capsule formation, preoperative liver function and large vascular invasion were independent risk factors for survival. In this study, capsule formation of PCCCL was different from the clinical characteristics of HCC. Capsule formation may limit tumor growth and spread and is conducive to tumor resection and treatment. Lower malignancy and better differentiation of clear cells may have contributed to the improved prognosis. The higher the proportion of clear cells, the better was the prognosis. Preoperative Child-Pugh classification was an independent risk factor for survival. High HCV prevalence led to poor liver function and shorter survival.

In summary, postoperative chemotherapy with calcium folinate and tegafur had no obvious effect on survival time of patients with PCCCL. Patients with a high clear cell ratio had improved prognosis. Capsule formation, poor preoperative liver function, HCV infection, large vascular invasion, and multiple tumor occurrence were risk factors for metastasis and postoperative recurrence of PCCCL. Patients with capsule formation, no large vascular invasion, high clear cell ratio, and better liver function had improved prognosis.

ACKNOWLEDGMENTS

The authors thank Dr. Young Tang, Department of Pancreatic Oncology, Cancer Hospital of Tianjin Medical University, for help in preparing the manuscript and the statistical analysis.

COMMENTS

Background

Primary clear cell carcinoma of the liver (PCCCL) is a type of primary hepatocellular carcinoma (HCC), which is characterized pathologically by diffuse clear cells of the tumor, and a clear cytoplasm that does not stain with hematoxylin-eosin. At present, treatment and prognosis of PCCCL have not been reported widely in the literature. Its treatment and clinical prognostic features have not been fully clarified.

Research frontiers

PCCCL is a particular histological type of HCC; PCCCL is not frequent and has been reported to account for 7.5%-12.5% of all liver cancer cases. Treatment and clinical prognostic features have not been fully clarified. The research hot topics are how to treat PCCCL, and its independent prognostic risk factors. Surgical resection is an effective way to achieve favorable outcomes and long-term survival of patients with PCCCL.

Innovations and breakthroughs

Previously, there have been more case studies of PCCCL, and large sample studies have been rare. The present study found that postoperative chemotherapy with calcium folinate and tegafur had no obvious effect on patient survival. The study found that the higher the proportion of clear cells, the better the prognosis. The authors also found that the clear cell ratio, capsule formation, preoperative liver function, and vascular invasion were independent prognostic risk factors, which had not been reported previously.

Applications

The study results suggest that postoperative chemotherapy with calcium folinate and tegafur has no obvious effect on patient survival. Surgical resection is an effective way to achieve favorable outcomes and long-term survival of patients with PCCCL.

Terminology

Hepatectomy is a treatment approach that involves the surgical removal of part or all of the liver for therapeutic purposes. Postoperative chemotherapy is the use of certain drugs to further treat cancer after surgery according to certain symptoms and physical signs.

Peer review

This is a good retrospective study which analyzed therapeutic strategies for patients with PCCCL, who were undergoing liver resection. The authors operated on 64 patients with this infrequent type of HCC within the past 6 years. The major oncological and surgical issues are discussed in the introduction and discussion.

REFERENCES

1 **Chin'ombe N**, Chavhunduka E, Matarira HT. Seroprevalence of HBV and HCV in primary hepatocellular carcinoma patients in Zimbabwe. *Infect Agent Cancer* 2009; **4**: 15

2 **Barazani Y**, Hiatt JR, Tong MJ, Busuttil RW. Chronic viral hepatitis and hepatocellular carcinoma. *World J Surg* 2007; **31**: 1243-1248

3 **But DY**, Lai CL, Yuen MF. Natural history of hepatitis-related hepatocellular carcinoma. *World J Gastroenterol* 2008; **14**: 1652-1656

4 **Tan A**, Yeh SH, Liu CJ, Cheung C, Chen PJ. Viral hepatocarcinogenesis: from infection to cancer. *Liver Int* 2008; **28**: 175-188

5 **Avila MA**, Berasain C, Sangro B, Prieto J. New therapies for hepatocellular carcinoma. *Oncogene* 2006; **25**: 3866-3884

6 **Parkin DM**, Bray F, Ferlay J, Pisani P. Global cancer statistics, 2002. *CA Cancer J Clin* 2005; **55**: 74-108

7 **Qiang L**, Huikai L, Butt K, Wang PP, Hao X. Factors associated with disease survival after surgical resection in Chinese patients with hepatocellular carcinoma. *World J Surg* 2006; **30**: 439-445

8 **Takahashi A**, Saito H, Kanno Y, Abe K, Yokokawa J, Irisawa A, Kenjo A, Saito T, Gotoh M, Ohira H. Case of clear-cell hepatocellular carcinoma that developed in the normal liver of a middle-aged woman. *World J Gastroenterol* 2008; **14**: 129-131

9 **Lai CL**, Wu PC, Lam KC, Todd D. Histologic prognostic indicators in hepatocellular carcinoma. *Cancer* 1979; **44**: 1677-1683

10 **Liu JH**, Tsai HL, Hsu SM, Hu DH, Chen SS. Clear cell and non-clear cell hepatocellular carcinoma: a case report and literature review. *Kaohsiung J Med Sci* 2004; **20**: 78-82

11 **Murakata LA**, Ishak KG, Nzeako UC. Clear cell carcinoma of the liver: a comparative immunohistochemical study with renal clear cell carcinoma. *Mod Pathol* 2000; **13**: 874-881

12 **Oliveira AM**, Erickson LA, Burgart LJ, Lloyd RV. Differentiation of primary and metastatic clear cell tumors in the liver by in situ hybridization for albumin messenger RNA. *Am J Surg Pathol* 2000; **24**: 177-182

13 **Kawagishi N**, Shirahata Y, Ishida K, Satoh K, Enomoto Y, Akamatsu Y, Sekiguchi S, Fukumori T, Fujimori K, Satoh A, Moriya T, Satomi S. Hepatic resection of giant metastatic tumor from clear cell carcinoma of the ovary. *J Hepatobiliary Pancreat Surg* 2005; **12**: 155-158

14 **Yang SH**, Watanabe J, Nakashima O, Kojiro M. Clinicopathologic study on clear cell hepatocellular carcinoma. *Pathol Int* 1996; **46**: 503-509

15 **Lao XM**, Zhang YQ, Jin X, Lin XJ, Guo RP, Li GH, Li JQ. Primary clear cell carcinoma of liver--clinicopathologic features and surgical results of 18 cases. *Hepatogastroenterology* 2006; **53**: 128-132

16 **Pecorella I**, Ciardi A, Aiello E, Piras MR, Farci C, Di Tondo U. Clear cell hepatocellular carcinoma treated with liver transplantation. *Pathologica* 1994; **86**: 307-310

17 **Emile JF**, Lemoine A, Azoulay D, Debuire B, Bismuth H, Reynès M. Histological, genomic and clinical heterogeneity of clear cell hepatocellular carcinoma. *Histopathology* 2001; **38**: 225-231

18 **Salvucci M**, Lemoine A, Saffroy R, Azoulay D, Lepère B, Gaillard S, Bismuth H, Reynès M, Debuire B. Microsatellite instability in European hepatocellular carcinoma. *Oncogene* 1999; **18**: 181-187

19 **Shah S**, Gupta S, Shet T, Maheshwari A, Wuntkal R, Mohandas KM. Metastatic clear cell variant of hepatocellular carcinoma with an occult hepatic primary. *Hepatobiliary Pancreat Dis Int* 2005; **4**: 306-307

20 **Adamek HE**, Spiethoff A, Kaufmann V, Jakobs R, Riemann JF. Primary clear cell carcinoma of noncirrhotic liver: immunohistochemical discrimination of hepatocellular and cholangiocellular origin. *Dig Dis Sci* 1998; **43**: 33-38

S- Editor Wang JL **L- Editor** Kerr C **E- Editor** Lin YP

World Journal of Gastroenterology

Online Submissions: http://www.wjgnet.com/1007-9327office
wjg@wjgnet.com
doi:10.3748/wjg.v16.i6.770

World J Gastroenterol 2010 February 14; 16(6): 770-777
ISSN 1007-9327 (print)

BRIEF ARTICLE

Treatment of hepatitis B virus-associated glomerulonephritis: A meta-analysis

Yu Zhang, Jian-Hua Zhou, Xiao-Ling Yin, Feng-Yu Wang

Yu Zhang, Jian-Hua Zhou, Xiao-Ling Yin, Feng-Yu Wang, Department of Pediatrics, Tongji Hospital, Tongji Medical College, Huazhong University of Science and Technology, Wuhan 430030, Hubei Province, China
Author contributions: Zhang Y designed the research, collected and analyzed the data and wrote the manuscript; Zhou JH designed the research and revised the manuscript; Yin XL and Wang FY participated in the data collection.
Supported by National Natural Science Foundation of China, No. 30772360
Correspondence to: Jian-Hua Zhou, Professor, Department of Pediatrics, Tongji Hospital, Tongji Medical College, Huazhong University of Science and Technology, Wuhan 430030, Hubei Province, China. jhzhou@tjh.tjmu.edu.cn
Telephone: +86-27-83663256 Fax: +86-27-83663256
Received: October 13, 2009 Revised: December 31, 2009
Accepted: January 7, 2010
Published online: February 14, 2010

Abstract

AIM: To evaluate the efficacy of antiviral or corticosteroid treatment on hepatitis B virus-associated glomerulonephritis (HBV-GN).

METHODS: Six and five trials were used respectively to evaluate the efficacy of either antiviral or corticosteroid treatment on HBV-GN. Pediatric patients were pooled separately to assess their response to the above treatment modalities. The primary and secondary outcomes were remission of proteinuria and clearance of Hepatitis B e-antigen (HBeAg), respectively. A fixed or random effect model was established to collect the data.

RESULTS: The remission rate of proteinuria (RR = 1.69, 95% CI: 1.08-2.65) and the clearance rate of HBeAg (RR = 6.44, 95% CI: 3.11-13.35) were significantly higher in antiviral treatment group than in control group. The proteinuria remission was significantly associated with HBeAg clearance (P = 0.002). However, the difference in proteinuria remission rate was not statistically significant between corticosteroid treatment group and control group (RR = 1.45, 95% CI: 0.68-3.11). Antiviral therapy could significantly promote the HBeAg clearance in pediatric patients, but neither antiviral nor corticosteroid therapy could significantly decrease proteinuria in pediatric patients compared to controls.

CONCLUSION: Antiviral but not corticosteroid treatment can decrease proteinuria and promote HBeAg clearance in HBV-GN patients.

Key words: Hepatitis B virus-associated glomerulonephritis; Drug therapy; Meta-analysis

Peer reviewer: Eva Herrmann, Professor, Department of Internal Medicine, Biomathematics Saarland University, Faculty of Medicine, Kirrberger Str., 66421 Homburg/Saar, Germany

Zhang Y, Zhou JH, Yin XL, Wang FY. Treatment of hepatitis B virus-associated glomerulonephritis: A meta-analysis. *World J Gastroenterol* 2010; 16(6): 770-777 Available from: URL: http://www.wjgnet.com/1007-9327/full/v16/i6/770.htm DOI: http://dx.doi.org/10.3748/wjg.v16.i6.770

INTRODUCTION

Hepatitis B virus-associated glomerulonephritis (HBV-GN) remains one of the most common secondary glomerular diseases in Chinese children, although its incidence seems to decrease nowadays after the popularization of HBV vaccination[1,2]. Most HBV-GN patients present with nephrotic syndrome and some show mild to moderate proteinuria with hematuria[3]. Although spontaneous remission has been reported in many pediatric patients[3], some still develop progressive renal failure[4-6]. Therefore, it is very important to attenuate proteinuria and slow down renal disease progression in HBV-GN patients.

HBV-GN is treated with either antiviral drugs including interferon, lamivudine, and entecavir or with corticosteroids

and even immunosuppressive agents like mycophenolate mofetil, leflunomide[7,8]. It has been shown that antiviral therapy can promote the clearance of HBV and improve the coexisting renal disease[3], but the efficacy of interferon on HBV-GN has not been confirmed[9,10]. Moreover, interferon therapy is not as successful for HBV-GN in children as for HBV-GN in adults[3]. Thus, the efficacy of antiviral therapy on HBV-GN remains to have been established, especially in pediatric patients. Corticosteroids are also used in treatment of some patients with nephrotic syndrome. However, it is argued that corticosteroid and immunosuppressive agents are unfavorable for HBV-GN since they inhibit the immune system and activate latent HBV, leading to active replication of HBV and deterioration of renal lesions[3,11]. So the efficacy of these treatment modalities on HBV-GN is still uncertain. Up to date, we are not sure if patients with HBV-GN can be treated with antiviral drugs alone and if nephrotic patients can be treated with corticosteroids.

Unfortunately, the data available in studies on HBV-GN treatment are limited and often provide inconsistent results, which can be explained by many factors like variable sample size, racial differences, disease variation as well as interference of other treatment. These inconsistencies can be solved by meta-analysis. In a meta-analysis[12] of antiviral therapy for HBV-GN published in 2006, 2 of the 6 trials included were non-controlled studies, other treatments like corticosteroids and pediatric patients were not analyzed. Thus, we performed a meta-analysis including just controlled trials to evaluate the effects of antiviral drugs and corticosteroids on HBV-GN both in adults and in children.

MATERIALS AND METHODS

Literature search

All eligible articles in English and Chinese published prior to November 2008 were searched from PubMed, EMBASE, Cochrane Library and CNKI. The terms, including hepatitis B virus (or hepatitis B), nephropathy, nephrotic syndrome and therapy, interferon, lamivudine, corticosteroid, prednisolone, *etc.*, were crossed. Furthermore, bibliographies of retrieved articles, proceedings of major recent meetings on nephrology and hepatology and related dissertations in English or Chinese were manually searched.

Criteria for inclusion

Controlled clinical trials, cohort studies, and case-control studies were searched for this systematic review. The diagnosis of HBV-GN was established based on renal pathology. The primary and secondary outcomes were remission of proteinuria and clearance of Hepatitis B e-antigen (HBeAg), respectively. Only dissertations, conference papers and full-text papers published in peer-reviewed journals concerning the treatment of HBV-GN were included in the study. The decision was made based on the quality of studies rather than on their results.

Criteria for exclusion

Publications were excluded if they were non-controlled studies or on treatment of HBV-GN with Chinese herbal drugs. For serial reports of the same patients, only those who provided the most comprehensive information were included.

Definition of treatment effect

The assessed outcomes included clinical and virologic responses. Clinical responses were divided into complete remission and partial remission, which were respectively defined as disappearance of proteinuria (< 0.3 g/d) and reduction in urine protein excretion. Virologic response was defined as clearance of HBeAg from serum.

Data extraction and quality assessment

Two reviewers independently selected the studies, and extracted data and outcomes according to the inclusion criteria. In case of disagreement between the two reviewers, a third reviewer was introduced to discuss with the two reviewers and extracted the data when all the three reviewers reached a consensus.

Statistical analysis

Meta-analysis was performed using fixed-effect or random-effect methods, depending on the absence or presence of significant heterogeneity. Statistical heterogeneity between trials was evaluated by the Cochran χ^2 test and significance was considered when $P < 0.10$. In the absence of statistically significant heterogeneity, the Mantel-Haenszel method in the fixed-effect model was used for meta-analysis. Otherwise, the DerSimonian and Laird method[13] in the random-effect model was selected. The relative risk (RR) with 95% confidence interval (CI) was used to assess the treatment efficacy. The combined result was an average RR and 95% CI weighted according to the standard error of the RR of the trial. $P < 0.05$ was considered statistically significant. We used funnel plots to assess the publication bias, and tested for funnel plot asymmetry using Egger's test[14] and Begg's test[15]. All analyses were performed with STATA version 9.0 (Stata Corp, College Station, Tx) and Review Manager version 4.2 (RevMan, Cochrane Collaboration, Oxford, England).

RESULTS

Description of included trials in the meta-analysis

Of the 998 studies we identified in the search, 55 and 943 articles were published in English and Chinese, respectively. After a review of the titles and abstracts or full texts, 989 articles were excluded and 9 articles[16-24] (8 in English and 1 in Chinese) were included based on the pre-specified criteria. One of them was randomized controlled trial (RCT)[16], others were cohort studies. Among the 9 articles, 5 (55.6%) were from China, corresponding to the high incidence of HBV-GN in China and the low incidence in Europe and North American. The characteristics of 9 clinical trials included are shown in Table 1, and the details of intervention methods like dose and duration of drugs, main outcomes, and follow-up time in each study are provided in Tables 2 and 3.

Table 1 Characteristics of 9 included studies

Study	Country or region	Patients		Study design
		Gender	Age (yr)	
Lin[16], 1995	Taiwan, China	29M, 11F	6.2 ± 2.4	RCT (3 score)
Bhimma *et al*[17], 2002	South Africa	34M, 5F	8.7, 9.2	Cohort study
Lai *et al*[18], 1991	Hong Kong, China	14M, 2F	27.2 ± 6.2	Cohort study
Tang *et al*[19], 2005	Hong Kong, China	14M, 8F	48.3 ± 12.8, 43.1 ± 22.8	Cohort study
Panomsak *et al*[20], 2006	Thailand	14M, 10F	39.8	Cohort study
Yang *et al*[21], 2003	Wenzhou, China	28M, 5F	8.01 ± 1.23	Cohort study
Lai *et al*[22], 1990	Hong Kong, China	10M, 5F	22.8 ± 14.4, 17.2 ± 8.2	Cohort study
Ozdamar *et al*[23], 2003	Turkey	11M, 3F	10	Cohort study
Peña *et al*[24], 2001	Spain	11M, 1F	4.52 ± 2.34	Cohort study

RCT: Randomized controlled trial.

Table 2 Design of 6 clinical trials on efficacy of antiviral therapy for HBV-GN

Author	Group	Case (*n*)	Intervention	Dropped-out (*n*)	Outcome			Follow-up
					CR	VR	Renal insufficiency (*n*)	
Lin[16], 1995	Control	20	The same supportive treatment as treatment group	0	7 complete remission, 10 partial remission	0 HBeAg clearance	UA	24 mo
	Treatment	20	rIFNα, 5 mU (weight < 20 kg), 8 mU (weight ⩾ 20 kg), 3 t/w for 12 mo	0	20 complete remission	16 HBeAg clearance	UA	
Bhimma *et al*[17], 2002	Control	20	Anti-hypertension and diuretics if needed	0	0 complete remission, 5 partial remission	1 HBeAg clearance	0	40 wk
	Treatment	24	rIFNα-2b, 10 mU/m^2, 3 t/w for 16 wk	5	10 complete remission, 4 partial remission	10 HBeAg clearance, 4 reverters, 5 failures	2	
Lai *et al*[18], 1991	Control	11	Diuretic agents or dipyridamole or none	0	0 complete remission, 8 partial remission	0 HBeAg clearance	4	60 mo
	Treatment	5	2 wk of prednisolone 40 mg/d followed by 12 wk of rIFNα-2b 3 mU, 3 t/w	0	1 complete remission, 4 partial remission	1 HBeAg seroconversion	1	
Tang *et al*[19], 2005	Control	12	ACEI or ARB	0	2 complete remission, 2 partial remission	1 HBeAg clearance, 2 HBeAg seroconversion	5 ESRD	49.2 ± 16.5 mo
	Treatment	10	3TC, 100 mg/d, 49.2 ± 16.5 mo, plus ACEI or ARB	0	7 complete remission, 3 partial remission	8 HBV-DNA clearance (5 HBeAg clearance)	0	
Panomsak *et al*[20], 2006	Control	10	ACEI, fish oil, or neither	3	2 complete remission	0 HBeAg clearance	2 ESRD	5-120 mo
	Treatment	7	1 month of prednisolone followed by 3TC in 6 case and IFNα in one case	0	2 complete remission, 5 partial remission	1 HBeAg seroconversion	0	
Yang *et al*[21], 2003	Control	14	The supportive or symptomatic treatment	0	9 complete remission, 2 partial remission	3 HBeAg seroconversion	0	3.8 ± 2.4 yr
	Treatment	6	rIFNα, 1-3 mU, 3 t/w for 3-6 mo	0	3 complete remission, 2 partial remission	3 HBeAg seroconversion	0	

HBV-GN: Hepatitis B virus-associated glomerulonephritis; CR: Clinical response; VR: Virologic response; UA: Unavailable; 3TC: Lamivudine; rIFNα: Recombinant α-interferon; HBeAg: Hepatitis B e-antigen; ACEI: Angiotension converting enzyme inhibitors; ARB: Angiotensin Ⅱ receptor blocker; ESRD: End-stage renal disease; t/w: Times per week.

Therapeutic evaluation: Antiviral therapy

The efficacy of antiviral therapy on HBV-GN was assessed using 6 trials[16-21], including 1 RCT[16] and 5 cohort studies[17-21]. The total number of patients was 159 (72 in treatment group with 5 dropped out, 87 in control group with 3 dropped out). Among the 159 patients, 133 presented with nephrotic syndrome and 134 with membranous nephropathy. The mean follow-up time was five months to ten years, significantly different between trials.

Clinical response in antiviral treatment group and control group: The χ^2 test of heterogeneity was highly significant (P = 0.0001). Accordingly, a random-effect model was used. The remission rate of proteinuria was significantly higher in antiviral treatment group (91.0%) than in control group (56.0%) with a combined RR of 1.69 (95% CI: 1.08-2.65, Figure 1A). The result of sensitivity analysis remained unchanged even if lamivudine treatment studies were excluded (RR = 1.50, 95% CI: 0.99-2.26, Figure 1B), indicating that the result is stable.

Furthermore, three trials[16,17,21] on pediatric patients were analyzed. The χ^2 test of heterogeneity was also highly significant (P = 0.007), so a random-effect model was selected. As shown in Figure 1C, the remission rate

Table 3 Design of 5 clinical trials on efficacy of corticosteroid therapy for HBV-GN

Author	Group	Case (*n*)	Intervention	Dropped-out (*n*)	Outcome		Follow-up
					CR	Renal insufficiency (*n*)	
Lai *et al*[22], 1990	Control	7	Diuretic agents	0	2 complete remission	UA	14-37 mo
	Treatment	8	Prednisolone 60 mg/d (adult), 40 mg/m^2 per day (< 15 yr), for 6 mo	0	3 complete remission, 4 partial remission, 1 relapse	UA	
Ozdamar *et al*[23], 2003	Control	4	None	0	4 complete remission	UA	5-120 mo
	Treatment	8	Prednisolone, 2 mg/kg per day	2	1 complete remission, 4 partial remission, 1 death due to sepsis	UA	
Panomsak *et al*[20], 2006	Control	10	ACEI, fish oil, or neither	3	2 complete remission	2 ESRD	5-120 mo
	Treatment	6	Prednisolone, 2 mg/kg per day	1	3 complete remission, 2 partial remission	0	
Yang *et al*[21], 2003	Control	14	The same supportive and symptomatic treatment as treatment group	0	9 complete remission, 2 partial remission	0	3.8 ± 2.4 yr
	Treatment	8	Prednisolone, 1.5-2 mg/kg per day, for 3 mo	0	4 complete remission, 2 partial remission	0	
Peña *et al*[24], 2001	Control	4	Symptomatic treatment	0	4 complete remission	UA	9.95 ± 5.88 yr
	Treatment	7	Prednisone, 1.5-2 mg/kg per day, a minimun of 4 wk (1 case prednisone + CTX)	0	7 steroid-resistant during therapy, but all complete remission at the end of follow-up	UA	

CTX: Cytoxan.

of proteinuria in pediatric patients was slightly higher in treatment group (86.7%) than in control group (61.1%) with a combined RR of 1.40 (95% CI: 0.80-2.47), but the difference was not statistically significant ($P = 0.24$).

Virologic response in antiviral treatment group and control group: The χ^2 test of heterogeneity was not significant ($P = 0.13$), therefore a fixed-effect model was selected. The clearance rate of HBeAg was significantly higher in antiviral treatment group (59.7%) than in control group (8.33%) with a RR of 6.44 (95% CI: 3.11-13.35, Figure 2A).

In addition, 3 trials[16,17,21] on pediatric patients were separately analyzed for virologic response. The χ^2 test of heterogeneity was significant ($P = 0.05$), therefore a random-effect model was used. The clearance rate of HBeAg was significantly higher in antiviral treatment group (73.3%) than in control group (7.4%) with a RR of 10.71 (95% CI: 3.74-30.63, Figure 2B).

Consistency analysis of clinical and virologic responses: Kappa analysis showed that proteinuria remission was significantly related with HBeAg clearance after antiviral therapy (kappa = 0.285, $P = 0.002$)

Effect of antiviral therapy on protection of renal function

The renal function of patients was observed in 5 of the 6 trials during the follow-up (Table 2). Renal insufficiency was found in only 3 of 47 (6.38%) patients in the antiviral treatment group and in 11 of 64 (17.2%) patients in the control group, respectively.

Therapeutic evaluation: Corticosteroid treatment

The efficacy of corticosteroid treatment on HBV-GN was assessed in 5 out of 9 articles[20-24]. Two of them were included in meta-analysis of antiviral therapy efficacy. Of the 23 patients in Panomsak's study[20], 7, 6 and 10 were treated with antiviral drugs, prednisolone and symptomatic treatment, respectively. Of the 28 patients in Yang's study[21], 6, 8 and 14 were treated with antiviral drugs, prednisolone and symptomatic treatment, respectively. All the 5 trials were cohort studies. The clinical response at the end of follow-up is shown in Figure 3A. Of the 76 patients analyzed, 37 were in corticosteroid treatment group with 3 dropped out, 39 were in control group with 3 dropped out. Among them, 52 presented with nephrotic syndrome and 56 with membranous nephropathy. The χ^2 test of heterogeneity was highly significant ($P = 0.001$), so a random-effect model was used. The combined RR was 1.45 with a 95% CI of 0.68-3.11 ($P = 0.34$), indicating that there is no significant difference in proteinuria remission rate between corticosteroid treatment group and control group. However, this result should be carefully interpreted since a limited number of clinical trials can affect the conclusion of meta-analysis. Besides, it was difficult to assess the protective effect of corticosteroid treatment on renal function since only 2 of 5 clinical trials described the renal function during the followed-up.

Moreover, 3 trials[21,23,24] on pediatric patients were separately pooled to analyze the efficacy of corticosteroid treatment. The χ^2 test of heterogeneity was not significant ($P = 0.61$), so a fixed-effect model was used. The combined RR was 0.91 with a 95% CI of 0.65-1.27 ($P = 0.58$), indicating that the difference in the remission rate of proteinuria was also not significant between corticosteroid treatment group and control group (Figure 3B).

Publication bias

Publication bias may exist when no significant findings remain unpublished, thus artificially inflating the apparent magnitude of an effect. Egger and Begg tests showed that the risk of having missed trials was acceptably low, since the P values for the clinical and virologic responses to antiviral therapy and the clinical response to corticosteroid

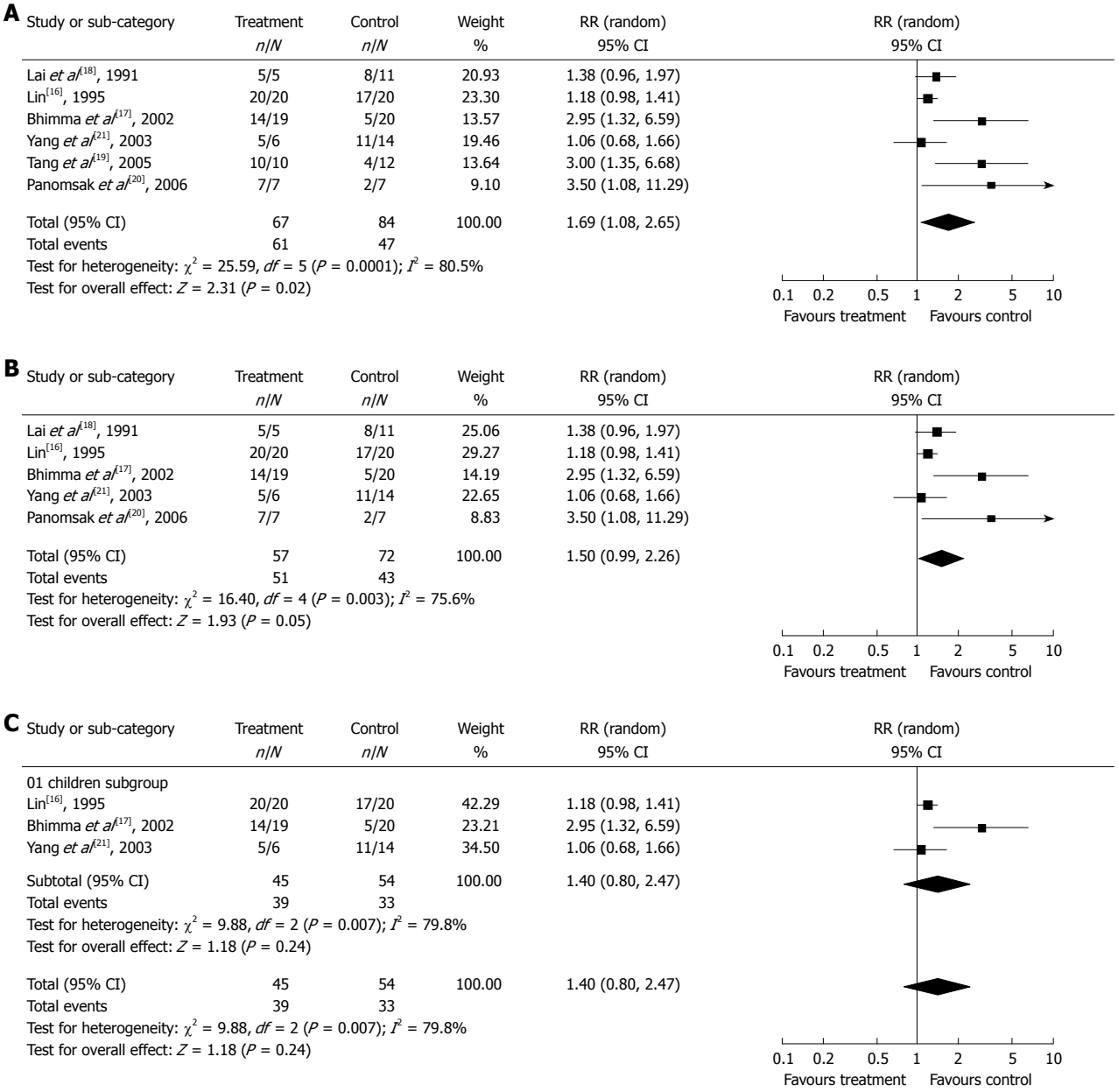

Figure 1 Proteinuria remission rate in antiviral treatment group and control group (A, B) and in pediatric patients (C).

treatment were greater than 0.05. The funnel plots of study results against precision are shown in Figure 4.

Adverse events

Since adverse events were reported inconsistently in across studies and the relevant information in these studies was incomplete, we did not evaluate their incidence and severity of adverse events of these drugs. Some adverse events such as influenza-like illness, anemia, leucopenia, *etc*, were reported in patients treated with IFN. Almost all patients showed good tolerance to long-term administration of lamivudine, although some patients complained of headache, dizziness, local myalgia, paresthesia, *etc*.

DISCUSSION

Most HBV-GN patients presented with nephrotic syndrome, many of them, especially pediatric patients showed a spontaneous remission trend, so whether the patients should be treated with antiviral drugs or with immunosuppressive agents remains to be elucidated. Antiviral therapy has been recommended in many studies for HBV-GN since it can effectively inhibit HBV replication and attenuate proteinuria[9,25-33]. Our results demonstrated that antiviral therapy could significantly improve the remission rate of proteinuria, the clearance rate of HBeAg, and renal progression. Moreover, Kappa analysis showed that proteinuria remission is significantly related with HBeAg clearance after antiviral therapy. Only 5 patients were dropped out in antiviral treatment group due to economical reasons. Almost all patients were tolerable to antiviral drugs. Our results are consistent with Fabrizi's study[12]. Since each trial used different kinds, dosages and treatment courses of antiviral drugs, the

A

Study or sub-category	Treatment *n/N*	Control *n/N*	Weight %	RR (fixed) 95% CI
Lai *et al*[18], 1991	1/5	0/11	4.88	6.00 (0.29, 126.30)
Lin[16], 1995	16/20	0/20	7.32	33.00 (2.11, 515.02)
Bhimma *et al*[17], 2002	14/19	1/20	14.26	14.74 (2.14, 101.44)
Yang *et al*[21], 2003	3/6	3/14	26.34	2.33 (0.65, 8.42)
Tang *et al*[19], 2005	5/10	3/12	39.90	2.00 (0.63, 6.38)
Panomsak *et al*[20], 2006	1/7	0/7	7.32	3.00 (0.14, 63.15)
Total (95% CI)	67	84	100.00	6.44 (3.11, 13.35)
Total events	40	7		

Test for heterogeneity: χ^2 = 8.62, *df* = 5 (*P* = 0.13); I^2 = 42.0%
Test for overall effect: *Z* = 5.01 (*P* < 0.00001)

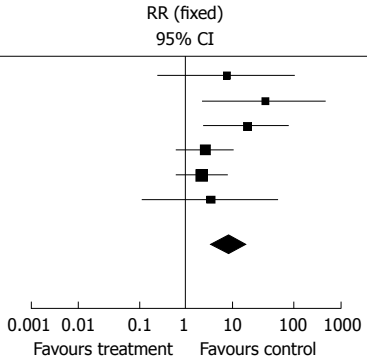

B

Study or sub-category	Treatment *n/N*	Control *n/N*	Weight %	RR (fixed) 95% CI
01 children subgroup				
Lin[16], 1995	16/20	0/20	15.27	33.00 (2.11, 515.02)
Bhimma *et al*[17], 2002	14/19	1/20	29.76	14.74 (2.14, 101.44)
Yang *et al*[21], 2003	3/6	3/14	54.97	2.33 (0.65, 8.42)
Subtotal (95% CI)	45	54	100.00	10.71 (3.74, 30.63)
Total events	33	4		

Test for heterogeneity: χ^2 = 6.17, *df* = 2 (*P* = 0.05); I^2 = 67.6%
Test for overall effect: *Z* = 4.42 (*P* < 0.00001)

Total (95% CI)	45	54	100.00	10.71 (3.74, 30.63)
Total events	33	4		

Test for heterogeneity: χ^2 = 6.17, *df* = 2 (*P* = 0.05); I^2 = 67.6%
Test for overall effect: *Z* = 4.42 (*P* < 0.00001)

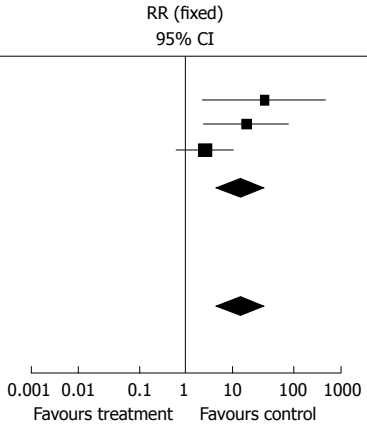

Figure 2 Clearance rate of HBeAg in antiviral treatment group and control group (A) and in pediatric patients (B).

A

Study or sub-category	Treatment *n/N*	Control *n/N*	Weight %	RR (random) 95% CI
Lai *et al*[22], 1990	7/8	2/7	18.57	3.06 (0.92, 10.17)
Peña *et al*[24], 2001	7/7	4/4		Not estimable
Ozdamar *et al*[23], 2003	5/6	4/4	32.12	0.83 (0.58, 1.19)
Yang *et al*[21], 2003	6/8	11/14	30.32	0.95 (0.59, 1.55)
Panomsak *et al*[20], 2006	5/5	2/7	18.99	3.50 (1.08, 11.29)
Total (95% CI)	34	36	100.00	1.45 (0.68, 3.11)
Total events	30	23		

Test for heterogeneity: χ^2 = 15.62, *df* = 3 (*P* = 0.001); I^2 = 80.8%
Test for overall effect: *Z* = 0.96 (*P* = 0.34)

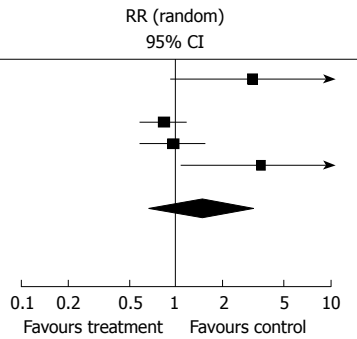

B

Study or sub-category	Treatment *n/N*	Control *n/N*	Weight %	RR (fixed) 95% CI
01 children subgroup				
Peña *et al*[24], 2001	7/7	4/4		Not estimable
Ozdamar *et al*[23], 2003	5/6	4/4	37.50	0.83 (0.58, 1.19)
Yang *et al*[21], 2003	6/8	11/14	62.50	0.95 (0.59, 1.55)
Suntotal (95% CI)	21	22	100.00	0.91 (0.65, 1.27)
Total events	18	19		

Test for heterogeneity: χ^2 = 0.27, *df* = 1 (*P* = 0.61); I^2 = 0%
Test for overall effect: *Z* = 0.56 (*P* = 0.58)

Total (95% CI)	21	22	100.00	0.91 (0.65, 1.27)
Total events	18	19		

Test for heterogeneity: χ^2 = 0.27, *df* = 1 (*P* = 0.61); I^2 = 0%
Test for overall effect: *Z* = 0.56 (*P* = 0.58)

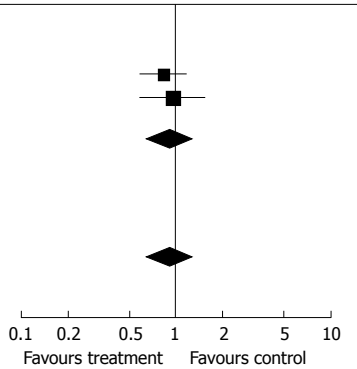

Figure 3 Proteinuria remission rate in corticosteroid treatment group and control group (A) and in pediatric patients (B).

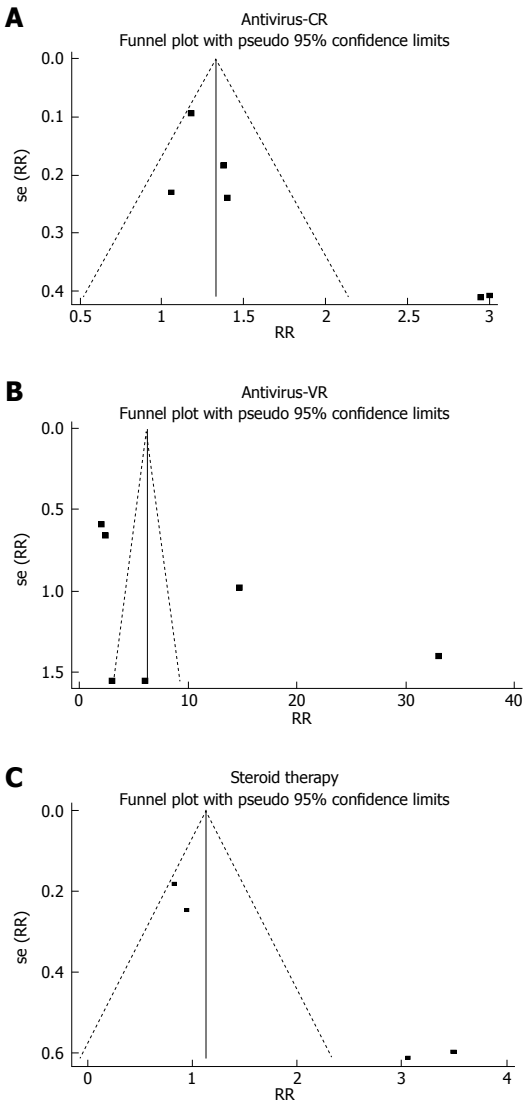

Figure 4 Funnel plots for 6 articles in meta-analysis of clinical response to antiviral therapy (A), 6 articles in meta-analysis of virologic response to antiviral therapy (B), and 5 articles in meta-analysis of clinical response to corticosteroid treatment (C).

meta-analysis proved the efficacy of antiviral treatment but did not necessarily mean that an exact treatment protocol should be recommended. The meta-analysis of pediatric patients showed that antiviral therapy could significantly increase the clearance rate of HBeAg, but not remarkably improve proteinuria, which is not consistent with our above findings possibly due the limited sample size. Large-scale randomized controlled trials on pediatric patients are needed to clarify if antiviral therapy can induce remission of proteinuria.

Corticosteroid is the first-line drug for idiopathic nephrotic syndrome, but it may activate potent HBV infection leading to deterioration of liver and renal lesion[22,34-36]. Our meta-analysis showed that corticosteroid treatment could not significantly improve proteinuria. The effect of corticosteroids on proteinuria remission was not better than nonspecific symptomatic treatment, but its potent risk could not be neglected. Therefore, based on the results of this meta-analysis, corticosteroid should not be recommended for HBV-GN patients solely, especially for those with a high viral load and abnormal liver functions. Theoretically, corticosteroid in combination with antiviral drugs is certainly superior over corticosteroid alone, but no trials are available. So corticosteroid may only be used cautiously on the basis of antiviral therapy with viral load closely monitored.

As with all meta-analyses, our study had certain limitations of publication bias[37]. The number of high-quality clinical trials and enrolled patients was limited in this study. Moreover, the time of treatment was not long enough to evaluate its effects on chronic HBV-GN.

In conclusion, the efficacy and safety of antiviral therapy (including IFN and lamivudine) on HBV-GN are good. Antiviral therapy is effective on remission of proteinuria, and HBeAg clearance, delaying renal function deterioration. However, corticosteroids cannot ameliorate HBV-GN.

COMMENTS

Background

Hepatitis B virus-associated glomerulonephritis (HBV-GN) is one of the common secondary glomerular diseases in China. Although spontaneous remission can occur in many pediatric patients, some still develop progressive renal failure. Therefore, it is very important to attenuate proteinuria and delay renal disease progression.

Research frontiers

So far HBV-GN has been treated like hepatitis B with antiviral drugs including interferon, lamivudine, entecavir or like primary nephrotic syndrome with corticosteroids and even immunosuppressive agents such as mycophenolate mofetil, leflunomide, *etc*. However, it is still uncertain up to now about the efficacy of these treatment modalities.

Innovations and breakthroughs

The data available in previous studies on HBV-GN treatment are limited and often provide inconsistent results. So far only one meta-analysis of antiviral therapy for HBV-GN was published in 2006, but 2 of the 6 trials included were non-controlled studies. The meta-analysis including controlled studies is the first to evaluate the effects of antiviral drugs and corticosteroids on HBV-GN. Moreover, pediatric patients were separately assessed.

Applications

The results of this study suggest that antiviral but not corticosteroid treatment can decrease proteinuria and promote Hepatitis B e-antigen clearance in HBV-associated glomerulonephritis patients. It may help doctors to optimally treat HBV-GN patients.

Terminology

Hepatitis B virus-associated glomerulonephritis is an immune-mediated secondary glomerular disease characterized by deposits of hepatitis B viral antigens, immunoglobulins and C3 in the glomerular capillary wall and mesangium. Nephrotic syndrome, proteinuria and/or hematuria are the most common renal manifestations.

Peer review

The present manuscript describes a meta-analysis for the evaluation of clinical and virologic responses to antiviral and corticosteroid treatment of hepatitis B-associated nephritis. Overall, the methods are appropriate and the results are believable.

REFERENCES

1 **Bhimma R**, Coovadia HM, Adhikari M, Connolly CA. The impact of the hepatitis B virus vaccine on the incidence of hepatitis B virus-associated membranous nephropathy. *Arch Pediatr Adolesc Med* 2003; **157**: 1025-1030

2 **Xu H**, Sun L, Zhou LJ, Fang LJ, Sheng FY, Guo YQ. The effect of hepatitis B vaccination on the incidence of childhood HBV-

associated nephritis. *Pediatr Nephrol* 2003; **18**: 1216-1219
3 **Walters S**, Levin M. Infectious diseases and the kidney. In: Barratt TM, Avner ED, Harmon WE, editors. Pediatric Nephrology. 4th ed. Philadelphia, PA: Lippincott Williams & Wilkins, 1999: 1088-1090
4 **Lai KN**, Lai FM, Chan KW, Chow CB, Tong KL, Vallance-Owen J. The clinico-pathologic features of hepatitis B virus-associated glomerulonephritis. *Q J Med* 1987; **63**: 323-333
5 **Gilbert RD**, Wiggelinkhuizen J. The clinical course of hepatitis B virus-associated nephropathy. *Pediatr Nephrol* 1994; **8**: 11-14
6 **Lin CY**. Hepatitis B virus-associated membraneous nephropathy: clinical features, immunological profiles and outcome. *Nephron* 1990; **55**: 37-44
7 **Bhimma R**, Coovadia HM. Hepatitis B virus-associated nephropathy. *Am J Nephrol* 2004; **24**: 198-211
8 **Zhou JH**, Zhang Y. Treatment of Hepatitis B Virus Associated Nephritis in Children. *Shiyong Erke Linchuang Zazhi* 2008; **23**: 329-332
9 **Chung DR**, Yang WS, Kim SB, Yu E, Chung YH, Lee Y, Park JS. Treatment of hepatitis B virus associated glomerulonephritis with recombinant human alpha interferon. *Am J Nephrol* 1997; **17**: 112-117
10 **Wong SN**, Yu EC, Lok AS, Chan KW, Lau YL. Interferon treatment for hepatitis B-associated membranous glomerulonephritis in two Chinese children. *Pediatr Nephrol* 1992; **6**: 417-420
11 Appel GB, Radhakrishnan J, D'Agati V. Secondary glomerular disease. In: Brenner BM, editor. The Kidney. 6th ed. Philadelphia, PA: WB Saunders, 2000: 1411
12 **Fabrizi F**, Dixit V, Martin P. Meta-analysis: anti-viral therapy of hepatitis B virus-associated glomerulonephritis. *Aliment Pharmacol Ther* 2006; **24**: 781-788
13 **DerSimonian R**, Laird N. Meta-analysis in clinical trials. *Control Clin Trials* 1986; **7**: 177-188
14 **Egger M**, Davey Smith G, Schneider M, Minder C. Bias in meta-analysis detected by a simple, graphical test. *BMJ* 1997; **315**: 629-634
15 **Begg CB**, Mazumdar M. Operating characteristics of a rank correlation test for publication bias. *Biometrics* 1994; **50**: 1088-1101
16 **Lin CY**. Treatment of hepatitis B virus-associated membranous nephropathy with recombinant alpha-interferon. *Kidney Int* 1995; **47**: 225-230
17 **Bhimma R**, Coovadia HM, Kramvis A, Adhikari M, Kew MC. Treatment of hepatitis B virus-associated nephropathy in black children. *Pediatr Nephrol* 2002; **17**: 393-399
18 **Lai KN**, Li PK, Lui SF, Au TC, Tam JS, Tong KL, Lai FM. Membranous nephropathy related to hepatitis B virus in adults. *N Engl J Med* 1991; **324**: 1457-1463
19 **Tang S**, Lai FM, Lui YH, Tang CS, Kung NN, Ho YW, Chan KW, Leung JC, Lai KN. Lamivudine in hepatitis B-associated membranous nephropathy. *Kidney Int* 2005; **68**: 1750-1758
20 **Panomsak S**, Lewsuwan S, Eiam-Ong S, Kanjanabuch T. Hepatitis-B virus-associated nephropathies in adults: a clinical study in Thailand. *J Med Assoc Thai* 2006; **89** Suppl 2: S151-S156
21 **Yang Q**, Zhuang JQ, Lin RX, Yang YZ, Wang ZX. Clinicopathological Features and Treatment of Hepatitis B Virus Associated Membranous Nephropathy in Children. *Zhongguo Zhongxiyi Jiehe Shenbing Zazhi* 2003; **4**: 706-708
22 **Lai KN**, Tam JS, Lin HJ, Lai FM. The therapeutic dilemma of the usage of corticosteroid in patients with membranous nephropathy and persistent hepatitis B virus surface antigenaemia. *Nephron* 1990; **54**: 12-17
23 **Ozdamar SO**, Gucer S, Tinaztepe K. Hepatitis-B virus associated nephropathies: a clinicopathological study in 14 children. *Pediatr Nephrol* 2003; **18**: 23-28
24 **Peña A**, Débora MJ, Melgosa M, Luz Picazo M, Navarro M. Membranous nephropathy associated with hepatitis B in Spanish children. *Clin Nephrol* 2001; **55**: 25-30
25 **Shapiro RJ**, Steinbrecher UP, Magil A. Remission of nephrotic syndrome of HBV-associated membranous glomerulopathy following treatment with interferon. *Am J Nephrol* 1995; **15**: 343-347
26 **Kavukçu S**, Başdemir G, Eroğlu Y, Türkmen M, Eser F, Büyükgebiz B. Interferon treatment in hepatitis B virus-associated membranous glomerulopathy. *Pediatr Nephrol* 1995; **9**: 539-540
27 **Conjeevaram HS**, Hoofnagle JH, Austin HA, Park Y, Fried MW, Di Bisceglie AM. Long-term outcome of hepatitis B virus-related glomerulonephritis after therapy with interferon alfa. *Gastroenterology* 1995; **109**: 540-546
28 **Connor FL**, Rosenberg AR, Kennedy SE, Bohane TD. HBV associated nephrotic syndrome: resolution with oral lamivudine. *Arch Dis Child* 2003; **88**: 446-449
29 **Filler G**, Feber J, Weiler G, Le Saux N. Another case of HBV associated membranous glomerulonephritis resolving on lamivudine. *Arch Dis Child* 2003; **88**: 460
30 **Gan SI**, Devlin SM, Scott-Douglas NW, Burak KW. Lamivudine for the treatment of membranous glomerulopathy secondary to chronic Hepatitis B infection. *Can J Gastroenterol* 2005; **19**: 625-629
31 **Kanaan N**, Horsmans Y, Goffin E. Lamivudine for nephrotic syndrome related to hepatitis B virus (HBV) infection. *Clin Nephrol* 2006; **65**: 208-210
32 **Okuse C**, Yotsuyanagi H, Yamada N, Ikeda H, Takahashi H, Suzuki M, Kondo S, Kimura K, Koike J, Itoh F. Successful treatment of hepatitis B virus-associated membranous nephropathy with lamivudine. *Clin Nephrol* 2006; **65**: 53-56
33 **Wen YK**, Chen ML. Remission of hepatitis B virus-associated membranoproliferative glomerulonephritis in a cirrhotic patient after lamivudine therapy. *Clin Nephrol* 2006; **65**: 211-215
34 **Taskapan H**, Oymak O, Dogukan A, Ozbakir O, Utas C. Transformation of hepatitis B virus-related membranous glomerulonephritis to crescentic form. *Clin Nephrol* 2000; **54**: 161-163
35 **Lai FM**, Tam JS, Li PK, Lai KN. Replication of hepatitis B virus with corticosteroid therapy in hepatitis B virus related membranous nephropathy. *Virchows Arch A Pathol Anat Histopathol* 1989; **414**: 279-284
36 **Lin CY**. Clinical features and natural course of HBV-related glomerulopathy in children. *Kidney Int Suppl* 1991; **35**: S46-S53
37 **Thornton A**, Lee P. Publication bias in meta-analysis: its causes and consequences. *J Clin Epidemiol* 2000; **53**: 207-216

S- Editor Tian L **L- Editor** Wang XL **E- Editor** Lin YP

World Journal of Gastroenterology

Online Submissions: http://www.wjgnet.com/1007-9327office
wjg@wjgnet.com
doi:10.3748/wjg.v16.i6.778

World J Gastroenterol 2010 February 14; 16(6): 778-781
ISSN 1007-9327 (print)

CASE REPORT

A case of gouty arthritis following percutaneous radiofrequency ablation for hepatocellular carcinoma

Dae Hee Choi, Hyo-Suk Lee

Dae Hee Choi, Department of Internal Medicine, Kangwon National University College of Medicine, Chuncheon 200-714, South Korea
Hyo-Suk Lee, Department of Internal Medicine and Liver Research Institute, Seoul National University College of Medicine, Seoul 110-744, South Korea
Author contributions: Choi DH collected the data and drafted the paper; Lee HS reviewed the data and edited the paper.
Correspondence to: Hyo-Suk Lee, MD, Professor, Department of Internal Medicine and Liver Research Institute, Seoul National University College of Medicine, 28 Yungun-dong, Chongno-gu, Seoul 110-744, South Korea. hsleemd@snu.ac.kr
Telephone: +82-2-7457557 Fax: +82-2-7436701
Received: November 10, 2009 Revised: December 19, 2009
Accepted: December 26, 2009
Published online: February 14, 2010

Abstract

Percutaneous radiofrequency thermal ablation (RFA) is considered an effective technique for providing local control in the majority of Hepatocellular carcinoma (HCC) patients. Although RFA is generally well tolerated, recent studies have reported complications associated with RFA. We describe a case of acute gouty arthritis in a 71-year-old man with chronic renal failure who was treated with RFA for a HCC lesion and who had hepatitis B-associated cirrhosis and mild renal insufficiency. Regular surveillance of the patient detected a 3.5 cm HCC lesion. Because the patient had declined surgery, RFA was chosen for therapy. On the third post-procedural day, the laboratory results showed increases in his uric acid and potassium levels, which were compatible with a tumor lysis syndrome. On the 6th post-procedural day, the patient complained of new right knee pain. Subsequent joint aspiration revealed monosodium urate monohydrate crystals. We made the diagnosis of acute gouty arthritis arising from tumor lysis and liver infarction caused by HCC ablation, which was aggravated by acute renal insufficiency. After adequate hydration and administration of oral colchicines, the patient's right knee pain subsided and the uric acid serum level returned to normal. This is the first described case of acute gouty arthritis after RFA for a HCC lesion in a patient with underlying chronic renal insufficiency. To avoid hyperuricemia and an acute attack of gout after RFA therapy for HCC, early identification of patients at risk is warranted, such as those with a large tumor, rapid tumor growth, and renal insufficiency, and preventative measures should be considered.

Key words: Radiofrequency thermal ablation; Hepatocellular carcinoma; Gout; Tumor lysis syndrome; Complications

Peer reviewer: Kenji Miki, MD, Department of Surgery, Showa General Hospital, 2-450 Tenjin-cho, Kodaira, Tokyo 187-8510, Japan

Choi DH, Lee HS. A case of gouty arthritis following percutaneous radiofrequency ablation for hepatocellular carcinoma. *World J Gastroenterol* 2010; 16(6): 778-781 Available from: URL: http://www.wjgnet.com/1007-9327/full/v16/i6/778.htm DOI: http://dx.doi.org/10.3748/wjg.v16.i6.778

INTRODUCTION

Although the optimal treatment for hepatocellular carcinoma (HCC) is surgical resection, there are only a small number of patients who meet resectability criteria for HCC[1]. Percutaneous radiofrequency thermal ablation (RFA) is one of the emerging therapeutic modalities used for the minimally invasive treatment in the management of liver malignancies, particularly in patients who cannot undergo surgery[2,3]. It has been reported that the morbidity and mortality rates are low, and there are few complications associated with RFA[4,5]. Although RFA is relatively well-tolerated, severe and potentially fatal complications, such as liver failure, colon perforation and portal vein

thrombosis can arise[6,7]. In addition, there are non-fatal serious complications, such as liver abscess, pleural effusion, skin burns, hypoxemia during treatment, pneumothorax, subcapsular hematoma, acute renal insufficiency, hemoperitoneum, needle tract seeding, and self-limited post-ablation syndrome[8]. However, acute gouty arthritis attacks following RFA for HCC have not been reported. We describe a case of gouty arthritis in a 71-year-old man who was treated with RFA for a large HCC in segment Ⅳ of the liver adjacent to the gallbladder bed.

CASE REPORT

A 71-year-old male with hepatitis B virus-associated cirrhosis had undergone a previous percutaneous ethanol injection for a small HCC. Regular surveillance detected a 3.5 cm HCC lesion at segment Ⅳ of the liver adjacent to the gallbladder, posterior to the lesion where a previous percutaneous ethanol injection had been performed (Figure 1A). The baseline laboratory tests showed thrombocytopenia (platelet count, 101 × 10^3/mm^3; normal range, 150-440 × 10^3/mm^3), an elevated blood urea nitrogen level (44 mg/dL; normal range, 8-20 mg/dL), an increased creatinine level (1.8 mg/dL; normal range, 0.4-1.0 mg/dL), a normal uric acid level (5.5 mg/dL; normal range, 2.6-8.0 mg/dL), and a normal potassium level (3.7 mmol/L; normal range, 3.6-5.0 mmol/dL). The liver function tests revealed a borderline low albumin level (3.2 g/dL; normal range, 3.2-4.9 g/dL), a normal total bilirubin level (1.1 mg/dL; normal range, 0.3-1.2 mg/dL) and a normal prothrombin time (international normalized ratio, 0.93). The other laboratory tests, including the total calcium, phosphorus, lactate dehydrogenase (LDH), and aspartate transaminase levels, were within normal limits. Among several curative treatment options available, RFA was chosen for further therapy because the patient had declined surgery. Written informed consent was obtained from the patient before RFA.

RFA was performed under sonographic guidance using a 3.5 MHz convex probe (Sequoia, Siemens Medical Solutions). The treatment was performed under local anesthesia using 100 μg of fentanyl citrate (Myengmun) to control pain. The vital signs were monitored continuously during the procedure. Once proper positioning of the electrode in the tumor area had been confirmed by sonography, the electrodes were connected to a 500 KHz monopolar radiofrequency generator (CC-1, Valleylab) capable of producing 200 W. Four internally cooled 17-gauge electrodes (Cool-Tip, Valleylab) with 3.0 cm exposed tips delivered radiofrequency energy to the tumors. During withdrawal of the electrode, the entire electrode track was heated briefly to a temperature of 80℃ by application of radiofrequency. The procedure lasted 23 min with complete ablation of the HCC without apparent complications, such as injury to the gallbladder, on the immediate follow-up computed tomography scan (Figure 1B).

The morning after the procedure, the patient complained of abdominal distension. A simple abdominal radiograph revealed no evidence of bowel perforation, although the large intestine was distended (Figure 2). The laboratory results were normal, except an elevation of the potassium level (5.0 mmol/L) and a sustained elevated creatinine level (1.7 mg/dL). On the third post-procedural day, although the patient's symptoms had not changed, repeat laboratory results showed that his uric acid level had increased to 8.7 mg/dL, and the potassium level was maintained at 5.1 mmol/L, which were compatible with a tumor lysis syndrome. The urine output was adequate, and the acid-base gas analysis revealed no disturbances. The patient was hydrated with crystalloids and subjected to close observation. On the 6th post-procedural day, the patient complained of new right knee pain. The physical examination showed swelling and tenderness on the medial side of the right knee that was warm to touch. Joint aspiration revealed a yellow serous fluid that was confirmed, by polarizing microscopy, to be monosodium urate monohydrate crystals (Figure 3). On the same day, the laboratory data revealed that the serum uric acid and creatinine levels increased to 9.8 mg/dL and 3.2 mg/dL, respectively, which were both higher than the baseline levels before the RFA procedure. We made the diagnosis of acute gouty arthritis arising not only from tumor lysis caused by HCC ablation, but also from liver infarction adjacent to the tumor by broad ablation, which was aggravated by acute renal insufficiency in chronic renal failure. We treated the patient with an adequate intravenous

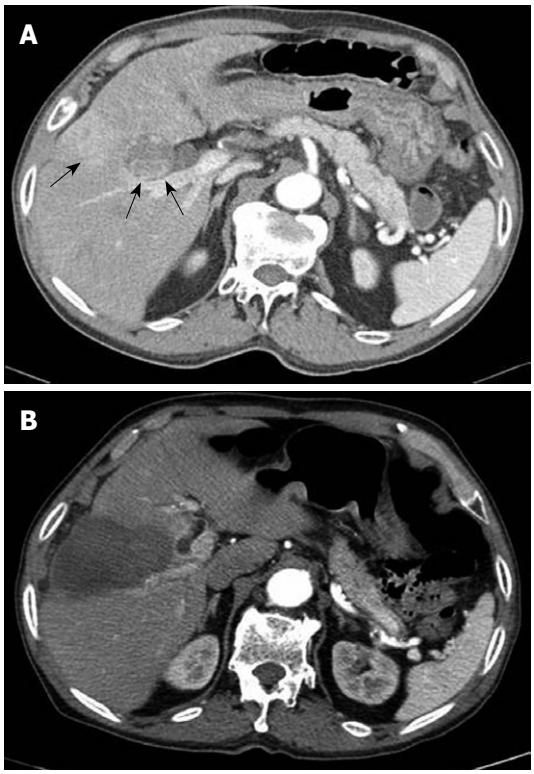

Figure 1 Computed tomography (CT) scan of the patient. A: CT scan in an arterial phase demonstrates a 3.5 cm hepatocellular carcinoma lesion (arrows) at segment Ⅳ of the liver adjacent to the gallbladder, posterior to the lesion where a previous percutaneous ethanol injection has been performed; B: CT scan obtained after radiofrequency thermal ablation reveals complete ablation for the hepatocellular carcinoma without apparent complications such as a gallbladder injury on the immediate follow-up.

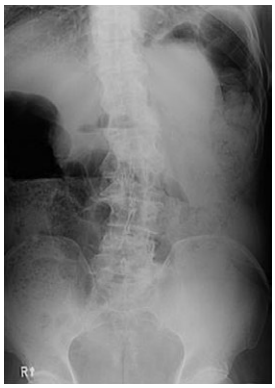

Figure 2 A simple abdominal radiograph reveals no evidence of bowel perforation, except a distension of the large intestine.

Figure 3 Strongly negative birefringent, needle-shaped monosodium urate crystals (arrow) in synovial fluid from a patient under compensated polarized light.

crystalloid infusion and oral colchicine (0.6 mg/d). As a result, the patient's right knee pain subsided. On the 11th post-procedural day, the uric acid level was within normal limits (7.2 mg/dL) and the levels of other electrolytes and creatinine had returned to baseline values.

DISCUSSION

Tumor lysis syndrome has been reported for many different types of poorly differentiated lymphomas, such as high grade non-Hodgkin's lymphoma, Burkitt's lymphoma, and acute lymphocytic leukemia[9]. Because this syndrome is mostly frequently related to the cytotoxic treatment of poorly differentiated lymphomas or combination chemotherapy, it has rarely been reported for solid organ tumors, including lung, breast, and advanced gastric cancers[10-12]. However, several recent reports have demonstrated that tumor lysis syndrome may occur after various treatments of HCC, including RFA and transarterial chemoembolization (TACE)[13-15]. Shiba *et al*[14] reported a case of TACE-induced tumor lysis syndrome resulting from necrosis of a large HCC. Moreover, they suggested that factors predisposing a patient to tumor lysis include large tumor size, tumors with high sensitivity to treatment, renal insufficiency, dehydration, and hyperuricemia before treatment[14].

Tumor lysis syndrome causes hyperuricemia, hyperkalemia, hyperphosphatemia and hypocalcemia, and may lead to acute renal failure or metabolic acidosis resulting from deposition of uric acid in the kidney, and calcium phosphate complex in renal tubules[16]. In our patient, although metabolic acidosis did not develop, tumor lysis syndrome, including hyperuricemia, hyperkalemia, and acute renal failure did develop. Therefore, we believe that acute tumor lysis syndrome occurred in our patient as a result of tumor necrosis following RFA.

Lehner *et al*[15] reported a death caused by acute tumor lysis syndrome after ablation of a 3.2 cm HCC. They indicated that patients with pre-existing azotemia, along with elevated baseline LDH which exists in most cases of cirrhosis, and elevated uric acid level are at increased risk of tumor lysis syndrome[15]. Therefore, we suggest that the predisposing factors in our case included underlying cirrhosis with pre-existing azotemia. Moreover, because we observed that the ablated field was large compared to the target lesion, we believe hyperuricemia could be caused by liver infarction induced by ablation.

We describe, for the first time, a case of acute gouty arthritis as a possible complication following thermal ablation for HCC. A definite diagnosis of gout was made by identification of monosodium urate crystals within phagocytes in the synovial fluid using compensated polarized microscopy[17]. It is well known that numerous circumstances, such as surgery, dietary overindulgence, and ingestion of drugs affecting serum uric acid concentrations are associated with acute attacks of gouty arthritis[18]. The likely explanation for the development of acute gouty arthritis in this elderly man was the abrupt increase in the serum uric acid level from tumor cell necrosis after HCC ablation. Therefore, in this case, the acute gouty attack on the 6th post-procedural day was likely caused not only by chronic renal insufficiency, but also by hyperuricemia following tumor cell lysis and liver infarction.

After the diagnosis of acute gouty arthritis was established, the patient received colchicine immediately. Although colchicine is not a urate-lowering agent, adequate hydration and colchicine administration resulted in lowering of the serum level of uric acid to the baseline value and resolution of the patient's right knee pain 2 d after drug administration.

To date, RFA is considered an effective procedure for providing local control in HCC patients. RFA is associated with the possibility of effecting long-term, disease-free survival in selected patients compared to other local techniques, such as cryoablation and percutaneous ethanol injection[19,20]. Although RFA is a generally well-tolerated and relatively safe localized-regional therapy, complications can develop[4-8]. A recent report showed that RFA was associated with a 4% rate of major complications, a 4.8% rate of minor complications, and a negligible risk of death[4,5]. As shown in this case, acute gouty arthritis is not a life-threatening condition, but it affects the quality of life of the patient. Therefore, during therapy, patients who are at risk should be monitored closely for this possible complication. To avoid hyperuricemia and acute gouty arthritis after RFA therapy for HCC, early identification of patients at risk is warranted, such as those with a large tumor, rapid tumor growth, and renal insufficiency, and

preventative measures should be considered.

In conclusion, this is the first described case of acute gouty arthritis after RFA for a HCC lesion in a patient with underlying chronic renal insufficiency. This complication should be considered in patients at risk. Appropriate screening, management, and treatment may reduce the complications associated with RFA.

REFERENCES

1 **Song TJ**, Ip EW, Fong Y. Hepatocellular carcinoma: current surgical management. *Gastroenterology* 2004; **127**: S248-S260

2 **Decadt B**, Siriwardena AK. Radiofrequency ablation of liver tumours: systematic review. *Lancet Oncol* 2004; **5**: 550-560

3 **Lencioni R**, Cioni D, Crocetti L, Bartolozzi C. Percutaneous ablation of hepatocellular carcinoma: state-of-the-art. *Liver Transpl* 2004; **10**: S91-S97

4 **Livraghi T**, Solbiati L, Meloni MF, Gazelle GS, Halpern EF, Goldberg SN. Treatment of focal liver tumors with percutaneous radio-frequency ablation: complications encountered in a multicenter study. *Radiology* 2003; **226**: 441-451

5 **Kong WT**, Zhang WW, Qiu YD, Zhou T, Qiu JL, Zhang W, Ding YT. Major complications after radiofrequency ablation for liver tumors: analysis of 255 patients. *World J Gastroenterol* 2009; **15**: 2651-2656

6 **Cho YK**, Kim JK, Kim MY, Rhim H, Han JK. Systematic review of randomized trials for hepatocellular carcinoma treated with percutaneous ablation therapies. *Hepatology* 2009; **49**: 453-459

7 **Yeung YP**, Hui J, Yip WC. Delayed colonic perforation after percutaneous radiofrequency ablation of hepatocellular carcinoma. *Surg Laparosc Endosc Percutan Tech* 2007; **17**: 342-344

8 **Carrafiello G**, Laganà D, Ianniello A, Dionigi G, Novario R, Recaldini C, Mangini M, Cuffari S, Fugazzola C. Post-radiofrequency ablation syndrome after percutaneous radio-frequency of abdominal tumours: one centre experience and review of published works. *Australas Radiol* 2007; **51**: 550-554

9 **Hande KR**, Garrow GC. Acute tumor lysis syndrome in patients with high-grade non-Hodgkin's lymphoma. *Am J Med* 1993; **94**: 133-139

10 **Kalemkerian GP**, Darwish B, Varterasian ML. Tumor lysis syndrome in small cell carcinoma and other solid tumors. *Am J Med* 1997; **103**: 363-367

11 **Rostom AY**, El-Hussainy G, Kandil A, Allam A. Tumor lysis syndrome following hemi-body irradiation for metastatic breast cancer. *Ann Oncol* 2000; **11**: 1349-1351

12 **Han HS**, Park SR, Kim SY, Park YI, Lee JS, Kook MC, Choi IJ, Kim CG, Lee JR, Cho SJ, Kim NK. Tumor lysis syndrome after capecitabine plus cisplatin treatment in advanced gastric cancer. *J Clin Oncol* 2008; **26**: 1006-1008

13 **Hsieh PM**, Hung KC, Chen YS. Tumor lysis syndrome after transarterial chemoembolization of hepatocellular carcinoma: case reports and literature review. *World J Gastroenterol* 2009; **15**: 4726-4728

14 **Shiba H**, Ishida Y, Wakiyama S, Sakamoto T, Misawa T, Yanaga K. Acute tumor lysis syndrome after transarterial chemoembolization for hepatocellular carcinoma. *Cancer Sci* 2008; **99**: 2104-2105

15 **Lehner SG**, Gould JE, Saad WE, Brown DB. Tumor lysis syndrome after radiofrequency ablation of hepatocellular carcinoma. *AJR Am J Roentgenol* 2005; **185**: 1307-1309

16 **Alkhuja S**, Ulrich H. Acute renal failure from spontaneous acute tumor lysis syndrome: a case report and review. *Ren Fail* 2002; **24**: 227-232

17 **Terkeltaub RA**. Clinical practice. Gout. *N Engl J Med* 2003; **349**: 1647-1655

18 **Teng GG**, Nair R, Saag KG. Pathophysiology, clinical presentation and treatment of gout. *Drugs* 2006; **66**: 1547-1563

19 **Lin SM**, Lin CJ, Lin CC, Hsu CW, Chen YC. Radiofrequency ablation improves prognosis compared with ethanol injection for hepatocellular carcinoma < or =4 cm. *Gastroenterology* 2004; **127**: 1714-1723

20 **Shiina S**, Teratani T, Obi S, Sato S, Tateishi R, Fujishima T, Ishikawa T, Koike Y, Yoshida H, Kawabe T, Omata M. A randomized controlled trial of radiofrequency ablation with ethanol injection for small hepatocellular carcinoma. *Gastroenterology* 2005; **129**: 122-130

S- Editor Tian L **L- Editor** Cant MR **E- Editor** Lin YP

World Journal of Gastroenterology

Online Submissions: http://www.wjgnet.com/1007-9327office
wjg@wjgnet.com
doi:10.3748/wjg.v16.i6.782

World J Gastroenterol 2010 February 14; 16(6): 782-784
ISSN 1007-9327 (print)

CASE REPORT

Multiple chronic non-specific ulcer of small intestine characterized by anemia and hypoalbuminemia

Yan Chen, Wang-Qian Ma, Jia-Min Chen, Jian-Ting Cai

Yan Chen, Wang-Qian Ma, Jia-Min Chen, Jian-Ting Cai, Department of Gastroenterology, Second Affiliated Hospital of Medical College, Zhejiang University, Hangzhou 310009, Zhejiang Province, China
Author contributions: Ma WQ and Cai JT contributed equally to this work, provided the data; Chen JM performed the capsule endoscopy; Chen Y wrote the paper.
Correspondence to: Dr. Wang-Qian Ma, Department of Gastroenterology, Second Affiliated Hospital of Medical College, Zhejiang University, Hangzhou 310009, Zhejiang Province, China. chenyan72_72@hotmail.com
Telephone: +86-571-87783936 Fax: +86-571-88833653
Received: October 31, 2009 Revised: December 10, 2009
Accepted: December 17, 2009
Published online: February 14, 2010

Abstract

A female patient with anemia and hypoalbuminemia was admitted to our hospital due to an over 20-year history of recurrent dizziness, fatigue and ankle edema. She was diagnosed as multiple chronic non-specific ulcer of the small intestine characterized by non-specific histology and persistent gastrointestinal bleeding.

Key words: Small intestinal ulcer; Hypoalbuminemia; Anemia; Gastrointestinal bleeding; Capsule endoscopy

Peer reviewer: Dr. Dinesh Vyas, Department of Minimally and Endoscopic Surgery, St John Mercy Hospital, 851 E Fifth Street, Washington, MO 63090, United States

Chen Y, Ma WQ, Chen JM, Cai JT. Multiple chronic non-specific ulcer of small intestine characterized by anemia and hypoalbuminemia. *World J Gastroenterol* 2010; 16(6): 782-784 Available from: URL: http://www.wjgnet.com/1007-9327/full/v16/i6/782.htm DOI: http://dx.doi.org/10.3748/wjg.v16.i6.782

INTRODUCTION

With the wide use of capsule endoscopy, small intestinal ulcer associated with chronic bleeding is commonly seen in clinical practice. However, its diagnosis and treatment are complicated. After the causes of ulcer such as Crohn's disease, Behcet's disease and tuberculosis are excluded, most cases are diagnosed as "idiopathic chronic ulcerative enteritis"[1]. Since 1960, cases of non-specific ulcer of small intestine have been reported[2-4]. Most of them were caused by non-steroidal anti-inflammatory drugs (NSAID) or potassium tablets. Matsumoto *et al*[5,6] have reported a multiple chronic non-specific ulcer of small intestine (CNSU), which is not related to NSAID. We, here, report a case of multiple chronic non-specific ulcer of the small intestine characterized by non-specific histology and persistent gastrointestinal (GI) bleeding.

CASE REPORT

A 42-year-old female was admitted to our hospital due to an over 20-year history of recurrent dizziness, fatigue and ankle edema. Over the past 20 years, she had dizziness, fatigue and abdominal distension without any identifiable causes. At the same time, she developed ankle edema which resolved spontaneously after rest. Laboratory test at a local hospital showed that she had severe iron deficiency anemia [hemoglobin (HB) 27 g/L] and hypoalbuminemia (albumin 11 g/L). Her symptoms could always be relieved temporarily after intravenous infusion of albumin and packed red blood cells. However, over the past 4 mo, she had repeated episodes of chest tightness and palpitation after activities. She also complained of intermittent abdominal pain after meal but had no fever, nausea or vomit. Her bowel movements were normal except for occasionally mild diarrhea. She denied any decreased appetite, nausea and vomiting, hematemesis, hematochezia, melena, tenesmus and stools with mucus or pus.

She had no known history of hepatitis or chronic renal disease or smoking or alcohol, and exposure to contaminated water. She denied any use of NSAID. Her parents were healthy and her little brother was dead at the age of 10 years due to unknown cause. Her son and husband were healthy.

Physical examination demonstrated that her temperature was 36.8℃, blood pressure was 92/60 mmHg, respiration was 18/min, and heart rate was 92 bpm. The patient was alert and fully oriented but appeared pale, cold and clammy. She had no jaundice, liver palm or spider angioma, eruption or purpura on the skin. No superficial lymph nodes could be palpated. Her trachea was slightly shifted to the left with no jugular venous distention. Her right chest wall movement and tactile fremitus over the right lung base were decreased with absent breath sounds and dullness to percussion. Her heart had a grade 2/6 diastolic murmur at the apex. An abdominal bulge and positive shifting dullness were found with active bowel sound. No abdominal wall vein dilatation, tenderness or rebound tenderness were found. No mass, liver and spleen were palpable. Digital rectal examination was negative. She had moderate pitting edema of the lower extremities.

Her white blood cells were 8.0×10^{12}/L, HB was 59 g/L, mean cell volume was 65 fL, mean corpuscular hemoglobin was 18.1 pg, and platelets were 445×10^{9}/L. Her TB/CB was 0.15/0.07 mg/mL, A/G was 1.3/2.0, alanine aminotransferase was 25 U/L, aspartate aminotransferase was 20 U/L, reticulocytes was 2.9%, erythrocyte sedimentation rate was 28 mm/h. Bone marrow aspiration showed proliferation of erythrocyte lineage and mature red blood cells with an increased central pallor. Iron staining revealed 2% intracellular iron but no extracellular iron. No proteinuria or haematuria was detected at a urinalysis. Renal function was normal. Rheumatoid factors and full antinuclear autoantibodies were negative. Serological tests were negative for hepatitis B virus, hepatitis C virus and human immunodeficiency virus. Her serum K^+ and Na^+ were 3.15 mEq/L and 133 mEq/L, respectively. Abdominal ultrasonography showed the presence of moderate ascites and a right pleural effusion. Fecal occult blood test (FOBT) was positive while stool culture was negative. Both upper GI endoscopy and colonoscopy were negative. Capsule endoscopy showed multiple, sharply demarcated ulcers limited in the ileum with a circular shape. The margins of ulcers were clear and the intervening mucosa was normal. Stenosis could also be seen in the ileum.

The patient was treated with intravenous infusion of albumin and packed red blood cells as well as intramuscular injection of iron. After 4 wk of treatment, the dizziness and abdominal distension were gradually improved and lower extremity edema also receded. Hb increased temporarily to 90 g/L and abdominal ultrasound showed only a small amount of ascites and pleural effusion. However, FOBT remained positive and abdominal pain did not relieve. Oral prednisone was given for 1 wk but did not relieve the pain. A laparotomy was proposed but she refused. She was discharged and scheduled for outpatient follow-up.

DISCUSSION

GI bleeding-induced anemia is the most typical presenting symptom of patients suffering from CNSU and low serum protein concentration is also seen[5]. Our patient had pronounced anemia and hypoalbuminemia. Her initial manifestation was pronounced anemia followed by ascites and pleural effusions. The diagnostic criteria for CNSU were established as previously described[6], including persistent anemia for more than 1 year, small intestinal ulcers, absence of clinical evidence suggestive of mycobacterial infection, absence of clinical evidence suggestive of Crohn's disease, and lack of any dermatologic, ophthalmologic or genital symptom suggestive of Behcet's disease. The ulcers in our patient were different from those of Crohn's disease characterized by longitudinal ulcers and cobblestone appearance. There was also no evidence of complication suggestive of Crohn's disease because no perforation and fistulisation were found although the patient had a very long course of disease. Behcet's disease could also be excluded since there was no clinical evidence showing dermatologic, ophthalmologic or genital symptom in our patient.

Capsule endoscopy confirmed the diagnosis of CNSU in our patient. Matsumoto *et al*[5] reported that ulcers in CNSU patients are predominantly found in the ileum, which are circular or irregular in shape. The margins of ulcers are always clear and the intervening mucosa appears normal. Capsule endoscopy showed typical circular ulcers limited in the ileum of our patient, which is consistent with the reported findings[5].

The clinical and endoscopic features of CNSU are similar to those of NSAID-induced enteropathy. Matsumoto *et al*[6] compared the enteroscopic findings in CNSU and NSAID-induced enteropathy, and found that both are characterized by concentric stenosis and ulcers with non-specific histology while the lesions of small intestine are different in respect to their site and stage. CNSU patients have active, sharply demarcated ulcers limited in ileum while few ulcers are found in NSAID-induced enteropathy. Since our patient had no history of NSAID use, the possibility of NSAID-induced enteropathy could be excluded.

CNSU is different from another idiopathic small intestinal multiple ulcer disease described as cryptogenic multifocal ulcerous stenosing enteritis (CMUSE)[7], which is an independent, rare and poorly understood disease characterized by non-specific small intestinal ulceration and stenosis which responds to corticosteroid therapy[7]. Perlemuter *et al*[7] described that CMUSE syndrome is characterized by chronic diarrhea, bouts of intestinal obstruction, and ulcerative stenosis of the small intestine. A very important feature of CMUSE is that patients respond dramatically to corticosteroid therapy[7]. However, the therapeutic effect of corticosteroid in our patient was not good. Another dif-

ference is that anemia and hypoalbuminemia are not often seen in CMUSE patients. Our patient had a long history of pronounced anemia and hypoalbuminemia prior to the development of abdominal pain, suggesting that stenosis may not develop rapidly in CNSU.

Capsule endoscopy is the best diagnostic tool for obscure GI bleeding. Our patient was admitted because of her chronic GI bleeding with unknown origin. Since upper GI endoscopy and colonoscopy showed negative results, capsule endoscopy showed multiple circular ulcers. The affected site was limited in the ileum, thus providing the most important evidence for the diagnosis of our patient.

In conclusion, the pathophysiology of CNSU remains poorly understood. CNSU is a disease responsible for obscure GI bleeding arising from the small intestine. Capsule endoscopy contributes to the diagnosis of this peculiar form of small intestine disease.

ACKNOWLEDGMENTS

The authors thank Dr. Qing Du for his technical assistance.

REFERENCES

1 **Robertson DA**, Dixon MF, Scott BB, Simpson FG, Losowsky MS. Small intestinal ulceration: diagnostic difficulties in relation to coeliac disease. *Gut* 1983; **24**: 565-574

2 **Graham DY**, Bynum TE. Primary nonspecific small bowel ulceration as a source of chronic bleeding. Report of a case and review of the approach to localization of the site of small bowel hemorrhage. *Am J Gastroenterol* 1974; **62**: 350-355

3 **Glynn MJ**, Pendower J, Shousha S, Parkins RA. Recurrent bleeding from idiopathic ulceration of small bowel. *Br Med J* (Clin Res Ed) 1984; **288**: 975-976

4 **Wilson IR**, Cooley NV, Luibel FJ. Nonspecific stenosing small bowel ulcers. Experience in one California county. *Am J Gastroenterol* 1968; **50**: 449-455

5 **Matsumoto T**, Iida M, Matsui T, Yao T, Watanabe H, Yao T, Okabe H. Non-specific multiple ulcers of the small intestine unrelated to non-steroidal anti-inflammatory drugs. *J Clin Pathol* 2004; **57**: 1145-1150

6 **Matsumoto T**, Nakamura S, Esaki M, Yada S, Koga H, Yao T, Iida M. Endoscopic features of chronic nonspecific multiple ulcers of the small intestine: comparison with nonsteroidal anti-inflammatory drug-induced enteropathy. *Dig Dis Sci* 2006; **51**: 1357-1363

7 **Perlemuter G**, Guillevin L, Legman P, Weiss L, Couturier D, Chaussade S. Cryptogenetic multifocal ulcerous stenosing enteritis: an atypical type of vasculitis or a disease mimicking vasculitis. *Gut* 2001; **48**: 333-338

S- Editor Wang JL **L- Editor** Wang XL **E- Editor** Zheng XM

World Journal of Gastroenterology

Online Submissions: http://www.wjgnet.com/1007-9327office
wjg@wjgnet.com
doi:10.3748/wjg.v16.i6.785

World J Gastroenterol 2010 February 14; 16(6): 785-786
ISSN 1007-9327 (print)

LETTERS TO THE EDITOR

Meta-analysis of capsule endoscopy in patients diagnosed or suspected with esophageal varices

Daniel Ahn, Praveen Guturu

Daniel Ahn, Department of Internal Medicine, University of Texas Southwestern Medical Center, Dallas, TX 75390, United States
Praveen Guturu, Department of Internal Medicine, University of Texas Medical Branch, Galveston, TX 77550, United States
Author contributions: Guturu P designed and wrote the letter; Ahn D extracted analyzed the data.
Correspondence to: Praveen Guturu, MD, Department of Internal Medicine, University of Texas Medical Branch, 301 University Boulevard, Route 0570, Galveston, TX 77555, United States. prguturu@utmb.edu
Telephone: +1-409-7721011 Fax: +1-409-7725462
Received: November 25, 2009 Revised: January 2, 2010
Accepted: January 9, 2010
Published online: February 14, 2010

Abstract

The PillCam ESO (Given Imaging, Israel) or esophageal capsule endoscopy (ECE) is a novel technique used in the diagnostic evaluation of esophagus. Many studies have been performed to compare the accuracy of ECE against the current gold standard esophago-gastro-duodenoscopy and a meta-analysis recently published by Lu *et al* suggests that ECE may have an acceptable sensitivity and specificity in detecting esophageal varices. We would like to discuss the importance and implication of publication bias in this meta-analysis.

Key words: Capsule endoscopy; Screening varices

Peer reviewer: Atsushi Nakajima, Professor, Division of Gastroenterology, Yokohama City University Graduate School of Medicine, 3-9 Fuku-ura, Kanazawa-ku, Yokohama 236-0004, Japan

Ahn D, Guturu P. Meta-analysis of capsule endoscopy in patients diagnosed or suspected with esophageal varices. *World J Gastroenterol* 2010; 16(6): 785-786 Available from: URL: http://www.wjgnet.com/1007-9327/full/v16/i6/785.htm DOI: http://dx.doi.org/10.3748/wjg.v16.i6.785

TO THE EDITOR

In March 2009 issue of *World Journal of Gastroenterology*, Lu *et al*[1] published their interesting findings regarding the accuracy of esophageal capsule endoscopy (ECE) in detecting esophageal varices and its utility in screening and surveillance of esophageal varices. We would like to add that it is vital to comment on the presence or absence of any bias when reporting a meta-analysis as this will allow the readers to assess the strengths and weaknesses of the recommendation made. A recently published statement on preferred reporting items for systematic reviews and meta-analyses (PRISMA)[2], an evolution of the original quality of reporting of meta-analyses (QUOROM) guidelines, suggests that publication bias should be assessed while reporting meta-analyses and systematic reviews. Since publication bias was not reported in the above meta-analysis, we analyzed the data for the presence or absence of publication bias.

We assessed the publication bias using funnel plot. Funnel plots were plotted using log odds ratio *vs* standard error (Figure 1A) and log odds ratio *vs* precision (Figure 1B), both showed no evidence of publication bias. We complemented the funnel plots with Eggers test[3] and rank correlation analysis[4] and both also showed no evidence of publication bias ($P > 0.05$).

We hope that this information about the absence of publication bias in this meta-analysis will add more value to the conclusion reported in the above meta-analysis.

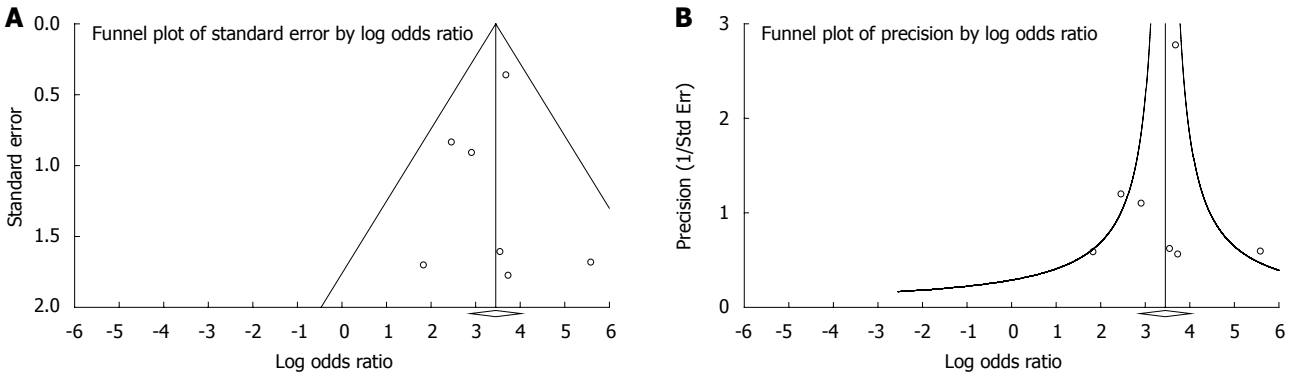

Figure 1 Funnel plot. A: Log odds ratio *vs* standard error; B: Log odds ratio *vs* precision (Precision = 1/standard error).

REFERENCES

1 **Lu Y**, Gao R, Liao Z, Hu LH, Li ZS. Meta-analysis of capsule endoscopy in patients diagnosed or suspected with esophageal varices. *World J Gastroenterol* 2009; **15**: 1254-1258

2 **Liberati A**, Altman DG, Tetzlaff J, Mulrow C, Gøtzsche PC, Ioannidis JP, Clarke M, Devereaux PJ, Kleijnen J, Moher D. The PRISMA statement for reporting systematic reviews and meta-analyses of studies that evaluate health care interventions: explanation and elaboration. *J Clin Epidemiol* 2009; **62**: e1-34

3 **Egger M**, Davey Smith G, Schneider M, Minder C. Bias in meta-analysis detected by a simple, graphical test. *BMJ* 1997; **315**: 629-634

4 **Begg CB**, Mazumdar M. Operating characteristics of a rank correlation test for publication bias. *Biometrics* 1994; **50**: 1088-1101

S- Editor Wang JL **L- Editor** Wang XL **E- Editor** Ma WH

World Journal of Gastroenterology

Online Submissions: http://www.wjgnet.com/1007-9327office
wjg@wjgnet.com
www.wjgnet.com

World J Gastroenterol 2010 February 14; 16(6): I
ISSN 1007-9327 (print)

Acknowledgments to reviewers of *World Journal of Gastroenterology*

Many reviewers have contributed their expertise and time to the peer review, a critical process to ensure the quality of *World Journal of Gastroenterology*. The editors and authors of the articles submitted to the journal are grateful to the following reviewers for evaluating the articles (including those published in this issue and those rejected for this issue) during the last editing time period.

Philip Abraham, Dr., Professor, Consultant Gastroenterologist & Hepatologist, P. D. Hinduja National Hospital & Medical Research Centre, Veer Savarkar Marg, Mahim, Mumbai 400 016, India

Taku Aoki, MD, Division of Hepato-Biliary-Pancreatic and Transplantation Surgery, Department of Surgery, Graduate School of Medicine, University of Tokyo, 7-3-1 Hongo, Bunkyo-ku, Tokyo, 113-8655, Japan

Marc Basson, MD, PhD, MBA, Department of Surgery, Michigan State University, 1200 East Michigan Avenue, Suite #655, Lansing, MI 48912, United States

Christa Buechler, PhD, Internal Medicine I, Regensburg University Medical Center, Franz Josef Strauss Allee 11, 93042 Regensburg, Germany

Itaru Endo, MD, PhD, Professor and Chairman, Department of Gastroenterological Surgery, Yokohama City University, Graduate School of Medicine, 3-9 Fukuura, Kanazawa-ku, Yokohama, 2360004, Japan

Omar Vergara-Fernandez, MD, Departments of Surgery, National Institute for Medical Sciences and Nutrition Salvador Zubirán, Vasco de Quiroga No. 15, Col. Seccion XVI. Deleg. Tlalpan, CP 14000, México

Nikolaus Gassler, Professor, Institute of Pathology, University Hospital RWTH Aachen, Pauwelsstrasse 30, 52074 Aachen, Germany

Werner Hohenberger, Professor, Department of Surgery, Hospital Strasse 12, D-91054 Erlangen, Germany

Kevin Cheng-Wen Hsiao, MD, Assistant Professor, Colon and Rectal Surgery, Tri-Service General Hospital, No. 325, Sec. 2, Cheng-Kung Rd, Nei-Hu District, 114 Taipei, Taiwan, China

Masahiro Iizuka, MD, PhD, Director, Akita Health Care Center, Akita Red Cross Hospital, 3-4-23, Nakadori, Akita, 010-0001, Japan

Beata Jolanta Jablońska, MD, PhD, Department of Digestive Tract Surgery, University Hospital of Medical University of Silesia, Medyków 14 St. 40-752 Katowice, Poland

Sherif M Karam, Dr., Professor, Department of Anatomy, Faculty of Medicine and Health Sciences, United Arab Emirates University, PO Box 17666, Al-Ain, United Arab Emirates

Patricia F Lalor, PhD, Dr., Liver Research Laboratory, Room 537 Institute of Biomedical Research, Division of Medical Science, University of Birmingham, Birmingham B15 2TT, United Kingdom

Vance Matthews, Dr., PhD, BS, Cellular and Molecular Metabolism Laboratory, Baker University of Texas Medical Branch, IDI, PO Box 6492, St Kilda Road Central, VIC 8008, Melbourne, Australia

Sri P Misra, Professor, Gastroenterology, Moti Lal Nehru Medical College, Allahabad 211001, India

Emiko Mizoguchi, MD, PhD, Department of Medicine, Gastrointestinal Unit, GRJ 702, Massachusetts General Hospital, Boston, MA 02114, United States

Naofumi Mukaida, MD, PhD, Chairperson and Professor, Division of Molecular Bioregulation, Cancer Research Institute, Kanazawa University, 13-1 Takara-machi, Kanazawa 920-0934, Japan

Akihito Nagahara, Associate Professor, Department of Gastroenterology, Juntendo University School of Medicine, 2-1-1 Hongo Bunkyo-ku, Tokyo 113-8421, Japan

Mihaela Petrova, MD, PhD, Dr., Clinic of Gastroenterology, Medical Institute, Ministry of Interior, Sofia 1606, Bulgaria

Andreas G Schreyer, Dr., Professor, Department of Radiology, University Hospital Regensburg, Franz-Josef-Strauss-Allee 11, Regensburg 93053, Germany

Rafiq A Sheikh, MBBS, MD, MRCP, FACP, FACG, Department of Gastroenterology, Kaiser Permanente Medical Center, 6600 Bruceville Road, Sacramento, CA 95823, United States

Martin Storr, MD, PhD, Associate Professor, Department of Medicine, Gastroenterology, University of Calgary, 3330 Hospital Dr NW, T2N 2N1, Calgary, Canada

Shoichiro Sumi, MD, PhD, Associate Professor, Department of Organ Reconstruction, Institute for Frontier Medical Sciences, Kyoto University, Sakyo-ku, Kyoto, 606-8507, Japan

World Journal of Gastroenterology

Online Submissions: http://www.wjgnet.com/1007-9327office
wjg@wjgnet.com
www.wjgnet.com

World J Gastroenterol 2010 February 14; 16(6): I
ISSN 1007-9327 (print)

Meetings

Events Calendar 2010

January 25-26
Tamilnadu, India
International Conference on Medical Negligence and Litigation in Medical Practice

January 25-29
Waikoloa, HI, United States
Selected Topics in Internal Medicine

January 26-27
Dubai, United Arab Emirates
2nd Middle East Gastroenterology Conference

January 28-30
Hong Kong, China
The 1st International Congress on Abdominal Obesity

February 11-13
Fort Lauderdale, FL, United States
21th Annual International Colorectal Disease Symposium

February 26-28
Carolina, United States
First Symposium of GI Oncology at The Caribbean

March 04-06
Bethesda, MD, United States
8th International Symposium on Targeted Anticancer Therapies

March 05-07
Peshawar, Pakistan
26th Pakistan Society of Gastroenterology & Endoscopy Meeting

March 09-12
Brussels, Belgium
30th International Symposium on Intensive Care and Emergency Medicine

March 12-14
Bhubaneswar, India
18th Annual Meeting of Indian National Association for Study of the Liver

March 23-26
Cairo, Egypt
14th Pan Arab Conference on Diabetes PACD14

March 25-28
Beijing, China
The 20th Conference of the Asian Pacific Association for the Study of the Liver

March 27-28
San Diego, California, United States
25th Annual New Treatments in Chronic Liver Disease

April 07-09
Dubai, United Arab Emirates
The 6th Emirates Gastroenterology and Hepatology Conference, EGHC 2010

April 14-17
Landover, Maryland, United States
12th World Congress of Endoscopic Surgery

April 14-18
Vienna, Austria
The International Liver Congress™ 2010

April 28-May 01
Dubrovnik, Croatia
3rd Central European Congress of surgery and the 5th Croatian Congress of Surgery

May 01-05
New Orleans, LA, United States
Digestive Disease Week Annual Meeting

May 06-08
Munich, Germany
The Power of Programming: International Conference on Developmental Origins of Health and Disease

May 15-19
Minneapolis, MN, United States
American Society of Colon and Rectal Surgeons Annual Meeting

June 04-06
Chicago, IL, United States
American Society of Clinical Oncologists Annual Meeting

June 09-12
Singapore, Singapore
13th International Conference on Emergency Medicine

June 14
Kosice, Slovakia
Gastro-intestinal Models in the Research of Probiotics and Prebiotics-Scientific Symposium

June 16-19
Hong Kong, China
ILTS: International Liver Transplantation Society ILTS Annual International Congress

June 20-23
Mannheim, Germany
16th World Congress for Bronchoesophagology-WCBE

June 25-29
Orlando, FL, United States
70th ADA Diabetes Scientific Sessions

August 28-31
Boston, Massachusetts, United States
10th OESO World Congress on Diseases of the Oesophagus 2010

September 10-12
Montreal, Canada
International Liver Association's Fourth Annual Conference

September 11-12
La Jolla, CA, United States
New Advances in Inflammatory Bowel Disease

September 12-15
Boston, MA, United States
ICAAC: Interscience Conference on Antimicrobial Agents and Chemotherapy Annual Meeting

September 16-18
Prague, Czech Republic
Prague Hepatology Meeting 2010

September 23-26
Prague, Czech Republic
The 1st World Congress on Controversies in Gastroenterology & Liver Diseases

October 07-09
Belgrade, Serbia
The 7th Biannual International Symposium of Society of Coloproctology

October 15-20
San Antonio, TX, United States
ACG 2010: American College of Gastroenterology Annual Scienitfic Meeting

October 23-27
Barcelona, Spain
18th United European Gastroenterology Week

October 29-November 02
Boston, Massachusetts, United States
The Liver Meeting® 2010--AASLD's 61st Annual Meeting

November 13-14
San Francisco, CA, United States
Case-Based Approach to the Management of Inflammatory Bowel Disease

December 02-04
San Francisco, CA, United States
The Medical Management of HIV/AIDS

World Journal of Gastroenterology

Online Submissions: http://www.wjgnet.com/1007-9327office
wjg@wjgnet.com
www.wjgnet.com

World J Gastroenterol 2010 February 14; 16(6): I-IV
ISSN 1007-9327 (print)

Instructions to authors

GENERAL INFORMATION

World Journal of Gastroenterology (*World J Gastroenterol*, *WJG*, print ISSN 1007-9327, DOI: 10.3748) is a weekly, open-access (OA), peer-reviewed journal supported by an editorial board of 1096 experts in gastroenterology and hepatology from 60 countries.

The biggest advantage of the OA model is that it provides free, full-text articles in PDF and other formats for experts and the public without registration, which eliminates the obstacle that traditional journals possess and usually delays the speed of the propagation and communication of scientific research results. The open access model has been proven to be a true approach that may achieve the ultimate goal of the journals, i.e. the maximization of the value to the readers, authors and society.

The role of academic journals is to exhibit the scientific levels of a country, a university, a center, a department, and even a scientist, and build an important bridge for communication between scientists and the public. As we all know, the significance of the publication of scientific articles lies not only in disseminating and communicating innovative scientific achievements and academic views, as well as promoting the application of scientific achievements, but also in formally recognizing the "priority" and "copyright" of innovative achievements published, as well as evaluating research performance and academic levels. So, to realize these desired attributes of *WJG* and create a well-recognized journal, the following four types of personal benefits should be maximized. The maximization of personal benefits refers to the pursuit of the maximum personal benefits in a well-considered optimal manner without violation of the laws, ethical rules and the benefits of others. (1) Maximization of the benefits of editorial board members: The primary task of editorial board members is to give a peer review of an unpublished scientific article via online office system to evaluate its innovativeness, scientific and practical values and determine whether it should be published or not. During peer review, editorial board members can also obtain cutting-edge information in that field at first hand. As leaders in their field, they have priority to be invited to write articles and publish commentary articles. We will put peer reviewers' names and affiliations along with the article they reviewed in the journal to acknowledge their contribution; (2) Maximization of the benefits of authors: Since *WJG* is an open-access journal, readers around the world can immediately download and read, free of charge, high-quality, peer-reviewed articles from *WJG* official website, thereby realizing the goals and significance of the communication between authors and peers as well as public reading; (3) Maximization of the benefits of readers: Readers can read or use, free of charge, high-quality peer-reviewed articles without any limits, and cite the arguments, viewpoints, concepts, theories, methods, results, conclusion or facts and data of pertinent literature so as to validate the innovativeness, scientific and practical values of their own research achievements, thus ensuring that their articles have novel arguments or viewpoints, solid evidence and correct conclusion; and (4) Maximization of the benefits of employees: It is an iron law that a first-class journal is unable to exist without first-class editors, and only first-class editors can create a first-class academic journal. We insist on strengthening our team cultivation and construction so that every employee, in an open, fair and transparent environment, could contribute their wisdom to edit and publish high-quality articles, thereby realizing the maximization of the personal benefits of editorial board members, authors and readers, and yielding the greatest social and economic benefits.

The major task of *WJG* is to report rapidly the most recent results in basic and clinical research on esophageal, gastrointestinal, liver, pancreas and biliary tract diseases, *Helicobacter pylori*, endoscopy and gastrointestinal surgery, including: gastroesophageal reflux disease, gastrointestinal bleeding, infection and tumors; gastric and duodenal disorders; intestinal inflammation, microflora and immunity; celiac disease, dyspepsia and nutrition; viral hepatitis, portal hypertension, liver fibrosis, liver cirrhosis, liver transplantation, and metabolic liver disease; molecular and cell biology; geriatric and pediatric gastroenterology; diagnosis and screening, imaging and advanced technology.

The columns in the issues of *WJG* will include: (1) Editorial: To introduce and comment on the substantial advance and its importance in the fast-developing areas; (2) Frontier: To review the most representative achievements and comment on the current research status in the important fields, and propose directions for the future research; (3) Topic Highlight: This column consists of three formats, including (A) 10 invited review articles on a hot topic, (B) a commentary on common issues of this hot topic, and (C) a commentary on the 10 individual articles; (4) Observation: To update the development of old and new questions, highlight unsolved problems, and provide strategies on how to solve the questions; (5) Guidelines for Basic Research: To provide Guidelines for basic research; (6) Guidelines for Clinical Practice: To provide guidelines for clinical diagnosis and treatment; (7) Review: To systemically review the most representative progress and unsolved problems in the major scientific disciplines, comment on the current research status, and make suggestions on the future work; (8) Original Article: To originally report the innovative and valuable findings in gastroenterology and hepatology; (9) Brief Article: To briefly report the novel and innovative findings in gastroenterology and hepatology; (10) Case Report: To report a rare or typical case; (11) Letters to the Editor: To discuss and make reply to the contributions published in *WJG*, or to introduce and comment on a controversial issue of general interest; (12) Book Reviews: To introduce and comment on quality monographs of gastroenterology and hepatology; and (13) Guidelines: To introduce Consensuses and Guidelines reached by international and national academic authorities worldwide on basic research and clinical practice gastroenterology and hepatology.

CSSN
ISSN 1007-9327 (print)
CN 14-1219/R

Indexed and Abstracted in
Current Contents®/Clinical Medicine, Science Citation Index Expanded (also known as SciSearch®), Journal Citation Reports®, Index Medicus, MEDLINE, PubMed, PubMed Central, Digital Object Identifer, and EMBASE/Excerpta Medica. ISI, Thomson Reuters, 2008 Impact Factor: 2.081 (32/55 Gastroenterology and Hepatology).

Published by
Beijing Baishideng BioMed Scientific Co., Ltd.

SUBMISSION OF MANUSCRIPTS

Manuscripts should be typed in 1.5 line spacing and 12 pt. Book Antiqua with ample margins. Number all pages consecutively, and start each of the following sections on a new page: Title Page,

Abstract, Introduction, Materials and Methods, Results, Discussion, Acknowledgements, References, Tables, Figures, and Figure Legends. Neither the editors nor the publisher are responsible for the opinions expressed by contributors. Manuscripts formally accepted for publication become the permanent property of Beijing Baishideng BioMed Scientific Co., Ltd, and may not be reproduced by any means, in whole or in part, without the written permission of both the authors and the publisher. We reserve the right to copy-edit and put onto our website accepted manuscripts. Authors should follow the relevant guidelines for the care and use of laboratory animals of their institution or national animal welfare committee. For the sake of transparency in regard to the performance and reporting of clinical trials, we endorse the policy of the International Committee of Medical Journal Editors to refuse to publish papers on clinical trial results if the trial was not recorded in a publicly-accessible registry at its outset. The only register now available, to our knowledge, is http://www. clinicaltrials.gov sponsored by the United States National Library of Medicine and we encourage all potential contributors to register with it. However, in the case that other registers become available you will be duly notified. A letter of recommendation from each author's organization should be provided with the contributed article to ensure the privacy and secrecy of research is protected.

Authors should retain one copy of the text, tables, photographs and illustrations because rejected manuscripts will not be returned to the author(s) and the editors will not be responsible for loss or damage to photographs and illustrations sustained during mailing.

Online submissions

Manuscripts should be submitted through the Online Submission System at: http://www.wjgnet.com/1007-9327office. Authors are highly recommended to consult the ONLINE INSTRUCTIONS TO AUTHORS (http://www.wjgnet.com/1007-9327/Instructions-toAuthprs.asp) before attempting to submit online. For assistance, authors encountering problems with the Online Submission System may send an email describing the problem to wjg@wjgnet.com, or by telephone: +86-10-5908-0039. If you submit your manuscript online, do not make a postal contribution. Repeated online submission for the same manuscript is strictly prohibited.

MANUSCRIPT PREPARATION

All contributions should be written in English. All articles must be submitted using word-processing software. All submissions must be typed in 1.5 line spacing and 12 pt. Book Antiqua with ample margins. Style should conform to our house format. Required information for each of the manuscript sections is as follows:

Title page

Title: Title should be less than 12 words.

Running title: A short running title of less than 6 words should be provided.

Authorship: Authorship credit should be in accordance with the standard proposed by International Committee of Medical Journal Editors, based on (1) substantial contributions to conception and design, acquisition of data, or analysis and interpretation of data; (2) drafting the article or revising it critically for important intellectual content; and (3) final approval of the version to be published. Authors should meet conditions 1, 2, and 3.

Institution: Author names should be given first, then the complete name of institution, city, province and postcode. For example, Xu-Chen Zhang, Li-Xin Mei, Department of Pathology, Chengde Medical College, Chengde 067000, Hebei Province, China. One author may be represented from two institutions, for example, George Sgourakis, Department of General, Visceral, and Transplantation Surgery, Essen 45122, Germany; George Sgourakis, 2nd Surgical Department, Korgialenio-Benakio Red Cross Hospital, Athens 15451, Greece

Author contributions: The format of this section should be: Author contributions: Wang CL and Liang L contributed equally to this work; Wang CL, Liang L, Fu JF, Zou CC, Hong F and Wu XM designed the research; Wang CL, Zou CC, Hong F and Wu XM performed the research; Xue JZ and Lu JR contributed new reagents/analytic tools; Wang CL, Liang L and Fu JF analyzed the data; and Wang CL, Liang L and Fu JF wrote the paper.

Supportive foundations: The complete name and number of supportive foundations should be provided, e.g., Supported by National Natural Science Foundation of China, No. 30224801

Correspondence to: Only one corresponding address should be provided. Author names should be given first, then author title, affiliation, the complete name of institution, city, postcode, province, country, and email. All the letters in the email should be in lower case. A space interval should be inserted between country name and email address. For example, Montgomery Bissell, MD, Professor of Medicine, Chief, Liver Center, Gastroenterology Division, University of California, Box 0538, San Francisco, CA 94143, United States. montgomery.bissell@ucsf.edu

Telephone and fax: Telephone and fax should consist of +, country number, district number and telephone or fax number, e.g., Telephone: +86-10-59080039 Fax: +86-10-85381893

Peer reviewers: All articles received are subject to peer review. Normally, three experts are invited for each article. Decision for acceptance is made only when at least two experts recommend an article for publication. Reviewers for accepted manuscripts are acknowledged in each manuscript, and reviewers of articles which were not accepted will be acknowledged at the end of each issue. To ensure the quality of the articles published in *WJG*, reviewers of accepted manuscripts will be announced by publishing the name, title/position and institution of the reviewer in the footnote accompanying the printed article. For example, reviewers: Professor Jing-Yuan Fang, Shanghai Institute of Digestive Disease, Shanghai, Affiliated Renji Hospital, Medical Faculty, Shanghai Jiaotong University, Shanghai, China; Professor Xin-Wei Han, Department of Radiology, The First Affiliated Hospital, Zhengzhou University, Zhengzhou, Henan Province, China; and Professor Anren Kuang, Department of Nuclear Medicine, Huaxi Hospital, Sichuan University, Chengdu, Sichuan Province, China.

Abstract

There are unstructured abstracts (no more than 256 words) and structured abstracts (no more than 480). The specific requirements for structured abstracts are as follows:

An informative, structured abstracts of no more than 480 words should accompany each manuscript. Abstracts for original contributions should be structured into the following sections. AIM (no more than 20 words): Only the purpose should be included. Please write the aim as the form of "To investigate/study/…; MATERIALS AND METHODS (no more than 140 words); RESULTS (no more than 294 words): You should present *P* values where appropriate and must provide relevant data to illustrate how they were obtained, e.g. 6.92 ± 3.86 *vs* 3.61 ± 1.67, $P < 0.001$; CONCLUSION (no more than 26 words). Available from: http://www.wjgnet.com/wjg/help/8.doc; Writing requirements of abstract at: http://www.wjgnet.com/1007-9327/links/Abstract.doc.

Key words

Please list 5-10 key words, selected mainly from *Index Medicus*, which reflect the content of the study.

Text

For articles of these sections, original articles, rapid communication and case reports, the main text should be structured into the following sections: INTRODUCTION, MATERIALS AND METHODS, RESULTS and DISCUSSION, and should include appropriate Figures and Tables. Data should be presented in the

main text or in Figures and Tables, but not in both. The main text format of these sections, editorial, topic highlight, case report, letters to the editors, can be found at: http://www.wjgnet.com/wjg/help/instructions.jsp.

Illustrations

Figures should be numbered as 1, 2, 3, *etc.*, and mentioned clearly in the main text. Provide a brief title for each figure on a separate page. Detailed legends should not be provided under the figures. This part should be added into the text where the figures are applicable. Figures should be either Photoshop or Illustrator files (in tiff, eps, jpeg formats) at high-resolution. Examples can be found at: http://www.wjgnet.com/1007-9327/13/4520.pdf; http://www.wjgnet.com/1007-9327/13/4554.pdf; http://www.wjgnet.com/1007-9327/13/4891.pdf; http://www.wjgnet.com/1007-9327/13/4986.pdf; http://www.wjgnet.com/1007-9327/13/4498.pdf. Keeping all elements compiled is necessary in line-art image. Scale bars should be used rather than magnification factors, with the length of the bar defined in the legend rather than on the bar itself. File names should identify the figure and panel. Avoid layering type directly over shaded or textured areas. Please use uniform legends for the same subjects. For example: Figure 1 Pathological changes in atrophic gastritis after treatment. A:...; B:...; C:...; D:...; E:...; F:...; G: …*etc.* It is our principle to publish high resolution-figures for the printed and E-versions.

Tables

Three-line tables should be numbered 1, 2, 3, *etc.*, and mentioned clearly in the main text. Provide a brief title for each table. Detailed legends should not be included under tables, but rather added into the text where applicable. The information should complement, but not duplicate the text. Use one horizontal line under the title, a second under column heads, and a third below the Table, above any footnotes. Vertical and italic lines should be omitted.

Notes in tables and illustrations

Data that are not statistically significant should not be noted. $^{a}P < 0.05$, $^{b}P < 0.01$ should be noted ($P > 0.05$ should not be noted). If there are other series of P values, $^{c}P < 0.05$ and $^{d}P < 0.01$ are used. A third series of P values can be expressed as $^{e}P < 0.05$ and $^{f}P < 0.01$. Other notes in tables or under illustrations should be expressed as ^{1}F, ^{2}F, ^{3}F; or sometimes as other symbols with a superscript (Arabic numerals) in the upper left corner. In a multi-curve illustration, each curve should be labeled with ●, ○, ■, □, ▲, △, *etc.*, in a certain sequence.

Acknowledgments

Brief acknowledgments of persons who have made genuine contributions to the manuscript and who endorse the data and conclusions should be included. Authors are responsible for obtaining written permission to use any copyrighted text and/or illustrations.

REFERENCES

Coding system

The author should number the references in Arabic numerals according to the citation order in the text. Put reference numbers in square brackets in superscript at the end of citation content or after the cited author's name. For citation content which is part of the narration, the coding number and square brackets should be typeset normally. For example, "Crohn's disease (CD) is associated with increased intestinal permeability[1,2]". If references are cited directly in the text, they should be put together within the text, for example, "From references[19,22-24], we know that..."

When the authors write the references, please ensure that the order in text is the same as in the references section, and also ensure the spelling accuracy of the first author's name. Do not list the same citation twice.

PMID and DOI

Pleased provide PubMed citation numbers to the reference list, e.g. PMID and DOI, which can be found at http://www.ncbi.nlm.nih.gov/sites/entrez?db=pubmed and http://www.crossref.org/SimpleTextQuery/, respectively. The numbers will be used in E-version of this journal.

Style for journal references

Authors: the name of the first author should be typed in bold-faced letters. The family name of all authors should be typed with the initial letter capitalized, followed by their abbreviated first and middle initials. (For example, Lian-Sheng Ma is abbreviated as Ma LS, Bo-Rong Pan as Pan BR). The title of the cited article and italicized journal title (journal title should be in its abbreviated form as shown in PubMed), publication date, volume number (in black), start page, and end page [PMID: 11819634 DOI: 10.3748/wjg.13.5396].

Style for book references

Authors: the name of the first author should be typed in bold-faced letters. The surname of all authors should be typed with the initial letter capitalized, followed by their abbreviated middle and first initials. (For example, Lian-Sheng Ma is abbreviated as Ma LS, Bo-Rong Pan as Pan BR) Book title. Publication number. Publication place: Publication press, Year: start page and end page.

Format

Journals

English journal article (list all authors and include the PMID where applicable)

1 **Jung EM**, Clevert DA, Schreyer AG, Schmitt S, Rennert J, Kubale R, Feuerbach S, Jung F. Evaluation of quantitative contrast harmonic imaging to assess malignancy of liver tumors: A prospective controlled two-center study. *World J Gastroenterol* 2007; **13**: 6356-6364 [PMID: 18081224 DOI: 10.3748/wjg.13.6356]

Chinese journal article (list all authors and include the PMID where applicable)

2 **Lin GZ**, Wang XZ, Wang P, Lin J, Yang FD. Immunologic effect of Jianpi Yishen decoction in treatment of Pixu-diarrhoea. *Shijie Huaren Xiaohua Zazhi* 1999; **7**: 285-287

In press

3 **Tian D**, Araki H, Stahl E, Bergelson J, Kreitman M. Signature of balancing selection in Arabidopsis. *Proc Natl Acad Sci USA* 2006; In press

Organization as author

4 **Diabetes Prevention Program Research Group**. Hypertension, insulin, and proinsulin in participants with impaired glucose tolerance. *Hypertension* 2002; **40**: 679-686 [PMID: 12411462 PMCID:2516377 DOI:10.1161/01.HYP.0000035706.28494.09]

Both personal authors and an organization as author

5 **Vallancien G**, Emberton M, Harving N, van Moorselaar RJ; Alf-One Study Group. Sexual dysfunction in 1, 274 European men suffering from lower urinary tract symptoms. *J Urol* 2003; **169**: 2257-2261 [PMID: 12771764 DOI:10.1097/01.ju.0000067940.76090.73]

No author given

6 21st century heart solution may have a sting in the tail. *BMJ* 2002; **325**: 184 [PMID: 12142303 DOI:10.1136/bmj.325.7357.184]

Volume with supplement

7 **Geraud G**, Spierings EL, Keywood C. Tolerability and safety of frovatriptan with short- and long-term use for treatment of migraine and in comparison with sumatriptan. *Headache* 2002; **42** Suppl 2: S93-99 [PMID: 12028325 DOI:10.1046/j.1526-4610.42.s2.7.x]

Issue with no volume

8 **Banit DM**, Kaufer H, Hartford JM. Intraoperative frozen section analysis in revision total joint arthroplasty. *Clin Orthop Relat Res* 2002; (**401**): 230-238 [PMID: 12151900 DOI:10.1097/00003086-200208000-00026]

No volume or issue

9 Outreach: Bringing HIV-positive individuals into care. *HRSA Careaction* 2002; 1-6 [PMID: 12154804]

Books

Personal author(s)

10 **Sherlock S**, Dooley J. Diseases of the liver and billiary system. 9th ed. Oxford: Blackwell Sci Pub, 1993: 258-296

Chapter in a book (list all authors)

11 **Lam SK**. Academic investigator's perspectives of medical treatment for peptic ulcer. In: Swabb EA, Azabo S. Ulcer disease: investigation and basis for therapy. New York: Marcel Dekker, 1991: 431-450

Author(s) and editor(s)

12 **Breedlove GK**, Schorfheide AM. Adolescent pregnancy. 2nd ed. Wieczorek RR, editor. White Plains (NY): March of Dimes Education Services, 2001: 20-34

Conference proceedings

13 **Harnden P**, Joffe JK, Jones WG, editors. Germ cell tumours V. Proceedings of the 5th Germ cell tumours Conference; 2001 Sep 13-15; Leeds, UK. New York: Springer, 2002: 30-56

Conference paper

14 **Christensen S**, Oppacher F. An analysis of Koza's computational effort statistic for genetic programming. In: Foster JA, Lutton E, Miller J, Ryan C, Tettamanzi AG, editors. Genetic programming. EuroGP 2002: Proceedings of the 5th European Conference on Genetic Programming; 2002 Apr 3-5; Kinsdale, Ireland. Berlin: Springer, 2002: 182-191

Electronic journal (list all authors)

15 Morse SS. Factors in the emergence of infectious diseases. Emerg Infect Dis serial online, 1995-01-03, cited 1996-06-05; 1(1): 24 screens. Available from: URL: http//www.cdc.gov/ncidod/EID/eid.htm

Patent (list all authors)

16 **Pagedas AC**, inventor; Ancel Surgical R&D Inc., assignee. Flexible endoscopic grasping and cutting device and positioning tool assembly. United States patent US 20020103498. 2002 Aug 1

Statistical data

Write as mean ± SD or mean ± SE.

Statistical expression

Express *t* test as *t* (in italics), *F* test as *F* (in italics), chi square test as χ^2 (in Greek), related coefficient as *r* (in italics), degree of freedom as υ (in Greek), sample number as *n* (in italics), and probability as *P* (in italics).

Units

Use SI units. For example: body mass, m (B) = 78 kg; blood pressure, p (B) = 16.2/12.3 kPa; incubation time, t (incubation) = 96 h, blood glucose concentration, c (glucose) 6.4 ± 2.1 mmol/L; blood CEA mass concentration, p (CEA) = 8.6 24.5 μg/L; CO_2 volume fraction, 50 mL/L CO_2, not 5% CO_2; likewise for 40 g/L formaldehyde, not 10% formalin; and mass fraction, 8 ng/g, *etc.* Arabic numerals such as 23, 243, 641 should be read 23 243 641.

The format for how to accurately write common units and quantums can be found at: http://www.wjgnet.com/wjg/help/15.doc.

Abbreviations

Standard abbreviations should be defined in the abstract and on first mention in the text. In general, terms should not be abbreviated unless they are used repeatedly and the abbreviation is helpful to the reader. Permissible abbreviations are listed in Units, Symbols and Abbreviations: A Guide for Biological and Medical Editors and Authors (Ed. Baron DN, 1988) published by The Royal Society of Medicine, London. Certain commonly used abbreviations, such as DNA, RNA, HIV, LD50, PCR, HBV, ECG, WBC, RBC, CT, ESR, CSF, IgG, ELISA, PBS, ATP, EDTA, mAb, can be used directly without further explanation.

Italics

Quantities: *t* time or temperature, *c* concentration, *A* area, *l* length, *m* mass, *V* volume.

Genotypes: *gyrA*, *arg* 1, *c myc*, *c fos*, *etc.*

Restriction enzymes: *Eco*RI, *Hin*dI, *Bam*HI, *Kbo* I, *Kpn* I, *etc.*

Biology: *H. pylori*, *E coli*, *etc.*

RESUBMISSION OF THE REVISED MANUSCRIPTS

Please revise your article according to the revision policies of *WJG*. The revised version includes manuscript and high-resolution image figures. The author should re-submit the revised manuscript online, along with printed high-resolution color or black and white photos; Copyright transfer letter, and responses to the reviewers, and science news are sent to us *via* email.

Editorial Office

World Journal of Gastroenterology
Editorial Department: Room 903, Building D,
Ocean International Center,
No. 62 Dongsihuan Zhonglu,
Chaoyang District, Beijing 100025, China
E-mail: wjg@wjgnet.com
http://www.wjgnet.com
Telephone: +86-10-5908-0039
Fax: +86-10-85381893

Language evaluation

The language of a manuscript will be graded before it is sent for revision. (1) Grade A: priority publishing; (2) Grade B: minor language polishing; (3) Grade C: a great deal of language polishing needed; and (4) Grade D: rejected. Revised articles should reach Grade A or B.

Copyright assignment form

Please download a Copyright assignment form from http://www.wjgnet.com/1007-9327/news/10.doc.

Responses to reviewers

Please revise your article according to the comments/suggestions provided by the reviewers. The format for responses to the reviewers' comments can be found at: http://www.wjgnet.com/1007-9327/news/12.doc.

Proof of financial support

For paper supported by a foundation, authors should provide a copy of the document and serial number of the foundation.

Science news releases

Authors of accepted manuscripts are suggested to write a science news item to promote their articles. The news will be released rapidly at EurekAlert/AAAS (http://www.eurekalert.org). The title for news items should be less than 90 characters; the summary should be less than 75 words; and main body less than 500 words. Science news items should be lawful, ethical, and strictly based on your original content with an attractive title and interesting pictures.

Publication fee

Authors of accepted articles must pay a publication fee.
EDITORIAL, TOPIC HIGHLIGHTS, BOOK REVIEWS and LETTERS TO THE EDITOR are published free of charge.