ISSN 1007-9327 (print)
ISSN 2219-2840 (online)

World Journal of *Gastroenterology*

World J Gastroenterol 2020 October 7; 26(37): 5534-5744

Published by Baishideng Publishing Group Inc

World Journal of Gastroenterology

Contents

Weekly Volume 26 Number 37 October 7, 2020

OPINION REVIEW

5534 Review of inflammatory bowel disease and COVID-19

Sultan K, Mone A, Durbin L, Khuwaja S, Swaminath A

REVIEW

5543 Hepatitis E virus: Epidemiology, diagnosis, clinical manifestations, and treatment

Aslan AT, Balaban HY

5561 Transjugular intrahepatic portosystemic shunt in cirrhosis: An exhaustive critical update

Rajesh S, George T, Philips CA, Ahamed R, Kumbar S, Mohan N, Mohanan M, Augustine P

MINIREVIEWS

5597 Calcifying fibrous tumor of the gastrointestinal tract: A clinicopathologic review and update

Turbiville D, Zhang X

5606 Artificial intelligence technologies for the detection of colorectal lesions: The future is now

Attardo S, Chandrasekar VT, Spadaccini M, Maselli R, Patel HK, Desai M, Capogreco A, Badalamenti M, Galtieri PA, Pellegatta G, Fugazza A, Carrara S, Anderloni A, Occhipinti P, Hassan C, Sharma P, Repici A

5617 Application of artificial intelligence in the diagnosis and treatment of hepatocellular carcinoma: A review

Jiménez Pérez M, Grande RG

ORIGINAL ARTICLE

Basic Study

5629 Antioxidant activity and hepatoprotective effect of 10 medicinal herbs on CCl_4-induced liver injury in mice

Meng X, Tang GY, Liu PH, Zhao CJ, Liu Q, Li HB

Case Control Study

5646 Short- and long-term outcomes associated with enhanced recovery after surgery protocol *vs* conventional management in patients undergoing laparoscopic gastrectomy

Tian YL, Cao SG, Liu XD, Li ZQ, Liu G, Zhang XQ, Sun YQ, Zhou X, Wang DS, Zhou YB

Retrospective Cohort Study

5661 Periodontitis combined with smoking increases risk of the ulcerative colitis: A national cohort study

Kang EA, Chun J, Kim JH, Han K, Soh H, Park S, Hong SW, Moon JM, Lee J, Lee HJ, Park JB, Im JP, Kim JS

Contents

Retrospective Study

5673 Preliminary experience of hybrid endoscopic submucosal dissection by duodenoscope for recurrent laterally spreading papillary lesions

Wang ZK, Liu F, Wang Y, Wang XD, Tang P, Li W

5682 *Helicobacter pylori* infection with atrophic gastritis: An independent risk factor for colorectal adenomas

Chen QF, Zhou XD, Fang DH, Zhang EG, Lin CJ, Feng XZ, Wang N, Wu JS, Wang D, Lin WH

Clinical Trials Study

5693 Endoscopic ultrasound-fine needle biopsies of pancreatic lesions: Prospective study of histology quality using Franseen needle

Stathopoulos P, Pehl A, Breitling LP, Bauer C, Grote T, Gress TM, Denkert C, Denzer UW

Prospective Study

5705 Risk prediction rule for advanced neoplasia on screening colonoscopy for average-risk individuals

Sharara AI, El Mokahal A, Harb AH, Khalaf N, Sarkis FS, M El-Halabi M, Mansour NM, Malli A, Habib R

EVIDENCE-BASED MEDICINE

5718 Endoscopic retrograde cholangiopancreatography in the treatment of pancreaticopleural fistula in children

Zhang J, Gao LC, Guo S, Mei TL, Zhou J, Wang GL, Yu FH, Fang YL, Xu BP

CASE REPORT

5731 Abernethy syndrome in Slovenian children: Five case reports and review of literature

Peček J, Fister P, Homan M

Contents

ABOUT COVER

Editorial Board of *World Journal of Gastroenterology*, Dr. Angelo Zambam de Mattos is a Professor of Medicine – Gastroenterology at the Federal University of Health Sciences of Porto Alegre (UFCSPA), where he is also a permanent faculty member of the Graduate Program in Medicine: Hepatology (the only Brazilian graduate program specialized specifically in Hepatology). His research focuses on cirrhosis and its complications, culminating in > 50 academic papers. He also carries out clinical work at Irmandade Santa Casa de Misericórdia of Porto Alegre, one of the largest hospital complexes in southern Brazil. Prof. Mattos received his Medical degree in 2005, Master's degree in 2012 and PhD in 2015, all from UFCSPA. He is a member of the Brazilian Federation of Gastroenterology, Brazilian Association of Hepatology, and Brazilian Association of Digestive Endoscopy, and he is past president of the Gastroenterology Association of Rio Grande do Sul, Brazil (2017-2018). (L-Editor: Filipodia)

AIMS AND SCOPE

The primary aim of *World Journal of Gastroenterology* (*WJG*, *World J Gastroenterol*) is to provide scholars and readers from various fields of gastroenterology and hepatology with a platform to publish high-quality basic and clinical research articles and communicate their research findings online. *WJG* mainly publishes articles reporting research results and findings obtained in the field of gastroenterology and hepatology and covering a wide range of topics including gastroenterology, hepatology, gastrointestinal endoscopy, gastrointestinal surgery, gastrointestinal oncology, and pediatric gastroenterology.

INDEXING/ABSTRACTING

The *WJG* is now indexed in Current Contents®/Clinical Medicine, Science Citation Index Expanded (also known as SciSearch®), Journal Citation Reports®, Index Medicus, MEDLINE, PubMed, PubMed Central, and Scopus. The 2020 edition of Journal Citation Report® cites the 2019 impact factor (IF) for *WJG* as 3.665; IF without journal self cites: 3.534; 5-year IF: 4.048; Ranking: 35 among 88 journals in gastroenterology and hepatology; and Quartile category: Q2.

RESPONSIBLE EDITORS FOR THIS ISSUE

Production Editor: *Yu-Jie Ma*; **Production Department Director:** *Xiang Li*; **Editorial Office Director:** *Ze-Mao Gong*.

NAME OF JOURNAL
World Journal of Gastroenterology

ISSN
ISSN 1007-9327 (print) ISSN 2219-2840 (online)

LAUNCH DATE
October 1, 1995

FREQUENCY
Weekly

EDITORS-IN-CHIEF
Andrzej S Tarnawski, Subrata Ghosh

EDITORIAL BOARD MEMBERS
http://www.wjgnet.com/1007-9327/editorialboard.htm

PUBLICATION DATE
October 7, 2020

INSTRUCTIONS TO AUTHORS
https://www.wjgnet.com/bpg/gerinfo/204

GUIDELINES FOR ETHICS DOCUMENTS
https://www.wjgnet.com/bpg/GerInfo/287

GUIDELINES FOR NON-NATIVE SPEAKERS OF ENGLISH
https://www.wjgnet.com/bpg/gerinfo/240

PUBLICATION ETHICS
https://www.wjgnet.com/bpg/GerInfo/288

PUBLICATION MISCONDUCT
https://www.wjgnet.com/bpg/gerinfo/208

ARTICLE PROCESSING CHARGE
https://www.wjgnet.com/bpg/gerinfo/242

STEPS FOR SUBMITTING MANUSCRIPTS
https://www.wjgnet.com/bpg/GerInfo/239

ONLINE SUBMISSION
https://www.f6publishing.com

World Journal of Gastroenterology

Submit a Manuscript: https://www.f6publishing.com

World J Gastroenterol 2020 October 7; 26(37): 5534-5542

DOI: 10.3748/wjg.v26.i37.5534

ISSN 1007-9327 (print) ISSN 2219-2840 (online)

OPINION REVIEW

Review of inflammatory bowel disease and COVID-19

Keith Sultan, Anjali Mone, Laura Durbin, Samreen Khuwaja, Arun Swaminath

ORCID number: Keith Sultan 0000-0002-7619-2024; Anjali Mone 0000-0002-4619-6585; Laura Durbin 0000-0002-2766-0899; Samreen Khuwaja 0000-0003-3676-9906; Arun Swaminath 0000-0003-3495-012X.

Author contributions: Sultan K conceived of the manuscript and wrote the first and final versions of the manuscript; Swaminath A did the final editing; Khuwaja S, Mone A and Durbin L conducted the literature search and edited the original and final versions of the manuscript.

Conflict-of-interest statement: None of the authors have conflicts of interest to declare.

Manuscript source: Unsolicited manuscript

Keith Sultan, Division of Gastroenterology, Northwell Health, North Shore University Hospital and Long Island Jewish Medical Center, Great Neck, NY 10021, United States

Anjali Mone, Department of Gastroenterology, Northwell Health, Lenox Hill Hospital, New York, NY 10075, United States

Laura Durbin, Department of Medicine, Northwell Health, Lenox Hill Hospital, New York, NY 10075, United States

Samreen Khuwaja, Department of Medicine, Northwell Health, Long Island Jewish Forest Hills Hospital, Queens, NY 11375, United States

Arun Swaminath, Division of Gastroenterology, Northwell Health, Lenox Hill Hospital, New York, NY 10075, United States

Corresponding author: Keith Sultan, MD, Associate Professor, Division of Gastroenterology, Northwell Health, North Shore University Hospital and Long Island Jewish Medical Center, 600 Northern BLVD, Suite 111, Great Neck, NY 10021, United States. ksultan@northwell.edu

Abstract

The first cases of a novel corona virus infection were reported in Wuhan China in December of 2019, followed by the declaration of an international pandemic by the World Health Organization in March 2020. Early reports of the virus, now known as severe acute respiratory syndrome coronavirus 2, and its clinical disease coronavirus disease 2019 (COVID-19), has shown higher rates of morbidity and mortality in the elderly and those with pre-existing medical conditions. Of particular concern is the safety of those with compromised immune systems. Inflammatory Bowel disease (IBD) is itself caused by a disordered immune response, with the most effective medical therapies being immune suppressing or modifying. As such, the risk of COVID-19, virus related outcomes, and appropriate management of IBD patients during the global pandemic is of immediate concern to gastroenterologists worldwide. There has been a rapid accumulation of clinical data and expert opinion on the topic. This review will highlight the latest source information on clinical observation/outcomes of the IBD population and provide a concise summary of the most up to date perspectives on IBD management in the age of COVID-19.

Key Words: Inflammatory bowel disease; COVID-19; SARS-CoV-2; Corona virus; Pandemic

Received: April 22, 2020
Peer-review started: April 22, 2020
First decision: May 15, 2020
Revised: August 14, 2020
Accepted: September 1, 2020
Article in press: September 1, 2020
Published online: October 7, 2020

P-Reviewer: Orlando A, Spadaccini M
S-Editor: Wang DM
L-Editor: A
P-Editor: Wu YXJ

Core Tip: The rapid spread of coronavirus disease 2019 (COVID-19) has impacted patients and medical practice across the globe. While all individuals are at risk for COVID-19, this risk is of particular concern to those with compromised immune systems. Inflammatory bowel disease (IBD) patients are presumed to be particularly vulnerable, particularly those on immune suppressing/modifying medications. There has been rapid publication of peer reviewed source material and expert opinion addressing IBD experience, outcomes, and management in the age of COVID-19. This review provides a concise summary to help facilitate safe and effective patient management.

Citation: Sultan K, Mone A, Durbin L, Khuwaja S, Swaminath A. Review of inflammatory bowel disease and COVID-19. *World J Gastroenterol* 2020; 26(37): 5534-5542
URL: https://www.wjgnet.com/1007-9327/full/v26/i37/5534.htm
DOI: https://dx.doi.org/10.3748/wjg.v26.i37.5534

INTRODUCTION

The first cases of a novel coronavirus infection were reported in Wuhan, China in December of 2019[1]. Since that time the virus has spread to all continents except Antarctica, with the World Health Organization declaring a global pandemic on March 11, 2020. As with other, similar coronaviruses, such as those associated with severe acute respiratory syndrome (SARS) and Middle East respiratory syndrome (MERS), the primary manifestations of active infection are respiratory. Patients typically develop fever, cough, and shortness of breath, with a significant minority progressing to severe lung injury requiring the use of supplemental oxygen, and the need for mechanical ventilation with a high associated mortality rate[2-4]. Since its identification, the virus has been assigned the formal nomenclature of severe acute respiratory syndrome coronavirus 2 (SARS-CoV-2), with the associated clinical illness designated as 2019 novel coronavirus (2019-nCoV) or coronavirus disease 2019 (COVID-19)[5].

As was observed during the initial outbreak in China, and then even more dramatically in Italy, those at highest risk were noted to be the elderly and those with preexisting medical conditions, particularly cardiovascular, respiratory, endocrine, and oncologic[6,7]. As with most communicable infectious diseases, particular concern has also been raised for the safety of those with coexisting immune mediated disease, and/or those on immune compromising therapies. For the gastroenterology community (providers, patients and caregivers) this has obviously sparked particular concern for those individuals with inflammatory bowel disease (IBD). IBD is regarded as a disease of immune dysregulation, and with the exception of some limited use of diet, antibiotic and topical anti-inflammatory therapies, the vast majority of effective IBD medications for moderate to severe disease are immune suppressing/modifying[8-10]. While IBD itself is not regarded to increase non-gastrointestinal (GI) infectious disease risk[11], there is ample evidence demonstrating an increased risk of non-GI, opportunistic infections associated with IBD therapies[12-16]. Given the need for clinical evidence and expert guidance, the past weeks have seen the rapid growth of information specifically geared towards answering the core questions faced by IBD patients and providers. This work falls into two main categories, each of which we will briefly review: (1) Clinical observation of the IBD patient experience during the COVID-19 pandemic; and (2) Expert opinion on the management of IBD in an environment of COVID-19.

IBD AND COVID-19 CLINICAL EXPERIENCE

Though there is currently no evidence of SARS-CoV-2 exacerbating underlying IBD, it is now well recognized that many patients with COVID-19 will develop GI complaints. The SARS-CoV-2 invades human cells by interactions with angiotensin-converting enzyme 2 (ACE2). The ACE2 receptor is found in different tissues throughout the body, including those of enterocytes[17-19]. Studies have shown the presence of SARS-

CoV-2 in stool with persistence of viral shedding in the stool even after the resolution of respiratory complaints[20,21]. Notably, recent basic scientific evidence has observed an up-regulation of ACE2 in the inflamed mucosa of IBD patients, suggesting how IBD patients might be at increased risk for COVID-19[22,23]. However, it is also worth noting that a soluble form of ACE2 circulating in the blood is also up-regulated in IBD, which may provide an alternate binding site for SARS-CoV-2 that could limit viral binding to cell surfaces[24]. Further studies on viral load and viral dynamics are required to clarify the clinical significance of these findings.

Cheung *et al*[25] in their systematic review and meta-analysis of 69 studies (53 from China) including 4243 COVID-19 patients, demonstrated a pooled prevalence of all gastrointestinal symptoms of 16.1% [95% Confidence Interval (CI): 10.9-23.0] from China, and 33.4% (95%CI: 15.2-58.3) in studies from all other countries. The most common complaint was anorexia 26.8% (95%CI: 16.2-40.8), followed by nausea/vomiting 10.2% (95%CI: 6.6-15.3), diarrhea 12.5% (95%CI: 9.6-16.0), and abdominal pain/discomfort 9.2% (95%CI: 5.7-14.5). It is unknown however how many of these patients had a prior IBD diagnosis or other GI condition. Goyal *et al*[26] in a more recent analysis of 393 consecutive patients admitted to 2 New York City hospitals also showed GI complaints were prominent, including diarrhea (23.7%) and nausea with vomiting (19.1%).

Despite these high rates of GI complaints, Mao *et al*[27] in their report of COVID-19's impact on those with preexisting GI conditions, noted that there had been no reports of IBD patients infected with SARS-CoV-2 in the IBD Elite Union, a consortium of the seven largest Chinese IBD referral centers, caring for over 20000 patients. The authors also reported that there had been no cases of IBD/SARS-CoV-2 infected patients in the three largest tertiary IBD centers in Wuhan (Tongji Hospital, Union Hospital, and Zhongnan Hospital) at the time their manuscript was prepared, March 8, 2020. While these results are encouraging, the methodology of case identification/reporting, and thus the true rate of IBD/SARS-CoV-2, remains unclear. Also, as rates of IBD and utilization of IBD medication may differ in China from those in other countries, these results may not be applicable to other populations.

Low rates of IBD/SARS-CoV-2 have also been reported in Lombardy, Italy, the next major COVID-19 hot spot. Norsa *et al*[28] acknowledging that the pandemic is still ongoing, reported on their region's experience (including their IBD center) up to the time of publication. At that time they observed the highest rates reported in the world: 6471 cases of COVID-19 out of a population of 1.1 million. Of the 522 IBD patients followed at their center (11% pediatric, 22% on immunomodulators (IMM), and 16% on biologics) there had been no cases of COVID-19 reported. Based on Wuhan population modeling, the authors had anticipated 21 IBD infected patients by that time point. The authors do acknowledge that their results are not definitive, as only patients with severe symptoms and/or those receiving a nasopharyngeal swab were counted. The case reporting methodology, which was at least partially dependent upon patient self-reporting, again may have been biased towards an underestimate of true cases.

More recently, case series and observational cohort data has emerged reporting on identified IBD/COVID-19 patients. Rodriguez-Lago *et al*[29] reported on 40 cases of IBD (21 hospitalized) with confirmed positive tests for SARS-CoV-2 from 5 sites in the Basque Country (Spain), median age 59 years, 60% male, 32% Crohn's disease (CD), with 28% on immune therapy, 18% biologic, and 10% systemic corticosteroids. Two deaths (5%) were reported, including an 86 years old male, on mesalamine, with prostate adenocarcinoma, and a 77 years old male on mesalamine and methotrexate. Taxonera *et al*[30] reporting from the Madrid region of Spain, observed 12 IBD cases with laboratory confirmed COVID-19 from 1912 IBD patients followed in their database. Their patients' mean age was 52 years, with 75% female, and 58.3% CD. Seven patients (58.3%) were on immune and/or biologic therapy. There was no reporting of rates of corticosteroid use. Eight patients required hospitalization, 1 required mechanical ventilation and 2 died; a 76 years old male with UC and a 72 years old female with UC, neither of whom was receiving immune or biologic therapy. The authors additionally compared their findings in the IBD cohort to the observed rates and mortality of COVID-19 in the general population of Madrid. They found a significantly lower risk of COVID-19 for IBD [Odds ratio (OR) 0.74, 95%CI: 0.70-0.77; P < 001], with no significant difference in the case fatality rate for COVID-19 for IBD patients of 16.7% *vs* 13.2% for the general population (OR 1.31, 95%CI: 0.29-6.00, P = 0.72). An additional 15 IBD patients with COVID-19 have been reported by the combined centers of Nancy University Hospital in France and Humanitas, Milan, Italy[31] from their combined cohorts of over 6000 IBD patients, they identified 15 patients who tested positive for COVID-19 via routine tele-medicine and infusion center visits. Thirteen patients were on immune and/or biologic therapy, and there

was no mention of corticosteroid use. Five patients required hospitalization, but no deaths were reported. The authors observed an incidence of COVID-19 positive IBD patients in the cohort of 0.0025, which was similar to the current cumulative incidence of 0.0017 in France and Italy at that time.

To date, the largest national case reporting has come from a combined 24 IBD referral centers in Italy, affiliated with the Italian Group for the Study of Inflammatory Bowel Disease (IG-IBD)[32]. Patients either had laboratory testing confirming Sars-CoV-2 or a known infected contact and a combination of suspicious clinical complaints and/or lung CT findings of COVID-19. In total 79 patients were described, median age 45 years, 44.3% female, 32 CD, of whom 8% were on thiopurines, 37% anti-TNF, 20% vedolizumab, 4% ustekinumab and 11% systemic corticosteroids. Additionally, 28% of patients (12% of CD and 35% of UC) were determined to have active disease based upon chart abstraction of the Harvey-Bradshaw index for CD and partial Mayo score for UC. Overall 36 patients (46%) had COVID-19 related pneumonia, 22 (28%) were hospitalized, 2 (3%) required mechanical ventilation, and 6 (8%) died. Important observations included a significant association between active IBD and COVID-19 related pneumonia (OR 10.25, 95%CI 2.11-49.73, P = 0.003), and active IBD and COVID-19 related death (OR 8.45, 95%CI: 1.26-56.56, P = 0.02). There was no association between either corticosteroid use or anti-TNF use and COVID-19 related death. Age > 65 years was the strongest predictor of COVID-19 related death (OR 19.6, 95%CI 2.95-130.6, P = 0.002).

Also, in keeping with the observed low rates of clinically significant disease in the young, low rates have also been reported from a sample of the 102 pediatric IBD (PIBD) centers (mostly in Europe), part of the Porto group of the European Society of Pediatric Gastroenterology, Hepatology and Nutrition (ESPGHAN)[33]. A voluntary reporting system was constructed to include those with virologically confirmed SARS-CoV-2, as well as cases with strong clinical suspicion in those without access to testing. Reporting required a 7-d follow-up to ensure documentation of disease severity. The Chinese pediatric centers (84% from Wuhan) reported 917 confirmed or suspected cases of COVID-19, none in the IBD patients. The South Korean cohort reported no cases of COVID-19 out of the 272 children with IBD followed at four tertiary care centers. Reporting from a combined 32 centers in Europe, Canada, and Israel up through March 26, 2020 resulted in a total of 7 cases of PIBD and COVID-19, all with mild disease despite ongoing treatment with immunomodulators, corticosteroids and/or biologics. Notably, despite reporting no cases of IBD patients contracting COVID-19 at the Chinese centers, the crisis created by COVID-19 resulted in delays of scheduled infusions. There were 233 PIBD patients scheduled to receive infliximab during the pandemic. Of these, 66 (28%) had their infusions delayed, resulting in 14 disease exacerbations and 10 hospitalizations.

In an attempt to keep up with the pace of the pandemic and the need for updated data, the Surveillance Epidemiology of Coronavirus Under Research Exclusion (SECURE-IBD) database has been established[34]. It is an international, pediatric and adult database to monitor and report on outcomes of COVID-19 occurring in IBD patients. The database is open to reporting by IBD clinicians, both pediatric and adult, worldwide. Reporters are encouraged to include both symptomatic and asymptomatic patients. De-identified data points collected for analysis include age, gender, country of origin, IBD disease type and IBD medication use. The database is tracking rates of hospitalizations, ICU admission, need for mechanical ventilation and mortality. At the time of this manuscript's submission, the first published reports from the database have become available. Currently "in press," the authors report 525 cases from 33 countries (Median age 43 years, 53% men). The primary outcome of interest was severe COVID-19, defined as a composite of ICU admission, ventilator use, and/or death. Thirty seven patients (7%) had severe COVID-19 (as determined by physician global assessment), 161 (31%) were hospitalized, and 16 patients died (3% case fatality rate). Age-standardized mortality ratios for IBD patients were 1.8 (95%CI: 0.9-2.6), 1.5 (95%CI: 0.7-2.2), and 1.7 (95%CI: 0.9-2.5) relative to data from China, Italy, and the US, respectively. On multivariable analysis, risk factors for severe COVID-19 among IBD patients included increasing age [adjusted OR (aOR) 1.04, 95%CI: 1.01-1.02], ≥ 2 comorbidities (aOR 2.9, 95%CI: 1.1-7.8), systemic corticosteroids (aOR 6.9, 95%CI: 2.3-20.5), and sulfasalazine or 5-aminosalicylate use (aOR 3.1, 95%CI: 1.3-7.7). TNF antagonist treatment was not associated with severe COVID-19 (aOR 0.9, 95%CI: 0.4-2.2). Of note, only 3 cases of COVID-19 were reported in the age range of 0-9 years, and 26 patients in the range 1-19 years. Only 3 pediatric patients required hospitalization; none required ICU or ventilator support.

IBD AND COVID-19 EXPERT RECOMMENDATIONS

In the weeks and months since the initial outbreak, several GI professional societies and patient support organizations have developed recommendations for the management of IBD in the era of COVID-19[27,35-38]. Expert opinion has focused on several core questions: (1) Are IBD patients at greater risk for contracting COVID-19? (2) How should IBD be managed in an environment of COVID-19? And (3) How should IBD patients with known or suspected COVID-19 be treated? As acknowledged by the authors, much more data is still needed, with the current recommendations drawing heavily upon IBD experience with other infections, and with the mechanisms and the accumulated clinical experience with different IBD therapies. The current consensus is that IBD itself is not a risk factor for COVID-19, but that the risk lies mainly with the use of IBD medications, including corticosteroids, immunomodulators and biologic therapies. While there are active clinical trials using immune therapies to treat the inflammatory storm typical of severe COVID-19, none of the drugs involved are those currently approved for IBD management, and the results of these trials all are still pending. None of the society statements recommend discontinuing 5-ASA/mesalamine therapies. All of the recommendations support continuity of IBD therapy as long as the patient has not acquired SARS-CoV-2 or developed COVID-19, and all of the groups that address endoscopy/surgery suggest postponing any non-urgent procedures. Tables 1 and 2 summarize some key points related to disease management from the recommendations. For detailed clinical management scenarios, we recommend referring to the treatment algorithm provided in the AGA practice update or to the 76 expert consensus statements provided by the IOIBD.

CONCLUSION

Just a few months ago patients with IBD and their providers entered a new and uncertain world dominated daily by the specter of COVID-19. Added to the significant concerns of the general public, facing a highly communicable and sometimes fatal illness, the IBD community carries the additional concerns of a high-risk group. While IBD is characterized by an innate immune dysfunction, there fortunately is no evidence yet to suggest a higher risk for a severe clinical course of COVID-19 conferred by IBD alone. While it is too early to say whether the therapies used for IBD, currently centered around immune suppression/modification, place patients at higher risk of infection itself or severe outcomes of infection, we are hopeful that the rapid accumulation of collaborative data from around the world will begin to provide answers. While the rapidity of data collection is impressive, there remains a significant risk of bias in the cases submitted to "real time" registries that may prevent their generalization to specific populations. It is also not clear whether "risks" of a severe outcome from COVID-19 infection in this population is modified by country specific variables, such as severity of lockdowns, access to care, access to ventilators, threshold for admission to hospitals based on availability of beds, availability of COVID PCR testing, all of which vary by locality and cannot be adjusted for in the final analysis. This leaves a knowledge gap for concentrated data from a single location that minimizes the risk of bias during data collection and variability in outcomes resulting from country specific health care resources. Just as we are increasingly in a world where many of our patients can receive expert care without the risks of leaving their own home, so too does the almost real time collection and analysis of data from around the world offer the promise of rapidly providing answers to those most urgent questions raised by the worldwide IBD community.

Table 1 Summary of expert opinions and guidelines

Organization	IBD treatment, stable disease (No known or suspected COVID-19)		Known or suspected COVID-19
Chinese IBD Society	May continue anti-TNF; May continue vedolizumab; May continue ustekinumab but avoid new IV infusion initiation (to avoid infusion center); Discourage new tofacitinib use in endemic areas; Discourage new or increased dose of immunosuppressant; Postpone elective surgery or endoscopy		Contact physician for temperature over 38 C; Hold immunosuppressant and biologic agents for suspected COVID-19
		SARS-CoV-2 positive testing (without COVID-19 disease)	SARS-CoV-2 positive testing (with COVID-19 disease)
IOIBD	Continue infusions (if center has COVID-19 testing protocol); Reduce or DC prednisone (but not other therapies); Treat moderate to severe IBD (new or relapsing disease) with same therapies as pre-COVID-19; Postpone elective procedures	Uncertain if need to stop anti-TNF; Uncertain if need to stop ustekinumab; Stop tofacitinib; (IBD medications can be restarted after 14 d if the patient has not developed COVID-19)	Stop anti-TNF, ustekinumab, tofacitinib; Stop IMM if on combination therapy; Uncertain if need to stop vedolizumab; (IBD medications stopped may be restarted after COVID-19 symptoms resolve and/or after 2 nasopharyngeal PCR tests are negative
AGA	Continue current IBD therapies; Continue infusions at appropriate infusion centers; Only perform urgent or emergent procedures	Hold thiopurines, methotrexate, and tofacitinib; Delay biologic therapy for 2 wk while monitoring for COVID-19 symptoms	Hold thiopurines, methotrexate, tofacitinib, and biological therapies; (IBD medications may be restarted after complete symptom resolution or when follow up viral testing is negative or serology demonstrates convalescent stage

IBD: Inflammatory bowel disease; COVID-19: Coronavirus disease 2019; TNF: Tumor necrosis factor; SARS-CoV-2: Severe acute respiratory syndrome coronavirus 2; IOIBD: International Organization for the Study of Inflammatory Bowel Disease; DC: Discontinue; IMM: Immunomodulators; AGA: American Gastroenterological Association.

Table 2 Continued summary of expert opinions and guidelines

	General recommendations	Serious COVID-19 disease risk: Highest risk	Moderate risk	Lowest risk
BSG	Continue current medications; Avoid corticosteroids if possible Observe "shielding" while prednisone dose ≥ 20 mg daily; Initiation of IMM monotherapy not advised; Consider stopping thiopurines in older patients or those with significant comorbidity who are in sustained remission; Consider monotherapy with anti-TNF; Consider adalimumab over infliximab to promote home care; Early use of therapeutic drug monitoring; Do not recommend switching from IV to S/C	IBD and a comorbidity; Hypertension Diabetes; Age ≥ 70 yr; AND one from "Moderate Risk" column OR; Moderate to severely active disease; ≥ 20 mg prednisolone or equivalent; New biologic < 6 wk; Moderate to severely active disease NOT controlled on Moderate risk Rx; Short bowel syndrome ON nutritional support; Requirement for Parenteral nutrition	Anti-TNF monotherapy; Biologic plus immunomodulator in stable patients; Ustekinumab; Vedolizumab; Thiopurines; Methotrexate; Calcineurin inhibitors (tacrolimus or ciclosporin); Janus kinase inhibitors (tofacitinib); Immunosuppressive trial medication; Mycophenolate mofetil; Thalidomide; Prednisolone < 20 mg or equivalent per day	5-ASA users; Rectal therapies; Orally administered topically acting steroids (budesonide or beclometasone); Therapies for bile acid diarrhoea (cholestyramine, colesevelam, colestipol); Antidiarrhoeals (*e.g.*, loperamide); Antibiotics for bacterial overgrowth or perianal disease
CCF	Stay on your medications; Do not skip infusion appointments; Consider rescheduling non urgent endoscopic procedures			

COVID-19: Coronavirus disease 2019; BSG: British society of gastroenterology; IBD: Inflammatory bowel disease;
TNF: Tumor Necrosis Factor; IMM: Immunomodulators; ASA: Aminosalicylic acids;
CCF: Crohn's and colitis foundation.

REFERENCES

1 **Centers for Disease Control and Prevention**. Coronavirus disease 2019 (COVID-19). Available from: https://www.cdc.gov/coronavirus/2019-ncov/downloads/2019-ncov-factsheet.pdf

2 **Wang D**, Hu B, Hu C, Zhu F, Liu X, Zhang J, Wang B, Xiang H, Cheng Z, Xiong Y, Zhao Y, Li Y, Wang X, Peng Z. Clinical Characteristics of 138 Hospitalized Patients With 2019 Novel Coronavirus-Infected Pneumonia in Wuhan, China. *JAMA* 2020 [PMID: 32031570 DOI: 10.1001/jama.2020.1585]

3 **Guan WJ**, Ni ZY, Hu Y, Liang WH, Ou CQ, He JX, Liu L, Shan H, Lei CL, Hui DSC, Du B, Li LJ, Zeng G, Yuen KY, Chen RC, Tang CL, Wang T, Chen PY, Xiang J, Li SY, Wang JL, Liang ZJ, Peng YX, Wei L, Liu Y, Hu YH, Peng P, Wang JM, Liu JY, Chen Z, Li G, Zheng ZJ, Qiu SQ, Luo J, Ye CJ, Zhu SY, Zhong NS; China Medical Treatment Expert Group for Covid-19. Clinical Characteristics of Coronavirus Disease 2019 in China. *N Engl J Med* 2020; **382**: 1708-1720 [PMID: 32109013 DOI: 10.1056/NEJMoa2002032]

4 **Huang C**, Wang Y, Li X, Ren L, Zhao J, Hu Y, Zhang L, Fan G, Xu J, Gu X, Cheng Z, Yu T, Xia J, Wei Y, Wu W, Xie X, Yin W, Li H, Liu M, Xiao Y, Gao H, Guo L, Xie J, Wang G, Jiang R, Gao Z, Jin Q, Wang J, Cao B. Clinical features of patients infected with 2019 novel coronavirus in Wuhan, China. *Lancet* 2020; **395**: 497-506 [PMID: 31986264 DOI: 10.1016/S0140-6736(20)30183-5]

5 **Morens DM**, Daszak P, Taubenberger JK. Escaping Pandora's Box - Another Novel Coronavirus. *N Engl J Med* 2020; **382**: 1293-1295 [PMID: 32101660 DOI: 10.1056/NEJMp2002106]

6 **Wu Z**, McGoogan JM. Characteristics of and Important Lessons From the Coronavirus Disease 2019 (COVID-19) Outbreak in China: Summary of a Report of 72 314 Cases From the Chinese Center for Disease Control and Prevention. *JAMA* 2020 [PMID: 32091533 DOI: 10.1001/jama.2020.2648]

7 **Grasselli G**, Zangrillo A, Zanella A, Antonelli M, Cabrini L, Castelli A, Cereda D, Coluccello A, Foti G, Fumagalli R, Iotti G, Latronico N, Lorini L, Merler S, Natalini G, Piatti A, Ranieri MV, Scandroglio AM, Storti E, Cecconi M, Pesenti A; COVID-19 Lombardy ICU Network, Nailescu A, Corona A, Zangrillo A, Protti A, Albertin A, Forastieri Molinari A, Lombardo A, Pezzi A, Benini A, Scandroglio AM, Malara A, Castelli A, Coluccello A, Micucci A, Pesenti A, Sala A, Alborghetti A, Antonini B, Capra C, Troiano C, Roscitano C, Radrizzani D, Chiumello D, Coppini D, Guzzon D, Costantini E, Malpetti E, Zoia E, Catena E, Agosteo E, Barbara E, Beretta E, Boselli E, Storti E, Harizay F, Della Mura F, Lorini FL, Donato Sigurtà F, Marino F, Mojoli F, Rasulo F, Grasselli G, Casella G, De Filippi G, Castelli G, Aldegheri G, Gallioli G, Lotti G, Albano G, Landoni G, Marino G, Vitale G, Battista Perego G, Evasi G, Citerio G, Foti G, Natalini G, Merli G, Sforzini I, Bianciardi L, Carnevale L, Grazioli L, Cabrini L, Guatteri L, Salvi L, Dei Poli M, Galletti M, Gemma M, Ranucci M, Riccio M, Borelli M, Zambon M, Subert M, Cecconi M, Mazzoni MG, Raimondi M, Panigada M, Belliato M, Bronzini N, Latronico N, Petrucci N, Belgiorno N, Tagliabue P, Cortellazzi P, Gnesin P, Grosso P, Gritti P, Perazzo P, Severgnini P, Ruggeri P, Sebastiano P, Covello RD, Fernandez-Olmos R, Fumagalli R, Keim R, Rona R, Valsecchi R, Cattaneo S, Colombo S, Cirri S, Bonazzi S, Greco S, Muttini S, Langer T, Alaimo V, Viola U. Baseline Characteristics and Outcomes of 1591 Patients Infected With SARS-CoV-2 Admitted to ICUs of the Lombardy Region, Italy. *JAMA* 2020 [PMID: 32250385 DOI: 10.1001/jama.2020.5394]

8 **Feuerstein JD**, Isaacs KL, Schneider Y, Siddique SM, Falck-Ytter Y, Singh S; AGA Institute Clinical Guidelines Committee. AGA Clinical Practice Guidelines on the Management of Moderate to Severe Ulcerative Colitis. *Gastroenterology* 2020; **158**: 1450-1461 [PMID: 31945371 DOI: 10.1053/j.gastro.2020.01.006]

9 **Torres J**, Bonovas S, Doherty G, Kucharzik T, Gisbert JP, Raine T, Adamina M, Armuzzi A, Bachmann O, Bager P, Biancone L, Bokemeyer B, Bossuyt P, Burisch J, Collins P, El-Hussuna A, Ellul P, Frei-Lanter C, Furfaro F, Gingert C, Gionchetti P, Gomollon F, González-Lorenzo M, Gordon H, Hlavaty T, Juillerat P, Katsanos K, Kopylov U, Krustins E, Lytras T, Maaser C, Magro F, Marshall JK, Myrelid P, Pellino G, Rosa I, Sabino J, Savarino E, Spinelli A, Stassen L, Uzzan M, Vavricka S, Verstockt B, Warusavitarne J, Zmora O, Fiorino G. ECCO Guidelines on Therapeutics in Crohn's Disease: Medical Treatment. *J Crohns Colitis* 2020; **14**: 4-22 [PMID: 31711158 DOI: 10.1093/ecco-jcc/jjz180]

10 **Ooi CJ**, Makharia GK, Hilmi I, Gibson PR, Fock KM, Ahuja V, Ling KL, Lim WC, Thia KT, Wei SC, Leung WK, Koh PK, Gearry RB, Goh KL, Ouyang Q, Sollano J, Manatsathit S, de Silva HJ, Rerknimitr R, Pisespongsa P, Abu Hassan MR, Sung J, Hibi T, Boey CC, Moran N, Leong RW; Asia Pacific Association of Gastroenterology (APAGE) Working Group on Inflammatory Bowel Disease. Asia-Pacific consensus statements on Crohn's disease. Part 2: Management. *J Gastroenterol Hepatol* 2016; **31**: 56-68 [PMID: 25819311 DOI: 10.1111/jgh.12958]

11 **Rahier JF**, Magro F, Abreu C, Armuzzi A, Ben-Horin S, Chowers Y, Cottone M, de Ridder L, Doherty G, Ehehalt R, Esteve M, Katsanos K, Lees CW, Macmahon E, Moreels T, Reinisch W, Tilg H, Tremblay L, Veereman-Wauters G, Viget N, Yazdanpanah Y, Eliakim R, Colombel JF; European Crohn's and Colitis Organisation (ECCO). Second European evidence-based consensus on the prevention, diagnosis and management of opportunistic infections in inflammatory bowel disease. *J Crohns Colitis* 2014; **8**: 443-468 [PMID: 24613021 DOI: 10.1016/j.crohns.2013.12.013]

12 **Shah ED**, Farida JP, Siegel CA, Chong K, Melmed GY. Risk for Overall Infection with Anti-TNF and Anti-integrin Agents Used in IBD: A Systematic Review and Meta-analysis. *Inflamm Bowel Dis* 2017; **23**: 570-577 [PMID: 28230558 DOI: 10.1097/MIB.0000000000001049]

13 **Bonovas S**, Fiorino G, Allocca M, Lytras T, Nikolopoulos GK, Peyrin-Biroulet L, Danese S. Biologic Therapies and Risk of Infection and Malignancy in Patients With Inflammatory Bowel Disease: A Systematic Review and Network Meta-analysis. *Clin Gastroenterol Hepatol* 2016; **14**: 1385-1397.e10 [PMID: 27189910 DOI: 10.1016/j.cgh.2016.04.039]

14 **Luthra P**, Peyrin-Biroulet L, Ford AC. Systematic review and meta-analysis: opportunistic infections and malignancies during treatment with anti-integrin antibodies in inflammatory bowel disease. *Aliment Pharmacol Ther* 2015; **41**: 1227-1236 [PMID: 25903741 DOI: 10.1111/apt.13215]

15 **Ford AC**, Peyrin-Biroulet L. Opportunistic infections with anti-tumor necrosis factor-α therapy in inflammatory bowel disease: meta-analysis of randomized controlled trials. *Am J Gastroenterol* 2013; **108**: 1268-1276 [PMID: 23649185 DOI: 10.1038/ajg.2013.138]

16 **Olivera PA**, Lasa JS, Bonovas S, Danese S, Peyrin-Biroulet L. Safety of Janus Kinase Inhibitors in Patients With Inflammatory Bowel Diseases or Other Immune-mediated Diseases: A Systematic Review and Meta-Analysis. *Gastroenterology* 2020; **158**: 1554-1573.e12 [PMID: 31926171 DOI: 10.1053/j.gastro.2020.01.001]

17 **Wan Y**, Shang J, Graham R, Baric RS, Li F. Receptor Recognition by the Novel Coronavirus from Wuhan: an Analysis Based on Decade-Long Structural Studies of SARS Coronavirus. *J Virol* 2020; **94** [PMID: 31996437 DOI: 10.1128/JVI.00127-20]

18 **Liang W**, Feng Z, Rao S, Xiao C, Xue X, Lin Z, Zhang Q, Qi W. Diarrhoea may be underestimated: a missing link in 2019 novel coronavirus. *Gut* 2020; **69**: 1141-1143 [PMID: 32102928 DOI: 10.1136/gutjnl-2020-320832]

19 **Xiao F**, Tang M, Zheng X, Liu Y, Li X, Shan H. Evidence for Gastrointestinal Infection of SARS-CoV-2. *Gastroenterology* 2020; **158**: 1831-1833.e3 [PMID: 32142773 DOI: 10.1053/j.gastro.2020.02.055]

20 **Gu J**, Han B, Wang J. COVID-19: Gastrointestinal Manifestations and Potential Fecal-Oral Transmission. *Gastroenterology* 2020; **158**: 1518-1519 [PMID: 32142785 DOI: 10.1053/j.gastro.2020.02.054]

21 **Wu Y**, Guo C, Tang L, Hong Z, Zhou J, Dong X, Yin H, Xiao Q, Tang Y, Qu X, Kuang L, Fang X, Mishra N, Lu J, Shan H, Jiang G, Huang X. Prolonged presence of SARS-CoV-2 viral RNA in faecal samples. *Lancet Gastroenterol Hepatol* 2020; **5**: 434-435 [PMID: 32199469 DOI: 10.1016/S2468-1253(20)30083-2]

22 **Monteleone G**, Ardizzone S. Are patients with inflammatory bowel disease at increased risk for Covid-19 infection? *J Crohns Colitis* 2020 [PMID: 32215548 DOI: 10.1093/ecco-jcc/jjaa061]

23 **Garg M**, Royce SG, Tikellis C, Shallue C, Batu D, Velkoska E, Burrell LM, Patel SK, Beswick L, Jackson A, Britto K, Lukies M, Sluka P, Wardan H, Hirokawa Y, Tan CW, Faux M, Burgess AW, Hosking P, Monagle S, Thomas M, Gibson PR, Lubel J. Imbalance of the renin-angiotensin system may contribute to inflammation and fibrosis in IBD: a novel therapeutic target? *Gut* 2020; **69**: 841-851 [PMID: 31409604 DOI: 10.1136/gutjnl-2019-318512]

24 **Garg M**, Burrell LM, Velkoska E, Griggs K, Angus PW, Gibson PR, Lubel JS. Upregulation of circulating components of the alternative renin-angiotensin system in inflammatory bowel disease: A pilot study. *J Renin Angiotensin Aldosterone Syst* 2015; **16**: 559-569 [PMID: 24505094 DOI: 10.1177/1470320314521086]

25 **Cheung KS**, Hung IFN, Chan PPY, Lung KC, Tso E, Liu R, Ng YY, Chu MY, Chung TWH, Tam AR, Yip CCY, Leung KH, Fung AY, Zhang RR, Lin Y, Cheng HM, Zhang AJX, To KKW, Chan KH, Yuen KY, Leung WK. Gastrointestinal Manifestations of SARS-CoV-2 Infection and Virus Load in Fecal Samples From a Hong Kong Cohort: Systematic Review and Meta-analysis. *Gastroenterology* 2020; **159**: 81-95 [PMID: 32251668 DOI: 10.1053/j.gastro.2020.03.065]

26 **Goyal P**, Choi JJ, Pinheiro LC, Schenck EJ, Chen R, Jabri A, Satlin MJ, Campion TR Jr, Nahid M, Ringel JB, Hoffman KL, Alshak MN, Li HA, Wehmeyer GT, Rajan M, Reshetnyak E, Hupert N, Horn EM, Martinez FJ, Gulick RM, Safford MM. Clinical Characteristics of Covid-19 in New York City. *N Engl J Med* 2020; **382**: 2372-2374 [PMID: 32302078 DOI: 10.1056/NEJMc2010419]

27 **Mao R**, Liang J, Shen J, Ghosh S, Zhu LR, Yang H, Wu KC, Chen MH; Chinese Society of IBD, Chinese Elite IBD Union; Chinese IBD Quality Care Evaluation Center Committee. Implications of COVID-19 for patients with pre-existing digestive diseases. *Lancet Gastroenterol Hepatol* 2020; **5**: 425-427 [PMID: 32171057 DOI: 10.1016/S2468-1253(20)30076-5]

28 **Norsa L**, Indriolo A, Sansotta N, Cosimo P, Greco S, D'Antiga L. Uneventful Course in Patients With Inflammatory Bowel Disease During the Severe Acute Respiratory Syndrome Coronavirus 2 Outbreak in Northern Italy. *Gastroenterology* 2020; **159**: 371-372 [PMID: 32247695 DOI: 10.1053/j.gastro.2020.03.062]

29 **Rodríguez-Lago I**, Ramírez de la Piscina P, Elorza A, Merino O, Ortiz de Zárate J, Cabriada JL. Characteristics and Prognosis of Patients With Inflammatory Bowel Disease During the SARS-CoV-2 Pandemic in the Basque Country (Spain). *Gastroenterology* 2020; **159**: 781-783 [PMID: 32330477 DOI: 10.1053/j.gastro.2020.04.043]

30 **Taxonera C**, Sagastagoitia I, Alba C, Mañas N, Olivares D, Rey E. 2019 novel coronavirus disease (COVID-19) in patients with inflammatory bowel diseases. *Aliment Pharmacol Ther* 2020; **52**: 276-283 [PMID: 32359205 DOI: 10.1111/apt.15804]

31 **Allocca M**, Fiorino G, Zallot C, Furfaro F, Gilardi D, Radice S, Danese S, Peyrin-Biroulet L. Incidence and Patterns of COVID-19 Among Inflammatory Bowel Disease Patients From the Nancy and Milan Cohorts. *Clin Gastroenterol Hepatol* 2020; **18**: 2134-2135 [PMID: 32360811 DOI: 10.1016/j.cgh.2020.04.071]

32 **Bezzio C**, Saibeni S, Variola A, Allocca M, Massari A, Gerardi V, Casini V, Ricci C, Zingone F, Amato A, Caprioli F, Lenti MV, Viganò C, Ascolani M, Bossa F, Castiglione F, Cortelezzi C, Grossi L, Milla M, Morganti D, Pastorelli L, Ribaldone DG, Sartini A, Soriano A, Manes G, Danese S, Fantini MC, Armuzzi A, Daperno M, Fiorino G; Italian Group for the Study of Inflammatory Bowel Disease (IG-IBD). Outcomes of COVID-19 in 79 patients with IBD in Italy: an IG-IBD study. *Gut* 2020; **69**: 1213-1217 [PMID: 32354990 DOI: 10.1136/gutjnl-2020-321411]

33 **Turner D**, Huang Y, Martín-de-Carpi J, Aloi M, Focht G, Kang B, Zhou Y, Sanchez C, Kappelman MD. Uhlig HH, Pujol-Muncunill G, Ledder O, Lionetti P, Dias JA, Ruemmele FM, Russell RK; Paediatric IBD Porto group of ESPGHAN. COVID-19 and Paediatric Inflammatory Bowel Diseases: Global Experience and Provisional Guidance (March 2020) from the Paediatric IBD Porto group of ESPGHAN. *J Pediatr Gastroenterol Nutr* 2020; **70**: 727-733 [PMID: 32235161 DOI: 10.1097/MPG.0000000000002729]

34 Coronavirus and IBD Reporting Database. Available from: https://covidibd.org/

35 **Kennedy NA**, Jones GR, Lamb CA, Appleby R, Arnott I, Beattie RM, Bloom S, Brooks AJ, Cooney R, Dart RJ, Edwards C, Fraser A, Gaya DR, Ghosh S, Greveson K, Hansen R, Hart A, Hawthorne AB, Hayee B, Limdi JK, Murray CD, Parkes GC, Parkes M, Patel K, Pollok RC, Powell N, Probert CS, Raine T, Sebastian S, Selinger C, Smith PJ, Stansfield C, Younge L, Lindsay JO, Irving PM, Lees CW. British Society of Gastroenterology guidance for management of inflammatory bowel disease during the COVID-19 pandemic. *Gut* 2020; **69**: 984-990 [PMID: 32303607 DOI: 10.1136/gutjnl-2020-321244]

36 **Rubin DT**, Feuerstein JD, Wang AY, Cohen RD. AGA Clinical Practice Update on Management of Inflammatory Bowel Disease During the COVID-19 Pandemic: Expert Commentary. *Gastroenterology* 2020; **159**: 350-357 [PMID: 32283100 DOI: 10.1053/j.gastro.2020.04.012]

37 **Rubin DT**, Abreu MT, Rai V, Siegel CA; International Organization for the Study of Inflammatory Bowel Disease. Management of Patients With Crohn's Disease and Ulcerative Colitis During the Coronavirus Disease-2019 Pandemic: Results of an International Meeting. *Gastroenterology* 2020; **159**: 6-13.e6 [PMID:

32272113 DOI: 10.1053/j.gastro.2020.04.002]
38 COVID-19 (Coronavirus): What IBD Patients Should Know. Available from: https://www.crohnscolitisfoundation.org/coronavirus/what-ibd-patients-should-know

World Journal of Gastroenterology

Submit a Manuscript: https://www.f6publishing.com

World J Gastroenterol 2020 October 7; 26(37): 5543-5560

DOI: 10.3748/wjg.v26.i37.5543

ISSN 1007-9327 (print) ISSN 2219-2840 (online)

REVIEW

Hepatitis E virus: Epidemiology, diagnosis, clinical manifestations, and treatment

Abdullah Tarık Aslan, Hatice Yasemin Balaban

ORCID number: Abdullah Tarık Aslan 0000-0001-9804-0972; Hatice Yasemin Balaban 0000-0002-0901-9192.

Author contributions: Aslan AT wrote the paper and collected data; Balaban HY carried out data collection; Both authors read and approved the final manuscript.

Conflict-of-interest statement: All authors have no conflicts of interest to be stated.

Manuscript source: Invited manuscript

Received: June 28, 2020
Peer-review started: June 28, 2020
First decision: July 28, 2020
Revised: August 11, 2020

Abdullah Tarık Aslan, Department of Internal Medicine, Gölhisar State Hospital, Burdur 15100, Turkey

Hatice Yasemin Balaban, Department of Gastroenterology, Hacettepe University Faculty of Medicine, Ankara 06100, Turkey

Corresponding author: Hatice Yasemin Balaban, MD, Professor, Department of Gastroenterology, Hacettepe University Faculty of Medicine, Hacettepe University Sihhiye Campus, Ankara 06100, Turkey. yhbalaban@gmail.com

Abstract

The hepatitis E virus (HEV) is the fifth known form of viral hepatitis and was first recognized as the cause of an epidemic of unexplained acute hepatitis in the early 1980s. Globally, it is one of the most frequent causes of acute viral hepatitis. The majority of HEV infections are asymptomatic and lead to the spontaneous clearance of the virus. Among the eight different genotypes identified to date, HEV genotype 1 (HEV1), HEV2, HEV3, and HEV4 are the most frequent genotypes causing infections in humans. HEV1 and HEV2 are prevalent in developing regions and able to result in large-scale outbreaks originating from contaminated water supplies. They are also responsible for severe hepatitis in pregnant patients and infants. In contrast, HEV3 and HEV4 are zoonotic, and the transmission of these genotypes to humans occurs mainly through the fecal contamination of water and consumption of contaminated meat from infected animals. Their main reservoir is the pig, and they are mostly encountered in developed countries. The major risk groups for HEV infection and its ensuing adverse consequences are pregnant women, infants, older people, immunocompromised individuals, patients with underlying chronic liver diseases, and workers that come into close contact with HEV-infected animals. In the clinical perspective, HEV infections have diverse clinical manifestations including acute and self-limiting hepatitis, acute-on-chronic liver disease, chronic hepatitis, cirrhosis, and liver failure. Although HEV mainly results in acute self-limiting infection, chronic HEV infection may occur among immunocompromised patients (*e.g.*, solid-organ transplant recipients). Additionally, HEV-associated extrahepatic manifestations involving various organs have been reported in the last decade, although the causal link for many of them still needs to be proven. Ribavirin and interferon-alpha are the most widely used agents for the treatment of HEV infections with a certain level of success. However, ribavirin is contraindicated in pregnant patients, and interferon-alpha cannot be used in most

Accepted: September 10, 2020
Article in press: September 10, 2020
Published online: October 7, 2020

P-Reviewer: Parvez MK, Pineau P, Shim J
S-Editor: Huang P
L-Editor: Filipodia
P-Editor: Li JH

transplant recipients. Therefore, there is an urgent need for novel antiviral compounds that are safe and effective particularly for patients having contraindications for ribavirin or interferon-alpha and infected by the ribavirin-resistant HEV. In this review article, a literature search using PubMed and MEDLINE databases was performed, up to March 2020. Only the articles published in English were reviewed.

Key Words: Hepatitis E; Hepatitis E virus; Extrahepatic manifestations; Zoonotic infection; Chronic hepatitis; Acute hepatitis

Core Tip: The hepatitis E virus (HEV) is the most common cause of acute viral hepatitis worldwide. To date, four main genotypes of the HEV infecting humans have been described. While HEV1 and HEV2 cause only acute hepatitis, HEV3 or HEV4 can become chronic in immunocompromised patients. Extrahepatic manifestations have also been defined for these genotypes. Acute infections are generally self-limiting and do not require special treatment. For chronic hepatitis, ribavirin is the drug of choice. Nevertheless, novel drugs are required for patients in whom ribavirin treatment fails. We herein reviewed the epidemiology, diagnosis, clinical manifestations, and treatment of HEV infections.

Citation: Aslan AT, Balaban HY. Hepatitis E virus: Epidemiology, diagnosis, clinical manifestations, and treatment. *World J Gastroenterol* 2020; 26(37): 5543-5560
URL: https://www.wjgnet.com/1007-9327/full/v26/i37/5543.htm
DOI: https://dx.doi.org/10.3748/wjg.v26.i37.5543

INTRODUCTION

The hepatitis E virus (HEV) is the most common cause of acute viral hepatitis worldwide and belongs to the *Hepeviridae* family[1-3]. Despite being an important cause of hepatitis and increasing knowledge on the HEV, the origin of the HEV remains obscure[4]. In 1983, the Russian virologists Balayan *et al*[5] visualized the virus by electron microscopy while examining one of their own feces after ingestion of a pooled fecal extract of infected soldiers.

The HEV is a small non-enveloped virus, 27-34 nm in diameter, with a single-stranded positive sense ribonucleic acid (RNA) genome[6,7]. The HEV genome harbors discontinuous regions called open reading frames (ORF). Among these regions, ORF1 encodes nonstructural (functional) proteins (*e.g.*, RNA-dependent RNA polymerase, methyltransferase)[8,9], ORF2 encodes the viral capsid protein[10], and ORF3 encodes a functional ion channel that has important roles in the release of viral particles[11]. The recently discovered ORF4 is unique for HEV genotype 1 (HEV1) and plays a critical role in the proper functioning of HEV RNA polymerase[12]. The capsid protein encoded by ORF2 is highly immunogenic, and antibodies against this protein have neutralizing and protective features[13,14]. Therefore, the capsid protein seems to be a suitable target for vaccine development against HEV. HEV molecular biology is outside the scope of this review. Therefore, we direct the readers to other review articles on this topic[15,16].

Our viewpoint of the HEV has undergone a dramatic change over the past decade. Previously, HEV was considered to be limited to some developing countries. Currently, it is known to be endemic as a zoonotic infectious agent in most high-income countries. Locally acquired (autochthonous) HEV infections caused by HEV3 and HEV4 have become the most common cause of acute viral hepatitis in several developed countries. The best example of this is China where previously HEV1 was the most frequent genotype. However, HEV4 has surpassed HEV1 in recent years, most probably due to improved sanitation and hygiene measures[17].

In this review, we aimed to present contemporary data about the epidemiology, diagnosis, clinical manifestations, and management of HEV infections.

EPIDEMIOLOGY

Among the eight distinct HEV genotypes that have been identified in the *Orthohepevirus* A species, HEV1, HEV2, HEV3, and HEV4 are able to infect humans. Humans are the main reservoir of HEV1 and HEV2, and any transmission from animals to humans for HEV1 and HEV2 has not yet been reported. The epidemics of HEV1 and HEV2 develop periodically in several regions of Asia, Africa, Mexico, and the Middle East[18]. In these regions, large waterborne outbreaks can be caused by the inadvertent fecal contamination of water supplies particularly after heavy rainfall and flooding[19,20]. In 1955-1956, the first identified HEV outbreak had infected 29300 individuals in India[19]. In addition to the epidemic infection, sporadic HEV infections have occurred in endemic areas[21].

Although HEV1 and HEV2 usually lead to self-limiting acute viral hepatitis, HEV1- and HEV2-related infections still have a substantial burden on public health in low-income countries. According to the mathematical model developed in 2005, these genotypes were associated with 20.1 million annual new infections in Asia and Africa with 3.4 million symptomatic hepatitis E cases, 70000 fatalities attributed to acute liver failure, and 3000 stillbirths[22]. However, these estimates have several restrictions and require updating. The person-to-person transmission of HEV1 and HEV2 is infrequent in both sporadic and epidemic settings[23], whereas vertical transmission from mother to fetus during pregnancy is well defined[24]. Moreover, HEV1 transmission through blood transfusion was also reported[25]. For unknown mechanisms, the mortality rate of acute HEV1 or HEV2 infection is considerably high in pregnant women and infants.

HEV3 and HEV4 infections mainly develop through zoonotic transmission that is caused by close contact with infected animals or the consumption of contaminated food products (most commonly raw or undercooked meat). The main reservoir for these genotypes is the pig, and they have also been demonstrated in wild boars, rabbits, goats, sheep, deer, horses, cats, and dogs[26-29]. Therefore, these animals can be considered as potential zoonotic sources for transmission to humans. They can also be detected in large quantities in the feces of asymptomatic animals and in the milk of infected cows[30]. Some experiments revealed that the HEV can be inactivated if heated up to 71 °C for at least 20 min[31]. In addition, fruits and vegetables washed with contaminated waters can be putative routes of HEV transmission[32,33]. Considering the transmission routes of HEV3 and HEV4, we can conclude that farmers, veterinarians, and individuals working in the slaughterhouse are more prone to HEV infections than the general population.

Albeit less common than zoonotic and waterborne transmissions, infected blood or blood products from a viremic patient should be considered as a possible transmission route for HEV infections[34]. However, most of iatrogenic transmissions remain asymptomatic in immunocompetent individuals. A study from the United Kingdom involving 225000 blood donations demonstrated that 0.035% of recipients were viremic, and almost 42% of recipients being transfused with HEV RNA-positive blood products became viremic or developed antibodies against HEV[35]. Currently, blood products are routinely tested for HEV RNA in the United Kingdom, Ireland, and the Netherlands[36]. Selective screening is performed in Germany and France for high-risk patients, and authorities in Greece, Portugal, Italy, and Spain are assessing whether to initiate HEV screening in blood products[36]. A study from the United Kingdom showed the cost-effectiveness of routine screening of the HEV in solid-organ transplant recipients by the nucleic acid amplification tests (NAATs) or antigen test[37]. The screening of plasma-derived blood products in the United States may not be necessary since only 0.002% of plasma donations in the United States were found HEV RNA positive[38]. In addition to blood products, HEV acquisition can occur from a transplanted organ. Schlosser *et al*[39] reported a case of a liver transplant recipient who experienced chronic HEV infection and cirrhosis after receiving an organ from a donor with negative HEV serology.

In developed countries, HEV3 is the most frequent causative genotype in HEV infections[21]. However, HEV4 has become as equally important as HEV3 in China, Japan, Taiwan, Hong Kong, and South Korea over the last decades[40]. In Europe, the prevalence of HEV infections varies according to regions. In particular, HEV3 is hyperendemic in southwest France with a very high rate of seroprevalence (> 50%)[41]. It is also endemic in northern France, Belgium, the Netherlands, and Germany. The rates of previous HEV exposure can reach up to 30% in these countries[21]. In a survey conducted in 30 European countries, the number of cases with HEV infection has increased from 514 per year in 2005 to 5617 in 2015[42]. In addition, HEV infection was reported as the most frequent type of acute viral hepatitis between 2013 and 2015 in the Netherlands[43]. These infections are generally locally acquired (autochthonous),

and both symptomatic infections and seroprevalence rates increase significantly with age. In the United States, a recent study reported an HEV seroprevalence rate of 6%[44]. The lower rate of seropositivity in the United States compared with that in other developed countries, especially in Europe, can be partly explained by less frequent organ meat consumption, insufficient awareness of HEV among United States health-care providers, and lack of a Food and Drug Administration-licensed assay to diagnose HEV infection[45]. Turkey has been reported as an HEV1 and HEV2 endemic country based upon outdated data. However, for the first time in the literature, we have identified HEV3 viremia in two Turkish patients involved in a cross-sectional study including the high-risk groups for HEV infection, and there was no HEV1 or HEV2 viremic patient (unpublished data).

Thus far, HEV5 and HEV6 have only been reported in wild boars and are not associated with infections in human beings[46]. HEV7 and HEV8 have been detected in camels[47]. In 2016, HEV7 was detected for the first time in a patient regularly consuming camel milk and meat from the United Arab Emirates[48]. Phylogenetic analysis proved that the viruses identified in the samples obtained from the patient and samples from camel meat and milk belong to HEV7. However, no further cases in humans have been identified since then. In addition to these well-defined HEV genotypes infecting humans, some recent studies found that a new HEV genotype called HEVC1 that is normally infecting rats leads to acute and/or chronic hepatitis as well as extrahepatic manifestations in humans[49].

The estimation of HEV seroprevalence by examining the frequencies of anti-HEV antibodies (immunoglobulin (Ig)G and IgM) in a population would be extremely difficult considering the use of different assays with varied sensitivities in the detection of anti-HEV antibodies. For instance, the seroprevalence rate of anti-HEV antibodies in Asia and Africa was 10%-40% with increasing frequency in older age groups (> 50 years of age)[50]. This low rate of anti-HEV antibody positivity in these endemic regions could be explained by the disappearance of anti-HEV antibodies with time, failure of the surveillance systems to detect symptomatic HEV cases, or low sensitivity of previously used serological assays[45]. Nevertheless, new-generation serological assays are more sensitive and have similar specificity than older widely used serological assays[51,52].

DIAGNOSIS

The incubation period of HEV infection is usually 2-6 wk[51]. At the time of diagnosis, HEV RNA and anti-HEV IgM can be detected, followed by anti-HEV IgG antibodies. Anti-HEV IgM antibody positivity in the serum can be considered an important marker for acute HEV infection. Anti-HEV IgM antibodies have a positivity for a short period of time (approximately 3-4 mo), but sometimes it persists for a year[53]. Anti-HEV IgG antibody is relatively long-lasting, and the exact duration of this response remains uncertain[45]. Furthermore, anti-HEV IgG antibody has an increasing avidity over time[54]. HEV RNA can be detected in the blood after 3 wk of exposure, and viral shedding lasts approximately 4-6 wk in the stool[54].

Enzyme immunoassay is the most widely used serological method for the identification of anti-HEV IgG and IgM antibodies in the diagnosis of HEV infection. The detection of anti-HEV IgM and rising titers of anti-HEV IgG antibodies alone are not sufficient for diagnosis since some commercial assays have insufficient specificities for these antibodies. In addition, anti-HEV IgM may disappear or not yet become positive until a sample is taken for the diagnosis of HEV infection. Moreover, anti-HEV IgG antibodies do not provide lifelong immunity, and the level of antibodies in the serum decreases over time. It has been suggested that having anti-HEV IgG titers < 7 units/mL is insufficient to prevent subsequent acute or chronic infections[55]. Conversely, a vaccine study suggested that anti-HEV IgG titers > 2.5 units/mL are protective[23].

Enzyme immunoassays are used not only for the detection of anti-HEV antibodies but also for that of the HEV capsid antigen. Although previously used antigen assays are not as sensitive as the NAATs, a newer version of assays has improved sensitivity[56,57]. Strikingly, HEV antigen may persist for several months after ribavirin-induced HEV RNA clearance of chronic HEV infection. This finding suggests that the presence of HEV antigen does not indicate the presence of infectious virions[58]. Therefore, the role of HEV antigen in diagnosis remains to be determined.

The detection of HEV RNA in the blood or stool is a diagnostic means for HEV infection. Particularly, the results of serological assays are often negative in acute and

chronic HEV infections of patients with immunosuppressed conditions (*e.g.*, solid-organ transplant recipients). Chronic HEV infection is defined as the persistence of HEV RNA in the blood or stool for at least 3 mo[59]. Different types of the NAATs have various sensitivities in the detection of HEV RNA. Therefore, the World Health Organization developed the international standard and international reference panel for HEV1, HEV2, HEV3, and HEV4[60]. This enabled us not only to compare the results obtained by different NAATs but also to report the results using a common unit, that is, the international unit (IU). Several different types of the NAATs are being used for the detection of HEV RNA in blood or stool samples. These tests can be exemplified as follows: Conventional reverse transcription polymerase chain reaction (RT-PCR), real-time RT-PCR, and reverse transcription loop-mediated isothermal amplification. The NAATs are able to detect the HEV RNA target, specifically conserved domains of the HEV genome (the region of ORF2 that overlaps ORF3), of all four major genotypes of HEV (genotypes 1-4) that infect humans[61]. However, polymorphisms in the targeted regions or problems in the designation of highly specific primers and probes' sequences may result in false-negative test results. The diagnostic algorithm of both acute and chronic HEV infections is shown in Figure 1.

CLINICAL MANIFESTATIONS OF HEV INFECTIONS

Acute HEV infections

In general, acute HEV infection is relatively asymptomatic or mildly symptomatic. However, acute icteric hepatitis is seen in almost 5%-30% of patients infected by the HEV[62]. Malaise, fever, body aches, nausea, and vomiting are characteristic symptoms observed through the 1-wk prodromal phase of acute icteric hepatitis, which is followed by the icteric phase lasting approximately 1 wk. It is marked by dark-colored urine and jaundice[62]. Then, the convalescent phase results in the resolution of icteric symptoms. Generally, HEV1 and HEV2 cause more severe acute hepatitis presentation than HEV3 and HEV4[63]. Nonetheless, HEV3 and HEV4 may lead to severe acute HEV infections in older men and acute-on-chronic liver failure (ACLF) in patients with chronic liver diseases.

Although the vast majority of acute HEV infections do not need any special treatment in immunocompetent patients, it is consistently shown that HEV1 infection in a pregnant woman (particularly at the third trimester) is associated with high maternal morbidity and mortality. Acute HEV1 infection-related mortality reaches up to 20% and is caused by eclampsia, hemorrhagic complications, and liver failure[64]. The newborns have a risk of maternal–fetal transmission and consequent clinical manifestations such as hypoglycemia, hepatitis, and neonatal death[65]. As mentioned above, HEV genotype seems to be closely associated with the worse clinical outcome in pregnant women, since HEV3 does not generally cause death or fulminant hepatitis for pregnant women and the data are not available for the course of HEV4 infection during pregnancy[66,67]. As a possible mechanism of this fact, Gouilly *et al*[68] found that HEV1 proliferates more efficiently than HEV3 *ex vivo* in stromal cells and in tissue explants of decidua basalis and fetal placenta. They also demonstrated significant changes in the structure of the placental barrier with increased cellular death and necrosis at the maternal-fetal interface in HEV1-infected pregnant women. HEV1 also leads to the production of more infectious virions and pro-inflammatory cytokines like chemokines and IL-6. These changes in the cytokine microenvironment are associated with high viral load and an increase in tissue damage[68]. Additionally, significant changes occur in the immune system during pregnancy to protect the fetus from the maternal immune system. These alterations result in a shift from a T helper (Th)1-dominated immune response to a Th2-dominated one[69]. Furthermore, the function of the monocyte-macrophage system of pregnant women with acute liver failure is significantly impaired[70]. Nevertheless, the implications of these immunological alterations for the severity of acute HEV infections are not known yet. Lastly, pregnancy-related hormonal changes may also contribute to a poor outcome. The pregnant women with fulminant hepatic failure due to HEV infection have higher concentrations of estrogen, progesterone, and β-human chorionic gonadotrophin than HEV-negative pregnant women with fulminant hepatic failure or healthy controls[65]. Consistent with this, an *in vitro* study showed that serum from pregnant women, particularly those in the third trimester, amplified the HEV replication *via* inhibiting estrogen receptors and the synthesis of type I interferons[71]. As a result, the causal mechanisms of fatal courses in pregnancy remain unknown; thereby, further studies investigating the potential role of patients' hormonal, immunological, and genetic

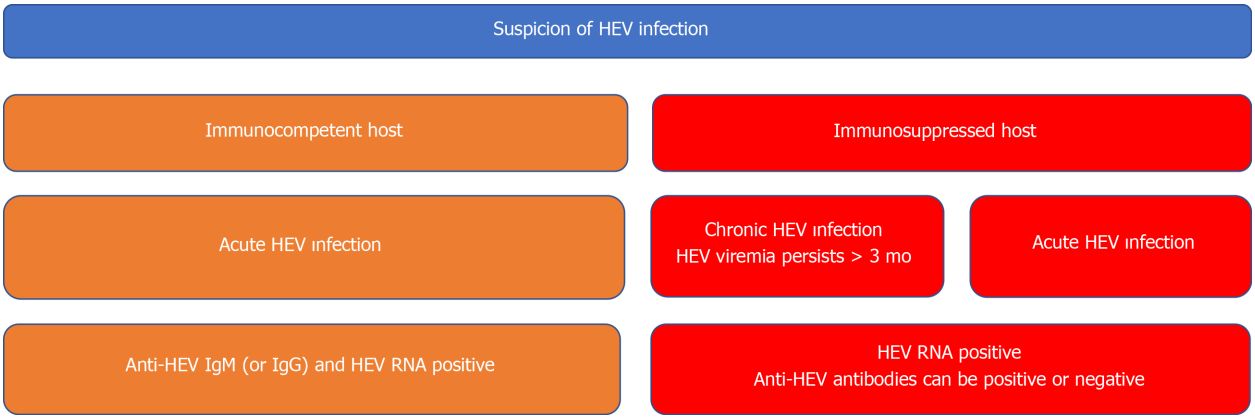

Figure 1 Diagnostic algorithm of hepatitis E virus infection. For diagnosis of acute hepatitis E virus (HEV) infection in immunocompetent patients, both serologic assays and nucleic acid amplification tests (PCR) should be used in combination. Negative PCR results can be seen in early period of acute infection. On the other hand, serologic tests are not reliable tools in immunosuppressed patients. Therefore, PCR results are much more important in diagnosis of acute infection among these patients. In addition, HEV RNA positivity that is lasting at least 3 mo is accepted as a diagnostic marker for chronic HEV infection in some immunocompromised patients (*e.g.*, solid-organ transplant recipients, allogeneic hematopoietic stem cell transplant recipients). HEV: Hepatitis E virus; RNA: Ribonucleic acid; Ig: Immunoglobulin.

factors and HEV variants should be performed to clarify the relationship between pregnancy and worse clinical outcomes in acute HEV1 and HEV2 infections.

ACLF

The typical manifestations of ACLF include acute worsening of the liver function with clinical complications such as the onset or deterioration of ascites and hepatic encephalopathy and coagulopathy. ACLF is associated with an elevated mortality level of nearly 70% in some reports[72,73]. A large prospective study including 343 patients with decompensated liver disease found that hepatic decompensations were associated with acute HEV infection in 11 patients, and three of these patients died[74]. HEV has been proposed as an overlooked cause of infectious trigger for ACLF. Manka *et al*[75] performed a retrospective analysis of 80 acute liver failure cases in a single center from Germany. Among all patients, eight had HEV RNA positivity together with supporting clinical findings of acute HEV infection, but half of them had an initially erroneous diagnosis of drug-induced liver injury. Another study from the United States also showed that a minority of suspected cases of drug-induced liver injury were actually caused by the HEV[76]. For the definition of ACLF, the European definition proposed by the European Association for the Study of the Liver-Chronic Liver Failure consortium was used through this article[77].

Chronic HEV infections in immunocompromised patients

Immunocompromised patients cannot achieve HEV clearance and may develop chronic hepatitis and cirrhosis if infected by HEV3 and HEV4[79,80]. In contrast, chronic HEV infection has not been observed in cases infected with HEV1 and HEV2 until now[78,79]. Although Kamar *et al*[78] described chronic HEV infections in liver and kidney transplant recipients for the first time in the literature in 2008, the exact definition of chronic HEV infection has been intensively debated for a long time. According to Kamar *et al*[59], solid organ transplant recipients who are viremic for more than 3 mo after the onset of HEV infection can be regarded as chronically infected and evaluated for treatment. However, spontaneous clearance without any HEV-specific treatment was demonstrated between 3 and 6 mo of the first detection of HEV viremia in a small number of solid-organ transplant recipients[80]. Importantly, performing the NAATs is mandatory in all patients for the identification of persistent HEV replication as a sign of chronic HEV infection since both anti-HEV IgG and IgM may remain negative under immunocompromised status[81].

Although fatigue is the most frequent symptom in chronic HEV infection, most patients have no symptom and only mild elevations in liver enzymes[81]. Nevertheless, chronic HEV infections may lead to structural injuries in the liver including nodules, fibrotic remodeling, and subsequent cirrhosis[82]. Approximately 20%-50% of transplant recipients having exposure with HEV3 develop chronic infection[83]. Within 2-5 years of chronic HEV infection, approximately 10% of patients develop cirrhosis[84]. Often, the progression in liver inflammation and injury can regress with HEV clearance[85]. The

risk of the development of chronic HEV infection after HEV3 exposure is not associated with the magnitude of HEV load, but it is related with previous tacrolimus use and low lymphocyte count[71]. The clinical presentation of chronic HEV infection has mainly been described in the setting of solid-organ transplantation, but it can be similarly observed in other immunosuppressed patients including those with hematological malignancies undergoing chemotherapy[86-88], individuals with human immunodeficiency virus (HIV)/acquired immune deficiency syndrome having low CD4+ cell count (< 200 cells/mm^3)[89,90], and patients afflicted by rheumatic disorders and receiving immunosuppressive therapy[91].

Extrahepatic manifestations

HEV infections not only affect the liver but may also include other organ systems. Some disorders, including Guillain-Barre syndrome (GBS), neuralgic amyotrophy (NA), lymphoma, pancreatitis, thrombocytopenia, viral meningitis, thyroiditis, myocarditis, cryoglobulinemia, glomerulonephritis, Henoch-Schönlein purpura, and myasthenia gravis, have been claimed to be associated with HEV infection. Although some case series, animal models, and seroepidemiological studies supported casual relations between HEV infection and these extrahepatic manifestations, the exact underlying pathophysiological mechanisms have not yet been proven. Nevertheless, immune-mediated reactions and direct viral (cytopathic) tissue damage are the most commonly assumed culprit mechanisms in extrahepatic manifestations.

Neurological disorders: GBS is a typical neurological disorder emerging after some types of infections and causing severe damage to the peripheral nerves and nerve roots. Antibodies that are produced against gangliosides through molecular mimicry after culprit infections have been shown to lead to GBS[92]. GBS is one of the most frequently published extrahepatic complications of HEV infection, and it can occur after both acute and chronic infections of various HEV genotypes[93]. HEV-related GBS cases have been reported from both developed and developing countries. In a study from the United Kingdom and France, more than 5% of patients having HEV3 infection had neurological complications during follow-up[94]. In a case-control study, 10 out of 201 patients having GBS were infected by the HEV just before or at the onset of their illness[95]. The clinical features and outcomes in HEV-associated GBS resemble those in non-HEV-related GBS cases. A case-control study from Bangladesh reported that 11% (11 patients) of all patients who developed GBS had anti-HEV IgM positivity, and only one patient was HEV1 RNA positive. Of note, antibodies against gangliosides cannot be identified among these patients[96].

Besides GBS, facial nerve paralysis (Bell's palsy), NA, polyradiculopathy, mononeuritis multiplex, viral meningitis, encephalitis, and myelitis are asserted as possibly related with HEV infection. NA (*i.e.* brachial neuritis) is another relatively frequent neurological manifestation of HEV infection and characterized by severe shoulder and arm pain, followed by weakness and atrophy[97]. The pathogenesis of NA is considered to be similar to that of GBS. Most patients presented with bilateral and severe involvement of the brachial plexus. In contrast to other causative agents, HEV-associated NA is not confined to the brachial plexus[98]. Other neurological presentations of HEV infections have been reported in case reports only.

Further studies should be performed to appreciate the actual pathophysiological mechanisms of neurological manifestations in HEV infection. Although some studies have demonstrated the ability of the HEV to complete the full viral life cycle in an oligodendrocyte[99], penetrate the blood-brain barrier[100], and stimulate mitochondrial apoptosis in HEV-infected gerbil brain tissues[101], it is unknown whether neurological manifestations are consequences of immune-mediated (mostly associated with molecular mimicry) mechanisms or the direct cytopathic effect of the HEV.

Hematological manifestations: Thrombocytopenia associated with HEV infections is generally not severe and does not require any specific treatment. However, severe thrombocytopenia was observed in nine patients who were infected by the HEV. Among these patients, the mean platelet count was 12×10^9/L[97]. The mechanism by which HEV infections lead to thrombocytopenia is not yet understood. It is considered being associated with the production of antiplatelet antibodies, as in most viral infections. However, only two out of nine patients had antibody against platelet in the aforementioned cases.

Hemolytic anemia was reported in patients with glucose-6-phosphate dehydrogenase deficiency having acute HEV infection[102,103]. In addition, aplastic anemia was reported in a young man from Pakistan[104]. However, more supporting data are needed to be confident about the causal relationship.

Acute pancreatitis: Acute pancreatitis is associated not only with the HEV but also with other hepatitis viruses (A, B, C). Most acute pancreatitis cases were reported from the Southern Asia region, suggesting that these were possibly caused by HEV1 infections[105,106]. HEV-associated acute pancreatitis is usually resolved with supportive care and mild to moderate in severity[106]. Although we do not have any strong evidence for the relation of HEV infection with acute pancreatitis, acute and severe epigastric pain should bring acute pancreatitis to mind as a possible differential diagnosis in patients having HEV infection. It is still unclear whether there is an increasing risk of acute pancreatitis after HEV3 and HEV4 infections.

Renal manifestations: The HEV can cause glomerulonephritis in both immunocompetent and immunosuppressed patients[107,108]. All glomerular diseases that have possible association with HEV infection were only reported in patients infected by HEV3, except one patient with HEV1 infection[108-110]. In total, at least eight patients with HEV3-associated glomerulonephritis have been described. The types of glomerulonephritis included membranoproliferative glomerulonephritis (n = 4), IgA-glomerulonephritis (n = 2), membranous nephropathy (n = 1), and nephroangiosclerosis (n = 1). All except one glomerulonephritis case were identified in immunocompromised patients. HEV clearance achieved either by therapy or spontaneously improved renal functions and proteinuria levels among these cases[109,110]. Additionally, HEV RNA was detected in the cryoprecipitate obtained from one patient who developed cryoglobulinemic glomerulonephritis[108].

The underlying mechanism by which HEV infection may induce glomerular disease remains to be established. In HEV-induced glomerulonephritis, immune-mediated mechanisms are presumably playing an important role similar to hepatitis C virus (HCV)-associated glomerulonephritis in which immune complexes consisting of HCV antigen, anti-HCV IgG antibodies, and a rheumatoid factor accumulate in the glomerular tissue. To date, 10 cases of mixed cryoglobulinemia likely caused by HEV infection have been published[107-109,111]. All cases had type II or III mixed cryoglobulinemia and were considered to be caused by HEV3 since these occurred in HEV3 endemic regions. In mixed cryoglobulinemia, immunoglobulins that are insoluble at reduced temperatures cause injury in various tissues by accumulating in the vascular bed[97]. Cryoglobulinemia-associated glomerulonephritis is likely to be caused by an uncontrolled immune response to particular viral antigens, as seen in hepatitis B virus- or HCV-associated glomerulonephritis[107-109]. However, a direct cytopathic effect of the HEV on the glomeruli cannot be excluded.

Other manifestations: Other HEV-related extrahepatic manifestations have also been described. These include myocarditis, myositis, thyroiditis, Henoch-Schönlein purpura, and myasthenia gravis. However, more convincing data are needed to construct causality between these disorders and HEV infection.

TREATMENT

Treatment of acute HEV infection and ACLF

To date, no specific drugs have been approved for the treatment of HEV infections. Fortunately, in the vast majority of cases, acute HEV infection can be cleared spontaneously and does not require any specific treatment. However, acute HEV infection can progress to severe hepatitis and liver failure particularly in pregnant women and patients with underlying chronic liver diseases. In severe cases like ACLF, rapid clearance of the HEV and normalization of liver enzymes were noted with ribavirin treatment[112]. In these cases, there was a great variability in doses and durations of ribavirin treatment, and no severe adverse reaction related with ribavirin treatment[113]. Although there is no alternative treatment option to ribavirin in acute and severe hepatitis or ACLF caused by the HEV, the efficacy of ribavirin has still not been clarified by large-scale studies or randomized, controlled trials. In some case reports, corticosteroids were offered for slowing down the rate of progression to liver failure in patients with fulminant hepatitis E[78].

Current treatment options for pregnant women with HEV1- or HEV2-related severe hepatitis or liver failure are much more limited. Since ribavirin treatment is contraindicated in pregnant patients because of the teratogenic potential of ribavirin, no study has demonstrated the effectiveness of ribavirin in pregnant patients with severe hepatitis until now. However, Sinclair *et al*[114] reported no teratogenicity with ribavirin treatment for pregnant patients who were infected by the HCV and exposed

to ribavirin directly or indirectly. This finding can be partly explained by the lack of teratogenic effects of ribavirin at the last trimester due to the completion of organogenesis in the first trimester of pregnancy. Therefore, ribavirin can be suggested for pregnant patients infected by the HEV in the last trimester of pregnancy in a case-by-case fashion considering the very high mortality rate (almost 20%) of HEV infection in that period. As an alternative approach, diligent follow-up of the liver function test and supportive care can be applied in treatment for pregnant patients infected by HEV1 or HEV2. Early liver transplantation should be considered in indicated patients[115]. However, the therapeutic termination of pregnancy cannot be recommended based on the current literature[116].

Treatment of chronic HEV infection

The first-line therapeutic approach for solid organ transplant recipients who have chronic HEV3 or HEV4 infection should be dose reduction of immunosuppressive medications, particularly those targeting T lymphocytes. This approach alone provides sustained viral clearance in up to one-third of patients[86]. Kamar *et al*[81] reported 25% (4/16) success rate in viral clearance only by reducing the doses of immuno-suppressive medications in solid-organ transplant recipients. However, all immunosuppressive drugs do not have the same effects. In *in vitro* studies, viral replication has been shown to be upregulated by mammalian target of rapamycin inhibitors but suppressed by mycophenolate mofetil[117,118]. It is essential to establish the clinical implications of these *in vitro* findings since chronic HEV infections have been reported in mycophenolate-receiving transplant patients.

Although pegylated interferon-alpha can be considered in liver transplant recipients and patients undergoing hemodialysis for the treatment of chronic HEV infection[118,119], it is contraindicated in renal, pancreas, heart, and lung transplant patients because of enhanced immune response and the risk of rejection[120]. Therefore, ribavirin constitutes the treatment of choice in chronic HEV infections in many solid-organ transplant recipients, despite that its efficacy has not been endorsed by randomized, controlled trials. In a multicenter retrospective study including 59 solid organ transplant recipients treated with ribavirin at a median dose of 600 (range, 29-1200) mg/d for 3 (range, 1-18) mo, the rate of sustained virologic response (undetectable HEV RNA in serum 6 mo after the completion of ribavirin treatment) was 78%. Additionally, one-third of patients with persistent HEV viremia at the end of the 3-mo treatment achieved sustained virologic response after receiving ribavirin for a longer period[121]. Kamar *et al*[122] collected data retrospectively from 30 European centers to depict the outcomes of ribavirin treatment among 255 solid-organ transplant recipients with chronic HEV3 infection. The primary aim of this study was to describe the ribavirin treatment responses and determinants of sustained virologic response. In the results of this study, 81% of all patients achieved sustained virologic response with an initial ribavirin treatment at a median dose of 600 mg/d for a median duration of 3 mo, while the rate of sustained virologic response elevated to 90% when an additional course of ribavirin was given to those who did not initially achieve sustained virologic response. This study also confirmed that higher baseline lymphocyte count and good hematologic tolerance to ribavirin (*i.e.*, not needing ribavirin dose reduction) were predictors of achieving sustained virologic response. Nevertheless, tolerability of ribavirin treatment is still a major concern. In this study, 28% of patients needed ribavirin dose adjustment because of hematological side effects. Although the optimal duration of ribavirin therapy remains unclear, the 3-mo treatment is the most widely used treatment modality for chronic HEV infections. At the completion of ribavirin treatment, the detection of HEV RNA in the stools of patients in whom HEV RNA was negative in the serum was reported as being associated with an increased risk of HEV viremia at follow-up[123]. Also, Kamar *et al*[124] showed that a reduction in the HEV RNA concentration of ≥ 0.5 log10 IU/mL at day 7 was a highly predictive marker of sustained virologic response. In the same study, the serum ribavirin trough level had no impact on sustained virologic response at the 7th or 60th d of therapy.

Chronic HEV infection can be treated by pegylated interferon-alpha, ribavirin, or the combination of two drugs in non-transplant immunosuppressed patients, that is patients with hematological disorders or HIV, according to the results of a few case reports and small case series[88,125-127]. In line with these findings, Tavitian *et al*[128] reported that 75% (9/12) of stem cell transplant recipients achieved sustained virologic response with ribavirin treatment.

The antiviral mechanism of ribavirin against the HEV is not completely understood. Ribavirin seems to inhibit HEV replication by depleting guanosine triphosphate pools, which probably inhibits inosine monophosphate dehydrogenase and prevents HEV RNA replication[129]. However, the deep sequences revealed *G1634R* and *Y1320H*

mutations in the HEV RNA polymerase gene in patients who cannot achieve sustained virologic response with ribavirin treatment[130,131]. Furthermore, the *G1634R* mutation was found to emerge during ribavirin treatment in relapsed patients[130]. Interestingly, some studies showed that prolong treatment with ribavirin (*e.g.*, 6 mo duration) can achieve sustained virologic response even in HEV infections that cannot be cured by 3-mo ribavirin therapy and caused by HEV strains carrying the *G1634R* mutation[132]. Additional mutational variants in the HEV polymerase gene have been subsequently described. Interestingly, some of these mutations render the HEV sensitive to ribavirin; others promote or suppress HEV replication[131,133]. Hence, the role of HEV RNA polymerase mutations and their effects on HEV infection-related outcomes are not yet established.

Ribavirin treatment can cause some side effects including skin reactions, dose-dependent hemolytic anemia, and dry cough. As patients with chronic HEV infection have some comorbidities resulting in impaired renal function or anemia, ribavirin doses should be adjusted cautiously in these patients[134].

Treatment of extrahepatic complications

The extrahepatic manifestations of HEV infections can be treated by either ribavirin or immunosuppressive medications such as corticosteroids. Before deciding treatment for these manifestations, the main mechanism of extrahepatic manifestation in question should first be determined. As mentioned before, extrahepatic manifestations are mainly mediated by immunological mechanisms or the direct viral (cytopathic) effect of the HEV. Therefore, treatment (ribavirin or immunosuppressive drugs) should be chosen according to the main pathophysiological mechanisms of extrahepatic manifestations.

PROMISING TREATMENT OPTIONS FOR RIBAVIRIN-RESISTANT HEV INFECTIONS

Sofosbuvir, an *NS5B* polymerase inhibitor, was approved by the Food and Drug Administration for the treatment of hepatitis C. Because of its high *in vitro* efficacy, sofosbuvir was also considered as an option in the treatment of ribavirin-resistant HEV infections[135]. However, a study involving 10 cases with chronic HEV infection reported only partial response and high rate of relapse with sofosbuvir monotherapy[136]. Moreover, it was administered as combination therapy with ribavirin in some ribavirin-resistant cases. Biliotti *et al*[137] showed the clearance of the HEV with sofosbuvir/ribavirin combination therapy in patients with acute HEV infection. In another study, combination therapy was reported to treat refractory HEV infection in an immunosuppressed individual[138]. In contrast, other studies demonstrated that sofosbuvir/ribavirin combination therapy was not able to provide sustained virologic response in chronic HEV infections observed in solid-organ transplant recipients and patients infected by the HIV[139-141]. Similarly, Schulz *et al*[142] reported that sustained virologic response could not be achieved with ribavirin and sofosbuvir combination in a multi-organ transplanted patient with chronic HEV3 infection. In the deep sequence analysis undertaken at three separate time points, a stepwise accumulation of four well-characterized ribavirin-associated resistance mutations (*K1383N*, *D1384N*, *V1479I*, and *G1634R*) was identified. The results of an ongoing phase 2 clinical trial are curiously awaited to understand the efficacy of sofosbuvir in the treatment of HEV infection.

Nishiyama *et al*[143] reported a promising compound, 2'-C-methylguanosine, that suppressed the growth of HEV3 in cell cultures and showed *in vitro* synergistic interaction with ribavirin against the HEV. However, there is no study yet exploring its efficacy and safety in animal models and human trials.

Zinc can be a potential adjuvant therapy in ribavirin-resistant and/or relapsed HEV infections. Horvatits *et al*[144] reported the favorable *in vitro* efficacy of zinc in a patient with a breakthrough HEV infection under 800 mg/d of ribavirin treatment[145]. Additionally, authors identified significantly lower serum zinc level in patients with chronic HEV infection than in the control group[144]. More importantly, the addition of 120 mg/d of zinc to existing ribavirin treatment cleared the HEV in this patient[144]. In contrast, two solid-organ transplant recipients with chronic HEV infections failed to achieve sustained virologic response with ribavirin treatment despite having elevated intra-erythrocyte zinc concentrations[145]. Clearly, further large-scale studies are required to understand the impact of adjuvant zinc therapy on patients who have chronic HEV infection and fail to achieve sustained virologic response under ribavirin

monotherapy.

In vitro, the natural compound silvestrol has an inhibitory effect on HEV replication[146]. Additionally, silvestrol-treated mice showed a rapid diminish in fecal concentrations of HEV RNA[146]. However, it has not yet been tested on humans.

NITD008 and GPC-N114 were originally developed to treat the dengue virus and picornaviruses, respectively. These two novel antiviral candidates demonstrated a potent inhibitory effect against HEV replication without causing significant cellular cytotoxicity in cell cultures[147]. However, the antiviral efficacy and safety of these compounds are still unknown for HEV infections in humans.

VACCINE

In 2010, an HEV vaccine, based on a protein encoded by ORF 2 of an HEV1, was assessed in a phase 3 trial including more than 100000 participants from China[148]. In this phase 3 trial, the long-term efficacy and safety of this vaccine was explored over more than 4 years in a vaccinated group (n = 56302 participants) in comparison with a control group (n = 56302 participants). The authors of this trial identified only 60 cases of hepatitis E, and seven of them belonged to the vaccinated group. Furthermore, no serious adverse events related to the vaccine were observed[148]. Because of the endemicity of HEV1 and HEV4 in China, the protective effect of this vaccine could be assumed for HEV1 and four infections, but these findings cannot be extrapolated for HEV3 infections. That is why the National Institute of Health decided to perform a phase 1 trial to investigate the safety of this vaccine, and phase 2 and 3 trials will likely follow that trial. Therefore, the findings from these trials will demonstrate the safety and efficacy of HEV vaccine (Hecolin) in an HEV3 endemic region. Additionally, an ongoing large trial is testing Hecolin in more than 20000 pregnant women in Bangladesh. The results of this study would be quite important to understand the effectiveness and safety of Hecolin in pregnant women (clinicaltrials.gov, NCT02759991) who are under great risk of HEV1 infections.

CONCLUSION

The HEV is an important cause of viral hepatitis in both high- and low-income countries. Previously, HEV infections were considered a problem of undeveloped countries, which have poor sanitation standards and clean drinking water supply systems. The recent data revealed that the global burden of HEV infection is greater than previously estimated, and autochthonous HEV infections in high-income countries are prevailing worldwide. Additionally, the epidemiology of HEV infections has not yet been established in many countries. The great majority of HEV infections are asymptomatic or mildly symptomatic, although pregnant women and patients with chronic liver diseases have a significant risk of severe hepatitis and hepatic failure. Furthermore, immunocompromised patients may develop chronic hepatitis after HEV3 or HEV4 exposure. Besides hepatic manifestations, HEV infections may lead to diverse extrahepatic involvements such as neurological and renal manifestations. Although ribavirin has been used in the treatment of chronic HEV infections for several years, there is no randomized, controlled trial that supports the safety and efficacy of ribavirin in the treatment of HEV infections. Similarly, there is no robust evidence for the effectiveness of ribavirin and interferon-alpha therapies in acute HEV infection. Moreover, ribavirin is not a panacea, and the administration of ribavirin for pregnant women is highly debatable. Therefore, new compounds that are safe and effective are needed for patients having ribavirin intolerance and infected by the ribavirin-resistant HEV.

REFERENCES

1 **Hoofnagle JH**, Nelson KE, Purcell RH. Hepatitis E. *N Engl J Med* 2012; **367**: 1237-1244 [PMID: 23013075 DOI: 10.1056/NEJMra1204512]

2 **Krawczynski K**. Foreword. Hepatitis E virus. *Semin Liver Dis* 2013; **33**: 1-2 [PMID: 23564384 DOI: 10.1055/s-0033-1338119]

3 **Chandra NS**, Sharma A, Malhotra B, Rai RR. Dynamics of HEV viremia, fecal shedding and its relationship with transaminases and antibody response in patients with sporadic acute hepatitis E. *Virol J* 2010; **7**: 213 [PMID: 20815928 DOI: 10.1186/1743-422X-7-213]

4 **Guerra JAAA**, Kampa KC, Morsoletto DGB, Junior AP, Ivantes CAP. Hepatitis E: A Literature Review. *J Clin Transl Hepatol* 2017; **5**: 376-383 [PMID: 29226104 DOI: 10.14218/JCTH.2017.00012]
5 **Balayan MS**, Andjaparidze AG, Savinskaya SS, Ketiladze ES, Braginsky DM, Savinov AP, Poleschuk VF. Evidence for a virus in non-A, non-B hepatitis transmitted via the fecal-oral route. *Intervirology* 1983; **20**: 23-31 [PMID: 6409836 DOI: 10.1159/000149370]
6 **Reyes GR**, Purdy MA, Kim JP, Luk KC, Young LM, Fry KE, Bradley DW. Isolation of a cDNA from the virus responsible for enterically transmitted non-A, non-B hepatitis. *Science* 1990; **247**: 1335-1339 [PMID: 2107574 DOI: 10.1126/science.2107574]
7 **Tam AW**, Smith MM, Guerra ME, Huang CC, Bradley DW, Fry KE, Reyes GR. Hepatitis E virus (HEV): molecular cloning and sequencing of the full-length viral genome. *Virology* 1991; **185**: 120-131 [PMID: 1926770 DOI: 10.1016/0042-6822(91)90760-9]
8 **Fry KE**, Tam AW, Smith MM, Kim JP, Luk KC, Young LM, Piatak M, Feldman RA, Yun KY, Purdy MA. Hepatitis E virus (HEV): strain variation in the nonstructural gene region encoding consensus motifs for an RNA-dependent RNA polymerase and an ATP/GTP binding site. *Virus Genes* 1992; **6**: 173-185 [PMID: 1589964 DOI: 10.1007/BF01703066]
9 **Rozanov MN**, Koonin EV, Gorbalenya AE. Conservation of the putative methyltransferase domain: a hallmark of the 'Sindbis-like' supergroup of positive-strand RNA viruses. *J Gen Virol* 1992; **73**: 2129-2134 [PMID: 1645151 DOI: 10.1099/0022-1317-73-8-2129]
10 **Jameel S**, Zafrullah M, Ozdener MH, Panda SK. Expression in animal cells and characterization of the hepatitis E virus structural proteins. *J Virol* 1996; **70**: 207-216 [PMID: 8523527 DOI: 10.1128/JVI.70.1.207-216.1996]
11 **Ding Q**, Heller B, Capuccino JM, Song B, Nimgaonkar I, Hrebikova G, Contreras JE, Ploss A. Hepatitis E virus ORF3 is a functional ion channel required for release of infectious particles. *Proc Natl Acad Sci USA* 2017; **114**: 1147-1152 [PMID: 28096411 DOI: 10.1073/pnas.1614955114]
12 **Nair VP**, Anang S, Subramani C, Madhvi A, Bakshi K, Srivastava A, Shalimar, Nayak B, Ranjith Kumar CT, Surjit M. Endoplasmic Reticulum Stress Induced Synthesis of a Novel Viral Factor Mediates Efficient Replication of Genotype-1 Hepatitis E Virus. *PLoS Pathog* 2016; **12**: e1005521 [PMID: 27035822 DOI: 10.1371/journal.ppat.1005521]
13 **Xing L**, Wang JC, Li TC, Yasutomi Y, Lara J, Khudyakov Y, Schofield D, Emerson SU, Purcell RH, Takeda N, Miyamura T, Cheng RH. Spatial configuration of hepatitis E virus antigenic domain. *J Virol* 2011; **85**: 1117-1124 [PMID: 21068233 DOI: 10.1128/JVI.00657-10]
14 **Guu TS**, Liu Z, Ye Q, Mata DA, Li K, Yin C, Zhang J, Tao YJ. Structure of the hepatitis E virus-like particle suggests mechanisms for virus assembly and receptor binding. *Proc Natl Acad Sci USA* 2009; **106**: 12992-12997 [PMID: 19622744 DOI: 10.1073/pnas.0904848106]
15 **Nimgaonkar I**, Ding Q, Schwartz RE, Ploss A. Hepatitis E virus: advances and challenges. *Nat Rev Gastroenterol Hepatol* 2018; **15**: 96-110 [PMID: 29162935 DOI: 10.1038/nrgastro.2017.150]
16 **Holla RP**, Ahmad I, Ahmad Z, Jameel S. Molecular virology of hepatitis E virus. *Semin Liver Dis* 2013; **33**: 3-14 [PMID: 23564385 DOI: 10.1055/s-0033-1338110]
17 **Dai X**, Dong C, Zhou Z, Liang J, Dong M, Yang Y, Fu J, Tian H, Wang S, Fan J, Meng J, Purdy MA. Hepatitis E virus genotype 4, Nanjing, China, 2001-2011. *Emerg Infect Dis* 2013; **19**: 1528-1530 [PMID: 23965731 DOI: 10.3201/eid1909.130013]
18 **Aggarwal R**. Hepatitis E: Historical, contemporary and future perspectives. *J Gastroenterol Hepatol* 2011; **26** Suppl 1: 72-82 [PMID: 21199517 DOI: 10.1111/j.1440-1746.2010.06540.x]
19 **VISWANATHAN R**. A review of the literature on the epidemiology of infectious hepatitis. *Indian J Med Res* 1957; **45**: 145-155 [PMID: 13438550]
20 **Naik SR**, Aggarwal R, Salunke PN, Mehrotra NN. A large waterborne viral hepatitis E epidemic in Kanpur, India. *Bull World Health Organ* 1992; **70**: 597-604 [PMID: 1464145]
21 **Kamar N**, Bendall R, Legrand-Abravanel F, Xia NS, Ijaz S, Izopet J, Dalton HR. Hepatitis E. *Lancet* 2012; **379**: 2477-2488 [PMID: 22549046 DOI: 10.1016/S0140-6736(11)61849-7]
22 **Rein DB**, Stevens GA, Theaker J, Wittenborn JS, Wiersma ST. The global burden of hepatitis E virus genotypes 1 and 2 in 2005. *Hepatology* 2012; **55**: 988-997 [PMID: 22121109 DOI: 10.1002/hep.25505]
23 **Kamar N**, Dalton HR, Abravanel F, Izopet J. Hepatitis E virus infection. *Clin Microbiol Rev* 2014; **27**: 116-138 [PMID: 24396139 DOI: 10.1128/CMR.00057-13]
24 **Khuroo MS**, Kamili S, Khuroo MS. Clinical course and duration of viremia in vertically transmitted hepatitis E virus (HEV) infection in babies born to HEV-infected mothers. *J Viral Hepat* 2009; **16**: 519-523 [PMID: 19228284 DOI: 10.1111/j.1365-2893.2009.01101.x]
25 **Khuroo MS**, Kamili S, Yattoo GN. Hepatitis E virus infection may be transmitted through blood transfusions in an endemic area. *J Gastroenterol Hepatol* 2004; **19**: 778-784 [PMID: 15209625 DOI: 10.1111/j.1440-1746.2004.03437.x]
26 **Doceul V**, Bagdassarian E, Demange A, Pavio N. Zoonotic Hepatitis E Virus: Classification, Animal Reservoirs and Transmission Routes. *Viruses* 2016; **8** [PMID: 27706110 DOI: 10.3390/v8100270]
27 **Schlosser J**, Eiden M, Vina-Rodriguez A, Fast C, Dremsek P, Lange E, Ulrich RG, Groschup MH. Natural and experimental hepatitis E virus genotype 3-infection in European wild boar is transmissible to domestic pigs. *Vet Res* 2014; **45**: 121 [PMID: 25421429 DOI: 10.1186/s13567-014-0121-8]
28 **Izopet J**, Dubois M, Bertagnoli S, Lhomme S, Marchandeau S, Boucher S, Kamar N, Abravanel F, Guérin JL. Hepatitis E virus strains in rabbits and evidence of a closely related strain in humans, France. *Emerg Infect Dis* 2012; **18**: 1274-1281 [PMID: 22840216 DOI: 10.3201/eid1808.120057]
29 **Yan B**, Zhang L, Gong L, Lv J, Feng Y, Liu J, Song L, Xu Q, Jiang M, Xu A. Hepatitis E Virus in Yellow Cattle, Shandong, Eastern China. *Emerg Infect Dis* 2016; **22**: 2211-2212 [PMID: 27869603 DOI: 10.3201/eid2212.160641]
30 **Huang F**, Li Y, Yu W, Jing S, Wang J, Long F, He Z, Yang C, Bi Y, Cao W, Liu C, Hua X, Pan Q. Excretion of infectious hepatitis E virus into milk in cows imposes high risks of zoonosis. *Hepatology* 2016; **64**: 350-359 [PMID: 27286751 DOI: 10.1002/hep.28668]
31 **Barnaud E**, Rogée S, Garry P, Rose N, Pavio N. Thermal inactivation of infectious hepatitis E virus in

experimentally contaminated food. *Appl Environ Microbiol* 2012; **78**: 5153-5159 [PMID: 22610436 DOI: 10.1128/AEM.00436-12]

32 **Terio V**, Bottaro M, Pavoni E, Losio MN, Serraino A, Giacometti F, Martella V, Mottola A, Di Pinto A, Tantillo G. Occurrence of hepatitis A and E and norovirus GI and GII in ready-to-eat vegetables in Italy. *Int J Food Microbiol* 2017; **249**: 61-65 [PMID: 28319799 DOI: 10.1016/j.ijfoodmicro.2017.03.008]

33 **Maunula L**, Kaupke A, Vasickova P, Söderberg K, Kozyra I, Lazic S, van der Poel WH, Bouwknegt M, Rutjes S, Willems KA, Moloney R, D'Agostino M, de Roda Husman AM, von Bonsdorff CH, Rzeżutka A, Pavlik I, Petrovic T, Cook N. Tracing enteric viruses in the European berry fruit supply chain. *Int J Food Microbiol* 2013; **167**: 177-185 [PMID: 24135674 DOI: 10.1016/j.ijfoodmicro.2013.09.003]

34 **Riveiro-Barciela M**, Sauleda S, Quer J, Salvador F, Gregori J, Pirón M, Rodríguez-Frías F, Buti M. Red blood cell transfusion-transmitted acute hepatitis E in an immunocompetent subject in Europe: a case report. *Transfusion* 2017; **57**: 244-247 [PMID: 27785789 DOI: 10.1111/trf.13876]

35 **Hewitt PE**, Ijaz S, Brailsford SR, Brett R, Dicks S, Haywood B, Kennedy IT, Kitchen A, Patel P, Poh J, Russell K, Tettmar KI, Tossell J, Ushiro-Lumb I, Tedder RS. Hepatitis E virus in blood components: a prevalence and transmission study in southeast England. *Lancet* 2014; **384**: 1766-1773 [PMID: 25078306 DOI: 10.1016/S0140-6736(14)61034-5]

36 **Nicaise G**, Gillot I, Julliard AK, Keicher E, Blaineau S, Amsellem J, Meyran JC, Hernandez-Nicaise ML, Ciapa B, Gleyzal C. X-ray microanalysis of calcium containing organelles in resin embedded tissue. *Scanning Microsc* 1989; **3**: 199-219; discussion 219-220 [PMID: 2662396 DOI: 10.1111/apt.13484]

37 **Ankcorn MJ**, Tedder RS, Cairns J, Sandmann FG. Cost-Effectiveness Analysis of Screening for Persistent Hepatitis E Virus Infection in Solid Organ Transplant Patients in the United Kingdom: A Model-Based Economic Evaluation. *Value Health* 2020; **23**: 309-318 [PMID: 32197726 DOI: 10.1016/j.jval.2019.09.2751]

38 **Vento S**, Garofano T, Renzini C, Cainelli F, Casali F, Ghironzi G, Ferraro T, Concia E. Fulminant hepatitis associated with hepatitis A virus superinfection in patients with chronic hepatitis C. *N Engl J Med* 1998; **338**: 286-290 [PMID: 9445408 DOI: 10.1056/NEJM199801293380503]

39 **Schlosser B**, Stein A, Neuhaus R, Pahl S, Ramez B, Krüger DH, Berg T, Hofmann J. Liver transplant from a donor with occult HEV infection induced chronic hepatitis and cirrhosis in the recipient. *J Hepatol* 2012; **56**: 500-502 [PMID: 21798217 DOI: 10.1016/j.jhep.2011.06.021]

40 **Lu L**, Li C, Hagedorn CH. Phylogenetic analysis of global hepatitis E virus sequences: genetic diversity, subtypes and zoonosis. *Rev Med Virol* 2006; **16**: 5-36 [PMID: 16175650 DOI: 10.1002/rmv.482]

41 **Mansuy JM**, Bendall R, Legrand-Abravanel F, Sauné K, Miédouge M, Ellis V, Rech H, Destruel F, Kamar N, Dalton HR, Izopet J. Hepatitis E virus antibodies in blood donors, France. *Emerg Infect Dis* 2011; **17**: 2309-2312 [PMID: 22172156 DOI: 10.3201/eid1712.110371]

42 **Aspinall EJ**, Couturier E, Faber M, Said B, Ijaz S, Tavoschi L, Takkinen J, Adlhoch C; The Country Experts. Hepatitis E virus infection in Europe: surveillance and descriptive epidemiology of confirmed cases, 2005 to 2015. *Euro Surveill* 2017; **22** [PMID: 28681720 DOI: 10.2807/1560-7917.ES.2017.22.26.30561]

43 **Doting MHE**, Weel J, Niesters HGM, Riezebos-Brilman A, Brandenburg A. The added value of hepatitis E diagnostics in determining causes of hepatitis in routine diagnostic settings in the Netherlands. *Clin Microbiol Infect* 2017; **23**: 667-671 [PMID: 28285979 DOI: 10.1016/j.cmi.2017.02.026]

44 **Ditah I**, Ditah F, Devaki P, Ditah C, Kamath PS, Charlton M. Current epidemiology of hepatitis E virus infection in the United States: low seroprevalence in the National Health and Nutrition Evaluation Survey. *Hepatology* 2014; **60**: 815-822 [PMID: 24824965 DOI: 10.1002/hep.27219]

45 **Kamar N**, Izopet J, Pavio N, Aggarwal R, Labrique A, Wedemeyer H, Dalton HR. Hepatitis E virus infection. *Nat Rev Dis Primers* 2017; **3**: 17086 [PMID: 29154369 DOI: 10.1038/nrdp.2017.86]

46 **Li TC**, Kataoka M, Takahashi K, Yoshizaki S, Kato T, Ishii K, Takeda N, Mishiro S, Wakita T. Generation of hepatitis E virus-like particles of two new genotypes G5 and G6 and comparison of antigenic properties with those of known genotypes. *Vet Microbiol* 2015; **178**: 150-157 [PMID: 25934534 DOI: 10.1016/j.vetmic.2015.04.020]

47 **Rasche A**, Saqib M, Liljander AM, Bornstein S, Zohaib A, Renneker S, Steinhagen K, Wernery R, Younan M, Gluecks I, Hilali M, Musa BE, Jores J, Wernery U, Drexler JF, Drosten C, Corman VM. Hepatitis E Virus Infection in Dromedaries, North and East Africa, United Arab Emirates, and Pakistan, 1983-2015. *Emerg Infect Dis* 2016; **22**: 1249-1252 [PMID: 27315454 DOI: 10.3201/eid2207.160168]

48 **Lee GH**, Tan BH, Teo EC, Lim SG, Dan YY, Wee A, Aw PP, Zhu Y, Hibberd ML, Tan CK, Purdy MA, Teo CG. Chronic Infection With Camelid Hepatitis E Virus in a Liver Transplant Recipient Who Regularly Consumes Camel Meat and Milk. *Gastroenterology* 2016; **150**: 355-7.e3 [PMID: 26551551 DOI: 10.1053/j.gastro.2015.10.048]

49 **Sridhar S**, Yip CC, Wu S, Chew NF, Leung KH, Chan JF, Zhao PS, Chan WM, Poon RW, Tsoi HW, Cai JP, Chan HS, Leung AW, Tse CW, Zee JS, Tsang OT, Cheng VC, Lau SK, Woo PC, Tsang DN, Yuen KY. Transmission of rat hepatitis E virus infection to humans in Hong Kong: a clinical and epidemiological analysis. *Hepatology* 2020 [PMID: 31960460 DOI: 10.1002/hep.31138]

50 **World Health Organization**. Waterborne outbreaks of hepatitis E: recognition, investigation and control. Technical report. 2014. Available from: https://www.who.int/hiv/pub/hepatitis/HepE-manual/en/

51 **Abravanel F**, Chapuy-Regaud S, Lhomme S, Miedougé M, Peron JM, Alric L, Rostaing L, Kamar N, Izopet J. Performance of anti-HEV assays for diagnosing acute hepatitis E in immunocompromised patients. *J Clin Virol* 2013; **58**: 624-628 [PMID: 24183927 DOI: 10.1016/j.jcv.2013.10.003]

52 **Legrand-Abravanel F**, Thevenet I, Mansuy JM, Saune K, Vischi F, Peron JM, Kamar N, Rostaing L, Izopet J. Good performance of immunoglobulin M assays in diagnosing genotype 3 hepatitis E virus infections. *Clin Vaccine Immunol* 2009; **16**: 772-774 [PMID: 19321696 DOI: 10.1128/CVI.00438-08]

53 **Huang S**, Zhang X, Jiang H, Yan Q, Ai X, Wang Y, Cai J, Jiang L, Wu T, Wang Z, Guan L, Shih JW, Ng MH, Zhu F, Zhang J, Xia N. Profile of acute infectious markers in sporadic hepatitis E. *PLoS One* 2010; **5**: e13560 [PMID: 21042408 DOI: 10.1371/journal.pone.0013560]

54 **European Association for the Study of the Liver**. EASL Clinical Practice Guidelines on hepatitis E virus infection. *J Hepatol* 2018; **68**: 1256-1271 [PMID: 29609832 DOI: 10.1016/j.jhep.2018.03.005]

55 **Abravanel F**, Lhomme S, Chapuy-Regaud S, Mansuy JM, Muscari F, Sallusto F, Rostaing L, Kamar N, Izopet J. Hepatitis E virus reinfections in solid-organ-transplant recipients can evolve into chronic infections. *J Infect Dis* 2014; **209**: 1900-1906 [PMID: 24436450 DOI: 10.1093/infdis/jiu032]

56 **Wen GP**, Tang ZM, Yang F, Zhang K, Ji WF, Cai W, Huang SJ, Wu T, Zhang J, Zheng ZZ, Xia NS. A valuable antigen detection method for diagnosis of acute hepatitis E. *J Clin Microbiol* 2015; **53**: 782-788 [PMID: 25540394 DOI: 10.1128/JCM.01853-14]

57 **Zhao C**, Geng Y, Harrison TJ, Huang W, Song A, Wang Y. Evaluation of an antigen-capture EIA for the diagnosis of hepatitis E virus infection. *J Viral Hepat* 2015; **22**: 957-963 [PMID: 25732029 DOI: 10.1111/jvh.12397]

58 **Behrendt P**, Bremer B, Todt D, Brown RJ, Heim A, Manns MP, Steinmann E, Wedemeyer H. Hepatitis E Virus (HEV) ORF2 Antigen Levels Differentiate Between Acute and Chronic HEV Infection. *J Infect Dis* 2016; **214**: 361-368 [PMID: 27234418 DOI: 10.1093/infdis/jiw161]

59 **Kamar N**, Rostaing L, Legrand-Abravanel F, Izopet J. How should hepatitis E virus infection be defined in organ-transplant recipients? *Am J Transplant* 2013; **13**: 1935-1936 [PMID: 23659713 DOI: 10.1111/ajt.12253]

60 **Baylis SA**, Blümel J, Mizusawa S, Matsubayashi K, Sakata H, Okada Y, Nübling CM, Hanschmann KM; HEV Collaborative Study Group. World Health Organization International Standard to harmonize assays for detection of hepatitis E virus RNA. *Emerg Infect Dis* 2013; **19**: 729-735 [PMID: 23647659 DOI: 10.3201/eid1905.121845]

61 **Jothikumar N**, Cromeans TL, Robertson BH, Meng XJ, Hill VR. A broadly reactive one-step real-time RT-PCR assay for rapid and sensitive detection of hepatitis E virus. *J Virol Methods* 2006; **131**: 65-71 [PMID: 16125257 DOI: 10.1016/j.jviromet.2005.07.004]

62 **Lhomme S**, Marion O, Abravanel F, Izopet J, Kamar N. Clinical Manifestations, Pathogenesis and Treatment of Hepatitis E Virus Infections. *J Clin Med* 2020; **9** [PMID: 31991629 DOI: 10.3390/jcm9020331]

63 **Pischke S**, Wedemeyer H. Hepatitis E virus infection: multiple faces of an underestimated problem. *J Hepatol* 2013; **58**: 1045-1046 [PMID: 23266489 DOI: 10.1016/j.jhep.2012.12.013]

64 **NAIDU SS**, VISWANATHAN R. Infectious hepatitis in pregnancy during Delhi epidemic. *Indian J Med Res* 1957; **45**: 71-76 [PMID: 13438540]

65 **Jilani N**, Das BC, Husain SA, Baweja UK, Chattopadhya D, Gupta RK, Sardana S, Kar P. Hepatitis E virus infection and fulminant hepatic failure during pregnancy. *J Gastroenterol Hepatol* 2007; **22**: 676-682 [PMID: 17444855 DOI: 10.1111/j.1440-1746.2007.04913.x]

66 **Anty R**, Ollier L, Péron JM, Nicand E, Cannavo I, Bongain A, Giordanengo V, Tran A. First case report of an acute genotype 3 hepatitis E infected pregnant woman living in South-Eastern France. *J Clin Virol* 2012; **54**: 76-78 [PMID: 22336086 DOI: 10.1016/j.jcv.2012.01.016]

67 **Bouthry E**, Benachi A, Vivanti AJ, Letamendia E, Vauloup-Fellous C, Roque-Afonso AM. Autochthonous Hepatitis E during Pregnancy, France. *Emerg Infect Dis* 2018; **24**: 1586-1587 [PMID: 30016249 DOI: 10.3201/eid2408.180105]

68 **Gouilly J**, Chen Q, Siewiera J, Cartron G, Levy C, Dubois M, Al-Daccak R, Izopet J, Jabrane-Ferrat N, El Costa H. Genotype specific pathogenicity of hepatitis E virus at the human maternal-fetal interface. *Nat Commun* 2018; **9**: 4748 [PMID: 30420629 DOI: 10.1038/s41467-018-07200-2]

69 **Romagnani S**. The Th1/Th2 paradigm. *Immunol Today* 1997; **18**: 263-266 [PMID: 9190109 DOI: 10.1016/s0167-5699(97)80019-9]

70 **Sehgal R**, Patra S, David P, Vyas A, Khanam A, Hissar S, Gupta E, Kumar G, Kottilil S, Maiwall R, Sarin SK, Trehanpati N. Impaired monocyte-macrophage functions and defective Toll-like receptor signaling in hepatitis E virus-infected pregnant women with acute liver failure. *Hepatology* 2015; **62**: 1683-1696 [PMID: 26331854 DOI: 10.1002/hep.28143]

71 **Bi Y**, Yang C, Yu W, Zhao X, Zhao C, He Z, Jing S, Wang H, Huang F. Pregnancy serum facilitates hepatitis E virus replication in vitro. *J Gen Virol* 2015; **96**: 1055-1061 [PMID: 25614592 DOI: 10.1099/vir.0.000054]

72 **Péron JM**, Bureau C, Poirson H, Mansuy JM, Alric L, Selves J, Dupuis E, Izopet J, Vinel JP. Fulminant liver failure from acute autochthonous hepatitis E in France: description of seven patients with acute hepatitis E and encephalopathy. *J Viral Hepat* 2007; **14**: 298-303 [PMID: 17439518 DOI: 10.1111/j.1365-2893.2007.00858.x]

73 **Kumar A**, Saraswat VA. Hepatitis E and Acute-on-Chronic Liver Failure. *J Clin Exp Hepatol* 2013; **3**: 225-230 [PMID: 25755504 DOI: 10.1016/j.jceh.2013.08.013]

74 **Blasco-Perrin H**, Madden RG, Stanley A, Crossan C, Hunter JG, Vine L, Lane K, Devooght-Johnson N, Mclaughlin C, Petrik J, Stableforth B, Hussaini H, Phillips M, Mansuy JM, Forrest E, Izopet J, Blatchford O, Scobie L, Peron JM, Dalton HR. Hepatitis E virus in patients with decompensated chronic liver disease: a prospective UK/French study. *Aliment Pharmacol Ther* 2015; **42**: 574-581 [PMID: 26174470 DOI: 10.1111/apt.13309]

75 **Manka P**, Bechmann LP, Coombes JD, Thodou V, Schlattjan M, Kahraman A, Syn WK, Saner F, Gerken G, Baba H, Verheyen J, Timm J, Canbay A. Hepatitis E Virus Infection as a Possible Cause of Acute Liver Failure in Europe. *Clin Gastroenterol Hepatol* 2015; **13**: 1836-1842.e2; quiz e157-158 [PMID: 25912835 DOI: 10.1016/j.cgh.2015.04.014]

76 **Davern TJ**, Chalasani N, Fontana RJ, Hayashi PH, Protiva P, Kleiner DE, Engle RE, Nguyen H, Emerson SU, Purcell RH, Tillmann HL, Gu J, Serrano J, Hoofnagle JH; Drug-Induced Liver Injury Network (DILIN). Acute hepatitis E infection accounts for some cases of suspected drug-induced liver injury. *Gastroenterology* 2011; **141**: 1665-72.e1-9 [PMID: 21855518 DOI: 10.1053/j.gastro.2011.07.051]

77 **Moreau R**, Jalan R, Gines P, Pavesi M, Angeli P, Cordoba J, Durand F, Gustot T, Saliba F, Domenicali M, Gerbes A, Wendon J, Alessandria C, Laleman W, Zeuzem S, Trebicka J, Bernardi M, Arroyo V; CANONIC Study Investigators of the EASL–CLIF Consortium. Acute-on-chronic liver failure is a distinct syndrome that develops in patients with acute decompensation of cirrhosis. *Gastroenterology* 2013; **144**: 1426-1437, 1437.e1-1437.e9 [PMID: 23474284 DOI: 10.1053/j.gastro.2013.02.042]

78 **Kamar N**, Selves J, Mansuy JM, Ouezzani L, Péron JM, Guitard J, Cointault O, Esposito L, Abravanel F,

Danjoux M, Durand D, Vinel JP, Izopet J, Rostaing L. Hepatitis E virus and chronic hepatitis in organ-transplant recipients. *N Engl J Med* 2008; **358**: 811-817 [PMID: 18287603 DOI: 10.1056/NEJMoa0706992]

79 **Geng Y**, Zhang H, Huang W, J Harrison T, Geng K, Li Z, Wang Y. Persistent hepatitis e virus genotype 4 infection in a child with acute lymphoblastic leukemia. *Hepat Mon* 2014; **14**: e15618 [PMID: 24596581 DOI: 10.5812/hepatmon.15618]

80 **Meisner S**, Polywka S, Memmler M, Nashan B, Lohse AW, Sterneck M, Pischke S. Definition of chronic hepatitis E after liver transplant conforms to convention. *Am J Transplant* 2015; **15**: 3011-3012 [PMID: 26288311 DOI: 10.1111/ajt.13428]

81 **Kamar N**, Garrouste C, Haagsma EB, Garrigue V, Pischke S, Chauvet C, Dumortier J, Cannesson A, Cassuto-Viguier E, Thervet E, Conti F, Lebray P, Dalton HR, Santella R, Kanaan N, Essig M, Mousson C, Radenne S, Roque-Afonso AM, Izopet J, Rostaing L. Factors associated with chronic hepatitis in patients with hepatitis E virus infection who have received solid organ transplants. *Gastroenterology* 2011; **140**: 1481-1489 [PMID: 21354150 DOI: 10.1053/j.gastro.2011.02.050]

82 **Gérolami R**, Moal V, Colson P. Chronic hepatitis E with cirrhosis in a kidney-transplant recipient. *N Engl J Med* 2008; **358**: 859-860 [PMID: 18287615 DOI: 10.1056/NEJMc0708687]

83 **Pischke S**, Stiefel P, Franz B, Bremer B, Suneetha PV, Heim A, Ganzenmueller T, Schlue J, Horn-Wichmann R, Raupach R, Darnedde M, Scheibner Y, Taubert R, Haverich A, Manns MP, Wedemeyer H, Bara CL. Chronic hepatitis e in heart transplant recipients. *Am J Transplant* 2012; **12**: 3128-3133 [PMID: 22823202 DOI: 10.1111/j.1600-6143.2012.04200.x]

84 **Kamar N**, Mansuy JM, Cointault O, Selves J, Abravanel F, Danjoux M, Otal P, Esposito L, Durand D, Izopet J, Rostaing L. Hepatitis E virus-related cirrhosis in kidney- and kidney-pancreas-transplant recipients. *Am J Transplant* 2008; **8**: 1744-1748 [PMID: 18557740 DOI: 10.1111/j.1600-6143.2008.02286.x]

85 **Kamar N**, Abravanel F, Selves J, Garrouste C, Esposito L, Lavayssière L, Cointault O, Ribes D, Cardeau I, Nogier MB, Mansuy JM, Muscari F, Peron JM, Izopet J, Rostaing L. Influence of immunosuppressive therapy on the natural history of genotype 3 hepatitis-E virus infection after organ transplantation. *Transplantation* 2010; **89**: 353-360 [PMID: 20145528 DOI: 10.1097/TP.0b013e3181c4096c]

86 **Péron JM**, Mansuy JM, Récher C, Bureau C, Poirson H, Alric L, Izopet J, Vinel JP. Prolonged hepatitis E in an immunocompromised patient. *J Gastroenterol Hepatol* 2006; **21**: 1223-1224 [PMID: 16824086 DOI: 10.1111/j.1440-1746.2006.04209.x]

87 **Tamura A**, Shimizu YK, Tanaka T, Kuroda K, Arakawa Y, Takahashi K, Mishiro S, Shimizu K, Moriyama M. Persistent infection of hepatitis E virus transmitted by blood transfusion in a patient with T-cell lymphoma. *Hepatol Res* 2007; **37**: 113-120 [PMID: 17300706 DOI: 10.1111/j.1872-034X.2007.00024.x]

88 **Alric L**, Bonnet D, Laurent G, Kamar N, Izopet J. Chronic hepatitis E virus infection: successful virologic response to pegylated interferon-alpha therapy. *Ann Intern Med* 2010; **153**: 135-136 [PMID: 20547885 DOI: 10.7326/0003-4819-153-2-201007200-00256]

89 **Colson P**, Kaba M, Moreau J, Brouqui P. Hepatitis E in an HIV-infected patient. *J Clin Virol* 2009; **45**: 269-271 [PMID: 19757504 DOI: 10.1016/j.jcv.2009.06.002]

90 **Kenfak-Foguena A**, Schöni-Affolter F, Bürgisser P, Witteck A, Darling KE, Kovari H, Kaiser L, Evison JM, Elzi L, Gurter-De La Fuente V, Jost J, Moradpour D, Abravanel F, Izpopet J, Cavassini M; Data Center of the Swiss HIV Cohort Study, Lausanne, Switzerland. Hepatitis E Virus seroprevalence and chronic infections in patients with HIV, Switzerland. *Emerg Infect Dis* 2011; **17**: 1074-1078 [PMID: 21749774 DOI: 10.3201/eid/1706.101067]

91 **Pischke S**, Peron JM, von Wulffen M, von Felden J, Höner Zu Siederdissen C, Fournier S, Lütgehetmann M, Iking-Konert C, Bettinger D, Par G, Thimme R, Cantagrel A, Lohse AW, Wedemeyer H, de Man R, Mallet V. Chronic Hepatitis E in Rheumatology and Internal Medicine Patients: A Retrospective Multicenter European Cohort Study. *Viruses* 2019; **11** [PMID: 30813268 DOI: 10.3390/v11020186]

92 **van Doorn PA**, Ruts L, Jacobs BC. Clinical features, pathogenesis, and treatment of Guillain-Barré syndrome. *Lancet Neurol* 2008; **7**: 939-950 [PMID: 18848313 DOI: 10.1016/S1474-4422(08)70215-1]

93 **Dalton HR**, Kamar N, van Eijk JJ, Mclean BN, Cintas P, Bendall RP, Jacobs BC. Hepatitis E virus and neurological injury. *Nat Rev Neurol* 2016; **12**: 77-85 [PMID: 26711839 DOI: 10.1038/nrneurol.2015.234]

94 **Kamar N**, Bendall RP, Peron JM, Cintas P, Prudhomme L, Mansuy JM, Rostaing L, Keane F, Ijaz S, Izopet J, Dalton HR. Hepatitis E virus and neurologic disorders. *Emerg Infect Dis* 2011; **17**: 173-179 [PMID: 21291585 DOI: 10.3201/eid1702.100856]

95 **van den Berg B**, van der Eijk AA, Pas SD, Hunter JG, Madden RG, Tio-Gillen AP, Dalton HR, Jacobs BC. Guillain-Barré syndrome associated with preceding hepatitis E virus infection. *Neurology* 2014; **82**: 491-497 [PMID: 24415572 DOI: 10.1212/WNL.0000000000000111]

96 **Geurtsvankessel CH**, Islam Z, Mohammad QD, Jacobs BC, Endtz HP, Osterhaus AD. Hepatitis E and Guillain-Barre syndrome. *Clin Infect Dis* 2013; **57**: 1369-1370 [PMID: 23899686 DOI: 10.1093/cid/cit512]

97 **Pischke S**, Hartl J, Pas SD, Lohse AW, Jacobs BC, Van der Eijk AA. Hepatitis E virus: Infection beyond the liver? *J Hepatol* 2017; **66**: 1082-1095 [PMID: 27913223 DOI: 10.1016/j.jhep.2016.11.016]

98 **van Eijk JJJ**, Dalton HR, Ripellino P, Madden RG, Jones C, Fritz M, Gobbi C, Melli G, Pasi E, Herrod J, Lissmann RF, Ashraf HH, Abdelrahim M, Masri OABAL, Fraga M, Benninger D, Kuntzer T, Aubert V, Sahli R, Moradpour D, Blasco-Perrin H, Attarian S, Gérolami R, Colson P, Giordani MT, Hartl J, Pischke S, Lin NX, Mclean BN, Bendall RP, Panning M, Peron JM, Kamar N, Izopet J, Jacobs BC, van Alfen N, van Engelen BGM. Clinical phenotype and outcome of hepatitis E virus-associated neuralgic amyotrophy. *Neurology* 2017; **89**: 909-917 [PMID: 28768846 DOI: 10.1212/WNL.0000000000004297]

99 **Drave SA**, Debing Y, Walter S, Todt D, Engelmann M, Friesland M, Wedemeyer H, Neyts J, Behrendt P, Steinmann E. Extra-hepatic replication and infection of hepatitis E virus in neuronal-derived cells. *J Viral Hepat* 2016; **23**: 512-521 [PMID: 26891712 DOI: 10.1111/jvh.12515]

100 **Shi R**, Soomro MH, She R, Yang Y, Wang T, Wu Q, Li H, Hao W. Evidence of Hepatitis E virus breaking through the blood-brain barrier and replicating in the central nervous system. *J Viral Hepat* 2016; **23**: 930-939 [PMID: 27329366 DOI: 10.1111/jvh.12557]

101 **Tian J**, Shi R, Xiao P, Liu T, She R, Wu Q, An J, Hao W, Soomro M. Hepatitis E Virus Induces Brain

Injury Probably Associated With Mitochondrial Apoptosis. *Front Cell Infect Microbiol* 2019; **9**: 433 [PMID: 31921708 DOI: 10.3389/fcimb.2019.00433]

102 **Zamvar V**, McClean P, Odeka E, Richards M, Davison S. Hepatitis E virus infection with nonimmune hemolytic anemia. *J Pediatr Gastroenterol Nutr* 2005; **40**: 223-225 [PMID: 15699702 DOI: 10.1097/00005176-200502000-00027]

103 **Monga A**, Makkar RP, Arora A, Mukhopadhyay S, Gupta AK. Case report: Acute hepatitis E infection with coexistent glucose-6-phosphate dehydrogenase deficiency. *Can J Infect Dis* 2003; **14**: 230-231 [PMID: 18159462 DOI: 10.1155/2003/913679]

104 **Shah SA**, Lal A, Idrees M, Hussain A, Jeet C, Malik FA, Iqbal Z, Rehman Hu. Hepatitis E virus-associated aplastic anaemia: the first case of its kind. *J Clin Virol* 2012; **54**: 96-97 [PMID: 22441030 DOI: 10.1016/j.jcv.2012.02.002]

105 **Mishra A**, Saigal S, Gupta R, Sarin SK. Acute pancreatitis associated with viral hepatitis: a report of six cases with review of literature. *Am J Gastroenterol* 1999; **94**: 2292-2295 [PMID: 10445566 DOI: 10.1111/j.1572-0241.1999.01318.x]

106 **Bazerbachi F**, Haffar S, Garg SK, Lake JR. Extra-hepatic manifestations associated with hepatitis E virus infection: a comprehensive review of the literature. *Gastroenterol Rep (Oxf)* 2016; **4**: 1-15 [PMID: 26358655 DOI: 10.1093/gastro/gov042]

107 **Kamar N**, Weclawiak H, Guilbeau-Frugier C, Legrand-Abravanel F, Cointault O, Ribes D, Esposito L, Cardeau-Desangles I, Guitard J, Sallusto F, Muscari F, Peron JM, Alric L, Izopet J, Rostaing L. Hepatitis E virus and the kidney in solid-organ transplant patients. *Transplantation* 2012; **93**: 617-623 [PMID: 22298032 DOI: 10.1097/TP.0b013e318245f14c]

108 **Guinault D**, Ribes D, Delas A, Milongo D, Abravanel F, Puissant-Lubrano B, Izopet J, Kamar N. Hepatitis E Virus-Induced Cryoglobulinemic Glomerulonephritis in a Nonimmunocompromised Person. *Am J Kidney Dis* 2016; **67**: 660-663 [PMID: 26682764 DOI: 10.1053/j.ajkd.2015.10.022]

109 **Del Bello A**, Guilbeau-Frugier C, Josse AG, Rostaing L, Izopet J, Kamar N. Successful treatment of hepatitis E virus-associated cryoglobulinemic membranoproliferative glomerulonephritis with ribavirin. *Transpl Infect Dis* 2015; **17**: 279-283 [PMID: 25708383 DOI: 10.1111/tid.12353]

110 **Taton B**, Moreau K, Lepreux S, Bachelet T, Trimoulet P, De Ledinghen V, Pommereau A, Ronco P, Kamar N, Merville P, Couzi L. Hepatitis E virus infection as a new probable cause of de novo membranous nephropathy after kidney transplantation. *Transpl Infect Dis* 2013; **15**: E211-E215 [PMID: 24103101 DOI: 10.1111/tid.12143]

111 **Pischke S**, Behrendt P, Manns MP, Wedemeyer H. HEV-associated cryoglobulinaemia and extrahepatic manifestations of hepatitis E. *Lancet Infect Dis* 2014; **14**: 678-679 [PMID: 25056019 DOI: 10.1016/S1473-3099(14)70823-0]

112 **Péron JM**, Dalton H, Izopet J, Kamar N. Acute autochthonous hepatitis E in western patients with underlying chronic liver disease: a role for ribavirin? *J Hepatol* 2011; **54**: 1323-4; author reply 1324-1325 [PMID: 21281681 DOI: 10.1016/j.jhep.2011.01.009]

113 **Pischke S**, Hardtke S, Bode U, Birkner S, Chatzikyrkou C, Kauffmann W, Bara CL, Gottlieb J, Wenzel J, Manns MP, Wedemeyer H. Ribavirin treatment of acute and chronic hepatitis E: a single-centre experience. *Liver Int* 2013; **33**: 722-726 [PMID: 23489973 DOI: 10.1111/liv.12114]

114 **Sinclair SM**, Jones JK, Miller RK, Greene MF, Kwo PY, Maddrey WC. The Ribavirin Pregnancy Registry: An Interim Analysis of Potential Teratogenicity at the Mid-Point of Enrollment. *Drug Saf* 2017; **40**: 1205-1218 [PMID: 28689333 DOI: 10.1007/s40264-017-0566-6]

115 **Kar P**, Sengupta A. A guide to the management of hepatitis E infection during pregnancy. *Expert Rev Gastroenterol Hepatol* 2019; **13**: 205-211 [PMID: 30791760 DOI: 10.1080/17474124.2019.1568869]

116 **Zhou X**, Wang Y, Metselaar HJ, Janssen HL, Peppelenbosch MP, Pan Q. Rapamycin and everolimus facilitate hepatitis E virus replication: revealing a basal defense mechanism of PI3K-PKB-mTOR pathway. *J Hepatol* 2014; **61**: 746-754 [PMID: 24859454 DOI: 10.1016/j.jhep.2014.05.026]

117 **Wang Y**, Zhou X, Debing Y, Chen K, Van Der Laan LJ, Neyts J, Janssen HL, Metselaar HJ, Peppelenbosch MP, Pan Q. Calcineurin inhibitors stimulate and mycophenolic acid inhibits replication of hepatitis E virus. *Gastroenterology* 2014; **146**: 1775-1783 [PMID: 24582714 DOI: 10.1053/j.gastro.2014.02.036]

118 **Kamar N**, Rostaing L, Abravanel F, Garrouste C, Esposito L, Cardeau-Desangles I, Mansuy JM, Selves J, Peron JM, Otal P, Muscari F, Izopet J. Pegylated interferon-alpha for treating chronic hepatitis E virus infection after liver transplantation. *Clin Infect Dis* 2010; **50**: e30-e33 [PMID: 20113176 DOI: 10.1086/650488]

119 **Haagsma EB**, Riezebos-Brilman A, van den Berg AP, Porte RJ, Niesters HG. Treatment of chronic hepatitis E in liver transplant recipients with pegylated interferon alpha-2b. *Liver Transpl* 2010; **16**: 474-477 [PMID: 20373458 DOI: 10.1002/lt.22014]

120 **Rostaing L**, Izopet J, Baron E, Duffaut M, Puel J, Durand D. Treatment of chronic hepatitis C with recombinant interferon alpha in kidney transplant recipients. *Transplantation* 1995; **59**: 1426-1431 [PMID: 7770930 DOI: 10.1097/00007890-199505270-00012]

121 **Kamar N**, Izopet J, Tripon S, Bismuth M, Hillaire S, Dumortier J, Radenne S, Coilly A, Garrigue V, D'Alteroche L, Buchler M, Couzi L, Lebray P, Dharancy S, Minello A, Hourmant M, Roque-Afonso AM, Abravanel F, Pol S, Rostaing L, Mallet V. Ribavirin for chronic hepatitis E virus infection in transplant recipients. *N Engl J Med* 2014; **370**: 1111-1120 [PMID: 24645943 DOI: 10.1056/NEJMoa1215246]

122 **Kamar N**, Abravanel F, Behrendt P, Hofmann J, Pageaux GP, Barbet C, Moal V, Couzi L, Horvatits T, De Man RA, Cassuto E, Elsharkawy AM, Riezebos-Brilman A, Scemla A, Hillaire S, Donnelly MC, Radenne S, Sayegh J, Garrouste C, Dumortier J, Glowaki F, Matignon M, Coilly A, Figueres L, Mousson C, Minello A, Dharancy S, Rerolle JP, Lebray P, Etienne I, Perrin P, Choi M, Marion O, Izopet J; Hepatitis E Virus Ribavirin Study Group. Ribavirin for Hepatitis E Virus Infection After Organ Transplantation: A Large European Retrospective Multicenter Study. *Clin Infect Dis* 2020; **71**: 1204-1211 [PMID: 31793638 DOI: 10.1093/cid/ciz953]

123 **Abravanel F**, Lhomme S, Rostaing L, Kamar N, Izopet J. Protracted fecal shedding of HEV during ribavirin therapy predicts treatment relapse. *Clin Infect Dis* 2015; **60**: 96-99 [PMID: 25249523 DOI:

10.1093/cid/ciu742]
124 **Kamar N**, Lhomme S, Abravanel F, Cointault O, Esposito L, Cardeau-Desangles I, Del Bello A, Dörr G, Lavayssière L, Nogier MB, Guitard J, Ribes D, Goin AL, Broué P, Metsu D, Sauné K, Rostaing L, Izopet J. An Early Viral Response Predicts the Virological Response to Ribavirin in Hepatitis E Virus Organ Transplant Patients. *Transplantation* 2015; **99**: 2124-2131 [PMID: 26214817 DOI: 10.1097/TP.0000000000000850]
125 **Alric L**, Bonnet D, Beynes-Rauzy O, Izopet J, Kamar N. Definitive clearance of a chronic hepatitis E virus infection with ribavirin treatment. *Am J Gastroenterol* 2011; **106**: 1562-1563 [PMID: 21811285 DOI: 10.1038/ajg.2011.158]
126 **Neukam K**, Barreiro P, Macías J, Avellón A, Cifuentes C, Martín-Carbonero L, Echevarría JM, Vargas J, Soriano V, Pineda JA. Chronic hepatitis E in HIV patients: rapid progression to cirrhosis and response to oral ribavirin. *Clin Infect Dis* 2013; **57**: 465-468 [PMID: 23575198 DOI: 10.1093/cid/cit224]
127 **Hajji H**, Gérolami R, Solas C, Moreau J, Colson P. Chronic hepatitis E resolution in a human immunodeficiency virus (HIV)-infected patient treated with ribavirin. *Int J Antimicrob Agents* 2013; **41**: 595-597 [PMID: 23507411 DOI: 10.1016/j.ijantimicag.2013.02.005]
128 **Tavitian S**, Peron JM, Huguet F, Kamar N, Abravanel F, Beyne-Rauzy O, Oberic L, Faguer S, Alric L, Roussel M, Gaudin C, Ysebaert L, Huynh A, Recher C. Ribavirin for Chronic Hepatitis Prevention among Patients with Hematologic Malignancies. *Emerg Infect Dis* 2015; **21**: 1466-1469 [PMID: 26197210 DOI: 10.3201/eid2108.150199]
129 **Debing Y**, Emerson SU, Wang Y, Pan Q, Balzarini J, Dallmeier K, Neyts J. Ribavirin inhibits *in vitro* hepatitis E virus replication through depletion of cellular GTP pools and is moderately synergistic with alpha interferon. *Antimicrob Agents Chemother* 2014; **58**: 267-273 [PMID: 24145541 DOI: 10.1128/AAC.01795-13]
130 **Debing Y**, Gisa A, Dallmeier K, Pischke S, Bremer B, Manns M, Wedemeyer H, Suneetha PV, Neyts J. A mutation in the hepatitis E virus RNA polymerase promotes its replication and associates with ribavirin treatment failure in organ transplant recipients. *Gastroenterology* 2014; **147**: 1008-11.e7; quiz e15-16 [PMID: 25181691 DOI: 10.1053/j.gastro.2014.08.040]
131 **Debing Y**, Ramière C, Dallmeier K, Piorkowski G, Trabaud MA, Lebossé F, Scholtès C, Roche M, Legras-Lachuer C, de Lamballerie X, André P, Neyts J. Hepatitis E virus mutations associated with ribavirin treatment failure result in altered viral fitness and ribavirin sensitivity. *J Hepatol* 2016; **65**: 499-508 [PMID: 27174035 DOI: 10.1016/j.jhep.2016.05.002]
132 **Galante A**, Pischke S, Polywka S, Luetgehethmann M, Suneetha PV, Gisa A, Hiller J, Dienes HP, Nashan B, Lohse AW, Sterneck M. Relevance of chronic hepatitis E in liver transplant recipients: a real-life setting. *Transpl Infect Dis* 2015; **17**: 617-622 [PMID: 26094550 DOI: 10.1111/tid.12411]
133 **Todt D**, Gisa A, Radonic A, Nitsche A, Behrendt P, Suneetha PV, Pischke S, Bremer B, Brown RJ, Manns MP, Cornberg M, Bock CT, Steinmann E, Wedemeyer H. In vivo evidence for ribavirin-induced mutagenesis of the hepatitis E virus genome. *Gut* 2016; **65**: 1733-1743 [PMID: 27222534 DOI: 10.1136/gutjnl-2015-311000]
134 **Kamar N**, Chatelut E, Manolis E, Lafont T, Izopet J, Rostaing L. Ribavirin pharmacokinetics in renal and liver transplant patients: evidence that it depends on renal function. *Am J Kidney Dis* 2004; **43**: 140-146 [PMID: 14712437 DOI: 10.1053/j.ajkd.2003.09.019]
135 **Dao Thi VL**, Debing Y, Wu X, Rice CM, Neyts J, Moradpour D, Gouttenoire J. Sofosbuvir Inhibits Hepatitis E Virus Replication In Vitro and Results in an Additive Effect When Combined With Ribavirin. *Gastroenterology* 2016; **150**: 82-85.e4 [PMID: 26408347 DOI: 10.1053/j.gastro.2015.09.011]
136 **Horvatits T**, Schulze Zur Wiesch J, Lütgehetmann M, Lohse AW, Pischke S. The Clinical Perspective on Hepatitis E. *Viruses* 2019; **11** [PMID: 31284447 DOI: 10.3390/v11070617]
137 **Biliotti E**, Franchi C, Spaziante M, Garbuglia AR, Volpicelli L, Palazzo D, De Angelis M, Esvan R, Taliani G. Autochthonous acute hepatitis E: treatment with sofosbuvir and ribavirin. *Infection* 2018; **46**: 725-727 [PMID: 29946850 DOI: 10.1007/s15010-018-1168-7]
138 **Drinane M**, Jing Wang X, Watt K. Sofosbuvir and Ribavirin Eradication of Refractory Hepatitis E in an Immunosuppressed Kidney Transplant Recipient. *Hepatology* 2019; **69**: 2297-2299 [PMID: 30549275 DOI: 10.1002/hep.30428]
139 **Donnelly MC**, Imlach SN, Abravanel F, Ramalingam S, Johannessen I, Petrik J, Fraser AR, Campbell JD, Bramley P, Dalton HR, Hayes PC, Kamar N, Simpson KJ. Sofosbuvir and Daclatasvir Anti-Viral Therapy Fails to Clear HEV Viremia and Restore Reactive T Cells in a HEV/HCV Co-Infected Liver Transplant Recipient. *Gastroenterology* 2017; **152**: 300-301 [PMID: 27883881 DOI: 10.1053/j.gastro.2016.05.060]
140 **Todesco E**, Demeret S, Calin R, Roque-Afonso AM, Thibault V, Mallet V, Akhavan S, Jaspard M, Peytavin G, Poynard T, Katlama C, Pourcher V. Chronic hepatitis E in HIV/HBV coinfected patient: lack of power of sofosbuvir-ribavirin. *AIDS* 2017; **31**: 1346-1348 [PMID: 28492398 DOI: 10.1097/QAD.0000000000001474]
141 **van der Valk M**, Zaaijer HL, Kater AP, Schinkel J. Sofosbuvir shows antiviral activity in a patient with chronic hepatitis E virus infection. *J Hepatol* 2017; **66**: 242-243 [PMID: 27702641 DOI: 10.1016/j.jhep.2016.09.014]
142 **Schulz M**, Papp CP, Bock CT, Hofmann J, Gerlach UA, Maurer MM, Eurich D, Mueller T. Combination therapy of sofosbuvir and ribavirin fails to clear chronic hepatitis E infection in a multivisceral transplanted patient. *J Hepatol* 2019; **71**: 225-227 [PMID: 31027993 DOI: 10.1016/j.jhep.2019.03.029]
143 **Nishiyama T**, Kobayashi T, Jirintai S, Nagashima S, Primadharsini PP, Nishizawa T, Okamoto H. Antiviral candidates against the hepatitis E virus (HEV) and their combinations inhibit HEV growth in in vitro. *Antiviral Res* 2019; **170**: 104570 [PMID: 31362004 DOI: 10.1016/j.antiviral.2019.104570]
144 **Horvatits T**, Schübel N, Kamar N, Polywka S, Lütgehetmann M, Rutter K, zur Wiesch JS, Manns MP, Lohse A, Roque-Afonso AM, Pischke S, Behrendt P, Mallet V. SAT-208-Zinc/Ribavirin: A possible treatment option in chronically HEV genotype 3 infected patients without SVR under ribavirin monotherapy. *J Hepatol* 2019; **70** Suppl: e721-e722 [DOI: 10.1016/S0618-8278(19)31442-2]
145 **Marion O**, Abravanel F, Izopet J, Kamar N. Failure to respond to ribavirin despite elevated intra-erythrocyte zinc level in transplant-patients with chronic hepatitis E virus infection. *Transpl Infect Dis*

2019; **21**: e13050 [PMID: 30663838 DOI: 10.1111/tid.13050]

146 **Todt D**, Moeller N, Praditya D, Kinast V, Friesland M, Engelmann M, Verhoye L, Sayed IM, Behrendt P, Dao Thi VL, Meuleman P, Steinmann E. The natural compound silvestrol inhibits hepatitis E virus (HEV) replication *in vitro* and in vivo. *Antiviral Res* 2018; **157**: 151-158 [PMID: 30036559 DOI: 10.1016/j.antiviral.2018.07.010]

147 **Netzler NE**, Enosi Tuipulotu D, Vasudevan SG, Mackenzie JM, White PA. Antiviral Candidates for Treating Hepatitis E Virus Infection. *Antimicrob Agents Chemother* 2019; **63** [PMID: 30885901 DOI: 10.1128/AAC.00003-19]

148 **Zhu FC**, Zhang J, Zhang XF, Zhou C, Wang ZZ, Huang SJ, Wang H, Yang CL, Jiang HM, Cai JP, Wang YJ, Ai X, Hu YM, Tang Q, Yao X, Yan Q, Xian YL, Wu T, Li YM, Miao J, Ng MH, Shih JW, Xia NS. Efficacy and safety of a recombinant hepatitis E vaccine in healthy adults: a large-scale, randomised, double-blind placebo-controlled, phase 3 trial. *Lancet* 2010; **376**: 895-902 [PMID: 20728932 DOI: 10.1016/S0140-6736(10)61030-6]

World Journal of Gastroenterology

Submit a Manuscript: https://www.f6publishing.com

World J Gastroenterol 2020 October 7; 26(37): 5561-5596

DOI: 10.3748/wjg.v26.i37.5561

ISSN 1007-9327 (print) ISSN 2219-2840 (online)

REVIEW

Transjugular intrahepatic portosystemic shunt in cirrhosis: An exhaustive critical update

Sasidharan Rajesh, Tom George, Cyriac Abby Philips, Rizwan Ahamed, Sandeep Kumbar, Narain Mohan, Meera Mohanan, Philip Augustine

ORCID number: Sasidharan Rajesh 0000-0002-3293-1817; Tom George 0000-0002-3515-6457; Cyriac Abby Philips 0000-0002-9587-336X; Rizwan Ahamed 0000-0003-4747-6359; Sandeep Kumbar 0000-0001-9701-9960; Narain Mohan 0000-0002-5412-9753; Meera Mohanan 0000-0002-8752-4530; Philip Augustine 0000-0003-0787-0984.

Author contributions: Rajesh S designed the study and wrote manuscript and was involved in revision, editing and review; George T was involved in writing, editing and reformatting of the manuscript; Philips CA was involved in the writing, revision and editing of the manuscript; Ahamed R was involved in the review and editing of the manuscript; Kumbar S was involved in the editing and review of the manuscript; Mohan N was involved in the editing and review of the manuscript; Mohanan M was involved in the editing and review of the manuscript; Augustine P was involved in the editing and review of the manuscript; all authors read and approved the final manuscript.

Conflict-of-interest statement: None to declare.

Sasidharan Rajesh, Tom George, Division of Hepatobiliary Interventional Radiology, Cochin Gastroenterology Group, Ernakulam Medical Center, Kochi 682028, Kerala, India

Cyriac Abby Philips, Narain Mohan, The Liver Unit and Monarch Liver Lab, Cochin Gastroenterology Group, Ernakulam Medical Center, Kochi 682028, Kerala, India

Rizwan Ahamed, Sandeep Kumbar, Philip Augustine, Gastroenterology and Advanced GI Endoscopy, Cochin Gastroenterology Group, Ernakulam Medical Center, Kochi 682028, Kerala, India

Meera Mohanan, Anesthesia and Critical Care, Cochin Gastroenterology Group, Ernakulam Medical Center, Kochi 682028, Kerala, India

Corresponding author: Cyriac Abby Philips, MBBS, MD, DM, Consultant Physician-Scientist, The Liver Unit and Monarch Liver Lab, Cochin Gastroenterology Group, Ernakulam Medical Center, NH-Bypass, Palarivattom, Kochi 682028, Kerala, India. abbyphilips@gmail.com

Abstract

More than five decades after it was originally conceptualized as rescue therapy for patients with intractable variceal bleeding, the transjugular intrahepatic portosystemic shunt (TIPS) procedure continues to remain a focus of intense clinical and biomedical research. By the impressive reduction in portal pressure achieved by this intervention, coupled with its minimally invasive nature, TIPS has gained increasing acceptance in the treatment of complications of portal hypertension. The early years of TIPS were plagued by poor long-term patency of the stents and increased incidence of hepatic encephalopathy. Moreover, the diversion of portal flow after placement of TIPS often resulted in derangement of hepatic functions, which was occasionally severe. While the incidence of shunt dysfunction has markedly reduced with the advent of covered stents, hepatic encephalopathy and instances of early liver failure continue to remain a significant issue after TIPS. It has emerged over the years that careful selection of patients and diligent post-procedural care is of paramount importance to optimize the outcome after TIPS. The past twenty years have seen multiple studies redefining the role of TIPS in the management of variceal bleeding and refractory ascites while exploring its application in other complications of cirrhosis like hepatic hydrothorax, portal hypertensive gastropathy, ectopic varices, hepatorenal and hepatopulmonary syndromes, non-tumoral portal vein

Manuscript source: Invited manuscript

Received: June 5, 2020
Peer-review started: June 5, 2020
First decision: July 25, 2020
Revised: July 31, 2020
Accepted: August 29, 2020
Article in press: August 29, 2020
Published online: October 7, 2020

P-Reviewer: Chen Z, Jamali R, Schoenhagen P
S-Editor: Gao CC
L-Editor: A
P-Editor: Ma YJ

thrombosis and chylous ascites. It has also been utilized to good effect before extrahepatic abdominal surgery to reduce perioperative morbidity and mortality. The current article aims to review the updated literature on the status of TIPS in the management of patients with liver cirrhosis.

Key Words: Early transjugular portosystemic shunt; Preemptive transjugular intrahepatic portosystemic shunt; Portal hypertension; Esophageal varices; Gastric varices; Refractory ascites

Core Tip: Covered transjugular intrahepatic portosystemic shunt has proven effective in ameliorating the symptoms associated with cirrhosis and portal hypertension in a subset of patients. However, hepatic encephalopathy (HE) and deterioration of liver function remain a concern. The meticulous selection of patients is the most fruitful measure to improve patient outcomes. While patients having preserved hepatic and renal functions and without any prior history of, HE and cardiopulmonary disease are ideal candidates, patients with high liver disease severity scores, poor cardiac reserve, and risk of HE should be considered for transjugular intrahepatic portosystemic shunt only as a last resort or a bridge to transplant. With the advent of controlled expansion stent, and improvements in patient selection criteria, the incidence of HE and early liver failure is expected to reduce further.

Citation: Rajesh S, George T, Philips CA, Ahamed R, Kumbar S, Mohan N, Mohanan M, Augustine P. Transjugular intrahepatic portosystemic shunt in cirrhosis: An exhaustive critical update. *World J Gastroenterol* 2020; 26(37): 5561-5596
URL: https://www.wjgnet.com/1007-9327/full/v26/i37/5561.htm
DOI: https://dx.doi.org/10.3748/wjg.v26.i37.5561

INTRODUCTION

Portal hypertension (PH) is the primary vascular consequence of cirrhosis and responsible for the majority of its potentially life-threatening complications. Transjugular intrahepatic portosystemic shunt (TIPS), involving the creation of a side-to-side shunt between the portal and hepatic vein, was envisaged as a salvage therapy for patients with acute variceal hemorrhage (VH) not responding to standard medical care[1]. With the discovery of self-expandable metal stents, TIPS started gaining wider acceptance not only for managing episodes of acute VH but also in other complications of PH like refractory ascites (RA) and hepatic hydrothorax (HH)[2]. The diversion of portal flow, so effectively achieved by TIPS, also resulted in hepatic hypoperfusion resulting in hepatic encephalopathy (HE) and deterioration in liver functions. Moreover, the uncovered self-expandable metal stents used in the initial years of TIPS were notorious for early thrombosis due to leakage of bile into the stent within the hepatic parenchymal tract and pseudointimal hyperplasia at the hepatic venous end of the stent. This resulted in frequent shunt dysfunctions necessitating multiple re-interventions. With the advent of expanded-polytetrafluoroethylene (e-PTFE) covered stents for TIPS in 2004, the incidence of shunt dysfunction reduced markedly. Additional studies showed that the use of covered stents for TIPS may not increase episodes of de novo or worsening HE, although this issue is still debatable[3]. Liver failure after TIPS continues to remain an area of concern. Appropriate patient selection for TIPS plays a major role in clinical outcomes. Significant modifications in patient selection criteria for TIPS have occurred in the recent past. The role of TIPS in management of other complications of cirrhosis and PH such as HH, portal hypertensive gastropathy (PHG), ectopic varices, hepatorenal syndrome (HRS) and hepatopulmonary syndrome (HPS), non-tumoral portal vein thrombosis (PVT) and chylous ascites has also been explored. With the introduction of the novel controlled-expansion stent, options for modulation of the portosystemic gradient (PSPG) after placement of TIPS stent has evolved. Recent studies have demonstrated a reduction in the incidence of HE, stent dysfunction, readmission for sepsis, and ascites with the use of these stents[4,5]. In this review, we present an exhaustive update of current literature

on the role of TIPS in the management of PH in patients with cirrhosis with emphasis on emerging indications of TIPS, evolving patient selection criteria, and technical aspects of the procedure.

ESTABLISHED AND EMERGING INDICATIONS FOR TIPS

Acute esophageal VH

VH is one of the most severe and life-threatening complications in cirrhosis patients and constitutes the second most frequent decompensating event after ascites[6]. About 10%-15% of patients experience treatment failure, warranting repeated endoscopic interventions, with up to 80% mortality[6,7]. The overall mortality at 6 wk with each episode of VH also remains high at around 15%-25%, despite improvements in therapy[8,9].

Rescue TIPS and the role of early/preemptive TIPS: TIPS is highly effective in reducing the portal pressure, control of bleed, and prevention of early rebleeding. Due to the increased risk of HE and the absence of survival benefit with the use of uncovered stents, TIPS was traditionally recommended as rescue therapy for uncontrolled bleeding. The prognosis of patients undergoing rescue (or salvage) TIPS is dismal, with 35%-55% mortality due to failure to control bleeding or early rebleeding. The time-delay associated with the decision on performing TIPS also contributes to poor outcome[7,10,11]. A recent large observational study showed a 6-wk mortality of 36% in patients undergoing rescue TIPS[11]. The model for end-stage liver disease (MELD) and Child–Turcotte-Pugh (CTP) scores were predictive of short- and long-term mortality, respectively, and pre-TIPS intensive care unit stay was independently associated with TIPS failure and mortality at 6 wk and 12 mo. Rescue TIPS was found futile in patients with CTP score > 13. With the advent of e-PTFE–covered stents, the incidence of TIPS dysfunction and recurrence of complications related to PH reduced drastically. Additionally, it was found that covered TIPS did not significantly increase the frequency and severity of episodes of de-novo HE[3]. Hepatic venous pressure gradient (HVPG), the surrogate marker of portal pressure, is an objective and reproducible measurement. Moitinho *et al*[12] found that measurement of HVPG in patients with cirrhosis admitted with acute VH provided useful prognostic information, and those with HVPG > 20 mmHg required closer surveillance. Monescillo and colleagues showed that early portal decompression by TIPS placement in those with HVPG > 20 mmHg significantly reduced the risk of treatment failure, prevented recurrent VH, and improved short and long-term survival despite having higher baseline bilirubin levels[13]. HVPG was found more accurate than the CTP score for 6 wk survival prediction. This study, however, used endoscopic sclerotherapy in the medical treatment group, and bare stents were used in the early-TIPS group, both of which are not the current standard of care.

To address these issues, a multicentre randomized controlled trial (RCT) was conducted in which patient selection was based on clinical and endoscopic criteria[3]. In this study, early treatment with covered TIPS (within 72 h, and preferably within 24 h) in high-risk patients-defined as CTP score 10-13 points and CTP class B with active bleeding at endoscopy-resulted in significant bleed control and reduction in mortality, without an increase in the risk of HE. Additionally, the study found lower rates of ascites formation, HRS, and reduced hospital stay. A retrospective post-RCT surveillance study by the same group found only a trend to improvement in survival when compared with standard medical therapy[14]. The Baveno VI consensus endorsed these findings and recommended that "an early TIPS within 72 h (ideally < 24 h) should be considered in patients at high risk of treatment failure after initial pharmacological and endoscopic therapy"[15].

Further, a meta-analysis confirmed the survival benefit offered by early TIPS in high-risk patients[16]. The original trial by Garcia-Pagan *et al*[3] was not powered to conduct appropriate subgroup analyses to identify benefits on survival between CTP B and C groups. Studies conducted later showed that clinical outcomes among CTP B patients on standard medical treatment were significantly better than that of Child-Pugh C patients without added benefits with early-TIPS[17]. The re-calibrated MELD score as an alternative to the CTP score was shown to have better prognostic value in patients with acute VH on standard care[18]. CTP C patients with a baseline creatinine ≥ 1 mg/dL (Child C-C1 criteria) were found to have high-risk of death after VH[17]. A recent multicentre study showed that the mortality risk among CTP B compared to CTP class C patients with active bleeding at endoscopy, on the standard of care was

lower[17]. The study also identified MELD score ≥ 19 as a high risk for death with standard care alone. This implied that the grouping of Child-Pugh B and Child-Pugh C as high-risk for mortality on standard therapy of acute VH was inaccurate. Subsequently, observational studies showed that the early use of TIPS was justified in those with MELD ≥ 19 or Child-Pugh class C[19]. For patients with MELD 12–18 or Child-Pugh B patients, survival benefit could not be uniformly demonstrated.

An RCT from a single center in China reported improved control of bleeding and rebleeding and better transplant-free survival (TFS) at 6 wk and one year with early TIPS[20]. The benefit was seen in all groups regardless of active bleeding or stage of liver disease. There was no difference in the incidence of HE. Besides, the actuarial probability of remaining free from new or worsening ascites was higher in the early TIPS group than in the control group at one year. A slight increase of median bilirubin levels and the international normalized ratio at 1 and 3 mo was observed in the early-TIPS group, which improved after 6 mo. Similarly, median MELD scores were significantly higher at 1 and 3 mo in the TIPS group disappearing after 6 mo. Notably, all patients with Child-Pugh class B and class C disease were included irrespective of active bleeding, and 75% had a chronic hepatitis-B infection. Therefore, antiviral therapy could have influenced the outcome. Another recent RCT from the United Kingdom reported that early-TIPS reduced rebleeding without survival benefit and higher incidence of HE in those undergoing early TIPS[21]. However, out of the 29 patients enrolled in the TIPS-arm of this study, only 13 underwent TIPS stent placement within 72 h of index bleeding, making it underpowered to derive any conclusions. Despite the contradictory results shown by these two recent RCTs, there is enough evidence now (Table 1) to recommend early TIPS in patients with Child-Pugh class C disease and MELD > 19; however, the upper limit of MELD requires confirmation. Even though the question of survival benefit in patients with Child-Pugh class B and MELD score of 12-18 remains open to debate, the reduction in rebleeding and ascites, without increasing the risk or severity of HE could also justify the use of early TIPS in this subgroup of patients. In keeping with this, the British society of interventional radiology and British association of the study of the liver recommends that "in patients who have Child's C disease (C 10-13) or MELD ≥ 19, and bleeding from esophageal varices (EV) or GOV1 and GOV2 gastric varices (GV) and are hemodynamically stable, early or pre-emptive TIPS should be considered within 72 h of a variceal bleed where local resources allow"[22]. Despite these recommendations, the rate of implementation of early TIPS in a real-world situation is dismal, with only 6%-13% of eligible candidates undergoing the procedure according to two recent large multicentre observational studies[23,24].

Secondary prophylaxis of variceal bleeding: Patients who survive an episode of acute VH are at high risk of rebleeding and death. The 1-year rate of recurrent VH is approximately 60% in patients without treatment, with a mortality rate approaching 30%[25]. It is recommended that endoscopic band ligation (EBL), in combination with non-selective beta-blockers (NSBB), be the first line of therapy for the prevention of recurrent VH with reservation of TIPS only for non-responders[15,22]. In this regard, two RCTs compared covered stents with EBL[26,27]. TIPS significantly reduced VH without any remarkable effect on overall survival. In one study, 8 mm stents were used, leading to a comparatively lower rate of HE[26]. However, in the other trial using 10 mm stents, although early HE (within one year) was significantly more frequent in the TIPS group (35% *vs* 14%), during long-term follow-up, this difference disappeared[27]. In the previous study, there was no difference in rebleeding or mortality rates beyond 6 wk. Two RCTs conducted later comparing TIPS with EBL plus NSBB in patients with PVT found no increase in the rates of HE in the two groups[28,29]. The absence of survival benefit offered by TIPS in this clinical setting when compared to early TIPS can be explained by the fact that liver failure and infection were the most common cause of death of patients in studies for secondary prevention of variceal bleeding. Contrarily, in the studies on the role of early TIPS, the most common cause of death was early rebleeding, which can be effectively controlled by TIPS, thus conferring survival benefit. A recent study, published in abstract form, demonstrated that TIPS performed at first symptomatic portal hypertension related decompensation (VH or ascites requiring paracentesis) event termed 'anticipant TIPS' improved overall survival even on sub-group analysis for VH. On further grouping, based on CTP and MELD scores, a higher proportion of patients survived after anticipant-TIPS for all-causes at 1 year. Compared to standard treatment, those undergoing anticipant TIPS had significantly lesser sepsis events and hospitalization and recurrence of varices at one year, even though overall and grouped survival outcomes and were similar[30]. TIPS is not indicated for the prevention of varices (pre-primary prophylaxis) or

Table 1 Summary of the randomised controlled trials on early (preemptive) transjugular intrahepatic portosystemic shunt

Ref.	No. of pts (TIPS/control)	Primary inclusion criteria	Primary and secondary end-points	Rebleeding (%; TIPS/control)	1-yr survival (%; TIPS/control)	HE (%; TIPS/control)
Monescillo *et al*[13]	26/26	HVPG > 20 mmHg	Primary: sensivity and specificity of HVPG cutoff value (20 mmHg) in predicting TFS, and assessment of TFS as well as short- and long-term survival; secondary: transfusional needs, ICU stay, complications during the first week of treatment, and causes of death	12/50	62/35	31/35
Garcia-Pagán *et al*[14]	32/31	Child–Pugh class C disease (a score of 10 to 13) or class B disease but with active bleeding at diagnostic endoscopy	Primary: failure to control bleeding and failure to prevent clinically significant variceal rebleeding within 1 yr; secondary: mortality at 6 wk and at 1 yr, failure to control acute bleeding, early rebleeding, rate of rebleeding between 6 wk and 1 yr, other complications of portal hypertension, the number of days in the ICU, days spent in the hospital, and the use of alternative treatments	3/50	86/61	25/39
Lv *et al*[20]	84/45	Child–Pugh class C disease (a score of 10 to 13) or class B disease (with or without active bleeding at diagnostic endoscopy)	Primary: TFS; secondary: failure to control bleeding or rebleeding, new or worsening ascites, overt HE, and other complications of portal hypertension	11/34	62/35	35/36
Dunne *et al*[21]	29/29	Child–Pugh class C disease (a score of 10 to 13) or class B disease (with or without active bleeding at diagnostic endoscopy); inability to control bleeding at index endoscopy was considered an exclusion criteria	Primary: 1-yr survival; secondary: survival at 6 wk, early rebleeding (within 6 wk) and late rebleeding (between 6 wk and 1 yr), and the development of HE	24/34	79/76	41/17

HVPG: Hepatic venous pressure gradient; TFS: Transplant free survival; ICU: Intensive care unit; HE: Hepatic encephalopathy.

prevention of the first episode of bleeding from varices (primary prophylaxis), since the risks associated with TIPS, clearly outweighs the potential benefits in this group. Based on the current evidence, it may be appropriate to stratify the patients with cirrhosis with index VH into a "high-risk" and "low-risk" group based on their CTP score and endoscopic findings (Figure 1).

Gastric VH

GV are seen in 5%-33% of patients with cirrhosis and PH[31]. Although they bleed less often than EV-accounting for only 10%-30% episodes of VH–the bleeding is often severe with higher transfusion requirements[31]. GV is frequently associated with large gastrorenal shunts (GRS) and have a "downhill" drainage as opposed to "uphill" drainage of EV *via* azygos-hemiazygos venous system[32]. GVs exist as "low pressure, high volume" channels, and can bleed at lower portal pressures than EVs[33,22]. Between 10%-16% of GV can bleed at PSPG < 12 mmHg[33]. Thus, the management of GV hemorrhage (GVH) requires a different therapeutic approach compared to EV.

Recently, endosonographic coiling and glue have shown promising results in the management of GV but may not suffice for those associated with large portosystemic shunts[34]. Significantly more failure to control bleeding, early rebleeding, and recurrent bleeding were notable in GOV2 and IGV1 related bleeds, with mortality rates reaching

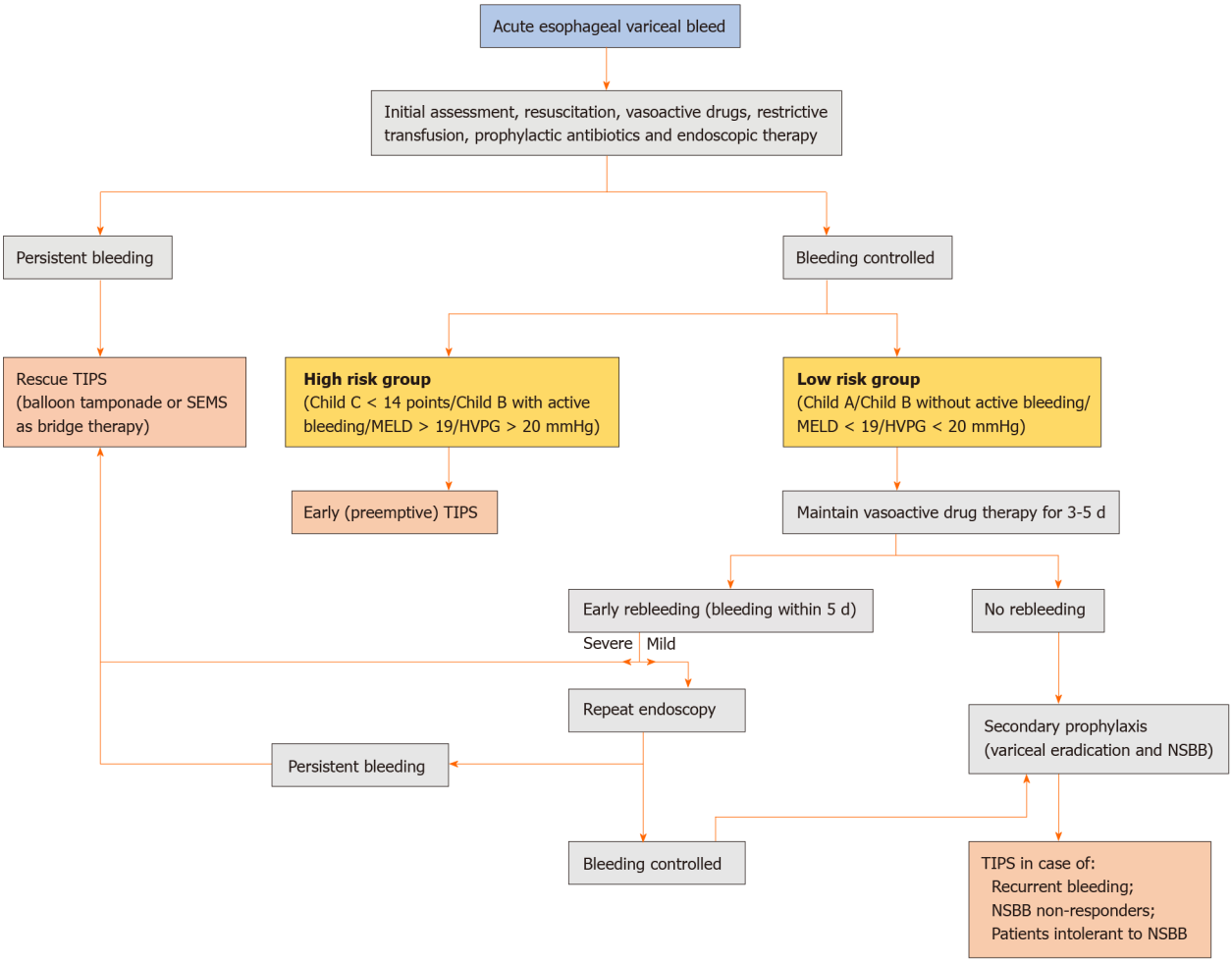

Figure 1 Proposed algorithm for the management of index acute esophageal variceal hemorrhage. Mild rebleeding is defined as clinical symptoms of bleeding only while severe rebleeding is bleeding associated with hemodynamic compromise or requirement of blood transfusion. TIPS: Transjugular intrahepatic portosystemic shunt; SEMS: Self-expandable metal stents; MELD: Model for end-stage liver disease; HVPG: Hepatic venous pressure gradient; NSBB: Non-selective beta-blockers.

up to 20%[35]. For cases unresponsive to pharmacological and endoscopic management, percutaneous endovascular therapy is indicated. Although TIPS can establish initial hemostasis in up to 90% of cases of acute GVH, it has not proven to be as efficacious as in EV hemorrhage[22,33,35]. Indeed, multiple studies have shown that GV can persist and rebleed (incidence of 25%-30%) after successful TIPS placement[35]. Other explanations proposed for the suboptimal efficacy of TIPS in controlling GVH are the "proximity", "throughput", and "recruitment" theories[35-37]. The 'proximity theory' suggests that since GV (supplied more commonly by posterior and short gastric veins) are anatomically farther away from the TIPS shunt, they are less likely to be decompressed as compared to EV (supplied predominantly by left gastric vein). The "throughput theory" states that large GRS associated with GV can compete with the TIPS stent and may lead to early TIPS dysfunction. The "recruitment theory" describes the development of new feeders after the proximal embolization of a GV complex. These factors have led to the development of obliterative therapies, like balloon-occluded retrograde transvenous obliteration (B-RTO), in the management of GV. B-RTO and its other variants, like coil-assisted retrograde transvenous obliteration, plug-assisted retrograde transvenous obliteration, and balloon-assisted antegrade occlusion, have emerged as a popular method for treatment of GV. The goal of these therapies is to trap sclerosant within the gastric variceal complex by controlling both inflow and the outflow using balloon, coils, or plug. Since its introduction, multiple studies and meta-analyses have reported technical and clinical success rates over 95% for B-RTO[38-40]. Also, GV rebleed rates of patients who had undergone a successful B-RTO procedure range between 0-20%[38-40]. Notably, compared to TIPS, these shunt occlusion therapies divert blood towards the liver and have shown to preserve or improve the liver

functions in the first 6-9 mo[40,41].

Additionally, B-RTO is a proven therapy for patients with severe recurrent shunt-related HE, unresponsive to medical therapy[40,42]. Thus, patients with spontaneous portosystemic shunts, who are at high risk of developing HE after TIPS can safely undergo B-RTO. However, occlusion of GRS can also aggravate the PH. Long term follow-up of patients undergoing B-RTO revealed development or aggravation of esophageal and duodenal varices, ascites, hydrothorax, and PHG[40]. Prospective studies and meta-analysis comparing TIPS and B-RTO in the management of GV have found that B-RTO is at least as efficacious as TIPS in controlling the acute bleeding with a trend towards a lower incidence of rebleeding[43-46]. Of note, B-RTO was associated with lower post procedure HE and mortality at one year. More recently, a combination of TIPS and B-RTO (Figure 2) has been utilized for the management of GV[32]. Since the obliteration of GRS can lead to worsening of PH, simultaneous or staged placement of TIPS could ameliorate the associated symptoms. The combined procedure can also reduce the risk of development of HE since GRS are often larger in diameter and have higher flow rates compared to TIPS.

Moreover, occluding a competing GRS (shunt steal phenomenon) may decrease the risk of TIPS dysfunction in the long run. Typically, TIPS is performed first, and a splenoportal venogram is obtained. The GRS is cannulated retrogradely, and suitable sized coils or vascular plug deployed. The inflow vein is then occluded with a balloon and sclerosant injected into the variceal complex to achieve complete obliteration. Conversely, doing B-RTO first may make TIPS less technically challenging in cases where the portal vein is severely attenuated due to the siphoning of blood away from the liver by the large GRS. These tiny portal veins can be difficult to target during TIPS. Following B-RTO, due to the diversion of blood towards the liver, portal vein caliber may improve, making it easier to access. A proposed algorithm for the management of GVH is shown in Figure 3.

Ectopic varices

The term ectopic varices are used to describe portosystemic collaterals located at sites other than the gastroesophageal region. Stomal varices are the most common, followed by small bowel (predominantly duodenum), colon, rectum, and peritoneum. Rare sites include the biliary tree, umbilicus, and pelvic organs[47]. Bleeding from ectopic varices represents an uncommon but challenging clinical problem. The prevalence ranges between 1%-5% of all variceal bleeds with a higher prevalence (up to 40%) seen in patients with extrahepatic PH and after surgery[47-49]. Postoperative adhesions and the creation of an enterostomy can facilitate the formation of portosystemic collaterals. Depending on the location of varices, clinical presentation, and available local expertise, the management of bleeding ectopic varices can differ. After initial resuscitation and pharmacological treatment, the treatment options include endoscopic management, percutaneous variceal embolization, TIPS, or surgical therapies[50]. Endoscopic therapy is often not feasible or successful due to an inaccessible location. Percutaneous variceal embolization using balloon-occluded sclerotherapy, coils, glue, gel foam, thrombin, or a combination of these is an effective short-term therapy for bleeding ectopic varices. However, it fails to decompress the portal venous system resulting in high 1-year rebleeding rates. Surgical treatment options such as local suturing, segmental bowel resection, devascularisation procedures, or stomal revision are associated with a high risk of recurrence[50]. TIPS has shown excellent results in achieving initial hemostasis and reducing the incidence of recurrent bleeds. However, the available evidence is limited to case reports, small case series, and related reviews[50-54]. A recent multicentre cohort study showed that TIPS was particularly effective in patients with less severe liver disease and those with stomal varices[50]. Contrarily, the rebleeding risk in patients with duodenal varices was surprisingly high. Rebleeding in 75% of patients was associated with TIPS stent dysfunction. Multiple studies have shown that patients with ectopic varices can rebleed after TIPS despite the achievement of hemodynamic target and stent patency[51,52]. Notably, the overall risk of rebleeding after TIPS in patients with ectopic varices was significantly higher than in patients with gastroesophageal variceal bleeding (23% *vs* 0-6%, respectively, at 1 year)[50]. This discrepancy can be explained by the anatomical differences between varices at these two sites. It has been suggested that unlike gastroesophageal varices, ectopic varices are true veins and are likely to have larger diameters resulting in greater wall tension resulting in higher rates of bleeding[55,56].

Based on this, few authors recommend concomitant embolization of variceal complex during TIPS (Figure 4). In the series by Vangeli *et al*[51], rebleeding was more commonly seen in those who had TIPS alone compared to those who had concomitant

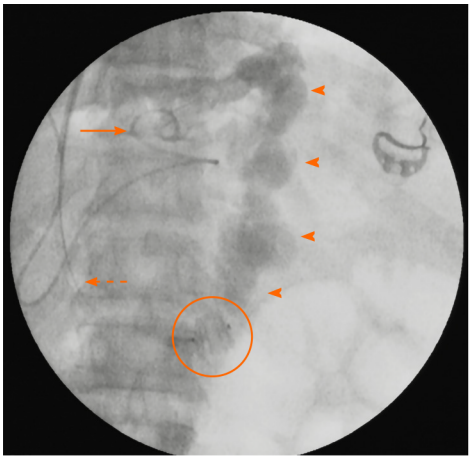

Figure 2 Fluoroscopic spot image demonstrating the "combined approach" to management of a patient with intractable gastric variceal bleeding due to IGV1 and severely attenuated portal vein. A type-II amplatzer vascular plug (encircled) has been deployed within the gastrorenal shunt retrogradely through the jugular route with vascular access sheath (dashed arrow) in situ. Subsequently, a catheter (solid arrow) was used to inject the sclerosant mixture into the shunt (arrowheads) antegrade through the transjugular intrahepatic route. The transjugular intrahepatic portosystemic shunt stent was then placed in the usual way within the intrahepatic tract after ensuring stasis of sclerosant mixture within the shunt and detachment of the vascular plug.

variceal embolization. Furthermore, they also found that the rebleeding in the majority of patients responded to subsequent variceal embolization. However, multiple other studies have reported contradictory results[52-54]. Technically, variceal embolization in this setting can be difficult since ectopic varices are frequently multiple, tortuous, and complex, and access to them may be challenging. Even when accessible, complete obliteration of ectopic varices may not be possible because of the presence of other communications with the systemic or mesenteric venous system.

Moreover, variceal embolization has the risk of inherent complications, such as propagative thrombus or paradoxical systemic embolization. Although a recent meta-analysis showed a trend favoring variceal embolization along with TIPS for ectopic variceal bleeding, the evidence is insufficient to recommend the same routinely[57]. However, when the target PSPG could not be achieved after TIPS stent placement and in whom the ectopic varices continue to be opacified on completion splenoportogram, concomitant variceal embolization may be appropriate. Variceal embolization alone can be offered to patients in whom TIPS is contraindicated due to advanced cirrhosis or overt HE (Figure 5).

PHG

PHG is characterized by vascular ectasia, which appears as a mosaic-like pattern of gastric mucosa on endoscopy[58,59]. The reported prevalence of PHG ranges from 20%-98% in patients with known cirrhosis[59-62]. Studies have shown an increased prevalence in patients with high CTP scores, EV, or history of treatment for EV (sclerotherapy or ligation)[60,61]. PHG is thought to be a direct consequence of passive congestion induced by increased portal pressure because it does not develop in the absence of established PH. A direct correlation between portal pressure values and severity of PHG remains to be demonstrated[63,64]. The incidence of acute PHG related bleeding varies between 2%-12%[60,61]. NSBB, octreotide, and terlipressin are effective in the initial treatment of PHG with reported rates of hemostasis between 93%-100%[65,66]. Endoscopic argon plasma coagulation, sclerotherapy, and coagulation therapy with the heater probe may be considered with focal bleeding. Antioxidants like vitamin E, thalidomide, and prednisolone have also been used to treat acute PHG bleeding, with anecdotal success in case reports[67,68]. After the resolution of the episode of acute bleeding, propranolol should be initiated as secondary prophylaxis. The published evidence for TIPS in the management of PHG is limited to a few case reports[69-71]. Current evidence suggests that TIPS reduces the severity of PHG, ameliorates mucosal lesions, and could be considered in patients with transfusion-dependent PHG when pharmacological measures and endoscopic interventions fail. It is important to differentiate PHG from gastric antral vascular ectasia (GAVE) as the latter can be seen in patients with and without PH or cirrhosis. GAVE has a characteristic endoscopic appearance but can co-

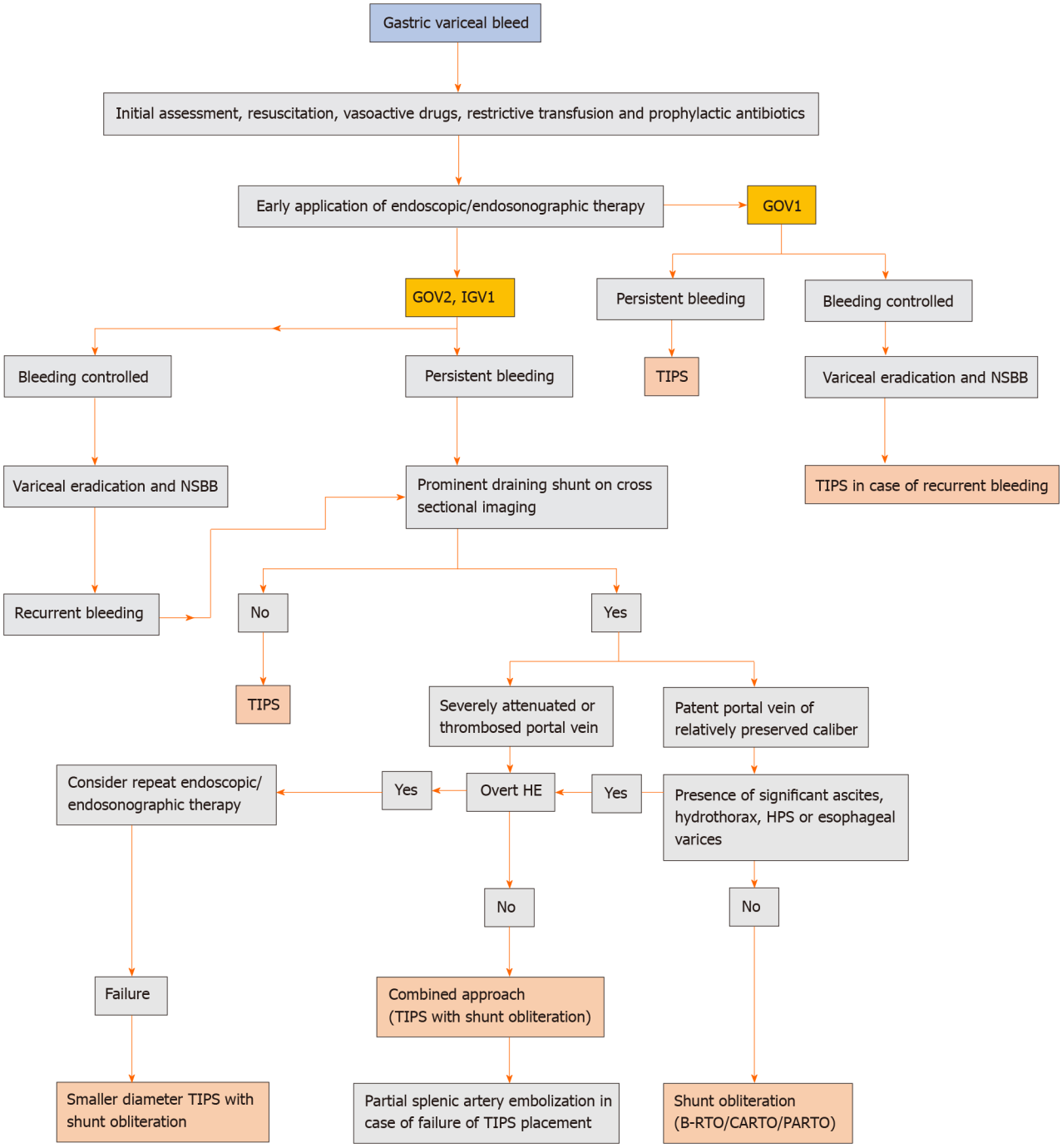

Figure 3 Proposed algorithm for the management of acute gastric variceal hemorrhage. TIPS: Transjugular intrahepatic portosystemic shunt; NSBB: Non-selective beta-blockers; HE: Hepatic encephalopathy; HPS: Hepatopulmonary syndrome; B-RTO: Balloon-occluded retrograde transvenous obliteration; CARTO: Coil-assisted retrograde transvenous obliteration; PARTO: Plug-assisted retrograde transvenous obliteration.

exist with PHG[72,73]. TIPS does not have a role in the management of bleeding solely from GAVE.

ASCITES

Ascites is the most common complication of PH in cirrhosis, with approximately 60% of compensated cirrhosis patients developing the condition within ten years of diagnosis[74]. The 5-year survival is approximately 30% in patients with decompensated cirrhosis and ascites[75]. Moreover, ascites is a direct cause of further complications,

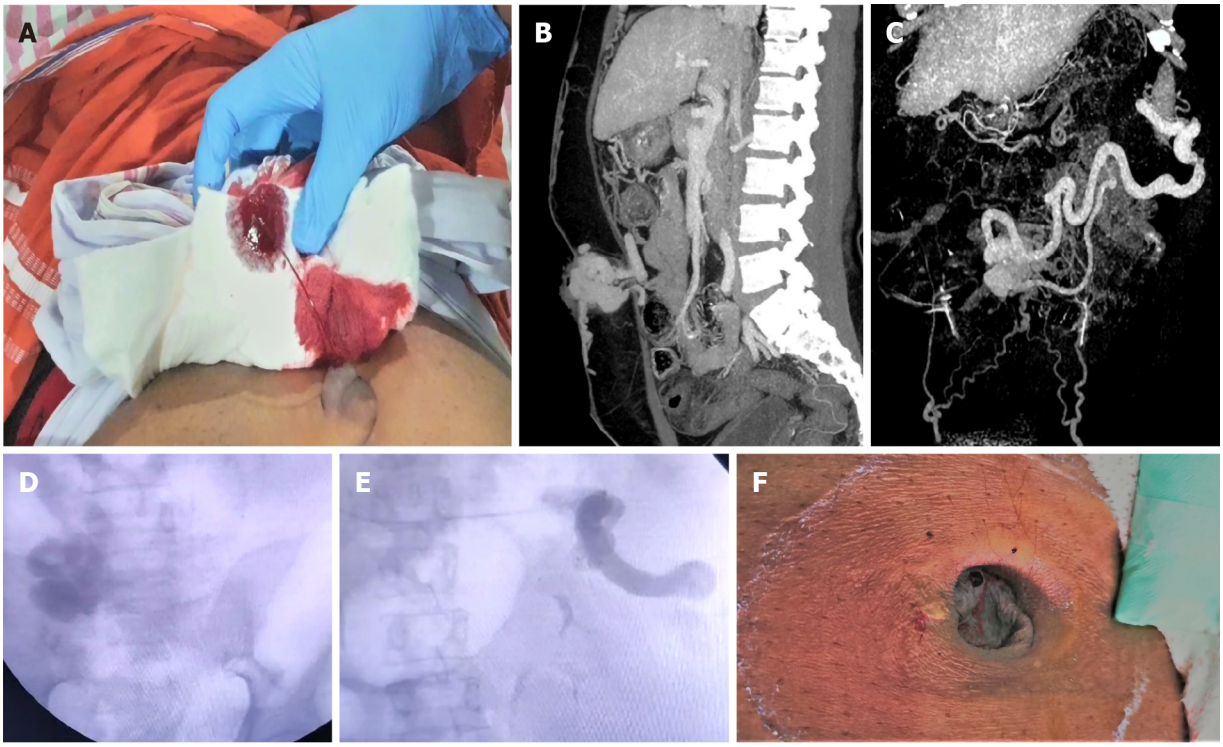

Figure 4 Ectopic umbilical variceal bleeding controlled using TIPS procedure and adjuvant percutaneous intravariceal glue injection. A: The patient with cirrhosis and portal hypertension presented with spontaneous blood soakage of clothes associated with painless spurting of blood from umbilical region; B: Contrast imaging of abdomen revealed large umbilical varix with extracutaneous component; C: The umbilical varix supply was from the splenic vein; D and E: Fluroscopy guided transjugular intrahepatic portosystemc shunt placement, shunt embolization with multiple coils followed by percutaneous glue injection for variceal obliteration was performed; F: Complete resolution of the variceal complex was noted clinically post transjugular intrahepatic portosystemc shunt procedure.

such as spontaneous bacterial peritonitis, hyponatremia, and HRS. For patients developing grade 3 ascites, large-volume paracentesis (LVP) with intravenous albumin (8 g for every L of fluid removed above 5 L) supplementation is the treatment of choice[76]. However, despite optimal medical therapy, 5%-10% of these patients develop RA, which is associated with an extremely poor prognosis and median survival of 6 mo[74,76,77]. Liver transplantation, the only definitive treatment of RA, is limited by donor resources and high costs in developing countries. Repeated LVP with albumin infusion is currently recommended as the first-line therapy for RA[76]. Current guidelines recommend consideration of TIPS placement if more than three sessions of LVP have to be performed per month for symptomatic relief or procedure intolerance[78].

Although the efficacy of TIPS in controlling ascites has been well validated by several RCT's (between 1996-2004) and subsequent meta-analysis (2005-2006), the increased incidence of HE and controversial results on survival benefit resulted in LVP to be continually recommended as the first-line therapy for RA, ahead of TIPS[79-86]. However, these RCTs were primarily evaluating the efficacy of ascites control rather than survival. Moreover, the early meta-analysis did not analyze survival as a time-dependent variable, and the confounding effect of liver transplantation on survival in patients with advanced cirrhosis was not considered[84-86]. A meta-analysis conducted later using individual patient data of these RCTs confirmed that TIPS significantly improved TFS and reduced the recurrence of tense ascites[87]. Another RCT conducted later employed even stricter inclusion criteria (Child-Pugh score of < 11, serum bilirubin < 3 mg/dL, and creatinine < 1.9 mg/dL) and found that TIPS was significantly superior to paracentesis in the control of ascites in cirrhotic patients with RA with response rates of up to 60% at one year[88]. More importantly, survival was significantly higher in the TIPS group attesting to the fact that careful patient selection is a pre-requisite for better outcomes after TIPS in patients with RA. This finding was confirmed in a recent updated meta-analysis[89]. However, the probability of post-treatment HE was increased by TIPS in all the studies with a significantly higher average number of episodes per patient. Nevertheless, all these RCTs have used bare-metal stents for TIPS, and there was a high incidence of shunt dysfunction requiring stent revision. Thus, the conclusions drawn cannot be applied to the current clinical scenario where covered stents for TIPS are the norm.

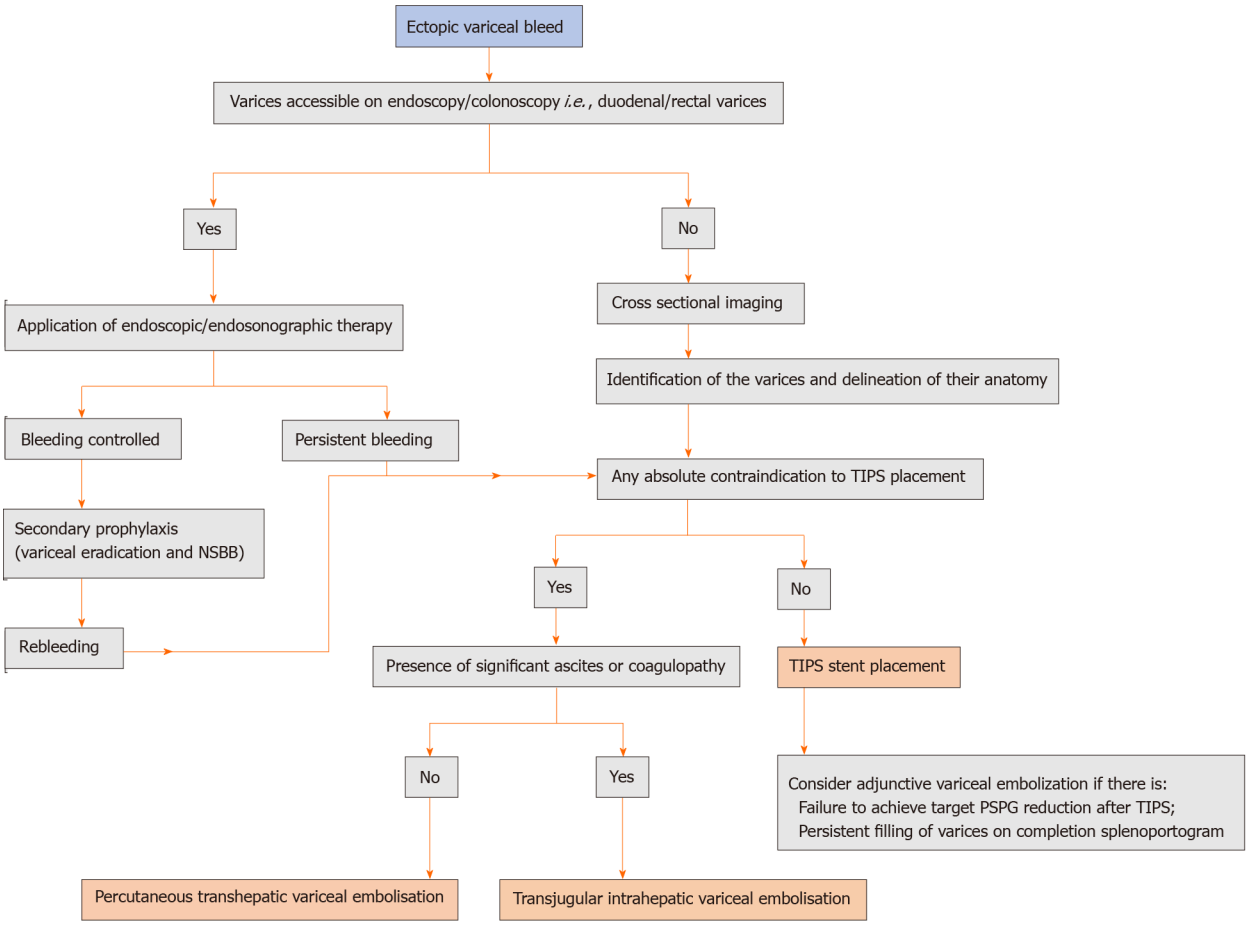

Figure 5 Proposed algorithm for the management of ectopic variceal bleeding. NSBB: Non-selective beta-blockers; TIPS: Transjugular intrahepatic portosystemic shunt; PSPG: Portosystemic gradient.

Multiple retrospective studies since then have reported survival benefit after covered TIPS in this clinical setting[90,91]. Interestingly, the most recent RCT comparing TIPS (using covered stents) with LVP in patients with ascites found that covered TIPS improved survival and did not increase the risk of HE[92]. Another retrospective study conducted later, which included patients with RA similarly showed that the risk of de-novo HE was not increased in the TIPS group[93]. Notably, this study employed smaller 8 mm diameter TIPS stents and found that while ascites control was similarly effective between TIPS responders and non-responders (as defined by a decrease in portal pressure to < 12 mmHg after TIPS implantation), HE occurred more often in patients with hemodynamic TIPS response, implying that a less aggressive PSPG reduction might be sufficiently effective for ascites control, while concomitantly decreasing the risk of post-TIPS HE. However, a randomized study comparing 8 mm *vs* 10 mm covered TIPS for RA had to be stopped midway after early results revealed worse ascites control with 8 mm stents[94]. Another recent retrospective study reported higher post-TIPS PSPG and greater need for LVP with 8 mm stents, with similar rates of encephalopathy[95]. Therefore, the optimal diameter of covered TIPS stents for this indication remains unclear. Some studies have suggested that TIPS should not be undertaken in patients with a high (≥ 18) MELD score[96,97]. However, the role of MELD in patient selection remains unclear. In the meta-analysis by Salerno *et al*[87], it was shown that compared with paracentesis, the benefit of TIPS on TFS could be seen across all MELD scores. More recently, two retrospective studies found no evidence that TIPS creation confers worse survival in patients with higher MELD scores compared with serial LVP[98,99]. A higher MELD score predicted poor survival, but survival was equally poor among patients whose RA was treated with serial LVP compared to TIPS. Another retrospective review showed that early death after elective TIPS was highest in patients with MELD greater than 24[100]. Gaba *et al*[101] compared various scores, including MELD and CTP score in the prediction of outcome after TIPS, and found that CTP score had the best overall capability at predicting mortality when TIPS is used for ascites. Bureau *et al*[102] have proposed the use of simple

laboratory parameters (bilirubin < 50 μmol/L and platelets > 75 × 10^9/L) to predict 1-year survival following TIPS for RA, which form the basis of European Association for the Study of Liver Disease guidelines.

There has been a renewed interest in the role of TIPS in patients with recurrent ascites (three recurrences of symptomatic ascites within a year). Studies, including the initial RCT's comparing TIPS with LVP, have grouped patients having recurrent ascites with those having RA. However, subgroup analyses performed on the pooled data of these RCTs showed that TIPS significantly improved TFS regardless of whether recurrent ascites patients were included or not in the trials[89]. A recent single-center retrospective study of 128 patients showed that placement of TIPS in patients with lower LVP frequency and creatinine levels is associated with superior ascites control[103]. Similar findings were reported by a prospective RCT comparing TIPS to LVP in patients with recurrent ascites and a limited LVP frequency, which demonstrated benefits in ascites control and survival in TIPS-treated patients but no difference in HE between the two groups[92]. This was reiterated in the recent study on very early TIPS performed in patients with cirrhosis and first symptomatic ascites development[30]. Thus, currently available data (Table 2) suggest that TIPS should be considered early in patients with difficult-to-treat ascites (not necessarily fulfilling the criteria of RA) having a stable underlying liver disease with relatively preserved renal function. However, a recent observational study on outcomes and mortality of patients with cirrhosis with recurrent ascites found that mortality does not differ significantly between patients with recurrent ascites and patients with ascites responsive to medical treatment and that recurrent ascites is not necessarily a sign of worsening of the liver disease, implying that these patients should not be prioritized for TIPS or liver transplant[104]. Further large multicentre prospective RCTs are needed to assess the role of "early TIPS" in ascites.

HH

HH is the accumulation of a significant amount of transudative fluid, usually over 500 mL, in the pleural cavity of patients with decompensated liver cirrhosis without coexisting primary cardiopulmonary or pleural diseases[105]. It is a relatively uncommon complication of end-stage liver disease, seen in approximately 5%-10% of patients and constitutes 2%-3% of all cases of pleural effusions[105,106]. It has a dismal prognosis with a median survival of 8-12 mo[107]. Approximately 20%-25% of patients with HH have persistent symptomatic rapidly refilling HH despite adequate dietary sodium restriction and maximum tolerated diuretic dose[107]. Early liver transplantation is the only curative treatment for these patients, but it is not always available because of recipient condition and limited donor availability. Therapeutic thoracentesis can be offered as an alternative for symptomatic relief. However, therapeutic thoracentesis is not recommended as a long-term treatment due to the risk of re-expansion pulmonary edema, pneumothorax, bleeding, and infection. TIPS effectively reduce the portal pressure, thereby providing symptomatic relief in close to 2/3rds of patients[108,109]. However, since HH is relatively uncommon, controlled studies assessing the role of TIPS for this condition are lacking. Recently, Ditah *et al*[110] and colleagues conducted a systematic review and meta-analysis of 6 retrospective studies involving a total of 198 patients suffering from HH. The analysis of pooled data showed that TIPS was successful in relieving the symptoms in 73% of cases, with complete response seen in 56% of patients. The occurrence of HE and overall mortality was found to fall within the observed range, as seen with TIPS performed for other established indications. In the absence of controlled studies comparing TIPS with standard medical treatment, the benefit of TIPS on TFS in HH cannot be commented upon. In a recent retrospective single-center analysis, despite the selection of patients with lower mean CTP (9.9 ± 1.6) and MELD score (18.7 ± 5.4), the 6-mo mortality after TIPS for HH was close to 36%[111]. The independent predictors of mortality were MELD > 25, spontaneous bacterial peritonitis, and septic shock. The study found no difference in 6 mo mortality and complication rates when TIPS was compared to other treatment groups (standard medical therapy, thoracentesis, and catheter drainage) based on propensity matching analysis. Early TIPS in selected patients may be effective as a bridge to liver transplantation.

Chylous ascites and chylothorax

Of all cases of cirrhosis-related ascites, only 0.5%-1% is chylous[112]. The underlying mechanism is believed to be excessive hepatic and gastrointestinal lymph flow and

Table 2 Summary of the randomised controlled trials on transjugular intrahepatic portosystemic shunt in patients with ascites

Ref.	No. of pts (LVP/TIPS)	Definition of ascites for inclusion	Exclusion criteria	Primary and secondary outcomes and mean follow-up time (LVP/TIPS) in months	Improvement in ascites (%; LVP/TIPS)	HE (%; LVP/TIPS)	Survival (%; LVP/TIPS)
Lebrec *et al*[49]	12/13	Despite adequate diuretics and sodium restriction: (1) Weight loss < 200 g/d in 5 d or (2) > 2 episodes of tense ascites in 4 mth	Age > 70 yr, severe extra-hepatic diseases, HCC, pulmonary hypertension, HE, bacterial infection, severe alcoholic hepatitis, portal or hepatic vein obstruction or thrombosis, obstruction of biliary tract, obstruction of hepatic artery, serum creatinine >1.7 mg/dL	Primary: Recurrence of ascites; secondary: Overall survival, HE, hemodynamic, liver; and renal function; Follow-up: 12.4/7.5	0/38	6/15	60/29
Rossle *et al*[80]	31/29	Definition reported in 1996 by IAC (45% patients had recidivant ascites)	Overt HE, serum bilirubin > 5 mg/dL, serum creatinine > 3 mg/dL, PVT, hepatic hydrothorax, advanced cancer, failure of LVP (ascites persisting after LVP or need for LVP > once per week)	Primary: TFS; secondary: Recurrence of ascites, liver and renal function, HE; Follow-up: 44/45	43/84	13/23	32/58
Gines *et al*[81]	35/35	Definition reported in 1996 by IAC	Age > 18 or > 75 yr; serum bilirubin > 10 mg/dL; prothrombin time < 40% (INR 2.5); platelet count < than 40000/mm^3; serum creatinine > 3 mg/dL, HCC, complete portal vein thrombosis; cardiac or respiratory failure; organic renal failure; bacterial infection; chronic HE	Primary: TFS; secondary: Recurrence of ascites, liver and renal function, HE, GI, bleeding, HRS; Follow-up: 10.8/9.5	17/51	34/60	30/26
Sanyal *et al*[82]	57/52	Definition reported in 1996 by IAC	Causes of ascites other than cirrhosis, advanced liver failure (serum bilirubin bilirubin > 5 mg/dL, PT INR > 2), incurable cancers or nonhepatic diseases that were likely to limit life expectancy to 1 yr, congestive heart failure, acute renal failure, parenchymal renal disease, PVT; bacterial infections, overt HE, florid alcoholic hepatitis, HCC, GI hemorrhage within 6 wk of randomisation	Primary: Recurrence of ascites and TFS; secondary: Overall survival, HE, GI bleeding, liver and renal function, quality of life; Follow-up: 38/41	16/58	21/38	33/35
Salerno *et al*[83]	33/33	Definition reported in 1996 by IAC (32% patients had recidivant ascites)	Age > 72 yr, recurrent overt HE, serum bilirubin > 6 mg/dL, serum creatinine > 3 mg/dL, CTP score> 11, complete PVT; HCC; GI bleeding within 15 d of randomisation, serious cardiac or pulmonary dysfunctions, bacterial infection, SAAG gradient < 11 g/L	Primary: TFS; secondary: Recurrence of ascites, HE, GI bleeding, liver and renal function, HRS; Follow-up: 15/21	42/79	39/61	29/59
Narahara *et al*[88]	30/30	Definition reported in 1996 by IAC	Age > 70 yr, chronic HE, HCC and other malignancies, complete portal vein thrombosis with cavernomatous transformation, bacterial infection, severe cardiac or pulmonary disease, organic renal disease	Primary: Overall survival; secondary: Recurrence of ascites, HE; Follow-up: 13/27	30/87	17/67	30/43
Bureau *et al*[92]	33/29	At least 2 LVPs within a minimum interval of 3 wk	Age < 18 and > 70 yrs, patients who had required > 6 LVPs within the previous 3 mo; patients on transplant waiting list, congestive heart failure, history or presence of pulmonary hypertension, complete PVT, recurrent overt HE, HCC, severe liver failure (prothrombin index < 35%, total bilirubin > 100 mmol/L or CTP score > 12), serum creatinine > 250 mmol/L, uncontrolled sepsis	Primary: 1-yr liver TFS; secondary: Ascites recurrence and treatment failure, overt HE, PHT-related complications, other complications of cirrhosis, and the number of days in hospital during a 1-yr period after inclusion; Follow-up: 10.4 /11.5	At 1-yr follow-up, total number of paracentesis in the TIPS and LVP group were 32 and 320, respectively	35/35	52/93

HCC: Hepatocellular carcinoma; HE: Hepatic encephalopathy; IAC: International ascites club; PVT: Portal vein thrombus; LVP: Large volume paracentesis; TFS: Transplant free survival; INR: International normalised ratio; HCC: Hepatocellular carcinoma; GI: Gastrointestinal; HRS: Hepatorenal syndrome; PVT: Portal vein thrombus; CTP: Child-Turcotte-Pugh; SAAG: Serum ascites albumin gradient; PHT: Portal hypertension; TIPS: Transjugular intrahepatic portosystemic shunt.

pressure secondary to PH, which may lead to spontaneous rupture of serosal lymphatic channels[113]. Triglyceride level > 110 mg/dL or the presence of

chylomicrons in pleural or ascitic fluid is used to confirm the diagnosis[113-116]. High protein, low-fat diet (supplemented with medium-chain triglycerides) with sodium restriction and diuretics form the first-line of management[113]. Octreotide, a somatostatin analog, has been used successfully in some patients but requires long-term therapy to achieve and maintain consistent symptom control[117]. Given the rarity of the disease, the evidence on the role of TIPS in this condition is limited to seven case reports and one series of 4 patients[118-126]. Four patients received covered stents, while five patients received bare stents. In two patients, the stent type was not described[118,123]. TIPS was uniformly successful in providing symptomatic relief in all these cases without any major procedure-related complications, except self-limiting HE in three patients. On mean patient follow-up of 13.9 mo (range 0.6-35), one patient had TIPS dysfunction with recurrence of chylous ascites twice (at 43 d and 70 d post procedure), but the ascites improved after TIPS revision on both occasions. Based on available published literature and the fact that prospective controlled trials with adequate sample size are likely to remain unavailable shortly, TIPS can be considered an effective and safe method for treating chylothorax and chylous ascites in patients with cirrhosis.

Portal vein thrombus

Non-tumoral PVT is the most common thrombotic event in patients with cirrhosis, with an annual incidence of up to 12%[127,128]. Asymptomatic presentation is common with incidental diagnosis during routine surveillance or pretransplant workup. PVT has a significant but variable influence on the outcome of patients with cirrhosis. Multiple studies have found that in the natural history of cirrhosis and PVT, 40%-70% of patients will have a progression of thrombus leading to complete occlusion of portal vein or extension to other splanchnic vessels[129-131]. While anticoagulation is considered to be the mainstay of therapy in PVT in the absence of cirrhosis, optimal management of PVT in cirrhosis has not been addressed adequately in clinical guidelines. In a prospective study on the role of anticoagulation and TIPS in 56 patients from Europe, only 36% of patients on anticoagulation showed complete recanalization, while 27% of patients showed partial recanalization[130]. The presence of ascites and splenic vein thrombosis were independently associated with the failure of anticoagulation therapy. Previously considered a contraindication for TIPS, multiple case reports, and few case series have described the successful placement of TIPS in patients with cirrhosis with PVT with acute VH, and RA[132-135]. Besides, recently two RCTs comparing TIPS with EBL plus propranolol in patients with PVT showed that TIPS was more effective than medical and endoscopic therapy without an increase in the risk of HE in the vast majority of patients leading to a recanalization rate of 95%[28,29]. Studies had also shown that even when persistent thrombus on completion splenoportogram was not stented (to preserve the long length of the unstented portal vein for liver transplant) and TIPS was not followed by anticoagulation or thrombolytic therapy, recanalization was frequently observed, implying that PVT in these patients is mainly due to hemodynamic factors[133]. With the advent of multiple imaging techniques for real-time visualization of the portal vein during TIPS, PVT is no longer considered as an absolute contraindication to TIPS placement. Also, portal vein thrombolysis and balloon angioplasty *via* recently described percutaneous transhepatic and transsplenic routes allow better visualization of the portal vein before transjugular puncture, resulting in markedly improved outcomes[133,136]. However, the presence of portal cavernoma has been associated with high failure rates despite the use of three dimensional (3D) imaging and fusion technology during TIPS. Concomitant embolization of varices has also been found to increase the long-term patency rates of TIPS and prevent thrombosis. Based on the current evidence, TIPS can be utilized for cirrhosis patients in whom thrombosis persists or progresses, despite optimal anticoagulation therapy and in those who present with complications of PH, such as acute variceal bleeding or RA (Figure 6). Standard anticoagulation following the TIPS procedure for other indications is not recommended.

Pre-surgical/neoadjuvant TIPS

Extrahepatic surgery is associated with higher postoperative morbidity and mortality in patients with cirrhosis[137]. The reported mortality is between 10% to 30%, while the perioperative morbidity is about 30%. The outcome is mainly influenced by the severity of liver disease, type of surgery, and the degree of PH[138,139]. Pre-operative TIPS may reduce the portal pressure and decrease the risk of bleeding as well as help in managing pre-or-post operative ascites[140-147]. The optimal time between TIPS and the performance of surgery is controversial. Nonetheless, a delay of 1 mo from TIPS to surgery has been suggested to be the most appropriate for optimal portal

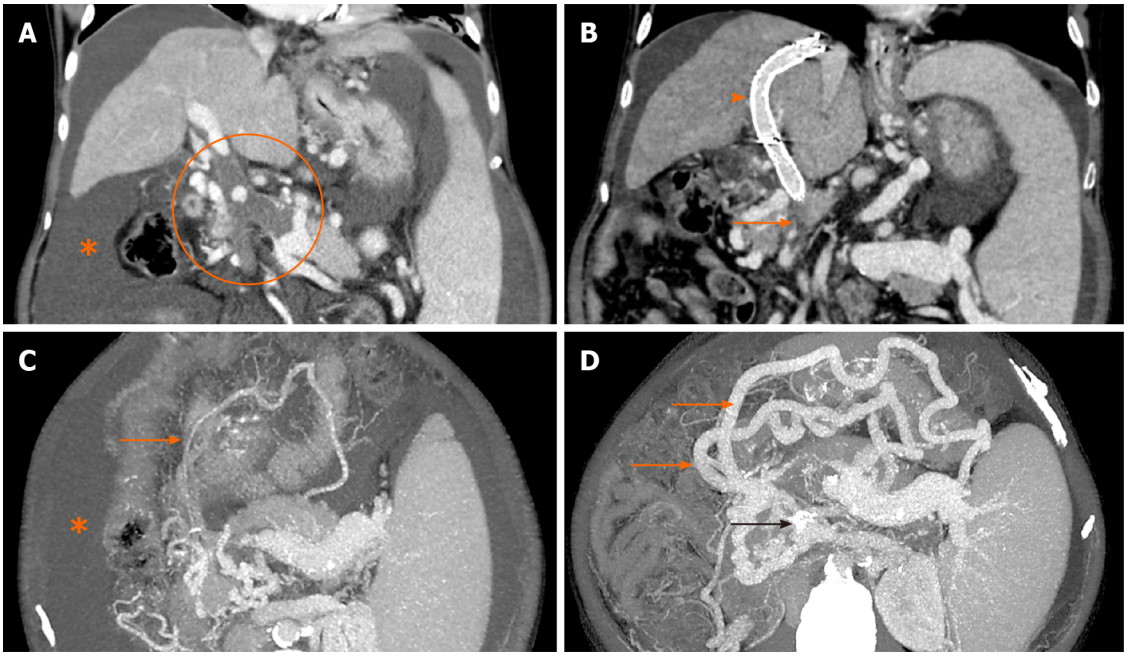

Figure 6 Contrast-enhanced computed tomography image. A: Coronal image showing bland occlusive thrombus involving the main portal vein, superior mesenteric vein (SMV) and splenic vein (encircled) with gross ascites (asterisk); B: Image taken 2 wk after transjugular intrahepatic portosystemic shunt (TIPS) shows the stent in situ (arrowhead) with its distal end in one of the major tributaries of SMV. The main trunk of SMV (solid arrow) and splenic vein could not be fully recanalized during TIPS. Trans-splenic access was not taken due to gross ascites; C and D: Corresponding axial images show marked enlargement of the gastroepiploic collaterals (solid orange arrows) arising from the patent portion of splenic vein at splenic hilum draining through the TIPS stent (black arrow in D) into the portal venous system. Note the significant regression of ascites on the follow up scans.

decompression[142]. That being, the perceived benefit of TIPS must be weighed against the risk of the procedure itself and the associated time delay. All publications on the role of pre-operative TIPS are retrospective in the form of single clinical reports or case series with a fairly small number of patients[140-147]. Out of these, only two studies have had a control group, but both were retrospective comparative studies without randomization[143,146]. A systematic analysis of all the published data showed that there is marked heterogeneity with regards to patient selection based on the severity of the underlying liver disease, indication for TIPS, criteria for successful TIPS, and time-lapse between TIPS placement and surgical procedure[148]. The study by Vinet *et al*[143] compared patients who underwent an elective abdominal surgery after preoperative TIPS placement (n = 18) with those who underwent surgery without TIPS (n = 17) during the same period. The authors found that the preoperative portal decompression with TIPS did not improve outcome after abdominal surgery in patients with cirrhosis. However, the TIPS group in this study had a higher mean CTP score compared to the control group. The other retrospective, multi-institutional, comparative study by Tabchouri *et al*[146] also did not find any significant differences between TIPS and control groups in terms of severe postoperative complications and mortality. Notably, they found deterioration of hepatocellular function after TIPS placement, which persisted postoperatively despite a mean interval of 51 d between TIPS placement and planned surgery. In this study, a subset of patients with less severe PHT (HVPG ≤ 13 mmHg) and less advanced liver dysfunction (MELD-sodium score ≤ 15) seemed to benefit from preoperative TIPS placement in terms of postsurgical complications in the absence of statistical significance. Contrarily, in the study by Kim *et al*[144], despite a preoperative mean MELD score of 15 among the patients (n = 6), the 1-year survival rate was 74%. A recent prospective study showed the value of HVPG in predicting outcomes in cirrhosis patients undergoing non-hepatic surgery, with no patient having HVPG < 10 mmHg or indocyanine green clearance > 0.63 developing decompensation[149]. On the other hand, HVPG > 16 mmHg was independently associated with higher mortality, and patients with HVPG > 20 mmHg were found to be at the highest risk. Interestingly, MELD and CTP scores were not independent predictors of post-surgical mortality. The findings of this study reiterate that the potential of pre-surgical TIPS in high-risk patients deserves further research to improve outcomes. Based on all the available published evidence, routine TIPS placement cannot be recommended before surgical procedures in all patients with cirrhosis and PH. Pre-operative TIPS is likely to benefit cirrhosis patients having

preserved liver function but with features of severe PH who are undergoing curative oncosurgery. For patients who require emergency surgery, TIPS might still be beneficial by decreasing the risk of perioperative hemorrhage related to venous congestion and varices.

HRS

HRS is usually manifested in the advanced stage of cirrhosis with PH. International Club of Ascites has defined HRS as an increase in serum creatinine ≥ 0.3 mg/dL (≥ 26.5 mmol/L) within 48 h; or a percentage increase in serum creatinine ≥ 50% from the baseline that is known, or presumed, to have occurred within the previous seven days[150]. As per the recent International Club of Ascites classification, patients with cirrhosis and acute kidney injury (AKI) are subgrouped into HRS AKI and HRS non-AKI[150,151]. HRS non-AKI is further subdivided into HRS-acute kidney disease and HRS-chronic kidney disease. In the former, the calculated glomerular filtration rate (eGFR) is < 60 mL/min per 1.73 m^2 for < 3 mo in the absence of other (structural) causes along with percent increase in serum creatinine < 50% using the last available value of outpatient creatinine value within 3 mo as the baseline value. In the latter, the eGFR is < 60 mL/min per 1.73 m^2 for ≥ 3 mo in the absence of other (structural) causes. In patients not responding to medical management in the presence of ascites, TIPS is a useful procedure in the management of HRS.

The utility of TIPS in patients with HRS non-AKI has been discussed previously in the section on RA as most of these patients present with the need for repeated paracentesis. In a recent systematic review on TIPS in HRS, nine publications with 128 patients were analyzed. The pooled short-term and 1-year survival rates were 72% and 47% in HRS-AKI and 86% and 64% in HRS non-AKI. The pooled rate of HE after TIPS was 49%. The pooled rate of renal function improvement post-TIPS was 93% in HRS-AKI and 83% in any type of HRS. Post-procedure, creatinine, blood urea nitrogen, serum sodium, sodium excretion, and urine volume significantly improved with a nonsignificant elevation in serum bilirubin[152]. The use of TIPS in patients with HRS-AKI remains controversial since a majority of these patients are sick at presentation with sepsis or acute decompensation. A recent retrospective cohort study in HRS patients showed TIPS is a relatively safe, bridging therapeutic option in patients who underwent TIPS in comparison to patients who received dialysis[153]. Decreased recurrence of ascites and increased incidence of HE in the TIPS group was seen in a small randomized study where they compared patients with Type 2 HRS (HRS non-AKI) who underwent TIPS with another group of patients receiving paracentesis plus albumin[81]. TIPS may prevent permanent renal damage and the need for further liver-kidney transplantation due to portosystemic shunting and resultant hemodynamic changes[154]. However, further RCTs showing the role of TIPS in HRS patients are required.

HPS

In HPS, patients with underlying chronic liver disease present with shortness of breath and hypoxemia, which occurs secondary to pulmonary vasodilation and intrapulmonary shunts[155]. Liver transplantation is considered as the most effective treatment in HPS[156]. PH is one of the key events that is considered to play a role in the pathogenesis of this syndrome, and hence reduction of portal pressure using TIPS may be considered as an alternative therapeutic procedure[157,158]. Few studies have compared the difference between a left branch of the portal vein (LPV-TIPS) and right branch of the portal vein (RPV-TIPS) for performing TIPS and have shown that the incidence of HE is lower in LPV-TIPS group[159,160]. Zhao *et al*[155] in their study recommend LPV-TIPS over RPV-TIPS to improve the symptoms of hypoxemia and thereby improve the arterial oxygenation. Even though controlled studies assessing the role of TIPS in HPS are lacking, there is evidence of improvement in oxygenation after the procedure[161-163]. TIPS also has a role in patients awaiting liver transplantation[155,164,165]. Additional prospective studies are required to understand the pathogenesis of this syndrome and identify the effects of reducing portal pressure.

CONSIDERATIONS DURING SELECTION OF PATIENTS FOR TIPS

Age

Initial studies identified advanced age as an independent predictor of early mortality after TIPS, attributing it to age-related physiologic decline in hepatic functional reserve, which might not be picked up on routine laboratory tests[166,167]. However, the

majority of patients in these studies received bare-metal stents for TIPS. Also, there was significant heterogeneity in terms of severity of underlying disease in the study group with different cut-offs for defining advanced age, precluding drawing of any robust conclusions. Nevertheless, a recent study using covered stents for TIPS did find a trend towards greater mortality and hospitalization in the elderly, without reaching statistical significance[168]. Another retrospective study in which the subjects were well matched for MELD score, indication for TIPS, and comorbidities showed that age is strongly and independently associated with 90-day post-TIPS mortality risk, particularly in those > 70 years[169]. Adlakha *et al*[170], in a retrospective study of 100 patients, similarly showed that re-admission rates and incidence of severe HE requiring hospital admission were higher in elderly patients, even after accounting for MELD score. They also found that TIPS for secondary prophylaxis of variceal bleeding, RA, and HH had acceptable morbidity and mortality. However, there was high mortality when TIPS was placed for acute variceal bleed, even in patients with MELD score < 18. There was a trend towards increased 30 d mortality despite a low baseline MELD, particularly in patients aged 80 years and more, without reaching statistical significance. Current evidence suggests that older age (no absolute cut-off; generally accepted as > 65 years) is a relevant consideration in assessing mortality risk of TIPS. However, advanced age alone should not be an absolute contraindication for TIPS, especially for conditions in which TIPS has proven benefit in terms of symptomatic relief and survival, like acute variceal bleeding or RA. These patients should be followed for occurrence of HE after TIPS closely. Moreover, the need for frequent readmissions and the heightened risk of early mortality should be part of routine counseling before TIPS in this subset of patients.

HE

Multiple studies have shown that TIPS, by portosystemic shunting, increases the risk of HE[171,172]. The median cumulative 1-year incidence of overt HE after TIPS has been reported to be between 10% and 50%[172,173]. The incidence of persistent overt HE is around 8% and that of de-novo, covert HE around 35%[171]. However, even in the mildest form, HE significantly reduces health-related quality of life and reflects a poor outcome of TIPS, especially when the procedure was done as palliative therapy in an elective setting. One study showed that neither rifaximin nor lactulose prevented post-TIPS HE any better than the placebo[174]. Thus, careful case selection is the most effective way to reduce the incidence of HE after TIPS. Risk factors for HE post-TIPS include advanced age, the severity of the liver disease, sarcopenia, history of prior encephalopathy, and the presence of any pre-existing portosystemic shunt[173]. Diabetes has also recently been recognized as a risk factor for HE, which is particularly important in the current scenario where a significant proportion of patients who come for TIPS have NASH-related cirrhosis associated with diabetes[175]. Although age > 65 is not an absolute contraindication, it might increase the risk of encephalopathy and should be taken into account when deciding the eligibility, especially for elective TIPS. Similarly, although studies have suggested that sarcopenia and HE are causally related, an overall improvement in muscle mass and density after TIPS has also been reported in recent literature, which resulted in a reduction in episodes of overt HE and venous ammonia levels. Furthermore, the majority of patients who come for elective TIPS will have relatively well-preserved hepatic and renal functions without any documented history of overt HE. Diligent screening of these patients to identify signs of covert HE is crucial. Patients who have evidence of covert HE should ideally not undergo TIPS for an elective indication unless there is a large portosystemic shunt that can be embolized during TIPS. Stent characteristics and desired portal pressure gradient reduction has been implicated in post TIPS HE. Recent studies have shown reduced rates of HE with covered TIPS stents compared to bare-metal stents[3]. However, conclusive evidence is still lacking. Similarly, there is a lack of consensus on whether to aim to reduce PSPG by 20% or below 12 mmHg (discussed later). Too low a pressure because of large stent diameter has been shown to predispose to intractable HE in some studies.

Cardiopulmonary status

In advanced stages of cirrhosis, structural, and functional cardiac abnormalities occur. This cirrhosis associated cardiomyopathy (CCM) leads to impaired contractile responsiveness to stress, diastolic dysfunction, myocardial hypertrophy, and electrophysiological abnormalities in the absence of other known cardiac disease[176,177]. Cirrhosis associated cardiomyopathy has been suggested as a key factor in the development of RA, hyponatremia, and HRS. As many as 50% of end-stage patients undergoing liver transplantation show signs of cardiac dysfunction[177-179]. Shunting of

portal blood into the systemic circulation after TIPS leads to a sudden increase in cardiac preload and output that can rapidly worsen the hyperdynamic circulatory state in patients with cirrhosis. Cardiac complications noted post-TIPS commonly include clinically evident heart failure in those with RA. Long-term cardiovascular changes, including cardiac volume overload and an increased rate of pulmonary hypertension, have also been reported[180]. Initial prospective studies reported that the presence of diastolic dysfunction before TIPS was associated with post-procedural mortality within one year[178,181]. However, these studies lacked an independent, blinded review of the echocardiography and relied solely on E/A (early maximal ventricular filling velocity/atrial maximal ventricular filling velocity) ratio < 1.0 to define diastolic dysfunction.

Recent studies have found no relationship between diastolic dysfunction and post-TIPS survival or cardiac failure despite pre-TIPS rates of diastolic dysfunction ranging from 30%-45%[180,182,183]. Another study found that symptomatic heart failure was rare after TIPS (seen in < 1% of patients) and that this condition can be managed successfully when it is recognized early[184]. However, a recent prospective study of 100 patients from France undergoing a complete cardiac evaluation before TIPS found that hospitalization for cardiac decompensation was observed in 20% of patients in the year after TIPS insertion[185]. The serum N-Terminal pro-B-type natriuretic peptide (NT-proBNP) was found to be predictive of cardiac decompensation after TIPS, but not mortality. The authors recommended that combining BNP or NT-proBNP levels and echocardiographic parameters should help improve patient selection. Recently left ventricular global longitudinal strain has been utilized to identify cirrhotic patients with underlying cardiac dysfunction[186]. It was found that impaired cardiac contractility, reflected by higher left ventricular global longitudinal strain, predisposes to the development of acute-on-chronic liver failure and death in cirrhosis.

Current guidelines suggest a detailed cardiac history, physical examination, 12-lead electrocardiogram, echocardiography, and NT-proBNP in all patients undergoing elective TIPS placement with invasive cardiac assessment reserved for patients in whom the initial evaluation is abnormal[187]. Severe PAH-defined as mean pulmonary artery pressure (mPAP) > 45 mmHg-represents an absolute contraindication to TIPS. In patients with moderate PAH (mPAP between 35-45 mmHg) with elevated pulmonary capillary wedge pressure (> 15 mmHg), TIPS can be placed in emergencies for established indications (like variceal bleeding refractory to endoscopic and pharmacologic treatment)[187]. In patients with severe left ventricular dysfunction, elective TIPS is contraindicated. The cardiologic workup should also include contrast echocardiography aimed to demonstrate a patent foramen ovale, particularly in patients with PVT. Foramen ovale may serve as a conduit for paradoxical embolization, the occurrence of which has been reported following TIPS[188].

Nutritional status

Alterations in the nutritional status are one of the most frequent complications of cirrhosis that worsens with disease progression and negatively affects the outcome in these patients. The etiology is multifactorial and includes reduced caloric and protein intake, increased catabolism, malabsorption, reduced protein synthesis, and anabolic resistance[189]. Malnutrition in cirrhosis can lead to reduced muscle mass and strength-also called sarcopenia-as well as the loss of subcutaneous and visceral fat mass called adipopenia[190]. Sarcopenia is the predominant nutritional consequence of cirrhosis, with a reported prevalence as high as 95%[191]. The risk of malnutrition is assumed to be high in Child-C patients and those with BMI < 18.5[192]. The Royal free hospital-nutritional prioritizing tool is a screening score that has been reported to correlate with clinical deterioration, the severity of the liver disease, and clinical complications[193]. CT image analysis at L3 vertebra (L3 skeletal muscle index; L3SMI) is widely recognized as a specific method to quantify the loss of muscle mass[194]. Bedside anthropometric methods like mid-arm muscle circumference, triceps skinfold, and mid-arm muscular area have also shown comparable predictive value to L3SMI with good intra and inter-observer agreement[195,196].

TIPS has been shown to improve body composition and increase fat-free mass in cirrhotics in observational studies[189,197,198]. Resolution of ascites leading to better nutritional intake, improvement in splanchnic venous return, a reversal of protein-losing enteropathy, prevention of further episodes of bleeding and paracentesis, and a possible reversal of hypermetabolism have been proposed as possible mechanisms by which TIPS improves the muscle mass[189]. A recent study showed that the creation of TIPS was strongly associated with an increase in cross-sectional area and attenuation of truncal musculature with maximal gains noted by 6 mo after TIPS[198]. Furthermore, TIPS related increase in muscle mass was independently associated with lower patient

mortality. This study also identified a positive effect of TIPS on muscle attenuation, an indicator of myosteatosis that has been associated with sarcopenia and mortality in patients with cirrhosis. This survival advantage could prove crucial in patients awaiting a liver transplant. Multiple other studies have shown that reversal of sarcopenia and improvement of muscle attenuation after TIPS were independently associated with a reduction in mortality[197].

Similarly, the persistence of sarcopenia after TIPS is associated with a reduced response to TIPS and a higher risk of acute-on-chronic liver failure development and mortality[199]. A retrospective observational study found that the measurement of psoas muscle density improved overall survival predictability in patients with cirrhosis undergoing TIPS creation when used in conjunction with the MELD score[200]. Another retrospective study found that sarcopenic obesity is a risk factor for mortality after TIPS and contributes additional prognostic information beyond the MELD score[201]. However, sarcopenia has also been shown to increase the incidence of post TIPS HE[202,203]. This is because skeletal muscle is an important site for ammonia metabolism in cirrhosis. Also, hyperammonemia can impair muscle function and contribute to muscle loss, leading to a vicious cycle[192]. A prospective study of 46 patients from Italy showed that sarcopenia was independently associated with the development of post TIPS HE[202]. However, compared to the patients without sarcopenia, patients with muscle depletion in this study were older, had a higher MELD score, and more often had a previous episode of HE before TIPS.

Nevertheless, all the patients who developed HE in this study could be managed medically. Another retrospective study found a correlation between sarcopenia and development of HE within 6 mo of a TIPS procedure without reaching statistical significance[203]. More recently, a study published in abstract form showed that amelioration of muscle wasting after TIPS resulted in a decrease in the episodes of overt HE and venous ammonia levels, suggesting that sarcopenia and HE are causally related[204]. Contrarily, another study published in abstract form showed that in patients undergoing TIPS for RA, sarcopenia did not have any impact on mortality, HE, or ascites control and that sarcopenia should not be considered as a contraindication for TIPS[205]. Available evidence suggests that TIPS has a positive influence on muscle mass and overall body composition, and the addition of nutritional indices to the MELD score could enhance its predictive value. Although TIPS might increase the incidence of HE and acute-on-chronic liver failure in patients with sarcopenia, further studies are needed to identify patients who might be at risk of these complications.

UPDATE ON THE TECHNICAL ASPECTS OF TIPS

Optimal stent diameter

The 8-mm *vs* 10-mm debate: The availability of covered stents for TIPS has significantly reduced the incidence of stent dysfunction with attendant improvement in patient outcomes[206]. While covered stents have become the standard of care for TIPS world over, the question of optimal stent diameter for TIPS remains unanswered. The diameter of the stent determines the amount of portal blood shunted into the systemic circulation and the PSPG. Several studies have found a relationship between the degree of portosystemic shunting and post TIPS HE[172]. Similarly, a lower PSPG has also been identified as a risk factor for HE after TIPS[207,208]. Also, impairment of hepatic function often seen after TIPS could be reduced by decreasing the size of the stent to avoid significant portal flow diversion and maintain sufficient hepatic perfusion. According to Poiseuille's law, shunt flow is proportional to the fourth power of the stent radius. This underlines the impact of small variations of the stent diameter on shunt flow and, eventually, shunt-related complications. Thus, the use of a smaller diameter stent is desirable. However, placement of smaller diameter stent runs the risk of not achieving adequate portal pressure reduction defeating the purpose for which TIPS was done. The earliest RCT comparing 8-mm and 10-mm covered stents for TIPS had to be stoped early after the results in the first 45 patients showed significantly less efficient control of complications of PH in the patients receiving 8-mm stents[94]. Due to the premature closure of the study, the trial could not provide any evidence on the risk of development of HE. Contrarily, another randomized multicentre trial from Germany comparing covered 8-mm diameter TIPS with HVPG-guided medical therapy for prophylaxis of rebleeding from EV showed that TIPS prevented variceal rebleeding more effectively than drugs without any improvement in survival or quality of life[26]. Compared to other studies using covered

TIPS stents, the two-year incidence of overt encephalopathy in the TIPS group in this study was low at 18%. However, the patients included in this study had rather compensated liver disease (Child A or B cirrhosis), and there was no head-to-head comparison between 8-mm and 10-mm stents. Notably, only 43% of patients in the TIPS group had a reduction of PSPG below 10 mmHg. TIPS revisions were required in 8% of the patients with PSPG < 10 mmHg and in 29% of patients with PSPG ≥ 10 mmHg. Nevertheless, a recent RCT from China of 127 patients found that 8 mm covered TIPS stents showed similar shunt function to 10-mm stents, with the halved risk of spontaneous overt HE and less hepatic function impairment[209]. Notably, the majority of patients in this study had hepatitis-B as the etiology of cirrhosis, which is different from the earlier study by Sauerbruch *et al*[26], in which more than 60% of patients had alcoholic cirrhosis. Although the stent used for TIPS was Fluency® and not Viatorr®, the same stent was used in both groups and might not have influenced the outcomes. Whether the trend towards beneficial effects of 8-mm stents could be extended to patients receiving TIPS for RA is unclear. A retrospective study of 171 patients in this regard showed that 10-mm covered stents for TIPS resulted in better control of ascites compared to an 8-mm stent without increasing the incidence of HE[95]. They found that the mean PSPG after TIPS was significantly higher in the 8-mm stent group than in the 10-mm stent group, and in the overall study cohort, the need for paracentesis was associated with a higher PSPG. Another recent analysis of 185 patients from the German TIPS registry showed that patients receiving 8-mm stents had prolonged survival compared to those receiving 10-mm stents[210]. However, in this study, 8-mm stents were used more frequently in patients with variceal bleeding, while 10-mm stents were placed more commonly in patients having RA. Since patients with RA are generally at a more advanced stage of liver cirrhosis than those with variceal bleeding, derivation of any robust conclusion on survival benefit is not possible from this study. Moreover, although patients in the two groups were matched for age, MELD score, and serum bilirubin concentration, they remained different concerning CTP score and creatinine concentration. Thus, the 10 mm group had more patients with Child C cirrhosis, and the mean creatinine concentration of patients in this group was higher. Other confounding factors affecting survival like sarcopenia were not available for analysis, and the incidence of HE in both groups was not compared. The incidence of rebleeding and recurrence of ascites was also not analyzed in this study. Thus, comparisons on the clinical efficacy of TIPS in both groups of patients cannot be drawn and properly matched patient cohort with adequate sub-group analysis followed by quality prospective studies remain an unmet need to clarify the current issue at hand. Notably, 8-mm stents resulted in less reduction of the PSPG (45% *vs* 65%) compared to 10-mm stents, and patients with an 8-mm stent required significantly more revisions. Current evidence is inadequate to recommend routine use of smaller diameter stents in all patients. However, in patients who are at higher risk of development of HE or liver failure, especially when TIPS is used in the setting of acute variceal bleeding, there may be a role of 8-mm stents.

Target PSPG reduction and passive expansion of under dilated TIPS stents: It has been found that barring few exceptions, patients with de novo or worsening HE after TIPS had PSPG of < 12 mmHg, while those with rebleeding often had stent dysfunction with gradients of > 12 mmHg[207]. Thus, a cut-off of 12 mmHg for post-TIPS PSPG is useful to stratify patients into high or low-risk groups when it comes to HE or rebleeding[207]. It is recommended that a relative reduction of PSPG by 20%-50% may be more practical[211]. In contrast to the situation for variceal bleeding, the optimum target PSPG when placing TIPS for RA remains unclear. A threshold of 5 mmHg or 8 mmHg is not as useful in risk stratification as the cut-off of 12 mmHg[212]. Despite this conflicting evidence, quality improvement guidelines of the American Society of Interventional Radiology recommend that the PSPG after TIPS should not be less than 5 mmHg[213]. Many centers have anecdotally adopted a strategy of step-wise dilatation of 10-mm diameter covered TIPS stents by using balloon catheters of increasing diameter, starting with a 6 mm or 8 mm balloon. The extent of dilatation is considered acceptable when the target PSPG is reached. Further balloon dilatation is reserved for patients with insufficient clinical response. This approach is based on the assumption that TIPS stents which are made of nitinol do not have the necessary radial force to self-expand within a cirrhotic liver. However, it has been reported that under dilated stents passively auto-expand over a variable period[214,215]. Therefore, the practice of under dilating the stent may only have a temporary benefit and may not sufficiently decrease the risk of shunt-related complications. To overcome this limitation, modifications in the TIPS technique have been described by multiple authors, which essentially involve deploying a covered TIPS stent within a smaller

balloon-expandable stent allowing calibration of PSPG to a predetermined value at the time of TIPS creation or at a later time, as and when needed. This technique is called as 'incrementally expandable' TIPS stents[216]. However, this requires the placement of an additional stent, adding to the cost and complexity of the procedure.

Controlled expansion stents: Recently, a new controlled expansion stent has been introduced into clinical practice by Gore and associates (Viatorr® controlled expansion endoprosthesis; VCX, Flagstaff, AZ, United States), which allows more accurate diameter control in the diameter range 8 to 10 mm during implantation. VCX is similar to the regular 10-mm Viatorr® e-PTFE stent graft with the added feature of an outer constraining balloon-expandable sleeve that allows adjustment of the stent diameter[217]. Thus, it allows the calibration of PSPG with a single device. In vivo studies have shown that VCX can assume and maintain the intended diameter on clinical follow-up[217]. VCX was associated with a good short term clinical success with a lower rate of HE and stent dysfunction[4,5]. Also, a reduced rate of readmission for sepsis and ascites was observed over a three-month follow-up[217]. However, further studies with longer follow up are needed to confirm this data.

Update on portal venous puncture technique

Cannulation of the portal vein is one of the most crucial and technically challenging steps during TIPS and often determines the duration of the procedure and total radiation dose[218,219]. The majority of potential intraoperative complications are also related to this part of the procedure, including arterial and biliary tract injury and hepatic capsular penetration. A "blind" fluoroscopic approach was originally described to access the portal vein during TIPS. Many centers have switched over to wedged carbon dioxide portovenography to facilitate the advancement of the needle towards the portal vein under two dimensional (2D) fluoroscopy[220]. However, it cannot be used in cases with occlusive portal vein thrombus. Arterial portography is another technique of navigation but requires intra-arterial injection of contrast, and visualization of portal vein may be suboptimal, particularly when the vein is small in caliber or shows hepatofugal flow[221]. Many studies have described computed tomography or ultrasound -guided percutaneous marking of portal vein using guidewires or metallic coils, which is not without risk in patients with advanced cirrhosis[222,223]. The use of transabdominal ultrasound-guided portal vein puncture (Figure 7) overcomes these problems and has been shown to reduce the radiation dose[224]. It is also useful in patients with portal vein thrombosis. Intravascular ultrasound guidance is a potentially exciting tool for portal vein access and has been shown to reduce the radiation dose, multiple needle passes, and volume of contrast used compared to the conventional technique[225,226]. However, intravascular ultrasound has a learning curve and requires additional expensive equipment. Recently, 3D cone-beam computed tomography-guided portal vein cannulation using image fusion technology has been described[227,228]. It allows registration of pre-procedural 3D multimodality imaging data sets with 2D fluoroscopy for real-time instrument visualization and has been shown to reduce the number of liver puncture, complications, and failed attempts at TIPS stent placement. Apart from the difficulty in portal venous access during procedure and associated technical challenges, various other complications associated with the technical aspect of TIPS have been described. A comprehensive discussion on these technical aspects is beyond the scope of this review. Nonetheless, Table 3 shows a concise and clarified discussion of these pertinent challenges.

Adjunctive embolization of varices and portosystemic shunts

Persistence of varices after deployment of TIPS can potentially cause recurrent variceal bleeding, especially in cases where adequate reduction of PSPG could not be achieved. Few retrospective studies and one RCT have explored this aspect of the TIPS procedure[229-234]. Angiographic filling of varices despite the adequate reduction of PSPG, presence of gastric or ectopic varices, and suboptimal reduction of PSPG after TIPS have been identified as some of the clinical situations in which patients may benefit from concomitant embolization of varices[229]. Recently, a prospective RCT of 106 patients from China compared TIPS alone with TIPS and coronary vein embolization to assess the rates of rebleeding and stent dysfunction[232]. They found that the cumulative rates of recurrent variceal bleeding in the two groups were not significantly different, except at 6 mo, when the bleeding rate in the embolotherapy group was 2.5-fold lower than that in the TIPS group, without any survival advantage.

Interestingly, the primary stent patency rates in the adjunctive embolization group

Table 3 Complications associated with transjugular intrahepatic portosystemic shunt placement and prevention or management strategies

Complication	Prevention/management
Carotid artery puncture during internal jugular vein access	Using ultrasound and fluoroscopic guidance for jugular venous access
Right atrial perforation	Avoid keeping the large 10-F sheath in the right atrium after the procedure
Capsular laceration during wedged hepatic venography	Using closed bag system for CO_2 delivery/gentle injection of iodinated contrast
Hepatic capsular transgression or extrahepatic portal venous puncture	Using guidance for portal venous access
Non-target TIPS stent insertion into biliary tract or hepatic artery	Using guidance (USG/IVUS/CBCT) for portal venous access, confirm successful puncture with contrast injection
TIPS stent migration	Careful stent deployement and maintaining wire access across the stent until satisfactory, positioning is confirmed with portal venography, in case retrieval is needed
Early shunt occlusion	Positioning the proximal end of the stent till the hepatico-caval junction; thrombectomy, thrombolysis and restenting can be done for establishing flow
Hernia incarceration	Pre-TIPS hernia repair; alternatively, keeping a high index of suspicion after TIPS and prompt referral to a surgeon for management

CO_2: Carbondioxide; TIPS: transjugular intrahepatic portosystemic shunt; USG: Ultrasonography; IVUS: Intravascular ultrasound; CBCT: Cone beam computed tomography.

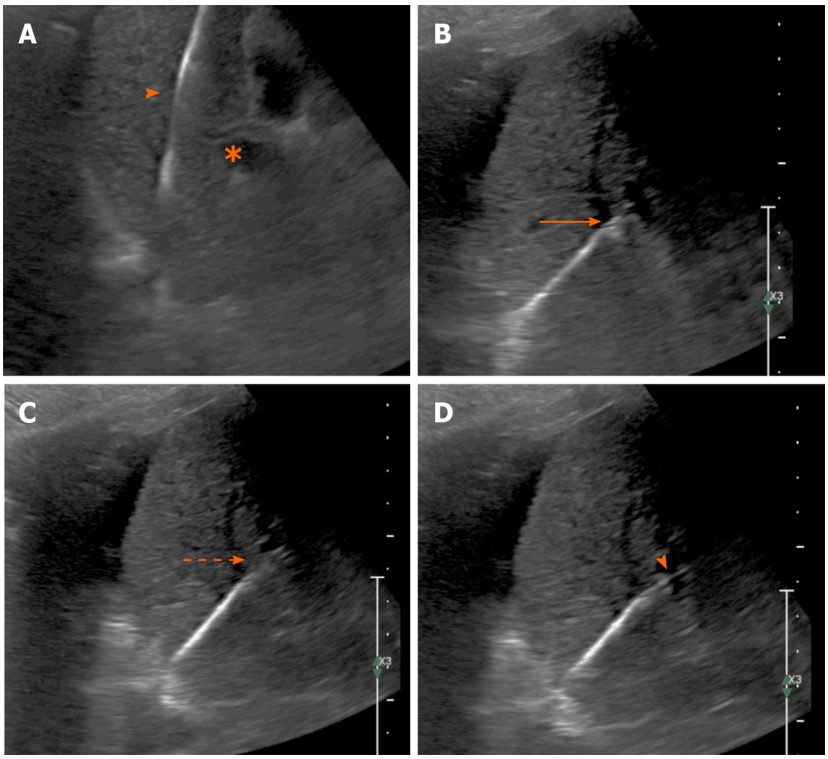

Figure 7 Ultrasound image. A: Gray scale ultrasound image showing the stiff guidewire in the right hepatic vein (arrowhead) with the right portal vein branch in the same image (asterisk); B: The needle-catheter combination advancing towards the portal vein branch (arrow); C: Indentation of the needle (arrow); D: The needle is seen entering the portal vein (arrowhead).

were higher than the TIPS group at 6 mo. This was attributed to the increased antegrade flow in the TIPS shunt due to the embolization of the varices. However, the incidence of stent dysfunction in the TIPS group in this study at 6 mo (18%) was worse than the 1-year incidence of shunt dysfunction (12.8%) reported by another RCT from Europe in which majority of the patients underwent placement of covered TIPS stents for variceal bleeding. One reason for this discrepancy could be that Fluency® stents, instead of Viatorr®, were used for TIPS creation in the Chinese study, which tends to

have a higher rate of dysfunction. A meta-analysis of these studies suggested that the incidence of variceal rebleeding was significantly less in the group who underwent concomitant variceal embolization with TIPS[234].

It is generally accepted that liquid embolic agents should be used along with coils to achieve effective occlusion of the afferent veins as well as the variceal complex and prevent the persistent filling of varices. However, many studies have reported the use of coils alone for embolization[229]. Proximal embolization of the afferent vessels using only coils potentially allows persistent variceal perfusion *via* collaterals and has poor outcomes. Embolization before TIPS insertion allows for better visualization of collateral vessels, which may decompress after shunt creation. Furthermore, a patent TIPS stent represents a potential channel for systemic non-target embolization of misplaced coils or liquid embolic material into the pulmonary circulation.

On the other hand, post-stent embolization allows the operator to determine the effect of PSPG reduction on the filling of varices. It is suggested that the use of extensive adjunctive variceal embolotherapy theoretically allows for the use of a smaller shunt diameter, which may lower rates of post-procedure encephalopathy[229]. However, the embolization of varices may lead to an increase in portal pressure necessitating placement of larger shunt for adequate decompression. Based on current evidence, adjunctive variceal embolization can be considered in patients in whom the target PSPG reduction could not be achieved after TIPS stent placement or when the persistent filling of variceal channels is noted on completion splenoportogram. It is important to note that the completion splenoportogram should be obtained from the catheter tip at the splenic vein near the splenic hilum to optimally assess the presence or absence of variceal filling after TIPS. Pre-existing large spontaneous portosystemic shunts can compete with the antegrade flow in the TIPS stent and theoretically lead to early stent dysfunction in addition to increasing the incidence of HE. While there are no dedicated studies to assess this aspect of TIPS, it is generally accepted that any large accessible portosystemic shunts should be embolized during TIPS.

Post-TIPS HE

The diagnosis and treatment of post-TIPS overt and covert HE is not different from that of HE occurring independently of the procedure. Embolization of any large pre-existing spontaneous portosystemic shunts (if not already embolized during TIPS) is an important step in the management of post TIPS HE. Stent lumen reduction or occlusion is indicated in case of severe persistent overt HE. Unfortunately, complete shunt occlusion with the help of vascular plug, multiple coils, or detachable balloons has often resulted in life-threatening sequelae due to the sudden hemodynamic alterations. Even intentional reversible TIPS stent occlusion using latex balloons kept inflated for up to 48 h carries the risk of recurrent VH and death. To overcome these problems, multiple techniques of stent reduction have been described. Initially, constrained uncovered stents were utilized for shunt reduction. These were either customized or required use of a parallel balloon-expandable stent. However, this technique was limited by inaccurate regulation of blood flow even after the embolization of dead space surrounding the narrowed portion of the stent using coils. Nowadays, stent reduction is almost exclusively done using stent-grafts, which provide a more predictable outcome in terms of blood flow regulation. On-table customization of balloon-expandable stent-grafts into an hourglass configuration using sutures was initially described. Later, Sze *et al*[235] reported a technique of parallel placement of stent graft and balloon-expandable stent within the TIPS stent. The balloon-expandable stent is used to compress the stent-graft, which will determine the flow lumen.

Post TIPS liver failure

Despite its minimally invasive nature, TIPS inevitably cause stress on the liver due to the parenchymal injury and diversion of already compromised portal blood flow. Besides, depending on the location and configuration of the stent, one or more branches of the portal vein or hepatic artery might be obstructed or compressed, resulting in ischemia. Also, the covered portion of TIPS stent can occlude the drainage of one or more hepatic veins leading to venous congestion[236-238]. These can manifest as mild transient derangement of liver functions in the days after TIPS stent placement or liver failure. Studies have shown a two-to-three fold increase in liver enzymes and bilirubin after TIPS, independent of baseline[239,240]. These alterations usually get resolved within 2 wk because of a compensatory increase in hepatic arterial flow, also called as 'hepatic artery buffer response'[239]. However, marked derangement and delayed stabilization of liver functions might be an indicator of irreversible liver injury and liver failure. Bilirubin is an independent predictor of 30-d mortality after TIPS

placement with a 40% increased risk of death for each 1 mg/dL increase above 3.0 mg/dL[241]. Bilirubin levels increased to at least triple the baseline value in approximately 50% of dying patients *vs* only 20% of surviving patients[240]. Similarly, patients with a MELD score of 18 or more have a significantly lower 3-mo survival rate than those with a MELD score of 17 or less[242]. It is recommended that patients with a CTP score > 10 or MELD score > 14 should not have their post-TIPS PSPG reduced to < 5 mmHg[243]. Thus, patients showing a persistent threefold increase in bilirubin after TIPS should be considered to be at risk of liver failure warranting aggressive management, including referral to a transplant center.

Follow-up imaging protocol and shunt revision

No rigorous studies have addressed the issue of optimal follow-up time intervals for doppler surveillance after TIPS, while majority of the centers have anecdotally adopted a strategy of doing doppler ultrasonography at 1, 2, 6 and 12 mo following stent placement and every 6-12 mo after that unless there is the recurrence of symptoms for which TIPS was done (ascites or hydrothorax)[244]. For patients in whom TIPS stent was placed for VH, a stringent doppler follow-up is required because they might not be immediately symptomatic even after shunt dysfunction. Evaluation of stent flow velocities is the primary tool for assessing shunt patency. Normal flow velocities within the stent fall within the range of 90-190 cm/s[245]. A main portal vein velocity below 30 cm/s is another useful parameter[246]. Another recent study found that a greater than 25% interval change in peak TIPS velocity was significantly more sensitive at detecting dysfunction in a covered TIPS stent[247]. If there is a suspicion of in-stent stenosis or occlusion on surveillance Doppler ultrasound, a TIPS venogram and pressure measurements should be carried out.

In-stent stenosis most commonly occurs at the hepatico-caval junction. Multiple studies have shown that angioplasty with the placement of covered stents gives better long term results compared to angioplasty alone[248]. Restenting is also useful in cases of stent shortening or portal venous stenosis. Shunt extension (placement of another stent in the portal venous or hepatic venous end) is used mainly to correct problems with angulation. In cases of chronic stent thrombosis, accessing the stent may be difficult from the transjugular route[249]. Percutaneous transhepatic and trans-splenic routes have been described for obtaining wire access in such cases[249,250]. The transhepatic route requires percutaneously puncturing the midportion of the stent and snaring the wire *via* the internal jugular venous route[249]. For the trans-splenic approach, a small peripheral tributary of the splenic vein is punctured, and the caudal end of the stent is accessed *via* the portal vein[250]. In cases where the primary stent is unsalvageable, placement of a parallel TIPS stent has been described to provide symptomatic relief[251].

CONCLUSION

Transjugular intrahepatic portosystemic shunt placement has been demonstrated to have benefit on the control and recurrence of PH events and transplant free survival in patients with cirrhosis. Nonetheless, various applicability of TIPS among specific subsets of patients with cirrhosis need further validation and thus form prospects for future studies in the form of observation, hypothesis generation and validation in controlled trials. Of these the most important include utility among Child Pugh class B patients with variceal bleeding, role in non-responders to primary prophylaxis with beta blocker therapy and benefits with early use in patients with recurrent ascites who do not fulfil criteria for refractoriness. Other pertinent areas for further research involve the role of TIPS in management of bleeding GV associated with large spontaneous shunts, in hepatopulmonary syndrome as a bridge to liver transplantation and biomarkers to predict post TIPS outcome such as stent dysfunction or death. Furthermore, an exciting area would also be the use of controlled-expansion stents for TIPS placement in those with advanced liver disease and recurrent or uncontrolled PH related complications.

REFERENCES

1 **Rösch J**, Hanafee WN, Snow H. Transjugular portal venography and radiologic portacaval shunt: an experimental study. *Radiology* 1969; **92**: 1112-1114 [PMID: 5771827 DOI: 10.1148/92.5.1112]

2 **Palmaz JC**, Garcia F, Sibbitt RR, Tio FO, Kopp DT, Schwesinger W, Lancaster JL, Chang P. Expandable

intrahepatic portacaval shunt stents in dogs with chronic portal hypertension. *AJR Am J Roentgenol* 1986; **147**: 1251-1254 [PMID: 3490761 DOI: 10.2214/ajr.147.6.1251]

3 **García-Pagán JC**, Caca K, Bureau C, Laleman W, Appenrodt B, Luca A, Abraldes JG, Nevens F, Vinel JP, Mössner J, Bosch J; Early TIPS (Transjugular Intrahepatic Portosystemic Shunt) Cooperative Study Group. Early use of TIPS in patients with cirrhosis and variceal bleeding. *N Engl J Med* 2010; **362**: 2370-2379 [PMID: 20573925 DOI: 10.1056/NEJMoa0910102]

4 **Miraglia R**, Maruzzelli L, Di Piazza A, Mamone G, Caruso S, Gentile G, Tuzzolino F, Floridia G, Petridis I, Volpes R, Luca A. Transjugular Intrahepatic Portosystemic Shunt Using the New Gore Viatorr Controlled Expansion Endoprosthesis: Prospective, Single-Center, Preliminary Experience. *Cardiovasc Intervent Radiol* 2019; **42**: 78-86 [PMID: 30073477 DOI: 10.1007/s00270-018-2040-y]

5 **Coronado WM**, Ju C, Bullen J, Kapoor B. Predictors of Occurrence and Risk of Hepatic Encephalopathy After TIPS Creation: A 15-Year Experience. *Cardiovasc Intervent Radiol* 2020; **43**: 1156-1164 [PMID: 32435836 DOI: 10.1007/s00270-020-02512-7]

6 **D'Amico G**, De Franchis R; Cooperative Study Group. Upper digestive bleeding in cirrhosis. Post-therapeutic outcome and prognostic indicators. *Hepatology* 2003; **38**: 599-612 [PMID: 12939586 DOI: 10.1053/jhep.2003.50385]

7 **Azoulay D**, Castaing D, Majno P, Saliba F, Ichaï P, Smail A, Delvart V, Danaoui M, Samuel D, Bismuth H. Salvage transjugular intrahepatic portosystemic shunt for uncontrolled variceal bleeding in patients with decompensated cirrhosis. *J Hepatol* 2001; **35**: 590-597 [PMID: 11690704 DOI: 10.1016/s0168-8278(01)00185-4]

8 **Augustin S**, Muntaner L, Altamirano JT, González A, Saperas E, Dot J, Abu-Suboh M, Armengol JR, Malagelada JR, Esteban R, Guardia J, Genescà J. Predicting early mortality after acute variceal hemorrhage based on classification and regression tree analysis. *Clin Gastroenterol Hepatol* 2009; **7**: 1347-1354 [PMID: 19699816 DOI: 10.1016/j.cgh.2009.08.011]

9 **Amitrano L**, Guardascione MA, Manguso F, Bennato R, Bove A, DeNucci C, Lombardi G, Martino R, Menchise A, Orsini L, Picascia S, Riccio E. The effectiveness of current acute variceal bleed treatments in unselected cirrhotic patients: refining short-term prognosis and risk factors. *Am J Gastroenterol* 2012; **107**: 1872-1878 [PMID: 23007003 DOI: 10.1038/ajg.2012.313]

10 **Vangeli M**, Patch D, Burroughs AK. Salvage tips for uncontrolled variceal bleeding. *J Hepatol* 2002; **37**: 703-704 [PMID: 12399244 DOI: 10.1016/s0168-8278(02)00321-5]

11 **Maimone S**, Saffioti F, Filomia R, Alibrandi A, Isgrò G, Calvaruso V, Xirouchakis E, Guerrini GP, Burroughs AK, Tsochatzis E, Patch D. Predictors of Re-bleeding and Mortality Among Patients with Refractory Variceal Bleeding Undergoing Salvage Transjugular Intrahepatic Portosystemic Shunt (TIPS). *Dig Dis Sci* 2019; **64**: 1335-1345 [PMID: 30560334 DOI: 10.1007/s10620-018-5412-x]

12 **Moitinho E**, Escorsell A, Bandi JC, Salmerón JM, García-Pagán JC, Rodés J, Bosch J. Prognostic value of early measurements of portal pressure in acute variceal bleeding. *Gastroenterology* 1999; **117**: 626-631 [PMID: 10464138 DOI: 10.1016/s0016-5085(99)70455-5]

13 **Monescillo A**, Martínez-Lagares F, Ruiz-del-Arbol L, Sierra A, Guevara C, Jiménez E, Marrero JM, Buceta E, Sánchez J, Castellot A, Peñate M, Cruz A, Peña E. Influence of portal hypertension and its early decompression by TIPS placement on the outcome of variceal bleeding. *Hepatology* 2004; **40**: 793-801 [PMID: 15382120 DOI: 10.1002/hep.20386]

14 **Garcia-Pagán JC**, Di Pascoli M, Caca K, Laleman W, Bureau C, Appenrodt B, Luca A, Zipprich A, Abraldes JG, Nevens F, Vinel JP, Sauerbruch T, Bosch J. Use of early-TIPS for high-risk variceal bleeding: results of a post-RCT surveillance study. *J Hepatol* 2013; **58**: 45-50 [PMID: 22940408 DOI: 10.1016/j.jhep.2012.08.020]

15 **de Franchis R**; Baveno VI Faculty. Expanding consensus in portal hypertension: Report of the Baveno VI Consensus Workshop: Stratifying risk and individualizing care for portal hypertension. *J Hepatol* 2015; **63**: 743-752 [PMID: 26047908 DOI: 10.1016/j.jhep.2015.05.022]

16 **Deltenre P**, Trépo E, Rudler M, Monescillo A, Fraga M, Denys A, Doerig C, Fournier N, Moreno C, Moradpour D, Bureau C, Thabut D. Early transjugular intrahepatic portosystemic shunt in cirrhotic patients with acute variceal bleeding: a systematic review and meta-analysis of controlled trials. *Eur J Gastroenterol Hepatol* 2015; **27**: e1-e9 [PMID: 26049710 DOI: 10.1097/MEG.0000000000000403]

17 **Conejo I**, Guardascione MA, Tandon P, Cachero A, Castellote J, Abraldes JG, Amitrano L, Genescà J, Augustin S. Multicenter External Validation of Risk Stratification Criteria for Patients With Variceal Bleeding. *Clin Gastroenterol Hepatol* 2018; **16**: 132-139.e8 [PMID: 28501536 DOI: 10.1016/j.cgh.2017.04.042]

18 **Reverter E**, Tandon P, Augustin S, Turon F, Casu S, Bastiampillai R, Keough A, Llop E, González A, Seijo S, Berzigotti A, Ma M, Genescà J, Bosch J, García-Pagán JC, Abraldes JG. A MELD-based model to determine risk of mortality among patients with acute variceal bleeding. *Gastroenterology* 2014; **146**: 412-19.e3 [PMID: 24148622 DOI: 10.1053/j.gastro.2013.10.018]

19 **Lv Y**, Zuo L, Zhu X, Zhao J, Xue H, Jiang Z, Zhuge Y, Zhang C, Sun J, Ding P, Ren W, Li Y, Zhang K, Zhang W, He C, Zhong J, Peng Q, Ma F, Luo J, Zhang M, Wang G, Sun M, Dong J, Bai W, Guo W, Wang Q, Yuan X, Wang Z, Yu T, Luo B, Li X, Yuan J, Han N, Zhu Y, Niu J, Li K, Yin Z, Nie Y, Fan D, Han G. Identifying optimal candidates for early TIPS among patients with cirrhosis and acute variceal bleeding: a multicentre observational study. *Gut* 2019; **68**: 1297-1310 [PMID: 30415233 DOI: 10.1136/gutjnl-2018-317057]

20 **Lv Y**, Yang Z, Liu L, Li K, He C, Wang Z, Bai W, Guo W, Yu T, Yuan X, Zhang H, Xie H, Yao L, Wang J, Li T, Wang Q, Chen H, Wang E, Xia D, Luo B, Li X, Yuan J, Han N, Zhu Y, Niu J, Cai H, Xia J, Yin Z, Wu K, Fan D, Han G; AVB-TIPS Study Group. Early TIPS with covered stents *vs* standard treatment for acute variceal bleeding in patients with advanced cirrhosis: a randomised controlled trial. *Lancet Gastroenterol Hepatol* 2019; **4**: 587-598 [PMID: 31153882 DOI: 10.1016/S2468-1253(19)30090-1]

21 **Dunne PDJ**, Sinha R, Stanley AJ, Lachlan N, Ireland H, Shams A, Kasthuri R, Forrest EH, Hayes PC. Randomised clinical trial: standard of care versus early-transjugular intrahepatic porto-systemic shunt (TIPSS) in patients with cirrhosis and oesophageal variceal bleeding. *Aliment Pharmacol Ther* 2020; **52**: 98-106 [PMID: 31153882 DOI: 10.1016/S2468-1253(19)30090-1]

22 **Tripathi D**, Stanley AJ, Hayes PC, Travis S, Armstrong MJ, Tsochatzis EA, Rowe IA, Roslund N, Ireland H, Lomax M, Leithead JA, Mehrzad H, Aspinall RJ, McDonagh J, Patch D. Transjugular intrahepatic portosystemic stent-shunt in the management of portal hypertension. *Gut* 2020; **69**: 1173-1192 [PMID: 32114503 DOI: 10.1136/gutjnl-2019-320221]

23 **Thabut D**, Pauwels A, Carbonell N, Remy AJ, Nahon P, Causse X, Cervoni JP, Cadranel JF, Archambeaud I, Bramli S, Ehrhard F, Ah-Soune P, Rostain F, Pariente A, Vergniol J, Dupuychaffray JP, Pelletier AL, Skinazi F, Guillygomarc'h A, Vitte RL, Henrion J, Combet S, Rudler M, Bureau C; des Hépato-Gastroentérologues des Hôpitaux Généraux (ANGH); Club Francophone pour l'Etude de l'Hypertension Portale (CFETHTP); CHOC Study Group collaborators:. Cirrhotic patients with portal hypertension-related bleeding and an indication for early-TIPS: a large multicentre audit with real-life results. *J Hepatol* 2017; **68**: 73-81 [PMID: 28918131 DOI: 10.1016/j.jhep.2017.09.002]

24 **Hernández-Gea V**, Procopet B, Giráldez Á, Amitrano L, Villanueva C, Thabut D, Ibañez-Samaniego L, Silva-Junior G, Martinez J, Genescà J, Bureau C, Trebicka J, Llop E, Laleman W, Palazon JM, Castellote J, Rodrigues S, Gluud LL, Noronha Ferreira C, Barcelo R, Cañete N, Rodríguez M, Ferlitsch A, Mundi JL, Gronbaek H, Hernández-Guerra M, Sassatelli R, Dell'Era A, Senzolo M, Abraldes JG, Romero-Gómez M, Zipprich A, Casas M, Masnou H, Primignani M, Krag A, Nevens F, Calleja JL, Jansen C, Robic MA, Conejo I, Catalina MV, Albillos A, Rudler M, Alvarado E, Guardascione MA, Tantau M, Bosch J, Torres F, Garcia-Pagán JC; International Variceal Bleeding Observational Study Group and Baveno Cooperation. Preemptive-TIPS Improves Outcome in High-Risk Variceal Bleeding: An Observational Study. *Hepatology* 2019; **69**: 282-293 [PMID: 30014519 DOI: 10.1002/hep.30182]

25 **Garcia-Tsao G**, Abraldes JG, Berzigotti A, Bosch J. Portal hypertensive bleeding in cirrhosis: Risk stratification, diagnosis, and management: 2016 practice guidance by the American Association for the study of liver diseases. *Hepatology* 2017; **65**: 310-335 [PMID: 27786365 DOI: 10.1002/hep.28906]

26 **Sauerbruch T**, Mengel M, Dollinger M, Zipprich A, Rössle M, Panther E, Wiest R, Caca K, Hoffmeister A, Lutz H, Schoo R, Lorenzen H, Trebicka J, Appenrodt B, Schepke M, Fimmers R; German Study Group for Prophylaxis of Variceal Rebleeding. Prevention of Rebleeding From Esophageal Varices in Patients With Cirrhosis Receiving Small-Diameter Stents Versus Hemodynamically Controlled Medical Therapy. *Gastroenterology* 2015; **149**: 660-8.e1 [PMID: 25989386 DOI: 10.1053/j.gastro.2015.05.011]

27 **Holster IL**, Tjwa ET, Moelker A, Wils A, Hansen BE, Vermeijden JR, Scholten P, van Hoek B, Nicolai JJ, Kuipers EJ, Pattynama PM, van Buuren HR. Covered transjugular intrahepatic portosystemic shunt *vs* endoscopic therapy + β-blocker for prevention of variceal rebleeding. *Hepatology* 2016; **63**: 581-589 [PMID: 26517576 DOI: 10.1002/hep.28318]

28 **Luo X**, Wang Z, Tsauo J, Zhou B, Zhang H, Li X. Advanced Cirrhosis Combined with Portal Vein Thrombosis: A Randomized Trial of TIPS *vs* Endoscopic Band Ligation Plus Propranolol for the Prevention of Recurrent Esophageal Variceal Bleeding. *Radiology* 2015; **276**: 286-293 [PMID: 25759969 DOI: 10.1148/radiol.15141252]

29 **Lv Y**, Qi X, He C, Wang Z, Yin Z, Niu J, Guo W, Bai W, Zhang H, Xie H, Yao L, Wang J, Li T, Wang Q, Chen H, Liu H, Wang E, Xia D, Luo B, Li X, Yuan J, Han N, Zhu Y, Xia J, Cai H, Yang Z, Wu K, Fan D, Han G; PVT-TIPS Study Group. Covered TIPS *vs* endoscopic band ligation plus propranolol for the prevention of variceal rebleeding in cirrhotic patients with portal vein thrombosis: a randomised controlled trial. *Gut* 2018; **67**: 2156-2168 [PMID: 28970291 DOI: 10.1136/gutjnl-2017-314634]

30 **Philips CA**, Rajesh S, George T, Betgeri SS, Mohanan M, Augustine P. Transjugular-intrahepatic-portosystemic shunt placement at first portal hypertensive decompensation (very-early or 'anticipant tips') compared to conventional tips and standard medical treatment in patients with cirrhosis. *Gastroenterology* 2020; **158**: S-128 [DOI: 10.1016/S0016-5085(20)33907-X]

31 **Sarin SK**, Lahoti D, Saxena SP, Murthy NS, Makwana UK. Prevalence, classification and natural history of gastric varices: a long-term follow-up study in 568 portal hypertension patients. *Hepatology* 1992; **16**: 1343-1349 [PMID: 1446890 DOI: 10.1002/hep.1840160607]

32 **Lipnik AJ**, Pandhi MB, Khabbaz RC, Gaba RC. Endovascular Treatment for Variceal Hemorrhage: TIPS, BRTO, and Combined Approaches. *Semin Intervent Radiol* 2018; **35**: 169-184 [PMID: 30087520 DOI: 10.1055/s-0038-1660795]

33 **Morrison JD**, Mendoza-Elias N, Lipnik AJ, Lokken RP, Bui JT, Ray CE Jr, Gaba RC. Gastric Varices Bleed at Lower Portosystemic Pressure Gradients than Esophageal Varices. *J Vasc Interv Radiol* 2018; **29**: 636-641 [PMID: 29352698 DOI: 10.1016/j.jvir.2017.10.014]

34 **Khoury T**, Massarwa M, Daher S, Benson AA, Hazou W, Israeli E, Jacob H, Epstein J, Safadi R. Endoscopic Ultrasound-Guided Angiotherapy for Gastric Varices: A Single Center Experience. *Hepatol Commun* 2019; **3**: 207-212 [PMID: 30766958 DOI: 10.1002/hep4.1289]

35 **Saad WE**, Darcy MD. Transjugular Intrahepatic Portosystemic Shunt (TIPS) *vs* Balloon-occluded Retrograde Transvenous Obliteration (BRTO) for the Management of Gastric Varices. *Semin Intervent Radiol* 2011; **28**: 339-349 [PMID: 22942552 DOI: 10.1055/s-0031-1284461]

36 **Saad WE**. Vascular anatomy and the morphologic and hemodynamic classifications of gastric varices and spontaneous portosystemic shunts relevant to the BRTO procedure. *Tech Vasc Interv Radiol* 2013; **16**: 60-100 [PMID: 23830670 DOI: 10.1053/j.tvir.2013.02.002]

37 **Lakhoo J**, Bui JT, Lokken RP, Ray CE Jr, Gaba RC. Transjugular Intrahepatic Portosystemic Shunt Creation and Variceal Coil or Plug Embolization Ineffectively Attain Gastric Variceal Decompression or Occlusion: Results of a 26-Patient Retrospective Study. *J Vasc Interv Radiol* 2016; **27**: 1001-1011 [PMID: 27106732 DOI: 10.1016/j.jvir.2016.02.019]

38 **Park JK**, Saab S, Kee ST, Busuttil RW, Kim HJ, Durazo F, Cho SK, Lee EW. Balloon-Occluded Retrograde Transvenous Obliteration (BRTO) for Treatment of Gastric Varices: Review and Meta-Analysis. *Dig Dis Sci* 2015; **60**: 1543-1553 [PMID: 25519690 DOI: 10.1007/s10620-014-3485-8]

39 **Cho SK**, Shin SW, Lee IH, Do YS, Choo SW, Park KB, Yoo BC. Balloon-occluded retrograde transvenous obliteration of gastric varices: outcomes and complications in 49 patients. *AJR Am J Roentgenol* 2007; **189**: W365-W372 [PMID: 18029851 DOI: 10.2214/AJR.07.2266]

40 **Fukuda T**, Hirota S, Sugimura K. Long-term results of balloon-occluded retrograde transvenous

obliteration for the treatment of gastric varices and hepatic encephalopathy. *J Vasc Interv Radiol* 2001; **12**: 327-336 [PMID: 11287510 DOI: 10.1016/s1051-0443(07)61912-5]

41 **Kumamoto M**, Toyonaga A, Inoue H, Miyakoda K, Morita Y, Emori K, Sakamoto Y, Oho K, Sata M. Long-term results of balloon-occluded retrograde transvenous obliteration for gastric fundal varices: hepatic deterioration links to portosystemic shunt syndrome. *J Gastroenterol Hepatol* 2010; **25**: 1129-1135 [PMID: 20594229 DOI: 10.1111/j.1440-1746.2010.06262.x]

42 **Philips CA**, Rajesh S, Augustine P, Padsalgi G, Ahamed R. Portosystemic shunts and refractory hepatic encephalopathy: patient selection and current options. *Hepat Med* 2019; **11**: 23-34 [PMID: 30774483 DOI: 10.2147/HMER.S169024]

43 **Choi YH**, Yoon CJ, Park JH, Chung JW, Kwon JW, Choi GM. Balloon-occluded retrograde transvenous obliteration for gastric variceal bleeding: its feasibility compared with transjugular intrahepatic portosystemic shunt. *Korean J Radiol* 2003; **4**: 109-116 [PMID: 12845306 DOI: 10.3348/kjr.2003.4.2.109]

44 **Kim SK**, Lee KA, Sauk S, Korenblat K. Comparison of Transjugular Intrahepatic Portosystemic Shunt with Covered Stent and Balloon-Occluded Retrograde Transvenous Obliteration in Managing Isolated Gastric Varices. *Korean J Radiol* 2017; **18**: 345-354 [PMID: 28246514 DOI: 10.3348/kjr.2017.18.2.345]

45 **Ninoi T**, Nakamura K, Kaminou T, Nishida N, Sakai Y, Kitayama T, Hamuro M, Yamada R, Arakawa T, Inoue Y. TIPS *vs* transcatheter sclerotherapy for gastric varices. *AJR Am J Roentgenol* 2004; **183**: 369-376 [PMID: 15269027 DOI: 10.2214/ajr.183.2.1830369]

46 **Sabri SS**, Abi-Jaoudeh N, Swee W, Saad WE, Turba UC, Caldwell SH, Angle JF, Matsumoto AH. Short-term rebleeding rates for isolated gastric varices managed by transjugular intrahepatic portosystemic shunt *vs* balloon-occluded retrograde transvenous obliteration. *J Vasc Interv Radiol* 2014; **25**: 355-361 [PMID: 24468043 DOI: 10.1016/j.jvir.2013.12.001]

47 **Helmy A**, Al Kahtani K, Al Fadda M. Updates in the pathogenesis, diagnosis and management of ectopic varices. *Hepatol Int* 2008; **2**: 322-334 [PMID: 19669261 DOI: 10.1007/s12072-008-9074-1]

48 **Norton ID**, Andrews JC, Kamath PS. Management of ectopic varices. *Hepatology* 1998; **28**: 1154-1158 [PMID: 9755256 DOI: 10.1002/hep.510280434]

49 **Lebrec D**, Benhamou JP. Ectopic varices in portal hypertension. *Clin Gastroenterol* 1985; **14**: 105-121 [PMID: 3872747]

50 **Oey RC**, de Wit K, Moelker A, Atalik T, van Delden OM, Maleux G, Erler NS, Takkenberg RB, de Man RA, Nevens F, van Buuren HR. Variable efficacy of TIPSS in the management of ectopic variceal bleeding: a multicentre retrospective study. *Aliment Pharmacol Ther* 2018; **48**: 975-983 [PMID: 30136292 DOI: 10.1111/apt.14947]

51 **Vangeli M**, Patch D, Terreni N, Tibballs J, Watkinson A, Davies N, Burroughs AK. Bleeding ectopic varices--treatment with transjugular intrahepatic porto-systemic shunt (TIPS) and embolisation. *J Hepatol* 2004; **41**: 560-566 [PMID: 15464235 DOI: 10.1016/j.jhep.2004.06.024]

52 **Vidal V**, Joly L, Perreault P, Bouchard L, Lafortune M, Pomier-Layrargues G. Usefulness of transjugular intrahepatic portosystemic shunt in the management of bleeding ectopic varices in cirrhotic patients. *Cardiovasc Intervent Radiol* 2006; **29**: 216-219 [PMID: 16284702 DOI: 10.1007/s00270-004-0346-4]

53 **Shibata D**, Brophy DP, Gordon FD, Anastopoulos HT, Sentovich SM, Bleday R. Transjugular intrahepatic portosystemic shunt for treatment of bleeding ectopic varices with portal hypertension. *Dis Colon Rectum* 1999; **42**: 1581-1585 [PMID: 10613477 DOI: 10.1007/BF02236211]

54 **Kochar N**, Tripathi D, McAvoy NC, Ireland H, Redhead DN, Hayes PC. Bleeding ectopic varices in cirrhosis: the role of transjugular intrahepatic portosystemic stent shunts. *Aliment Pharmacol Ther* 2008; **28**: 294-303 [PMID: 19086235 DOI: 10.1111/j.1365-2036.2008.03719.x]

55 **Miller LS**, Kim JK, Dai Q, Mekapati J, Izanec J, Chung C, Liu JB, Sanderson A, Bohning M, Desipio J, Gandegok J, Harberson JJ, Schneck C, Nicosia MA, Thangada V, Thomas B, Copeland B, Miller E, Miller A, Ahmed N, Brasseur JG. Mechanics and hemodynamics of esophageal varices during peristaltic contraction. *Am J Physiol Gastrointest Liver Physiol* 2004; **287**: G830-G835 [PMID: 15361363 DOI: 10.1152/ajpgi.00015.2004]

56 **Arakawa M**, Masuzaki T, Okuda K. Pathomorphology of esophageal and gastric varices. *Semin Liver Dis* 2002; **22**: 73-82 [PMID: 11928080 DOI: 10.1055/s-2002-23208]

57 **Perricone G**, Vangeli M, De Nicola S, Airoldi A, Belli LS. Adding embolization to TIPS implantation: A better therapy to control bleeding from ectopic varices? *J Hepatol* 2017; **67**: 200-201 [PMID: 28347802 DOI: 10.1016/j.jhep.2017.03.016]

58 **Thuluvath PJ**, Yoo HY. Portal Hypertensive gastropathy. *Am J Gastroenterol* 2002; **97**: 2973-2978 [PMID: 12492178 DOI: 10.1111/j.1572-0241.2002.07094.x]

59 **Sarin SK**, Misra SP, Singal A, Thorat V, Broor SL. Evaluation of the incidence and significance of the "mosaic pattern" in patients with cirrhosis, noncirrhotic portal fibrosis, and extrahepatic obstruction. *Am J Gastroenterol* 1988; **83**: 1235-1239 [PMID: 3263791]

60 **D'Amico G**, Montalbano L, Traina M, Pisa R, Menozzi M, Spanò C, Pagliaro L. Natural history of congestive gastropathy in cirrhosis. The Liver Study Group of V. Cervello Hospital. *Gastroenterology* 1990; **99**: 1558-1564 [PMID: 2227271 DOI: 10.1016/0016-5085(90)90458-d]

61 **Merli M**, Nicolini G, Angeloni S, Gentili F, Attili AF, Riggio O. The natural history of portal hypertensive gastropathy in patients with liver cirrhosis and mild portal hypertension. *Am J Gastroenterol* 2004; **99**: 1959-1965 [PMID: 15447756 DOI: 10.1111/j.1572-0241.2004.40246.x]

62 **Iwao T**, Toyonaga A, Sumino M, Takagi K, Oho K, Nishizono M, Ohkubo K, Inoue R, Sasaki E, Tanikawa K. Portal hypertensive gastropathy in patients with cirrhosis. *Gastroenterology* 1992; **102**: 2060-2065 [PMID: 1587424 DOI: 10.1016/0016-5085(92)90332-s]

63 **Perini RF**, Camara PR, Ferraz JG. Pathogenesis of portal hypertensive gastropathy: translating basic research into clinical practice. *Nat Clin Pract Gastroenterol Hepatol* 2009; **6**: 150-158 [PMID: 19190600 DOI: 10.1038/ncpgasthep1356]

64 **Ferraz JG**, Wallace JL. Underlying mechanisms of portal hypertensive gastropathy. *J Clin Gastroenterol* 1997; **25** Suppl 1: S73-S78 [PMID: 9479629 DOI: 10.1097/00004836-199700001-00012]

65 **Hosking SW**, Kennedy HJ, Seddon I, Triger DR. The role of propranolol in congestive gastropathy of

portal hypertension. *Hepatology* 1987; **7**: 437-441 [PMID: 3552921 DOI: 10.1002/hep.1840070304]
66 **Zhou Y**, Qiao L, Wu J, Hu H, Xu C. Comparison of the efficacy of octreotide, vasopressin, and omeprazole in the control of acute bleeding in patients with portal hypertensive gastropathy: a controlled study. *J Gastroenterol Hepatol* 2002; **17**: 973-979 [PMID: 12167118 DOI: 10.1046/j.1440-1746.2002.02775.x]
67 **Kawanaka H**, Tomikawa M, Jones MK, Szabo IL, Pai R, Baatar D, Tsugawa K, Sugimachi K, Sarfeh IJ, Tarnawski AS. Defective mitogen-activated protein kinase (ERK2) signaling in gastric mucosa of portal hypertensive rats: potential therapeutic implications. *Hepatology* 2001; **34**: 990-999 [PMID: 11679970 DOI: 10.1053/jhep.2001.28507]
68 **Karajeh MA**, Hurlstone DP, Stephenson TJ, Ray-Chaudhuri D, Gleeson DC. Refractory bleeding from portal hypertensive gastropathy: a further novel role for thalidomide therapy? *Eur J Gastroenterol Hepatol* 2006; **18**: 545-548 [PMID: 16607153 DOI: 10.1097/00042737-200605000-00016]
69 **Urata J**, Yamashita Y, Tsuchigame T, Hatanaka Y, Matsukawa T, Sumi S, Matsuno Y, Takahashi M. The effects of transjugular intrahepatic portosystemic shunt on portal hypertensive gastropathy. *J Gastroenterol Hepatol* 1998; **13**: 1061-1067 [PMID: 9835325 DOI: 10.1111/j.1440-1746.1998.tb00571.x]
70 **Mezawa S**, Homma H, Ohta H, Masuko E, Doi T, Miyanishi K, Takada K, Kukitsu T, Sato T, Niitsu Y. Effect of transjugular intrahepatic portosystemic shunt formation on portal hypertensive gastropathy and gastric circulation. *Am J Gastroenterol* 2001; **96**: 1155-1159 [PMID: 11316163 DOI: 10.1111/j.1572-0241.2001.03694.x]
71 **Kamath PS**, Lacerda M, Ahlquist DA, McKusick MA, Andrews JC, Nagorney DA. Gastric mucosal responses to intrahepatic portosystemic shunting in patients with cirrhosis. *Gastroenterology* 2000; **118**: 905-911 [PMID: 10784589 DOI: 10.1016/S0016-5085(00)70176-4]
72 **Burak KW**, Lee SS, Beck PL. Portal hypertensive gastropathy and gastric antral vascular ectasia (GAVE) syndrome. *Gut* 2001; **49**: 866-872 [PMID: 11709525 DOI: 10.1136/gut.49.6.866]
73 **Patwardhan VR**, Cardenas A. Review article: the management of portal hypertensive gastropathy and gastric antral vascular ectasia in cirrhosis. *Aliment Pharmacol Ther* 2014; **40**: 354-362 [PMID: 24889902 DOI: 10.1111/apt.12824]
74 **Ginés P**, Quintero E, Arroyo V, Terés J, Bruguera M, Rimola A, Caballería J, Rodés J, Rozman C. Compensated cirrhosis: natural history and prognostic factors. *Hepatology* 1987; **7**: 122-128 [PMID: 3804191 DOI: 10.1002/hep.1840070124]
75 **D'Amico G**, Garcia-Tsao G, Pagliaro L. Natural history and prognostic indicators of survival in cirrhosis: a systematic review of 118 studies. *J Hepatol* 2006; **44**: 217-231 [PMID: 16298014 DOI: 10.1016/j.jhep.2005.10.013]
76 **European Association for the Study of the Liver**. EASL Clinical Practice Guidelines for the management of patients with decompensated cirrhosis. *J Hepatol* 2018; **69**: 406-460 [PMID: 29653741 DOI: 10.1016/j.jhep.2018.03.024]
77 **Arroyo V**, Ginès P, Gerbes AL, Dudley FJ, Gentilini P, Laffi G, Reynolds TB, Ring-Larsen H, Schölmerich J. Definition and diagnostic criteria of refractory ascites and hepatorenal syndrome in cirrhosis. International Ascites Club. *Hepatology* 1996; **23**: 164-176 [PMID: 8550036 DOI: 10.1002/hep.510230122]
78 **Moore KP**, Wong F, Gines P, Bernardi M, Ochs A, Salerno F, Angeli P, Porayko M, Moreau R, Garcia-Tsao G, Jimenez W, Planas R, Arroyo V. The management of ascites in cirrhosis: report on the consensus conference of the International Ascites Club. *Hepatology* 2003; **38**: 258-266 [PMID: 12830009 DOI: 10.1053/jhep.2003.50315]
79 **Lebrec D**, Giuily N, Hadengue A, Vilgrain V, Moreau R, Poynard T, Gadano A, Lassen C, Benhamou JP, Erlinger S. Transjugular intrahepatic portosystemic shunts: comparison with paracentesis in patients with cirrhosis and refractory ascites: a randomized trial. French Group of Clinicians and a Group of Biologists. *J Hepatol* 1996; **25**: 135-144 [PMID: 8878773 DOI: 10.1016/s0168-8278(96)80065-1]
80 **Rössle M**, Ochs A, Gülberg V, Siegerstetter V, Holl J, Deibert P, Olschewski M, Reiser M, Gerbes AL. A comparison of paracentesis and transjugular intrahepatic portosystemic shunting in patients with ascites. *N Engl J Med* 2000; **342**: 1701-1707 [PMID: 10841872 DOI: 10.1056/NEJM200006083422303]
81 **Ginès P**, Uriz J, Calahorra B, Garcia-Tsao G, Kamath PS, Del Arbol LR, Planas R, Bosch J, Arroyo V, Rodés J. Transjugular intrahepatic portosystemic shunting *vs* paracentesis plus albumin for refractory ascites in cirrhosis. *Gastroenterology* 2002; **123**: 1839-1847 [PMID: 12454841 DOI: 10.1053/gast.2002.37073]
82 **Sanyal AJ**, Genning C, Reddy KR, Wong F, Kowdley KV, Benner K, McCashland T; North American Study for the Treatment of Refractory Ascites Group. The North American Study for the Treatment of Refractory Ascites. *Gastroenterology* 2003; **124**: 634-641 [PMID: 12612902 DOI: 10.1053/gast.2003.50088]
83 **Salerno F**, Merli M, Riggio O, Cazzaniga M, Valeriano V, Pozzi M, Nicolini A, Salvatori F. Randomized controlled study of TIPS *vs* paracentesis plus albumin in cirrhosis with severe ascites. *Hepatology* 2004; **40**: 629-635 [PMID: 15349901 DOI: 10.1002/hep.20364]
84 **Albillos A**, Bañares R, González M, Catalina MV, Molinero LM. A meta-analysis of transjugular intrahepatic portosystemic shunt *vs* paracentesis for refractory ascites. *J Hepatol* 2005; **43**: 990-996 [PMID: 16139922 DOI: 10.1016/j.jhep.2005.06.005]
85 **D'Amico G**, Luca A, Morabito A, Miraglia R, D'Amico M. Uncovered transjugular intrahepatic portosystemic shunt for refractory ascites: a meta-analysis. *Gastroenterology* 2005; **129**: 1282-1293 [PMID: 16230081 DOI: 10.1053/j.gastro.2005.07.031]
86 **Deltenre P**, Mathurin P, Dharancy S, Moreau R, Bulois P, Henrion J, Pruvot FR, Ernst O, Paris JC, Lebrec D. Transjugular intrahepatic portosystemic shunt in refractory ascites: a meta-analysis. *Liver Int* 2005; **25**: 349-356 [PMID: 15780061 DOI: 10.1111/j.1478-3231.2005.01095.x]
87 **Salerno F**, Cammà C, Enea M, Rössle M, Wong F. Transjugular intrahepatic portosystemic shunt for refractory ascites: a meta-analysis of individual patient data. *Gastroenterology* 2007; **133**: 825-834 [PMID: 17678653 DOI: 10.1053/j.gastro.2007.06.020]
88 **Narahara Y**, Kanazawa H, Fukuda T, Matsushita Y, Harimoto H, Kidokoro H, Katakura T, Atsukawa M, Taki Y, Kimura Y, Nakatsuka K, Sakamoto C. Transjugular intrahepatic portosystemic shunt *vs* paracentesis plus albumin in patients with refractory ascites who have good hepatic and renal function: a

prospective randomized trial. *J Gastroenterol* 2011; **46**: 78-85 [PMID: 20632194 DOI: 10.1007/s00535-010-0282-9]

89 **Bai M**, Qi XS, Yang ZP, Yang M, Fan DM, Han GH. TIPS improves liver transplantation-free survival in cirrhotic patients with refractory ascites: an updated meta-analysis. *World J Gastroenterol* 2014; **20**: 2704-2714 [PMID: 24627607 DOI: 10.3748/wjg.v20.i10.2704]

90 **Maleux G**, Perez-Gutierrez NA, Evrard S, Mroue A, Le Moine O, Laleman W, Nevens F. Covered stents are better than uncovered stents for transjugular intrahepatic portosystemic shunts in cirrhotic patients with refractory ascites: a retrospective cohort study. *Acta Gastroenterol Belg* 2010; **73**: 336-341 [PMID: 21086935]

91 **Tan HK**, James PD, Sniderman KW, Wong F. Long-term clinical outcome of patients with cirrhosis and refractory ascites treated with transjugular intrahepatic portosystemic shunt insertion. *J Gastroenterol Hepatol* 2015; **30**: 389-395 [PMID: 25168607 DOI: 10.1111/jgh.12725]

92 **Bureau C**, Thabut D, Oberti F, Dharancy S, Carbonell N, Bouvier A, Mathurin P, Otal P, Cabarrou P, Péron JM, Vinel JP. Transjugular Intrahepatic Portosystemic Shunts With Covered Stents Increase Transplant-Free Survival of Patients With Cirrhosis and Recurrent Ascites. *Gastroenterology* 2017; **152**: 157-163 [PMID: 27663604 DOI: 10.1053/j.gastro.2016.09.016]

93 **Bucsics T**, Hoffman S, Grünberger J, Schoder M, Matzek W, Stadlmann A, Mandorfer M, Schwabl P, Ferlitsch A, Peck-Radosavljevic M, Trauner M, Karner J, Karnel F, Reiberger T. ePTFE-TIPS *vs* repetitive LVP plus albumin for the treatment of refractory ascites in patients with cirrhosis. *Liver Int* 2018; **38**: 1036-1044 [PMID: 29091351 DOI: 10.1111/liv.13615]

94 **Riggio O**, Ridola L, Angeloni S, Cerini F, Pasquale C, Attili AF, Fanelli F, Merli M, Salvatori FM. Clinical efficacy of transjugular intrahepatic portosystemic shunt created with covered stents with different diameters: results of a randomized controlled trial. *J Hepatol* 2010; **53**: 267-272 [PMID: 20537753 DOI: 10.1016/j.jhep.2010.02.033]

95 **Miraglia R**, Maruzzelli L, Tuzzolino F, Petridis I, D'Amico M, Luca A. Transjugular Intrahepatic Portosystemic Shunts in Patients with Cirrhosis with Refractory Ascites: Comparison of Clinical Outcomes by Using 8- and 10-mm PTFE-covered Stents. *Radiology* 2017; **284**: 281-288 [PMID: 28121521 DOI: 10.1148/radiol.2017161644]

96 **Salerno F**, Merli M, Cazzaniga M, Valeriano V, Rossi P, Lovaria A, Meregaglia D, Nicolini A, Lubatti L, Riggio O. MELD score is better than Child-Pugh score in predicting 3-month survival of patients undergoing transjugular intrahepatic portosystemic shunt. *J Hepatol* 2002; **36**: 494-500 [PMID: 11943420 DOI: 10.1016/s0168-8278(01)00309-9]

97 **Schepke M**, Roth F, Fimmers R, Brensing KA, Sudhop T, Schild HH, Sauerbruch T. Comparison of MELD, Child-Pugh, and Emory model for the prediction of survival in patients undergoing transjugular intrahepatic portosystemic shunting. *Am J Gastroenterol* 2003; **98**: 1167-1174 [PMID: 12809844 DOI: 10.1111/j.1572-0241.2003.07515.x]

98 **Spengler EK**, Hunsicker LG, Zarei S, Zimmerman MB, Voigt MD. Transjugular intrahepatic portosystemic shunt does not independently increase risk of death in high model for end stage liver disease patients. *Hepatol Commun* 2017; **1**: 460-468 [PMID: 29404473 DOI: 10.1002/hep4.1053]

99 **Ronald J**, Rao R, Choi SS, Kappus M, Martin JG, Sag AA, Pabon-Ramos WM, Suhocki PV, Smith TP, Kim CY. No Increased Mortality After TIPS Compared with Serial Large Volume Paracenteses in Patients with Higher Model for End-Stage Liver Disease Score and Refractory Ascites. *Cardiovasc Intervent Radiol* 2019; **42**: 720-728 [PMID: 30603968 DOI: 10.1007/s00270-018-02155-9]

100 **Montgomery A**, Ferral H, Vasan R, Postoak DW. MELD score as a predictor of early death in patients undergoing elective transjugular intrahepatic portosystemic shunt (TIPS) procedures. *Cardiovasc Intervent Radiol* 2005; **28**: 307-312 [PMID: 15886944 DOI: 10.1007/s00270-004-0145-y]

101 **Gaba RC**, Couture PM, Bui JT, Knuttinen MG, Walzer NM, Kallwitz ER, Berkes JL, Cotler SJ. Prognostic capability of different liver disease scoring systems for prediction of early mortality after transjugular intrahepatic portosystemic shunt creation. *J Vasc Interv Radiol* 2013; **24**: 411-420, 420.e1-4; quiz 421 [PMID: 23312989 DOI: 10.1016/j.jvir.2012.10.026]

102 **Bureau C**, Métivier S, D'Amico M, Péron JM, Otal P, Pagan JC, Chabbert V, Chagneau-Derrode C, Procopet B, Rousseau H, Bosch J, Vinel JP. Serum bilirubin and platelet count: a simple predictive model for survival in patients with refractory ascites treated by TIPS. *J Hepatol* 2011; **54**: 901-907 [PMID: 21145798 DOI: 10.1016/j.jhep.2010.08.025]

103 **Piecha F**, Radunski UK, Ozga AK, Steins D, Drolz A, Horvatits T, Spink C, Ittrich H, Benten D, Lohse AW, Sinning C, Kluwe J. Ascites control by TIPS is more successful in patients with a lower paracentesis frequency and is associated with improved survival. *JHEP Rep* 2019; **1**: 90-98 [PMID: 32039356 DOI: 10.1016/j.jhepr.2019.04.001]

104 **Tonon M**, Piano S, Gambino CG, Romano A, Pilutti C, Incicco S, Brocca A, Sticca A, Bolognesi M, Angeli P. Outcomes and Mortality of Grade 1 Ascites and Recurrent Ascites in Patients With Cirrhosis. *Clin Gastroenterol Hepatol* 2020 [PMID: 32272250 DOI: 10.1016/j.cgh.2020.03.065]

105 **Cardenas A**, Kelleher T, Chopra S. Review article: hepatic hydrothorax. *Aliment Pharmacol Ther* 2004; **20**: 271-279 [PMID: 15274663 DOI: 10.1111/j.1365-2036.2004.02081.x]

106 **Xiol X**, Guardiola J. Hepatic hydrothorax. *Curr Opin Pulm Med* 1998; **4**: 239-242 [PMID: 10813241 DOI: 10.1097/00063198-199807000-00011]

107 **Surani SR**, Mendez Y, Anjum H, Varon J. Pulmonary complications of hepatic diseases. *World J Gastroenterol* 2016; **22**: 6008-6015 [PMID: 27468192 DOI: 10.3748/wjg.v22.i26.6008]

108 **Rössle M**, Gerbes AL. TIPS for the treatment of refractory ascites, hepatorenal syndrome and hepatic hydrothorax: a critical update. *Gut* 2010; **59**: 988-1000 [PMID: 20581246 DOI: 10.1136/gut.2009.193227]

109 **Dhanasekaran R**, West JK, Gonzales PC, Subramanian R, Parekh S, Spivey JR, Martin LG, Kim HS. Transjugular intrahepatic portosystemic shunt for symptomatic refractory hepatic hydrothorax in patients with cirrhosis. *Am J Gastroenterol* 2010; **105**: 635-641 [PMID: 19904245 DOI: 10.1038/ajg.2009.634]

110 **Ditah IC**, Al Bawardy BF, Saberi B, Ditah C, Kamath PS. Transjugular intrahepatic portosystemic stent shunt for medically refractory hepatic hydrothorax: A systematic review and cumulative meta-analysis. *World J Hepatol* 2015; **7**: 1797-1806 [PMID: 26167253 DOI: 10.4254/wjh.v7.i13.1797]

111 **Jindal A**, Mukund A, Kumar G, Sarin SK. Efficacy and safety of transjugular intrahepatic portosystemic shunt in difficult-to-manage hydrothorax in cirrhosis. *Liver Int* 2019; **39**: 2164-2173 [PMID: 31356712 DOI: 10.1111/liv.14200]

112 **Rector WG Jr**. Spontaneous chylous ascites of cirrhosis. *J Clin Gastroenterol* 1984; **6**: 369-372 [PMID: 6481122]

113 **Cárdenas A**, Chopra S. Chylous ascites. *Am J Gastroenterol* 2002; **97**: 1896-1900 [PMID: 12190151 DOI: 10.1111/j.1572-0241.2002.05911.x]

114 **Romero S**, Martín C, Hernandez L, Verdu J, Trigo C, Perez-Mateo M, Alemany L. Chylothorax in cirrhosis of the liver: analysis of its frequency and clinical characteristics. *Chest* 1998; **114**: 154-159 [PMID: 9674463 DOI: 10.1378/chest.114.1.154]

115 **Maldonado F**, Hawkins FJ, Daniels CE, Doerr CH, Decker PA, Ryu JH. Pleural fluid characteristics of chylothorax. *Mayo Clin Proc* 2009; **84**: 129-133 [PMID: 19181646 DOI: 10.1016/S0025-6196(11)60820-3]

116 **Staats BA**, Ellefson RD, Budahn LL, Dines DE, Prakash UB, Offord K. The lipoprotein profile of chylous and nonchylous pleural effusions. *Mayo Clin Proc* 1980; **55**: 700-704 [PMID: 7442324]

117 **Berzigotti A**, Magalotti D, Cocci C, Angeloni L, Pironi L, Zoli M. Octreotide in the outpatient therapy of cirrhotic chylous ascites: a case report. *Dig Liver Dis* 2006; **38**: 138-142 [PMID: 16389001 DOI: 10.1016/j.dld.2005.05.013]

118 **Chen J**, Lin RK, Hassanein T. Use of orlistat (xenical) to treat chylous ascites. *J Clin Gastroenterol* 2005; **39**: 831-833 [PMID: 16145348 DOI: 10.1097/01.mcg.0000177232.51888.2e]

119 **Rosser BG**, Poterucha JJ, McKusick MA, Kamath PS. Thoracic duct-cutaneous fistula in a patient with cirrhosis of the liver: successful treatment with a transjugular intrahepatic portosystemic shunt. *Mayo Clin Proc* 1996; **71**: 793-796 [PMID: 8691901 DOI: 10.1016/S0025-6196(11)64845-3]

120 **Vignaux O**, Gouya H, Dousset B, Mazuir E, Buffet C, Calmus Y, Legmann P. Refractory chylothorax in hepatic cirrhosis: successful treatment by transjugular intrahepatic portosystemic shunt. *J Thorac Imaging* 2002; **17**: 233-236 [PMID: 12082377 DOI: 10.1097/00005382-200207000-00010]

121 **Kinney TB**, Ferrara SL, Miller FJ, Roberts AC, Hassanein T. Transjugular intrahepatic portosystemic shunt creation as treatment for refractory chylous ascites and chylothorax in a patient with cirrhosis. *J Vasc Interv Radiol* 2004; **15**: 85-89 [PMID: 14709693 DOI: 10.1097/01.rvi.0000106391.63463.4c]

122 **de Vries GJ**, Ryan BM, de Bièvre M, Driessen A, Stockbrugger RW, Koek GH. Cirrhosis related chylous ascites successfully treated with TIPS. *Eur J Gastroenterol Hepatol* 2005; **17**: 463-466 [PMID: 15756102 DOI: 10.1097/00042737-200504000-00013]

123 **Lutz P**, Strunk H, Schild HH, Sauerbruch T. Transjugular intrahepatic portosystemic shunt in refractory chylothorax due to liver cirrhosis. *World J Gastroenterol* 2013; **19**: 1140-1142 [PMID: 23467463 DOI: 10.3748/wjg.v19.i7.1140]

124 **Kikolski SG**, Aryafar H, Rose SC, Roberts AC, Kinney TB. Transjugular intrahepatic portosystemic shunt for treatment of cirrhosis-related chylothorax and chylous ascites: single-institution retrospective experience. *Cardiovasc Intervent Radiol* 2013; **36**: 992-997 [PMID: 23207657 DOI: 10.1007/s00270-012-0530-x]

125 **Tsauo J**, Shin JH, Han K, Yoon HK, Ko GY, Ko HK, Gwon DI. Transjugular Intrahepatic Portosystemic Shunt for the Treatment of Chylothorax and Chylous Ascites in Cirrhosis: A Case Report and Systematic Review of the Literature. *J Vasc Interv Radiol* 2016; **27**: 112-116 [PMID: 26723922 DOI: 10.1016/j.jvir.2015.09.022]

126 **Khaliq MF**, Noorani MM, Chowdhry M, Mohamed H, Koirala A. Transjugular Intrahepatic Portosystemic Shunt (TIPS) in Refractory Transudative Chylothorax due to Liver Cirrhosis. *Case Rep Med* 2020; **2020**: 2581040 [PMID: 32089702 DOI: 10.1155/2020/2581040]

127 **Zocco MA**, Di Stasio E, De Cristofaro R, Novi M, Ainora ME, Ponziani F, Riccardi L, Lancellotti S, Santoliquido A, Flore R, Pompili M, Rapaccini GL, Tondi P, Gasbarrini GB, Landolfi R, Gasbarrini A. Thrombotic risk factors in patients with liver cirrhosis: correlation with MELD scoring system and portal vein thrombosis development. *J Hepatol* 2009; **51**: 682-689 [PMID: 19464747 DOI: 10.1016/j.jhep.2009.03.013]

128 **Rodríguez-Castro KI**, Porte RJ, Nadal E, Germani G, Burra P, Senzolo M. Management of nonneoplastic portal vein thrombosis in the setting of liver transplantation: a systematic review. *Transplantation* 2012; **94**: 1145-1153 [PMID: 23128996 DOI: 10.1097/TP.0b013e31826e8e53]

129 **Luca A**, Caruso S, Milazzo M, Marrone G, Mamone G, Crinò F, Maruzzelli L, Miraglia R, Floridia G, Vizzini G. Natural course of extrahepatic nonmalignant partial portal vein thrombosis in patients with cirrhosis. *Radiology* 2012; **265**: 124-132 [PMID: 22891357 DOI: 10.1148/radiol.12112236]

130 **Senzolo M**, M Sartori T, Rossetto V, Burra P, Cillo U, Boccagni P, Gasparini D, Miotto D, Simioni P, Tsochatzis E, A Burroughs K. Prospective evaluation of anticoagulation and transjugular intrahepatic portosystemic shunt for the management of portal vein thrombosis in cirrhosis. *Liver Int* 2012; **32**: 919-927 [PMID: 22435854 DOI: 10.1111/j.1478-3231.2012.02785.x]

131 **Nery F**, Chevret S, Condat B, de Raucourt E, Boudaoud L, Rautou PE, Plessier A, Roulot D, Chaffaut C, Bourcier V, Trinchet JC, Valla DC; Groupe d'Etude et de Traitement du Carcinome Hépatocellulaire. Causes and consequences of portal vein thrombosis in 1,243 patients with cirrhosis: results of a longitudinal study. *Hepatology* 2015; **61**: 660-667 [PMID: 25284616 DOI: 10.1002/hep.27546]

132 **Van Ha TG**, Hodge J, Funaki B, Lorenz J, Rosenblum J, Straus C, Leef J. Transjugular intrahepatic portosystemic shunt placement in patients with cirrhosis and concomitant portal vein thrombosis. *Cardiovasc Intervent Radiol* 2006; **29**: 785-790 [PMID: 16850140 DOI: 10.1007/s00270-005-0090-4]

133 **Salem R**, Vouche M, Baker T, Herrero JI, Caicedo JC, Fryer J, Hickey R, Habib A, Abecassis M, Koller F, Vogelzang R, Desai K, Thornburg B, Hohlastos E, Resnick S, Lewandowski RJ, Sato K, Ryu RK, Ganger D, Kulik L. Pretransplant Portal Vein Recanalization-Transjugular Intrahepatic Portosystemic Shunt in Patients With Complete Obliterative Portal Vein Thrombosis. *Transplantation* 2015; **99**: 2347-2355 [PMID: 25905983 DOI: 10.1097/TP.0000000000000729]

134 **Qi X**, He C, Guo W, Yin Z, Wang J, Wang Z, Niu J, Bai M, Yang Z, Fan D, Han G. Transjugular intrahepatic portosystemic shunt for portal vein thrombosis with variceal bleeding in liver cirrhosis: outcomes and predictors in a prospective cohort study. *Liver Int* 2016; **36**: 667-676 [PMID: 26235541 DOI:

10.1111/liv.12929]
135 **Zhao M**, Yue Z, Zhao H, Wang L, Fan Z, He F, Yao J, Dong X, Liu F. Techniques of TIPS in the treatment of liver cirrhosis combined with incompletely occlusive main portal vein thrombosis. *Sci Rep* 2016; **6**: 33069 [PMID: 27620282 DOI: 10.1038/srep33069]
136 **Chen Y**, Ye P, Li Y, Ma S, Zhao J, Zeng Q. Percutaneous transhepatic balloon-assisted transjugular intrahepatic portosystemic shunt for chronic, totally occluded, portal vein thrombosis with symptomatic portal hypertension: procedure technique, safety, and clinical applications. *Eur Radiol* 2015; **25**: 3431-3437 [PMID: 25903717 DOI: 10.1007/s00330-015-3777-1]
137 **Bhangui P**, Laurent A, Amathieu R, Azoulay D. Assessment of risk for non-hepatic surgery in cirrhotic patients. *J Hepatol* 2012; **57**: 874-884 [PMID: 22634123 DOI: 10.1016/j.jhep.2012.03.037]
138 **Friedman LS**. Surgery in the patient with liver disease. *Trans Am Clin Climatol Assoc* 2010; **121**: 192-204; discussion 205 [PMID: 20697561]
139 **Nicoll A**. Surgical risk in patients with cirrhosis. *J Gastroenterol Hepatol* 2012; **27**: 1569-1575 [PMID: 22694313 DOI: 10.1111/j.1440-1746.2012.07205.x]
140 **Azoulay D**, Buabse F, Damiano I, Smail A, Ichai P, Dannaoui M, Castaing D, Bismuth H. Neoadjuvant transjugular intrahepatic portosystemic shunt: a solution for extrahepatic abdominal operation in cirrhotic patients with severe portal hypertension. *J Am Coll Surg* 2001; **193**: 46-51 [PMID: 11442253 DOI: 10.1016/s1072-7515(01)00911-5]
141 **Grübel P**, Pratt DS, Elhelw T. Transjugular intrahepatic portosystemic shunt for portal decompression before abdominal and retroperitoneal surgery in patients with severe portal hypertension. *J Clin Gastroenterol* 2002; **34**: 489-490 [PMID: 11907372 DOI: 10.1097/00004836-200204000-00026]
142 **Gil A**, Martínez-Regueira F, Hernández-Lizoain JL, Pardo F, Olea JM, Bastarrika G, Cienfuegos JA, Bilbao JI. The role of transjugular intrahepatic portosystemic shunt prior to abdominal tumoral surgery in cirrhotic patients with portal hypertension. *Eur J Surg Oncol* 2004; **30**: 46-52 [PMID: 14736522 DOI: 10.1016/j.ejso.2003.10.014]
143 **Vinet E**, Perreault P, Bouchard L, Bernard D, Wassef R, Richard C, Létourneau R, Pomier-Layrargues G. Transjugular intrahepatic portosystemic shunt before abdominal surgery in cirrhotic patients: a retrospective, comparative study. *Can J Gastroenterol* 2006; **20**: 401-404 [PMID: 16779457 DOI: 10.1155/2006/245082]
144 **Kim JJ**, Dasika NL, Yu E, Fontana RJ. Cirrhotic patients with a transjugular intrahepatic portosystemic shunt undergoing major extrahepatic surgery. *J Clin Gastroenterol* 2009; **43**: 574-579 [PMID: 19169145 DOI: 10.1097/MCG.0b013e31818738ef]
145 **Schlenker C**, Johnson S, Trotter JF. Preoperative transjugular intrahepatic portosystemic shunt (TIPS) for cirrhotic patients undergoing abdominal and pelvic surgeries. *Surg Endosc* 2009; **23**: 1594-1598 [PMID: 19263108 DOI: 10.1007/s00464-009-0405-7]
146 **Tabchouri N**, Barbier L, Menahem B, Perarnau JM, Muscari F, Fares N, D'Alteroche L, Valette PJ, Dumortier J, Alves A, Lubrano J, Bureau C, Salamé E. Original Study: Transjugular Intrahepatic Portosystemic Shunt as a Bridge to Abdominal Surgery in Cirrhotic Patients. *J Gastrointest Surg* 2019; **23**: 2383-2390 [PMID: 30820792 DOI: 10.1007/s11605-018-4053-x]
147 **Schmitz A**, Haste P, Johnson MS. Transjugular Intrahepatic Portosystemic Shunt (TIPS) Creation Prior to Abdominal Operation: a Retrospective Analysis. *J Gastrointest Surg* 2019 [PMID: 31485902 DOI: 10.1007/s11605-019-04384-w]
148 **Lahat E**, Lim C, Bhangui P, Fuentes L, Osseis M, Moussallem T, Salloum C, Azoulay D. Transjugular intrahepatic portosystemic shunt as a bridge to non-hepatic surgery in cirrhotic patients with severe portal hypertension: a systematic review. *HPB (Oxford)* 2018; **20**: 101-109 [PMID: 29110990 DOI: 10.1016/j.hpb.2017.09.006]
149 **Reverter E**, Cirera I, Albillos A, Debernardi-Venon W, Abraldes JG, Llop E, Flores A, Martínez-Palli G, Blasi A, Martínez J, Turon F, García-Valdecasas JC, Berzigotti A, de Lacy AM, Fuster J, Hernández-Gea V, Bosch J, García-Pagán JC. The prognostic role of hepatic venous pressure gradient in cirrhotic patients undergoing elective extrahepatic surgery. *J Hepatol* 2019; **71**: 942-950 [PMID: 31330170 DOI: 10.1016/j.jhep.2019.07.007]
150 **Angeli P**, Gines P, Wong F, Bernardi M, Boyer TD, Gerbes A, Moreau R, Jalan R, Sarin SK, Piano S, Moore K, Lee SS, Durand F, Salerno F, Caraceni P, Kim WR, Arroyo V, Garcia-Tsao G; International Club of Ascites. Diagnosis and management of acute kidney injury in patients with cirrhosis: revised consensus recommendations of the International Club of Ascites. *Gut* 2015; **64**: 531-537 [PMID: 25631669 DOI: 10.1136/gutjnl-2014-308874]
151 **Wong F**, Nadim MK, Kellum JA, Salerno F, Bellomo R, Gerbes A, Angeli P, Moreau R, Davenport A, Jalan R, Ronco C, Genyk Y, Arroyo V. Working Party proposal for a revised classification system of renal dysfunction in patients with cirrhosis. *Gut* 2011; **60**: 702-709 [PMID: 21325171 DOI: 10.1136/gut.2010.236133]
152 **Song T**, Rössle M, He F, Liu F, Guo X, Qi X. Transjugular intrahepatic portosystemic shunt for hepatorenal syndrome: A systematic review and meta-analysis. *Dig Liver Dis* 2018; **50**: 323-330 [PMID: 29422242 DOI: 10.1016/j.dld.2018.01.123]
153 **Charilaou P**, Devani K, Petrosyan R, Reddy C, Pyrsopoulos N. Inpatient Mortality Benefit with Transjugular Intrahepatic Portosystemic Shunt for Hospitalized Hepatorenal Syndrome Patients. *Dig Dis Sci* 2020 [PMID: 32062714 DOI: 10.1007/s10620-020-06136-2]
154 **Brensing KA**, Textor J, Perz J, Schiedermaier P, Raab P, Strunk H, Klehr HU, Kramer HJ, Spengler U, Schild H, Sauerbruch T. Long term outcome after transjugular intrahepatic portosystemic stent-shunt in non-transplant cirrhotics with hepatorenal syndrome: a phase II study. *Gut* 2000; **47**: 288-295 [PMID: 10896924 DOI: 10.1136/gut.47.2.288]
155 **Zhao H**, Liu F, Yue Z, Wang L, Fan Z, He F. Clinical efficacy of transjugular intrahepatic portosystemic shunt in the treatment of hepatopulmonary syndrome. *Medicine (Baltimore)* 2017; **96**: e9080 [PMID: 29245324 DOI: 10.1097/MD.0000000000009080]
156 **Taillé C**, Cadranel J, Bellocq A, Thabut G, Soubrane O, Durand F, Ichaï P, Duvoux C, Belghiti J, Calmus Y, Mal H. Liver transplantation for hepatopulmonary syndrome: a ten-year experience in Paris, France.

Transplantation 2003; **75**: 1482-9; discussion 1446-7 [PMID: 12792501 DOI: 10.1097/01.TP.0000061612.78954.6C]

157 **Martinez-Palli G**, Drake BB, Garcia-Pagan JC, Barbera JA, Arguedas MR, Rodriguez-Roisin R, Bosch J, Fallon MB. Effect of transjugular intrahepatic portosystemic shunt on pulmonary gas exchange in patients with portal hypertension and hepatopulmonary syndrome. *World J Gastroenterol* 2005; **11**: 6858-6862 [PMID: 16425397 DOI: 10.3748/wjg.v11.i43.6858]

158 **Chevallier P**, Novelli L, Motamedi JP, Hastier P, Brunner P, Bruneton JN. Hepatopulmonary syndrome successfully treated with transjugular intrahepatic portosystemic shunt: a three-year follow-up. *J Vasc Interv Radiol* 2004; **15**: 647-648 [PMID: 15178729 DOI: 10.1097/01.rvi.0000127885.68272.e9]

159 **Chen L**, Xiao T, Chen W, Long Q, Li R, Fang D, Wang R. Outcomes of transjugular intrahepatic portosystemic shunt through the left branch vs. the right branch of the portal vein in advanced cirrhosis: a randomized trial. *Liver Int* 2009; **29**: 1101-1109 [PMID: 19386025 DOI: 10.1111/j.1478-3231.2009.02016.x]

160 **Bai M**, He CY, Qi XS, Yin ZX, Wang JH, Guo WG, Niu J, Xia JL, Zhang ZL, Larson AC, Wu KC, Fan DM, Han GH. Shunting branch of portal vein and stent position predict survival after transjugular intrahepatic portosystemic shunt. *World J Gastroenterol* 2014; **20**: 774-785 [PMID: 24574750 DOI: 10.3748/wjg.v20.i3.774]

161 **Tsauo J**, Weng N, Ma H, Jiang M, Zhao H, Li X. Role of Transjugular Intrahepatic Portosystemic Shunts in the Management of Hepatopulmonary Syndrome: A Systemic Literature Review. *J Vasc Interv Radiol* 2015; **26**: 1266-1271 [PMID: 26074026 DOI: 10.1016/j.jvir.2015.04.017]

162 **Riegler JL**, Lang KA, Johnson SP, Westerman JH. Transjugular intrahepatic portosystemic shunt improves oxygenation in hepatopulmonary syndrome. *Gastroenterology* 1995; **109**: 978-983 [PMID: 7657128 DOI: 10.1016/0016-5085(95)90409-3]

163 **Selim KM**, Akriviadis EA, Zuckerman E, Chen D, Reynolds TB. Transjugular intrahepatic portosystemic shunt: a successful treatment for hepatopulmonary syndrome. *Am J Gastroenterol* 1998; **93**: 455-458 [PMID: 9517657 DOI: 10.1111/j.1572-0241.1998.00455.x]

164 **Paramesh AS**, Husain SZ, Shneider B, Guller J, Tokat I, Gondolesi GE, Moyer S, Emre S. Improvement of hepatopulmonary syndrome after transjugular intrahepatic portasystemic shunting: case report and review of literature. *Pediatr Transplant* 2003; **7**: 157-162 [PMID: 12654059 DOI: 10.1034/j.1399-3046.2003.00033.x]

165 **Lasch HM**, Fried MW, Zacks SL, Odell P, Johnson MW, Gerber DA, Sandhu FS, Fair JH, Shrestha R. Use of transjugular intrahepatic portosystemic shunt as a bridge to liver transplantation in a patient with severe hepatopulmonary syndrome. *Liver Transpl* 2001; **7**: 147-149 [PMID: 11172400 DOI: 10.1053/jlts.2001.21287]

166 **Pan JJ**, Chen C, Caridi JG, Geller B, Firpi R, Machicao VI, Hawkins IF Jr, Soldevila-Pico C, Nelson DR, Morelli G. Factors predicting survival after transjugular intrahepatic portosystemic shunt creation: 15 years' experience from a single tertiary medical center. *J Vasc Interv Radiol* 2008; **19**: 1576-1581 [PMID: 18789725 DOI: 10.1016/j.jvir.2008.07.021]

167 **Wakabayashi H**, Nishiyama Y, Ushiyama T, Maeba T, Maeta H. Evaluation of the effect of age on functioning hepatocyte mass and liver blood flow using liver scintigraphy in preoperative estimations for surgical patients: comparison with CT volumetry. *J Surg Res* 2002; **106**: 246-253 [PMID: 12175974 DOI: 10.1006/jsre.2002.6462]

168 **Suraweera D**, Jimenez M, Viramontes M, Jamal N, Grotts J, Elashoff D, Lee EW, Saab S. Age-related Morbidity and Mortality After Transjugular Intrahepatic Portosystemic Shunts. *J Clin Gastroenterol* 2017; **51**: 360-363 [PMID: 27159421 DOI: 10.1097/MCG.0000000000000541]

169 **Saad N**, Rude MK, Darcy M, Hanin JB, Wentworth A, Korenblat KM. Older age is associated with increased early mortality after transjugular intrahepatic portosystemic shunt. *Ann Hepatol* 2016; **15**: 215-221 [PMID: 31196403 DOI: 10.5604/16652681.1193716]

170 **Adlakha N**, Russo MW. Outcomes After Transjugular Intrahepatic Portosystemic Shunt in Cirrhotic Patients 70 Years and Older. *J Clin Med* 2020; **9** [PMID: 32023959 DOI: 10.3390/jcm9020381]

171 **Nolte W**, Wiltfang J, Schindler C, Münke H, Unterberg K, Zumhasch U, Figulla HR, Werner G, Hartmann H, Ramadori G. Portosystemic hepatic encephalopathy after transjugular intrahepatic portosystemic shunt in patients with cirrhosis: clinical, laboratory, psychometric, and electroencephalographic investigations. *Hepatology* 1998; **28**: 1215-1225 [PMID: 9794904 DOI: 10.1002/hep.510280508]

172 **Riggio O**, Angeloni S, Salvatori FM, De Santis A, Cerini F, Farcomeni A, Attili AF, Merli M. Incidence, natural history, and risk factors of hepatic encephalopathy after transjugular intrahepatic portosystemic shunt with polytetrafluoroethylene-covered stent grafts. *Am J Gastroenterol* 2008; **103**: 2738-2746 [PMID: 18775022 DOI: 10.1111/j.1572-0241.2008.02102.x]

173 **Bai M**, Qi X, Yang Z, Yin Z, Nie Y, Yuan S, Wu K, Han G, Fan D. Predictors of hepatic encephalopathy after transjugular intrahepatic portosystemic shunt in cirrhotic patients: a systematic review. *J Gastroenterol Hepatol* 2011; **26**: 943-951 [PMID: 21251067 DOI: 10.1111/j.1440-1746.2011.06663.x]

174 **Riggio O**, Masini A, Efrati C, Nicolao F, Angeloni S, Salvatori FM, Bezzi M, Attili AF, Merli M. Pharmacological prophylaxis of hepatic encephalopathy after transjugular intrahepatic portosystemic shunt: a randomized controlled study. *J Hepatol* 2005; **42**: 674-679 [PMID: 15826716 DOI: 10.1016/j.jhep.2004.12.028]

175 **Jepsen P**, Watson H, Andersen PK, Vilstrup H. Diabetes as a risk factor for hepatic encephalopathy in cirrhosis patients. *J Hepatol* 2015; **63**: 1133-1138 [PMID: 26206073 DOI: 10.1016/j.jhep.2015.07.007]

176 **Wong F**. Cirrhotic cardiomyopathy. *Hepatol Int* 2009; **3**: 294-304 [PMID: 19669380 DOI: 10.1007/s12072-008-9109-7]

177 **Zardi EM**, Abbate A, Zardi DM, Dobrina A, Margiotta D, Van Tassell BW, Afeltra A, Sanyal AJ. Cirrhotic cardiomyopathy. *J Am Coll Cardiol* 2010; **56**: 539-549 [PMID: 20688208 DOI: 10.1016/j.jacc.2009.12.075]

178 **Rabie RN**, Cazzaniga M, Salerno F, Wong F. The use of E/A ratio as a predictor of outcome in cirrhotic patients treated with transjugular intrahepatic portosystemic shunt. *Am J Gastroenterol* 2009; **104**: 2458-2466 [PMID: 19532126 DOI: 10.1038/ajg.2009.321]

179 **Ruíz-del-Árbol L**, Achécar L, Serradilla R, Rodríguez-Gandía MÁ, Rivero M, Garrido E, Natcher JJ. Diastolic dysfunction is a predictor of poor outcomes in patients with cirrhosis, portal hypertension, and a normal creatinine. *Hepatology* 2013; **58**: 1732-1741 [PMID: 23703953 DOI: 10.1002/hep.26509]

180 **Wannhoff A**, Hippchen T, Weiss CS, Friedrich K, Rupp C, Neumann-Haefelin C, Dollinger M, Antoni C, Stampfl U, Schemmer P, Stremmel W, Weiss KH, Radeleff B, Katus HA, Gotthardt DN. Cardiac volume overload and pulmonary hypertension in long-term follow-up of patients with a transjugular intrahepatic portosystemic shunt. *Aliment Pharmacol Ther* 2016; **43**: 955-965 [PMID: 26919285 DOI: 10.1111/apt.13569]

181 **Cazzaniga M**, Salerno F, Pagnozzi G, Dionigi E, Visentin S, Cirello I, Meregaglia D, Nicolini A. Diastolic dysfunction is associated with poor survival in patients with cirrhosis with transjugular intrahepatic portosystemic shunt. *Gut* 2007; **56**: 869-875 [PMID: 17135305 DOI: 10.1136/gut.2006.102467]

182 **Shounak M**, Vimal R, Colin S, David I S. A retrospective analysis of the impact of diastolic dysfunction on one-year mortality after transjugular intrahepatic porto-systemic shunt, liver transplantation and non-transplant abdominal surgery in patients with cirrhosis. *Ann Gastroenterol* 2015; **28**: 385-390 [PMID: 26129720]

183 **Armstrong MJ**, Gohar F, Dhaliwal A, Nightingale P, Baker G, Greaves D, Mangat K, Zia Z, Karkhanis S, Olliff S, Mehrzad H, Steeds RP, Tripathi D. Diastolic dysfunction on echocardiography does not predict survival after transjugular intrahepatic portosystemic stent-shunt in patients with cirrhosis. *Aliment Pharmacol Ther* 2019; **49**: 797-806 [PMID: 30773660 DOI: 10.1111/apt.15164]

184 **Modha K**, Kapoor B, Lopez R, Sands MJ, Carey W. Symptomatic Heart Failure After Transjugular Intrahepatic Portosystemic Shunt Placement: Incidence, Outcomes, and Predictors. *Cardiovasc Intervent Radiol* 2018; **41**: 564-571 [PMID: 29181605 DOI: 10.1007/s00270-017-1848-1]

185 **Billey C**, Billet S, Robic MA, Cognet T, Guillaume M, Vinel JP, Péron JM, Lairez O, Bureau C. A Prospective Study Identifying Predictive Factors of Cardiac Decompensation After Transjugular Intrahepatic Portosystemic Shunt: The Toulouse Algorithm. *Hepatology* 2019; **70**: 1928-1941 [PMID: 31512743 DOI: 10.1002/hep.30934]

186 **Jansen C**, Schröder A, Schueler R, Lehmann J, Praktiknjo M, Uschner FE, Schierwagen R, Thomas D, Monteiro S, Nickenig G, Strassburg CP, Meyer C, Arroyo V, Hammerstingl C, Trebicka J. Left Ventricular Longitudinal Contractility Predicts Acute-on-Chronic Liver Failure Development and Mortality After Transjugular Intrahepatic Portosystemic Shunt. *Hepatol Commun* 2019; **3**: 340-347 [PMID: 30984902 DOI: 10.1002/hep4.1308]

187 **Fagiuoli S**, Bruno R, Debernardi Venon W, Schepis F, Vizzutti F, Toniutto P, Senzolo M, Caraceni P, Salerno F, Angeli P, Cioni R, Vitale A, Grosso M, De Gasperi A, D'Amico G, Marzano A; AISF TIPS Special Conference. Consensus conference on TIPS management: Techniques, indications, contraindications. *Dig Liver Dis* 2017; **49**: 121-137 [PMID: 27884494 DOI: 10.1016/j.dld.2016.10.011]

188 **Vizzutti F**, Rega L, Arena U, Romanelli RG, Meucci F, Barletta G, Schepis F, Tsalouchos A, Laffi G, Marra F. Paradoxical embolization in TIPS: take a closer look to the heart. *Ann Hepatol* 2015; **14**: 127-131 [PMID: 25536651]

189 **Dasarathy J**, Alkhouri N, Dasarathy S. Changes in body composition after transjugular intrahepatic portosystemic stent in cirrhosis: a critical review of literature. *Liver Int* 2011; **31**: 1250-1258 [PMID: 21745273 DOI: 10.1111/j.1478-3231.2011.02498.x]

190 **Periyalwar P**, Dasarathy S. Malnutrition in cirrhosis: contribution and consequences of sarcopenia on metabolic and clinical responses. *Clin Liver Dis* 2012; **16**: 95-131 [PMID: 22321468 DOI: 10.1016/j.cld.2011.12.009]

191 **Dasarathy S**. Consilience in sarcopenia of cirrhosis. *J Cachexia Sarcopenia Muscle* 2012; **3**: 225-237 [PMID: 22648736 DOI: 10.1007/s13539-012-0069-3]

192 **European Association for the Study of the Liver**. EASL Clinical Practice Guidelines on nutrition in chronic liver disease. *J Hepatol* 2019; **70**: 172-193 [PMID: 30144956 DOI: 10.1016/j.jhep.2018.06.024]

193 **Borhofen SM**, Gerner C, Lehmann J, Fimmers R, Görtzen J, Hey B, Geiser F, Strassburg CP, Trebicka J. The Royal Free Hospital-Nutritional Prioritizing Tool Is an Independent Predictor of Deterioration of Liver Function and Survival in Cirrhosis. *Dig Dis Sci* 2016; **61**: 1735-1743 [PMID: 26725059 DOI: 10.1007/s10620-015-4015-z]

194 **Cruz-Jentoft AJ**, Baeyens JP, Bauer JM, Boirie Y, Cederholm T, Landi F, Martin FC, Michel JP, Rolland Y, Schneider SM, Topinková E, Vandewoude M, Zamboni M; European Working Group on Sarcopenia in Older People. Sarcopenia: European consensus on definition and diagnosis: Report of the European Working Group on Sarcopenia in Older People. *Age Ageing* 2010; **39**: 412-423 [PMID: 20392703 DOI: 10.1093/ageing/afq034]

195 **Alberino F**, Gatta A, Amodio P, Merkel C, Di Pascoli L, Boffo G, Caregaro L. Nutrition and survival in patients with liver cirrhosis. *Nutrition* 2001; **17**: 445-450 [PMID: 11399401 DOI: 10.1016/s0899-9007(01)00521-4]

196 **Morgan MY**, Madden AM, Soulsby CT, Morris RW. Derivation and validation of a new global method for assessing nutritional status in patients with cirrhosis. *Hepatology* 2006; **44**: 823-835 [PMID: 17006918 DOI: 10.1002/hep.21358]

197 **Tsien C**, Shah SN, McCullough AJ, Dasarathy S. Reversal of sarcopenia predicts survival after a transjugular intrahepatic portosystemic stent. *Eur J Gastroenterol Hepatol* 2013; **25**: 85-93 [PMID: 23011041 DOI: 10.1097/MEG.0b013e328359a759]

198 **Jahangiri Y**, Pathak P, Tomozawa Y, Li L, Schlansky BL, Farsad K. Muscle Gain after Transjugular Intrahepatic Portosystemic Shunt Creation: Time Course and Prognostic Implications for Survival in Cirrhosis. *J Vasc Interv Radiol* 2019; **30**: 866-872.e4 [PMID: 31053265 DOI: 10.1016/j.jvir.2019.01.005]

199 **Praktiknjo M**, Book M, Luetkens J, Pohlmann A, Meyer C, Thomas D, Jansen C, Feist A, Chang J, Grimm J, Lehmann J, Strassburg CP, Abraldes JG, Kukuk G, Trebicka J. Fat-free muscle mass in magnetic resonance imaging predicts acute-on-chronic liver failure and survival in decompensated cirrhosis. *Hepatology* 2018; **67**: 1014-1026 [PMID: 29059469 DOI: 10.1002/hep.29602]

200 **Shoreibah MG**, Mahmoud K, Aboueldahab NA, Vande Lune P, Massoud M, Bae S, El Khudari H, Gunn AJ, Abdel Aal AK. Psoas Muscle Density in Combination with Model for End-Stage Liver Disease Score

Can Improve Survival Predictability in Transjugular Intrahepatic Portosystemic Shunts. *J Vasc Interv Radiol* 2019; **30**: 154-161 [PMID: 30717946 DOI: 10.1016/j.jvir.2018.10.006]

201 **Ronald J**, Bozdogan E, Zaki IH, Kappus MR, Choi SS, Martin JG, Suhocki PV, Smith TP, Kim CY, Bashir MR. Relative Sarcopenia With Excess Adiposity Predicts Survival After Transjugular Intrahepatic Portosystemic Shunt Creation. *AJR Am J Roentgenol* 2020; **214**: 200-205 [PMID: 31670594 DOI: 10.2214/AJR.19.21655]

202 **Nardelli S**, Lattanzi B, Torrisi S, Greco F, Farcomeni A, Gioia S, Merli M, Riggio O. Sarcopenia Is Risk Factor for Development of Hepatic Encephalopathy After Transjugular Intrahepatic Portosystemic Shunt Placement. *Clin Gastroenterol Hepatol* 2017; **15**: 934-936 [PMID: 27816756 DOI: 10.1016/j.cgh.2016.10.028]

203 **Farkas ZC**, Rashid T, Chen YS, Siddiqui TM, Yandrapalli S, Frager S, Aronow WS, Bodin R, Maddineni S. The correlation between sarcopaenia and post-transjugular intrahepatic portosystemic shunt hepatic encephalopathy: a single-institution review. *Arch Med Sci Atheroscler Dis* 2019; **4**: e89-e93 [PMID: 31211275 DOI: 10.5114/amsad.2019.85380]

204 **Gioia S**, Nardelli S, Pitocchi F, Pileggi R, Lattanzi B, Merli M, Riggio O. The amelioration of muscle wasting leads to the improvement of cognitive impairment after transjugular intrahepatic portosystemic shunt: A proof of concept that sarcopenia and hepatic encephalopathy are causally related. *J Hepatol* 2018; **68**: S700-701 [DOI: 10.1016/S0168-8278(18)31664-7]

205 **Benmassaoud A**, Roccarina D, Yu D, Cheng F, Yu B, Patch D, Tsochatzis E. Impact of sarcopenia in patients undergoing transjugular intrahepatic portosystemic shunt insertion for refractory ascites. *J Hepatol* 2019; **70**: E-632 [DOI: 10.1016/S0618-8278(19)31259-9]

206 **Perarnau JM**, Le Gouge A, Nicolas C, d'Alteroche L, Borentain P, Saliba F, Minello A, Anty R, Chagneau-Derrode C, Bernard PH, Abergel A, Ollivier-Hourmand I, Gournay J, Ayoub J, Gaborit C, Rusch E, Giraudeau B; STIC-TIPS group. Covered vs. uncovered stents for transjugular intrahepatic portosystemic shunt: a randomized controlled trial. *J Hepatol* 2014; **60**: 962-968 [PMID: 24480619 DOI: 10.1016/j.jhep.2014.01.015]

207 **Casado M**, Bosch J, García-Pagán JC, Bru C, Bañares R, Bandi JC, Escorsell A, Rodríguez-Láiz JM, Gilabert R, Feu F, Schorlemer C, Echenagusia A, Rodés J. Clinical events after transjugular intrahepatic portosystemic shunt: correlation with hemodynamic findings. *Gastroenterology* 1998; **114**: 1296-1303 [PMID: 9609767 DOI: 10.1016/s0016-5085(98)70436-6]

208 **Zuckerman DA**, Darcy MD, Bocchini TP, Hildebolt CF. Encephalopathy after transjugular intrahepatic portosystemic shunting: analysis of incidence and potential risk factors. *AJR Am J Roentgenol* 1997; **169**: 1727-1731 [PMID: 9393198 DOI: 10.2214/ajr.169.6.9393198]

209 **Wang Q**, Lv Y, Bai M, Wang Z, Liu H, He C, Niu J, Guo W, Luo B, Yin Z, Bai W, Chen H, Wang E, Xia D, Li X, Yuan J, Han N, Cai H, Li T, Xie H, Xia J, Wang J, Zhang H, Wu K, Fan D, Han G. Eight millimetre covered TIPS does not compromise shunt function but reduces hepatic encephalopathy in preventing variceal rebleeding. *J Hepatol* 2017; **67**: 508-516 [PMID: 28506905 DOI: 10.1016/j.jhep.2017.05.006]

210 **Trebicka J**, Bastgen D, Byrtus J, Praktiknjo M, Terstiegen S, Meyer C, Thomas D, Fimmers R, Treitl M, Euringer W, Sauerbruch T, Rössle M. Smaller-Diameter Covered Transjugular Intrahepatic Portosystemic Shunt Stents Are Associated With Increased Survival. *Clin Gastroenterol Hepatol* 2019; **17**: 2793-2799.e1 [PMID: 30940552 DOI: 10.1016/j.cgh.2019.03.042]

211 **Rössle M**, Siegerstetter V, Olschewski M, Ochs A, Berger E, Haag K. How much reduction in portal pressure is necessary to prevent variceal rebleeding? A longitudinal study in 225 patients with transjugular intrahepatic portosystemic shunts. *Am J Gastroenterol* 2001; **96**: 3379-3383 [PMID: 11774952 DOI: 10.1111/j.1572-0241.2001.05340.x]

212 **Casadaban LC**, Parvinian A, Minocha J, Lakhoo J, Grant CW, Ray CE Jr, Knuttinen MG, Bui JT, Gaba RC. Clearing the Confusion over Hepatic Encephalopathy After TIPS Creation: Incidence, Prognostic Factors, and Clinical Outcomes. *Dig Dis Sci* 2015; **60**: 1059-1066 [PMID: 25316553 DOI: 10.1007/s10620-014-3391-0]

213 **Dariushnia SR**, Haskal ZJ, Midia M, Martin LG, Walker TG, Kalva SP, Clark TW, Ganguli S, Krishnamurthy V, Saiter CK, Nikolic B; Society of Interventional Radiology Standards of Practice Committee. Quality Improvement Guidelines for Transjugular Intrahepatic Portosystemic Shunts. *J Vasc Interv Radiol* 2016; **27**: 1-7 [PMID: 26614596 DOI: 10.1016/j.jvir.2015.09.018]

214 **Pieper CC**, Sprinkart AM, Nadal J, Hippe V, Meyer C, Schild HH, Thomas D. Postinterventional passive expansion of partially dilated transjugular intrahepatic portosystemic shunt stents. *J Vasc Interv Radiol* 2015; **26**: 388-394 [PMID: 25541420 DOI: 10.1016/j.jvir.2014.10.021]

215 **Mollaiyan A**, Bettinger D, Rössle M. The underdilation of nitinol stents at TIPS implantation: Solution or illusion? *Eur J Radiol* 2017; **89**: 123-128 [PMID: 28267527 DOI: 10.1016/j.ejrad.2017.01.032]

216 **Cui J**, Smolinski SE, Liu F, Xu D, Dulaimy K, Irani Z. Incrementally Expandable Transjugular Intrahepatic Portosystemic Shunts: Single-Center Experience. *AJR Am J Roentgenol* 2018; **210**: 438-446 [PMID: 29261352 DOI: 10.2214/AJR.17.18222]

217 **Praktiknjo M**, Lehmann J, Fischer S, Strassburg CP, Meyer C, Trebicka J. Novel diameter controlled expansion TIPS (Viatorr CX®) graft reduces readmission compared to regular covered TIPS graft and bare metal graft. *J Hepatol* 2017; **66**: S48-S49 [DOI: 10.1016/S0168-8278(17)30360-4]

218 **Miraglia R**, Maruzzelli L, Cortis K, D'Amico M, Floridia G, Gallo G, Tafaro C, Luca A. Radiation Exposure in Transjugular Intrahepatic Portosystemic Shunt Creation. *Cardiovasc Intervent Radiol* 2016; **39**: 210-217 [PMID: 26126582 DOI: 10.1007/s00270-015-1164-6]

219 **Marquardt S**, Rodt T, Rosenthal H, Wacker F, Meyer BC. Impact of Anatomical, Procedural, and Operator Skill Factors on the Success and Duration of Fluoroscopy-Guided Transjugular Intrahepatic Portosystemic Shunt. *Cardiovasc Intervent Radiol* 2015; **38**: 903-912 [PMID: 25501265 DOI: 10.1007/s00270-014-1035-6]

220 **Owen AR**, Stanley AJ, Vijayananthan A, Moss JG. The transjugular intrahepatic portosystemic shunt (TIPS). *Clin Radiol* 2009; **64**: 664-674 [PMID: 19520210 DOI: 10.1016/j.crad.2008.09.017]

221 **Fidelman N**, Kwan SW, LaBerge JM, Gordon RL, Ring EJ, Kerlan RK Jr. The transjugular intrahepatic

portosystemic shunt: an update. *AJR Am J Roentgenol* 2012; **199**: 746-755 [PMID: 22997364 DOI: 10.2214/AJR.12.9101]

222 **Teitelbaum GP**, Van Allan RJ, Reed RA, Hanks S, Katz MD. Portal venous branch targeting with a platinum-tipped wire to facilitate transjugular intrahepatic portosystemic shunt (TIPS) procedures. *Cardiovasc Intervent Radiol* 1993; **16**: 198-200 [PMID: 8334696 DOI: 10.1007/BF02641894]

223 **Haochen W**, Yinghua Z, Jian W. Intrahepatic arterial localizer guided transjugular intrahepatic portosystemic shunt placement: Feasibility, efficacy, and technical success assessed by a case series-a STROBE- compliant article. *Medicine (Baltimore)* 2019; **98**: e16868 [PMID: 31415422 DOI: 10.1097/MD.0000000000016868]

224 **Tavare AN**, Wigham A, Hadjivassilou A, Alvi A, Papadopoulou A, Goode A, Woodward N, Patch D, Yu D, Davies N. Use of transabdominal ultrasound-guided transjugular portal vein puncture on radiation dose in transjugular intrahepatic portosystemic shunt formation. *Diagn Interv Radiol* 2017; **23**: 206-210 [PMID: 28223261 DOI: 10.5152/dir.2016.15601]

225 **Kao SD**, Morshedi MM, Narsinh KH, Kinney TB, Minocha J, Picel AC, Newton I, Rose SC, Roberts AC, Kuo A, Aryafar H. Intravascular Ultrasound in the Creation of Transhepatic Portosystemic Shunts Reduces Needle Passes, Radiation Dose, and Procedure Time: A Retrospective Study of a Single-Institution Experience. *J Vasc Interv Radiol* 2016; **27**: 1148-1153 [PMID: 27052948 DOI: 10.1016/j.jvir.2016.01.137]

226 **Pillai AK**, Andring B, Faulconer N, Reis SP, Xi Y, Iyamu I, Suthpin PD, Kalva SP. Utility of Intravascular US-Guided Portal Vein Access during Transjugular Intrahepatic Portosystemic Shunt Creation: Retrospective Comparison with Conventional Technique in 109 Patients. *J Vasc Interv Radiol* 2016; **27**: 1154-1159 [PMID: 27363298 DOI: 10.1016/j.jvir.2016.05.010]

227 **Luo X**, Ye L, Zhou X, Tsauo J, Zhou B, Zhang H, Zhang X, Li X. C-Arm Cone-Beam Volume CT in Transjugular Intrahepatic Portosystemic Shunt: Initial Clinical Experience. *Cardiovasc Intervent Radiol* 2015; **38**: 1627-1631 [PMID: 25832762 DOI: 10.1007/s00270-015-1087-2]

228 **Ketelsen D**, Groezinger G, Maurer M, Lauer UM, Grosse U, Horger M, Nikolaou K, Syha R. Three-dimensional C-arm CT-guided transjugular intrahepatic portosystemic shunt placement: Feasibility, technical success and procedural time. *Eur Radiol* 2016; **26**: 4277-4283 [PMID: 27048535 DOI: 10.1007/s00330-016-4340-4]

229 **Gaba RC**, Bui JT, Cotler SJ, Kallwitz ER, Mengin OT, Martinez BK, Berkes JL, Carrillo TC, Knuttinen MG, Owens CA. Rebleeding rates following TIPS for variceal hemorrhage in the Viatorr era: TIPS alone *vs* TIPS with variceal embolization. *Hepatol Int* 2010; **4**: 749-756 [PMID: 21286346 DOI: 10.1007/s12072-010-9206-2]

230 **Tesdal IK**, Filser T, Weiss C, Holm E, Dueber C, Jaschke W. Transjugular intrahepatic portosystemic shunts: adjunctive embolotherapy of gastroesophageal collateral vessels in the prevention of variceal rebleeding. *Radiology* 2005; **236**: 360-367 [PMID: 15955858 DOI: 10.1148/radiol.2361040530]

231 **Xiao T**, Chen L, Chen W, Xu B, Long Q, Li R, Li L, Peng Z, Fang D, Wang R. Comparison of transjugular intrahepatic portosystemic shunt (TIPS) alone *vs* TIPS combined with embolotherapy in advanced cirrhosis: a retrospective study. *J Clin Gastroenterol* 2011; **45**: 643-650 [PMID: 21301360 DOI: 10.1097/MCG.0b013e318203dfb3]

232 **Chen S**, Li X, Wei B, Tong H, Zhang MG, Huang ZY, Cao JW, Tang CW. Recurrent variceal bleeding and shunt patency: prospective randomized controlled trial of transjugular intrahepatic portosystemic shunt alone or combined with coronary vein embolization. *Radiology* 2013; **268**: 900-906 [PMID: 23657891 DOI: 10.1148/radiol.13120800]

233 **Shi Y**, Tian X, Hu J, Zhang J, Zhang C, Yang Y, Qin C. Efficacy of transjugular intrahepatic portosystemic shunt with adjunctive embolotherapy with cyanoacrylate for esophageal variceal bleeding. *Dig Dis Sci* 2014; **59**: 2325-2332 [PMID: 24748182 DOI: 10.1007/s10620-014-3150-2]

234 **Qi X**, Liu L, Bai M, Chen H, Wang J, Yang Z, Han G, Fan D. Transjugular intrahepatic portosystemic shunt in combination with or without variceal embolization for the prevention of variceal rebleeding: a meta-analysis. *J Gastroenterol Hepatol* 2014; **29**: 688-696 [PMID: 24117967 DOI: 10.1111/jgh.12391]

235 **Sze DY**, Hwang GL, Kao JS, Frisoli JK, Kee ST, Razavi MK, Ahmed A. Bidirectionally adjustable TIPS reduction by parallel stent and stent-graft deployment. *J Vasc Interv Radiol* 2008; **19**: 1653-1658 [PMID: 18823797 DOI: 10.1016/j.jvir.2008.08.011]

236 **Wolf DC**, Siddiqui S, Rayyan Y, Rozenblit G. Emergent stent occlusion for TIPS-induced liver failure. *Dig Dis Sci* 2005; **50**: 2356-2358 [PMID: 16416189 DOI: 10.1007/s10620-005-3062-2]

237 **López-Méndez E**, Zamora-Valdés D, Díaz-Zamudio M, Fernández-Díaz OF, Avila L. Liver failure after an uncovered TIPS procedure associated with hepatic infarction. *World J Hepatol* 2010; **2**: 167-170 [PMID: 21160990 DOI: 10.4254/wjh.v2.i4.167]

238 **Vizzutti F**, Arena U, Rega L, Zipoli M, Abraldes JG, Romanelli RG, Tarquini R, Laffi G, Pinzani M. Liver failure complicating segmental hepatic ischaemia induced by a PTFE-coated TIPS stent. *Gut* 2009; **58**: 582-584 [PMID: 19299387 DOI: 10.1136/gut.2008.172486]

239 **Casadaban LC**, Parvinian A, Couture PM, Minocha J, Knuttinen MG, Bui JT, Gaba RC. Characterization of liver function parameter alterations after transjugular intrahepatic portosystemic shunt creation and association with early mortality. *AJR Am J Roentgenol* 2014; **203**: 1363-1370 [PMID: 25415716 DOI: 10.2214/AJR.13.12232]

240 **Gaba RC**, Lakhoo J. What constitutes liver failure after transjugular intrahepatic portosystemic shunt creation? A proposed definition and grading system. *Ann Hepatol* 2016; **15**: 230-235 [PMID: 26845600]

241 **Rajan DK**, Haskal ZJ, Clark TW. Serum bilirubin and early mortality after transjugular intrahepatic portosystemic shunts: results of a multivariate analysis. *J Vasc Interv Radiol* 2002; **13**: 155-161 [PMID: 11830621 DOI: 10.1016/s1051-0443(07)61932-0]

242 **Ferral H**, Gamboa P, Postoak DW, Albernaz VS, Young CR, Speeg KV, McMahan CA. Survival after elective transjugular intrahepatic portosystemic shunt creation: prediction with model for end-stage liver disease score. *Radiology* 2004; **231**: 231-236 [PMID: 14990811 DOI: 10.1148/radiol.2311030967]

243 **Chung HH**, Razavi MK, Sze DY, Frisoli JK, Kee ST, Dake MD, Hellinger JC, Kang BC. Portosystemic pressure gradient during transjugular intrahepatic portosystemic shunt with Viatorr stent graft: what is the critical low threshold to avoid medically uncontrolled low pressure gradient related complications? *J*

Gastroenterol Hepatol 2008; **23**: 95-101 [PMID: 18171347 DOI: 10.1111/j.1440-1746.2006.04697.x]
244 **Darcy M**. Evaluation and management of transjugular intrahepatic portosystemic shunts. *AJR Am J Roentgenol* 2012; **199**: 730-736 [PMID: 22997362 DOI: 10.2214/AJR.12.9060]
245 **Kanterman RY**, Darcy MD, Middleton WD, Sterling KM, Teefey SA, Pilgram TK. Doppler sonography findings associated with transjugular intrahepatic portosystemic shunt malfunction. *AJR Am J Roentgenol* 1997; **168**: 467-472 [PMID: 9016228 DOI: 10.2214/ajr.168.2.9016228]
246 **Surratt RS**, Middleton WD, Darcy MD, Melson GL, Brink JA. Morphologic and hemodynamic findings at sonography before and after creation of a transjugular intrahepatic portosystemic shunt. *AJR Am J Roentgenol* 1993; **160**: 627-630 [PMID: 8430568 DOI: 10.2214/ajr.160.3.8430568]
247 **Engstrom BI**, Horvath JJ, Suhocki PV, Smith AD, Hertzberg BS, Smith TP, Kim CY. Covered transjugular intrahepatic portosystemic shunts: accuracy of ultrasound in detecting shunt malfunction. *AJR Am J Roentgenol* 2013; **200**: 904-908 [PMID: 23521468 DOI: 10.2214/AJR.12.8761]
248 **Kim SK**, Belikoff BG, Guevara CJ, Park SJ. An Algorithm for Management After Transjugular Intrahepatic Portosystemic Shunt Placement According to Clinical Manifestations. *Dig Dis Sci* 2017; **62**: 305-318 [PMID: 28058594 DOI: 10.1007/s10620-016-4399-4]
249 **Tanaka T**, Günther RW, Isfort P, Kichikawa K, Mahnken AH. Pull-through technique for recanalization of occluded portosystemic shunts (TIPS): technical note and review of the literature. *Cardiovasc Intervent Radiol* 2011; **34**: 406-412 [PMID: 20440498 DOI: 10.1007/s00270-010-9874-2]
250 **Zhu K**, Meng X, Zhou B, Qian J, Huang W, Deng M, Shan H. Percutaneous transsplenic portal vein catheterization: technical procedures, safety, and clinical applications. *J Vasc Interv Radiol* 2013; **24**: 518-527 [PMID: 23522157 DOI: 10.1016/j.jvir.2012.12.028]
251 **Parvinian A**, Gaba RC. Parallel TIPS for treatment of refractory ascites and hepatic hydrothorax. *Dig Dis Sci* 2013; **58**: 3052-3056 [PMID: 23625294 DOI: 10.1007/s10620-013-2688-8]

World Journal of Gastroenterology

Submit a Manuscript: https://www.f6publishing.com

World J Gastroenterol 2020 October 7; 26(37): 5597-5605

DOI: 10.3748/wjg.v26.i37.5597

ISSN 1007-9327 (print) ISSN 2219-2840 (online)

MINIREVIEWS

Calcifying fibrous tumor of the gastrointestinal tract: A clinicopathologic review and update

Donald Turbiville, Xuchen Zhang

ORCID number: Donald Turbiville N?A; Xu-Chen Zhang 0000-0002-1484-4672.

Author contributions: Turbiville D drafted the paper; Zhang X edited, revised and contributed with conceptual development.

Conflict-of-interest statement: The authors have no conflicts of interest to disclose.

Manuscript source: Invited manuscript

Received: July 6, 2020
Peer-review started: July 6, 2020
First decision: July 28, 2020
Revised: August 9, 2020
Accepted: September 12, 2020

Donald Turbiville, Xuchen Zhang, Department of Pathology, Yale University School of Medicine, New Haven, CT 06510, United States

Corresponding author: Xuchen Zhang, MD, PhD, Department of Pathology, Yale University School of Medicine, 310 Cedar Street, PO Box 208023, New Haven, CT 06510, United States. xuchen.zhang@yale.edu

Abstract

Calcifying fibrous tumor (CFT) is a rare mesenchymal lesion that has been documented throughout the gastrointestinal tract. Gastrointestinal CFTs may occur at virtually any age, with a predilection for adults and for females. They occur most commonly in the stomach and the small and large intestines. CFTs are most often found incidentally, cured by local resection, and have a low risk of recurrence. Histology shows three characteristic features: Spindle cell proliferations within a densely hyalinized stroma, scattered calcifications, and lymphoplasmacytic inflammation. CFTs are immunoreactive for CD34, vimentin and factor XIIIa, helping to distinguish them from other benign mesenchymal neoplasms. The differential diagnosis of CFTs includes sclerosing gastrointestinal stromal tumor, leiomyoma, schwannoma, solitary fibrous tumor, inflammatory myofibroblastic tumor, plexiform fibromyxoma, fibromatosis, sclerosing mesenteritis, and reactive nodular fibrous pseudotumor. The pathogenesis of CFTs remains unclear, but some have hypothesized that they may be linked to IgG4-related disease, inflammatory myofibroblastic lesions, hyaline vascular type Castleman disease, sclerosing angiomatoid nodular transformation of the spleen, or trauma.

Key Words: Calcifying fibrous tumor; Calcifying fibrous pseudotumor; Gastrointestinal tract; Mesenchymal lesion; Calcification; Pathology

Core Tip: Calcifying fibrous tumors (CFTs) are rare benign mesenchymal tumors of the gastrointestinal tract. Originally thought to be tumors of soft tissue sites, recent studies have shown the gastrointestinal tract to be a primary site for these tumors. CFTs present a diagnostic challenge due to histologic features that overlap with numerous stromal lesions. Understanding of the core clinical, histologic and immunophenotypic features of CFTs is

Article in press: September 12, 2020
Published online: October 7, 2020

P-Reviewer: Larson B
S-Editor: Huang P
L-Editor: A
P-Editor: Ma YJ

important in making an accurate diagnosis. In this review we summarize and update the clinical and pathologic features of CFT as well as the differential diagnosis for this entity.

Citation: Turbiville D, Zhang X. Calcifying fibrous tumor of the gastrointestinal tract: A clinicopathologic review and update. *World J Gastroenterol* 2020; 26(37): 5597-5605
URL: https://www.wjgnet.com/1007-9327/full/v26/i37/5597.htm
DOI: https://dx.doi.org/10.3748/wjg.v26.i37.5597

INTRODUCTION

Calcifying fibrous tumor (CFT) is a rare benign mesenchymal lesion that was first described by Rosenthal *et al*[1] in 1988. Originally, CFTs were considered to primarily be tumors of soft tissue sites. Since that time, CFTs, also described as calcifying fibrous pseudotumors, have been documented at a variety of anatomic sites including the pleura, mediastinum, heart, lung, neck, mandible, spine, back, arm, thigh, as well as oral, inguinal, paratesticular, and intrascrotal locations[2]. Recently, CFTs arising from the gastrointestinal tract have been documented, with CFTs reported in the small bowel, large intestine, stomach, esophagus, and appendix[3]. Previously thought to be rare in the gastrointestinal tract, improved clinical recognition of this entity has led to the observation that the majority of these tumors may in fact arise in the gastrointestinal tract[2,4]. The occurrence of CFTs in the gastrointestinal tract presents a diagnostic dilemma, firstly due to the rarity of the lesion, and secondly, due to the occurrence of a variety of other stromal lesions in the gastrointestinal tract with histologic features that overlap with CFT. Here we provide a review and update of the clinical and pathologic features of CFTs, as well as a description of other stromal lesions to consider in the differential diagnosis of CFT.

CLINICAL CHARACTERISTICS

CFTs of the gastrointestinal tract are rare lesions with nonspecific clinical features. The tumor has a predilection for adults with a median age of 49.2 years and occurs slightly more often in females[2,3]. CFTs have been reported in the stomach, small intestine, colon, and appendix, with one documented case arising in the esophagus[2-5]. Previous studies have shown the most common sites to be the stomach and small bowel, however, a recent large case series found a higher frequency of CFTs in the large bowel than in the stomach[2,3,6]. CFTs are most commonly asymptomatic and discovered incidentally[2]. When present, symptoms are non-specific and most commonly include abdominal pain and discomfort[2,3]. Additional symptoms include lack of appetite, fever, weight loss, fatigue, dyspepsia, flatulence, halitosis, nausea, vomiting, red blood per rectum, and altered bowel habits[2]. CFTs are occasionally associated with more severe manifestations including gastric ulcers, obstruction, intussusception and volvulus[3,6].

Imaging findings show evidence of a mass lesion but are not specific for CFT. The clear border, coarse calcification on conventional ultrasound and peripheral hypoenhancement without central enhancement on contrast-enhanced ultrasound may help to distinguish CFT from other lesions[7].

Computerized tomography scan typically shows a well-circumscribed, homogenous mass with mild enhancement and calcification[6]. Magnetic resonance imaging examination may show isosignal intensity on gadolinium-enhanced T1-weighted imaging and hyposignal intensity on T2-weighted imaging[8].

PATHOLOGIC FINDINGS

The gross examination of gastrointestinal CFTs reveals a well-circumscribed, unencapsulated, spherical to lobulated mass with variable calcifications. Sectioning reveals a homogenous, partially gritty, grey-white cut surface that is firm to rubbery (Figure 1A and B). The average size is 2.6 cm with a range in size of less than 1 to greater than 10 cm[9].

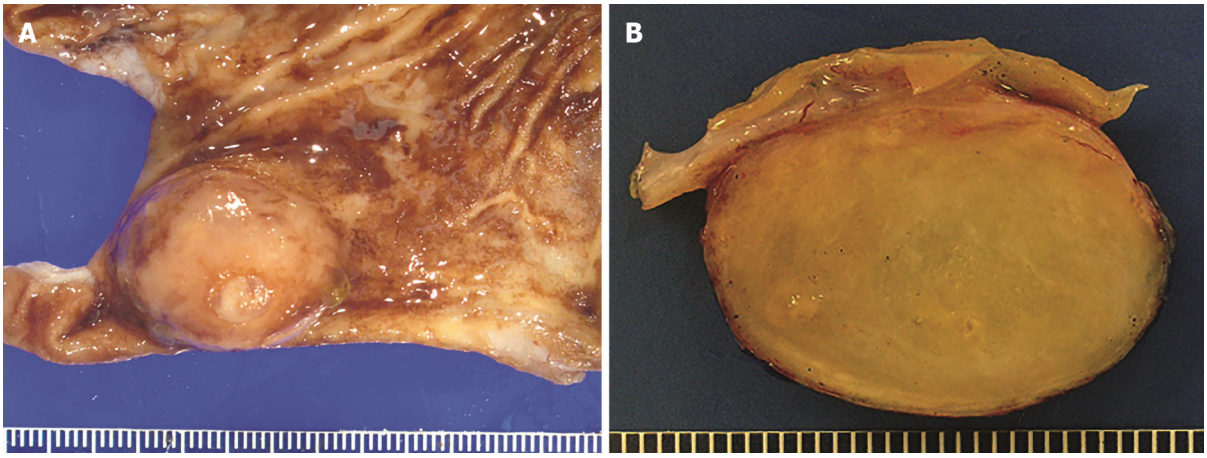

Figure 1 Gross findings of calcifying fibrous tumor. A: Partial gastrectomy showing a submucosal calcifying fibrous tumor mass lesion; B: Cut surface of calcifying fibrous tumor showing a well-circumscribed, unencapsulated, firm mass with variable calcifications.

The histologic features that characterize CFTs include well-circumscribed, unencapsulated hypocellular spindle cell proliferations embedded within abundant hyalinized collagen. The collagen may be arranged in a haphazard or whorled pattern (Figure 2A). The spindle cells exhibit bland, ovoid, vesicular nuclei with inconspicuous nucleoli and abundant eosinophilic cytoplasm (Figure 2B). Atypia and mitotic figures are rare with less than 1 per 10 high power field. Necrosis is universally absent. Scattered calcifications are common and may be psammomatous or dystrophic. A lymphoplasmacytic infiltrate is virtually always present (Figure 2C), and may occasionally form lymphoid follicles (Figure 2D), which in turn may have germinal centers. A lymphoplasmacytic cuff may be noted at the periphery of the tumor. Entrapment of nerves or adipocytes is only rarely observed[3,6].

Immunohistochemically, the spindle cells stain positively for CD34, vimentin and factor XIIIa. Smooth muscle actin, muscle specific actin, ALK (anaplastic lymphoma kinase), desmin, S100, cytokeratin, DOG1 (discovered on gastrointestinal stromal tumors protein 1) and c-kit immunostains are typically negative[6,10].

PATHOGENESIS

Currently, the pathogenesis of CFT is uncertain. Possible etiologies include previous infection, trauma or surgical intervention. The plasma cells in CFT may stain positively for IgG and IgG4, which has raised the possibility that CFT may be a manifestation of IgG4-related disease (IgG4-RD)[9]. IgG4-RD leads to formation of pseudotumors, most commonly in the pancreas[11]. Similar to CFT, IgG4-RD gives rise to inflammatory mass lesions that are clinically benign. However, IgG4-RD giving rise to mass lesions in the stomach is remarkably rare, although such cases have been reported[12]. Histologically, IgG4-RD shows storiform fibrosis, lymphoplasmacytic inflammation, and obliterative phlebitis[11]. CFT similarly shows a lymphoplasmacytic infiltrate, and the dense fibrosis seen in CFT frequently shows a vaguely but not classic storiform pattern[13]. Cases of CFT with increases in IgG4-positive plasma cells have been reported, occasionally with elevated serum IgG4[9,14,15]. However, cases of CFT in patients with other manifestations of IgG4-RD such as autoimmune pancreatitis type I are often lacking. Histologic evidence of obliterative phlebitis, a major criterion of IgG4-RD, has not been convincingly demonstrated in CFT. Furthermore, the finding of variably increased IgG4-positive plasma cells is nonspecific, and may be seen in a variety of inflammatory conditions[16].

It has been hypothesized that CFT may represent a late sclerosing ("burnt-out") phase of inflammatory myofibroblastic tumor (IMT). This hypothesis was formed due to the observation that CFT and IMT may co-exist in close proximity in the same patient[17]. Late-stage IMTs are paucicellular with dense collagenous fibrosis and are occasionally associated with calcification. Studies showing the presence of ALK rearrangements in IMT, which are not present in CFT, have suggested that CFT is a distinct neoplastic process[18]. However, genome-wide methylation analysis has shown overlapping methylation patterns of CFT and IMT, suggesting that both lesions may represent a spectrum of the same disease, irrespective of gene fusion analysis[19].

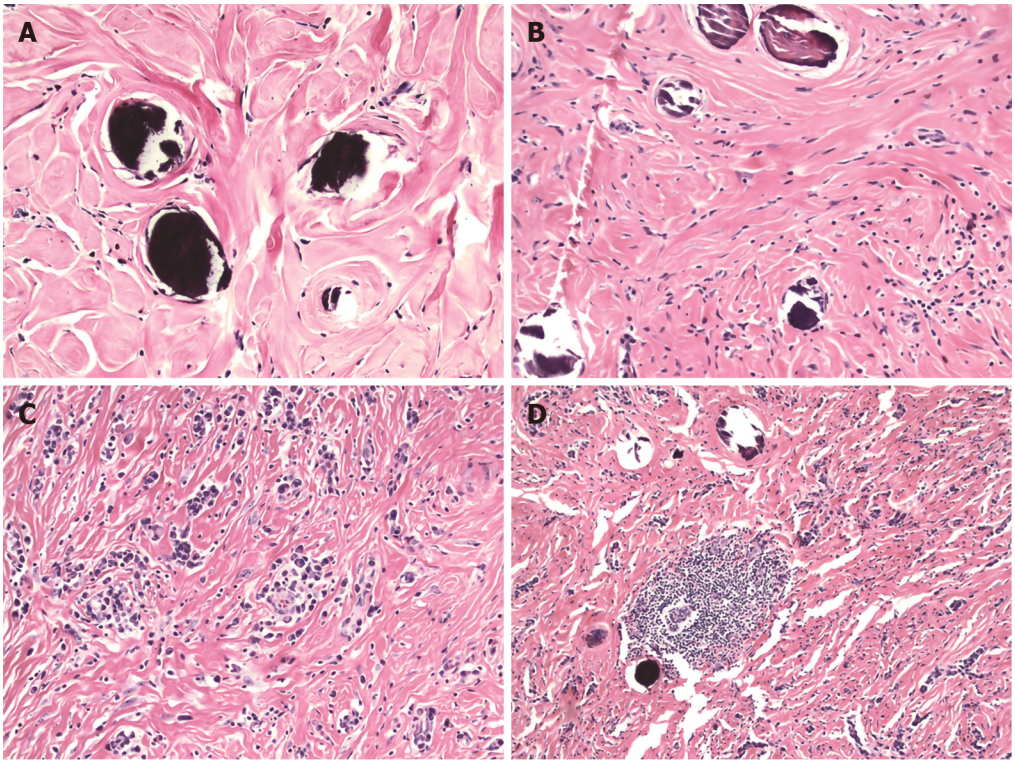

Figure 2 Histologic features of calcifying fibrous tumor. A: Haphazard or whorled pattern hyalinization admixed with calcifications (original magnification 200 ×); B: Dense hyalinization admixed with spindle cells and psammomatous calcification (original magnification 200 ×); C: Lymphoplasmacytic infiltrate in a background of dense hyalinization (original magnification 200 ×); D: Lymphoid follicle in a background of dense hyalinization and scattered calcification (original magnification 100 ×). Hematoxylin-eosin stain.

CFT has also been associated with hyaline vascular type Castleman disease, although such an association appears to be remarkably rare. Castleman disease is a benign lymphoproliferative disorder that may occur in a single (unicentric) or in multiple (multicentric) lymph nodes. The hyaline vascular type is characterized by germinal centers surrounded by concentric rings of mantle zone lymphocytes and a hyalinized vascular proliferation between follicles[20]. Six cases have been reported from 1999 to 2019 in which CFT was found in association with hyaline vascular type Castleman disease[21-26]. In some cases, both CFT and hyaline vascular type Castleman disease were found to co-exist within the same lymph node tissue[21,22,25,26], while in other cases, patients with gastrointestinal CFTs were found to have hyaline vascular type Castleman disease in adjacent lymph nodes[23,24]. The etiology of this association remains unclear and raises the possibility that both entities may represent different stages of the same reactive disease process. It has been suggested that CFT-like features in lymph nodes of patients with hyaline vascular type Castleman disease are the result of fine needle aspiration-induced trauma, supporting the notion that CFTs may be reactive proliferations resulting from trauma[21,22]. Further supporting this theory are reports of patients developing soft tissue CFTs within a few months of sustaining trauma at the same anatomic site[27]. However, many cases of CFTs in the gastrointestinal tract are not associated with a prior history of trauma or acute tissue injuries such as peptic ulcers or perforations, suggesting that gastrointestinal tract CFTs may be the result of chronic tissue injury, rather than acute trauma, or may have a different pathogenesis altogether. The passage of food contents conceivably exposes the gastrointestinal tract to localized tissue injury that may induce an inflammatory sclerotic reaction, ultimately giving rise to CFTs, and potentially accounting for the relatively high frequency of CFTs in the gastrointestinal tract.

An additional rare association has been made between CFT and sclerosing angiomatoid nodular transformation of the spleen (SANT). SANT refers to a splenic non-neoplastic vascular proliferation of unknown etiology, histologically characterized by nodules with vascular spaces lined with plump endothelial cells interspersed with ovoid or spindle cells, surrounded by concentric collagen fibers[28]. Rare cases of SANT co-existing with disseminated abdominal CFTs have been described[29,30], and suggest a possibly common reactive mechanism. Additionally, increased IgG4-positive plasma cells have been observed in SANT and in associated CFTs, suggesting that both

processes may be pathophysiologically associated with IgG4-RD[29].

Ultimately, the pathogenesis of CFTs remains unclear, although emerging evidence has suggested that these lesions may be pathophysiologically associated with other inflammatory lesions such as IgG4-RD, IMT, hyaline vascular type Castleman disease, or SANT. CFTs may represent a late-stage manifestation of any one of these lesions. Alternatively, CFTs may simply represent an end-stage manifestation of a variety of inflammatory and sclerotic processes, without regard to a specific etiology. This may account for the association of CFT with such a variety of other lesions. Other genetic and/or environmental factors, such as trauma, may contribute to formation of CFTs, and etiologies may differ based upon anatomic site. More studies are needed to further elucidate the pathogenesis of CFT.

DIFFERENTIAL DIAGNOSIS

CFT, with a hypocellular spindle cell proliferation, abundant hyalinized collagen, scattered calcifications, and variable degree of lymphoplasmacytic inflammation, lends itself to a myriad of differential diagnostic considerations. The differential diagnosis for CFT of the gastrointestinal tract includes gastrointestinal stromal tumor (GIST), schwannoma, leiomyoma, solitary fibrous tumor, IMT, plexiform fibromyxoma, fibromatosis, sclerosing mesenteritis, and reactive nodular fibrous pseudotumor (RNFP).

Spindle cell GIST consists of a uniform, bland spindle cell population arranged in short fascicles[31]. The sclerosing subtype of GIST shows extensive collagen deposition with relatively low cellularity, and frequently shows calcifications, complicating distinction of this entity from CFT[32]. Features that, when present, would favor CFT over sclerosing GIST include psammomatous calcification and a prominent lymphoplasmacytic infiltrate. Immunohistochemically, the spindle cells of GIST stain diffusely positive for c-kit and DOG1, while these stains are negative in CFT. CD34 immunostaining is positive in both entities, however, positivity is typically variable and focal in CFT and diffuse in GIST[3,31]. The mutations of c-*kit* and *PDGFRA* commonly seen in GIST were not identified in gastric or colonic CFTs, and can be used to differentiate these two entities at the molecular level[13,33].

Gastrointestinal schwannomas are most commonly found in the stomach and consist of spindle cells with "wavy" nuclei and tapered ends that are arranged in a microtrabecular pattern[34]. A peripheral lymphoid cuff is characteristic of schwannoma and may be a confounding factor with CFT. A microtrabecular pattern and scattered atypical cells assists in distinguishing schwannoma from CFT. However, definitive exclusion of schwannoma is best accomplished by S100 staining, which is diffusely positive in schwannoma and negative in CFT.

Leiomyomas typically arise in the stomach, sigmoid colon, rectum and esophagus and consist of spindle cells with elongated, cigar-shaped nuclei and abundant red-pink cytoplasm[35]. Similar to CFTs, leiomyomas may have a hyalinizing stroma, and mitoses and nuclear atypia are rare. Unlike in CFTs, immunohistochemistry in leiomyomas shows positivity for smooth muscle actin and desmin, and negativity for CD34[36].

Solitary fibrous tumors (SFTs) consist of spindle-shaped cells with thick bands of hyalinized collagen, with hemangiopericytoma-like (staghorn) vessels, and perivascular hyalinization[37]. Like CFTs, solitary fibrous tumors show extensive hyalinization and an absence of atypia or mitotic figures[3,37]. However, SFTs typically lack lymphoplasmacytic inflammation[37]. Solitary fibrous tumors stain positively for CD34 (95%), CD99 (70%), BCL-2, EMA (20%-30%), and show nuclear expression of STAT-6[38].

IMT is a myofibroblastic spindle-cell proliferation with a predominantly lymphoplasmacytic infiltrate and abundant background blood vessels. The inflammatory infiltrate occasionally contains neutrophils, eosinophils and/or foamy histiocytes. IMT demonstrates variable cellularity and typically shows a myxoid background. Unlike CFT, IMTs only rarely contain calcifications[39]. Positive immunohistochemical stains for smooth muscle actin and ALK are typically seen in IMT, but are negative in CFT[39].

Plexiform fibromyxoma (also known as plexiform angiomyxoid myofibroblastic tumor) is a benign tumor occurring in the stomach that generally forms a submucosal or transmural mass ranging from 0.3 cm to 17 cm[40]. The tumor shows a plexiform multinodular growth pattern with a hypocellular proliferation of bland spindle cells, myxoid stroma, and prominent network of small blood vessels[41]. Plexiform fibromyxomas are positive for smooth muscle actin and negative for CD34, DOG1,

S100, and c-kit[40,42].

Desmoid tumor (fibromatosis) commonly involves the abdominal wall or mesentery and is characterized by sweeping fascicles of bland spindle cells with an infiltrative growth pattern. Isolated mass-forming desmoid tumors involving the stomach and gastroesophageal junction have been reported[43,44]. Desmoid tumor is occasionally associated with keloid-like fibers. Unlike CFT, desmoid tumor is not characterized by prominent lymphoplasmacytic inflammation or calcifications, and it shows strong immunoreactivity for nuclear b-catenin[45].

A subset of sclerosing mesenteritis is now considered to be a manifestation of IgG4-RD[46]. The disease involves the small bowel mesentery and, similar to CFT, is characterized by a paucicellular, fibrotic spindle cell proliferation with a prominent lymphoplasmacytic infiltrate. Additionally, sclerosing mesenteritis may show variable focal calcifications, although prominent calcifications are not a classic feature[46]. Sclerosing mesenteritis surrounds and entraps fat and classically is associated with fat necrosis, helping to distinguish this entity from CFT. Additionally, the presence of obliterative phlebitis in IgG4-related sclerosing mesenteritis may help to distinguish this entity from CFT.

RNFP is a rare fibroinflammatory lesion of the gastrointestinal tract which histologically closely resembles CFT. Similar to CFT, RNFP is composed of a paucicellular proliferation of fibroblasts within a hyalinized collagenous stroma, associated with a sparse lymphocytic inflammatory infiltrate[47]. However, CFT is typically more cellular, the fascicles of the spindle cells are more regular, and the inflammatory infiltrate consists of granulocytes and plasma cells as well as lymphocytes. The presence of dystrophic or psammomatous calcification in CFT assists in distinguishing these two entities. By immunohistochemistry, RNFP shows positive staining for vimentin, smooth muscle actin, and desmin, and is negative for CD34. In contrast, CFT is negative for smooth muscle actin and desmin, but shows positive staining for CD34[47].

MANAGEMENT AND CLINICAL OUTCOMES

CFTs are benign lesions and are most commonly treated by local surgical resection[2]. Few cases of complete resection by endoscopic submucosal dissection have been reported and have not been associated with recurrence[48,49]. While complete excision appears appropriate for large tumors, some have suggested that long-term follow-up is sufficient for patients with small, asymptomatic gastrointestinal CFTs[50]. The local recurrence rate for CFT has been estimated to be approximately 10%[51], and some authors have recommended follow-up for patients following excision of CFT[52]. However, no guidelines for follow-up have been established. Furthermore, the rate of recurrence in gastrointestinal CFTs as opposed to CFTs arising at other sites remains unclear. Some authors have suggested that gastric CFTs, for example, have no tendency for local recurrence compared to soft tissue CFTs[51]. While multifocal CFTs in the gastrointestinal tract have been reported, true recurrence or metastatic disease has not been shown[18,50]. To date, there are no reported cases of malignant transformation of CFT or of metastatic disease. No deaths due to CFT have thus far been reported in the literature.

CONCLUSION

The gastrointestinal tract is a common site of involvement by CFT. CFTs are histologically characterized by a spindle cell proliferation with a densely hyalinized stroma, calcifications, and variable degree of lymphoplasmacytic infiltrate. Distinction of this entity from other stromal lesions of the GI tract is important as management and prognosis may differ. The most important entity to consider in the differential diagnosis is GIST, which is considerably more common, and which may have aggressive behavior. Similarly, IMT often has a worse prognosis and must be excluded. Further studies are needed to clarify the pathogenesis of CFTs. The relationship between CFT and IgG4-RD remains unclear, and could have important implications for management and prognosis. IgG4-RDs are treated with steroids, while CFTs are currently managed with local resection. Furthermore, IgG4-RD is a systemic illness, and establishing CFT as an IgG4-RD would necessitate increased surveillance for other IgG4-RDs in patients with CFT. It is possible that only a subset of CFTs may arise in the context of either IgG4-RD or IMT. Additional larger studies with molecular

characterization of CFTs could help to clarify these relationships. Further studies are needed to clarify the recurrence rate of CFTs in different anatomic sites in the gastrointestinal tract. Such studies could drive guidelines for management of patients with CFT, as certain populations may be amenable to close follow-up without the need for an invasive procedure. However, current data suggest that local resection is typically curative.

REFERENCES

1 **Rosenthal NS**, Abdul-Karim FW. Childhood fibrous tumor with psammoma bodies. Clinicopathologic features in two cases. *Arch Pathol Lab Med* 1988; **112**: 798-800 [PMID: 3395217]

2 **Chorti A**, Papavramidis TS, Michalopoulos A. Calcifying Fibrous Tumor: Review of 157 Patients Reported in International Literature. *Medicine (Baltimore)* 2016; **95**: e3690 [PMID: 27196478 DOI: 10.1097/MD.0000000000003690]

3 **Pezhouh MK**, Rezaei MK, Shabihkhani M, Ghosh A, Belchis D, Montgomery EA, Voltaggio L. Clinicopathologic study of calcifying fibrous tumor of the gastrointestinal tract: a case series. *Hum Pathol* 2017; **62**: 199-205 [PMID: 28153506 DOI: 10.1016/j.humpath.2017.01.002]

4 **Li BJ**, Yang XD, Chen WX, Shi YH, Nie ZH, Wu J. Calcifying fibrous tumor of stomach: A case report. *Medicine (Baltimore)* 2017; **96**: e8882 [PMID: 29382014 DOI: 10.1097/MD.0000000000008882]

5 **Lee SW**, Yeh HZ, Chang CS. Calcifying fibrous pseudotumor of the esophagus. *J Chin Med Assoc* 2010; **73**: 599-601 [PMID: 21093829 DOI: 10.1016/S1726-4901(10)70130-1]

6 **Larson BK**, Dhall D. Calcifying Fibrous Tumor of the Gastrointestinal Tract. *Arch Pathol Lab Med* 2015; **139**: 943-947 [PMID: 26125434 DOI: 10.5858/arpa.2014-0032-RS]

7 **Liu Y**, Lu Q, Wu XL, Shen GJ, Luo T. Ultrasonographic imaging of calcifying fibrous tumor of cervical esophagus: A case report. *Medicine (Baltimore)* 2019; **98**: e16425 [PMID: 31305462 DOI: 10.1097/MD.0000000000016425]

8 **Delbecque K**, Legrand M, Boniver J, Lauwers GY, de Leval L. Calcifying fibrous tumour of the gastric wall. *Histopathology* 2004; **44**: 399-400 [PMID: 15049909 DOI: 10.1111/j.1365-2559.2004.01779.x]

9 **Larson BK**, Balzer B, Goldwasser J, Dhall D. Calcifying fibrous tumor: an unrecognized IgG4--related disease? *APMIS* 2015; **123**: 72-76 [PMID: 25244325 DOI: 10.1111/apm.12302]

10 **Zhou J**, Zhou L, Wu S, Li R, Yang X, Xu H, Zheng S, Wang A, Wang C. Clinicopathologic Study of Calcifying Fibrous Tumor Emphasizing Different Anatomical Distribution and Favorable Prognosis. *Biomed Res Int* 2019; **2019**: 5026860 [PMID: 31355265 DOI: 10.1155/2019/5026860]

11 **Inoue D**, Yoshida K, Yoneda N, Ozaki K, Matsubara T, Nagai K, Okumura K, Toshima F, Toyama J, Minami T, Matsui O, Gabata T, Zen Y. IgG4-related disease: dataset of 235 consecutive patients. *Medicine (Baltimore)* 2015; **94**: e680 [PMID: 25881845 DOI: 10.1097/MD.0000000000000680]

12 **Woo CG**, Yook JH, Kim AY, Kim J. IgG4-Related Disease Presented as a Mural Mass in the Stomach. *J Pathol Transl Med* 2016; **50**: 67-70 [PMID: 26420251 DOI: 10.4132/jptm.2015.07.28]

13 **Agaimy A**, Bihl MP, Tornillo L, Wünsch PH, Hartmann A, Michal M. Calcifying fibrous tumor of the stomach: clinicopathologic and molecular study of seven cases with literature review and reappraisal of histogenesis. *Am J Surg Pathol* 2010; **34**: 271-278 [PMID: 20090503 DOI: 10.1097/PAS.0b013e3181ccb172]

14 **Hamura R**, Koyama T, Kawamura M, Kawamura T, Nakamura M, Yanaga K. Gastric calcifying fibrous tumor suspected to be complicated with immunoglobulin G4-related disease treated by laparoscopy and endoscopy cooperative surgery: a case report. *Surg Case Rep* 2019; **5**: 150 [PMID: 31641880 DOI: 10.1186/s40792-019-0714-6]

15 **Hu YH**, Yu CT, Chen CJ, Wen MC. Calcifying fibrous tumour: An IgG4-related disease or not? *Int J Exp Pathol* 2020; **101**: 38-44 [PMID: 32090409 DOI: 10.1111/iep.12339]

16 **Strehl JD**, Hartmann A, Agaimy A. Numerous IgG4-positive plasma cells are ubiquitous in diverse localised non-specific chronic inflammatory conditions and need to be distinguished from IgG4-related systemic disorders. *J Clin Pathol* 2011; **64**: 237-243 [PMID: 21233087 DOI: 10.1136/jcp.2010.085613]

17 **Van Dorpe J**, Ectors N, Geboes K, D'Hoore A, Sciot R. Is calcifying fibrous pseudotumor a late sclerosing stage of inflammatory myofibroblastic tumor? *Am J Surg Pathol* 1999; **23**: 329-335 [PMID: 10078925 DOI: 10.1097/00000478-199903000-00013]

18 **Nascimento AF**, Ruiz R, Hornick JL, Fletcher CD. Calcifying fibrous 'pseudotumor': clinicopathologic study of 15 cases and analysis of its relationship to inflammatory myofibroblastic tumor. *Int J Surg Pathol* 2002; **10**: 189-196 [PMID: 12232572 DOI: 10.1177/106689690201000304]

19 **Tomassen T**, Koelsche C, de Leng WWJ, Kommoss FKF, Voijs CMA, Peeters T, van Noesel MM, Creytens D, van Gorp JM, Petersen I, Vokuhl C, von Deimling A, Mentzel T, Flucke U. Calcifying fibrous tumor and inflammatory myofibroblastic tumor are epigenetically related: A comparative genome-wide methylation study. *Ann Diagn Pathol* 2019; **41**: 102-105 [PMID: 31202195 DOI: 10.1016/j.anndiagpath.2019.05.013]

20 **Murro D**, Agab M, Brickman A, Loew J, Gattuso P. Cytological features of Castleman disease: a review. *J Am Soc Cytopathol* 2016; **5**: 100-106 [PMID: 31042489 DOI: 10.1016/j.jasc.2015.08.002]

21 **Marbaniang E**, Khonglah Y, Dey B, Shunyu B, Gogoi B. Castleman's disease associated with calcifying fibrous tumor: A rare association with review of literature. *J Lab Physicians* 2019; **11**: 171-173 [PMID: 31160859 DOI: 10.4103/JLP.JLP_16_19]

22 **Dargent JL**, Delplace J, Roufosse C, Laget JP, Lespagnard L. Development of a calcifying fibrous pseudotumour within a lesion of Castleman disease, hyaline-vascular subtype. *J Clin Pathol* 1999; **52**: 547-549 [PMID: 10605414 DOI: 10.1136/jcp.52.7.547]

23 **Azam M**, Husen YA, Pervez S. Calcifying fibrous pseudotumor in association with hyaline vascular type Castleman's disease. *Indian J Pathol Microbiol* 2009; **52**: 527-529 [PMID: 19805963 DOI: 10.4103/0377-4929.56151]

24 **Valladolid G**, Weisenberg E, Sundaresan R, Maker AV. Calcifying fibrous tumor of the small intestine associated with Castleman-like lymphadenopathy. *J Gastrointest Surg* 2014; **18**: 1205-1208 [PMID: 24452381 DOI: 10.1007/s11605-014-2458-8]

25 **Ma H**, Jiang M, Xiao W. A rare stroma-rich variant of hyaline-vascular Castleman's disease associated with calcifying fibrous pseudotumor. *Int J Clin Exp Pathol* 2015; **8**: 3362-3364 [PMID: 26045869]

26 **Harmankaya İ**, Ugras NS, Sekmenli T, Demir F, Köksal Y. Calcified fibrous pseudotumor with Castleman disease. *Autops Case Rep* 2018; **8**: e2018033 [PMID: 30101137 DOI: 10.4322/acr.2018.033]

27 **Zámecník M**, Dorociak F, Veselý L. Calcifying fibrous pseudotumor after trauma. *Pathol Int* 1997; **47**: 812 [PMID: 9413045 DOI: 10.1111/j.1440-1827.1997.tb04464.x]

28 **Pradhan D**, Mohanty SK. Sclerosing angiomatoid nodular transformation of the spleen. *Arch Pathol Lab Med* 2013; **137**: 1309-1312 [PMID: 23991745 DOI: 10.5858/arpa.2012-0601-RS]

29 **Kuo TT**, Chen TC, Lee LY. Sclerosing angiomatoid nodular transformation of the spleen (SANT): clinicopathological study of 10 cases with or without abdominal disseminated calcifying fibrous tumors, and the presence of a significant number of IgG4+ plasma cells. *Pathol Int* 2009; **59**: 844-850 [PMID: 20021608 DOI: 10.1111/j.1440-1827.2009.02456.x]

30 **Lee JC**, Lien HC, Hsiao CH. Coexisting sclerosing angiomatoid nodular transformation of the spleen with multiple calcifying fibrous pseudotumors in a patient. *J Formos Med Assoc* 2007; **106**: 234-239 [PMID: 17389168 DOI: 10.1016/S0929-6646(09)60245-X]

31 **Patil DT**, Rubin BP. Gastrointestinal stromal tumor: advances in diagnosis and management. *Arch Pathol Lab Med* 2011; **135**: 1298-1310 [PMID: 21970485 DOI: 10.5858/arpa.2011-0022-RA]

32 **Miettinen M**, Sobin LH, Lasota J. Gastrointestinal stromal tumors of the stomach: a clinicopathologic, immunohistochemical, and molecular genetic study of 1765 cases with long-term follow-up. *Am J Surg Pathol* 2005; **29**: 52-68 [PMID: 15613856 DOI: 10.1097/01.pas.0000146010.92933.de]

33 **Zhang L**, Wei JG, Fang SG, Luo RK, Xu ZG, Li DJ, Kong LF. [Calcifying fibrous tumor: a clinicopathological analysis of 32 cases]. *Zhonghua Bing Li Xue Za Zhi* 2020; **49**: 129-133 [PMID: 32074724 DOI: 10.3760/cma.j.issn.0529-5807.2020.02.005]

34 **Voltaggio L**, Murray R, Lasota J, Miettinen M. Gastric schwannoma: a clinicopathologic study of 51 cases and critical review of the literature. *Hum Pathol* 2012; **43**: 650-659 [PMID: 22137423 DOI: 10.1016/j.humpath.2011.07.006]

35 **Rittershaus AC**, Appelman HD. Benign gastrointestinal mesenchymal BUMPS: a brief review of some spindle cell polyps with published names. *Arch Pathol Lab Med* 2011; **135**: 1311-1319 [PMID: 21970486 DOI: 10.5858/arpa.2011-0038-RA]

36 **Miettinen M**, Sarlomo-Rikala M, Sobin LH, Lasota J. Esophageal stromal tumors: a clinicopathologic, immunohistochemical, and molecular genetic study of 17 cases and comparison with esophageal leiomyomas and leiomyosarcomas. *Am J Surg Pathol* 2000; **24**: 211-222 [PMID: 10680889 DOI: 10.1097/00000478-200002000-00007]

37 **Lee WA**, Lee MK, Jeen YM, Kie JH, Chung JJ, Yun SH. Solitary fibrous tumor arising in gastric serosa. *Pathol Int* 2004; **54**: 436-439 [PMID: 15144403 DOI: 10.1111/j.1440-1827.2004.01638.x]

38 **Doyle LA**, Vivero M, Fletcher CD, Mertens F, Hornick JL. Nuclear expression of STAT6 distinguishes solitary fibrous tumor from histologic mimics. *Mod Pathol* 2014; **27**: 390-395 [PMID: 24030747 DOI: 10.1038/modpathol.2013.164]

39 **Hill KA**, Gonzalez-Crussi F, Chou PM. Calcifying fibrous pseudotumor *versus* inflammatory myofibroblastic tumor: a histological and immunohistochemical comparison. *Mod Pathol* 2001; **14**: 784-790 [PMID: 11504838 DOI: 10.1038/modpathol.3880390]

40 **Lai J**, Kresak JL, Cao D, Zhang D, Zhang S, Leon ME, Shenoy A, Liu W, Trevino J, Starostik P, Gonzalo DH, Wang H, Liu X, Fan X. Gastric Plexiform Fibromyxoma: A Great Mimic of Gastrointestinal Stromal Tumor (GIST) and Diagnostic Pitfalls. *J Surg Res* 2019; **239**: 76-82 [PMID: 30822694 DOI: 10.1016/j.jss.2019.01.062]

41 **Takahashi Y**, Suzuki M, Fukusato T. Plexiform angiomyxoid myofibroblastic tumor of the stomach. *World J Gastroenterol* 2010; **16**: 2835-2840 [PMID: 20556828 DOI: 10.3748/wjg.v16.i23.2835]

42 **Rau TT**, Hartmann A, Dietmaier W, Schmitz J, Hohenberger W, Hofstaedter F, Katenkamp K. Plexiform angiomyxoid myofibroblastic tumour: differential diagnosis of gastrointestinal stromal tumour in the stomach. *J Clin Pathol* 2008; **61**: 1136-1137 [PMID: 18820104 DOI: 10.1136/jcp.2008.059162]

43 **Lu Q**, Wang K, Liu D, Huang S, Li H, Jiang Y, Chen H, Wang G, Hu J. Stomach desmoid tumor: a case report and review of the literature. *Int J Clin Exp Pathol* 2017; **10**: 10531-10538 [PMID: 31966392]

44 **Díaz Ruiz R**, Flores Fernández V, Pajares Díaz JA. Desmoid fibromatosis of the esophagogastric junction. *Rev Esp Enferm Dig* 2018; **110**: 677-678 [PMID: 30168335 DOI: 10.17235/reed.2018.5630/2018]

45 **Montgomery E**, Torbenson MS, Kaushal M, Fisher C, Abraham SC. Beta-catenin immunohistochemistry separates mesenteric fibromatosis from gastrointestinal stromal tumor and sclerosing mesenteritis. *Am J Surg Pathol* 2002; **26**: 1296-1301 [PMID: 12360044 DOI: 10.1097/00000478-200210000-00006]

46 **Lee SJ**, Park CK, Yang WI, Kim SK. IgG4-Related Sclerosing Mesenteritis. *J Pathol Transl Med* 2016; **50**: 309-311 [PMID: 26755359 DOI: 10.4132/jptm.2015.12.03]

47 **Yantiss RK**, Nielsen GP, Lauwers GY, Rosenberg AE. Reactive nodular fibrous pseudotumor of the gastrointestinal tract and mesentery: a clinicopathologic study of five cases. *Am J Surg Pathol* 2003; **27**: 532-540 [PMID: 12657940 DOI: 10.1097/00000478-200304000-00015]

48 **Ogasawara N**, Izawa S, Mizuno M, Tanabe A, Ozeki T, Noda H, Takahashi E, Sasaki M, Yokoi T, Kasugai K. Gastric calcifying fibrous tumor removed by endoscopic submucosal dissection. *World J Gastrointest Endosc* 2013; **5**: 457-460 [PMID: 24044047 DOI: 10.4253/wjge.v5.i9.457]

49 **Tian S**, Zeng Z, Peng X, Dong W. Gastric calcifying fibrous tumor: A clinicopathological study of nine cases. *Exp Ther Med* 2018; **16**: 5137-5143 [PMID: 30546412 DOI: 10.3892/etm.2018.6892]

50 **Tseng IT**, Chen ST, Huang ZZ, I. TH, Ker CK. Multiple calcifying fibrous tumors in the small intestine and the mesentery. *Formos J Surg* 2012; **45**: 33-36 [DOI: 10.1016/j.fjs.2011.11.007]

51 **George SA**, Abdeen S. Gastric Calcifying Fibrous Tumor Resembling Gastrointestinal Stromal Tumor: A Case Report. *Iran J Pathol* 2015; **10**: 306-309 [PMID: 26351502]

52 **Luques L**, Atlan KA, Shussman N. A Rare Benign Gastrointestinal Lesion Identified as a Calcifying Fibrous Tumor. *Clin Gastroenterol Hepatol* 2017; **15**: A25 [PMID: 27765730 DOI: 10.1016/j.cgh.2016.10.014]

World Journal of Gastroenterology

Submit a Manuscript: https://www.f6publishing.com

World J Gastroenterol 2020 October 7; 26(37): 5606-5616

DOI: 10.3748/wjg.v26.i37.5606

ISSN 1007-9327 (print) ISSN 2219-2840 (online)

MINIREVIEWS

Artificial intelligence technologies for the detection of colorectal lesions: The future is now

Simona Attardo, Viveksandeep Thoguluva Chandrasekar, Marco Spadaccini, Roberta Maselli, Harsh K Patel, Madhav Desai, Antonio Capogreco, Matteo Badalamenti, Piera Alessia Galtieri, Gaia Pellegatta, Alessandro Fugazza, Silvia Carrara, Andrea Anderloni, Pietro Occhipinti, Cesare Hassan, Prateek Sharma, Alessandro Repici

ORCID number: Simona Attardo 0000-0003-0232-3682; Viveksandeep Thoguluva Chandrasekar 0000-0001-5256-4113; Marco Spadaccini 0000-0003-3909-9012; Roberta Maselli 0000-0001-7291-9110; Harsh K Patel 0000-0002-9180-2150; Madhav Desai 0000-0001-8871-3627; Antonio Capogreco 0000-0002-2212-2266; Matteo Badalamenti 0000-0002-95439862; Piera Alessia Galtieri 0000-0002-3253-6972; Gaia Pellegatta 0000-0003-0235-4905; Alessandro Fugazza 0000-0003-0485-4903; Silvia Carrara 0000-0003-4206-9463; Andrea Anderloni 0000-0002-1021-0031; Pietro Occhipinti 0000-0001-7048-4600; Cesare Hassan 0000-0001-7167-1459; Prateek Sharma 0000-0003-4003-7548; Alessandro Repici 0000-0002-1621-6450.

Author contributions: Attardo S, Chandrasekar VT equally contributed to this work; Attardo S, Chandrasekar VT and Spadaccini M substantial contributions to conception and design of the study, acquisition of data, or analysis and interpretation of data, drafting the article; Maselli R, Patel HK, Desai M, Capogreco A, Badalamenti M, Galtieri PA, Pellegatta G, Fugazza A, Carrara S, Anderloni A, Occhipinti P, Hassan C, Sharma P and Repici A substantial contributions to

Simona Attardo, Pietro Occhipinti, Department of Endoscopy and Digestive Disease, AOU Maggiore della Carità, Novara 28100, Italy

Viveksandeep Thoguluva Chandrasekar, Madhav Desai, Prateek Sharma, Department of Gastroenterology and Hepatology, Kansas City VA Medical Center, Kansas City, MO 66045, United States

Marco Spadaccini, Roberta Maselli, Antonio Capogreco, Matteo Badalamenti, Piera Alessia Galtieri, Gaia Pellegatta, Alessandro Fugazza, Silvia Carrara, Andrea Anderloni, Alessandro Repici, Department of Endoscopy, Humanitas Research Hospital, Rozzano 20089, Italy

Marco Spadaccini, Antonio Capogreco, Alessandro Repici, Department of Biomedical Sciences, Humanitas University, Rozzano 20089, Italy

Harsh K Patel, Department of Internal Medicine, Ochsner Clinic Foundation, New Orleans, LA 70124, United States

Cesare Hassan, Endoscopy Unit, Nuovo Regina Margherita Hospital, Roma 00153, Italy

Corresponding author: Marco Spadaccini, MD, Doctor, Department of Endoscopy, Humanitas Research Hospital, via Manzoni 56, Rozzano 20089, Italy. marco.spadaccini@humanitas.it

Abstract

Several studies have shown a significant adenoma miss rate up to 35% during screening colonoscopy, especially in patients with diminutive adenomas. The use of artificial intelligence (AI) in colonoscopy has been gaining popularity by helping endoscopists in polyp detection, with the aim to increase their adenoma detection rate (ADR) and polyp detection rate (PDR) in order to reduce the incidence of interval cancers. The efficacy of deep convolutional neural network (DCNN)-based AI system for polyp detection has been trained and tested in *ex vivo* settings such as colonoscopy still images or videos. Recent trials have evaluated the real-time efficacy of DCNN-based systems showing promising results in term of improved ADR and PDR. In this review we reported data from the preliminary *ex vivo* experiences and summarized the results of the initial randomized controlled trials.

conception and design of the study, acquisition of data, or analysis and interpretation of data, making critical revisions related to important intellectual content of the manuscript; and all authors approved the final version of the article to be published.

Conflict-of-interest statement: No conflict of interest.

Manuscript source: Invited manuscript

Received: June 2, 2020
Peer-review started: June 2, 2020
First decision: June 12, 2020
Revised: June 30, 2020
Accepted: September 16, 2020
Article in press: September 16, 2020
Published online: October 7, 2020

P-Reviewer: Triantafyllou K, Madalinski M, Qayed E, Li X
S-Editor: Wang JL
L-Editor: A
P-Editor: Ma YJ

Key Words: Endoscopy; Colonoscopy; Screening; Surveillance; Technology; Quality; Artificial intelligence

Core Tip: The use of artificial intelligence (AI) in colonoscopy has been gaining popularity in current times. At first, the efficacy of deep convolutional neural network (DCNN)-based AI system for polyp detection has been tested in *ex vivo* settings such as still images or videos from colonoscopies. Recent trials have evaluated the real-time efficacy of DCNN-based systems in improving adenoma detection rate and polyp detection rate. In this review we reported all the preliminary *ex vivo* experiences and summarized the promising results of the initial randomized controlled trials.

Citation: Attardo S, Chandrasekar VT, Spadaccini M, Maselli R, Patel HK, Desai M, Capogreco A, Badalamenti M, Galtieri PA, Pellegatta G, Fugazza A, Carrara S, Anderloni A, Occhipinti P, Hassan C, Sharma P, Repici A. Artificial intelligence technologies for the detection of colorectal lesions: The future is now. *World J Gastroenterol* 2020; 26(37): 5606-5616
URL: https://www.wjgnet.com/1007-9327/full/v26/i37/5606.htm
DOI: https://dx.doi.org/10.3748/wjg.v26.i37.5606

INTRODUCTION

Colorectal cancer (CRC) remains one of the leading causes of mortality among neoplastic diseases in the world[1]. Adequate colonoscopy based CRC screening programs have proved to be the key to reduce the risk of mortality, by early diagnosis of existing CRC and detection of pre-cancerous lesions[2-4]. Nevertheless, long-term effectiveness of colonoscopy is influenced by a range of variables that make it far from a perfect tool[5]. The effectiveness of a colonoscopy mainly depends on its quality, which in turn is dependent on the skill and expertise of the endoscopist. In fact, several studies have shown a significant adenoma miss rate of 24%-35%, especially in patients with diminutive adenomas[6,7]. These data are in line with interval cancers incidence (I-CRC), defined as the percentage of cancers diagnosed after a screening program and before the intended surveillance duration, of approximately 3%-5%[8,9].

Adenoma detection rate (ADR), defined as the proportion of patients in which at least one adenoma is detected (> 30% in men and 20% in women), along with adequate bowel preparation rate (> 85% of all colonoscopies), cecal intubation rate (> 95% in screening colonoscopies) and withdrawal time > 6 min, have been identified as quality metrics in screening and diagnostic colonoscopies, to reduce the I-CRC incidence[5,10,11]. Increase in ADR by 1% has shown to decrease the risk of incidence of CRC by 3%[9].

Innovations such as virtual and dye-spray chromoendoscopy and add on devices may help in improving ADR, particularly in low detectors[12-14]. However, all these strategies are operator-dependent tools requiring a learning curve. Further, individual experience and preference, may influence their use and efficacy.

The development of the artificial intelligence (AI) applications in the medical field has grown in interest in the past decade. Its performance on increasing automatic polyp and adenoma detection has shown promising results in order to achieve an higher ADR[15]. The use of computer aided diagnosis (CAD) for detection and further characterization of polyps had initially been studied in *ex vivo* studies but in the last few years, with the advancement in computer aided technology and emergence of deep learning algorithms, use of AI during colonoscopy has been achieved and more studies have been undertaken[16].

The aim of this review is to provide an overview on the progress of AI, with deep learning technologies, with experiences from initial *ex vivo* studies to real time adenoma detection from most recent studies.

AI

AI is the result of the evolution of general software systems that provide an input and

obtain an output through an algorithm. Machine Learning is the ability of a program, to learn, after an adequate training, from data that were initially entered, in order to obtain a model that can cope with scenarios that had not specifically been instructed for.

In gastroenterology, AI could be applied to tasks and clinical concerns faced by endoscopists every day. For instance, the human eye is capable of capturing only a fixed number of frames or images per second. AI can help the endoscopist to highlight a specific region of interest which needs a closer examination for identification of polyps, or can assist with categorizing polyps as hyperplastic versus adenomatous polyp, thus eventually improving the ADR[17].

In the endoscopic field, this innovative technology uses two principal Machine learning methods.

Handcrafted knowledge

In these systems, engineers create a set of rules that describe knowledge in a well-defined field. It is, historically, the first approach to artificial intelligence that, in the 1980s, led to the development of the first Expert Systems based on an approach "If … Then". The systems that fall into this category "reason" on a very specific problem, have no ability to learn and a poor ability to reason in conditions of uncertainty, when they do not have all the elements to make the decision. Indeed object characteristics are extracted and selected manually and are used to create a model capable of categorizing them through algorithms. With regards to the evaluation of polyps, it will record a series of fixed parameters such as shape, size and texture, alone or in combination, from polyp image datasets in order to differentiate a polyp from the normal mucosa.

Deep learning

In deep learning, large artificial neural networks receive algorithms and increasing amounts of data, constantly enhancing the ability to “think” and “learn”. The adjective “deep” refers to the many levels that the neural network accumulates over time, improving performance proportionally to the depth of the network. Although most of the current deep learning is performed with human supervision, the goal is the creation of neural networks that can self-train and “learn” autonomously. Similar to our biological brain which tries to formulate an answer to a question by deducing a logical hypothesis and arrive at a solution for a problem, deep learning sets neural connections in motion (exactly as the human mind does), improving its performance through continuous learning using the convolutional neural network (CNN), mathematical-computer calculation models based on the functioning of biological neural networks.

An artificial neural network receives external signals on a layer of input nodes (processing units), each of which is connected with numerous internal nodes, organized in several levels. Each node processes the received signals and transmits the result to subsequent nodes working in parallel (Figure 1). They need a system training phase that fixes the weights of individual neurons and this phase can take a long time, if the number of records and variables to be analyzed are exceptionally large. As a result, the network success significantly depends on the creator’s experience[18].

The following would be a solid example of how a deep neural network works with the visual recognition of the patterns. In polyp or adenoma detection, the neurons of the first layer could learn to recognize the edges, the neurons in the second layer could learn to recognize elementary shapes, for example the round shape created by the edges. The third layer would recognize even more complex forms as a 3D structure, the fourth would recognize further details as a granular pattern and so on.

EX VIVO STUDIES

Several *ex vivo* studies on AI have been published in the past 20 years (Table 1).

In the early 2000s, Karkanis *et al*[19] developed the first algorithm based on color analysis. They chose 180 polyp sample images and then randomly analyzed 1200 polyp frames from a 5-10 s extract of 60 videos. Algorithm results were promising with a 93.6% sensitivity and 99.3% specificity for polyp, although with the limitation of long processing time and the still images[19]. To address these issues, Wang *et al*[20] introduced a new algorithm called “Polyp-Alert”, that by using edge detection, succeeded in a near real-time video analysis at 10 frames per second from a sample of 43 polyp shots extrapolated randomly from 53 videos. They reported a 97.7% per-

Table 1 *Ex vivo* studies

Ref.	Country	Algorithm	Number of images/videos	Outcomes
Karkanis *et al*[19], 2003	Greece	Hand-crafted	60 videos	Sensitivity 94%, specificity 99%
Maroulis *et al*[34], 2003	Greece	Hand-crafted	2809 video frame	Accuracy > 95%
Jerebko *et al*[35], 2006	United States	Hand-crafted	56 images	Sensitivity 84%
Hwang *et al*[21], 2007	United States	Hand-crafted	8621 video frame	Per-polyp sensitivity 96%
Park *et al*[36], 2012	United States	Hand-crafted	35 videos, > 1 million frames	AUROC 0.89
Wang *et al*[37], 2014	United States	Hand-crafted	46 video file	Sensitivity 81,4%
Bernal *et al*[38], 2015	Spain	Hand-crafted	612 video frame	PPV 70%
Tajbakhsh *et al*[39], 2015	United States	Hand-crafted	19400 video frame (property), 300 video frame in CVC-ColonDB	Sensitivity on property database 48%, sensitivity in CVC-ColonDB 88%
Wang *et al*[20], 2015	United States	Hand-crafted	53 videos	Per-polyp senstivity 97.7%
Geetha *et al*[40], 2016	India	Hand-crafted	Still images 703 frames	Sensitivity 95%, specificity 97%
Fernández-Esparrach *et al*[22], 2016	Spain	Hand-crafted	25 videos	Sensitivity 70.4%, specificity 72.4%
Angermann *et al*[41], 2017	France	Hand-crafted	18 video with 10924 frames	100% per-polyp sensitivity PPV 50%
Park *et al*[42], 2016	United States	CNN	562 images	Sensitivity 86%, specificity 85%
Billah *et al*[43], 2017	Bangladesh	CNN	14000 still images	Sensitivity 99%, Specificity 99%
Yu *et al*[44], 2017	China	CNN	18 videos	Sensitivity 71%, PPV 88%
Zhang *et al*[23], 2017	China	CNN	150 random + 30 NBI images	Sensitivity 98%, PPV 99%, AUROC 1, Accuracy 86%
Urban *et al*[25], 2018	United States	CNN	ImageNet 1.2 mil, 53588 imges from videos	90% sensitivity
Misawa *et al*[24], 2018	Japan	CNN	135 video clips	Per-polyp sensitivity 94%, per-frame sensitivity 90%, specificity 63.3%, accuracy 76.5%
Pogorelov *et al*[45], 2018	Norway	CNN	1359 to 11954 frame from still images	Sensitivity 75%, specificity 94%
Yamada *et al*[46], 2018	Japan	CNN	4840 video images	Sensitivity 97%, specificity 99%, AUROC 0.975
Zhu *et al*[47], 2018	China	CNN	616 still images	Sensitivity 89%, 92% classification accuracy
Hassan *et al*[26], 2019	Italy	CNN	338 videos, 1.5 milion frames	Sensitivity per lesion 99.7%
Ahmad *et al*[48], 2019	England	CNN	24596 video frames	Sensitivity 85%, specificity 93%
Eelbode *et al*[49], 2019	Belgium	CNN	758 frames of still imges	Sensitiviy 92%, specificity 85%
Ka-Luen Lui *et al*[50], 2019	China	CNN	6 unedited videos	Per-polyp sensitivity 100%, per frame sensitivity 98.3%, specificity 99.7%, AUROC 0.99
Misawa *et al*[51], 2019	Japan	CNN	64 videos	86% sensitivity
Shichijo *et al*[52], 2019	Japan	CNN	1233 still images	Per-polyp sensitivity 100%, per-image semsitivity 99%, 76% PPV
Ozawa *et al*[53], 2020	Japan	CNN	7077 images	92% sensitivity, 86% PPV, accuracy 83%

USA: United States of America; CNN: Convolutional neural network; PPV: Positive predictive value; AUROC: Area under the receiver operating characteristic.

polyp sensitivity making this algorithm one of the first to be able to compete with real time speed. Many others methods have been proposed such as the one focusing on elliptical shape features from Hwang *et al*[21] or the window median depth of valleys accumulation energy maps system by Fernàndez-Esparrach *et al*[22], which have been able to detect a specific area of the image containing a polyp as it perceives polyps as mucosal protrusions with precise boundaries. As already pointed out, a steppingstone in the progress of AI was the advent of CNN and deep learning for CAD of polyps. The real innovation is tied to the fact that CAD systems can recognize polypoid and non-polypoid features without a continuous external input, after an initial training. In 2017, Zhang *et al*[23] devised an algorithm able to outperform expert endoscopists in polyp detection accuracy (86% *vs* 74%). They also reported a 98% sensitivity using a dataset which contained millions of naturalistic images in addition to images of polyps. Misawa *et al*[24] had trained the CNN with a dataset of 1.8 million of frames of polyps from 73 colonoscopy videos, with a total of 155 polyps. Each frame was retrospectively evaluated by two expert endoscopists before being included in the dataset. The sensitivity achieved was 90% with a specificity of 63.3% for the frame-based analysis[24]. Another interesting work was published in 2018 by Urban *et al*[25]. The group pre-trained the algorithm with a dataset of 8641 colonoscopy images from about 2000 patients achieving a 96.4% of accuracy. Moreover the authors confirmed the CNN value, empowering the polyps detection potential of any senior endoscopist. Further, they also showed the possibility to reduce the miss rate, including 11 videos with 73 polyps deliberately missed by the endoscopist because of a fast withdrawal. The CNN identified 67 of the 73 polyps with a false positive rate of 5%. Another comparison between the human brain and the AI was made by Hassan and colleagues with a new system, the GI-Genius (Medtronic)[26]. It uses a dataset of 2684 histologically confirmed neoplastic polyps manually annotated by expert endoscopists and listed in 1.5 million frames. They quantified the reaction time in polyp detection for AI and five expert endoscopists were asked to observe 338 video clips and to press a button, once a polyp was identified. The overall sensitivity per lesion was 99.7%. The AI anticipated the detection against endoscopists in 82% of cases. They concluded that this result is probably due to the variability of endoscopist expertise, a greater detection of hyperplastic polyps in the AI group and benefits of AI outweighing the limitations of human beings such as fatigue and distraction.

Data from main *ex vivo* experiences on AI systems are summarized in Table 1.

IN VIVO STUDIES

There is currently a lack of robust data on AI application in real time colonoscopy and its utility compared to *ex vivo* studies, but recently there have been more studies published. Registration data on different CAD systems are summarized in Table 2.

Klare *et al*[27] published a prospective study on CAD (KoloPal) to aid with polyp detection in high definition (HD) white light endoscopy in 55 patients. Fifty-five HD-white light colonoscopies were carried out by experienced endoscopists that through a verbal signal communicated the presence of any polyp. In parallel, another independent operator observed the examination on two other screens projecting images with and without the automated polyp detection software (APDS). The system highlighted with a green ring, particular areas of interest chosen by a combination of color, structure, textures, and motion, with a delay of 50-ms. Comparing APDS and endoscopists, polyp detection rate (PDR) (50.9% *vs* 56.4%) and ADR (29.1% *vs* 30.9%) were comparable. In particular a good performance was observed for larger (≥ 10 mm) and Paris morphology 0-Ip and 0-Is polyps. Smaller and flat polyp morphology had insufficient polyp detection rates by APDS. However, no polyp was detected by the APDS before detected by endoscopists, probably because of the software delay[27].

In the last year, there have been randomized controlled trials (RCT) published on the use of AI in colonoscopy (Table 3). In 2019 the first prospective RCT on real time automatic detection system using deep neural networks was conducted in China. Wang *et al*[15] enrolled 1058 patients undergoing routine colonoscopy. They were randomly assigned to either the CAD assisted colonoscopy group or the control group. They reported a significantly higher ADR in CAD group (29.1% *vs* 20.3%), primarily due to increase in detection of diminutive adenomas without a significant difference in large adenomas. The detection of hyperplastic polyps was also significantly higher in CAD group (43.6% *vs* 34.9%), which could potentially minimize the resection of these polyps and adverse events. There was also a higher mean number of adenomas detected (0.53 *vs* 0.31) in the CAD group[15].

Table 2 Artificial intelligence system country approval

Artificial intelligence system	Country
GI-Genius (Medtronic)	European Union, Australia, Israel, South Arabia
CAD-Eye (Fuji)	European Union
Discovery (Pentax)	European Union
Endobrain-EYE (Olympus)	Japan
Wision-AI	China

Table 3 *In vivo* randomized control trials characteristics

Ref.	Country	CAD system	CAD system aim	Number of patients		ADR (%)	ADR (%)
				WL	CAD	WL	CAD
Wang *et al*[15], 2019	China	EndoScreener	Detection	536	522	20.3	28.9
Wang *et al*[54], 2020	China	EndoScreener	Detection	478	484	28	34.1
Gong *et al*[30], 2020	China	ENDOANGEL	Quality	318	324	8	16
Repici *et al*[31], 2020	Italy	GI-Genius	Detection	344	341	40.4	54.8
Liu *et al*[28], 2020	China	Henan Xuanweitang Medical Information technology Co. Ltd.	Detection	518	508	23.9	39.2
Su *et al*[29], 2020	China	-	Detection; quality	315	308	16.5	28.9

WL: White light (control group); CAD: Computer aided diagnosis; ADR: Adenoma detection rate.

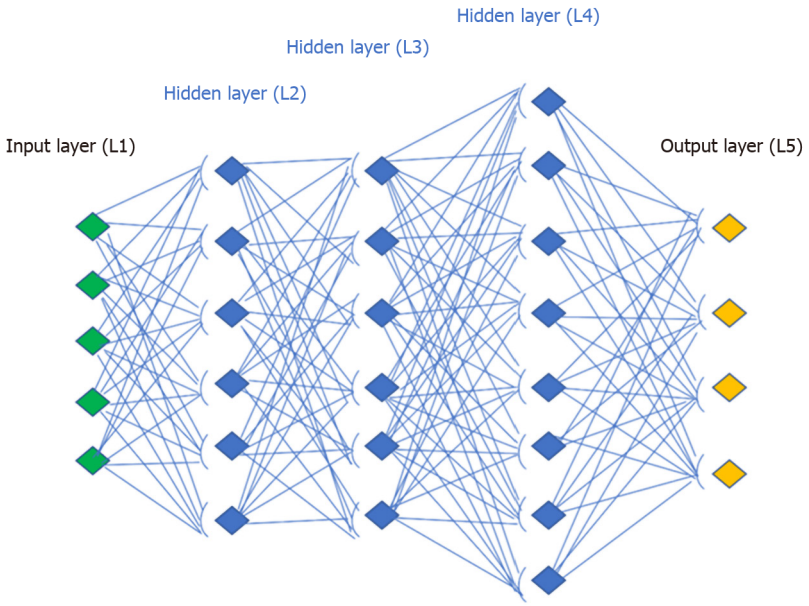

Figure 1 Convolutional neural network design.

Liu *et al*[28] published their experience from China and reported that the average number of polyps detected in the CAD group were higher (0.87 *vs* 0.57, $P < 0.001$). CAD group also achieved an ADR of 39% compared to 23% in the control group. The detection power was particularly improved for sessile serrated lesions and diminutive adenomas[28]. Su *et al*[29] developed an automatic quality control system (AQCS) using deep CNN and randomized 659 patients between AI and control groups. They reported significantly higher ADR, PDR, mean number of adenomas and mean number of polyps in the AQCS group[29].

The most recent eastern RCT was by Gong *et al*[30] using another CAD technology called ENDOANGEL. Apart from its help in polyp detection, ENDOANGEL technology was also trained for recording, and possibly improving, colonoscopy quality indicators such as cecal intubation or withdrawal time by real-time signaling during the procedure[30]. They reported a significant improvement in ADR but one of the principal limitations of this study is the lack of external validity due to very low ADR rates in both groups (17% *vs* 8%, CAD *vs* control group). In countries like China where the incidence of CRC is lower[1], it may be acceptable, but it's performance in Western countries where rates are much higher these such low ADR rates would indicate a low quality colonoscopy[5] .

As a matter of fact Repici *et al*[31] recently investigated the role of the GI-Genius CADe system (Figure 2) among expert endoscopists in a western-setting. The ADR of 40.4% of the control group was further increased up to 54.8% using the CADe system. Diminutive adenomas (≤ 5 mm) were detected in a significantly higher proportion of subjects in the CADe group (33.7%) than in the control group (26.5%), as were adenomas of 6–9 mm (10.6% *vs* 5.8%), regardless of morphology or location. Based on colonoscopy videos of such a trial, the authors developed a "false positive" classification aiming to standardize future reports on this topic for a better insight on AI systems[32].

FUTURE NEEDS

The utility of AI has come a long way with computed assisted technology making significant strides in colonoscopy and improving the outcomes for quality metrics. Initial studies published were retrospective in nature, based primarily on feeding still images to the software. This could potentially introduce selection bias in polyp selection and hence influence the outcomes. Following these, there have been several prospective studies, designed for both polyp detection and characterization which reduce the possibility of bias and help with better interpretation of the functioning and accuracy of the CAD system. In the last year, we have had few RCTs published on this subject, mainly from China. They have shown improvement in quality metrics like ADR, withdrawal times and other outcomes like PDR, mean adenomas and polyps per person[33]. We believe that the future studies should be directed towards these goals: it is important to investigate in future studies, the utility of AI in the diagnosis and characterization of flat lesions and sessile serrated lesions which are known to have significant malignant potential. Only one of the RCTs has been performed in a multi-center setting and we need more RCTs performed in various centers across the world for generalizability and reproducibility of the results. Also several different CAD systems have been investigated including laser-induced fluorescent spectroscopy, endocytoscopy, narrow band imaging and chromoendoscopy but an ideal AI system combined with high definition white light endoscopy, aiding with polyp detection and characterization, is yet to be found and this is a work in progress currently. Moreover, the impact of false positive (futile activations) on endoscopists behave was only reported by a single experience and will deserve further insights. The impact of the ability of CAD in assisting with accurate prediction of polyp surveillance intervals also need to be investigated with longitudinal studies including follow-up data.

CONCLUSION

Performance of a high-quality colonoscopy is essential in preventing the incidence of colorectal cancer. Significant progress has been made in the field of AI assisted colonoscopy, especially with the advent of deep CNN, which helps in overcoming the limitations of a traditional colonoscopy related to technical variations by operators and human errors. Early evidences on AI application in colonoscopy have shown it to be an effective tool in increasing efficacy in adenoma detection. RCT's investigating these

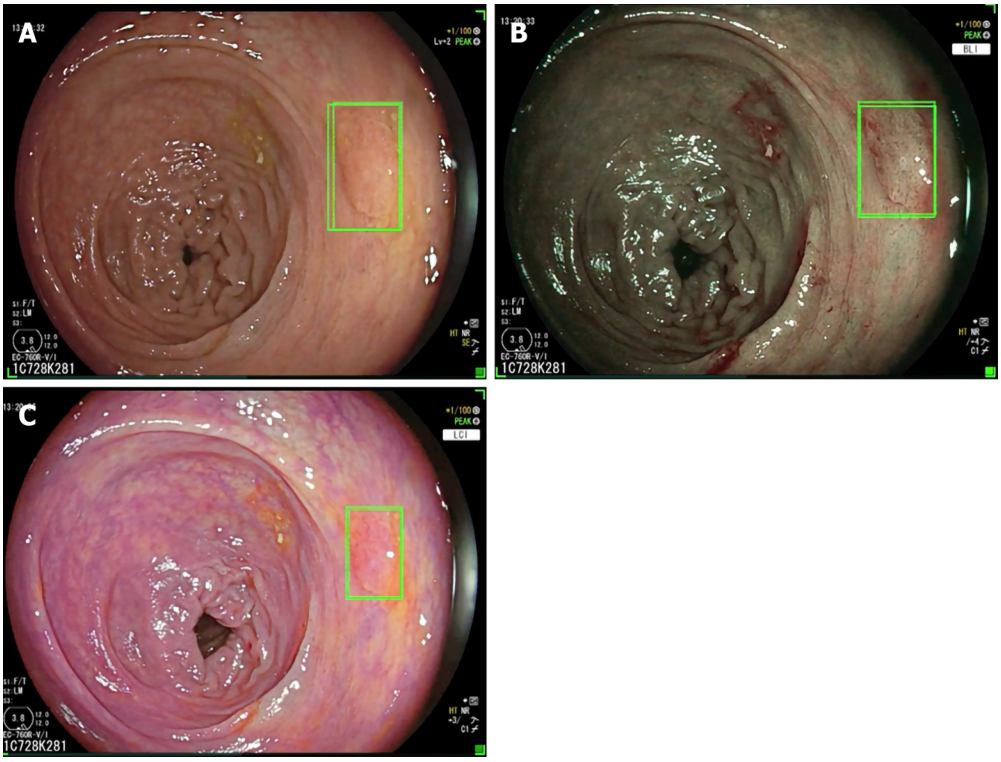

Figure 2 GI-Genius computer aided polyp detection system in high definition white light, and virtual chromoendoscopy with blue light imaging and linked color imaging. A: High definition white light; B: Virtual chromoendoscopy with blue light imaging; C: Virtual chromoendoscopy with linked color imaging.

quality metrics have been published recently and more are in progress. However, the role of the endoscopist and in particular his abilities and experience cannot be overshadowed: (1) The detection ability of AI systems is dependent on the inspection of the mucosa exposed by the endoscopist during the scope withdrawal, and an adequate technique and the quality of bowel preparation are essential for its effective operating; and (2) The improving in detection seems to involve even hyperplastic polyps with low malignant potential and the endoscopist should be able to make a decision on which need to be resected and which do not. However, the ability of optical diagnosis is still suboptimal compared to histopathological evaluation, obtaining valid results only in specific settings[55]. Also in this field, CNN systems are being developed in order to further assist the endoscopist[56]. These would be key factors in deciding the efficacy and success of AI assistance and also play an important role with cost-benefit related outcomes in the future. Longitudinal follow-up and performance of AI in different study populations is essential in future studies to study its impact and generalizability of its use in clinical practice.

REFERENCES

1 **Bray F**, Ferlay J, Soerjomataram I, Siegel RL, Torre LA, Jemal A. Global cancer statistics 2018: GLOBOCAN estimates of incidence and mortality worldwide for 36 cancers in 185 countries. *CA Cancer J Clin* 2018; **68**: 394-424 [PMID: 30207593 DOI: 10.3322/caac.21492]

2 **Hewitson P**, Glasziou P, Irwig L, Towler B, Watson E. Screening for colorectal cancer using the faecal occult blood test, Hemoccult. *Cochrane Database Syst Rev* 2007; CD001216 [PMID: 17253456 DOI: 10.1002/14651858]

3 **Doubeni CA**, Corley DA, Quinn VP, Jensen CD, Zauber AG, Goodman M, Johnson JR, Mehta SJ, Becerra TA, Zhao WK, Schottinger J, Doria-Rose VP, Levin TR, Weiss NS, Fletcher RH. Effectiveness of screening colonoscopy in reducing the risk of death from right and left colon cancer: a large community-based study. *Gut* 2018; **67**: 291-298 [PMID: 27733426 DOI: 10.1136/gutjnl-2016-312712]

4 **Brenner H**, Stock C, Hoffmeister M. Effect of screening sigmoidoscopy and screening colonoscopy on colorectal cancer incidence and mortality: systematic review and meta-analysis of randomised controlled trials and observational studies. *BMJ* 2014; **348**: g2467 [PMID: 24922745 DOI: 10.1136/bmj.g2467]

5 **Kaminski MF**, Thomas-Gibson S, Bugajski M, Bretthauer M, Rees CJ, Dekker E, Hoff G, Jover R, Suchanek S, Ferlitsch M, Anderson J, Roesch T, Hultcranz R, Racz I, Kuipers EJ, Garborg K, East JE, Rupinski M, Seip B, Bennett C, Senore C, Minozzi S, Bisschops R, Domagk D, Valori R, Spada C, Hassan

C, Dinis-Ribeiro M, Rutter MD. Performance measures for lower gastrointestinal endoscopy: a European Society of Gastrointestinal Endoscopy (ESGE) quality improvement initiative. *United European Gastroenterol J* 2017; **5**: 309-334 [PMID: 28507745 DOI: 10.1177/2050640617700014]

6 **Heresbach D**, Barrioz T, Lapalus MG, Coumaros D, Bauret P, Potier P, Sautereau D, Boustière C, Grimaud JC, Barthélémy C, Sée J, Serraj I, D'Halluin PN, Branger B, Ponchon T. Miss rate for colorectal neoplastic polyps: a prospective multicenter study of back-to-back video colonoscopies. *Endoscopy* 2008; **40**: 284-290 [PMID: 18389446 DOI: 10.1055/s-2007-995618]

7 **Kim NH**, Jung YS, Jeong WS, Yang HJ, Park SK, Choi K, Park DI. Miss rate of colorectal neoplastic polyps and risk factors for missed polyps in consecutive colonoscopies. *Intest Res* 2017; **15**: 411-418 [PMID: 28670239 DOI: 10.5217/ir.2017.15.3.411]

8 **Singh S**, Singh PP, Murad MH, Singh H, Samadder NJ. Prevalence, risk factors, and outcomes of interval colorectal cancers: a systematic review and meta-analysis. *Am J Gastroenterol* 2014; **109**: 1375-1389 [PMID: 24957158 DOI: 10.1038/ajg.2014.171]

9 **Ertem FU**, Ladabaum U, Mehrotra A, Tehranian S, Shi Z, Saul M, Morris M, Crockett SD, Schoen RE. Incidence of interval colorectal cancer attributable to an endoscopist in clinical practice. *Gastrointest Endosc* 2018; **88**: 705-711.e1 [PMID: 29803767 DOI: 10.1016/j.gie.2018.05.012]

10 **Corley DA**, Jensen CD, Marks AR, Zhao WK, Lee JK, Doubeni CA, Zauber AG, de Boer J, Fireman BH, Schottinger JE, Quinn VP, Ghai NR, Levin TR, Quesenberry CP. Adenoma detection rate and risk of colorectal cancer and death. *N Engl J Med* 2014; **370**: 1298-1306 [PMID: 24693890 DOI: 10.1056/NEJMoa1309086]

11 **Spadaccini M**, Frazzoni L, Vanella G, East J, Radaelli F, Spada C, Fuccio L, Benamouzig R, Bisschops R, Bretthauer M, Dekker E, Dinis-Ribeiro M, Ferlitsch M, Gralnek I, Jover R, Kaminski MF, Pellisé M, Triantafyllou K, Van Hooft JE, Dumonceau JM, Marmo C, Alfieri S, Chandrasekar VT, Sharma P, Rex DK, Repici A, Hassan C. Efficacy and Tolerability of High- vs Low-Volume Split-Dose Bowel Cleansing Regimens for Colonoscopy: A Systematic Review and Meta-analysis. *Clin Gastroenterol Hepatol* 2020; **18**: 1454-1465.e14 [PMID: 31683057 DOI: 10.1016/j.cgh.2019.10.044]

12 **Williet N**, Tournier Q, Vernet C, Dumas O, Rinaldi L, Roblin X, Phelip JM, Pioche M. Effect of Endocuff-assisted colonoscopy on adenoma detection rate: meta-analysis of randomized controlled trials. *Endoscopy* 2018; **50**: 846-860 [PMID: 29698990 DOI: 10.1055/a-0577-3500]

13 **Shinozaki S**, Kobayashi Y, Hayashi Y, Sakamoto H, Sunada K, Lefor AK, Yamamoto H. Colon polyp detection using linked color imaging compared to white light imaging: Systematic review and meta-analysis. *Dig Endosc* 2020; **32**: 874-881 [PMID: 31869487 DOI: 10.1111/den.13613]

14 **Shirin H**, Shpak B, Epshtein J, Karstensen JG, Hoffman A, de Ridder R, Testoni PA, Ishaq S, Reddy DN, Gross SA, Neumann H, Goetz M, Abramowich D, Moshkowitz M, Mizrahi M, Vilmann P, Rey JW, Sanduleanu-Dascalescu S, Viale E, Chaudhari H, Pochapin MB, Yair M, Shnell M, Yaari S, Hendel JW, Teubner D, Bogie RMM, Notaristefano C, Simantov R, Gluck N, Israeli E, Stigaard T, Matalon S, Vilkin A, Benson A, Sloth S, Maliar A, Waizbard A, Jacob H, Thielsen P, Shachar E, Rochberger S, Hershcovici T, Plougmann JI, Braverman M, Tsvang E, Abedi AA, Brachman Y, Siersema PD, Kiesslich R. G-EYE colonoscopy is superior to standard colonoscopy for increasing adenoma detection rate: an international randomized controlled trial (with videos). *Gastrointest Endosc* 2019; **89**: 545-553 [PMID: 30273591 DOI: 10.1016/j.gie.2018.09.028]

15 **Wang P**, Berzin TM, Glissen Brown JR, Bharadwaj S, Becq A, Xiao X, Liu P, Li L, Song Y, Zhang D, Li Y, Xu G, Tu M, Liu X. Real-time automatic detection system increases colonoscopic polyp and adenoma detection rates: a prospective randomised controlled study. *Gut* 2019; **68**: 1813-1819 [PMID: 30814121 DOI: 10.1136/gutjnl-2018-317500]

16 **Hoerter N**, Gross SA, Liang PS. Artificial Intelligence and Polyp Detection. *Curr Treat Options Gastroenterol* 2020 [PMID: 31960282 DOI: 10.1007/s11938-020-00274-2]

17 **Ebigbo A**, Palm C, Probst A, Mendel R, Manzeneder J, Prinz F, de Souza LA, Papa JP, Siersema P, Messmann H. A technical review of artificial intelligence as applied to gastrointestinal endoscopy: clarifying the terminology. *Endosc Int Open* 2019; **7**: E1616-E1623 [PMID: 31788542 DOI: 10.1055/a-1010-5705]

18 **Min JK**, Kwak MS, Cha JM. Overview of Deep Learning in Gastrointestinal Endoscopy. *Gut Liver* 2019; **13**: 388-393 [PMID: 30630221 DOI: 10.5009/gnl18384]

19 **Karkanis SA**, Iakovidis DK, Maroulis DE, Karras DA, Tzivras M. Computer-aided tumor detection in endoscopic video using color wavelet features. *IEEE Trans Inf Technol Biomed* 2003; **7**: 141-152 [PMID: 14518727 DOI: 10.1109/TITB.2003.813794]

20 **Martínez Barellas MR**, Chaure López I, Inarejos García M, Ortiz Berroeta I, Villanueva López C. [Continuing education. 41. Subject: pediatric nursing. Topic: How to care for the nursing infant?]. *Rev Enferm* 1989; **12**: 80-82 [PMID: 2595207 DOI: 10.1016/j.cmpb.2015.04.002]

21 **Hwang S**, Oh J, Tavanapong W, Wong J, De Groen J, De Groen PC. Polyp detection in colonoscopy video using ellipical shape features. In: IEEE International Conference on Image Processing; 2007 Sep 16-Oct 19; San Antonio, USA. IEEE, 2007 [DOI: 10.1109/ICIP.2007.4379193]

22 **Fernández-Esparrach G**, Bernal J, López-Cerón M, Córdova H, Sánchez-Montes C, Rodríguez de Miguel C, Sánchez FJ. Exploring the clinical potential of an automatic colonic polyp detection method based on the creation of energy maps. *Endoscopy* 2016; **48**: 837-842 [PMID: 27285900 DOI: 10.1055/s-0042-108434]

23 **Zhang R**, Zheng Y, Mak TW, Yu R, Wong SH, Lau JY, Poon CC. Automatic Detection and Classification of Colorectal Polyps by Transferring Low-Level CNN Features From Nonmedical Domain. *IEEE J Biomed Health Inform* 2017; **21**: 41-47 [PMID: 28114040 DOI: 10.1109/JBHI.2016.2635662]

24 **Misawa M**, Kudo SE, Mori Y, Cho T, Kataoka S, Yamauchi A, Ogawa Y, Maeda Y, Takeda K, Ichimasa K, Nakamura H, Yagawa Y, Toyoshima N, Ogata N, Kudo T, Hisayuki T, Hayashi T, Wakamura K, Baba T, Ishida F, Itoh H, Roth H, Oda M, Mori K. Artificial Intelligence-Assisted Polyp Detection for Colonoscopy: Initial Experience. *Gastroenterology* 2018; **154**: 2027-2029.e3 [PMID: 29653147 DOI: 10.1053/j.gastro.2018.04.003]

25 **Urban G**, Tripathi P, Alkayali T, Mittal M, Jalali F, Karnes W, Baldi P. Deep Learning Localizes and Identifies Polyps in Real Time With 96% Accuracy in Screening Colonoscopy. *Gastroenterology* 2018; **155**:

1069-1078.e8 [PMID: 29928897 DOI: 10.1053/j.gastro.2018.06.037]
26 **Hassan C**, Wallace MB, Sharma P, Maselli R, Craviotto V, Spadaccini M, Repici A. New artificial intelligence system: first validation study versus experienced endoscopists for colorectal polyp detection. *Gut* 2020; **69**: 799-800 [PMID: 31615835 DOI: 10.1136/gutjnl-2019-319914]
27 **Klare P**, Sander C, Prinzen M, Haller B, Nowack S, Abdelhafez M, Poszler A, Brown H, Wilhelm D, Schmid RM, von Delius S, Wittenberg T. Automated polyp detection in the colorectum: a prospective study (with videos). *Gastrointest Endosc* 2019; **89**: 576-582.e1 [PMID: 30342029 DOI: 10.1016/j.gie.2018.09.042]
28 **Liu WN**, Zhang YY, Bian XQ, Wang LJ, Yang Q, Zhang XD, Huang J. Study on detection rate of polyps and adenomas in artificial-intelligence-aided colonoscopy. *Saudi J Gastroenterol* 2020; **26**: 13-19 [PMID: 31898644 DOI: 10.4103/sjg.SJG_377_19]
29 **Su JR**, Li Z, Shao XJ, Ji CR, Ji R, Zhou RC, Li GC, Liu GQ, He YS, Zuo XL, Li YQ. Impact of a real-time automatic quality control system on colorectal polyp and adenoma detection: a prospective randomized controlled study (with videos). *Gastrointest Endosc* 2020; **91**: 415-424.e4 [PMID: 31454493 DOI: 10.1016/j.gie.2019.08.026]
30 **Gong D**, Wu L, Zhang J, Mu G, Shen L, Liu J, Wang Z, Zhou W, An P, Huang X, Jiang X, Li Y, Wan X, Hu S, Chen Y, Hu X, Xu Y, Zhu X, Li S, Yao L, He X, Chen D, Huang L, Wei X, Wang X, Yu H. Detection of colorectal adenomas with a real-time computer-aided system (ENDOANGEL): a randomised controlled study. *Lancet Gastroenterol Hepatol* 2020; **5**: 352-361 [PMID: 31981518 DOI: 10.1016/S2468-1253(19)30413-3]
31 **Repici A**, Badalamenti M, Maselli R, Correale L, Radaelli F, Rondonotti E, Ferrara E, Spadaccini M, Alkandari A, Fugazza A, Anderloni A, Galtieri PA, Pellegatta G, Carrara S, Di Leo M, Craviotto V, Lamonaca L, Lorenzetti R, Andrealli A, Antonelli G, Wallace M, Sharma P, Rosch T, Hassan C. Efficacy of Real-Time Computer-Aided Detection of Colorectal Neoplasia in a Randomized Trial. *Gastroenterology* 2020; **159**: 512-520.e7 [PMID: 32371116 DOI: 10.1053/j.gastro.2020.04.062]
32 **Hassan C**, Badalamenti M, Maselli R, Correale L, Iannone A, Radaelli F, Rondonotti E, Ferrara E, Spadaccini M, Alkandari A, Fugazza A, Anderloni A, Galtieri PA, Pellegatta G, Carrara S, Di Leo M, Craviotto V, Lamonaca L, Lorenzetti R, Andrealli A, Antonelli G, Wallace M, Sharma P, Rosch T, Repici A. Computer-aided detection-assisted colonoscopy: classification and relevance of false positives. *Gastrointest Endosc* 2020 [PMID: 32561410 DOI: 10.1016/j.gie.2020.06.021]
33 **Hassan C**, Spadaccini M, Iannone A, Maselli R, Jovani M, Chandrasekar VT, Antonelli G, Yu H, Areia M, Dinis-Ribeiro M, Bhandari P, Sharma P, Rex DK, Rösch T, Wallace M, Repici A. Performance of artificial intelligence for colonoscopy regarding adenoma and polyp detection: a meta-analysis. *Gastrointest Endosc* 2020 [PMID: 32598963 DOI: 10.1016/j.gie.2020.06.059]
34 **Maroulis DE**, Iakovidis DK, Karkanis SA, Karras DA. CoLD: a versatile detection system for colorectal lesions in endoscopy video-frames. *Comput Methods Programs Biomed* 2003; **70**: 151-166 [PMID: 12507791 DOI: 10.1016/s0169-2607(02)00007-x]
35 **Jerebko A**, Lakare S, Cathier P, Periaswamy S, Bogoni L. Symmetric curvature patterns for colonic polyp detection. *Med Image Comput Comput Assist Interv* 2006; **9**: 169-176 [PMID: 17354769 DOI: 10.1007/11866763_21]
36 **Park SY**, Sargent D, Spofford I, Vosburgh KG, A-Rahim Y. A colon video analysis framework for polyp detection. *IEEE Trans Biomed Eng* 2012; **59**: 1408-1418 [PMID: 22361654 DOI: 10.1109/TBME.2012.2188397]
37 **Wang Y**, Tavanapong W, Wong J, Oh J, de Groen PC. Part-based multiderivative edge cross-sectional profiles for polyp detection in colonoscopy. *IEEE J Biomed Health Inform* 2014; **18**: 1379-1389 [PMID: 24122609 DOI: 10.1109/JBHI.2013.2285230]
38 **Bernal J**, Sánchez FJ, Fernández-Esparrach G, Gil D, Rodríguez C, Vilariño F. WM-DOVA maps for accurate polyp highlighting in colonoscopy: Validation vs. saliency maps from physicians. *Comput Med Imaging Graph* 2015; **43**: 99-111 [PMID: 25863519 DOI: 10.1016/j.compmedimag.2015.02.007]
39 **Tajbakhsh N**, Gurudu SR, Liang J. Automated Polyp Detection in Colonoscopy Videos Using Shape and Context Information. *IEEE Trans Med Imaging* 2016; **35**: 630-644 [PMID: 26462083 DOI: 10.1109/TMI.2015.2487997]
40 **Geetha K**, Rajan C. Automatic Colorectal Polyp Detection in Colonoscopy Video Frames. *Asian Pac J Cancer Prev* 2016; **17**: 4869-4873 [PMID: 28030914 DOI: 10.22034/APJCP.2016.17.11.4869]
41 **Angermann Q**, Bernal J, Sanchez-Montes C. Towards real-time polyp detection in colonoscopy videos:adapting still frame-based methodologies for video sequences analysis. In: Cardoso MJ, Arbel T, Luo X, Wesarg S, Reichl T, González Ballester MA, McLeod J, Drechsler K, Peters T, Erdt M, Mori K, Linguraru MG, Uhl A, Oyarzun Laura C, Shekhar R, editors. Computed assisted and robotic endoscopy and clinical image-based procedures. 2017 Sep 14; Québec, Canada. Springer, 2017: 29-41 [DOI: 10.1007/978-3-319-67543-5]
42 **Park SY**, Sargent D. Colonoscopic polyp detection using convolutional neural networks. In: Tourassi GD; Armato III SG, editors. Medical imaging 2016: Computer-Aided Diagnosis. International Society for Optics and Photonics, 2016: 978528
43 **Billah M**, Waheed S, Rahman MM. An Automatic Gastrointestinal Polyp Detection System in Video Endoscopy Using Fusion of Color Wavelet and Convolutional Neural Network Features. *Int J Biomed Imaging* 2017; **2017**: 9545920 [PMID: 28894460 DOI: 10.1155/2017/9545920]
44 **Lequan Yu**, Hao Chen, Qi Dou, Jing Qin, Pheng Ann Heng. Integrating Online and Offline Three-Dimensional Deep Learning for Automated Polyp Detection in Colonoscopy Videos. *IEEE J Biomed Health Inform* 2017; **21**: 65-75 [PMID: 28114049 DOI: 10.1109/JBHI.2016.2637004]
45 **Pogorelov K**, Ostroukhova O, Jeppson M, Hespeland H, Griwodz C, de Lange T, Johansen D, Riegler M, Halvorsen P. Deep learning and hand-crafted feature based approaches for polyp detection in medical videos. In: 2018 IEEE 31st international sumposium oncomputer-based medical system (CBMS). 2018 June 18 to 21; Karlstad Sweden. IEEE, 2018: 381-386 [DOI: 10.1109/CBMS.2018.00073]
46 **Yamada M**, Saito Y, Imaoka H, Saiko M, Yamada S, Kondo H, Takamaru H, Sakamoto T, Sese J, Kuchiba A, Shibata T, Hamamoto R. Development of a real-time endoscopic image diagnosis support system using deep learning technology in colonoscopy. *Sci Rep* 2019; **9**: 14465 [PMID: 31594962 DOI:

10.1038/s41598-019-50567-5]
47 **Zhu X**, Nemoto D, Wang Y, Guo Z, Shen Y, Aizawa M, Takayanagi D, Endo S, Hewett DG, Togasho K. Detection and diagnosis of sessile serrated adenoma/polyps using convolutional neural network (artificial intelligence). *Gastrointest Endosc* 2018; 87; AB251 [DOI: 10.1016/j.gie.2018.04.445]
48 **Ahmad OF**, Soares AS, Mazomenos E, Brandao P, Vega R, Seward E, Stoyanov D, Chand M, Lovat LB. Artificial intelligence and computer-aided diagnosis in colonoscopy: current evidence and future directions. *Lancet Gastroenterol Hepatol* 2019; **4**: 71-80 [PMID: 30527583 DOI: 10.1016/S2468-1253(18)30282-6]
49 **Eelbode T**, Hassan C, Demedts I, Roelandt P, Coron E, Bhandari P, Neumann H, Pech P, Repici A, Maes F, Bisschops R. Tu1959 BLI and LCI improve polyp detection and delineatino accuracy for deep learning networks. *Gastrointest Endosc* 2019; **89**: AB632 [DOI: 10.1016/j.gie.2019.03.1103]
50 **Ka-Luen Lui T**, Yee K, Wong K, Leung WK. 1062 Use of artificial intelligence image classifier for real-time detection of colonic polyps. *Gastrointest Endosc* 2019; **89**: AB135 [DOI: 10.1016/j.gie.2019.04.175]
51 **Misawa M**, Kudo S, Mori Y, Cho T, Kataoka S, Maeda Y, Ogawa Y, Takeda K, Nakamura H, Ichimasa K, Toyoshima N, Ogata N, Kudo T, Hisayuki T, Hayashi T, Wakamura K, Baba T, Ishida F, Itoh H, Oda M, Mori K. Tu1990 Artificial intelligence-assisted polyp detection system for colonoscopy, based on the largest available collection of clinical video data for machine learning. *Gastrointest Endosc* 2019; **89**: AB646 [DOI: 10.1016/j.gie.2019.03.1134]
52 **Shichijo S**, Aoyama K, Ozawa T, Miura M, Fukuda H, Takeuchi Y, Takiyama Y, Hirasawa T, Onishi T, Matsuo K, Ishihara S, Ishihara R, Tada T. Tu2003 Application of convolutional neural networks could detect all laterally spreading tumor in colonoscopy images. *Gastrointest Endosc* 2019; **89**: AB653 [DOI: 10.1016/j.gie.2019.03.1147]
53 **Ozawa T**, Ishihara S, Fujishiro M, Kumagai Y, Shichijo S, Tada T. Automated endoscopic detection and classification of colorectal polyps using convolutional neural networks. *Therap Adv Gastroenterol* 2020; **13**: 1756284820910659 [PMID: 32231710 DOI: 10.1177/1756284820910659]
54 **Wang P**, Liu X, Berzin TM, Glissen Brown JR, Liu P, Zhou C, Lei L, Li L, Guo Z, Lei S, Xiong F, Wang H, Song Y, Pan Y, Zhou G. Effect of a deep-learning computer-aided detection system on adenoma detection during colonoscopy (CADe-DB trial): a double-blind randomised study. *Lancet Gastroenterol Hepatol* 2020; **5**: 343-351 [PMID: 31981517 DOI: 10.1016/S2468-1253(19)30411-X]
55 **ASGE Technology Committee**, Abu Dayyeh BK, Thosani N, Konda V, Wallace MB, Rex DK, Chauhan SS, Hwang JH, Komanduri S, Manfredi M, Maple JT, Murad FM, Siddiqui UD, Banerjee S. ASGE Technology Committee systematic review and meta-analysis assessing the ASGE PIVI thresholds for adopting real-time endoscopic assessment of the histology of diminutive colorectal polyps. *Gastrointest Endosc* 2015; **81**: 502.e1-502.e16 [PMID: 25597420 DOI: 10.1016/j.gie.2014.12.022]
56 **Mori Y**, Kudo SE, Misawa M, Saito Y, Ikematsu H, Hotta K, Ohtsuka K, Urushibara F, Kataoka S, Ogawa Y, Maeda Y, Takeda K, Nakamura H, Ichimasa K, Kudo T, Hayashi T, Wakamura K, Ishida F, Inoue H, Itoh H, Oda M, Mori K. Real-Time Use of Artificial Intelligence in Identification of Diminutive Polyps During Colonoscopy: A Prospective Study. *Ann Intern Med* 2018; **169**: 357-366 [PMID: 30105375 DOI: 10.7326/M18-0249]

World Journal of Gastroenterology

Submit a Manuscript: https://www.f6publishing.com

World J Gastroenterol 2020 October 7; 26(37): 5617-5628

DOI: 10.3748/wjg.v26.i37.5617

ISSN 1007-9327 (print) ISSN 2219-2840 (online)

MINIREVIEWS

Application of artificial intelligence in the diagnosis and treatment of hepatocellular carcinoma: A review

Miguel Jiménez Pérez, Rocío González Grande

ORCID number: Miguel Jiménez Pérez 0000-0001-7550-1019; Rocío González Grande 0000-0002-7691-5755.

Author contributions: Jiménez Pérez M and Grande RG contributed equally to this work.

Conflict-of-interest statement: Authors have no conflict of interest.

Manuscript source: Invited manuscript

Received: July 8, 2020
Peer-review started: July 8, 2020
First decision: August 8, 2020
Revised: September 1, 2020
Accepted: September 18, 2020
Article in press: September 18, 2020

Miguel Jiménez Pérez, Rocío González Grande, UGC de Aparato Digestivo, Unidad de Hepatología-Trasplante Hepático, Hospital Regional Universitario de Málaga, Málaga 29010, Spain

Corresponding author: Miguel Jiménez Pérez, MD, PhD, Chief Doctor, UGC de Aparato Digestivo, Unidad de Hepatología-Trasplante Hepático, Hospital Regional Universitario de Málaga, Avenida Carlos Haya, Málaga 29010, Spain. mjimenezp@commalaga.com

Abstract

Although artificial intelligence (AI) was initially developed many years ago, it has experienced spectacular advances over the last 10 years for application in the field of medicine, and is now used for diagnostic, therapeutic and prognostic purposes in almost all fields. Its application in the area of hepatology is especially relevant for the study of hepatocellular carcinoma (HCC), as this is a very common tumor, with particular radiological characteristics that allow its diagnosis without the need for a histological study. However, the interpretation and analysis of the resulting images is not always easy, in addition to which the images vary during the course of the disease, and prognosis and treatment response can be conditioned by multiple factors. The vast amount of data available lend themselves to study and analysis by AI in its various branches, such as deep-learning (DL) and machine learning (ML), which play a fundamental role in decision-making as well as overcoming the constraints involved in human evaluation. ML is a form of AI based on automated learning from a set of previously provided data and training in algorithms to organize and recognize patterns. DL is a more extensive form of learning that attempts to simulate the working of the human brain, using a lot more data and more complex algorithms. This review specifies the type of AI used by the various authors. However, well-designed prospective studies are needed in order to avoid as far as possible any bias that may later affect the interpretability of the images and thereby limit the acceptance and application of these models in clinical practice. In addition, professionals now need to understand the true usefulness of these techniques, as well as their associated strengths and limitations.

Key Words: Artificial intelligence; Machine learning; Hepatocellular carcinoma; Diagnosis; Treatment; Prognosis

Published online: October 7, 2020

P-Reviewer: Azer S, Du Z, Gao YT
S-Editor: Yan JP
L-Editor: A
P-Editor: Ma YJ

Core Tip: The biological variability in the behavior of hepatocellular carcinoma (HCC), conditioned by multiple factors, makes it difficult to establish general standards of action applicable equally to all patients. Analysis of the vast amount of data now available and their relation with tumor behavior is fundamental to be able to establish an efficient approach to HCC. It is here that the computational power of artificial intelligence can play a determining role, though it is necessary to understand the strengths and limitations of this technology before it can be applied in clinical practice.

Citation: Jiménez Pérez M, Grande RG. Application of artificial intelligence in the diagnosis and treatment of hepatocellular carcinoma: A review. *World J Gastroenterol* 2020; 26(37): 5617-5628
URL: https://www.wjgnet.com/1007-9327/full/v26/i37/5617.htm
DOI: https://dx.doi.org/10.3748/wjg.v26.i37.5617

INTRODUCTION

In the era of Big Data, the need for the efficient management of the great amount of information available has led to the development and application of artificial intelligence (AI) and its various techniques in the general field of medicine. Although the concept of AI arose in the 1950s[1], it was not until a few years ago that it really came to experience its breakthrough.

The term AI refers to those computer programs that try to reproduce human cognitive functions, like learning or problem solving. Initially, machine learning (ML), developed as a branch of AI, analyzed data in order to create algorithms that can detect patterns of behavior from which predictive models can be established. Different ML techniques, such as support vector machines (SVM), artificial neural networks (ANNs) or classification and regression trees, have all been used in multiple studies in the field of medicine[2]. Technological advances over the last ten years have resulted in the appearance of deep learning (DL) as a new model of ML to develop multi-layered neural network algorithms, using such techniques as convolutional neural network (CNN), a multilayer of ANN, that has proven of great use in the analysis of radiological images[3,4].

Although the application of AI in various fields of medicine has shown promising results, we should nevertheless be aware of its limitations. The retrospective manner of many of these studies and the use of not particularly suitable databases, with their inherent bias, can affect the accuracy of AI. Thus, it is necessary to draw up prospective, well-designed, multicenter studies that are free from bias which could affect their interpretability and thereby limit their acceptance and application in clinical practice. And of course, we must not forget such other aspects as cost-effectiveness, regulations by the health authorities and ethical considerations.

AI has been used in the field of hepatology for the diagnosis, treatment and prognostic prediction of various different disorders, though with special relevance in the study of hepatocellular carcinoma (HCC) as this is a very common tumor. Estimates by the American Cancer Society put the number of new cases of liver and intrahepatic bile duct cancer during 2020 to be 42810, with 30160 deaths[5]. HCC has particular radiological features that enable its diagnosis without the need for any histological study. Accordingly, the analysis of imaging tests takes on special relevance as their interpretation is not always easy, in addition to which they vary over the course of the disease, as do the prognosis and response to treatment, which are all affected by multiple factors. This all results in a vast amount of data whose integration and efficient analysis lend themselves to study by AI. Indeed, several studies have recently been undertaken to aid in the decision-making process and overcome the limitations of human evaluation[4,6].

Figure 1 gives a schematic idea of how AI, with its variants, could be used to study a patient with HCC, whether diagnosed or suspected. AI is able to perform a combined analysis of radiological, clinical and histological data, producing information that can aid in the diagnostic accuracy, tumor staging, treatment planning using methods of segmentation and evaluation of the presence of microvascular invasion, in addition to giving a prognostic estimate.

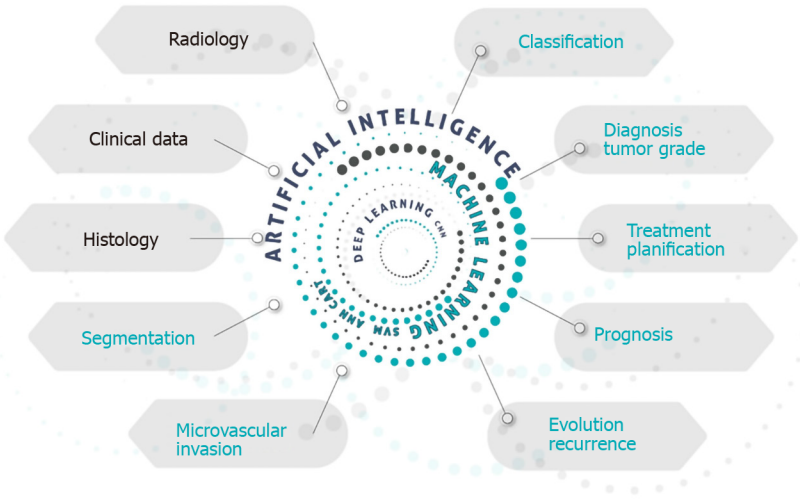

Figure 1 Graphic presentation of the applications of artificial intelligence in the approach to hepatocellular carcinoma.

AI IN THE DIAGNOSIS OF HCC

In the field of liver cancer, the use of AI techniques to aid traditional diagnostic techniques is promising. CNN is a multilayer ANN interconnected in such a way that all input data traverse all the various layers during which the information is processed to produce output data. It can be considered an advanced form of DL with its own learning capacity. CNN can increase the diagnostic yield of ultrasound studies, abdominal computerized tomography or abdominal magnetic resonance imaging (MRI), positron emission tomography (PET) and histology.

Abdominal ultrasound

HCC usually, though not always, develops in a cirrhotic liver. Accordingly, clinical practice guidelines recommend regular abdominal ultrasound in patients with hepatic cirrhosis; indeed, it is considered the method of choice for screening of space-occupying lesions. Ultrasound is therefore the main tool to evaluate liver disease and detect new lesions. However, image interpretation is not always easy and may present interobserver variability.

To assess the underlying disease, Bharti *et al*[7] proposed an ANN model to differentiate four stages of liver disease using data obtained from ultrasound images: normal liver, chronic liver disease, cirrhosis, and HCC. The classification accuracy of the model was 96.6%[7]. Liu *et al*[8] designed an algorithm to classify ultrasound images. They selected the liver capsule to determine the presence of cirrhosis, even in early stages when the usual findings reported by the radiologist, such as a nodular liver outline, enlarged porta or splenomegaly, are still not obvious. Using their analysis of the morphology of the liver capsule, they were able to determine the presence or absence of cirrhosis, with an area under the curve of 0.968[8].

The human yield when characterizing a liver lesion from ultrasound images is limited. Schmauch *et al*[9] designed a DL system able to detect and classify space-occupying lesions in the liver as benign or malignant. After a supervised training using a database of 367 images together with the radiological reports, the resulting algorithm detected and characterized the lesions with a mean receiver operating characteristic of 0.93 and 0.916, respectively. Although the system requires validation, it could increase the diagnostic yield of ultrasound and warn of possibly malignant lesions[9].

AI has also been used in contrast-enhanced ultrasound (C-US), improving its ability to identify characteristics suggestive of cancer. Guo *et al*[10] demonstrated that DL applied to the behavior of liver lesions seen on C-US in three phases (arterial, portal and late) increased the accuracy, sensitivity and specificity of the study[10].

Abdominal computed tomography with IV contrast

When a follow-up ultrasound shows a new liver lesion, other imaging studies are undertaken, mainly dynamic contrast-enhanced computed tomography (CT) or MRI, to obtain a more precise evaluation. The radiological behavior of liver lesions in

dynamic CT or MRI studies is useful for characterization of the lesion. If a liver lesion > 1 cm fulfils certain radiological criteria, almost pathognomonic for HCC such as the presence of hyperenhancement at arterial phase and washout at portal or late phases in a cirrhotic patient, no further studies are needed for its diagnosis or histological confirmation. However, liver nodules often present an indeterminate behavior on CT and a biopsy of the lesion is required, as recommended in the European Association for the Study of the Liver guidelines[11]. This, though, requires assuming the risks involved in the procedure, or close follow-up, as indicated in the American Association for the Study of Liver Diseases guidelines[12], with a high number of studies and the possibility of not diagnosing a malignant lesion in time. Mokrane *et al*[13] undertook a retrospective analysis of 178 patients with cirrhosis and liver nodules in whom the Liver Reporting and Data System criteria were unable to distinguish the neoplastic from the non-neoplastic lesions, thereby necessitating a biopsy; 77% proved to be malignant on biopsy. Using DL techniques to classify nodules as HCC or non-HCC achieved an area under the curve (AUC) of 0.70. Another retrospective study, by Yasaka *et al*[14], analyzed the yield of an ANN, composed of three layers, classifying liver masses using contrast-enhanced CT into five categories: A, classic HCC; B, malignant tumors apart from HCC (cholangiocarcinoma, hepatocholangiocarcinoma or metastasis); C, indeterminate masses, dysplastic nodules or early HCC and benign masses other than cysts or hemangiomas; D, hemangiomas; E, cysts. After supervised training using over 55000 image sets the authors obtained a high accuracy for the classification of liver lesions, especially for the differentiation between categories A-B and C-D.

Quantifying the tumor load may be useful, particularly for the detection of tumor recurrence in follow-up CT studies. As tumor relapses can be small and go unnoticed, Vivanti *et al*[15] described an automated detection method of recurrence, based on the initial appearance of the tumor, its CT behavior, and the quantification of the tumor load at baseline and during the follow-up. The technique had a high rate of true positives in the identification of tumor recurrence, with an accuracy of 86%.

Liver segmentation is of great importance to assess liver lesions and for planning the ideal treatment. However, manual segmentation is made more difficult by the heterogeneity of the lesions or their diffuse borders. Li *et al*[16] proposed a CNN that can segment liver tumors based on CT images, with an accuracy of 82.67% ± 1.43%, better than that of traditional techniques, thereby favoring suitable treatment planning.

MRI of the abdomen

CNN applied to MRI has also been analyzed. Hamm *et at*[17] developed and validated a DL system based on a CNN that classifies MRI liver lesions, with an accuracy of 92%, a sensitivity of 92% and a specificity of 98%; and an average computation time of 5.6 ms.

Other studies have associated additional MRI sequences and risk factors plus the patient's clinical data to apply an automated classification system cataloguing liver lesions as adenoma, cyst, hemangioma, HCC and metastasis, with a sensitivity and specificity of 0.8/0.78, 0.93/0.93, 0.84/0.82, 0.73/0.56 and 0.62/0.77, respectively[18]. Zhang *et al*[19] described a training model using MRI in 20 patients to classify liver tissues. Their results were promising, improving the yield of the reference models used.

PET

Preis *et al*[20] evaluated the yield of fluorine 18 fluorodeosyglucose positron emission tomography/computed tomography (18F-FDG PET/CT) using a neural network to analyze liver uptake of 18F together with patient and laboratory data. They achieved a high sensitivity and specificity to detect liver malignancy unidentified visually, showing that this technique could complement the radiologist in the interpretation of PET, though their main aim was to evaluate metastatic liver disease, where 18F-FDG PET/CT has greater applicability.

Histology

The histopathological classification of a liver lesion and the differentiation of the tumor strain is crucial for treatment planning and a prognostic estimate of the disease, though this can sometimes prove challenging even for expert pathologists. Kiani *et al*[21] used AI as a support for the pathologists, focusing on the histological differentiation between HCC and cholangiocarcinoma. They analyzed prospectively the impact of this aid in the diagnostic yield of 11 pathologists, finding that it made no change to their mean accuracy.

Others have described how a deep CNN using previous histopathological images of HCC can make an automated diagnosis of HCC and distinguish healthy tissue from tumor tissue, in addition to identifying certain biological predictors[22]. Table 1 shows the main studies using AI techniques in the diagnosis of HCC.

AI IN THE TREATMENT OF HCC

The individual biological variability between patients in the behavior of HCC hinders evidence-based clinical assessment that is applicable to all patients. Accordingly, powerful, standardized risk stratification systems are needed in order to optimize treatment strategies and assess their effects. It is here that AI can play an important role in the therapeutic approach to HCC. Most studies on the use of AI in the treatment of HCC are aimed at the analysis of certain particular tumor characteristics, such as radiological, histological or genetic features, or a combination of the clinical data in order to predict the response to a particular treatment. This, in turn, will allow for the suitable selection of patients for particular treatment options.

AI strategies based on radiomics

In usual clinical practice the diagnosis and treatment assessment of HCC are commonly done with such imaging techniques as C-US, CT and MRI, after analyzing certain tumor features like vascularization or behavior after the administration of contrast material[23]. However, these characteristics are liable to subjectivity in their interpretation by the radiologist, in addition to the lack of high resolution dimensional images. But a new technology has recently appeared in the area of radiology and cancer, radiomics[24]. Although it is not yet in extensive use in clinical practice, it has nevertheless awoken great interest. This technology allows for the extraction of a great amount of quantifiable objective data contained in the radiological images and their later association with the underlying biological processes. Analysis of all these data with AI software can provide useful diagnostic and prognostic information with predictive accuracy[24,25].

Evaluation of surgical resection

Early tumor recurrence after surgical resection is associated with a poor prognosis. The preoperative identification of patients at high risk of recurrence is fundamental to avoid unnecessary treatment. Computer models have been developed that analyze certain tumor characteristics and aid in the preoperative prediction of the risk of recurrence or the evaluation of survival after resection.

Vascular microinvasion (VMI) has been established as an independent predictive factor of recurrence, associated with poor results after tumor resection[26]. Although the preoperative availability of information about VMI would be of much benefit, radiological techniques currently in clinical use do not provide for an adequate direct diagnosis.

Several studies have managed to elaborate radiomic signatures that enable prediction of the preoperative status of VMI, based on contrast-enhanced CT[27,28] or MRI[29]. However, these techniques involve radiological exposure, and are laborious to perform and costly. Recently, Dong *et al*[30] published a study using radiomic algorithms based on grayscale ultrasound images to elaborate radiomic signatures with the potential to aid in the prediction of VMI, with promising results. Ji *et al*[31] created predictive models for recurrence after surgical resection using radiomic techniques to analyze contrast-enhanced CT images, with a C-index of 0.633-0.699. In conjunction with the inclusion of clinical data, the model can be used to establish a personalized risk stratification facilitating the individual management of HCC.

Survival after surgical resection has also been assessed in several studies using ML techniques[32-34], and more recently with more advanced DL models based on digitalized histological images of the tumor. Saillard *et al*[35] drew up a predictive model of survival after resection, attaining a C-index for survival prediction of 0.78. A recent prospective study by Schoenberg *et al*[36] involving 180 patients also led to a predictive model based on the analysis of 26 preoperative routine clinical variables, obtaining a predictive value of 0.78.

Evaluation of transcatheter arterial chemoembolization

Transcatheter arterial chemoembolization (TACE) is the treatment of choice for intermediate stage B HCC, in the Barcelona Clinical Liver Cancer (BCLC) classification[37]. Adequate selection of patients who might benefit from this treatment

Table 1 Studies applying artificial intelligence in the diagnosis of hepatocellular carcinoma

Ref.	Title	Aim of the study of the use of AI in imaging techniques	Diagnostic technique studied	AI tool used	University/department
Bharti *et al*[7] 2018	Preliminary study of chronic liver classification on ultrasound images using an ensemble model	Classification of liver disease in four stages; normal liver, chronic liver disease, cirrhosis and HCC	Ultrasound	CNN	Thapar Institute of Engineering & Technology, Patiala, India
Liu *et al*[8] 2017	Accurate prediction of responses to transarterial chemoembolization for patients with hepatocellular carcinoma by using artificial intelligence in contrast-enhanced ultrasound	Early identification of the presence of cirrhosis	Ultrasound	ML	Sun Yat-sen University, Guangzhou, China
Schmauch *et al*[9] 2019	Diagnosis of focal liver lesions from ultrasound using deep learning	Classify liver lesions as benign or malignant	Ultrasound	DL	Owkin Inc, Research and Development Laboratory, Paris, France
Guo *et al*[10] 2018	A two-stage multi-view learning framework based computer-aided diagnosis of liver tumors with contrast enhanced ultrasound images	Characterize liver lesions and identify data of malignancy	C-US	ML	University School of Medicine, Shanghai, China
Mokrane *et al*[13] 2020	Radiomics machine-learning signature for diagnosis of hepatocellular carcinoma in cirrhotic patients with indeterminate liver nodules	Identify malignancy in hepatic space-occupying lesions catalogued as indeterminate	CT	Radiomics	Department of Radiology, New York Presbyterian Hospital, Columbia University Vagelos College of Physicians and Surgeons, New York City, NY, United States
Yasaka *et al*[14] 2018	Deep learning with convolutional neural network for differentiation of liver masses at dynamic contrast-enhanced CT: A preliminary study	Classification of liver lesions in five categories	CT	CNN	Department of Radiology, The University of Tokyo Hospital, Tokyo, Japan
Vivanti *et al*[15] 2017	Automatic detection of new tumors and tumor burden evaluation in longitudinal liver CT scan studies	Detection of tumor recurrence analyzing volume/tumor load	CT	CNN	The Rachel and Selim Benin School of Computer Science and Engineering, The Hebrew University of Jerusalem, Jerusalem, Israel
Li *et al*[16] 2015	Automatic segmentation of liver tumor in CT Images with deep convolutional neural networks	Liver tumor segmentation	CT	CNN	Research Lab for Medical Imaging and Digital Surgery, Shenzhen Institutes of Advanced Technology, Chinese Academy of Sciences, Shenzhen, China
Hamm *et al*[17] 2019	Deep learning for liver tumor diagnosis part I: development of a convolutional neural network classifier for multi-phasic MRI	Classification of liver lesions	MRI	DL	Department of Radiology and Biomedical Imaging, Yale School of Medicine, United States
Jansen *et al*[18] 2019	Automatic classification of focal liver lesions based on MRI and risk factors	Classification of liver lesions in: Adenomas, cysts, hemangiomas, HCC and metastasis	MRI	ML	Image Sciences Institute, University Medical Center Utrecht & Utrecht University, Utrecht, the Netherlands
Zhang *et al*[19] 2018	Liver tissue classification using an auto-context-based deep neural network with a multi-phase training framework	Classification of liver tissue	MRI	CNN	Department of Biomedical Engineering, Yale University, New Haven, CT, United States
Preis *et al*[20] 2011	Neural network evaluation of pet scans of the liver: A potentially useful adjunct in clinical interpretation	Identify metastatic liver disease	PET	CNN	Department of Radiology, Massachusetts General Hospital and Harvard Medical School, Boston
Kiani *et al*[21] 2020	Impact of a deep learning assistant on the histopathologic classification of liver cancer	Differentiate HCC from cholangiocarcinoma	Histology	DL	Department of Computer Science, Stanford University, Stanford, CA, United States
Liao *et al*[22] 2020	Deep learning-based classification and mutation prediction from histopathological images of hepatocellular carcinoma	Automated identification of liver tumor tissue, differentiating it from healthy	Histology	DL	Department of Liver Surgery & Liver Transplantation, State Key Laboratory of Biotherapy and Cancer Center, West China Hospital, Sichuan University and

tissue	Collaborative Innovation Center of Biotherapy, Chengdu, China

Note: AI: Artificial intelligence; HCC: Hepatocellular carcinoma; CNN: Convolutional neural network; ML: Machine learning; DL: Deep learning; C-US: Contrast-enhanced ultrasound; CT: Computed tomography; MRI: Magnetic resonance imaging; PET: Positron emission tomography.

is vital in order to avoid unnecessary examinations that can sometimes have undesirable secondary effects for the patient and waste costs for the health system. Studies have been developed based on AI techniques to attempt to predict the response to treatment with TACE and aid adequate patient selection. Most of these studies are based on imaging analysis, though some have used genomic signatures. Morshid *et al*[38] elaborated a fully automated ML algorithm using the combination of quantitative characteristics of CT images plus pretreatment patient clinical data to predict the response to TACE. They achieved a prediction accuracy rate of 74.2% using a combination of the BCLC stage plus quantitative image features *vs* using just the BCLC stage alone. Peng *et al*[39] validated a DL model to predict the response to TACE using CT images from a total of 789 patients in three different hospitals. They obtained an accuracy of 84% and an AUC of 0.97 to predict complete response. Liu *et al*[40] constructed and validated a DL model (DL radiomics-based C-US model) but based on the quantitative analysis of C-US cine recordings. It was highly reproducible and had an AUC of 0.93 (95%CI: 0.80-0.98) to predict the response to TACE.

Other studies have used ML techniques combining MRI with clinical data to predict the response to TACE. Abajian *et al*[41] studied 36 patients who underwent MRI before TACE. They developed a predictive model of response with an accuracy of 78%, sensitivity of 62.5% and specificity of 82%.

The efficacy of TACE has also been examined by survival analysis of the patients after its application. Mähringer-Kunz *et al*[42] developed a prediction model of survival after TACE by constructing an ANN, using all the parameters of the main conventional prediction scores (ART[43], ABCR[44] and SNACOR[45]). They predicted a one-year survival with an AUC of 0.77, sensitivity of 78% and specificity of 81%, better results compared to those of the conventional scores mentioned.

Although most studies evaluating the use of AI to assess TACE have used radiomics, some have also evaluated the prediction of response to TACE using genetic analysis. Ziv *et al*[46] studied genetic mutations using SVM techniques to predict the tumor response after TACE, though it was a retrospective study with a low number of cases.

Evaluation of radiofrequency ablation

Radiofrequency ablation (RFA) as a therapy aimed at curing HCC in early stages[37] has also been evaluated. Liang *et al*[47] drew up a predictive model of HCC recurrence based on SVM. They studied 83 patients with HCC who underwent RFA, obtaining an AUC of 0.69, sensitivity of 67% and specificity of 86%, with which they were able to identify patients at a high risk of recurrence. Table 2 summarizes the studies using AI

Table 2 Studies applying artificial intelligence for the treatment of hepatocellular carcinoma

Ref.	Tittle	*n*	Study type	Study aim	AI tool used	Outcome	University/department
Dong *et al*[30] 2020	Preoperative prediction of microvascular invasion in hepatocellular carcinoma: initial application of a radiomic algorithm based on grayscale ultrasound images	322	Retrospective	Prediction of VMI using C-US	Radiomics	AUC: 0.73; Sen: 0.919; Spe: 0.359	Department of Ultrasound, Zhongshan Hospital, Fudan University, Shanghai, China
Xu *et al*[28] 2019	Radiomic analysis of contrast-enhanced CT predicts microvascular invasion and outcome in hepatocellular carcinoma	495	Retrospective	Prediction of VMI using C-CT	Radiomics	AUC: 0.90	Department of Radiology, The First Affiliated Hospital with Nanjing Medical University, Nanjing, Jiangsu Province, China
Ma *et al*[27] 2019	Preoperative radiomics nomogram for microvascular invasion prediction in hepatocellular carcinoma using contrast-enhanced CT	157	Retrospective	Prediction of VMI using C-CT	Radiomics	AUC: 0.73	Department of Diagnostic Radiology, National Cancer Center/Cancer Hospital, Chinese Academy of Medical Sciences and Peking Union Medical College, China
Zhou *et al*[29] 2017	Malignancy characterization of hepatocellular carcinomas based on texture analysis of contrast-enhanced MR images	46	Retrospective	Prediction of VMI using C-MRI		AUC: 0.918; Sen: 92%; Spe: 66%	Laboratory for Health Informatics, Shenzhen Institutes of Advanced Technology, Chinese Academy of Sciences, Shenzhen, China
Ziv *et al*[46] 2017	Gene signature associated with upregulation of the Wnt/β-Catenin signaling pathway predicts tumor response to transarterial embolization	17	Retrospective	Prediction of response to TACE using signature gene		Prediction accuracy: 70%	Interventional Radiology Service, Department of Radiology, Memorial Sloan Kettering Cancer Center, New York, NY, United States
Morshid *et al*[38] 2019	A machine learning model to predict hepatocellular carcinoma response to transcatheter arterial chemoembolization	105	Retrospective	Prediction of response to TACE using CT	ML	Acc: 74%	Departments of Imaging Physics, Diagnostic Radiology, Gastrointestinal Oncology and Interventional Radiology, The University of Texas, MD Anderson Cancer Center, Houston
Liu *et al*[40] 2020	Accurate prediction of responses to transarterial chemoembolization for patients with hepatocellular carcinoma by using artificial intelligence in contrast-enhanced ultrasound	130	Retrospective	Prediction of response to TACE using C-US	DL	AUC: 0.93	Department of Medical Ultrasonics, Institute of Diagnostic and Interventional Ultrasound, The First Affiliated Hospital of Sun Yat-sen University, China
Peng *et al*[39] 2020	Residual convolutional neural network for predicting response of transarterial chemoembolization in hepatocellular carcinoma from CT imaging	789	Retrospective	Prediction of response to TACE using CT	CNN	AUC: 0.97; Acc: 84.3%	Hepatology Unit and Department of Infectious Diseases, Nanfang Hospital, Southern Medical University, China
Abajian *et al*[41] 2018	Predicting treatment response to intra-arterial therapies for hepatocellular carcinoma with the use of supervised machine learning-an artificial intelligence concept	36	Retrospective	Prediction of response to TACE using MRI	ML	Acc: 78%; Sen: 62%; Spe: 82%	Yale School of Medicine, Department of Radiology and Biomedical Imaging, United States
Mähringer-Kunz *et al*[42] 2020	Predicting survival after transarterial chemoembolization for hepatocellular carcinoma using a neural network: A pilot study	282	Retrospective	Prediction of survival after TACE	CNN	Acc: 0.77; Sen: 78%; Spe: 81%	Department of Diagnostic and Interventional Radiology, University Medical Center of the Johannes Gutenberg-University Mainz, Mainz, Germany
Saillard *et al*[35] 2020	Predicting survival after hepatocellular carcinoma resection using deep-learning on histological slides	194	Retrospective	Prediction of survival after surgical resection	DL	C-index: 0.78	Owkin Lab, Owkin
Liang *et al*[47] 2014	Recurrence predictive models for patients with hepatocellular carcinoma after radiofrequency ablation using support vector machines with feature selection methods	83	Prospective	Prediction of recurrence after RFA	ML	AUC: 67%; Sen: 86%; Spe: 82%	Department of Internal Medicine, National Taiwan University Hospital and National Taiwan University College of Medicine, Taipei, Taiwan
Ji	Machine-learning analysis of contrast-enhanced CT radiomics	470	Retrospective	Prediction of	ML	C-index: 0.633-	Hepatobiliary Center, The First Affiliated Hospital of Nanjing

et al[31] 2019	predicts recurrence of hepatocellular carcinoma after resection: A multi-institutional study	recurrence after resection	0.699	Medical University, Nanjing, PR China

Note: All studies were retrospective studies in their design, except the study by Liang *et al*[47] was prospective. AI: Artificial intelligence; CNN: Convolutional neural network; ML: Machine learning; DL: Deep learning; VMI: Vascular microinvasion; C-US: Contrast-enhanced ultrasound; AUC: Area under the curve; Acc: Accuracy; Sen: Sensitivity; Spe: Specificity; CT: Computed tomography; C-CT: Contrast-enhanced CT; MRI: Magnetic resonance imaging; C-MRI: Contrast-enhanced MRI; TACE: Transcatheter arterial chemoembolization; RFA: Radiofrequency ablation.

techniques in the treatment of HCC.

PREDICTING OVERALL SURVIVAL OF HCC

The prediction of overall survival of HCC, apart from the application of any therapy, has also been assessed using AI techniques. Current evidence on the relation of abnormalities in DNA methylation and HCC[48-50] was the basis for the study by Dong *et al*[51]. These authors used ML techniques (SVM) to analyze DNA methylation data from 377 HCC samples, and constructed three risk categories to predict overall survival, with a mean 10-fold cross-validation score of 0.95.

FUTURE DIRECTIONS

Larger studies are needed comparing the yield of medical professionals with the support of AI *vs* other professionals without such support in order to demonstrate its benefit as an aid in medicine. In particular, to assess liver masses and study HCC these trials should focus on aspects related to treatment and prognosis, such as the characterization of hepatic lesions catalogued as indeterminate, the presence of vascular invasion and the response to percutaneous therapy. Another important aspect is the use of AI in the analysis of the behavior of HCC in cirrhotic and non-cirrhotic patients, as well as the differentiation of primary and metastatic liver lesions[52] and especially the differential diagnosis with cholangiocarcinoma that can be complicated with currently available techniques and whose management and prognosis are completely different from those of HCC. At the same time, it is also necessary to start training health-care professionals to be prepared for the future incorporation of AI in daily practice in the field of liver cancer.

CONCLUSION

The incorporation of AI technologies in medicine has represented one of the most

relevant advances in recent years. It will doubtless experience a progressively increasing rise, due to its usefulness in the processing and analysis of the enormous amount of data currently available. Nevertheless, we should be aware that certain constraints still exist that can limit its acceptance and applicability in clinical practice. Health care professionals must learn the true usefulness of AI and accept the need for its coexistence with the indispensable need for human evaluation, accepting that AI is here to support human intelligence, never to replace it. Despite the great progress represented by AI, it is nevertheless vital to guarantee that medical protocols remain rigorously transparent.

REFERENCES

1 **Turing AM**. I.—Computing Machinery and Intelligence. *Mind* 1950; **LIX**: 433-460 [DOI: 10.1093/mind/LIX.236.433]

2 **Kaul V**, Enslin S, Gross SA. History of artificial intelligence in medicine. *Gastrointest Endosc* 2020 [PMID: 32565184 DOI: 10.1016/j.gie.2020.06.040]

3 **Yang YJ**, Bang CS. Application of artificial intelligence in gastroenterology. *World J Gastroenterol* 2019; **25**: 1666-1683 [PMID: 31011253 DOI: 10.3748/wjg.v25.i14.1666]

4 **Le Berre C**, Sandborn WJ, Aridhi S, Devignes MD, Fournier L, Smaïl-Tabbone M, Danese S, Peyrin-Biroulet L. Application of Artificial Intelligence to Gastroenterology and Hepatology. *Gastroenterology* 2020; **158**: 76-94.e2 [PMID: 31593701 DOI: 10.1053/j.gastro.2019.08.058]

5 **Siegel RL**, Miller KD, Jemal A. Cancer statistics, 2020. *CA Cancer J Clin* 2020; **70**: 7-30 [PMID: 31912902 DOI: 10.3322/caac.21590]

6 **Briceño J**. Artificial intelligence and organ transplantation: challenges and expectations. *Curr Opin Organ Transplant* 2020; **25**: 393-398 [PMID: 32487888 DOI: 10.1097/MOT.0000000000000775]

7 **Bharti P**, Mittal D, Ananthasivan R. Preliminary Study of Chronic Liver Classification on Ultrasound Images Using an Ensemble Model. *Ultrason Imaging* 2018; **40**: 357-379 [PMID: 30015593 DOI: 10.1177/0161734618787447]

8 **Liu X**, Song JL, Wang SH, Zhao JW, Chen YQ. Learning to Diagnose Cirrhosis with Liver Capsule Guided Ultrasound Image Classification. *Sensors (Basel)* 2017; **17**: 149 [PMID: 28098774 DOI: 10.3390/s17010149]

9 **Schmauch B**, Herent P, Jehanno P, Dehaene O, Saillard C, Aubé C, Luciani A, Lassau N, Jégou S. Diagnosis of focal liver lesions from ultrasound using deep learning. *Diagn Interv Imaging* 2019; **100**: 227-233 [PMID: 30926443 DOI: 10.1016/j.diii.2019.02.009]

10 **Guo LH**, Wang D, Qian YY, Zheng X, Zhao CK, Li XL, Bo XW, Yue WW, Zhang Q, Shi J, Xu HX. A two-stage multi-view learning framework based computer-aided diagnosis of liver tumors with contrast enhanced ultrasound images. *Clin Hemorheol Microcirc* 2018; **69**: 343-354 [PMID: 29630528 DOI: 10.3233/CH-170275]

11 **European Association for the Study of the Liver**. EASL Clinical Practice Guidelines: Management of hepatocellular carcinoma. *J Hepatol* 2018; **69**: 182-236 [PMID: 29628281 DOI: 10.1016/j.jhep.2018.03.019]

12 **Heimbach JK**, Kulik LM, Finn RS, Sirlin CB, Abecassis MM, Roberts LR, Zhu AX, Murad MH, Marrero JA. AASLD guidelines for the treatment of hepatocellular carcinoma. *Hepatology* 2018; **67**: 358-380 [PMID: 28130846 DOI: 10.1002/hep.29086]

13 **Mokrane FZ**, Lu L, Vavasseur A, Otal P, Peron JM, Luk L, Yang H, Ammari S, Saenger Y, Rousseau H, Zhao B, Schwartz LH, Dercle L. Radiomics machine-learning signature for diagnosis of hepatocellular carcinoma in cirrhotic patients with indeterminate liver nodules. *Eur Radiol* 2020; **30**: 558-570 [PMID: 31444598 DOI: 10.1007/s00330-019-06347-w]

14 **Yasaka K**, Akai H, Abe O, Kiryu S. Deep Learning with Convolutional Neural Network for Differentiation of Liver Masses at Dynamic Contrast-enhanced CT: A Preliminary Study. *Radiology* 2018; **286**: 887-896 [PMID: 29059036 DOI: 10.1148/radiol.2017170706]

15 **Vivanti R**, Szeskin A, Lev-Cohain N, Sosna J, Joskowicz L. Automatic detection of new tumors and tumor burden evaluation in longitudinal liver CT scan studies. *Int J Comput Assist Radiol Surg* 2017; **12**: 1945-1957 [PMID: 28856515 DOI: 10.1007/s11548-017-1660-z]

16 **Li W**, Jia F, Hu Q. Automatic Segmentation of Liver Tumor in CT Images with Deep Convolutional Neural Networks. *J Comput Commun* 2015; **3**: 146-151 [DOI: 10.4236/jcc.2015.311023]

17 **Hamm CA**, Wang CJ, Savic LJ, Ferrante M, Schobert I, Schlachter T, Lin M, Duncan JS, Weinreb JC, Chapiro J, Letzen B. Deep learning for liver tumor diagnosis part I: development of a convolutional neural network classifier for multi-phasic MRI. *Eur Radiol* 2019; **29**: 3338-3347 [PMID: 31016442 DOI: 10.1007/s00330-019-06205-9]

18 **Jansen MJA**, Kuijf HJ, Veldhuis WB, Wessels FJ, Viergever MA, Pluim JPW. Automatic classification of focal liver lesions based on MRI and risk factors. *PLoS One* 2019; **14**: e0217053 [PMID: 31095624 DOI: 10.1371/journal.pone.0217053]

19 **Zhang F**, Yang J, Nezami N, Laage-Gaupp F, Chapiro J, De Lin M, Duncan J. Liver Tissue Classification Using an Auto-context-based Deep Neural Network with a Multi-phase Training Framework. *Patch Based Tech Med Imaging (2018)* 2018; **11075**: 59-66 [PMID: 32432233 DOI: 10.1007/978-3-030-00500-9_7]

20 **Preis O**, Blake MA, Scott JA. Neural network evaluation of PET scans of the liver: a potentially useful adjunct in clinical interpretation. *Radiology* 2011; **258**: 714-721 [PMID: 21339347 DOI: 10.1148/radiol.10100547]

21 **Kiani A**, Uyumazturk B, Rajpurkar P, Wang A, Gao R, Jones E, Yu Y, Langlotz CP, Ball RL, Montine TJ, Martin BA, Berry GJ, Ozawa MG, Hazard FK, Brown RA, Chen SB, Wood M, Allard LS, Ylagan L, Ng AY, Shen J. Impact of a deep learning assistant on the histopathologic classification of liver cancer. *NPJ Digit Med* 2020; **3**: 23 [PMID: 32140566 DOI: 10.1038/s41746-020-0232-8]

22 **Liao H**, Xiong T, Peng J, Xu L, Liao M, Zhang Z, Wu Z, Yuan K, Zeng Y. Classification and Prognosis Prediction from Histopathological Images of Hepatocellular Carcinoma by a Fully Automated Pipeline Based on Machine Learning. *Ann Surg Oncol* 2020; **27**: 2359-2369 [PMID: 31916093 DOI: 10.1245/s10434-019-08190-1]

23 **Villanueva A**. Hepatocellular Carcinoma. *N Engl J Med* 2019; **380**: 1450-1462 [PMID: 30970190 DOI: 10.1056/NEJMra1713263]

24 **Gillies RJ**, Kinahan PE, Hricak H. Radiomics: Images Are More than Pictures, They Are Data. *Radiology* 2016; **278**: 563-577 [PMID: 26579733 DOI: 10.1148/radiol.2015151169]

25 **Lambin P**, Leijenaar RTH, Deist TM, Peerlings J, de Jong EEC, van Timmeren J, Sanduleanu S, Larue RTHM, Even AJG, Jochems A, van Wijk Y, Woodruff H, van Soest J, Lustberg T, Roelofs E, van Elmpt W, Dekker A, Mottaghy FM, Wildberger JE, Walsh S. Radiomics: the bridge between medical imaging and personalized medicine. *Nat Rev Clin Oncol* 2017; **14**: 749-762 [PMID: 28975929 DOI: 10.1038/nrclinonc.2017.141]

26 **Erstad DJ**, Tanabe KK. Prognostic and Therapeutic Implications of Microvascular Invasion in Hepatocellular Carcinoma. *Ann Surg Oncol* 2019; **26**: 1474-1493 [PMID: 30788629 DOI: 10.1245/s10434-019-07227-9]

27 **Ma X**, Wei J, Gu D, Zhu Y, Feng B, Liang M, Wang S, Zhao X, Tian J. Preoperative radiomics nomogram for microvascular invasion prediction in hepatocellular carcinoma using contrast-enhanced CT. *Eur Radiol* 2019; **29**: 3595-3605 [PMID: 30770969 DOI: 10.1007/s00330-018-5985-y]

28 **Xu X**, Zhang HL, Liu QP, Sun SW, Zhang J, Zhu FP, Yang G, Yan X, Zhang YD, Liu XS. Radiomic analysis of contrast-enhanced CT predicts microvascular invasion and outcome in hepatocellular carcinoma. *J Hepatol* 2019; **70**: 1133-1144 [PMID: 30876945 DOI: 10.1016/j.jhep.2019.02.023]

29 **Zhou W**, Zhang L, Wang K, Chen S, Wang G, Liu Z, Liang C. Malignancy characterization of hepatocellular carcinomas based on texture analysis of contrast-enhanced MR images. *J Magn Reson Imaging* 2017; **45**: 1476-1484 [PMID: 27626270 DOI: 10.1002/jmri.25454]

30 **Dong Y**, Zhou L, Xia W, Zhao XY, Zhang Q, Jian JM, Gao X, Wang WP. Preoperative Prediction of Microvascular Invasion in Hepatocellular Carcinoma: Initial Application of a Radiomic Algorithm Based on Grayscale Ultrasound Images. *Front Oncol* 2020; **10**: 353 [PMID: 32266138 DOI: 10.3389/fonc.2020.00353]

31 **Ji GW**, Zhu FP, Xu Q, Wang K, Wu MY, Tang WW, Li XC, Wang XH. Machine-learning analysis of contrast-enhanced CT radiomics predicts recurrence of hepatocellular carcinoma after resection: A multi-institutional study. *EBioMedicine* 2019; **50**: 156-165 [PMID: 31735556 DOI: 10.1016/j.ebiom.2019.10.057]

32 **Ho WH**, Lee KT, Chen HY, Ho TW, Chiu HC. Disease-free survival after hepatic resection in hepatocellular carcinoma patients: a prediction approach using artificial neural network. *PLoS One* 2012; **7**: e29179 [PMID: 22235270 DOI: 10.1371/journal.pone.0029179]

33 **Chiu HC**, Ho TW, Lee KT, Chen HY, Ho WH. Mortality predicted accuracy for hepatocellular carcinoma patients with hepatic resection using artificial neural network. *ScientificWorldJournal* 2013; **2013**: 201976 [PMID: 23737707 DOI: 10.1155/2013/201976]

34 **Shi HY**, Lee KT, Lee HH, Ho WH, Sun DP, Wang JJ, Chiu CC. Comparison of artificial neural network and logistic regression models for predicting in-hospital mortality after primary liver cancer surgery. *PLoS One* 2012; **7**: e35781 [PMID: 22563399 DOI: 10.1371/journal.pone.0035781]

35 **Saillard C**, Schmauch B, Laifa O, Moarii M, Toldo S, Zaslavskiy M, Pronier E, Laurent A, Amaddeo G, Regnault H, Sommacale D, Ziol M, Pawlotsky JM, Mulé S, Luciani A, Wainrib G, Clozel T, Courtiol P, Calderaro J. Predicting survival after hepatocellular carcinoma resection using deep-learning on histological slides. *Hepatology* 2020 [PMID: 32108950 DOI: 10.1002/hep.31207]

36 **Schoenberg MB**, Bucher JN, Koch D, Börner N, Hesse S, De Toni EN, Seidensticker M, Angele MK, Klein C, Bazhin AV, Werner J, Guba MO. A novel machine learning algorithm to predict disease free survival after resection of hepatocellular carcinoma. *Ann Transl Med* 2020; **8**: 434 [PMID: 32395478 DOI: 10.21037/atm.2020.04.16]

37 **Forner A**, Reig M, Bruix J. Hepatocellular carcinoma. *Lancet* 2018; **391**: 1301-1314 [PMID: 29307467 DOI: 10.1016/S0140-6736(18)30010-2]

38 **Morshid A**, Elsayes KM, Khalaf AM, Elmohr MM, Yu J, Kaseb AO, Hassan M, Mahvash A, Wang Z, Hazle JD, Fuentes D. A machine learning model to predict hepatocellular carcinoma response to transcatheter arterial chemoembolization. *Radiol Artif Intell* 2019; **1**: e180021 [PMID: 31858078 DOI: 10.1148/ryai.2019180021]

39 **Peng J**, Kang S, Ning Z, Deng H, Shen J, Xu Y, Zhang J, Zhao W, Li X, Gong W, Huang J, Liu L. Residual convolutional neural network for predicting response of transarterial chemoembolization in hepatocellular carcinoma from CT imaging. *Eur Radiol* 2020; **30**: 413-424 [PMID: 31332558 DOI: 10.1007/s00330-019-06318-1]

40 **Liu D**, Liu F, Xie X, Su L, Liu M, Xie X, Kuang M, Huang G, Wang Y, Zhou H, Wang K, Lin M, Tian J. Accurate prediction of responses to transarterial chemoembolization for patients with hepatocellular carcinoma by using artificial intelligence in contrast-enhanced ultrasound. *Eur Radiol* 2020; **30**: 2365-2376 [PMID: 31900703 DOI: 10.1007/s00330-019-06553-6]

41 **Abajian A**, Murali N, Savic LJ, Laage-Gaupp FM, Nezami N, Duncan JS, Schlachter T, Lin M, Geschwind JF, Chapiro J. Predicting Treatment Response to Image-Guided Therapies Using Machine Learning: An Example for Trans-Arterial Treatment of Hepatocellular Carcinoma. *J Vis Exp* 2018; **140**: e58382 [PMID: 30371657 DOI: 10.3791/58382]

42 **Mähringer-Kunz A**, Wagner F, Hahn F, Weinmann A, Brodehl S, Schotten S, Hinrichs JB, Düber C, Galle PR, Pinto Dos Santos D, Kloeckner R. Predicting survival after transarterial chemoembolization for hepatocellular carcinoma using a neural network: A Pilot Study. *Liver Int* 2020; **40**: 694-703 [PMID: 31943703 DOI: 10.1111/liv.14380]

43 **Sieghart W**, Hucke F, Pinter M, Graziadei I, Vogel W, Müller C, Heinzl H, Trauner M, Peck-Radosavljevic M. The ART of decision making: retreatment with transarterial chemoembolization in patients with hepatocellular carcinoma. *Hepatology* 2013; **57**: 2261-2273 [PMID: 23316013 DOI: 10.1002/hep.26256]

44 **Adhoute X**, Penaranda G, Naude S, Raoul JL, Perrier H, Bayle O, Monnet O, Beaurain P, Bazin C, Pol B,

Folgoc GL, Castellani P, Bronowicki JP, Bourlière M. Retreatment with TACE: the ABCR SCORE, an aid to the decision-making process. *J Hepatol* 2015; **62**: 855-862 [PMID: 25463541 DOI: 10.1016/j.jhep.2014.11.014]

45 **Kim BK**, Shim JH, Kim SU, Park JY, Kim DY, Ahn SH, Kim KM, Lim YS, Han KH, Lee HC. Risk prediction for patients with hepatocellular carcinoma undergoing chemoembolization: development of a prediction model. *Liver Int* 2016; **36**: 92-99 [PMID: 25950442 DOI: 10.1111/liv.12865]

46 **Ziv E**, Yarmohammadi H, Boas FE, Petre EN, Brown KT, Solomon SB, Solit D, Reidy D, Erinjeri JP. Gene Signature Associated with Upregulation of the Wnt/β-Catenin Signaling Pathway Predicts Tumor Response to Transarterial Embolization. *J Vasc Interv Radiol* 2017; **28**: 349-355.e1 [PMID: 28126478 DOI: 10.1016/j.jvir.2016.11.004]

47 **Liang JD**, Ping XO, Tseng YJ, Huang GT, Lai F, Yang PM. Recurrence predictive models for patients with hepatocellular carcinoma after radiofrequency ablation using support vector machines with feature selection methods. *Comput Methods Programs Biomed* 2014; **117**: 425-434 [PMID: 25278224 DOI: 10.1016/j.cmpb.2014.09.001]

48 **Xu RH**, Wei W, Krawczyk M, Wang W, Luo H, Flagg K, Yi S, Shi W, Quan Q, Li K, Zheng L, Zhang H, Caughey BA, Zhao Q, Hou J, Zhang R, Xu Y, Cai H, Li G, Hou R, Zhong Z, Lin D, Fu X, Zhu J, Duan Y, Yu M, Ying B, Zhang W, Wang J, Zhang E, Zhang C, Li O, Guo R, Carter H, Zhu JK, Hao X, Zhang K. Circulating tumour DNA methylation markers for diagnosis and prognosis of hepatocellular carcinoma. *Nat Mater* 2017; **16**: 1155-1161 [PMID: 29035356 DOI: 10.1038/nmat4997]

49 **Villanueva A**, Portela A, Sayols S, Battiston C, Hoshida Y, Méndez-González J, Imbeaud S, Letouzé E, Hernandez-Gea V, Cornella H, Pinyol R, Solé M, Fuster J, Zucman-Rossi J, Mazzaferro V, Esteller M, Llovet JM; HEPTROMIC Consortium. DNA methylation-based prognosis and epidrivers in hepatocellular carcinoma. *Hepatology* 2015; **61**: 1945-1956 [PMID: 25645722 DOI: 10.1002/hep.27732]

50 **Yeh CC**, Goyal A, Shen J, Wu HC, Strauss JA, Wang Q, Gurvich I, Safyan RA, Manji GA, Gamble MV, Siegel AB, Santella RM. Global Level of Plasma DNA Methylation is Associated with Overall Survival in Patients with Hepatocellular Carcinoma. *Ann Surg Oncol* 2017; **24**: 3788-3795 [PMID: 28593503 DOI: 10.1245/s10434-017-5913-4]

51 **Dong RZ**, Yang X, Zhang XY, Gao PT, Ke AW, Sun HC, Zhou J, Fan J, Cai JB, Shi GM. Predicting overall survival of patients with hepatocellular carcinoma using a three-category method based on DNA methylation and machine learning. *J Cell Mol Med* 2019; **23**: 3369-3374 [PMID: 30784182 DOI: 10.1111/jcmm.14231]

52 **Azer SA**. Deep learning with convolutional neural networks for identification of liver masses and hepatocellular carcinoma: A systematic review. *World J Gastrointest Oncol* 2019; **11**: 1218-1230 [PMID: 31908726 DOI: 10.4251/wjgo.v11.i12.1218]

World Journal of Gastroenterology

Submit a Manuscript: https://www.f6publishing.com

World J Gastroenterol 2020 October 7; 26(37): 5629-5645

DOI: 10.3748/wjg.v26.i37.5629

ISSN 1007-9327 (print) ISSN 2219-2840 (online)

ORIGINAL ARTICLE

Basic Study

Antioxidant activity and hepatoprotective effect of 10 medicinal herbs on CCl_4-induced liver injury in mice

Xiao Meng, Guo-Yi Tang, Pin-He Liu, Chan-Juan Zhao, Qing Liu, Hua-Bin Li

ORCID number: Xiao Meng 0000-0002-9388-2895; Guo-Yi Tang 0000-0003-2264-730X; Pin-He Liu 0000-0001-9793-5379; Chan-Juan Zhao 0000-0001-7166-2093; Qing Liu 0000-0002-6255-6894; Hua-Bin Li 0000-0003-2332-8554.

Author contributions: Meng X and Li HB contributed to the conception and design of the study; Meng X, Tang GY, Liu PH, and Liu Q performed the experiments and acquired data; Meng X and Liu PH drafted the article; Tang GY, Zhao CJ, and Liu Q made critical revisions; all authors approved the final version of the article.

Institutional animal care and use committee statement: All experimental procedures were performed based on the approval of Animal Ethics Committee of School of Public Health, Sun Yat-Sen University (No. 2017-011).

Conflict-of-interest statement: The authors declare no conflict of interest.

Data sharing statement: No additional data are available.

ARRIVE guidelines statement: The authors have read the ARRIVE guidelines, and the manuscript was prepared and revised

Xiao Meng, Guo-Yi Tang, Pin-He Liu, Qing Liu, Hua-Bin Li, Department of Nutrition, School of Public Health, Sun Yat-Sen University, Guangzhou 510080, Guangdong Province, China

Chan-Juan Zhao, Department of Bio-statistics, School of Public Health, Hainan Medical University, Haikou 571199, Hainan Province, China

Corresponding author: Xiao Meng, PhD, Lecturer, Department of Nutrition, School of Public Health, Sun Yat-Sen University, No. 74 Zhongshan Road 2, Yuexiu District, Guangzhou 510080, Guangdong Province, China. mengx7@mail2.sysu.edu.cn

Abstract

BACKGROUND

Many natural products confer health benefits against diverse diseases through their antioxidant activities. Carbon tetrachloride (CCl_4) is often used in animal experiments to study the effects of substances on liver injury and the related mechanisms of action, among which oxidative stress is a major pathogenic factor.

AIM

To compare antioxidant and hepatoprotective activities of ten herbs and identify and quantify phytochemicals for the one with strongest hepatoprotection.

METHODS

The antioxidant activity of ten medicinal herbs was determined by both ferric-reducing antioxidant power and Trolox equivalent antioxidant capacity assays. The total phenolic and flavonoid contents were determined by Folin–Ciocalteu method and aluminum chloride colorimetry, respectively. Their effects on CCl_4-induced oxidative liver injury were evaluated and compared in a mouse model by administrating each water extract (0.15 g/mL, 10 mL/kg) once per day for seven consecutive days and a dose of CCl_4 solution in olive oil (8%, v/v, 10 mL/kg). The herb with the strongest hepatoprotective performance was analyzed for the detailed bioactive components by using high-performance liquid chromatography-electrospray ionization source-ion trap tandem mass spectrometry.

RESULTS

The results revealed that all tested herbs attenuated CCl_4-induced oxidative liver injury; each resulted in significant decreases in levels of serum alanine transaminase, aspartate transaminase, alkaline phosphatase, and triacylglycerols.

Manuscript source: Unsolicited manuscript

Received: June 12, 2020
Peer-review started: June 12, 2020
First decision: July 25, 2020
Revised: July 28, 2020
Accepted: September 9, 2020
Article in press: September 9, 2020
Published online: October 7, 2020

P-Reviewer: Boeckxstaens G, Ryan E
S-Editor: Ma YJ
L-Editor: Filipodia
P-Editor: Ma YJ

In addition, most herbs restored hepatic superoxide dismutase and catalase activities, glutathione levels, and reduced malondialdehyde levels. *Sanguisorba officinalis* (*S. officinalis*) L., *Coptis chinensis* Franch., and *Pueraria lobata* (Willd.) Ohwi root were the three most effective herbs, and *S. officinalis* L. exhibited the strongest hepatoprotective effect. Nine active components were identified in *S. officinalis* L. Gallic acid and (+)-catechin were quantified (7.86 ± 0.45 mg/g and 8.19 ± 0.57 mg/g dried weight, respectively). Furthermore, the tested herbs displayed a range of *in vitro* antioxidant activities proportional to their phenolic content; the strongest activities were also found for *S. officinalis* L.

CONCLUSION

This study is of value to assist the selection of more effective natural products for direct consumption and the development of nutraceuticals or therapeutics to manage oxidative stress-related diseases.

Key Words: Antioxidant activity; CCl_4-induced liver injury; Medicinal herbs; Hepatoprotection; *Sanguisorba officinalis* L.; *Coptis chinensis* Franch

Core Tip: Many natural products confer health benefits against diverse diseases through their antioxidant activities. In this study, ten medicinal herbs were selected for an evaluation and comparison of their effects on carbon tetrachloride (CCl_4)-induced oxidative liver injury. *Sanguisorba officinalis* (*S. officinalis*) L. exhibited the strongest hepatoprotective effect, and the strongest *in vitro* activities were also found for *S. officinalis* L. Our results provided valuable information for the selection of more efficient herbs to protect against CCl_4-induced liver injury and to support the direct application of herbs or the development of novel therapies for the management of oxidative stress-related diseases.

Citation: Meng X, Tang GY, Liu PH, Zhao CJ, Liu Q, Li HB. Antioxidant activity and hepatoprotective effect of 10 medicinal herbs on CCl_4-induced liver injury in mice. *World J Gastroenterol* 2020; 26(37): 5629-5645
URL: https://www.wjgnet.com/1007-9327/full/v26/i37/5629.htm
DOI: https://dx.doi.org/10.3748/wjg.v26.i37.5629

INTRODUCTION

Redox reactions are involved in numerous physiological and pathological processes; moreover, cellular homeostasis depends on the interaction between oxidants and the defense system, which includes reductants and antioxidant enzymes[1,2]. The prevalence of free radicals, such as reactive oxygen species and reactive nitrogen species, at a desirable level can contribute to cell growth and differentiation[2]. However, the overproduction of free radicals is destructive, resulting in oxidative stress and contributing to various diseases, such as cardiovascular diseases, cancer, diabetes, obesity, neurodegenerative disorders, and liver diseases[3-6].

Many factors can cause liver damage. In addition to physical factors (*e.g.*, radiation) and biological factors (*e.g.*, viruses), some chemicals are hepatotoxic. Carbon tetrachloride (CCl_4) is often used in animal experiments to study the effects of substances on liver injury and the related mechanisms of action[7-9]. The causal link between CCl_4 and liver diseases has been well established[9,10]. During the metabolism of CCl_4 in the liver, hepatotoxic metabolites and excessive free radicals such as trichloromethyl radical ($\cdot CCl_3$) and trichloromethylperoxy radical ($\cdot OOCCl_3$) are generated, accompanied by other free radicals (*e.g.*, O^{2-} and H_2O_2). Consequently, reductants (*e.g.*, glutathione, GSH) are depleted, and antioxidant enzymes [*e.g.*, superoxide dismutase (SOD) and catalase (CAT)] are inhibited, inducing oxidative stress[9]. Meanwhile, the toxic metabolites and free radicals bind to phospholipid molecules embedded in the membranes of mitochondria, the endoplasmic reticulum, and hepatocytes, which leads to lipid peroxidation and membrane dysfunction or damage[9]. In addition, they can also bind with other macromolecules, such as proteins

and DNA, and result in cell damage or death. Such a condition may aggravate hypoxia, induce the accumulation of more lipids, facilitate gut leakage and bacterial translocation, promote cytokine release, and increase hepatic iron accumulation, which exacerbates the production of highly reactive radicals[4,11]. Therefore, oxidative stress is a major pathogenic factor for CCl_4-induced liver injury.

Through their antioxidant activities, many natural products have been shown to exert protective effects against various oxidative stress-related diseases, such as cardiovascular disease, cancer, and liver diseases[4,12,13]. Notably, based on observations from many cultures over many years, numerous foods and herbs, including staple foods, vegetables, seasonings, and herbal teas[14,15], have been reported to protect the liver. Subsequently, scientific evidence has shown that many related products and specific bioactive components have protective effects in the liver against oxidative injuries[8,16]. In this study, ten medicinal foods and herbs were selected for an evaluation and comparison of their effects on CCl_4-induced oxidative liver injury. In addition, the herb with the strongest hepatoprotective performance was analyzed for the detailed bioactive components by using high-performance liquid chromatography-electrospray ionization source-ion trap tandem mass spectrometry (HPLC-ESI-ITMS/MS). The *in vitro* antioxidant capacities, total phenolic content (TPC), and total flavonoid content (TFC) of the ten herbs were also determined. This study aimed to provide valuable information for the selection of more efficient herbs to protect against CCl_4-induced liver injury and to support the direct application of herbs or the development of novel therapies for the management of oxidative stress-related diseases.

MATERIALS AND METHODS

Chemicals

CCl_4, sodium chloride, and acetic acid were obtained from Damao Chemical Reagent Factory (Tianjin, China). Olive oil was purchased from Aladdin Industrial Corporation (Shanghai, China). Methanol (99.9%, HPLC/ACS grade) and formic acid (≥ 90%, guaranteed grade) were purchased from Amethyst Chemicals (Beijing, China) and Kermel Chemical Factory (Tianjin, China), respectively. The phenolic standards, 2,4,6-tripyridyl-s-triazine (TPTZ), 6-hydroxy-2,5,7,8-tetramethylchromane-2-carboxylic acid (Trolox), Folin and Ciocalteu's phenol, and 2,2′-azino-bis(3-ethylbenothiazoline-6-sulphonic acid) diammonium salt (ABTS) were purchased from Sigma-Aldrich (St. Louis, MO, United States). Gallic acid (> 98%) and (+)-catechin (> 98%) were obtained from Chengdu Derick Biotechnology Co. Ltd. (Sichuan, China).

All chemicals were of analytical or chromatographical grade. Double-distilled water was used in all experiments. Bifendate was obtained from the Beijing Union Pharmaceutical Factory. Detection kits for total protein, malondialdehyde (MDA), triglyceride (TG), GSH, SOD, and CAT were purchased from Nanjing Jiancheng Bioengineering Institute (Nanjing, China).

Preparation of water extract

Ten medicinal foods and herbs, *Acanthopanax senticosus* (Rupr. et Maxim.) harms (root and rhizome), *Amomum villosum* Lour. (fruit), *Amomum kravanh* Pierre ex Gagnep. (fruit), *Artemisia capillaris* Thunb. (herb), *Cimicifuga heracleifolia* Kom. (rhizome), *Coptis chinensis* Franch. (rhizome), *Glycyrrhiza uralensis* Fisch. (root and rhizome), *Pueraria lobata* (Willd.) Ohwi (flower), *P. lobata* (Willd.) Ohwi (root), and *Sanguisorba officinalis* L. (root) were purchased from Tong Ren Tang Chinese Medicine Co., Ltd. (Guangzhou, Guangdong, China). The samples were processed in accordance with a published method[17] but with minor modifications. The finely ground powder of each sample was filtered through a 100-mesh sieve. Then, 10.00 g of filtered powder was mixed with 100 mL of water (room temperature, 30 min) before the mixture was decocted in a water bath (98 °C, 30 min). The cooled mixtures were then centrifuged (4200 *g*, 10 min), and the supernatant was collected. The extraction was conducted twice, and the supernatants were combined for further use.

Animals and experimental design

Each of the water extracts was freeze dried in a FreeZone Freeze Dryer (Labconco FreeZone®, United States), and the dried crude extract was dissolved in water to give a concentration of 0.15 g/mL. Therefore, when gavaged with 10 mL/kg water extract, each mouse received 1.5 g dried weight (DW)/kg, which is equivalent to the desired human dose recommended by National Administration of Traditional Chinese

Medicine[18-20].

SPF Kunming mice (male, weight 18–22 g) were provided by the Laboratory Animal Center of Sun Yat-Sen University, Guangzhou, China. With free access to water and rodent chow, the animals were kept in a controlled environment (22 °C ± 0.5 °C, 40%–60% relative humidity, and a 12 h light-dark cycle). All animal procedures were approved by the Animal Ethics Committee of the School of Public Health at Sun Yat-Sen University (No. 2017-011). The mice were randomly assigned into 13 groups each containing eight mice: control group, model group, positive control, and ten treatment groups. Each herb extract (15 mg/mL, 10 mL/kg) was administered to the mice by gavage once per day for seven consecutive days; bifendate (150 mg/kg) was administered in the positive control group[21], and an equivalent volume of water was administered in the control and model groups. One hour after the final administration, CCl_4 solution in olive oil (8%, v/v, 10 mL/kg)[22,23] was administered by intraperitoneal injection to the mice in the model group, positive control group, and ten treatment groups; an equivalent concentration of olive oil (10 mL/kg) was administered to the control group. After 16 h, the mice were anesthetized, blood samples were taken, and the livers were harvested.

The blood samples were centrifuged twice at 3600 *g* for 15 min, and the serum was separated and analyzed by using a Beckman Coulter Chemistry Analyzer (AU5821, Tokyo, Japan), and the following serum biomarkers were analyzed: alanine transaminase (ALT), aspartate transaminase (AST), alkaline phosphatase (ALP), total bilirubin (TBIL), and TG. Two slides of liver were sampled from the middle of the left lobe of the liver, one for histopathologic examination (hematoxylin and eosin staining) and the other for biomarker assessment. Liver homogenate was prepared from liver tissue (0.2 g) and physiological saline (ice-cold, 1.8 mL), centrifuged at 2500 *g* for 10 min and then examined for the activities of SOD and CAT and the levels of GSH, MDA, and TG in accordance with the manufacturer's instructions and as described in our previous publications[24].

HPLC-ESI-ITMS/MS

The decoction of the herb with the strongest hepatoprotective effect (*S. officinalis* L.) was analyzed by reverse-phase HPLC using a Shim-pack GIS C18 column (5 μm, 4.6 mm × 250 mm; Shimadzu) maintained at 30 °C and a gradient elution (solvent A: H_2O containing 0.1% (v/v) formic acid; solvent B, methanol containing 0.1% (v/v) formic acid). The phytochemical compounds were separated using a 70-min linear gradient from 20% to 70% solvent B at a flow rate of 1.0 mL/min and detected at 280 nm. The injection volumes were 20 μL (sample without dilution) for HPLC analysis and 50 μL (sample with 10-fold dilution) for HPLC-MS/MS analysis.

The MS analysis was performed by using an Ion Trap Mass Spectrometer (ITMS; Thermo Scientific, United States) equipped with an ESI under the following conditions: ESI source temperature, 320 °C; source voltages, 4.0 kV for positive mode and 3.5 kV for negative mode; capillary voltages, 24.0 V for positive polarity, and -12.0 V for negative polarity; desolvation gas, nitrogen; full scan mass range, *m/z* 50–1500. Tandem mass spectrometry analyses were performed using nitrogen as the collision gas with a collision energy of 35 eV. The MS/MS spectrum was obtained to the tenth most intense ion from ITMS.

Evaluation of in vitro antioxidant activities

The ferric-reducing antioxidant power (FRAP) assay was performed to assess the antioxidant activity (Fe^{3+}-reducing capability) of the tested herbs using a slightly modified version of a published method[25]. In short, FRAP reagent was freshly prepared and kept in a water bath at 37 °C until use with the following three solutions (10:1:1, v/v/v): (1) Sodium acetate buffer (300 mmol/L, pH 3.6); (2) TPTZ solution (10 mmol/L, solvent: 40 mmol/L HCl); and (3) Ferric chloride solution (20 mmol/L). Then, the mixture of the water extract of each sample (100 μL) and FRAP reagents (3 mL) were incubated at room temperature for 4 min. The absorbance of each mixture at 593 nm was recorded. The results were expressed in the form of μmol Fe^{2+}/g DW, with reference to ferrous sulfate as the standard.

The Trolox equivalent antioxidant capacity (TEAC) assay was also conducted to measure the antioxidant activities (free radical, *i.e.*, $ABTS^{\bullet+}$-scavenging capability) of the tested herbs and was performed using a slightly modified version of a published method[26]. Briefly, the ABTS free radical ($ABTS^{\bullet+}$) solution was a 1:1 (v/v) solution of ABTS stock solution (7 mmol/L) and potassium persulfate (2.45 mmol/L). The mixture was kept in the dark (room temperature, more than 16 h) for no more than 2 d. The $ABTS^{\bullet+}$ solution was diluted with ethanol until the solution had an absorbance of 0.710 ± 0.050 at 734 nm. Each water extract (100 μL) was mixed with diluted $ABTS^{\bullet+}$

solution (3.8 mL) and allowed to react for 6 min; subsequently, the absorbance was recorded, and the results were presented as μmol Trolox equivalent per gram DW (μmol TE/g DW).

Determination of TPC and TFC

The TPC was determined in accordance with the Folin–Ciocalteu method[27]. Briefly, a properly diluted sample (0.5 mL) was mixed with Folin–Ciocalteu reagent (2.5 mL, 0.2 M). After 4 min, a saturated sodium carbonate solution (2 mL, 75 g/L) was added, and the mixture was kept at room temperature for 2 h. The absorbance at 760 nm was recorded. The results were presented as mg gallic acid equivalent per gram DW (mg GAE/g DW).

The TFC was determined by using a slightly modified version of a published aluminum chloride colorimetric method[28]. Specifically, ethanol (1.5 mL, 95%, v/v), aluminum chloride (0.1 mL, 10%, w/v), potassium acetate (0.1 mL, 1 mol/L), and water (2.8 mL) were added to the diluted sample (0.5 mL), and the mixture was kept at room temperature for 30 min. Absorbance was recorded at 415 nm. The results were expressed in terms of mg quercetin equivalent per gram DW (mg QE/g DW).

Statistical analysis

All data were expressed as the mean ± standard deviation. IBM SPSS Statistics 20.0 (SPSS Inc., Chicago, IL, United States) was used for statistical analysis. Analysis of variance and the least significant difference test were applied to examine the differences in means. Systematic cluster analysis with online analytical processing was also performed. For all tests, $P < 0.05$ and $P < 0.01$ were defined as two levels of statistical significance. The statistical methods of this study were reviewed by Chan-Juan Zhao from Department of Bio-statistics, School of Public Health, Hainan Medical University, Hainan Province, China.

RESULTS

Effects of tested foods and herbs on CCl_4-induced injury

Effects on serum biomarkers: Compared with the control group, significantly increased serum levels of ALT, AST, ALP, TBIL, and TG were observed in the model group (all $P < 0.01$), indicating that liver injury was successfully induced by CCl_4 (Figure 1). Bifendate is often used to lower the levels of serum transaminases in the treatment of hepatitis[21,29]. Compared with the model group, bifendate significantly decreased ALT, AST, ALP, and TG, and moderately reduced TBIL. As Figure 1A and 1B showed, each herb significantly decreased ALT and AST levels ($P < 0.05$ or $P < 0.01$). Notably, four herbs (*A. villosum*, *C. chinensis*, *P. lobata* root, and *S. officinalis*) were more effective in reducing both ALT and AST (each $P < 0.01$). Compared with the model group, each herb significantly reduced ALP, with the lowest values found after treatment with *P. lobata* root and *S. officinalis* (Figure 1C). Moreover, four herbs (*A. villosum*, *C. chinensis*, *P. lobata* root, and *S. officinalis*) exhibited better ALP-lowering effects than bifendate (each $P < 0.05$). Furthermore, *A. senticosus*, *A. villosum*, *A. kravanh*, *C. chinensis*, *P. lobata* flower, *P. lobata* root, and *S. officinalis* significantly decreased TBIL compared with the model group (Figure 1D). Specifically, better performance was found for *S. officinalis*, *P. lobata* root, and *A. villosum* (each $P < 0.01$). In addition, *A. capillaris*, *C. heracleifolia*, and *G. uralensis*, only slightly decreased TBIL. All herbs remarkably reduced TG compared with the model group ($P < 0.05$ or $P < 0.01$) (Figure 1E).

Effects of herbs on hepatic antioxidant enzymes, GSH, and lipid peroxidation in the liver: As shown in Figure 2, a significant decrease was observed in SOD and CAT activities and GSH level in the CCl_4 model group (each $P < 0.01$) as well as a significant increase in the MDA level ($P < 0.01$), indicating that oxidative liver injury had been successfully induced. Bifendate and all herbs restored SOD activity compared with the model group (each $P < 0.05$) (Figure 2A). In addition, each herb significantly increased CAT activity ($P < 0.05$ or $P < 0.01$), except for *A. senticosus* and *A. capillaris* (Figure 2B). Moreover, compared with the model group, significant increases in GSH were found in the *S. officinalis*, *P. lobata* root, *C. chinensis*, *G. uralensis*, *A. capillaris*, *C. heracleifolia*, and *A. villosum* groups and moderate elevations of GSH in the *A. kravanh*, *P. lobata* flower, and *A. senticosus* group (Figure 2C). Overall, *S. officinalis*, *P. lobata* root, and *C. chinensis* were more effective than the other herbs in restoring the hepatic antioxidant activity in CCl_4-induced liver injury. As shown in Figure 2D, only *S. officinalis*, *G.*

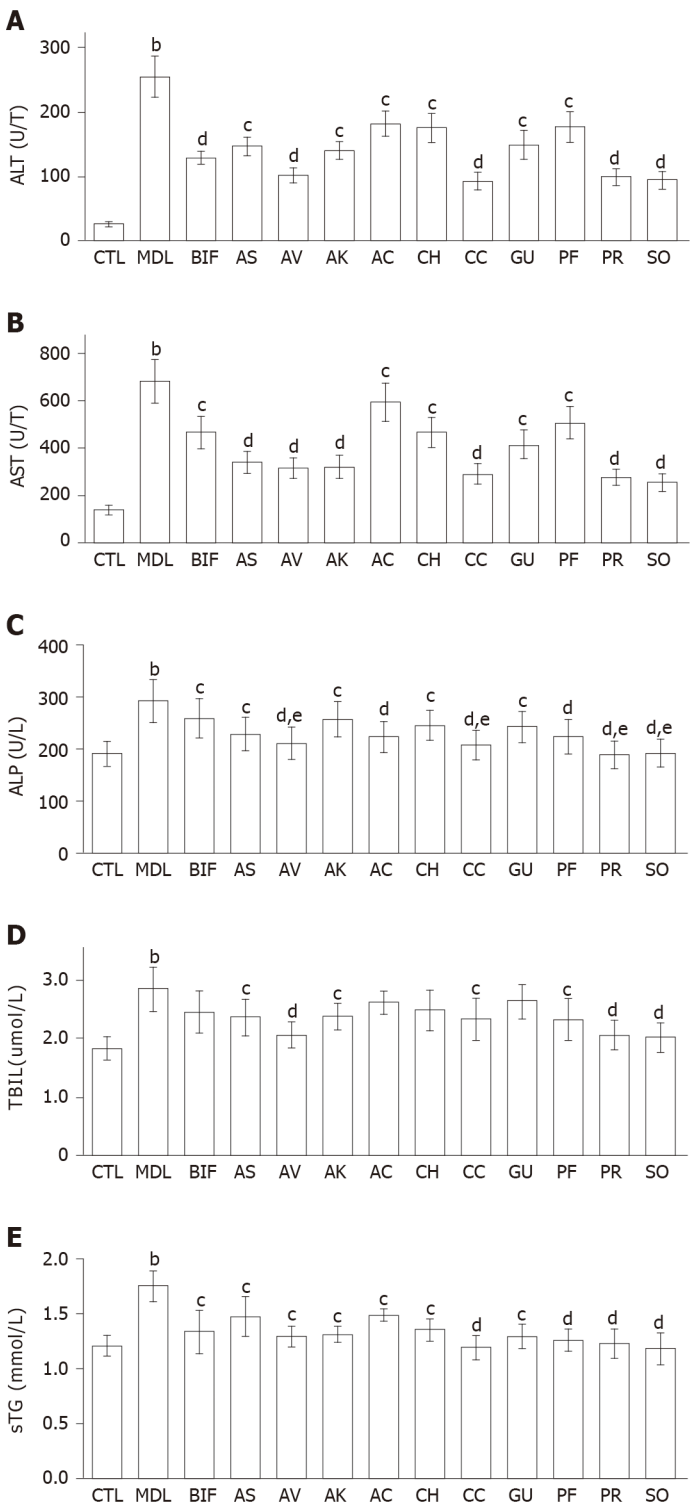

Figure 1 Effects of ten herbs on serum biomarkers (*n* = 8). A: Alanine transaminase ; B: Aspartate transaminase; C: Alkaline phosphatase; D: Total bilirubin; E: Triglyceride. The values are presented as the mean ± standard deviation. $^{a}P < 0.05$, $^{b}P < 0.01$ *vs* control; $^{c}P < 0.05$, $^{d}P < 0.01$ *vs* model; $^{e}P < 0.05$, $^{f}P < 0.01$ *vs* bifendate. ALT: Alanine transaminase; AST: Aspartate transaminase; ALP: Alkaline phosphatase; TBIL: Total bilirubin; TG: Triglyceride; CTL: Control; MDL: Model; BIF: Bifendate; AS: *Acanthopanax senticosus*; AV: *Amomum villosum*; AK: *Amomum kravanh*; AC: *Artemisia capillaris*; CH: *Cimicifuga heracleifolia*; CC: *Coptis chinensis*; GU: *Glycyrrhiza uralensis*; PF: *Pueraria lobata* flower; PR: *Pueraria lobata* root; SO: *Sanguisorba officinalis*.

uralensis, *P. lobata* root, *C. chinensis*, *P. lobata* flower, and *A. kravanh* ameliorated the increase in MDA. *S. officinalis*, *P. lobata* root, *C. chinensis* and *G. uralensis* showed better lipid peroxidation-reducing effects than the other herbs (each $P < 0.01$).

Histopathological analysis: No visible histological abnormalities were found in the control group (Figure 3A). The liver pathology of the CCl_4 model showed necrosis and

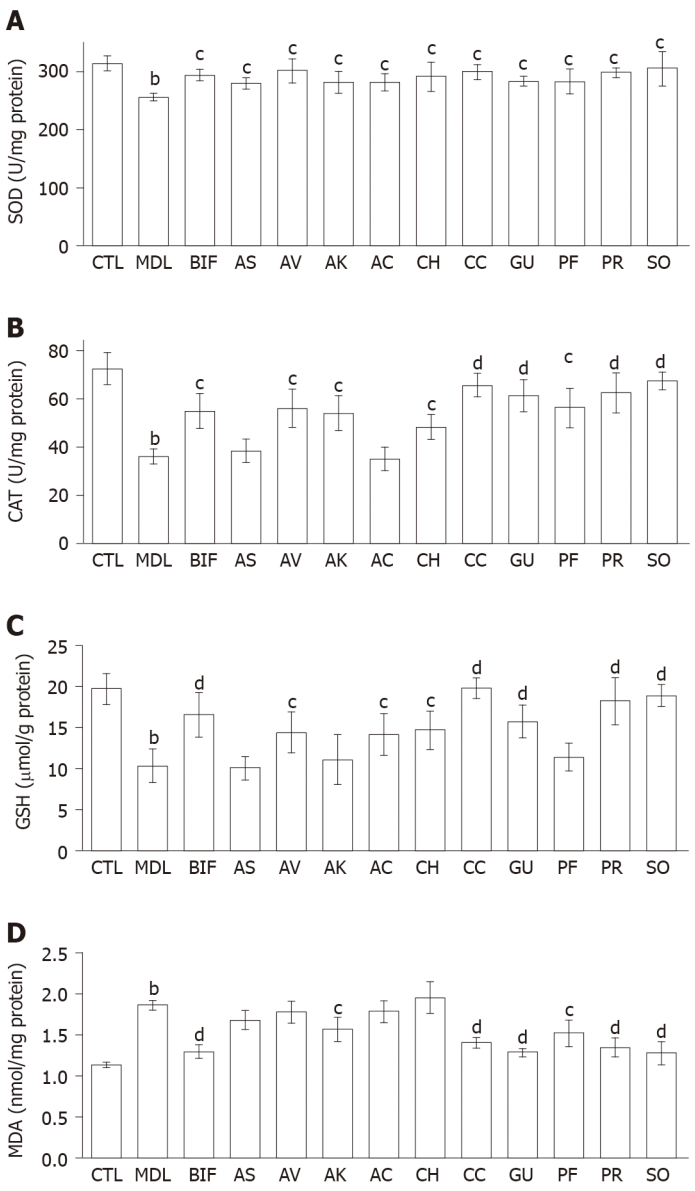

Figure 2 Effects of ten herbs on hepatic antioxidant enzymes, glutathione, and malondialdehyde (*n* = 8). A: Superoxide dismutase; B: Catalase; C: Glutathione; D: Malondialdehyde. The values are presented as the mean ± standard deviation. $^{a}P < 0.05$, $^{b}P < 0.01$ *vs* control; $^{c}P < 0.05$, $^{d}P < 0.01$ *vs* model; $^{e}P < 0.05$, $^{f}P < 0.01$ *vs* bifendate. SOD: Superoxide dismutase; CAT: Catalase; GSH: Glutathione; MDA: Malondialdehyde; CTL: Control; MDL: Model; BIF: Bifendate; AS: *Acanthopanax senticosus*; AV: *Amomum villosum*; AK: *Amomum kravanh*; AC: *Artemisia capillaris*; CH: *Cimicifuga heracleifolia*; CC: *Coptis chinensis*; GU: *Glycyrrhiza uralensis*; PF: *Pueraria lobata* flower; PR: *Pueraria lobata* root; SO: *Sanguisorba officinalis*.

ballooning degeneration in the perivenular zone as a result of severe cell injury, obvious massive inflammatory cells, and the accumulation of lipid droplets in hepatocytes (Figure 3B). These findings indicated the occurrence of CCl_4-induced liver injury. Meanwhile, bifendate and the ten tested materials ameliorated the morphological changes by mitigating necrosis, attenuating inflammatory cell infiltration, and resulting in lower lipid droplet accumulation, as shown below, for *C. chinensis*, *P. lobata* root, and *S. officinalis*, respectively (Figure 3D-F).

Antioxidant activities, TPC, and TFC of tested herbs

Antioxidant activities of herbs: The FRAP values of the ten medicinal foods and herbs ranged from 29.80 ± 0.29 to 1141.88 ± 81.16 μmol Fe^{2+}/g DW, and the TEAC values varied from 37.34 ± 1.02 to 1554.48 ± 68.58 μmol TE/g DW (Table 1). The three highest FRAP values (in decreasing order) were found in *S. officinalis* (1141.88 ± 81.16 μmol Fe^{2+}/g DW), *C. chinensis* (557.04 ± 4.73 μmol Fe^{2+}/g DW), and *P. lobata* root (554.38 ± 3.92 μmol Fe^{2+}/g DW). The lowest two were found in *G. uralensis* and *A. kravanh* (29.85 ± 2.10 and 29.80 ± 0.29 μmol Fe^{2+}/g DW, respectively). Meanwhile, the top three TEAC values were found in *S. officinalis* (1554.48 ± 68.58 μmol TE/g DW), *P. lobata* root

Table 1 Ferric-reducing antioxidant power, Trolox equivalent antioxidant capacity, total phenolic content, and total flavonoid content values of ten medicinal herbs (*n* = 8)

Scientific name of original medicinal plant	Parts with medicinal properties	FRAP value (μmol Fe^{2+}/g DW)	TEAC value (μmol TE/g DW)	TPC value (mg GAE/g DW)	TFC value (mg QE/g DW)
Acanthopanax senticosus (Rupr. et Maxim.) Harms	Root and rhizome	53.07 ± 0.23^{e}	54.70 ± 3.73^{d}	2.05 ± 0.16^{d}	0.44 ± 0.01^{e}
Amomum villosum Lour.	Fruit	219.85 ± 14.44^{c}	210.18 ± 23.88^{c}	18.42 ± 0.25^{c}	$1.98 \pm 0.07^{c,d}$
Amomum kravanh Pierre ex Gagnep.	Fruit	29.80 ± 0.29^{e}	37.34 ± 1.02^{d}	18.49 ± 0.70^{c}	0.32 ± 0.01^{e}
Artemisia capillaris Thunb.	Herb	146.71 ± 2.91^{d}	208.16 ± 1.42^{c}	19.06 ± 0.21^{c}	1.55 ± 0.11^{d}
Cimicifuga heracleifolia Kom.	Rhizome	$191.25 \pm 6.38^{c,d}$	214.60 ± 25.17^{c}	17.07 ± 0.28^{c}	0.40 ± 0.06^{e}
Coptis chinensis Franch.	Rhizome	557.04 ± 4.73^{b}	450.36 ± 27.23^{b}	50.15 ± 1.14^{b}	7.39 ± 0.39^{b}
Glycyrrhiza uralensis Fisch.	Root and rhizome	29.85 ± 2.10^{e}	53.09 ± 2.59^{d}	5.70 ± 0.04^{d}	3.71 ± 0.19^{c}
Pueraria lobata (Willd.) Ohwi	Flower	216.53 ± 11.34^{c}	213.25 ± 9.65^{c}	14.18 ± 0.11^{c}	2.86 ± 0.35^{c}
Pueraria lobata (Willd.) Ohwi	Root	554.38 ± 3.92^{b}	454.06 ± 8.14^{b}	45.06 ± 0.07^{b}	6.84 ± 0.08^{b}
Sanguisorba officinalis L.	Root	1141.88 ± 81.16^{a}	1554.48 ± 68.58^{a}	91.59 ± 0.00^{a}	14.93 ± 0.24^{a}

$^{a,b,c,d,e}P < 0.05$, different superscript letters indicate statistical significance. DW: dried weight; FRAP: ferric-reducing antioxidant power; GAE: gallic acid equivalent; QE: quercetin equivalent; TE: Trolox equivalent; TEAC: Trolox equivalent antioxidant capacity; TFC: total flavonoid content; TPC: total phenolic content.

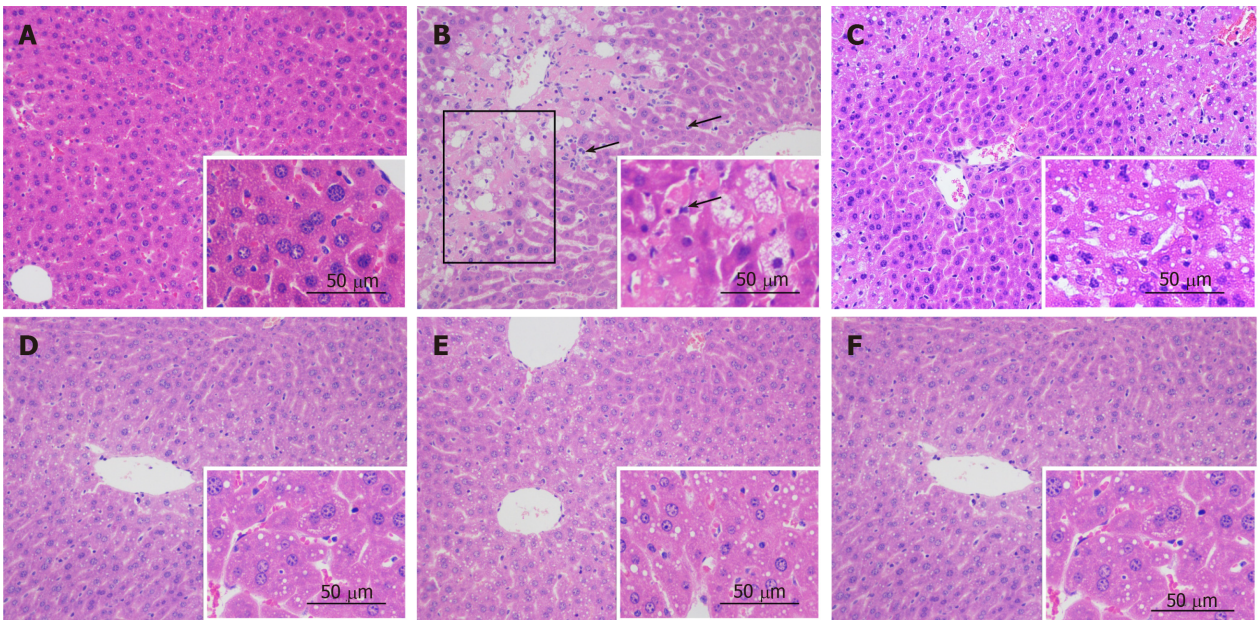

Figure 3 Histopathological findings showing the effects of ten tested materials on carbon tetrachloride-induced liver injury (200 × and 400 × magnification) (*n* = 8). A: Control; B: carbon tetrachloride (CCl_4) model; C: Bifendate + CCl_4; D: *Coptis chinensis* + CCl_4; E: *Pueraria lobata* root + CCl_4; F: *Sanguisorba officinalis* + CCl_4. Scale bar, 50 μm in 400×; Box, necrotic area; arrow, inflammatory cell. CCl_4: Carbon tetrachloride.

(454.06 ± 8.14 μmol TE/g DW), *C. chinensis* (450.36 ± 27.23 μmol TE/g DW), and the lowest two were also found in *G. uralensis* and *A. kravanh* (53.09 ± 2.59 and 37.34 ± 1.02 μmol TE/g DW, respectively).

TPC and TFC of herbs: The TPC and TFC of the ten materials were determined (Table 1). The TPC values ranged from 2.05 ± 0.16 to 91.59 ± 0.00 mg GAE/g DW, which was a difference of more than 40-fold. The three highest TPC values were found for *S. officinalis* (91.59 ± 0.00 mg GAE/g DW), *C. chinensis* (50.15 ± 1.14 mg GAE/g DW), and *P. lobata* root (45.06 ± 0.07 mg GAE/g DW). The lowest TPC values were found for *G. uralensis* and *A. senticosus*; both were below 10 mg GAE/g DW. The

highest three TFC values were found for *S. officinalis* (14.93 ± 0.24 mg QE/g DW), *C. chinensis* (7.39 ± 0.39 mg QE/g DW), and *P. lobata root* (6.84 ± 0.08 mg QE/g DW); in contrast, the lowest three TFC values were found in *A. senticosus*, *C. heracleifolia*, and *A. kravanh*, all of which were below 1 mg QE/g DW. Our results revealed that *S. officinalis* showed the strongest *in vitro* antioxidant activities, possibly because it contained the highest contents of phenols and flavonoids.

Correlations between FRAP, TEAC, TPC, and TFC values: Correlation analyses were performed to identify the strength of relationships between FRAP, TEAC, TPC, and TFC values (Table 2). A strong correlation between FRAP and TEAC (R^2 = 0.9340) indicated that the herbs possessed the ability to reduce Fe^{3+} to Fe^{2+} and to scavenge $ABTS^{\bullet+}$. In addition, the FRAP and TEAC values were both found to correlate with the TPC values (R^2 = 0.9600 for FRAP and TPC; R^2 = 0.9013 for TEAC and TPC), implying that the phenolic components contributed to the Fe^{3+}-reducing and $ABTS^{\bullet+}$-scavenging activities[30]. Moreover, a correlation between the TPC and TFC values (R^2 = 0.8829) suggested that flavonoids may be the major phenolic compounds but were not the only ones. Correlations were also found between FRAP/TEAC and TFC (R^2 = 0.9139 for FRAP and TFC; R^2 = 0.8729 for TEAC and TFC). In summary, the antioxidants in the tested medicinal herbs were able to both reduce oxidants (*e.g.*, Fe^{3+}) and scavenge free radicals (*e.g.*, $ABTS^{\bullet+}$), which was largely dependent on their TPC.

Relationship between *in vitro* antioxidant activity, effects on liver injury and *in vivo* antioxidant activity: To investigate the relationship between *in vivo* antioxidant activity of the tested herbs, their effects on liver injury, and *in vitro* antioxidant activity, systematic cluster analyses were performed (range of solutions, 2–6 cluster numbers) for clinical indicators of CCl_4-induced liver injury and the values of FRAP, TEAC, and TPC (Table 3 and Figure 4). Then, a cluster number of 3 was used for online analytical processing and analysis of variance. With the exception of seven herbs in Cluster 1, Cluster 2 included *P. lobata* root and *C. chinensis*, and Cluster 3 contained *S. officinalis*. Herbs in Clusters 2 and 3 (*P. lobata* root, *C. chinensis*, and *S. officinalis*) showed stronger hepatoprotective effects and *in vivo* antioxidant activity, and they exhibited stronger *in vitro* antioxidant activities, together with higher TPC and TFC.

Identification and quantification of phytochemical compounds in S. officinalis

As *S. officinalis* showed the strongest hepatoprotective effect against CCl_4-induced liver injury compared with the other tested medicinal foods and herbs, its phytochemical compounds in the decoction were identified by HPLC-ESI-ITMS/MS using external standards and/or according to MS and MS/MS information found in references[31-33]. As shown in Figure 5, eight main peaks were observed on the HPLC chromatogram; these corresponded to nine main compounds in the *S. officinalis* decoction (Table 4). The four major peaks (Peak 1-4) were identified as gallic acid (Peak 1), galloyl-methylglucoside, procyanidin C2 (Peak 2), (+)-catechin (Peak 3), and procyanidin B3 3-*O*-gallate (Peak 4)[33]. In addition, the quantification of unambiguously identified compounds was performed by HPLC using corresponding standards; *i.e.*, gallic acid (Peak 1) and (+)-catechin (Peak 3) were quantified as 7.86 ± 0.45 and 8.19 ± 0.57 mg/g DW, respectively.

DISCUSSION

AST and ALT are distributed predominantly in the liver cells. When the liver is damaged, they enter the bloodstream. Clinically, elevations in serum ALT and AST can be regarded as indicators of liver diseases, although ALT is more specific than AST[21]. In our study, all the herbs significantly decreased ALT and AST levels showing their hepatoprotection, with more effectiveness found for *A. villosum*, *C. chinensis*, *P. lobata* root, and *S. officinalis*. Clinically, increased ALP often indicates cholestasis caused by liver injury[34,35]. The ALP-lowering effects were also found for each herb. TBIL is also a sensitive indicator of bilirubin metabolic disorders, which are often increased in acute liver injury[36-38]. *A. senticosus*, *A. villosum*, *A. kravanh*, *C. chinensis*, *P. lobata* flower, *P. lobata* root, and *S. officinalis* significantly decreased TBIL compared with the model group, particularly *S. officinalis*, *P. lobata* root, and *A. villosum*. Serum TG is another biomarker of liver dysfunction and is found to be elevated if the liver is damaged. In this study, all herbs reduced TG significantly compared with the model group. Histopathological examinations confirmed the hepatoprotective effects of the ten tested medicinal foods and herbs by improving the degenerative morphological

Table 2 Correlation analysis between ferric-reducing antioxidant power, Trolox equivalent antioxidant capacity, total phenolic content, and total flavonoid content values

Correlation Coefficient (R^2)	FRAP value (μmol Fe^{2+}/g DW)	TEAC value (μmol TE/g DW)	TPC value (mg GAE/g DW)	TFC value (mg QE/g DW)
FRAP value	1	0.9340	0.9600	0.9139
TEAC value	-	1	0.9013	0.8729
TPC value	-	-	1	0.8829
TFC value	-	-	-	1

DW: Dried weight; FRAP: Ferric-reducing antioxidant power; GAE: Gallic acid equivalent; TE: Trolox equivalent; TEAC: Trolox equivalent antioxidant capacity; TFC: Total flavonoid content; TPC: Total phenolic content; QE: quercetin equivalent.

changes induced by CCl_4 (Figure 3).

Many chemicals can cause liver injury, and the mechanisms of action involved in CCl_4-induced liver disease have been investigated widely[4]. Briefly, CCl_4 is metabolized in the liver by cytochrome P450 enzymes, biotransformed into $\cdot CCl_3$, and then oxygenated to $\cdot OOCCl_3$; both of these radicals are highly reactive and can induce the depletion of reductants, inhibit antioxidant enzymes, induce lipid peroxidation, hypomethylate proteins, and mutate nucleic acids, resulting in oxidative stress, inflammation, apoptosis, and necrosis[23].

Whether oxidative injury occurs is dependent on the outcome of the interaction between oxidants and the protective system. In the body, there is a complex defense system consisting of antioxidant enzymes that can protect against oxidative damage, such as SOD, CAT, and glutathione peroxidase and some nonenzymatic antioxidants, including GSH, vitamins, and ubiquinone, that can also help to maintain the redox balance[39]. The metabolism of CCl_4 results in the accumulation of reactive oxygen species, mainly O^{2-} and H_2O_2, which can be scavenged by SOD and CAT, respectively[40]. The depletion of reduced endogenous antioxidants (such as GSH) can therefore increase the sensitivity of hepatocytes to oxidative stress[41]. Therefore, the activities of SOD and CAT as well as levels of GSH, are often used to evaluate *in vivo* antioxidant activity[30,42]. Free radicals are often highly reactive, and they can quickly bind to other molecules or atoms to form reactive metabolites, leading to lipid peroxidation, which results in elevated MDA[11]. Thus, MDA is often used to evaluate lipid peroxidation status[30,42].

Compared with the model group, all herbs restored SOD activity, and each herb significantly increased CAT activity, except for *A. senticosus* and *A. capillarys*. Significant increases in GSH were also found in the *S. officinalis*, *P. lobata* root, *C. chinensis*, *G. uralensis*, *A. capillaris*, *C. heracleifolia*, and *A. villosum* groups. Additionally, *S. officinalis*, *G. uralensis*, *P. lobata* root, *C. chinensis*, *P. lobata* flower, and *A. kravanh* ameliorated the increase in MDA. Overall, *S. officinalis*, *P. lobata* root, and *C. chinensis* were more effective than the other herbs in restoring the hepatic antioxidant activity and reducing lipid peroxidation in CCl_4-induced liver injury.

The chemical composition of most natural products is complex. Moreover, the antioxidant activities of medicinal herbs are often multifunctional and may be influenced by various factors; as such, more than one method is preferred to evaluate the antioxidant activity of natural products[43,44]. In this study, the antioxidant activities of selected medicinal herbs were determined by using the FRAP assay and the TEAC assay. The former indicates the antioxidant activity that is dependent on the capacity to reduce $[Fe(TPTZ)_2]^{3+}$ to $[Fe(TPTZ)_2]^{2+}$[25], whereas the latter is based on the ability to scavenge $ABTS^{\bullet+}$[24,44].

The FRAP and TEAC values of the ten medicinal foods and herbs ranged with a nearly 40-fold difference, both of which *S. officinalis* ranked first, and *C. chinensis* and *P. lobata* root were the second or the third. Similar results were found for TPC and TFC. Because bioactive components, especially phenols and flavonoids, are the main contributors to the antioxidant activities of natural products[17,45], our results revealed that *S. officinalis* showed the strongest *in vitro* antioxidant activities, which was possibly because it contained the highest contents of phenols and flavonoids. The correlations between FRAP, TEAC, TPC, and TFC values indicated that the antioxidants in the tested medicinal herbs possessed both oxidant-reducing and free radical-scavenging capability, mainly according to their TPC. Moreover, relationship between *in vitro* antioxidant activity, effects on liver injury, and *in vivo* antioxidant

Table 3 Online analytical processing cubes based on systematic cluster analysis for indicators of CCl_4-induced liver injury, antioxidant activity, total phenolic content, and total flavonoid content (cluster number = 3)

		ALT	AST	ALP	TBIL	sTG	SOD	CAT	GSH	MDA	FRAP	TEAC	TPC	TFC
Clt 1	**Sum**	1080.59	3017.02	1640.70	16.89	9.48	1997.54	349.62	91.24	11.58	887.06	991.32	94.97	11.26
AV	***n***	7	7	7	7	7	7	7	7	7	7	7	7	7
AS	**mean**	154.37	431.00	234.39	2.41	1.35	285.36	49.95	13.03	1.65	126.72	141.62	13.57	1.61
AK	**SD**	27.92	82.89	15.86	0.20	0.09	7.67	9.92	2.17	0.22	87.09	87.42	6.89	1.33
GU	**% of TS**	78.9%	78.6%	73.5%	72.5%	72.0%	68.9%	64.1%	61.6%	74.2%	28.2%	28.7%	33.7%	27.9%
AC	**% of TN**	70.0%	70.0%	70.0%	70.0%	70.0%	70.0%	70.0%	70.0%	70.0%	70.0%	70.0%	70.0%	70.0%
CH														
PF														
Clt 2	**Sum**	193.77	567.29	398.53	4.39	2.46	595.96	128.15	37.99	2.74	1111.42	904.42	95.21	14.23
CC	***n***	2	2	2	2	2	2	2	2	2	2	2	2	2
PR	**mean**	96.89	283.65	199.27	2.20	1.23	297.98	64.08	19.00	1.37	555.71	452.21	47.61	7.12
	SD	4.79	9.30	13.09	0.19	0.06	1.27	2.10	1.10	0.04	1.88	2.62	3.60	0.39
	% of TS	14.1%	14.8%	17.9%	18.8%	18.7%	20.6%	23.5%	25.7%	17.6%	35.4%	26.2%	33.8%	35.2%
	% of TN	20.0%	20.0%	20.0%	20.0%	20.0%	20.0%	20.0%	20.0%	20.0%	20.0%	20.0%	20.0%	20.0%
Clt 3	**Sum**	95.34	256.05	192.78	2.03	1.23	304.69	67.44	18.85	1.28	1141.88	1554.48	91.59	14.93
SO	***n***	1	1	1	1	1	1	1	1	1	1	1	1	1
	mean	95.34	256.05	192.78	2.03	1.23	304.69	67.44	18.85	1.28	1141.88	1554.48	91.59	14.93
	SD	/	/	/	/	/	/	/	/	/	/	/	/	/
	% of TS	7.0%	6.7%	8.6%	8.7%	9.3%	10.5%	12.4%	12.7%	8.2%	36.4%	45.1%	32.5%	36.9%
	% of TN	10.0%	10.0%	10.0%	10.0%	10.0%	10.0%	10.0%	10.0%	10.0%	10.0%	10.0%	10.0%	10.0%
Total	**Sum**	1369.70	3840.36	2232.01	23.31	13.17	2898.19	545.21	148.08	15.60	3140.36	3450.22	281.77	40.42
	n	10	10	10	10	10	10	10	10	10	10	10	10	10
	mean	136.97	384.04	223.20	2.33	1.32	289.82	54.52	14.81	1.56	314.04	345.02	28.18	4.04
	SD	36.16	101.81	22.67	0.22	0.10	9.71	11.01	3.38	0.23	348.53	449.84	27.02	4.59
	% of TS	100.0%	100.0%	100.0%	100.0%	100.0%	100.0%	100.0%	100.0%	100.0%	100.0%	100.0%	100.0%	100.0%

% of TN	100.0%	100.0%	100.0%	100.0%	100.0%	100.0%	100.0%	100.0%	100.0%	100.0%	100.0%	100.0%	100.0%

ALT: Alanine transaminase; AST: Aspartate transaminase; ALP: Alkaline phosphatase; TBIL: Total bilirubin; sTG: Serum triglycerides; SOD: Superoxide dismutase; CAT: Catalase; GSH: Glutathione; MDA: Malondialdehyde; FRAP: Ferric-reducing antioxidant power; TEAC: Trolox equivalent antioxidant capacity; TPC: Total phenolic content; TFC: Total flavonoid content; Clt: Cluster; SD: Standard deviation; TN: Total number; TS: Total sum; AS: *Acanthopanax senticosus*; AV: *Amomum villosum*; AK: *Amomum kravanh*; AC: *Artemisia capillaris*; CH: *Cimicifuga heracleifolia*; CC: *Coptis chinensis*; GU: *Glycyrrhiza uralensis*; PF: *Pueraria lobata* flower; PR: *Pueraria lobata* root; SO: *Sanguisorba officinalis*.

activity revealed that *P. lobata* root, *C. chinensis*, and *S. officinalis* performed better hepatoprotection with *in vivo* antioxidant activity; meanwhile, they also showed stronger *in vitro* antioxidant activities containing higher TPC and TFC.

As *S. officinalis* showed the best performance in protecting the liver from CCl_4-induced injury among the tested herbs, the identification and quantification of phytochemical compounds in its decoction was conducted. Nine main compounds were identified, and (+)-catechin and gallic acid were also quantified. According to the Chinese Pharmacopeia, the gallic acid content was a crucial criterion to evaluate the quality of *S. officinalis*, and it should be no less than 0.60%[46]. The gallic acid content quantified in our study was in this desirable range. The phytochemical compounds identified in our study, such as gallic acid and catechin, have been regarded as strong antioxidants that can confer health benefits and may contribute to the hepatoprotective activity[47-49].

S. officinalis has a cucumber-like flavor, and many parts are edible. For example, the young leaves and flower buds are often used in salads, the fresh or dried leaves are used to make tea, and the root can be cooked as a constituent in porridge or soups. It is an alpine plant that grows at high elevation and is adapted to harsh conditions, such as low temperatures, strong ultraviolet radiation, and dryness, which result in the altitude-dependent accumulation of antioxidants[50]. The phytochemical compounds identified in our study, such as gallic acid and catechin, have been regarded as strong antioxidants that can provide health benefits and may contribute to the hepatoprotective actions and *in vitro* antioxidant activities[47-49].

CONCLUSION

In conclusion, the results of our study indicated that all ten medicinal foods and herbs could individually protect against CCl_4-induced oxidative liver injury, and *S. officinalis* L., *C. chinensis* Franch., and *P. lobata* (Willd.) Ohwi root were more effective than the others. In addition, *S. officinalis* L. exhibited the strongest hepatoprotective effect, and nine components of its decoction were identified, among which gallic acid and (+)-catechin were quantified. It was also revealed that the tested materials exhibited various *in vitro* antioxidant activities, proportionate to their phenolic content and that the highest values were found in *S. officinalis* L. The results of this study are valuable for the selection of more effective natural products to be consumed directly or

Table 4 Identification of the main phytochemical components in *Sanguisorba officinalis* decoction using high-performance liquid chromatography-electrospray ionization source-ion trap tandem mass spectrometry (positive or negative mode)

Peak	RT (min)	λ_{max} (nm)	$[M+H]^+$	$[M-H]^-$	MS/MS fragments	MW	Putative compound	Ref.
1	7.10	270	/	169	125	170	Gallic acid[1]	[33]
2	10.52	275	/	345; 865	313, 169, 151, 125; 739, 695, 577, 543, 407, 287	346; 866	Galloyl-methylglucoside; Procyanidin C2	[33]
3	16.10	278	291	/	273, 165, 151, 139, 123	290	(+)-Catechin[1]	[33]
4	20.87	275	/	729	577, 559, 407	730	Procyanidin B3 3-*O*-gallate	[33]
5	22.35	274	563	/	545, 423, 411, 435, 393, 271	562	Fisetinidol-(4α/β→8)-(+)-catechin	[33]
6	23.65	272	/	1103	1059, 935, 633, 469	1104	Sanguiin H-2	[31]
7	54.30	264/362	/	277	197, 182, 111	278	Methoxygallic acid methyl ester 5-*O*-sulfate	[32]
8	68.30	243/372	345	/	330, 313	344	3,3′,4′-*O*-trimethylellagic acid	[33]

[1]Identification of phytochemical compounds by high-performance liquid chromatography, mass spectrometry (MS), and MS/MS using commercial standards or based on published values[31-33]. RT: Retention time; λmax: Maximum absorbance wavelength; MS: Mass spectrometry; MW: Molecular weight.

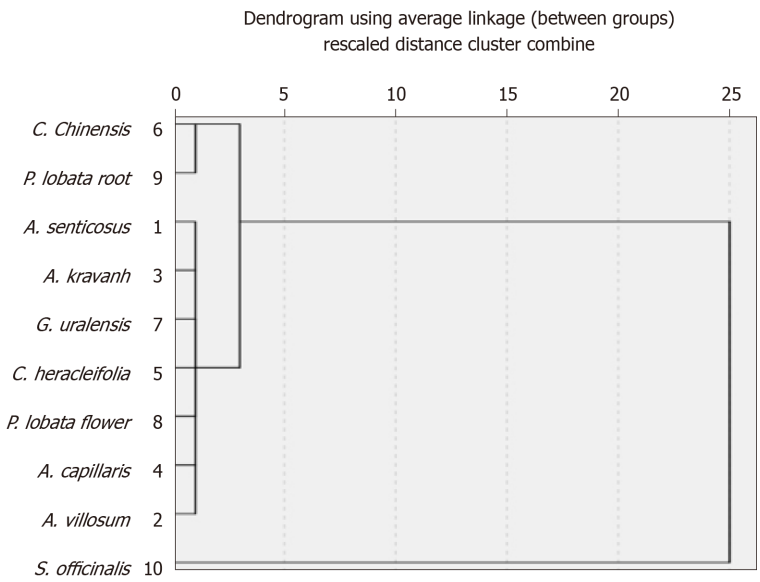

Figure 4 Dendrogram using average linkage (between groups) from systematic cluster analysis of ten medicinal herbs.

developed into nutraceuticals or therapeutics for the prevention and treatment of oxidative stress-related diseases.

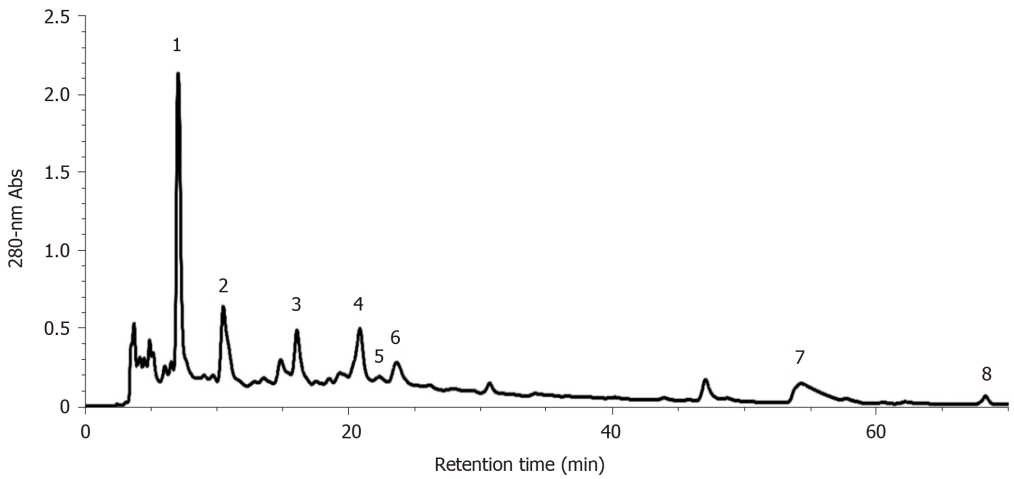

Figure 5 Reverse-phase high-performance liquid chromatography analysis of *Sanguisorba officinalis* decoction.

ARTICLE HIGHLIGHTS

Research background

Many natural products confer health benefits against diverse diseases through their antioxidant activities. Carbon tetrachloride (CCl_4) is often used in animal experiments to study the effects of substances on liver injury and the related mechanisms of action, among which oxidative stress is a major pathogenic factor.

Research motivation

The antioxidant activities of ten herbs were evaluated both *in vitro* and *in vivo*. Their hepatoprotective effects were also evaluated in order to elect more effective natural products for direct consumption and the development of nutraceuticals or therapeutics to manage oxidative stress-related diseases.

Research objectives

To compare antioxidant and hepatoprotective activities of ten herbs and identify and quantify phytochemicals for the one with strongest hepatoprotection, which could be helpful in the prevention and treatment of oxidative liver injury.

Research methods

The antioxidant activity of ten medicinal herbs was determined by both ferric-reducing antioxidant power and Trolox equivalent antioxidant capacity assays. The total phenolic and flavonoid contents were determined by Folin–Ciocalteu method and aluminum chloride colorimetry, respectively. Their effects on CCl_4-induced oxidative liver injury were evaluated and compared in a mouse model by administrating each water extract [(0.15 g/mL, 10 mL/kg) once per day] for seven consecutive days and a dose of CCl_4 solution in olive oil (8%, v/v, 10 mL/kg). The herb with the strongest hepatoprotective performance was analyzed for the detailed bioactive components by using high-performance liquid chromatography-electrospray ionization source-ion trap tandem mass spectrometry.

Research results

The results revealed that all tested herbs attenuated CCl_4-induced oxidative liver injury; each resulted in significant decreases in levels of serum alanine transaminase, aspartate transaminase, alkaline phosphatase, and triacylglycerols. In addition, most herbs restored hepatic superoxide dismutase and catalase activities, glutathione levels, and reduced malondialdehyde levels. *Sanguisorba officinalis* (*S. officinalis*) L., *Coptis chinensis* Franch., and *Pueraria lobata* (Willd.) Ohwi root were the three most effective herbs, and *S. officinalis* L. exhibited the strongest hepatoprotective effect. Nine active components were identified in *S. officinalis*, and gallic acid and (+)-catechin were quantified (7.86 ± 0.45 mg/g and 8.19 ± 0.57 mg/g dried weight, respectively). Furthermore, the tested herbs displayed a range of *in vitro* antioxidant activities proportional to their phenolic content; the strongest activities were also found for *S. officinalis* L.

Research conclusions

The results of this study indicated that all ten medicinal foods and herbs could individually protect against CCl_4-induced oxidative liver injury, and *S. officinalis* L., *C. chinensis* Franch., and *P. lobata* (Willd.) Ohwi root were more effective than the others. In addition, *S. officinalis* L. exhibited the strongest hepatoprotective effect, and nine components of its decoction were identified, among which gallic acid and (+)-catechin were quantified. It was also revealed that the tested materials exhibited various *in vitro* antioxidant activities proportionate to their phenolic content, and that the highest values were found in *S. officinalis* L. The results are valuable for the selection of more effective natural products to be consumed directly or developed into nutraceuticals or therapeutics for the prevention and treatment of oxidative stress-related diseases.

Research perspectives

This study is of value to assist the selection of more effective natural products for direct consumption and the development of nutraceuticals or therapeutics to manage oxidative stress-related diseases. In the future, methods to identify and quantify the phytochemical compounds in medicinal herbs must be investigated more comprehensively. The bioavailability, desirable dose range, and side effects should also be clarified.

ACKNOWLEDGEMENTS

The authors would like to acknowledge Ms Ping-Ping Wu for her assistance in raising animals.

REFERENCES

1 **Bardaweel SK**, Gul M, Alzweiri M, Ishaqat A, ALSalamat HA, Bashatwah RM. Reactive Oxygen Species: the Dual Role in Physiological and Pathological Conditions of the Human Body. *Eurasian J Med* 2018; **50**: 193-201 [PMID: 30515042 DOI: 10.5152/eurasianjmed.2018.17397]

2 **Dröge W**. Free radicals in the physiological control of cell function. *Physiol Rev* 2002; **82**: 47-95 [PMID: 11773609 DOI: 10.1152/physrev.00018.2001]

3 **Lichtenberg D**, Pinchuk I. Oxidative stress, the term and the concept. *Biochem Biophys Res Commun* 2015; **461**: 441-444 [PMID: 25911322 DOI: 10.1016/j.bbrc.2015.04.062]

4 **Meng X**, Li Y, Li S, Gan RY, Li HB. Natural products for prevention and treatment of chemical-induced liver injuries. *Compr Rev Food Sci Food Saf* 2018; **17**: 472-495 [DOI: 10.1111/1541-4337.12335]

5 **Ke Y**, Xu C, Lin J, Li Y. Role of Hepatokines in Non-alcoholic Fatty Liver Disease. *J Transl Int Med* 2019; **7**: 143-148 [PMID: 32010600 DOI: 10.2478/jtim-2019-0029]

6 **Li C**, Qu L, Farragher C, Vella A, Zhou B. MicroRNA Regulated Macrophage Activation in Obesity. *J Transl Int Med* 2019; **7**: 46-52 [PMID: 31380236 DOI: 10.2478/jtim-2019-0011]

7 **Ahn M**, Park JS, Chae S, Kim S, Moon C, Hyun JW, Shin T. Hepatoprotective effects of Lycium chinense Miller fruit and its constituent betaine in CCl4-induced hepatic damage in rats. *Acta Histochem* 2014; **116**: 1104-1112 [PMID: 24998029 DOI: 10.1016/j.acthis.2014.05.004]

8 **Peng WH**, Chen YW, Lee MS, Chang WT, Tsai JC, Lin YC, Lin MK. Hepatoprotective Effect of Cuscuta campestris Yunck. Whole Plant on Carbon Tetrachloride Induced Chronic Liver Injury in Mice. *Int J Mol Sci* 2016; **17** [PMID: 27941627 DOI: 10.3390/ijms17122056]

9 **Slater TF**, Cheeseman KH, Ingold KU. Carbon tetrachloride toxicity as a model for studying free-radical mediated liver injury. *Philos Trans R Soc Lond B Biol Sci* 1985; **311**: 633-645 [PMID: 2869522 DOI: 10.1098/rstb.1985.0169]

10 **Clawson GA**. Mechanisms of carbon tetrachloride hepatotoxicity. *Pathol Immunopathol Res* 1989; **8**: 104-112 [PMID: 2662164 DOI: 10.1159/000157141]

11 **Louvet A**, Mathurin P. Alcoholic liver disease: mechanisms of injury and targeted treatment. *Nat Rev Gastroenterol Hepatol* 2015; **12**: 231-242 [PMID: 25782093 DOI: 10.1038/nrgastro.2015.35]

12 **Cao SY**, Li Y, Meng X, Zhao CN, Li S, Gan RY, Li HB. Dietary natural products and lung cancer: Effects and mechanisms of action. *J Funct Foods* 2019; **52**: 316-331 [DOI: 10.1016/j.jff.2018.11.004]

13 **Tang GY**, Meng X, Li Y, Zhao CN, Liu Q, Li HB. Effects of Vegetables on Cardiovascular Diseases and Related Mechanisms. *Nutrients* 2017; **9** [PMID: 28796173 DOI: 10.3390/nu9080857]

14 **Ding RB**, Tian K, Huang LL, He CW, Jiang Y, Wang YT, Wan JB. Herbal medicines for the prevention of alcoholic liver disease: a review. *J Ethnopharmacol* 2012; **144**: 457-465 [PMID: 23058988 DOI: 10.1016/j.jep.2012.09.044]

15 **Song G**, Zhang C. Statistical analysis of the drugs used in the ancient anti-alcohol prescriptions. *Shizhen Guoyi Guoyao* 2009; **20**: 216-217

16 **Huang GJ**, Deng JS, Huang SS, Shao YY, Chen CC, Kuo YH. Protective effect of antrosterol from Antrodia camphorata submerged whole broth against carbon tetrachloride-induced acute liver injury in mice. *Food Chem* 2012; **132**: 709-716 [DOI: 10.1016/j.foodchem.2011.11.004]

17 **Fu L**, Xu BT, Xu XR, Gan RY, Zhang Y, Xia EQ, Li HB. Antioxidant capacities and total phenolic contents of 62 fruits. *Food Chem* 2011; **129**: 345-350 [PMID: 30634236 DOI: 10.1016/j.foodchem.2011.04.079]

18 **USFDA**. Guidance for Industry: Estimating the maximum safe starting dose in initial clinical trials for therapeutics in adult healthy volunteers. 2005. [Accessed on 2 Jan 2020] . Available from: URL: https://www.fda.gov/media/72309/download

19 **China National Administration of Traditional Chinese Medicine**. Hovenia dulcis seeds. 2015. [Accessed on 2 April 2020]. Available from: https://baike.baidu.com/item/%E6%9E%B3%E6%A4%87%E5%AD%90/758262?fr=aladdin

20 **Walpole SC**, Prieto-Merino D, Edwards P, Cleland J, Stevens G, Roberts I. The weight of nations: an estimation of adult human biomass. *BMC Public Health* 2012; **12**: 439 [PMID: 22709383 DOI: 10.1186/1471-2458-12-439]

21 **Wu SK**, Zhang N, Shen XR, Mei WW, He Y, Ge WH. Preparation of total flavonoids from loquat flower and its protective effect on acute alcohol-induced liver injury in mice. *J Food Drug Anal* 2015; **23**: 136-143 [PMID: 28911437 DOI: 10.1016/j.jfda.2014.07.001]

22 **Borkham-Kamphorst E**, van de Leur E, Zimmermann HW, Karlmark KR, Tihaa L, Haas U, Tacke F, Berger T, Mak TW, Weiskirchen R. Protective effects of lipocalin-2 (LCN2) in acute liver injury suggest a novel function in liver homeostasis. *Biochim Biophys Acta* 2013; **1832**: 660-673 [PMID: 23376114 DOI: 10.1016/j.bbadis.2013.01.014]

23 **Scholten D**, Trebicka J, Liedtke C, Weiskirchen R. The carbon tetrachloride model in mice. *Lab Anim* 2015; **49**: 4-11 [PMID: 25835733 DOI: 10.1177/0023677215571192]

24 **Xu XY**, Zheng J, Meng JM, Gan RY, Mao QQ, Shang A, Li BY, Wei XL, Li HB. Effects of Food Processing on In Vivo Antioxidant and Hepatoprotective Properties of Green Tea Extracts. *Antioxidants (Basel)* 2019; **8** [PMID: 31766414 DOI: 10.3390/antiox8120572]

25 **Benzie IF**, Strain JJ. The ferric reducing ability of plasma (FRAP) as a measure of "antioxidant power": the FRAP assay. *Anal Biochem* 1996; **239**: 70-76 [PMID: 8660627 DOI: 10.1006/abio.1996.0292]

26 **Re R**, Pellegrini N, Proteggente A, Pannala A, Yang M, Rice-Evans C. Antioxidant activity applying an improved ABTS radical cation decolorization assay. *Free Radic Biol Med* 1999; **26**: 1231-1237 [PMID: 10381194 DOI: 10.1016/s0891-5849(98)00315-3]

27 **Lopez-Froilan R**, Hernandez-Ledesma B, Camara M, Perez-Rodriguez ML. Evaluation of the antioxidant potential of mixed fruit-based beverages: A new insight on the Folin-Ciocalteu method. *Food Anal Meth* 2018; **11**: 2897-2906 [DOI: 10.1007/s12161-018-1259-1]

28 **Kalia K**, Sharma K, Singh HP, Singh B. Effects of extraction methods on phenolic contents and antioxidant activity in aerial parts of Potentilla atrosanguinea Lodd. and quantification of its phenolic constituents by RP-HPLC. *J Agric Food Chem* 2008; **56**: 10129-10134 [PMID: 18841977 DOI: 10.1021/jf802188b]

29 **Zeng Y**, He YJ, He FY, Fan L, Zhou HH. Effect of bifendate on the pharmacokinetics of cyclosporine in relation to the CYP3A4*18B genotype in healthy subjects. *Acta Pharmacol Sin* 2009; **30**: 478-484 [PMID: 19343062 DOI: 10.1038/aps.2009.27]

30 **Liu Q**, Tang GY, Zhao CN, Gan RY, Li HB. Antioxidant Activities, Phenolic Profiles, and Organic Acid Contents of Fruit Vinegars. *Antioxidants (Basel)* 2019; **8** [PMID: 30934715 DOI: 10.3390/antiox8040078]

31 **Kool MM**, Comeskey DJ, Cooney JM, McGhie TK. Structural identification of the main ellagitannins of a boysenberry (Rubus loganbaccus×baileyanus Britt.) extract by LC–ESI-MS/MS, MALDI-TOF-MS and NMR spectroscopy. *Food Chem* 2010; **119**: 1535-1543 [DOI: 10.1016/j.foodchem.2009.09.039]

32 **Li KP**, Gao CK, Li WM. Analysis of vitexin and isorhamnetin-3-O-β-D-rutinoside by UPLC-ESI-Q-TOF-MS-MS. *Zhongguo Zhongyao Zazhi* 2011; **36**: 180-184

33 **Xu WT**, Huo ZP, Lei L, Shi JW, Wang Y, He Y. Chemical constituent cluster of decoction of Sanguisorbae Radix by HPLC-IT-TOF/MS. *Zhongcaoyao* 2018; **49**: 1277-1288

34 **Mauro P**, Renze B, Wouter W. Enzymes. In: Burtis CA, Ashwood ER, Bruns DE, editors. Tietz text book of clinical chemistry and molecular diagnostics. 6th ed. St Louis, Missouri, USA: Elsevier, 2006: 604-616

35 **Djiambou-Nganjeu H**. Relationship Between Portal HTN and Cirrhosis as a Cause for Diabetes. *J Transl Int Med* 2019; **7**: 79-83 [PMID: 31380241 DOI: 10.2478/jtim-2019-0009]

36 **Koca TT**. Clinical Significance of Serum Bilirubin in Behçet's Disease. *J Transl Int Med* 2018; **6**: 185-188 [PMID: 30637206 DOI: 10.2478/jtim-2018-0034]

37 **Xu X**, Bai Z, Zhao Q, Li H, Shi Q, Deng J, Zhang J, Guo X, Qi X. Successful Pharmacotherapy for Multiple Acute Decompensation Events in a Cirrhotic Patient with Acute-on-chronic Liver Failure: A Case Report. *J Transl Int Med* 2018; **6**: 189-193 [PMID: 30637207 DOI: 10.2478/jtim-2018-0035]

38 **Pratt D**. Sleisenger and Fordtran´s Gastrointestinal and Liver Disease: Pathophysiology/Diagnosis/Management. 10th ed. Philadelphia, USA: Elsevier Saunders, 2016

39 **Grasselli E**, Compalati AD, Voci A, Vecchione G, Ragazzoni M, Gallo G, Borro P, Sumberaz A, Testino G, Vergani L. Altered oxidative stress/antioxidant status in blood of alcoholic subjects is associated with alcoholic liver disease. *Drug Alcohol Depend* 2014; **143**: 112-119 [PMID: 25107314 DOI: 10.1016/j.drugalcdep.2014.07.013]

40 **Cederbaum AI**. Cytochrome P450 2E1-dependent oxidant stress and upregulation of anti-oxidant defense in liver cells. *J Gastroenterol Hepatol* 2006; **21** Suppl 3: S22-S25 [PMID: 16958665 DOI: 10.1111/j.1440-1746.2006.04595.x]

41 **Hirano T**, Kaplowitz N, Tsukamoto H, Kamimura S, Fernandez-Checa JC. Hepatic mitochondrial glutathione depletion and progression of experimental alcoholic liver disease in rats. *Hepatology* 1992; **16**: 1423-1427 [PMID: 1446896 DOI: 10.1002/hep.1840160619]

42 **Zhao CN**, Tang GY, Liu Q, Xu XY, Cao SY, Gan RY, Zhang KY, Meng SL, Li HB. Five-Golden-Flowers Tea: Green Extraction and Hepatoprotective Effect against Oxidative Damage. *Molecules* 2018; **23** [PMID: 30200362 DOI: 10.3390/molecules23092216]

43 **Huang D**, Ou B, Prior RL. The chemistry behind antioxidant capacity assays. *J Agric Food Chem* 2005; **53**: 1841-1856 [PMID: 15769103 DOI: 10.1021/jf030723c]

44 **Alam MN**, Bristi NJ, Rafiquzzaman M. Review on *in vivo* and *in vitro* methods evaluation of antioxidant activity. *Saudi Pharm J* 2013; **21**: 143-152 [PMID: 24936134 DOI: 10.1016/j.jsps.2012.05.002]

45 **Wang H**, Liu YM, Qi ZM, Wang SY, Liu SX, Li X, Wang HJ, Xia XC. An overview on natural polysaccharides with antioxidant properties. *Curr Med Chem* 2013; **20**: 2899-2913 [PMID: 23627941 DOI: 10.2174/0929867311320230006]

46 **Chinese Pharmacopoecia Commission**. Sanguisorbae Radix. *Zhongguo Yaodian* 2015; 126-127
47 **Wang J**, Tang L, White J, Fang J. Inhibitory effect of gallic acid on CCl4-mediated liver fibrosis in mice. *Cell Biochem Biophys* 2014; **69**: 21-26 [PMID: 24096707 DOI: 10.1007/s12013-013-9761-y]
48 **Quan M**, Li Q, Zhao P, Tian C. Chemical composition and hepatoprotective effect of free phenolic extract from barley during malting process. *Sci Rep* 2018; **8**: 4460 [PMID: 29535394 DOI: 10.1038/s41598-018-22808-6]
49 **Liu J**, Lu JF, Wen XY, Kan J, Jin CH. Antioxidant and protective effect of inulin and catechin grafted inulin against CCl4-induced liver injury. *Int J Biol Macromol* 2015; **72**: 1479-1484 [PMID: 25316429 DOI: 10.1016/j.ijbiomac.2014.09.066]
50 **Wildi B**, Lutz C. Antioxidant composition of selected high alpine plant species from different altitudes. *Plant Cell Environ* 1996; **19**: 138-146 [DOI: 10.1111/j.1365-3040.1996.tb00235.x]

World Journal of Gastroenterology

Submit a Manuscript: https://www.f6publishing.com

World J Gastroenterol 2020 October 7; 26(37): 5646-5660

DOI: 10.3748/wjg.v26.i37.5646

ISSN 1007-9327 (print) ISSN 2219-2840 (online)

ORIGINAL ARTICLE

Case Control Study

Short- and long-term outcomes associated with enhanced recovery after surgery protocol *vs* conventional management in patients undergoing laparoscopic gastrectomy

Yu-Long Tian, Shou-Gen Cao, Xiao-Dong Liu, Ze-Qun Li, Gan Liu, Xing-Qi Zhang, Yu-Qi Sun, Xin Zhou, Dao-Sheng Wang, Yan-Bing Zhou

ORCID number: Yu-Long Tian 0000-0002-7284-4128; Shou-Gen Cao 0000-0002-0858-8940; Xiao-Dong Liu 0000-0001-7509-6383; Ze-Qun Li 0000-0001-6048-0534; Gan Liu 0000-0002-4931-8680; Xing-Qi Zhang 000-0003-4981-9933; Yu-Qi Sun 0000-0003-4334-2564; Xin Zhou 0000-0001-6652-8041; Dao-Sheng Wang 0000-0003-4923-1937; Yan-Bing Zhou 0000-0001-9393-9743.

Author contributions: Zhou YZ and Tian YL conceived and designed the study; Tian YL, Cao SG, Liu XD, and Li ZQ drafted the manuscript; Sun YQ, Zhou X, and Wang DS completed data management and statistical analysis; all authors have agreed to be responsible for all aspects of the work.

Institutional review board statement: The study was reviewed and approved by the Affiliated Hospital of Qingdao University Ethics Review Committee.

Informed consent statement: All study participants, or their legal guardian, provided informed written consent prior to study enrollment.

Yu-Long Tian, Shou-Gen Cao, Xiao-Dong Liu, Ze-Qun Li, Gan Liu, Xing-Qi Zhang, Yu-Qi Sun, Xin Zhou, Dao-Sheng Wang, Yan-Bing Zhou, Department of Gastrointestinal Surgery, Affiliated Hospital of Qingdao University, Qingdao 266003, Shandong Province, China

Corresponding author: Yan-Bing Zhou, MD, Professor, Department of Gastrointestinal Surgery, Affiliated Hospital of Qingdao University, No. 16 Jiangsu Road, Shinan District, Qingdao 266003, Shandong Province, China. zhou_yb2008@126.com

Abstract

BACKGROUND

At present, the enhanced recovery after surgery (ERAS) protocol is widely implemented in the field of gastric surgery. However, the effect of the ERAS protocol on the long-term prognosis of gastric cancer has not been reported.

AIM

To compare the effects of ERAS and conventional protocols on short-term outcomes and long-term prognosis after laparoscopic gastrectomy.

METHODS

We retrospectively analyzed the data of 1026 consecutive patients who underwent laparoscopic gastrectomy between 2012 and 2015. The patients were divided into either an ERAS group or a conventional group. The groups were matched in a 1:1 ratio using propensity scores based on covariates that affect cancer survival. The primary outcomes were the 5-year overall and cancer-specific survival rates. The secondary outcomes were the postoperative short-term outcomes and inflammatory indexes.

RESULTS

The patient demographics and baseline characteristics were similar between the two groups after matching. Compared to the conventional group, the ERAS group had a significantly shorter postoperative hospital day (7.09 d *vs* 8.67 d, $P < 0.001$), shorter time to first flatus, liquid intake, and ambulation (2.50 d *vs* 3.40 d, $P < 0.001$; 1.02 d *vs* 3.64 d, $P < 0.001$; 1.47 d *vs* 2.99 d, $P < 0.001$, respectively), and lower medical costs ($7621.75 *vs* $7814.16, $P = 0.009$). There was a significantly

Conflict-of-interest statement: The authors have no conflicts of interest to declare.

Data sharing statement: No additional data are available.

STROBE statement: The authors have read the STROBE Statement—checklist of items, and the manuscript was prepared and revised according to the STROBE Statement—checklist of items.

Manuscript source: Unsolicited manuscript

Received: June 9, 2020
Peer-review started: June 9, 2020
First decision: July 25, 2020
Revised: August 2, 2020
Accepted: September 3, 2020
Article in press: September 3, 2020
Published online: October 7, 2020

P-Reviewer: Yeoh SW
S-Editor: Gao CC
L-Editor: Wang TQ
P-Editor: Ma YJ

higher rate of postoperative complications among patients in the conventional group than among those in the ERAS group (18.1 *vs* 12.3, $P = 0.030$). Regarding inflammatory indexes, the C-reactive protein and procalcitonin levels on postoperative day 3/4 were significantly different between the two groups ($P < 0.001$ and $P = 0.025$, respectively). The ERAS protocol was associated with significantly improved 5-year overall survival and cancer-specific survival rates compared with conventional protocol ($P = 0.013$ and 0.032, respectively). When stratified by tumour stage, only the survival of patients with stage III disease was significantly different between the two groups ($P = 0.044$).

CONCLUSION

Adherence to the ERAS protocol improves both the short-term outcomes and the 5-year overall survival and cancer-specific survival of patients after laparoscopic gastrectomy.

Key Words: Enhanced recovery after surgery; Conventional management; Laparoscopic gastrectomy; Short-term outcomes; Survival

Core Tip: The results of this retrospective study suggest that enhanced recovery after surgery might be a promising perioperative management protocol for gastric cancer in terms of short-term and long-term outcomes. To the best of our knowledge, this is the first propensity score-matched study to reveal that the enhanced recovery after surgery protocol can improve the 5-year overall survival and cancer-specific survival rates of patients with gastric cancer.

Citation: Tian YL, Cao SG, Liu XD, Li ZQ, Liu G, Zhang XQ, Sun YQ, Zhou X, Wang DS, Zhou YB. Short- and long-term outcomes associated with enhanced recovery after surgery protocol *vs* conventional management in patients undergoing laparoscopic gastrectomy. *World J Gastroenterol* 2020; 26(37): 5646-5660
URL: https://www.wjgnet.com/1007-9327/full/v26/i37/5646.htm
DOI: https://dx.doi.org/10.3748/wjg.v26.i37.5646

INTRODUCTION

Globally, gastric cancer is a common malignant tumour and has the third highest mortality rate. In 2018, there were more than 1.3 million new cases of gastric cancer and more than 780000 gastric cancer related deaths[1]. The treatments and outcomes of gastric cancer have improved substantially over recent decades because of the introduction of new surgical techniques and chemotherapeutic drugs[2-5]. Enhanced recovery after surgery (ERAS) pathways have been proven to improve postoperative recovery and reduce postoperative complications, the length of hospital stay, and medical costs after gastric cancer surgery[6-8]. In a previously published randomized controlled trial, we investigated the relationship between postoperative compliance to ERAS protocols and short-term postoperative outcomes, and similar results were obtained[9]. Despite the short-term outcomes achieved with the perioperative ERAS protocol, the postoperative complication rate remains at approximately 10% to 30%.

Emerging evidence suggests that the ERAS protocol can influence long-term oncological outcomes after colorectal cancer surgery and elective orthopaedic surgery[10-12]. The mechanism behind this effect may not only be related to the reduction of complications and immune suppression but also to changes in immune response leading to a higher recurrence rate and distant metastasis rate[13-16]. However, it is not clear whether the ERAS regimen can improve the long-term prognosis of gastric cancer. Therefore, the aim of this retrospective study was to determine the effect of the ERAS protocol after laparoscopic gastrectomy on long-term survival. Moreover, short-term clinical outcomes and inflammatory parameters were compared between the ERAS and conventional protocols.

MATERIALS AND METHODS

Study design and participants

From January 2012 to December 2015, 1026 consecutive laparoscopic gastrectomies were performed at the Department of General Surgery of the Affiliated Hospital of Qingdao University, China. Data from these procedures were prospectively collected in a database and then retrospectively reviewed. The ERAS protocol was introduced in 2010 as a standard protocol for perioperative care in our department. Because the ERAS protocol was not be accepted by some patients at that time, based on the willingness of the patients, the department was divided into an ERAS ward (ERAS protocol) and a non-ERAS ward (conventional pathway). In the same period, we extensively performed laparoscopic surgery for gastric cancer. According to the postoperative pathological stage, patients with advanced gastric cancer were treated with S-1 combined with oxaliplatin for 6-8 cycles. All patients were followed by outpatient clinic visits and telephone interviews for up to 5 years after the primary operation.

After excluding some patients who did not meet the criteria, the ERAS group was matched in a ratio of 1:1 with the conventional group. Matching was achieved based on propensity scores including the following seven covariates: Age, American Society of Anesthesiology score, primary tumour location, histologic type, pathological stage, operation date, and adjuvant chemotherapy. The study design is shown in Figure 1.

Perioperative management and operation

Patients in the ERAS ward were managed according to the ERAS pathway during the perioperative period, the specific protocol includes 17 care elements (Table 1), and their compliance with all care elements was more than 80%, while the non-ERAS ward was managed according to the conventional pathway (Supplementary Table 1). To ensure recovery and reduce hospitalizations after gastric surgery, we paid particular attention to the "key components" of the ERAS programme, namely, the following six basic elements: Preoperative patient information and education, thoracic epidural anaesthesia combined with multimodal analgesia, target-oriented liquid management, no nasogastric tube, early oral feeding, and early mobilization.

Before surgery, chest computed tomography (CT), abdominal enhanced CT, and pelvic CT were performed to confirm the size and location of the tumour, and distant organ metastases were excluded according to the evaluation by two experienced radiologists. Echocardiography and pulmonary function tests were used to evaluate the tolerance of cardiopulmonary function to laparoscopic surgery. Nutrition risk screening 2002 was used to evaluate the nutritional status of patients; if the score was ≥ 3, the patients were given nutritional support.

Laparoscopic-assisted radical resection of distal gastric cancer (D2 Billroth-I/Billroth-II/Roux-en-Y) was performed under general anaesthesia. During the operation, we followed the basic principles of tumour treatment, mastered the appropriate scope of gastrectomy, performed fine lymph node dissection and gastrointestinal reconstruction, and recorded the volume of intraoperative infusion, volume of blood loss, operation time, and use of opioids and muscle relaxants.

Definition of surgical complications and mortality

Complications and mortality were defined as those occurring within 30 d after gastrectomy. Intraoperative complications were defined as bleeding due to vessel injury, injury to visceral organs, mechanical factor-related problems, cardiopulmonary dysfunction due to hypercapnia, and other complications. Wound infection was defined as a skin and subcutaneous tissue infection. A specific complication was diagnosed on the basis of either a medical imaging examination or obvious clinical evidence. Gastroparesis referred to the occurrence of emptying difficulties after surgery, combined with clinical features and imaging examinations for a final diagnosis. Anastomotic complications such as leakage, stenosis, or intracavitary haemorrhage were confirmed by gastrointestinal X-ray imaging, endoscopy, or angiography. Intra-abdominal collections and abscesses were proven by ultrasonography or CT scans and had concomitant systemic inflammatory responses that lasted for at least 24 h. Both intraoperative major bleeding and postoperative haemorrhage were defined as an amount of haemorrhage exceeding 300 mL. Traumatic pancreatitis was defined as increased serum amylase levels exceeding three times the upper limit of normal accompanied by obvious clinical symptoms and signs. Lymphatic leakage was confirmed by a chyle test when the abdominal drainage fluid volume exceeded 300 mL per day for 5 continuous days after postoperative day (POD)

Table 1 Compliance with the enhanced recovery after surgery protocol in enhanced recovery after surgery group

ERAS variable	Compliance (%), *n* = 365
Health education, exercise advice, dietary guidance	365 (100)
Organ function evaluation, pre-rehabilitation treatment	312 (85.5)
Fasting for 6 h and drinking for 2 h before operation	332 (91.0)
No indwelling nasogastric tube	310 (84.9)
Intraoperative safety check (WHO check list)	365 (100)
Precision surgery scheme	365 (100)
Goal-directed therapy	306 (83.8)
Epidural anesthesia/analgesia	299 (81.9)
Intraoperative heat preservation	349 (95.6)
Small midline (< 8 cm) incision of upper abdomen	358 (98.1)
Incision infiltration anesthesia	310 (93.2)
Multimodal analgesia	358 (98.1)
Prevention of deep venous thrombosis	348 (95.3)
Mobilization on the first postoperative day	320 (87.7)
Oral diet on the first postoperative day	311 (85.2)
Early removal of catheter (< 24 h)	339 (92.9)
Early extraction of abdominal drainage tube (< 48 h)	304 (83.3)

ERAS: Enhanced recovery after surgery; WHO: World Health Organization.

3. The severity of postoperative complications was assessed according to the Clavien-Dindo classification[17].

Statistical analysis

Categorical variables are described as numbers and percentages and were compared between groups using Pearson's chi-square test or Fisher's exact test. Continuous variables are described as the mean ± standard deviation. Non-normally distributed continuous data are presented as the median and interquartile range, and Student's *t*-test was used for normally distributed continuous variables. Survival curves were plotted using the Kaplan-Meier method. The log-rank test was used to compare survival curves. Survival time was defined as the interval between the primary operation date and a new event or the last follow-up. Patients who did not experience any event and were still alive at 60 mo were censored at this time. Significance was defined as $P < 0.05$. All statistical tests were two-sided and performed using SPSS software version 24.0 (SPSS, Chicago, IL, United States).

Ethical statement

The study was approved by the Affiliated Hospital of Qingdao University Ethics Review Committee (No. QYFYKYLL-2018-34). All procedures were performed in accordance with the ethical standards laid down in the 1964 Declaration of Helsinki and its later amendments.

RESULTS

Compliance to the ERAS protocol

Table 1 lists the specific ERAS programmes and compliance to its 17 care elements. The following three elements achieved 100% compliance: Health education, intraoperative safety check, and precision surgery scheme. As compliance to the ERAS programme is affected by multidisciplinary cooperation among surgeons, anaesthesiologists, and nurses as well as the physical status and willingness of

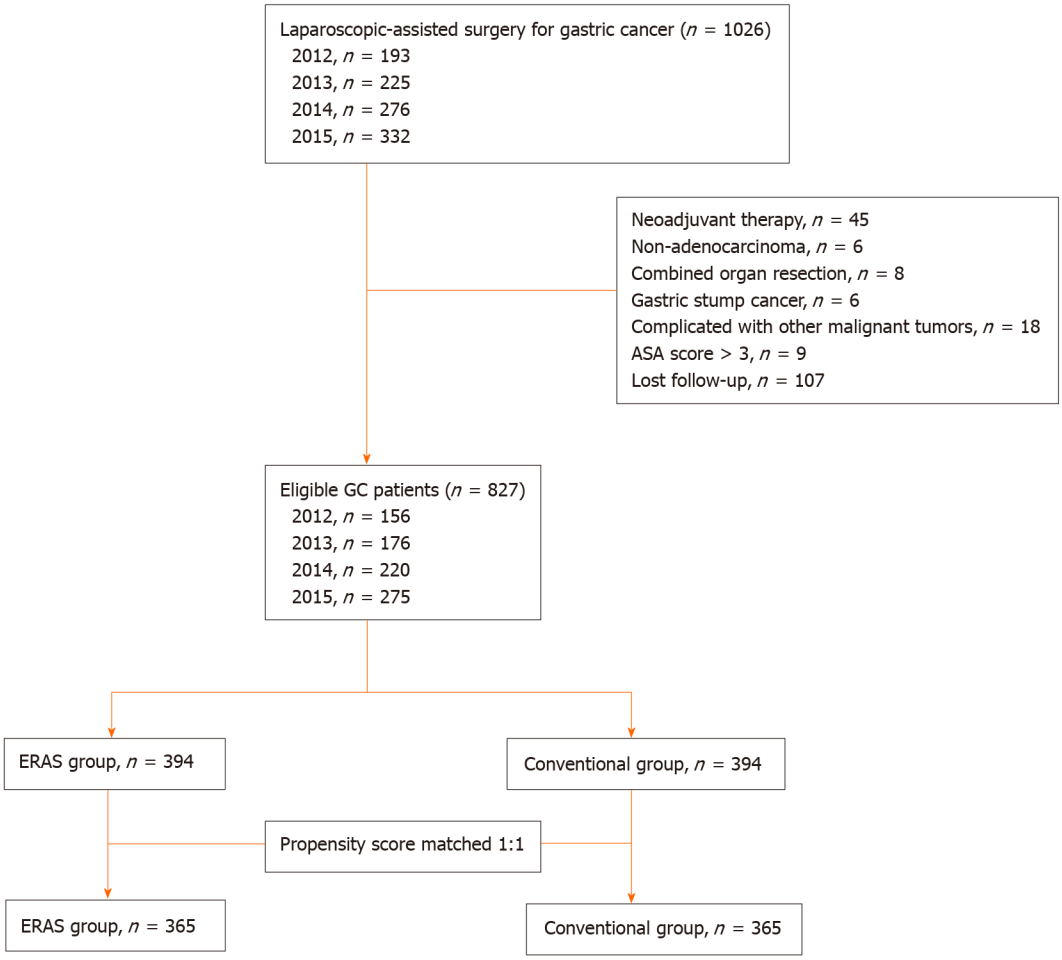

Figure 1 Flow diagram of patient selection process. GC: Gastric cancer; ASA: American Society of Anesthesiologists; ERAS: Enhanced recovery after surgery.

patients, the compliance rate to partial elements is typically low. Fortunately, our ERAS team is united and cooperative, and the implementation rate of all elements was greater than 80%. According to the database, more than 90% of patients implemented four and more 'key components' of the ERAS protocol, which is essential for our research.

Demographics and baseline characteristics

After the ERAS group was matched in a 1:1 ratio to the conventional group, there were 365 patients in each group. The patient demographics and baseline characteristics are detailed in Table 2 (Pathologic stage according to the American Joint Committee on Cancer)[18]. The baseline characteristics were well balanced after matching. We can observe that with the advancement of surgical technology, the number of laparoscopic surgeries increased year by year. There were 245 and 233 patients in the ERAS group and the conventional group who received adjuvant chemotherapy, respectively.

Surgical results

In the matched population, the surgical results of the ERAS and conventional groups are presented in Table 3. The mean time to first flatus in the conventional group was 0.9 days longer than that in the ERAS group (3.40 d *vs* 2.50 d; $P < 0.001$). Both the time to first liquid intake (1.02 d *vs* 3.64 d; $P < 0.001$) and time to ambulation (1.47 d *vs* 2.99 d; $P < 0.001$) were earlier in the ERAS group than in the conventional group. Compared to the conventional group, the ERAS group had a significantly shorter postoperative hospital stay (7.09 d *vs* 8.67 d; $P < 0.001$) and lower medical costs ($7621.75 *vs* $7814.76; $P = 0.009$). There were no statistically significant differences between the two groups in the other surgical results, especially in 30-d reoperation and 30-d readmission.

Table 2 Patient demographics and baseline characteristics

	Entire cohort			Propensity score matched cohort		
	Conventional group (*n* = 433)	ERAS group (*n* = 394)	*P* value	Conventional group (*n* = 365)	ERAS group (*n* = 365)	*P* value
Age, yr (mean ± SD)	59.4 ± 10.2	59.6 ± 10.3	0.105	59.4 ± 10.3	59.5 ± 10.3	0.881
Gender			0.534			0.810
Male, *n* (%)	298 (68.8)	279 (70.8)		253 (69.3)	256 (70.1)	
Female, *n* (%)	135 (31.2)	115 (29.2)		112 (30.7)	109 (29.9)	
BMI, kg/m^2 (mean ± SD)	23.7 ± 3.0	24.0 ± 3.1	0.287	23.8 ± 3.2	24.0 ± 3.1	0.379
ASA score			0.594			0.833
I, *n* (%)	226 (52.2)	210 (53.3)		190 (52.1)	196 (53.7)	
II, *n* (%)	179 (41.3)	165 (41.9)		153 (41.9)	152 (41.6)	
III, *n* (%)	28 (6.5)	19 (4.9)		22 (6.0)	17 (4.7)	
NRS 2002			0.784			0.767
< 3	197 (45.5)	183 (46.4)		165 (45.2)	169 (46.3)	
≥ 3	236 (54.5)	211 (53.6)		200 (54.8)	196 (53.7)	
Comorbidity						
Diabetes, *n* (%)	52 (12.0)	36 (9.1)	0.181	35 (9.6)	32 (8.8)	0.700
Cardiovascular, *n* (%)	80 (18.5)	52 (13.2)	0.038	49 (13.4)	40 (11.0)	0.309
Hypertension, *n* (%)	115 (26.6)	110 (27.9)	0.660	98 (26.8)	105 (28.8)	0.563
Pulmonary, *n* (%)	45 (10.4)	38 (9.6)	0.720	33 (9.0)	32 (8.8)	0.896
Hepatic, *n* (%)	17 (3.9)	20 (5.1)	0.424	17 (4.7)	19 (5.2)	0.528
Renal, *n* (%)	3 (0.7)	4 (1.0)	0.614	3 (0.8)	4 (1.1)	0.614
Tumor location			0.892			0.962
Upper, *n* (%)	59 (13.6)	56 (14.2)		55 (15.1)	54 (14.8)	
Middle, *n* (%)	88 (20.3)	84 (21.3)		75 (20.5)	78 (21.4)	
Lower, *n* (%)	286 (66.1)	254 (64.5)		235 (64.4)	233 (63.8)	
Histologic type			0.651			0.829
Well, *n* (%)	42 (9.7)	31 (7.9)		31 (8.5)	31 (8.5)	
Moderate, *n* (%)	101 (23.3)	94 (23.9)		93 (25.5)	86 (23.6)	
Poor, *n* (%)	290 (67.0)	269 (68.3)		241 (66.0)	248 (67.9)	
Pathological T stage			0.254			0.350
T1, *n* (%)	56 (12.9)	42 (10.7)		48 (13.2)	38 (10.4)	
T2, *n* (%)	89 (20.6)	91 (23.1)		72 (19.7)	82 (22.5)	
T3, *n* (%)	99 (22.9)	107 (27.2)		85 (23.3)	98 (26.8)	
T4, *n* (%)	189 (43.6)	154 (39.1)		160 (43.8)	147 (40.3)	
Pathological N stage			0.091			0.417
N0, *n* (%)	95 (21.9)	97 (24.6)		86 (23.6)	91 (24.9)	
N1, *n* (%)	89 (20.6)	104 (26.4)		79 (21.6)	95 (26.0)	
N2, *n* (%)	92 (21.2)	70 (17.8)		74 (20.3)	64 (17.5)	
N3, *n* (%)	157 (36.3)	123 (31.2)		126 (34.5)	115 (31.5)	
pTNM stage			0.502			0.819
IA, *n* (%)	45 (10.4)	48 (12.2)		40 (11.0)	46 (12.6)	

IB, *n* (%)	69 (15.9)	70 (17.8)		62 (17.0)	64 (17.5)	
IIA, *n* (%)	66 (15.2)	64 (16.2)		56 (15.3)	62 (17.0)	
IIB, *n* (%)	72 (16.6)	63 (16.0)		60 (16.4)	58 (15.9)	
IIIA, *n* (%)	47 (10.9)	52 (13.2)		42 (11.5)	48 (13.2)	
IIIB, *n* (%)	66 (15.2)	51 (12.9)		54 (14.8)	46 (12.6)	
IIIC, *n* (%)	68 (15.7)	46 (11.7)		51 (14.0)	41 (11.2)	
Operation date			0.049			0.573
2012, *n* (%)	91 (21.0)	65 (16.5)		71 (19.5)	60 (16.4)	
2013, *n* (%)	98 (22.6)	78 (19.8)		70 (19.2)	69 (18.9)	
2014, *n* (%)	118 (27.3)	102 (25.9)		102 (27.9)	98 (26.8)	
2015, *n* (%)	126 (29.1)	179 (45.4)		122 (33.4)	138 (37.8)	
Adjuvant chemotherapy, *n* (%)	282 (65.1)	261 (66.2)	0.736	233 (63.8)	245 (67.1)	0.351

ERAS: Enhanced recovery after surgery; SD: Standard deviation; BMI: Body mass index; ASA: American Society of Anesthesiologists; NRS: Nutrition risk screening; pTNM: Pathologic tumor-node-metastasis.

Table 3 Surgical results for enhanced recovery after surgery and conventional groups

Variable	Conventional group (*n* = 365)	ERAS group (*n* = 365)	*P* value
Extent of resection			0.716
Proximal gastrectomy, *n* (%)	9 (2.5)	6 (1.6)	
Total gastrectomy, *n* (%)	90 (24.7)	88 (24.1)	
Distal gastrectomy, *n* (%)	266 (72.9)	271 (74.2)	
Reconstruction			0.520
Esophagogastrostomy, *n* (%)	7 (1.9)	6 (1.6)	
Billroth-I, *n* (%)	11 (3.0)	7 (1.9)	
Billroth-II, *n* (%)	21 (5.8)	29 (7.9)	
Roux-en-Y, *n* (%)	326 (89.3)	323 (88.5)	
Retrieved LN number (mean ± SD)	33.02 ± 13.14	32.72 ± 14.05	0.763
Operation time, min (mean ± SD)	198.35 ± 40.07	195.26 ± 42.94	0.315
Estimated blood loss, mL (mean ± SD)	72.49 ± 34.24	69.91 ± 34.22	0.308
Intraoperative transfusion, *n* (%)	23 (6.3)	16 (4.4)	0.249
Length of incision, cm (mean ± SD)	7.58 ± 1.54	7.47 ± 1.39	0.315
Time to first flatus, d (mean ± SD)	3.40 ± 1.21	2.50 ± 0.81	< 0.001
Time to first liquid intake, d (mean ± SD)	3.64 ± 1.20	1.02 ± 0.57	< 0.001
Time to ambulation, d (mean ± SD)	2.99 ± 1.51	1.47 ± 062	< 0.001
Postoperative hospital stay, d (mean ± SD)	8.67 ± 2.38	7.09 ± 1.76	< 0.001
30-d reoperation, *n* (%)	7 (1.9)	5 (1.4)	0.560
30-d readmission, *n* (%)	17 (4.7)	15 (4.1)	0.717
Medical cost, $ (mean ± SD)	7814.16 ± 1024.19	7621.75 ± 949.73	0.009

ERAS: Enhanced recovery after surgery; SD: Standard deviation; LN: Lymph node.

Postoperative complications

Postoperative morbidity and mortality are reported in Table 4. Apart from a significantly higher rate of postoperative complications among patients in the conventional group than among those in the ERAS group (18.1 *vs* 12.3; $P = 0.030$), no significant differences in intraoperative complications, mortality, or Clavien-Dindo classification could be detected between the two groups. Moreover, according to the Clavien-Dindo classification of surgical complications, the distribution of severity (grade 3 or more) was similar between the two groups ($P = 0.192$). Remarkably, 20 (5.5%) patients in the ERAS group and 13 (3.6%) in the conventional group had pulmonary complications, with no statistically significant difference between the two groups ($P = 0.212$).

Inflammatory indexes

The serum white blood cell (WBC), C-reactive protein (CRP), and procalcitonin were used as indicators of the surgical stress response. On POD 1, the WBC, CRP, and procalcitonin levels increased significantly in both groups compared to the preoperative values ($P < 0.05$ for all). The WBC, CRP, and procalcitonin did not increase as much in the ERAS group as in the conventional group. In particular, the CRP (0.63 ± 0.33 *vs* 0.58 ± 0.30) and procalcitonin (90.61 ± 20.42 *vs* 78.35 ± 16.73) levels on POD 3/4 were significantly different between the two groups ($P < 0.001$, Figure 2A; $P = 0.025$, Figure 2B). There was no significant difference between the groups in terms of WBC (Figure 2C). Notably, from POD 4-6, all indicators of both groups gradually recovered.

Survival

The follow-up endpoint was December 31, 2019. The median follow-up duration was 67 (range, 3-92) mo. The deaths of 226 patients resulted in a 5-year overall survival (OS) rate of 72.9% (99 of 365) in the ERAS group and 65.2% (127 of 365) in the conventional group (log-rank test, $P = 0.013$, Figure 3A). ERAS interventions were associated with a significantly improved 5-year cancer-specific survival rate compared with that in the conventional group ($P = 0.033$, Figure 3B). When stratified by tumour stage, the 5-year OS rates were 91.8%, 83.3%, and 48.1% for stages I, II, and III disease in the ERAS group, respectively, but 90.2%, 76.7%, and 38.3% in the conventional group, respectively (Figure 3C). In particular, the 5-year OS rate of the ERAS group was better than that of the traditional group, but only the survival of patients with stage III disease was significantly different between the two groups (log-rank test, $P = 0.044$).

DISCUSSION

The results of this retrospective study suggest that ERAS might be a promising perioperative management protocol for gastric cancer in terms of short-term and long-term outcomes. To the best of our knowledge, this is the first propensity score-matched study to reveal that the ERAS protocol can improve the 5-year OS and cancer-specific survival rates of patients with gastric cancer.

In this study, the perioperative ERAS protocol for gastric cancer surgery included at least 17 independent components. The formulation of consensus guidelines for enhanced recovery after gastrectomy, which consisted of 25 items in 2014, filled in the gap of an ERAS protocol in the perioperative period of gastric cancer surgery[19]. After more than 10 years of development, the ERAS protocol has been further improved and developed; we also summarized the protocol. Many studies have shown that compliance to the ERAS protocol is closely related to the surgical outcome[20,21]. In fact, fully implementing the ERAS protocol in clinical practice is indeed a challenge, and a nationwide survey in Korea also found similar problems[22]. There are many reasons behind these challenges, and they include a lack of knowledge, lack of acceptance, lack of ability, or lack of wish to change, or lack of clinical leadership; thus, many elements have to be implemented in a busy clinical department[23]. Fortunately, with total multidisciplinary collaboration among anaesthesiologists, surgeons, nurses, and physiotherapists, the patients' adherence to all components was greater than 80%. Research from the ERAS Compliance Group showed that increasing the compliance to an ERAS programme independently improved outcomes[24]. Next, we will pay more attention to focusing on how to improve patient compliance, including strengthening ERAS care training, strengthening education, improving clinical leadership, and simplifying the ERAS elements.

Table 4 Postoperative morbidity and mortality

Variable	Conventional group (*n* = 365)	ERAS group (*n* = 365)	*P* value
Intraoperative complications, *n* (%)	15 (4.1)	16 (4.4)	0.854
Postoperative complications, *n* (%)	66 (18.1)	45 (12.3)	0.030
Wound infection, *n* (%)	7 (1.9)	4 (1.1)	0.546
Pulmonary, *n* (%)	20 (5.5)	13 (3.6)	0.212
Gastroparesis, *n* (%)	6 (1.6)	6 (1.6)	1.000
Anastomotic leakage, *n* (%)	9 (2.5)	7 (1.9)	0.613
Lymphatic leakage, *n* (%)	4 (1.1)	2 (0.5)	0.686
Pancreatic fistula, *n* (%)	2 (0.5)	1 (0.3)	1.000
Intra-abdominal bleeding, *n* (%)	2 (0.5)	0 (0)	0.499
Intraluminal bleeding, *n* (%)	5 (1.4)	5 (1.4)	1.000
Intra-abdominal abscess, *n* (%)	2 (0.5)	1 (0.3)	1.000
Deep vein thrombosis, *n* (%)	2 (0.5)	0 (0)	0.499
Ileus, *n* (%)	3 (0.8)	2 (0.5)	1.000
Cerebrovascular, *n* (%)	0 (0)	0 (0)	1.000
Cardiac, *n* (%)	2 (0.5)	1 (0.3)	1.000
Cholecystitis, *n* (%)	0 (0)	1 (0.3)	1.000
Hepatic, *n* (%)	1 (0.3)	1 (0.3)	1.000
Renal, *n* (%)	1 (0.3)	1 (0.3)	1.000
Mortality, *n* (%)	0 (0)	0 (0)	1.000
Clavien-Dindo classification			
I, *n* (%)	6 (1.6)	4 (1.1)	0.752
II, *n* (%)	50 (13.7)	35 (9.6)	0.083
IIIa, *n* (%)	4 (1.1)	4 (1.1)	1.000
IIIb, *n* (%)	3 (0.8)	1 (0.3)	0.624
IV, *n* (%)	3 (0.8)	1 (0.3)	0.624

ERAS: Enhanced recovery after surgery.

ERAS protocols in elective radical gastrectomy for gastric cancer have been widely accepted, and the evidence behind the feasibility and safety of ERAS has repeatedly been shown[20,21]. After the ERAS group was matched with the conventional group, there were no differences in demographics or baseline characteristics between the two groups in this study. The present study showed that ERAS is a safe and feasible protocol for gastric cancer because this approach led to a faster recovery, shorter hospital stay, and lower medical costs. Moreover, the total incidence of postoperative complications in the ERAS group was significantly lower than that in the conventional group. Although there was no significant difference, the incidence of pulmonary complications and wound infections in the ERAS group was lower than that in the conventional group, which may be related to the use of pre-rehabilitation (health education, exercise advice, psychological guidance, organ function evaluation and intervention, and nutritional assessment and intervention), multimodal analgesia, and early mobilization and intake. In addition, it is worth mentioning that the 30-d reoperation and readmission and perioperative mortality rates were not different between the two groups.

Surgical trauma will stimulate the release of a large number of inflammatory molecules, such as CRP, procalcitonin, interleukin-6 (IL-6), and necrosis factor-alpha (TNF-α), which will lead to a systemic inflammatory response, affect immune function, and increase the incidence of postoperative symptoms. CRP is one of the most commonly used inflammatory proteins to study acute response, and its

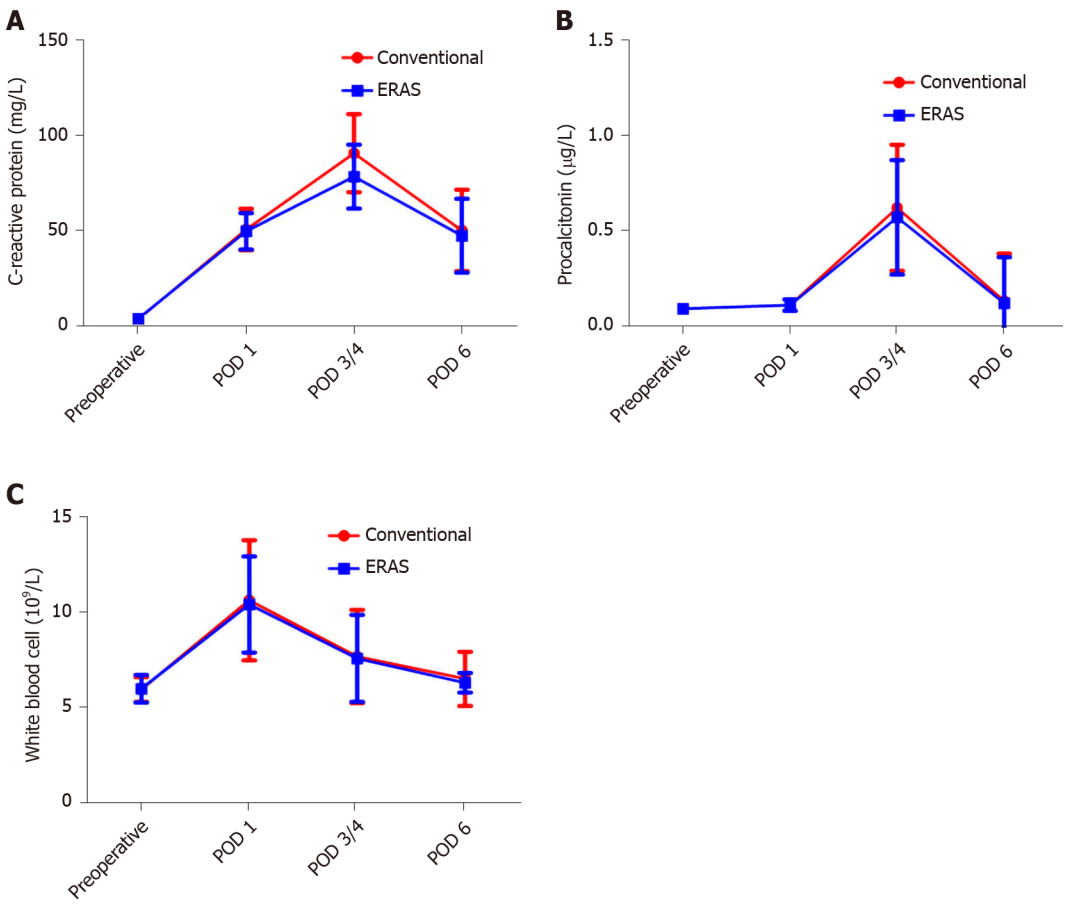

Figure 2 Comparison of levels of inflammatory indexes in the two groups. A: C-reactive protein; B: Procalcitonin; C: White blood cell count. POD: Postoperative day; ERAS: Enhanced recovery after surgery.

expression level is related to the stress response to surgery. In healthy people, procalcitonin levels are very low, but lipopolysaccharides, microbial toxins, and inflammatory mediators (IL-6 or TNF-α) can directly or indirectly cause its increase during inflammation. Therefore, procalcitonin also reflects systemic inflammatory response and stress activity. Although the CRP and procalcitonin levels on POD 3/4 were significantly different between the two groups, the WBC, CRP, and procalcitonin did not increase as much in the ERAS group as in the conventional group. The results of this study are similar to those of previous studies: The ERAS pathway can reduce the postoperative stress response[20].

The adoption of ERAS principles is increasing due to the significantly better short-term outcomes, but little is known about how ERAS can improve long-term prognosis. All things considered, the results of this study seem to have established that ERAS is superior to the conventional protocol in terms of oncological outcomes, particularly for stage III gastric cancer. Although there was no significant difference in survival of patients with stage II disease, the 5-year OS rate in the ERAS group was better than that in the conventional group. We conducted a retrospective study of gastric cancer patients who underwent standard radical gastrectomy from 2007 to 2012 and reached similar conclusions[25]. However, there are several potential explanations for why compliance to ERAS protocols better contributed to improved survival. First, perioperative complications have been shown to be strongly associated with impaired long-term outcomes[26,27]. This could be the result of either delayed adjuvant chemoradiation or no adjuvant chemoradiation in complicated cases[28]. Moreover, ERAS protocols can bring potential benefits to advanced gastric cancer that may be related to a lower stress response and reduction in insulin resistance, which are considered to be factors associated with a good cancer long-term prognosis[29-31]. Studies show that a relative perioperative cortisol deficiency appears to be an under-recognised contributor to perioperative organ injury[32]. Recent data from high-dose preoperative steroid administrations (*i.e.*, greater than 8 mg dexamethasone) are promising and showed that this approach improves pain relief, reduces the inflammatory response and early fatigue, and enhances patient recovery[33].

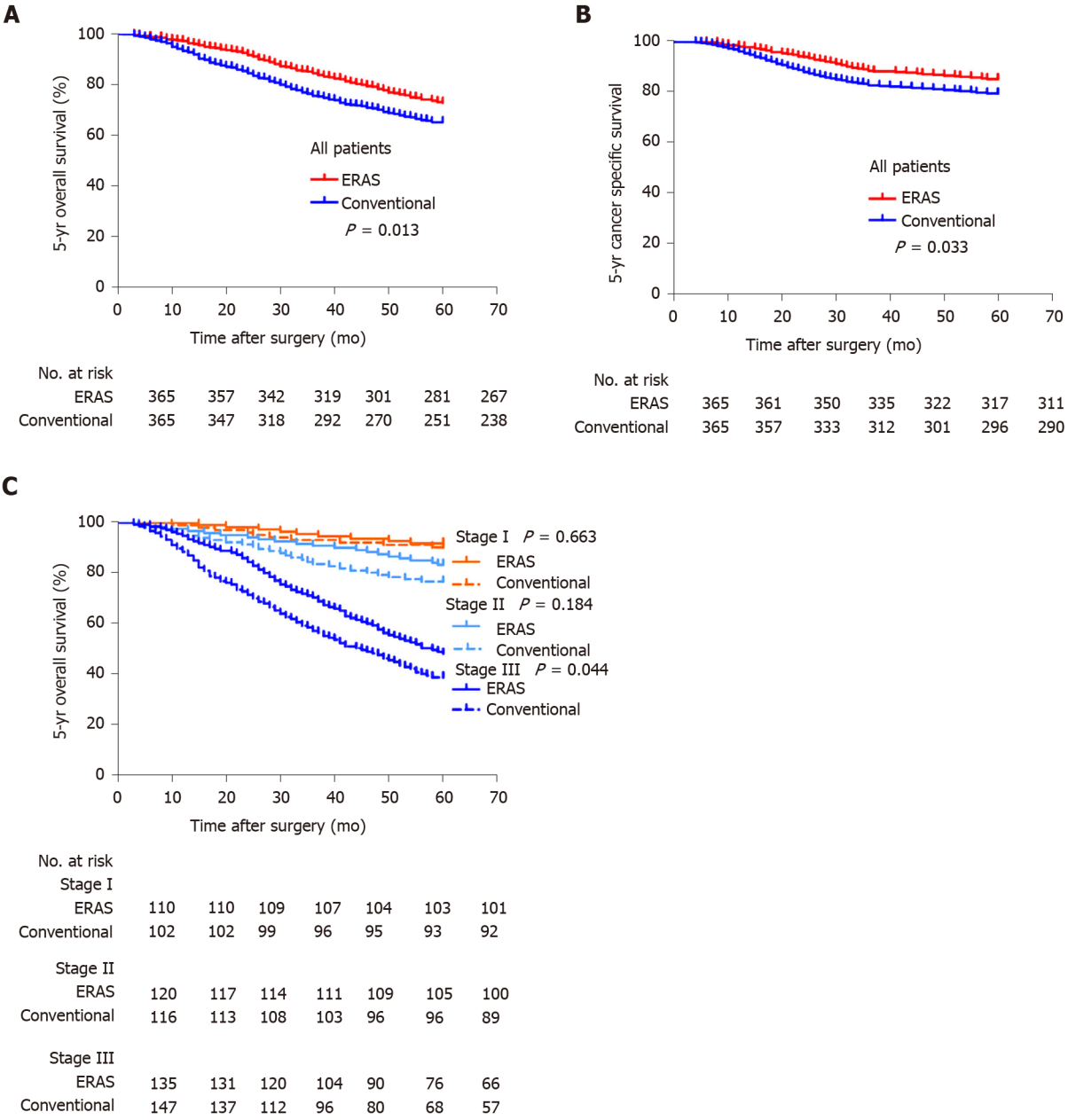

Figure 3 Kaplan-Meier curves. A: 5-yr overall survival; B: 5-yr cancer-specific survival; C: 5-yr overall survival for stages I, II, and III disease between the two groups. ERAS: Enhanced recovery after surgery.

Furthermore, environmental challenges that affect the patient perioperatively, such as psychological distress, intraoperative hypothermia, and use of anaesthetic drugs or blood transfusions, also trigger a variety of stress responses that can substantially affect the metastatic process through effects on distal malignant cells, their microenvironment, and interacting immunocytes[34-36]. In contrast, ERAS protocols advocate for preoperative education, pre-rehabilitation, an avoidance of intraoperative hypothermia, multimodal analgesia, and an avoidance of unnecessary blood transfusions to reduce the stress response of surgical patients[37]. The unavoidable damage to the patients' tissues and the removal and manipulations of the primary tumour during surgery have been shown to increase tumour cell shedding into the blood and lymphatic systems and to decrease systemic levels of primary tumour-associated antiangiogenic factors (such as endostatin)[38,39]. In addition, the patients' paracrine and neuroendocrine responses to surgery, including the release of prostaglandins and catecholamines, facilitate malignant cell survival, motility, invasion, and proliferation and the release of proangiogenic factors, and suppress antimetastatic immunity[40,41]. In summary, every element plays an important role in the ERAS protocol, and even a combination of small changes can have a large impact on the outcome.

Our study has several limitations. First, we attempted to analyse the changes in stress response, but due to the limitations of retrospective data, there was no analysis of additional indicators (TNF-α and IL-6). Second, many components related to the time-varying ERAS protocol may have affected the results regarding both short-term and long-term outcomes; however, the weight of these components in the ERAS protocol requires further evaluation to determine the rational essential elements. Third, it is impossible to clarify the mechanism behind the influence of the ERAS protocol on short-term and long-term outcomes; detailed mechanistic studies are needed in the future. Finally, this was a single-centre retrospective study; therefore, multicentre randomised controlled trial studies should be performed to verify the reliability of the results. Fortunately, we have registered (Chinese Clinical Trial Registry, CHiCTR1900022438) and started such a project, and patients are currently being recruited[42]. We hope that our data will provide trustworthy evidence that the ERAS pathway improves survival in patients with gastric cancer.

CONCLUSION

In conclusion, the ERAS protocol has been proven to be a safe and effective perioperative management pathway in the current literature. In particular, the ERAS protocol has shown promising results in improving the survival of patients with gastric cancer after surgery.

ARTICLE HIGHLIGHTS

Research background

At present, the enhanced recovery after surgery (ERAS) protocol is widely implemented in the field of gastric surgery. Emerging evidence suggests that the ERAS protocol can influence long-term oncological outcomes after colorectal cancer surgery and elective orthopaedic surgery. However, the effect of the ERAS protocol on the long-term prognosis of gastric cancer has not been reported.

Research motivation

We urgently need to understand that ERAS can improve the long-term prognosis of patients with gastric cancer, so as to standardize our clinical care and improve the terms of ERAS protocol.

Research objectives

The primary aim of this retrospective study was to determine the effect of the ERAS protocol after laparoscopic gastrectomy on long-term survival. The secondary aim was to compare short-term clinical outcomes and inflammatory parameters between the ERAS and conventional protocols.

Research methods

We retrospectively analyzed the data of 1026 consecutive patients who underwent laparoscopic gastrectomy between 2012 and 2015. Data from these procedures were prospectively collected in a database and then retrospectively reviewed. The patients were divided into either an ERAS group or a conventional group based on the willingness of the patients. The groups were matched in a 1:1 ratio using propensity scores based on covariates that affect cancer survival. The primary outcomes were the 5-year overall and cancer-specific survival rates. The secondary outcomes were the postoperative short-term outcomes and inflammatory indexes.

Research results

The patient demographics and baseline characteristics were similar between the two groups after matching. Compared to the conventional group, the ERAS group had a significantly shorter postoperative hospital day (7.09 d *vs* 8.67 d, $P < 0.001$), shorter time to first flatus, liquid intake, and ambulation (2.50 d *vs* 3.40 d, $P < 0.001$; 1.02 d *vs* 3.64 d, $P < 0.001$; 1.47 d *vs* 2.99 d, $P < 0.001$, respectively), and lower medical costs ($7621.75 *vs* $7814.16, $P = 0.009$). There was a significantly higher rate of postoperative complications among patients in the conventional group than among those in the ERAS group (18.1 *vs* 12.3, $P = 0.030$). Regarding inflammatory indexes, the C-reactive

protein and procalcitonin levels on postoperative day 3/4 were significantly different between the two groups ($P < 0.001$ and $P = 0.025$, respectively). The ERAS protocol was associated with significantly improved 5-year overall survival and cancer-specific survival rates compared with conventional protocol ($P = 0.013$, $P = 0.032$, respectively). When stratified by tumour stage, only the survival of patients with stage III disease was significantly different between groups ($P = 0.044$).

Research conclusions

The ERAS protocol has been proven to be a safe and effective perioperative management pathway in the current literature. In particular, the ERAS protocol has shown promising results in improving the survival of patients with gastric cancer after surgery.

Research perspectives

This was a single-centre retrospective study; therefore, multicentre randomised controlled trial studies should be performed to verify the reliability of the results. Fortunately, we have registered (Chinese Clinical Trial Registry, CHiCTR1900022438) and started such a project, and patients are currently being recruited. We hope that our data will provide trustworthy evidence that the ERAS pathway improves survival in patients with gastric cancer.

ACKNOWLEDGEMENTS

We thank the patients participating in the study as well as the nurses and the management staff at the hospital. We also thank Wang H and Wang LK for contribution to the data collection.

REFERENCES

1 **Bray F**, Ferlay J, Soerjomataram I, Siegel RL, Torre LA, Jemal A. Global cancer statistics 2018: GLOBOCAN estimates of incidence and mortality worldwide for 36 cancers in 185 countries. *CA Cancer J Clin* 2018; **68**: 394-424 [PMID: 30207593 DOI: 10.3322/caac.21492]

2 **Yu J**, Huang C, Sun Y, Su X, Cao H, Hu J, Wang K, Suo J, Tao K, He X, Wei H, Ying M, Hu W, Du X, Hu Y, Liu H, Zheng C, Li P, Xie J, Liu F, Li Z, Zhao G, Yang K, Liu C, Li H, Chen P, Ji J, Li G; Chinese Laparoscopic Gastrointestinal Surgery Study (CLASS) Group. Effect of Laparoscopic *vs* Open Distal Gastrectomy on 3-Year Disease-Free Survival in Patients With Locally Advanced Gastric Cancer: The CLASS-01 Randomized Clinical Trial. *JAMA* 2019; **321**: 1983-1992 [PMID: 31135850 DOI: 10.1001/jama.2019.5359]

3 **Lee HJ**, Hyung WJ, Yang HK, Han SU, Park YK, An JY, Kim W, Kim HI, Kim HH, Ryu SW, Hur H, Kong SH, Cho GS, Kim JJ, Park DJ, Ryu KW, Kim YW, Kim JW, Lee JH, Kim MC; Korean Laparo-endoscopic Gastrointestinal Surgery Study (KLASS) Group. Short-term Outcomes of a Multicenter Randomized Controlled Trial Comparing Laparoscopic Distal Gastrectomy With D2 Lymphadenectomy to Open Distal Gastrectomy for Locally Advanced Gastric Cancer (KLASS-02-RCT). *Ann Surg* 2019; **270**: 983-991 [PMID: 30829698 DOI: 10.1097/SLA.0000000000003217]

4 **Bang YJ**, Van Cutsem E, Feyereislova A, Chung HC, Shen L, Sawaki A, Lordick F, Ohtsu A, Omuro Y, Satoh T, Aprile G, Kulikov E, Hill J, Lehle M, Rüschoff J, Kang YK; ToGA Trial Investigators. Trastuzumab in combination with chemotherapy *vs* chemotherapy alone for treatment of HER2-positive advanced gastric or gastro-oesophageal junction cancer (ToGA): a phase 3, open-label, randomised controlled trial. *Lancet* 2010; **376**: 687-697 [PMID: 20728210 DOI: 10.1016/S0140-6736(10)61121-X]

5 **Sasako M**, Sano T, Yamamoto S, Kurokawa Y, Nashimoto A, Kurita A, Hiratsuka M, Tsujinaka T, Kinoshita T, Arai K, Yamamura Y, Okajima K; Japan Clinical Oncology Group. D2 Lymphadenectomy alone or with para-aortic nodal dissection for gastric cancer. *N Engl J Med* 2008; **359**: 453-462 [PMID: 18669424 DOI: 10.1056/NEJMoa0707035]

6 **Yamada T**, Hayashi T, Cho H, Yoshikawa T, Taniguchi H, Fukushima R, Tsuburaya A. Usefulness of enhanced recovery after surgery protocol as compared with conventional perioperative care in gastric surgery. *Gastric Cancer* 2012; **15**: 34-41 [PMID: 21573918 DOI: 10.1007/s10120-011-0057-x]

7 **Sugisawa N**, Tokunaga M, Makuuchi R, Miki Y, Tanizawa Y, Bando E, Kawamura T, Terashima M. A phase II study of an enhanced recovery after surgery protocol in gastric cancer surgery. *Gastric Cancer* 2016; **19**: 961-967 [PMID: 26260875 DOI: 10.1007/s10120-015-0528-6]

8 **Tanaka R**, Lee SW, Kawai M, Tashiro K, Kawashima S, Kagota S, Honda K, Uchiyama K. Protocol for enhanced recovery after surgery improves short-term outcomes for patients with gastric cancer: a randomized clinical trial. *Gastric Cancer* 2017; **20**: 861-871 [PMID: 28062937 DOI: 10.1007/s10120-016-0686-1]

9 **Wang D**, Kong Y, Zhong B, Zhou X, Zhou Y. Fast-track surgery improves postoperative recovery in patients with gastric cancer: a randomized comparison with conventional postoperative care. *J Gastrointest Surg* 2010; **14**: 620-627 [PMID: 20108171 DOI: 10.1007/s11605-009-1139-5]

10 **Gustafsson UO**, Oppelstrup H, Thorell A, Nygren J, Ljungqvist O. Adherence to the ERAS protocol is Associated with 5-Year Survival After Colorectal Cancer Surgery: A Retrospective Cohort Study. *World J*

Surg 2016; **40**: 1741-1747 [PMID: 26913728 DOI: 10.1007/s00268-016-3460-y]
11 **Savaridas T**, Serrano-Pedraza I, Khan SK, Martin K, Malviya A, Reed MR. Reduced medium-term mortality following primary total hip and knee arthroplasty with an enhanced recovery program. *Acta Orthop* 2013; **84**: 40-43 [PMID: 23368747 DOI: 10.3109/17453674.2013.771298]
12 **Pisarska M**, Torbicz G, Gajewska N, Rubinkiewicz M, Wierdak M, Major P, Budzyński A, Ljungqvist O, Pędziwiatr M. Compliance with the ERAS Protocol and 3-Year Survival After Laparoscopic Surgery for Non-metastatic Colorectal Cancer. *World J Surg* 2019; **43**: 2552-2560 [PMID: 31286185 DOI: 10.1007/s00268-019-05073-0]
13 **Smith T**, Li X, Nylander W, Gunnar W. Thirty-Day Postoperative Mortality Risk Estimates and 1-Year Survival in Veterans Health Administration Surgery Patients. *JAMA Surg* 2016; **151**: 417-422 [PMID: 26747331 DOI: 10.1001/jamasurg.2015.4882]
14 **Holmgren L**, O'Reilly MS, Folkman J. Dormancy of micrometastases: balanced proliferation and apoptosis in the presence of angiogenesis suppression. *Nat Med* 1995; **1**: 149-153 [PMID: 7585012 DOI: 10.1038/nm0295-149]
15 **Oosterling SJ**, van der Bij GJ, Meijer GA, Tuk CW, van Garderen E, van Rooijen N, Meijer S, van der Sijp JR, Beelen RH, van Egmond M. Macrophages direct tumour histology and clinical outcome in a colon cancer model. *J Pathol* 2005; **207**: 147-155 [PMID: 16104052 DOI: 10.1002/path.1830]
16 **Mantovani A**, Allavena P, Sica A, Balkwill F. Cancer-related inflammation. *Nature* 2008; **454**: 436-444 [PMID: 18650914 DOI: 10.1038/nature07205]
17 **Dindo D**, Demartines N, Clavien PA. Classification of surgical complications: a new proposal with evaluation in a cohort of 6336 patients and results of a survey. *Ann Surg* 2004; **240**: 205-213 [PMID: 15273542 DOI: 10.1097/01.sla.0000133083.54934.ae]
18 Edge SB, Byrd DR, Compton CC, Fritz AG, Greene FL, Trotti A. American Joint Committee on Cancer AJCC Cancer Staging Manual. 7th ed[M]. New York, NY: Springer, 2010
19 **Mortensen K**, Nilsson M, Slim K, Schäfer M, Mariette C, Braga M, Carli F, Demartines N, Griffin SM, Lassen K; Enhanced Recovery After Surgery (ERAS®) Group. Consensus guidelines for enhanced recovery after gastrectomy: Enhanced Recovery After Surgery (ERAS®) Society recommendations. *Br J Surg* 2014; **101**: 1209-1229 [PMID: 25047143 DOI: 10.1002/bjs.9582]
20 **Wee IJY**, Syn NL, Shabbir A, Kim G, So JBY. Enhanced recovery *vs* conventional care in gastric cancer surgery: a meta-analysis of randomized and non-randomized controlled trials. *Gastric Cancer* 2019; **22**: 423-434 [PMID: 30805742 DOI: 10.1007/s10120-019-00937-9]
21 **So JB**, Lim ZL, Lin HA, Ti TK. Reduction of hospital stay and cost after the implementation of a clinical pathway for radical gastrectomy for gastric cancer. *Gastric Cancer* 2008; **11**: 81-85 [PMID: 18595014 DOI: 10.1007/s10120-008-0458-7]
22 **Jeong O**, Kim HG. Implementation of Enhanced Recovery after Surgery (ERAS) Program in Perioperative Management of Gastric Cancer Surgery: a Nationwide Survey in Korea. *J Gastric Cancer* 2019; **19**: 72-82 [PMID: 30944760 DOI: 10.5230/jgc.2019.19.e3]
23 **Kehlet H**. ERAS Implementation-Time To Move Forward. *Ann Surg* 2018; **267**: 998-999 [PMID: 29462010 DOI: 10.1097/SLA.0000000000002720]
24 **ERAS Compliance Group**. The Impact of Enhanced Recovery Protocol Compliance on Elective Colorectal Cancer Resection: Results From an International Registry. *Ann Surg* 2015; **261**: 1153-1159 [PMID: 25671587 DOI: 10.1097/SLA.0000000000001029]
25 **Yang FZ**, Wang H, Wang DS, Niu ZJ, Li SK, Zhang J, Lü L, Chen D, Li Y, Jiang HT, Han HD, Chu HC, Cao SG, Zhou YB. [The effect of perioperative ERAS pathway management on short-and long-term outcomes of gastric cancer patients]. *Zhonghua Yi Xue Za Zhi* 2020; **100**: 922-927 [PMID: 32234167 DOI: 10.3760/cma.j.cn112137-20190711-01325]
26 **Khuri SF**, Henderson WG, DePalma RG, Mosca C, Healey NA, Kumbhani DJ; Participants in the VA National Surgical Quality Improvement Program. Determinants of long-term survival after major surgery and the adverse effect of postoperative complications. *Ann Surg* 2005; **242**: 326-41; discussion 341 [PMID: 16135919 DOI: 10.1097/01.sla.0000179621.33268.83]
27 **Wang S**, Xu L, Wang Q, Li J, Bai B, Li Z, Wu X, Yu P, Li X, Yin J. Postoperative complications and prognosis after radical gastrectomy for gastric cancer: a systematic review and meta-analysis of observational studies. *World J Surg Oncol* 2019; **17**: 52 [PMID: 30885211 DOI: 10.1186/s12957-019-1593-9]
28 **Kanda M**, Ito S, Mochizuki Y, Teramoto H, Ishigure K, Murai T, Asada T, Ishiyama A, Matsushita H, Tanaka C, Kobayashi D, Fujiwara M, Murotani K, Kodera Y. Multi-institutional analysis of the prognostic significance of postoperative complications after curative resection for gastric cancer. *Cancer Med* 2019; **8**: 5194-5201 [PMID: 31353821 DOI: 10.1002/cam4.2439]
29 **Palumbo JS**, Talmage KE, Massari JV, La Jeunesse CM, Flick MJ, Kombrinck KW, Jirousková M, Degen JL. Platelets and fibrin(ogen) increase metastatic potential by impeding natural killer cell-mediated elimination of tumor cells. *Blood* 2005; **105**: 178-185 [PMID: 15367435 DOI: 10.1182/blood-2004-06-2272]
30 **Hiller JG**, Perry NJ, Poulogiannis G, Riedel B, Sloan EK. Perioperative events influence cancer recurrence risk after surgery. *Nat Rev Clin Oncol* 2018; **15**: 205-218 [PMID: 29283170 DOI: 10.1038/nrclinonc.2017.194]
31 **van der Bij GJ**, Oosterling SJ, Beelen RH, Meijer S, Coffey JC, van Egmond M. The perioperative period is an underutilized window of therapeutic opportunity in patients with colorectal cancer. *Ann Surg* 2009; **249**: 727-734 [PMID: 19387333 DOI: 10.1097/SLA.0b013e3181a3ddbd]
32 **Manou-Stathopoulou V**, Korbonits M, Ackland GL. Redefining the perioperative stress response: a narrative review. *Br J Anaesth* 2019; **123**: 570-583 [PMID: 31547969 DOI: 10.1016/j.bja.2019.08.011]
33 **de la Motte L**, Kehlet H, Vogt K, Nielsen CH, Groenvall JB, Nielsen HB, Andersen A, Schroeder TV, Lönn L. Preoperative methylprednisolone enhances recovery after endovascular aortic repair: a randomized, double-blind, placebo-controlled clinical trial. *Ann Surg* 2014; **260**: 540-8; discussion 548 [PMID: 25115430 DOI: 10.1097/SLA.0000000000000895]
34 **Hijazi Y**, Gondal U, Aziz O. A systematic review of prehabilitation programs in abdominal cancer surgery. *Int J Surg* 2017; **39**: 156-162 [PMID: 28161527 DOI: 10.1016/j.ijsu.2017.01.111]
35 **Squires MH 3rd**, Kooby DA, Poultsides GA, Weber SM, Bloomston M, Fields RC, Pawlik TM,

Votanopoulos KI, Schmidt CR, Ejaz A, Acher AW, Worhunsky DJ, Saunders N, Levine EA, Jin LX, Cho CS, Winslow ER, Russell MC, Staley CA, Maithel SK. Effect of Perioperative Transfusion on Recurrence and Survival after Gastric Cancer Resection: A 7-Institution Analysis of 765 Patients from the US Gastric Cancer Collaborative. *J Am Coll Surg* 2015; **221**: 767-777 [PMID: 26228017 DOI: 10.1016/j.jamcollsurg.2015.06.012]

36 **Horowitz M**, Neeman E, Sharon E, Ben-Eliyahu S. Exploiting the critical perioperative period to improve long-term cancer outcomes. *Nat Rev Clin Oncol* 2015; **12**: 213-226 [PMID: 25601442 DOI: 10.1038/nrclinonc.2014.224]

37 **Kehlet H**, Wilmore DW. Evidence-based surgical care and the evolution of fast-track surgery. *Ann Surg* 2008; **248**: 189-198 [PMID: 18650627 DOI: 10.1097/SLA.0b013e31817f2c1a]

38 **Yamaguchi K**, Takagi Y, Aoki S, Futamura M, Saji S. Significant detection of circulating cancer cells in the blood by reverse transcriptase-polymerase chain reaction during colorectal cancer resection. *Ann Surg* 2000; **232**: 58-65 [PMID: 10862196 DOI: 10.1097/00000658-200007000-00009]

39 **O'Reilly MS**, Boehm T, Shing Y, Fukai N, Vasios G, Lane WS, Flynn E, Birkhead JR, Olsen BR, Folkman J. Endostatin: an endogenous inhibitor of angiogenesis and tumor growth. *Cell* 1997; **88**: 277-285 [PMID: 9008168 DOI: 10.1016/s0092-8674(00)81848-6]

40 **Thaker PH**, Sood AK. Neuroendocrine influences on cancer biology. *Semin Cancer Biol* 2008; **18**: 164-170 [PMID: 18201896 DOI: 10.1016/j.semcancer.2007.12.005]

41 **Gullino PM**. Prostaglandins and gangliosides of tumor microenvironment: their role in angiogenesis. *Acta Oncol* 1995; **34**: 439-441 [PMID: 7540024 DOI: 10.3109/02841869509094005]

42 **Tian Y**, Cao S, Li L, He Q, Xia L, Jiang L, Ding Y, Wang X, Wang H, Mao W, Hui X, Shi Y, Zhang H, Chu X, Kehlet H, Zhou Y. Effects of perioperative enhanced recovery after surgery pathway management *vs* traditional management on the clinical outcomes of laparoscopic-assisted radical resection of distal gastric cancer: study protocol for a randomized controlled trial. *Trials* 2020; **21**: 369 [PMID: 32357913 DOI: 10.1186/s13063-020-04272-8]

World Journal of Gastroenterology

Submit a Manuscript: https://www.f6publishing.com

World J Gastroenterol 2020 October 7; 26(37): 5661-5672

DOI: 10.3748/wjg.v26.i37.5661

ISSN 1007-9327 (print) ISSN 2219-2840 (online)

ORIGINAL ARTICLE

Retrospective Cohort Study

Periodontitis combined with smoking increases risk of the ulcerative colitis: A national cohort study

Eun Ae Kang, Jaeyoung Chun, Jee Hyun Kim, Kyungdo Han, Hosim Soh, Seona Park, Seung Wook Hong, Jung Min Moon, Jooyoung Lee, Hyun Jung Lee, Jun-Beom Park, Jong Pil Im, Joo Sung Kim

ORCID number: Eun Ae Kang 0000-0003-0220-937X; Jaeyoung Chun 0000-0002-4212-0380; Jee Hyun Kim 0000-0003-1019-6345; Kyungdo Han 0000-0002-6096-1263; Hosim Soh 0000-0001-5107-6521; Seona Park 0000-0002-7281-0833; Seung Wook Hong 0000-0003-1440-9950; Jung Min Moon 0000-0002-8994-7465; Jooyoung Lee 0000-0003-1652-088X; Hyun Jung Lee 0000-0003-2764-9339; Jun-Beom Park 0000-0002-8915-1555; Jong Pil Im 0000-0003-1584-0160; Joo Sung Kim 0000-0001-6835-4735.

Author contributions: Kang EA, Chun J, Kim JH and Han K completed the conception and design of the study; Kim JH, Han K, Soh H, Park S, Hong SW, Moon JM and Lee J completed the acquisition, analysis and interpretation of data; Kang EA and Chun J drafted and revised the article; Kang EA, Chun J, Lee HJ, Park JB, Im JP and Kim JS completed the final approval of the article submitted.

Institutional review board statement: The study was approved by the Institutional Review Board of the University of Seoul National University Hospital, No. H-1703-107-840.

Informed consent statement: The

Eun Ae Kang, Department of Internal Medicine and Institute of Gastroenterology, Yonsei University College of Medicine, Seoul 03722, South Korea

Jaeyoung Chun, Department of Internal Medicine, Gangnam Severance Hospital, Yonsei University College of Medicine, Seoul 06229, South Korea

Jee Hyun Kim, Department of Internal Medicine, Bundang CHA Medical Center, CHA University School of Medicine, Seoul 13496, South Korea

Kyungdo Han, Department of Statistics and Actuarial Science, Soongsil University, Seoul 06978, South Korea

Hosim Soh, Seona Park, Seung Wook Hong, Jung Min Moon, Jooyoung Lee, Hyun Jung Lee, Jong Pil Im, Joo Sung Kim, Department of Internal Medicine and Liver Research Institute, Seoul National University College of Medicine, Seoul 03080, South Korea

Jun-Beom Park, Department of Periodontics, the Catholic University of Korea College of Medicine, Seoul 06591, South Korea

Corresponding author: Jaeyoung Chun, MD, Assistant Professor, Department of Internal Medicine, Gangnam Severance Hospital, Yonsei University College of Medicine, Yeonju-ro 63-gil, Gangnam-gu, Seoul 06229, South Korea. chunjmd@yuhs.ac

Abstract

BACKGROUND

Periodontitis is a chronic inflammation of periodontal tissues. The effect of periodontitis on the development of inflammatory bowel disease (IBD) remains unclear.

AIM

To assessed the risk of IBD among patients with periodontitis, and the risk factors for IBD related to periodontitis.

METHODS

A nationwide population-based cohort study was performed using claims data from the Korean National Healthcare Insurance Service. In total, 9950548 individuals aged ≥ 20 years who underwent national health screening in 2009

were included. Newly diagnosed IBD [Crohn's disease (CD), ulcerative colitis (UC)] using the International Classification of Disease 10th revision and rare intractable disease codes, was compared between the periodontitis and non-periodontitis groups until 2017.

RESULTS

A total of 1092825 individuals (11.0%) had periodontitis. Periodontitis was significantly associated with older age, male gender, higher body mass index, quitting smoking, not drinking alcohol, and regular exercise. The mean age was 51.4 ± 12.9 years in the periodontitis group and 46.6 ± 14.2 years in the non-periodontitis group ($P < 0.01$), respectively. The mean body mass index was 23.9 ± 3.1 and 23.7 ± 3.2 in the periodontitis and non-periodontitis groups, respectively ($P < 0.01$). Men were 604307 (55.3%) and 4844383 (54.7%) in the periodontitis and non-periodontitis groups, respectively. The mean follow-up duration was 7.26 years. Individuals with periodontitis had a significantly higher risk of UC than those without periodontitis [adjusted hazard ratio: 1.091; 95% confidence interval (CI): 1.008-1.182], but not CD (adjusted hazard ratio: 0.879; 95% confidence interval: 0.731-1.057). The risks for UC were significant in the subgroups of age ≥ 65 years, male gender, alcohol drinker, current smoker, and reduced physical activity. Current smokers aged ≥ 65 years with periodontitis were at a 1.9-fold increased risk of UC than non-smokers aged ≥ 65 years without periodontitis.

CONCLUSION

Periodontitis was significantly associated with the risk of developing UC, but not CD, particularly in current smokers aged ≥ 65 years.

Key Words: Inflammatory bowel disease; Periodontitis; Smoking; Ulcerative colitis; Crohn's disease

Core Tip: We evaluate the impact of periodontitis on the development of ulcerative colitis (UC) using the nationwide population-based cohort data. In total, 9950548 individuals undergoing national health screenings in 2009 were included in this study and were followed for an average of 7.26 years. Patients with periodontitis had a higher risk of UC than those without periodontitis. Current smokers over 65 years with periodontitis were at a 1.9-fold increased risk of UC than non-smokers without periodontitis. Periodontitis was significantly associated with the risk of UC and cigarette smoking could superimpose the impact of periodontitis on UC, especially in elderly people.

Citation: Kang EA, Chun J, Kim JH, Han K, Soh H, Park S, Hong SW, Moon JM, Lee J, Lee HJ, Park JB, Im JP, Kim JS. Periodontitis combined with smoking increases risk of the ulcerative colitis: A national cohort study. *World J Gastroenterol* 2020; 26(37): 5661-5672
URL: https://www.wjgnet.com/1007-9327/full/v26/i37/5661.htm
DOI: https://dx.doi.org/10.3748/wjg.v26.i37.5661

INTRODUCTION

Periodontitis is a chronic infectious and inflammatory disease of periodontal tissues caused by interactions between the microbiota in the root canals and the host immune system[1]. Periodontitis can be caused by a variety of etiologies, such as alveolar bone destruction, dental plaque bacteria, remnant food material, and an abnormal immune response[2]. The prevalence of periodontitis ranges from 20% to 50% globally and increases with age[3,4]. Risk factors for periodontitis, such as smoking and alcohol consumption, diabetes mellitus, obesity, and metabolic syndrome, have been reported in previous studies[5,6]. Furthermore, periodontitis is closely linked to the pathogenesis of systemic disease[7,8].

Inflammatory bowel diseases (IBD), including Crohn's disease (CD) and ulcerative colitis (UC) are chronic relapsing inflammatory diseases of the gastrointestinal tract with many causes. Complex interactions among gut dysbiosis, changes in the host

subjects' information in the database was de-identified before the investigator accessed the data, thus informed consent was waived.

Conflict-of-interest statement: The authors declare no conflicts of interest for this article.

Data sharing statement: No additional data are available

STROBE statement: The authors have read the STROBE Statement-checklist of items, and the manuscript was prepared and revised according to the STROBE Statement-checklist of items.

Manuscript source: Unsolicited manuscript

Received: May 18, 2020
Peer-review started: May 18, 2020
First decision: July 29, 2020
Revised: August 7, 2020
Accepted: September 16, 2020
Article in press: September 16, 2020
Published online: October 7, 2020

P-Reviewer: Ramakrishna B, Sales-Campos H
S-Editor: Gao CC
L-Editor: A
P-Editor: Li JH

immune system, and genetic factors affect the development of IBD. In Asia, the prevalence of IBD is rapidly increasing, and its genetic predisposition and environmental impact is different from that of western countries[9]. Environmental factors such as smoking and alcohol consumption can be associated with the development of IBD. The effects of smoking on the pathogenesis of CD and UC are different. Smoking may have a minor role in the development of CD in Asia, unlike western populations[10]. In contrast, former smokers have a significantly higher risk of developing UC than non-smokers[11]. Alcohol consumption is related to exacerbation of symptoms in patients with IBD[12].

The destruction of periodontal tissues might induce activation of a variety of cytokines related to the pathophysiology of IBD[13]. In addition, changes in the gut microbiota and immunosuppressive agents used to treat IBD can deteriorate oral health *via* changes in the oral microbiota, resulting in an increased risk for periodontitis[14,15]. Periodontitis and IBD are characterized by chronic inflammation initiated in the oro-intestinal tract, and share a number of similar pathophysiological features. However, the pathogenic relationship between periodontitis and IBD remains unclear. Epidemiological studies regarding the effects of periodontitis based on age and environmental factors on the occurrence of IBD are lacking. The aims of the study were to assess the incidence and risk of IBD among patients with periodontitis and identify the risk factors for the occurrence of IBD related to periodontitis.

MATERIALS AND METHODS

Database

The National Health Insurance (NHI) service is a single, mandatory medical insurer providing a health insurance to approximately 51 million citizens in South Korea. The NHI database contains information on comorbidities, drug prescriptions, treatment, and demographic characteristics of Koreans due to the unique nature of the NHI service. The National Health Screening Program (NHSP) is conducted every 2 years for all qualified adults > 20 years of age, and the information collected by the NHSP accumulates as a separate cohort. Clinical data at baseline and trends in changes in the data can be evaluated in the cohort. The Rare and Intractable Diseases (RID) system supports additional medical costs for patients with RIDs, such as IBD. We identified the RIDs with a special diagnostic code (V code). CD is a rare disease, and UC is regarded as an intractable disease in South Korea.

Study population

This was a nationwide population-based retrospective cohort study using the NHI claims data from a population who underwent the NHSP in 2009 (index year). Patients were classified into the periodontitis group when the International Classification of Diseases (ICD)-10 code for periodontitis (K05.3) was identified at the index examination. The periodontitis group was divided into three stages according to the severity of periodontitis based on therapeutic procedures, including scaling, sub-gingival curettage, and surgery. Individuals without periodontitis were considered the non-periodontitis group. In both groups, patients who were diagnosed with IBD from 2004 to 2009 were excluded to rule out IBD cases not related to periodontitis (washout period). Newly diagnosed IBD patients in the first year after the index year were also excluded (lag period). Patients who were newly diagnosed with periodontitis during the follow-up period in the non-periodontitis group were censored in this study.

Definition and data acquisition

Age, sex, body mass index (BMI), waist circumference, cigarette smoking, alcohol drinking, exercise, income, comorbidities, and laboratory findings were collected in the periodontitis and non-periodontitis groups. Smoking was classified as current smoker, ex-smoker, and nonsmoker based on a questionnaire[11]. Current smokers were defined as those who had smoked more than five packs of cigarettes throughout their lives and continued cigarette smoking. Ex-smokers were defined as those who had smoked more than five packs of cigarettes but quit smoking at least 1 mo ago. Non-smokers were defined as those who had no experience with cigarette smoking or had smoked less than five packs throughout their lifetime. Alcohol drinking was categorized into non-drinker, mild, and excessive drinker. The excessive drinker was defined as consuming more than 30 g per day of alcohol[16]. Exercise was considered 'yes' according to the questionnaire when the participant performed moderate-intensity exercise for 30 min or vigorous-intensity exercise for 20 min at least once per

week[17]. Obesity was defined as BMI > 25 kg/m^2, and central obesity was defined as a waist circumference > 90 cm in males and > 85 cm in females. Hypertension was defined as blood pressure ≥ 140/90 mmHg, or ICD-10 code (I10-13, I15) and a prescription for anti-hypertensive medication[18,19]. Diabetes was identified using an ICD-10 code (E11-14) and anti-diabetic medication or fasting glucose levels ≥ 126 g/dL[16]. Dyslipidemia was defined using ICD-10 code (E78) and taking one of the lipid-lowering agents, or a total cholesterol level ≥ 240 mg/dL. Laboratory data, including serum glucose, total cholesterol, gamma glutamyltransferase and triglyceride levels, were also collected.

End points

The study population was followed up from the index date to December 31, 2017. Newly diagnosed IBD was the study endpoint. IBDs, including CD and UC were identified with the ICD-10 code (K50 for CD and K51 for UC) and the V code for RIDs (V130 for CD and V131 for UC), as defined previously[11,16,18-25]. The risk for IBD was compared between the periodontitis and non-periodontitis groups, according to age, sex, smoking, alcohol drinking, exercise, obesity, and central obesity. In addition, we investigated the specific risk groups for developing UC in a subgroup analysis. This study was approved by International Review Board of Seoul National University Hospital (H-1703-107-840) and the Korean NHI.

Statistical analysis

Base characteristics of study population were analyzed by χ^2 test for categorical variables and Student's *t*-test for continuous variables. The incidence rate was represented by incident cases of IBD per 100000 person-years. Cumulative incidence probability of CD and UC was shown using Kaplan-Meyer methods and the log-rank test. Hazard ratio (HR) of CD and UC in the periodontitis and non-periodontitis groups was calculated using Cox-proportional hazard models adjusted by age, sex, smoking, alcohol drinking, exercise, BMI, and income. A P value less than 0.05 is considered significant. SAS version 9.3 (SAS Institute, Cary, NC, United States) was used for statistical analyses.

RESULTS

Baseline characteristics of the study population

A total of 9950548 participants were included in this study. Among them, 1092825 subjects (11.0%) had periodontitis. The demographic characteristics and baseline laboratory profile are shown in Table 1. Mean age was 51.4 ± 12.9 years in the periodontitis group and 46.6 ± 14.2 years in the non-periodontitis group, respectively (P < 0.0001). The periodontitis group was significantly older, had a higher proportion of males, and a higher BMI and waist circumference than those in the non-periodontitis group (P < 0.0001 for each variable). Patients with periodontitis had significantly higher proportions of individuals quitting smoking, not drinking alcohol, but performing regular exercise, compared with the non-periodontitis group (P < 0.0001 for each variable). Comorbid hypertension and diabetes were significantly associated with periodontitis (P < 0.0001 for each variable). Serum glucose, total cholesterol, gamma glutamyltransferase, and triglyceride levels were significantly higher in the periodontitis group than the non-periodontitis group (P < 0.0001 for each variable).

Risk of developing IBD

The mean follow-up duration was 7.26 ± 0.76 years. The incidence rate values of UC represented by newly diagnosed cases per 100000 person-years were 7.1 and 7.7 in the non-periodontitis and periodontitis groups, respectively (Table 2). The cumulative incidence of UC was significantly higher in the periodontitis group than in the non-periodontitis group (P < 0.0001) (Figure 1). The HR of UC adjusted for age, sex, BMI, smoking, alcohol drinking, exercise, and income was 1.091 [95% confidence interval (CI): 1.008–1.182] in the periodontitis group. However, periodontitis did not increase the risk of CD compared with not having periodontitis (adjusted HR: 0.879; 95%CI: 0.731–1.057). The HRs of UC and CD in the periodontitis group did not differ significantly from those in the non-periodontitis group (data not shown).

Subgroup analysis

A subgroup analysis of the comparative risk for developing UC and CD was

Table 1 Baseline characteristics of the study population

	Periodontitis	Non-periodontitis	*P* value
Patients, *n*	1092825	8857723	
Age, yr (mean ± SD)	51.4 ± 12.9	46.6 ± 14.2	< 0.01
Age, 3 groups (%)			< 0.01
20-39	188805 (17.2)	2929998 (33.1)	
40-64	719197 (65.8)	4810132 (54.3)	
≥ 65	184823 (16.9)	1117593 (12.6)	
Male (%)	604307 (55.3)	4844383 (54.7)	
BMI, kg/m^2 (mean ± SD)	23.9 ± 3.1	23.7 ± 3.2	< 0.01
Waist circumference, cm (mean ± SD)	81.2 ± 8.8	80.1 ± 9.1	< 0.01
Cigarette smoking (%)			< 0.01
Nonsmoker	644790 (59.0)	5276142 (59.6)	
Ex-smoker	188825 (17.3)	1238268 (14.0)	
Current smoker	259210 (23.7)	2343313 (26.4)	
Drinking (%)			< 0.01
Non	597901 (54.7)	4528675 (51.1)	
Mild	423429 (38.8)	3718,835 (42.0)	
Heavy	71495 (6.5)	610213 (6.9)	
Exercise; yes (%)	572684 (52.4)	4544197 (51.3)	< 0.01
Income; low (less than 20% of total population) (%)	274356 (25.1)	2347661 (26.5)	< 0.01
Underlying illness			< 0.01
Hypertension (%)	338855 (31.0)	2220906 (17.8)	
Systolic BP, mmHg (mean ± SD)	123.1 ± 15.0	122.3 ± 14.9	
Diastolic BP, mmHg (mean ± SD)	76.6 ± 10.0	76.3 ± 10.0	
Dyslipidemia (%)	244342 (22.4)	1574251 (17.8)	
Diabetes (%)	131663 (12.1)	734481 (8.3)	
Initial laboratory findings			
Glucose, mg/dL (mean ± SD)	99.6 ± 25.3	96.8 ± 22.6	< 0.01
Total cholesterol, mg/dL (mean ± SD)	196.8 ± 37.0	191.7 ± 35.4	< 0.01
GGT, IU/L (median and 95%CI)	28.5 (28.4–28.6)	27.4 (27.4–27.42)	< 0.01
Triglycerides, mg/dL (median and 95%CI)	117.9 (117.7–117.9)	113.2 (113.1–113.2)	< 0.01

SD: Standard deviation; BMI: Body mass index; BP: Blood pressure; GGT: Gamma glutamyltransferase; CI: Confidence interval.

performed based on age, sex, alcohol drinking, cigarette smoking, and exercise (Figure 2A and B). We compared the risk of developing UC between the periodontitis and non-periodontitis groups by dividing the two groups into three subgroups according to age: < 40 years, 40-64 years, and > 65 years. The significant comparative risk of developing UC was found only in the subgroup > 65 years (adjusted HR: 1.292; 95%CI: 1.033-1.615). The risk of UC in male patients with periodontitis was significantly higher than those without periodontitis (adjusted HR: 1.117; 95%CI: 1.015–1.229), but not in females. Significantly increased risks of developing UC were detected in the periodontitis group among the subgroups with excessive alcohol drinking (adjusted HR: 1.593; 95%CI: 1.221-2.079), current smoking (adjusted HR: 1.255; 95%CI: 1.079-1.461), and no regular exercise (adjusted HR: 1.205; 95%CI: 1.076-1.349). Periodontitis did not significantly increase the risk of developing UC among the subpopulations with obesity and central obesity.

Table 2 The incidence and risk for inflammatory bowel disease in patients with periodontitis

		UC			CD		
	n	UC	IR	aHR (95%CI)	CD	IR	aHR (95%CI)
Periodontitis							
No	8857723	5224	7.1433	1 (ref.)	1300	1.7773	1 (ref.)
Yes	1092825	692	7.6730	1.091 (1.008-1.182)	126	1.3968	0.879 (0.731-1.057)

The incidence rate is represented by incident cases of ulcerative colitis or Crohn's disease per 100000 person-years. The hazard ratio was adjusted for age, sex, body mass index, smoking, alcohol drinking, exercise, and income. UC: Ulcerative colitis; CD: Crohn's disease; IR: Incidence rate; aHR: Adjusted hazard ratio; CI: Confidence intervals.

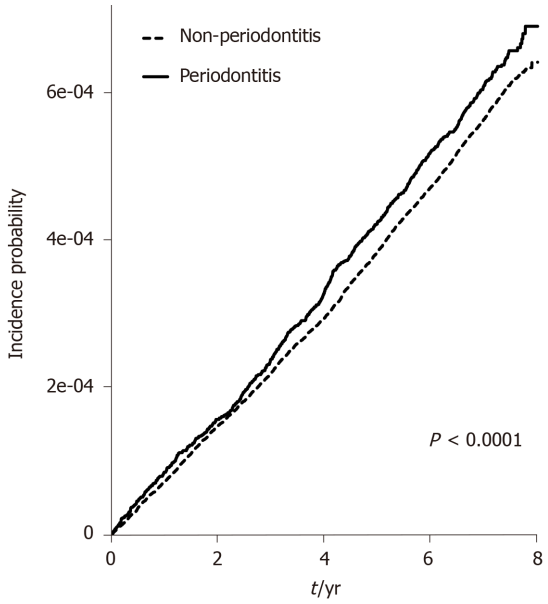

Figure 1 Cumulative incidence of ulcerative colitis in patients with and without periodontitis.

Risks of developing UC according to cigarette smoking behavior

We investigated the risks of developing UC in the periodontitis and non-periodontitis groups, respectively, according to smoking behavior (Figure 3). Ex-smokers in both groups had the highest risks of developing UC compared to nonsmokers without periodontitis, but the difference in the adjusted HRs between the periodontitis (adjusted HR: 1.667; 95%CI: 1.425-1.950) and non-periodontitis groups (adjusted HR: 1.740; 95%CI: 1.606-1.884) among ex-smokers was not significant. However, current smokers in the periodontitis group (adjusted HR: 1.255; 95%CI: 1.078-1.462) had a significantly higher risk of developing UC, but not those in the non-periodontitis group (adjusted HR: 0.946; 95%CI: 0.874–1.025) compared to nonsmokers without periodontitis. A significant difference in adjusted HRs was observed between the periodontitis and non-periodontitis groups among current smokers (Figure 3A). The significant risk of developing UC in current smokers with periodontitis (adjusted HR: 1.924; 95%CI: 1.197–3.092) was more pronounced in the elderly subgroup > 65 years than in nonsmokers without periodontitis (Figure 3B and C).

DISCUSSION

This population-based cohort study of approximately 10 million individuals reported that periodontitis significantly increased the risk of developing UC, but not CD, compared to those without periodontitis. The effect of periodontitis on the risk of developing UC was prominent, particularly among elderly male current smokers who drank alcohol and participated in reduced physical activity. In particular, current

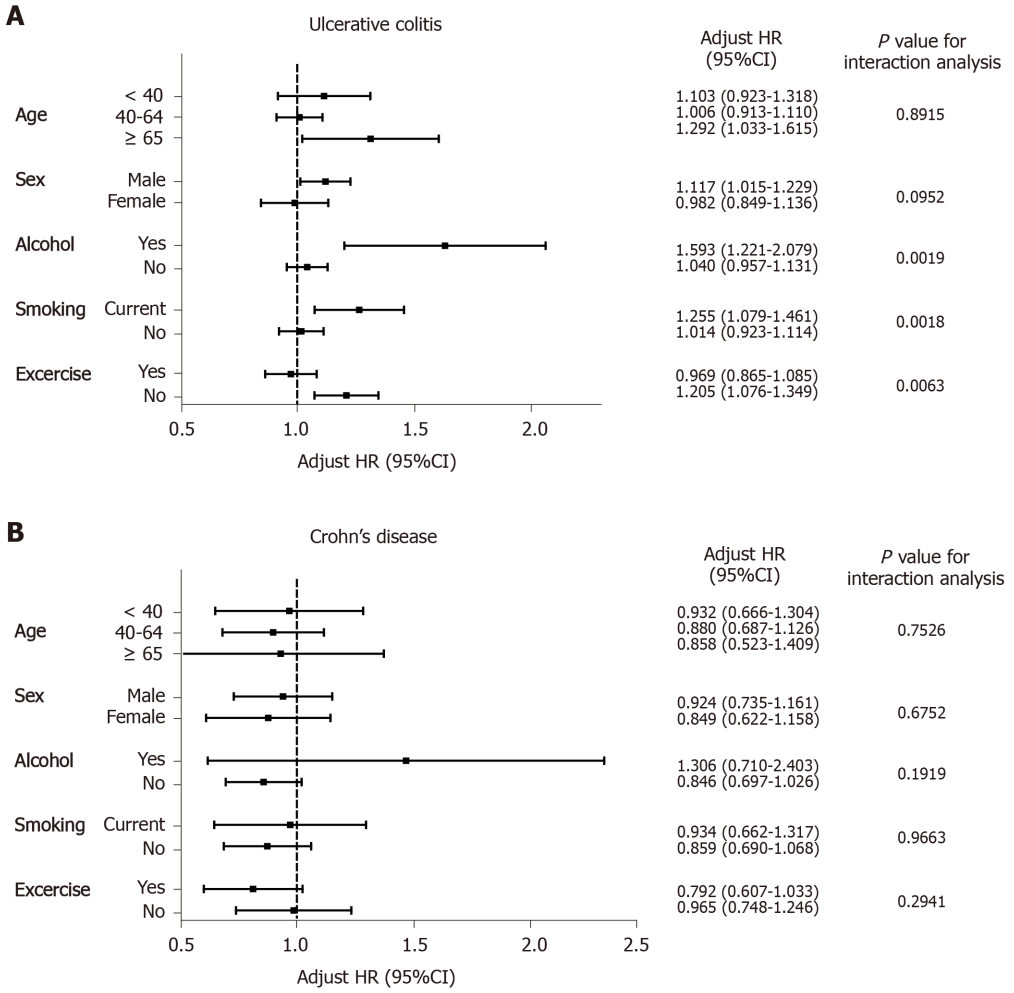

Figure 2 Subgroup analysis of the comparative risk of ulcerative colitis and Crohn's disease in patients with periodontitis compared with those without periodontitis. Error bars represent 95% confidence intervals. A: Ulcerative colitis; B: Crohn's disease. HR: Hazard ratio; CI: Confidence interval.

smoking and the presence of periodontitis had a synergistic effect on the occurrence of UC in the elderly. To the best of our knowledge, this is the largest epidemiological study demonstrating the impact of periodontitis on the development of IBD based on demographic and environmental factors.

The risk for periodontitis among patients with IBD has been reported in recent studies[15,26-28]. In a matched-cohort study demonstrating the prevalence and relative risk of periodontitis, patients with CD were at a 1.36-fold increased risk for periodontitis than controls[29]. The relative risk of periodontitis is also significantly higher in patients with UC[30], especially in smokers[31], which suggests that periodontitis is an oral manifestation of IBD. Periodontitis may occur as a complication of IBD itself or as an adverse event related to IBD therapeutic agents. Changes in the host immune system in patients with a systemic disease may affect oral mucosal immunity. Subgingival microflora changes have been detected in patients with IBD and periodontitis[32], and dysregulation of the host immune system, such as in Th17 cells and the interleukin (IL)-23/IL-17 axis have been proposed to be involved in the pathophysiology of periodontitis related to IBD[33].

In contrast, there is little evidence regarding the risk of developing IBD in patients with periodontitis. A Taiwanese cohort study reported a 1.56-fold significantly higher risk of UC, but not CD, in 27000 patients with periodontal diseases, including acute periodontitis, chronic periodontitis, and gingivitis[34], which is comparable with our results in a nationwide study of 1 million subjects with chronic periodontitis. Our study has the strength of demonstrating the impacts of chronic periodontitis, which may reflect the dynamics of chronic inflammatory conditions and lifestyle factors, such as cigarette smoking, on the pathogenesis of IBD. Taken together, the risk of developing UC increased significantly in patients with periodontitis, although the relatively low HR for UC in the periodontitis group needs to be evaluated by epidemiologic studies in other countries.

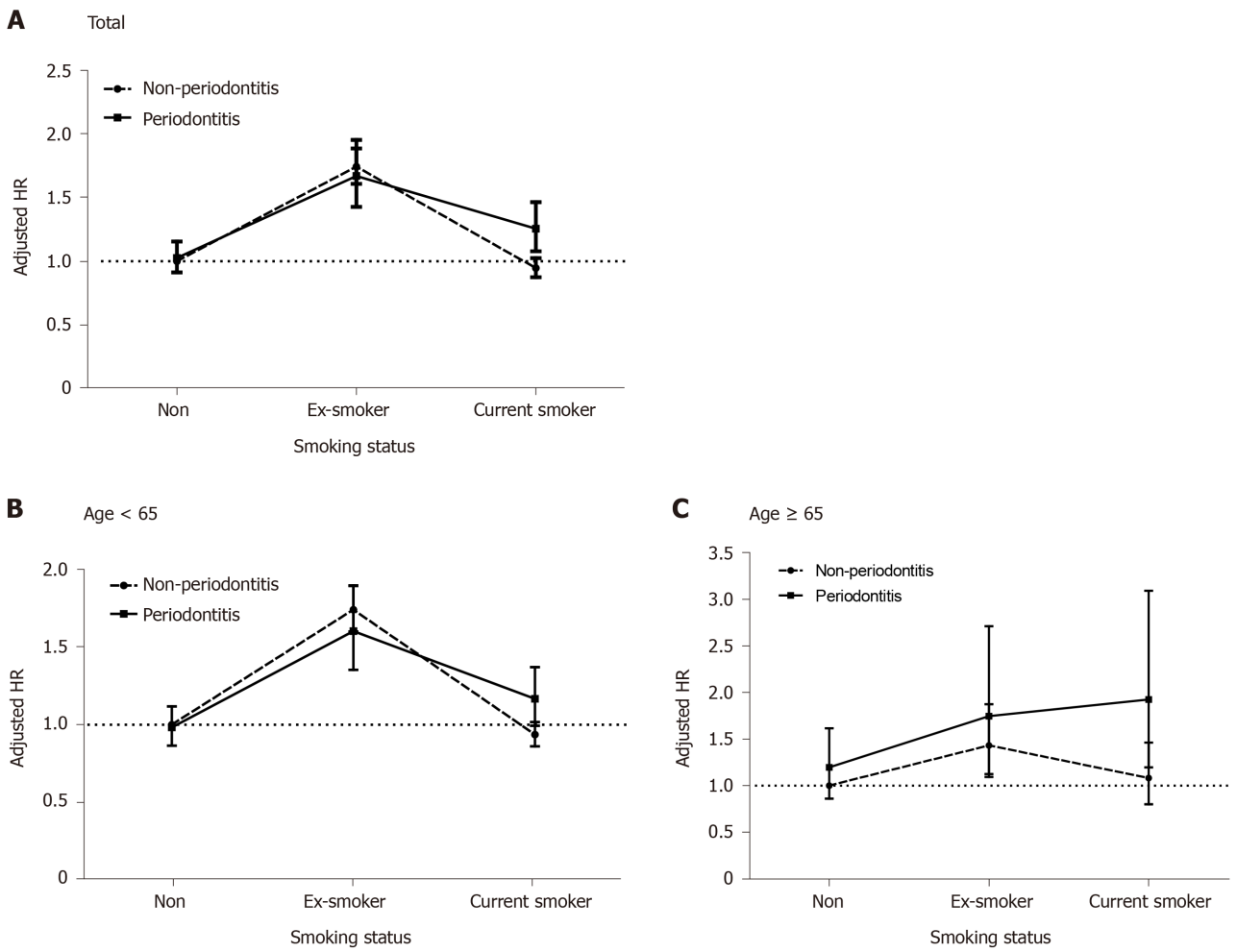

Figure 3 The risk for developing ulcerative colitis with age and cigarette smoking behavior in the periodontitis and non-periodontitis groups. Error bars represent 95% confidence intervals. A: All ages; B: Age < 65; C: Age ≥ 65. HR: Hazard ratio.

The effect of periodontitis on the pathogenesis of UC may be associated with dysbiosis in the oral and intestinal microenvironments[35]. The role of the gut microbiota is critical in the pathogenesis of IBD in terms of nutrition, host immune response, and defense[36]. UC is associated with reduced microbial diversity and depletion of *Bacteroidetes* and *Firmicutes* in the gastrointestinal tract. Gut dysbiosis in IBD, particularly UC, is associated with changes in the salivary microbiome[37]. Therefore, oral hygiene and biofilms related to periodontitis might affect the initiation and perpetuation of inflammation *via* dysbiosis in the colon. In contrast, the dynamic interactions between the oral microenvironment and the development of intestinal inflammation in patients with CD are weak. In a recent population-based cohort study in Sweden, dental plaques were negatively associated with a 68% reduced risk of CD[38]. The dynamic impacts of oral hygiene on dysbiosis and chronic inflammation in the gastrointestinal tract should be clarified in further research.

We determined that the risk groups for UC related to periodontitis were elderly, male, alcohol drinking, current smoking, and reduced physical activity. These demographic and lifestyle factors that can alter oral hygiene have crucial effects on the development of UC among patients with periodontitis. Cigarette smoking may have a protective effect on the development of UC, while quitting smoking increases the risk of developing UC[39-42]. However, smoking and smoking cessation was not associated with disease course of UC[42]. Recent studies have demonstrated a dose-response relationship between quitting smoking and the risk of developing UC[11,43]. In line with previous results, ex-smokers had the highest risk of developing UC, regardless of the presence of periodontitis and age in this study. In contrast, current smoking effect on the prevention of UC is still controversial depending on subgroups such as ethnicity and gender. Interestingly, the comparative risk of developing UC in the elderly tended to be more pronounced in current smokers than in ex-smokers, suggesting that the synergistic effects of periodontitis and cigarette smoking increase the risk of elderly

onset UC. Cigarette smoking causes changes in both oral and intestinal microbial composition[44,45], and may play a key role as an environmental cause of UC *via* oral and gut dysbiosis. Cigarette smoking affects microbial diversity and composition resulting in decreases in *Proteobacteria* and *Bacteroidetes* and increases in *Firmicutes*[46]. A *Treponema denticola* infection is frequently detected in current smokers with periodontal disease[47]. Further research is needed to determine the combined effects of cigarette smoking and periodontitis on the pathogenesis of elderly onset UC, in terms of oral dysbiosis.

The incidence of UC shows a bimodal distribution in the age at onset[48-51], and the second peak of incidence in the elderly is closely related to the environmental etiologies of UC. Surprisingly, the age-specific incidence of UC is in a steady state between the ages of the 20 s to 60 s with the highest rates for men in their 60 s in a recent 30-year follow-up epidemiological study from South Korea[50]. The consistent evidence of ex-smokers related to the risk of UC development and the harmful synergistic effects of current cigarette smoking and periodontitis in the elderly provide an important clue to explain the role of environmental etiologies in the complex pathophysiology of elderly onset UC.

The present study had several limitations due to its retrospective design. First, the severity and disease extent of IBD could not be investigated. Second, the risk of developing IBD among patients with periodontitis was not adjusted by medication. Antibiotics are possible confounders in the relationship between periodontitis and IBD but are generally used within a short period in actual practice in this general population. It is assumed that the chaotic effects of antibiotics might be minimized considering the median follow-up period of more than 7 years. Use of corticosteroids and immunomodulatory agents could not be also identified due to the limitations of claims data. Third, the operational definition for the severity of periodontitis was not validated, although there was no significant difference in the comparative risk of developing UC based on the severity of periodontitis. Further prospective research is required to assess how the severity of periodontitis and oral dysbiosis affect the risk of developing UC.

CONCLUSION

Periodontitis was significantly associated with the risk of developing UC, but not CD. Current smoking superimposed the impacts of periodontitis on the occurrence of elderly onset UC. These findings suggest that adding cigarette smoking in the background of periodontitis are potential risk factors for elderly onset UC.

ARTICLE HIGHLIGHTS

Research background

Environmental factors in addition to genetic and immunological factors are known to influence on the development of inflammatory bowel disease (IBD) including Crohn's disease (CD) and ulcerative colitis (UC). The effects of etiologies such as smoking, alcohol consumption, age and comorbidities on the occurrence of chronic intestinal inflammation may vary based on race and gender.

Research motivation

Gut dysbiosis is associated with IBD as a cause or result and is related to oral microflora. Oral disease can occur as an extra-intestinal manifestation of IBD. However, the risk of developing IBD in patients with periodontitis remains unclear.

Research objectives

We aimed to evaluate the risk of developing IBD in patients with periodontitis and to determine the combined effect of risk factors on the development of IBD associated with periodontitis.

Research methods

Using database of the National Health Insurance and National Health Screening Program in South Korea in 2009, we compared people with and without periodontitis and evaluated newly diagnosed IBD in both group during follow-up period until 2017.

All 9950548 people over the age of 20 who received a national health check in 2009 were included. Periodontitis was defined using the International Classification of Disease 10th revision (ICD-10). CD and UC were defined using ICD-10 and rare intractable disease codes specific to South Korea.

Research results

Out of 9950548 individuals, a total of 1092825 subjects (11.0%) had periodontitis. The periodontitis group was older and had a higher male proportion. During the median follow-up period of 7.26 years, people with periodontitis had a significantly higher risk of developing UC than those without periodontitis. In a subgroup analysis, current smokers aged 65 and older with periodontitis had a 1.9-fold increase in UC risk than non-smokers aged 65 and older without periodontitis.

Research conclusions

Periodontitis is highly associated with the risk of developing UC, especially in current smokers over 65. It suggests that periodontitis and current smoking are a potential combined risk factor for the development of elderly-onset UC.

Research perspectives

Based on the results of this study, we need future prospective studies to focus on the synergistic impacts of the environmental risk factors on elderly onset UC in terms of complex interaction of oral and intestinal microflora. Ultimately, it can lead to a better understanding of the pathogenesis of IBD.

REFERENCES

1 **Slots J**. Periodontitis: facts, fallacies and the future. *Periodontol 2000* 2017; **75**: 7-23 [PMID: 28758294 DOI: 10.1111/prd.12221]

2 **Meyle J**, Chapple I. Molecular aspects of the pathogenesis of periodontitis. *Periodontol 2000* 2015; **69**: 7-17 [PMID: 26252398 DOI: 10.1111/prd.12104]

3 **Eke PI**, Dye BA, Wei L, Slade GD, Thornton-Evans GO, Borgnakke WS, Taylor GW, Page RC, Beck JD, Genco RJ. Update on Prevalence of Periodontitis in Adults in the United States: NHANES 2009 to 2012. *J Periodontol* 2015; **86**: 611-622 [PMID: 25688694 DOI: 10.1902/jop.2015.140520]

4 **Eke PI**, Wei L, Borgnakke WS, Thornton-Evans G, Zhang X, Lu H, McGuire LC, Genco RJ. Periodontitis prevalence in adults ≥ 65 years of age, in the USA. *Periodontol 2000* 2016; **72**: 76-95 [PMID: 27501492 DOI: 10.1111/prd.12145]

5 **Albandar JM**. Epidemiology and risk factors of periodontal diseases. *Dent Clin North Am* 2005; **49**: 517-532, v-vi [PMID: 15978239 DOI: 10.1016/j.cden.2005.03.003]

6 **Genco RJ**, Borgnakke WS. Risk factors for periodontal disease. *Periodontol 2000* 2013; **62**: 59-94 [PMID: 23574464 DOI: 10.1111/j.1600-0757.2012.00457.x]

7 **Michaud DS**, Fu Z, Shi J, Chung M. Periodontal Disease, Tooth Loss, and Cancer Risk. *Epidemiol Rev* 2017; **39**: 49-58 [PMID: 28449041 DOI: 10.1093/epirev/mxx006]

8 **Tong C**, Wang YH, Chang YC. Increased Risk of Carotid Atherosclerosis in Male Patients with Chronic Periodontitis: A Nationwide Population-Based Retrospective Cohort Study. *Int J Environ Res Public Health* 2019; **16** [PMID: 31344786 DOI: 10.3390/ijerph16152635]

9 **Ng WK**, Wong SH, Ng SC. Changing epidemiological trends of inflammatory bowel disease in Asia. *Intest Res* 2016; **14**: 111-119 [PMID: 27175111 DOI: 10.5217/ir.2016.14.2.111]

10 **Park SC**, Jeen YT. Role of Smoking as a Risk Factor in East Asian Patients with Crohn's Disease. *Gut Liver* 2017; **11**: 7-8 [PMID: 28053297 DOI: 10.5009/gnl16534]

11 **Park S**, Chun J, Han KD, Soh H, Kang EA, Lee HJ, Im JP, Kim JS. Dose-response relationship between cigarette smoking and risk of ulcerative colitis: a nationwide population-based study. *J Gastroenterol* 2019; **54**: 881-890 [PMID: 31093771 DOI: 10.1007/s00535-019-01589-3]

12 **Khasawneh M**, Spence AD, Addley J, Allen PB. The role of smoking and alcohol behaviour in the management of inflammatory bowel disease. *Best Pract Res Clin Gastroenterol* 2017; **31**: 553-559 [PMID: 29195675 DOI: 10.1016/j.bpg.2017.10.004]

13 **Figueredo CM**, Brito F, Barros FC, Menegat JS, Pedreira RR, Fischer RG, Gustafsson A. Expression of cytokines in the gingival crevicular fluid and serum from patients with inflammatory bowel disease and untreated chronic periodontitis. *J Periodontal Res* 2011; **46**: 141-146 [PMID: 20701671 DOI: 10.1111/j.1600-0765.2010.01303.x]

14 **Vasovic M**, Gajovic N, Brajkovic D, Jovanovic M, Zdravkovaic N, Kanjevac T. The relationship between the immune system and oral manifestations of inflammatory bowel disease: a review. *Cent Eur J Immunol* 2016; **41**: 302-310 [PMID: 27833449 DOI: 10.5114/ceji.2016.63131]

15 **Papageorgiou SN**, Hagner M, Nogueira AV, Franke A, Jäger A, Deschner J. Inflammatory bowel disease and oral health: systematic review and a meta-analysis. *J Clin Periodontol* 2017; **44**: 382-393 [PMID: 28117909 DOI: 10.1111/jcpe.12698]

16 **Kang EA**, Han K, Chun J, Soh H, Park S, Im JP, Kim JS. Increased Risk of Diabetes in Inflammatory Bowel Disease Patients: A Nationwide Population-based Study in Korea. *J Clin Med* 2019; **8** [PMID: 30862129 DOI: 10.3390/jcm8030343]

17 **Task Force on Community Preventive Services**. A recommendation to improve employee weight status

through worksite health promotion programs targeting nutrition, physical activity, or both. *Am J Prev Med* 2009; **37**: 358-359 [PMID: 19765508 DOI: 10.1016/j.amepre.2009.07.004]

18 **Park S**, Chun J, Han KD, Soh H, Choi K, Kim JH, Lee J, Lee C, Im JP, Kim JS. Increased end-stage renal disease risk in patients with inflammatory bowel disease: A nationwide population-based study. *World J Gastroenterol* 2018; **24**: 4798-4808 [PMID: 30479466 DOI: 10.3748/wjg.v24.i42.4798]

19 **Soh H**, Chun J, Han K, Park S, Choi G, Kim J, Lee J, Im JP, Kim JS. Increased Risk of Herpes Zoster in Young and Metabolically Healthy Patients with Inflammatory Bowel Disease: A Nationwide Population-Based Study. *Gut Liver* 2019; **13**: 333-341 [PMID: 30602222 DOI: 10.5009/gnl18304]

20 **Lee J**, Im JP, Han K, Kim J, Lee HJ, Chun J, Kim JS. Changes in Direct Healthcare Costs before and after the Diagnosis of Inflammatory Bowel Disease: A Nationwide Population-Based Study. *Gut Liver* 2020; **14**: 89-99 [PMID: 31158951 DOI: 10.5009/gnl19023]

21 **Kim J**, Chun J, Lee C, Han K, Choi S, Lee J, Soh H, Choi K, Park S, Kang EA, Lee HJ, Im JP, Kim JS. Increased risk of idiopathic pulmonary fibrosis in inflammatory bowel disease: A nationwide study. *J Gastroenterol Hepatol* 2020; **35**: 249-255 [PMID: 31420894 DOI: 10.1111/jgh.14838]

22 **Choi K**, Chun J, Han K, Park S, Soh H, Kim J, Lee J, Lee HJ, Im JP, Kim JS. Risk of Anxiety and Depression in Patients with Inflammatory Bowel Disease: A Nationwide, Population-Based Study. *J Clin Med* 2019; **8** [PMID: 31083476 DOI: 10.3390/jcm8050654]

23 **Lee J**, Im JP, Han K, Park S, Soh H, Choi K, Kim J, Chun J, Kim JS. Risk of inflammatory bowel disease in patients with chronic obstructive pulmonary disease: A nationwide, population-based study. *World J Gastroenterol* 2019; **25**: 6354-6364 [PMID: 31754295 DOI: 10.3748/wjg.v25.i42.6354]

24 **Soh H**, Im JP, Han K, Park S, Hong SW, Moon JM, Kang EA, Chun J, Lee HJ, Kim JS. Crohn's disease and ulcerative colitis are associated with different lipid profile disorders: a nationwide population-based study. *Aliment Pharmacol Ther* 2020; **51**: 446-456 [PMID: 31691306 DOI: 10.1111/apt.15562]

25 **Park S**, Kim J, Chun J, Han K, Soh H, Kang EA, Lee HJ, Im JP, Kim JS. Patients with Inflammatory Bowel Disease Are at an Increased Risk of Parkinson's Disease: A South Korean Nationwide Population-Based Study. *J Clin Med* 2019; **8** [PMID: 31398905 DOI: 10.3390/jcm8081191]

26 **Poyato-Borrego M**, Segura-Sampedro JJ, Martín-González J, Torres-Domínguez Y, Velasco-Ortega E, Segura-Egea JJ. High Prevalence of Apical Periodontitis in Patients With Inflammatory Bowel Disease: An Age- and Gender- matched Case-control Study. *Inflamm Bowel Dis* 2020; **26**: 273-279 [PMID: 31247107 DOI: 10.1093/ibd/izz128]

27 **Lauritano D**, Boccalari E, Di Stasio D, Della Vella F, Carinci F, Lucchese A, Petruzzi M. Prevalence of Oral Lesions and Correlation with Intestinal Symptoms of Inflammatory Bowel Disease: A Systematic Review. *Diagnostics (Basel)* 2019; **9** [PMID: 31311171 DOI: 10.3390/diagnostics9030077]

28 **Piras V**, Usai P, Mezzena S, Susnik M, Ideo F, Schirru E, Cotti E. Prevalence of Apical Periodontitis in Patients with Inflammatory Bowel Diseases: A Retrospective Clinical Study. *J Endod* 2017; **43**: 389-394 [PMID: 28231978 DOI: 10.1016/j.joen.2016.11.004]

29 **Chi YC**, Chen JL, Wang LH, Chang K, Wu CL, Lin SY, Keller JJ, Bai CH. Increased risk of periodontitis among patients with Crohn's disease: a population-based matched-cohort study. *Int J Colorectal Dis* 2018; **33**: 1437-1444 [PMID: 30003361 DOI: 10.1007/s00384-018-3117-4]

30 **Tan CX**, Brand HS, de Boer NK, Forouzanfar T. Gastrointestinal diseases and their oro-dental manifestations: Part 2: Ulcerative colitis. *Br Dent J* 2017; **222**: 53-57 [PMID: 28084352 DOI: 10.1038/sj.bdj.2017.37]

31 **Brito F**, de Barros FC, Zaltman C, Carvalho AT, Carneiro AJ, Fischer RG, Gustafsson A, Figueredo CM. Prevalence of periodontitis and DMFT index in patients with Crohn's disease and ulcerative colitis. *J Clin Periodontol* 2008; **35**: 555-560 [PMID: 18400026 DOI: 10.1111/j.1600-051X.2008.01231.x]

32 **Brito F**, Zaltman C, Carvalho AT, Fischer RG, Persson R, Gustafsson A, Figueredo CM. Subgingival microflora in inflammatory bowel disease patients with untreated periodontitis. *Eur J Gastroenterol Hepatol* 2013; **25**: 239-245 [PMID: 23060013 DOI: 10.1097/MEG.0b013e32835a2b70]

33 **Bunte K**, Beikler T. Th17 Cells and the IL-23/IL-17 Axis in the Pathogenesis of Periodontitis and Immune-Mediated Inflammatory Diseases. *Int J Mol Sci* 2019; **20** [PMID: 31295952 DOI: 10.3390/ijms20143394]

34 **Lin CY**, Tseng KS, Liu JM, Chuang HC, Lien CH, Chen YC, Lai CY, Yu CP, Hsu RJ. Increased Risk of Ulcerative Colitis in Patients with Periodontal Disease: A Nationwide Population-Based Cohort Study. *Int J Environ Res Public Health* 2018; **15** [PMID: 30469385 DOI: 10.3390/ijerph15112602]

35 **Hajishengallis G**. Periodontitis: from microbial immune subversion to systemic inflammation. *Nat Rev Immunol* 2015; **15**: 30-44 [PMID: 25534621 DOI: 10.1038/nri3785]

36 **Nishida A**, Inoue R, Inatomi O, Bamba S, Naito Y, Andoh A. Gut microbiota in the pathogenesis of inflammatory bowel disease. *Clin J Gastroenterol* 2018; **11**: 1-10 [PMID: 29285689 DOI: 10.1007/s12328-017-0813-5]

37 **Xun Z**, Zhang Q, Xu T, Chen N, Chen F. Dysbiosis and Ecotypes of the Salivary Microbiome Associated With Inflammatory Bowel Diseases and the Assistance in Diagnosis of Diseases Using Oral Bacterial Profiles. *Front Microbiol* 2018; **9**: 1136 [PMID: 29899737 DOI: 10.3389/fmicb.2018.01136]

38 **Yin W**, Ludvigsson JF, Liu Z, Roosaar A, Axéll T, Ye W. Inverse Association Between Poor Oral Health and Inflammatory Bowel Diseases. *Clin Gastroenterol Hepatol* 2017; **15**: 525-531 [PMID: 27392757 DOI: 10.1016/j.cgh.2016.06.024]

39 **Beaugerie L**, Massot N, Carbonnel F, Cattan S, Gendre JP, Cosnes J. Impact of cessation of smoking on the course of ulcerative colitis. *Am J Gastroenterol* 2001; **96**: 2113-2116 [PMID: 11467641 DOI: 10.1111/j.1572-0241.2001.03944.x]

40 **Mahid SS**, Minor KS, Soto RE, Hornung CA, Galandiuk S. Smoking and inflammatory bowel disease: a meta-analysis. *Mayo Clin Proc* 2006; **81**: 1462-1471 [PMID: 17120402 DOI: 10.4065/81.11.1462]

41 **Höie O**, Wolters F, Riis L, Aamodt G, Solberg C, Bernklev T, Odes S, Mouzas IA, Beltrami M, Langholz E, Stockbrügger R, Vatn M, Moum B; European Collaborative Study Group of Inflammatory Bowel Disease (EC-IBD). Ulcerative colitis: patient characteristics may predict 10-yr disease recurrence in a European-wide population-based cohort. *Am J Gastroenterol* 2007; **102**: 1692-1701 [PMID: 17555460 DOI: 10.1111/j.1572-0241.2007.01265.x]

42 **Blackwell J**, Saxena S, Alexakis C, Bottle A, Cecil E, Majeed A, Pollok RC. The impact of smoking and

smoking cessation on disease outcomes in ulcerative colitis: a nationwide population-based study. *Aliment Pharmacol Ther* 2019; **50**: 556-567 [PMID: 31389044 DOI: 10.1111/apt.15390]

43 **Wang P**, Hu J, Ghadermarzi S, Raza A, O'Connell D, Xiao A, Ayyaz F, Zhi M, Zhang Y, Parekh NK, Lazarev M, Parian A, Brant SR, Bedine M, Truta B, Hu P, Banerjee R, Hutfless SM. Smoking and Inflammatory Bowel Disease: A Comparison of China, India, and the USA. *Dig Dis Sci* 2018; **63**: 2703-2713 [PMID: 29862485 DOI: 10.1007/s10620-018-5142-0]

44 **Johannsen A**, Susin C, Gustafsson A. Smoking and inflammation: evidence for a synergistic role in chronic disease. *Periodontol 2000* 2014; **64**: 111-126 [PMID: 24320959 DOI: 10.1111/j.1600-0757.2012.00456.x]

45 **Huang C**, Shi G. Smoking and microbiome in oral, airway, gut and some systemic diseases. *J Transl Med* 2019; **17**: 225 [PMID: 31307469 DOI: 10.1186/s12967-019-1971-7]

46 **Capurso G**, Lahner E. The interaction between smoking, alcohol and the gut microbiome. *Best Pract Res Clin Gastroenterol* 2017; **31**: 579-588 [PMID: 29195678 DOI: 10.1016/j.bpg.2017.10.006]

47 **Kanmaz B**, Lamont G, Danacı G, Gogeneni H, Buduneli N, Scott DA. Microbiological and biochemical findings in relation to clinical periodontal status in active smokers, non-smokers and passive smokers. *Tob Induc Dis* 2019; **17**: 20 [PMID: 31582931 DOI: 10.18332/tid/104492]

48 **Cosnes J**, Gower-Rousseau C, Seksik P, Cortot A. Epidemiology and natural history of inflammatory bowel diseases. *Gastroenterology* 2011; **140**: 1785-1794 [PMID: 21530745 DOI: 10.1053/j.gastro.2011.01.055]

49 **Thia KT**, Loftus EV Jr, Sandborn WJ, Yang SK. An update on the epidemiology of inflammatory bowel disease in Asia. *Am J Gastroenterol* 2008; **103**: 3167-3182 [PMID: 19086963 DOI: 10.1111/j.1572-0241.2008.02158.x]

50 **Park SH**, Kim YJ, Rhee KH, Kim YH, Hong SN, Kim KH, Seo SI, Cha JM, Park SY, Jeong SK, Lee JH, Park H, Kim JS, Im JP, Yoon H, Kim SH, Jang J, Kim JH, Suh SO, Kim YK, Ye BD, Yang SK; Songpa-Kangdong Inflammatory Bowel Disease [SK-IBD] Study Group. A 30-year Trend Analysis in the Epidemiology of Inflammatory Bowel Disease in the Songpa-Kangdong District of Seoul, Korea in 1986-2015. *J Crohns Colitis* 2019; **13**: 1410-1417 [PMID: 30989166 DOI: 10.1093/ecco-jcc/jjz081]

51 **Takahashi H**, Matsui T, Hisabe T, Hirai F, Takatsu N, Tsurumi K, Kanemitsu T, Sato Y, Kinjyo K, Yano Y, Takaki Y, Nagahama T, Yao K, Washio M. Second peak in the distribution of age at onset of ulcerative colitis in relation to smoking cessation. *J Gastroenterol Hepatol* 2014; **29**: 1603-1608 [PMID: 24731020 DOI: 10.1111/jgh.12616]

World Journal of Gastroenterology

Submit a Manuscript: https://www.f6publishing.com

World J Gastroenterol 2020 October 7; 26(37): 5673-5681

DOI: 10.3748/wjg.v26.i37.5673

ISSN 1007-9327 (print) ISSN 2219-2840 (online)

ORIGINAL ARTICLE

Retrospective Study

Preliminary experience of hybrid endoscopic submucosal dissection by duodenoscope for recurrent laterally spreading papillary lesions

Zi-Kai Wang, Fang Liu, Yun Wang, Xiang-Dong Wang, Ping Tang, Wen Li

ORCID number: Zi-Kai Wang 0000-0002-6293-7179; Fang Liu 0000-0002-2013-9881; Yun Wang 0000-0003-0512-5307; Xiang-Dong Wang 0000-0002-7445-9274; Ping Tang 0000-0002-7401-1330; Wen Li 0000-0003-3963-6850.

Author contributions: Wang ZK and Liu F contributed equally to this manuscript; Li W and Wang ZK completed study conception and design, endoscopic operation; Wang ZK and Liu F wrote and edited the manuscript; Wang Y finished pathological analysis; Wang ZK, Liu F, Wang XD, and Tang P completed endoscopic operation, data analysis and interpretation.

Institutional review board statement: The study was reviewed and approved by the Ethics Committee of the PLA General Hospital, No. s2019-274-01.

Informed consent statement: All study participants, or their legal guardian, provided informed written consent.

Conflict-of-interest statement: All authors declare no conflicts-of-interest related to this article.

Data sharing statement: No additional data are available.

Zi-Kai Wang, Fang Liu, Xiang-Dong Wang, Ping Tang, Wen Li, Department of Gastroenterology and Hepatology, The First Medical Center, Chinese PLA General Hospital, Beijing 100853, China

Yun Wang, Department of Pathology, The First Medical Center, Chinese PLA General Hospital, Beijing 100853, Beijing, China

Corresponding author: Wen Li, MD, PhD, Chief Doctor, Department of Gastroenterology and Hepatology, The First Medical Center, Chinese PLA General Hospital, No. 28 Fuxing Road, Haidian District, Beijing 100853, China. liwen2000@yahoo.com

Abstract

BACKGROUND

The management strategies for recurrent ampullary adenoma after endoscopic papillectomy are still controversial. Patients with the recurrent papillary lesions need to receive repetitive endoscopic interventions due to the limitations of conventional endoscopic techniques.

AIM

To assess the feasibility, efficacy, and safety of hybrid endoscopic submucosal dissection (ESD) by duodenoscope for recurrent, laterally spreading papillary lesions.

METHODS

We enrolled two patients with recurrent, laterally spreading, duodenal papillary adenomas with no intraductal extension confirmed by follow-up between March 2017 and September 2018. After marking the resection borders of the lesion using a dual knife, a submucosal cushion was created by injecting a mixture of saline solution, methylene blue, and adrenaline. A total circumferential incision and submucosal excision was performed by dual knife combined with insulated-tip diathermic knife, and then the lesion was ligated and resected using an electric snare. Endoscopic hemostasis was applied during the endoscopic procedures. Moreover, the endoscopic retrograde cholangiopancreatography (ERCP) procedures, including selective cannulation and stent implantation of biliary and pancreatic ducts, were performed. Additionally, we performed endoclip closure for mucosal defect after ESD.

RESULTS

Manuscript source: Unsolicited manuscript

Received: June 15, 2020
Peer-review started: June 15, 2020
First decision: July 25, 2020
Revised: August 8, 2020
Accepted: September 12, 2020
Article in press: September 12, 2020
Published online: October 7, 2020

P-Reviewer: Kishida Y, Weiss H
S-Editor: Gao CC
L-Editor: Filipodia
P-Editor: Li JH

Hybrid ESD using a duodenoscope and biliary and pancreatic stent placement were performed successfully in two patients. The endoscopic size of recurrent papillary lesions was no more than 2 cm. Generally, the average total procedure time was 95.5 min, and the procedure time of ESD and ERCP was 38.5 min and 15.5 min, respectively. No serious complications occurred during the intraoperative and postoperative periods. The histopathological examination revealed tubulovillous adenoma negative for neoplastic extension at the cut margin in both patients. The duodenoscopic follow-up and histopathology of biopsy specimens at 3 mo after ESD showed no residual or recurrent lesions in ampullary areas in both cases. Both cases have been followed up with no recurrence to June 2020.

CONCLUSION

Hybrid ESD by duodenoscope is technically challenging, and may be curative for recurrent, laterally spreading papillary adenomas < 2 cm. It should be performed cautiously in selected patients by experienced endoscopists.

Key Words: Endoscopic submucosal dissection; Ampullary adenoma; Recurrent; Laterally spreading; Papillary lesions

Core Tip: The management strategies for recurrent ampullary adenomas after endoscopic papillectomy are still controversial. Our preliminary experience showed that hybrid endoscopic submucosal dissection by duodenoscope could be feasible for recurrent, laterally spreading ampullary adenomas. Follow-up after hybrid endoscopic submucosal dissection showed no residual or recurrent lesions in ampullary areas. However, it should be performed with caution by experienced endoscopists in selected patients, and the effectiveness should be verified by large-scale studies.

Citation: Wang ZK, Liu F, Wang Y, Wang XD, Tang P, Li W. Preliminary experience of hybrid endoscopic submucosal dissection by duodenoscope for recurrent laterally spreading papillary lesions. *World J Gastroenterol* 2020; 26(37): 5673-5681
URL: https://www.wjgnet.com/1007-9327/full/v26/i37/5673.htm
DOI: https://dx.doi.org/10.3748/wjg.v26.i37.5673

INTRODUCTION

The clinical practice or consensus for endoscopic management of duodenal papillary lesions is not fully established[1]. Several endoscopic resection techniques such as snare polypectomy, endoscopic mucosal resection (EMR) and argon plasma coagulation (APC) ablation are available for papillary lesions[1-3]. Endoscopic resection of the laterally spreading ampullary lesions is difficult technically and usually involves surgery. Moreover, the management strategies for recurrent duodenal papillary adenomas after endoscopic papillectomy are still controversial[2]. Patients with recurrent papillary adenomas need to receive repetitive endoscopic interventions due to the limitations of conventional endoscopic techniques, such as incomplete resection. At present, endoscopic submucosal dissection (ESD) has become common and has gradually replaced most surgical procedures for management of early gastrointestinal neoplasms[4], which could provide a higher *en bloc* resection rate than conventional endoscopic resection techniques. Until now, ESD has rarely been used for the treatment of duodenal papillary lesions by duodenoscope due to the complex anatomy of the duodenal papilla and technical difficulties.

In this paper, we report our preliminary experience of hybrid ESD by duodenoscope combined with biliary and pancreatic stent placement for the treatment of recurrent, laterally spreading, duodenal papillary lesions.

MATERIALS AND METHODS

Patient selection and evaluation

Ten patients with recurrent duodenal papillary adenomatous lesions after endoscopic snare papillectomy were admitted to the Department of Gastroenterology and Hepatology, The First Medical Center of Chinese PLA General Hospital between March 2017 and September 2018. We excluded patients who received endoscopic management using an electric snare or APC ablation for small, locally recurrent adenomas < 1 cm without intraductal growth, and those who underwent pancreatoduodenectomy and/or chemoradiotherapy due to cancerization and ductal infiltration. Finally, we enrolled two patients with recurrent, laterally spreading papillary adenomas confirmed by duodenoscopic and biopsy examination. The patients had undergone hybrid ESD by duodenoscope and subsequent endoscopic retrograde cholangiopancreatography (ERCP). The clinical symptoms and physical and laboratory examination were evaluated. Computed tomography (CT), magnetic resonance imaging, magnetic resonance cholangiopancreatography and abdominal ultrasound were performed preoperatively, and the imaging examinations confirmed no infiltration of tumor into biliary and pancreatic ducts. Moreover, these two patients refused surgical management and gave informed consent.

Materials and equipment

Hybird ESD was performed using a standard duodenoscope (TJF240 or TJF260V; Olympus, Tokyo, Japan). The equipment included a dual knife (KD-650L; Olympus), insulated-tip diathermic (IT) knife II (KD-611L; Olympus), injection needle (NM-200L-0525), hemostatic forceps (FD-410LR; Olympus), electric snare (Cook Medical, Bloomington, IL, United States), endoclips (Olympus), SureClips (Micro-Tech, Nanjing, China), intraductal ultrasound (IDUS) (UM-DG20-31R; Olympus), cannulating sphincterotome (Dreamtome RX, Boston, MA, United States), bile duct stent (10 Fr in diameter, 3-8 cm in length; Cook Medical), pancreatic duct stent (5-7 Fr in diameter, 7-8 cm in length; Cook Medical), and a high-frequency electrosurgical generator (VIO 200D; ERBE, Tubingen, Germany). An endoscopic CO_2 insufflator (UCR; Olympus) was used during the endoscopic procedures. Saline solution with diluted methylene blue, sodium hyaluronate and adrenaline was used for submucosal injection, and 1:10000 diluted epinephrine submucosal injection was used for hemostasis.

Operative procedures

All endoscopic procedures were performed by an experienced endoscopist who had > 20 years' experience in advanced endoscopic techniques and had performed > 2000 ESD and ERCP procedures. Patients were placed in the prone position and underwent intravenous anesthesia. Before ESD, the duodenal papillary lesions were evaluated by white light and narrow band imaging. Hybrid ESD with snaring was performed using a standard duodenoscope. After marking the resection borders of the lesion using a dual knife, a submucosal cushion was created by injecting a mixture of saline solution, methylene blue and adrenaline. A total circumferential incision and submucosal excision were performed by Dual knife combined with IT knife, and the lesion was ligated and resected using an electric snare. The electric coagulation, injection of saline solution with epinephrine and endoclips placement were applied for hemostasis during the endoscopic procedures. After hybrid ESD, ERCP, including selective cannulation of biliary and pancreatic ducts, and IDUS were performed to identify whether there was tumor ductal infiltration. Moreover, stent implantation of the biliary and pancreatic ducts was performed to prevent postoperative complications. Endoclip closure for mucosal defect after hybrid ESD was performed. During the postoperative period, intravenous proton pump inhibitors, somatostatin and antibiotics were given to prevent infection and post-ERCP pancreatitis. Meanwhile, diet was gradually restored if no complications occurred after postoperative fasting for 2-3 d.

Evaluation data

The primary outcome measures included clinical symptoms; physical and laboratory examination; imaging characteristics, especially endoscopic and histopathological characteristics; detailed procedure-related outcome data, including the time of hybrid ESD and ERCP; *en bloc* resection; procedure-related complications; and hospital stay. Endoscopic and histopathological follow-up was performed to assess the presence of duodenal papillary lesions after hybrid ESD procedures.

RESULTS

This study included two patients with recurrent, laterally spreading, duodenal papillary adenomas. The previous characteristics of recurrent cases are listed in Table 1, and the duodenoscopic follow-up confirmed recurrent adenomas located in the therapeutic scar tissues. The main characteristics of all patients are shown in Table 2. Preoperative imaging confirmed no infiltration of tumor into biliary and pancreatic ducts, and the endoscopic findings showed a clear border with no evidence of malignancy, such as ulceration and spontaneous bleeding.

Hybrid ESD combined with ERCP was performed successfully using duodenoscope. The detailed endoscopic procedures are shown in Figures 1 and 2. The average total procedure time was 95.5 min, and the procedure time of hybrid ESD and ERCP was 38.5 min and 15.5 min, respectively. After submucosal injection, the surrounding mucosa of the lesion was lifted, except the central scar tissues. When the circumferential incision was completed, the IT knife was used to dissect the fibrotic area for prevention of perforation. The lesion was ligated and resected *en bloc* using a polypectomy snare. After hybrid ESD, ERCP and IDUS procedures were performed. Selective cannulation, angiography, and IDUS revealed a clear layer of the biliary and pancreatic ducts and no intraductal growth of the lesions in these two patients. Meanwhile, cholangiopancreatography and IDUS revealed common bile duct stones with obvious dilated biliary and pancreatic ducts in case 1, but the stones were not extracted simultaneously, considering the increasing risk of complications. Subsequently, the biliary and pancreatic stents were placed successfully in both cases (Figures 1 and 2, and Table 2). Furthermore, endoscopic clips were deployed for closure of mucosal defects. In both cases, no serious complications occurred during the intraoperative and postoperative periods. Postoperative laboratory tests showed normal routine blood and biochemical examinations, except for transient hyperamylasemia in case 2. Histopathological examination revealed tubulovillous adenoma negative for neoplastic extension at the horizontal and vertical margins in both cases (Figures 1 and 2).

Duodenoscopic and histopathological follow-up was undertaken at 3 mo after hybrid ESD. Endoscopic examination showed no residual or recurrent lesions in ampullary areas in both cases. ERCP showed dilated common bile duct and pancreatic ducts, and the common bile duct stones were extracted successfully in case 1, and the biliary stent was removed in case 2 (Figures 1 and 2). Histopathology of biopsy specimens showed chronic and acute inflammation of small intestinal mucosa with no adenomatous tissues in both cases (Figures 1 and 2). Both cases have been followed up with no recurrence up to June 2020.

DISCUSSION

Duodenal papillary neoplasms are uncommon and occur sporadically with a prevalence of 0.1%-0.2%[5]. The majority of papillary adenomas undergo the adenoma–carcinoma sequence, and complete removal is mandatory for curative therapy due to the malignant potential[6]. Traditionally, recommended surgical management has included pancreaticoduodenectomy and local surgical excision for complete removal of duodenal papillary tumors[7], but surgery often results in extensive resection with significant morbidity and mortality[1]. This is considered overtreatment for some benign duodenal papillary lesions or early noninvasive tumors of the papilla without intraductal growth. Endoscopic papillectomy by snare polypectomy or EMR has the advantages of being less invasiveness, which represents an alternative to surgical resection[1]. At present, it is not definitive which size or endoscopic morphology of ampullary lesions should not be treated by endoscopic resection[2]. Most studies have not recommended endoscopic resection for the duodenal papillary lesions ≥ 3-4 cm or those with extrapapillary extension[8]. Endoscopic snare polypectomy or EMR for ampullary lesions often requires repetitive interventions due to incomplete resection, residual lesion and tumor recurrence. The recurrent rate of ampullary adenomas after endoscopic papillectomy is 7%-33%[9-12]. Our team reported that 13 of 110 patients who underwent endoscopic papillectomy experienced recurrence during a mean follow-up period of 16.3 mo, and the predictive factors related to recurrence were complete resection and final pathological findings[13]. Although 75% of recurrences can be cleared endoscopically[12], surgery is usually the last choice. In our experience, there is still the possibility of multiple recurrence after endoscopic snare polypectomy or APC ablation for recurrent

Table 1 Previous characteristics of patients with recurrent laterally spreading duodenal papillary lesions

Case	Pathological characteristics of initial resected specimen	*En bloc* resection	Complete resection	The first recurrent time (mo)	Time of follow-up (mo)	Previous endoscopic managements
Case 1	Tubulovillous adenoma with local HIN	Yes	Yes	31	96	Endoscopic snare papillectomy, and multiple APC ablation for adenoma recurrence and three ERCP procedures for biliary stones and acute cholangitis
Case 2	Tubulovillous adenoma with local LIN	Yes	Yes	15	15	Endoscopic snare papillectomy

HIN: High-grade intraepithelial neoplasia; LIN: Low-grade intraepithelial neoplasia; APC: Argon plasma coagulation; ERCP: Endoscopic retrograde cholangiopancreatography.

Table 2 Main characteristics of patients in this study

Characteristics	Case 1	Case 2
Age (yr) /sex	54/male	54/female
Clinical symptoms	Negative	Negative
Physical and laboratory examinations	Normal	Normal
Recent endoscopic characteristics	Laterally spreading adenomatous lesion with a diameter of 1.5 cm on the resected scar	A red and protuberant laterally spreading lesion with a diameter of 1 cm on the resected scar
Total procedure time (min)	107	84
Hybrid ESD procedure time (min)	57	30
Bleeding and wound control time (min)	24	22
ERCP procedure time (min)	16	15
ERCP characteristics	No intraductal growth of lesion, but biliary stones with dilated biliary and pancreatic ducts; bile duct stent (10 Fr in diameter, 8 cm in length) and pancreatic stent (7 Fr in diameter, 8 cm in length) placement	No intraductal growth of lesion and no dilatation of biliary and pancreatic ducts; biliary stent (10 Fr in diameter, 3 cm in length) and pancreatic stent (5 Fr in diameter, 7 cm in length) placement
IDUS characteristics	Clear layer of the biliary and pancreatic ducts without intraductal extension; bile duct stones with dilated biliary and pancreatic ducts	Clear layer of the biliary and pancreatic ducts without intraductal extension; no dilatation of biliary and pancreatic ducts
No. of endoscopic clips	2	5
Size of resected specimen (cm)	1.4 × 1.0	2.0 × 1.5
Histology of resected specimen	Tubulovillous adenoma	Tubulovillous adenoma
En blot resection	Yes	Yes
R0 resection	Yes	Yes
Complications	None	Postoperative transient hyperamylasemia
Postoperative hospital stay (d)	4	4

ERCP: Endoscopic retrograde cholangiopancreatography; ESD: Endoscopic submucosal dissection; IDUS: Intraductal ultrasound.

ampullary lesions. This indicates the technical difficulty and limitations of the conventional endoscopic papillectomy for recurrent duodenal papillary lesions.

Preoperative evaluation of ampullary lesions is important for the subsequent management strategy. In this study, preoperative endoscopic findings showed a clear border with no evidence of malignancy, such as ulceration or spontaneous bleeding, and the appropriate ampullary lesion size (≤ 2 cm). Meanwhile, preoperative histopathological examination of biopsy sample revealed papillary adenoma for both cases. Furthermore, endoscopic ultrasonography (EUS) and IDUS are useful diagnostic tools for selecting endoscopic or surgical treatment for ampullary adenomas[14,15]. These methods may be more efficient than CT for preoperative evaluation of local T staging, regional lymph node metastasis, ductal infiltration, and major vascular invasion in patients with ampullary lesions. It is reported that the accuracy of EUS in diagnosing extension into the bile duct and pancreatic duct is as high as 86%-90% and 77%-92%, respectively. IDUS can be more accurate in visualizing mucosal layers than conventional EUS, with a high accuracy of 90%-95% and 88%-100% in diagnosing extension into the bile duct and pancreatic duct, respectively[16]. In our study, both patients received careful preoperative evaluation, and several imaging examinations indicated no intraductal involvement of ampullary lesions. EUS for the estimation of tumor staging and ductal infiltration was not performed routinely in this study, but subsequent ERCP and IDUS confirmed no intraductal extension. Whatever, accurate preoperative evaluation could reduce the technical difficulties and the risk of severe complications[17].

At present, ESD has been widely accepted as standard treatment for early gastrointestinal neoplasms and large laterally spreading lesions[4], and as an appropriate resection technique for locally remnant and recurrent lesions in patients receiving endoscopic resection[18,19]. Several studies have reported successful ESD for duodenal lesions[20-22] using therapeutic gastroscopy, but ESD is rarely used for treatment of recurrent, laterally spreading ampullary lesions by duodenoscope. This is mainly due to the special physiology and complex anatomical features of duodenal papillary lesions (*e.g.*, lesion location, lesion size, thin muscle layer, rich blood supply, secretion of biliary and pancreatic juice, and fibrosis of recurrent lesions), and technical difficulties (*e.g.*, limited operating space and operational difficulties to achieve good endoscopic control and optimal visual fields based on forward-viewing endoscopy)[2]. Meanwhile, ESD for recurrent, laterally spreading ampullary adenomas raises concerns about a high risk of procedure-related complications. Therefore, ESD should be performed by experienced endoscopists with both ERCP and ESD techniques to reduce the risk of severe complications. In our study, all endoscopic procedures were performed by an experienced endoscopist who had > 20 years' experience in advanced endoscopic techniques and had performed > 2000 ESD and ERCP procedures. Carefully attention was focused on endoscopic management for procedure-related complications. Submucosal fibrosis after endoscopic papillectomy for recurrent cases is a significant risk factor for adverse events. Therefore, we used a hybrid ESD technique for complete resection with a polypectomy snare to remove the lesions after dissecting the submucosal layer. Additionally, strict hemostasis including injection, electrocoagulation and endoclip placement during hybrid ESD were compulsory. The resection wound after ampullary hybrid ESD is exposed directly to biliary and pancreatic juices, which is believed to cause postoperative complications, so we suggest that after biliary and pancreatic stent placement, the resection wound should be closed by endoclips as much as possible. In this study, hybrid ESD with snaring using duodenoscope was technically successful, and *en bloc* resection of the therapeutic scar tissue was achieved. The average procedure time of hybrid ESD was 38.5 min, which was acceptable. No severe adverse events such as bleeding and perforation occurred in the recurrent cases.

ERCP as an important procedure and should be performed after ampullary ESD treatment. Generally, it is easy to perform selective cannulation due to the exposure of biliary and pancreatic duct after papillectomy. Limited endoscopic resection of ampullary lesions may have a risk of leaving residual tissues; therefore, ERCP and IDUS are useful for further evaluation of the condition of the biliary and pancreatic ducts. For these cases, selective cannulation for biliary and pancreatic ducts was successfully performed, and ERCP and IDUS demonstrated no biliary or pancreatic extension and no residual lesions after ESD. Prophylactic stent placement in the pancreatic duct after endoscopic removal is necessary to minimize the risk of post-ERCP pancreatitis[23]. In this study, we implanted both biliary and pancreatic stents to avoid early complications and late adverse events. There are four purposes of deploying biliary and pancreatic stenting after ESD: to prevent post-ERCP pancreatitis and cholangitis; to drain bile and pancreatic juice far from the wound surface to reduce

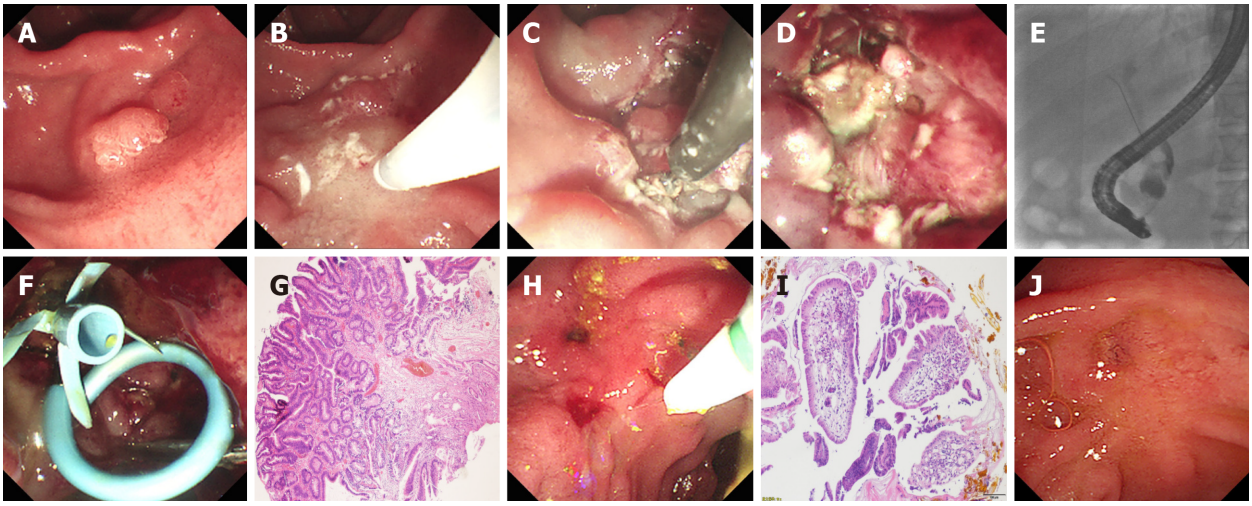

Figure 1 Endoscopic and pathological characteristics of case 1. A-D: Hybrid endoscopic submucosal dissection (ESD) for recurrent, laterally spreading, duodenal papillary adenoma, including marks, submucosal injection and submucosal dissection. The lesion was resected completely using a polypectomy snare, and the artificial ulcer was visible; E: Endoscopic retrograde cholangiopancreatography (ERCP) showed the dilated biliary duct, common bile duct stones, and mildly dilated pancreatic duct; F: Biliary and pancreatic duct stents were implanted, and the endoscopic clips were used for closure of mucosal defects and prevention of complications; G: Hematoxylin and eosin stained resected specimen showing tubulovillous adenoma with a clean cutting edge, 4 ×; H: Endoscopic follow-up 3 mo after hybrid ESD, biliary stent and stones were extracted by ERCP; I: Histological follow-up of biopsy specimen revealed chronic and acute inflammation of small intestinal mucosa, 10 ×; J: Endoscopic follow-up 20 mo after hybrid ESD with no recurrence.

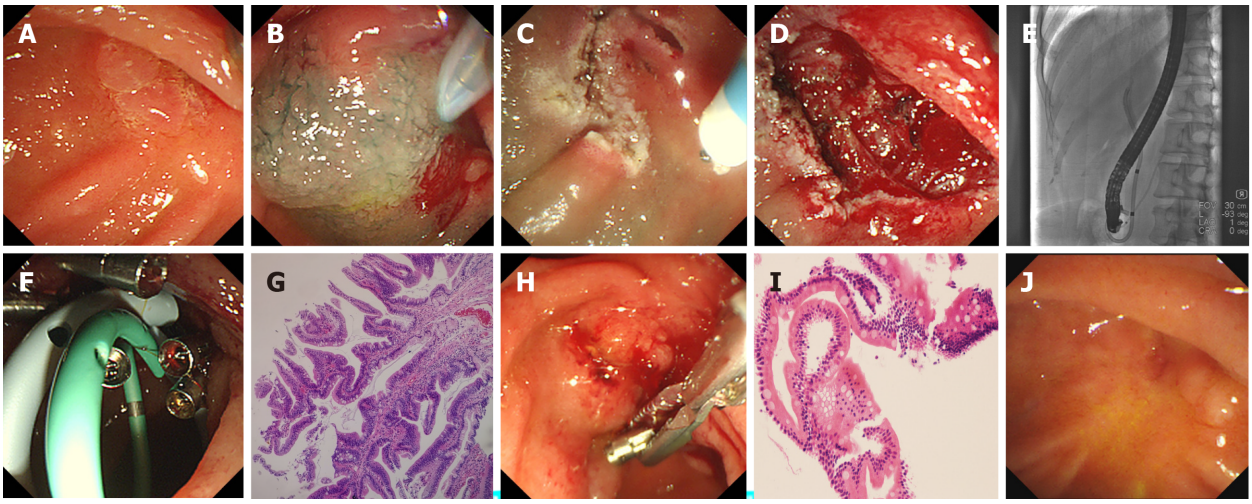

Figure 2 Endoscopic and pathological characteristics of case 2. A: Red and protuberant laterally spreading lesion was seen in the mucosa around the opening of the pancreaticobiliary duct; B-D: Hybrid endoscopic submucosal dissection (ESD) such as submucosal injection and submucosal dissection are shown, and the artificial ulcer was created; E and F: Endoscopic retrograde cholangiopancreatography showed the normal bile and pancreatic ducts, biliary and pancreatic stents were implanted, and close incision was performed by endoscopic clips; G: Hematoxylin and eosin-stained resected specimen showing tubulovillous adenoma with clean cutting edge, 4 ×; H: Endoscopic follow-up 3 mo after hybrid ESD showed that the pancreatic stent disappeared, and the biliary stent and clips were removed; I: Histological follow-up of biopsy specimen revealed chronic and acute inflammation of small intestinal mucosa, 20 ×; J: Endoscopic follow-up 38 mo after hybrid ESD with no recurrence.

the risk of perforation and bleeding; to avoid closure of the pancreaticobiliary opening when the hemostatic clip closes the wound; and to prevent biliary and/or pancreatic stenosis.

CONCLUSION

In conclusion, hybrid ESD by duodenoscope is technically challenging, and may be curative for recurrent, laterally spreading ampullary adenomas < 2 cm in diameter. It should be performed with caution by experienced endoscopists in selected patients to avoid severe complications.

ARTICLE HIGHLIGHTS

Research background

Management of recurrent ampullary adenomas after endoscopic papillectomy is still controversial. Some patients have to receive repetitive endoscopic interventions due to the limitations of conventional endoscopic techniques.

Research motivation

Endoscopic submucosal dissection (ESD) has become a standard treatment for early gastrointestinal neoplasms, as well as an appropriate technique for resection locally remnant and recurrent lesions. At present, ESD is rarely used in the treatment of duodenal papillary lesions by duodenoscope due to the complex anatomy of duodenal papilla and technical difficulties.

Research objectives

In this retrospective study, we report our preliminary experience of hybrid ESD by duodenoscope combined with biliary and pancreatic stent placement for recurrent, laterally spreading, duodenal papillary lesions.

Research methods

Two patients with recurrent, laterally spreading, papillary adenomas underwent hybrid ESD by duodenoscope and endoscopic retrograde cholangiopancreatography (ERCP). Outcomes, including endoscopic and histopathological characteristics, time of hybrid ESD and ERCP procedures, *en bloc* resection, procedure-related complications, and hospital stay were recorded.

Research results

Hybrid ESD using duodenoscope and subsequent biliary and pancreatic stent placement was performed successfully for both patients. The endoscopic size of recurrent papillary lesions was no more than 2 cm. No serious complications occurred during the intraoperative and postoperative periods. Histopathological examination revealed tubulovillous adenoma negative for neoplastic extension at the cut margin in both patients. No recurrence were observed during follow-up.

Research conclusions

Hybrid ESD by duodenoscope is technically challenging, and may be curative for recurrent, laterally spreading papillary adenomas < 2 cm.

Research perspectives

Hybrid ESD by duodenoscope should be performed cautiously in selected patients by experienced endoscopists. A prospective study should be conducted to compare hybrid ESD with conventional endoscopic techniques to gain more evidence.

REFERENCES

1 **El Hajj II**, Coté GA. Endoscopic diagnosis and management of ampullary lesions. *Gastrointest Endosc Clin N Am* 2013; **23**: 95-109 [PMID: 23168121 DOI: 10.1016/j.giec.2012.10.004]

2 **ASGE Standards of Practice Committee**, Chathadi KV, Khashab MA, Acosta RD, Chandrasekhara V, Eloubeidi MA, Faulx AL, Fonkalsrud L, Lightdale JR, Salztman JR, Shaukat A, Wang A, Cash BD, DeWitt JM. The role of endoscopy in ampullary and duodenal adenomas. *Gastrointest Endosc* 2015; **82**: 773-781 [PMID: 26260385 DOI: 10.1016/j.gie.2015.06.027]

3 **Napoleon B**, Gincul R, Ponchon T, Berthiller J, Escourrou J, Canard JM, Boyer J, Barthet M, Ponsot P, Laugier R, Helbert T, Coumaros D, Scoazec JY, Mion F, Saurin JC; Sociéte Française d'Endoscopie Digestive (SFED; French Society of Digestive Endoscopy). Endoscopic papillectomy for early ampullary tumors: long-term results from a large multicenter prospective study. *Endoscopy* 2014; **46**: 127-134 [PMID: 24477368 DOI: 10.1055/s-0034-1364875]

4 **Tanaka S**, Kashida H, Saito Y, Yahagi N, Yamano H, Saito S, Hisabe T, Yao T, Watanabe M, Yoshida M, Kudo SE, Tsuruta O, Sugihara KI, Watanabe T, Saitoh Y, Igarashi M, Toyonaga T, Ajioka Y, Ichinose M, Matsui T, Sugita A, Sugano K, Fujimoto K, Tajiri H. JGES guidelines for colorectal endoscopic submucosal dissection/endoscopic mucosal resection. *Dig Endosc* 2015; **27**: 417-434 [PMID: 25652022 DOI: 10.1111/den.12456]

5 **Martin JA**, Haber GB. Ampullary adenoma: clinical manifestations, diagnosis, and treatment. *Gastrointest Endosc Clin N Am* 2003; **13**: 649-669 [PMID: 14986792 DOI: 10.1016/s1052-5157(03)00101-6]

6 **Fischer HP**, Zhou H. Pathogenesis of carcinoma of the papilla of Vater. *J Hepatobiliary Pancreat Surg* 2004; **11**: 301-309 [PMID: 15549428 DOI: 10.1007/s00534-004-0898-3]

7 **de Castro SM**, van Heek NT, Kuhlmann KF, Busch OR, Offerhaus GJ, van Gulik TM, Obertop H, Gouma DJ. Surgical management of neoplasms of the ampulla of Vater: local resection or pancreatoduodenectomy and prognostic factors for survival. *Surgery* 2004; **136**: 994-1002 [PMID: 15523392 DOI: 10.1016/j.surg.2004.03.010]

8 **Cheng CL**, Sherman S, Fogel EL, McHenry L, Watkins JL, Fukushima T, Howard TJ, Lazzell-Pannell L, Lehman GA. Endoscopic snare papillectomy for tumors of the duodenal papillae. *Gastrointest Endosc* 2004; **60**: 757-764 [PMID: 15557951 DOI: 10.1016/s0016-5107(04)02029-2]

9 **Sahar N**, Krishnamoorthi R, Kozarek RA, Gluck M, Larsen M, Ross AS, Irani S. Long-Term Outcomes of Endoscopic Papillectomy for Ampullary Adenomas. *Dig Dis Sci* 2020; **65**: 260-268 [PMID: 31463668 DOI: 10.1007/s10620-019-05812-2]

10 **Tringali A**, Valerii G, Boškoski I, Familiari P, Landi R, Perri V, Costamagna G. Endoscopic snare papillectomy for adenoma of the ampulla of vater: Long-term results in 135 consecutive patients. *Dig Liver Dis* 2020; **52**: 1033-1038 [PMID: 32532606 DOI: 10.1016/j.dld.2020.05.029]

11 **Lü S**, Jiang M, Liu F, Tang H, Yang Y, Zhang W, Zhang M, Jin Z, Li Z. Endoscopic papillectomy of benign papillary tumors: A single-center experience. *Medicine (Baltimore)* 2020; **99**: e20414 [PMID: 32481436 DOI: 10.1097/MD.0000000000020414]

12 **Lee R**, Huelsen A, Gupta S, Hourigan LF. Endoscopic ampullectomy for non-invasive ampullary lesions: a single-center 10-year retrospective cohort study. *Surg Endosc* 2020; : [PMID: 32215745 DOI: 10.1007/s00464-020-07433-7]

13 **Li S**, Wang Z, Cai F, Linghu E, Sun G, Wang X, Meng J, Du H, Yang Y, Li W. New experience of endoscopic papillectomy for ampullary neoplasms. *Surg Endosc* 2019; **33**: 612-619 [PMID: 30421083 DOI: 10.1007/s00464-018-6577-2]

14 **Peng CY**, Lv Y, Shen SS, Wang L, Ding XW, Zou XP. The impact of endoscopic ultrasound in preoperative evaluation for ampullary adenomas. *J Dig Dis* 2019; **20**: 248-255 [PMID: 30834717 DOI: 10.1111/1751-2980.12719]

15 **Okano N**, Igarashi Y, Hara S, Takuma K, Kamata I, Kishimoto Y, Mimura T, Ito K, Sumino Y. Endosonographic preoperative evaluation for tumors of the ampulla of vater using endoscopic ultrasonography and intraductal ultrasonography. *Clin Endosc* 2014; **47**: 174-177 [PMID: 24765600 DOI: 10.5946/ce.2014.47.2.174]

16 **Yamamoto K**, Iwasaki E, Itoi T. Insights and updates on endoscopic papillectomy. *Expert Rev Gastroenterol Hepatol* 2020; **14**: 435-444 [PMID: 32380873 DOI: 10.1080/17474124.2020.1766965]

17 **Catalano MF**, Linder JD, Chak A, Sivak MV Jr, Raijman I, Geenen JE, Howell DA. Endoscopic management of adenoma of the major duodenal papilla. *Gastrointest Endosc* 2004; **59**: 225-232 [PMID: 14745396 DOI: 10.1016/s0016-5107(03)02366-6]

18 **Rahmi G**, Tanaka S, Ohara Y, Ishida T, Yoshizaki T, Morita Y, Toyonaga T, Azuma T. Efficacy of endoscopic submucosal dissection for residual or recurrent superficial colorectal tumors after endoscopic mucosal resection. *J Dig Dis* 2015; **16**: 14-21 [PMID: 25366265 DOI: 10.1111/1751-2980.12207]

19 **Oka S**, Tanaka S, Kaneko I, Mouri R, Hirata M, Kanao H, Kawamura T, Yoshida S, Yoshihara M, Chayama K. Endoscopic submucosal dissection for residual/Local recurrence of early gastric cancer after endoscopic mucosal resection. *Endoscopy* 2006; **38**: 996-1000 [PMID: 17058164 DOI: 10.1055/s-2006-944780]

20 **Yamamoto Y**, Yoshizawa N, Tomida H, Fujisaki J, Igarashi M. Therapeutic outcomes of endoscopic resection for superficial non-ampullary duodenal tumor. *Dig Endosc* 2014; **26** Suppl 2: 50-56 [PMID: 24750149 DOI: 10.1111/den.12273]

21 **Marques J**, Baldaque-Silva F, Pereira P, Arnelo U, Yahagi N, Macedo G. Endoscopic mucosal resection and endoscopic submucosal dissection in the treatment of sporadic nonampullary duodenal adenomatous polyps. *World J Gastrointest Endosc* 2015; **7**: 720-727 [PMID: 26140099 DOI: 10.4253/wjge.v7.i7.720]

22 **Jung JH**, Choi KD, Ahn JY, Lee JH, Jung HY, Choi KS, Lee GH, Song HJ, Kim DH, Kim MY, Bae SE, Kim JH. Endoscopic submucosal dissection for sessile, nonampullary duodenal adenomas. *Endoscopy* 2013; **45**: 133-135 [PMID: 23364841 DOI: 10.1055/s-0032-1326178]

23 **Yamao T**, Isomoto H, Kohno S, Mizuta Y, Yamakawa M, Nakao K, Irie J. Endoscopic snare papillectomy with biliary and pancreatic stent placement for tumors of the major duodenal papilla. *Surg Endosc* 2010; **24**: 119-124 [PMID: 19517183 DOI: 10.1007/s00464-009-0538-8]

World Journal of Gastroenterology

Submit a Manuscript: https://www.f6publishing.com

World J Gastroenterol 2020 October 7; 26(37): 5682-5692

DOI: 10.3748/wjg.v26.i37.5682

ISSN 1007-9327 (print) ISSN 2219-2840 (online)

ORIGINAL ARTICLE

Retrospective Study

Helicobacter pylori infection with atrophic gastritis: An independent risk factor for colorectal adenomas

Qin-Fen Chen, Xiao-Dong Zhou, Dan-Hong Fang, En-Guang Zhang, Chun-Jing Lin, Xiao-Zhen Feng, Na Wang, Jian-Sheng Wu, Dan Wang, Wei-Hong Lin

ORCID number: Qin-Fen Chen 0000-0001-6596-5004; Xiao-Dong Zhou 0000-0002-8534-0818; Dan-Hong Fang 0000-0001-9087-7073; En-Guang Zhang 0000-0002-3748-6724; Chun-Jing Lin 0000-0001-7604-8914; Xiao-Zhen Feng 0000-0002-2372-5595; Na Wang 0000-0002-8643-7486; Jian-Sheng Wu 0000-0001-8021-8584; Dan Wang 0000-0002-0284-2776; Wei-Hong Lin 0000-0003-1888-736X.

Author contributions: Chen QF and Zhou XD contributed equally to this work; Chen QF, Zhou XD, Lin WH, Wang D and Wu JS designed the study; Chen QF, Zhou XD, Feng XZ and Wang N collected data; Chen QF, Zhou XD and Fang DH did the statistical analyses; Chen QF, Zhou XD, Zhang EG and Lin CJ reviewed the results, interpreted data and wrote the manuscript; Lin WH and Wang D are both corresponding authors; All authors have made an intellectual contribution to the manuscript and approved the submission.

Institutional review board statement: The investigation conforms to the principles outlined in the Declaration of Helsinki. The study was approved by the ethical committee of The First Affiliated Hospital of Wenzhou Medical

Qin-Fen Chen, Dan-Hong Fang, En-Guang Zhang, Chun-Jing Lin, Xiao-Zhen Feng, Na Wang, Jian-Sheng Wu, Dan Wang, Wei-Hong Lin, Department of Physical Examination Medical Care Center, The First Affiliated Hospital of Wenzhou Medical University, Wenzhou 325000, Zhejiang Province, China

Xiao-Dong Zhou, Department of Cardiovascular Medicine, The Key Laboratory of Cardiovascular Diseases of Wenzhou, The First Affiliated Hospital of Wenzhou Medical University, Wenzhou 325000, Zhejiang Province, China

Corresponding author: Wei-Hong Lin, MD, Nurse, Department of Physical Examination Medical Care Center, The First Affiliated Hospital of Wenzhou Medical University, No. 2 Fuxue Lane, Wenzhou 325000, Zhejiang Province, China. linweihong@wmu.edu.cn

Abstract

BACKGROUND

The significance of *Helicobacter pylori* (*H. pylori*) infection and atrophic gastritis (AG) in the prevalence of colorectal adenomas has been examined in a limited number of studies. However, these studies reported disputed conclusions.

AIM

To investigate whether *H. pylori* infection, AG, and *H. pylori*-related AG increase the risk of colorectal adenomas.

METHODS

This retrospective cross-sectional study included 6018 health-check individuals. The relevant data for physical examination, laboratory testing, ^{13}C-urea breath testing, gastroscopy, colonoscopy and histopathological examination of gastric and colorectal biopsies were recorded. Univariate and multivariate logistic regression analyses were performed to determine the association between *H. pylori*-related AG and colorectal adenomas.

RESULTS

Overall, 1012 subjects (16.8%) were diagnosed with colorectal adenomas, of whom 143 (2.4%) had advanced adenomas. Among the enrolled patients, the prevalence of *H. pylori* infection and AG was observed as 49.5% (2981/6018) and 10.0% (602/6018), respectively. Subjects with *H. pylori* infection had an elevated risk of colorectal adenomas (adjusted odds ratio [OR] of 1.220, 95% confidence interval

(CI): 1.053-1.413, $P = 0.008$) but no increased risk of advance adenomas (adjusted OR = 1.303, 95%CI: 0.922-1.842, $P = 0.134$). AG was significantly correlated to an increased risk of colorectal adenomas (unadjusted OR = 1.668, 95%CI: 1.352-2.059, $P < 0.001$; adjusted OR = 1.237, 95%CI: 0.988-1.549, $P = 0.064$). *H. pylori* infection accompanied by AG was significantly associated with an increased risk of adenomas (adjusted OR = 1.491, 95%CI: 1.103-2.015, $P = 0.009$) and advanced adenomas (adjusted OR = 1.910, 95%CI: 1.022-3.572, $P = 0.043$).

CONCLUSION

H. pylori-related AG was associated with a high risk of colorectal adenomas and advanced adenomas in Chinese individuals.

Key Words: *Helicobacter pylori*; Gastritis; Atrophy; Adenomas; Colorectal; Health-check

Core Tip: The relationship among *Helicobacter pylori* (*H. pylori*), atrophic gastritis (AG), and colorectal adenomas has been inconclusive. We conducted this retrospective study on 6018 health-check individuals and observed that *H. pylori*-related AG is an independent risk factor for colorectal adenomas in Chinese individuals. Clinically, rigorous colonoscopy screening and monitoring may be necessary for individuals with *H. pylori*-positive AG.

Citation: Chen QF, Zhou XD, Fang DH, Zhang EG, Lin CJ, Feng XZ, Wang N, Wu JS, Wang D, Lin WH. *Helicobacter pylori* infection with atrophic gastritis: An independent risk factor for colorectal adenomas. *World J Gastroenterol* 2020; 26(37): 5682-5692
URL: https://www.wjgnet.com/1007-9327/full/v26/i37/5682.htm
DOI: https://dx.doi.org/10.3748/wjg.v26.i37.5682

INTRODUCTION

Colorectal cancer is one of the most common human malignancies worldwide, and the fifth common cause of cancer death in China[1]. Due to genetic mutations, colorectal adenomas may develop into carcinoma[2,3]. Common risk factors, such as age, male gender, nonalcoholic fatty liver disease, metabolic syndrome, family history, smoking, alcohol consumption, diet and lifestyle, contribute to the development of colorectal neoplasms[4,5].

Helicobacter pylori (*H. pylori*) is a gram-negative, microaerophilic bacterium generally found in the stomach[6]. *H. pylori* infection is associated with the development of gastric cancer[7]. In addition to its well-known association with gastric adenocarcinoma, *H. pylori* is associated with numerous extragastric malignancies[8,9]. Inconsistent conclusions of the relationship between *H. pylori* infection and colorectal neoplasia were presented in previous studies. In the early years, *H. pylori* infection had been confirmed as a risk factor for colorectal neoplasm[10-14]. However, the association between *H. pylori* infection and development of colorectal neoplasia remains unclear in recent studies[15].

Gastric mucosal atrophy is a typical symptom of atrophic gastritis (AG). AG in 8.1% of patients per year results from a chronic *H. pylori* infection with a ten-fold increased risk[16,17]. It is well established that gastric cancer and/or adenomas are associated with higher rates of colorectal cancer. In addition, precancerous lesions such as dysplasia or AG are important risk factors for gastric adenomas and gastric cancer[18,19]. However, only limited studies have investigated the association between AG and colorectal neoplasia. One study reported that intestinal metaplasia, often accompanied by AG, was closely related to any type of colorectal neoplasia[13].

In contrast, another study showed that the presence of AG has insignificantly increased the risk of colon cancer[20]. In addition, a recent study showed a significant association between colorectal neoplasm and AG, which was diagnosed by Kimura and Takemoto criteria. However, this study did not have the criteria for a histologic diagnosis[21]. The relationship between AG and colorectal neoplasia, especially that between *H. pylori*-related AG and colorectal neoplasia, is still controversial.

University Ethical Committee.

Informed consent statement: Patients were not required to give informed consent to the study because the analysis used anonymous clinical data that were obtained after each patient agreed to examination by verbal consent. Individuals can't be identified according to the data presented.

Conflict-of-interest statement: All authors declare that they have no conflicts of interest.

Data sharing statement: No additional data are available.

Manuscript source: Unsolicited manuscript

Received: April 21, 2020
Peer-review started: April 21, 2020
First decision: May 1, 2020
Revised: May 29, 2020
Accepted: September 9, 2020
Article in press: September 9, 2020
Published online: October 7, 2020

P-Reviewer: Durazzo M, Ekmektzoglou K, Song Z
S-Editor: Gao CC
L-Editor: Filipodia
P-Editor: Li JH

Thus, the aim was to assess the relationship between colorectal adenomas and *H. pylori*-related AG based on the histologic diagnosis.

MATERIALS AND METHODS

Eligible subjects

This retrospective study analyzed records between August 2014 and August 2017 that were extracted from the Medical and Health Care Center at The First Affiliated Hospital of Wenzhou Medical University. Relevant information was obtained *via* a survey, utilizing a standard relevant questionnaire. Out of these 13400 individuals, 6086 individuals aged 30 years and older underwent a gastroscopy, colonoscopy, ^{13}C-urea breath test and related pathological examination. Exclusion criteria were: A previous history of *H. pylori* eradication therapy; incomplete colonoscopy; polyp resection; inflammatory bowel disease; and gastrointestinal cancers. Finally, the data of 6018 individuals were included in our analysis. The investigation conforms to the principles outlined in the Declaration of Helsinki. The study was approved by the ethical committee of The First Affiliated Hospital of Wenzhou Medical University Ethical Committee

Data collection

Baseline characteristics, including age, gender, smoking, alcohol consumption, previous medical history and family history, were obtained from the standard questionnaires. Physical parameters and laboratory assays, including body mass index (BMI), systolic blood pressure (SBP), diastolic blood pressure (DBP), fasting blood glucose (FBG), total cholesterol (TC), triglyceride (TG), low-density lipoprotein (LDL), and high-density lipoprotein (HDL) and were collected and recorded from reports of physical examination. All blood samples were drawn from antecubital vein sampling following an overnight fast. The tests for physical parameter measurements were operated by trained nurses.

Diagnostic criteria

H. pylori (HP) infection was diagnosed by the ^{13}C-urea breath test or a histological diagnosis of biopsied stomach specimens. All enrolled subjects were divided into HP (+) group and HP (-) group depending on the above check mentions. Also, subjects were divided into AG (+) group and AG (-) group depending on the histopathological results of the gastric mucosa. For further subgroup analysis, subjects were divided into the nonpolyp group, the nonadenomatous polyp group (including inflammatory polyps and hyperplastic polyps) and the adenoma group based on the results from colorectal biopsies. Advanced colorectal adenoma was diagnosed by an adenoma with a diameter of ≥ 10 mm, a significant villous component, high-grade dysplasia or any combination thereof[21]. Additionally, the size of the polyps was divided into two groups: 0-9 mm and 10 mm +. While the number of polyps was divided into two groups: One and two or more. Following full bowel preparation, GIF-H260 gastroscopy and CF-H260AI colonoscopy (OLYMPUS, Tokyo, Japan) were performed in all eligible subjects. The surgeries were performed by experienced gastroenterologists with standard protocol followed. All examinations were performed in 2 d.

Statistical analysis

SPSS software (SPSS version 23.0 for Windows) was used for analysis. Continuous variables for nonadenomatous polyps, adenoma and advanced adenoma were presented as mean ± standard deviation. Pearson χ^2 tests for categorical variables and one-way analysis of variance or Kruskal–Wallis test for continuous variables were used to compare the baseline of the study population among the previously described groups. Associations of the risk factors with nonadenomatous polyps, adenoma and advanced adenoma were tested using univariate logistic regression and multivariate analysis. A two-sided P value of < 0.05 was considered statistically significant.

RESULTS

Baseline characteristics of eligible subject

As shown in Table 1, a summary of the characteristics stratified by nonpolyp, adenoma, nonadenomatous polyp and advanced adenoma groups are presented. Of 6018 subjects studied, 2035 (33.8%) presented with colorectal polyps, 1012 (16.8%) with adenomas and 1023 (17.0%) with nonadenomatous polyps. Out of 1012 subjects in the adenoma group, there were 143 cases of advanced adenomas. The prevalence of *H. pylori* infection in the nonpolyp group, adenoma group, nonadenomatous polyp group and advanced adenoma group were 48.6% (1936/3983), 53.0% (536/1012), 49.8% (509/1023) and 54.5% (78/143), respectively. The prevalence of AG in the nonpolyp group, adenoma group, nonadenomatous polyp group and advanced adenoma group were 8.7% (347/3983), 13.7% (139/1012), 11.3% (116/1023) and 14.7% (21/143), respectively. Overall, subjects with adenoma were older, had higher values of BMI, SBP, DBP, FBG, TC, TG, LDL, and lower values of HDL-cholesterol.

Association between H. pylori infection and adenoma

Based on the status of the *H. pylori* infection, all 6018 subjects were divided into HP (+) (2981, 49.5%) and HP (-) (3037, 50.5%). As reported in Table 2, the prevalence of adenoma in the HP (+) group was significantly higher than that of HP (-) group [unadjusted odds ratio (OR) = 1.1919, 95% confidence interval (CI): 1.037-1.367, P = 0.013; adjusted OR = 1.220, 95%CI: 1.053-1.413, P = 0.008, Table 3]. The mean age was not significantly different between the HP (+) and HP (-) groups. Compared to the HP (-) group, individuals in the HP (+) group had a higher proportion of men (P = 0.027, Table 2) and a higher prevalence of multiple colorectal polyps (P = 0.045). But the prevalence of nonadenomatous polyp, advanced adenoma, villous adenoma, adenoma size of ≥ 10 mm, single polyps, polyp size and *H. pylori* infection were similar (P > 0.05).

Association between AG and adenoma

Based on the AG status of all the 6018 subjects, we divided our cohort into two groups, the AG (+) group (602, 10.0%) and the AG (-) group (5416, 90.0%). Compared with the AG (-) group, subjects in the AG (+) group were older (P < 0.001, Table 4). The prevalence of adenoma in the AG (+) group was higher than that in the AG (-) group (unadjusted OR = 1.668, 95%CI: 1.352-2.059, P < 0.001, Table 4; adjusted OR = 1.237, 95%CI: 0.988-1.549, P = 0.064; Table 3). The prevalence of nonadenomatous polyps in the AG (+) group and AG (-) group was 19.3% and 16.7%, respectively (unadjusted OR = 1.340, 95%CI: 1.073-1.674, P = 0.010; adjusted OR = 1.103, 95%CI: 0.872-1.394, P = 0.413, Table 3). In addition, the prevalence of advanced adenoma in the AG (+) group and AG (-) group was 3.49% and 2.25%, respectively (unadjusted OR = 1.804 (95%CI: 1.121-2.903, P = 0.015; adjusted OR = 1.320, 95%CI: 0.805-2.165, P = 0.271, Table 3). The association of polyps with AG (+) was highest for individuals with more than one polyp (OR = 1.608, 95%CI: 1.302-1.985, P = 0.003). In patients with a polyp size of 0-9 mm, there existed a significant association between the prevalence of polyps and AG status (OR = 1.519, 95%CI: 1.275-1.809, P < 0.001).

Presence of both H. pylori infection and AG may increase the risk for adenoma significantly

According to the different statuses of *H. pylori* infection and AG, the individuals in our study were divided into HP (-) AG (-) group, HP (-) AG (+) group, HP (+) AG (-) group and HP (+) AG (+) group to understand whether *H. pylori* infection with AG increased the risk of adenoma. As reported in Table 5 and Table 6, the HP (+) AG (+) group had an approximately 1.5-fold risk for colorectal adenomas in comparison with that in the HP (-) AG (-) group (unadjusted OR = 1.964, 95%CI: 1.477-2.610, P < 0.001; adjusted OR = 1.491, 95%CI: 1.103-2.015, P = 0.009).

Presence of both H. pylori infection and AG also increase the risk for advanced adenoma

In subgroup analysis, the risk of colorectal adenomas was similar in either the HP (-) AG (-) group or HP (-) AG (+) group (unadjusted OR = 1.377, 95%CI: 0.618-3.064, P = 0.434), or between the HP (-) AG (-) group and HP (+) AG (-) group (unadjusted OR = 1.184, 95%CI: 0.825-1.699, P = 0.360). However, the presence of *H. pylori*-related AG was related to a significant increased risk for advanced adenomas (unadjusted OR = 2.496, 95%CI: 1.366-4.562, P = 0.003; adjusted OR = 1.910, 95%CI: 1.022-3.572, P =

Table 1 Baseline characteristics of 6018 subjects

Parameter	Nonpolyp, *n* = 3983	Adenoma, *n* = 1012	Nonadenomatous polyp, *n* = 1023	Advanced adenoma, *n* = 143	[a]*P* value	[b]*P* value	[c]*P* value
Male/female	2336/1647	780/232	788/235	110/33	< 0.001	< 0.001	< 0.001
HP (+/-)	1936/2047	536/476	509/514	78/65	0.013	0.512	0.165
AG (+/-)	347/3636	139/873	116/907	21/122	< 0.001	0.016	0.049
Smoker (+/-)	1029/2954	402/610	430/593	61/82	< 0.001	< 0.001	< 0.001
Alcohol (+/-)	1423/2560	494/518	476/547	68/75	< 0.001	< 0.001	0.006
Age in yr	46.430 (10.150)	52.680 (9.981)	50.010 (10.269)	53.310 (9.738)	< 0.001	< 0.001	< 0.001
BMI	23.611 (3.160)	24.355 (2.938)	24.667 (3.099)	24.809 (2.929)	< 0.001	< 0.001	< 0.001
SBP	123.950 (17.747)	129.700 (18.488)	127.810 (18.388)	131.650 (17.271)	< 0.001	< 0.001	< 0.001
DBP	73.410 (12.255)	76.990 (12.036)	75.910 (12.541)	77.520 (11.798)	< 0.001	< 0.001	< 0.001
TC	5.296 (1.076)	5.434 (1.155)	5.387 (1.077)	5.528 (1.083)	< 0.001	0.016	0.012
TG	1.771 (1.586)	1.982 (1.784)	2.001 (1.525)	2.194 (1.693)	< 0.001	< 0.001	0.002
HDL	1.296 (0.330)	1.252 (0.330)	1.216 (0.304)	1.237 (0.335)	< 0.001	< 0.001	0.034
LDL	3.169 (0.841)	3.253 (0.866)	3.258 (0.855)	3.259 (0.905)	0.005	0.003	0.208
FBG	4.818 (1.136)	5.065 (1.422)	5.055 (1.395)	5.091 (1.608)	< 0.001	< 0.001	0.047

[a]Two-sided *P* values for the difference between adenoma and nonpolyp were based on the χ^2 test and *t* test.
[b]Two-sided *P* values for the difference between nonadenomatous polyp and nonpolyp were based on the χ^2 test and *t* test.
[c]Two-sided *P* values for the difference between advanced adenoma and nonpolyp were based on the χ^2 test and *t* test. HP: *Helicobacter pylori*; AG: Atrophic gastritis; BMI: Body mass index; SBP: Systolic blood pressure; DBP: Diastolic blood pressure; TC: Total cholesterol; TG: Triglyceride; HDL: High-density lipoprotein; LDL: Low-density lipoprotein; FBG: Fasting blood glucose.

0.043).

DISCUSSION

In this study, the potential roles of *H. pylori* infection, AG and *H. pylori*-related AG in the progress of colorectal adenomas and advanced adenoma were investigated. According to previous research, the association between *H. pylori* and colorectal adenomas remains unclear[20,22-26]. In our study, *H. pylori* infection was an independent risk factor for colorectal adenomas. The finding is consistent with current studies that indicate a positive correlation was revealed between colorectal adenomas and *H. pylori*. Additionally, HP (+) AG (-) may indicate a higher risk of colorectal adenomas. However, it was not associated with an increased risk of advanced adenomas. In our study, *H. pylori* infection was diagnosed by the results from the ^{13}C-urea breath test or a histological diagnosis of biopsied gastric specimen serology test that can accurately reflect a current *H. pylori* infection[21]. With the development of detection technologies of *H. pylori* infection, the role of *H. pylori* in the colorectal carcinogenesis may be revealed.

No significant association between AG and colorectal adenomas was observed in our cohort. Moreover, HP (-) AG (+) was not an independent risk factor for colorectal adenomas. Some subjects with HP (-) AG (+) may be affected with severe AG following a long-term infection with *H. pylori*. Theoretically, these patients may present with hypergastrinemia and have a higher risk of colorectal adenomas. However, our study did not indicate any correlation based on this hypothetical reasoning. In the multivariate analysis, the relatively small number (n = 279) of the HP (-) AG (+) group may have concealed the possible effects on colorectal adenomas.

After controlling all confounding factors, the ORs for colorectal adenomas in eligible individuals with *H. pylori*-related AG were higher than those in individuals of the HP (-) AG (-) group (adjust OR = 1.491, 95%CI: 1.103-2.015, P = 0.009). HP (+) AG (+) is independently associated with colorectal adenomas. Additionally, HP (+) AG (+) is significantly associated with an increased risk of advanced adenomas. However, no such association was observed in the HP (-) AG (+) or the HP (+) AG (-) group. This

Table 2 Correlation between *Helicobacter pylori* infection and colorectal neoplasm

Parameter	HP (-), *n* = 3037	HP (+), *n* = 2981	OR (95%CI)	*P* value
Age in yr	48.130 (10.678)	48.040 (10.177)	0.999 (0.994-1.004)	0.745
Female	1026	1088	1	
Male	2011	1893	0.888 (0.798-0.987)	0.027
Nonpolyp	2047	1936	1	
Nonadenomatous polyp	514	509	1.047 (0.913-1.201)	0.512
Adenoma	476	536	1.191 (1.037-1.367)	0.013
Advanced adenoma	65	78	1.269 (0.908-1.774)	0.164
Villous adenoma	24	23	1.013 (0.570-1.801)	0.964
Size of adenoma ≥ 10 mm	49	64	1.381 (0.947-2.014)	0.093
High-grade dysplasia	5	8	1.692 (0.552-5.180)	0.357
Polyps number				
One	509	521	1.082 (0.944-1.241)	0.258
Two or more	481	524	1.152 (1.003-1.323)	0.045
Polyps size				
0-9 mm	925	963	1.101 (0.987-1.228)	0.086
≥ 10 mm	65	82	1.334 (0.958-1.858)	0.088

Correlation between *Helicobacter pylori* (+) and *Helicobacter pylori* (-) by logistic regression analysis. OR: Odds ratio; CI: Confidence interval; HP: *Helicobacter pylori*.

Table 3 Logistic regression model of the association between *Helicobacter pylori* infection, atrophic gastritis and colorectal neoplasm after adjustments for confounding factors

	Nonadenomatous polyp		Adenoma		Advanced adenoma	
	Adjusted OR (95%CI)	*P* value	Adjusted OR (95%CI)	*P* value	Adjusted OR (95%CI)	*P* value
HP (+)	1.033 (0.895-1.193)	0.658	1.220 (1.053-1.413)	0.008	1.303 (0.922-1.842)	0.134
AG (+)	1.103 (0.872-1.394)	0.413	1.237 (0.988-1.549)	0.064	1.320 (0.805-2.165)	0.271

Adjusted for age, gender, systolic blood pressure, diastolic blood pressure, body mass index, smoking habit, alcohol consumption, total cholesterol level, triglyceride level, high-density lipoprotein-C level, low-density lipoprotein-C level and fasting blood glucose level by logistic regression analysis. HP: *Helicobacter pylori*; AG: Atrophic gastritis; OR: Odds ratio; CI: Confidence interval.

finding is consistent with that of a recent study that indicated that *H. pylori* infection along with AG increased the risk of both overall and advanced colorectal neoplasm[21]. Chronic *H. pylori* infection can lead to the occurrence of gastric mucosal atrophy[27]. In our study, the mean age in HP (+) AG (+) group was higher than in the HP (+) AG (-) group (52.3 years *vs* 47.5 years). This can be explained as the individuals in the HP (+) AG (+) group may have *H. pylori* infection for a longer period.

The presence of the *H. pylori* infection and AG increases the risk of colorectal adenoma. This may occur *via* various mechanisms. The cholecystokinin type B/gastrin receptor and gastrin are present in human colorectal polyps, and they are activated in the early stages of the adenoma-carcinoma sequence[28,29]. Persistent exposure to *H. pylori* infection directly induces the atrophic changes of the gastric body mucosa and increases the gastrin secretion. This has a nutritional effect on the growth and proliferation of epithelial cells and ultimately contributes to colorectal carcinogenesis[30,31]. In addition, hypochlorhydria caused by *H. pylori*-related AG may hamper protein assimilation, leading to an increase of some unabsorbed nutrients and metabolites[32]. Hypochlorhydria generates bacterial overgrowth and colorectal disorders, resulting in colorectal carcinogenesis[33].

Table 4 Correlation between atrophic gastritis and colorectal neoplasm

Parameter	AG (-), *n* = 5416	AG (+), *n* = 602	OR (95%CI)	*P* value
Age in yr	47.590 (10.350)	52.530 (10.117)	1.045 (1.037-1.053)	< 0.001
Female	1921	193	1	
Male	3495	409	1.165 (0.973-1.394)	0.097
Nonpolyp	3636	347	1	
Nonadenomatous polyp	907	116	1.340 (1.073-1.674)	0.010
Adenoma	873	139	1.668 (1.352-2.059)	< 0.001
Advanced adenoma	122	21	1.804 (1.121-2.903)	0.015
Villous adenoma	40	7	1.834 (0.815-4.124)	0.143
Size of adenoma ≥ 10 mm	98	15	1.604 (0.921-2.792)	0.095
High-grade dysplasia	12	1	0.873 (0.113-6.735)	0.897
Polyps number				
One	893	137	1.608 (1.302-1.985)	< 0.001
Two or more	887	118	1.394 (1.117-1.739)	0.003
Polyps size				
0-9 mm	1649	239	1.519 (1.275-1.809)	< 0.001
≥ 10 mm	131	16	1.280 (0.753-2.176)	0.362

Correlation between atrophic gastritis (+) and atrophic gastritis (-) by logistic regression analysis. OR: Odds ratio; CI: Confidence interval; AG: Atrophic gastritis.

Table 5 Association between *Helicobacter pylori* infection, atrophic gastritis and colorectal neoplasm

	HP (–) AG (–), *n* = 2758		HP (–) AG (+), *n* = 279			HP (+) AG (–), *n* = 2658			HP (+) AG (+), *n* = 323		
	n (%)	OR (95%CI)	*n* (%)	OR (95%CI)	*P* value	*n* (%)	OR (95%CI)	*P*	*n* (%)	OR (95%CI)	*P*
Age in yr, mean ± SD	47.7 ± 10.6		52.8 ± 10.5			47.5 ± 10.1			52.3 ± 9.8		
Male sex	1818 (65.9)		193 (69.2)			1677 (63.1)			216 (66.9)		
Nonadenomatous polyp	460 (16.7)	1	54 (19.4)	1.339 (0.969-1.851)	0.077	447 (16.8)	1.043 (0.901-1.206)	0.574	62 (19.2)	1.394 (1.027-1.892)	0.033
Adenoma	416 (15.1)	1	60 (21.5)	1.645 (1.202-2.252)	0.002	457 (17.2)	1.179 (1.017-1.367)	0.029	79 (24.5)	1.964 (1.477-2.610)	< 0.001
Advanced adenoma	58 (2.1)	1	7 (2.5)	1.377 (0.618-3.064)	0.434	64 (2.4)	1.184 (0.825-1.699)	0.360	14 (4.3)	2.496 (1.366-4.562)	0.003

Univariate logistic regression was used to analyze the association between *Helicobacter pylori* infection, atrophic gastritis and colorectal neoplasm. HP: *Helicobacter pylori*; AG: Atrophic gastritis; OR: Odds ratio; CI: Confidence interval; SD: Standard deviation.

Table 6 Logistic regression model of the association between *Helicobacter pylori* infection, atrophic gastritis and colorectal neoplasm after adjustments for confounding factors

	HP (–) AG (–), *n* = 2758	HP (–) AG (+), *n* = 279		HP (+) AG (–), *n* = 2658		HP (+) AG (+), *n* = 323	
	OR (95%CI)	OR (95%CI)	*P* value	OR (95%CI)	*P* value	OR (95%CI)	*P* value
Non-adenomatous polyp	1	1.093 (0.776-1.540)	0.612	1.03 (0.884-1.199)	0.707	1.141 (0.830-1.568)	0.417
Adenoma	1	1.216 (0.868-1.705)	0.255	1.213 (1.037-1.419)	0.016	1.491 (1.103-2.015)	0.009
Advanced adenoma	1	0.979 (0.431-2.226)	0.960	1.214 (0.836-1.763)	0.308	1.910 (1.022-3.572)	0.043

Adjusted for age, gender, systolic blood pressure, diastolic blood pressure, body mass index, smoking habit, alcohol consumption, total cholesterol level, triglyceride level, high-density lipoprotein-C level, low-density lipoprotein-C level and fasting blood glucose level by logistic regression analysis. HP: *Helicobacter pylori*; AG: Atrophic gastritis; OR: Odds ratio; CI: Confidence interval.

Generalizability of findings in this study is limited by several factors. First, based on general health check-ups, a potential selection bias may have existed. In addition, the data affecting the changes of gastric mucosa, viz. dietary habit, was insufficient. Second, serum gastrin level, as a key mechanism in the progress of colorectal carcinogenesis, was not included in our analysis. Third, biopsy samples accounted for only 74% of the data. This may have potentially lowered the rate of gastric disease detection. Finally, our analyzable data were derived from a single center and local region in Chinese people, thereby limiting the ability to generalize our finding. Therefore, further multicenter research should be established to determine the potential association of individuals with other nations and ethnic groups. Despite these limitations, it is a novel study as we not only analyzed the relationship between *H. pylori* infection and colorectal adenomas but also further investigated the role of AG in colorectal carcinogenesis.

CONCLUSION

In summary, our study clearly demonstrated that subjects with *H. pylori*-related AG did have an increased risk for colorectal adenoma. Due to the high prevalence of *H. pylori* infection and colorectal cancer in the Chinese population, strict colonoscopy screening and surveillance are necessary for patients with *H. pylori* infection, especially for those with *H. pylori*-related AG.

ARTICLE HIGHLIGHTS

Research background

Several previous studies demonstrated the significance of *Helicobacter pylori* (*H. pylori*) infection and atrophic gastritis (AG) in the prevalence of colorectal adenomas. A recent study showed a significant association between colorectal neoplasm and AG, which was diagnosed by Kimura and Takemoto criteria without the histologic diagnosis. However, the relationship between AG and colorectal neoplasia, especially that between *H. pylori*-related AG and colorectal neoplasia, is still controversial.

Research motivation

Colorectal adenomas may develop colorectal cancer, which is considered to be one of the most common human malignancies worldwide. Early diagnosis of colorectal adenomas is important to reduce mortality. The association of *H. pylori* infection and AG in the prevalence of colorectal adenomas has been examined in a limited number of studies. However, there exists disputed conclusions in the studies reported.

Research objectives

The aim was to investigate the relationship between colorectal adenomas and *H. pylori*-related AG based on the histologic diagnosis.

Research methods

This retrospective cross-sectional study analyzed records between August 2014 and August 2017 and were extracted from the Medical and Health Care Center at The First Affiliated Hospital of Wenzhou Medical University. Based on the relevant inclusion and exclusion criteria, 6018 health-check individuals were eventually enrolled. The relevant data were recorded. Univariate and multivariate logistic regression analyses were performed to determine the association between *H. pylori*-related AG and colorectal adenomas.

Research results

H. pylori infection accompanied by AG was significantly associated with an increased risk of adenomas (adjusted odds ratio = 1.491, 95% confidence interval: 1.103-2.015, P = 0.009) and advanced adenomas (adjusted odds ratio = 1.910, 95% confidence interval: 1.022-3.572, P = 0.043).

Research conclusions

Our research demonstrated that *H. pylori*-related AG is an independent risk factor for colorectal adenomas in the Chinese population.

Research perspectives

The Chinese have a high prevalence of *H. pylori* infection and colorectal cancer. Therefore, strict colonoscopy screening and surveillance are necessary for patients with *H. pylori* infection, especially for those with *H. pylori*-related AG.

ACKNOWLEDGEMENTS

The authors thank all the staff at the Medical and Health Care Center of The First Affiliated Hospital of Wenzhou Medical University for their assistance.

REFERENCES

1 **Chen W**, Zheng R, Baade PD, Zhang S, Zeng H, Bray F, Jemal A, Yu XQ, He J. Cancer statistics in China, 2015. *CA Cancer J Clin* 2016; **66**: 115-132 [PMID: 26808342 DOI: 10.3322/caac.21338]

2 **Dhaliwal A**, Vlachostergios PJ, Oikonomou KG, Moshenyat Y. Fecal DNA testing for colorectal cancer screening: Molecular targets and perspectives. *World J Gastrointest Oncol* 2015; **7**: 178-183 [PMID: 26483873 DOI: 10.4251/wjgo.v7.i10.178]

3 **Yan Y**, Chen YN, Zhao Q, Chen C, Lin CJ, Jin Y, Pan S, Wu JS. *Helicobacter pylori* infection with intestinal metaplasia: An independent risk factor for colorectal adenomas. *World J Gastroenterol* 2017; **23**: 1443-1449 [PMID: 28293091 DOI: 10.3748/wjg.v23.i8.1443]

4 **Rawla P**, Sunkara T, Barsouk A. Epidemiology of colorectal cancer: incidence, mortality, survival, and risk factors. *Prz Gastroenterol* 2019; **14**: 89-103 [PMID: 31616522 DOI: 10.5114/pg.2018.81072]

5 **Chen QF**, Zhou XD, Sun YJ, Fang DH, Zhao Q, Huang JH, Jin Y, Wu JS. Sex-influenced association of non-alcoholic fatty liver disease with colorectal adenomatous and hyperplastic polyps. *World J Gastroenterol* 2017; **23**: 5206-5215 [PMID: 28811715 DOI: 10.3748/wjg.v23.i28.5206]

6 **Zhao Y**, Wang X, Wang Y. *Helicobacter pylori* infection and colorectal carcinoma risk: A meta-analysis. *J Cancer Res Ther* 2016; **12**: 15-18 [PMID: 27721244 DOI: 10.4103/0973-1482.191621]

7 **Venerito M**, Vasapolli R, Rokkas T, Delchier JC, Malfertheiner P. Helicobacter pylori, gastric cancer and other gastrointestinal malignancies. *Helicobacter* 2017; **22** Suppl 1 [PMID: 28891127 DOI: 10.1111/hel.12413]

8 **Roubaud Baudron C**, Franceschi F, Salles N, Gasbarrini A. Extragastric diseases and Helicobacter pylori. *Helicobacter* 2013; **18** Suppl 1: 44-51 [PMID: 24011245 DOI: 10.1111/hel.12077]

9 **Rabelo-Gonçalves EM**, Roesler BM, Zeitune JM. Extragastric manifestations of Helicobacter pylori infection: Possible role of bacterium in liver and pancreas diseases. *World J Hepatol* 2015; **7**: 2968-2979 [PMID: 26730276 DOI: 10.4254/wjh.v7.i30.2968]

10 **Kim TJ**, Kim ER, Chang DK, Kim YH, Baek SY, Kim K, Hong SN. Helicobacter pylori infection is an independent risk factor of early and advanced colorectal neoplasm. *Helicobacter* 2017; **22** [PMID: 28124492 DOI: 10.1111/hel.12377]

11 **Brim H**, Zahaf M, Laiyemo AO, Nouraie M, Pérez-Pérez GI, Smoot DT, Lee E, Razjouyan H, Ashktorab H. Gastric Helicobacter pylori infection associates with an increased risk of colorectal polyps in African Americans. *BMC Cancer* 2014; **14**: 296 [PMID: 24774100 DOI: 10.1186/1471-2407-14-296]

12 **Zhang Y**, Hoffmeister M, Weck MN, Chang-Claude J, Brenner H. Helicobacter pylori infection and colorectal cancer risk: evidence from a large population-based case-control study in Germany. *Am J Epidemiol* 2012; **175**: 441-450 [PMID: 22294430 DOI: 10.1093/aje/kwr331]

13 **Sonnenberg A**, Genta RM. Helicobacter pylori is a risk factor for colonic neoplasms. *Am J Gastroenterol* 2013; **108**: 208-215 [PMID: 23208272 DOI: 10.1038/ajg.2012.407]

14 **Guo Y**, Li HY. Association between Helicobacter pylori infection and colorectal neoplasm risk: a meta-analysis based on East Asian population. *J Cancer Res Ther* 2014; **10** Suppl: 263-266 [PMID: 25693932 DOI: 10.4103/0973-1482.151482]

15 **Patel S**, Lipka S, Shen H, Barnowsky A, Silpe J, Mosdale J, Pan Q, Fridlyand S, Bhavsar A, Abraham A, Viswanathan P, Mustacchia P, Krishnamachari B. The association of H. pylori and colorectal adenoma: does it exist in the US Hispanic population? *J Gastrointest Oncol* 2014; **5**: 463-468 [PMID: 25436126 DOI: 10.3978/j.issn.2078-6891.2014.074]

16 **Holleczek B**, Schöttker B, Brenner H. Helicobacter pylori infection, chronic atrophic gastritis and risk of stomach and esophagus cancer: Results from the prospective population-based ESTHER cohort study. *Int J Cancer* 2020; **146**: 2773-2783 [PMID: 31376284 DOI: 10.1002/ijc.32610]

17 **Adamu MA**, Weck MN, Gao L, Brenner H. Incidence of chronic atrophic gastritis: systematic review and meta-analysis of follow-up studies. *Eur J Epidemiol* 2010; **25**: 439-448 [PMID: 20585973 DOI: 10.1007/s10654-010-9482-0]

18 **Yang MH**, Son HJ, Lee JH, Kim MH, Kim JY, Kim YH, Chang DK, Rhee PL, Kim JJ, Rhee JC. Do we need colonoscopy in patients with gastric adenomas? The risk of colorectal adenoma in patients with gastric adenomas. *Gastrointest Endosc* 2010; **71**: 774-781 [PMID: 20363417 DOI: 10.1016/j.gie.2009.11.042]

19 **de Vries AC**, van Grieken NC, Looman CW, Casparie MK, de Vries E, Meijer GA, Kuipers EJ. Gastric cancer risk in patients with premalignant gastric lesions: a nationwide cohort study in the Netherlands. *Gastroenterology* 2008; **134**: 945-952 [PMID: 18395075 DOI: 10.1053/j.gastro.2008.01.071]

20 **Machida-Montani A**, Sasazuki S, Inoue M, Natsukawa S, Shaura K, Koizumi Y, Kasuga Y, Hanaoka T, Tsugane S. Atrophic gastritis, Helicobacter pylori, and colorectal cancer risk: a case-control study. *Helicobacter* 2007; **12**: 328-332 [PMID: 17669106 DOI: 10.1111/j.1523-5378.2007.00513.x]

21 **Lee JY**, Park HW, Choi JY, Lee JS, Koo JE, Chung EJ, Chang HS, Choe J, Yang DH, Myung SJ, Jung HY, Yang SK, Byeon JS. *Helicobacter pylori* Infection with Atrophic Gastritis Is an Independent Risk Factor for Advanced Colonic Neoplasm. *Gut Liver* 2016; **10**: 902-909 [PMID: 27458180 DOI: 10.5009/gnl15340]

22 **Hong SN**, Lee SM, Kim JH, Lee TY, Kim JH, Choe WH, Lee SY, Cheon YK, Sung IK, Park HS, Shim CS. Helicobacter pylori infection increases the risk of colorectal adenomas: cross-sectional study and meta-analysis. *Dig Dis Sci* 2012; **57**: 2184-2194 [PMID: 22669208 DOI: 10.1007/s10620-012-2245-x]

23 **Zhao YS**, Wang F, Chang D, Han B, You DY. Meta-analysis of different test indicators: Helicobacter pylori infection and the risk of colorectal cancer. *Int J Colorectal Dis* 2008; **23**: 875-882 [PMID: 18506454 DOI: 10.1007/s00384-008-0479-z]

24 **Wu Q**, Yang ZP, Xu P, Gao LC, Fan DM. Association between Helicobacter pylori infection and the risk of colorectal neoplasia: a systematic review and meta-analysis. *Colorectal Dis* 2013; **15**: e352-e364 [PMID: 23672575 DOI: 10.1111/codi.12284]

25 **Siddheshwar RK**, Muhammad KB, Gray JC, Kelly SB. Seroprevalence of Helicobacter pylori in patients with colorectal polyps and colorectal carcinoma. *Am J Gastroenterol* 2001; **96**: 84-88 [PMID: 11197293 DOI: 10.1111/j.1572-0241.2001.03355.x]

26 **Abbass K**, Gul W, Beck G, Markert R, Akram S. Association of Helicobacter pylori infection with the development of colorectal polyps and colorectal carcinoma. *South Med J* 2011; **104**: 473-476 [PMID: 21886044 DOI: 10.1097/SMJ.0b013e31821e9009]

27 **Vannella L**, Lahner E, Annibale B. Risk for gastric neoplasias in patients with chronic atrophic gastritis: a critical reappraisal. *World J Gastroenterol* 2012; **18**: 1279-1285 [PMID: 22493541 DOI: 10.3748/wjg.v18.i12.1279]

28 **Smith AM**, Watson SA. Gastrin and gastrin receptor activation: an early event in the adenoma-carcinoma sequence. *Gut* 2000; **47**: 820-824 [PMID: 11076881 DOI: 10.1136/gut.47.6.820]

29 **Boyuk B**, Ozgur A, Atalay H, Celebi A, Ekizoglu I, Aykurt E. *Helicobacter pylori* infection coexisting with intestinal metaplasia is not associated with colorectal neoplasms. *Prz Gastroenterol* 2019; **14**: 133-139 [PMID: 31616528 DOI: 10.5114/pg.2019.85897]

30 **Watson SA**, Grabowska AM, El-Zaatari M, Takhar A. Gastrin - active participant or bystander in gastric carcinogenesis? *Nat Rev Cancer* 2006; **6**: 936-946 [PMID: 17128210 DOI: 10.1038/nrc2014]

31 **Espinoza JL**, Matsumoto A, Tanaka H, Matsumura I. Gastric microbiota: An emerging player in

Helicobacter pylori-induced gastric malignancies. *Cancer Lett* 2018; **414**: 147-152 [PMID: 29138097 DOI: 10.1016/j.canlet.2017.11.009]

32 **Kanno T**, Matsuki T, Oka M, Utsunomiya H, Inada K, Magari H, Inoue I, Maekita T, Ueda K, Enomoto S, Iguchi M, Yanaoka K, Tamai H, Akimoto S, Nomoto K, Tanaka R, Ichinose M. Gastric acid reduction leads to an alteration in lower intestinal microflora. *Biochem Biophys Res Commun* 2009; **381**: 666-670 [PMID: 19248769 DOI: 10.1016/j.bbrc.2009.02.109]

33 **Inoue I**, Kato J, Tamai H, Iguchi M, Maekita T, Yoshimura N, Ichinose M. Helicobacter pylori-related chronic gastritis as a risk factor for colonic neoplasms. *World J Gastroenterol* 2014; **20**: 1485-1492 [PMID: 24587623 DOI: 10.3748/wjg.v20.i6.1485]

World Journal of Gastroenterology

Submit a Manuscript: https://www.f6publishing.com

World J Gastroenterol 2020 October 7; 26(37): 5693-5704

DOI: 10.3748/wjg.v26.i37.5693

ISSN 1007-9327 (print) ISSN 2219-2840 (online)

ORIGINAL ARTICLE

Clinical Trials Study

Endoscopic ultrasound-fine needle biopsies of pancreatic lesions: Prospective study of histology quality using Franseen needle

Petros Stathopoulos, Anika Pehl, Lutz Philipp Breitling, Christian Bauer, Tobias Grote, Thomas Mathias Gress, Carsten Denkert, Ulrike Walburga Denzer

ORCID number: Petros Stathopoulos 0000-0003-2637-8346; Anika Pehl 0000-0002-7285-6743; Lutz Philipp Breitling 0000-0003-3653-4138; Christian Bauer 0000-0003-1349-0160; Tobias Grote 0000-0002-5314-8565; Thomas Mathias Gress 0000-0002-9333-5461; Carsten Denkert 0000-0002-2249-0982; Ulrike Walburga Denzer 0000-0001-8926-160X.

Author contributions: Denzer UW conceived the idea and designed the study, performed the endoscopies, reviewed the draft and approved the final manuscript; Stathopoulos P performed the literature search, collected the data and drafted and approved the final manuscript; Pehl A and Denkert C performed the histological analyses of the specimens, reviewed the draft and approved the final manuscript; Breitling LP (MSc in Epidemiology) analysed the data reviewed the draft and approved the final manuscript; Bauer C and Grote T performed the endoscopies, reviewed the draft and approved the final manuscript; Gress T critically reviewed the draft and approved the final manuscript; all the authors contributed to this manuscript.

Institutional review board statement: This study was

Petros Stathopoulos, Lutz Philipp Breitling, Christian Bauer, Tobias Grote, Thomas Mathias Gress, Ulrike Walburga Denzer, Division of Endoscopy, Department of Gastroenterology, Endocrinology, Metabolism and Clinical Infectiology, University Hospital Marburg, Marburg 35043, Hessen, Germany

Anika Pehl, Carsten Denkert, Institute of pathology, University Hospital Marburg, Marburg 35043, Hessen, Germany

Corresponding author: Ulrike Walburga Denzer, MD, Professor, Division of Endoscopy, Department of Gastroenterology, Endocrinology, Metabolism and Clinical Infectiology, University Hospital Marburg, Baldingerstrasse 1, Marburg 35043, Hessen, Germany. uwdenzer@gmail.com

Abstract

BACKGROUND

The introduction of fine needle biopsies (FNB) to clinical practice presents a changing trend towards histology in the endoscopic ultrasound-guided tissue acquisition (EUS-TA).

AIM

To evaluate the clinical performance of a new FNB needle, the 22-gauge (22G) Franseen needle, when sampling pancreatic solid lesions.

METHODS

Consecutive patients with an indication for EUS-TA for the assessment of pancreatic solid lesions were included in this prospective, single-center, single-arm trial. Each patient underwent a puncture of the lesion two times using the 22G Franseen needle and the obtained samples were directly placed into formalin for histological analysis. The primary study endpoint was the rate of high-quality obtained specimen. Secondary endpoints included the length and diameter of the core specimen, the diagnostic accuracy and the complication rate.

RESULTS

From June 2017 to December 2018, forty patients with pancreatic solid lesions (22 females; mean age 67.2 years) were enrolled. Tissue acquisition was achieved in all cases. High-quality histology, rated with Payne score 3, was obtained in 37/40 cases (92.5%) after two needle passes. The mean size of the acquired histological

reviewed and approved by the local ethical review board (Philipps-Universität Marburg, study number 174/16).

Clinical trial registration statement: This study has been registered at https://clinicaltrials.gov/ct2/show/NCT03621852 (ID: NCT03621852).

Informed consent statement: All the individuals who participated in this study provided their written informed consent prior to study enrolment.

Conflict-of-interest statement: Division of Endoscopy took grant from Boston Scientific Medizintechnik GmbH, outside the submitted work.

Data sharing statement: No additional data are available.

CONSORT 2010 statement: The authors have read the CONSORT 2010 statement, and the manuscript was prepared and revised according to the CONSORT 2010 Statement.

Manuscript source: Unsolicited manuscript

Received: July 29, 2020
Peer-review started: July 29, 2020
First decision: August 8, 2020
Revised: August 21, 2020
Accepted: September 15, 2020
Article in press: September 15, 2020
Published online: October 7, 2020

P-Reviewer: Chin YK
S-Editor: Gong ZM

core tissue was 1.54 mm × 0.39 mm. The diagnostic accuracy for the correct diagnosis was 85% (34/40). Only one adverse event was occurred, consisting of a self-limiting bleeding in the puncture site.

CONCLUSION

The 22G Franseen needle achieved according to our standardized protocol a high rate of histological core procurement, and a high diagnostic accuracy, with one minor adverse event reported.

Key Words: Endosonography; Fine needle biopsy; Histology; Pancreatic lesions; Franseen needle

Core Tip: Endoscopic ultrasound-guided tissue acquisition (EUS-TA) has been established in the evaluation of pancreatic masses and recently developed fine needle biopsy (FNB) needles improve the diagnostic yield of EUS-TA providing tissue blocks for performing immunohistochemistry and flow cytometry. We prospectively evaluated the Franseen needle when sampling pancreatic solid lesions. EUS-FNB with the 22-gauge Franseen needle achieved a high rate of histological core procurement and high diagnostic accuracy after only two passes and flushing out the acquired samples directly into formalin, without a rapid on-site evaluation by a cytopathologist or macroscopic on-site evaluation by the endoscopist.

Citation: Stathopoulos P, Pehl A, Breitling LP, Bauer C, Grote T, Gress TM, Denkert C, Denzer UW. Endoscopic ultrasound-fine needle biopsies of pancreatic lesions: Prospective study of histology quality using Franseen needle. *World J Gastroenterol* 2020; 26(37): 5693-5704
URL: https://www.wjgnet.com/1007-9327/full/v26/i37/5693.htm
DOI: https://dx.doi.org/10.3748/wjg.v26.i37.5693

INTRODUCTION

Endoscopic ultrasound-guided tissue acquisition (EUS-TA) has been established and is being widely used for the evaluation of pancreatobiliary masses, metastases to the liver and adrenal gland, neoplastic subepithelial gastrointestinal lesions and peri-intestinal or mediastinal lymph nodes[1]. EUS-guided fine-needle aspiration (EUS-FNA) has been traditionally used for EUS-TA based mostly on cytological evaluation.

Although EUS-FNA is considered to be very safe and have a high diagnostic accuracy, its most important limitation is the poor capability to provide tissue blocks for performing immunohistochemistry, flow cytometry and molecular analysis. Nevertheless, retention of tissue architecture and morphological characterisation of certain neoplasms (*e.g.*, presence of desmoplastic fibrosis in pancreatic cancer) may be required for individualized tumour therapy in the future[2-5]. Performing rapid on-site evaluation (ROSE) may improve the adequacy of FNA specimens and reduces the number of passes required[6-9]. Nevertheless, the presence of an onsite cytopathologist makes the procedure more time consuming and costly and is therefore not very common in European countries.

In recent years, fine needle biopsy (FNB) has been introduced in order to obtain samples with preserved tissue architecture. The FNB needle designs include reverse bevel needle (Echotip ProCore, Cook Medical), fork-tip needle (SharkCore, Medtronic) and Franseen-type needle (Acquire, Boston Scientific)[1,10].

One of the most recent introduced FNB needles mentioned above, the Franseen needle (Acquire, Boston Scientific) with three-pronged cutting edges (Franseen geometry), has been reported to acquire histological core tissue with a rate from 89.8% to 97.2%[5,11-28]. Therefore, we conducted this prospective single arm study to evaluate the quality of histologic tissue obtained with a predetermined biopsy protocol during EUS-guided sampling of pancreatic solid masses with the 22-gauge (22G) Franseen needle.

L-Editor: A
P-Editor: Wang LL

MATERIALS AND METHODS

Study design and endpoints

We performed a prospective, single-center, single-arm study of patients undergoing EUS-FNB with the 22G Acquire needle for pancreatic solid lesions at the Department of Interdisciplinary Endoscopy of the University Hospital in Marburg, Germany from June 2017 to December 2018. The study protocol conforms to the ethical guidelines of the 1975 Declaration of Helsinki as reflected in a priori approval by the institution's human research committee. The study was approved by the local ethical review board (Philipps-Universität Marburg, study number 174/16) and was registered at the ClinicalTrials.gov database (ID: NCT03621852). Each patient provided written, informed consent for the procedure and study participation.

The primary endpoint of our study was the percentage of cases in which the obtained specimen was regarded by the pathologist as representative (score 3). The quality of the histological specimens was rated with scores from 0 to 3, [0, non-representative; 1, representation questionable (poorly preserved, crush artefacts, overlapping cell groups); 2, representation limited (scant amount of diagnostic cells); 3, representative], as modified from Payne *et al*[29].

Secondary endpoints included: (1) The length and diameter of the core specimen; (2) The rate of correct diagnosis of the obtained material (diagnostic accuracy for malignancy *vs* non-malignancy); and (3) The rate of procedure-related complications. The gold standard criterion for definite diagnosis was considered as one or more of the following: (a) Definite cytopathological analysis based on EUS-FNB; (b) Surgical resection; and (c) Clinical follow-up up to 12 mo. The procedure-related complications included bleeding, perforation, acute pancreatitis or death up to 24 h after the intervention.

Patients and data collection

All the patients, between 18 and 85 years old and with an indication for EUS-TA for the assessment of pancreatic solid lesions were included. Patients were excluded if they were undergoing EUS-TA of a cystic lesion without solid tissue or had a coagulopathy (Quick time < 40% or platelets < 40 G/L) or poor performance status (American Society of Anesthesiologists physical status classification – ASA IV).

For all patients, the following parameters were recorded: Basic characteristics (age, gender, body mass index), symptoms (pain, jaundice, inappetence, weight loss), laboratory data (complete blood count, liver enzymes, international normalised ratio) and available imaging studies prior to EUS. Following procedural or lesion-related characteristics were also recorded: Size, location and echogenicity of the lesion, dose of propofol administered for sedation, size of core specimen of each needle pass, cytological/histological quality of the material, cytohistological analysis result, final diagnosis and postinterventional complications. Follow-up was performed by telephone interviews and hospital visits.

Procedure and specimen preparation

All procedures were performed under conscious sedation by means of intravenous propofol administration with a linear array echoendoscope (GF-UCT180, Olympus Europa, Hamburg, Germany) connected to a processor featuring the colour Doppler function (EU-ME2, Olympus Europa, Hamburg, Germany) by two experienced endoscopists.

After careful evaluation of the lesion with EUS and exclusion of vessel interposition along the puncture route, using the colour Doppler function, the targeted lesion was punctured by the study needle. After the needle had successfully entered the lesion, its stylet was removed and suction was applied using a 10 mL syringe, followed by 5 to 10 needle movements back and forth. The needle was withdrawn from the lesion, after suction has been released. The puncture was repeated two times according to the standardized study protocol. The obtained samples from the two passes were directly placed into formalin for histological analysis using air flushing as well as by reinsertion of the stylet into the needle. No further passes were undertaken. The acquired material was completely paraffin embedded and cut to obtain haematoxylin-eosin stained sections. If necessary, further special stainings were performed.

Statistical analysis

Previous studies evaluating the Franseen needle reported a probability of obtaining high-quality histologic material of approximately 90%. The required sample size of 40 patients was calculated to provide power > 95% (type II error < 5%) for detecting the

probability of obtaining high-quality histological material, which exceeds 70%.

Datasets were compiled by using Microsoft Excel and statistical analysis was performed using R version 3.4.1 software [R Core Team (2017). R: A language and environment for statistical computing. R Foundation for Statistical Computing, Vienna, Austria.]. Continuous variables are presented as means with standard deviation or medians with range. Categorical variables are presented as absolute values and percentages. For proportions, 95% confidence intervals were calculated using exact methods as implemented in the Hmisc add-on package [Frank E Harrell Jr, with contributions from Charles Dupont and many others. (2019). Hmisc: Harrell Miscellaneous. R package version 4.2-0]. Test-performance measures (sensitivity, specificity, predictive values) were calculated for the diagnosis of malignancy in needle biopsy compared to our gold standard for definite diagnosis. Of note, a definite diagnosis of malignancy in needle biopsy was counted as a definite final diagnosis in our definition of gold standard -motivated by clinical practice and pragmatism-, which means that false positive results were not possible, resulting in perfect specificity and positive predictive value per definitionem. The statistical methods of this study were reviewed by Lutz P Breitling from Philipps-Universität Marburg.

RESULTS

Patients' demographics and baseline characteristics

From June 2017 to December 2018, 40 patients (18 males and 22 females) with a mean age of 67.2 years were enrolled in our study (Figure 1). Patients' demographics and baseline characteristics are presented in detail in Table 1.

About 2/3 (67.5%) of the pancreatic lesions were located in the head of the gland, 8 (20%) were located in the body, and 5 (12.5%) were located in the tail. The mean lesion size was 31.5 mm. As shown in Table 2, a final diagnosis of pancreatic adenocarcinoma was made in 23 patients (57.5%), pancreatic metastases of other malignancies in 6 patients (15%), chronic pancreatitis in 3 patients (7.5%), and serous cystic neoplasm/serous cystadenoma in two patients (5%). Six patients (15%) had a variety of other diagnoses. The final diagnosis was confirmed based on definite EUS-FNB histological evaluation only in 21 patients (52.5%), surgery in 8 patients (20%), on both definite EUS-FNB and surgery in 5 patients (12.5%) and based on clinical follow-up up to 12 mo in 6 patients (15%).

Primary and secondary outcomes

Technically successful advancement of the study needle into the target lesion and tissue acquisition was achieved in 36/40 cases (90%). As shown in Table 3, material for histology was obtained in all 40 cases (100%). High-quality histology, rated with score 3, was obtained in 37/40 cases (92.5%) after two needle passes. The mean size of the acquired histological core tissue was 1.54 mm × 0.39 mm. Immunhistochemistry staining was performed in 12/40 cases (30%) to confirm the diagnosis in a lymphoma, in suspected metastatic lesions and in indeterminate cases (Figure 2).

A correct diagnosis, compared to the gold standard, was achieved in 34/40 patients (85%). Missed cases included 5 pancreatic adenocarcinomas -3 of them were misinterpreted as chronic pancreatitis in EUS-FNB- and a pancreatic metastasis of a neuroendocrine tumour originating from the ileum. In two out of six missed cases the obtained sample was not of high quality (Payne score 0 and 1) and in four cases the needle did not obviously enter the targeted lesion. In four out of six missed cases the correct diagnosis was confirmed by surgical resection. In another one was confirmed by follow-up interval imaging because the patient used best supportive care measures. The last one was confirmed by follow-up interval imaging and an interval EUS-guided FNB once again.

Only one early-adverse event was occurred, consisting of a self-limiting bleeding in the puncture site in a patient with recurrence of a pancreatic adenocarcinoma. There were no late adverse events reported in any of our patients.

DISCUSSION

The introduction of the following three FNB needles to clinical practice in recent years presents a changing trend in EUS-TA. The reverse bevel needle (Echotip ProCore, Cook Medical) has a laterally placed, reverse facing bevel. In contrast, the Fork-tip

Table 1 Patients' demographics and baseline characteristics

Parameter	Value
No. of patients	40
Age (yr), mean (SD)	67.2 (13.8)
Sex, *n* (%)	
Male	18 (45)
Female	22 (55)
BMI (kg/m^2)	24.3 (5.1)
Presenting symtom(s), *n* (%)	
Pain	15 (37.5)
Weight loss	23 (57.5)
Jaundice	9 (22.5)
Anorexia	16 (40)
Propofol sedation dose (mg)[1], mean (SD)	436 (201)
Examination prior to EUS	
Abdominal ultrasound	3 (7.5)
CT	25 (62.5)
MRI	9 (22.5)
PET/CT	3 (7.5)

[1]Data available in 36/40 patients. BMI: Body mass index; EUS: Endoscopic ultrasonography; SD: Standard deviation; CT: Computed tomography; MRI: Magnetic resonance imaging; PET/CT: Positron emission tomography/computed tomography.

needle (SharkCore, Medtronic) and the Franseen-type needle (Acquire, Boston Scientific) both have an opposing bevel design; the Fork-tip needle has two opposing bevels and the Franseen-type needle has three opposing bevels.

According to a meta-analysis by Bang *et al*[30] there is no evidence to support the superiority of ProCore over the standard FNA needle in the subgroup analysis of pancreatic mass lesions with regards to diagnostic accuracy (87% *vs* 85.3%) and histological core tissue procurement (79.2% *vs* 83.1%), except for establishing a diagnosis with fewer passes (standardized mean difference -1.03, $P < 0.001$). In contrast to the previous meta-analysis there is data supporting the superiority of the second-generation FNB needles (Franseen and Fork-tip) to FNA regarding the sample adequacy, even without ROSE. Facciorusso *et al*[21] reported in their meta-analysis a rate of histological core procurement and diagnostic accuracy of 92.5% and 95%, using the Franseen and the Fork-tip needle respectively, with no difference between the two needles. Sample adequacy in targeting pancreatic masses was superior with the two FNB needles over FNA and number of passes was significantly lower in comparison to FNA. Another recently published meta-analysis[31] reported no difference in the diagnostic yield rate between the Franseen and the Fork-tip needle (92.8% *vs* 92.7%, $P = 0.98$), giving similar results in the subgroup analysis of studies with and without ROSE (95.9% without ROSE *vs* 93.7% with ROSE), though there was no subgroup analysis of the results when targeting pancreatic lesions. Furthermore, the number of needle passes performed to obtain a successful sample was comparable between both needles.

Our study showed 90% technical success rate of EUS-FNB using the 22G Franseen needle and produced a 92.5% rate of high-quality histological tissue procurement (defined as Payne Score 3) according to a standardised protocol, namely only two needle passes, placing the obtained material directly into formalin without assessment of an on-site cytopathologist, as well as without macroscopic on-site evaluation (MOSE) by the endoscopist, taking into consideration that a visible core tissue does not always correlate with a true histologic core (tissue distortion, blood clot or necrosis). A correct diagnosis was rendered in 34/40 (85%) patients. Immunhistochemistry staining was performed in 12/40 cases (30%), where indicated.

Among prospective studies evaluating the Franseen needle alone[22,23], prospective

Table 2 Lesion characteristics

Parameter	Value
Location in pancreas, *n* (%)	
Head	27 (67.5)
Body	8 (20)
Tail	5 (12.5)
Size max (mm), mean (SD)	31.5 (12.3)
Echogenicity on EUS, *n* (%)	
Hypoechoic	34 (85)
Isoechoic	3 (7.5)
Hyperechoic	0
Non-homogeneous	3 (7.5)
Final diagnosis, *n* (%)	
Pancreatic adenocarcinoma	23 (57.5)
Pancreatic metastases[1]	6 (15)
Chronic pancreatitis	3 (7.5)
Serous cystic neoplasm/serous cystadenoma	2 (5)
Pancreatic NET	1 (2.5)
Lymphoma	1 (2.5)
Solid pseudopapillary neoplasm	1 (2.5)
Acinar cell carcinoma	1 (2.5)
Mucinous cystic neoplasm	1 (2.5)
Intrapancreatic accessory spleen	1 (2.5)
Gold standard method, *n* (%)	
Definite EUS-FNB	21 (52.5)
Definite EUS-FNB + surgery	5 (12.5)
Surgery	8 (20)
Clinical follow up	6 (15)

[1]Ileum-NET (n = 2), lung cancer (n = 2), renal cell carcinoma (n = 1), paraganglioma (n = 1). EUS-FNB: Endoscopic ultrasound-guided fine needle biopsy; NET: Neuroendocrine tumour.

comparative studies evaluating the Franseen needle *vs* FNA[5,27,28] and a prospective comparative study evaluating the Franseen needle *vs* Fork-tip needle[12], three studies[5,12,27] included only pancreatic lesions. In the other three studies[22,23,28] pancreatic lesions represented between 52% and 81% of the targeted lesions. Sugiura *et al*[23] prospectively assessed the 25G Franseen needle, whereas all other trials assessed the 22G Franseen needle.

Like our standardised protocol of only two passes, a predetermined number of passes was performed by the following trials. Mita *et al*[22] performed three passes, reporting an acquisition rate of adequate specimen for histological assessment (cellularity score ≥ 4) of 90.7% on the first pass and 98.7% on the best of three passes. Sugiura *et al*[23] performed one pass with the 25G Franseen needle, resulting in an acquisition rate of adequate specimen for histological assessment (cellularity score ≥ 4) of 81.5% when targeting pancreatic lesions. Leung *et al*[19] performed after one pass MOSE and if no macroscopic core was visualized a second pass was performed. In 93% of the targeted lesions a core histology was obtained and the final correlation of MOSE and histologic core was 94%, suggesting that MOSE could be interestingly a potential practical alternative to ROSE. In the comparative study (Franseen *vs* FNA) of Matsuno *et al*[27] one pass was performed with the Franseen needle and one pass with

Table 3 Technical characteristics and outcomes of endoscopic ultrasound-fine needle biopsies

Parameter	Value
Needle passes/patient, *n* (%)	2 (100)
Acquired histology, *n* (%)	40 (100)
Immunhistochemistry, *n* (%)	12 (30)
Histologic quality (Payne score), *n* (%)	
Score 0 (needle pass 1/needle pass 2/overall)	1 (2.5)/1 (2.5)/1 (2.5)
Score 1 (needle pass 1/needle pass 2/overall)	2 (5)/3 (7.5)/1 (2.5)
Score 2 (needle pass 1/needle pass 2/overall)	3 (7.5)/3 (7.5)/1 (2,5)
Score 3 (needle pass 1/needle pass 2/overall)	34 (85)/33 (82.5)/37 (92.5)
Histologic quality, median (range)	2.85 (0-3)
Acquired high quality histology[1],*n* (%)	
Needle pass 1/needle pass 2/overall	34 (85)/33 (82.5)/37 (92.5)
Length of the biopsy cylinder (mm), mean (SD)	
Needle pass 1/needle pass 2/overall	1.56 (0.9)/1.5 (0.9)/1.54 (0.9)
Diameter of the biopsy cylinder (mm), mean (SD)	
Needle pass 1/needle pass 2/overall	0.41 (0.1)/0.38 (0.1)/0.39 (0.1)
Diagnostic accuracy	85%[2]/89.2%[3]
Sensitivity	78%
Specificity	100%
Positive predictive value	100%
Negative predictive value	53%
Complications, *n* (%)	1 (2.5)[4]

[1]Defined as Payne score 3.
[2]In all patients (n = 40).
[3]In patients with an available high quality (Payne score 3) histological specimen (n = 37).
[4]self-limiting bleeding at puncture site.

the FNA, resulting in a rate of adequate tissue obtained of 89.3% with the Franseen needle and 62.5% with the standard needle. Finally, Asokkumar *et al*[28] performed three passes for pancreatic lesions using each needle (Franseen and FNA), reporting that FNB obtained histological core tissue more frequent than FNA (97% *vs* 77%, P = 0.03). In spite of the different definitions of an adequate tissue sample in the previously mentioned studies, Franseen needle achieved high rates (> 80%) of acquisition of high-quality histological samples on the basis of a predetermined low number of passes (1-3). These data are comparable to our study resulting in a high-quality histological tissue procurement of 92.5% performing two passes and flushing out the acquired samples directly into formalin. However, we consider that further prospective studies with a standardised protocol of a predetermined low number of needle passes are required to draw a conclusion about the need of rapid on site evaluation.

We showed in our study a diagnostic accuracy of 85%, whereas the diagnostic accuracy for pancreatic lesions in other series was reported between 90% and 97.9%[5,11,14,16,18,19,24,26,28]. Bang *et al*[5] reported a significantly higher diagnostic accuracy of Franseen needle over FNA needle (97.8% *vs* 82.6%, P = 0.03), whereas three other series demonstrated an equal to higher diagnostic accuracy, though not significantly[14,26,28].

EUS-FNB is a safe diagnostic tool. Consistently with the frequency of adverse events reported in other series[11-28] and recently published meta-analyses[21,31], between 0%-4%, we experienced only one self-limiting bleeding as adverse event in our study (2.5%).

The strengths of the present study are its prospective design, the enrolment of patients with only pancreatic solid lesions and the fact that all procedures were

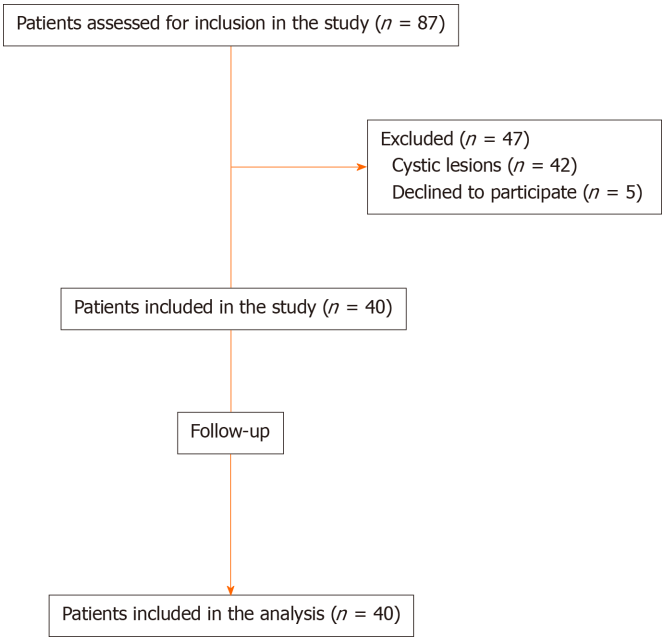

Figure 1 Study flow diagram.

performed by three experienced endoscopists. Nevertheless, it bears the limitation of only one participating centre.

CONCLUSION

In conclusion, our study showed a high rate of histological core procurement, adequate for interpretation, as well as high diagnostic accuracy, with only one minor adverse event reported. This study may suggest that two needle passes with the Franseen needle, submitting the obtained material directly into formalin and without visible assessment by the endoscopist or access to on-site cytopathologist are adequate for establishing a correct diagnosis during the evaluation of pancreatic solid lesions.

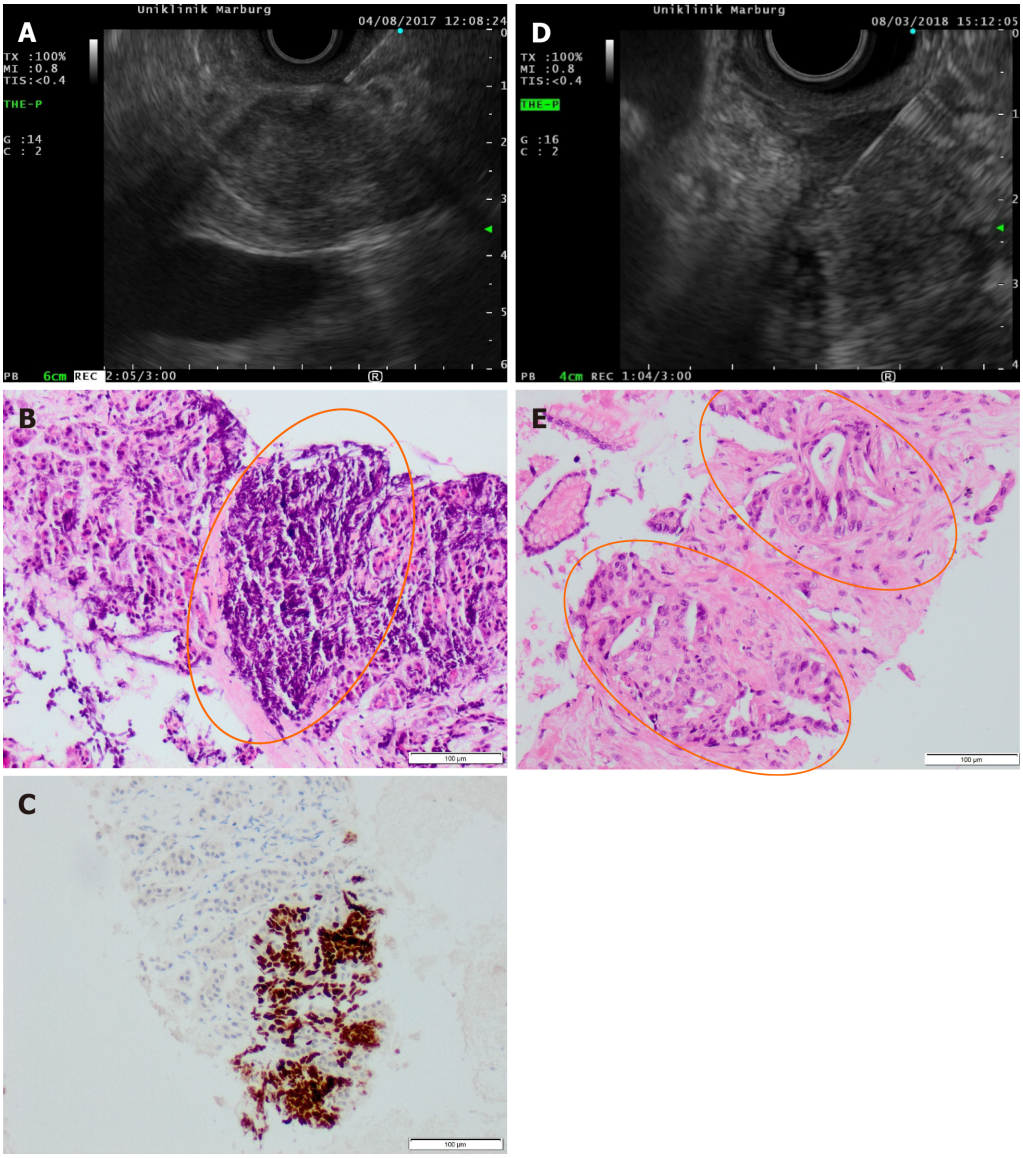

Figure 2 Endoscopic ultrasound and histology images of two lesions. A: Endoscopic ultrasound-fine needle biopsies (EUS-FNB) of a pancreatic metastasis of a non-small-cell lung cancer; B: The corresponding hematoxylin-eosin (H&E) staining (100 ×), showing a cluster of small tumor cells, high nuclear to cytoplasm ratio and crush artifacts; C: The immunohistochemistry for TTF-1 reactive in the nuclei of tumor. D: EUS-FNB of a pancreatic adenocarcinoma with the Franseen needle; E: The corresponding H&E staining (100 ×), showing characteristic infiltrating glands with tumor cells with nuclear hyperchromatism, pleiomorphism and prominent nucleoli in a cell block.

ARTICLE HIGHLIGHTS

Research background

Endoscopic ultrasound-guided tissue acquisition (EUS-TA) is an established modality for the evaluation of pancreatic lesions. Recently fine needle biopsy (FNB) has been introduced in order to obtain samples with preserved tissue architecture. Studies evaluating one of the most recent introduced FNB needles, the Franseen needle, have shown very promising results of high histological tissue acquisition rate.

Research motivation

So far there is little evidence about the performance of the Franseen needle in the evaluation of pancreatic lesions, when applying a standardised protocol of a predetermined low number of needle passes, without access to an on-site cytopathologist and flushing out the obtained material direct into formalin.

Research objectives

We performed a prospective, single-arm study to evaluate the clinical performance of the 22-gauge (22G) Franseen needle, when sampling pancreatic lesions according to a

standardised protocol, focusing on the quality of the acquired histological specimens.

Research methods

Consecutive patients with an indication for EUS-FNB for the assessment of pancreatic lesions from June 2017 to December 2018 underwent a puncture of the lesion two times using the 22G Franseen needle in our department. The obtained material was treated like a biopsy specimen, placed directly into formalin, completely embedded in paraffin and cut to provide heamatoxylin-eosin stained sections for histological analysis. Our primary endpoint was the acquisition rate of high-quality histological specimen, regarded by the pathologist as representative (Payne score 3). Secondary endpoints were size of the core specimen, the diagnostic accuracy and the complication rate. The gold standard for definite diagnosis was considered one or more of the following: A definite histology obtained from EUS-FNB, a surgical resection or clinical follow-up up to twelve months.

Research results

Forty patients with a mean age of 67.2 years were included in this study. Tissue acquisition was achieved in all cases, whereas high-quality histology, rated with Payne score 3, was obtained in 37 out of 40 cases (92.5%). A correct diagnosis (diagnostic accuracy) was made in 34 out of 40 cases (85%). The final diagnosis was confirmed based on definite EUS-FNB histology in 21 patients, on surgical resection in 8 patients, on both definite EUS-FNB and surgery in 5 further patients and on interval follow-up in 6 patients. The only complication occurred was a self-limiting bleeding in the puncture site.

Research conclusions

We demonstrated that EUS-FNB of pancreatic lesions with the 22G Franseen needle following a standardised simplified protocol achieved a high acquisition rate of representative histological specimen and a high diagnostic accuracy.

Research perspectives

We consider that further prospective studies with a standardised protocol of a predetermined low number of needle passes are required to draw a conclusion about the need of ROSE.

REFERENCES

1 **Wani S**, Muthusamy VR, McGrath CM, Sepulveda AR, Das A, Messersmith W, Kochman ML, Shah J. AGA White Paper: Optimizing Endoscopic Ultrasound-Guided Tissue Acquisition and Future Directions. *Clin Gastroenterol Hepatol* 2018; **16**: 318-327 [PMID: 29074447 DOI: 10.1016/j.cgh.2017.10.020]

2 **Ribeiro A**, Vazquez-Sequeiros E, Wiersema LM, Wang KK, Clain JE, Wiersema MJ. EUS-guided fine-needle aspiration combined with flow cytometry and immunocytochemistry in the diagnosis of lymphoma. *Gastrointest Endosc* 2001; **53**: 485-491 [PMID: 11275890 DOI: 10.1067/mge.2001.112841]

3 **Kopelman Y**, Marmor S, Ashkenazi I, Fireman Z. Value of EUS-FNA cytological preparations compared with cell block sections in the diagnosis of pancreatic solid tumours. *Cytopathology* 2011; **22**: 174-178 [PMID: 20482717 DOI: 10.1111/j.1365-2303.2010.00766.x]

4 **Varadarajulu S**, Bang JY, Holt BA, Hasan MK, Logue A, Hawes RH, Hebert-Magee S. The 25-gauge EUS-FNA needle: Good for on-site but poor for off-site evaluation? Results of a randomized trial. *Gastrointest Endosc* 2014; **80**: 1056-1063 [PMID: 24973173 DOI: 10.1016/j.gie.2014.05.304]

5 **Bang JY**, Hebert-Magee S, Navaneethan U, Hasan MK, Hawes R, Varadarajulu S. EUS-guided fine needle biopsy of pancreatic masses can yield true histology. *Gut* 2018; **67**: 2081-2084 [PMID: 28988195 DOI: 10.1136/gutjnl-2017-315154]

6 **Hébert-Magee S**, Bae S, Varadarajulu S, Ramesh J, Frost AR, Eloubeidi MA, Eltoum IA. The presence of a cytopathologist increases the diagnostic accuracy of endoscopic ultrasound-guided fine needle aspiration cytology for pancreatic adenocarcinoma: a meta-analysis. *Cytopathology* 2013; **24**: 159-171 [PMID: 23711182 DOI: 10.1111/cyt.12071]

7 **Matynia AP**, Schmidt RL, Barraza G, Layfield LJ, Siddiqui AA, Adler DG. Impact of rapid on-site evaluation on the adequacy of endoscopic-ultrasound guided fine-needle aspiration of solid pancreatic lesions: a systematic review and meta-analysis. *J Gastroenterol Hepatol* 2014; **29**: 697-705 [PMID: 24783248 DOI: 10.1111/jgh.12431]

8 **Kong F**, Zhu J, Kong X, Sun T, Deng X, Du Y, Li Z. Rapid On-Site Evaluation Does Not Improve Endoscopic Ultrasound-Guided Fine Needle Aspiration Adequacy in Pancreatic Masses: A Meta-Analysis and Systematic Review. *PLoS One* 2016; **11**: e0163056 [PMID: 27657529 DOI: 10.1371/journal.pone.0163056]

9 **Hewitt MJ**, McPhail MJ, Possamai L, Dhar A, Vlavianos P, Monahan KJ. EUS-guided FNA for diagnosis of solid pancreatic neoplasms: a meta-analysis. *Gastrointest Endosc* 2012; **75**: 319-331 [PMID: 22248600 DOI: 10.1016/j.gie.2011.08.049]

10 **Polkowski M**, Jenssen C, Kaye P, Carrara S, Deprez P, Gines A, Fernández-Esparrach G, Eisendrath P, Aithal GP, Arcidiacono P, Barthet M, Bastos P, Fornelli A, Napoleon B, Iglesias-Garcia J, Seicean A, Larghi A, Hassan C, van Hooft JE, Dumonceau JM. Technical aspects of endoscopic ultrasound (EUS)-guided sampling in gastroenterology: European Society of Gastrointestinal Endoscopy (ESGE) Technical Guideline - March 2017. *Endoscopy* 2017; **49**: 989-1006 [PMID: 28898917 DOI: 10.1055/s-0043-119219]

11 **Bang JY**, Hebert-Magee S, Hasan MK, Navaneethan U, Hawes R, Varadarajulu S. Endoscopic ultrasonography-guided biopsy using a Franseen needle design: Initial assessment. *Dig Endosc* 2017; **29**: 338-346 [PMID: 27878861 DOI: 10.1111/den.12769]

12 **Bang JY**, Hebert-Magee S, Navaneethan U, Hasan MK, Hawes R, Varadarajulu S. Randomized trial comparing the Franseen and Fork-tip needles for EUS-guided fine-needle biopsy sampling of solid pancreatic mass lesions. *Gastrointest Endosc* 2018; **87**: 1432-1438 [PMID: 29305893 DOI: 10.1016/j.gie.2017.11.036]

13 **Adler DG**, Muthusamy VR, Ehrlich DS, Parasher G, Thosani NC, Chen A, Buscaglia JM, Appannagari A, Quintero E, Aslanian H, Taylor LJ, Siddiqui A. A multicenter evaluation of a new EUS core biopsy needle: Experience in 200 patients. *Endosc Ultrasound* 2019; **8**: 99-104 [PMID: 29623911 DOI: 10.4103/eus.eus_53_17]

14 **Mukai S**, Itoi T, Yamaguchi H, Sofuni A, Tsuchiya T, Tanaka R, Tonozuka R, Honjo M, Fujita M, Yamamoto K, Matsunami Y, Asai Y, Kurosawa T, Nagakawa Y. A retrospective histological comparison of EUS-guided fine-needle biopsy using a novel franseen needle and a conventional end-cut type needle. *Endosc Ultrasound* 2019; **8**: 50-57 [PMID: 29786033 DOI: 10.4103/eus.eus_11_18]

15 **Abdelfatah MM**, Grimm IS, Gangarosa LM, Baron TH. Cohort study comparing the diagnostic yields of 2 different EUS fine-needle biopsy needles. *Gastrointest Endosc* 2018; **87**: 495-500 [PMID: 28882575 DOI: 10.1016/j.gie.2017.08.033]

16 **Bang JY**, Kirtane S, Krall K, Navaneethan U, Hasan M, Hawes R, Varadarajulu S. In memoriam: Fine-needle aspiration, birth: Fine-needle biopsy: The changing trend in endoscopic ultrasound-guided tissue acquisition. *Dig Endosc* 2019; **31**: 197-202 [PMID: 30256458 DOI: 10.1111/den.13280]

17 **El Hajj II**, Wu H, Reuss S, Randolph M, Harris A, Gromski MA, Al-Haddad M. Prospective Assessment of the Performance of a New Fine Needle Biopsy Device for EUS-Guided Sampling of Solid Lesions. *Clin Endosc* 2018; **51**: 576-583 [PMID: 30001616 DOI: 10.5946/ce.2018.053]

18 **Haseeb A**, Taylor LJ, Adler DG. Comparing endoscopic ultrasound-guided core biopsies of solid pancreatic and extrapancreatic lesions: a large single-operator experience with a new fine-needle biopsy needle. *Ann Gastroenterol* 2018; **31**: 742-746 [PMID: 30386126 DOI: 10.20524/aog.2018.0313]

19 **Leung Ki EL**, Lemaistre AI, Fumex F, Gincul R, Lefort C, Lepilliez V, Pujol B, Napoléon B. Macroscopic onsite evaluation using endoscopic ultrasound fine needle biopsy as an alternative to rapid onsite evaluation. *Endosc Int Open* 2019; **7**: E189-E194 [PMID: 30705952 DOI: 10.1055/a-0770-2726]

20 **Ishikawa T**, Kawashima H, Ohno E, Tanaka H, Sakai D, Iida T, Nishio R, Yamamura T, Furukawa K, Nakamura M, Miyahara R, Hashimoto S, Ishigami M, Hirooka Y. Clinical Impact of EUS-Guided Fine Needle Biopsy Using a Novel Franseen Needle for Histological Assessment of Pancreatic Diseases. *Can J Gastroenterol Hepatol* 2019; **2019**: 8581743 [PMID: 30854353 DOI: 10.1155/2019/8581743]

21 **Facciorusso A**, Del Prete V, Buccino VR, Purohit P, Setia P, Muscatiello N. Diagnostic yield of Franseen and Fork-Tip biopsy needles for endoscopic ultrasound-guided tissue acquisition: a meta-analysis. *Endosc Int Open* 2019; **7**: E1221-E1230 [PMID: 31579703 DOI: 10.1055/a-0982-2997]

22 **Mita N**, Iwashita T, Uemura S, Iwasa Y, Toda K, Mukai T, Miyazaki T, Yasuda I, Shimizu M. Endoscopic Ultrasound-Guided Fine Needle Biopsy Using 22-Gauge Franseen Needle for the Histological Diagnosis of Solid Lesions: A Multicenter Prospective Pilot Study. *Dig Dis Sci* 2020; **65**: 1155-1163 [PMID: 31531819 DOI: 10.1007/s10620-019-05840-y]

23 **Sugiura R**, Kuwatani M, Yane K, Taya Y, Ihara H, Onodera M, Eto K, Sano I, Kudo T, Mitsuhashi T, Katanuma A, Sakamoto N; Hokkaido Interventional EUS/ERCP study (HONEST) group. Prospective, multicenter, observational study of tissue acquisition through EUS-guided fine-needle biopsy using a 25G Franseen needle. *Endosc Ultrasound* 2019; **8**: 321-328 [PMID: 30880724 DOI: 10.4103/eus.eus_66_18]

24 **Mitri RD**, Rimbaş M, Attili F, Fabbri C, Carrara S, Di Maurizio L, Inzani F, Repici A, Gasbarrini A, Costamagna G, Larghi A. Performance of a new needle for endoscopic ultrasound-guided fine-needle biopsy in patients with pancreatic solid lesions: A retrospective multicenter study. *Endosc Ultrasound* 2018; **7**: 329-334 [PMID: 28836520 DOI: 10.4103/eus.eus_33_17]

25 **Alkhateeb K**, Lee BB, Alatassi H, Sanders MA, Omer EM, McClave SA, Fraig M. Comparison between two types of needles for Endoscopic Ultrasound (EUS)-guided fine aspiration biopsy of pancreatic and upper gastrointestinal masses. *Diagn Cytopathol* 2020; **48**: 197-202 [PMID: 31850666 DOI: 10.1002/dc.24361]

26 **Fujita A**, Ryozawa S, Mizuide M, Araki R, Nagata K, Tanisaka Y, Harada M, Ogawa T, Tashima T, Nonaka K. Does endoscopic ultrasound-guided fine needle biopsy using a Franseen needle really offer high diagnostic accuracy? A propensity-matched analysis. *Endosc Int Open* 2019; **7**: E1327-E1332 [PMID: 31673602 DOI: 10.1055/a-0957-3005]

27 **Matsuno J**, Ogura T, Kurisu Y, Miyano A, Imanishi M, Onda S, Okuda A, Nishioka N, Higuchi K. Prospective comparison study of franseen needle and standard needle use for pancreatic lesions under EUS guidance. *Endosc Ultrasound* 2019; **8**: 412-417 [PMID: 31417069 DOI: 10.4103/eus.eus_38_19]

28 **Asokkumar R**, Yung Ka C, Loh T, Kah Ling L, Gek San T, Ying H, Tan D, Khor C, Lim T, Soetikno R. Comparison of tissue and molecular yield between fine-needle biopsy (FNB) and fine-needle aspiration (FNA): a randomized study. *Endosc Int Open* 2019; **7**: E955-E963 [PMID: 31367675 DOI: 10.1055/a-0903-2565]

29 **Payne M**, Staerkel G, Gong Y. Indeterminate diagnosis in fine-needle aspiration of the pancreas: reasons and clinical implications. *Diagn Cytopathol* 2009; **37**: 21-29 [PMID: 18973122 DOI: 10.1002/dc.20949]

30 **Bang JY**, Hawes R, Varadarajulu S. A meta-analysis comparing ProCore and standard fine-needle aspiration needles for endoscopic ultrasound-guided tissue acquisition. *Endoscopy* 2016; **48**: 339-349 [PMID: 26561917 DOI: 10.1055/s-0034-1393354]

31 **Mohan BP**, Shakhatreh M, Garg R, Asokkumar R, Jayaraj M, Ponnada S, Navaneethan U, Adler DG. Comparison of Franseen and fork-tip needles for EUS-guided fine-needle biopsy of solid mass lesions: A

systematic review and meta-analysis. *Endosc Ultrasound* 2019; **8**: 382-391 [PMID: 31249163 DOI: 10.4103/eus.eus_27_19]

World Journal of Gastroenterology

Submit a Manuscript: https://www.f6publishing.com

World J Gastroenterol 2020 October 7; 26(37): 5705-5717

DOI: 10.3748/wjg.v26.i37.5705

ISSN 1007-9327 (print) ISSN 2219-2840 (online)

ORIGINAL ARTICLE

Prospective Study

Risk prediction rule for advanced neoplasia on screening colonoscopy for average-risk individuals

Ala I Sharara, Ali El Mokahal, Ali H Harb, Natalia Khalaf, Fayez S Sarkis, Mustapha M El-Halabi, Nabil M Mansour, Ahmad Malli, Robert Habib

ORCID number: Ala I Sharara 0000-0003-0248-9527; Ali El Mokahal 0000-0002-2129-9203; Ali H Harb 0000-0002-5827-2098; Natalia Khalaf 0000-0002-7585-6183; Fayez S Sarkis 0000-0003-4250-6985; Mustapha M El-Halabi 0000-0002-7688-0732; Nabil M Mansour 0000-0002-5660-8942; Ahmad Malli 0000-0001-8130-138; Robert Habib 0000-0003-2877-4481.

Author contributions: Sharara AI contributed to study conception, design and supervision; oversight of data collection and interpretation; review of literature; drafting of the manuscript; guarantor of the study; El Mokahal A and Harb AH contributed to review of the literature, regulatory administration, data entry and analysis, drafting and critical review of the manuscript; Khalaf N contributed to review of the literature, data analysis, critical review and editing of the manuscript; Sarkis F, El-Halabi MM, Mansour NM and Malli A contributed to regulatory administration, data entry and analysis, critical review and editing of the manuscript; Habib R contributed to interpretation of data, statistical expertise, critical review and editing of the manuscript; all authors have read

Ala I Sharara, Ali El Mokahal, Division of Gastroenterology, Department of Internal Medicine, American University of Beirut Medical Center, Beirut 1107 2020, Lebanon

Ali H Harb, Digestive and Liver Diseases Division, University of Texas-Southwestern, Dallas, TX 75390, United States

Natalia Khalaf, Division of Gastroenterology, Department of Internal Medicine, Baylor College of Medicine, Houston, TX 77030, United States

Fayez S Sarkis, Division of Gastroenterology and Hepatology, University of Kansas Medical Center, Kansas City, MO 66160, United States

Mustapha M El-Halabi, Division of Gastroenterology, St Elizabeth Healthcare, Crestview Hills, KY 41017, United States

Nabil M Mansour, Department of Internal Medicine, Section of Gastroenterology and Hepatology, Baylor College of Medicine, Houston, TX 77030, United States

Ahmad Malli, Gastroenterology, Hennepin Healthcare, Minneapolis, MN 55404, United States

Robert Habib, Department of Internal Medicine, American University of Beirut, Beirut 1107 2020, Lebanon

Corresponding author: Ala I Sharara, AGAF, FACG, FRCP, MD, Attending Doctor, Professor, Division of Gastroenterology, Department of Internal Medicine, American University of Beirut Medical Center, Cairo Street, PO Box 11-0236/16-B, Beirut 1107 2020, Lebanon. as08@aub.edu.lb

Abstract

BACKGROUND

In resource-limited countries, risk stratification can be used to optimize colorectal cancer screening. Few prospective risk prediction models exist for advanced neoplasia (AN) in true average-risk individuals.

AIM

To create and internally validate a risk prediction model for detection of AN in average-risk individuals.

METHODS
Prospective study of asymptomatic individuals undergoing first screening colonoscopy. Detailed characteristics including diet, exercise and medications were collected. Multivariate logistic regression was used to elucidate risk factors for AN (adenoma ≥1 cm, villous histology, high-grade dysplasia or carcinoma). The model was validated through bootstrapping, and discrimination and calibration of the model were assessed.

RESULTS
980 consecutive individuals (51% F; 49% M) were enrolled. Adenoma and AN detection rates were 36.6% (F 29%: M 45%; $P < 0.001$) and 5.1% (F 3.8%; M 6.5%) respectively. On multivariate analysis, predictors of AN [OR (95%CI)] were age [1.036 (1.00-1.07); $P = 0.048$], BMI [overweight 2.21 (0.98-5.00); obese 3.54 (1.48-8.50); $P = 0.018$], smoking [< 40 pack-years 2.01 (1.01-4.01); ≥ 40 pack-years 3.96 (1.86-8.42); $P = 0.002$], and daily red meat consumption [2.02 (0.92-4.42) $P = 0.079$]. Nomograms of AN risk were developed in terms of risk factors and age separately for normal, overweight and obese individuals. The model had good discrimination and calibration.

CONCLUSION
The prevalence of adenoma and AN in average-risk Lebanese individuals is similar to the West. Age, smoking, and BMI are important predictors of AN, with obesity being particularly powerful. Though external validation is needed, this model provides an important platform for improved risk-stratification for screening programs in regions where universal screening is not currently employed.

Key Words: Colon; Adenoma; Cancer; Risk factors

Core Tip: Colonoscopy is a powerful tool for colorectal cancer screening, but its wide adoption may incur a large burden on healthcare systems. Risk stratification may be an attractive strategy particularly in resource-constrained settings. Previously developed risk calculators have important limitations including retrospective design and/or inclusion of at-risk individuals such as those with a positive family history. Using 4 easy-to-obtain baseline variables (BMI, smoking, age, and red meat consumption), we present a risk calculator for advanced neoplasia in true average-risk individuals. This simple tool can be used to stratify patients for colorectal cancer screening but requires external validation.

Citation: Sharara AI, El Mokahal A, Harb AH, Khalaf N, Sarkis FS, M El-Halabi M, Mansour NM, Malli A, Habib R. Risk prediction rule for advanced neoplasia on screening colonoscopy for average-risk individuals. *World J Gastroenterol* 2020; 26(37): 5705-5717
URL: https://www.wjgnet.com/1007-9327/full/v26/i37/5705.htm
DOI: https://dx.doi.org/10.3748/wjg.v26.i37.5705

INTRODUCTION

Colorectal cancer (CRC) carries a large burden of cancer-related morbidity and mortality. In 2018, CRC was the 3rd most common malignancy and the 2nd deadliest cancer, with more than 1800000 new cases and 881000 attributable deaths worldwide[1]. The lifetime risk of CRC in patients at average risk is estimated to be 4.2% in women and 4.6% in men without screening[2]. The pathogenesis of CRC is characterized by its slow progression from a benign preneoplastic lesion to a malignant carcinoma, with an estimated natural history of over 10 years for this process to occur[3]. This allows for prevention by removing precursors prior to malignant transformation, as well as early treatment by detecting the neoplastic lesion at an early stage[4]. Advanced adenomas have a 25%-40% cumulative 10-year risk of progression to CRC depending on patient age[5]. Survival is related to stage at diagnosis[2], and thus earlier detection leads to better outcomes.

and approved the final manuscript.

Institutional review board statement: The study was reviewed and approved by the institutional review board of the American University of Beirut Medical Center (AUBMC).

Informed consent statement: All study participants or their legal guardian provided written consent prior to study enrollment.

Conflict-of-interest statement: The authors of this manuscript have no conflict of interest to disclose.

Data sharing statement: No additional data available.

Manuscript source: Invited manuscript

Received: April 17, 2020
Peer-review started: April 17, 2020
First decision: May 15, 2020
Revised: May 20, 2020
Accepted: September 12, 2020
Article in press: September 12, 2020
Published online: October 7, 2020

P-Reviewer: Zhao ZY
S-Editor: Liu JH
L-Editor: A
P-Editor: Ma YJ

Screening through the use of fecal occult blood tests (FOBT), sigmoidoscopy and colonoscopy have been found to decrease both the incidence and mortality of CRC[6]. Screening programs have been instituted in many countries around the world. Published guidelines from multiple medical societies recommend screening all average-risk adults beginning at age 50, with the most commonly used modalities being colonoscopy and stool-based tests such an annual fecal immunohistochemistry testing (FIT) or FOBT. Less commonly employed methods of screening include flexible sigmoidoscopy, virtual colonoscopy and multi-targeted stool DNA testing. Some recommend earlier screening for patients depending on race and/or family history, but these recommendations do not employ risk stratification based on other risk factors of advanced neoplasia (AN) or CRC. Notably, resource-sensitive guidelines for screening have been recently published by the American Society of Clinical Oncology[6-9]. These guidelines recommend screening average risk individuals with colonoscopy only as an option in optimal settings[10]. In resource limited settings, screening through FIT, FOBT or a combination of sigmoidoscopy and FIT is recommended[10].

The Center for Disease Control and Prevention reports that 68.8% of age-eligible patients in the United States were screened in 2018[11]. However, screening rates around the world are not homogenous, with rates of 55% in Canada and 36% in France[12,13]. In Lebanon, CRC incidence is 12.6 and 10.7 per 100000 for men and women respectively[14], with an increasing trend possibly due to the increasing prevalence of risk factors such as obesity, tobacco use and increasing life expectancy. This is the second highest incidence rate of colorectal cancer in the Middle East and North Africa (MENA) region[14]. No formal study has evaluated the percentage of age-eligible patients who have received colorectal cancer screening, but one study reported a rate of 15% in an inpatient cohort aged 25 and older[15]. This makes improved enrollment in screening programs and the subsequent detection of adenomas and AN of crucial importance in Lebanon and similar regions where no national screening programs have been formally implemented.

Clinically usable risk assessment tools are powerful strategies by which healthcare systems and individual providers in resource-limited settings can optimize AN and early CRC detection strategies. Recently, the Lebanese Society of Gastroenterology and the Ministry of Health issued CRC screening guidelines[16]. As new programs can often result in enormous burden on the healthcare system and difficulty with implementation[17], especially in more remote regions, we set out to develop a risk prediction model for AN and CRC risk on screening colonoscopy based on easy to assess, previously validated clinical risk factors given the lack of such tools in Lebanon, the broader MENA region and similar healthcare systems. Quantifying the effect of risk factors on the detection of AN will provide a tailored tool that highlights high-risk characteristics and allow physicians and public health agencies to more efficiently target those at highest risk for both engagement in screening programs and discussion regarding risk factor modification.

MATERIALS AND METHODS

Setting

This was a prospective cohort study conducted at the American University of Beirut Medical Center (AUBMC). Over a 5-year period, 980 consecutive average-risk, asymptomatic patients scheduled for screening colonoscopy were prospectively enrolled in the study if they were aged 50 years or above and presenting for first-time screening. Patients were excluded if they had a prior history of colonoscopy, known colon polyps, inflammatory bowel disease, had undergone previous colonic resection or had family history of CRC or AN in any first-degree relative or two or more second degree relatives at any age. Diagnostic colonoscopies done for symptoms such as bleeding or abdominal pain were excluded. 92% of endoscopic examinations were performed by 4 senior attendings with > 10 years of experience. Only patients with an adequate bowel preparation (defined as excellent or good on the Aronchick scale)[18] were included. The study protocol was approved by the AUBMC Institutional Review Board and all patients provided informed consent. AUBMC is an urban, private not-for-profit, academic tertiary care center in Beirut, Lebanon.

Data collection

The study coordinator approached eligible patients prior to their procedure, obtained informed consent and then interviewed the patients using a paper-based

questionnaire. This questionnaire included questions on 18 factors on the following categories: Demographics, Tobacco and alcohol use, Dietary Patterns, and concomitant medical history and medication use. We specifically inquired about the use of medications and supplements such as aspirin, nonsteroidal anti-inflammatory drugs, oral contraceptive pills/hormone replacement therapy and calcium supplements. We also inquired about the consumption of poultry, red meat, dairy and vegetables.

Information on withdrawal time, quality of bowel preparation, location, size, number and histology of polyps was collected. AN was defined as a tubular adenoma or serrated lesion ≥ 10 mm in size, any adenoma with villous features, or any lesion with high-grade dysplasia or carcinoma. In cases of multiple polyps, classification was based on the most advanced histology.

Statistical analysis

Patients' socio-demographics, clinical and dietary habits and colonoscopy results were compared by univariate analysis for patients with and without confirmed AN. Continuous variables were summarized as mean ± SD and as median + interquartile range. Categorical factors were summarized as counts and percentages (%). Group comparisons of qualitative variables were performed using χ^2 tests and Analysis of variance (ANOVA) tests as applicable, and post-hoc analyses were also conducted. For comparisons of quantitative variables, independent *t*-test or Mann Whitney tests were used based on the normality of data. A two-sided *P* value less than 0.05 was used to indicate statistical significance. Statistical analyses were conducted using IBM Statistical Package for Social Sciences (SPSS), version 24 (IBM SPSS Statistics for Windows, Version 24.0. Armonk, NY: IBM Corp). A backward multivariable binary logistic regression was used to determine independent predictors of AN in the study population. For each risk factor, we derived odds ratios (OR) and corresponding 95% confidence intervals (CIs). Model results were confirmed in forward fashion *via* bootstrapping 1000 times and were used to derive the adjusted ORs with 95%CIs for all predictor variables.

The discriminatory ability of this model was assessed using the area under the Receiver-Operator-Characteristic (ROC) curve. Model calibration was examined using observed versus expected AN rate in logistic regression model derived probability of AN decile groups. The robustness of the model estimates was further tested using a 1000 bootstrap from which the corresponding *P* values and 95%CIs were derived and compared to those derived by the backward model. The multivariate model coefficients were used to calculate % Risk of (AN) in nomogram format as a function of patient age and separately for normal body mass index (BMI), overweight and obese patients. The model coefficients were then used to develop a risk calculator. The risk calculator provides an output percentage risk of AN as a function of patient age, BMI, smoking status and daily consumption of red meat.

RESULTS

Patient characteristics

The characteristics of the patients enrolled are listed in Table 1. The mean age of the patients was 61 ± 8 years; 501 females (51.1%) and 479 (48.9%) males were enrolled. Of those, 330 patients had a BMI < 25 kg/m^2 (34%), 454 (46%) had a BMI between 25 and 30 kg/m^2 and 196 (20%) had a BMI > 30 kg/m^2. More than half the patients (53%) were smokers. Daily red meat consumption was reported by 9.2% of the enrolled patients and 10.2% consumed alcohol daily.

Colonoscopy and Pathology Findings

Of the 980 patients enrolled, 62.7% were found to have no polyp, 36.6% had tubular adenomas, 3.5% had adenoma ≥ 1 cm, 1.4% had villous histology, and 0.8% had carcinoma. The overall adenoma detection rate was 36.6% (F 29%: M 45%; $P < 0.001$). In total, 50 patients were found to have AN, making up 5.1% of the patients (F 3.8%; M 6.5%) enrolled in the study. The distribution of the adenomas was as follows: 29.2% of the patients had right sided adenomas, 37.7% had left sided adenomas, and 33.1% had adenomas on both sides.

Univariate analysis of risk factors for AN

The following factors were found to be significantly associated with AN risk on univariate analysis (Table 1): BMI both when categorized into obese, overweight and

Table 1 Univariate analysis of clinical features and detection of advanced neoplasia

Characteristic	Total	Absence of AN	Presence of AN	*P* value
	n (%)	*n* (%)	*n* (%)	
Age (mean ± SD)	980 (100)	61 ± 8	63 ± 9	0.242
Median, IQR		60, 12	63, 13	
Male	479 (48.9)	448 (48.2)	31(62.0)	0.07
Smoking	460 (46.9)	425 (45.7)	35 (70.0)	**0.01**
Daily bowel movement	859 (87.7)	814 (87.6)	45 (90.0)	0.62
Caffeine	885 (90.3)	836 (89.9)	49 (98.0)	0.06
Exercise	544 (55.5)	52 (56.5)	19 (38.0)	**0.01**
Alcohol	491 (50.1)	468 (50.3)	23 (46.0)	0.55
Daily red meat consumption	90 (9.2)	81 8.7)	9 (18.0)	**0.03**
Daily poultry consumption	39 (4.0)	37 (4.0)	2 (4.0)	0.99
Daily dairy consumption	744 (75.9)	703 (75.6)	41 (82.0)	0.30
Daily fruit/vegetable consumption	909 (92.8)	865 (93.0)	44 (88.0)	0.18
NSAID use	177 (18.1)	171 (18.4)	6 (12.0)	1.31
Aspirin use	312 (31.8)	294 (31.6)	18 (36.0)	0.42
Multi vitamin/antixoidant use	415 (42.3)	397 (42.7)	18 (36.0)	0.87
Oral contraceptive pills/hormone replacement therapy used	126 (12.9)	121 (13.0)	5 (10.0)	0.38
Calcium supplementation	429 (43.8)	413 (44.4)	16 (32.0)	0.30
Diabetes mellitus	80 (8.2)	74 (8.0)	6 (12.0)	1.04
Body Mass Index (BMI)				**0.01**
mean ± SD	980 (100)	26.7 ± 4.1	28.4 ± 3.3	**0.01**
Median, IQR		26.7, 5.1	28.5, 4.5	
< 25[a]	330 (33.7)	322 (34.6)	8 (16.0)	
25-30	454 (46.3)	429 (46.1)	25 (50.0)	
> 30[a]	196 (20.0)	179 (19.2)	17 (34.0)	
Pack years				**< 0.01**
mean ± SD	980 (100)	13 ± 21	29 ± 33	**< 0.01**
Median, IQR		0, 20	18, 40	
≤ 10[a]	520 (53.1)	505 (54.3)	15 (30.0)	
11-40[a]	331 (33.8)	311 (33.4)	20 (40.0)	
> 40[a]	129 (13.2)	114 (12.3)	15 (30.0)	
Frequency of alcohol intake				0.8
None	489 (49.9)	462 (49.7)	27 (54.0)	
< 1 drink daily	391 (39.9)	377 (40.5)	14 (28.0)	
At least 1 drink daily	100 (10.2)	91 (9.8)	9 (18.0)	
Daily alcohol consumption	100 (10.2)	91 (9.8)	9 (18.0)	0.06
Body surface area (mean ± SD)		1.8 ± 2.045	1.9 ± 0.02	**0.02**
Median, IQR		1.8, 0.28	1.9, 0.22	

[a]Indicates significance on posthoc analysis ($P < 0.05$), AN: Advanced neoplasia.

normal, and when taken as a continuous variable. Daily red meat consumption, smoking as a qualitative variable and pack years smoked (both when grouped and when treated as a numeric variable), and exercise. Factors that were not associated with AN risk were age, alcohol consumption, or the presence of diabetes.

Development of a risk model for AN

We used backward binary logistic regression. Variables were removed from our model in case the *P* value found on logistic regression was ≥ 1. BMI values were grouped into 3 categories (< 25, 25-30 and > 30), smoking was quantified by pack years and age was taken as a continuous variable. Daily red meat consumption was categorized as yes or no. Independent predictors of AN were age [OR = 1.036 (CI = 1.00-107), *P* 0.048], higher BMI (*vs* Normal BMI ≤ 25) if [Overweight: OR = 2.21 (CI = 0.98-5.00); Obese: OR = 3.54 (CI = 1.48-8.50) *P* 0.018], tobacco pack-years [< 40: OR = 2.01 (1.01-4.01); ≥ 40: 3.96 (1.86-8.42); *P* 0.002] and daily read meat consumption [OR = 2.02 (0.92-4.42) *P* 0.079] (Table 2).

Internal validation of the model was done *via* bootstrapping and the results are shown in Table 2. The discrimination of the model was then assessed by the Area Under the Curve (AUC) of the ROC (Figure 1). We found an AUC of 0.73 (CI = 0.66-0.79, *P* < 0.001). Model calibration was assessed by plotting observed *vs* expected results of AN (Figure 2). A linear trend of y = 0.9204x + 0.0041 was found, with an R^2 of 0.8509. Using the β coefficients derived from the regression, the percent risk of AN was then calculated through a 4-factor model (age, BMI, smoking, pack years). We plotted the percent risk of AN as a function of age for the 3 separate categories of BMI, and we plotted multiple lines to show the effects of pack years smoked and the daily consumption of red meat. (Figure 3) Finally, we used the β coefficients derived by multivariate analysis to construct a risk calculator for the detection of advanced neoplasia for individuals undergoing initial screening with endoscopy. We published this risk calculator (Risk Calculator for Advanced Neoplasia for Average Risk Individuals Undergoing Screening Colonoscopy) online at http://anriskcalc.000webhostapp.com.

DISCUSSION

This cross-sectional prospective study resulted in the development of the first internally validated risk assessment tool for predicting presence of AN in an average risk cohort from the MENA region. Previous studies on Middle Eastern populations had only assessed the factors associated with development of CRC and not AN in case control studies[19-21]. Our model has good discriminatory ability through internal validation by bootstrapping. The AUCs of similar models have ranged from 0.65-0.75, showing that the discriminatory ability of the developed model is on the higher end of this range[19]. The model was also found to be well calibrated, meaning that the probabilities predicted matched the empirically derived probabilities well. We found that age, smoking and BMI were the most important risk factors for the detection of AN. These are well established risk factors that have been used in many models of colon cancer risk with biological plausibility previously explored[15,19].

We chose to exclude any patients who underwent prior CRC screening, and patients with a positive family history. As previously argued[22], prior colonoscopy is an extremely powerful surveillance tool that is able to overshadow any baseline risk stratification. A family history positive for CRC has a similar impact. Including these patient populations serves as a significant source of bias when attempting to develop risk prediction models for true average-risk individuals. In our review of the literature (Table 3), we found that of the 22 risk prediction models for average-risk individuals undergoing screening colonoscopy[24-29,33-48], only 2 excluded patients who underwent a prior colonoscopy and those with a family history of colon cancer[34,41]. One was based on a retrospective study, limiting the ability to assess the influence of life-style factors[41], while the second enrolled any patient above the age of 20[34], inconsistent with guidelines-based recommendations for CRC screening.

Although the association between age and AN was not found to be a strong one when analyzed as the variable of interest in logistic regression it remains a well-known important predictor of AN, clearly demonstrated by the nomograms in Figure 3, in which the risk of AN increases after age of 50, with steeper slope after the age of 65.

Our data also supports age as a risk factor for AN with an additive effect when combined with other risk factors such as increasing BMI and smoking. Age has been used in all 17 risk prediction models identified by a systematic review[23]. The effect of

Table 2 Binary logistic regression and internal validation

Patient factors	Binary logistic regression				1000 bootstrap	
	β-coefficient	SE	*P* value	OR (95%CI)	*P* value	AOR (95%CI)
Age (yr)	0.035	0.018	0.048	1.04 (1-1.07)	0.047	1.04 (1-1.08)
BMI category						
Normal (< 25 kg/m^2)	0		0.018	1.00 (ref)		
Overweight (25-29.99 kg/m^2)	0.794	0.417	0.057	2.21 (0.98-5)	0.042	2.21 (1.09-6.49)
Obese (≥ 30 kg/m^2)	1.265	0.447	0.005	3.54 (1.48-8.51)	0.004	3.54 (1.5-11.32)
Smoking (packyears)						
No			0.002	1.00 (ref)		
< 40 packyears	0.697	0.353	0.048	2.01 (1.01-4.01)	0.048	2.01 (0.95-4.37)
≥ 40 packyears	1.376	0.385	0.000	3.96 (1.86-8.42)	0.001	3.96 (1.78-9.24)
Daily red meat	0.702	0.400	0.079	2.02 (0.92-4.42)	0.082	2.02 (0.72-4.41)
Constant	-6.467	1.213	0.000		0.001	

SE: Standard error, OR: Odds ratio, AOR: Adjusted odds ratio.

age in our study is considerably weaker than in other models[24-26] however, in all of those models, patients were included if their age was greater than 40, while in our study patients were only included if they were older than 50, and the age spread was fairly narrow (mean 60 ± 8) limiting our ability to capture the full effect of age on AN risk. Since more than 90% of cases of CRC occur after the age of 50[27] this may have made the effect of age more pronounced in the other studies, and this may account for the discrepancy with our model. The Lebanese Ministry of Public Health has put forth screening guidelines[16] that state that screening for average risk patients should be done with FIT testing annually from age 50-75[16] however, the guidelines do not take into consideration risk factors other than age and conditions that predispose to the development of CRC, a gap our findings help fill.

We found a strong increase in the risk of CRC with increased cumulative exposure to smoking. Smoking more than 40 pack-years was associated with a 4-fold increase in the odds of AN, making it the strongest risk factor in our study. This finding is particularly striking when we note that amongst our study population, 46.9% of the patients reported to be smokers[28]. The large prevalence of smoking may explain the discrepancy in the effect of smoking in our model compared to other models in which it seems to carry less influence on risk[25-27,29]. BMI was another factor found to significantly influence the risk of development of AN. Overweight individuals (BMI 25-30) have 2 times the odds of developing AN, though this did not attain statistical significance. However, obese individuals (BMI > 30) had a 3.5 times increased risk of developing AN, and this was found to be statistically significant, supporting the influence of BMI on risk in our population. This effect seems to be much larger than those found in other prediction models[24-26]. Our study population had an average BMI of 26.7, and approximately two-thirds of participants were obese or overweight. For Betes *et al*[25] the average BMI was 27 kg/m^2, while Kamniski *et al*[29] had a nearly identical distribution of BMI to our study. Indeed, the effect of BMI seems to be magnified amongst our population. A pooled analysis on the effect of obesity on the detection of adenomas showed an OR of 1.47, and our odds ratio was much larger than any of the studies in the systematic review[30]. Although reasons for this are unclear, this points to the importance of BMI as a risk factor in our population.

Red meat consumption was found to correlate with AN on univariate analysis when participants were categorized by daily consumption *vs* not, but not when participants were subcategorized by frequency of consumption. This either suggests that our study was not powered to adequately detect subtle differences in red meat intake, or possibly that red meat consumption only causes a significant effect when larger quantities are consumed. Other factors that were not found to correlate with risk of AN were alcohol use and the presence of diabetes, in contrast to findings of prior studies[31] Regarding alcohol use, 18% of patients with AN reported intake of at least one drink daily, compared to 9.8% of those with no AN, a non-significant difference.

Table 3 Existing risk prediction studies by design, age, exclusion of family history and previous colonoscopy

Ref.	Design	Positive family history excluded	Age for inclusion	Mean age (SD)	Included only first screening colonoscopy
Betés *et al*[25], 2003	Prospective	Yes	≥ 40	58 (8.6)	No[1]
Cai *et al*[27], 2012	Prospective	No	≥ 40	60 (11.1)	No[1]
Chen *et al*[33], 2014	Prospective	Yes	≥ 40	62.7 (9.7)	No[1]
Hong *et al*[34], 2017	Prospective	Yes	≥ 20	49.9 (9.3)	Yes
Imperiale *et al*[35], 2015	Prospective	No	50-80	57.3 (6.6)	Yes
Imperiale *et al*[36], 2016	Prospective	No	30-49	57.2 (6.6)	No[2]
Jung *et al*[24], 2017	Prospective	No	< 50	38.9 (5.3)	Yes
Kaminski *et al*[29], 2014	Retrospective	No	50-80	55.6 (5.2)	No[2]
Kim *et al*[37], 2019	Retrospective	No	< 50	38.9 (5.3)	Yes
Ladabaum *et al*[38], 2016	Prospective	Yes	50-80	Median (IQR) 58 (52 – 65)	No
Li *et al*[39], 2016	Prospective	No	40-75	52 (IQR 47 – 59)	No
Lin *et al*[40], 2016	Prospective	No	≥ 50	59.6 (8.1)	No[1]
Murchie *et al*[41], 2017	Retrospective	Yes	40-49	51.5	Yes
Park *et al*[42], 2017	Retrospective	No	50-59	44.8 (2.8)	Yes
Ruco *et al*[43], 2015	Prospective	No	50-74	58.3 (6.2)	No[2]
Schroy *et al*[44], 2015	Prospective	Yes[†]	50-79	74.7% aged 50-59	No
Sekiguchi *et al*[26], 2018	Retrospective	No	≥ 40	56 (40–88)	Yes
Sung *et al*[45], 2017	Prospective	No	≥ 50	57.6 (4.9)	No[1]
Tao *et al*, 2014[46]	Prospective	No	≥ 55	63.5 (6.7)	No[1]
Wong *et al*[45], 2016	Prospective	No	50-70	57.7 (4.93)	No
Yang *et al*[47], 2017		No	≥ 50	41.6 (8.3)	Yes
Yeoh *et al*[48], 2011	Prospective	No	≥ 16	54 (11.6)	No[1]
Current study	Prospective	Yes	≥ 50	61 (8)	Yes

Participants with a family history of colorectal cancer and/or colorectal polyps detected above the age of 60 were included. Those below the age of 60 were excluded. Included subjects with prior colonoscopic screening (≥ 5 yr[1] or ≥ 10 yr[2]).

Similarly, 12% of those with AN reported diabetes, compared to 8% with no AN. Likely we were not able to find an association between these factors and AN risk due to overall low prevalence of exposure in our study population, due in part to differences in lifestyle between our population and other previously studied populations.

The overall prevalence of AN in our cohort was 5.1%, which is comparable to rates reported in the United States[32], Europe[25,29] and Asia[26,27]. In a country like Lebanon, where resources are scarce and there is no formal national screening program for CRC, the costs of screening colonoscopy for an average-risk population may be too great to bear at the current time. In resource-limited contexts, risk stratification models could play an important role in prioritizing delivery of care. For instance, our predictive model show that the risk of advanced neoplasia in a 65 year old non-smoker male with a BMI < 25 is approximately 2%, while the risk for a 65 year old male with a BMI between 25-30 who has smoked between 10-40 pack years and consumes meat red meat daily is approximately 14%, *i.e.*, more than 7 times the risk of the first patient. However, most published guidelines on screening with colonoscopy do not distinguish between these 2 hypothetical patients. In resource-limited settings, it may be advantageous to reserve screening colonoscopy for patients found to be at high-risk

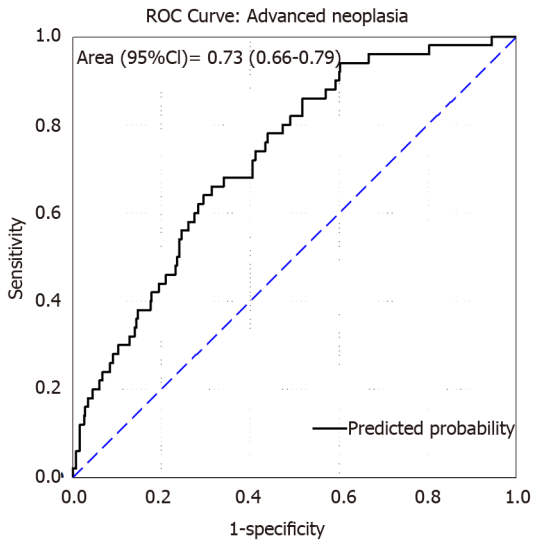

Figure 1 Receiver operator curve (Area under the curve = 0.73).

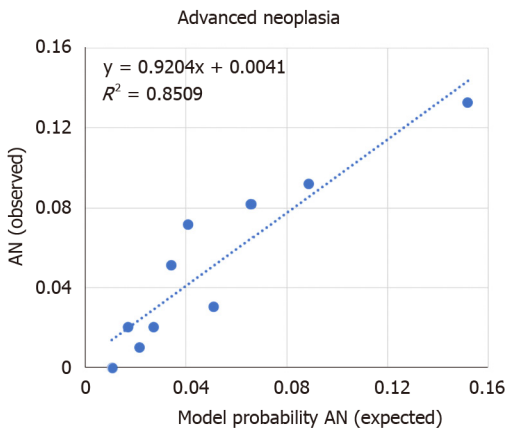

Figure 2 Model calibration plot. Each data point represents the comparison of observed (y) to expected (x) rates of advanced neoplasia in ten decile size groups (n = 98 each). The dashed line represents the linear trend with the corresponding line equation. (linear trend of y = 0.9204x + 0.0041 ; R^2 = 0.8509). AN: Advanced neoplasia.

through risk stratification models, while screening low risk patients with FIT testing for cost-effectiveness. The presented model can be considered a prototype tool for underserved countries, as CRC incidence is increasing in developing countries, and has particularly been increasing in Lebanon, which currently has the second highest rate of CRC in the MENA region[11].

Our study has important strengths and a few limitations. The sample size is large for a country the size of Lebanon constituting 1:1000 of the at-risk population aged 50-75 in Lebanon (n = 798440)[16]. The variables used in our model are easy to ascertain clinically and often already elicited by healthcare professionals as they require only history taking, weight and height measurements in order to quantify the risk. In addition to stratification leading to more efficient CRC screening, this model can be used to educate patients on the magnitude of their risks, potentially spurring them to take an active role in modifiable risk factor modification. Our study is subject to some limitations. While internal model validation was performed, external validation in a separate population is needed to optimize model performance and increase generalizability. This study was only conducted at one large hospital, where the majority of patients have private insurance. Thus, patients from low socioeconomic status may have not been adequately represented in our sample. The patient population was also derived from patients willing to undergo screening colonoscopy, and so we may have excluded less health-conscious patients from our study. These patients may be less likely to have lifestyle-related risk factors to their health and excluding these patients may have led us to underestimate the effect of these risk

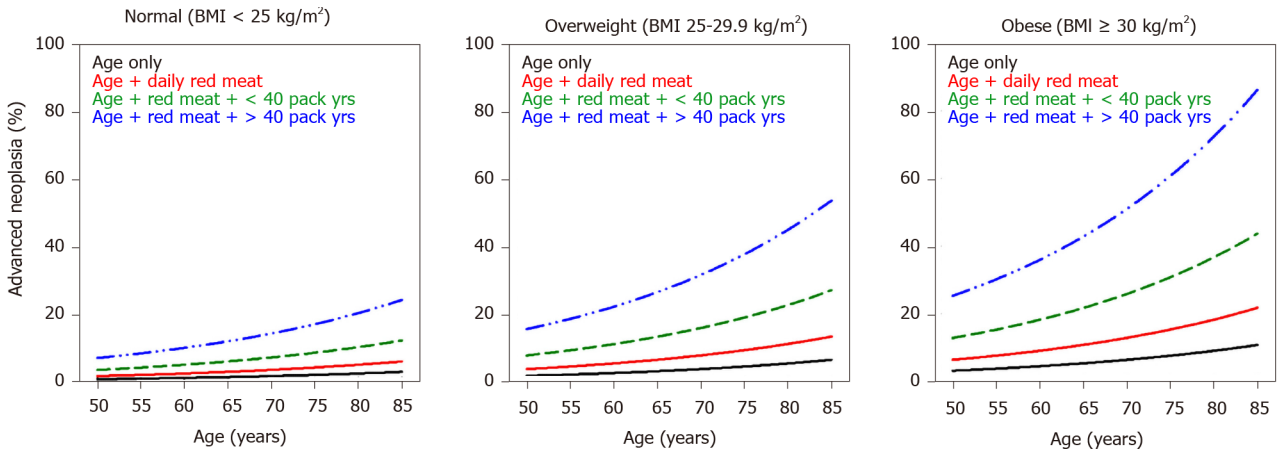

Figure 3 Nomograms showing the predictive model. These nomograms are a function of age and show the risk of advanced neoplasia for (BMI < 25), overweight (BMI 25-29.9) and obese (BMI > 30).

factors on the presence of AN.

CONCLUSION

This prospective cross-sectional study identified age, obesity, smoking, and daily red meat consumption as significant predictors of advanced colorectal neoplasia in a multivariate-logarithmic analysis. Our prediction rule was internally validated by bootstrapping, and this model exhibited good calibration and discrimination. This model, available through a free online calculator, may aid in risk-stratifying patients presenting for screening for CRC in Lebanon, with the caveat that external validation is still required for this model.

ARTICLE HIGHLIGHTS

Research background

Colorectal cancer is the third leading cause of cancer globally. Screening for colorectal cancer has been shown to decrease colon cancer mortality. While colonoscopy is the best modality to screen for colon cancer, it is also the most expensive. In resource-limited countries, risk stratification may be useful to optimize colorectal cancer screening.

Research motivation

Few prospective risk prediction models exist for advanced neoplasia (AN) in true average-risk individuals.

Research objectives

To create a validated risk prediction model to predict advanced neoplasia in average risk patients.

Research methods

980 consecutive, average-risk, asymptomatic patients undergoing their first screening colonoscopy were prospectively enrolled. We completed a detailed assessment of risk factors, and collected results of endoscopy findings from the endoscopy and pathology reports. Group comparisons of categorical factors were done using χ^2, and for quantitative variables independent t-test or Mann Whitney tests were used based on normality of data. Multivariate logistic regression analysis was performed to identify independent predictors of AN in our cohort. Discriminatory ability of the model was assessed through the area under the curve (AUC) of the receiver-operator-characteristic curve. Model calibration was examined through observed *vs* expected rates of advanced neoplasia as the derived probability of AN decile groups. Internal validation of the model was done by bootstrapping. The multivariate model

coefficients were used to present the percent risk of AN in nomogram format as a function of age and separately for different categories of BMI. The model coefficients were then used to develop a risk calculator.

Research results

Adenoma detection and advanced neoplasia detection rates were 36.6% (F 29%: M 45%; $P < 0.001$) and 5.1% (F 3.8%; M 6.5%) respectively. On multivariate analysis, the predictors of AN were age [1.036 (1.00-1.07); $P = 0.048$], BMI [overweight 2.21 (0.98-5.00); obese 3.54 (1.48-8.50); $P = 0.018$], smoking [< 40 pack-years 2.01 (1.01-4.01); ≥ 40 pack-years 3.96 (1.86-8.42); $P = 0.002$], and daily red meat consumption [2.02 (0.92-4.42) $P = 0.079$]. The model had an AUC = 0.73 (CI = 0.66-0.79, $P < 0.001$) and $R^2 = 0.8509$.

Research conclusions

The prevalence of adenoma and AN in the average-risk Lebanese population is 5.1%, similar to those in the West. Age, smoking and BMI are important predictors of AN in our study cohort, and our model had good calibration and discrimination.

Research perspectives

In this project, we developed a risk prediction tool for advanced neoplasia at first screening colonoscopy for average risk individuals. We provide an important platform for improved risk-stratification for screening programs in resource limiting settings, although external validation of our model is needed.

ACKNOWLEDGEMENTS

The authors would like to thank the following clinicians for contributing their patients to the study: Kassem Barada, Fadi Mourad, Assaad Soweid.

REFERENCES

1 **Bray F**, Ferlay J, Soerjomataram I, Siegel RL, Torre LA, Jemal A. Global cancer statistics 2018: GLOBOCAN estimates of incidence and mortality worldwide for 36 cancers in 185 countries. *CA Cancer J Clin* 2018; **68**: 394-424 [PMID: 30207593 DOI: 10.3322/caac.21492]

2 **Siegel RL**, Miller KD, Fedewa SA, Ahnen DJ, Meester RGS, Barzi A, Jemal A. Colorectal cancer statistics, 2017. *CA Cancer J Clin* 2017; **67**: 177-193 [PMID: 28248415 DOI: 10.3322/caac.21395]

3 **Morson B**. President's address. The polyp-cancer sequence in the large bowel. *Proc R Soc Med* 1974; **67**: 451-457 [PMID: 4853754 DOI: 10.1177/00359157740676p115]

4 **Grady WM**, Markowitz SD. The molecular pathogenesis of colorectal cancer and its potential application to colorectal cancer screening. *Dig Dis Sci* 2015; **60**: 762-772 [PMID: 25492499 DOI: 10.1007/s10620-014-3444-4]

5 **Brenner H**, Hoffmeister M, Stegmaier C, Brenner G, Altenhofen L, Haug U. Risk of progression of advanced adenomas to colorectal cancer by age and sex: estimates based on 840,149 screening colonoscopies. *Gut* 2007; **56**: 1585-1589 [PMID: 17591622 DOI: 10.1136/gut.2007.122739]

6 **Rex DK**, Boland CR, Dominitz JA, Giardiello FM, Johnson DA, Kaltenbach T, Levin TR, Lieberman D, Robertson DJ. Colorectal Cancer Screening: Recommendations for Physicians and Patients From the U.S. Multi-Society Task Force on Colorectal Cancer. *Gastroenterology* 2017; **153**: 307-323 [PMID: 28600072 DOI: 10.1053/j.gastro.2017.05.013]

7 **Wolf AMD**, Fontham ETH, Church TR, Flowers CR, Guerra CE, LaMonte SJ, Etzioni R, McKenna MT, Oeffinger KC, Shih YT, Walter LC, Andrews KS, Brawley OW, Brooks D, Fedewa SA, Manassaram-Baptiste D, Siegel RL, Wender RC, Smith RA. Colorectal cancer screening for average-risk adults: 2018 guideline update from the American Cancer Society. *CA Cancer J Clin* 2018; **68**: 250-281 [PMID: 29846947 DOI: 10.3322/caac.21457]

8 **US Preventive Services Task Force**, Bibbins-Domingo K Grossman DC, Curry SJ, Davidson KW, Epling JW Jr, García FAR, Gillman MW, Harper DM, Kemper AR, Krist AH, Kurth AE, Landefeld CS, Mangione CM, Owens DK, Phillips WR, Phipps MG, Pignone MP, Siu AL. Screening for Colorectal Cancer: US Preventive Services Task Force Recommendation Statement. *JAMA* 2016; **315**: 2564-2575 [PMID: 27304597 DOI: 10.1001/jama.2016.5989]

9 **Qaseem A**, Denberg TD, Hopkins RH Jr, Humphrey LL, Levine J, Sweet DE, Shekelle P; Clinical Guidelines Committee of the American College of Physicians. Screening for colorectal cancer: a guidance statement from the American College of Physicians. *Ann Intern Med* 2012; **156**: 378-386 [PMID: 22393133 DOI: 10.7326/0003-4819-156-5-201203060-00010]

10 **Lopes G**, Stern MC, Temin S, Sharara AI, Cervantes A, Costas-Chavarri A, Engineer R, Hamashima C, Ho GF, Huitzil FD, Moghani MM, Nandakumar G, Shah MA, Teh C, Manjarrez SEV, Verjee A, Yantiss R, Correa MC. Early Detection for Colorectal Cancer: ASCO Resource-Stratified Guideline. *J Glob Oncol* 2019; **5**: 1-22 [PMID: 30802159 DOI: 10.1200/jgo.18.00213]

11 Division of Cancer Prevention and Control CfDCaP. Colorectal Cancer Statistics. 2019

12 **Navarro M**, Nicolas A, Ferrandez A, Lanas A. Colorectal cancer population screening programs worldwide in 2016: An update. *World J Gastroenterol* 2017; **23**: 3632-3642 [PMID: 28611516 DOI: 10.3748/wjg.v23.i20.3632]

13 **Singh H**, Bernstein CN, Samadder JN, Ahmed R. Screening rates for colorectal cancer in Canada: a cross-sectional study. *CMAJ Open* 2015; **3**: E149-E157 [PMID: 26389092 DOI: 10.9778/cmajo.20140073]

14 **Khachfe HH**, Salhab HA, Fares MY, Khachfe HM. Probing the Colorectal Cancer Incidence in Lebanon: an 11-Year Epidemiological Study. *J Gastrointest Cancer* 2020; **51**: 805-812 [PMID: 31422543 DOI: 10.1007/s12029-019-00284-z]

15 **Tfaily MA**, Naamani D, Kassir A, Sleiman S, Ouattara M, Moacdieh MP, Jaffa MA. Awareness of Colorectal Cancer and Attitudes Towards Its Screening Guidelines in Lebanon. *Ann Glob Health* 2019; 85 [PMID: 31148437 DOI: 10.5334/aogh.2437]

16 Health RoLMoP. National Guidelines for Colorectal Cancer Early Detection. 2019

17 **Vijan S**, Inadomi J, Hayward RA, Hofer TP, Fendrick AM. Projections of demand and capacity for colonoscopy related to increasing rates of colorectal cancer screening in the United States. *Aliment Pharmacol Ther* 2004; **20**: 507-515 [PMID: 15339322 DOI: 10.1111/j.1365-2036.2004.01960.x]

18 **Kastenberg D**, Bertiger G, Brogadir S. Bowel preparation quality scales for colonoscopy. *World J Gastroenterol* 2018; **24**: 2833-2843 [PMID: 30018478 DOI: 10.3748/wjg.v24.i26.2833]

19 **Bener A**, Moore MA, Ali R, El Ayoubi HR. Impacts of family history and lifestyle habits on colorectal cancer risk: a case-control study in Qatar. *Asian Pac J Cancer Prev* 2010; **11**: 963-968 [PMID: 21133608]

20 **Almurshed KS**. Colorectal cancer: case-control study of sociodemographic, lifestyle and anthropometric parameters in Riyadh. *East Mediterr Health J* 2009; **15**: 817-826 [PMID: 20187533 DOI: 10.26719/2009.15.4.817]

21 **Guesmi F**, Zoghlami A, Sghaiier D, Nouira R, Dziri C. [Alimentary factors predisposing to colorectal cancer risk: a prospective epidemiologic study]. *Tunis Med* 2010; **88**: 184-189 [PMID: 20415192]

22 **Sharara AI**, Harb AH. Development and validation of a scoring system to identify individuals at high risk for advanced colorectal neoplasms who should undergo colonoscopy screening. *Clin Gastroenterol Hepatol* 2014; **12**: 2135-2136 [PMID: 24735793 DOI: 10.1016/j.cgh.2014.04.009]

23 **Peng L**, Weigl K, Boakye D, Brenner H. Risk Scores for Predicting Advanced Colorectal Neoplasia in the Average-risk Population: A Systematic Review and Meta-analysis. *Am J Gastroenterol* 2018; **113**: 1788-1800 [PMID: 30315282 DOI: 10.1038/s41395-018-0209-2]

24 **Jung YS**, Park CH, Kim NH, Lee MY, Park DI. Impact of Age on the Risk of Advanced Colorectal Neoplasia in a Young Population: An Analysis Using the Predicted Probability Model. *Dig Dis Sci* 2017; **62**: 2518-2525 [PMID: 28733868 DOI: 10.1007/s10620-017-4683-y]

25 **Betés M**, Muñoz-Navas MA, Duque JM, Angós R, Macías E, Súbtil JC, Herraiz M, De La Riva S, Delgado-Rodríguez M, Martínez-González MA. Use of colonoscopy as a primary screening test for colorectal cancer in average risk people. *Am J Gastroenterol* 2003; **98**: 2648-2654 [PMID: 14687811 DOI: 10.1111/j.1572-0241.2003.08771.x]

26 **Sekiguchi M**, Kakugawa Y, Matsumoto M, Matsuda T. A scoring model for predicting advanced colorectal neoplasia in a screened population of asymptomatic Japanese individuals. *J Gastroenterol* 2018; **53**: 1109-1119 [PMID: 29359244 DOI: 10.1007/s00535-018-1433-7]

27 **Cai QC**, Yu ED, Xiao Y, Bai WY, Chen X, He LP, Yang YX, Zhou PH, Jiang XL, Xu HM, Fan H, Ge ZZ, Lv NH, Huang ZG, Li YM, Ma SR, Chen J, Li YQ, Xu JM, Xiang P, Yang L, Lin FL, Li ZS. Derivation and validation of a prediction rule for estimating advanced colorectal neoplasm risk in average-risk Chinese. *Am J Epidemiol* 2012; **175**: 584-593 [PMID: 22328705 DOI: 10.1093/aje/kwr337]

28 **El-Roueiheb Z**, Tamim H, Kanj M, Jabbour S, Alayan I, Musharrafieh U. Cigarette and waterpipe smoking among Lebanese adolescents, a cross-sectional study, 2003-2004. *Nicotine Tob Res* 2008; **10**: 309-314 [PMID: 18236295 DOI: 10.1080/14622200701825775]

29 **Kaminski MF**, Polkowski M, Kraszewska E, Rupinski M, Butruk E, Regula J. A score to estimate the likelihood of detecting advanced colorectal neoplasia at colonoscopy. *Gut* 2014; **63**: 1112-1119 [PMID: 24385598 DOI: 10.1136/gutjnl-2013-304965]

30 **Omata F**, Deshpande GA, Ohde S, Mine T, Fukui T. The association between obesity and colorectal adenoma: systematic review and meta-analysis. *Scand J Gastroenterol* 2013; **48**: 136-146 [PMID: 23130996 DOI: 10.3109/00365521.2012.737364]

31 **Lieberman DA**, Prindiville S, Weiss DG, Willett W, VA Cooperative Study Group 380. Risk factors for advanced colonic neoplasia and hyperplastic polyps in asymptomatic individuals. *JAMA* 2003; **290**: 2959-2967 [PMID: 14665657 DOI: 10.1001/jama.290.22.2959]

32 **Heitman SJ**, Ronksley PE, Hilsden RJ, Manns BJ, Rostom A, Hemmelgarn BR. Prevalence of adenomas and colorectal cancer in average risk individuals: a systematic review and meta-analysis. *Clin Gastroenterol Hepatol* 2009; **7**: 1272-1278 [PMID: 19523536 DOI: 10.1016/j.cgh.2009.05.032]

33 **Chen G**, Mao B, Pan Q, Liu Q, Xu X, Ning Y. Prediction rule for estimating advanced colorectal neoplasm risk in average-risk populations in southern Jiangsu Province. *Chin J Cancer Res* 2014; **26**: 4-11 [PMID: 24653621 DOI: 10.3978/j.issn.1000-9604.2014.02.03]

34 **Hong SN**, Son HJ, Choi SK, Chang DK, Kim YH, Jung SH, Rhee PL. A prediction model for advanced colorectal neoplasia in an asymptomatic screening population. *PLoS One* 2017; **12**: e0181040 [PMID: 28841657 DOI: 10.1371/journal.pone.0181040]

35 **Imperiale TF**, Monahan PO, Stump TE, Glowinski EA, Ransohoff DF. Derivation and Validation of a Scoring System to Stratify Risk for Advanced Colorectal Neoplasia in Asymptomatic Adults: A Cross-sectional Study. *Ann Intern Med* 2015; **163**: 339-346 [PMID: 26259154 DOI: 10.7326/m14-1720]

36 **Imperiale TF**, Yu M, Monahan PO, Stump TE, Tabbey R, Glowinski E, Ransohoff DF. Risk of Advanced Neoplasia Using the National Cancer Institute's Colorectal Cancer Risk Assessment Tool. *J Natl Cancer Inst* 2017; 109 [PMID: 27582444 DOI: 10.1093/jnci/djw181]

37 **Kim JY**, Choi S, Park T, Kim SK, Jung YS, Park JH, Kim HJ, Cho YK, Sohn CI, Jeon WK, Kim BI, Choi KY, Park DI. Development and validation of a scoring system for advanced colorectal neoplasm in young Korean subjects less than age 50 years. *Intest Res* 2019; **17**: 253-264 [PMID: 30449080 DOI: 10.5217/ir.2018.00062]

38 **Ladabaum U**, Patel A, Mannalithara A, Sundaram V, Mitani A, Desai M. Predicting advanced neoplasia at colonoscopy in a diverse population with the National Cancer Institute colorectal cancer risk-assessment tool. *Cancer* 2016; **122**: 2663-2670 [PMID: 27219715 DOI: 10.1002/cncr.30096]

39 **Li W**, Zhang L, Hao J, Wu Y, Lu D, Zhao H, Wang Z, Xu T, Yang H, Qian J, Li J. Validity of APCS score as a risk prediction score for advanced colorectal neoplasia in Chinese asymptomatic subjects: A prospective colonoscopy study. *Medicine (Baltimore)* 2016; **95**: e5123 [PMID: 27741134 DOI: 10.1097/md.0000000000005123]

40 **Lin OS**, Kozarek RA, Schembre DB, Ayub K, Gluck M, Cantone N, Soon MS, Dominitz JA. Risk stratification for colon neoplasia: screening strategies using colonoscopy and computerized tomographic colonography. *Gastroenterology* 2006; **131**: 1011-1019 [PMID: 17030171 DOI: 10.1053/j.gastro.2006.08.015]

41 **Murchie B**, Tandon K, Hakim S, Shah K, O'Rourke C, Castro FJ. A New Scoring System to Predict the Risk for High-risk Adenoma and Comparison of Existing Risk Calculators. *J Clin Gastroenterol* 2017; **51**: 345-351 [PMID: 27322531 DOI: 10.1097/mcg.0000000000000576]

42 **Park YM**, Kim HS, Park JJ, Baik SJ, Youn YH, Kim JH, Park H. A simple scoring model for advanced colorectal neoplasm in asymptomatic subjects aged 40-49 years. *BMC Gastroenterol* 2017; **17**: 7 [PMID: 28068908 DOI: 10.1186/s12876-016-0562-9]

43 **Ruco A**, Stock D, Hilsden RJ, McGregor SE, Paszat LF, Saskin R, Rabeneck L. Evaluation of a clinical risk index for advanced colorectal neoplasia among a North American population of screening age. *BMC Gastroenterol* 2015; **15**: 162 [PMID: 26585867 DOI: 10.1186/s12876-015-0395-y]

44 **Schroy PC 3rd**, Wong JB, O'Brien MJ, Chen CA, Griffith JL. A Risk Prediction Index for Advanced Colorectal Neoplasia at Screening Colonoscopy. *Am J Gastroenterol* 2015; **110**: 1062-1071 [PMID: 26010311 DOI: 10.1038/ajg.2015.146]

45 **Sung JJY**, Wong MCS, Lam TYT, Tsoi KKF, Chan VCW, Cheung W, Ching JYL. A modified colorectal screening score for prediction of advanced neoplasia: A prospective study of 5744 subjects. *J Gastroenterol Hepatol* 2018; **33**: 187-194 [PMID: 28561279 DOI: 10.1111/jgh.13835]

46 **Tao S**, Hoffmeister M, Brenner H. Development and validation of a scoring system to identify individuals at high risk for advanced colorectal neoplasms who should undergo colonoscopy screening. *Clin Gastroenterol Hepatol* 2014; **12**: 478-485 [PMID: 24022090 DOI: 10.1016/j.cgh.2013.08.042]

47 **Yang HJ**, Choi S, Park SK, Jung YS, Choi KY, Park T, Kim JY, Park DI. Derivation and validation of a risk scoring model to predict advanced colorectal neoplasm in adults of all ages. *J Gastroenterol Hepatol* 2017; **32**: 1328-1335 [PMID: 28012211 DOI: 10.1111/jgh.13711]

48 **Yeoh KG**, Ho KY, Chiu HM, Zhu F, Ching JY, Wu DC, Matsuda T, Byeon JS, Lee SK, Goh KL, Sollano J, Rerknimitr R, Leong R, Tsoi K, Lin JT, Sung JJ; Asia-Pacific Working Group on Colorectal Cancer. The Asia-Pacific Colorectal Screening score: a validated tool that stratifies risk for colorectal advanced neoplasia in asymptomatic Asian subjects. *Gut* 2011; **60**: 1236-1241 [PMID: 21402615 DOI: 10.1136/gut.2010.221168]

World Journal of Gastroenterology

Submit a Manuscript: https://www.f6publishing.com

World J Gastroenterol 2020 October 7; 26(37): 5718-5730

DOI: 10.3748/wjg.v26.i37.5718

ISSN 1007-9327 (print) ISSN 2219-2840 (online)

EVIDENCE-BASED MEDICINE

Endoscopic retrograde cholangiopancreatography in the treatment of pancreaticopleural fistula in children

Jing Zhang, Liu-Cun Gao, Shu Guo, Tian-Lu Mei, Jin Zhou, Guo-Li Wang, Fei-Hong Yu, Yong-Li Fang, Bao-Ping Xu

ORCID number: Jing Zhang 0000-0002-2832-239X; Liu-Cun Gao 0000-0002-7264-0184; Shu Guo 0000-0002-4286-729X; Tian-Lu Mei 0000-0003-0689-241X; Jin Zhou 0000-0003-0770-5620; Guo-Li Wang 0000-0003-3093-3920; Fei-Hong Yu 0000-0001-8706-0337; Yong-Li Fang 0000-0002-8982-5759; Bao-Ping Xu 0000-0001-8938-7691.

Author contributions: Zhang J, Gao LC, Guo S, Mei TL, Zhou J, Wang GL, Yu FH, Fang YL, and Xu BP wrote and revised the manuscript.

Conflict-of-interest statement: There are no conflicts of interest arising from this work.

PRISMA 2009 Checklist statement: The authors have read the PRISMA 2009 Checklist, and the manuscript was prepared and revised according to the PRISMA 2009 Checklist.

Jing Zhang, Shu Guo, Tian-Lu Mei, Jin Zhou, Guo-Li Wang, Fei-Hong Yu, Yong-Li Fang, Department of Gastroenterology, Beijing Children's Hospital, Capital Medical University, National Center for Children's Health, Beijing 100045, China

Liu-Cun Gao, Clinical Research Center, Beijing Children's Hospital, Capital Medical University, National Center for Children's Health, Beijing 100045, China

Bao-Ping Xu, China National Clinical Research Center of Respiratory Diseases, Department of Respiratory, Beijing Children's Hospital, Capital Medical University, National Center for Children's Health, Beijing 100045, China

Corresponding author: Jing Zhang, MD, Chief Physician, Department of Gastroenterology, Beijing Children's Hospital, Capital Medical University, National Center for Children's Health, No. 56 Nanlishi Road, Xicheng District, Beijing 100045, China. zhjtg666@163.com

Abstract

BACKGROUND

Pancreaticopleural fistula (PPF) is a rare disease, especially in children. Conservative treatment and surgery are traditional therapies, but surgery is invasive. The emergence of endoscopic retrograde cholangiopancreatography (ERCP) has provided a new noninvasive treatment for PPF and may become the first choice for children with PPF.

AIM

To explore the treatment response to ERCP for PPF in children.

METHODS

Seven children with PPF were hospitalized in the Gastroenterology Department of Beijing Children's Hospital from December 2007 to May 2019. Data on these seven patients' clinical characteristics, diagnosis, treatments, and outcomes were analyzed, and their treatment responses following surgery and ERCP were compared. The correlation between the length of hospital stay and conservative treatment was analyzed. Peer-reviewed articles written in English and Chinese published from January 2009 to December 2019 were obtained from various open data sources and reviewed.

RESULTS

The seven patients comprised three boys and four girls with a mean age of 6.57 ±

Manuscript source: Unsolicited manuscript

Received: May 31, 2020
Peer-review started: May 31, 2020
First decision: June 18, 2020
Revised: July 1, 2020
Accepted: September 15, 2020
Article in press: September 15, 2020
Published online: October 7, 2020

P-Reviewer: Karagyozov PI, Makmun D
S-Editor: Gong ZM
L-Editor: A
P-Editor: Wang LL

3.26 years. The main symptoms were chest tightness and pain (n = 4), intermittent fever (n = 3), dyspnea (n = 3), and abdominal pain (n = 1), and all patients had bloody pleural effusion. All seven patients were diagnosed with PPF by magnetic resonance cholangiopancreatography, and all were initially treated conservatively for a mean of 34.67 ± 22.03 d with a poor response. Among five patients who underwent ERCP, one required surgery because of intubation failure; thus, the success rate of ERCP was 80%. Two patients were successfully treated with surgery (100%). The postoperative hospital stay of the two patients treated by surgery was 20 and 30 d, respectively (mean of 25 d), and that of the four patients treated by ERCP ranged from 12 to 30 d (mean of 19.25 ± 8.85 d). The recovery time after ERCP was short [time to oral feeding, 4-6 d (mean, 5.33 ± 1.15 d); duration of closed thoracic drainage, 2-22 d (mean, 13.3 d)]. Analysis of previous cases of PPF published worldwide during the past decade showed that the treatment success rate of ERCP is not lower than that of surgery. There was no significant difference in the postoperative hospital stay between surgery (16 ± 10.95 d) and ERCP (18.7 ± 6.88 d, P > 0.05). A positive linear correlation was found between the overall hospital stay and ERCP intervention time (R^2 = 0.9992).

CONCLUSION

ERCP is recommended as the first-choice treatment for PPF in children. ERCP should be performed as early as possible if conditions permit.

Key Words: Pancreaticopleural fistula; Childhood; Endoscopic retrograde cholangiopancreatography; Magnetic resonance cholangiopancreatography; Diagnostic; Treatment

Core Tip: Data on the clinical characteristics, diagnosis, treatments, and outcomes of seven Chinese children with pancreaticopleural fistula (PPF) were analyzed and compared with those described in previous publications of children and adults with PPF worldwide. There was no significant difference in the postoperative hospital stays between surgical treatment (17.2 ± 11.9 d) and endoscopic retrograde cholangiopancreatography (ERCP) (20.75 ± 5.78 d). However, there was a positive linear correlation between the overall hospital stay and ERCP intervention time (R^2 = 0.9992). Therefore, ERCP is recommended as the first-choice treatment of PPF in children. ERCP should be performed as early as possible if conditions permit.

Citation: Zhang J, Gao LC, Guo S, Mei TL, Zhou J, Wang GL, Yu FH, Fang YL, Xu BP. Endoscopic retrograde cholangiopancreatography in the treatment of pancreaticopleural fistula in children. *World J Gastroenterol* 2020; 26(37): 5718-5730
URL: https://www.wjgnet.com/1007-9327/full/v26/i37/5718.htm
DOI: https://dx.doi.org/10.3748/wjg.v26.i37.5718

INTRODUCTION

Pancreaticopleural fistula (PPF) is a rare complication of chronic pancreatitis in both adults and children. In adults, PPF is often secondary to chronic alcoholic pancreatitis, accounting for about 0.4%of patients with pancreatitis[1] and 4.5% of patients with pancreatic pseudocysts[2]. The cause and incidence of PPF in children are still unclear. PPF can be diagnosed by laboratory examination and imaging examination. The traditional treatments are conservative treatment and surgery[3]. ERCP was a breakthrough in the diagnosis and treatment of biliopancreatic diseases when it was developed in 1968, replacing some of the traditional methods of examination and treatment of biliopancreatic diseases with endoscopy[4]. In 1993, Saeed *et al*[5] performed pancreatic stent implantation to cure adult PPF for the first time. ERCP has since been performed increasingly more often in the diagnosis and treatment of PPF in adults. However, the experience of ERCP in the treatment of PPF in children is limited. In the present study, the clinical data of children with PPF diagnosed in Beijing Children's

Hospital from December 2007 to May 2019 were retrospectively analyzed, and the children's therapeutic response to ERCP was explored by comparison with previous publications worldwide.

MATERIALS AND METHODS

Objective

To explore the treatment response to ERCP for PPF in children.

Setting, design, and sample size

From December 2007 to May 2019, the clinical data of seven children with PFF in our department were retrospectively analyzed. The patients comprised three boys and four girls ranging in age from 2 to 10 years (mean age, 6.57 ± 3.26 years). Their main symptoms were chest distress and pain (n = 3), intermittent fever (n = 3), dyspnea (n = 3), and abdominal pain and distention (n = 4). Five patients had massive pleural effusion, and two had moderate pleural effusion. Three patients had pleural effusion on the right side, one had effusion on the left, and three had effusion on both sides. One patient had a history of abdominal trauma, but no patients had a history of abdominal surgery.

Diagnostic criteria

All seven patients were confirmed to have PPF by laboratory and imaging examinations. The laboratory examinations mainly included pancreatic and pleural effusion biochemical examinations. The imaging examinations mainly included B-ultrasound, enhanced computed tomography, magnetic resonance cholangio-pancreatography, and ERCP.

Treatments

All seven children initially received conservative treatment, including fasting, a somatostatin prescription to inhibit pancreatic secretion, anti-infection medication, and nutritional support. After conservative treatment, the body temperature normalized and pleural effusion disappeared in one patient, while a poor response was seen in six patients. Therefore, two patients were treated by surgery and five underwent ERCP, however, one of the five patients who underwent ERCP required surgery because of ERCP intubation failure.

Literature review

Peer-reviewed English-language publications were retrieved from the PubMed database using the search term "[Pancreaticopleural Fistula] OR [PPF]," and Chinese publications were retrieved from the Wanfang and China National Knowledge Infrastructure databases using the search term "Pancreaticopleural Fistula." The time limit for the literature search was January 2009 to December 2019.

Statistical analysis

SPSS 22.0 software (IBM Corp, Armonk, NY, United States) was used to analyze the correlation between the length of hospital stay and conservative treatment. Descriptive data are expressed as mean ± standard deviation. The effects of surgical treatment and ERCP were compared by a t-test, and $P < 0.05$ indicated a statistically significant difference.

RESULTS

Diagnostic results

All seven patients with pleural effusion had hemothorax. Four had a leukocyte count of > 500 × 10^6/L, and five had a pleural effusion protein concentration of > 30 g/L. The concentration of amylase in the pleural fluid was substantially increased in all patients (> 1000 U/L; reference, < 150 U/L); five patients had a pleural fluid amylase concentration of 1000 to 50000 U/L, and two had a pleural fluid amylase concentration of > 50000 U/L. Table 1 shows that five of the seven patients had a high serum amylase concentration (mean, 792.8 ± 409.97 U/L). The serum lipase concentration was increased in all seven children (mean, 1826.1 ± 1650.21 U/L), and one patient had a

Table 1 Laboratory findings in patients with pancreaticopleural fistula

Patients	Appearance of pleural effusion	Leukocyte count of pleural fluid (× 10^6 L)	Pleural effusion protein (g/L)	Pleural amylase (U/L)	Serum amylase (U/L)	Blood lipase (U/L)	Ascites amylase (U/L)
1	Bloody	300	40.0	6625	1026	3912.9	13053.0
2	Bloody	560	34.0	10477	423	1051	-
3	Bloody	3600	40	3178	409	950	-
4	Bloody	1700	17.4	50465	284-654	355.4	-
5	Bloody	800	45	1584	110	4470	-
6	Bloody	1200	27.6	65000	1368	1312.2	
7	Bloody	6	46.7	25549	738	731.2	-

large amount of ascites with an amylase concentration of 13053 U/L. Table 2 shows that all seven patients had negative results of acid-fast staining and bacterial culture of the pleural effusion, and no tumor cells were found in the pathological examination. All seven patients were diagnosed with PPF by magnetic resonance cholangiopancreatography. Pulmonary imaging showed a large amount of pleural effusion in all children; the effusion was present on the right side in three children, on the left side in one, and on both sides in three.

Treatments and outcomes

All seven patients with PPF were initially treated with conservative therapy for 10 to 60 d (mean, 34.67 ± 22.03 d). Six of them had a recurrent fever and continuous pleural effusion following the conservative treatment. Therefore, five patients underwent ERCP, and one of these patients was transferred to surgery after ERCP intubation failed. The remaining four children who underwent ERCP recovered well without a recurrent fever after the procedure. Their body temperature normalized within 2 to 4 d, and they began to eat within 4 to 6 d. Pump infusion of a somatostatin was continued for 4 to 20 d, and the amylase concentration recovered to normal in 4 to 23 d. The patients underwent 2 to 22 d of closed thoracic drainage; the one child who underwent drainage for 22 d required prolonged drainage because of obstruction of the ERCP tent by small stones. The hospitalization stay after ERCP ranged from 12 to 30 d among these four patients (mean, 18 ± 10.39 d) (Table 3).

Association between overall hospital stay and duration of conservative treatment

SPSS software was used to fit the overall hospital stay and duration of conservative treatment, and a positive linear correlation was obtained (R^2 = 0.9992) (Figure 1).

Literature review

Articles describing clinical operations for PPF published worldwide during the past decade were reviewed and summarized (Table 4)[6-40]. In total, 37 case reports were found among 35 non-duplicated publications. The 37 patients comprised 25 adults and 12 children. Among seven patients who received conservative treatment, one died of a poor response. Thirteen patients received surgical treatment, and among the 17 patients who received ERCP treatment, three were converted to surgical treatment because of a poor response to ERCP. The duration of conservative treatment ranged from 7 to 60 d (mean, 30.76 ± 17.4 d). The postoperative hospital stay of patients who underwent surgical treatment ranged from 5 to 30 d (mean, 16 ± 10.95 d), and the postoperative hospital stay of patients who underwent ERCP ranged from 12 to 30 d (mean, 18.7 ± 6.88 d). There was no significant difference in the postoperative hospital stay between the two groups (P > 0.05).

DISCUSSION

Treatment status of PPF worldwide

PPF is a rare complication of chronic pancreatitis. The main symptoms of PPF are chest pain, tachypnea, and dyspnea, and the condition is difficult to diagnose. In 1976, Cameron *et al*[41] considered PPF to be caused by entry of pancreatic secretions into the

Table 2 Clinical symptoms, treatments, and outcomes of seven children with pancreaticopleural fistula

Patients	1	2	3	4	5	6	7
Age (yr)	8	10	3	2	5	8	10
Gender	Male	Female	Male	Male	Female	Female	Female
Symptom	Fatigue, poor appetite, intermittent fever, abdominal distention	Intermittent chest tightness and upper abdominal pain	Chronic pancreatitis, recurrent abdominal pain	Wheezing, shortness of breath, repeated bloody pleural effusion	Abdominal pain for half a year, fever and chest tightness	Intermittent chest tightness and dyspnea for more than 20 d	Chest pain with dyspnea
Etiology	Suspected trauma and pseudocyst	Dilatation and calculus of pancreatic duct	Congenital pancreatic duct dysplasia and pseudocyst	Pseudocyst and dilatation of pancreatic duct	Pseudocyst and dilatation of pancreatic duct	Dilatation and calculus of pancreatic duct	Pancreatic duct stone, pseudocyst, dilatation of pancreatic duct
Diagnosis	laboratory examination, B ultrasound, MRCP	laboratory examination, MRCP	laboratory examination, enhanced CT, MRC, ERCP	laboratory examination, CT, B ultrasound, MRCP	laboratory examination, CT, B ultrasound, MRCP	laboratory examination, CT, MRCP, ERCP	laboratory examination, CT, B ultrasound, MRCP
Location of pleural effusion	Right	Bilateral	Bilateral	Left	Right	Bilateral	Right
Amylase in pleural effusion (U/L)	6625	10477	3178	50465	1584	65000	25549
Conservative treatment time (d)	10	21	60	24	19	20	10
ERCP treatment	Yes (Surgical treatment after ERCP failure)	No (Operation)	Yes	Yes	No (Operation)	Yes	Yes
Serum amylase concentration before operation (U/L)	889.4	153	367	429	93.0	292	283
Serum amylase concentration after operation (U/L)	102		267	315		105	110
Time for amylase to return to normal (Days after operation)			23	10		9	4
Lipase concentration before operation/ERCP (U/L)	567	1051		355.4	115	106	731.2
Lipase concentration after operation/ERCP (U/L)						51.7	62.4
Stop somatostatin pump maintenance time (days after operation)			19	5		3	4
Postoperative recovery time of eating (days after operation)	3	3	6	6		4	15
Times of fever treated	1	3	5	3	4		Normal temperature

conservatively							
Chest closed drainage time (days after operation)	-	-	16	-	-		-
Postoperative hospital stay (d)	20	30	30	12		12	23
Total length of stay (d)	30	52	90	36		32	33

CT: Computed tomography; ERCP: Endoscopic retrograde cholangiopancreatography; MRCP: Magnetic resonance cholangiopancreatography.

body cavity rather than the duodenum. In the present study, PPF originated from a ruptured main pancreatic duct or leaking pseudocyst. If the front of the pancreatic duct is damaged, extrapancreatic secretions will leak into the abdominal cavity, resulting in pancreatic ascites; if the duct is damaged at the rear, extrapancreatic secretions will leak into the mediastinum through the posterior peritoneum *via* the aorta or esophageal hiatus; and if the secretion penetrates the pleura, it will cause fluid accumulation (with or without bleeding) in one or both thoracic cavities[41-44]. In adults, PPF is usually secondary to chronic alcoholic pancreatitis. However, the cause is unclear in children.

PPF can be treated by conservative therapy with medication, surgery, or endoscopic technology[9,44]. In previous research, 31% to 65% of adult patients with PPF fully responded to octreotide combined with total parenteral nutrition treatment and usually took 2 to 3 wk to recover[6,45]. However, because of the repeated occurrence of pleural effusion in children, a closed thoracic drainage tube should be placed. During conservative treatment, children may develop malnutrition, catheter infection, septicemia, and other complications that are difficult to treat[46]. Children who undergo failed conservative treatment need further surgical and endoscopic treatment. Surgery is one of the main treatment methods for PPF. The purpose of surgical treatment is to connect the pancreaticojejunal channel to drain fully the pancreatic juice. The most common surgical treatment is pancreatojejunostomy. Frey's operation can be performed when a pancreatic head mass compresses the pancreatic duct and biliary tract; this procedure involves pancreatectomy and longitudinal pancreato-jejunostomy[47]. Placement of an ERCP stent is a new nonsurgical treatment for PPF. An ERCP stent can open the proximal end of the pancreatic duct, smoothly drain the pancreatic juice, allow the pancreatic juice to flow to the duodenum with low resistance, and close the fistula that is abnormally connecting the pancreatic duct and pleura[29].

In the present study, we summarized 37 cases of PPF treatment published in the past decade (25 adults and 12 children). The proportions of adults and children who received conservative treatment, surgical treatment, and ERCP treatment were 16.67% and 25%, 50% and 41.7%, and 42.7% and 33.3%, respectively. However, conservative treatment produced a limited response. One of seven patients who received conservative treatment died, and the success rate was only 16.67%. Surgery was

Table 3 Comparison of therapeutic effect of endoscopic retrograde cholangiopancreatography *vs* conservative treatment

Patients	Conservative treatment time (d)	Recovery time of indexes after ERCP (d)				Serum amylase concentration (U/L)		Hospital stay after different treatment (d)		Total length of stay (d)
		Postoperative discharge	Somatostatin pump maintenance	Recovery time of eating	Blood amylase recovery	2 d before operation	2 d after operation	Operation	ERCP	
1[2]	10							20		30
2[2]	21							31		52
5[2]	19	-								
3[3]	60	30	19	6	23	367	292		30	90
4[3]	24	12	5	6	10	267	249		12	36
6[3]	20	12	3	4	9	429	283		12	32
7[1,3]	10	23	4	15	4	315	110-		23	33
Average (ERCP)	34.67 ± 22.03	18 ± 10.39	9 ± 8.72	5.33 ± 1.15	14 ± 7.81	344.5 ± 69.58	233.5 ± 84.39	25.5 ± 7.78	18 ± 10.39	-

[1]The second day after endoscopic retrograde cholangiopancreatography (ERCP) stent placement, the patient had poor drainage of the pancreatic stent outflow tract because of stone blockage. This made it difficult to control the secondary infection, and the hospitalization time was prolonged. This patient was not included in the statistical analysis.
[2]Surgical treatment.
[3]ERCP treatment. ERCP: Endoscopic retrograde cholangiopancreatography.

historically the most frequently used treatment but was invasive. With the development of minimally invasive ERCP in recent years, ERCP is now being increasingly used in the treatment of patients with PPF, especially children.

Optimal PPF treatment method

PPF is a rare disease, and no systematic study has been performed to determine the best treatment; therefore, no consensus has been reached regarding the optimal therapy. Conservative treatment has a low success rate and is associated with many complications, and patients often need secondary surgery or endoscopic treatment. Both surgery and endoscopic treatment can effectively treat PPF. However, no systematic study has been performed to compare the efficacy of the two treatments. We herein performed a preliminary comparison of surgery and endoscopic treatment of PPF by summarizing the treatment results and prognosis of seven children treated in our hospital and both adults and children described in previous publications worldwide. The first case of PPF cured by surgery was reported in 1960[48]. The first adult with PPF cured by ERCP was reported by Saeed *et al*[5] in 1993. Current research data show that more adults and children with PPF choose ERCP treatment.

All seven patients with PPF in this study initially received conservative treatment, but the responses were poor. Among the five patients who received ERCP treatment, one was converted to surgery because of incubation failure; the treatment success rate was thus 80%. Two patients underwent surgery (one was lost to follow-up after transfer to another hospital), and both recovered. The mean postoperative hospital stay for the two patients who underwent surgery and the four patients who underwent ERCP was 25 d and 19.25 d, respectively. The preliminary conclusion was that the recovery time was shorter after ERCP than after surgical treatment. However, because of the small number of cases, the hospital stay of the two treatment methods could not be statistically analyzed. The present study also showed that patients with PPF who undergo ERCP require a very short time until they start to eat, discontinue somatostatin pump maintenance, return to a normal amylase concentration, and discontinue closed thoracic drainage.

Because children very rarely develop PPF, the present study summarized the clinical outcome data for both adults and children with PPF worldwide during the past decade for a comprehensive analysis. The mean postoperative hospital stay of patients treated with surgery and ERCP was 16 ± 10.95 d and 18.7 ± 6.88 d, respectively ($P > 0.05$). There was no significant difference in the postoperative hospital stay between the two treatment methods, and the curative effect of the two

Table 4 Worldwide cases of pancreaticopleural fistula published in the most recent 10 years

Publication years	Gender/age (yr)	Diagnosis	Treatments	Conservative treatment time (d)	Postoperative hospital stays (d)	
					Operation	ERCP
Adult						
2009[6]	F/52	CT/MRCP	Conservative/ERCP	14		7
2009[6]	M/46	MRCP	Conservative/ERCP	27		14
2010[7]	F/44	CT	Conservative/operation		5	
2012[8]	M/64	B ultrasound/ERCP	Conservative/ERCP			
2012[9]	F/52	CT	Conservative/operation			
2012[10]	M/58	CT/ERCP	Conservative/operation	42		
2013[11]	F/47	CT	Conservative			
2013[12]	M/59	CT/ERCP	Conservative	56		
2013[13]	F/58	CT/MRI	Conservative/ERCP	7		12
2016[14]	F/65	CT/MRCP	Conservative/operation		21	
2014[15]	F/50	CT/MRCP	Conservative/ERCP/operation			
2014[16]	M/49	CT/MRCP/MRI	Conservative/operation			
2015[17]	M/43	CT/ERCP	Conservative/operation	35	10	
2015[18]	M/43	CT/MRCP	Conservative/ERCP/operation	28		
2016[19]	M/58	CT	Conservative/ERCP			
2016[20]	M/51	CT/ERCP/MRI	ERCP	21		
2016[21]	F/51	CT/MRCP	Conservative/operation	28	5	
2016[22]	F/63	CT/MRCP	Conservative/operation		30	
2016[23]	M/78	CT	Conservative			
2017[24]	M/44	MRCP	Conservative/ERCP			
2017[25]	M/52	CT/MRCP	Conservative			
2018[26]	M/49	CT/MRCP/ERCP	Conservative/ERCP			
2019[27]	M/52	Operation	Conservative/ERCP			21
2019[28]	M/35	CT	Conservative/ERCP	14		20
2019[29]	M/65	CT/MRCP/ERCP	Conservative/operation			
Children						
2009[30]	M/4	CT/MRCP	Conservative/ERCP	60		30
2013[31]	F/5	CT	Conservative	50		
2013[32]	M/15	CT/MRI	Conservative/ERCP			28
2014[33]	M/2.5	B ultrasound/CT	Conservative/operation	26	11	
2014[34]	M/8	CT	Conservative	60		
2014[34]	M/2	CT	Conservative			
2016[35]	M/2	CT	operation			
2018[36]	F/8	CT/MRCP	Conservative/ERCP	17		19
2018[37]	F/14	CT/MRCP	Conservative/operation		30	
2019[38]	M/3	CT/MRCP	Conservative/ERCP			18
2019[39]	F/8	CT/MRCP	Conservative/ERCP	8		18

2019[40]	M/14	CT	Conservative/operation	30		
AVG				30.76 ± 17.4	16 ± 10.95	18.7 ± 6.88
P value					*P* > 0.05	

CT: Computed tomography; ERCP: Endoscopic retrograde cholangiopancreatography; MRCP: Magnetic resonance cholangiopancreatography; MRI: Magnetic resonance imaging.

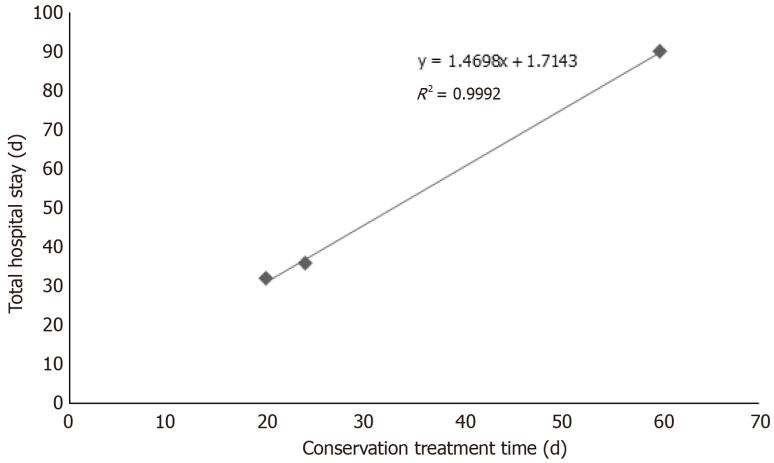

Figure 1 The correlation between endoscopic retrograde cholangiopancreatography intervention time and total hospital stay. The linear equation is not a model prediction but only a correlation analysis.

methods was equivalent. The success rate of ERCP treatment (80%) was slightly lower than that of surgical treatment (100%), which may have been due to the small number of patients. In some studies, the duration of using ERCP to cure PPF was 4 to 12 wk with different success rates. The success rates reported by Khan *et al*[49], Pai *et al*[50], and Varadarajulu *et al*[51] were 100%, 96.4%, and 50.0% (the low success rate was due to stent placement failure or failure to pass through the pancreatic duct rupture site), respectively, similar to the surgery success rate (94%) reported by King *et al*[7]. These findings indicate that the success rate of ERCP treatment is not lower than that of surgical treatment. Our data are consistent with the findings of most previous studies; statistical analysis was impossible because of the limited sample size. The results of the literature review of studies published in the past decade indicated that the average recovery time following ERCP was slightly longer than that following surgery. This result might have been related to either variations in techniques between surgery and ERCP or limited information from the publications reviewed. The literature describes multiple surgical procedures (including distal pancreatectomy with splenectomy, pancreatic duct anastomosis with an intestinal loop, pancreaticoduodenectomy, cystogastrostomy, and cystojejunostomy)[14], which are traumatizing and associated with many complications such as leakage, intra-abdominal infections, and fistula recurrence[7]. No further analysis was performed because of the limited number of cases reported. In addition, the results showed that the standard deviation of the ERCP group was smaller, suggesting that the ERCP group had less invasive treatment, a shorter postoperative recovery time, and a lower incidence of complications (infection, bleeding, destruction of pancreatic duct anatomy, repeated fluid accumulation, and pancreatitis). All four patients treated with ERCP reportedly had a good prognosis with no complications. The standard deviation of the postoperative recovery time in the surgery group was larger, indicating that the postoperative recovery time in the surgery group had greater variation and higher uncertainty. In summary, we believe that ERCP can reduce the hospitalization time and should be the preferred treatment for PPF in children.

Aswani *et al*[3] also reported that after ERCP, patients can quickly transition to the oral feeding stage and have a short recovery time, which reduces the hospital stay and mortality rate compared with a traditional operation. Therefore, existing research suggests that ERCP should be the first choice for patients with PPF who have a poor response to conservative treatment, and only after failure of conservative treatment and ERCP treatment should surgical treatment be considered. Because of the limited

number of patients in the present study, further prospective studies are needed to compare the cost-effectiveness and long-term results of ERCP and surgery.

Best operation time for ERCP

Patients with PPF initially receive conservative treatment and will choose surgery or ERCP treatment if their condition does not fully respond. We recommend ERCP as the first-choice treatment. Pleural effusion readily recurs after conservative treatment, potentially resulting in malnutrition, catheter infection, septicemia, and other complications. A longer duration of conservative treatment is associated with a greater risk for the patient. The present study investigated the relationship between the duration of conservative treatment and the overall hospital stay. The fitting analysis of the conservative treatment time and the total length of stay of three patients who received ERCP showed a positive linear correlation and suggested that a shorter conservative treatment time is associated with earlier performance of ERCP and a shorter overall hospital stay. Although conservative treatment has a certain response rate for PPF, the rate is very low, and the treatment cycle is long. Some researchers have proposed that conservative treatment should only be used as the initial stage of PPF treatment to stabilize the condition and should not be used as the treatment plan for PPF[7,52]. For patients with PPF, the duration of conservative treatment should be reduced, and ERCP treatment should be carried out as early as possible.

CONCLUSION

In conclusion, the success rate of ERCP for patients with PPF was similar to that of surgical treatment, and the prognosis was not worse than that of surgical treatment. Compared with traditional surgery, ERCP does not require laparotomy, is a simple operation, induces less trauma and fewer complications, and promotes rapid fast recovery. Thus, it is very suitable for children and advanced-age patients who cannot tolerate surgery or have poor health conditions. Earlier performance of ERCP promotes faster recovery and a shorter total length of stay. Therefore, ERCP is recommended as the first-choice treatment for PPF in children. ERCP should be performed as early as possible if conditions permit during conservative treatment. Because PPF is a rare disease and it is difficult to obtain data on clinical cases, the present study included only seven patients, one of whom was lost to follow-up after discharge. Thus, we were unable to perform a scientific and systematic comparative analysis on the curative effect of surgery and ERCP. The conclusions of this study still need to be validated.

ARTICLE HIGHLIGHTS

Research background

Pancreaticopleural fistula (PPF) can be diagnosed by laboratory examination and imaging examination. The traditional treatments are conservative treatment and surgery. Endoscopic retrograde cholangiopancreatography (ERCP) has since been performed increasingly more often in the diagnosis and treatment of PPF in adults. However, the experience of ERCP in the treatment of PPF in children is limited.

Research motivation

In the present study, the clinical data of children with PPF diagnosed in Beijing Children's Hospital were retrospectively analyzed, and the children's therapeutic response to ERCP was explored by comparison with previous publications worldwide.

Research objectives

This study is aimed to explore the treatment response to ERCP for PPF in children.

Research methods

Data on the clinical characteristics, diagnosis, treatments, and outcomes of seven Chinese children with PPF were analyzed and compared with those described in previous publications of children and adults with PPF worldwide.

Research results

There was no significant difference in the postoperative hospital stays between surgical treatment and ERCP. However, there was a positive linear correlation between the overall hospital stay and ERCP intervention time.

Research conclusions

ERCP is recommended as the first-choice treatment of PPF in children. ERCP should be performed as early as possible if conditions permit.

Research perspectives

Because PPF is a rare disease and it is difficult to obtain data on clinical cases, the present study included only seven patients, one of whom was lost to follow-up after discharge. Thus, we were unable to perform a scientific and systematic comparative analysis on the curative effect of surgery and ERCP. The conclusions of this study still need to be validated.

ACKNOWLEDGEMENTS

We thank the families of these patients for their support in this study.

REFERENCES

1 **Sut M**, Gray R, Ramachandran M, Diamond T. Pancreaticopleural fistula: a rare complication of ERCP-induced pancreatitis. *Ulster Med J* 2009; **78**: 185-186 [PMID: 19907687]
2 **Fulcher AS**, Capps GW, Turner MA. Thoracopancreatic fistula: clinical and imaging findings. *J Comput Assist Tomogr* 1999; **23**: 181-187 [PMID: 10096323 DOI: 10.1097/00004728-199903000-00004]
3 **Aswani Y**, Hira P. Pancreaticopleural fistula: a review. *JOP* 2015; **16**: 90-94 [PMID: 25640793 DOI: 10.6092/1590-8577/2915]
4 **McCune WS**, Shorb PE, Moscovitz H. Endoscopic cannulation of the ampulla of vater: a preliminary report. *Ann Surg* 1968; **167**: 752-756 [PMID: 5646296 DOI: 10.1097/00000658-196805000-00013]
5 **Saeed ZA**, Ramirez FC, Hepps KS. Endoscopic stent placement for internal and external pancreatic fistulas. *Gastroenterology* 1993; **105**: 1213-1217 [PMID: 8405869 DOI: 10.1016/0016-5085(93)90970-n]
6 **Ali T**, Srinivasan N, Le V, Chimpiri AR, Tierney WM. Pancreaticopleural fistula. *Pancreas* 2009; **38**: e26-e31 [PMID: 19106743 DOI: 10.1097/MPA.0b013e3181870ad5]
7 **King JC**, Reber HA, Shiraga S, Hines OJ. Pancreatic-pleural fistula is best managed by early operative intervention. *Surgery* 2010; **147**: 154-159 [PMID: 19744435 DOI: 10.1016/j.surg.2009.03.024]
8 **Kutz Leoz M**, Irisarri Garde R, Vila Costas JJ, Martínez Echeverría A, Elizalde Apestegui I, Basterra Ederra M, Gómez Alonso M, Zozaya Urmeneta JM. [Pleural effusion secondary to pancreaticopleural fistula following acute pancreatitis]. *Gastroenterol Hepatol* 2012; **35**: 70-73 [PMID: 22240268 DOI: 10.1016/j.gastrohep.2011.10.008]
9 **Shah D**, Desai AB, Salvi B. Pancreaticopleural fistula complicating chronic pancreatitis. *BMJ Case Rep* 2012; **2012** [PMID: 22878984 DOI: 10.1136/bcr-03-2012-6038]
10 **Sonoda S**, Taniguchi M, Sato T, Yamasaki M, Enjoji M, Mae S, Irie T, Ina H, Sumi Y, Inase N, Kobayashi T. Bilateral pleural fluid caused by a pancreaticopleural fistula requiring surgical treatment. *Intern Med* 2012; **51**: 2655-2661 [PMID: 22989845 DOI: 10.2169/internalmedicine.51.7859]
11 **Huang TY**, Tsai MJ. Education and imaging. Gastrointestinal: black pleural effusion induced by pancreaticopleural fistula. *J Gastroenterol Hepatol* 2013; **28**: 1798 [PMID: 24261952 DOI: 10.1111/jgh.12409]
12 **Okano A**, Ohana M, Kusumi F, Nabeshima M. Education and imaging. Hepatobiliary and pancreatic: pancreaticopleural fistula. *J Gastroenterol Hepatol* 2013; **28**: 1692 [PMID: 24147455 DOI: 10.1111/jgh.12383]
13 **Houlihan MD**, Bowyer BA, Barclay RL. Resolution of pancreatico-pleural fistula with endoscopic ultrasound-guided therapy. *Respir Med Case Rep* 2013; **9**: 30-33 [PMID: 26029626 DOI: 10.1016/j.rmcr.2013.05.001]
14 **Tay CM**, Chang SK. Diagnosis and management of pancreaticopleural fistula. *Singapore Med J* 2013; **54**: 190-194 [PMID: 23624444 DOI: 10.11622/smedj.2013071]
15 **Choe IS**, Kim YS, Lee TH, Kim SM, Song KH, Koo HS, Park JH, Pyo JS, Kim JY, Choi IS. Acute mediastinitis arising from pancreatic mediastinal fistula in recurrent pancreatitis. *World J Gastroenterol* 2014; **20**: 14997-15000 [PMID: 25356062 DOI: 10.3748/wjg.v20.i40.14997]
16 **Thyagaraj VK**, Rangappa P, Jacob I, Rao K. Recurrent pleural effusions: an unusual presentation of chronic pancreatitis. *J Assoc Physicians India* 2014; **62**: 627-630 [PMID: 25672042]
17 **Soares JT**, Ressurreição J, Marques I, Batista L, Pereira T, Mendes M. Pancreatopleural fistula contributing to a large volume recurrent pleural effusion. *Rev Port Pneumol (2006)* 2015; **21**: 163-164 [PMID: 25926245 DOI: 10.1016/j.rppnen.2015.01.001]
18 **Francisco E**, Mendes M, Vale S, Ferreira J. Pancreaticopleural fistula: an unusual complication of pancreatitis. *BMJ Case Rep* 2015; **2015** [PMID: 25678619 DOI: 10.1136/bcr-2014-208814]
19 **Hirosawa T**, Shimizu T, Isegawa T, Tanabe M. Left pleural effusion caused by pancreaticopleural fistula with a pancreatic pseudocyst. *BMJ Case Rep* 2016; **2016** [PMID: 27558195 DOI: 10.1136/bcr-2016-217175]

20 **Sánchez A**, Ramírez de la Piscina P, Duca IM, Estrada S, Salvador M, Campos A, Ganchegui I, Urtasun L, Delgado E, García Campos F, Pérez Miranda M. [Right pleural effusion secondary to a pancreaticopleural fistula in a patient with asymptomatic chronic pancreatitis]. *Gastroenterol Hepatol* 2016; **39**: 529-531 [PMID: 26548736 DOI: 10.1016/j.gastrohep.2015.07.006]
21 **Chan EE**, Shelat VG. Pancreaticopleural Fistula Causing Massive Right Hydrothorax and Respiratory Failure. *Case Rep Surg* 2016; **2016**: 8294056 [PMID: 27747128 DOI: 10.1155/2016/8294056]
22 **Abdalla S**, Nikolopoulos I, Kerwat R. Pancreatic Pseudocyst Pleural Fistula in Gallstone Pancreatitis. *Case Rep Emerg Med* 2016; **2016**: 4269424 [PMID: 27274876 DOI: 10.1155/2016/4269424]
23 **Virgilio E**, Mercantini P, Catta F, Grieco M, Cavallini M, Ferri M. Pancreaticopleural Fistula. *Surg Infect (Larchmt)* 2016; **17**: 266-267 [PMID: 26828566 DOI: 10.1089/sur.2015.156]
24 **Bustamante Bernal MA**, Gonzalez Martinez JL, Ortiz A, Zuckerman MJ. Recurrent Pleural Effusion Secondary to a Pancreatic-Pleural Fistula Treated Endoscopically. *Am J Case Rep* 2017; **18**: 750-753 [PMID: 28676624 DOI: 10.12659/ajcr.903925]
25 **Vijaykumar K**, Dsouza KG, Lerner L. Pancreaticopleural Fistula: The Formidable Liaison. *J Bronchology Interv Pulmonol* 2017; **24**: e60-e61 [PMID: 28957899 DOI: 10.1097/LBR.0000000000000405]
26 **Kord Valeshabad A**, Acostamadiedo J, Xiao L, Mar W, Xie KL. Pancreaticopleural Fistula: A Review of Imaging Diagnosis and Early Endoscopic Intervention. *Case Rep Gastrointest Med* 2018; **2018**: 7589451 [PMID: 30210880 DOI: 10.1155/2018/7589451]
27 **Daza Fernández ML**, Cuevas López L. Surgical management of pancreaticopleural fistula with video-assisted retroperitoneal pancreatic debridement: A case report. *Int J Surg Case Rep* 2020; **66**: 16-20 [PMID: 31785567 DOI: 10.1016/j.ijscr.2019.10.068]
28 **Chawla G**, Niwas R, Chauhan NK, Dutt N, Yadav T, Jain P. Pancreatic pleural effusion masquerading as right sided tubercular pleural effusion. *Monaldi Arch Chest Dis* 2019; **89** [PMID: 31558004 DOI: 10.4081/monaldi.2019.1125]
29 **Ramahi A**, Aburayyan KM, Said Ahmed TS, Rohit V, Taleb M. Pancreaticopleural Fistula: A Rare Presentation and a Rare Complication. *Cureus* 2019; **11**: e4984 [PMID: 31501720 DOI: 10.7759/cureus.4984]
30 **Li HM**, Zhao SY, Zhou J, Zeng Q, Zeng JJ, Jiang ZF. [Recurrent massive bloody pleural effusion caused by pancreatic pleural fistula in a case]. *Zhonghua Er Ke Za Zhi* 2009; **47**: 621-623 [PMID: 19951498]
31 **Ozbek S**, Gumus M, Yuksekkaya HA, Batur A. An unexpected cause of pleural effusion in paediatric emergency medicine. *BMJ Case Rep* 2013; **2013** [PMID: 23595187 DOI: 10.1136/bcr-2013-009072]
32 **Altasan T**, Aljehani Y, Almalki A, Algamdi S, Talag A, Alkattan K. Pancreaticopleural fistula: an overlooked entity. *Asian Cardiovasc Thorac Ann* 2014; **22**: 98-101 [PMID: 24585655 DOI: 10.1177/0218492312474453]
33 **Zhang LL**, Wu YL, Zhang HL, Zhang ZR, Xie XZ. [Polypnea-emaciation-hemorrhagic pleural effusion-pancreatic pleural fistula]. *Zhonghua Yixue Zazhi* 2014; **94**: 3681-3682 [DOI: 10.3760/cma.j.issn.0376-2491.2014.46.018]
34 **Chen B**, Mao J, Cheng JM, Xiong S, Xu X. [Two cases of pancreatic pleural fistula in children with massive pleural effusion as the first symptom]. *Zhonghua Fangshexue Zazhi* 2014; **48**: 606-607 [DOI: 10.3760/cma.j.issn.1005-1201.2014.07.021]
35 **Daib A**, Hellal Y, Boughdir M, Abdallah RB, Kaabar N. [Pancreatic-pleural fistula in children: a rare cause of great abundant pleurisy]. *Pan Afr Med J* 2017; **26**: 240 [PMID: 28690754 DOI: 10.11604/pamj.2017.26.240.9003]
36 **Yu Y**, Yu Z, Huang X. A rare case of pediatric pleural effusion: Pancreaticopleural fistula. *Pediatr Pulmonol* 2019; **54**: 5-6 [PMID: 30451400 DOI: 10.1002/ppul.24191]
37 **Zhuang LL**, Gong HH. [A case of pancreatic pleural fistula and literature review]. *Jiangsu Yiyao* 2018; **44**: 973-976 [DOI: 10.19460/j.cnki.0253-3685.2018.08.039]
38 **Lee D**, Lee EJ, Kim JW, Moon JS, Kim YT, Ko JS. Endoscopic Management of Pancreaticopleural Fistula in a Child with Hereditary Pancreatitis. *Pediatr Gastroenterol Hepatol Nutr* 2019; **22**: 601-607 [PMID: 31777728 DOI: 10.5223/pghn.2019.22.6.601]
39 **Yu ZX**, Yu YP, Huang XM. [Massive hemorrhagic pleural effusion caused by pancreaticopleural fistula in children: a case report and literature review]. *Linchuang Erke Zazhi* 2019; **37**: 427-431 [DOI: 10.3969/j.issn.1000-3606.2019.06.007]
40 **Liu XY**, Li YL. [A case of pleural effusion caused by chronic pancreatic pleural fistula]. *Linchuang Neike Zazhi* 2019; **36**: 172-173 [DOI: 10.3969/j.issn.1001-9057.2019.03.0009]
41 **Cameron JL**, Kieffer RS, Anderson WJ, Zuidema GD. Internal pancreatic fistulas: pancreatic ascites and pleural effusions. *Ann Surg* 1976; **184**: 587-593 [PMID: 984927 DOI: 10.1097/00000658-197611000-00009]
42 **Lipsett PA**, Cameron JL. Internal pancreatic fistula. *Am J Surg* 1992; **163**: 216-220 [PMID: 1739176 DOI: 10.1016/0002-9610(92)90104-y]
43 **Lerner A**, Branski D, Lebenthal E. Pancreatic diseases in children. *Pediatr Clin North Am* 1996; **43**: 125-156 [PMID: 8596678 DOI: 10.1016/s0031-3955(05)70400-4]
44 **Mihai C**, Floria M, Vulpoi R, Nichita L, Cijevschi Prelipcean C, Drug V, Scripcariu V. Pancreatico-Pleural Fistula - from Diagnosis to Management. A Case Report. *J Gastrointestin Liver Dis* 2018; **27**: 465-469 [PMID: 30574630 DOI: 10.15403/jgld.2014.1121.274.ple]
45 **Oh YS**, Edmundowicz SA, Jonnalagadda SS, Azar RR. Pancreaticopleural fistula: report of two cases and review of the literature. *Dig Dis Sci* 2006; **51**: 1-6 [PMID: 16416200 DOI: 10.1007/s10620-006-3073-7]
46 **Singh S**, Yakubov M, Arya M. The unusual case of dyspnea: a pancreaticopleural fistula. *Clin Case Rep* 2018; **6**: 1020-1022 [PMID: 29881555 DOI: 10.1002/ccr3.1434]
47 **Cazzo E**, Apodaca-Rueda M, Gestic MA, Chaim FHM, Saito HPA, Utrini MP, Callejas-Neto F, Chaim EA. Management of pancreaticopleural fistulas secondary to chronic pancreatitis. *Arq Bras Cir Dig* 2017; **30**: 225-228 [PMID: 29019567 DOI: 10.1590/0102-6720201700030014]
48 **Anderson WJ**, Skinner DB, Zuidema GD, Cameron JL. Chronic pancreatic pleural effusions. *Surg Gynecol Obstet* 1973; **137**: 827-830 [PMID: 4746503 DOI: 10.1016/S0361-1124(77)80283-9]
49 **Khan AZ**, Ching R, Morris-Stiff G, England R, Sherridan MB, Smith AM. Pleuropancreatic fistulae: specialist center management. *J Gastrointest Surg* 2009; **13**: 354-358 [PMID: 18972169 DOI:

10.1007/s11605-008-0699-0]

50 **Pai CG**, Suvarna D, Bhat G. Endoscopic treatment as first-line therapy for pancreatic ascites and pleural effusion. *J Gastroenterol Hepatol* 2009; **24**: 1198-1202 [PMID: 19486258 DOI: 10.1111/j.1440-1746.2009.05796.x]

51 **Varadarajulu S**, Noone TC, Tutuian R, Hawes RH, Cotton PB. Predictors of outcome in pancreatic duct disruption managed by endoscopic transpapillary stent placement. *Gastrointest Endosc* 2005; **61**: 568-575 [PMID: 15812410 DOI: 10.1016/s0016-5107(04)02832-9]

52 **Vanderbruggen W**, Dhooghe V, Bracke B, Hartman V, Roeyen G, Ysebaert D, Van Schil P, Chapelle T. Pancreaticopleural fistula: a rare cause of pleural empyema. *Acta Chir Belg* 2019; **119**: 396-399 [PMID: 29716451 DOI: 10.1080/00015458.2018.1470293]

World Journal of Gastroenterology

Submit a Manuscript: https://www.f6publishing.com

World J Gastroenterol 2020 October 7; 26(37): 5731-5744

DOI: 10.3748/wjg.v26.i37.5731

ISSN 1007-9327 (print) ISSN 2219-2840 (online)

CASE REPORT

Abernethy syndrome in Slovenian children: Five case reports and review of literature

Jerneja Peček, Petja Fister, Matjaž Homan

ORCID number: Jerneja Peček 0000-0002-9609-2039; Petja Fister 0000-0003-0983-9366; Matjaž Homan 0000-0001-5764-5430.

Author contributions: All authors equally contributed to this paper with conception and design of the study, acquisition and interpretation of data, literature review and analysis, drafting and critical revision and editing; all authors approved the final version of the manuscript for submission.

Informed consent statement: Informed written consent was obtained from the patients' legally authorized representatives for publication of this case series.

Conflict-of-interest statement: The authors declare that they have no conflict of interest.

CARE Checklist (2016) statement: The authors have read CARE Checklist (2016), and the manuscript was prepared and revised according to the CARE Checklist (2016).

Jerneja Peček, Division of Paediatrics, University Medical Centre Ljubljana, Ljubljana 1000, Slovenia

Petja Fister, Department of Neonatology, Division of Paediatrics, University Medical Centre Ljubljana; Faculty of medicine, University of Ljubljana, Ljubljana 1000, Slovenia

Matjaž Homan, Department of Gastroenterology, Hepatology and Nutrition, Division of Paediatrics, University Medical Centre Ljubljana; Faculty of Medicine, University of Ljubljana, Ljubljana 1000, Slovenia

Corresponding author: Matjaž Homan, MD, PhD, Associate Professor, Doctor, Department of Gastroenterology, Hepatology and Nutrition, University Children's Hospital, Faculty of Medicine, University of Ljubljana, Bohoričeva 20, Ljubljana 1000, Slovenia. matjaz.homan@guest.arnes.si

Abstract

BACKGROUND

Abernethy syndrome is a congenital vascular anomaly in which the portal blood completely or partially bypasses the liver through a congenital portosystemic shunt. Although the number of recognized and reported cases is gradually increasing, Abernethy syndrome is still a rare disease entity, with an estimated prevalence between 1 per 30000 to 1 per 50000 cases. With this case series, we aimed to contribute to the growing knowledge of potential clinical presentations, course and complications of congenital portosystemic shunts (CPSS) in children.

CASE SUMMARY

Five children are presented in this case series: One female and four males, two with an intrahepatic CPSS and three with an extrahepatic CPSS. The first patient, who was diagnosed with an intrahepatic CPSS, presented with gastrointestinal bleeding, abdominal pain and hyperammonaemia at six years of age. He underwent a percutaneous embolization of his shunt and has remained asymptomatic ever since. The second patient presented with direct hyperbilirubinemia in the neonatal period and his intrahepatic CPSS later spontaneously regressed. The third patient had pulmonary hypertension and hyperammonaemia due to complete portal vein agenesis and underwent liver transplantation at five years of age. The fourth patient was diagnosed immediately after birth, when evaluated due to another congenital vascular anomaly, and the last patient presented as a teenager with recurrent bone fractures associated with severe osteoporosis. In addition, the last two patients are

Manuscript source: Invited manuscript

Received: May 30, 2020
Peer-review started: May 30, 2020
First decision: July 29, 2020
Revised: August 11, 2020
Accepted: September 17, 2020
Article in press: September 17, 2020
Published online: October 7, 2020

P-Reviewer: Takama Y, Tang ST, Zhang J
S-Editor: Ma YJ
L-Editor: A
P-Editor: Wang LL

characterised by benign liver nodules; however, they are clinically stable on symptomatic therapy.

CONCLUSION
Abernethy syndrome is a rare anomaly with diverse clinical features, affecting almost all organ systems and presenting at any age.

Key Words: Abernethy syndrome; Abernethy malformation; Congenital portosystemic shunt; Liver vascular malformation; Children; Infants; Case report

Core Tip: Although congenital portosystemic shunts causing Abernethy syndrome are rare, the disease is complex, with the possibility of severe multi-organ complications. Searching for the congenital condition should therefore be included in the extended work-up of a newborn with other congenital, especially vascular malformations, neonatal cholestasis or hypergalactosemia. Furthermore, Abernethy syndrome should also be considered in older children presenting with pulmonary arterial hypertension, hyperammonemia and elevated liver enzymes. Additionally, according to our experience, a congenital portosystemic shunt should be considered in the differential diagnosis of children with unexplained hypoglycaemic episodes, gastrointestinal bleeding and osteoporosis with fat-soluble vitamin deficiency.

Citation: Peček J, Fister P, Homan M. Abernethy syndrome in Slovenian children: Five case reports and review of literature. *World J Gastroenterol* 2020; 26(37): 5731-5744
URL: https://www.wjgnet.com/1007-9327/full/v26/i37/5731.htm
DOI: https://dx.doi.org/10.3748/wjg.v26.i37.5731

INTRODUCTION

Abernethy syndrome is named after John Abernethy, a London surgeon who first described this disease entity in the 18th century[1]. It is a rare anomaly of the portal venous system, whereby the blood from the splanchnic venous system completely or partially bypasses the liver and is diverted directly into a systemic vein *via* a congenital portosystemic shunt (CPSS)[2]. The estimated prevalence of this malformation is 1 per 30000 Live births[3]. Spontaneous closure of a CPSS is possible[2]. The incidence of permanent CPSS is around 1 per 50000. CPSS is defined as intrahepatic if abnormal communications between the branches of the portal vein and hepatic veins or inferior vena cava exist, or extrahepatic if it originates from the main portal vein before dividing or when the portal vein is completely absent[4]. Extrahepatic shunts are commonly accompanied by other congenital anomalies[2] and are further divided according to Morgan and Superina into two types. Type 1 represents complete shunting of the portal venous blood (*i.e.*, end-to-side shunt) with severe hypoplasia or total absence of the intrahepatic tree, and type 2, which exhibit partial shunting (*i.e.*, side-to-side shunt) and where some perfusion of the liver with portal blood remains[5]. If there is a congenital absence of the portal vein, type 1 shunt is identified as type 1A, and if the superior mesenteric vein and splenic vein drain into a common trunk and form a sort of portal vein, which then flows directly into the inferior vena cava, the shunt is type 1B – the one that Abernethy originally described[4].

The clinical significance of CPSS mainly depends on the ratio of blood flow through the shunt[6]. The clinical picture of the shunt can range from an asymptomatic patient with incidentally detected elevated liver enzymes or changes detected on liver imaging[2,7,8], to a symptomatic patient with severe disease presenting with multiple organ involvement[7-9].

Diagnosis is usually made by Doppler ultrasonography (US) of the liver[10,11], commonly in combination with computed tomography (CT) or magnetic resonance imaging (MRI) of the abdomen[8,12,13]. A liver biopsy is necessary to confirm or exclude the presence of venules in the portal triads, which is important for distinguishing between type 1 and type 2 extrahepatic CPSS and guiding treatment. Diagnostic testing for the presence of comorbidities or complications is performed based on the

clinical picture[2,7,9].

Treatment depends on the type of shunt and the development of complications[14]. For type 1 CPSS, the only definitive treatment option is a liver transplant, whereas type 2 CPSS and intrahepatic CPSS are amenable to percutaneous or surgical closure[2,14-16]. Unlike extrahepatic shunts, intrahepatic CPSS can close spontaneously in the first year of life[2,7,17,18].

Herein we present five children diagnosed with Abernethy syndrome in the last 15 years at the University Children's Hospital in Ljubljana. We reviewed their clinical features, radiological and laboratory findings, management strategies and outcomes, which are summarized in Table 1.

CASE PRESENTATION

Chief complaints

Case 1: A six-year-old boy presented with severe, recurrent gastrointestinal bleeding and abdominal pain.

Case 2: A newborn boy developed jaundice after the start of oral feeding following abdominal surgery.

Case 3: A 22-month-old boy was referred to our clinic because of breathing difficulties during a viral infection of the upper respiratory tract.

Case 4: A newborn boy presented because of a vascular malformation on his right leg.

Case 5: A 14-year-old girl presented with symptoms and signs of severe osteoporosis.

History of present illness

Case 1: The patient fell ill a few days before admission with abdominal pain and vomiting. His parents also reported that he had been passing dark stools and that he was becoming increasingly more drowsy and somnolent.

Case 2: The patient was born after the completed 38th week of gestation as symmetrically small for gestational age (SGA) male infant. He developed high ileus and was operated on soon after birth. Intraoperatively, a duodenal membrane was found and duodenotomy with membrane incision was performed and his early postoperative course was mostly unremarkable. We introduced oral feeding on postoperative day 7, when the patient was 9 d old.

Case 3: The patient's parents reported that he had had exertional dyspnea and frequent tachycardias for several weeks before admission, but that his condition worsened a couple of days prior.

Case 4: The patient was born full-term after a normal pregnancy, with normal birth and length measurements. While still in the newborn nursery, he received 36 h of phototherapy due to hyperbilirubinemia.

Case 5: At the age of nine, she began experiencing recurrent bone fractures. In the seven years prior to admission, she had suffered six bone fractures, which occurred with minor injuries. Her dual-energy X-ray absorptiometry (DEXA) scan showed severe osteoporosis and she underwent diagnostic testing prior to the initiation of bisphosphonate therapy.

History of past illness

Case 1: His previous clinical history was remarkable for a congenital vascular malformation on the left shoulder, cardiomyopathy and increased galactose level, discovered in the neonatal period. Since further testing excluded an inborn error in galactose metabolism and galactose levels normalized without any specific diet, no additional diagnostic testing was pursued at that time. His follow-up echocardiography was also normal.

Case 3: He had suffered a small subdural hematoma after a fall when he was 18 mo old but had been otherwise healthy and developing normally.

Case 5: Her clinical history included an atrial septal defect (ASD) type secundum, which was hemodynamically significant and was therefore surgically closed at four

Table 1 Patients' clinical features, management and outcome

Case/gender	Type of shunt	Age at diagnosis	Associated congenital anomalies	Main clinical features at presentation	Additional clinical features and development of complications	Management	Outcome
1/M	Intrahepatic	8 yr	Congenital vascular malformation of the left shoulder	Diffuse abdominal pain and gastrointestinal haemorrhage	Signs of increased blood flow through pulmonary circulation, prominent gastric submucosal vasculature	Percutaneous closure of the shunt with Amplatzer plug	Age 13 yr: No shunt present, no signs and symptoms
2/M	Intrahepatic	< 1 mo	Duodenal membrane	Direct hyperbilirubinemia, increased liver enzymes	None	Conservative treatment with close follow-up	Age 8 mo: Spontaneous shunt regression, no signs or symptoms
3/M	Extrahepatic (1A)	22 mo	None	Pulmonary arterial hypertension, hyperammonemia	Worsening of pulmonary hypertension, basal ganglia hyperintensity on brain MRI	Liver transplantation at five years of age	Age 14 yr: Persistent pulmonary arterial hypertension
4/M	Extrahepatic (1A)	< 1 mo	Klippel–Trénaunay syndrome	Hyperbilirubinemia, hyperammonemia, hypovitaminosis	Osteoporosis, hypoglycemic episodes, regenerative liver nodules	Conservative treatment with close follow-up	Age 9 yr: Shunt present, no further complications
5/F	Extrahepatic (1B)	14 yr	ASD type secundum	Bone fractures from severe osteoporosis	Focal nodular hyperplasia, basal ganglia hyperintensity on brain MRI	Conservative treatment with close follow-up	Age 18 yr: Shunt present, no further complications, stable hepatic lesions

MRI: Magnetic resonance imaging; ASD: Atrial septal defect.

years of age.

Physical examination

Case 1: The patient was awake and responsive, but disoriented. He was pale, with diffuse abdominal tenderness on palpation. Otherwise, his physical exam and vital signs were within normal limits.

Case 2: The main finding on clinical examination was jaundice, accompanied by increasing lethargy and poor feeding.

Case 3: In addition to the signs of acute upper respiratory tract infection, clinical examination revealed peripheral edema and a systolic heart murmur. We also observed a slight tremor of the hands.

Case 4: On clinical examination, an extensive erythematous-livid vascular malformation was noted on his right thigh and lower leg. The patient was also icteric.

Case 5: No abnormalities were discovered in the physical examination.

Laboratory examinations

Case 1: The patient had acute anemia (Hb 79 g/L) and hyperammonemia (ammonia levels 112 μmol/L, normal range 9-33 μmol/L). All other laboratory findings were within normal limits.

Case 2: Blood work-up revealed direct hyperbilirubinemia (133/92 μmol/L) and increased liver enzymes (AST 2.16 μkat/L, normal up to 0.58 μkat/L; ALT 0.94 μkat/L, normal up to 0.74 μkat/L; GGT 0.96 μkat/L, normal up to 0.92 μkat/L). His bilirubin levels continued to rise despite treatment with ursodeoxycholic acid and phototherapy to a maximum of 430/226 μmol/L. When searching for a potential cause, an increased level of galactose in the urine with normal serum galactose and normal GALT enzyme activity in the erythrocytes was found. His serum ammonia was 66 μmol/L (normal range for newborns up to 113 μmol/L) and his coagulation tests were slightly abnormal (INR 1.50).

Case 3: Hyperammonemia was detected. Biochemical investigations otherwise showed good liver function, with normal liver enzymes, increased bile acids and slightly prolonged INR value of 1.69.

Case 4: The laboratory work-up revealed normal liver enzymes, indirect and also direct hyperbilirubinemia, elevated bile acids (neonatal levels of 82 μmol/L, maximum 245 μmol/L at 11 wk of age, normal up to 10 μmol/L), hyperammonemia (maximum ammonia levels 200 μmol/L, normal 9-33 μmol/L), increased levels of alpha-fetoprotein (1398 kU/L, normal up to 5.5 kU/L), prolonged APTT (49.5 s, normal range 23-42 s) and PT/INR (1.69, normal range 0.90-1.27). He had vitamin A hypovitaminosis (0.19 μmol/L, normal range 0.7-2.8 μmol/L) and his vitamin E and D levels were on the lower limit of normal.

Case 5: Elevated liver enzymes were found (AST 0.99 μkat/L, normal up to 0.52 μkat/L, ALT 0.79 μkat/L, normal up to 0.56 μkat/L, GGT 2.69 μkat/L, normal up to 0.63 μkat/L and AP 4.07 μkat/L, normal up to 1.74 μkat/L). Her vitamin D levels were on the lower limit of normal (25-hydroxyvitamin D 33 nmol/L, normal range 32-165 nmol/L).

Imaging examinations

Case 1: At the time of his first presentation with gastrointestinal bleeding, esophago-gastro-duodenoscopy (EGD) showed Mallory-Weiss tears. His initial abdominal US was normal and Meckel's diverticulum was excluded with scintigraphy. The hyperammonemia was thought to be caused by a gastrointestinal haemorrhage and no further work-up was pursued at that time. The bleeding subsided with symptomatic treatment.

He returned to the clinic after one and a half years because of sudden, severe abdominal pain. At that time, his chest X-ray revealed signs of increased blood flow through the pulmonary circulation and on EGD, prominent gastric submucosal vasculature was observed. Abdominal Doppler US showed an anomalous vascular connection between the wider left hepatic vein and left portal vein (Figure 1). The diagnosis of intrahepatic CPSS was confirmed by abdominal CT with contrast, which demonstrated a direct inflow of the left portal vein into the left hepatic vein (Figure 2). An enlarged venous plexus at the gastric antrum was also noted. Liver biopsy was performed and it showed normal hepatic tissue with venules present in the portal triads.

Case 2: His initial abdominal US showed hepatosplenomegaly without biliary atresia. Later, abdominal US was repeated and Doppler study identified an intrahepatic CPSS with two anastomoses between the branches of the portal vein and the branches of the left hepatic vein. It was estimated that 30% of the portal blood flowed through the anastomoses and therefore bypassed the liver. The hepatic structure was otherwise unremarkable and no pathologic lesions were seen. The diagnosis of an intrahepatic CPSS was confirmed by MRI.

Case 3: On echocardiography, his heart was structurally normal, but his right ventricle was hypertrophied and moderately dilated, with mild to moderate tricuspid regurgitation. He was diagnosed with moderate pulmonary hypertension, confirmed by cardiac catheterization, which showed a mean pulmonary arterial pressure of 45 mmHg. On abdominal US and abdominal MRI, portal vein agenesis was confirmed with a communication between the splenic and mesenteric vein and inferior vena cava. Wedge venography confirmed a total absence of the intrahepatic portal vein. Liver biopsy excluded liver cirrhosis. On brain MRI, basal ganglia hyperintensity was seen,

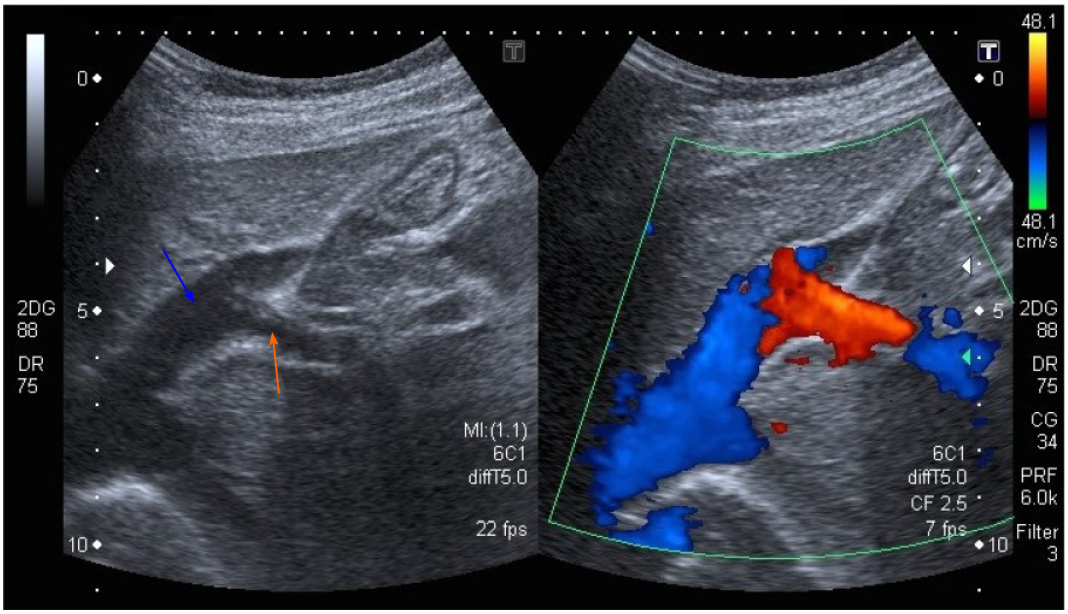

Figure 1 Abdominal ultrasound with Doppler color flow (case 1). An anomalous vascular connection between the left hepatic vein (blue arrow) and left portal vein (orange arrow) is seen.

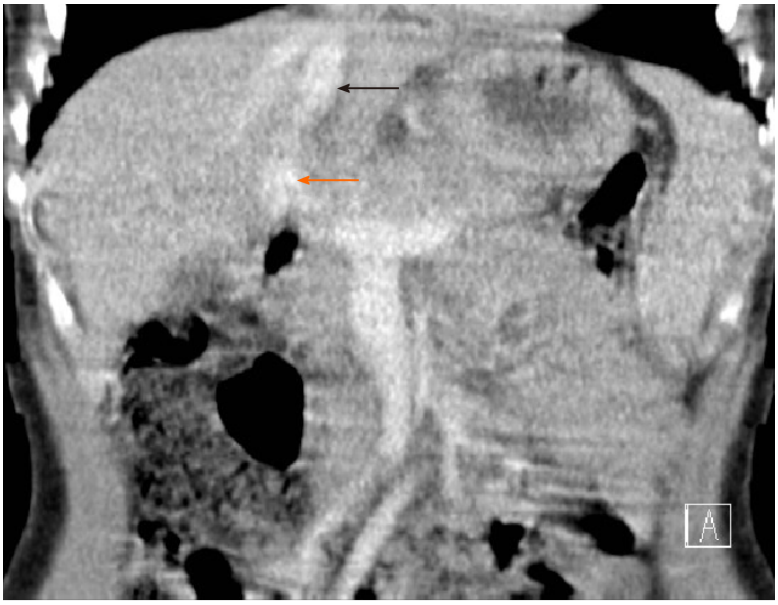

Figure 2 Abdominal computed tomography image of the intrahepatic portosystemic shunt (case 1). The left portal vein (orange arrow) flows directly into the left hepatic vein (black arrow).

but the EEG did not show diffuse slow waves.

Case 4: We performed an abdominal US as a screening test for additional congenital malformations. On Doppler imaging, anomalous abdominal venous vasculature was noted (possible anastomosis of mesenteric vasculature with inferior vena cava) but the exact anatomy was not clear. To obtain a detailed view of his abdominal vasculature, an MRI was ordered, and it displayed a congenital extrahepatic portosystemic shunt without any communication with the intrahepatic portal venous system. The extrahepatic course of the portal vein was not visible. A liver biopsy was also performed and it showed diffuse steatosis without any evidence of liver cirrhosis. His EEG showed minimal diffuse slow electrical brain activity and his echocardiography and chest X-ray were normal.

Case 5: An abdominal US revealed a structurally non-homogeneous tumour formation

with central calcinations in the right liver lobe. An abdominal CT was also performed and it showed an anomalous course of the portal vein, which was shorter than normal and drained directly into the inferior vena cava from the anteromedial side, just above the drainage of renal veins – an anomaly typical of CPPS type 1B. The liver was completely perfused solely by the strong hepatic artery (complete arterialization of blood flow). The liver parenchyma was also structurally non-homogenous. MRI of the abdomen showed a combination of adenomas and regenerative nodules (Figure 3) and histologic examination of tumor formations revealed focal nodular hyperplasia. Three months after initial diagnostics, she began experiencing headaches and an MRI of the brain was obtained, which showed globus pallidus hyperintensity (Figure 4). Her serum ammonia levels were normal, however, as was her EEG. No other cause for her severe osteoporosis was found and genetic testing for osteogenesis imperfecta was negative.

FINAL DIAGNOSIS

Case 1

The final diagnosis of the presented case is intrahepatic CPSS with an anastomosis between the left portal vein and left hepatic vein.

Case 2

The final diagnosis of the presented case is intrahepatic CPSS with two anastomoses between the branches of the portal vein and the branches of the left hepatic vein.

Case 3

The final diagnosis of the presented case is type 1A extrahepatic CPSS – complete agenesis of the portal vein.

Case 4

The final diagnosis of the presented case is type 1A extrahepatic CPSS.

Case 5

The final diagnosis of the presented case is type 1B extrahepatic CPSS.

TREATMENT

Case 1

We opted for a percutaneous embolization of his shunt with an Amplatzer plug when the patient was 10 years old. A 16 mm large Amplatzer plug was inserted into a short segment of the left portal vein, just behind the bifurcation. Complete occlusion of the shunt was confirmed by Doppler US before discharge.

Case 2

The patient was treated symptomatically with ursodeoxycholic acid and an amino-acid based formula (Neocate LCP®). Later, when a disorder of galactose metabolism had been ruled out, he was switched back to a normal diet. Due to prolonged INR, he received vitamin K intravenously, after which the coagulation normalized. Exchange transfusion was performed due to severe direct hyperbilirubinemia when he was eight days old.

Case 3

At first, the patient was treated pharmacologically with medication for pulmonary hypertension, intermittent vitamin K applications, ursodeoxycholic acid and lactulose, vitamin D3 and vitamin E. At four years of age, he was started on home oxygen therapy and, one year later, he underwent a liver transplantation.

Case 4

The patient was treated symptomatically with lactulose, dietary protein restriction, ursodeoxycholic acid and fat soluble vitamins.

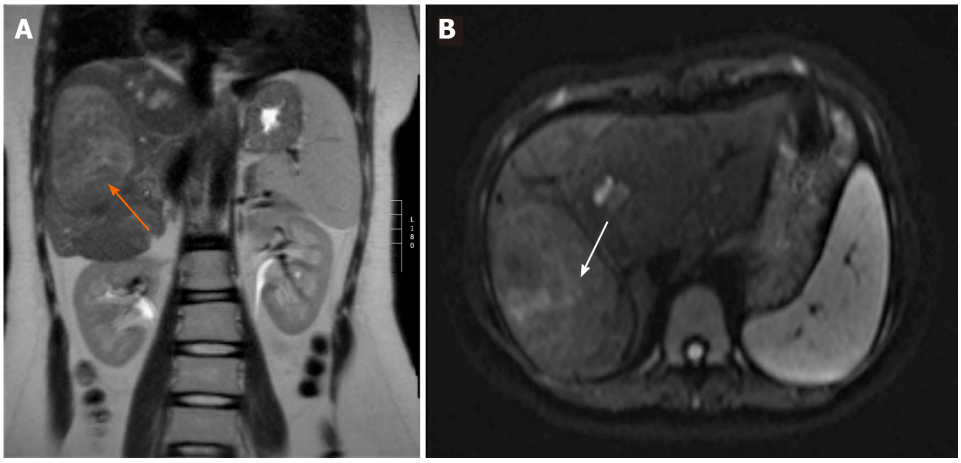

Figure 3 Abdominal magnetic resonance imaging scan demonstrating a lesion in the right liver lobe (case 5). A: The lesion (orange arrow) is slightly hyperintense compared to the sorrounding liver tissue on coronal T2-weighted imaging; B: The same lesion (white arrow) has no restriction of diffusion on axial diffusion-weighted imaging (DWI) sequence - a benign lesion.

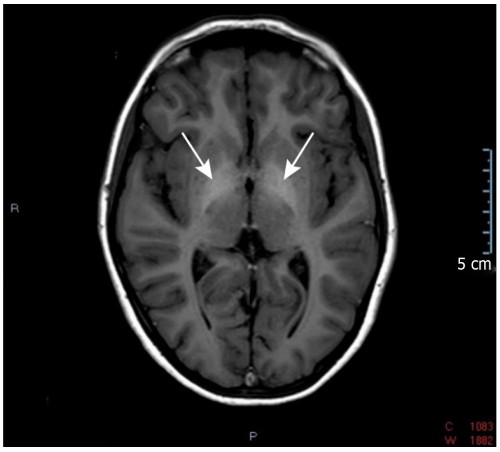

Figure 4 Axial T1-weighted brain magnetic resonance imaging scan (case 5). Arrows indicate symmetrical T1-hyperintensity involving the bilateral globus pallidus.

Case 5

The patient was treated symptomatically with vitamin D3, calcium carbonate, bisphosphonates, ursodeoxycholic acid and lactulose.

OUTCOME AND FOLLOW-UP

Case 1

In the presented patient, at check-ups, the flow through the shunt did not reappear and, after a couple of months, his right portal vein became significantly more canalised and prominent in comparison with the pre-occlusion state. Since percutaneous closure of the shunt four years prior, the patient has been followed-up regularly and remains asymptomatic. His blood tests and ECG are normal and on EGD, performed 2 years after the closure of the shunt, hypertensive gastropathy was less pronounced than prior to treatment.

Case 2

The patient was discharged from the hospital in good clinical condition and during his follow-up after eight months, a spontaneous regression of the shunt was observed on the abdominal US with color and pulsed Doppler examination. His blood tests were normal and his parents did not report any additional signs; he was developing and growing normally. Ursodeoxycholic acid was discontinued. A follow-up Doppler US

is planned at 18 mo of age to see whether the shunt will close completely on its own.

Case 3

Regression of pulmonary hypertension in the presented patient was observed two years after the transplantation. Pulmonary vascular resistance remained elevated, however, so specific pharmacologic treatment was continued. At seven years of age, he underwent treatment for a newly diagnosed Burkitt lymphoma of the small intestine, which occurred during intensive immunosuppressive treatment due to graft rejection. Later, at 14 years of age, during one of his regular echocardiographic examinations, signs of deterioration of pulmonary hypertension were observed, which was confirmed on cardiac catheterization. Further work-up in collaboration with pediatric cardiologists, pulmonologists and hepatologists is planned.

Case 4

When the patient was four years old, we discovered decreased bone mineral density in the range of osteoporosis and calcium carbonate was added to his therapy, while vitamin D3 was switched to its active form (calcitriol). He also began experiencing occasional transient hypoglycemic episodes, which occur about two hours after meals and manifest with sudden tiredness and somnolence. These episodes resolve spontaneously or by ingesting a sugary meal and can be prevented by drinking fruit juices throughout the day.

He is currently nine years old and clinically stable on his medical therapy. On his imaging investigations, we have detected several small hepatic lesions, which have been present and of equal size since he was four years old and have the US appearance of regenerative nodules. His laboratory investigations also did not show any dynamics thus far and he is therefore not on the active transplant list.

Case 5

In the presented patient, regular follow-ups with alpha-fetoprotein, LDH, ammonia, echocardiography and abdominal imaging with Doppler US and MRI are performed. The patient's osteoporosis is slowly improving on the appropriate therapy, although her mineral bone density is still markedly low. Her liver enzymes also remain elevated. She is at the moment on the non-active transplant list due to the stability of her clinical condition.

DISCUSSION

The first case series of 19 patients was reported in the literature in 1997 by Howard and Davenport[19]. However, the number of reported cases is increasing[2]. In 2013, Sokollik *et al*[7] identified 316 published cases and, up to 2019, more than 310 cases of just the extrahepatic type of CPSS had been published[8,11]. During a 15-year period (2004-2019), five children were diagnosed with a CPSS at the University Children's Hospital in Ljubljana. Two of our patients had an intrahepatic CPSS and three had an extrahepatic CPSS – a ratio of 2:3 that is very similar to existing reports[2,7]. Among the children with extrahepatic CPSS, however, two of our patients had type 1A and one patient had type 1B extrahepatic CPSS, which differs from a recent observational, international study by Baiges *et al*[8], who found that type 1A extrahepatic CPSS were the rarest, representing only 11% of all extrahepatic CPSS in their series.

In our patients, the mean age at diagnosis was four years (range from less than 1 mo to 14 years), which is considerably later than was reported by Kim *et al*[18], who described that seven out of ten children were diagnosed at an age younger than 1 mo, but in agreement with a larger series by Sokolik *et al*[7], in which 66% of patients were diagnosed before 12 years of age. One of our patient was female; the others were male. In contrast to that, there is no clear male or female preponderance in patients with CPSS reported in the literature, with 56% males and 44% females affected, but intrahepatic shunts were previously reported to be more common in male patients[2,7].

CPSS, especially type 2 extrahepatic shunts, frequently occur in conjunction with other congenital malformations[2,4,16], which was also true for four out of five patients described. Two patients had congenital malformations of the peripheral vasculature: The patient with an intrahepatic CPSS had a vascular malformation on the left shoulder and the patient with type 1A extrahepatic CPSS had a vascular malformation on his right leg, diagnosed as Klippel–Trénaunay syndrome. The girl with type 1B extrahepatic CPSS was born with ASD type secundum and the second patient described had a congenital duodenal membrane. Whereas congenital cardiac

anomalies are found in 20%-30% of CPSS patients[7,8], the association with Klippel–Trénaunay syndrome, which was actually the clue for the discovery of CPSS in one of our patients, has rarely been described[20-22].

Clinical features of CPSS can be divided into several types according to their pathophysiology.

Deficient nutrition of the liver due to a lack of blood flow may cause intrauterine growth restriction[23]. Intrauterine growth restriction affects up to 50% of children with CPSS[2], but it was present in only one of our patients, in whom the lack of portal venous blood flow also caused anoxic-ischemic neonatal cholestasis. Neonatal cholestasis can be a part of the clinical picture and has been described in 24 out of 265 clinical cases of CPSS[2]. Moreover, in 10 of them it was an initial presenting sign that prompted further diagnostic work-up, similar to our case. Searching for a CPSS should therefore be included in the neonatal cholestasis work-up.

Due to the diversion of metabolites and vasoactive mediators from the splanchnic venous system directly into systemic circulation, blood galactose level and blood ammonia may be elevated and portosystemic encephalopathy, hepatopulmonary syndrome or pulmonary arterial hypertension with congestive heart failure might develop. Neonatal hypergalactosemia with normal enzyme activities was detected in two of our patients. According to the published literature, hypergalactosemia is present in up to 70% of newborns with CPSS[2] and vice versa – data show that around 60% of newborns with persistent galactosemia without enzyme deficiencies have CPSS[24]. A CPSS can also lead to hyperammonemia, present in all but one patient from our case series, as well as portosystemic encephalopathy, with a spectrum of different neurological manifestations – from episodes of lethargy or irritability with agitation, to intellectual disability and behavioral problems[2,7]. Typical of portosystemic encephalopathy, but sometimes detected with portosystemic shunting alone, are slow waves on EEG, a minimal degree of which were present in one patient during infancy, while his hyperammonemia was well-controlled on conservative treatment, and a high signal intensity in the globus pallidus on brain MRI, present at the time of diagnosis in two of our patients. This change is thought to be related to hypermanganesemia[2,25]. Takama *et al*[26] previously reported on a case of a 1-year-and-7-month-old girl with two intrahepatic portosystemic shunts, who had hypermanganesemia and abnormal globus pallidus hyperintensity which disappeared after the treatment with a right hepatectomy. Levels of serum manganese have not been measured in our patients.

Another common complication of CPSS is porto-pulmonary arterial hypertension, which can occur in children of all ages and with all anatomical types of shunt and can frequently be a first presenting sing of CPSS, as we described in case number 3. Because it can lead to right heart failure and death, screening by clinical history, physical examination and echocardiography are necessary in all children with CPSS, and significant porto-pulmonary hypertension is one of the indications for surgical treatment of CPSS[2,16,27].

One of our patients (case 4) also began experiencing hypoglycemic episodes when he was four years old, which is one of the rarer clinical complications of CPSS and has been described mostly in newborns, in whom it can be clinically very severe and persistent and is most likely due to hyperinsulinism from reduced hepatic degradation of insulin[28]. In our case, the patient responded well to increased oral glucose intake.

Additionally, with CPSS there is an increased incidence of benign and malignant hepatic lesions[2,7,29,30] which are presumed to be linked to decreased perfusion of hepatic tissue with portal blood and concomitantly increased hepatic arterial blood flow[12,13]. Benign liver tumors were present in two patients with extrahepatic CPSS from our series. In one of them, the CPSS was found incidentally during diagnostic work-up for tumor formation in the right liver lobe, which was performed due to increased liver enzymes. The other patient with neonatally-diagnosed CPSS (case 4) had had increased alpha-fetoprotein levels since the newborn period and had multiple tumor formations, observed on US when he was four years old. Since these changes were stable and had the US appearance of regenerative nodules, no invasive treatment has been necessary up to now. Both patients continue to receive serial imaging investigations in order to detect potential malignant alteration.

We also present two unusual complications of CPSS, upper gastrointestinal bleeding and osteoporosis.

The first patient presented with severe, recurrent gastrointestinal bleeding, which is a rare clinical manifestation of CPSS. Gastrointestinal bleeding in CPSS was previously reported in 2015 by Gong *et al*[31], who described six patients that initially presented with bleeding from the lower gastrointestinal tract and were all found to have superior rectal vein and colonic varices due to an extrahepatic shunt that drained portal blood into the iliac vein *via* the inferior mesenteric vein. This was also reported to be the most

common type of CPSS associated with gastrointestinal bleeding by Kobayashi *et al*[32], who reviewed clinical features of 136 published cases of extrahepatic CPSS, 8% of which were associated with gastrointestinal bleeding. In contrast to the most commonly reported association of gastrointestinal bleeding with extrahepatic CPSS, the patient we describe had an intrahepatic CPSS between the left portal and left hepatic vein. He presented with melena, which indicates that the bleeding was of upper gastrointestinal origin and not due to rectal or colonic varices, as described by Gong *et al*[31] Of the previously published cases of CPSS with gastrointestinal bleeding, only one patient reported by Alomari *et al*[33] had an intrahepatic CPSS, as our patient did. They proposed that the bleeding was caused by diversion of the mesenteric blood flow from the bowel, which resulted in relative intestinal mucosal ischemia, with diffuse erosive changes in the intestine[33]. In our patient, prominent gastric submucosal vasculature (consistent with hypertensive gastropathy) was seen two years after his first presentation, when the abdominal CT with contrast also revealed an enlarged venous plexus at the gastric antrum. This finding is somewhat unusual, however, since portal hypertension normally does not develop in CPSS, because the blood flows easily through the shunt[6].

Osteoporosis was present in two of our patients: In a 14-year-old girl, severe osteoporosis was the first clinical sign of CPSS, and a boy was discovered to have osteoporosis 4 years after he was diagnosed with CPSS (case 4). Cholestatic liver disease is known to be frequently accompanied by hepatic osteodystrophy but, to the best of our knowledge, the correlation of osteoporosis and CPSS has not previously been studied. Severe osteoporosis was reported in a 17-year-old patient with extrahepatic CPSS and several others concomitant anomalies in a case series by Ponziani *et al*[11], but this association has not been explored further. Studies on hepatic osteodystrophy postulate, however, that, in addition to hepatic dysfunction, portal blood flow abnormalities and malabsorption could contribute to its pathogenesis. van der Merwe *et al*[34] showed that portosystemic shunting is a major pathogenic factor causing bone loss in rats, but this pathophysiologic mechanism has not yet been studied in humans. Abnormalities in vitamin D metabolism or vitamin D deficiency may also play a role in the development of osteoporosis in CPSS. The girl with severe osteoporosis (case 5) was found to have 25-OH vitamin D, on the lower limit of normal and in the boy from case 4, osteoporosis developed despite vitamin D3 supplementation. Other patients from our series also had vitamin D, as well as other fat-soluble vitamins deficiencies and are receiving regular replacement therapy. This underscores the importance of checking the levels of fat soluble vitamins in patients with CPSS. No clinical reports have highlighted this issue thus far, with the exception of coagulopathy reflected in prolonged prothrombin time, which was described in 31 of 77 patients reviewed by Bernard *et al*[2] and in 2 of 3 patients from a case series by Fu *et al*[35]. Among our patients, coagulopathy responsive to vitamin K substitution was detected in three children. A possible mechanism for fat soluble vitamin deficiencies in CPSS could be a disruption in the enterohepatic circulation of bile acids as a result of intestinal blood bypassing the liver. Anoxic-ischemic cholestasis due to liver underperfusion could also be a contributing factor.

When it comes to treatment, occlusion of type 1 CPSS is not possible in most cases, because the shunt is the only possible drainage pathway for blood from the mesenteric and splenic veins[2,36], which is best proven by portography after occlusion of the shunt. The only treatment option for patients with no intrahepatic portal venous system who develop severe complications is therefore liver transplant, which was performed in the patient with severe porto-pulmonary hypertension from our case series, in whom a total absence of the intrahepatic portal vein was confirmed with wedge venography. The two other patients with extrahepatic CPSS are clinically stable and are not yet on the active liver transplant list. This is in accordance with the reports from Sokollik *et al*[7] and Knirsch *et al*[16], who described several patients in good clinical condition on symptomatic treatment. It is important to note, however, that we did not perform portography in these two patients and therefore the correct malformation subtype might not have been identified.

After confirming that the intrahepatic portal system is intact, partial CPSS can be occluded either by surgical ligation or percutaneously by an interventional radiologist[2,16,18], such as was successfully performed in our first case, in whom the biopsy showed normal hepatic tissue with venules present in the portal triads

Stabilization and regression of the pulmonary, neurologic, cardiac and vascular complications can be expected after liver transplantation or shunt resolution[2,15,35-37]. Jain *et al*[9], for example reported marked improvement in clinical signs, symptoms and laboratory values in all five patients with extrahepatic CPSS type 2 who underwent shunt ligation and complete closure of the shunt stabilized or even reduced

pulmonary arterial pressure in two of the patients from a case series by Kirsch *et al*[16]. Orthotopic liver transplantation has similarly good results, as reported by Xiang *et al*[36]. In our series, we discovered an improvement of hypertensive gastropathy in the first patient from our case series. In the patient who underwent liver transplant, pulmonary hypertension did not improve significantly at least in long term.

In the second child of our patients, who had an intrahepatic shunt discovered in the neonatal period, spontaneous regression was observed and, according to the published literature, the shunt will probably close with time[2,7,17,18].

The principle limitations of our study are the relatively small sample size due to the rarity of the condition and the size of our centre, and retrospective data analysis with data quality depending on the accuracy of the medical records and the extent of diagnostic workup. Because patients were diagnosed at different time points during the 15-year period, the length of follow-up and the age at the end of the study were variable. Another possible limitation is the aforementioned lack of imaging of the portal venous system by portography which may have led to diagnostic error in some of our patients.

CONCLUSION

In conclusion, Abernethy syndrome is a rare congenital anomaly that can affect all organ systems and most commonly presents with neonatal cholestasis, hyperammonemia, pulmonary arterial hypertension and liver tumors. Rarer clinical manifestations of CPSS are also possible, such as upper gastrointestinal tract bleedings and bone fractures. Along with the well-known correlation of CPSS with congenital cardiac disease, we also describe a possible association with other congenital vascular anomalies, such as Klippel–Trénaunay syndrome, which should perhaps prompt screening for CPSS. Our patients were treated according to the existing algorithms, based on the anatomy of the lesion and the clinical picture itself and continue to receive close follow-up.

REFERENCES

1 **Abernethy J**. Account of Two Instances of Uncommon Formation in the Viscera of the Human Body: From the Philosophical Transactions of the Royal Society of London. *Med Facts Obs* 1797; 100-108 [PMID: 29106224 DOI: 10.1098/rstl.1793.0010]

2 **Bernard O**, Franchi-Abella S, Branchereau S, Pariente D, Gauthier F, Jacquemin E. Congenital portosystemic shunts in children: recognition, evaluation, and management. *Semin Liver Dis* 2012; **32**: 273-287 [PMID: 23397528 DOI: 10.1055/s-0032-1329896]

3 **Gitzelmann R**, Forster I, Willi UV. Hypergalactosaemia in a newborn: self-limiting intrahepatic portosystemic venous shunt. *Eur J Pediatr* 1997; **156**: 719-722 [PMID: 9296538 DOI: 10.1007/s004310050698]

4 **Stringer MD**. The clinical anatomy of congenital portosystemic venous shunts. *Clin Anat* 2008; **21**: 147-157 [PMID: 18161055 DOI: 10.1002/ca.20574]

5 **Morgan G**, Superina R. Congenital absence of the portal vein: two cases and a proposed classification system for portasystemic vascular anomalies. *J Pediatr Surg* 1994; **29**: 1239-1241 [PMID: 7807356 DOI: 10.1016/0022-3468(94)90812-5]

6 **Witters P**, Maleux G, George C, Delcroix M, Hoffman I, Gewillig M, Verslype C, Monbaliu D, Aerts R, Pirenne J, Van Steenbergen W, Nevens F, Fevery J, Cassiman D. Congenital veno-venous malformations of the liver: widely variable clinical presentations. *J Gastroenterol Hepatol* 2008; **23**: e390-e394 [PMID: 17868331 DOI: 10.1111/j.1440-1746.2007.05156.x]

7 **Sokollik C**, Bandsma RH, Gana JC, van den Heuvel M, Ling SC. Congenital portosystemic shunt: characterization of a multisystem disease. *J Pediatr Gastroenterol Nutr* 2013; **56**: 675-681 [PMID: 23412540 DOI: 10.1097/MPG.0b013e31828b3750]

8 **Baiges A**, Turon F, Simón-Talero M, Tasayco S, Bueno J, Zekrini K, Plessier A, Franchi-Abella S, Guerin F, Mukund A, Eapen CE, Goel A, Shyamkumar NK, Coenen S, De Gottardi A, Majumdar A, Onali S, Shukla A, Carrilho FJ, Nacif L, Primignani M, Tosetti G, La Mura V, Nevens F, Witters P, Tripathi D, Tellez L, Martínez J, Álvarez-Navascués C, Fraile López ML, Procopet B, Piscaglia F, de Koning B, Llop E, Romero-Cristobal M, Tjwa E, Monescillo-Francia A, Senzolo M, Perez-LaFuente M, Segarra A, Sarin SK, Hernández-Gea V, Patch D, Laleman W, Hartog H, Valla D, Genescà J, García-Pagán JC; REHEVASC, VALDIG an EASL consortium, Abernethy group. Congenital Extrahepatic Portosystemic Shunts (Abernethy Malformation): An International Observational Study. *Hepatology* 2020; **71**: 658-669 [PMID: 31211875 DOI: 10.1002/hep.30817]

9 **Jain V**, Sangdup T, Agarwala S, Bishoi AK, Chauhan S, Dhua A, Jana M, Kandasamy D, Malik R, Kothari SS, Patcharu R, Varshney A, Bhatnagar V. Abernethy malformation type 2: varied presentation, management and outcome. *J Pediatr Surg* 2019; **54**: 760-765 [PMID: 30262201 DOI: 10.1016/j.jpedsurg.2018.08.053]

10 **De Gaetano AM**, Rinaldi P, Barbaro B, Mirk P, Di Stasi C, Gui B, Maresca G, Bonomo L. Intrahepatic portosystemic venous shunts: Color Doppler sonography. *Abdom Imaging* 2007; **32**: 463-469 [PMID:

17334878 DOI: 10.1007/s00261-006-9068-1]
11 **Ponziani FR**, Faccia M, Zocco MA, Giannelli V, Pellicelli A, Ettorre GM, De Matthaeis N, Pizzolante F, De Gaetano AM, Riccardi L, Pompili M, Rapaccini GL. Congenital extrahepatic portosystemic shunt: description of four cases and review of the literature. *J Ultrasound* 2019; **22**: 349-358 [PMID: 30357760 DOI: 10.1007/s40477-018-0329-y]
12 **Grazioli L**, Alberti D, Olivetti L, Rigamonti W, Codazzi F, Matricardi L, Fugazzola C, Chiesa A. Congenital absence of portal vein with nodular regenerative hyperplasia of the liver. *Eur Radiol* 2000; **10**: 820-825 [PMID: 10823641 DOI: 10.1007/s003300051012]
13 **Hu GH**, Shen LG, Yang J, Mei JH, Zhu YF. Insight into congenital absence of the portal vein: is it rare? *World J Gastroenterol* 2008; **14**: 5969-5979 [PMID: 18932274 DOI: 10.3748/wjg.14.5969]
14 **Chocarro G**, Amesty MV, Encinas JL, Vilanova Sánchez A, Hernandez F, Andres AM, Gamez M, Tovar JA, Lopez Santamaria M. Congenital Portosystemic Shunts: Clinic Heterogeneity Requires an Individual Management of the Patient. *Eur J Pediatr Surg* 2016; **26**: 74-80 [PMID: 26528850 DOI: 10.1055/s-0035-1566097]
15 **Franchi-Abella S**, Branchereau S, Lambert V, Fabre M, Steimberg C, Losay J, Riou JY, Pariente D, Gauthier F, Jacquemin E, Bernard O. Complications of congenital portosystemic shunts in children: therapeutic options and outcomes. *J Pediatr Gastroenterol Nutr* 2010; **51**: 322-330 [PMID: 20601902 DOI: 10.1097/MPG.0b013e3181d9cb92]
16 **Knirsch W**, Benz DC, Bühr P, Quandt D, Weber R, Kellenberger C, Braegger CP, Kretschmar O. Catheter interventional treatment of congenital portosystemic venous shunts in childhood. *Catheter Cardiovasc Interv* 2016; **87**: 1281-1292 [PMID: 26715199 DOI: 10.1002/ccd.26362]
17 **Uchino T**, Matsuda I, Endo F. The long-term prognosis of congenital portosystemic venous shunt. *J Pediatr* 1999; **135**: 254-256 [PMID: 10431123 DOI: 10.1016/s0022-3476(99)70031-4]
18 **Kim MJ**, Ko JS, Seo JK, Yang HR, Chang JY, Kim GB, Cheon JE, Kim WS. Clinical features of congenital portosystemic shunt in children. *Eur J Pediatr* 2012; **171**: 395-400 [PMID: 21912894 DOI: 10.1007/s00431-011-1564-9]
19 **Howard ER**, Davenport M. Congenital extrahepatic portocaval shunts--the Abernethy malformation. *J Pediatr Surg* 1997; **32**: 494-497 [PMID: 9094026 DOI: 10.1016/s0022-3468(97)90614-x]
20 **Yazaki M**, Kaneko K, Tojo K, Miyazaki D, Shimojima Y, Ueda K, Ikeda S. An unusual case of Klippel-Trénaunay-Weber syndrome presenting with portosystemic encephalopathy. *Intern Med* 2008; **47**: 1621-1625 [PMID: 18797123 DOI: 10.2169/internalmedicine.47.1130]
21 **Ogul H**, Ozgokce M, Yalcin A, Taskin GA, Havan N, Kantarci M. Photoclinic. Co-existence of Abernethy malformation and Klippel-Trenaunay-Weber syndrome. *Arch Iran Med* 2014; **17**: 591-592 [PMID: 25065286]
22 **Yamagami T**, Yoshimatsu R, Matsumoto T, Terayama K, Nishiumra A, Maeda Y, Nishimura T. Successful embolization using interlocking detachable coils for a congenital extrahepatic portosystemic venous shunt in a child. *J Pediatr Surg* 2007; **42**: 1949-1952 [PMID: 18022455 DOI: 10.1016/j.jpedsurg.2007.08.048]
23 **Delle Chiaie L**, Neuberger P, Von Kalle T. Congenital intrahepatic portosystemic shunt: prenatal diagnosis and possible influence on fetal growth. *Ultrasound Obstet Gynecol* 2008; **32**: 233-235 [PMID: 18663772 DOI: 10.1002/uog.6116]
24 **Ono H**, Mawatari H, Mizoguchi N, Eguchi T, Sakura N. Clinical features and outcome of eight infants with intrahepatic porto-venous shunts detected in neonatal screening for galactosaemia. *Acta Paediatr* 1998; **87**: 631-634 [PMID: 9686654 DOI: 10.1080/080352598750014021]
25 **Rovira A**, Alonso J, Córdoba J. MR imaging findings in hepatic encephalopathy. *AJNR Am J Neuroradiol* 2008; **29**: 1612-1621 [PMID: 18583413 DOI: 10.3174/ajnr.A1139]
26 **Takama Y**, Nakamura T, Santo K, Yoneda A. Liver resection for a congenital intrahepatic portosystemic shunt in a child with hyperammonemia and hypermanganesemia: a case report. *Surg Case Rep* 2020; **6**: 73 [PMID: 32303849 DOI: 10.1186/s40792-020-00838-5]
27 **Ohno T**, Muneuchi J, Ihara K, Yuge T, Kanaya Y, Yamaki S, Hara T. Pulmonary hypertension in patients with congenital portosystemic venous shunt: a previously unrecognized association. *Pediatrics* 2008; **121**: e892-e899 [PMID: 18362102 DOI: 10.1542/peds.2006-3411]
28 **Weigert A**, Bierwolf J, Reutter H, Gembruch U, Woelfle J, Ganschow R, Mueller A. Congenital intrahepatic portocaval shunts and hypoglycemia due to secondary hyperinsulinism: a case report and review of the literature. *J Med Case Rep* 2018; **12**: 336 [PMID: 30415638 DOI: 10.1186/s13256-018-1881-y]
29 **Benedict M**, Rodriguez-Davalos M, Emre S, Walther Z, Morotti R. Congenital Extrahepatic Portosystemic Shunt (Abernethy Malformation Type Ib) With Associated Hepatocellular Carcinoma: Case Report and Literature Review. *Pediatr Dev Pathol* 2017; **20**: 354-362 [PMID: 28727971 DOI: 10.1177/1093526616686458]
30 **Kawano S**, Hasegawa S, Urushihara N, Okazaki T, Yoshida A, Kusafuka J, Mimaya J, Horikoshi Y, Aoki K, Hamazaki M. Hepatoblastoma with congenital absence of the portal vein - a case report. *Eur J Pediatr Surg* 2007; **17**: 292-294 [PMID: 17806031 DOI: 10.1055/s-2007-965448]
31 **Gong Y**, Zhu H, Chen J, Chen Q, Ji M, Pa M, Zheng S, Qiao Z. Congenital portosystemic shunts with and without gastrointestinal bleeding - case series. *Pediatr Radiol* 2015; **45**: 1964-1971 [PMID: 26209117 DOI: 10.1007/s00247-015-3417-6]
32 **Kobayashi N**, Niwa T, Kirikoshi H, Fujita K, Yoneda M, Saito S, Nakajima A. Clinical classification of congenital extrahepatic portosystemic shunts. *Hepatol Res* 2010; **40**: 585-593 [PMID: 20618456 DOI: 10.1111/j.1872-034X.2010.00667.x]
33 **Alomari AI**, Chaudry G, Fox VL, Fishman SJ, Buchmiller TL. Atypical manifestation of patent ductus venosus in a child: intervening against a paradoxical presentation. *J Vasc Interv Radiol* 2009; **20**: 537-542 [PMID: 19250842 DOI: 10.1016/j.jvir.2009.01.002]
34 **van der Merwe SW**, van den Bogaerde JB, Goosen C, Maree FF, Milner RJ, Schnitzler CM, Biscardi A, Mesquita JM, Engelbrecht G, Kahn D, Fevery J. Hepatic osteodystrophy in rats results mainly from portasystemic shunting. *Gut* 2003; **52**: 580-585 [PMID: 12631673 DOI: 10.1136/gut.52.4.580]
35 **Fu L**, Wang Q, Wu J, Guo Y, Huang M, Liu T, Chen Q, Li F. Congenital extrahepatic portosystemic shunt: an underdiagnosed but treatable cause of hepatopulmonary syndrome. *Eur J Pediatr* 2016; **175**: 195-201

[PMID: 26311567 DOI: 10.1007/s00431-015-2623-4]
36 **Xiang W**, Wang H, Si ZZ, Chen GS, Wang GW, Li T. Type I congenital extrahepatic portosystemic shunt treated by orthotopic liver transplantation: A case report. *World J Clin Cases* 2019; **7**: 903-907 [PMID: 31024963 DOI: 10.12998/wjcc.v7.i7.903]
37 **Elias N**, Scirica CV, Hertl M. Liver transplantation for the Abernathy malformation. *N Engl J Med* 2008; **358**: 858 [PMID: 18287614 DOI: 10.1056/NEJMc0707762]

Published by **Baishideng Publishing Group Inc**
7041 Koll Center Parkway, Suite 160, Pleasanton, CA 94566, USA
Telephone: +1-925-3991568
E-mail: bpgoffice@wjgnet.com
Help Desk: https://www.f6publishing.com/helpdesk
https://www.wjgnet.com