

World Journal of *Surgical Procedures*

World J Surg Proced 2017 March 28; 7(1): 1-5



Editorial Board

2016-2019

The *World Journal of Surgical Procedures* Editorial Board consists of 262 members, representing a team of worldwide experts in surgical procedures. They are from 36 countries, including Australia (9), Austria (2), Belgium (1), Brazil (4), Canada (3), China (20), Egypt (2), France (1), Germany (9), Greece (9), Hungary (1), India (5), Iran (3), Ireland (1), Israel (6), Italy (29), Japan (34), Lithuania (1), Mexico (1), Netherlands (2), New Zealand (1), Nigeria (1), Norway (1), Pakistan (1), Poland (1), Romania (2), Saudi Arabia (1), Singapore (1), South Korea (7), Spain (11), Switzerland (5), Thailand (1), Turkey (7), United Kingdom (11), and United States (68).

EDITORS-IN-CHIEF

Timothy M Pawlik, *Baltimore*
Dinesh Vyas, *Lansing*
Feng Wu, *Oxford*

GUEST EDITORIAL BOARD MEMBERS

Da-Tian Bau, *Taichung*
Chong-Chi Chiu, *Tainan*
Chiung-Nien Juan, *Taipei*
Po-Jen Ko, *Taoyuan Hsien*
KW Lee, *Ping Tung*
Chinsu Liu, *Taipei*
Jen-Kou Lin, *Taipei*
Sheng-Lei Yan, *Changhua County*

MEMBERS OF THE EDITORIAL BOARD



Australia

Savio Barreto, *Adelaide*
Adam Bryant, *Parkville*
Terence C Chua, *Kogarah*
G Darling, *Adelaide*
C Augusto Gonzalvo, *Victoria*
Neil D Merrett, *Penrith*
DL L Morris, *Sydney*
Carlo Pulitanò, *Sydney*
Zhonghua Sun, *Perth*



Austria

Herwig R Cerwenka, *Graz*
Rupert Menapace, *Vienna*



Belgium

Yicheng Ni, *Leuven*



Brazil

Cesar Augusto Arrais, *Sao Paulo*
Joao Luiz Moreira Coutinho Azevedo, *Sao Paulo*
Djalma José Fagundes, *Sao Paulo*
Hermes Pretel, *Sao Paulo*



Canada

Line Jacques, *Montreal*
Tatsuya Kin, *Alberta*
Michele Molinari, *Halifax*



China

Yong An, *Chongqing*
Andrew Burd, *Hong Kong*
Deliang Fu, *Shanghai*
Di Ge, *Shanghai*
Lan Huang, *Chongqing*
Yan Li, *Wuhan*
Simon SM Ng, *Hong Kong*
Qiang Wang, *Shanghai*
Yong-ming Yao, *Beijing*
Anthony Ping-Chuen Yim, *Hong Kong*
Jiang-Fan Zhu, *Shanghai*
Dan Zhu, *Wuhan*



Egypt

Samer S Bessa, *Alexandria*
Ahmed E Lasheen, *Sharkia*



France

Michel Henry, *Hyderabad*



Germany

Hans Beger, *Ulm*
Uta Dahmen, *Jena*
Alexander E Handschin, *Braunschweig*
Uwe Klinge, *Aachen*
Philipp Kobbe, *Aachen*
Matthias W Laschke, *Homburg*
M Javad Mirzayan, *Hannover*
Robert Rosenberg, *Munich*
Wolfgang Vanscheidt, *Freiburg*



Greece

Elco de Bree, *Heraklion*
Athanasios D Giannoukas, *Larissa*
Fotis Kalfarentzos, *Rio*
Dimitris Karnabatidis, *Patras*
Dimitrios Karnabatidis, *Patras*
Peppa Melpomeni, *Haidari*
Aristeidis Stavroulopoulos, *Kallithea*
Demosthenes E Ziogas, *Ioannina*
Odysseas Zoras, *Heraklion*



Hungary

Peter Horvath, *Pécs*



India

Nilakantan Ananthkrishnan, *Pondicherry*
Rakesh Kumar, *Bhopal*
Suguna Lonchin, *Tamilnadu*
Chinmay K Panda, *Kolkata*
Nihal Thomas, *Vellore*

**Iran**

Mehrdad Mohammadpour, *Tehran*
 Seyed R Mousavi, *Tehran*
 Mohammad T Rajabi, *South Kargar*

**Ireland**

Desmond Winter, *Dublin*

**Israel**

Nimer Assy, *Safed*
 Haim Gutman, *Tikva*
 Yoav Mintz, *Jerusalem*
 Solly Mizrahi, *Beer Sheva*
 Nir Wasserberg, *Petach Tiqua*
 Oded Zmora, *Tel Hashomer*

**Italy**

Ferdinando Agresta, *Adria*
 Luigi Ambra, *La Spezia*
 Franco Bassetto, *Padova*
 Gabrio Bassotti, *San Sisto*
 F Boccardo, *Genoa*
 Paolo Boscolo-Rizzo, *Treviso*
 Giuseppe Brisinda, *Rome*
 Fausto Catena, *Bologna*
 Massimo Chello, *Rome*
 Alessandro Franchini, *Florence*
 Giuseppe Galloro, *Naples*
 Massimo Gerosa, *Verona*
 Francesco Greco, *Bergamo*
 Roberto Iezzi, *Rome*
 Makoto Kume, *Gifu*
 Fabrizio Luca, *Milano*
 Simone Mocellin, *Padua*
 Giacomo Pata, *Brescia*
 Marcello Picchio, *Latina*
 Giuseppe Piccinni, *Bari*
 M Raffaelli, *Rome*
 Matteo Ravaioli, *Bologna*
 Vincenzo Russo, *Naples*
 Raffaele Russo, *Naples*
 Pierpaolo Sileri, *Rome*
 Luciano Solaini, *Ravenna*
 Pietro Valdastrì, *Pontedera*
 Luca Vigano, *Torino*
 Luigi Zorcolo, *Cagliari*

**Japan**

Hiroki Akamatsu, *Osaka*
 Mitsuhiro Asakuma, *Osaka*
 Tatsuto Ashizawa, *Tokyo*
 Bishara Atiyeh, *Beirut*
 Hideo Baba, *Kumamoto*
 A Cho, *Tokyo*
 Shotaro Enomoto, *Wakayama*
 Satoshi Hagiwara, *Oita*
 Yoshiki Hirooka, *Aichi*
 Motohiro Imano, *Osaka*
 Yasuhiro Ito, *Kobe*
 Koichi Iwatsuki, *Osaka*
 K Kamada, *Hokkaido*

Hirotohi Kobayashi, *Tokyo*
 Walid El Moghazy, *Kyoto*
 Daisuke Morioka, *Yokohama*
 Toshitaka Nagao, *Tokyo*
 Nobuhiro Ohkohchi, *Tsukuba*
 Kensaku Sanefuji, *Fukuoka*
 Norio Shiraishi, *Oita*
 Yasuhiko Sugawara, *Tokyo*
 Nobumi Tagaya, *Tochigi*
 Sonshin Takao, *Kagoshima*
 Hiroshi Takeyama, *Tokyo*
 Shinji Tanaka, *Hiroshima*
 Koji Tanaka, *Osaka*
 Kuniya Tanaka, *Yokohama*
 Akira Tsunoda, *Chiba*
 Dai Uematsu, *Nagano*
 Shinichi Ueno, *Kagoshima*
 Toshiaki Watanabe, *Tokyo*
 Atsushi Watanabe, *Sapporo*
 Yo-ichi Yamashita, *Hiroshima*
 Seiichi Yoshida, *Niigata*

**Lithuania**

Aleksandras Antusevas, *Kaunas*

**Mexico**

José Cervantes, *Guadalajara*

**Netherlands**

Paulus J van Diest, *Utrecht*
 Frans L Moll, *Utrecht*

**New Zealand**

Saleh Abbas, *Auckland*

**Nigeria**

Christopher Bode, *Lagos*

**Norway**

Michael Brauckhoff, *Bergen*

**Pakistan**

Drshamim M Shamim, *Karachi*

**Poland**

Lek Anna, *Katowice*

**Romania**

Mihai Ciocirlan, *Bucharest*

Adrian Iancu, *Cluj Napoca*

**Saudi Arabia**

Abdul-Wahed N Meshikhes, *Dammam*

**Singapore**

Zhi-Wei Huang, *Singapore*

**South Korea**

Sung H Choi, *Seoul*
 Young S Chung, *Seoul*
 Dong-Ik Kim, *Seoul*
 Choon Hyuck David Kwon, *Seoul*
 Ho-Yeon Lee, *Gangnam-gu*
 Sung-Soo Park, *Seoul*
 In Ja Park, *Seoul*

**Spain**

Maria-Angeles Aller, *Madrid*
 Aniceto Baltasar, *Alcoy*
 Manuel Giner, *Madrid*
 Fernando Hernanz, *Santander*
 Bernardo Hontanilla, *Cordovilla*
 Vaquero Jesus, *Madrid*
 Alvaro Jimenez, *Madrid*
 David Martinez-Ramos, *Castellon de La Plana*
 Juan Salas, *Lleida*
 Eduardo Targarona, *Barcelona*
 Carmen Peralta Uroz, *Barcelona*

**Switzerland**

Marco Buter, *Zürich*
 Pascal Gervaz, *Geneva*
 Merlin Guggenhei, *Mannedorf*
 Jurg Metzger, *Lucerne*
 Cafarotti Stefano, *Bellinzona*

**Thailand**

Varut Lohsiriwat, *Bangkok*

**Turkey**

Ali D Bozdog, *Aydin*
 Ugur Boylu, *Istanbul*
 Mehmet Fatih Can, *Ankara*
 Suleyman Kaplan, *Samsun*
 Cuneyt Narin, *Konya*
 Cem Parsak, *Adana*
 Taner Tanriverdi, *Fatih-Istanbul*

**United Kingdom**

Sanjoy Basu, *Ashford*
 Justin Davies, *Cambridge*
 Gianpiero Gravante, *Leicester*

Sanjeev Kanoria, *London*
James Kirkby-Bott, *London*
A Koulaouzidis, *Edinburgh*
Kefah Mokbel, *London*
Muthukumarang Rangarajan, *Grand Cayman*
Miael H Sodergren, *London*
Emmanouil Zacharakis, *London*



United States

Amir Abolhoda, *Orange*
Mohammad Al-Haddad, *Indianapolis*
Mario Ammirati, *Ohio*
Gintaras Antanavicius, *Warminster*
Mustafa K Baskaya, *Madison*
Ronald Chamberlain, *Livingston*
Yi-Jen Chen, *Duarte*
Gregory S Cherr, *Buffalo*
Gilwoo Choi, *Redwood*
Danny Chu, *Pittsburgh*
Gaetano Ciancio, *Miami*
John V Conte, *Maryland*
Daniel R Cottam, *Pittsburgh*
Ruy Cruz, *Pittsburgh*

Juan C Duchesne, *New Orleans*
Andrew J Duffy, *New Haven*
Konstantinos P Economopoulos, *Boston*
S H Emre, *New Haven*
Thomas Joseph Fahey, *New York*
John F Gibbs, *Buffalo*
Eric Grossman, *Chicago*
Walter A Hall, *Syracuse*
Jeffrey B Halldorson, *Seattle*
Michael R Hamblin, *Boston*
Steven N Hochwald, *Gainesville*
John Hovanesian, *Los Angeles*
Sergio Huerta, *Dallas*
Alexander Iribarne, *New York*
David Kahn, *Palo Alto*
Kanav Kahol, *Arizona*
Lewis Kaplan, *New Haven*
Randeep S Kashyap, *Rochester*
Melina R Kibbe, *Chicago*
Amosy M'Koma, *Nashville*
Rong-pei Lan, *San Antonio*
I. Michael Leitman, *New York*
Xiao-Long Li, *Houston*
Julian E Losanoff, *Las Vegas*
Joseph Keith Melancon, *Washington*
Kresimira Milas, *Cleveland*

Mark Morasch, *Billings*
Majid Moshirfar, *Salt Lake*
Kamal Nagpal, *Riveredge*
Pradeep K Narotam, *Terre Haute*
Scott Owens, *Ann Arbor*
Raymond M Planinsic, *Pittsburgh*
Guillermo Portillo-Ramila, *Texas*
Thanjavur S Ravikumar, *Danville*
Jonathan C Samuel, *Chapel Hill*
Mark J Seamon, *Camden*
Jatin P Shah, *York Avenue*
Herrick Siegel, *Birmingham*
Brad Snyder, *Houston*
Allan Stewart, *New York*
Rakesh M Suri, *Rochester*
Bill Tawil, *Los Angeles*
Swee H Teh, *South San Francisco*
James F Thornton, *Dallas*
R. Shane Tubbs, *Birmingham*
Andreas G Tzakis, *Miami*
JiPing Wang, *Boston*
Hongzhi Xu, *Boston*
Hua Yang, *Ann Arbor*
Rasa Zarnegar, *San Francisco*
Zhi Zhong, *Charleston*
Wei Zhou, *Stanford*

CASE REPORT

- 1 Surgical treatment of a rare complication after endoscopic stent placement for anastomotic leakage after esophageal resection

Klinkert M, de Jong MC, Sosef MN, van Nunen AB, Belgers HJ

ABOUT COVER

Editorial Board Member of *World Journal of Surgical Procedures*, Dr. Ferdinando Agresta, MD, Director, General Surgery, ULSS19 del Veneto, 45011 Adria (RO), Italy

AIM AND SCOPE

World Journal of Surgical Procedures (World J Surg Proced, WJSP, online ISSN 2219-2832, DOI: 10.5412) is a peer-reviewed open access academic journal that aims to guide clinical practice and improve diagnostic and therapeutic skills of clinicians.

WJSP covers topics concerning ambulatory surgical procedures, cardiovascular surgical procedures, digestive system surgical procedures, endocrine surgical procedures, obstetric surgical procedures, neurosurgical procedures, ophthalmologic surgical procedures, oral surgical procedures, orthopedic procedures, otorhinolaryngologic surgical procedures, reconstructive surgical procedures, thoracic surgical procedures, urogenital surgical procedures, computer-assisted surgical procedures, elective surgical procedures, and minimally invasive, surgical procedures, specifically including ablation techniques, anastomosis, assisted circulation, bariatric surgery, biopsy, body modification, non-therapeutic, curettage, debridement, decompression, deep brain stimulation, device removal, dissection, drainage, electrosurgery, extracorporeal circulation, hemostasis, intraoperative care, laparotomy, ligation, lymph node excision, mastectomy, microsurgery, monitoring, intraoperative, ostomy, paracentesis, pelvic exenteration, perioperative care, postoperative care, preoperative care, prosthesis implantation, reoperation, second-look surgery, splenectomy, suture techniques, symphysiotomy, tissue and organ harvesting, transplantation, diagnostic imaging, and endoscopy.

We encourage authors to submit their manuscripts to *WJSP*. We will give priority to manuscripts that are supported by major national and international foundations and those that are of great basic and clinical significance.

INDEXING/ABSTRACTING

World Journal of Surgical Procedures is now indexed in China National Knowledge Infrastructure (CNKI).

FLYLEAF

I-III Editorial Board

EDITORS FOR THIS ISSUE

Responsible Assistant Editor: *Xiang Li*
Responsible Electronic Editor: *Ya-Jing Lu*
Proofing Editor-in-Chief: *Lian-Sheng Ma*

Responsible Science Editor: *Fang-Fang Ji*
Proofing Editorial Office Director: *Xiu-Xiu Song*

NAME OF JOURNAL
World Journal of Surgical Procedures

ISSN
ISSN 2219-2832 (online)

LAUNCH DATE
December 29, 2011

FREQUENCY
Four-monthly

EDITORS-IN-CHIEF
Timothy M Pawlik, MD, Director, Professor, Department of Surgery, Johns Hopkins University, School of Medical, Baltimore, MD 21287, United States

Dinesh Vyas, MD, Adjunct Professor, Associate Professor, Director, Department of Surgery, Institute of International Health MS Surgery Clerkship, College of Human Medicine, Michigan State University, Lansing, MI 48912, United States

Feng Wu, MD, PhD, Professor, Nuffield Department of Surgical Sciences, University of Oxford, Level 6, John Radcliffe Hospital, Headley Way, Oxford, OX3 9DU, United Kingdom

EDITORIAL BOARD MEMBERS
All editorial board members resources online at <http://www.wjgnet.com/2219-2832/editorialboard.htm>

EDITORIAL OFFICE
 Fang-Fang Ji, Director
World Journal of Surgical Procedures
 Baishideng Publishing Group Inc
 8226 Regency Drive, Pleasanton, CA 94588, USA
 Telephone: +1-925-2238242
 Fax: +1-925-2238243
 E-mail: editorialoffice@wjgnet.com
 Help Desk: <http://www.f6publishing.com/helpdesk>
<http://www.wjgnet.com>

PUBLISHER
 Baishideng Publishing Group Inc
 8226 Regency Drive,
 Pleasanton, CA 94588, USA
 Telephone: +1-925-2238242
 Fax: +1-925-2238243
 E-mail: bpgoffice@wjgnet.com
 Help Desk: <http://www.f6publishing.com/helpdesk>
<http://www.wjgnet.com>

PUBLICATION DATE
March 28, 2017

COPYRIGHT
 © 2017 Baishideng Publishing Group Inc. Articles published by this Open Access journal are distributed under the terms of the Creative Commons Attribution Non-commercial License, which permits use, distribution, and reproduction in any medium, provided the original work is properly cited, the use is non commercial and is otherwise in compliance with the license.

SPECIAL STATEMENT
 All articles published in journals owned by the Baishideng Publishing Group (BPG) represent the views and opinions of their authors, and not the views, opinions or policies of the BPG, except where otherwise explicitly indicated.

INSTRUCTIONS TO AUTHORS
<http://www.wjgnet.com/bpg/gerinfo/204>

ONLINE SUBMISSION
<http://www.f6publishing.com>

Surgical treatment of a rare complication after endoscopic stent placement for anastomotic leakage after esophageal resection

Marjan Klinkert, Mechteld C de Jong, Meindert N Sosef, Annick B van Nunen, Henricus J Belgers

Marjan Klinkert, Mechteld C de Jong, Meindert N Sosef, Henricus J Belgers, Department of Surgery, Zuyderland Medical Centre, 6419 PC Heerlen, The Netherlands

Annick B van Nunen, Department of Gastroenterology, Zuyderland Medical Centre, 6419 PC Heerlen, The Netherlands

Author contributions: Klinkert M and de Jong MC designed and wrote the paper; Sosef MN, van Nunen AB and Belgers HJ designed- and performed the procedure.

Institutional review board statement: This case report was reviewed by our local IRB and according to local guidelines no official review was necessary.

Informed consent statement: The patient involved in this study gave her written informed consent authorizing use and disclosure of her protected health information.

Conflict-of-interest statement: None of the above participants declare to have conflict-of-interests.

Open-Access: This article is an open-access article which was selected by an in-house editor and fully peer-reviewed by external reviewers. It is distributed in accordance with the Creative Commons Attribution Non Commercial (CC BY-NC 4.0) license, which permits others to distribute, remix, adapt, build upon this work non-commercially, and license their derivative works on different terms, provided the original work is properly cited and the use is non-commercial. See: <http://creativecommons.org/licenses/by-nc/4.0/>

Manuscript source: Unsolicited manuscript

Correspondence to: Marjan Klinkert, MD, Department of Surgery, Zuyderland Medical Centre, Henri Dunantstraat 5, 6419 PC Heerlen, The Netherlands. m.klinkert@zuyderland.nl
Telephone: +31-455-766666
Fax: +31-455-767625

Received: February 3, 2017

Peer-review started: February 7, 2017

First decision: March 7, 2017

Revised: March 15, 2017

Accepted: March 20, 2017

Article in press: March 21, 2017

Published online: March 28, 2017

Abstract

The best approach to achieve cure in esophageal cancer is a combination of chemo-radiation and surgery. However, complications occur in half of patients. The current report, reports a rare but severe complication: Complete obstruction of the esophagus, induced by preoperative chemo-radiation therapy. Normally, strictures are treated by repeated dilatations, however, in case of complete obstruction, the perforation rate of standard blind anterograde wire access and dilation is severely increased. In order to minimize the risk of perforations, the rendezvous technique was introduced. This technique involves an anterograde approach in combination with a retrograde approach in order to open and dilate the esophagus. While technical success rates between 83% and 100% have been reported in literature, data on clinical outcomes are scarcer. The limited amount of studies available claim that success was achieved in almost half of patients. The patient in our case currently has an oral diet without restrictions and rates his quality of life with a VAS-score ten out of ten.

Key words: Esophageal cancer; Esophageal obstruction; Rendezvous procedure; Anterograde dilatation; Combined anterograde-retrograde endoscopic dilatation

© **The Author(s) 2017.** Published by Baishideng Publishing Group Inc. All rights reserved.

Core tip: A rare but severe complication of chemo-radiation of the esophagus, in case of esophageal cancer, is a complete esophageal obstruction. Blind anterograde

wire access and dilatation leads to a higher risk of perforation, due to lack of visualization and a disrupted anatomy. For this reason the rendezvous technique was introduced, which involves an antegrade approach in combination with a retrograde approach in order to open and dilate the esophagus.

Klinkert M, de Jong MC, Sosef MN, van Nunen AB, Belgers HJ. Surgical treatment of a rare complication after endoscopic stent placement for anastomotic leakage after esophageal resection. *World J Surg Proced* 2017; 7(1): 1-5 Available from: URL: <http://www.wjgnet.com/2219-2832/full/v7/i1/1.htm> DOI: <http://dx.doi.org/10.5412/wjsp.v7.i1.1>

INTRODUCTION

Esophageal carcinoma is the eighth most common cancer worldwide^[1]. Moreover, it is the sixth most common cause of cancer-related death^[1,2], with a 5-year-overall survival of only 18.4% for all patients following diagnosis^[3]. In case curative intent surgery is performed, 5-year-overall survival increases to 34%; moreover when surgery is performed subsequently to a neoadjuvant chemo-radiation regimen, overall survival rates increase to 47%^[4].

The best approach to achieve cure is a combination of chemo-radiation and surgery^[5,6], as the CROSS-trial demonstrated that neoadjuvant chemo-radiotherapy (nCRT) improves survival among patients with potentially curable esophageal cancer^[4]. Moreover, this increase in survival is achieved without a concomitant increase in postoperative morbidity or mortality^[7].

Nevertheless, a high complication rate after esophagectomy is reported, as complications occur after more than half of procedures - open or minimally invasive^[8]. While it is generally thought that the complication risk is lower in laparoscopy, due to diminished surgical trauma^[5,9], the incidence of postoperative morbidity remains high with incidences ranging from 17% up to 74%^[8,10,11]. Most common, severe complications include anastomotic leakage, conduit necrosis, chyle leakage, vocal cord injury or palsy and death^[8]. Importantly, these complications are known to directly impact other outcomes and cause prolonged hospital stay and readmission, early cancer recurrence and diminished overall survival and also a lower quality of life^[8,12-14]. More rare complications have also been described such as herniation of abdominal structures through the diaphragm and - even more rare - complete obstruction of the esophagus partly due to the preoperative chemo-radiation therapy. Postoperative mortality rates are reported in 7% to 9% of cases^[8,9].

CASE REPORT

A 64-year-old man with a mid-esophageal squamous cell carcinoma (eT3N3M0) underwent a minimal invasive

transthoracic esophagectomy, following neoadjuvant treatment with chemo-radiation - CROSS scheme.

Differential diagnosis, investigations and treatment

On postoperative day three (POD3), an elevated white blood count was noticed and therefore a chest- and abdominal computed axial tomography (CAT)-scan was performed, which showed suspicion of a pneumonia for which antibiotic treatment was started. However, 5 d later (POD8) a repeated CAT-scan was performed as the patient showed signs of clinical deterioration. This CAT-scan demonstrated free air and fluid around the anastomosis suspicious for anastomotic leakage. Upper endoscopy showed superficial circumferential ischemia of the top of the stomach-tube over a length of 7 cm, while no visible anastomotic leakage was seen. The ischemic area was fully shielded by a partially covered-stent (SEMS) (Ultraflex[®]). A planned re-endoscopy after 14 d, showed transmural ischemic ulceration over a length of at least 7 cm (Figure 1A). Initially therefore, the decision was taken to disconnect the anastomosis and to thereby create an esophagostomy, however during the re-laparoscopy this was found to be impossible due to the amount of adhesions. Therefore, a new partially covered SEMS (Ultraflex[®]) was endoscopically placed. The subsequent SEMS replacement endoscopy after 4 wk showed extensive tissue ingrowth into the stent, which was subsequently removed and replaced by a new partially covered stent of the same type. It was noted that the defect due to ischemia was much smaller than previously (Figure 1B). The removal of this SEMS, one month later, was complicated by a prolapse of esophageal mucosal tissue obstructing the upper esophageal entrance completely. We managed to insert a guidewire and place a fully covered SEMS (Hanaro[®]). Repeat endoscopy the following day, unfortunately showed it was impossible to pass the UES with either the gastroscope or fiber laryngoscope. A subsequently performed CAT-scan confirmed this finding, as it showed a complete obstruction of the upper esophagus over a distance of approximately 4-5 cm (Figure 2). A procedure under general anesthesia was planned. In order to pass this obstruction, the gastroenterologist struggled to identify the anatomical oral route, while the esophageal orifice was not found. Simultaneously, the surgeon performed a laparoscopy and entered the gastric conduit in a retrograde fashion. By moving proximally through the stent, the obstructed proximal esophagus was reached. Step by step, the surgeon, using a biopsy forceps, dissected upwards. At the level of the oral orifice, the oral mucosa could be perforated using a needle knife under light transillumination of the gastroscope. After this, the guide wire could pass through the obstruction (a so-called rendez-vous procedure). Following correct placement of the guidewire, a dilatation was performed and a new fully covered SEMS (Hanaro[®]) was placed to keep the orifice open. After the covered SEMS (Hanaro[®]) was removed, no defects in the mucosa underneath

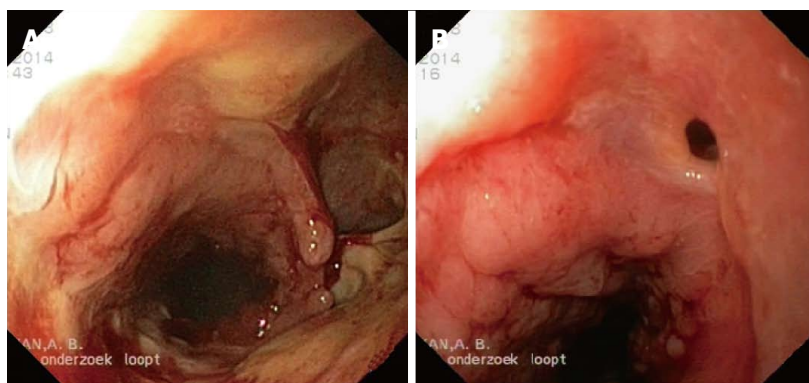


Figure 1 Endoscopy. A: Large transmurular ischemic ulcer at the proximal border of the stomach-tube for which an Ultraflex® stent was placed; B: The first stent replacement showed that the defect due to ischemia was much smaller than previously.

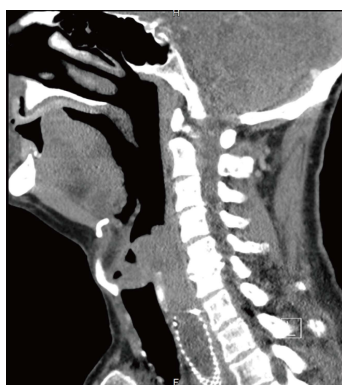

Figure 2 Computed tomography-scan: Complete obstruction of the esophagus.

it were seen.

Outcome and follow-up

Eleven dilatation sessions later, no defects in the mucosa were seen and the stent was removed. After this, our patients' ability of oral ingestion was fully restored. The patient is currently no longer dependent on any tube-feeding and rates his quality of life with a VAS-score 10 out of 10.

DISCUSSION

Strictures of the proximal esophagus have been reported in 3% to 4% of patients with head and neck cancer who underwent treatment with radiation therapy^[15]. These strictures are usually treated by repeated endoscopic dilatations, however complications of perforation or fistulae are described^[15]. Complete obstruction in the proximal esophagus is a rare condition and can occur as a result of radiotherapy, gastro-esophageal reflux disease or caustic injury^[16]. In our case, the hypothesis is that the traumatic stent removal, in combination with the neoadjuvant (chemo)radiation therapy, caused the (complete) obstruction of the esophagus.

In case of complete obstruction, the perforation rate of the standard blind anterograde wire access and subsequent dilatation is increased, due the suboptimal visualization and distorted anatomy^[15]. In order to minimize the incidence of this particular complication, the rendezvous technique was

proposed, which was first described in 1998 by van Twisk *et al.*^[17]. This technique involves an anterograde approach, in combination with a retrograde approach, in order to open and dilate the esophagus. This technique is therefore also called combined anterograde-retrograde endoscopic dilatation, abbreviated to CARD^[16].

The aim of this procedure is to gain access through the complete obstructed esophagus. Technical success rates between 83% and 100% have been reported in literature^[15,16,18-20], exemplifying its technical feasibility. The advantage of this procedure lays in the fact that it is safer than the blind anterograde approach, thereby theoretically reducing the risk of a perforation^[15,16]. In addition, in case a mucosal puncture does occur, during the retrograde maneuver this perforation occurs away from the mediastinum, thereby reducing the risk for potential complications of this puncture^[15].

However perforations after the rendez-vous procedure have been described, as Maple *et al.*^[15] reported two micro-perforations. These perforations, which were probably caused by the guide wire, resolved without (surgical) therapy. Conceivably, these micro-perforations occur more frequently than recognized, as they probably lack clinical relevance in the majority of cases^[15].

Apart from the guidewire as the source of perforation, the type of scope can also be of influence of risk of perforation. While Bertolini *et al.*^[16] only used a thin, nasal gastroscope and reported one single case of mediastinal emphysema, Goguen *et al.*^[18] used an adult gastroscope and reported a pneumomediastinum in 18% of patients, an esophageal perforation in 5% of patients and a gastrostomy tube site problem in 16% of patients.

While the technical feasibility of the rendez-vous approach has been described by different authors, the actual purpose of the rendez-vous approach, *i.e.*, to restore the ability of oral ingestion, is largely overlooked in series published thus far. Very scarce data have been published on the clinical side of this topic. This is a difficult parameter to report on, while there are very little disease-specific measures for this patient-group, as only swallowing, nutritional status and quality of life are acknowledged outcomes. In an attempt to specify nutritional intake following the rendez-vous procedure, Bertolini *et al.*^[16] decided to use the Functional Oral Intake Scale (FOIS), a scale specifically designed to document

changes in functional oral intake in stroke patients. In their case-series, they reported that half of patients remained PEG-tube independent, while overall there was a relative improvement in swallowing (FOIS level ≥ 3) and consequently an improved quality of life^[16]. The largest case-series published thus far is by Grooteman *et al.*^[21], they reported that 44% of their 25 patients were able to eat at least soft food. The other 56% of patients remained PEG-tube dependent (FOIS level < 3).

In summary, esophageal stricture is a serious long-term complication of (chemo)radiation therapy of the head and neck area. While currently fairly uncommon, more patients may suffer of strictures in coming years. With the current CROSS-scheme for esophageal carcinoma, which involves chemo-radiation therapy, the incidence of this complication might rise. Moreover, because this particular neoadjuvant regimen has prolonged the overall survival for this group of patients, it does not only enlarge the possible pool of patients at danger, but also prolongs the period during which the risk of developing an esophageal stricture exists. Although, anterograde dilatation is the most common approach, it is accompanied by a relative high risk of complications and cannot always be performed - like in our current case. Therefore, the rendez-vous technique is a good alternative for this group of patients. Data have shown that the rendez-vous procedure is a technically feasible and effective approach for patients with a complete obstruction of their esophagus. Data on clinical outcomes are scarcer; although the limited studies available claim that success was achieved in almost half of patients. Our patient currently has an oral diet without restrictions (FOIS level 7) and rates his quality of life with a VAS-score ten out of ten.

COMMENTS

Case characteristics

A 64-year-old man with a mid-esophageal carcinoma underwent a minimal invasive transthoracic esophagectomy (following neoadjuvant chemo-radiation) which was complicated by an anastomotic leakage and he developed a total obstruction of his esophagus due traumatic stent replacements.

Clinical diagnosis

On postoperative day three, an elevated white blood count was noticed, which led to performance of a subsequent computed axial tomography (CAT)-scan. Antibiotics were started by a suspicion on a pneumonia. Five days later, due clinical deterioration, a new CAT-scan was performed, which showed a suspicion for an anastomotic leakage.

Differential diagnosis

Pneumonia, anastomotic leakage, total obstruction of the esophagus.

Laboratory diagnosis

Elevated white blood count.

Imaging diagnosis

A chest- and abdominal-CAT scan showed signs of an anastomotic leakage, which was confirmed by an upper endoscopy - a stent was placed and after a few (traumatic) stent replacements, a re-placement endoscopy failed to pass the UES, a CAT-scan showed a total obstruction of the esophagus.

Treatment

A rendez-vous technique was used to dilate the complete obstructed esophagus.

Related reports

Complete obstruction in the proximal esophagus is a rare condition and can occur as a result of radiotherapy, gastro-esophageal reflux disease or caustic injury. Strictures are usually treated by repeated endoscopic dilatation, however in case of complete obstruction the perforation rate of standard blind anterograde wire access and subsequent dilation is increased, therefore the rendez-vous technique is developed.

Term explanation

Rendez-vous technique is an anterograde- and retrograde approach, in order to open and dilate the esophagus.

Experiences and lessons

In this case report, the authors showed that chemo-radiation (with or without the combination of a traumatic stent replacements) caused a complete obstruction of the esophagus. The incidence of this complication might rise due the neoadjuvant chemo-radiation treatment and the fact that this regime prolonged the overall survival and the period during the risk of developing strictures, of patients suffering of esophageal cancer.

Peer-review

This is a very interesting case report.

REFERENCES

- 1 **Herszényi L**, Tulassay Z. Epidemiology of gastrointestinal and liver tumors. *Eur Rev Med Pharmacol Sci* 2010; **14**: 249-258 [PMID: 20496531]
- 2 **Jemal A**, Bray F, Center MM, Ferlay J, Ward E, Forman D. Global cancer statistics. *CA Cancer J Clin* 2011; **61**: 69-90 [PMID: 21296855 DOI: 10.3322/caac.20107]
- 3 **US NCI**. SEER stat fact sheets: esophagus. [accessed 2016 Dec 6]. Available from: URL: <http://seer.cancer.gov/statfacts/html/esoph.html>
- 4 **van Hagen P**, Hulshof MC, van Lanschot JJ, Steyerberg EW, van Berge Henegouwen MI, Wijnhoven BP, Richel DJ, Nieuwenhuijzen GA, Hospers GA, Bonenkamp JJ, Cuesta MA, Blaisse RJ, Busch OR, ten Kate FJ, Creemers GJ, Punt CJ, Plukker JT, Verheul HM, Spillenaar Bilgen EJ, van Dekken H, van der Slangen MJ, Rozema T, Biermann K, Beukema JC, Piet AH, van Rij CM, Reinders JG, Tilanus HW, van der Gaast A. Preoperative chemoradiotherapy for esophageal or junctional cancer. *N Engl J Med* 2012; **366**: 2074-2084 [PMID: 22646630 DOI: 10.1056/NEJMoa1112088]
- 5 **Wan J**, Che Y, Kang N, Zhang R. Surgical Method, Postoperative Complications, and Gastrointestinal Motility of Thoraco-Laparoscopy 3-Field Esophagectomy in Treatment of Esophageal Cancer. *Med Sci Monit* 2016; **22**: 2056-2065 [PMID: 27310399 DOI: 10.12659/MSM.895882]
- 6 **Shapiro J**, van Lanschot JJ, Hulshof MC, van Hagen P, van Berge Henegouwen MI, Wijnhoven BP, van Laarhoven HW, Nieuwenhuijzen GA, Hospers GA, Bonenkamp JJ, Cuesta MA, Blaisse RJ, Busch OR, Ten Kate FJ, Creemers GJ, Punt CJ, Plukker JT, Verheul HM, Bilgen EJ, van Dekken H, van der Slangen MJ, Rozema T, Biermann K, Beukema JC, Piet AH, van Rij CM, Reinders JG, Tilanus HW, Steyerberg EW, van der Gaast A. Neoadjuvant chemoradiotherapy plus surgery versus surgery alone for oesophageal or junctional cancer (CROSS): long-term results of a randomised controlled trial. *Lancet Oncol* 2015; **16**: 1090-1098 [PMID: 26254683 DOI: 10.1016/S1470-2045(15)00040-6]
- 7 **Nederlof N**, Slaman AE, van Hagen P, van der Gaast A, Slinkamenac K, Gisbertz SS, van Lanschot JJ, Wijnhoven BP, van Berge Henegouwen MI. Using the Comprehensive Complication Index to Assess the Impact of Neoadjuvant Chemoradiotherapy on Complication Severity After Esophagectomy for Cancer. *Ann*

- Surg Oncol* 2016; **23**: 3964-3971 [PMID: 27301849 DOI: 10.1245/s10434-016-5291-3]
- 8 **Low DE**, Alderson D, Ceconello I, Chang AC, Darling GE, DJourno XB, Griffin SM, Hölscher AH, Hofstetter WL, Jobe BA, Kitagawa Y, Kucharczuk JC, Law SY, Lerut TE, Maynard N, Pera M, Peters JH, Pramesh CS, Reynolds JV, Smithers BM, van Lanschot JJ. International Consensus on Standardization of Data Collection for Complications Associated With Esophagectomy: Esophagectomy Complications Consensus Group (ECCG). *Ann Surg* 2015; **262**: 286-294 [PMID: 25607756 DOI: 10.1097/SLA.0000000000001098]
 - 9 **Finks JF**, Osborne NH, Birkmeyer JD. Trends in hospital volume and operative mortality for high-risk surgery. *N Engl J Med* 2011; **364**: 2128-2137 [PMID: 21631325 DOI: 10.1056/NEJMsa1010705]
 - 10 **Dunst CM**, Swanström LL. Minimally invasive esophagectomy. *J Gastrointest Surg* 2010; **14** Suppl 1: S108-S114 [PMID: 19789930]
 - 11 **Courrech Staal EF**, Aleman BM, Boot H, van Velthuysen ML, van Tinteren H, van Sandick JW. Systematic review of the benefits and risks of neoadjuvant chemoradiation for oesophageal cancer. *Br J Surg* 2010; **97**: 1482-1496 [PMID: 20645400 DOI: 10.1002/bjs.7175]
 - 12 **Derogar M**, Orsini N, Sadr-Azodi O, Lagergren P. Influence of major postoperative complications on health-related quality of life among long-term survivors of esophageal cancer surgery. *J Clin Oncol* 2012; **30**: 1615-1619 [PMID: 22473157 DOI: 10.1200/JCO.2011.40.3568]
 - 13 **Scarpa M**, Saadeh LM, Fasolo A, Alfieri R, Cagol M, Cavallin F, Pinto E, Zaninotto G, Ancona E, Castoro C. Health-related quality of life in patients with oesophageal cancer: analysis at different steps of the treatment pathway. *J Gastrointest Surg* 2013; **17**: 421-433 [PMID: 23297025]
 - 14 **Viklund P**, Lindblad M, Lagergren J. Influence of surgery-related factors on quality of life after esophageal or cardia cancer resection. *World J Surg* 2005; **29**: 841-848 [PMID: 15951920 DOI: 10.1007/s00268-005-7887-9]
 - 15 **Maple JT**, Petersen BT, Baron TH, Kasperbauer JL, Wong Kee Song LM, Larson MV. Endoscopic management of radiation-induced complete upper esophageal obstruction with an antegrade-retrograde rendezvous technique. *Gastrointest Endosc* 2006; **64**: 822-828 [PMID: 17055888 DOI: 10.1016/j.gie.2006.06.026]
 - 16 **Bertolini R**, Meyenberger C, Putora PM, Albrecht F, Broglie MA, Stoeckli SJ, Sulz MC. Endoscopic dilation of complete oesophageal obstructions with a combined antegrade-retrograde rendezvous technique. *World J Gastroenterol* 2016; **22**: 2366-2372 [PMID: 26900299]
 - 17 **van Twisk JJ**, Brummer RJ, Manni JJ. Retrograde approach to pharyngo-esophageal obstruction. *Gastrointest Endosc* 1998; **48**: 296-299 [PMID: 9744609 DOI: 10.1016/S0016-5107(98)70195-6]
 - 18 **Goguen LA**, Norris CM, Jaklitsch MT, Sullivan CA, Posner MR, Haddad RI, Tishler RB, Burke E, Annino DJ. Combined antegrade and retrograde esophageal dilation for head and neck cancer-related complete esophageal stenosis. *Laryngoscope* 2010; **120**: 261-266 [PMID: 19998421]
 - 19 **Fowlkes J**, Zald PB, Andersen P. Management of complete esophageal stricture after treatment of head and neck cancer using combined antegrade retrograde esophageal dilation. *Head Neck* 2012; **34**: 821-825 [PMID: 22127917 DOI: 10.1002/hed.21826]
 - 20 **Dellon ES**, Cullen NR, Madanick RD, Buckmire RA, Grimm IS, Weisler MC, Couch ME, Shaheen NJ. Outcomes of a combined antegrade and retrograde approach for dilatation of radiation-induced esophageal strictures (with video). *Gastrointest Endosc* 2010; **71**: 1122-1129 [PMID: 20421101 DOI: 10.1016/j.gie.2009.12.057]
 - 21 **Grooteman KV**, Wong Kee Song LM, Vleggaar FP, Siersema PD, Baron TH. Functional outcome of patients treated for radiation-induced complete esophageal obstruction after successful endoscopic recanalization (with video). *Gastrointest Endosc* 2014; **80**: 175-181 [PMID: 24810592 DOI: 10.1016/j.gie.2014.03.007]

P- Reviewer: Agresta F, Barreto S, Chello M, Mocellin S

S- Editor: Ji FF **L- Editor:** A **E- Editor:** Lu YJ





Published by **Baishideng Publishing Group Inc**
8226 Regency Drive, Pleasanton, CA 94588, USA
Telephone: +1-925-223-8242
Fax: +1-925-223-8243
E-mail: bpgoffice@wjgnet.com
Help Desk: <http://www.f6publishing.com/helpdesk>
<http://www.wjgnet.com>

