

# World Journal of *Dermatology*

*World J Dermatol* 2022 June 2; 10(1): 1-9



**MINIREVIEWS**

- 1 Platelet-rich plasma application in diabetic ulcers: A review

*Simão VP, Cury CS, Tavares GMZ, Ortega GC, Ribeiro AC, Santos GS, Lana JFSD*

**ABOUT COVER**

Editorial Board Member of *World Journal of Dermatology*, Luca Negosanti, MD, PhD, Chief Doctor, Doctor, Surgeon, Surgical Oncologist, Plastic Surgery Department, Montecatone Rehabilitation Institute Imola Hospital, Bologna 40138, Italy. luca.negosanti81@gmail.com

**AIMS AND SCOPE**

The primary aim of *World Journal of Dermatology* (*WJD*, *World J Dermatol*) is to provide scholars and readers from various fields of dermatology with a platform to publish high-quality basic and clinical research articles and communicate their research findings online.

*WJD* mainly publishes articles reporting research results and findings obtained in the field of dermatology and covering a wide range of topics including acneiform eruptions, acute generalized exanthematous pustulosis, angiolymphoid hyperplasia with eosinophilia, breast diseases, cutaneous fistula, dermatitis, dermatomyositis, erythema, exanthema, facial dermatoses, foot diseases, hair diseases, hand dermatoses, keratoacanthoma, keratosis, leg dermatoses, lipomatosis, lupus erythematosus, mastocytosis, morgellons disease, nail diseases *etc.*

**INDEXING/ABSTRACTING**

The *WJD* is now indexed in Reference Citation Analysis, China National Knowledge Infrastructure, China Science and Technology Journal Database, and Superstar Journals Database.

**RESPONSIBLE EDITORS FOR THIS ISSUE**

Production Editor: Yi-Xuan Cai, Production Department Director: Xiang Li, Editorial Office Director: Ya-Juan Ma.

**NAME OF JOURNAL**

*World Journal of Dermatology*

**ISSN**

ISSN 2218-6190 (online)

**LAUNCH DATE**

June 2, 2012

**FREQUENCY**

Continuous Publication

**EDITORS-IN-CHIEF**

Zekayi Kutlubay

**EDITORIAL BOARD MEMBERS**

<https://www.wjgnet.com/2218-6190/editorialboard.htm>

**PUBLICATION DATE**

June 2, 2022

**COPYRIGHT**

© 2022 Baishideng Publishing Group Inc

**INSTRUCTIONS TO AUTHORS**

<https://www.wjgnet.com/bpg/gerinfo/204>

**GUIDELINES FOR ETHICS DOCUMENTS**

<https://www.wjgnet.com/bpg/GerInfo/287>

**GUIDELINES FOR NON-NATIVE SPEAKERS OF ENGLISH**

<https://www.wjgnet.com/bpg/gerinfo/240>

**PUBLICATION ETHICS**

<https://www.wjgnet.com/bpg/GerInfo/288>

**PUBLICATION MISCONDUCT**

<https://www.wjgnet.com/bpg/gerinfo/208>

**ARTICLE PROCESSING CHARGE**

<https://www.wjgnet.com/bpg/gerinfo/242>

**STEPS FOR SUBMITTING MANUSCRIPTS**

<https://www.wjgnet.com/bpg/GerInfo/239>

**ONLINE SUBMISSION**

<https://www.f6publishing.com>

## Platelet-rich plasma application in diabetic ulcers: A review

Victoria Pereira Simão, Carolina Souza Cury, Gabriel Mota Zamariolli Tavares, Gabriel Calixto Ortega, Arthur Cichetto Ribeiro, Gabriel Silva Santos, José Fábio Santos Duarte Lana

**Specialty type:** Orthopedics

**Provenance and peer review:**

Unsolicited article; Externally peer reviewed.

**Peer-review model:** Single blind

**Peer-review report's scientific quality classification**

Grade A (Excellent): 0  
Grade B (Very good): B  
Grade C (Good): C, C, C  
Grade D (Fair): 0  
Grade E (Poor): 0

**P-Reviewer:** Bugaj AM, Poland; Ng HY, China; Papazafropoulou A, Greece; Zhang Q, China

**Received:** December 15, 2021

**Peer-review started:** December 15, 2021

**First decision:** March 16, 2022

**Revised:** March 29, 2022

**Accepted:** April 24, 2022

**Article in press:** April 24, 2022

**Published online:** June 2, 2022



**Victoria Pereira Simão, Carolina Souza Cury, Gabriel Mota Zamariolli Tavares, Gabriel Calixto Ortega, Arthur Cichetto Ribeiro,** Medical School, Centro Universitário Lusíada, Santos 11045-101, São Paulo, Brazil

**Gabriel Silva Santos,** Biomedical Science, Brazilian Institute of Regenerative Medicine, Indaiatuba 13334-170, São Paulo, Brazil

**José Fábio Santos Duarte Lana,** Department of Orthopedics, Brazilian Institute of Regenerative Medicine, Indaiatuba 13334-170, São Paulo, Brazil

**Corresponding author:** Gabriel Silva Santos, BSc, Academic Research, Instructor, Research Scientist, Technician, Biomedical Science, Brazilian Institute of Regenerative Medicine, 1386 Presidente Kennedy Avenue, Indaiatuba 13334-170, São Paulo, Brazil.

[gabriel1\\_silva@hotmail.com](mailto:gabriel1_silva@hotmail.com)

### Abstract

There are 422 million diabetic people in the world. 25% of these individuals are diagnosed with diabetic foot ulcer (DFU). 20% of patients with DFU will suffer amputation of the lower limbs. Following amputation procedures, the mortality rate of patients is over 70% in 5 years. Diabetes has no cure and, therefore, treatment aims to prevent and treat its complications. Autologous platelet-rich plasma (PRP) has been shown to be a therapeutic tool for many types of disorders, including the treatment of DFU. This manuscript aims to carry out a review to provide more knowledge about the efficacy and safety of autologous PRP for wound closure in patients with DFU. The majority of studies included in this review state that PRP promotes improvement of DFU lesions by accelerating tissue healing processes. However, many studies have a small sample size and thus require larger sample range in order to improve robustness of data in the literature.

**Key Words:** Diabetic foot ulcer; Platelet-rich plasma; Wound healing; Tissue regeneration; Inflammation

©The Author(s) 2022. Published by Baishideng Publishing Group Inc. All rights reserved.



**Core Tip:** Platelet-rich plasma (PRP) can be produced by the centrifugation of a patient's peripheral blood, separating the mixture into distinct layers containing plasma, platelets, leukocytes and erythrocytes. An elevated concentration of platelets above the basal value enables accelerated growth of bone and soft tissues with minimal side effects. Autologous PRP administration is a relatively new biotechnology undergoing expansion which continues to reveal optimistic results in the stimulation and enhanced healing of various sorts of tissue injuries.

**Citation:** Simão VP, Cury CS, Tavares GMZ, Ortega GC, Ribeiro AC, Santos GS, Lana JFSD. Platelet-rich plasma application in diabetic ulcers: A review. *World J Dermatol* 2022; 10(1): 1-9

**URL:** <https://www.wjgnet.com/2218-6190/full/v10/i1/1.htm>

**DOI:** <https://dx.doi.org/10.5314/wjd.v10.i1.1>

## INTRODUCTION

There are approximately 422 million diabetic people in the world, comprising 8.5% of the adult population[1]. According to the World Health Organization, the number of people with diabetes mellitus increased significantly over the last decades due to the growth of the global population, ageing and prevalence of diabetes in each age range as well as the exposure of individuals to risk factors of such chronic disease[2].

A common consequence of diabetes mellitus is the development of a wound that takes a great amount of time to heal. It arises from the combination of peripheral neuropathy, which results in the loss of peripheral sensibility as well as the changes in hemostatic and vascular systems. Thus, diabetic foot ulcer (DFU) occurs and are often characterized by a series of physiological alterations that may occur on the foot of a patient with non-treated diabetes. Infections or vasculopathies of the lower limbs are among the most common complications, promoting the development of persistent wounds and additional pedal infections, which may lead to extensive tissue necrosis[3].

In the United States, for instance, there are an estimated one million to 3.5 million adults with a history of DFU. Approximately 25% of diabetic adults will develop DFU, of which 20% end up amputated. The recurrence rate of such wounds is 40% in 1 year and 65% in 5 years. In addition, patients with DFU have 2.5 times higher risk of mortality in 5 years than diabetic patients without diabetic foot injuries, and in the presence of amputation, mortality is greater than 70%[4,5].

As there is still no actual cure for diabetes, the interventions aim at a greater control of glucose levels and reduction of the most diverse detrimental risks, offering the patient a better quality of life[6]. The treatment of DFU can comprise the antibiotic therapy, neuropathic drugs, anti-inflammatory drugs, debridement techniques, compressive therapy, hyperbaric oxygen therapy, topical oxygen therapy, negative pressure therapy, placenta-derived products, platelet and leukocyte-rich fibrin, recombinant growth factors and platelet-rich plasma (PRP). Since the disease presents multiple physiological and biochemical variations, there is no "gold standard" treatment[5,7].

PRP is an orthobiologic product defined by a high concentration of platelets, clotting factors and hematological components. These are transformed into a small volume of plasma with a concentration greater than the basal value. PRP has several bioactive proteins, including growth factors, cytokines and peptides, capable of eliciting regenerative properties. Thus, PRP is applied in many fields associated with regenerative medicine, envisioning the enhanced healing process[8].

The preparation of PRP can be achieved *via* manual or automatic means. The process is given in three stages: blood collection, centrifugation and platelet concentration. It is important to note that during the collection stage, the type of anticoagulant used may influence the final PRP product. In the manual method, blood is subjected to a centrifugation step, which creates a layer of plasma at the top, an intermediate portion referred to as the "buffy coat", and a dense layer of erythrocytes at the bottom. Plasma and buffy coat can be collected and submitted to a second centrifugation round, achieving greater concentration from platelet sedimentation, thus giving rise to a product rich in both platelets and leukocytes, in this case. Due to the existence of differences in protocols and centrifugation parameters (varying according to G force and time), great variance among PRP products is seen in the literature. In the automatic method, however, there are commercial kits which, although time-saving, can be much more expensive than manual methods and do not always yield great quantities of platelets. Furthermore, PRP varies significantly according to individual hematological characteristics on a per-patient basis. The fact that there is a lot of heterogeneity and variance of PRP products in the literature makes the evaluation of its efficacy far more challenging[8-10].

The preparation of PRP can also have additional steps such as platelet activation, characterizing the final product as PRP gel. Platelet activation can be commonly achieved *via* the addition of thrombin or calcium to PRP, promoting the formation of a fibrin network and fast liberation of growth factors and cytokines. Different products and concentrations used for platelet activation also contribute to the

heterogeneity of PRP. There is no consensus regarding the best platelet activator or even the most appropriate circumstances where PRP would benefit from the addition or exclusion of platelet activation[10,11].

---

## OBJECTIVE

---

The aim of this study is to prove the efficacy and safety of PRP and its use for healing of wounds in patients with diabetic foot ulcers.

---

## LITERATURE SEARCH

---

### *Information sources and search strategy*

In the present study, we used search strategies that are described on [Figure 1](#), which were conducted in the following databases: MEDLINE, COCHRANE, SCIELO and LILACS. The research was concluded in April 2021.

### *Eligibility criteria*

Prospective Cohort Studies and Randomized Clinical Trials were included. Restrictions were made considering the year of publication; choosing articles with, at most, 21 years of publication. In regards to the language, we considered only articles in English, Spanish and Portuguese. Studies without access to the full text were excluded. A review was made aiming the evaluation of PRP application, analyzing if it is related to healing or an effective improvement of diabetic foot ulcers.

---

## STUDIES CHARACTERISTICS

---

The studies of this review added a total of 296 patients with diabetic ulcers. The interventions include 149 patients subjected to the PRP treatment and, in comparison, 119 patients were subjected to standard treatments such as wound dressing and bandaging 119. Follow-up times vary from four to 20 wk. Characteristics of the selected studies are described in [Table 1](#).

---

## ETHIOPATHOGENESIS

---

Although complex, diabetic foot injuries appear to be attributed to nerve dysfunction and cell death mainly by means of oxidative stress and inflammation[12]. Insulin resistance and other key components of metabolic syndrome can significantly contribute to dysregulation of metabolic pathways[13]. Metabolic stress promotes an imbalance in mitochondrial redox, culminating in accumulation of mitochondrial and cytosolic reactive oxygen species[14]. Mitochondriopathies are generally responsible for damage and loss of energy in axonal structures, paving the way for neuropathy and subsequent foot ulcers[15]. Additionally, the polyol pathway hyperactivity is also another major contributor as it increases the turnover of cofactors NADPH and NAD<sup>+</sup>. This brings a significant decrease in the redox potency and regeneration of glutathione, elevated levels of advanced glycation end products and activation of diacylglycerol and protein kinase C isoforms[16]. Depletion of intracellular concentrations of glutathione is the principal cause of oxidative stress and accumulation of toxic by-products, being a major culprit in the development of many pathogenic processes[17].

Many authors believe that the main mechanism responsible for diabetic foot injuries is linked to damaged nerve endings. Irregular action potentials are produced by damaged nerve endings and may be incorrectly translated by the brain as pain or dysesthesia signals[16]. Altered ion channel expression in peripheral nerve fibers is also related to pedal nerve injury, hyperexcitability and neuropathic pain [18]. One study[19] found that calcium ion channels are also disrupted in diabetic conditions, increasing calcium influx in sensory neurons which promotes the rapid stimulation of substance P and glutamate release[19].

Microglial activation is another feature involved in the pathogenic progression of diabetes-mediated neurological disorders. Microglial cells are primarily associated with homeostasis, myelin sheath formation, protection and neuron support from both the peripheral and central nervous systems[20]. Microglial activation occurs after peripheral nerve injury and can last up to 3 mo. This triggers the secretion of many inflammatory mediators including chemokines, cytokines, and cytotoxic substances such as nitric oxide (NO) and free radicals, which shifts homeostasis towards a pro-inflammatory and catabolic microenvironment[19,21]. In patients with metabolic syndrome and diabetic complications, the state of chronic inflammation impedes the standard healing process and aggravates the inflammatory

**Table 1** Characteristic of the selected studies

Ref.	Study design	Intervention	Control	Follow-up	Outcome
Driver <i>et al</i> [33], 2006	RCT	PRP	Saline gel	12 wk	UHT; ARE; AE
Li <i>et al</i> [30], 2015	RCT	PRP	Gauze with Vaseline	12 wk	UHT; ARE; R
Ahmed <i>et al</i> [31], 2017	PC	PRP	AD + SS + IP	12 wk	UHT; ARE; PI; LLA
Singh <i>et al</i> [32], 2018	PC	PRP	ST	28 d	UHT; CH; AAE
Tsai <i>et al</i> [34], 2019	RCT	PRP	Advanced dressings	12 wk	UHT; ARE; PI; LLA

AAE: Absence of adverse effects; AD: Antiseptic dressing; AE: Adverse events; ARE: Average rate of epithelium; CH: Complete healing; LLA: Lower limb amputation; PC: Prospective cohort; PI: Presence of infection; PRP: Platelet-rich plasma; R: Recurrences; RCT: Randomized controlled trial; SS: Saline solution; ST: Standard treatment with glucose level control, infection control, remission of high blood pressure and dressing; UHT: Ulcer healing time.

MEDLINE: Platelet-rich plasma or PRP and diabetic foot or diabetic ulcer  
 SCIELO: Platelet-rich plasma and diabetes  
 COCHRANE: Platelet-rich plasma and diabetic ulcer  
 LILACS: Platelet-rich plasma and diabetic foot or ulcer

DOI: 10.5314/wjd.v10.i1.1 Copyright ©The Author(s) 2022.

**Figure 1** Literature search strategy. PRP: Platelet-rich plasma.

cascade[22-24].

## PRP MECHANISM OF ACTION

The local release of growth factors and cytokines present in the platelet alpha granules accelerates and improves tissue repair, mimicking and aiding in the lesion restoration pattern. This effect is enhanced when associated with the fibrinolytic system. Fibrinolytic reactions fine-tune cell recruitment of certain cell populations, such as mesenchymal stem cells and other immunomodulatory agents. Such reactions also control proteolytic activity in the areas of healing and regenerative process of mesenchymal tissues such as bone, cartilage and muscle. The regeneration cascade is divided into 4 phases: hemostasis, inflammation, cell and matrix proliferation and lesion remodeling[25].

### Hemostasis

Capillary leakage allows the recruitment of hemostatic factors and inflammatory mediators. Platelets adhere to exposed collagen and temporary extracellular matrix proteins, triggering the release of bioactive molecules present in alpha granules. Orban *et al*[26], to help platelets' adherence, debrided the top of wounds and callosities, turning a chronic ulcer into an acute wound. This process transformed the ulcer into a fertile environment for the application of PRP and the development of an adequate inflammatory cascade. Platelets contain a wide variety of bioactive molecules, including growth factors, chemokines and cytokines, as well as pro-inflammatory mediators such as prostaglandins, prostacyclins, histamine, thromboxane, serotonin and bradykinin[25]. The exposed collagen connects and activates glycoprotein VI, which is present on platelets and megakaryocytes membrane. Another pathway is through G-protein-coupled receptors, activated by adenosine 5'-diphosphate, thromboxane A<sub>2</sub>, and thrombin[25-27].

### Inflammation

Recruitment of neutrophils into the lesion occurs within one to two hours. Afterwards, approximately 48 to 72 h, macrophages reach the lesion and begin debridement and regulation of inflammation. These also participate in the recruitment of fibroblasts and endothelial cells. Lymphocytes are the last cells to reach the site of injury[25].

### Cell and matrix proliferation

Cellular activity is predominant, being derived from pluripotent progenitor cells from adjacent tissues. During this phase, there is the occurrence of key events including the formation of an epithelial barrier, angiogenesis and strengthening of injured tissue. Fibroblasts and epithelial cells are affected by some variables such as macrophage activity as well as the secretion of chemotactic, mitogenic and angiogenic

growth factors. These events allow cells to infiltrate the injury site, where fibroblasts then synthesize collagen and differentiate into myofibroblasts, specialized cells that promote and facilitate contraction, assisting in wound closure[25].

### Remodeling

In this phase, maturation and remodeling occurs, with a balance between anabolic and catabolic reactions. Platelet-derived growth factor, transforming growth factor beta (TGF- $\beta$ ) and fibronectin stimulate fibroblast proliferation and migration in order to synthesize components of the temporary cell matrix. The maturation time at this stage depends on the size of the lesion, individual characteristics and specific regeneration characteristics of the injured tissue. Some health conditions such as ischemia, hypoxia, infection, *etc.* can interfere with regenerative processes and aggravate DFU[25].

---

## EFFECTS OF PRP

---

PRP is much more than a mere source of growth factors. This therapeutic tool holds the capacity to effectively modulate the deleterious effects of prolonged tissue inflammation by controlling the exacerbated inflammatory state and establishing a pro-anabolic stimulus. PRP has the potential to regulate tissue turnover thanks to the release of growth factors located in platelet alpha granules, which also promotes pain relief. Thus, its main function is to interrupt the predominant inflammatory and catabolic state in the wound microenvironment, restoring equilibrium and a shift towards a more anti-inflammatory state[25].

Evidence suggests that activation of PRP by thrombin increases the release of many biomolecules such as hepatocyte growth factor, tumor necrosis factor- $\alpha$ , TGF- $\beta$ 1, vascular endothelial growth factor and epidermal growth factor. Some studies show that PRP does not only promote an increase in mRNA levels of collagen type II and aggrecan but also reduces their inhibition by the pro-inflammatory cytokine interleukin-1 $\beta$ [25].

Another biological feature of PRP is the reduction of high levels of NO. According to some authors [25], NO can, in many circumstances, cause inhibitory effects on collagen synthesis and induce chondrocyte apoptosis. There also seems to be an increase in the synthesis of matrix metalloproteinases, which promotes a shift towards catabolic reactions.

Parrish and Roides[28] previously described an interaction between platelets and neutrophils in great detail. In their investigation, the researchers explained that arachidonic acid released by activated platelets is absorbed by neutrophils and converted into leukotrienes and prostaglandins, which are both inflammatory molecules. Interestingly, the interaction between platelets and neutrophils allows the conversion of leukotriene into lipoxin, a potent anti-inflammatory protein capable of limiting neutrophil activation, which prevents diapedesis and improves the responses of the last stages of the inflammatory cascade. The cytokines and growth factors present in PRP contribute to anabolic reactions by modulating the inflammatory state in injured tissues[25,28].

The fibrinolytic system, which is regulated by plasmin, has a fair share of relevance in the healing cascade due. It controls many key components of the cascade including cell migration, bioavailability of growth factors and regulation of other protease systems present in inflammation and tissue regeneration. PRP nevertheless became a feasible therapeutic tool for regenerative medicine and even aesthetics due to its low cost, rapidity and uncomplicated isolation. This orthobiologic material does not trigger major side effects and has high healing potential due to its robust immunomodulatory and paracrine effects. Furthermore, PRP allows the reduction of inflammation *via* cytokine secretion, increasing the healing potential, regeneration, reepithelization and angiogenic activity of injured tissues and reduces the possibility of infection by eliciting defensive mechanisms against bacteria, which are often major aggressors of DFU[8]. Considering all the properties of platelets and PRP as a whole, the latter stimulates a wide set of natural biologic responses for healing and regeneration of injured tissues [29].

---

## APPLICATION OF PRP IN DIABETIC FOOT ULCER

---

In the current review, the majority of studies aimed to evaluate the efficacy, safety and healing potential of PRP in the treatment of DFU. The studies consider outcomes such as wound healing, ulcer healing time, reepithelization rate and presence of adverse effects. It was observed that many authors used different terms to refer to PRP throughout the work; as an example, in the study led by Li *et al*[30], the authors used the nomenclature "autologous platelet-rich gel" but described it, in their preparation, as obtaining PRP. Thus, such variability in terms has generated confusion[30].

The results obtained by Ahmed *et al*[31] are consistent with the statement that PRP has the property of reducing the possibility of infection[8]. All of the included studies state that PRP improves DFU or accelerates the healing process of such lesions, being consistent with the high healing power described by Samadi *et al*[8].



Ahmed *et al*[31] demonstrated that PRP is easy and safe to utilize in DFU, as well as Singh *et al*[32] and Li *et al*[30], who did not observe any adverse effects associated with the administration of PRP gel. Driver *et al*[33] found a minimum number of adverse effects and none of them serious. Tsai *et al*[34] mentioned neither the presence nor the absence of adverse reactions. Such statements are endorsed by the assertion that PRP is safe and easy[8,30-32].

Ahmed *et al*[31] observed a significantly slower rate of healing using PRP at the end of the 8<sup>th</sup> wk. The authors reported that this can be explained by the extremely high concentration of growth factors that lead to negative regulation of receptors due to biphasic effects. However, further studies including a larger group of patients are needed to support this observation. In addition, the authors suggested that PRP shall be used for 8 wk to accelerate the rate of healing, and then use the conventional dressing until complete healing is achieved. Moreover, the infection rate was lower in the group that received PRP, which may indicate that PRP also plays additional antimicrobial roles, as previously mentioned[31].

In their meta-analysis, Villela and Santos[35] concluded that evidence indicates favorable outcomes with the use of PRP in DFU. However, the authors stated that such conclusion depends on the association with a multidisciplinary treatment program, since this was present in all of the studies analyzed, indicating that future studies must evaluate the quality of life and cost-benefit outcomes of the treatment. Such relationship with multidisciplinary treatment was only reported by Driver *et al*[33], implicating the possible prevention of amputations, which directly influences the patient's quality of life. Furthermore, it must be emphasized that there is less accessibility to PRP compared to other conventional therapies, which was also stated in this review[35].

For Pino-Sedeño *et al*[36], PRP therapy positively impacts wound healing and is a safe option for the treatment of chronic ulcers in diabetic foot. In addition, the authors indicated the need for an interdisciplinary approach for the proper management of DFU; they cited the need for care such as the use of appropriate footwear to prevent recurrence of ulcers[36].

The conclusion of the systematic review by Hirase *et al*[37] was also consistent with the one obtained in this study, since it was found that the application of PRP in DFU resulted in higher cure rates and complication rates lower than those found in patients under conventional treatment[37].

Ahmed *et al*[31] and Li *et al*[30] described fewer complications in the group using PRP than in the control group. Driver *et al*[33], Singh *et al*[32] and Tsai *et al*[34] did not observe significant complications in the intervention group. As for the recurrence of ulcers, Driver *et al*[33] reported one recurrence in the intervention group and none in the control group, and Li *et al*[30] reported six recurrences in each group; the other authors did not report recurrence of ulcers during the study period. Hu *et al*[38] concluded that PRP can be an effective therapy for the treatment of DFU and is not associated with a significant increase in risk for adverse effects[30,32,33].

Among the biases and limitations of the use of PRP, there is its preparation. In all studies analyzed in this review, autologous PRP products were used. The type of anticoagulant used was dextrose citrate by Singh *et al*[32], while Li *et al*[30] decided to use an anticoagulant with a pH at a value of 8. The other studies reported no specifications regarding which anticoagulant was used. In terms of centrifugation, in the studies led by Tsai *et al*[34] and Driver *et al*[33], a single centrifugation was performed, whilst Singh *et al*[32], Li *et al*[30] and Ahmed *et al*[31] resorted to double centrifugation, all varying in the type of centrifuge as well as time and centrifugation force. Finally, concerning activation, studies used thrombin and/or calcium, varying the origin of thrombin (bovine or homologous) and the presentation of calcium (calcium chloride or gluconate)[30-34].

Another bias found is the way in which PRP is applied, patient follow-up, and decision of association with other therapies, which varied between studies. As for the preparation of the wound, in Singh *et al*[32], debridement was described; in Ahmed *et al*[31], the wound was cleaned; in Li *et al*[30], topical washing, cleaning, drainage and debridement of callous and necrotic tissue were performed; in Tsai *et al*[34], cleaning and debridement of the ulcer was described; finally, in Driver *et al*[33], initial excision/debridement, measurements (culture and vascular tests) and assessment of the wound baseline and application of saline control gel on the wound were described. As for the application of PRP, in Singh *et al*[32], the use was injectable, once a week; in Ahmed *et al*[31], use was topical, twice a week; in Li *et al*[30], the use was topical; in Tsai *et al*[34], the use was injectable; finally, in Driver *et al*[33], the use was topical, twice a week, with intervals between 3 d and 4 d, for 12 wk. Singh *et al*[32] combined PRP with antibiotic therapy and diabetes control with an oral hypoglycemic agent; Ahmed *et al*[31] combined glycemic control; in Li *et al*[30], insulin therapy, anti-infection, nerve-trophic therapies and improvement of the circulation were associated with PRP, and in addition to nutritional support and anti-symptomatic treatments, antihypertensive drugs and lipid regulators were also administered to patients with hypertension and dyslipidemia, respectively, finalizing with dressing changes. In the investigation led by Tsai *et al*[34], platelet-poor plasma, fibrin-rich plasma, negative pressure treatment to control excessive tissue exudate and hyperbaric oxygen therapy were also included in order to keep the wound infection-free; lastly, Driver *et al*[33] used a foam dressing in combination with PRP, with the non-absorptive layer on the contact dressing (on the PRP gel) and the external absorptive layer to drain the excessive exudate. A cream was placed on the intact skin around the wound to form a barrier[29-33, 37].

The low number of controlled studies included in the review and the variability of study samples also pose a limitation. Most of the studies had a small sample size, requiring larger sample coverage in order

to generate more robust data. In the study led by Singh *et al*[32], the sample consisted of 55 patients of various ages, accounting for variables such as average age of 53.76 ( $\pm$  10.38); sex, with 34 male and 21 female patients; and place of residence, with 31 patients residing in the rural area and 24 from the urban district. Ahmed *et al*[31] recruited 56 patients, 38 men and 18 women with an average age of 49.8 years in the control group and 43.2 years in the intervention group; risk factors included were hypertension, previous acute myocardial infection, hyperlipidemia and tobacco consumption. Li *et al*[30] set the sample size at 117 patients, the largest one in this review. It included patients with a mean age of 63.8 years, with 48 patients having foot ulcers, six in the leg, four in the hip, two in the hand, one on the neck and one on the popliteal fossa. Tsai *et al*[34] had a sample size of 28 patients, with the average age of the diabetic control group being 64.8 ( $\pm$  10.7) years, while in the intervention group, the average age was 62.9 ( $\pm$  10.5) years. Finally, in Driver *et al*[33], the sample consisted of 72 patients, including patients with type 1 and type 2 diabetes, aged between 18 and 95, with ulcers lasting at least 4 wk[30-32,34,36].

PRP has been shown to be an effective and safe option for DFU, as observed in the results of the studies analyzed, making it an attractive therapy. However, in Brazil, the Federal Council of Medicine (CFM) allowed the use of PRP only on an experimental basis until the present moment. For these reasons, the practical applicability of PRP has yet to be fully elucidated. Nevertheless, the regulatory process was accepted by The Brazilian Health Regulatory Agency due to the clinical indications suggested in the various medical areas listed in the literature. Another important point is the lack of standardization in the preparation, administration and follow-up of PRP. Stipulating a standard is necessary in order to facilitate reproducibility and comparison of studies. Thus, standardized studies concerning the effectiveness and safety of PRP are of utmost importance for reliability in the results so that this tool becomes part of the therapeutic arsenal of complicated disorders, especially DFU.

---

## CONCLUSION

Since the use of PRP in Brazil is only allowed by the CFM on an experimental basis, the practical applicability of this therapy becomes limited at this time. In this review, PRP demonstrated efficacy and safety in the treatment of diabetic foot ulcers. To increase the reliability of the results obtained and stimulate the regulation of PRP, the production of new studies is highly encouraged, with larger sample size, standardization in the preparation and application of PRP as well as in the patient follow-up and exclusion criteria in order to reduce the risk of bias.

---

## FOOTNOTES

**Author contributions:** Simão VP wrote the manuscript; Santos GS proposed the research subtopics; Cury CS and Tavares GMZ were responsible for navigating the literature and sharing the relevant studies that were included in this review; Lana JFSD shared significant knowledge regarding the use of PRP in regenerative medicine; Ortega GC formatted the citations and compiled the references; Ribeiro AC revised and formatted the body of the manuscript, verifying spelling, punctuation and grammatical errors.

**Conflict-of-interest statement:** The authors declare that they have no conflict of interest.

**Open-Access:** This article is an open-access article that was selected by an in-house editor and fully peer-reviewed by external reviewers. It is distributed in accordance with the Creative Commons Attribution NonCommercial (CC BY-NC 4.0) license, which permits others to distribute, remix, adapt, build upon this work non-commercially, and license their derivative works on different terms, provided the original work is properly cited and the use is non-commercial. See: <https://creativecommons.org/licenses/by-nc/4.0/>

**Country/Territory of origin:** Brazil

**ORCID number:** Victoria Pereira Simão 0000-0002-5492-0545; Carolina Souza Cury 0000-0003-3353-1388; Gabriel Mota Zamariolli 0000-0002-8517-3546; Gabriel Calixto Ortega 0000-0002-7554-9255; Arthur Cichetto Ribeiro 0000-0003-4489-4491; Gabriel Silva Santos 0000-0002-0549-6821; José Fábio Santos Duarte Lana 0000-0002-2330-3982.

**S-Editor:** Gong ZM

**L-Editor:** Filipodia

**P-Editor:** Gong ZM

---

## REFERENCES

- 1 **Monteiro-Soares M**, Russell D, Boyko EJ, Jeffcoate W, Mills JL, Morbach S, Game F; International Working Group on the Diabetic Foot (IWGDF). Guidelines on the classification of diabetic foot ulcers (IWGDF 2019). *Diabetes Metab Res*

- Rev 2020; **36** Suppl 1: e3273 [PMID: 32176445 DOI: 10.1002/dmrr.3273]
- 2 **Kakkur R.** Rising burden of Diabetes-Public Health Challenges and way out. *Nepal J Epidemiol* 2016; **6**: 557-559 [PMID: 27774342 DOI: 10.3126/nje.v6i2.15160]
  - 3 **Naidoo P,** Liu VJ, Mautone M, Bergin S. Lower limb complications of diabetes mellitus: a comprehensive review with clinicopathological insights from a dedicated high-risk diabetic foot multidisciplinary team. *Br J Radiol* 2015; **88**: 20150135 [PMID: 26111070 DOI: 10.1259/bjr.20150135]
  - 4 **Hicks CW,** Canner JK, Mathioudakis N, Lippincott C, Sherman RL, Abularrage CJ. Incidence and Risk Factors Associated With Ulcer Recurrence Among Patients With Diabetic Foot Ulcers Treated in a Multidisciplinary Setting. *J Surg Res* 2020; **246**: 243-250 [PMID: 31610352 DOI: 10.1016/j.jss.2019.09.025]
  - 5 **Rayman G,** Vas P, Dhatriya K, Driver V, Hartemann A, Londahl M, Piaggese A, Apelqvist J, Attinger C, Game F; International Working Group on the Diabetic Foot (IWGDF). Guidelines on use of interventions to enhance healing of chronic foot ulcers in diabetes (IWGDF 2019 update). *Diabetes Metab Res Rev* 2020; **36** Suppl 1: e3283 [PMID: 32176450 DOI: 10.1002/dmrr.3283]
  - 6 **Wexler DJ.** Initial management of hyperglycemia in adults with type 2 diabetes mellitus. *UpToDate* 2021. Available from: <https://www.uptodate.com/contents/initial-management>
  - 7 **Didangelos T,** Koliakos G, Kouzi K, Arsos G, Kotzampassi K, Tziomalos K, Karamanos D, Hatzitolios AI. Accelerated healing of a diabetic foot ulcer using autologous stromal vascular fraction suspended in platelet-rich plasma. *Regen Med* 2018; **13**: 277-281 [PMID: 29715071 DOI: 10.2217/rme-2017-0069]
  - 8 **Samadi P,** Sheykhhasan M, Khoshnani HM. The Use of Platelet-Rich Plasma in Aesthetic and Regenerative Medicine: A Comprehensive Review. *Aesthetic Plast Surg* 2019; **43**: 803-814 [PMID: 30552470 DOI: 10.1007/s00266-018-1293-9]
  - 9 **Acebes-Huerta A,** Arias-Fernández T, Bernardo Á, Muñoz-Turrillas MC, Fernández-Fuertes J, Seghatchian J, Gutiérrez L. Platelet-derived bio-products: Classification update, applications, concerns and new perspectives. *Transfus Apher Sci* 2020; **59**: 102716 [PMID: 31928859 DOI: 10.1016/j.transci.2019.102716]
  - 10 **Lana JFSD,** Andrade Santana MH, Dias Belangero W, Malheiros Luzo AC (eds). Platelet-Rich Plasma: Regenerative Medicine: Sports Medicine, Orthopedic, and Recovery of Musculoskeletal Injuries. Berlin, Heidelberg: Springer Berlin Heidelberg 2014: 1-59 [DOI: 10.1007/978-3-642-40117-6]
  - 11 **Huber SC,** Cunha Júnior JL, Montalvão S, da Silva LQ, Paffaro AU, da Silva FA, Rodrigues BL, Lana JF, Annichino-Bizzacchi JM. In vitro study of the role of thrombin in platelet rich plasma (PRP) preparation: utility for gel formation and impact in growth factors release. *J Stem Cells Regen Med* 2016; **12**: 2-9 [PMID: 27397996 DOI: 10.46582/jsrm.1201002]
  - 12 **Hicks CW,** Selvin E. Epidemiology of Peripheral Neuropathy and Lower Extremity Disease in Diabetes. *Curr Diab Rep* 2019; **19**: 86 [PMID: 31456118 DOI: 10.1007/s11892-019-1212-8]
  - 13 **Azzini GOM,** Santos GS, Visoni SBC, Azzini VOM, Santos RGD, Huber SC, Lana JF. Metabolic syndrome and subchondral bone alterations: The rise of osteoarthritis - A review. *J Clin Orthop Trauma* 2020; **11**: S849-S855 [PMID: 32999567 DOI: 10.1016/j.jcot.2020.06.021]
  - 14 **Sajic M.** Mitochondrial dynamics in peripheral neuropathies. *Antioxid Redox Signal* 2014; **21**: 601-620 [PMID: 24386984 DOI: 10.1089/ars.2013.5822]
  - 15 **Feldman EL,** Nave KA, Jensen TS, Bennett DLH. New Horizons in Diabetic Neuropathy: Mechanisms, Bioenergetics, and Pain. *Neuron* 2017; **93**: 1296-1313 [PMID: 28334605 DOI: 10.1016/j.neuron.2017.02.005]
  - 16 **Schreiber AK,** Nones CF, Reis RC, Chichorro JG, Cunha JM. Diabetic neuropathic pain: Physiopathology and treatment. *World J Diabetes* 2015; **6**: 432-444 [PMID: 25897354 DOI: 10.4239/wjd.v6.i3.432]
  - 17 **Setti T,** Arab MGL, Santos GS, Alkass N, Andrade MAP, Lana JFSD. The protective role of glutathione in osteoarthritis. *J Clin Orthop Trauma* 2021; **15**: 145-151 [PMID: 33717929 DOI: 10.1016/j.jcot.2020.09.006]
  - 18 **Dickenson AH,** Matthews EA, Suzuki R. Neurobiology of neuropathic pain: mode of action of anticonvulsants. *Eur J Pain* 2002; **6** Suppl A: 51-60 [PMID: 11888242 DOI: 10.1053/eujp.2001.0323]
  - 19 **Hall KE,** Liu J, Sima AA, Wiley JW. Impaired inhibitory G-protein function contributes to increased calcium currents in rats with diabetic neuropathy. *J Neurophysiol* 2001; **86**: 760-770 [PMID: 11495948 DOI: 10.1152/jn.2001.86.2.760]
  - 20 **Mika J,** Zychowska M, Popiolek-Barczyk K, Rojewska E, Przewlocka B. Importance of glial activation in neuropathic pain. *Eur J Pharmacol* 2013; **716**: 106-119 [PMID: 23500198 DOI: 10.1016/j.ejphar.2013.01.072]
  - 21 **Vydyanathan A,** Wu ZZ, Chen SR, Pan HL. A-type voltage-gated K<sup>+</sup> currents influence firing properties of isolectin B4-positive but not isolectin B4-negative primary sensory neurons. *J Neurophysiol* 2005; **93**: 3401-3409 [PMID: 15647393 DOI: 10.1152/jn.01267.2004]
  - 22 **Greenhalgh DG.** Wound healing and diabetes mellitus. *Clin Plast Surg* 2003; **30**: 37-45 [PMID: 12636214 DOI: 10.1016/s0094-1298(02)00066-4]
  - 23 **Khamaisi M,** Balanson S. Dysregulation of wound healing mechanisms in diabetes and the importance of negative pressure wound therapy (NPWT). *Diabetes Metab Res Rev* 2017; **33** [PMID: 28817237 DOI: 10.1002/dmrr.2929]
  - 24 **Tsalamandris S,** Antonopoulos AS, Oikonomou E, Papamikroulis GA, Vogiatzi G, Papaioannou S, Deftereos S, Tousoulis D. The Role of Inflammation in Diabetes: Current Concepts and Future Perspectives. *Eur Cardiol* 2019; **14**: 50-59 [PMID: 31131037 DOI: 10.15420/ecr.2018.33.1]
  - 25 **Dos Santos RG,** Santos GS, Alkass N, Chiesa TL, Azzini GO, da Fonseca LF, Dos Santos AF, Rodrigues BL, Mosaner T, Lana JF. The regenerative mechanisms of platelet-rich plasma: A review. *Cytokine* 2021; **144**: 155560 [PMID: 34004552 DOI: 10.1016/j.cyto.2021.155560]
  - 26 **Orban YA,** Soliman MA, Hegab YH, Alkilany MM. Autologous platelet-rich plasma vs conventional dressing in the management of chronic diabetic foot ulcers. *Wounds* 2022; **33**: 36-42 [PMID: 35108667 DOI: 10.25270/wnds/2022.3642]
  - 27 **Akbarzadeh S,** McKenzie MB, Rahman MM, Cleland H. Allogeneic Platelet-Rich Plasma: Is It Safe and Effective for Wound Repair? *Eur Surg Res* 2021; **62**: 1-9 [PMID: 33621973 DOI: 10.1159/000514223]
  - 28 **Parrish W,** Roides B. Platelet rich plasma in osteoarthritis: More than a growth factor therapy. *Musculoskel Regen* 2017; **3**: e1518 [DOI: 10.14800/mr.1518]
  - 29 **Babaei V,** Afradi H, Gohardani HZ, Nasser F, Azarafza M, Teimourian S. Management of chronic diabetic foot ulcers

- using platelet-rich plasma. *J Wound Care* 2017; **26**: 784-787 [PMID: 29244965 DOI: 10.12968/jowc.2017.26.12.784]
- 30 **Li L**, Chen D, Wang C, Yuan N, Wang Y, He L, Yang Y, Chen L, Liu G, Li X, Ran X. Autologous platelet-rich gel for treatment of diabetic chronic refractory cutaneous ulcers: A prospective, randomized clinical trial. *Wound Repair Regen* 2015; **23**: 495-505 [PMID: 25847503 DOI: 10.1111/wrr.12294]
- 31 **Ahmed M**, Reffat SA, Hassan A, Eskander F. Platelet-Rich Plasma for the Treatment of Clean Diabetic Foot Ulcers. *Ann Vasc Surg* 2017; **38**: 206-211 [PMID: 27522981 DOI: 10.1016/j.avsg.2016.04.023]
- 32 **Singh SP**, Kumar V, Pandey A, Pandey P, Gupta V, Verma R. Role of platelet-rich plasma in healing diabetic foot ulcers: a prospective study. *J Wound Care* 2018; **27**: 550-556 [PMID: 30204574 DOI: 10.12968/jowc.2018.27.9.550]
- 33 **Driver VR**, Hanft J, Fylling CP, Beriou JM; Autologel Diabetic Foot Ulcer Study Group. A prospective, randomized, controlled trial of autologous platelet-rich plasma gel for the treatment of diabetic foot ulcers. *Ostomy Wound Manage* 2006; **52**: 68-70, 72, 74 passim [PMID: 16799184]
- 34 **Tsai HC**, Lehman CW, Chen CM. Use of platelet-rich plasma and platelet-derived patches to treat chronic wounds. *J Wound Care* 2019; **28**: 15-21 [PMID: 30625042 DOI: 10.12968/jowc.2019.28.1.15]
- 35 **Villela DL**, Santos VL. Evidence on the use of platelet-rich plasma for diabetic ulcer: a systematic review. *Growth Factors* 2010; **28**: 111-116 [PMID: 20001406 DOI: 10.3109/08977190903468185]
- 36 **Del Pino-Sedeño T**, Trujillo-Martín MM, Andía I, Aragón-Sánchez J, Herrera-Ramos E, Iruzubieta Barragán FJ, Serrano-Aguilar P. Platelet-rich plasma for the treatment of diabetic foot ulcers: A meta-analysis. *Wound Repair Regen* 2019; **27**: 170-182 [PMID: 30575212 DOI: 10.1111/wrr.12690]
- 37 **Hirase T**, Ruff E, Surani S, Ratnani I. Topical application of platelet-rich plasma for diabetic foot ulcers: A systematic review. *World J Diabetes* 2018; **9**: 172-179 [PMID: 30364787 DOI: 10.4239/wjd.v9.i10.172]
- 38 **Hu Z**, Qu S, Zhang J, Cao X, Wang P, Huang S, Shi F, Dong Y, Wu J, Tang B, Zhu J. Efficacy and Safety of Platelet-Rich Plasma for Patients with Diabetic Ulcers: A Systematic Review and Meta-analysis. *Adv Wound Care (New Rochelle)* 2019; **8**: 298-308 [PMID: 31832277 DOI: 10.1089/wound.2018.0842]



Published by **Baishideng Publishing Group Inc**  
7041 Koll Center Parkway, Suite 160, Pleasanton, CA 94566, USA

**Telephone:** +1-925-3991568

**E-mail:** [bpgoffice@wjgnet.com](mailto:bpgoffice@wjgnet.com)

**Help Desk:** <https://www.f6publishing.com/helpdesk>


<https://www.wjgnet.com>





# World Journal of *Dermatology*

*World J Dermatol* 2022 September 2; 10(2): 10-16



**CASE REPORT**

- 10 Connection between dermatomyositis and montelukast sodium use: A case report

*Aly MH, Alshehri AA, Mohammed A, Almaghrabi MA, Alharbi MM*

**ABOUT COVER**

Editorial Board Member of *World Journal of Dermatology*, Shashank Bhargava, MD, Assistant Professor, Department of Dermatology, Venereology and Leprosy, Ruxmaniben Deepchand Gardi Medical College, Ujjain, Madhya Pradesh 456010, India. shashank2811@gmail.com

**AIMS AND SCOPE**

The primary aim of *World Journal of Dermatology (WJD, World J Dermatol)* is to provide scholars and readers from various fields of dermatology with a platform to publish high-quality basic and clinical research articles and communicate their research findings online.

*WJD* mainly publishes articles reporting research results and findings obtained in the field of dermatology and covering a wide range of topics including acneiform eruptions, acute generalized exanthematous pustulosis, angiolymphoid hyperplasia with eosinophilia, breast diseases, cutaneous fistula, dermatitis, dermatomyositis, erythema, exanthema, facial dermatoses, foot diseases, hair diseases, hand dermatoses, keratoacanthoma, keratosis, leg dermatoses, lipomatosis, lupus erythematosus, mastocytosis, morgellons disease, nail diseases *etc.*

**INDEXING/ABSTRACTING**

The *WJD* is now abstracted and indexed in Reference Citation Analysis, China National Knowledge Infrastructure, China Science and Technology Journal Database, and Superstar Journals Database.

**RESPONSIBLE EDITORS FOR THIS ISSUE**

Production Editor: *Xiang-Di Zhang*; Production Department Director: *Xu Guo*; Editorial Office Director: *Yun-Xiaoqiao Wu*.

**NAME OF JOURNAL**

*World Journal of Dermatology*

**ISSN**

ISSN 2218-6190 (online)

**LAUNCH DATE**

June 2, 2012

**FREQUENCY**

Continuous Publication

**EDITORS-IN-CHIEF**

Zekayi Kutlubay

**EDITORIAL BOARD MEMBERS**

<https://www.wjgnet.com/2218-6190/editorialboard.htm>

**PUBLICATION DATE**

September 2, 2022

**COPYRIGHT**

© 2022 Baishideng Publishing Group Inc

**INSTRUCTIONS TO AUTHORS**

<https://www.wjgnet.com/bpg/gerinfo/204>

**GUIDELINES FOR ETHICS DOCUMENTS**

<https://www.wjgnet.com/bpg/GerInfo/287>

**GUIDELINES FOR NON-NATIVE SPEAKERS OF ENGLISH**

<https://www.wjgnet.com/bpg/gerinfo/240>

**PUBLICATION ETHICS**

<https://www.wjgnet.com/bpg/GerInfo/288>

**PUBLICATION MISCONDUCT**

<https://www.wjgnet.com/bpg/gerinfo/208>

**ARTICLE PROCESSING CHARGE**

<https://www.wjgnet.com/bpg/gerinfo/242>

**STEPS FOR SUBMITTING MANUSCRIPTS**

<https://www.wjgnet.com/bpg/GerInfo/239>

**ONLINE SUBMISSION**

<https://www.f6publishing.com>

## Connection between dermatomyositis and montelukast sodium use: A case report

Mohammed H Aly, Abdulrahman A Alshehri, Abdelgaffar Mohammed, Murouj Adnan Almaghrabi, Malek M Alharbi

**Specialty type:** Dermatology

**Provenance and peer review:**

Unsolicited article; Externally peer reviewed.

**Peer-review model:** Single blind

**Peer-review report's scientific quality classification**

Grade A (Excellent): 0

Grade B (Very good): B

Grade C (Good): C

Grade D (Fair): 0

Grade E (Poor): 0

**P-Reviewer:** Fazilat-Panah D, Iran; Ghimire R, Nepal

**Received:** March 6, 2022

**Peer-review started:** March 6, 2022

**First decision:** April 13, 2022

**Revised:** April 22, 2022

**Accepted:** July 26, 2022

**Article in press:** July 26, 2022

**Published online:** September 2, 2022



**Mohammed H Aly, Abdelgaffar Mohammed,** Department of Internal Medicine, Security Forces Hospital, Makkah 21599, Saudi Arabia

**Abdulrahman A Alshehri,** Department of Rheumatology, Security Forces Hospital, Makkah 21599, Saudi Arabia

**Murouj Adnan Almaghrabi, Malek M Alharbi,** College of Medicine, Umm Al-Qura University, Makkah 24382, Saudi Arabia

**Corresponding author:** Murouj Adnan Almaghrabi, MBBS, Doctor, College of Medicine, Umm Al-Qura University, Al-Abdia Main Campus, 8WCQ+4RM, Makkah 24382, Saudi Arabia. [murouj.a.a@gmail.com](mailto:murouj.a.a@gmail.com)

### Abstract

#### BACKGROUND

Montelukast or Singulair is a leukotriene receptor antagonist that reduces inflammation and relaxes the smooth muscles. It is known to be a safe and tolerable drug; nevertheless, it might be associated with several mild to severe adverse effects, one of which is dermatomyositis. Dermatomyositis is a rare acquired autoimmune myositis of unknown cause affecting adults and children. The literature has infrequently reported the association between dermatomyositis and montelukast use.

#### CASE SUMMARY

The current study reports a case of a 48-year-old black woman with a previous history of bronchial asthma and allergic rhinosinusitis who presented with typical signs and symptoms of dermatomyositis which were confirmed by investigations. Before developing dermatomyositis, the patient was prescribed montelukast for atopy and consumed the drug for five months. After administration of prednisolone, the patient had a significant improvement and is still being followed up.

#### CONCLUSION

Even though montelukast is widely used and believed to be a safe drug for managing several conditions, the present case report highlights the possibility of adverse effects of montelukast. Therefore, future studies with advanced study designs are highly recommended to investigate the association between dermatomyositis and montelukast use.

**Key Words:** Montelukast; Singulair; Adverse effects; Dermatomyositis; Asthma medication; Case report

©The Author(s) 2022. Published by Baishideng Publishing Group Inc. All rights reserved.

**Core Tip:** Even though montelukast is widely used and believed to be a safe drug for managing several conditions, the present case report brings to light the possibility of adverse effects of montelukast. Especially in such a rare and serious complication of montelukast, physicians must be aware of the presentation of dermatomyositis, the diagnostic modalities, and the best treatment options for the patients, as the prompt diagnosis will prevent further complications progression of the condition.

**Citation:** Aly MH, Alshehri AA, Mohammed A, Almaghrabi MA, Alharbi MM. Connection between dermatomyositis and montelukast sodium use: A case report. *World J Dermatol* 2022; 10(2): 10-16

**URL:** <https://www.wjgnet.com/2218-6190/full/v10/i2/10.htm>

**DOI:** <https://dx.doi.org/10.5314/wjd.v10.i2.10>

## INTRODUCTION

Dermatomyositis is a rare acquired autoimmune myositis with unknown etiology that affects adults and children. It is an inflammatory myopathy characterized by a striated muscle mononuclear inflammatory infiltrate. Genetic susceptibility is no longer in doubt since predisposing human leukocyte antigen systems have been identified. Complement activation results in the deposition of the membrane attack complex in the blood vessel wall that leads to microangiopathy and inflammatory response. Because some infectious organisms may play a role in self-tolerance and generation of the autoimmune response, the disorder appears to be seasonal[1]. In addition to infectious microorganisms, medications can be a trigger to initiate these responses[2]. Females are more affected than males. The overall age and gender-adjusted incidence of dermatomyositis, including all subtypes, was 9.63 per 1000000, peaking at ages 45-60 years in adults and ages 5-15 years in children[1].

Dermatomyositis is characterized by distinct skin changes and symmetric proximal skeletal muscle weakness. It can also affect other organ systems, such as the cardiovascular, pulmonary, and gastrointestinal systems. A significant proportion of patients with dermatomyositis have an underlying malignancy that affects the case's prognosis[1,2]. In addition to corticosteroids and immunosuppressive therapy, several European and American national guidelines for treating dermatomyositis recommend intravenous immunoglobulin as adjuvant therapy[3].

## CASE PRESENTATION

### Chief complaints

A 48-year-old black woman comes into our clinic complaining of an erythematous skin rash and proximal weakness.

### History of present illness

The patient's symptoms began three months before. The patient had an erythematous skin rash with scaling on the dorsum of her hands, a heliotrope rash around her eyelids, and bilateral facial hyperpigmentation. It was associated with proximal weakness in both the upper and lower limbs. In addition, the patient experienced intermittent fever, night sweats, and constipation. The rest of the constitutional symptoms were negative. There has been no recent travel history or contact with sick individuals.

### History of past illness

The patient had a history of hypertension, allergic rhinosinusitis, nasal polyp, wheezing, and bronchial asthma suggestive of atopy and had been prescribed montelukast sodium for five months. Budesonide/formoterol fumarate, tiotropium bromide, salbutamol sulfate, amlodipine besylate, and clopidogrel bisulfate are also on the patient medication list. She took those medications for a long time, and the only new addition was montelukast. Polypectomy was performed on the patient several years ago with no complications. Other medical and surgical history revealed no significant findings.

### Personal and family history

The patient had no relevant family history.



### **Physical examination**

A neurological examination revealed proximal weakness in both the upper and lower limbs, with a power grade of 2/5 in both. The investigation also revealed signs of inflammation, which were supported by laboratory results.

### **Laboratory examinations**

Laboratory findings indicated that leukocytosis was 14.99 (normal range  $4.00-11.00 \times 10^4/\mu\text{L}$ ), neutrophilia was 98.40% (normal range 37%-80%), eosinophilia was 17.2% (normal range 0.60%-7.30%), and erythrocyte sedimentation rate was found to be 22 mm/h (normal 0-12 mm/h). **Table 1** shows the detailed results of the hematological parameters. **Table 2** illustrates the various biochemical parameters, which revealed an elevated serum creatinine kinase (CK) level of 16180 U/L (normal range 20-180 U/L). The renal function test and liver function test were normal.

Jo-1 and dsDNA autoantibodies were negative, while anti-Mi-2 antibodies were positive. The nerve conduction study revealed myopathic changes, and the electromyography showed low activity with non-specific changes.

### **Imaging examinations**

The magnetic resonance imaging of the patient's muscles revealed bilateral asymmetrical (right > left) quadriceps muscle affection with active/acute inflammation features in the context of long-standing/chronic atrophic changes. Therefore, the advanced potential target for muscle biopsy is the right vastus medialis muscle (middle third), as shown in **Figure 1**. Furthermore, the patient was tested negative for malignancy workup (mammogram and pan computer tomography), antineutrophil cytoplasmic antibodies (ANCA), and coronavirus disease 2019.

---

## **FINAL DIAGNOSIS**

The patient was diagnosed with dermatomyositis based on the findings mentioned above. Nonetheless, muscle biopsy is the gold standard for diagnosing dermatomyositis, and the patient was scheduled for one, but unfortunately, she declined.

---

## **TREATMENT**

Montelukast was withdrawn, and the patient was administered 60 mg of prednisolone every day for 45 d.

---

## **OUTCOME AND FOLLOW-UP**

After two weeks of using prednisolone, the patient's muscle power improved significantly (grade 4/5 in both upper and lower limbs), and her CK level returned to normal. She is currently on a tapering dose of orally disintegrating tablet formulation of prednisolone. The dose was reduced by 10 mg every two weeks until it reached 20 mg. And she is still being followed up.

---

## **DISCUSSION**

Montelukast (Singulair) is a leukotriene receptor antagonist that inhibits the binding of leukotriene D4 to its receptor[4]. It was approved for medical use in 1998[5]. The pathophysiological influence reduces the inflammation process that contributes to asthma symptoms and relaxes the smooth muscles[6,7]. The medication is frequently used in the maintenance therapy of asthma but not in acute asthma attacks [4,6]. Other indications include prevention of exercise-induced bronchoconstriction and symptomatic relief of seasonal or perennial allergic rhinitis[7].

Montelukast is a safe and tolerable drug in adults, children, and pregnant women[4,5]. However, it may cause mild adverse effects, such as headache, fatigue, gastrointestinal disturbance, pharyngitis, upper respiratory tract infection, cough, and sore throat[6,8]. Furthermore, the serious adverse effects may include depression, hallucinations, suicidal ideation, insomnia, anxiety, changes in behavior, tremors, moderate acute hepatitis, and acute pancreatitis[8-11]. Shear and Litt[12] (2004) identified dermatological reactions associated with montelukast, with the most common adverse effect being an unspecified rash with or without blistering. In addition to skin ulcers, erythema nodosum, ecchymosis, urticaria, vasculitis, angioedema, and rarely, nodules.

**Table 1 Hematological parameters during diagnostic work-up of the patient**

Parameter	Result	Reference range (units)
Hemoglobin	13.8	12.0-15.0 (g/dL)
Red blood cells	4.89	4.20-5.40 ( $10^7/\mu\text{L}$ )
NRBC count	0.0	0.0-0.1 ( $10^9/\text{L}$ )
Platelet count	406	150-450 ( $10^4/\mu\text{L}$ )
Total leukocyte count	<b>14.99</b>	4.00-11.00 ( $10^4/\mu\text{L}$ )
Neutrophils	<b>98.40</b>	37.00-80.00 (%)
Lymphocytes	22.00	10.00-50.00 (%)
Monocytes	4.60	0.0-12.00 (%)
Eosinophils	<b>17.2</b>	0.60-7.30 (%)
Basophils	1.40	0.0-1.70 (%)
Erythrocyte sedimentation rate	<b>22</b>	0.0-12.0 (mm/h)

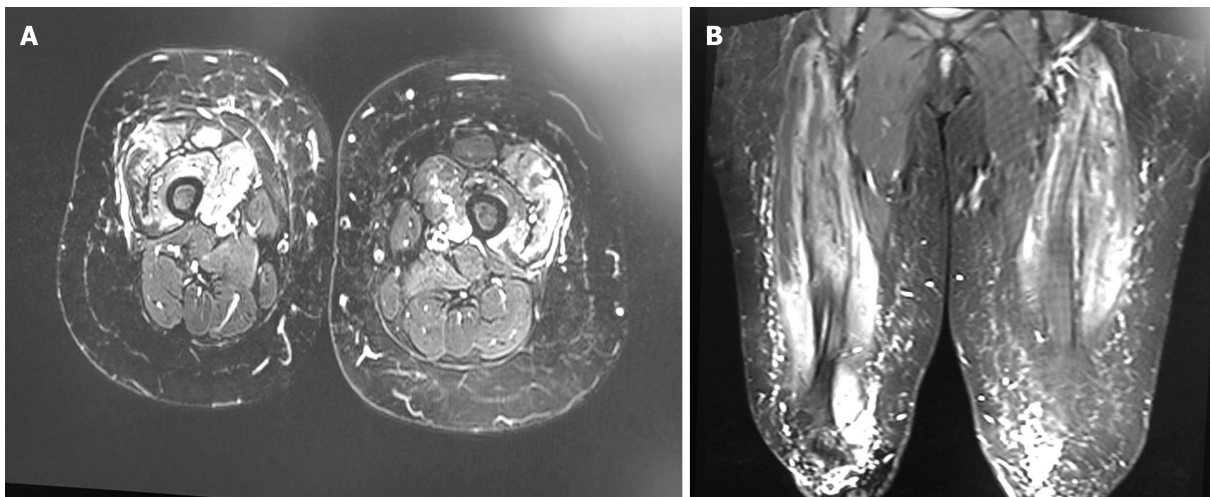
Bold face indicates the abnormal level of hematological parameter. NRBC: Nucleated red blood cell.

**Table 2 Biochemical parameters during diagnostic work-up of the patient**

Parameter	Result	Reference range (units)
Random blood sugar	139	70.2-140.5 (mg/dL)
Renal function test		
Urea	34	17.0-50.0 (mg/dL)
Creatinine	0.66	0.50-0.90 (mg/dL)
Sodium	139.3	136.0-145 (mmol/L)
Potassium	4.23	3.40-5.10 (mmol/L)
Magnesium	0.87	0.66-1.07 (mmol/L)
Liver function test		
Bilirubin, total	3.80	3.40-20.50 ( $\mu\text{mol/L}$ )
Bilirubin, conjugated	1.90	0.00-9.00 ( $\mu\text{mol/L}$ )
Alanine aminotransferase	10	5-55 (U/L)
Aspartate aminotransferase	12	5-34 (U/L)
Total protein	7.21	6.60-8.70 (g/dL)
Albumin	4.40	3.50-5.20 (g/dL)
Alkaline phosphatase	69	40-150 (U/L)
Lactate dehydrogenase	190	125-220 (U/L)
Creatinine kinase	<b>16.180</b>	20-180 (U/L)
Vitamin D (25-OH)	50	> 30.0-70.0 (ng/mL)
Calcium	9.74	8.40-10.20 (mg/dL)

Bold face indicates the abnormal level of hematological parameter.

Previous studies had evaluated the montelukast-induced ANCA-associated vasculitis, also known as Churg-Strauss syndrome (CSS), which has been widely reported in the literature and is a significant concern. CSS is an uncommon autoimmune disease that causes vasculitis in patients with asthma or allergic rhinitis[13,14]. Several studies have suggested the association between montelukast use and CSS development. A case-crossover previous survey illustrated that the drug was associated with a 4.5-fold



DOI: 10.5314/wjd.v10.i2.10 Copyright ©The Author(s) 2022.

**Figure 1** Magnetic resonance imaging scan T1 post-contrast. A: Axial image of the lower limbs revealed myopathic changes; B: Coronal image shows myopathic changes upon admission.

increased risk of CSS onset within three months[13]. However, a prior case series study in the United States on six asthmatic patients receiving montelukast demonstrates no association between montelukast and CSS development[14]. Furthermore, a recent study published by Pandey *et al*[13] in June 2021 reported that montelukast appeared to be a confounding factor not associated with the development of the syndrome. In contrast, steroid withdrawal is the primary factor contributing to CSS development.

In contrast to our patient, a recent clinical study was conducted by the United States Food and Drug Administration (FDA) and eHealthMe to analyze the side effects of montelukast based on the patient reports[15]. Phase IV of the clinical study concluded on August 16, 2021, that among 97983 patients who reported having side effects while taking montelukast, twenty patients (0.02%) had dermatomyositis. The study also found that the most common characteristics among those patients were female gender, age between 20-29 years, and use of the medication for 1 to 6 mo[15]. Therefore, an early diagnosis of dermatomyositis is critical to start treatment before conditional progression[1]. If dermatomyositis is not treated, it can progress to critical conditions affecting the heart, swallowing, and breathing, which can be fatal[1].

Although dermatomyositis was suspected in our patient, a confirmatory muscle biopsy was not performed, which is considered the gold standard to diagnose dermatomyositis. As a result, the patient improved significantly after discontinuing montelukast and receiving a short-term steroid, indicating that montelukast may play a role in this condition. This potential association was also proposed by the FDA and eHealthMe study[15].

Because montelukast was previously thought to be the leading cause of CSS, the present study raises concerns about the association between montelukast and dermatomyositis. Future studies with advanced study designs are strongly advised to investigate the possible link between dermatomyositis and montelukast use.

## CONCLUSION

Even though montelukast is thought to be a safe drug, the present case highlights the possibility of adverse effects of montelukast. Physicians must be aware of the presentation of dermatomyositis, the diagnostic modalities, and the best treatment options for the patients, especially in such a rare and severe montelukast complication. Future studies with advanced study designs are strongly recommended to investigate the potential link between dermatomyositis and montelukast use.

## ACKNOWLEDGEMENTS

The authors would like to acknowledge our superhero Dr. Almalki AM, College of Medicine, at Umm Al-Qura University, for the unlimited support and the incredible efforts he paid on this research project. Warmest congratulations on his graduation, and best wishes for him on the next adventure.

## FOOTNOTES

**Author contributions:** Aly MH, Alshehri AA and Mohammed A have reviewed the literature and contributed to manuscript drafting; Almaghrabi MA analyzed and interpreted the imaging findings and contributed to manuscript drafting; Alharbi MM was responsible for the revision of the manuscript for important intellectual content; all authors issued final approval for the version to be submitted.

**Informed consent statement:** The authors certify that they have obtained all appropriate patient consent forms. In the form, the patient has given consent for his images and other clinical information to be reported in the Journal. The patient understands that his names and initials will not be published, and due efforts will be made to conceal their identity, but anonymity cannot be guaranteed.

**Conflict-of-interest statement:** The authors declare that they have no conflict of interest.

**CARE Checklist (2016) statement:** The authors have read the CARE Checklist (2016), and the manuscript was prepared and revised according to the CARE Checklist (2016).

**Open-Access:** This article is an open-access article that was selected by an in-house editor and fully peer-reviewed by external reviewers. It is distributed in accordance with the Creative Commons Attribution NonCommercial (CC BY-NC 4.0) license, which permits others to distribute, remix, adapt, build upon this work non-commercially, and license their derivative works on different terms, provided the original work is properly cited and the use is non-commercial. See: <https://creativecommons.org/licenses/by-nc/4.0/>

**Country/Territory of origin:** Saudi Arabia

**ORCID number:** Murouj Adnan Almaghrabi 0000-0001-7357-9269.

**S-Editor:** Yan JP

**L-Editor:** A

**P-Editor:** Yan JP

## REFERENCES

- 1 **Gara S**, Jamil RT, Muse ME, Litaie N. Juvenile Dermatomyositis. In: StatPearls [Internet]. Treasure Island (FL): StatPearls Publishing; 2022 Jan 25 [PMID: 30480969]
- 2 **Shen C**, Che G. Dermatomyositis as an antecedent sign of lung cancer in an elderly patient: a case report. *J Thorac Dis* 2014; **6**: E15-E18 [PMID: 24605239 DOI: 10.3978/j.issn.2072-1439.2014.01.21]
- 3 **Aggarwal R**, Charles-Schoeman C, Schessl J, Dimachkie MM, Beckmann I, Levine T. Prospective, double-blind, randomized, placebo-controlled phase III study evaluating efficacy and safety of octagam 10% in patients with dermatomyositis ("ProDERM Study"). *Medicine (Baltimore)* 2021; **100**: e23677 [PMID: 33429735 DOI: 10.1097/MD.00000000000023677]
- 4 **Amirav I**. Real-life effectiveness of Singulair (montelukast) in 506 children with mild to moderate asthma. *Isr Med Assoc J* 2008; **10**: 287-291 [PMID: 18548983 DOI: 10.3410/f.1115379.571403]
- 5 **Sarkar M**, Koren G, Kalra S, Ying A, Smorlesi C, De Santis M, Diav-Citrin O, Avgil M, Lavigne SV, Berkovich M, Einarson A. Montelukast use during pregnancy: a multicentre, prospective, comparative study of infant outcomes. *Eur J Clin Pharmacol* 2009; **65**: 1259-1264 [PMID: 19707749 DOI: 10.1007/s00228-009-0713-9]
- 6 **Meltzer EO**, Lockey RF, Friedman BF, Kalberg C, Goode-Sellers S, Srebro S, Edwards L, Rickard K; Fluticasone Propionate Clinical Research Study Group. Efficacy and safety of low-dose fluticasone propionate compared with montelukast for maintenance treatment of persistent asthma. *Mayo Clin Proc* 2002; **77**: 437-445 [PMID: 12004993 DOI: 10.4065/77.5.437]
- 7 **Nayak A**, Langdon RB. Montelukast in the treatment of allergic rhinitis: an evidence-based review. *Drugs* 2007; **67**: 887-901 [PMID: 17428106 DOI: 10.2165/00003495-200767060-00005]
- 8 **Aypak C**, Türedi Ö, Solmaz N, Yıkılkan H, Görpelioglu S. A rare adverse effect of montelukast treatment: ecchymosis. *Respir Care* 2013; **58**: e104-e106 [PMID: 23322887 DOI: 10.4187/respcare.02298]
- 9 **Romero-Gómez M**, Sánchez-Muñoz D, Castilla L, Castro M. [Acute hepatitis due to montelukast]. *Med Clin (Barc)* 2003; **120**: 239 [PMID: 12605820 DOI: 10.1016/s0025-7753(03)73664-1]
- 10 **GOV**. UK. Montelukast (Singulair): reminder of the risk of neuropsychiatric reactions. Sep 19, 2019. [cited 5 March 2022]. Available from: <https://www.gov.uk/drug-safety-update/montelukast-singulair-reminder-of-the-risk-of-neuropsychiatric-reactions>
- 11 **Das S**, Mondal S, Dey JK, Bandyopadhyay S, Saha I, Tripathi SK. A case of montelukast induced hypercholesterolemia, severe hypertriglyceridemia and pancreatitis. *J Young Pharm* 2013; **5**: 64-66 [PMID: 24023457 DOI: 10.1016/j.jyp.2013.06.002]
- 12 **Shear N**, Litt JZ. *Litt's drug eruption reference manual including drug interactions*. 10th ed. London: CRC Press, 2004
- 13 **Pandey L**, Sawale G, Punmiya A. Research article a review on toxicological study of montelukast. *Int J Recent Adv Multidiscip Res* 2021; **8**: 6975-6982
- 14 **Wechsler ME**, Finn D, Gunawardena D, Westlake R, Barker A, Haranath SP, Pauwels RA, Kips JC, Drazen JM. Churg-

Strauss syndrome in patients receiving montelukast as treatment for asthma. *Chest* 2000; **117**: 708-713 [PMID: [10712995](#)  
DOI: [10.1378/chest.117.3.708](#)]

- 15 **eHealthMe**. Singulair and Dermatomyositis - a phase IV clinical study of FDA data. [cited 5 March 2022]. Available from: <https://www.ehealthme.com/ds/singulair/dermatomyositis/>





Published by **Baishideng Publishing Group Inc**  
7041 Koll Center Parkway, Suite 160, Pleasanton, CA 94566, USA  
**Telephone:** +1-925-3991568  
**E-mail:** [bpgoffice@wjgnet.com](mailto:bpgoffice@wjgnet.com)  
**Help Desk:** <https://www.f6publishing.com/helpdesk>  
<https://www.wjgnet.com>

